

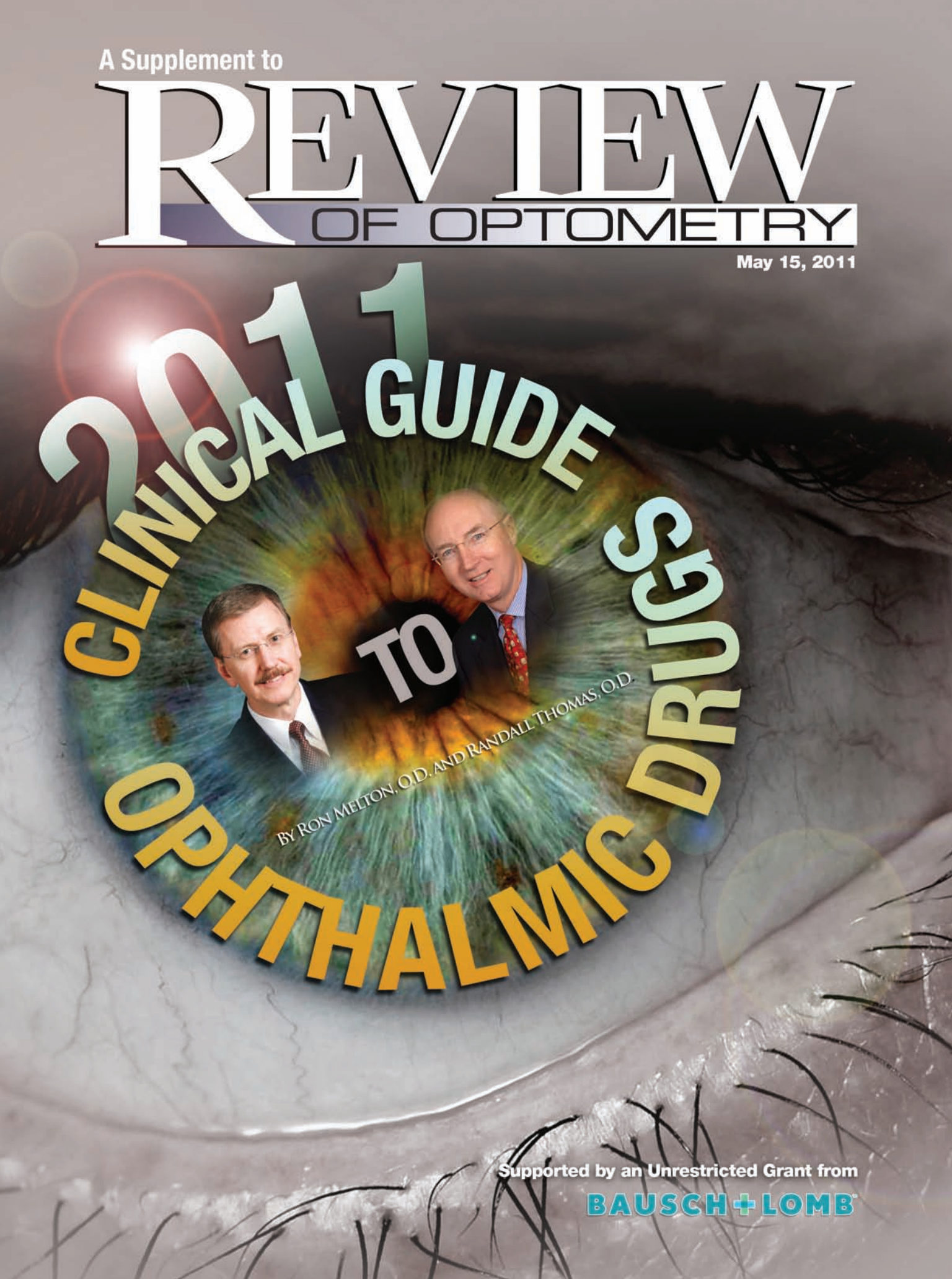
A Supplement to

# REVIEW

OF OPTOMETRY

May 15, 2011

# 2011 CLINICAL GUIDE TO OPHTHALMIC DRUGS



BY RON MELTON, O.D. AND RANDALL THOMAS, O.D.

Supported by an Unrestricted Grant from

**BAUSCH + LOMB**

# CURRENT THERAPY IN OCULAR DISEASE

by Drs. Ron Melton and Randall Thomas

Past recipients of the "Glaucoma Educator of the Year" Award  
by the American Academy of Optometry

Authors of Review of Optometry's annual Clinical Guide to Ophthalmic Drugs

## CONTINUING EDUCATION

### OUR COURSES ON YOUR COMPUTER!

OptSpace.com

A team of California optometrists/educators has developed a website, [OptSpace.com](http://OptSpace.com), to provide optometrists and their staff educational enrichment in the area of medical diagnosis and treatment, and other areas of interest to optometry. OptSpace has partnered with us for several video presentations that can be viewed from any computer or electronic media of your choice. This is a new way of accessing Melton and Thomas' lectures. Currently our emphasis is on glaucoma care, with additional topics available in the near future. Our series of lectures will be presented exclusively through the genius of OptSpace. We invite you to visit [www.OptSpace.com](http://www.OptSpace.com) for more details.

### COME TO CHINA WITH US!

**JUNE 12 - 23, 2012**

Bridgitte Shen Lee, O.D., a bilingual and bicultural Chinese-American optometrist, created iTravelCE LLC and put together a truly first-class (and beyond!) enlightening



journey into China for COPE-approved optometric CE. She will serve as both course director and tour guide. For the educational component of this exotic voyage, we will provide our comprehensive, 20-hour "Current Therapy in Ocular Disease" course.

The itinerary includes:

- Beijing, the imperial and modern capital city, rebuilt by Kublai Khan in 1215 and host of the 2008 Olympics
- Xi'an, the cradle of Chinese civilization, the

seat of the Emperor for more than 10 dynasties and the start of the Silk Road

- Yangtze River, cruise along the longest, most majestic waterway in Asia.

We invite you to join us for a trip of a lifetime!

For more details, visit [www.iTravelCE.com](http://www.iTravelCE.com), e-mail [info@iTravelCE.com](mailto:info@iTravelCE.com), or call 832-390-1393.

Visit our website: [www.eyupdate.com](http://www.eyupdate.com)

## A Brief Overview of the Past Twelve Months

Welcome to the 2011 *Clinical Guide to Ophthalmic Drugs!*

This year, we are attempting to answer many of the questions we have received during our lectures over this past year. We have collected well over 100 questions, and we are sharing our responses to as many of them as space allows. We encourage you to read this question-and-answer dialogue, as it contains many clinically practical pearls that we trust you will value

There have been two significant additions to the therapeutic landscape during the past year: Zirgan and generic latanoprost.

But there are also numerous “new and improved” remakes and enhanced formulations of medicines already in the marketplace:

- an increased concentration of gatifloxacin (Zymaxid, which is a 0.5% formulation)
- a decreased concentration of bimatoprost (Lumigan 0.01%)
- a decreased concentration of dexamethasone combined with tobramycin (TobraDex ST)
- another topical antihistamine for once-daily use (Lastacaft)
- a reformulation of moxifloxacin (Moxeza)
- a newer, lipid-based artificial tear (Systane Balance)
- the first once-daily topical NSAID, bromfenac (Bromday)
- loteprednol ophthalmic ointment (Lotemax ointment)

So, you can see the waters have been stirred! We will try to put these changes, and other relevant topics, into a clinically practical perspective for you. It must be absolutely stressed that everything written in this guide is explicitly aimed at enhancing the lives of the patients we all serve. We can never lose sight of why we exist and what our mission is.

With all best wishes to our esteemed colleagues,



Ron Melton, O.D.



Randall Thomas, O.D., M.P.H.

Supported by an unrestricted grant from

**BAUSCH + LOMB**

## CONTENTS

---

**Glaucoma ..... 2A**

**Beneath the Surface of Dry Eye Disease ..... 12A**

**Corticosteroids ..... 18A**

**Topical Antibiotics ..... 22A**

**Antiviral Strategies ..... 26A**

**Combination Drugs ..... 29A**

**Clinical Update on the NSAIDs ..... 32A**

**Keeping Allergy Management Simple ..... 34A**

**Overview of Oral Medicines ..... 36A**

**Questions & Answers From the Trenches ..... 40A**

Note: The clinical views and advice expressed in this publication are those of the authors, and do not necessarily reflect those of the sponsor, Bausch + Lomb, or the publisher, *Review of Optometry*.

# Glaucoma

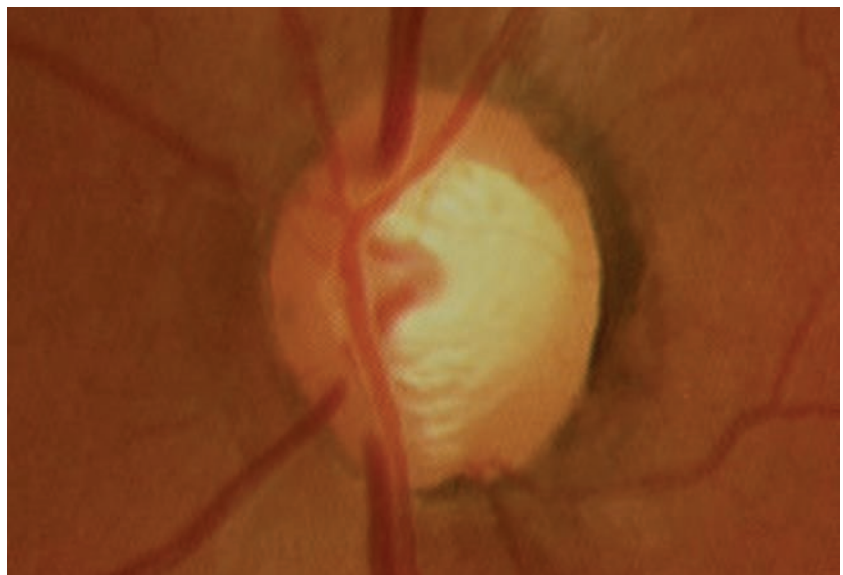New drugs may come and old drugs may go, but the essential question remains: At what point does the patient “convert” to glaucoma?

**A**fter 15 years of basking in the warm sun, the curtain has fallen on the most successful glaucoma drug in the history of the world. Generic latanoprost should radically re-script glaucoma care from a financial perspective. This same fate will soon occur for Lipitor. We think, and hope, this will bring financial relief to the masses. Like all of you, we are watching from the bleachers to see how this radical transformation will play out. (See “*Latanoprost Goes Generic*,” page 3A.)

There are other glaucoma medicines in research and development, and we anticipate newer and better therapies in the coming years.

But don't forget that a once-daily beta-blocker is an excellent second-line drug for monotherapy, or as additive therapy to a prostaglandin. All others must be used twice daily and preferably three times a day—but it is rare that patients can perform these complex instillations with any significant degree of consistency.

**Q:** When new patients present to our office on multiple glaucoma meds, we want to experiment with which meds are optimally effective. How long does it usually take for a medicine's effect to stop after



**At what point, clinically, do you begin to inform patients that you are following them as a “glaucoma suspect”? This is an optic nerve that has converted to glaucoma. Note the inferior erosion of the neuroretinal rim.**

discontinuing it?

**A:** Studies have shown that the effects of prostaglandins last longer than the other classes. In our practices, we wait a month to recheck the intraocular pressure after stopping a prostaglandin. We generally assess the effect of such “reverse therapeutic trials” in two to three weeks for the shorter duration-of-action drugs such as the alpha adrenergic agonists, the beta blockers, and the topical carbonic anhydrase inhibitors.

**Q:** Would you use a prostaglandin to manage increased intraocular pressure in a steroid responder?

**A:** Probably not. Most iatrogenic intraocular pressure increases quickly vanish upon the discontinuation of the offending corticosteroid, so additional medical therapy is usually unwarranted.

If the IOP was high enough to warrant therapeutic intervention (perhaps over 35mm Hg to 40mm Hg), then we would select a more rapid onset medicine such as a beta

blocker or brimonidine. Prostaglandins are relatively slow in their onset of action, and so are rarely a class of choice when rapid IOP reduction is desired.

**Q: Do you recommend occluding the nasolacrimal ducts to prevent systemic effects from glaucoma medicines?**

**A:** As a general rule, glaucoma medicines are very well tolerated, and therefore there is not a need to undertake unnecessary medication-modifying procedures.

However, if the medicine was truly needed for glaucoma care, and the patient had a rare side effect (such as taste perversion, a cough, slight shortness of breath, bradycardia, etc.), then punctal occlusion may be wise.

However, we would try switching to another class of drug first, if possible. In caring for many hundreds of patients with glaucoma, we have never found the need to punctally occlude.

**Q: If a visual field is abnormal, and repeat testing is normal, do you retest? Or is one normal visual field all you need?**

**A:** Clinically significant visual field defects are largely predictable, and not like a box of chocolates.

Generally speaking, if the visual field is normal, consider it to be so. If the visual field is defective and the catch trials (fixation losses, etc.) are reasonably normal, and if the optic nerve neuroretinal rim tissues are intact, then we would not believe this defective field to be a reflection of reality, and therefore would repeat the field in a few weeks (or even a few months).

However, if there are defects that correspond to alterations in the optic nerve head anatomy (such as polar erosion), then we would believe that the defect is true, and

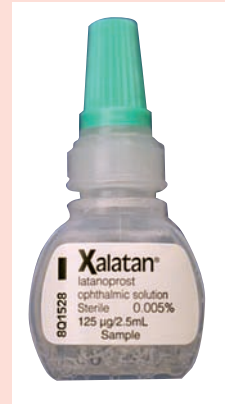## Latanoprost Goes Generic

The biggest news in glaucoma in 2011 is that Xalatan lost its patent protection March 28. This means we now have generic latanoprost. While this is bad news for the drug manufacturers, it is good news for glaucoma patients. A basic understanding of market dynamics explains why Travatan Z and Lumigan have also reduced their costs (either directly or through rebate programs, etc.) to be competitive with generic latanoprost. Generally speaking, and when prudent to do so, we prefer to prescribe quality brand-name products as opposed to generics of unknown quality. For this reason, we plan to prescribe Travatan Z or Lumigan 0.01% as long as the price points are similar to the generic latanoprost.

We encourage you to call around to your local pharmacies to ascertain the cost of these medications. You will be amazed at the differences. At press time, our survey of local pharmacies revealed great disparity among prostaglandin prices (anywhere from \$25 to \$85). Overall, it seems that \$38 is generally the going price. This brings great relief to the cost-burden of glaucoma therapy.

Also note that the prostaglandins exert a therapeutic effect well beyond 24 hours. For a few of our indigent patients with non-severe glaucoma, we have reduced dosing to Monday, Wednesday and Friday.

Now let's think about this rationally and apply some common sense: The goal in glaucoma management is to achieve and maintain an intraocular pressure within the target range deemed to be "safe" for each patient individually. With that in mind, medication management becomes very elementary: We simply check the IOP at one month and at two months after dosage-reduction to see if the IOP remains the same as it did with once-daily dosing. If that is the case, then we have achieved our IOP goal, and helped the patient from not only a health standpoint, but a financial one as well. We simply need to be thinking, compassionate and attentive doctors.



would repeat the field every six to 12 months to continue to monitor for stability or progression.

If the next field shows "progression," such as "progression" MUST be confirmed by repeat testing (again, in weeks to months based on the overall status of the patient's condition). It is well established that the vast majority of "progression" is artifactual, and disappears upon repeat testing!

**Q: When you see a family member of a glaucoma suspect patient, do you perform a full dilated comprehensive eye exam? Do you charge them, or is just a quick look with the indirect ophthalmoscope sufficient?**

**A:** If it has been over a year since the patient has seen an eye doctor,

we provide a standard dilated eye examination.

If there is a history of glaucoma suspicion in the family, then we would likely obtain pachymetry in addition to our always thorough study of the optic nerves via biomicroscopic-enabled (90D, etc.) ophthalmoscopy.

If the optic nerve(s) appear compromised in their structure, we would then consider accomplishing nerve fiber layer assessment, and if this were to be suspicious, then we would likely obtain a visual field assessment.

Notice that all subsequent testing is driven by the sequential findings during the course of the eye examination. We do not do tests that are unwarranted, and we always obtain exam elements that are rational,

# Glaucoma

prudent, and medically substantiated. Appropriate charges are assessed for indicated professional services and diagnostic testing. Some of these may be accomplished at the initial visit; others may be done days or weeks later, depending on assessed risk, the disease stage, the patient's desires, insurance coverage, etc.

**Q:** How do you code a claim for a family member's glaucoma examination when the results are normal?

**A:** How does an orthopedic surgeon code for a radiographic study if it is normal? The answer:

We charge a professional fee when whatever service or procedure performed is medically prudent. One could code "glaucoma suspect" if, in one's sound clinical judgment, there is rational justification to conduct such an examination along with any rational ancillary testing needed to facilitate accurate decision making.

**Q:** At what intraocular pressure would you treat the patient on the same day as the exam?

**A:** Probably 40mm Hg or greater, and even at lower IOP if there were substantial optic nerve compromise.

**Q:** At a recent glaucoma lecture, the specialist stated that nerve fiber analysis was pushing back glaucoma diagnosis by 10 years; that is, initiating treatment for patients in their 50s rather than their 60s. Bottom line: With no visual field defect, would you treat based on nerve fiber layer analysis, given the potential for long-term consequences of using glaucoma medicines?

**A:** First, glaucoma medicines are generally very well tolerated, even in patients who have ocular surface disease, so that concern is a minimal player in decision making. The larger question is actually much bigger than structural vs. functional

## Topical Glaucoma Drugs

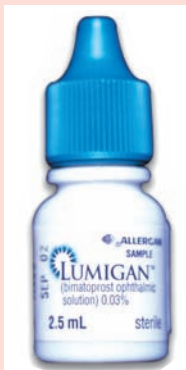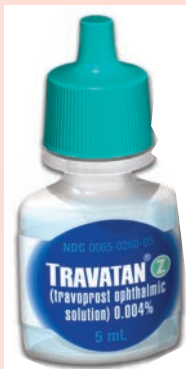BRAND NAME	GENERIC NAME	MANUFACTURER	CONCENTRATION	BOTTLE SIZE
<b>Beta Blockers</b>				
Betagan, and generic	levobunolol hydrochloride	Allergan, and generic	0.25% 0.5%	5ml, 10ml 5ml, 10ml, 15ml
Betimol	timolol hemihydrate	Vistakon Pharm.	0.25% 0.5%	5ml 5ml, 10ml, 15ml
Betoptic-S	betaxolol hydrochloride	Alcon	0.25%	5ml, 10ml, 15ml
Istalol	timolol maleate	Ista	0.5%	5ml
Timoptic, and generic	timolol maleate	Aton Pharma, and generic	0.25% 0.5%	5ml, 10ml, 15ml 5ml, 10ml, 15ml
Timoptic (preservative-free)	timolol maleate	Aton Pharma	0.25% 0.5%	unit-dose unit-dose
Timoptic-XE, and generic	timolol maleate	Aton Pharma, and generic	0.25% 0.5%	2.5ml, 5ml 2.5ml, 5ml
<b>Prostaglandin Analogs</b>				
Lumigan	bimatoprost	Allergan	0.01%, 0.03%	2.5ml, 5ml, 7.5ml
Travatan Z	travoprost	Alcon	0.004%	2.5ml, 5ml
Xalatan, and generic	latanoprost	Pfizer, and generic	0.005%	2.5ml
<b>Alpha Agonists</b>				
Alphagan P, and generic	brimonidine brimonidine	Allergan, generic	0.1%, 0.15%, 0.2%	5ml, 10ml, 15ml 5ml, 10ml, 15ml
<b>Carbonic Anhydrase Inhibitors</b>				
Azopt	brinzolamide	Alcon	1%	5ml, 10ml, 15ml
Trusopt, and generic	dorzolamide	Merck	2%	5ml, 10ml
<b>Combination Glaucoma Medications</b>				
Combigan	brimonidine/timolol	Allergan	0.2%/0.5%	5ml, 10ml
Cosopt	dorzolamide/timolol	Merck	2%/0.5%	5ml, 10ml

## Select Appropriate Therapy

Let's assume we have decided a patient merits IOP reduction, so what drug do we select?

- **Prostaglandins.** Most of the time, the answer is a prostaglandin, preferably one of the lower-concentration formulations (having less side effect potential) such as latanoprost 0.005% or travoprost 0.004%—and now bimatoprost 0.01%. All of the prostaglandins lower IOP nearly identically, so prescribing decisions are based on side effect profile and affordability for most patients.<sup>1</sup>

The time of instillation should center around when the patient finds it to be the most convenient. Remember, compliance is the weak link in the treatment chain, so we need to do whatever we can to make adherence most



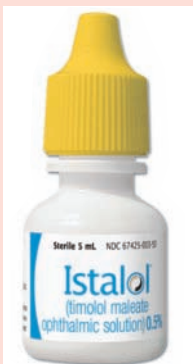for our black patients, and 0.25% for white patients. Furthermore, numerous studies clearly support the use of these two non-selective beta blockers once daily. It is best to have patients instill beta blockers shortly upon awakening for maximum therapeutic effect. Understand that these drugs suppress beta adrenergic tone. Our adrenergic system is active while we are awake, and physiologically asleep while we are asleep. There is little benefit in attempting to pharmacologically suppress a system that is already physiologically suppressed. This is why it is important to dose beta blockers shortly upon awakening.

The vast majority of our glaucoma patients are successfully managed with either a prostaglandin, or a beta blocker, or a combination of the two. This is relatively inexpensive, and requires a drop either

achievable for each patient.

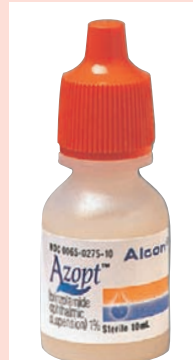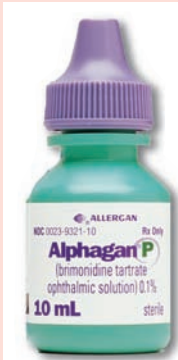- **Beta blockers.** Alternatively, if cost is an overriding factor (and cost can compromise compliance), initiate therapy with a non-selective beta blocker such as timolol or levobunolol. They are available in 0.25% and 0.5% concentrations, and are readily available for about \$4 per 5ml at many pharmacies.

Since melanin pigments can bind some medicines, we use the 0.5% concentrations



once daily, or if using both, b.i.d.

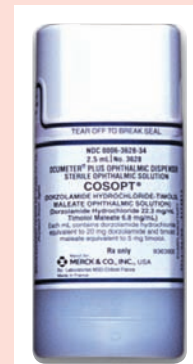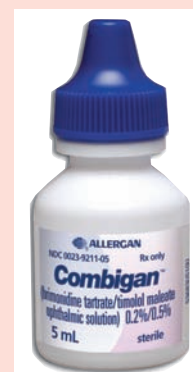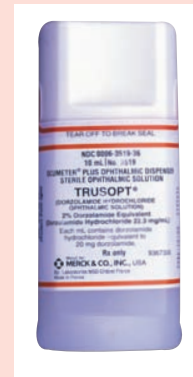- **Carbonic anhydrase inhibitors and alpha adrenergic agonists.** If there is a need to move beyond a prostaglandin and/or a non-selective beta blocker, then do a therapeutic trial of either brimonidine or a topical CAI—brinzolamide or dorzolamide. Both of these drugs are FDA-approved for t.i.d. therapy, and when used as monotherapy, will best serve the patient as one drop every eight hours. The problem is that there is an inverse relationship between dos-



ing frequency and compliance. In recognition of this reality, these drugs are generally prescribed b.i.d. (approximately every 12 hours).

The CAIs are known by their brand names: Trusopt (dorzolamide, Merck; and generic) and Azopt (brinzolamide, Alcon). Since brimonidine seems to be slightly more effective than a topical CAI, we generally try it as our "Plan B" of choice.

- **Combinations.** What about the "combination" drugs, such as 0.5% timolol with 0.2% dorzolamide (Cosopt [Merck], which has been generic since October 2008) or 0.5% timolol with 0.2% brimonidine (Combigan [Allergan], an expensive combination of two relatively inexpensive generic products)? We know that timolol is only needed once daily, and we know that brimonidine and the CAIs are most effective at their FDA-approved labeling of t.i.d. We suggest trying timolol alone, and to only "add" dorzolamide or brimonidine if truly needed to achieve target IOP. These are rare occasions.



1. Parrish RK, Palmberg P, Sheu WP; XLT Study Group. A comparison of latanoprost, bimatoprost, and travoprost in patients with elevated intraocular pressure: a 12-week, randomized, masked-evaluator multicenter study.

concerns, which is the essence of this question. The decision is just not so dichotomous!

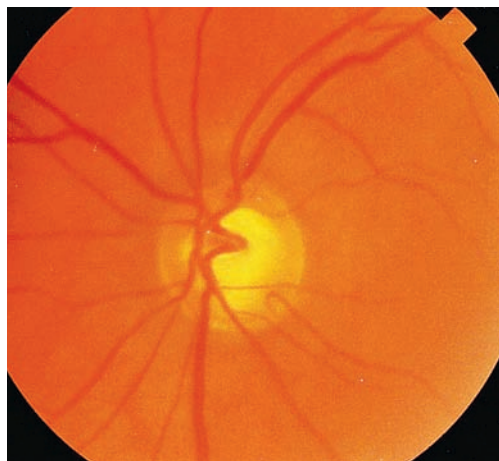
For background, we are currently treating hundreds of patients with glaucoma medicines who do not have glaucoma! We obsessively-compulsively assess each of our patients; for those whom we feel are at considerable risk to develop glaucoma, we intervene therapeutically in what we believe will prevent the development of glaucoma. Examples of such patients are younger people with very high intraocular pressures; very thin corneas (physiologically, not via keratorefractive surgery); compromised optic nerve head tissues (based on either stereoscopic ophthalmoscopy or a nerve fiber layer scanning device or both, without visual field defects); a very strong family history; or a combination of the above. These decisions are complex and require the assimilation of a constellation of parameters.

Lastly, note that doctors of equal competence legitimately differ on the decisions of treating vs. attentive monitoring. The soundness of whichever decision is made usually becomes clear over the ensuing five to 10 years. A patient is rarely a “glaucoma suspect” beyond five to eight years, because during this time span it should become clear whether they have progressive disease or just benign risk factors.

**Q: Are topical nonselective beta blockers an absolute or a relative contraindication in patients having reactive airway disease and/or chronic obstructive pulmonary disease (COPD)?**

**A:** Only recently has it become clear to us that the correct answer is “relative.” There are patients who have lesser expressed asthma

that can indeed safely use a topical nonselective beta blocker. We have, in fact, had the occasion to do such, but only after consultation with the patient’s primary care or pulmonary physician. It has recently been demonstrated that systemic beta blockers are in fact therapeutic in the setting of COPD for many such patients. So, if you have a need to use a beta blocker in a patient with what you might think are systemic contraindications, consult the patient’s physician—it may well be that your therapeutic need can be successfully met.



**When does the diagnosis change from ocular hypertension to glaucoma?**

**Q: When does the diagnosis change from ocular hypertension to glaucoma? Does the diagnostic definition of glaucoma require a visual field defect?**

**A:** This question is ubiquitous and haunts most glaucoma clinicians. Glaucoma is not like a light switch; either present or absent, but rather like a light controlled by a rheostat. As you begin to reduce the energy flow to the light, the light begins to become less bright—but when would the average person say the luminance goes from “bright” to “dim”? There is a zone or range in which this declaration is made.

Glaucoma is very similar. With the limits of our current technology, it could well be reasonable to proclaim a repeatable visual field defect as the “Holy Grail” of glaucoma confirmation. However, we have patients with 0.8 cups with no visual field defects, and we confidently tell them that they have glaucoma (based on progressive cupping, thin corneas, and/or high IOPs). So, in one sense, the question may be more academic and philosophical than clinical and firm.

**Q: A very similar question: At what point, clinically, do you begin to inform patients that you are following them as a “glaucoma suspect”?**

**A:** It depends. If there is a family history of glaucoma, a borderline IOP (around 18mm Hg to 26mm Hg), a 0.4 to 0.6 cup, a corneal thickness below 510 $\mu$ m, then such patients might be considered “suspicious.” But, these various parameters cannot be viewed in a vacuum! The entire clinical picture must be considered collectively. Only then can “risk” be rationally assessed.

**Q: When would you discontinue glaucoma therapy started by another clinician?**

**A:** If, in your clinical opinion, and after a thorough examination, you feel the patient may not merit therapy, then a thoughtful “reverse therapeutic trial” is very reasonable. We would have a long conversation with the patient explaining how good doctors commonly have different approaches to the same condition, and that at the least you would like to know the patient’s true baseline intraocular pressure. This is something we do commonly, especially if the patient has no positive family history of glaucoma,



has a thick cornea (greater than 580 $\mu$ m—our subjective cutoff), and/or has healthy-appearing optic nerve heads. We also get a Consent for Release of Records from the patient so that we can have the benefit of the prior doctor's observations and thoughts.

**Q: Do you obtain pachymetry on all of your low-normal tension patients, just to see if the cornea is thin?**

**A:** By "low-normal tension pa-

tients," we assume you mean those who have a 0.4 to 0.5 or greater cup. If the cup is small and the pressure is normal, this is almost always a plain ol' normal patient. But, if the optic nerve head is suspicious in appearance, there is a 100% chance we will assess the corneal thickness!

**Q: For patients who work second or third shift, how do you recommend dosing schedules for prostaglandins and beta blockers?**

**A:** Beta blockers are best instilled

shortly upon awakening, regardless of the actual time of the day. Prostaglandin efficacy is, by and large, time of instillation-independent. While slightly more effective when taken toward the end of a waking period, actual time of instillation is not a major issue with the prostaglandins. So, regardless of the time of the patient's sleep cycle, it is always best to instill beta blockers shortly upon awakening. While it is best to instill the prostaglandins just prior to retiring, time of dosing is

## Key Points to Ponder in Glaucoma Management

- **Visual field test results are extremely variable, and it may take three to five tests over a two to four-year period of time to truly know the extent (if any) and/or rate of progression of a visual field defect.** The exception to this is if there is a strong clinical correlation. For example, if there is observable inferior erosion of the optic nerve rim, and there is a dense superior field defect, then such a defect can be viewed with certainty, and probably annual retesting is all that is indicated.

The much more common finding, however, is a generalized scattering of scotomas, or a nonspecific clustering that does not correlate with the optic nerve anatomy or a nerve fiber analyzer scan. It is these vague, non-clinically-correlatable visual field defects that must be verified by repeat testing, perhaps three to five times, in order to know with certainty whether the defect(s) is a true reflection of optic nerve damage or simply artifactual noise. A classic mistake is to observe what appears to be a change in the visual field and make management decisions based upon "apparent" demise of the visual field. This is almost always an error in clinical judgment and management.

In summary, if the field is normal, believe it to be normal; if it is borderline or questionable, then repeat the testing.

- **It is by and large a myth that short wavelength (blue-on-yellow) or frequency doubling perimetry detects glaucoma earlier than standard (white-on-white) automated perimetry.** Furthermore, it truly may not be in the patient's best interest to be diagnosed "too early" in the setting of early glaucoma. Recent results from the Ocular Hypertension Treatment Study follow-up showed that delaying IOP reduction for a few years did not result in any loss of ultimate control. On average, glaucoma progresses at about 3% per year. With the excellent medicines available to us, we can intervene therapeutically in a thoughtful, timely manner to gain good control of the intraocular pressure once the need for control is clearly indicated.

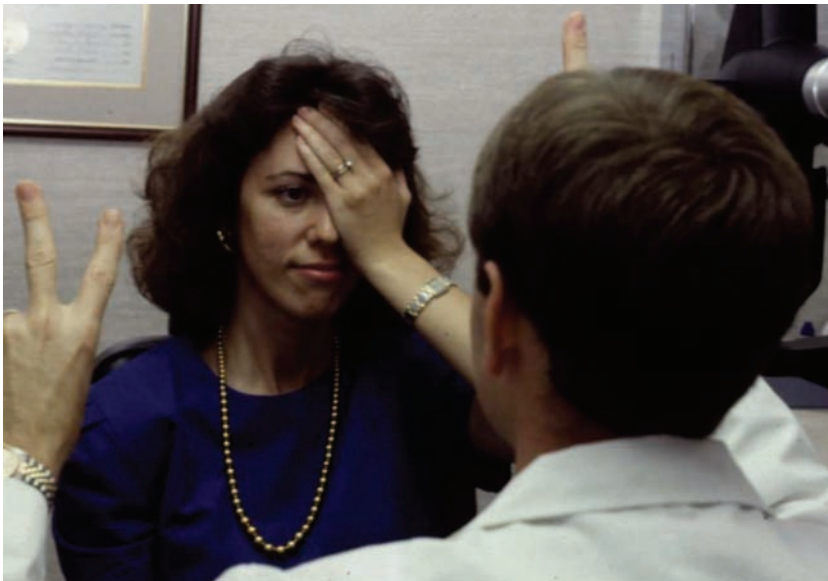It is well established that there is some diminution in quality of life when a person is diagnosed with glaucoma, as at that point their lifestyle is encumbered with medication habituation behavior, as well as cost concerns, and perhaps the ultimate concern of going blind. Note that we, like you, are attentive physicians, and we carefully monitor our patients. If there are any consistent signs of accelerated progression, we would institute therapy. Yet we have learned over the past 30 years to not be trigger-happy, but rather to be very thoughtful in our management decisions. Standard white-on-white perimetry can facilitate diagnosis, as well as provide guidance regarding progression.

- **Always initiate therapy with a lesser concentration of medication if available.** Remember, in therapeutic intervention, we have a target IOP range in our heads, and our goal should be to achieve an IOP within this range with the least medical intervention possible.

Unfortunately, we have few lower-concentration options in glaucoma therapy: 0.25% timolol (or levobunolol), bimatoprost 0.01% and pilocarpine 1%. Being faithful to this concept, our routine dilating drop only contains 0.25% tropicamide (Paremyd also contains 1% hydroxyamphetamine hydrobromide). Thankfully, we now have the lesser concentration of bimatoprost (0.01%) and the concentration of BAK has been increased from 0.005% to 0.02% (the same as is in latanoprost).

A couple of unsubstantiated thoughts come to mind: Because BAK enhances drug penetration, it may be that this higher concentration of preservative is what enables the 0.01% bimatoprost to provide the same reduction in IOP as the 0.03%, and that it is not the BAK potentially causing side effects, but rather the active drug itself. The manufacturer claims a significant reduction in side effects with the 0.01% rendition of the bimatoprost. So keep in mind that "less is better," as long as the target IOP goal is achieved and maintained.

*(continued on page 9A)*



**Confrontational visual field testing as a screening tool is standard-of-care, but is this test really adequate?**

not a major issue with the prostaglandins.

**Q: What is your opinion on confrontational visual field testing as a screening tool in the context of comprehensive eye examination? This is standard-of-care, but is this test really adequate?**

**A:** The world's premier authority in neuro-ophthalmology is Neil Miller, M.D., at the Wilmer Eye Institute at Johns Hopkins. He stated that 90% of all clinically significant neurologically-related visual field defects can be detected by confrontation examination. He recommended that this assessment be done as counting-fingers in each quadrant, not bringing in a target from non-seeing areas into seeing areas. We have followed Dr. Miller's guidance since the early 1980s, and have found his observations to be spot-on.

**Q: Why isn't thyroid function part of the glaucoma workup? I have seen three patients, and heard of more, with high IOP that normalized after their thyroid dys-**

**function was treated. I realize it's a multifactorial disease, but let's rule out the easy options.**

**A:** Thoughtful question. One would think that thyroid disorders could have an impact on aqueous production and/or outflow. In all of our exhaustive reading of the world literature, we have never read of any such association with thyroid dysfunction. We can't explain your anecdotal observations, and, as you rightfully point out, glaucoma is a multifactorial disease, so perhaps other factors are at play that are not yet fully elucidated.

**Q: Since it is known that some low tension glaucoma patients may be compromised by nocturnal systemic hypotension, should these patients have a sleep study?**

**A:** Perhaps. This is an area of ongoing research, and in select patients, knowing their diastolic nocturnal blood pressure profile could potentially be very helpful. Along this same line of thought is the consideration of the patient's medical treatment for systemic hypertension, if they carry that

diagnosis. It is well established that a subset of the population has quite marked nocturnal hypotensive episodes. This could cause a pathologically low perfusion pressure to the optic nerve (and brain) during the sleep cycle.

For this reason, patients with true low tension glaucoma (and especially patients who have had nonarteritic anterior ischemic optic neuropathy in one eye) should perhaps only take their blood pressure medicine near breakfast time and never at bedtime, where this "piling on" effect could play a key role in optic nerve tissue demise. A conversation with the patient's prescribing physician certainly should be accomplished.

**Q: Since breath-holding can increase episcleral venous pressure and therefore intraocular pressure, should we routinely emphasize "keep breathing normally" during tonometry?**

**A:** We would suggest that the clinician simply be attentive during the procedure, and perhaps just encourage the patient to relax beforehand. It is usually obese, anxious, short-waisted, large upper body-size patients that often struggle to properly position themselves at the slit lamp. This is why we all need to have alternative instruments at the ready to enable more accurate IOP assessments in these patients, such as a handheld (Kowa or Perkins) applanation tonometer or an Icare Rebound tonometer. Also, beyond breath-holding, the blepharospastic patients most always do better with handheld devices than those mounted at the slit lamp.

**Q: Do prostaglandins cause or increase the risk of recurrent corneal erosions?**

**A:** This question acknowledges two clinical realities:

(continued from page 7A)

• **Do not “micromanage” any single component of the glaucoma workup.** For example, refrain from performing a quantitative analysis on central corneal thickness: the cornea is simply thick, thin, or normal. Here are our entirely subjective breakpoints: thick is  $>580\mu\text{m}$  to  $590\mu\text{m}$ , and thin is  $<500\mu\text{m}$  to  $510\mu\text{m}$ . What’s in the middle is essentially normal, and minimally impactful to our decision-making process.

By the way, the cornea reaches adult thickness by age 10. We have already discussed how incredibly subjective visual field data are. Even so-called “objective” tests, such as nerve fiber layer analyses, are not precisely objective; they are simply less variable. We have seen nerve fiber layers “thicken” a bit year to year, and test to test, but short of retinal edema, nerve fiber layer thickness stays the same or slowly thins. So we know an “improved” nerve fiber layer is just a change relative to a prior test. As with visual fields, do not make a management change based on the result of a single test, even those that are supposedly objective.

With IOP, we know it can fluctuate wildly. Thus, if the IOP is up on one visit and down the next, we do not make proclamations such as “You’re doing great!” or “You’re getting worse;” rather, we proclaim that “overall, it appears that your pressure control is pretty stable,” or some other appropriate statement. We most certainly do not know what each individual’s IOP is during sleep.

It is well established that there is considerable inter- and intra-observer variability in the numeric assessment of the optic disc anatomy (i.e., the cup-to-disc ratio). It would perhaps be overconfident to chart “cup has enlarged from 0.3 to 0.4, therefore will initiate therapy,” etc. One would more likely have to see a 0.2 change, or perhaps even a 0.3 change in order to state with any authority that there has been progressive optic neuropathy.

So, it can be seen that there are several opportunities to become bogged down with minutiae in the global context of the comprehensive glaucoma evaluation. There are plenty of data points, plenty of parts, so that a thoughtful doctor should be able to assimilate these various pieces and arrive at a rational stratification of risks for, or stage of, glaucoma.

(1) Prostaglandins potentiate the cytoarchitecture remodeling ability of extracellular matrix metalloproteinases. This is indeed the mechanism of action by which prostaglandins enhance uveoscleral outflow.

(2) There is an abundance of matrix metalloproteinases at sites within the cornea where the epithelium is loosely adherent. These destructive enzymes weaken the epithelial-basement membrane-anterior stromal complex, setting the

stage for epithelial erosions.

While this question is quite intellectual, and obviously has a sound scientific basis, we are not aware of any studies that point toward an increased tendency in patients to experience recurrent corneal erosions while using prostaglandin eyedrops.

**Q:** I’ve carefully studied my patients’ optic nerves, and I estimate that 5% to 10% of them are

• **If you have not yet acquired a nerve fiber layer imaging instrument, we encourage you to do so as soon as you can justify the cost of the purchase.** Without debate, the technology to acquire is an ocular coherence tomography (OCT) unit. We recommend spectral-domain OCT technology because it can give you quantitative information on the retina nerve fiber layer for glaucoma assistance, and also provide diagnostic help for hydroxychloroquine and other screenings, as well as for macular conditions such as central serous retinopathy, macular edema, etc.

While the Fourier (spectral)-domain platform is the most sophisticated technology available, the truth is that a basic OCT is amply adequate to meet the vast majority of the clinical needs of practicing eye doctors. We’d much rather see an O.D. have a time-domain OCT than not have an OCT in his/her diagnostic armamentarium at all. One can always upgrade later. We have never encountered an O.D. who acquired an OCT who was not thrilled to have it. Do note, though, that the time-domain OCT technology is not adequate for hydroxychloroquine screening. This is the most notable shortcoming of the time-domain technology.

• **We think there is now a technology “ready for prime time” (it is awaiting FDA-approval) to allow patients to do self-tonometry.** It is from Icare, the inventor of the Icare Rebound tonometer ([www.icaretonometer.com](http://www.icaretonometer.com)).

It uses the same exact rebound technology as the standard, handheld unit, but is placed in a special handheld frame type device that should allow most adults to competently obtain a series of measurements on their own, and outside of typical office hours. This should be a huge help to learn our glaucoma suspects’ and glaucoma patients’ IOP behaviors early in the mornings, late in the evenings, and perhaps even mid-sleep, for those patients who habitually awake during the night to use the bathroom.



**glaucoma suspects. I have a large geriatric population, but is that percentage too much?**

**A:** It seems reasonable that your percentage is in keeping with the prevalence of glaucoma suspects in an aged population. We do know that increased age is a key risk factor for the development of glaucoma. We commend your keen attention to your patients, and further commend your focus on the optic nerve, not the IOP. ■

# Glaucoma


## Medical Management of Acute Angle-closure Glaucoma

Almost all cases of angle-closure glaucoma can be successfully—and calmly—managed in the office. First, one needs to have on hand all the meds that might be useful in such a rare presentation. These would include acetazolamide tablets, either 250mg or 500mg. Do not use the 500mg Diamox Sequels because an extended, time-release of the medicine is not as impactful as the quicker onset of action that one gets from the tablet forms.

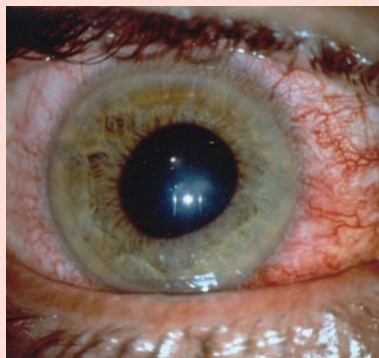You also need to have 0.5% nonselective beta blocker, brimonidine, and 2% pilocarpine at the ready. There is little to no value in the use of a prostaglandin in the setting of acute angle-closure glaucoma, as the aforementioned rapid-onset medications perform very nicely. The prostaglandins' speed-of-onset is relatively slow, and is simply not needed (like too many cooks in the kitchen) in this situation.

In the event the patient is vomiting, have Compazine (prochlorperazine) suppositories stored in the refrigerator. It is counterproductive, if not impossible, to get oral acetazolamide tablets into the patient's system when the patient has uncontrolled vomiting. A single antiemetic suppository quickly calms the storm in most cases, and thereby allows the appropriate administration of oral medication. (Note that most patients prefer to insert the suppositories themselves; another good reason to keep gloves available in the office.)

Since all carbonic anhydrase inhibitors contain a sulfa moiety, there is perhaps a slight chance of a sulfa allergy even in these non-sulfonamide medicines. Just to be thorough, always inquire if there is a history of severe allergic reaction to sulfa. If there is no history of such, then have the patient take 500mg of acetazolamide right away. If there is no asthma, then instill a drop of beta blocker, followed by a second drop in two to three minutes. Get in a drop of brimonidine in between the two administrations of beta blocker



**A gonioscopic image (above) of an angle in closure. In a different eye in acute angle closure (below), note the fixed, mid-dilated pupil in a red eye.**



drops, and then a second drop of brimonidine in two to three minutes. Both beta blockers and alpha adrenergic agonists rapidly decrease aqueous production via separate pharmacologic mechanisms.

In 10 minutes or so, instill 2% pilocarpine. It is the pilocarpine that will actually physically open the angle—the other three meds simply reduce the IOP by radically subduing aqueous production.

Why not use 4% pilocarpine? Pilocarpine is an acetylcholinergic agonist (parasympathomimetic) and can cause blood vessel dilation, thus enlarging the mass volume of the iris, and in turn causing some anterior-posterior dimensional swelling of the peripheral iris, which is

counterproductive to opening the angle. The 2% seems to be the optimum balance between effectively stimulating the parasympathomimetically innervated musculature of the iris sphincter, and not creating overall iris volume expansion. Keep in mind that the iris sphincter becomes very lethargic when the IOP exceeds around 60mm Hg, so the pilocarpine will be most pharmacologically active once the intraocular pressure drops into the 50s or 40s.

This is why the aqueous suppressants are used first, and pilocarpine shortly after. Of course, once the IOP is controlled, the patient is kept on the 2% pilocarpine q.i.d. until a YAG photostriptomycin can be performed—which may take a day or two to schedule, depending upon the location and availability of this service. Of note, there can be considerable conjunctival injection present as well, and if so, then a potent corticosteroid, such as Lotemax, Durezol or Pred Forte used q.i.d., can help the eye look and feel better, particularly if there is any associated anterior uveal inflammation present.

In summary, the diagnosis and treatment plan for the uncommon presentation of acute angle-closure glaucoma is very straightforward. The key is to have all the medications necessary at the ready to treat the patient quickly and efficiently.

## Glaucoma Pearls

- **Childhood glaucoma is very rare.** Note that virtually all cases of childhood glaucoma have significantly increased intraocular pressure.

The key in such suspicious cases is to examine the optic nerves of parents and/or siblings, to photodocument the optic nerves, and to attentively follow these children every six to 12 months until it becomes clear whether these suspicious optic nerves are either a physiological variant, or there is evidence of progression. Bear in mind that asymmetry of approximately 0.2 cup-to-disc ratio is a common physiological finding.<sup>1</sup>

- **Central corneal thickness reaches adult status by age 10.**

- **Most patients with ophthalmoscopically visible optic nerve drusen manifest wide-ranging variations of visual field defects.** If these patients are observed to have high intraocular pressure, or if there is a documented steady increase in IOP over time (years), then it may be prudent to institute IOP-lowering therapy. By and large, visual field and nerve fiber layer scanning data will be relatively useless, and so keeping IOP at physiological levels is likely the wisest course.

- **The single most challenging decision in the care of patients who are glaucoma suspects endures: When should therapy be initiated?** “In the end, the physician is struck with the persistent problem of whom to treat and whom to watch... The endless symposium and debate on how to best manage with ocular hypertension will probably continue unabated.”<sup>2</sup> This seminal declaration precisely establishes the imprecision of decision-making and caring for patients with glaucoma. One doctor may judge the best course of care to be watchful waiting, while another may pursue a course of active treatment. In these unclear cases, one doctor cannot declare the other errant in clinical judgment. The truth is, it may require many years of following such a patient in order to know with certainty which course confers the greater benefit to the patient.

We urge the clinician to provide all glaucoma suspects a state-of-the-art assessment, develop a solid patient care plan, and be confident in that care plan. Do not concern yourself with the potential for another clinician’s different approach. Above all, carefully, attentively follow the patient.<sup>2</sup>

- **The website [gonioscopy.org](http://gonioscopy.org) is a magnificent way to improve your assessment of the iridocorneal angle anatomy.** “In routine clinical practice, gonioscopy should be performed in a dark room to avoid misdiagnosis of treatable iridotrabeular apposition.”<sup>3</sup>

- **Even glaucoma subspecialists cannot always judge optic nerve glaucomatous “progression” from sequential optic nerve head photographs.** “Interobserver agreement among glaucoma specialists in judging progressive optic disc change from stereophotographs was slight to fair. After masked adjudication, in 40% of the cases in which the optic disc appeared to have progressed in glaucoma severity, the photograph of the ‘worse’ optic disc was in fact taken at the start of the study. Caution must be exercised when using disc change on photographs as the “gold standard” for diagnosing open-angle glaucoma or determining its progression.”<sup>4</sup>

It may take longer than the five to 50 months (median 26 months) of analysis performed in this study to accurately discern changes in optic nerve anatomy. Because glaucoma progresses on average at a rate of 3% per year, it may take more like eight to 10 years to competently and accurately judge progression using optic disc photography. We think sequential nerve fiber layer scanning technology may be a more refined manner to assess progression.

- **“Objective” technology is not absolutely objective, only objective relative to other subjective tests.** It is well understood that visual field testing can be highly variable from test to test. We love our nerve fiber layer scanning instruments, and depend upon them to aid us in the assessment of our glaucoma patients, but even these wonderful “objective” tests can vary slightly from test to test.

Our advice: Never micromanage any single component of the glaucoma evaluation, but rather look for repeatable trends over time (years).

Regarding visual field testing, we recommend the Humphrey 24-2 SITA-Standard or SITA-Fast, using standard white-on-white perimetry (standard achromatic perimetry, SAP). Newer research as shown that there is little or no advantage to using blue-on-yellow (short-wavelength automated perimetry, SWAP) or frequency doubling technologies.<sup>5-7</sup>

1. Beck A. Evaluating and Managing Optic Disc Cupping in Children. *Glaucoma Today*. Jan-Feb 2009.

2. Sommer A. Treatment of ocular hypertension: Hamlet’s Lament revisited. *Arch Ophthalmol*. 2010 Mar;128(3):363-4.

3. Barkana Y, Dorairaj SK, Gerber Y, et al. Agreement between gonioscopy and ultrasound biomicroscopy in detecting iridotrabeular apposition. *Arch Ophthalmol*. 2007 Oct;125(10):1331-5.

4. Jampel HD, Friedman D, Quigley H, et al. Agreement among glaucoma specialists in assessing progressive disc changes from photographs in open-angle glaucoma patients. *Am J Ophthalmol*. 2009 Jan;147(1):39-44.e1.

5. van der Schoot J, Reus NJ, Colen TP, Lemij HG. The ability of short-wavelength automated perimetry to predict conversion to glaucoma. *Ophthalmology*. 2010 Jan;117(1):30-4.

6. Bengtsson B, Heijl A. Diagnostic sensitivity of fast blue-yellow and standard automated perimetry in early glaucoma: a comparison between different test programs. *Ophthalmology*. 2006 Jul;113(7):1092-7.

7. SWAP or DOUBLE? *International Glaucoma Review: The Journal for the World Glaucoma Association*. 2008 Sep; 10-2. Available at: [www.e-igr.com/SP/index.php?issue=102&supID=7&pageID=146](http://www.e-igr.com/SP/index.php?issue=102&supID=7&pageID=146).

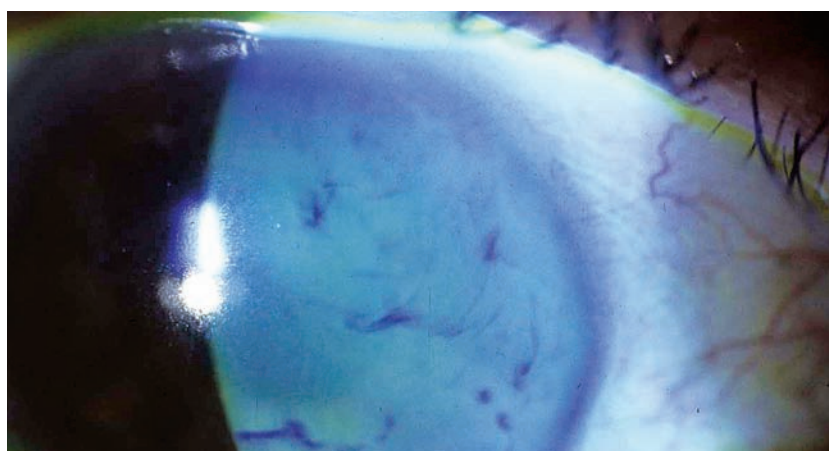# Beneath the Surface of Dry Eye Disease

We now understand that most ocular surface dryness is related in one way or another to meibomian gland dysfunction, which affects the tear film lipid layer.

**F**rom a disease management perspective, the single most common clinical challenge we face each day is helping patients who suffer from ocular surface disease, predominantly ocular surface dryness. It is now realized that most ocular surface dryness is related in one way or another to meibomian gland dysfunction.<sup>1</sup> This leads to a poorly performing tear film lipid layer. Logical thought would then move us to recommend a lipid-based artificial tear as initial therapy.

In addition, we start all of our dry eye patients on 2,000mg of fish oil. We urge them to take such with breakfast. We do not get hung up on micromanaging this oral supplement with regard to the debate over triglyceride versus ethyl ester formulations—just fish oil. By the way, and just for perspective, cardiologists commonly prescribe Lovaza (GlaxoSmithKline), a purified omega-3 fish oil supplement of an ethyl ester variety.

While fish oil can help with meibomian gland secretions, it often takes four to six months to begin to see an effect. For this reason, we often prescribe 50mg of oral doxycycline once daily for two to three months. From our observations, it more quickly and more potently en-



**Dry spots on the corneal surface are associated with reduced tear film break-up time.**

hances meibomian gland function. This gives more rapid improvement of patient comfort and simultaneously buys time for the fish oils to kick in. (For those few patients who cannot swallow these rather large capsules, Nordic Naturals, Coromega and others make very palatable liquid formulations.)

A more thorough discussion of meibomian gland treatment is found on page 12A, but



the ultimate treatment/management of meibomian gland disease is heat and massage, not medical.

With this comprehensive background, we now answer questions regarding dry eye.

**Q: If a patient were to be allergic to doxycycline, what would you recommend for treating meibomian gland dysfunction?**

**A:** We have never encountered this; the answer is probably oral erythromycin or oral azithromycin. We might even prescribe a 5mg steroid Dosepak, just to potentiate the mild anti-inflammatory properties of these two antibiotics.

**Q: In the setting of dry eye,**

which drop works best with contact lenses?

**A:** We would generally select any artificial tear that is not BAK-preserved, and have the patient use it as often as is needed to achieve and maintain comfort. We like to use punctal plugs to diminish the frequency of, or need for, any artificial tear. Don't forget to use fish oil supplements as well. We commonly recommend 2,000mg taken every day with breakfast.

**Q:** For dry eye, [Leiterspharmacy.com](http://Leiterspharmacy.com) will fill an Rx for 5% albumin drops—any comments?

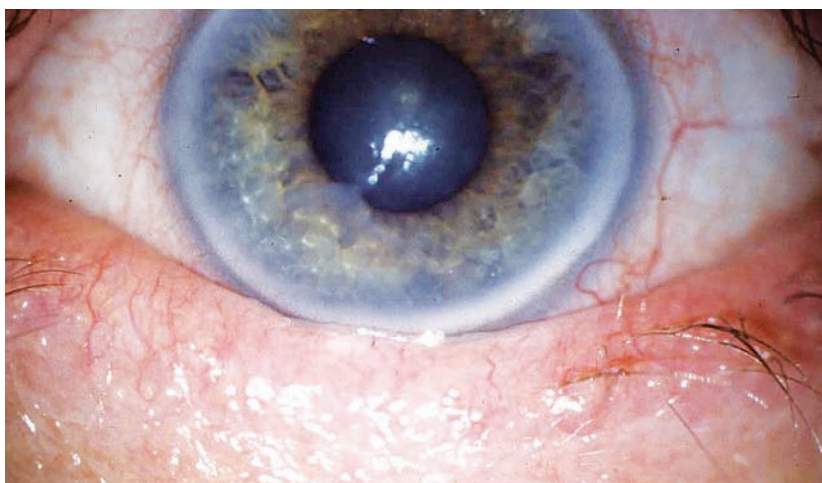
**A:** We have never used this approach with any of our patients, but for those few dry eye patients for whom the “kitchen sink” approach has not achieved control and relief, this would likely be worth a try.

Another approach that is talked about in these more challenging cases is the use of autologous serum, which we have each used on rare occasions with success, and think that this more comprehensive source of ocular nutrition would be superior to albumin.

**Q:** How do you approach the contact lens-wearing dry eye patient?

**A:** There are a number of approaches. Here's what we usually do:

- Quantify the degree of ocular surface dryness.
- Replace “rewetting drops” with a top-quality artificial tear. We have had excellent success with lipid-based tears.
- We recommend 2,000mg of fish oil supplementation every day for nearly all of our dry eye patients. Note that it may be three to six months before an effect can be appreciated. Whatever the case, fish oil is a very healthy substance, and is likely beneficial to total body health,



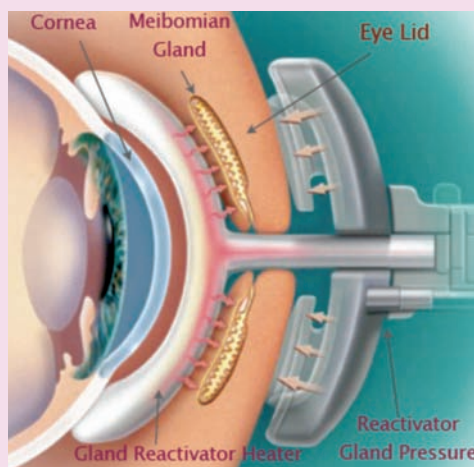
**Most ocular surface dryness is related in one way or another to meibomian gland dysfunction. This leads to a poorly performing tear film lipid layer. Logical thought would then move us to recommend a lipid-based artificial tear as initial therapy.**

## New MGD Device on the Way

While not yet FDA approved, there is an incredibly ingenious device known as the LipiFlow Thermal Pulsation System (TearScience Inc.), which both heats the eyelid (from the tarsal conjunctival side where adequate heat levels can be achieved), while simultaneously massaging/expressing the glands. Both the heat application and compression pressure are precisely controlled for optimum patient care.

We foresee the day when a patient who needs meibomian gland therapy will schedule a follow-up appointment to come into the office for a “meibomian expression treatment” session using the LipiFlow technology. Such a therapeutic session has the potential to reduce or eliminate symptoms for six to 12 months.

Necessity is the mother of invention, and the LipiFlow technology may just be what the doctor will soon order. It should come as no surprise that the inventor of this technology is Donald Korb, O.D. He has done so much over the years to enhance patient care and make our profession proud.



# Dry Eye

whether it improves tear function or not.

- Try loteprednol 0.5% b.i.d. (a drop in the morning a few minutes prior to lens insertion, and a second drop after lens removal in the evening) in the setting of acute inflammation. It is exceedingly rare that an individual has a legitimate reason (laziness is not one of them) to sleep in contact lenses.

- If, after a month of the above maneuvers, the patient remains symptomatic, try a punctal plug in the lower eyelid of the more symptomatic eye, and then evaluate the results in another month.

- Try a different brand of contact lenses.

- Try Restasis (cyclosporine, Allergan). It may do the trick in some patients. Like fish oil, it takes three to six months to produce an effect.

- Try a different disinfecting system, such as a hydrogen peroxide system.

By attentively and systematically considering the above interventions, most patients can be helped considerably.

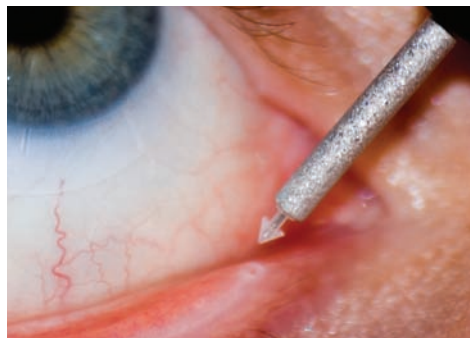**Q: Is it safe to use OTC Vaseline petroleum jelly directly into the lower cul-de-sac at bedtime for chronic nocturnal lagophthalmos? The cost is very minimal compared to a tiny tube of petrolatum jelly/mineral oil combination.**

**A:** It must be safe, because we have had many, many patients over the years use Vaseline-type products in their eyes without a problem.

**Q: Which punctal plug do you use for maximum patient comfort and efficacy, and do you ever use dissolvable/temporary plugs?**

**A:** From the outset, we have always used permanent plugs. It is our clinical impression that well-trained clinicians can determine the need for occlusion or not, so why

subject patients to more office visits than needed? We never use intracanalicular plugs because of an increased risk of canaliculitis, and we like to be able to see the plug at the punctum. This way, we—and our patients—can tell if the plug is present or not.



**If the patient remains symptomatic after a month of usual maneuvers, try a punctal plug in the lower eyelid of the more symptomatic eye.**

While all punctal plugs work well, we have evolved into using the Odyssey brand because of ease of insertion and retention properties. We do measure punctal diameter in an attempt to obtain the most optimum fit. Note that punctal plugs create some beneficial scarring once the plug has resided in the punctal tissues for several weeks. This explains why many patients do not revert to symptomatic status once a plug has been lost or extruded.

**Q: I recently read that flaxseed oil causes inflammation of the prostate. Has this influenced your recommendation for the male dry eye patient?**

**A:** Yes, it has. We instead recommend fish oil (2,000mg per day) for all of our dry eye patients.

**Q: If you are using Lotemax in the setting of managing dry eyes, when would you consider adding oral doxycycline, and for how long?**

**A:** Doxycycline has a faster onset

of action than omega-3 supplementation, so for our more symptomatic and inflamed dry eye patients we often prescribe 100mg (50mg b.i.d.) of generic oral doxycycline for a week or two, then decrease to 50mg once daily for two to three more months. After having been

on the doxycycline for two months, we often start fish oil as well. So, as we finish the course of doxycycline, the fish oil should be able to pick right up where the doxycycline leaves off. Both doxycycline and fish oil render a benefit to meibomian gland function. The topical steroid helps to quiet the ocular surface inflammation, while the doxycycline and/or fish oil supplementation aids meibomian gland function, which yields a two-pronged approach in helping the dry eye patient.

**Q: If you do get an increased intraocular pressure while using Lotemax, what do you suggest?**

**A:** It depends on how well the patient has responded to this therapy, and the degree of intraocular pressure increase. If the patient was getting a good response to the corticosteroid, then we would consider switching to the 0.2% loteprednol (Alrex) if the IOP increase was less than 10mm Hg above baseline, and monitor the intraocular pressure.

If the IOP increase is greater than 10mm Hg, then we would try a topical NSAID or cyclosporine *IF* the patient had a positive initial response to anti-inflammatory therapy. If there was little initial response to the steroid, we see little potential to try other anti-inflammatory approaches.

1. Green-Church KB, Butovich I, Willcox M, et al. The international workshop on meibomian gland dysfunction: report of the subcommittee on tear film lipids and lipid-protein interactions in health and disease. Invest Ophthalmol Vis Sci. 2011 Mar 30;52(4):1979-93.



# A Scientific View on Blepharitis and MGD

Recent literature has used the terms posterior blepharitis and meibomian gland dysfunction as if they were synonymous, but these terms are not interchangeable.

**T**hanks to the recent report from the International Workshop on Meibomian Gland Dysfunction, organized by the Tear Film & Ocular Surface Society, we have new and more scientifically proper nomenclature for these (mostly) distinct clinical entities.

Here is the definition from the MGD workshop:

“Posterior blepharitis is used to describe inflammatory conditions of the posterior lid margin, including MGD. Indeed, recent literature has used the terms posterior blepharitis and meibomian gland dysfunction or MGD as if they were synonymous, but these terms are not interchangeable. Distinct from the portion of lid margin anterior to the gray line, which includes the skin and eyelashes, the posterior lid margin contains the marginal mucosa, the mucocutaneous junction, the meibomian gland orifices and associated terminal ductules, and the neighboring keratinized skin. Posterior blepharitis is a term used to describe inflammatory conditions of the posterior lid margin, of which MGD is only one cause. Other causes include infectious or allergic conjunctivitis and systemic conditions such as acne rosacea.”<sup>1</sup>

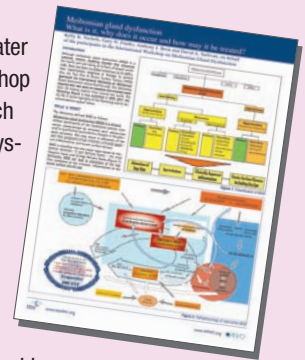
It has been our observation that MGD, with or without rosacea,

## MGD Report Released

Just as the Dry Eye WorkShop (DEWS) report brought greater understanding of dry eye in 2007, the International Workshop on Meibomian Gland Dysfunction report published in March 2011 brings greater understanding of meibomian gland dysfunction. All optometrists should read this report, if not in its entirety, then at least the “executive summary.” These can be viewed via [www.tearfilm.org/mgdworkshop](http://www.tearfilm.org/mgdworkshop).

Although several critical questions remain unanswered, this landmark report advances our understanding of meibomian gland functions and their clinical significance.

Because it is well known that most “dry eye” is underpinned by meibomian gland dysfunction and disease, it is imperative that all O.D.s acquaint themselves with this report.



constitutes the vast majority of afflictions to the posterior tissues of the eyelids. So, to keep things simple, blepharitis is an anterior infectious/inflammatory condition, while MGD represents the preponderance of posterior eyelid disease. They are managed very differently.

## Blepharitis

Blepharitis (like rheumatoid arthritis and dandruff) is a chronic disease, and the absolute mainstay for control (not cure) is initial and enduring eyelid hygiene. Forget baby shampoo; this is obsolete when compared to commercially available eyelid scrub products such as OCuSOFT Eyelid Cleanser or SteriLid (TheraTears). These have the appearance and function of a

“professional” therapeutic modality, and should completely replace the older, out-of-date baby shampoo approach.

There are those patients who do have clinically significant eyelid erythema and other signs of inflammation, such as lash misdirection and madarosis. These inflammatory signs are predominantly manifested as a response to staphylococcal exotoxins. When there is clinically significant eyelid inflammation, medical therapy is indicated to help achieve tissue restoration. This can be accomplished in several ways. One way is the use of combination antibiotic/steroid eye drops q.i.d. for two to four weeks. Options here include Zylet, generic TobraDex, TobraDex ST, or generic Maxitrol.

# Dry Eye

(We prefer Zylet purely because of the relative safety of the ester-based loteprednol.<sup>2</sup> The other three products would work equally as well, but because they contain the older ketone-based dexamethasone, we prefer to treat a chronic disease with the safest steroid available.)

If cost is a concern, generic Maxitrol is by far the least expensive drug within this class. Note that tobramycin (found in Zylet and TobraDex) and neomycin with polymyxin-B (found in Maxitrol,

which is generic neomycin, polymyxin B and dexamethasone) possess excellent anti-staphylococcal properties. Lotemax ophthalmic ointment could be used at bedtime for two to four weeks, but we would suggest either the eyedrop approach, or the ointment approach, but not both at the same time. The macrolide azithromycin is suboptimally staphylocidal (as documented in the Ocular TRUST data), and, as an antibiotic, it has limited anti-inflammatory proper-

ties when compared to a corticosteroid.<sup>3</sup>

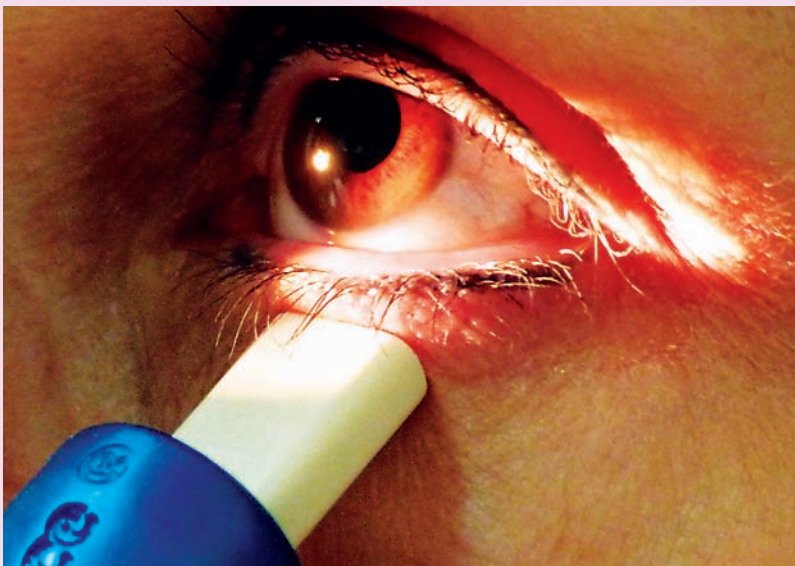If patients can be persistent with eyelid hygiene, the role of medical therapy should be very limited. Patients being patients, however, most slack off and therefore may require pulsed medical therapy once or twice a year. It is this realization of the episodic need for a corticosteroid that leads us to prefer loteprednol.

## Breakthrough Technology in Meibomian Gland Dysfunction

It is now known that a constantly applied pressure (1.25gm/mm<sup>2</sup>) for 15 seconds is needed to adequately evaluate meibomian gland dysfunction (MGD). New research out of Ocular Research of Boston has yielded a simple, handheld device known as the Meibomian Gland Evaluator. This device should bring to all physicians a simple, semi-qualitative means to objectively assess for MGD in all patients presenting with dry eye symptoms.

Doing this centrally and nasally on both lower eyes gives great clinical insight as to the

nature of the dry eye symptoms. After constant pressure with the handheld device for 15 seconds, just judge the character of the expressed glandular secretions. They should be clear. The more turbid, cloudy or cheesy the secretions, the more pathology is evident. For a description of the technique, visit [www.tearscience.com](http://www.tearscience.com).



## Meibomian Gland Dysfunction

It is now evident that most all cases of dry eye have some component of lipid layer dysfunction resulting from suboptimum meibomian gland function.

Now the question becomes: How can we restore or enhance these glandular secretions physiologically? We must first understand that dysfunctional glands are commonly blocked, so it makes no sense that any topical eyedrop or ointment can render a meaningful therapeutic effect. As with blepharitis, the mainstay of therapy is physical/mechanical. There may well be a rational and intellectually prudent reason to prescribe oral doxycycline, because the medicine can gain access to these glands via the systemic circulation (unlike with topical medications), and the benefit of oral medication can be enhanced by warm soaks and/or eyelid expression to help promote more normal secretions.

The mainstay therapy of aggressive use of warm soaks should be followed by physical massage. This can truly be a challenge, and is time-consuming. First, being cognizant that these glands anatomically reside in the posterior portion of the eyelid, it is difficult to achieve a sufficiently high heat level externally to “loosen” the glandular contents—but it is still worth the effort. Then try to immediately massage

and express these glands to purge their contents with the intent that newly formed secretions may be more physiologic. The oral doxycycline and/or fish oils can help foster more normal secretions.

A couple of notes about expression: It takes a sustained pressure for about 15 seconds to empty the glands that are not blocked, and these efforts need to focus on the centrally and nasally located glands. (The volume of the temporal meibomian glands is not worth the effort or time it takes to express them, so spend time on the central and nasal glands.) Next, the globe is a relatively soft substrate for adequate compression, so we recommend the in-office use of the Mastrota paddle (OCuSOFT) to help facilitate gland expression.

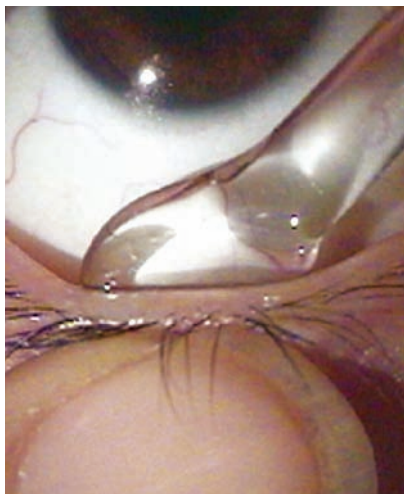


Photo: Katherine Mastrota, M.S., OD.

**It takes a sustained pressure for about 15 seconds to empty the glands that are not blocked.**

Obviously, it would be maximally beneficial if all gland expression could be done in the office, but at this time that is simply impractical. So, do attempt to express the glands for the patient in the office when treatment is initiated to accomplish some active therapy—but more importantly, do train the patient so that some therapy can be continued

at home.

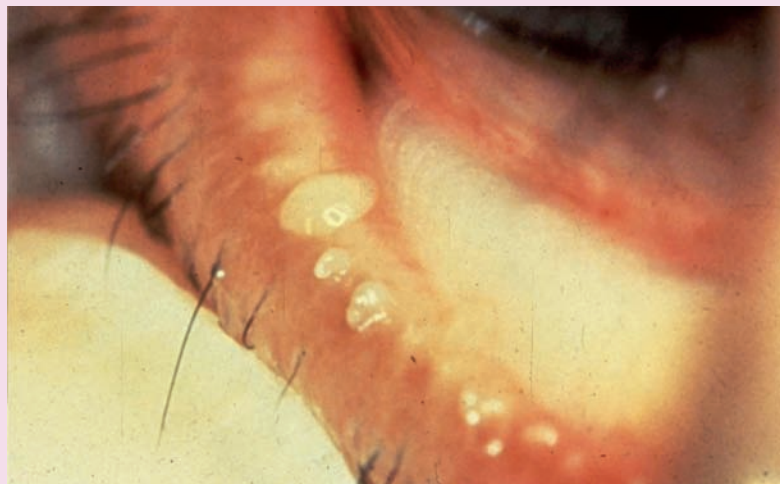In summary, blepharitis is essentially managed with enduring eyelid hygiene, often jumpstarted with two to four weeks of antibiotic-steroid or steroid therapy. Treatment of meibomian gland disease is complex and involves technically correct application of warm soaks, followed by glandular massage, and may be underpinned with a loading dose of 50mg of oral doxycycline for a couple of months, and continued with 2,000mg of fish oil thereafter.

As can be seen, the care of patients with meibomian gland dysfunction is rapidly changing, and we anticipate newer paradigms in managing this disorder in the near future. ■

1. Nelson JD, Shimazaki J, Benitez-Del-Castillo JM, et al. The international workshop on meibomian gland dysfunction: report of the definition and classification subcommittee. *Invest Ophthalmol Vis Sci.* 2011 Mar 30;52(4):1930-7.
2. Pavesio CE, Decory HH. Treatment of ocular inflammatory conditions with loteprednol etabonate. *Br J Ophthalmol.* 2008 Apr;92(4):455-9.
3. Asbell PA, Sahm DF, Shedden A. Ocular TRUST 3: Ongoing Longitudinal Surveillance of Antimicrobial Susceptibility in Ocular Isolates. Poster presented at American Society of Cataract and Refractive Surgery meeting, April 3-8, 2009; San Francisco.

### Observations on Meibomian Gland Dysfunction

“Overall, CD45 leukocyte infiltration into the meibomian gland acini was significantly associated with the severity of the MG expression,” says a recent report in the April 2011 *Archives of Ophthalmology*. “Additionally, meibomian glands exhibited variable amounts of leukocyte infiltration that are significantly correlated with the severity of MG expression.”



While this study did not discuss any treatment options, it is widely recognized that corticosteroids are highly effective in leukocytic infiltrative disease states. This is an example where we think a highly effective anti-staph medication combined with a corticosteroid would perhaps be most effective in combating blepharitis as well as MG disease. Treatment of both conditions would be enhanced by the use of aggressive warm soaks, eyelid hygiene, and massage.

The report adds, “In obstructive MGD, hyperkeratinization of the meibomian gland orifice is thought to lead to cystic ductal dilation and downstream disuse atrophy of the meibomian gland acini.”

This leads us to believe that eye doctors need to intervene as early as practical and appropriate in treating MGD with the goal of preventing disuse atrophy. Exactly how this is done is yet to be fully elucidated, but use of fish oil supplementation may be beneficial; and we recommend these omega-3 fatty acids for most all of our dry eye patients.

Nien CJ, Massei S, Lin G, et al. Effects of age and dysfunction on human meibomian glands. *Arch Ophthalmol.* 2011 Apr;129(4):462-9.

# Corticosteroids

Hit most cases of inflammation hard and heavy initially. Begin to taper only once the inflammation is well controlled.

**T**he key to managing most inflammatory processes is to select an appropriate steroid medicine and use it frequently until the inflammation comes under control, then conduct an appropriate taper of days to weeks, depending upon the nature, severity, and response of the condition. Selecting a potent corticosteroid is essential to effecting a clinical cure (or control) in most cases.

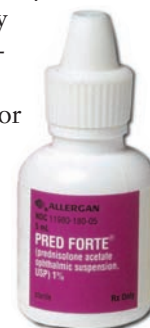Generally speaking, using a steroid more than necessary is superior to under-dosing. It is practically impossible to use a topical steroid eye drop too often, but under-treating can allow unchecked inflamma-

tion to damage ocular structures. This is probably most applicable to intraocular inflammation such as iridocyclitis. Of course, the ultimate goal is to prescribe with precision, which requires exquisite teaching coupled with clinical seasoning. The more patients one sees, the more precise the clinical care can be.

**Q: How often do you check IOP for patients on long-term steroid therapy (for example, dry eye or chronic iritis)?**

**A:** In our clinical experience, if patients are going to have an increased intraocular pressure secondary to steroid use, they usually do so within a few weeks. Such steroid responders generally show themselves more quickly with more frequent dosing, and the ketone steroids hasten this behavior more expressively than an ester-based corticosteroid.

If we are treating an aggressive anterior uveitis with difluprednate or prednisolone, we would monitor the IOP as part



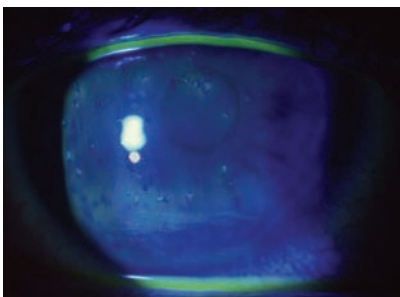
Topical Corticosteroid Drugs				
BRAND NAME	GENERIC NAME	MANUFACTURER	PREPARATION	BOTTLE/TUBE
<b>Maximum Strength Steroids</b>				
Durezol	difluprednate 0.05%	Alcon	emulsion	5ml
Lotemax	loteprednol etabonate 0.5%	Bausch + Lomb	suspension	5ml, 10ml, 15ml
Lotemax Ointment	loteprednol etabonate 0.5%	Bausch + Lomb	ointment	3.5g
Pred Forte, and generic	prednisolone acetate 1%	Allergan, and generic	suspension	5ml, 10ml, 15ml
generic	prednisolone sodium phosphate 1%	generic	solution	5ml, 10ml, 15ml
Vexol	rimexolone 1%	Alcon	suspension	5ml, 10ml
<b>Moderate Strength Steroids</b>				
Alex	loteprednol etabonate 0.5%	Bausch + Lomb	suspension	5ml, 10ml
Flarex, and generic	fluorometholone acetate 0.1%	Alcon	suspension	5ml, 10ml
FML, and generic	fluorometholone alcohol 0.1%	Allergan	suspension	5ml, 10ml, 15ml
FML S.O.P.	fluorometholone alcohol 0.1%	Allergan	ointment	3.5g
Pred Mild, and generic	prednisolone acetate 0.12%	Allergan	suspension	5ml, 10ml

of *all* of our follow-up visits. For chronic care patients using loteprednol, after the first month or two of evaluating the response of the clinical condition and evaluating the IOP at these same visits, if there has been no IOP increase, we then monitor the IOP every four to six months.

We do not schedule an “IOP check” visit, but during the course of patient follow-up evaluations, an assessment of the IOP is routinely done. What we have very clearly seen is that if a patient does not demonstrate an increased IOP with the use of steroids q.i.d. for a month, they do not exhibit a steroid response with once-daily or b.i.d. dosing over months or years.

**Q: Even the ophthalmologists I work with are hesitant about using steroids on any epithelial defects. So, how do I justify doing this with my patients?**

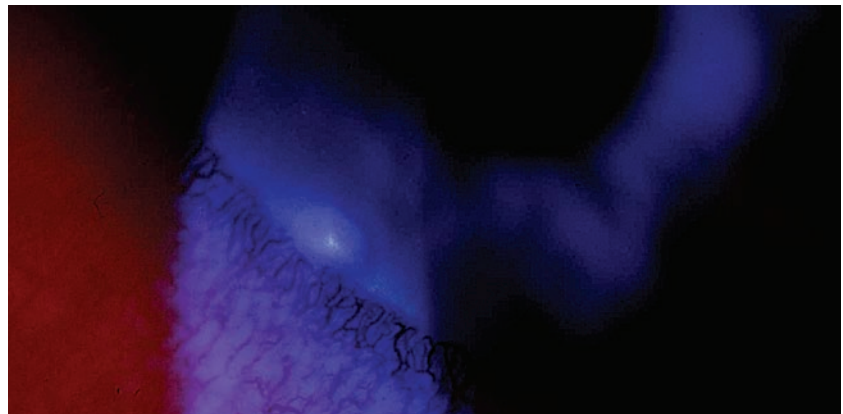
**A: The prime question is: “What is the nature of the epithelial compromise?” Is it a non-healing**



**Thygeson’s superficial punctate keratopathy (SPK).**

corneal abrasion from fingernail trauma, where associated anterior stromal inflammation is hindering epithelialization? Is there an abundance of anterior stromal leukocytic infiltration that is hindering re-epithelialization? A good history and attentive slit lamp examination will guide sound decision-making.

Ophthalmologists and optom-

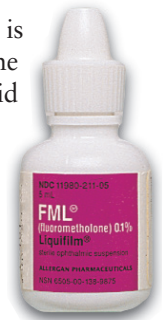
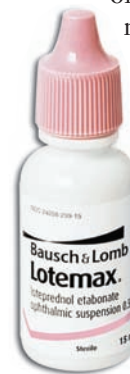
**This contact lens patient has a peripheral, white, corneal lesion that exhibits smaller fluorescein staining than the size of the underlying corneal stromal lesion.**

etrists alike struggle with clinical decision-making. Clinical conditions are not profession-specific, and a more keen understanding of the pathophysiology of certain epithelial defects enable the rational and prudent use of steroids. A common example would be Thygeson’s SPK. This condition’s recommended treatment is indeed topical corticosteroids—in this case, a mild one such as loteprednol 0.2% or fluorometholone 0.1%. There is no need to use any topical ophthalmic antibiotic here.

A slightly more challenging scenario is the contact lens wearer who presents with a peripheral, white, corneal lesion that exhibits a smaller fluorescein staining defect

than the size of the underlying corneal stromal lesion. The conjunctival injection pattern is accentuated in the juxtalésional region of the bulbar conjunctiva (the entire bulbar conjunctiva is not markedly red), and the anterior chamber is devoid of any significant inflammatory cells. Such a presentation would represent an inflammatory keratoconjunctivitis resulting from leukocytic chemotaxis into the anterior stroma of the cornea. This commonly results in some overlying epithelial compromise, as evidenced by a relatively small positive fluorescein staining defect.



## Lotemax Ophthalmic Ointment

Lotemax ointment (loteprednol 0.5%, Bausch + Lomb) was just approved by the FDA in April. Its indication is for treatment of postoperative inflammation and pain following ocular surgery; however, we anticipate using it “off-label” in a rational manner for a myriad of clinical conditions. These might include: inflammatory blepharitis; dry eye; augmentatively for severe uveitis, episcleritis and cystoid macular edema; contact blepharodermatitis; recurrent corneal erosion; and various other conditions where corticosteroid suppression would help restore tissue normalcy.

Because it’s an ester-based formulation with an enhanced safety profile, we anticipate this new product to largely replace fluorometholone ophthalmic ointment. It may be mid-to late summer before Lotemax ophthalmic ointment will be available for prescribing, however. (A photo was not available at press time.)

# Corticosteroids

## The Many Uses of Corticosteroids

Topical steroids are essential for the restoration of normal tissues for the following diseases, afflictions and conditions:

- Iridocyclitis
- Ultraviolet keratitis
- Contact lens overwear
- Inadvertent hydrogen peroxide keratoconjunctivitis
- Thygeson's superficial punctate keratopathy
- Allergic conjunctivitis
- Acute angle closure<sup>1</sup>
- Dry eye syndrome
- Infiltrative keratitis<sup>2</sup>
- Ulcerative keratitis<sup>3</sup>
- Microcystic edema of the cornea
- Vernal conjunctivitis
- Atopic conjunctivitis
- Bacterial conjunctivitis<sup>2</sup>
- Glaucomatocyclitic crisis
- Uveitis-associated ocular hypertension
- Blepharitis<sup>2,4</sup>
- Curling iron/burn injury (thermal keratoconjunctivitis)<sup>2</sup>
- Nasolacrimal stenosis<sup>2</sup>
- Traumatic hyphema
- Post foreign body removal<sup>2</sup>
- Acute adenoviral infection<sup>5</sup>
- Acute, symptomatic giant papillary conjunctivitis
- Corneal graft rejection
- Phlyctenulosis (<sup>2</sup>, if corneal)
- Inflamed pinguecula/pterygia
- Recurrent corneal erosion<sup>6</sup>
- Post anterior stromal micropuncture<sup>2</sup>
- Herpes simplex viral stromal keratitis<sup>7</sup>
- Episcleritis
- Acute hordeolum (stye)<sup>8</sup>
- Superior limbic keratoconjunctivitis
- Cyanoacrylate-induced chemical keratitis

<sup>1</sup> once IOP is controlled

<sup>2</sup> with antibiotic

<sup>3</sup> once active infection is controlled

<sup>4</sup> with eyelid hygiene

<sup>5</sup> following 5% Betadine treatment

<sup>6</sup> with oral doxycycline

<sup>7</sup> with antiviral cover

<sup>8</sup> with warm compresses

The use of the steroid will quickly suppress the stromal inflammation, and thus hasten the restoration of tissues to normal (which would include re-epithelialization). Since contact lens wear always increases the likelihood of bacterial infection, especially when the contacts are worn overnight, we always encourage conservative wearing schedules, strict adherence to proper lens care technique and replacement schedules, and quarterly replacement of the contact lens case.

**Q: Inflammation is classically discussed as a vascular or microvascular event. However, you have shown how suppressing an inflamed anterior stroma can hasten (not prolong) corneal re-epithelialization; yet, the cornea is avascular. Please comment.**

**A:** Many biochemical insults to the cornea can cause chemotactic migration of leukocytes from the blood vessels into the anterior stroma, where an inflammatory cascade of events can occur. Steroid eyedrops cause the cellular infiltrates to disappear from the cornea, and visual clarity returns. If there is an overlying, non-healing epithelial defect, suppressing the corneal stromal inflammation can enable these tissues to return to normal, thus potentiating re-epithelialization—not retarding it, as older, traditional teaching has held.

**Q: Saw my very first Lotemax steroid responder (after being in practice for 30 years). This 47-year-old white patient had a baseline intraocular pressure of 18mm Hg O.D. and 20mm Hg O.S. On Tobradex, IOP in the treated left eye increased to 33mm Hg. A trial with Lotemax also yielded an increased IOP (to 36mm Hg). In both cases, after stopping the steroid, the IOP**

**renormalized to baseline.**

**A:** This patient is obviously an exquisitely sensitive steroid responder. While topical NSAIDs pack very little anti-inflammatory punch, such a therapeutic trial is reasonable here (along with generous artificial tears). Bromfenac (Bromday, ISTA) would be an excellent choice because of its once-daily administration. However, it is very expensive, so perhaps generic diclofenac b.i.d. to q.i.d. may be a more practical approach.

We wonder if the 0.2% concentration of loteprednol (Alrex, Bausch + Lomb) would be sub-threshold to generate an increased IOP, especially if used perhaps b.i.d.?

All steroids have the potential to raise intraocular pressure, as witnessed in your case. Such responses are indeed rare, as evidenced by this being your first encounter in what is a busy therapeutic practice.

**Q: Poison oak is pretty common out here. Would triamcinolone be the best treatment around the eye for a child with poison oak?**

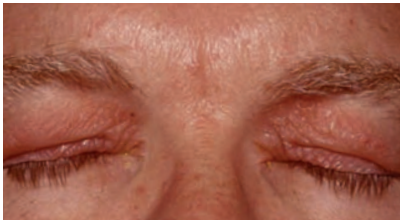**A:** Yes, but perhaps applied only b.i.d. for a child, as opposed to q.i.d. for an adult. And don't forget cold compresses.

**Q: Is 0.5% triamcinolone safe to use around the eye?**

**A:** Probably, but we never use this concentration because we have had perfect success in treating contact blepharodermatitis with the 0.1% concentration of triamcinolone cream. We always strive to use the least amount of medicine to meet our patients' needs.

**Q: Have you ever had a patient have an intraocular pressure increase as a result of using triamcinolone cream to the eyelids?**

**A:** We have not, but it is perhaps



**The 0.1% triamcinolone cream is likely more appropriate for use around the eye than the 0.5% concentration.**

possible. So, when doing your usual follow-up evaluations, go ahead and check the pressure.

**Q: What is an average taper for steroids, once acute stromal herpes simplex keratopathy has been controlled?**

**A:** The taper is typically done over several weeks or months; some patients require a drop a day, or even every other day, for life. We only use loteprednol for such protracted therapy. A typical example of a steroid taper might be q.i.d. for a month, then t.i.d. for a month, then b.i.d. for two months, and then once daily for two or three more months. If the inflammation rebounds when the dosage is reduced to b.i.d., we titrate back to t.i.d. for two months, and then try again to reduce to b.i.d., and we plan a longer taper at each phase. Ultimately, we try to get the patient to b.i.d. usage of the 0.2% loteprednol concentration for a few months, and then try to reduce the drop to once daily. It purely is a matter of therapeutic trial, trying to find the lowest dosage at which the eye remains quiet. Not all such stromal herpetic keratitis conditions will require such a long, drawn-out course of therapy, but some will.

**Q: How would you change treatment if seeing episcleritis or corneal leukocytic infiltrates in a pregnant woman? Would you still use steroids?**

**A:** The scenarios you describe are almost always steroid-dependent conditions, so yes, we would use steroids. We would use either competent punctal occlusion or gentle eyelid closure for three minutes if using eyedrops. We could consider using the new Lotemax ointment or FML ophthalmic ointment, since

it is well recognized that ointment medicines tend to stay local and not become systemically absorbed.

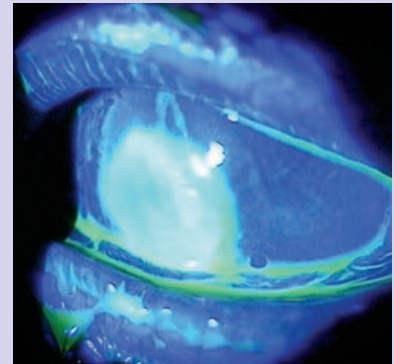
It is always good practice to consult by phone with the patient's obstetric physician, or at least get a letter to the OB/GYN so that the doctor is fully informed of the patient's condition and treatment. ■

## Is it an Infiltrate or is it an Ulcer?


Corneal infiltration is still commonly mistaken for an ulcerative process. There are a number of factors to consider in the differential diagnosis between a leukocytic infiltrate and a bacterial corneal ulcer:

- First, pay attention to the epidemiology of these two conditions: infiltrates are very common; ulcers are very rare.
- An anterior chamber reaction (i.e., cells and flare) is almost always seen with an ulcerative process. While an anterior chamber reaction is usually absent with an infiltrate, trace cells are sometimes seen, especially if the condition has been ongoing for several days.
- The appearance of the conjunctival injection pattern can also be very helpful. With an infiltrate, sector injection is the rule; in an ulcerative process, the entire bulbar conjunctiva is injected.
- While neither highly sensitive nor specific, the degree of pain the patient describes can be helpful. An ulcer tends to evoke much more pain than an infiltrate.
- Location can also be helpful. As a rule, ulcers are solitary and tend to be more central, while infiltrates can be single or multiple and strongly tend to express themselves at or near the corneal limbus.
- The fluorescein staining pattern of the lesion is probably one of the characteristics we find most helpful in making a definitive diagnosis. With an ulcer, the size of the fluorescein staining pattern closely mirrors the size of the corneal lesion, whereas the staining pattern of an infiltrate is significantly smaller than the underlying lesion.

This is because an ulcer begins in the epithelium, and expands laterally and in depth, creating an epithelial defect closely



**With an ulcer, the size of the staining pattern closely mirrors the size of the corneal lesion.**



**With an infiltrate, the size of the staining pattern is significantly smaller than the underlying lesion.**

paralleling its stromal invasion. An infiltrate results from the chemotactic attraction of leukocytes from the paralimbal microvasculature. The accumulation of white blood cells in the anterior stromal tissues results in some secondary compromise to the overlying epithelium, which tends to cause a relatively small defect in the center of the underlying stromal lesion.

# Topical Antibiotics

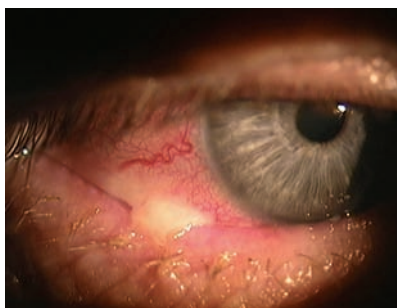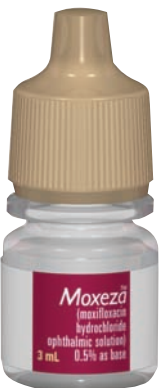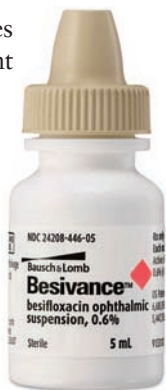The key to clinical success and bacterial eradication is not so much the drug prescribed, but rather the frequency of drug instillation.

The “go to” drugs for eyes evidencing mucopurulent discharge are: generic Polytrim (trimethoprim with Polymyxin B); a generic aminoglycoside (gentamicin or tobramycin); a chloro-fluoroquinolone (Besivance [besifloxacin, Bausch + Lomb]); or either gatifloxacin 0.5% (Zymaxid [Allergan]); or moxifloxacin 0.5% (either Vigamox or Moxeza [Alcon], the latter being essentially the same as the former except that Moxeza has a xanthum gum vehicle, which prolongs ocular surface residency time, and so requires less frequent dosing of the drug.)

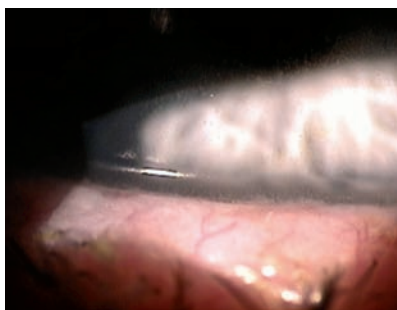
The key to clinical success is not so much the drug prescribed, but rather the frequency of drug instillation.

Q: Please go over what role doxycycline plays in treating recurrent corneal erosion and RCE-related abrasions.

A: It has been shown that



**Evident mucopurulent discharge is a red flag for bacterial conjunctivitis.**



**But not all bacterial infections present with obvious discharge. Check the lacrimal lake for microparticulate debris.**

extracellular matrix metalloproteinases are present in the corneal areas where epithelial breakdown occurs. These degrading enzymes are thought to play a role in setting the stage for these breaches in epithelial adhesion. The tetracyclines (doxycycline and minocycline) excellently inhibit these enzymes so that physi-

ological adhesion of the basal epithelium/Bowman’s layer/ anterior stromal complex can occur. This, in theory (and in clinical practice) breaks the cycle of recurrence, and is “curative” for most patients. Corticosteroids also inhibit these same enzymes, and work in concert with oral doxycycline.

Our general approach is to prescribe 50mg of doxycycline p.o. b.i.d. for a week, and then once daily for four to six weeks, along with loteprednol 0.5% q.i.d. for three weeks, and then b.i.d. for three more weeks (or some reasonable variation thereof).

Doxycycline should be taken with meals, and not within two hours of bedtime because of the remote possibility of esophageal reflux, resulting in epigastritis (heartburn).

**Q: Where do you send your cultures? What are some sources to purchase the mini-tip culturettes you espouse?**

A: There are many dozens of general medical supply businesses. We recommend you ask your personal physician or a local microbiologic laboratory (usually, it’s a



hospital lab). We keep several of these mini-cultures in our offices. Once we do the culture, one of our staff drives it over to the local hospital laboratory for processing. We get staining results (i.e., gram-positive or gram-negative) in about a day, and culture results in three to four days. Mini-Tip Culturette is available from multiple sources, including the following:

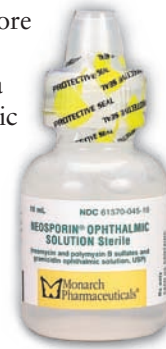- eGeneral Medical, Inc., Raleigh, NC (609-848-8890 or [www.egeneralmedical.com](http://www.egeneralmedical.com))
- Hardy Diagnostics, Santa Maria, CA (800-266-2222 or [www.hardydiagnostics.com](http://www.hardydiagnostics.com))

**Q: What about the statement years ago that 10% of all patients are allergic to neomycin?**

**A:** It may be more like 5% to 8%, but yes, neomycin can

rarely cause an allergic reaction. These are not acute anaphylactic reactions, but are type 4 delayed hypersensitivity reactions. While still rare, they are more likely to be seen when neomycin is used in a combination antibiotic, as opposed to being used in combination with a corticosteroid. The reason: the steroid is most likely to suppress the type 4 reaction were it to occur. The neomycin hypersensitivity reaction is more of an annoyance or bother, rather than a significant therapeutic misadventure.

For our patients who are indigent or self-pay, we commonly prescribe generic Maxitrol (neomycin/poly-



myxin B/dexamethasone). It is quite inexpensive, and we have yet to have an issue with it when used short-term; however, a hypersensitivity response is certainly possible. If it does occur, stop the antibiotic and use cold compresses for a day or two.

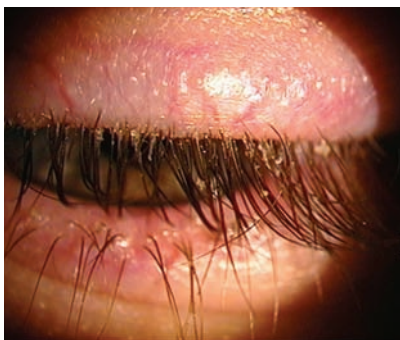**Q: When prescribing erythromycin for blepharitis, is it still advised to limit its use to a maximum of 14 days because of the potential development of bacterial resistance?**

**A:** Yes, this is true. However, we usually use bacitracin or Polysporin (bacitracin with polymyxin B) because the bacitracin more effectively eradicates *Staph.*



## Topical Antibiotic Drugs

BRAND NAME	GENERIC NAME	MANUFACTURER	PREPARATION	PEDIATRIC USE	BOTTLE/TUBE
<b>Fluoroquinolones</b>					
Besivance	besifloxacin 0.6%	Bausch + Lomb	suspension	≥ 1 yr.	5ml
Ciloxan, and generic	ciprofloxacin 0.3%	Alcon, and generic	sol./ung.	≥ 1 yr./ ≥ 2 yrs.	5ml, 10ml/3.5g
Iquix	levofloxacin 1.5%	Vistakon Pharm.	solution	≥ 6 yr.	5ml
Moxeza	moxifloxacin 0.5%	Alcon	solution	≥ 4 mos.	3ml
Ocuflox, and generic	ofloxacin 0.3%	Allergan, and generic	solution	≥ 1 yr.	5ml, 10ml
Quixin	levofloxacin 0.5%	Vistakon Pharm.	solution	≥ 1 yr.	5ml
Vigamox	moxifloxacin 0.5%	Alcon	solution	≥ 1 yr.	3ml
Zymar	gatifloxacin 0.3%	Allergan	solution	≥ 1 yr.	5ml
Zymaxid	gatifloxacin 0.5%	Allergan	solution	≥ 1 yr.	2.5ml
<b>Aminoglycosides</b>					
Tobrex, and generic	tobramycin 0.3%	Alcon, and generic	sol./ung.	≥ 2 mos.	5ml/3.5g
Genoptic, and generic	gentamicin 0.3%	Allergan, and generic	sol./ung.	N/A	5ml/3.5g
<b>Polymyxin B Combinations</b>					
Polytrim	polymyxin B/trimethoprim	Allergan, and generic	solution	≥ 2 mos.	10ml
Polysporin	polymyxin B/bacitracin	Monarch, and generic	unguent	N/A	3.5g
Neosporin	polymyxin B/neomycin/gramicidin	Monarch, and generic	sol./ung.	N/A	10ml/3.5g
<b>Other Antibiotics</b>					
AzaSite	azithromycin 1%	Inspire Pharm.	solution	≥ 1 yr.	2.5ml
Ilotycin, and generic	erythromycin 0.5%	Dista, and generic	unguent	≥ 2 mos.	3.5g
AK-Tracin, and generic	bacitracin 500u/g	Akorn, and generic	unguent	N/A	3.5g



**Manage blepharitis with good eyelid hygiene using eyelid scrubs, not baby shampoo.**

species than does erythromycin. If there is significant associated eyelid margin inflammation, we would consider an antibiotic/steroid combination drug q.i.d. for two weeks, rubbing the excess drop along the eyelid margin at each instillation.

Remember, blepharitis is almost exclusively managed via lifelong meticulous eyelid hygiene. We only use medicines to jumpstart the process for two or three weeks.

We have totally abandoned the baby shampoo approach, and now use commercially available eyelid foam scrubs. Once the lids are calm and clean, most patients need to continue with adequate lid scrubs two to four times a week to maintain healthy tissues.

**Q: In India and Tibet, cataract surgeries are done with minimal antibiotic use, but with good cleaning of the surgical area before surgery. Would you please comment on this?**

**A:** There are no scientific studies to our knowledge that support the need for antibiotics in concert with modern cataract surgery. To wit, these practices from afar clearly support this, assuming uneventful outcomes of those surgeries. The only proven effective maneuver is the use of 5% Betadine for two minutes prior to surgical entry into

the eye. It would be nice to see such a study, for we think its findings might guide us to stop using antibiotics unnecessarily; however, now that many cataract surgery centers are using generic antibiotics in their postoperative care, cost is minimal and no harm is done. New industry guidelines have brought the “postop kit wars” to an end, and this has significantly diminished the financial burden to the patient to purchase expensive medicines in order for the surgery center to get free (or at least cheap) kits.

**Q: What is the best antibiotic regimen for a mucopurulent conjunctivitis in a nursing home environment where methicillin-resistant *Staphylococcus aureus* bacteria is prevalent?**

**A:** Four choices: Besivance q2 hours (the DuraSite vehicle precludes the need for more frequent instillation); generic Polytrim q1 hour initially; generic tobramycin q1 hour initially; or generic Polysporin ophthalmic ointment instilled q3 to q4 hours and q h.s.

After using one of these medicines at the stated frequency of instillation for three or four days, it should be possible (assuming clinical improvement) to reduce the frequency of instillation by half for

another four to five days. By that time, the patient should be better.

**Q: Are there “standard-of-care” issues with older meds?**

**A:** We are not aware of any clinical or medicolegal issues with using older medicines that are effective. As stated above, many cataract surgical centers now use a generic antibiotic (usually tobramycin or the combination of trimethoprim with polymyxin B), a generic corticosteroid (usually prednisolone acetate 1%), and generic diclofenac. If there were such concerns, this practice would not be embraced.

On a broader note, and from an oral antibiotic perspective, note that the CDC/FDA-recommended drugs for systemic MRSA infections are: (1) trimethoprim/sulfamethoxazole (Bactrim or Septra); (2) doxycycline; (3) clindamycin. All of these are “older” medicines that are generically available. This latter observation probably best answers your question.

**Q: If vancomycin is effective against methicillin-resistant *Staphylococcus aureus* infection, why isn't it used to treat all MRSA infections?**

**A:** It is virtually impossible to know the nature of the bacterial pathogen without culturing. Vancomycin must be sterilely compounded, and is not commercially available, so it is not an easily accessed drug. Also, the aminoglycosides, besifloxacin, and trimethoprim with polymyxin B are quite effective against MRSA species.

With any advanced bacterial infection, any antibiotic should be used frequently until

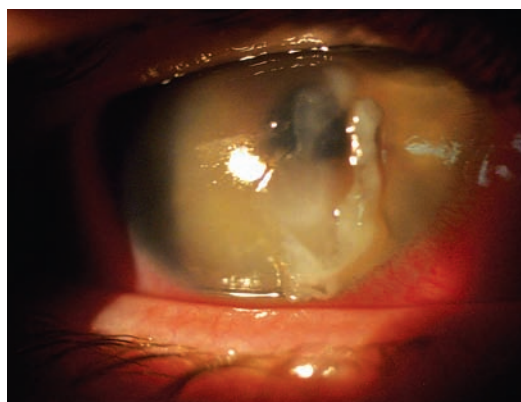


Photo: Paul Karpecki, O.D.

**For mucopurulent conjunctivitis (including MRSA infection), several topical antibiotic options are currently available.**

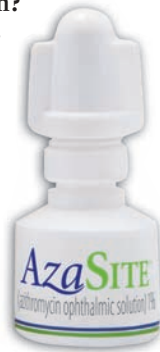the infection is controlled, then dropped to about half that frequency for several more days before stopping treatment.

**Q: What is your experience with using topical ophthalmic azithromycin (AzaSite, Inspire) for meibomian gland dysfunction?**

**A:** A thorough reading of the literature on this topic describes “plugged, inspissated, constipated glands.” Furthermore, the literature consistently discusses the therapy for meibomian gland dysfunction as aggressive warm soaks followed by glandular expression—two technically challenging maneuvers. Given these two clinical realities, a learned individual would rationally ask how any topical ophthalmic medication could gain access into these glands in sufficient concentration to affect a clinically meaningful therapeutic response.

Still, anecdotal reports and at least one clinical study have shown some success with topical azithromycin in relieving signs and symptoms and restoring the normal lipid properties of meibomian gland secretion.<sup>1</sup>

However, keep in mind that AzaSite is not clinically indicated by the FDA for meibomian gland dysfunction, and in its phase II clinical trials, it did not show any improvement compared to its vehicle in the treatment of blepharitis. (Indeed, the FDA recently sent a warning letter to Inspire because AzaSite’s advertising claims it “delivers significant anti-inflammatory effects, when this has not been demonstrated by substantial evidence or substantial clinical experience,” the FDA says.<sup>2</sup>) In our experience, oral doxycycline appears more effective.



In a year or two, it is anticipated that a physical device to heat and massage these glands as an in-office procedure will be approved and this will parallel the advent of antibiotics for infectious diseases in the setting of meibomian gland dysfunction. (See “New MGD Device on the Way,” page 13A.)

**Q: Is it okay to have patients use bacitracin OTC for blepharitis? It says “Not For Ophthalmic Use” on the OTC tube of bacitracin.**

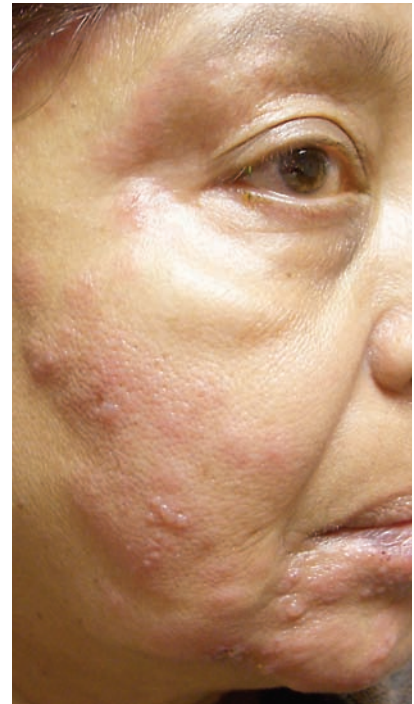**A:** Yes, it is okay. An “ophthalmic” ointment generally comes in a 1/8 ounce tube with a nozzle-shaped tip. Beyond this, we typically find that a combination antibiotic-steroid medication—such as Zylet, TobraDex, or generic neo-poly-dex (generic Maxitrol) used q.i.d. for two or three weeks then perhaps b.i.d. for two more weeks (along with eyelid hygiene maneuvers)—helps more than a pure antibiotic. Of course, it is standard procedure to have these patients back in three to four weeks to assess the clinical result and to monitor the intraocular pressure.

**Q: For patients with herpes zoster, do you ever prescribe antibiotic ointment to rub over the zoster skin lesions in an attempt to prevent secondary bacterial infection?**

**A:** Yes. Over-the-counter Polysporin ointment applied two to three times a day works well.

**Q: Could 5% Betadine be helpful in the setting of acute bacterial conjunctivitis? (For comparison, see Betadine discussion in “Antivirals,” page 26A?)**

**A:** Probably, but we would employ Betadine only if the infection were rather pronounced. We have plenty of good topical antibiotics to arrest bacteria, so other ancillary maneuvers are rarely indicated.



**Patients with herpes zoster skin lesions may apply Polysporin antibiotic ointment to prevent secondary bacterial infection.**

In summary, the topical antibiotics are grossly overutilized—in optometry, ophthalmology and general medicine. Make every effort to pinpoint an accurate diagnosis (which, in most cases of acute red eye, is not of bacterial etiology), and then select an appropriate drug or drug class to achieve renormalization of tissues.

In our 60 years of experience, we have found the frequency of instillation is almost always more important than the drug selected.

We are fortunate to have such an awesome arsenal of medicines available to treat bacterial infections. Use them wisely, judiciously—and aggressively when indicated. ■

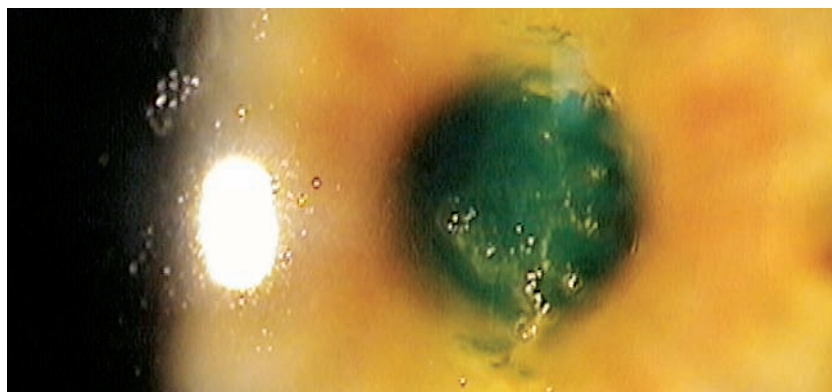
1. Foulks GN, Borchman D, Yappert M, et al. Topical azithromycin therapy for meibomian gland dysfunction: clinical response and lipid alterations. *Cornea*. 2010 Jul;29(7):781-8.

2. Davis CC. Letter to Inspire Pharmaceuticals. 2011 April 14. Available at: [www.fda.gov/Drugs/GuidanceComplianceRegulatoryInformation/EnforcementActivitiesbyFDA/WarningLettersandNoticeofViolationLetters/PharmaceuticalCompanies/ucm252369.pdf](http://www.fda.gov/Drugs/GuidanceComplianceRegulatoryInformation/EnforcementActivitiesbyFDA/WarningLettersandNoticeofViolationLetters/PharmaceuticalCompanies/ucm252369.pdf).

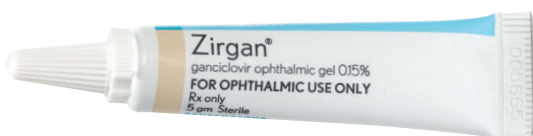# Antiviral Strategies

In addition to the Betadine treatment for epidemic keratoconjunctivitis (EKC), we now have a ganciclovir gel that is as effective as trifluridine, but much easier to use.

**A**s introduced in this drug guide last year, Zirgan (ganciclovir gel, Bausch + Lomb) is a major upgrade to the 30-year-old trifluridine. Its main advantage from the patient's perspective is the less frequent dosing schedule: only five times a day for four to five days and then three times a day for four to five days—as opposed to Viroptic (trifluridine, Monarch) every two hours for four to five days and then four times a day for four to five more days.



**An estimated 50,000 new or recurrent cases of herpes simplex keratitis are seen each year in the United States.<sup>1</sup> Here's one of them now!**



From the doctor's perspective, ganciclovir is viral specific, which means much less potential for epithelial toxicity, and because it

does not require pharmacy refrigeration, it should be more readily available.

Lastly, as a brand name-protected drug, samples are available to start therapy immediately in the event the pharmacy does not have the 5g tube in stock.

**Q:** When you leave the Betadine on the ocular surface for one minute, how do you take it off?

**A:** Betadine 5% Sterile Ophthalmic Prep Solution (povidone-iodine, Alcon) is used thousands of times each workday to prep human eyes for cataract surgeries. The package insert states to leave it on the eye for two minutes for this indication. However, we have found that 60 to 90 seconds of exposure beautifully eliminates active adenoviral replication.

We instill three or four drops, and ask the patient to roll the eyes around to distribute the medicine thoroughly over the ocular surface tissues. (Use good, courteous hygienic technique so that any drug overflow does not run down

## Topical Antiviral Options

### Trifluridine

- Old drug
- Indiscriminate expression
- Potentially toxic
- More frequent dosing
- Refrigerate until opened
- Thiomersal preserved
- Solution (7.5ml bottle)
- Viroptic (Monarch) and generic

### Ganciclovir

- New drug
- Infected cell-specific
- Minimally toxic
- Less frequent dosing
- No refrigeration needed
- BAK preserved
- Gel (5g tube)
- Zirgan (Bausch + Lomb)

the patient's face and/or stain their clothing.) After 60 to 90 seconds, we lavage the ocular surface for a few seconds with any sterile irrigating saline solution (again using thoughtful technique not to have water run down the face, neck, onto clothing, etc).

**Q: Is the Betadine EKC treat-**

**ment good to use if the patient has had EKC for two or more weeks?**

**A:** Like the oral antivirals, which are maximally effective when used within the first three days of the infectious process, they are still somewhat effective if used up to a week out. The natural history of most virulent adenoviral serotypes (those that cause clinically significant con-

junctivitis, i.e., EKC) is about eight days of latency, then about eight days of acute infection and, if not treated, subepithelial infiltrates can begin to form after approximately eight more days.

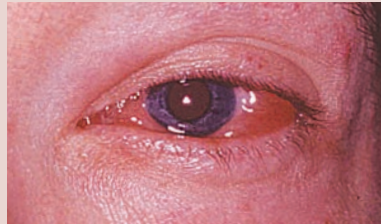
So, two weeks, huh? At this stage, the body's natural defenses should have the infectious phase pretty well controlled, so the an-

## The EKC-Betadine Protocol

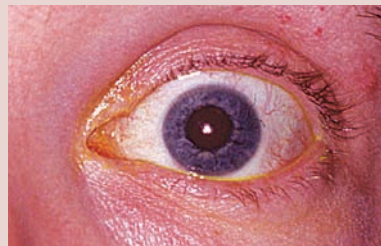
When we encounter a patient with moderate to advanced EKC, we generally use the following protocol:

- By history, rule out any allergy or sensitivity to iodine, the molecular backbone of Betadine.
- Instill a drop of 0.5% proparacaine into the eye(s), since Betadine can sting upon instillation.
- Because Betadine can cause mild stippling to the corneal epithelium resulting in marked stinging, instill a drop or two of a topical NSAID prior to instillation of the Betadine.
- Now instill four to six drops of Betadine into the eye(s).
- Ask the patient to gently close the eyes and roll them around to ensure thorough distribution of the Betadine across the ocular surfaces.
- After one minute, lavage out the Betadine (to avoid any unnecessary toxicity and discoloration of the tissues) with any sterile ophthalmic irrigating solution. Note: The package insert states to leave the 5% Betadine in contact with the ocular surface for two minutes (when prepping for intraocular surgery); however, our experience in the treatment of EKC has been that one minute of contact is sufficient.
- Just for good measure, instill another drop or two of the NSAID (or even proparacaine if the patient has any discomfort).
- Add a potent corticosteroid q.i.d. for four days.

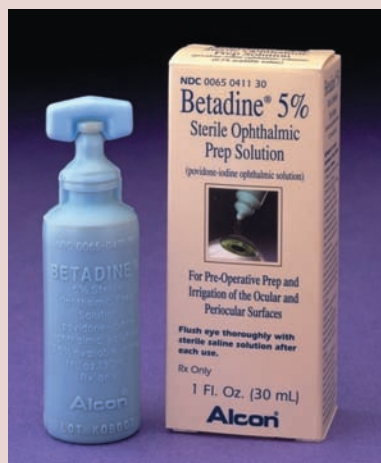Since using this protocol, we have not had a patient to go on to develop the legendary subepithelial infiltrates. We reason that by rapid diminution and/or elimination of live virus from the ocular surface, there is insufficient time for enough viral particles to migrate into the anterior stromal tissues to incite an immune response.



**This patient presented with severe EKC.**



**Two days after treatment with Betadine, his eyes were white and quiet.**



## Povidone-Iodine in Perspective

“Because of its spectrum of micro-biocidal activity, PI [povidone-iodine] is used widely in ophthalmology to prepare the eyelids, eyelashes, and conjunctiva before intraocular surgery to decrease the risk of endophthalmitis.”<sup>1</sup>

“Povidone ... serves as a carrier to deliver iodine. Povidone is used widely ... in many hairsprays, cosmetics, and pharmaceuticals.”<sup>1</sup>

“No cases of anaphylaxis related to ophthalmic use of PI have been reported.”<sup>1</sup>

“Seafood allergy does not equate to an iodine allergy and is not a contraindication to the use of topical PI.”<sup>1</sup>

Also note, Betadine is used in just-born infants to prevent ophthalmia neonatorum: “Topical azithromycin is likely as effective for the important causes of ophthalmia neonatorum as its fellow macrolide erythromycin ... A controlled clinical trial comparing erythromycin 0.5%, povidone-iodine 2.5%, and silver nitrate 1% for ophthalmia neonatorum prophylaxis demonstrated that povidone-iodine was more effective than the other agents for preventing infectious conjunctivitis, including chlamydial conjunctivitis ... We believe povidone-iodine would be a suitable and perhaps preferable alternative to azithromycin for ophthalmia neonatorum prophylaxis.”<sup>2</sup>

1. Wykoff CC, Flynn HW Jr, Han DP. Allergy to povidone-iodine and cephalosporins: the clinical dilemma in ophthalmic use. *Am J Ophthalmol.* 2011 Jan;151(1):4-6.

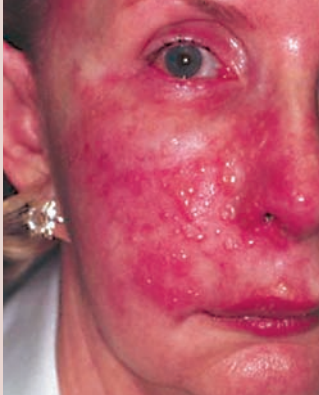2. Keenan JD, Eckert S, Rutar T. Cost analysis of povidone-iodine for ophthalmia neonatorum prophylaxis. *Arch Ophthalmol.* 2010 Jan;128(1):136-7.

# Antiviral Drugs

## What is Zostavax?

Zostavax vaccine (live zoster virus vaccine, Merck) is the adult form of Varivax vaccine (live varicella virus vaccine, Merck).

Varivax is used to inoculate children at least one year of age for the prevention of chickenpox. Zostavax is used in older adults to



**While most cases of facial shingles are first division, here is a more rare second division expression of shingles.**

try to prevent or dampen the expression of recurrent varicella infection (shingles).

Zostavax is an intramuscular injection vaccine of attenuated varicella zoster virus. It is approved for patients over age 50 to diminish the risk of contracting shingles. Note the words “diminish the risk,” because this vaccine only reduces the risk of getting shingles by about 50%; but for those older adults who do contract shingles after having the vaccine, the clinical expression is relatively

subdued. Also note that the FDA guideline reduced the approved age for injection of this vaccine from 60 to 50 in March 2011.

The question always arises as to whether an adult who has had shingles should have the Zostavax vaccination. Keep in mind the natural history of shingles. Once a person has had shingles, the risk of recurrence is somewhere between 2% and 4%. Also bear in mind that having shingles “self-immunizes” the patient, but immunity wanes with time. So, after a person is out five to ten years from the shingles, then perhaps it might be prudent to get the Zostavax vaccine.

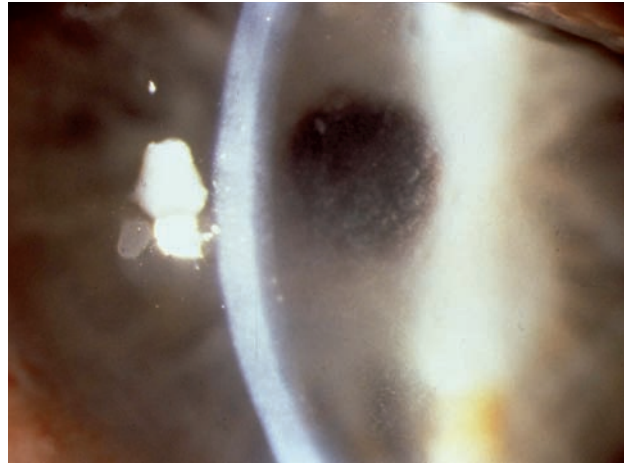
The downside is the cost; this one-time injection costs between \$200 and \$300. However, since shingles can be so debilitating, it seems prudent for optometrists to discuss the Zostavax vaccine with their over-50 patient population, or at the very least encourage your over-50 patients to discuss the vaccine with their primary care givers.

swer is that the 5% Betadine EKC treatment is probably not going to be the best treatment option at this time of presentation. We would recommend instead that a corticosteroid be used q.i.d. for a few days to quiet down any residual secondary inflammation.

Since we have been using the 5% Betadine, none of our EKC patients have developed subepithelial infiltrates. Why? The longer a viral infection resides on the ocular surface, the greater the likelihood that viral antigenic substances can penetrate down into the anterior stromal tissues where immune responses can occur. Because treatment with the 5% Betadine largely

eradicates the viral infection from the ocular surface, there are fewer viral antigen substances to trigger an immune response. Thus, subepithelial infiltrates do not occur.

So, beyond the overall benefit to a patient for a quick cure via early, appropriate 5% Betadine treatment, there can be a marked secondary benefit by



**Herpetic stromal immune keratitis.**

preempting a delayed immune response. This is true for both adenoviral and herpetic infections in that timely intervention with antiviral therapy can bring quick resolution to both herpes simplex epithelial keratitis as well as to virulent strains of adenoviral infection. Rapid eradication of these virus types can prevent or lessen the risk of subsequent stromal immune keratitis (in herpetic disease) and subepithelial infiltrates (in adenoviral infections).

## Q: Is 5% Betadine of any value in the initial treatment of herpes simplex keratitis?

A: Maybe, but we feel little need to use Betadine because there are highly effective antiviral medicines readily available that have proven efficacy in these situations, such as Zirgan, trifluridine or an oral antiviral.

## Q: It is evident that 5% Betadine is a jewel for epidemic keratoconjunctivitis, but what about for children with pharyngoconjunctival fever (PCF)?

A: PCF serotypes generally cause mild, often unilateral conjunctivitis, and are fairly quickly self-limiting. We generally treat these with Alex (loteprednol 0.2%, Bausch + Lomb) q.i.d. for four to six days. More conservative approaches could be artificial tears and an OTC vasoconstrictor for a few days. ■

1. Liesegang TJ. Herpes simplex virus epidemiology and ocular importance. *Cornea*. 2001 Jan;20(1):1-13.

# Combination Drugs

How do you choose when to use a pure steroid vs. a combination drug? If there is significant epithelial compromise, a combination drug will help prevent infection.

As many as half of all red eyes that we see are treated with a combination drug, rather than either a steroid or antibiotic alone. This observation clearly acknowledges two clinical realities:

- The need for topical antibiotics alone is relatively low.
- Almost all acute red eyes have a significant inflammatory component.

So, how does the astute clinician choose between a pure steroid and a combination drug? The answer is relatively straightforward, but, as always, there are exceptions to

generalizations.

The pivotal issue is the integrity of the corneal epithelium. If the corneal epithelium is intact, there is little or no reason for prophylaxis against opportunistic bacterial pathogens. This is because an intact epithelium is itself a firewall of defense. If there is significant epithelial compromise, then a combination drug may perfectly match the clinical need.

Remember that the conjunctiva will be inflamed in any patient presenting with an acute red eye. Simply put, the eye is red because

it is inflamed. Also, the conjunctiva will be inflamed in almost all cases in which keratitis is present. With either keratitis (with an intact epithelium) or non-infectious conjunctivitis, we almost always use a topical steroid.

If the accurate diagnosis of bacterial conjunctivitis is made, the decision is whether to prescribe an antibiotic or a combination drug. The prime determinants are twofold:

1. The severity of the infection.
2. The degree of conjunctival injection.

## Corticosteroid/Antibiotic Combination Drugs

BRAND NAME	MANUFACTURER	STEROID	ANTIBIOTIC	PREPARATION	BOTTLE/TUBE
Blephamide *	Allergan	prednisolone acetate 0.2%	sodium sulfacetamide 10%	susp./ung.	5ml, 10ml/3.5g
Cortisporin *	Monarch	hydrocortisone 1%	neomycin 0.35%, polymyxin B 10,000u/ml	suspension	7.5ml
FML-S	Allergan	fluorometholone 0.1%	sodium sulfacetamide 10%	suspension	5ml, 10ml
Maxitrol *	Alcon	dexamethasone 0.1%	neomycin 0.35%, polymyxin B 10,000u/ml	susp./ung.	5ml/3.5g
NeoDecadron *	Merck	dexamethasone 0.1%	neomycin 0.35%	solution	5ml
Poly-Pred	Allergan	prednisolone acetate 1%	neomycin 0.35%, polymyxin B 10,000u/ml	suspension	5ml, 10ml
Pred-G	Allergan	prednisolone acetate 1%	gentamicin 0.3%	susp./ung.	10ml/3.5g
TobraDex *	Alcon	dexamethasone 0.1%	tobramycin 0.3%	susp./ung.	5ml/3.5g
TobraDex ST	Alcon	dexamethasone 0.05%	tobramycin 0.3%	suspension	2.5ml, 5ml, 10ml
Zylet	Bausch + Lomb	loteprednol 0.5%	tobramycin 0.3%	suspension	5ml, 10ml

**PREGNANCY CATEGORY:** All drugs listed above are Category C.

\* = also available generically.

# Combination Drugs

If the infection presents with marked mucopurulence, we would likely treat with a pure antibiotic, such as moxifloxacin (and perhaps even culture if the infection was severe). If the infectious expression was only mild to moderate, the degree of conjunctival injection would be the overriding issue in choosing between an antibiotic and a combination drug such as **Zylet** (loteprednol/tobramycin, Bausch + Lomb), **TobraDex** or **TobraDex ST** (dexamethasone/tobramycin, Alcon), or **Maxitrol** (dexamethasone/neomycin/polymyxin B, Alcon). We stress again that bacterial infection is uncommon, especially relative to the numerous expressions of non-infectious conjunctivitis.

An exception is the patient who presents with what appears to be a low grade bacterial conjunctivitis (i.e., minimal discharge), yet with moderate to marked conjunctival injection. The patient usually complains that the affected eye was “stuck together when I woke up.” Commonly, by the time the patient arrives at your office, any excess debris may have been cleaned from the lids and lashes. Further, blinking has moved considerable mucopurulent debris down the nasolacrimal system so that the objective slit lamp find-

ings reveal only minimal micro-particulate debris in the lacrimal lake; a clear, non-staining cornea; and/or a red eye. Here is where a combination product is used mainly to address the conjunctival inflammation, while concurrently eliminating any infectious component, even when the cornea is uninvolved.

When there is significant corneal epithelial compromise, we almost always use a combination drug. For most cases, the choice of drug class is that simple.

The first blockbuster, highly effective combination antibiotic/corticosteroid was Maxitrol, containing neomycin, polymyxin B and dexamethasone. Maxitrol became a real workhorse in primary eye care. However, the occasional neomycin reaction, while not a major issue, prompted investigation into a “new and improved” combination drug.

Thus was born TobraDex, which replaced the neomycin and polymyxin B with tobramycin. This drug, like Maxitrol, enjoyed market dominance, though from time to time, and again not a major issue, intraocular pressure increases

prompted an investigation into a “new and improved” combination drug.

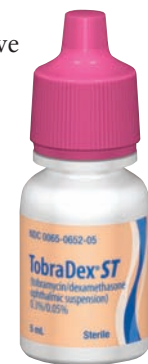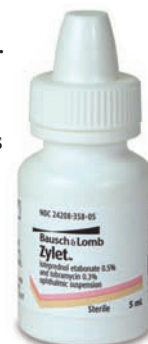
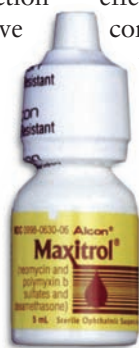
Thus was born Zylet. Keeping the highly efficacious tobramycin, the dexamethasone was replaced with a newer generation, ester-based corticosteroid, loteprednol. Now with Zylet, we have excellent antibiosis along with the safety and potency of loteprednol. It is available in 5ml and 10ml bottles.

More recently we have TobraDex ST, which contains the same concentration of tobramycin (0.3%) but half of the dexamethasone (0.05%) of the original TobraDex. The vehicle of TobraDex ST contains xanthan gum, a thickening agent that allows the lower concentration of the medication to be as effective because it provides a longer residence time on the ocular surface. Indeed, at least one head-to-head study has shown that TobraDex ST has greater in vitro bactericidal activity and higher relative tissue concentrations for the conjunctiva, cornea and aqueous humor compared to TobraDex.<sup>1</sup>

With these considerations in mind, let's talk about specific occasions when a combination drug may (or may not) be necessary.

**Q: Is a bandage contact lens appropriate for thermal (curling iron) keratitis?**

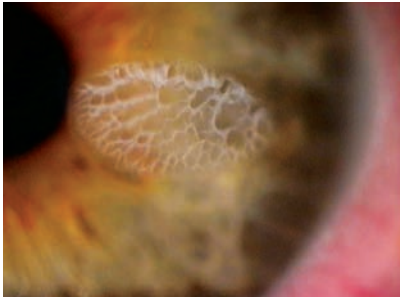
**A:** It depends on the extent of tissue compromise. For deeper epithelial burns where there is much positive fluorescein staining, a bandage lens (any silicone hydrogel lens will work fine) along with an



## Pearls for Using Combination Drugs

- Any time that you see any process at or near the limbus, it is inflammatory in nature. Herpetic infection can present at this area, but will typically be linear (as opposed to oval) in morphology.
- In any acute, unilateral red eye with a serous discharge, be sure to rule out herpetic keratitis.
- Never (or rarely) taper combination drugs below q.i.d. because subtherapeutic levels of antibiotic set the stage for antibiotic resistance.
- In the context of a red eye with a mild secondary iritis, instill a short-acting cycloplegic agent, particularly if a pure antibiotic is used. A combination product will generally eliminate such an iritis without the need for a cycloplegic, though this is a fine clinical point.





**Curling iron burn (thermal keratitis).**

antibiotic-steroid every two hours to q.i.d. would be reasonable.

Bear in mind that this condition is first and foremost an inflammatory keratoconjunctivitis, and the employment of a steroid (in combination with a prophylactic antibiotic) is essential to achieve rapid restoration of these compromised tissues.

For more superficial burns, we would just use a combination drug without a bandage lens.

**Q: What would happen if a corneal ulcer were treated with an antibiotic-steroid combination?**

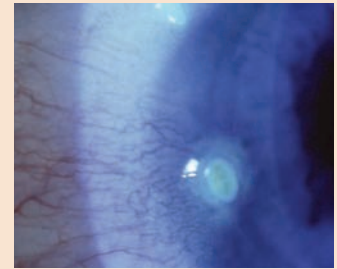
**A:** One of many things could occur, assuming we are talking about a true bacterial infection of the cornea and *not* a sterile peripheral infiltrate. If the infection was caught early and the causative bacterial were susceptible to the antibiotic, and if the drop were instilled every one to two hours, then the antibiotic would likely overwhelm the pathogen.

If, on the other hand, the patient delayed in seeking care, or if the organism were suboptimally susceptible to the antibiotic, or if the frequency of instillation of drops was q.i.d., then disaster could be in the making. The key here is to make a firm diagnosis, choose an appropriate antibiotic, and instill it frequently.

Finally, we tell each patient we medically treat something like this: “This medicine should work

## Phlyctenular Keratoconjunctivitis (PKC)

Most usually seen in young girls, this staphylococcal hypersensitivity response commonly targets the limbal tissues as one or two raised, whitish lesions, which stain lightly with fluorescein. However, in this case (*right*), the phlyctenule has migrated fully onto the cornea with a leash of fine blood vessels. (A sterile infiltrate has a clear, lucid interval between the lesion and the limbus.) A combination drug perfectly treats these peripheral corneal lesions.



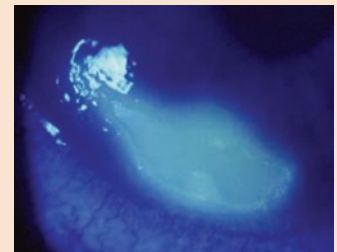
While one would think staphylococcal blepharitis would always be evident, such is not empirically the case. Certainly, if blepharitis is present, initiate proper care, but first treat the inflammatory keratoconjunctivitis. When there is a staining defect at the corneolimbus, a prophylactic antibiotic is counterproductively conservative.

The key clinical feature is the inflammatory component—the eye is red. Use a combination drug every two hours for a day or two, then q.i.d. for four to six days, and stop.

## Staph. Marginal “Ulcers”

Much more appropriately called “peripheral inflammatory epithelial defects,” these are uncommon events that have a similar pathophysiology to PKC and sterile infiltrates.

In these cases, the staphylococcal exotoxins begin to erode a section of the peripheral corneal epithelial tissues. The eye is red with accentuation of a sector of bulbar conjunctival inflammation adjacent to the affected cornea. The foci of compromised epithelium stains brightly with fluorescein dye. There may be a few cells in the anterior chamber. The epithelium is broken down as a result of the underlying anterior stromal inflammatory process, thus causing retrograde compromise to the overlying epithelium.



Once this subepithelial inflammation is subdued by the corticosteroid component in a combination drug, re-epithelialization is potentiated.

An antibiotic alone in this case is almost worthless. While an antibiotic can serve to protect against opportunistic bacterial potential, it will do nothing to curb the inflammatory process.

As with PKC, a combination corticosteroid/antibiotic product is perfectly suited to address the inflammatory process while simultaneously guarding the cornea against the possibility of bacterial infection.

Therapeutic management is as described for PKC, above.

quickly to make your eye better. If you are not improved in a couple of days, or if your symptoms become worse, be sure to come back to see me right away.”

Of course, when treating a true corneal ulcer (which is a rare occurrence), we see the patient daily until we are certain the condition is controlled. After a few days of successful antibiotic therapy, we often

do in fact add a steroid q.i.d. to help diminish corneal scarring.

In summary, we encourage the reader to limit the prescribing of an antibiotic for the gamut of red eyes, and recognize that most red eyes are inflammatory in nature. ■

1. Scoper SV, Kabat AG, Owen GR, et al. Ocular distribution, bactericidal activity and settling characteristics of TOBRADEX ST Ophthalmic Suspension compared with TOBRADEX Ophthalmic Suspension. *Adv Ther.* 2008 Feb;25(2):77-88.

# Clinical Update on the NSAIDs

There are four star players in the field of ‘nonsteroidal anti-inflammatory drugs.’ Older drugs have been reformulated and new drugs have come to market.

Compared to topical corticosteroids, NSAIDs have a limited role in primary eye care. Nonetheless, there are several situations where NSAIDs can be beneficial.

There is a partial disconnect between topical and systemic administration. Systemic NSAIDs are true to their name and do indeed render a marked anti-inflammatory effect, whereas topical NSAIDs have their forte in ocular surface pain amelioration while providing some limited activity against inflammation. (See “Uses for Topical NSAIDs,” right.)

Voltaren (diclofenac 0.1%, Novartis) and Acular LS (ketorolac 0.4%, Allergan) have been the standard bearers of

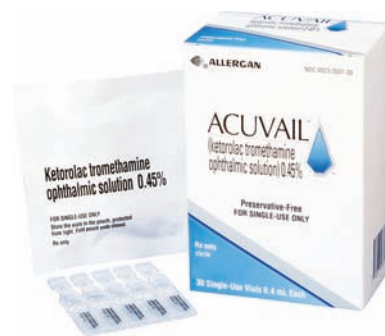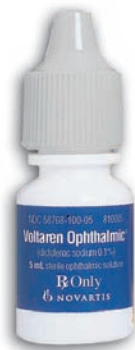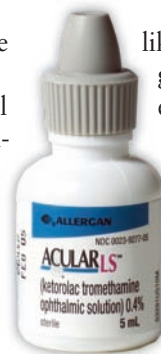
topical NSAID care over the past decade. Both are used q.i.d. and are largely clinical equivalents. One study compared ketorolac and diclofenac head-to-head. Its conclusion: “The decrease in corneal sensitivity in normal human corneas is more pronounced and longer lasting with diclofenac than with ketorolac.”<sup>1</sup>

The most recent modification in ketorolac is the introduction of a 0.45% concentration of ketorolac. Acuvail (Allergan) comes as a preservative-free unit-dose indicated for perioperative use b.i.d. one day prior to cataract surgery, and is continued for two weeks immediately postop.

However, Acuvail is very expensive, and patients would

likely be adequately served with generic diclofenac, or other less expensive NSAIDs.

The original formulation of ophthalmic ketorolac (Acular) was a 0.5% solution, but marked stinging upon instillation was its Achilles heel. The drug was reformulated a few years ago to a 0.4% solution (Acular LS) and is now quite tolerable—a very nice upgrade.



## Non-Steroidal Anti-Inflammatories

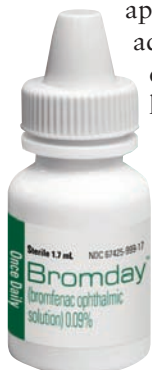BRAND NAME	GENERIC NAME	MANUFACTURER	DOSAGE	PEDIATRIC USE	BOTTLE SIZE(S)
Acular LS	ketorolac tromethamine 0.4%	Allergan	q.i.d.	3 years	5ml
Acuvail	ketorolac tromethamine 0.45%	Allergan	b.i.d.	N/A	unit-dose
Bromday	bromfenac 0.09%	ISTA Pharmaceuticals	q.d.	N/A	1.7ml
Nevanac	nepafenac 0.1%	Alcon	t.i.d.	10 years	3ml
Voltaren	diclofenac sodium 0.1%	Novartis	q.i.d.	N/A	2.5ml, 5ml

In the recent past, two more NSAIDs have come to market. They are **Nevanac** (nepafenac 0.1%, Alcon) and **Bromday** (bromfenac 0.09%, ISTA), which replaces twice-daily **Xibrom** (bromfenac 0.09%, ISTA).



Nevanac is unique in that it is the first available prodrug. Nevanac is enzymatically converted to amfenac sodium, which, like all NSAIDs, inhibits cyclooxygenase. It is dosed three times a day.

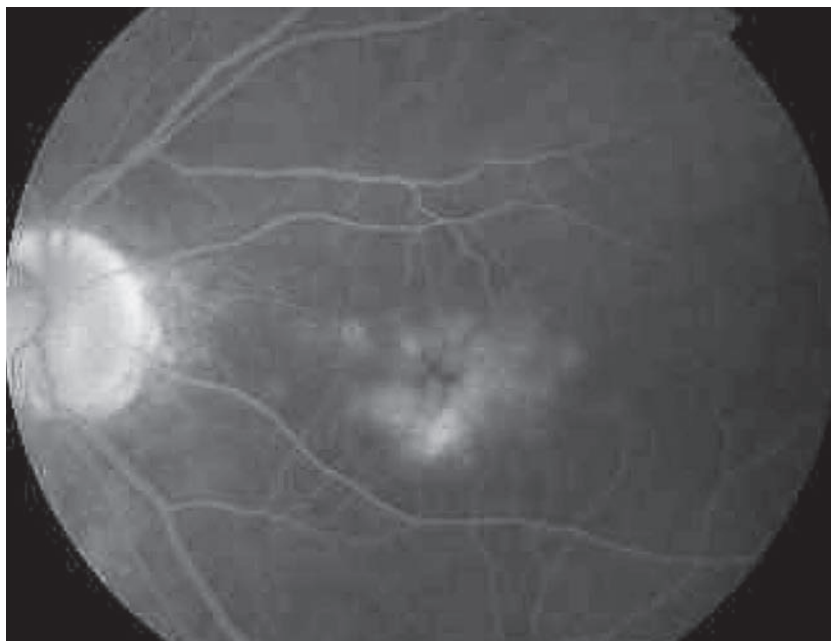
Bromday is unique in that it is the first approved NSAID that is administered only once daily, which should likely aid compliance.



(Incidentally, ISTA is evaluating a new formulation and lower concentrations of bromfenac called Remura for the potential treatment of dry eye, which is now in Phase III clinical studies.)

All these drugs are generally approved by the FDA for treating postoperative inflammation, and as such, will be used much more in a surgical context. Ketorolac is also approved to treat ocular allergy, and there are a number of other applicable uses for NSAIDs relevant to primary eye care, as enumerated above.

Because of the rare, but real, potential for corneal toxicity and melting, these drugs should be used cautiously when there is preexisting corneal epithelial compromise. As a general rule, we never prescribe any topical NSAID for use beyond one week—with the exception of CME, which we treat with a topical NSAID for a month, concurrent



**An extensive review of the world literature concludes that prevention and treatment of cystoid macular edema with NSAIDs is beneficial.**

**Q: Which NSAID do you prefer for dampening ocular surface pain, and at what dosage?**

**A:** Our preference is Bromday (bromfenac, ISTA) because it has a long half-life, and therefore needs to be dosed only once daily. However, it is very expensive.

So, when cost is a concern, we use generic diclofenac q.i.d., because it is inexpensive and works well.

with Pred Forte.

While steroids are often initially dosed as frequently as hourly for a few days, we strongly urge that NSAID use not exceed the FDA-approved dosing frequency.

In summary, there are several off-label uses for NSAIDs within the context of primary eye care. Their main use is in the prevention or treatment of cataract surgery-related cystoid macular edema concurrent with a potent corticosteroid. ■

1. Seitz B, Sorken K, LaBree LD, et al. Corneal sensitivity and burning sensation. Comparing topical ketorolac and diclofenac. Arch Ophthalmol. 1996 Aug;114(8):921-4.

**Uses for Topical NSAIDs**

The most common conditions for which topical NSAIDs can play an adjunctive beneficial role are:

- Corneal abrasions
- Just before, and just after, in-office Betadine 5% Sterile Ophthalmic Prep Solution treatment for highly symptomatic EKC
- Post foreign body removal
- Adapting to GP contact lenses
- Post anterior stromal puncture procedure
- Post PKP, or any surface disruptive laser procedure
- Treating and/or preventing cystoid macular edema
- Adapting to punctal plugs
- Allergic conjunctivitis
- Supplemental to steroids in treating recalcitrant uveitis
- Some cases of photophobia
- Post cataract surgery care
- Supplemental to oral NSAIDs in treating scleritis
- Treating and/or preventing inflamed pterygia and pingueculae

# Keeping Allergy Management Simple

Allergy management can be straightforward. For ocular itching, use OTC ketotifen. If there are also signs, add a steroid to quiet the eye.

Ocular allergy treatment is pretty straightforward: Treat with a topical (preferably OTC) antihistamine/mast cell stabilizer if the eye is white and quiet, and symptomatic itching is the chief complaint. If there are signs, such as conjunctival injection with or without chemosis accompanying the itching, then prescribe loteprednol either 0.2% or 0.5% depending upon the magnitude of the disease expression.

Making more of this condition and its treatment is like trying to make a mountain out of a molehill.

We have many topical allergy options to choose from, and we now add one more: Lastacraft (alcaftadine 0.25%, Allergan), which has the benefit of once-daily dosing. Alcaftadine is a new chemical entity with an affinity for H<sub>1</sub>, a histamine receptor associated with the early phase of allergic conjunctivitis.

Now that we know our options, let's look at our challenges.

**Q: Can any of the topical NSAIDs other than ketorolac (Acular LS, Allergan) be used for treating ocular allergy?**

**A:** All the NSAIDs, both topical and oral, work by inhibiting

the enzyme cyclooxygenase (which catalyzes the syntheses of prostaglandins). So we see no reason why this would not be a class effect. However, inhibiting the synthesis of prostaglandins in the setting of a histamine-mediated clinical condition is relatively counterintuitive to the use of a topical antihistamine. We long ago abandoned the use of NSAIDs in favor of the antihistamine/mast cell stabilizing drugs when treating ocular allergy. But, to your specific question, the answer is an untested "yes."

**Q: I was told Emadine (emedastine, Alcon) was the drug of choice for pet allergies. What is your opinion about this?**

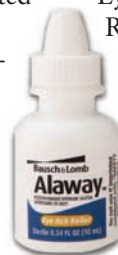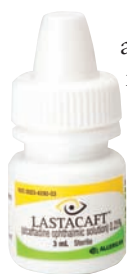**A:** Emadine is the only pure ophthalmic antihistamine in the United States market; all the others also have mast cell stabilizing properties. The key to suppressing allergy is to block the H<sub>1</sub> (histamine subtype I) receptor. This terminates the cellular processes that result in itching. Since both Emadine and all the other antihistamine eyedrops perform this task, it is likely advantageous to use a medicine that also stabilizes the mast cell membranes. Because there are no head-to-head studies, we cannot say with total certainty,

but we think that one of the later generation antihistamine/mast cell stabilizers would be an excellent choice to treat any and all types of allergy expressions.

**Q: Did you say that the OTC vs. Rx allergy drops work the same?**

**A:** There are two main types of OTC allergy eye drops: the antihistamine/vasoconstrictors, such as Naphcon-A, Opcon-A, etc., and the antihistamine/mast cell stabilizers represented by ketotifen, of which there are numerous brand names such as Zaditor (Novartis), Alaway (Bausch + Lomb), Claritin Eye (Schering-Plough), Refresh Allergy (Allergan), etc.

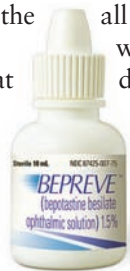Because the older antihistamine/vasoconstrictors are short-acting and cause blood vessel constriction, rebound hyperemia can occur—similar to the chronic use of nasal decongestants such as Afrin—so these are not recommended. Indeed, it has been our experience that chronic use of these eye drops is a fairly com-



mon cause of chronic conjunctivitis. Our observation is that most of the chronic users have primary dry eye, which leads to secondary low-grade conjunctival injection, which results in the patient behavior of purchasing OTC “get-the-red-out” type eyedrops.

Regarding the more contemporary antihistamine/mast cell stabilizing drops, their performances are all extremely similar; in our experience, there is no clinically significant difference between the OTC antihistamine/mast cell stabilizing drops and those that still require a prescription.

Given this, we look to the cost of these medicines, and because ketotifen is OTC and very inexpensive, we routinely recommend it. Within both prescription and OTC options, bottle size is another consideration that has a marked impact on the



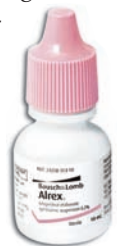value to the patient. Prescription bepotastine (Bepreve, ISTA) and OTC ketotifen (specifically Alaway) are both available in 10ml bottles (compared to 5ml bottles for the others), and therefore would offer the greatest value to our patients. These two medicines, and the other antihistamine/mast cell stabilizers, can be used b.i.d. for a week or two; after that time, once-daily administration can usually maintain absence of itch for virtually all patients. Especially for patients who are not on a prescription drug plan, the 10ml Alaway is the most cost-effective topical ophthalmic antihistamine/mast cell stabilizer.

**Q: Comment on treating a child under age 10 with severe ocular allergy. Steroids?**

**A:** We will assume you’re speaking of seasonal/perennial allergy,

and not vernal disease. A young child with *severe* allergy most likely also has allergic rhinitis or sinusitis, so your care may need to be done in concert with his/her primary care physician or allergist. We suggest cold compresses for flare-ups, but medical therapy would have to be initiated with loteprednol 0.5%, perhaps as often as every two hours for two or three days to gain control, then try q.i.d. for a week. Once control is firmly established, try reducing to the 0.2% concentration of loteprednol (Alrex) q.i.d. for a week, then b.i.d. for two weeks. If this holds, then try converting to an antihistamine/mast cell stabilizing drug for enduring therapy on a p.r.n. basis.

We would recommend OTC ketotifen, because it is the least expensive of the antihistamine/mast cell stabilizing drugs. ■



## Ocular Allergy Medicine Profile

BRAND NAME	GENERIC NAME	MANUFACTURER	PEDIATRIC USE	BOTTLE SIZE(S)	DOSING
<b>Acute Care Products</b>					
Acular LS	ketorolac tromethamine 0.4%	Allergan	3 years	5ml, 10ml	q.i.d.
Alaway (OTC)	ketotifen fumarate 0.025%	Bausch + Lomb	3 years	10ml	b.i.d.
Alrex	loteprednol etabonate 0.2%	Bausch + Lomb	12 years	5ml, 10ml	q.i.d.
Bepreve	bepotastine besilate 1.5%	ISTA	2 years	10ml	b.i.d.
Claritin Eye (OTC)	ketotifen fumarate 0.025%	Schering-Plough	3 years	5ml	b.i.d.
Elestat	epinastine HCl 0.05%	Allergan	3 years	5ml	b.i.d.
Emadine	emedastine difumarate 0.05%	Alcon	3 years	5ml	q.i.d.
Lastacaft	alcaftadine 0.25%	Allergan	2 years	3ml	q.d.
Optivar	azelastine hydrochloride 0.05%	Meda	3 years	6ml	b.i.d.
Pataday	olopatadine hydrochloride 0.2%	Alcon	3 years	2.5ml	q.d.
Patanol	olopatadine hydrochloride 0.1%	Alcon	3 years	5ml	b.i.d.
Refresh (OTC)	ketotifen fumarate 0.025%	Allergan	3 years	5ml	b.i.d.
Zaditor (OTC)	ketotifen fumarate 0.025%	Novartis	3 years	5ml	b.i.d.
<b>Chronic Care Products</b>					
Alamast	pemirolast potassium 0.1%	Vistakon Pharm.	3 years	10ml	q.i.d./b.i.d.
Alocril	nedocromil sodium 2%	Allergan	3 years	5ml	b.i.d.
Alomide	lodoxamide tromethamine 0.1%	Alcon	2 years	10ml	q.i.d.
Crolom	cromolyn sodium 4%	Bausch + Lomb	4 years	10ml	q.i.d.
Opticrom	cromolyn sodium 4%	Allergan	4 years	10ml	q.i.d.

# Overview of Oral Medicines

Optometrists in 47 states have at least some authority to prescribe oral drugs. Now, it is our task to prescribe thoughtfully and appropriately.

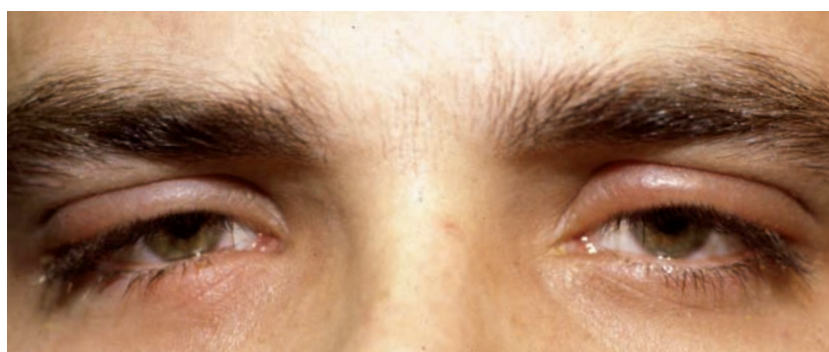**T**here are few oral medicines germane to ophthalmic patient care. The classes most commonly used are antibiotics, corticosteroids, antivirals, analgesics and carbonic anhydrase inhibitors.

Because oral therapy is becoming more widely embraced by doctors of optometry, we want to examine the clinical attributes of these medicines by answering some questions we have been asked regarding oral therapies.

**Q:** When using doxycycline on a chronic basis, are you concerned with killing off the “good bacteria” in the gut? Do you recommend a probiotic to replace the “good bacteria”?

**A:** As a general rule, when treating an active infection with doxycycline, the dosage is 100mg b.i.d. When attempting to improve meibomian gland function, we use “sub-antibiotic” levels, such as 50mg/day. This should spare, or minimally alter, the gut flora.

For those sensitive patients who do encounter GI problems with the oral doxycycline, we would suggest the patient try an OTC probiotic. Be sure to instruct the patient to take the doxycycline with a meal, preferably breakfast.



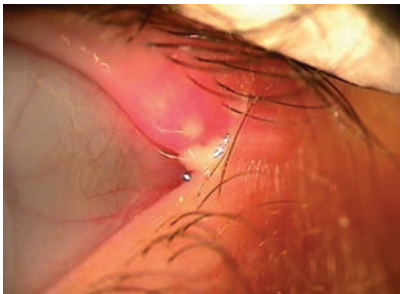
**Can oral azithromycin take the place of oral doxycycline for the treatment of meibomian gland dysfunction? Our dermatologist says to stick with doxy.**

**Q:** The corneal subspecialist we work with just came back from a cornea conference where she heard of using azithromycin 250mg b.i.d. or t.i.d. for a week, instead of oral doxycycline for the treatment of lipid (posterior) blepharitis.

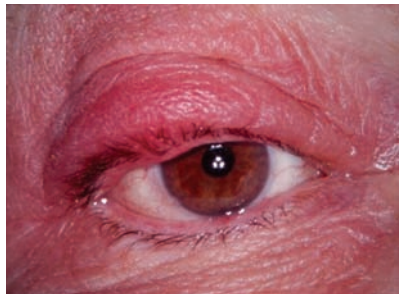
**A:** We have heard of this a time or two ourselves. So we consulted several dermatologists to learn that doxycycline has many more clinically apparent anti-inflammatory properties than azithromycin. Of all medical specialists, dermatology should be the most knowledgeable about how to positively affect intra-epidermal glandular secretions. Ask any dermatologist: Doxycycline reigns supreme in enhancing sebaceous gland function (and meibomian glands are modified sebaceous glands).

Last, keep in mind that meibomian gland dysfunction, like dandruff and arthritis, can be managed, but not “cured.” Many chronic disease processes require daily, weekly or monthly therapeutic maintenance.

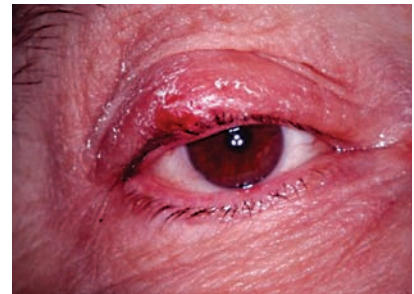
**Q:** Let’s say you have a recalcitrant case of anterior uveitis, where a potent topical steroid and good cycloplegia failed to suppress the inflammation, and you have to augment your therapy with oral prednisone to achieve successful suppression of inflammation. You now begin your oral taper, and when you drop below 20mg of oral prednisone, even with the continuation on hourly topical steroid eye-drops, the uveitis re-flares. Do you have a way to facilitate the taper



**Acute internal hordeolum being decompressed via gentle pressure by a cotton swab.**



**For an internal hordeolum, very warm soaks with a moist washcloth are usually all the treatment needed.**



**When an oral antibiotic is necessary for an infectious hordeolum, we generally prescribe Keflex 500mg b.i.d. for a week.**

and ultimate discontinuation of the oral prednisone?

**A:** That's a complex, really challenging case! Here's what we would do: As you taper the prednisone to the point that you reach the 20mg dose, then add Celebrex (celecoxib, Pfizer) 100mg or 200mg/day or ibuprofen 1,600mg/day. Then we have been successful in tapering off and stopping the oral steroid. We keep up the oral NSAID for another two weeks as we methodically taper down the topical drops.

Obviously, this is a scientific "guessing game" of just how to do this, and must be guided by each individual patient's response, but the general concept should be clear. Patients who are this difficult to treat successfully should have a rather exhaustive systemic workup.

**Q:** What do you prescribe for children with a hordeolum, and at what dosage?

**A:** Most acute meibomian gland infections can be managed with properly administered warm soaks. If the eyelid has been worsening, and if it is particularly tender, then we recommend either erythromycin, Keflex (cephalexin), or trimethoprim with sulfamethoxazole. The dosage can vary depending upon the severity of the condition and the age of the child.

We always consult with a pediatrician, family physician or

pharmacist to have them aid us in determining the pediatric dosage.

We also might choose a liquid as opposed to a pill if the child cannot swallow pills easily. All the above mentioned drugs are also available in liquid form.

**Q:** What oral medicine do you generally use, if any, for acute eyelid infections?

**A:** In our clinical experience, about 25% of patients presenting with acute hordeola (or styes) require oral antibiotic therapy in addition to the aggressive use of warm soaks—warm soaks constitute the foundational underpinning of therapy for any infectious process involving the eyelids.

We urge patients to apply a very warm, moist washcloth to the infected lid (or lids) five to 10 minutes at a time, and to repeat this every couple of hours, as able. We stress that about every 30 seconds, the cloth will need to be quickly reheated and reapplied to the eyelid to keep the heat level at a therapeutically sufficient level.

When an oral antibiotic is deemed appropriate, we generally prescribe Keflex (cephalexin) 500mg b.i.d. for a week. This is almost always successful.

If the patient is truly allergic to penicillin (which shares a slight [5 to 8%] potential cross-allergenicity), we might prescribe an oral

fluoroquinolone, such as Levaquin (levofloxacin) 500mg once daily, or trimethoprim/sulfamethoxazole (Bactrim or Septra) 1 or 2 (Double-Strength) tablets b.i.d. for one week.

**Q:** If a patient has a history of an anaphylactic reaction to aspirin, is the use of another NSAID contraindicated?

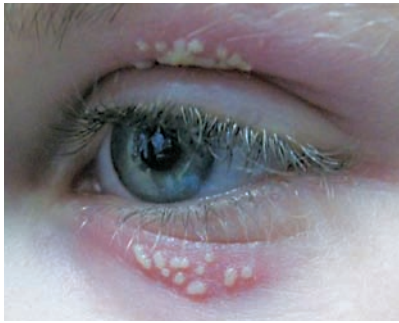**A:** Yes! Aspirin is the prototypic NSAID, and they all share similar antigenic properties. All NSAIDs work by inhibiting the enzyme cyclooxygenase, which catalyzes the production of prostaglandins from arachidonic acid.

## Penicillin and Cephalosporin Cross-sensitivity

- Both penicillins and cephalosporins possess a beta-lactam ring.
- "Cephalosporins are first-line treatments for many infections and are used widely in ophthalmology."
- "More than 90% of patients who report a history of penicillin allergy lack penicillin-specific IgE and can tolerate the antibiotic safely."
- Penicillin allergy "should not prevent the use of second- and third-generation cephalosporins with distinct side chains." These are cefuroxime, cefprozil, ceftazidime and cefpodoxime.

Wykoff CC, Flynn HW Jr, Han DP. Allergy to povidone-iodine and cephalosporins: the clinical dilemma in ophthalmic use. *Am J Ophthalmol.* 2011 Jan;151(1):4-6.

# Oral Drugs



**Primary herpes simplex periorbital dermatitis.**

**Q:** What most helps you distinguish between herpes simplex dermatitis and varicella zoster dermatitis in a patient who is 40 years old?

**A:** Zoster tends to have accompanying skin pain, whereas simplex is relatively painless. The skin lesions of simplex tend to cluster around the eyelid skin, whereas zoster lesions are larger and tend to be more distributed throughout the targeted dermatome.

If you are unsure about the diagnosis, just use the varicella zoster

strength of the oral antiviral—acyclovir 800mg taken 5qd, valacyclovir 1,000mg t.i.d. or famciclovir 500mg t.i.d. Regardless of the drug you choose, it should be taken for one week. Any of these medicines will nicely treat either herpes simplex or herpes zoster infection.

However, if you are confident the infection is simplex (and the dis-

## To Treat Shingles (VZV), Give Double the Dose Used for HSV

Antiviral Drug	Dosing for Varicella Zoster	Dosing for Herpes Simplex
Acyclovir	800mg 5x q.d. x 1 week	400mg 5x q.d. x 1 week
Valacyclovir	1,000mg t.i.d. x 1 week	500mg t.i.d. x 1 week
Famciclovir	500mg t.i.d. x 1 week	250mg t.i.d. x 1 week

## Perspective on Nutritional Supplements

**Face it:** Many Americans have suboptimum lifestyles. Have you ever pondered how many billions of health care dollars could be saved each year if we all would collectively improve our health-related lifestyles? It is well-established that cigarette smoking is only second to increased age as a risk factor for macular degeneration; one is modifiable, one is not! The acknowledgement of this reality is why we daily encourage our smoking patients to have a sincere conversation with their primary care provider regarding programs and medicines to help them stop. We all need to redouble our “encouragement” conversations with our smoking patients. Smoking is also known to be a risk factor for ulcerative keratitis.

Since we are not experts in nutrition—and extremely few physicians are—we are not going to attempt to discuss the molecular basis of nutrition here. We will succinctly discuss the clinically-relevant issues at hand. Realizing the exceedingly poor yield on impacting lifestyle changes, we should still encourage patients to try to be attentive to what they eat and how they live.

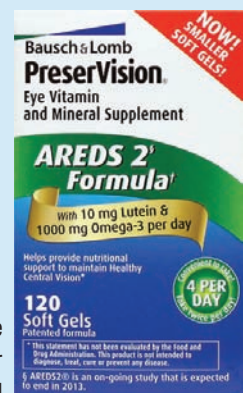
Being realists, we find that many people do indeed have a keen interest in “buying health.” For example, we had a patient recently who said he can now enjoy his cheeseburgers since he’s on a statin drug! This is the mindset we are talking about.

Perhaps this partially explains the public’s embrace of nutritional supplements. This topic can be immensely complex. We don’t do complex. Here’s a consensus of what is known regarding nutrition and the eye. Oxidative stress appears to be the underpinning of tissue demise. Therefore antioxidants, such as vitamins C and E, the carotenoids lutein, zeaxanthin, along with some zinc, and the essential fatty acid constituents, eicosapentaenoic acid (EPA) and docosahexaenoic acid (DHA), seem to share the limelight in the articles we read. Since beta-carotene seems relatively suboptimum to lutein/zeaxanthin in its antioxidant properties, and because of its association with increased risk of lung cancer in

smokers, it is being replaced in some supplements. Also, lutein and zeaxanthin have been shown to increase macular pigment optical density, which can improve visual function, flare recovery and contrast sensitivity. From all we can read, fish oils (preferably the triglyceride form) are clearly beneficial to health, and particularly to eye health. These fish oils contain therapeutic levels of EPA and DHA, which have been shown to be helpful in both macular function as well as enhancing meibomian gland function.

It will be interesting to see the results of the AREDS 2 study when it concludes around 2013. From a consensus of the literature, the combination of vitamins C and E, some zinc, the carotenoids lutein and zeaxanthin, and the long-chain essential fatty acids EPA and DHA may have a keenly therapeutic impact on both the prevention and treatment of AMD. For appropriate patients, it seems rational to recommend a supplement containing these ingredients, until further research reveals perhaps even more effective interventions.

As with any supplements taken by mouth, it is good practice to make the patient’s primary care provider aware of the specifics of any supplement we are asking our patients to take.

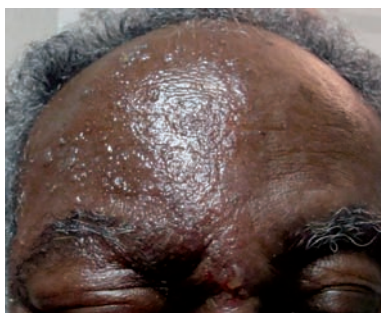




tion is usually straightforward), then use one-half the zoster dose as set forth above.

**Q: Is herpes zoster contagious?**

**A:** Only if a person has never had chickenpox or the Varivax vaccine (varicella zoster live vaccine, Merck) is there any risk to contract the virus. Even in these “at risk” persons, the risk is very slight, and even then only if there is direct skin-to-skin contact with open lesions.

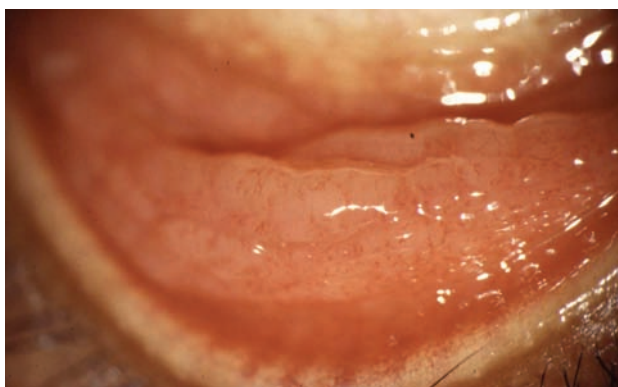


**Shingles (i.e., herpes zoster) is not usually contagious.**

**Q: I had a patient with chlamydial conjunctivitis, and I am convinced it wasn't sexually transmitted. She recalled handling feral kittens with goopy eyes a few weeks previously. Could the chlamydia have been transmitted by handling those kittens?**

**A:** It's possible. Cats can become infected with a form of chlamydia, and in rare instances it can be transferred to humans. Perhaps the best way to find out is to treat with a single 1gm dose of oral azithromycin, and if the patient is much improved in about three days, your etiologic suspicion will be substantiated. If she gets a recurrence weeks to months later, there had better be a wild cat to blame!

Lastly, parakeets also commonly carry chlamydial organisms that can cause a conjunctivitis identical to that seen with sexually transmitted disease, so always be sure to inquire about parakeet exposure in your history. ■



**A patient with chlamydial conjunctivitis. Could a stray cat be to blame? Or perhaps a parakeet?**

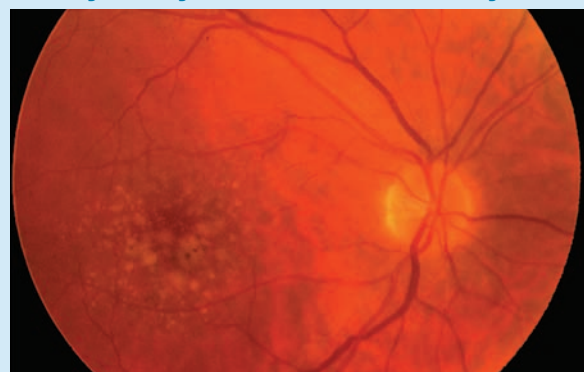
## Vitamin D Protects Against AMD in Women

“Among women younger than 75 years, intake of vitamin D from foods and supplements was related to decreased odds of early AMD in multivariate models; no relationship was observed with self-reported time spent in direct sunlight.

“Conclusion: High serum 25(OH)D concentrations may protect against early AMD in women younger than 75 years.”

Millen AE, Voland R, Sondel SA, et al; for the CAREDS Study Group. Vitamin D status and early age-related macular degeneration in postmenopausal women. *Arch Ophthalmol.* 2011;129(4):481-489.

## Healthy Lifestyles Reduce Risk for Early AMD



“A combination of healthy lifestyle behaviors that includes healthy diet, physical activity, and not smoking was associated with markedly lowered prevalence of early AMD an average of six years later in postmenopausal women. Adopting these healthy habits may markedly lower the prevalence of early AMD, the number of people who develop advanced AMD in their lifetime, and health care costs associated with treatment for this condition.

“These results also serve to remind us that risk for AMD is passed to subsequent generations not only through genes but also possibly through the lifestyle habits we model and encourage. Specifically, we believe that these results, together with current scientific evidence for chronic disease prevention, support recommendations to exercise (move at least at a low intensity for one to two hours per day; outside when possible), avoid smoking, and follow a healthy diet pattern that meets the following criteria: (1) is abundant in plant foods (vegetables [including dark leafy green and orange vegetables], fruits and whole grains); (2) contains daily protein sources in moderation and variety (beans, nuts, fish, dairy, eggs, meat and poultry); and (3) limits food high in sugar, fat, alcohol, refined starches and oils.

“Conclusion: Modifying lifestyles might reduce risk for early AMD as much as three-fold, lowering the risk for advanced AMD in a person's lifetime and the social and economic costs of AMD to society.”

Mares JA, Voland RP, Sondel SA, et al. Healthy lifestyles related to subsequent prevalence of age-related macular degeneration. *Arch Ophthalmol.* 2011 Apr;129(4):470-80.

# Questions and Answers From the Trenches

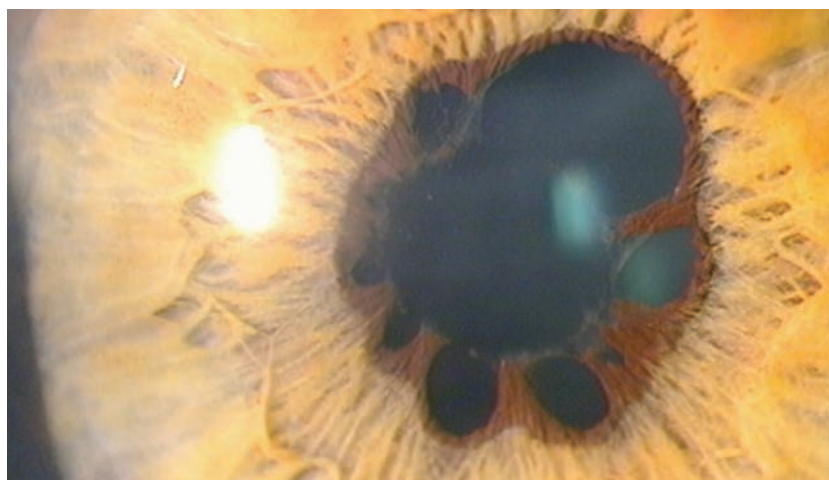
There are only a handful of oral medicines germane to eye care. Fortunately, O.D.s in most states can now prescribe most of these oral medicines.

**I**n our roles as optometrists and educators, we receive many interesting questions by letter, by e-mail, and from our colleagues at our lectures. We have selected numerous questions to answer here that we believe will benefit other clinicians who are in “the trenches” caring for patients every day.

**Q: I seem to get a lot of calls from patients about the cost of pharmaceuticals. Do you see this in your practice, and do you often call in substitute meds?**

**A:** We try to be cost-conscious when prescribing. There are times when we reluctantly allow a generic switch by the pharmacist. We say “reluctantly” because we have already exercised clinical judgment when initially prescribing, so had we felt a generic (or an alternate medicine) would be permissible, we would have written for it in the first place. Still, as clinicians, we need to be aware of the cost of various medicines, so that we can counsel patients about the costs before they present to the pharmacy. When treating a serious external infection, for example, we might prescribe Besivance, Zymaxid or Vigamox, and would not want a potentially less effective substitute.

But in some cases, we might



**Iris synechia as seen in acute anterior uveitis.**

alternate a very inexpensive generic (trimethoprim with polymyxin B) along with a fluoroquinolone, and have the patient use the fluoroquinolone drop every two hours, and the trimethoprim with polymyxin B every two hours. In this manner, the patient is instilling a drop every hour. This gives maximum antibiotic firepower while using two different medicines with two different mechanisms of action...in the event of resistance to one or the other. Such aggressive prescribing is rarely indicated, though.

Another example of cost-control vs. efficacy is in the initial control of ocular surface inflammation associated with dry eye disease.

We would specifically prescribe an ester-based corticosteroid (i.e., loteprednol) because there is no other steroid with which we are comfortable with patients using for perhaps two to three months. The key to many aspects of patient care, including the cost issues, is adequate communication with the patient.

**Q: What cycloplegic do you generally prefer for patients whose uveitis is accompanied by aggressive posterior synechiae?**

**A:** We tend to use 1% atropine q.i.d., along with Durezol q2 hours. At follow-up visits, we may instill a drop or two of 10% or 2.5%

phenylephrine, just to do our best to break the synechia. Almost invariably, once the steroid and the anticholinergic drops are used aggressively as outlined above, the synechia resolve.

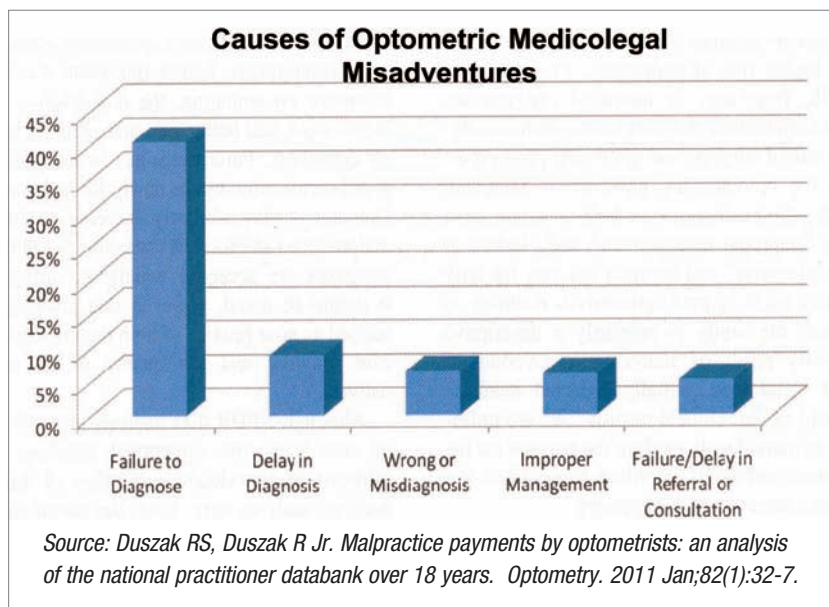
**Q: Do you use homatropine 2% in juvenile patients instead of the 5% concentration when therapeutic cycloplegia is indicated?**

**A:** Rather than use the 2% concentration q.i.d., we would typically go with the 5% concentration b.i.d. This is close to being clinically equivalent with a more patient-friendly dosing schedule.

We would build upon this question by pondering the steroid dosing in a juvenile with anterior uveitis. We would still use a potent steroid such as Durezol, Lotemax or brand name Pred Forte frequently (q2 hours for Lotemax or Pred Forte, or q.i.d. for Durezol, since its emulsion formulation allows for a longer ocular surface residence time) until the inflammation is brought under control, then taper off as indicated. The typical decision regarding frequency of instillation lies in the severity of the condition, more than the age of the patient.

**Q: Regarding clinical care, how do we know that doing the “right thing” is right in a climate where there are so many lawyers and people sue at the drop of a hat?**

**A:** This is a common question that is asked across the health professions. The basic answer is that it is our duty and responsibility to provide our patients with state-of-the-art, competent care. Contemporary reference texts, such as the *Wills Eye Manual* or the *Massachusetts Eye and Ear Infirmary Illustrated Manual of Ophthalmology*, can provide this general foundation. Medical care is an art,



**The main reason optometrists are successfully sued is “failure to diagnose,” not for actively providing medical care.**

and care must be individualized for each of our patients. The majority of eye care patients have excellent clinical outcomes when established standards-of-care are followed. But even in the best of hands, patients occasionally do poorly. Such is life. Our duty is to provide the best care possible. If this standard is honored, successful litigation is rare.

For perspective, it is well established that the main reason optometrists are successfully sued is “failure to diagnose,” not for actively providing medical care. Examples include *not* diagnosing giant cell (temporal) arteritis, missing a retinal tear in the setting of an acute symptomatic posterior vitreous detachment, missing glaucoma, etc.

Our advice? Know your stuff; focus on helping the patient; keep good, legible patient records; and don’t waste time looking over your shoulder.

**Q: What is the best technique for removing a corneal foreign body when a patient cannot keep the eye steady?**

**A:** Simply hold the foreign body removal instrument at the ocular surface near the foreign body, and as the patient’s eye saccades around, the foreign body will eventually hit the instrument and pop out... Just kidding!

We find such situations as stressful as anyone else. What we do is repeatedly urge and encourage the patient to look at a fixation point—the overhead light, the top of our ear, or any suitable target. During the brief moment of steady gaze, we act quickly to dislodge the foreign body.

Once the foreign body is removed, we enthusiastically proclaim that the offending object is now out, the worst is over, and now we are going to clean out a little bit of the rust, and that will be it. Just like in primary care medicine, a good part of what we do involves a lot of psychology.

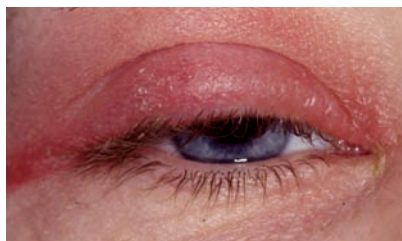
**Q: How do you tell papillae from follicles, and which one is present in bacterial, viral and allergic conjunctivitis?**

**A:** Technically, papillae have a single vessel in the center, whereas follicles have micro-fine telangiectatic vessels that course over the mound of tissue. In clinical practice, such distinction is minimally relevant because so many other features characterize the condition.

The only exception to this is in chlamydial infection, in which giant follicles in the inferior forniceal conjunctiva pathognomonically seal the diagnosis, as the giant-sized bumps seen with this condition are more useful than the histological morphology.

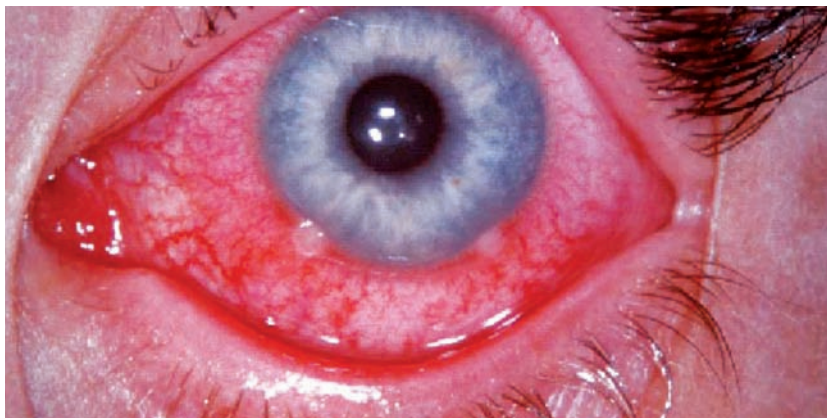
**Q:** How do you differentiate contact dermatitis from preseptal cellulitis?

**A:** Contact dermatitis itches, and one can commonly see subtle or obvious flaking of the epidermis of the eyelid skin. In the setting of cellulitis, the area is tender (often hurts), and does hurt with percussion. Cellulitis is an active bacterial infection, thus the skin feels hot. It generally starts out more focal and then spreads as the infection spreads.



**Contact dermatitis itches, and shows flaking of the eyelid skin.**

Contact blepharodermatitis is treated with topical or oral corticosteroids and cold compresses, whereas cellulitis is treated with warm soaks and oral antibiotic, such as cephalexin (Keflex), amoxicillin with clavulanic acid (Augmentin), trimethoprim with sulfamethoxazole (Bactrim or Septra), or an oral fluoroquinolone



**Here are two classic phlyctenules that straddle the limbal border.**

such as levofloxacin (Levaquin), for one week.

**Q:** How do you distinguish an intraepithelial infiltrate from a subepithelial infiltrate?

**A:** Generally speaking, *intraepithelial* lesions will stain (usually lightly) with vital dyes, in contrast to *subepithelial* lesions, which do not stain at all. Examples: the subepithelial infiltrates associated with epidemic keratoconjunctivitis do not stain; the intraepithelial lesions seen during the active phase of Thygeson's SPK will stain lightly.

**Q:** Can Thygeson's SPK be confused with contact lens overwear? Or is there a contact lens cause of Thygeson's?

**A:** Yes, and no. Thygeson's is bilateral 80% of the time, whereas acute overwear (CLARE) is almost always unilateral. However, there are those problematic contact lens wearers who present with bilateral, semi-diffuse, enduring SPK. Consider a different contact lens material for these patients, change to a hydrogen peroxide system, reduce wearing time, and rule out a subnormal tear film. Do a trial with 0.2% loteprednol. If it is Thygeson's, the cornea will clear in just a few days; that will answer the etiologic question.

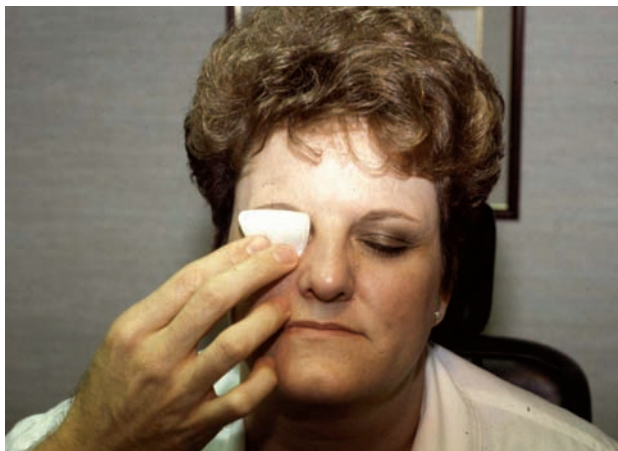**Q:** What characteristically differentiates a corneal phlyctenule from a peripheral marginal ulcer?

**A:** The corneal phlyctenular lesion will have a leash of blood vessels associated with it, whereas there is a clear, lucid interval between the sterile peripheral ulcer and the limbus.

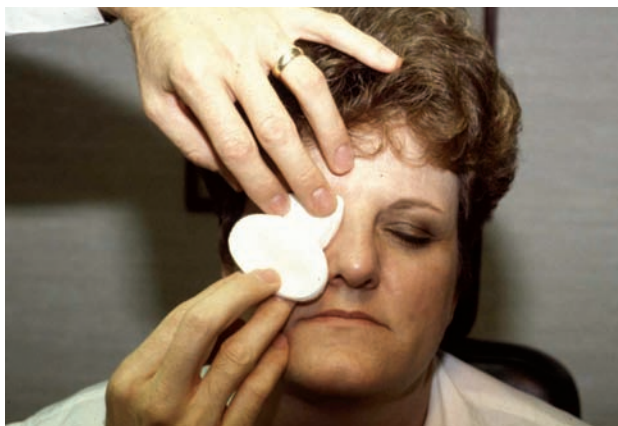**Q:** There are many techniques; how do you apply a pressure patch?

**A:** We use the small sized Johnson & Johnson eye pads (as opposed to the large size). We use two pads; the first we fold in half like a taco and use it to fill in the ocular sulcus (with the patient's eyes fully closed). Then we place an unfolded pad on top of the folded pad, and tape them firmly (but not too tightly) using four 5-inch strips of 1-inch-wide 3M or similar tape. Make sure the eyelid is completely closed before affixing the tape.

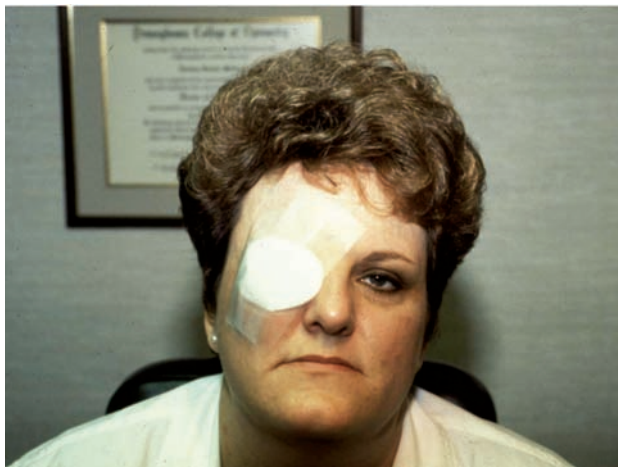When we do patch, which is rare, we always do so with an antibiotic ointment instilled into the eye first. While patching fell out of common use in the 1990s (because it was discovered that most corneal abrasions heal just as well without the time, trouble and aggravation of a patch), we still patch most of our larger and more painful abrasions, usually over erythromycin or Polysporin ophthalmic ointment.



**How do you apply a pressure patch? First, instill an antibiotic ointment into the eye. Then, take a large-size eye pad, fold it in half like a taco, and use it to fill in the ocular sulcus (with the patient's eyes fully closed).**



**Next, place an unfolded pad on top of the folded pad.**



**Last, tape the pads firmly (but not too tightly) using four 5-inch strips of 1-inch-wide 3M or similar tape. Make sure the eyelid is completely closed before affixing the tape.**

**Q: What instruments do you use for corneal debridement?**

**A:** Corneal debridement is usually performed in association with a fresh corneal abrasion when there are sheets of torn epithelium, or very irregular flaps of epithelium at the lesion margin. We grab these rough edges, or sheets, with jewelers' forceps and tear them circumferentially (in an arc pattern) and in toward the center of the abrasion. This cleaning of the abrasion margins prepares the surrounding intact epithelium for maximum re-epithelialization and healing. We use sterile cotton swabs, or Weck cell sponge devices when broader, more extensive debridement (such as for a deep epithelial thermal burn or multiple small foreign bodies) is indicated. A #15 Beaver blade could be used as well.

**Q: Do you run into problems with local pharmacies not stocking your favorite meds? No pharmacy in my area stocks dicloxacillin anymore—it's all special order.**

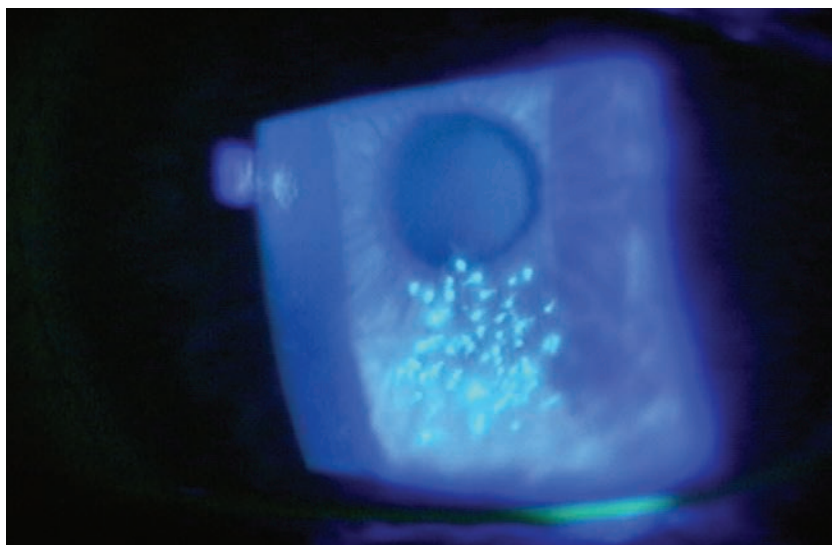
**A:** The most common shortcoming we have experienced over the years has been trifluoridine's (Virop-tic) availability. Such antivirals are not "high-need" medicines, and the requirement for refrigeration may be another reason why it is not always available. (We anticipate this problem will be obsolete with the advent of non-refrigerated Zirgan.) It is always nice to have samples of medicines on hand that can bridge the therapeutic gap for 24 hours—the time it takes for most any pharmacy to get most any drug. Note that there are samples available only for brand-name protected medicines, not generics.

Regarding your specific question: dicloxacillin is a perfectly noble antibiotic, but has been generic for two decades, and most physicians may well be unfamiliar with this medicine—thus is it not often prescribed. What we do is try to prescribe medicines that are more commonly used, as these are readily available.

In lieu of prescribing dicloxacillin 250mg q.i.d., we would prescribe cephalexin (Keflex) 500mg b.i.d. for one week. Cephalexin has a nearly identical spectrum of activity, a less frequent dosing administration, and is also very inexpensive. This is an example of where one's favorite drug may need to be put aside for a medicine that is simply more readily available.

**Q: Prior to punctal irrigation, what drops or ointment would you recommend for chronic epiphora?**

**A:** We have learned over the years that a combination antibiotic-steroid q.i.d. for a week or two resolves about half of such cases. If after seven to 14 days of medical treatment, the condition persists, then nasolac-



**Acute recurrent corneal erosion, as in a patient with epithelial basement membrane dystrophy (EBMD), is treated with anterior stromal micropuncture (ASP).**

rimal irrigation is indicated. This can be accomplished by the optometrist, a general ophthalmologist or an oculoplastics subspecialist.

When doing nasolacrimal irrigation, we would not pre-medicate because the drops would just get washed away. However, after the procedure, we commonly prescribe an antibiotic-steroid drop q.i.d. for a week.

**Q: Can anterior stromal micropuncture (ASP) be performed when there is an acute occurrence of recurrent corneal erosion, as in a patient with epithelial basement membrane dystrophy (EBMD)?**

**A:** Yes. Regardless of the origin (old traumatic abrasion, EBMD or spontaneously idiopathic), ASP can be applied at the time of the acute presentation. If there is even a day's delay, the epithelium can heal, and therefore be a real challenge to know exactly where to apply the anterior stromal micropunctures.


When we perform this elementary procedure, we complete the treatment process with instillation of a topical NSAID, a drop of 1% cyclopentolate, then placement of

a bandage/therapeutic soft contact lens, and prescribe an antibiotic such as generic tobramycin or trimethoprim/polymyxin B q.i.d. for three or four days.

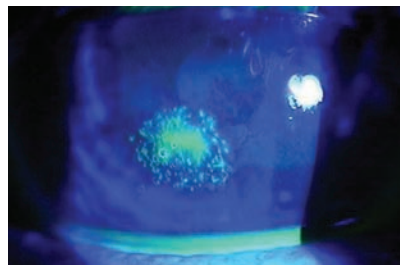
We see the patient back in three to four days, at which time we generally remove the soft contact lens and keep the eye lubricated with a lipid-based artificial tear during the day, and a lubricant eye gel at bedtime, for two to four weeks. ASP is generally curative.

**Q: When do you decide to actively treat a recurrent corneal erosion? And, how do you decide on performing ASP vs. treating medically with oral doxycycline and loteprednol?**

**A:** If a patient has had a previous injury from a fingernail, paper cut or other sharp object (as sharp objects tend to penetrate through Bowman's membrane, which then predisposes to RCEs), and the patient has a history of recurrent episodes, and presents to one of us as a new patient with an acute event, we act aggressively to try to halt these painful episodes. Depending on the disposition of the patient



**A highly magnified view of the needle tip used to perform ASP.**



**The corneal surface post-ASP.**

and the clinical circumstances, we would either perform ASP that day, or just treat the acute abrasion in standard manner with 50mg of oral doxycycline for a month and concurrently prescribe Lotemax q.i.d. for a month.

Both the procedural technique (ASP) and the medical approach (as outlined above) are largely curative, and bring great relief to patients. The ASP is a quicker fix, but as long as the patient tolerates the doxycycline well, the medical approach is perfectly prudent. Only under very unusual circumstances would we ever do both.

Because most cases of recurrent corneal erosion heal with conservative approaches, such as lubricating eyedrops by day and either GenTeal gel or a lubricating ointment at bedtime for six weeks (the typical healing time for basement membrane tissues), we only initiate active therapy when we think the patient is at high risk (such as in the instance of a severe fingernail abrasion near the inferior third of the cornea, where most erosions occur), or the patient has a history of multiple recurrences. ■

# How to Conquer Excess Mucus

A verbatim e-mail exchange.

Dear Drs. Melton and Thomas:

I have a post-penetrating keratoplasty (PKP) O.U. patient in bitoric RGPs who is plagued with 2+ giant papillary conjunctivitis (GPC). To take him out of his RGPs entirely incapacitates him. Pataday and Alrex have been ineffective. I have read your protocol of Lotemax every two hours for two days and then four times a day for five days with no contact lens wear. He will not be able to do this.

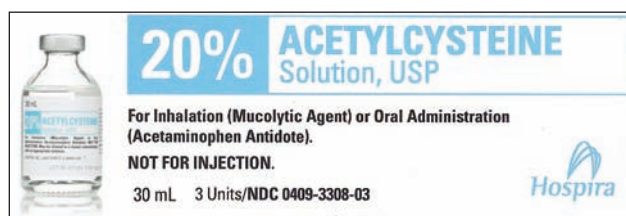
Another *huge* problem for him is the mucus that his irritated eyes produce and the interference with contact lens wear. He is at the point of considering repeat PKPs. If I could reduce the mucus problem, he would be overjoyed. He can physically handle the contact lens wear with GPC. I don't know how effective Lotemax t.i.d. with continued contact lens use will be. Can you make any recommendations? Thank you for your help.

**Our response:**

Dear Doctor:

Thank you for your thoughtful inquiry. Have a compounding pharmacist take either 10% or 20% Mucomyst (acetylcysteine, Bristol-Myers Squibb) and dilute it to a 5% ophthalmic solution. Have your patient instill this q.i.d. for a week or two. Then once control is achieved, taper use to perhaps b.i.d. as maintenance therapy. The acetylcysteine is an excellent mucolytic, and is heavily used in treating excess mucus in the pulmonary system.

We would also have him use the



*Lotemax q.i.d. for two weeks, right with the RGP. During the initial studies on GPC and Lotemax, this drop was instilled right on top of soft contact lenses, so it should only be even safer for RGPs. We would also recommend the frequent use of a lipid-based artificial tear. With any two different eye drops, we would have him wait about 20 minutes between use of the first and second medications.*

*If you do these things, you should have a pretty satisfied patient. Please let us know how this works.*

**The writer responds:**

Thank you for your suggestion! I've not run across this treatment plan. Because his complaints seem to be focused on the mucus production and not lens irritation, I am thrilled to have something that additionally addresses the mucus buildup. It's also nice to know that he can leave the RGPs in and still get a good effect from the Lotemax. I will let you know how this works! Thanks again!

**...and later writes:**

Thank you so much for your recommendations! I just spoke with the patient. The two weeks he was on the acetylcysteine and Lotemax q.i.d. was the best he's been in a year! Now that he's b.i.d., he is

having a few more problems with the mucus during the day. I told him to increase the acetylcysteine to

t.i.d. and see if that helped.

I have another question. I have run across some other patients who would benefit from this regimen. One of the patients is already taking oral Mucomyst daily. She still has fogging/coating problems. Is there any problem to adding this regimen on to her oral dose?

**Our response:**

Dear Doctor:

We are pleased that your patient has been helped with the Mucomyst and loteprednol. Your last question related to one of your patients using topical as well as systemic Mucomyst. We would see no problem with a patient using topical eye drops while at the same time taking oral Mucomyst.

**The writer responds:**

My patient currently taking Mucomyst said that her problem isn't that bad, but it's good to have this in my pocket if needed.

This has been "life changing" for my one patient, not having to take lenses out to clean three to four times a day. This would be a huge pearl for other doctors in your next drug guide!

**Our response:**

As you can see, doctor, your suggestion has been taken to heart! ■

# New Insights into Plaquenil Retinotoxicity

New, as of 2011, is the addition of one or more objective assessments, such as spectral-domain OCT, to evaluate early retinal damage.

Two new articles further refine our understanding of the retinotoxic risks of Plaquenil (hydroxychloroquine, Sanofi-Aventis) usage, and also provide new insights into patient evaluation and follow-up care.<sup>1,2</sup>

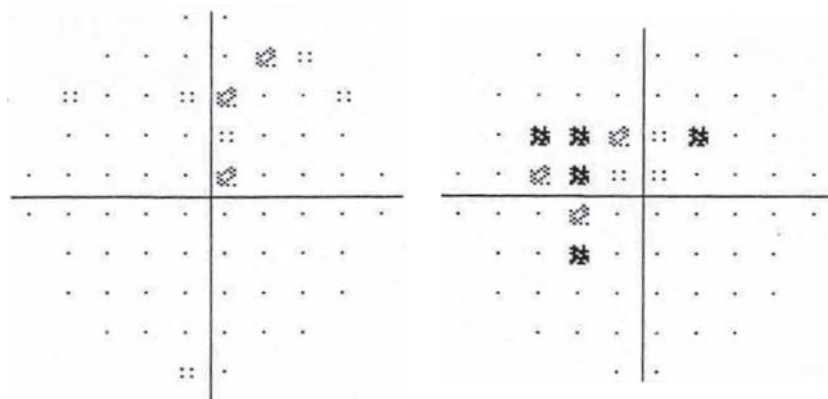
It is well understood that hydroxychloroquine (HCQ) has the potential to cause irreversible central vision loss. A baseline retinal evaluation is standard-of-care for patients being treated with HCQ, within a few months of initiation of therapy.

Because there is no known means available to diagnose toxic damage before some minor permanent damage has occurred, it is critical to assess risk factors for HCQ toxicity, thoroughly educate our patients, and perform appropriate screening measures in a timely manner.

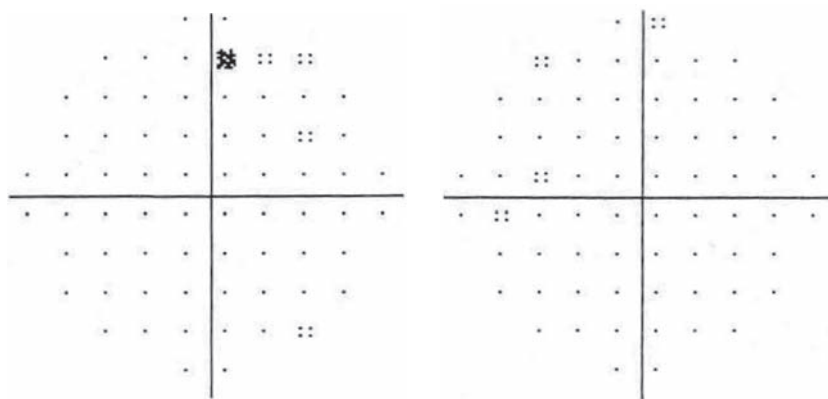
Known risk factors are:

- *Daily dosage of HCQ exceeding 6.5mg/kg* (that is, a daily dosage not to exceed 400mg in patients having a lean body weight of less than 135 lbs.)

- *Obesity.* We stress here that HCQ is not absorbed into adipose tissue. This means that an obese person who weighs 160 lbs may be considered within the “safe” zone, but their lean body weight may be only 120 lbs, which poses an increased relative risk. We have communicated this critical issue of lean body weight to our referring rheumatologists and dermatologists, and have asked them to assess the lean body weight of each of their HCQ patients and make this



**The gold standard for evaluation of Plaquenil retinotoxicity has been, and continues to be, a central 10-degree visual field test to look for repeatable central and paracentral scotomas. As with all types of visual field tests, there can be much variability. This HCQ patient demonstrated apparent paracentral defects at baseline...**



**But, when retested three months later, the patient revealed normal results. Use sound clinical judgment when interpreting any subjective data!**

information known to us, so that we can more accurately assess the risk for retinotoxicity. If you want to calculate it yourself, the formula for women (the vast preponderant gender prescribed HCQ) is:  $1.07 \times \text{weight} - 1.48 \times (\text{wt}^2/100 \times \text{height in meters}^2)$ .

- *Duration of use longer than*

*five years.* It is now more firmly established that duration of exposure (i.e., cumulative dose) portends more retinotoxic risk than daily intake. In fact, prevalence of toxic expression is quite limited within the first five years of use, and the risk “increased sharply after five to seven years to approximately 1%.”



So, it appears that initial screening during the first five years of therapy can be rationally relaxed in those patients not having significant risk factors. But beginning about Year 5, as dosage accumulates, more frequent (usually annually) assessments should be performed.

- **Renal or hepatic functional impairment.** Compromised kidney and/or liver function can lead to increased accumulation of HCQ in the tissues, so that the health status of these organs should be assessed by the prescribing physician.

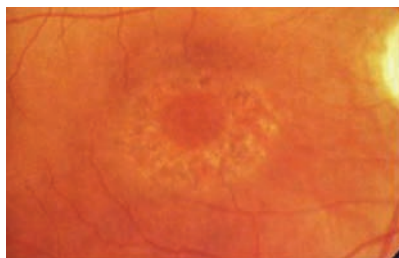
- **Older age.** “Patients older than 60 years, and with a duration of treatment greater than five years, appear to be at greater risk for retinal toxicity.”

- **Preexisting retinal disease.** It stands to reason that any clinically significant retinacular tissue compromise could place these delicate tissues at increased risk from HCQ exposure. Such patients may have a contraindication to HCQ use, or at least a lower dose should be tried.

### Toxicity Buildup

Most physicians, in our experience, prescribe the usual 400mg/day dosage. However, because of this drug’s long residence time in the blood and tissues, the clinical effects build up slowly. This unique pharmacology allows for intermediate dosing, which is easily achieved by varying the daily dosage. “For example, 300mg daily results from taking 200mg and 400mg on alternate days.”

A 2002 article stated: “These drugs are typically prescribed by internists, rheumatologists and dermatologists who may not be fully aware of the ophthalmic implications.”<sup>3</sup> Another 2002 article stated: “Under circumstances of proper dosing, screening could be rationally discontinued.”<sup>4</sup> While



**New recommendations aim to catch Plaquenil retinotoxicity long before this classic bullseye maculopathy appears.**

this is probably true for almost all patients, there may be a few patients who are indeed properly dosed yet, because of individual idiosyncrasies and variability, they still develop toxicity.

### Assessing the Damage

So how do we evaluate patients for early toxic effects? Unfortunately, no mechanism exists to detect ocular damage from HCQ before it occurs. We can only try to detect such damage at its earliest manifestation. Functional compromise occurs before any ophthalmoscopically-visible changes can be seen. The gold standard has been, and continues to be, a central 10-degree visual field test to look for repeatable central and paracentral scotomas.

As with any other visual field test, one must bear in mind that there can be a lot of subjective variability; thus if there are any suspicious defects, a second visual field test should be performed within a few weeks to determine if the same defects are still present. The Amsler grid is supra-threshold, and is of no value in the setting of HCQ screening. Use the 10-2 visual field test for all HCQ patient evaluations.

New, as of 2011, is the addition of one or more objective assessments, such as spectral-domain OCT, multifocal electroretinogram and fundus autofluorescence. Of these, the most practical and most

accessible is the SD-OCT, and it is our recommended instrumentation. These spectral-domain scans can reveal localized thinning in the parafoveal region. (Time-domain OCT instruments do not have the resolution to enable meaningful quantification of these crucial retinal tissues.) It is thought that these objective assessments may even be a bit more sensitive to tissue compromise than the 10-2 visual field test.

In summary, it is of paramount importance to inform HCQ patients of the remote (<1%) chance of a problem. Furthermore, it should be stressed that it is in detecting the earliest possible expression of damage that further, irreversible vision loss can be prevented. The patient should understand that risk is extremely low during the first five years of HCQ therapy, but that continued use beyond five to seven years confers an increasing risk (up to about 1%) for retinacular tissue damage.

Bottom line: Assess vision, baseline macular abnormalities, 10-2 visual field testing with a white target, and if at all possible, try to obtain a paramacular scan with an SD-OCT. Then follow these patients probably annually, particularly after five years of drug exposure. ■

1. Michaelides M, Stover NB, Francis PJ, Weleber RG. Retinal toxicity associated with hydroxychloroquine and chloroquine: risk factors, screening, and progression despite cessation of therapy. *Arch Ophthalmol*. 2011 Jan;129(1):30-9.
2. Marmor MF, Kellner U, Lai TY, et al; American Academy of Ophthalmology. Revised recommendations on screening for chloroquine and hydroxychloroquine retinopathy. *Ophthalmology*. 2011 Feb;118(2):415-22.
3. Marmor MF, Carr RE, Easterbrook M, et al; American Academy of Ophthalmology. Recommendations on screening for chloroquine and hydroxychloroquine retinopathy: a report by the American Academy of Ophthalmology. *Ophthalmology*. 2002 Jul;109(7):1377-82.
4. Browning DJ. Hydroxychloroquine and chloroquine retinopathy: screening for drug toxicity. *Am J Ophthalmol*. 2002 May;133(5):649-56.

*Next page: a hydroxychloroquine (Plaquenil) referral form.*

## Hydroxychloroquine (Plaquenil) Evaluation

Patient Name \_\_\_\_\_ D.O.B. \_\_\_\_\_

Referring Physician \_\_\_\_\_

Consultant Optometrist \_\_\_\_\_

Date \_\_\_\_/\_\_\_\_/\_\_\_\_

Plaquenil dose \_\_\_\_\_ mg \_\_\_\_\_ Number of years taking HCQ \_\_\_\_\_

Acuity Right 20/\_\_\_\_ Left 20/\_\_\_\_ Patient's Weight \_\_\_\_\_ lbs.

Estimated Lean Weight \_\_\_\_\_ lbs.

Fundus exam Normal \_\_\_\_\_ Other \_\_\_\_\_

Macular Visual Field Testing (10-2)  Normal \_\_\_\_\_ Other \_\_\_\_\_

Additional Testing \_\_\_\_\_

Recheck Annually \_\_\_\_\_ Other \_\_\_\_\_

Comments:

Thank you very much for entrusting us with the eye care of your patient.

## UNDERSTANDING AMBLYOPIA

Probably the single most important factor in the care and safeguarding of children's eyesight is a thorough eye examination between 3 and 4 years of age. Many parents assume little can be accomplished at such an early age; however, this is not the case. In fact, much critical information can be rather easily determined even in babies.

A common condition known as amblyopia (lazy eye) is one of the key problems that can only be prevented if its underlying cause is diagnosed and treated early. The main causes of amblyopia are 1) one eye being more farsighted than the other (the children will not be aware of this at all because the more normal of the two eyes will simply take over), and 2) one eye being turned in or out relative to the straight eye. Family members often detect crossed or deviated eyes; however, there is no way to detect the status of farsightedness by casual observation. Such a diagnosis can only be made with a thorough examination by an eye doctor.

Amblyopia, and the conditions that lead to amblyopia, are unilateral in nature—this means only one eye is affected. Sadly, and far too often, children with amblyopia are not brought into the eye doctor's office until they realize they see poorly out of one eye. If the child is older than 7 or 8, there may be little that can be done to improve his or her vision. While most people with amblyopia function well in life, their depth perception is decreased and this may restrict their choice of occupation to some degree. (A person with good eyesight in only one eye should always wear impact-resistant eyeglasses to protect the good eye. This is true even if there is no prescription in the lenses.)

Why is it so important to diagnose the conditions that can lead to amblyopia by the age 3 or 4? The central nervous system (specifically the occipital cortex tissues in the back of the brain) can be stimulated and enhanced in children until they are about 6 to 8 years old, and thus their vision can more likely be improved.

The two-step treatment of amblyopia is usually very straightforward.

First, perfect eyeglasses are prescribed to fully correct each eye. This

provides clear, crisp images focused on the retina at the back of the eye. These sharp images are then transmitted to the optic nerves to reach the occipital cortex where special vision cells are sufficiently stimulated so that they can develop to their fullest potential.

The second step in treating amblyopia is to selectively patch the "good" (stronger) eye. This forces the "bad" (weaker or *amblyopic*) eye to begin to be used more. This forced use of the amblyopic eye is what stimulates the specialized vision cells in the brain to develop properly, thereby allowing good vision development in both eyes. Usually, special dilating eyedrops are used by the doctor to determine the exact eyeglass prescription for the child. Of course, every patient with amblyopia is unique, so the frequency, duration and outcome of patching therapy will vary, depending on the visual status of each patient.

Here are some behaviors that might be observed in young children with potential vision problems:

- Frequent eye rubbing
- Excessive blinking
- Squinting
- Covering or closing one eye
- Stumbling over small objects

Any of these activities should prompt a visit to the eye doctor; however, even if no such behaviors are seen, every child should have his or her eyes examined by age 3 or 4.



