

2017 CLINICAL GUIDE TO OPHTHALMIC DRUGS

21st Edition



Ron Melton,
OD

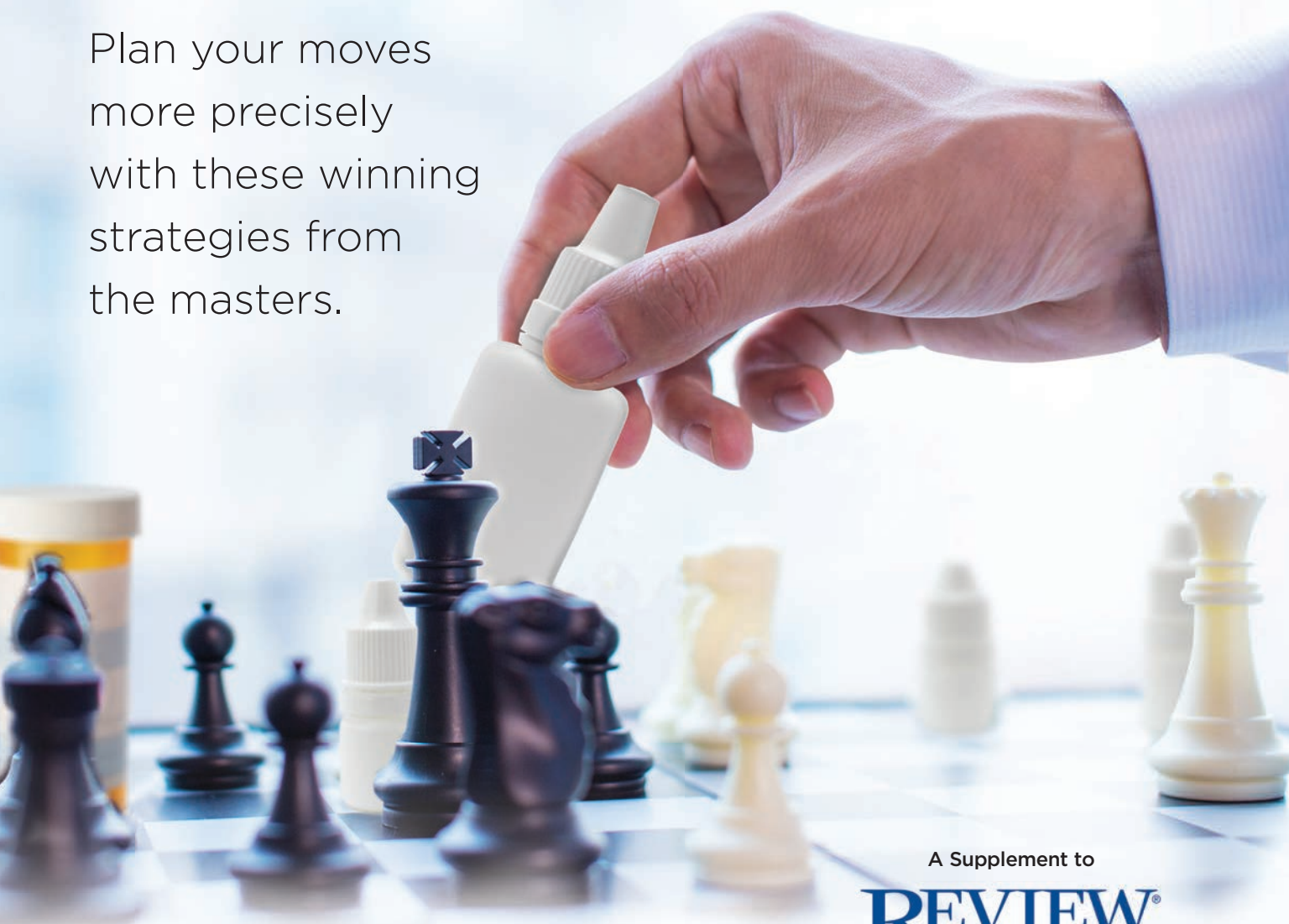

Randall Thomas,
OD, MPH



Patrick Vollmer,
OD

Plan your moves
more precisely
with these winning
strategies from
the masters.



A Supplement to

REVIEW[®]
OF OPTOMETRY

Supported by an unrestricted grant from Bausch + Lomb

DEAR OPTOMETRIC COLLEAGUES:

Welcome to the 2017 edition of our annual *Clinical Guide to Ophthalmic Drugs*. Although the market has not yielded an avalanche of new drugs to share with our readers this year, we will discuss myriad ways to better use most of the medicines already available. Further, we will offer a variety of clinical pearls to help you provide better care to your patients.

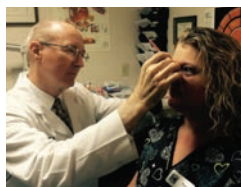The areas of eye care most germane to optometry involve two chronic conditions: dry eye disease and glaucoma. These two disease processes make up more than 50% of our patient population. The two newest drugs that currently, or soon will, grace our therapeutic armamentarium are designed for patients with these conditions: Xiidra (lifitegrast 5% ophthalmic solution) for treatment of signs and symptoms of dry eye disease, approved by the FDA in July 2016; and soon-to-be released Vyzulta (latanoprostene bunod 0.24% ophthalmic solution) for glaucoma, which would be the first nitric oxide-donating prostaglandin F₂ analog available for open-angle glaucoma or ocular hypertension.

As we become more seasoned clinicians and educators, we feel a duty to our profession to find the next generation of authors to carry on when we step aside in several years. Toward that end, we are pleased to introduce Patrick Vollmer, OD, a 2015 graduate of the Indiana University School of Optometry who completed his residency at William Jennings Bryan Dorn VA Medical Center, and who owns a private practice in Shelby, NC. Dr. Vollmer is contributing to this year's drug guide, and we are happy to have a third set of hands on this mammoth project. You can find Dr. Vollmer's complete CV on our website, www.eyupdate.com. We'd also like to thank our primary peer reviewers Bruce Onofrey, OD, RPh, FAAO, and Tammy Than MS, OD, FAAO, for taking time to review this publication.

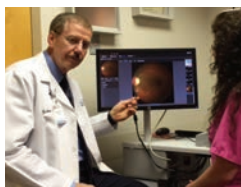
We are grateful that Bausch + Lomb and *Review of Optometry* continue to partner with us to produce this unique resource for our profession that we have put out for more than two decades.

We hope what is shared with you herein can enhance the excellent care you already provide your patients.

With best wishes,



Randall K. Thomas,
OD, MPH, FAAO



Ron Melton, OD,
FAAO



Patrick M. Vollmer, OD,
FAAO

Disclosure: Drs. Melton and Thomas are consultants to, but have no financial interests in, the following companies: Bausch + Lomb/Valeant and Icare. Dr. Vollmer has no financial interests in any company.

Supported by an
unrestricted grant from
Bausch + Lomb

CONTENTS

Allergy Drugs.....	3
Antibiotic Agents.....	8
Plaqueul Toxicity	15
Dry Eye Therapy	18
Corticosteroid Use.....	26
Nonsteroidal Drugs	33
Antiviral Therapy	34
Glaucoma Care.....	40



A PEER-REVIEWED
SUPPLEMENT

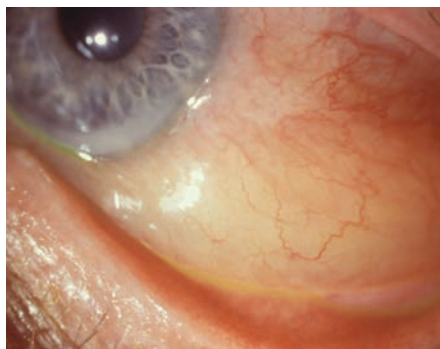Note: The authors present unapproved and "off-label" uses of specific drugs in this guide.

TAKE CONTROL OF OCULAR ALLERGY

Atopic diseases continue to increase in prevalence. Here's how to help your patients with allergic conjunctivitis.

Nearly one-third of the population is affected by allergic disease, with an estimated 40% to 80% of these people manifesting ocular involvement.¹ Reports from studies around the world indicate the prevalence of atopic diseases is continuing to increase, which has been well-documented over several decades of research.^{2,3} At the same time, ocular allergic disease is also on the rise. So, we need to understand more about the nature of the disease to better treat and manage our patients.

Allergic eye disease, an IgE-mediated response and type I hypersensitivity reaction, presents in numerous forms—from a persistent itch to a potentially sight-threatening corneal ulcer (vernal keratoconjunctivitis). According to the most recent epidemiological data, as many as two in five of your patients may have seasonal or perennial allergic conjunctivitis.⁴



Determine signs and symptoms by first asking, “Do your eyes *burn* or *itch*?”

IS IT ‘BURNING’ OR ‘ITCHING’?

- **Itching:** If the patient tells you itching is their primary concern, determine if it’s an isolated symptom or associated with parallel signs of inflammation, and then treat accordingly. Remember:

Symptoms Only: Use an antihistamine/mast cell stabilizer

Symptoms and Signs: Use a topical steroid (such as Alrex, Lotemax gel off-label or FML off-label)

- **Burning:** If the main symptom is burning, consider dry eye as the foundational condition and treat accordingly. A full dry eye workup is in order.

Of course, nothing in the rulebook says a patient can’t have both of these symptoms concomitantly. Due to the prevalence of dry eye across all ages, recognize and treat it whether or not it is affiliated with allergic eye disease.

Though the treatment options are essentially the same for perennial and seasonal allergic conjunctivitis, perennial allergic conjunctivitis follows a more indolent course, often requiring greater attention and persistent care by the attending doctor. Treatment for seasonal allergic conjunctivitis is more straightforward and includes antihistamines/mast cell stabilizers or corticosteroids.

To find out whether your patients are experiencing just symptoms or also signs, first ask them: “Do your eyes *burn* or *itch*?” Many patients will be able to provide an answer. For your patients who are unable to decide which symptom

OLOPATADINE: THE CLASSIC GOLD STANDARD OF ALLERGY TREATMENT

The first dual-action antihistamine/mast cell stabilizer to transform ocular allergy therapy was olopatadine 0.1% (Patanol, Alcon). In 1996, the FDA approved Patanol for the treatment of signs and symptoms of allergic conjunctivitis. The drug is highly selective for the H₁ receptor, and has shown in studies to apparently possess anti-inflammatory properties as well, inhibiting the release of leukotrienes, cytokines and adhesion molecules.¹ Olopatadine 0.1% was the first topical drop for allergic conjunctivitis approved for BID dosing, far surpassing the second-generation antihistamines, which in their time had advanced to QID.

In 2010, olopatadine 0.2% (Pataday, Alcon) became available with comparable efficacy and improved patient satisfaction, with relief from ocular symptomology for up to 18 hours. More recently, olopatadine 0.7% (Pazeo, Alcon) made its market debut in February 2015 with the efficacy for ocular itching surpassing 24-hour relief while maintaining a safety profile similar to the lesser concentrations that came before it.

1. Ackerman S, Smith LM, Gomes PJ, et al. Ocular itch associated with allergic conjunctivitis: latest evidence and clinical management. *Ther Adv Chronic Dis.* 2016 Jan; 7(1): 52-67.

DOSING OF A TOPICAL ANTIHISTAMINE: WHICH IS BETTER—ONE OR TWO?

Forget about prescribing pure mast cell stabilizing drugs, according to Mark Abelson, MD, a world-renowned ocular allergist at Harvard Medical School.

During a conversation with Dr. Abelson, he told us pure mast cell stabilizing drugs have little clinical use. Their lag period and mandatory chronic dosing severely limits their clinical applicability. With the advent of topical combination antihistamine/mast cell stabilizers, patients experience nearly instantaneous relief due to the rapid onset of action; bear in mind, too, that the cost of an OTC combination drop is very similar to a pure mast cell stabilizer. Remind your patients that transient burning and stinging upon instillation is common.

For patients who have symptomatic disease, one drop in the morning may suffice to get them through the entire day. However, a subset of our patients finds solace with a second, additional drop later in the evening. Which is correct? In the end, either is appropriate, as patient care is not a one-size-fits-all but rather a tailored approach to symptomatic relief.

In your patients with severe allergy expression, therapy is slightly more involved. In addition to an antihistamine/mast cell stabilizer BID, consider an ester-based corticosteroid such as Alrex (loteprednol 0.2%, Bausch + Lomb) or off-label use of Lotemax gel (loteprednol 0.5%, Bausch + Lomb) QID initially along with cold compresses.

Once the inflammation settles down, the steroid may be discontinued, preferably within two weeks, and the patient can remain on the antihistamine/mast cell stabilizer once or twice daily as needed.

distresses them the most, treatment with an ester-based steroid drop (e.g., Alrex [loteprednol etabonate 0.2%, Bausch + Lomb]) typically solves both complaints.

If patients report itching as their predominant symptom, therapy is directed toward one of two paths, as explained in upcoming pages.

SYMPTOMS ONLY

If the anterior segment exam shows minimal or unremarkable signs of an allergic conjunctivitis (i.e., conjunctival chemosis, conjunctival injection, eyelid edema and/or papillae), then treatment with a combination antihistamine/mast cell stabilizer remains the ideal clinical choice.

To date, there are six drugs in this class to choose from:

- *Alcaftadine* (Lastacaft, Allergan)
- *Azelastine* (Optivar, Meda Pharmaceuticals; generic available)
- *Bepotastine* (Bepreve, Bausch + Lomb)



FROM THE LITERATURE

ALLERGIC CONJUNCTIVITIS IS ON THE RISE WORLDWIDE

According to the International Study of Asthma and Allergies in Childhood (ISAAC), allergic conjunctivitis has shown a worldwide trend in increasing prevalence.¹ This has been attributed to changing climate, pollution, increased pollen and a heightened immunological sensitivity in response

to these environmental changes.²

More than 80% of patients who suffer with allergies experience some form of ocular symptomology (itching, chemosis, redness).^{3,4} In addition, various studies suggest that patients still vastly underreport the disease. Of equal significance are studies establishing the impact of ocular allergies on scholastic achievement, quality of life and behavior, which confirms the necessity of early therapeutic intervention.⁵

1. Björkstén B, Clayton T, Ellwood P, et al. Worldwide time trends for symptoms of rhinitis and conjunctivitis: Phase III of the International Study of Asthma and Allergies in Childhood. *Pediatr Allergy Immunol.* 2008 Mar;19(2):110-24.
2. D'Amato G, Holgate ST, Pawankar R, et al. Meteorological conditions, climate change, new emerging factors, and asthma and related allergic disorders. A statement of the World Allergy Organization. *World Allergy Organ J.* 2015; 8(1):25.
3. Singh K, Axelrod S, Bielory L. The epidemiology of ocular and nasal allergy in the United States, 1988-1994. *J Allergy Clin Immunol.* 2010 Oct;126(4):778-83.e6.
4. Blaiss MS. Allergic rhinoconjunctivitis: burden of disease. *Allergy Asthma Proc.* 2007 Jul-Aug; 28(4):393-7.
5. Bielory L, Katelaris CH, Lightman S, et al. Treating the ocular component of allergic rhinoconjunctivitis and related eye disorders. *MedGenMed.* 2007 Aug 15;9(3):35.

TIPS TO PREVENT EYE ALLERGIES

Avoidance is one of the best ways to prevent triggering eye allergies. Other tips from the Asthma and Allergy Foundation of America include:

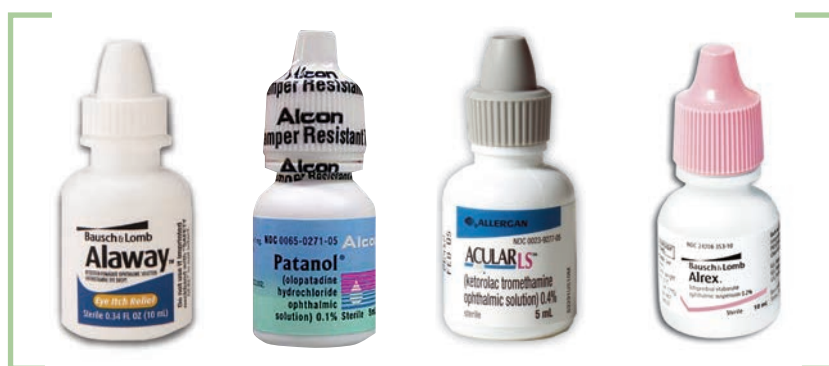- Don't touch or rub the eye(s).
- Wash hands often with soap and water.
- Use a vacuum with a HEPA filter to reduce exposure to allergens.
- Wash bed linens and pillow cases in hot water and detergent to reduce allergens.
- Use allergen covers (encasements) for pillows, comforters, duvets and mattresses, and consider them for box springs.
- Keep pets out of the bedroom to reduce pet dander allergen in bedding.
- Wear sunglasses and a wide-brimmed hat to help keep pollen from getting into the eyes.
- Close windows during high-pollen and mold seasons. Run the air conditioner in the car and at home, and consider using a HEPA filter.

Eye Allergies (Allergic Conjunctivitis). Asthma and Allergy Foundation of America. Available at: www.aafa.org/page/eye-allergy-conjunctivitis.aspx. Last accessed Dec 16, 2016.

- *Epinastine* (Elestat, Allergan; generic available)
- *Ketotifen* (Zaditor, Alcon; many generics available. This drop is OTC.)
- *Olopatadine* (Pazeo/Pataday/Patanol, Alcon)

Of these, all are rated pregnancy category C except for Lastacraft, which is pregnancy category B. Notwithstanding other fine differences, all of the antihistamine subtype 1 receptor blockers nicely suppress ocular itching. All are dosed initially BID (except Pazeo, Pataday and Lastacraft, which are dosed QD).

After two weeks of BID therapy, consider reducing instillation to QD for maintenance dosing. Remember, as with any treatment, the lowest effective dose is always desired. In our experience, once the inflammation is under control, less pharmaceutical intervention is necessary to maintain or suppress symptoms. Then again,

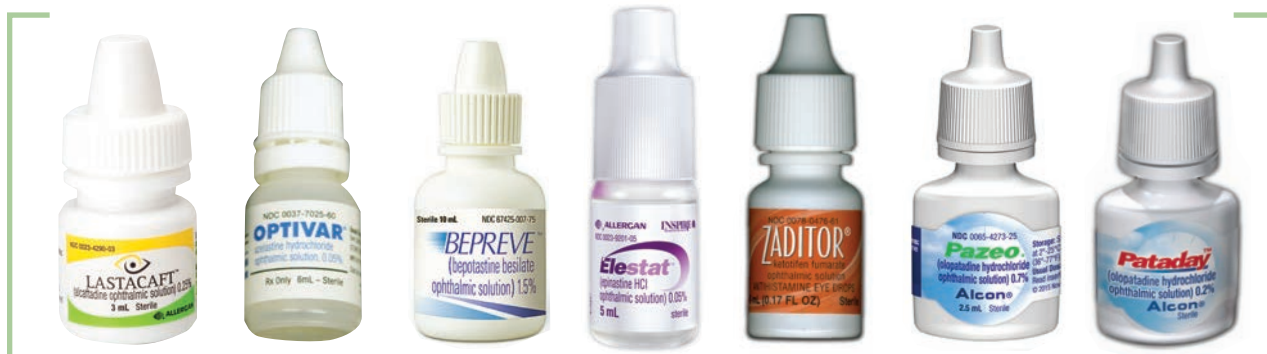

some patients still require a second additional drop later in the evening.

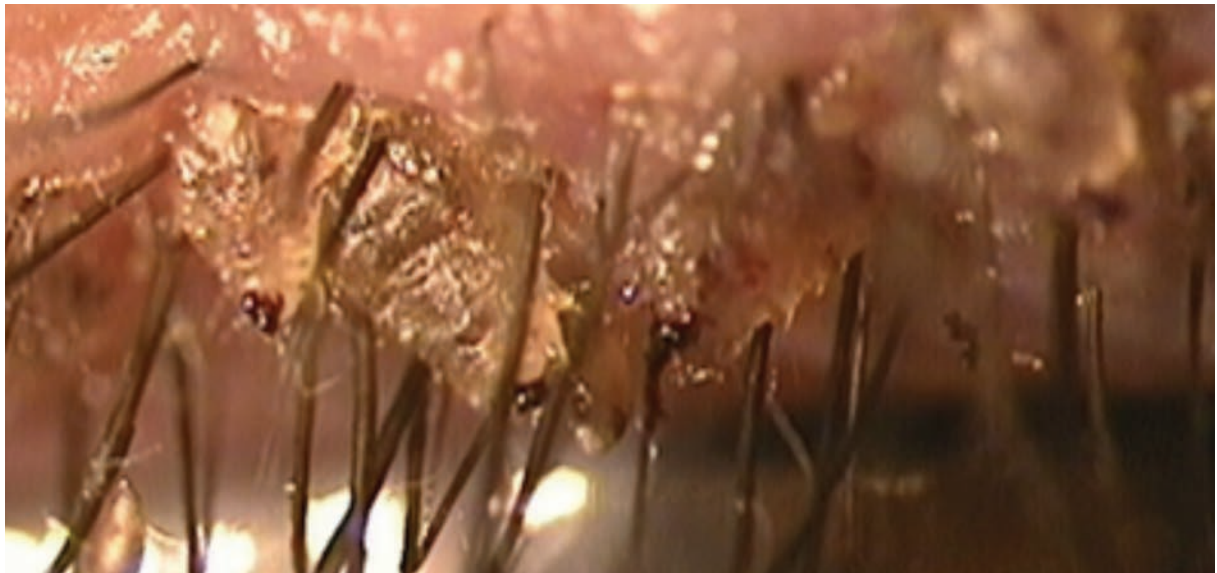
Perhaps the best news for the consumer was the loss of patent protection for Zaditor (Novartis). Since 2007, ketotifen has been available generically and over the counter. In addition to Zaditor, several brand-name OTC ketotifen preparations are available, including Alaway (Bausch + Lomb) and others. All come in 5ml bottles, except for Alaway, which comes in a 10ml bottle.

Interestingly, our observation in a variety of pharmacies reveals that the cost of the 10ml Alaway is very near to (and occasionally cheaper than) the price of its 5ml competitors.

When a prescription medication is preferred, perhaps a 10ml bottle of Bepreve (using a standard copay) would be of greatest cost value to the patient. Consider using a coupon to pay no more than \$35 and consulting www.goodrx.com to find the best price in your area.



A ‘LOUSY’ REASON FOR ITCHING



Severe itching of the eyelids can be caused by crab lice. Don't miss these. Using your toothed, curved tip forceps, simply remove them one by one. Slide one side of the forceps underneath the ventral aspect of the louse, gently close down on the dorsal side and slowly pull the critter off the tissues. Repeat for each louse you can find. Then have the patient apply an ophthalmic ointment at bedtime for a week, which will suffocate any juveniles you may have missed. Also have the patient do lid scrubs each evening before applying the ointment. In a week, the eyelid tissue should be restored to normal. Explain to the patient that these can be associated with sexual activity and any partner(s) should be examined by a physician.

OCULAR ALLERGY MEDICINES

BRAND NAME	GENERIC NAME	MANUFACTURER	PEDIATRIC USE	BOTTLE SIZE(S)	DOSING
Acute Care Products					
Acular LS	ketorolac tromethamine 0.4%	Allergan, and generic	3 yrs	5ml, 10ml	QID
Alaway (OTC)	ketotifen fumarate 0.035%	Bausch + Lomb	3 yrs	10ml	BID
Alrex	loteprednol etabonate 0.2%	Bausch + Lomb	12 yrs	5ml, 10ml	QID
Bepreve	bepotastine besilate 1.5%	Bausch + Lomb	2 yrs	5ml, 10ml	BID
Elestat	epinastine HCl 0.05%	Allergan, and generic	3 yrs	5ml	BID
Emadine	emedastine difumarate 0.05%	Alcon	3 yrs	5ml	QID
Lastacaft	alcaftadine 0.25%	Allergan, and generic	2 yrs	3ml	QD
Optivar	azelastine hydrochloride 0.05%	Meda, and generic	3 yrs	6ml	BID
Pataday	olopatadine hydrochloride 0.2%	Alcon	3 yrs	2.5ml	QD
Patanol	olopatadine hydrochloride 0.1%	Alcon, and generic	3 yrs	5ml	BID
Pazeo	olopatadine hydrochloride 0.7%	Alcon	2 yrs	2.5ml	QD
Zaditor (OTC)	ketotifen fumarate 0.035%	Alcon, and generic	3 yrs	5ml	BID
Chronic Care Products					
Alocril	nedocromil sodium 2%	Allergan, and generic	3 yrs	5ml	BID
Alomide	lodoxamide tromethamine 0.1%	Alcon	2 yrs	10ml	QID
Crolom	cromolyn sodium 4%	Bausch + Lomb, and generic	4 yrs	10ml	QID

ANTI-INFLAMMATORY EFFECTS OF TACROLIMUS

Tacrolimus, a topical calcineurin inhibitor, is a potent anti-inflammatory. Research has found that tacrolimus 0.1% can be highly effective in treating severe allergic conjunctival diseases.

However, a recent study found that “tacrolimus eye drops often cause a stinging sensation or conjunctival redness, especially in the beginning of treatment of severely inflamed eyes.” The authors recommended that “this can be avoided by topical steroid pretreatment before the use of topical tacrolimus.”

“In addition, tacrolimus eye drops did not have an immediate effect and required one to two weeks to be effective. In contrast, topical steroids are fast-acting and can immediately relieve allergic symptoms. Although treatments eventually can be conducted without topical steroids, prompt relief of symptoms merits topical steroids.”

Miyazaki D, Fukushima A, Ohashi Y, et al. Steroid-sparing effect of 0.1% tacrolimus eye drop for treatment of shield ulcer and corneal epitheliopathy in refractory allergic ocular diseases. *Ophthalmology*. 2017 Mar;124(3):287-294.

SYMPTOMS AND SIGNS

Therapy for ocular allergies should be prophylactic, if at all possible. Therefore, in the setting of allergic conjunctivitis, therapy should be initiated early in the process, be sufficient to suppress the patient’s signs and symptoms, and be continued for long enough to prevent conversion into a chronic disease. The basis of treating any allergic eye disease remains the same: Quell the inflammation early to help avoid potential late complications.

In patients who present with symptoms of allergy as well as classic anterior segment findings, a topical, ester-based corticosteroid is a wonderful option. We recommend Alrex or off-label use of Lotemax gel (loteprednol 0.5%, Bausch + Lomb). Additionally, the generic, ketone-based corticosteroid FML ophthalmic suspension (fluorometholone 0.1%, Allergan) is a viable off-label therapy, although we have found it has a higher propensity to increase IOP compared to its ester-based loteprednol counterparts.

Frequency of instillation is tailored to the severity of the patient’s signs and symptoms. Typically, we prescribe a steroid drop Q2H for two days, then QID for one week, followed by BID for one more week. When the signs of allergic eye disease are subdued, consider switching your patient

to an antihistamine/mast cell stabilizer for ongoing symptomatic regulation.

While originally considered to be a “disease of affluence,” allergic conjunctivitis is now clearly recognized around the world, with a sharp increasing prevalence in countries with

sustained growth and developing urban populations.³ Doctors should keep in mind that, while the disease is not life-threatening, the persistent symptoms experienced by those who suffer from ocular allergies can have a significant impact on productivity and quality of life.

Remember, allergy is an expression of inflammation. In addition to the therapies listed above, don’t forget to discuss palliative options such as daily cold compresses to the inflamed eye. Also consider educating the patient on avoidance therapy. Telling your patients to place their allergy drops in the refrigerator until it’s time to instill the drop can add extra relief. **DG**

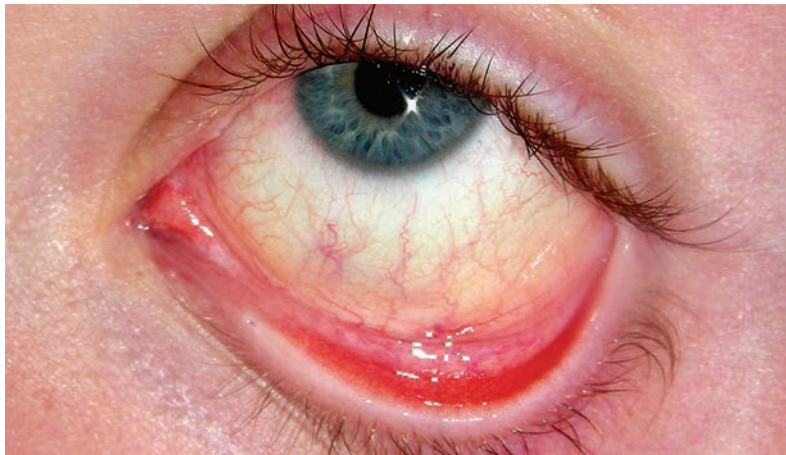1. Kari O, Saari KM. Diagnostics and new developments in the treatment of ocular allergies. *Curr Allergy Asthma Rep*. 2012;Jun;12(3):232-9.

2. Singh K, Axelrod S, Bielory L. The epidemiology of ocular and nasal allergy in the United States, 1988-1994. *J Allergy Clin Immunol*. 2010 Oct;126(4):778-83.

3. Gomes PJ. Trends in prevalence and treatment of ocular allergy. *Curr Opin Allergy Clin Immunol*. 2014 Oct;14(5):451-6.

4. Rosario N, Bielory L. Epidemiology of allergic conjunctivitis. *Curr Opin Allergy Clin Immunol*. 2011 Oct;11(5):471-6.

ITCHY EYES ARE OFTEN DRY EYES



Most patients with itchy eyes (consistent with allergic conjunctivitis) also suffer from dry eyes and hyperemia. Specifically, one study found the odds of patients with itchy eyes who also have dry eyes are more than twice that of patients with non-itchy eyes. The likelihood of these patients also experiencing redness were more than seven times that of patients with non-itchy eyes.

These results suggest that some symptomatic patients concomitantly have features of allergic conjunctivitis and dry eye syndrome.

Hom MM, Nguyen AL, Bielory L. Allergic conjunctivitis and dry eye syndrome. *Ann Allergy Asthma Immunol*. 2012 Mar;108(3):163-6.

EFFECTIVE USE OF ANTIBIOTIC AGENTS

Increasing antibiotic resistance sends many clinicians scrambling for more effective therapy. The key is to select the right medicine and dose it correctly. Here's how.

Since the early 1940s, the use of antibiotics is well-documented in reducing illnesses and fatalities attributed to many infections worldwide.

However, some bacteria are now resistant to the antibiotics that were at one time highly effective. This upward trend is causing concern throughout medical disciplines. Consequently, researchers are forced to find different, more effective drugs to fight off bacterial infections.

Antibiotic dosing is widespread and overprescribed. These drugs are generally cheap and are offered as pills, liquids and injections, so dosing is inherently easy for patients of all ages. While antibiotics do have a history of being remarkably effective, drug resistance has been underes-

timated. More recent medical literature bemoans the egregious overprescribing of systemic antibiotics, and begs physicians and other health care providers to use great restraint in such prescribing.

A recent report from the Centers for Disease Control and Prevention warns that antibiotic resistance causes two million bacterial and fungal illnesses, and 23,000 deaths yearly. It also causes an annual increase in direct health care costs of \$20 billion, plus \$35 billion in lost productivity.¹

Bear in mind that most studies on antibiotic resistance have focused on systemic antibiotics. But in the past few years, researchers have begun to look at resistance to topical ophthalmic antibiotics.

ANTIBIOTICS FOR ACUTE 'RED EYES'

In the setting of an acute red eye, we have found that the etiology is nearly always inflammatory, not infectious. An acute red eye with no mucopurulent discharge is rarely the result of bacterial infection. These inflammatory conditions require steroids, not antibiotics; yet time and time again clinicians prescribe an antibiotic drug that does not improve the patient's condition. Generally speaking, infectious diseases produce a discharge whereas inflammatory diseases do not. However, the hesitancy to prescribe a steroid and uncertainty of diagnosis continues to set the stage for antibiotics to be inappropriately prescribed in optometric practice.

WHY BACTERIAL DRUG RESISTANCE?

- When a strain of bacteria becomes resistant to an antibiotic, it becomes the dominant organism, as bacteria multiply quickly.
- Animals raised for dietary consumption are often fed antibiotics, thus potentially increasing resistance that can affect humans.
- Antibiotics have been and continue to be considerably overprescribed throughout the last 70 years.
- Antibiotics continue to be prescribed inappropriately, such as in the setting of a virus or inflammation.

TOPICAL ANTIBIOTIC DRUGS					
BRAND NAME	GENERIC NAME	MANUFACTURER	PREPARATION	PEDIATRIC USE	BOTTLE/TUBE
Fluoroquinolones					
Besivance	besifloxacin 0.6%	Bausch + Lomb	suspension	≥ 1 yr.	5ml
Ciloxan	ciprofloxacin 0.3%	Alcon, and generic	sol./oint.	≥ 1 yr./ ≥ 2 yrs.	5ml, 10ml/3.5g
Moxeza	moxifloxacin 0.5%	Alcon	solution	≥ 4 mos.	3ml
Ocuflox	ofloxacin 0.3%	Allergan, and generic	solution	≥ 1 yr.	5ml, 10ml
Vigamox	moxifloxacin 0.5%	Alcon	solution	≥ 1 yr.	3ml
Zymaxid	gatifloxacin 0.5%	Allergan, and generic	solution	≥ 1 yr.	2.5ml
Aminoglycosides					
Tobrex	tobramycin 0.3%	Alcon, and generic	sol./oint.	≥ 2 mos.	5ml/3.5g
Garamycin	gentamicin 0.3%	Perrigo, and generic	sol./oint.	N/A	5ml/3.5g
Polymyxin B Combinations					
Polytrim	polymyxin B/trimethoprim	Allergan, and generic	solution	≥ 2 mos.	10ml
Polysporin	polymyxin B/bacitracin	generic	ointment	N/A	3.5g
Neosporin	polymyxin B/neomycin/ gramicidin	generic	solution	N/A	10ml
	polymyxin B/neomycin/ bacitracin	generic	ointment	N/A	3.5g
Other Antibiotics					
AzaSite	azithromycin 1%	Akorn	solution	≥ 1 yr.	2.5ml
Ilotycin	erythromycin 0.5%	Perrigo, and generic	ointment	≥ 2 mos.	3.5g
Bacitracin	bacitracin 500u/g	Perrigo	ointment	N/A	3.5g

Accurate diagnosis and drug selection are paramount in patients presenting with red eyes. We have seen hundreds of patients who were treated elsewhere with topical antibiotics and presented to us for a second opinion when their condition did not resolve. We recognized the condition as inflammatory and initiated topical steroids; the patient improved in several days.

Thankfully, most of the commonly used antibiotic drops are broad-spectrum, and are generally effective against many common bacterial pathogens. We have found frequency of administration—rather than particular drug selection—to be the key determining factor of clinical outcome. Because most (but not all) of the currently approved topical antibiotics possess reasonable antimicrobial abilities, the more frequent the administration of these drops, the greater the clinical result. However,

the frequency for eye drop administration depends almost exclusively on the severity of the infectious expression.

In the setting of ocular infections, antibiotics are prescribed almost exclusively in topical or oral form. With the exception of besifloxacin—a suspension—all other antibiotic drops are solutions. Oral antibiotics are most commonly prescribed as a tablet, capsule or liquid (the latter used mostly in children).

In our practices, we prescribe oral antibiotics more commonly than topical ones simply because we encounter more patients needing oral antibiotic therapy, such as those with meibomian gland disease (doxycycline), rosacea blepharitis (doxycycline) and internal hordeola (cephalexin). For uncommon acute bacterial conjunctivitis, we typically prescribe generic Polytrim (polymyxin B/trimethoprim, Allergan), Tobrex

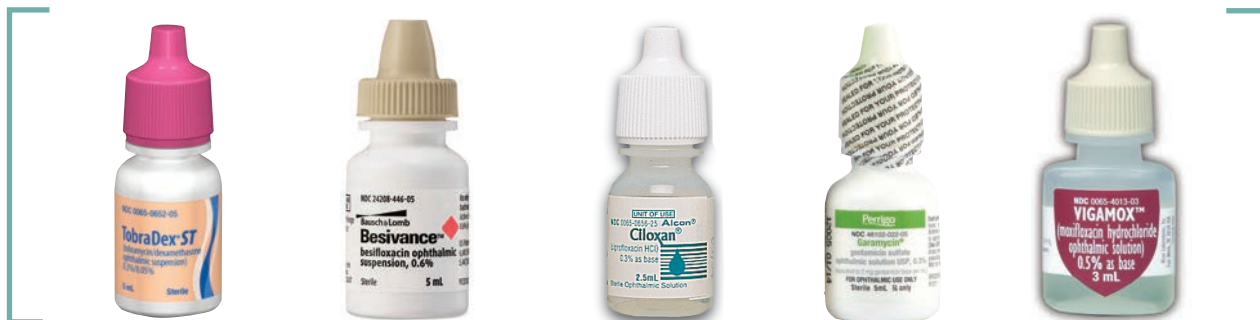(tobramycin, Alcon) or Besivance (besifloxacin, Bausch + Lomb).

Now, let's take a more in-depth look at this class of medicines. There are many antibiotics; however, only a few should have widespread use.

ANTIBIOTICS AND PREGNANCY

Clinicians are almost inherently overcautious when prescribing oral drugs for patients who are pregnant or breastfeeding. But like everyone else, pregnant women are just as susceptible to infections and should be treated appropriately.

Generally speaking, in a review of FDA categories (A-X), only category A and B drugs are considered safe for administration in pregnancy. While antibiotic usage in pregnancy is guarded due to ethical and legal issues, obstetricians use several classes of drugs routinely with no harmful effects to the mother or baby.



The three main drug classes that are safe in pregnancy are: penicillins, cephalosporins and macrolides—with penicillins, by far, the most prescribed antibiotic for pregnant women, based on our experience. All of these drugs are category B, with the exception of two macrolide drugs: clarithromycin and telithromycin (category C).

Penicillins and cephalosporins are considered category B due to a higher selective toxicity. This is because these drugs cause alterations of the beta-lactam ring, a structure that is unique to bacteria. Spanning from first (more gram-positive coverage) to fourth (more gram-negative) generation classes, cephalosporins are commonly used in eye care. First-generation drugs are especially common; cephalexin (e.g., Keflex) is routinely used to treat internal hordeola and mild cases of preseptal cellulitis. These drugs are perfectly fine to use during pregnancy and can prevent more serious disease sequelae.

Macrolides were first isolated in 1952, and quickly gained ground as a first choice of therapy for patients allergic to penicillin. Bacterial protein synthesis is inhibited by linking to the 50S sub-unit of the bacterial ribosome, which is different from the human ribosome. Erythromycin

is the oldest macrolide and is FDA-classified as category B.

One eye disease that must be treated with an oral medication (azithromycin) is adult chlamydial conjunctivitis. In one study comparing the efficacy of azithromycin and erythromycin, 15 pregnant women took 1g of azithromycin during gestation for a chlamydial infection.¹ Azithromycin was found to be better tolerated than erythromycin, and no adverse affects to the baby were reported.²

Keep in mind that the more commonly prescribed antibiotic drugs such as fluoroquinolones, aminoglycosides and tetracyclines are not safe in any stage of pregnancy due to documented harm to the fetus. As always, be mindful to comanage your pregnant patients with bacterial infections with their obstetrician when prescribing oral therapy.

BACITRACIN

Available since 1948, bacitracin, a strictly gram-positive antibiotic, is often employed in the clinical setting of staphylococcal blepharitis. It is only available in ointment form, which somewhat limits its practicality outside of bedtime dosing. After warm compresses and lid scrubs, bacitracin can be applied to the lid margins at night before the patient goes to bed.

This dosing is more sensible, as an ointment will blur the patient's vision if dosed during waking hours. If there is significant concurrent eyelid margin inflammation, then perhaps an antibiotic-steroid combination ointment such as generic Maxitrol (dexamethasone/neomycin/polymyxin B) would better serve the patient than just an antibiotic ointment.

Additionally, bacitracin can be used at bedtime to provide overnight coverage for moderate to severe ulcerative keratitis. Be advised that for true bacterial corneal infections, a broad-spectrum antibiotic is always preferred. In such cases, we dose besifloxacin ophthalmic suspension with Polysporin ophthalmic ointment (bacitracin/polymyxin B) because the polymyxin B is bactericidal against gram-negative pathogens.

THE AMINOGLYCOSIDES

While these drugs do (quite unfairly) carry a reputation for being potentially corneotoxic, aminoglycosides are relatively protected from bacterial resistance that comes from primary care use. Why? Due to ototoxicity issues, they are not used systemically, thereby considerably lowering the potential for antibiotic resistance. Remember, it is the widespread systemic use of antibiotics that tends to promote resistance. In fact, these older generic aminoglycosides are some of the most highly efficacious antibiotic eye drops available.

Aminoglycosides are often hesitantly prescribed due to their potential to cause a type IV hypersensitivity



reaction on rare occasions. Neomycin itself is broad-spectrum, but it does not cover *Pseudomonas*, which is why it is always packaged with polymyxin B or another antibiotic to cover gram-negative organisms. In our experience, type IV delayed hypersensitivity dermatconjunctivokeratitis reactions are exceedingly rare when the neomycin combination is used for no more than a week.

The exception is the rare patient who has been previously exposed to an aminoglycoside and already has immunosensitivity. Such patients can react to the aminoglycosides in just a day or two, which may also be the result of a type I hypersensitivity to initial exposure. Patient management is to simply stop the medication. Again, these are non-serious, annoying, superficial responses. In our many years of clinical practice, we have seen only half a dozen such events, mostly with neomycin exposure of greater than a week, and often when the drug was prescribed by primary care practitioners.

When neomycin (along with polymyxin B) is packaged with a steroid, such as generic Maxitrol, whatever expression of a hypersensitivity reaction that may be occurring typically remains subthreshold, or subdued, courtesy of the concurrent steroid.

As stated above, the aminoglycosides, used systemically, can cause ototoxicity. For this reason they are rarely, if ever, used in this way. Any drug actively or passively reserved for only topical use is relatively protect-

ed from resistance, thus enabling it to act as a powerful therapeutic agent for many decades. For example, bacitracin was brought to market in the 1940s and remains a superb, exclusively gram-positive antibiotic today. These medicines are highly effective, cheap and remain workhorse drugs in contemporary eye care.

We stress that bacterial infections are characterized by a mucopurulent discharge. Sometimes this is grossly visible; other times, the discharge is more subtle and is only found via slit-lamp observation of microparticulate debris in the lacrimal lake. Both the aqueous humor and lacrimal lake should be optically empty. Cellular and/or proteinaceous debris in the aqueous humor is exhibited in anterior uveitis, and debris in the lacrimal lake is typically seen in more subtle cases of acute bacterial ocular surface infection.

Every time you are uncertain of the diagnosis and are considering prescribing a topical antibiotic, always reconsider this low-yield therapeutic approach. At the very least, consider use of a combination antibiotic-steroid with appropriate follow-up care in two to three days.

POLYMYXIN B COMBINATIONS

Combination drugs that pair polymyxin B with a complementary agent can extend the total antibiotic coverage achieved.

Polytrim. Originally marketed by Allergan and now generically available, Polytrim (polymyxin B/trime-

thoprim) is an effective combination antibiotic available in solution form. Polymyxin B is active only against gram-negative bacteria. Trime-thoprim is broad-spectrum against many gram-positive and some gram-negative bacteria, and works by interfering with the folic acid pathway. Note that trimethoprim itself is not a sulfa drug, although it also inhibits the production of bacterial folic acid.

An advantage of Polytrim is that it is available in a 10mL bottle allowing more “bang for the buck.” Its propensity to cause ocular surface toxicity is minimal, so we often like to use it in combination with a bandage soft contact lens when there is significant epithelial compromise, such as a corneal abrasion.

Polysporin. This drug, which combines polymyxin B with bacitracin, is available generically but only as an ophthalmic ointment. The pairing of polymyxin B’s gram-negative and bacitracin’s gram-positive predilection makes this an excellent nontoxic, broad-spectrum antibiotic. However, because the preparation is only available in ointment form, its clinical utility is somewhat limited in patient care.

The drug is often used in pediatric eye care, instilled along the lids and lashes, where body temperature melts the ointment and allows adequate ocular surface application of the drug. Of course, this principle can be applied to patients of all ages.

In cases of bacterial keratitis or a severe bacterial conjunctivitis, Polysporin ointment can be especially



useful at night for sustained antibacterial coverage.

Neosporin. This triple-antibiotic comprised of neomycin, bacitracin and polymyxin B is conveniently available generically as an ophthalmic ointment and solution (the solution contains gramicidin, not bacitracin). Remember, both bacitracin and Polysporin are available only as ointments.

We rarely use Neosporin in eye drop form, as we prefer generic Polytrim (trimethoprim/polymyxin B), tobramycin or Besivance, depending on the nature and severity of the infectious condition. However, we use Neosporin ointment without hesitation for those rare occasions when overnight antibiosis is deemed necessary to enhance a clinical cure.

To be clear, neomycin is an efficacious drug that can occasionally cause a delayed type IV hypersensitivity reaction. Given that we have three alternatives (generic Polytrim, generic tobramycin and Besivance) that are much less prone to cause any sort of allergic response, we prefer to follow this simpler path for most patients most of the time.

THE FLUOROQUINOLONES

The options in this class have some notable differences.

Besifloxacin. Besivance, a unique, dual-halogenated fluoroquinolone, is the only topical ophthalmic antibiotic that comes as a suspension. As with all fluoroquinolones, Besivance provides activity against DNA gyrase and topoisomerase IV. Its broad-spectrum coverage combats gram-positive, gram-negative (including *Pseudomonas*), and anaerobic organisms, as well as methicillin-resistant *Staphylococcus aureus* (MRSA) and *Staphylococcus epidermidis* (MRSE). The latest research (ARMOR) has demonstrated *in vitro* that besifloxacin and vancomycin share very low MIC₉₀ levels against the common gram-positive ocular pathogens.³ (MIC₉₀ indicates the low-



KEEP IN MIND

THE EFFICIENT RED EYE EVALUATION

Each of these procedures generally takes about two to three minutes in most cases.

- Assess visual acuity (pinhole if indicated)
- Note the degree of conjunctival injection
 - Mild: dry eyes, allergy, chlamydia, mild bacterial infections
 - Marked: acute viral or non-specific bacterial infection, acute iritis
- Note the degree of conjunctival injection pattern
 - Sector injection: corneal infiltrate, episcleritis, phlyctenule, inflamed pinguecula
 - Global injection: uniform—bacterial or viral infection, or uveitis
 - More pronounced in fornices: bacterial infection
 - More pronounced paralimbally: uveitis
- Quality and quantity of discharge if any
 - Watery: viral
 - Mucoid: dry eyes, allergy, chlamydia
 - Mucopurulent: bacteria
- Preauricular lymphadenopathy (not grossly visible)
 - Most commonly, adenoviral
 - Less commonly, chlamydial
 - Rarely, hyperacute conjunctivitis
 - If grossly visible: Parinaud's oculoglandular syndrome (cat-scratch disease)
- Follicles vs. papillae: clinically virtually meaningless
 - Exception: Giant follicles in the inferior forniceal conjunctiva are highly indicative of chlamydial infection
- Character of cornea: Examine without, then with, fluorescein dye to rule out herpes keratitis, subtle abrasions, ulceration, through-and-through perforation (Seidel's sign)
- Measure the IOP if no contraindications exist
- Evert the eyelid to rule out conjunctival foreign material or pathology
- Examine the anterior chamber for cells/flare
- Quick ophthalmoscopy to rule out concurrent intraocular disease

est concentration of an antibiotic at which 90% of isolates are inhibited.)

As a suspension, this thick eye drop must be shaken prior to each use, and has been shown to maintain high concentrations on the ocular surface after instillation, with minimal systemic exposure.

A study in the *Journal of Ophthalmology and Therapy* concludes: "Large randomized, controlled clinical trials have established the efficacy and safety of besifloxacin administered three times daily for five days for the treatment of acute bacterial conjunctivitis in both adults and children, with high rates of clinical resolution

(up to more than 70% by day five) and bacterial eradication (more than 90% by day five), and a low incidence of adverse effects."⁴

For severe infectious processes such as microbial keratitis, we dose Besivance hourly (while awake) for one to three days, then taper the dose to every two hours for a few more days, then to four times a day for a few more days. Depending upon the severity and character of the infectious process, we may adjunctively prescribe Polysporin or Neosporin ointment at bedtime.

Ciprofloxacin. Ciloxan, a second-generation fluoroquinolone, remains

a drug of choice against the gram-negative *Pseudomonas* species, and remains close in efficacy to the fourth-generation fluoroquinolones. However, ciprofloxacin is a somewhat unstable solution that precipitates out when treating corneal ulcers and gives a fine powder-like appearance to the ulcer bed, which is of no clinical significance. Sight-threatening ulcers must always be cultured for identity and resistance to antibiotics.

Moxifloxacin. Two popular fourth-generation fluoroquinolones, topical moxifloxacin 0.5% available as Moxeza (Alcon) and Vigamox (Alcon), function very similarly. Of clinical note, Vigamox and Moxeza are the only preservative-free ophthalmic fluoroquinolone antibiotics, thus minimizing the potential for a toxic or allergic response (although such is exceedingly rare).

Patients should be informed that the drop has a slight yellow color to avoid the misconception that the drop has gone bad. In comparison to Vi-

gamox, Moxeza has a xanthan gum base that affords a prolonged contact time and allows a slight reduction in dosing frequency.

While all fluoroquinolones have developed significant antibiotic resistance, moxifloxacin appears to remain a satisfactory choice for bacterial conjunctivitis; personally, we would choose Besivance or fortified antibiotics (vancomycin or tobramycin) for bacterial keratitis because of their documented enhanced efficacy.

Ofloxacin. A second-generation fluoroquinolone, ofloxacin is rarely used. However, because the drug is generic, it remains a reasonable, inexpensive option for bacterial conjunctivitis. It is also available as brand-name Ocuflax (Allergan).

Gatifloxacin. A fairly effective fourth-generation fluoroquinolone, Zymar is FDA-approved to treat bacterial conjunctivitis. While useful, this and all fourth-generation fluoroquinolones are exhibiting increasing bacterial resistance.

Like all topical antibiotic medicines, use it more frequently initially (i.e., every one to two hours) until the condition improves. Then reduce its use to four times a day for a few more days until the condition is resolved.

SYSTEMIC AGENTS

Oral antibiotics remain wonderful options when used judiciously. Their clinical indications are vast, and they can be used in short-term to long-term or maintenance therapy (meibomian gland disease and rosacea blepharitis).

For an acute internal hordeola, we prefer the first-generation cephalosporin, cephalexin (Keflex), at 500mg BID for one week. If the condition is severe and/or the patient is large in size, 500mg QID for one week may be indicated. This predominantly gram-positive antibiotic has been shown to improve the infection in about a week. We may also prescribe generic Maxitrol ointment at night to the lid margins, after warm compresses and lid scrubs. Remind the patient that the

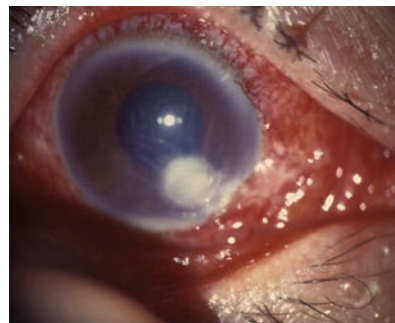THERAPEUTIC OPTIONS FOR CORNEAL ULCERS

Thankfully, infectious corneal ulcers are very rare, but when they do occur, they are treated aggressively with topical antibiotic eye drops. For perspective, leukocytic infiltrates also create little white lesions in the anterior stroma that may have a relatively small epithelial defect over the center of the white infiltrate. These infiltrates are often naively and incorrectly referred to as “ulcers,” when in fact they possess no infectious potential. Rather, these are inflammatory expressions—almost always occurring at or near the limbus—and treatment with a steroid (a combination drug such as Zylet, generic Maxitrol or generic TobraDex) is required to suppress this pathophysiological process.

Infectious ulcers come in two varieties: large, central ulcers; and small-to-large, noncentral ulcers. Central ulcers are most commonly treated with fortified tobramycin (for gram-negative coverage) and vancomycin (for gram-positive coverage). Most eye reference texts, such as the *Wills Eye Manual*, can guide you and the compounding pharmacy on how to make these preparations. Generally speaking, these medicines are used about every 30 minutes for the first few hours, then hourly while awake until obvious healing is occurring; every two hours for another few days; and finally, four times a day for a few more days. Rather than have the patients instill these drops around the clock, we prefer the use of Neosporin ophthalmic ointment at bedtime. Once good healing has occurred, the nocturnal ointment can be discontinued. Some patients are allergic to Neosporin, so alternatives exist (e.g., polysporin and Ciloxan, or even TobraDex ointment).

For noncentral ulcers, we use Besivance (besifloxacin 0.6% ophthalmic suspension) every 30 minutes for a few hours, then hourly, as outlined in the preceding paragraph concerning use of the fortified eye drops. Neosporin (or Polysporin) or TobraDex ointment at bedtime is also used as above.

We always cycloplege these patients, as they invariably will have a secondary anterior uveitis. Either atropine 1% or homatropine 5% is typically used to accomplish this purpose. The standard dosage is cycloplegia two to four times daily, depending upon the severity of the clinical condition.



STRATEGIES TO CONQUER BLEPHARITIS

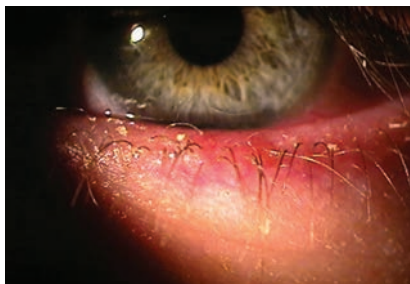Chronic anterior eyelid margin disease is most commonly caused by chronic, low-grade infection of *Staphylococcus aureus* and *Staphylococcus epidermidis* bacteria. These bacteria produce exotoxins, creating secondary inflammation to the adjacent eyelid marginal tissues. (This is distinct from meibomian gland disease, which has a wholly different pathophysiology.) Occasionally, these exotoxins can cause inferior corneal epithelial compromise.

Understanding the cascade of tissue compromise resulting from unchecked *Staph.* populations residing on the anterior lids perfectly provides the rationale for using a good antibiotic/corticosteroid combination drug for symptomatic blepharitis. No other drug or drug class even approximates the efficacy of such therapeutic intervention.

Any of the available combination drugs would work well short term (less than two weeks), but given that blepharitis is a chronic, recurrent disease, the drug we find best suited for treating blepharitis is a combination of tobramycin (excellent anti-*Staph.* action) with loteprednol (excellent, safe, anti-inflammatory action) known by the popular brand name Zylet.

Initiate treatment with Zylet four times daily for two weeks, depending upon the severity of the clinical disease, then just pulse dose four times a day for a week if or when breakthrough symptoms occur. Such pulse dosing is an effective and “steroid-sparing” therapeutic approach and one that we embrace for almost any chronic, recurrent ocular surface disease.

The combination drugs TobraDex and Maxitrol are both generic and relatively inexpensive, but contain dexamethasone, which limits their usefulness beyond a couple of weeks. One would rarely ever employ dexamethasone for a chronic condition because of its propensity to increase intraocular pressure. All three of these drugs are suspensions and, as such, need to be shaken well.



However, blepharitis is not treated exclusively with any eye drop. Concurrent use of eyelid scrubs is an essential component not only to help control the infectious/inflammatory disease, but as ongoing hygiene to maintain eyelid health. Avenova (hypochlorous acid 0.01%, NovaBay Pharmaceuticals) eyelid and eyelash cleanser has become quite popular, and does seem to help maintain healthy tissues in our patients. Further, with diminution of *Staph.* populations, there is a decreased risk of secondary styes and internal hordeola.

In summary, the combined use of an effective, safe antibiotic/steroid and meticulous eyelid hygiene perfectly embodies rational care for patients with anterior eyelid margin disease.

infection is typically secondary to an overproduction of bacteria on their lids, and that continued warm compresses and lid scrubs daily will help reduce the risk of recurrences.

Patients tend to have allergies to antibiotics more than other classes

CUT THE PILL—AND THE COST—IN HALF

The cost of brand name and generic drugs is continually changing, and clinicians are constantly faced with dynamic and ever-changing pricing structures. Regarding doxycycline, we have found in several instances that the 100mg units are cheaper than the 50mg units. To be more cost-effective for the patient, we occasionally prescribe 100mg doxycycline monohydrate tablets that can be split in half. (Patients can purchase affordable pill-splitters at most drug stores.)

of drugs. Always take a careful medical history to avoid the risk of an allergic reaction. If a patient has a true anaphylactic reaction to penicillin or penicillin-like drugs such as cephalosporin, we opt for Levaquin (500mg QD) or doxycycline (200mg QD), or Bactrim DS or Septra DS (both common brand names of trimethoprim with sulfamethoxazole) prescribed as two double-strength tablets BID for one week, which is the standard, commonly prescribed dosage.

If the patient is truly allergic to penicillin and sulfa, consider oral doxycycline 100mg BID for one week, or the oral fluoroquinolone levofloxacin 500mg once daily for one week. For perspective, the risk of a cross-sensitivity reaction of a cephalosporin in a patient who is truly allergic to penicillin is about 0.1%—but why ever take the miniscule risk? Just prescribe an alternative class.

Occasionally, we encounter pa-

tients who need antibiotic treatment for chronic conditions such as meibomian gland disease or rosacea blepharitis. We prescribe doxycycline at 50mg daily for three to six months. The dichotomous nature of doxycycline (anti-infective at high dosage and anti-inflammatory at low dosage) requires different dosing based on clinical intent.

While both doxycycline hyclate and doxycycline monohydrate are well-tolerated, the monohydrate form appears to be a bit better tolerated. **DG**

1. Centers for Disease Control and Prevention. Antibiotic Resistance Threats in the United States, 2013. Available at: www.cdc.gov/drugresistance/pdf/ar-threats-2013-508.pdf (last accessed March 24, 2017).

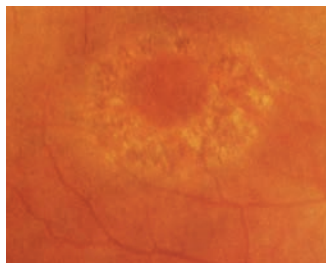
2. Bush MR, Rosa C. Azithromycin and erythromycin in the treatment of cervical chlamydial infection during pregnancy. *Obstet Gynecol.* 1994 Jul;84(1):61-3.

3. Asbell PA, Sanfilippo CM, Pillar CM, et al. Antibiotic resistance among ocular pathogens in the United States: Five-Year results from the antibiotic resistance monitoring in ocular microorganisms (AR-MOR) surveillance study. *JAMA Ophthalmol.* 2015 Dec;133(12):1445-54.

4. Mah FS, Sanfilippo CM. Besifloxacin: Efficacy and safety in treatment and prevention of ocular bacterial infections. *Ophthalmol Ther.* 2016 Jun; 5(1): 1-20.

PROTECT PATIENTS FROM PLAQUENIL TOXICITY

Despite its potential for retinal toxicity, this drug can be useful for treating immune or inflammatory diseases. Here is the latest information to guide your conversations with prescribing physicians.



The classic appearance of "bull's eye" maculopathy from hydroxychloroquine toxicity.

Virtually all optometrists have patients taking hydroxychloroquine (Plaquenil, AvKare). This drug is most commonly prescribed to moderate the expression of rheumatoid arthritis and systemic lupus erythematosus, but it is now being investigated for new applications in diabetes, heart disease and cancer.

Despite its potential for retinal toxicity, hydroxychloroquine is a useful drug, and has fewer systemic side effects than many of the alternative medications used for immune or inflammatory diseases. Hydroxychloroquine is a major lifestyle-enhancing medication and a lifesaver for patients and rheumatologists alike.

This is why we all need to use exceptional clinical judgment in consulting with and advising prescribing physicians regarding stopping this medication. This discussion will give you the guidance needed to make these critical decisions.

In keeping with our unrelenting admonition to colleagues to read the literature, the critical knowledge we share below was gained from "Recommendations on Screening for Chloroquine and Hydroxychloroquine Retinopathy (2016 Revision)" published in the June 2016 *Ophthalmology*.¹

Chloroquine has greater toxicity potential than does hydroxychloroquine, and as such, patients are now generally prescribed hydroxychloroquine. Thus, this article focuses exclusively on hydroxychloroquine. Further, this update builds from our discussions in the 2014, 2015 and 2016 *Clinical Guide to Ophthalmic Drugs*.

Since it is well-documented that a large minority of patients are overdosed on hydroxychloroquine, our prime responsibility is to help guide the prescribing physician on the proper dosage.² Our exclusive goal in providing this guidance is prevention of vision loss. We have very professionally, and very appropriately, corresponded with many rheumatologists over the decades. Dr. Thomas has been an expert witness on cases in which the optometrist was sued for failure to properly screen for hydroxychloroquine toxicity when the patient suffered vision loss; the rheumatologist was also a defendant in these cases—all preventable had proper doctor-to-doctor communication been accomplished for the benefit of the patient. So, ODs must not only screen patients appropriately but also advise our medical colleagues and patients about risks, safe dosing and appropriate screening procedures. Once you are armed with the appropriate knowledge, you are as expert as anyone else to give appropriate, patient-centric guidance. And, as such, you are equally legally liable for failing to do so.

Our primary responsibilities are (1) to conduct a proper hydroxychloroquine screening and (2) to provide proper dosing guidance to the prescribing physicians. Here, we address both goals by discussing select recommendations from the recent landmark article. Some quotes or in-context paraphrases from this article, and our commentary (indicated in italics), follow.

- "Toxicity is not rare among long-term users" of Plaquenil, and the risk is "highly dependent on the daily dose by weight."

- While non-Asian patients characteristically exhibit damage involving the central 2 to 8 degrees, Asian patients characteristically show more peripheral damage, so perform a 24-2 or 30-2 visual field with this subset of patients. Be mindful that these two test patterns have only four central tested points, so if even one such point is defective, there needs to be retesting with a 10-2 protocol—the recommended visual field test for non-Asian patients. A white (not red) target is recommended.

- While previous discussions have centered on “ideal” body weight, or lean body weight, newer research has shown that hydroxychloroquine stores “primarily in melanotic tissue, liver, and kidney, whereas concentrations are low in muscle, fat, and a variety of other organs.” For this reason, the authors recommend that all patients using hydroxychloroquine keep daily dosage to less than 5mg/kg of real body weight. Just for perspective, the historic dosage has been 6.5mg/kg of body weight, which equates to 135 pounds of ideal weight, based on the most common dosage of 400mg per day. With this newer dosage recommendation of less than 5mg/kg of actual weight, patients are relatively safe at a weight of 75 pounds or more.

Our practical conclusion is that 300mg/day can keep most patients well-controlled, and that enables a 25% overall reduction in drug exposure. This would enable many more smaller-bodied patients (from 135 pounds down to 100 pounds) to also realize a 25% reduction, and to safely use this dosage of hydroxychloroquine. This newer approach makes proper dosing easier for the prescribing physician and the optometrist monitoring for iatrogenic maculopathy.

- “Patients staying with 5mg/kg per day of actual body weight of at least 100 pounds have less than 1% risk in the first five years of therapy and less than 2% up to 10 years.” *Since hydroxychloroquine tablets come only as 200mg, “intermediate” dosing can easily be accomplished by taking one*

DEBATE ON PLAQUENIL DOSING

Given its basis in objective science, one would think that there would be uniform agreement on such a topic as Plaquenil dosing, but that is not the case. In the October 2016 issue of *The American Journal of Ophthalmology*, we see how brilliant physicians differ on this critical issue in their commentaries.^{1,2}

Points:

- “The concentration [of hydroxychloroquine] in skin and fat were just below those of muscle, indicating that the drug is stored to a similar level of all of these tissues.”
- Real body weight is more predictive of retinopathy than ideal weight over the full range of body mass index (BMI).”
- “Using real weight is simpler than performing unnecessary ideal body weight calculations, and we strongly urge that patients stay below a daily dose of 5mg/kg,” (i.e., 300mg/day). *The usual dosage of 6.5mg/kg—400mg per day—of ideal body weight would overdose patients weighing less than 135 pounds, whereas if dosed at 5mg/kg of real body weight, this 300mg per day could be used in patients weighing as little as 105 pounds without increasing the risk of retinopathy.*

Counterpoints:

- “The concentration of drug in muscle was 4.5 times that in fat.”
- “The concentration of chloroquine in liver, lung and spleen were 38.9, 22.6 and 16.3 times the concentration in fat.”
- Safe dosing “cannot be based on either ideal body weight or actual body weight alone, as a consequence of their non-uniform distribution across fat and other tissues. Properly performed, the lesser of ideal body weight and actual body weight should be used for calculating safe doses. For the commonly prescribed dose of hydroxychloroquine, 400mg per day, using ideal body weight alone, is dangerous if the patient is asthenic [skinny]. Using actual body weight alone is dangerous if the patient is short and obese.”
- “Obese individuals should be dosed on the basis of height, which allows estimation of asthenic or ‘ideal’ body weight.”

In summary, be attentive to the dosing of patients, especially small, short-statured persons. Assuming the perspective that uptake of hydroxychloroquine is less in fat, be mindful of how obesity, especially in the short-statured, could errantly influence one’s risk assessment. We still marvel that there is not a solid consensus on relative compartmental distribution of hydroxychloroquine in the body. Such firm knowledge would enable much simpler care.

As well, there are several mechanisms to calculate ideal body weight. Though there are slight differences, they are fairly close. Use your best judgment on which to use; after all, you are the one actually evaluating the patient.

1. Melles RB, Marmor MF. The prevalence of hydroxychloroquine retinopathy and toxic dosing, and the role of the ophthalmologist in reducing both. *Am J Ophthalmol.* 2016 Oct;170:240.

2. Browning DJ. The prevalence of hydroxychloroquine retinopathy and toxic dosing, and the role of the ophthalmologist in reducing both [reply]. *Am J Ophthalmol.* 2016 Oct;170:240-1.

tablet Monday, Wednesday and Friday, and two tablets on the alternate days. Or, for more refined dosing, take two tablets Monday, Wednesday and Friday, and one on the alternate days. Obviously, the total weekly exposure will be nearly identical, but for the ultimate on precision prescribing, these are two easily accomplished options.

- “The most critical risk factor” for the development of Plaquenil toxicity

is “excessive daily dose by weight.”

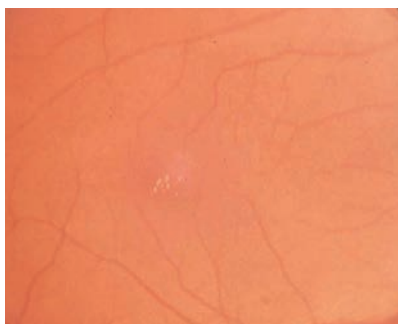
- “Even patients using a recommended dose have significant risk after decades of use.”

- Hydroxychloroquine is cleared to a large degree by the kidneys, so renal disease effectively increases the circulating level of the drug, and the toxicity risk. Be sure to inquire about any significant kidney disease when assessing risk.

- Tamoxifen is a commonly used drug to help treat or prevent breast cancer. A newer study found that concurrent use of tamoxifen with hydroxychloroquine increased the risk of toxicity approximately five times. Be keenly aware of this potential for exacerbation. Furthermore, tamoxifen is known to cause, albeit rarely, a crystalline maculopathy (as shown below). As you may be aware, tamoxifen is being slowly but steadily replaced with newer agents known as aromatase inhibitors; common brand names are Arimidex (anastrozole, AstraZeneca), Aromasin (exemestane, Pharmacia and Upjohn) and Femara (letrozole, Novartis). Research suggests that these newer medications to treat breast cancer do not cause an increase in risk associated with hydroxychloroquine use.

- Patients with underlying macular disease may be at higher risk for toxicity, although the degree of increased risk is unknown and likely varies from person to person based on the character and expression of the macular tissues. We recommend baseline photos of any underlying macular disease.

- “All patients beginning long-term hydroxychloroquine therapy should have a baseline ophthalmologic examination within the first year of starting the drug to document any complicating ocular conditions and to establish a record of the fundus appearance and



This patient, who was taking Tamoxifen, developed toxic maculopathy (not concurrently taking Plaquenil) in the right eye. The left eye was identical. Note the tiny crystalline deposits right at the foveal tissues.

functional status.” Though baseline visual fields and SD-OCT are always useful, “it is not critical to obtain them at baseline unless abnormalities are present (e.g., focal macular lesion, glaucoma) that might affect screening tests. The baseline examination also provides an opportunity for advising patients and prescribing physicians about proper dose levels (and the ability to adjust them) and the importance of regular screening if they continue the medication long-term.”

- “It is important to check the dosage relative to weight at every visit and to ask about changes in systemic status, such as major weight loss, kidney disease or tamoxifen use.” *You may think these considerations should be exclusively the responsibility of the prescribing physician, and we fully agree. But it is well-established that many seem to be aloof in this regard. Bear in mind that life is a team sport and that our patients also rely on us for their well-being. We, as optometrists, need to have a keenly watchful eye on our patients and communicate appropriately with the prescribing physician.*

- “We recommend the use of both automated visual fields and SD-OCT for routine primary screening because these are widely available.” They also recommend white SITA testing with pattern deviation plots, “which distinguish regional loss from background sensitivity better than the gray scale.” *This is similar to glaucoma, whereas the gray scale is excellent for detecting and monitoring neurological disease.*

- “The 10-2 field pattern has high resolution within the macula and is excellent for non-Asian patients. However, wider test patterns (24-2 or 30-2) are needed for Asian patients in whom toxicity often manifests beyond the macula. These larger patterns have only four central test spots, and even a single central spot of reduced sensitivity should be taken seriously.”

- “Visual fields can vary markedly between visits, and some patients re-

CALCULATING “IDEAL” BODY WEIGHT IS STRAIGHTFORWARD

- For women, starting at 5 feet and 100 pounds, add 5 pounds for each additional inch in height.
- For men, starting at 5 feet and 105 pounds, add 5 pounds for each additional inch in height.

spond more reliably than others. Proper field interpretation requires a sensitive eye to the characteristic pattern of hydroxychloroquine loss.”

- “As damage from hydroxychloroquine develops, the SD-OCT shows localized thinning of the photoreceptor layers in the parafoveal region in non-Asian eyes or near the arcades in many Asian eyes. These localized areas of photoreceptor loss are strong indications of toxicity.” As with all visual field testing, if very early changes seem tenuous, the test can be repeated or other tests can be performed for confirmation. As noted earlier: It is important to emphasize that hydroxychloroquine is a useful drug with fewer side effects than many of the alternative medications, the authors stress. “Thus, screening can be viewed as a means of helping patients continue hydroxychloroquine (by not stopping the drug for uncertain findings).”

- “Ophthalmoscopy is not a screening tool because photoreceptor damage is detectable with other techniques well before visible changes in the fundus.”

- “Amsler grid testing is not consistent enough for reliable screening of subtle scotomas.”

- “Color [vision] testing errors may occur, but are not sensitive or specific.”

A critical part of our global patient care services involves being attentive to patients taking hydroxychloroquine. We must be keenly aware of the clinical guidance set forth in this article and apply it to the care of our patients. DG

1. Marmor MF, Kellner U, Lai TY et al; American Academy of Ophthalmology. Recommendations on Screening for Chloroquine and Hydroxychloroquine Retinopathy - 2016. *Ophthalmology*. 2016 Jun;123(6):1386-94. Available at: www.aao.org/clinical-statement/revised-recommendations-on-screening-chloroquine-h. Accessed January 6, 2017.

2. Melles RB, Marmor MF. The risk of toxic retinopathy in patients on long-term hydroxychloroquine therapy. *JAMA Ophthalmol*. 2014;132:1453-60.

NEGOTIATING DRY EYE DISEASE PATHWAYS

Management of dry eye is shifting from solely using tear replacement strategies to also controlling inflammation. Also, research is targeting meibomian gland disease as the primary driver.

Interest in dry eye disease is at an all-time high. In this chapter, we present rational, scientifically sound, patient-centric approaches to helping those with this unique ocular surface disease. The goal is not to address the cascade of dry eye disease at the cellular level; it is to provide a comprehensive overview of our clinical perspective, bolstered by the peer-reviewed literature and expert commentary.

PRIMARY FOUNDATION OF DED

Historically, the therapy for dry eye has been to manage the signs and symptoms using tear replacement and tear conservation strategies. In addition to the numerous tear replacement options, we also currently enjoy access to multiple medications for managing inflammation.

Most encouraging is that scientific research has shifted our thinking and practice to also address tear film instability—considered to be the root cause of dry eye—along with the most common cause of dry eye: meibomian gland disease (MGD), the predominant driver of dry eye, as it results in a poor lipid layer that destabilizes the tear film. Understanding that the ocular surface cannot be rehabilitated in the absence of healthy meibomian gland function has dramatically improved the care of our patients and streamlined our overall approach.

** Loteprednol (Lotemax) therapy for inflammation due to dry eye disease is considered an off-label use. All mentions of such use herein reflect the views of the authors.*

With the meibomian glands, rather than the lacrimal glands, at center stage in the etiopathogenesis of this highly complex disorder, our core therapeutic goal is to enhance meibomian gland function for all patients. No matter what signs and symptoms they present with, we know they all require rehabilitation to healthy meibomian gland function. To address gland function, we have incorporated the essential methods of treating meibomian gland obstruction.

In an ideal world, we would all have LipiFlow (TearScience) or a similar device in our offices, which we would use on our dry eye patients every six to 24 months; however, in the absence of LipiFlow or similar, we know that manual expression of the glands can be effective. Whether automated or manual, evacuating the gland contents to improve gland function diminishes the need for all other topical interventions for dry eye over the long term.

It is common knowledge that a defective lipid layer is the epicenter of precorneal tear film dysfunction in most dry eye patients. With insufficient quantity and quality of the lipid layer, aberrations of the voluminous watery layer occur, leading to ocular surface inflammation. Once the tear film begins to deteriorate and inflammation subsequently occurs, patients present to us with the typical complaints of dry, burning, sandy or gritty, and itchy eyes.

SYMPTOMATOLOGY SIMPLIFIED

Diagnosing manifest dry eye disease can be profoundly simple and largely defined by attentive history; however, this is not

DRY EYE DISEASE WITH CHRONIC PAIN SYNDROMES

A small subset of dry eye patients may remain symptomatic even after trying exhaustive therapeutic interventions. These unfortunate patients may have a central (i.e., central nervous system) nociceptor malfunction that has nothing to do with their ocular surface status. A corneal subspecialist has no better tools than we do in this regard, and a neurology or pain clinic consultation may be in order.

This concept of central pain receptor dysfunction is in its infancy, and remains elusive in both diagnostic and therapeutic intervention. Excerpts from a recent article help to explain this phenomenon:¹

- Chronic pain syndromes are often described as conditions with chronic pain in one or more body parts without obvious tissue-level pathology. These conditions include irritable bowel syndrome, chronic pelvic pain and fibromyalgia (also known as chronic widespread pain syndrome), among others.
- Dry eye patients with a self-reported chronic pain syndrome report worse dry eye symptoms, despite having the same or less severe clinical grading of their ocular surface disease than dry eye patients without a chronic pain syndrome.
- Given the high prevalence of chronic pain syndromes in the general population, and especially in the dry eye population, these findings may help optometrists, ophthalmologists and family doctors understand the discrepancy between signs and symptoms in subgroups of patients with dry eye disease.
- The finding of increased symptoms in dry eye disease patients with chronic pain syndrome adds further evidence to the theory that dry eye symptoms are, in part, a consequence of neuropathic ocular pain, instead of thinking of dry eye as a tear dysfunction syndrome only. Indeed, many studies have shown dysfunction in the corneal pain system in dry eye settings, including the presence of spontaneous dysesthesias, allodynia, hyperalgesia and corneal nerve morphologic and functional abnormalities.
- Results indicate that dry eye patients with a chronic pain syndrome, both in the general population and in the dry eye clinic, might have dysfunctional pain perception, and this should be considered, particularly when symptoms appear more severe than the ocular signs suggest. This subgroup represents a challenge to healthcare providers, as these patients may be more likely resistant to standard therapies of dry eye aimed at the ocular surface.
- Based on this and other corroborating articles, it appears that there is indeed a small subset of dry eye-type patients beyond our current therapeutic reach. Our duty to these patients is to have them consult with specialists in neurology, rheumatology or a pain management clinic, all of which have limited resources to help these patients.

Allodynia: a condition in which typically non-noxious stimuli elicit pain. It is the perception of pain/discomfort to brushing, pressure, exposure to wind, light, heat or cold out of proportion, or beyond a normal response.

Hyperalgesia: Abnormally heightened sensitivity to pain.

1. Vehof J, Sillevs Smitt-Kamminga N, Kozareva D, et al. Clinical characteristics of dry eye patients with chronic pain syndromes. *Am J Ophthalmol.* 2016;Feb;162:59-65.e2.

always the case. Once patients describe the hallmark complaints, some clinicians choose to use a variety of in-office assessments beyond slit-lamp examination of the lacrimal lake and measuring tear film break-up time, although we have found these evaluations to be superfluous. Our next step is to develop an interventional plan to

manage the manifest symptoms.

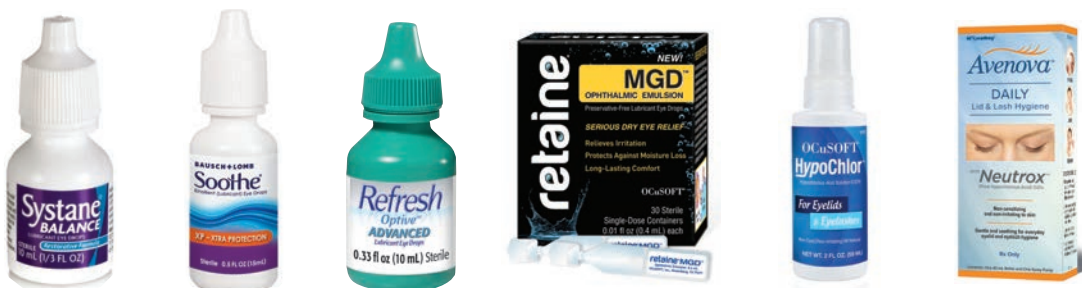To quantify the symptoms, Dr. Melton has developed an approach that is simply to ask the patient: “On a scale from one to 10, how badly do your eyes bother you?”

The success of your therapeutic strategy in addressing symptoms can be ascertained by re-asking the same

question. We see no reason to have patients complete any questionnaire when we use this straightforward and practical approach.

TREATING AND MANAGING THE DRY EYE PATIENT

Besides capturing symptoms, how do we best care for this population? It’s



COMMONLY USED LIPID-BASED ARTIFICIAL TEARS

Brand Name	Manufacturer	Lipid	Lubricants	Preservative
Refresh Optive Advanced	Allergan	castor oil	carboxymethylcellulose, glycerin, polysorbate 80	Purite (stabilized oxychloro complex)
Refresh Optive Advanced Preservative Free	Allergan	castor oil	carboxymethylcellulose, glycerin, polysorbate 80	none
Retaine MGD	OcuSoft	glycerol	light mineral oil, mineral oil	none
Soothe XP	Bausch + Lomb	light mineral oil, mineral oil	polysorbate 80	polyquarternium-1
Systane Balance	Alcon	mineral oil	propylene glycol	polyquarternium-1

nanced and can be quite complex. Not all patients need all of the following interventions. As with any chronic, progressive disease, care must be individualized based on the time of diagnosis and specific patient characteristics. What is common to all patients is the need for tear film stability to be restored. Beyond this, given that MGD is one major driver of dry eye, meibomian gland rehabilitation and the management of inflammation are key approaches.

- *The goal in treating meibomian gland obstruction is to evacuate the gland contents.* This is not done by pressing the lower eyelid against the globe without protecting the globe from pressure, as that maneuver would require the intraocular pressure to be very high for it to be effective. Rather, use the Mastrota Meibomian Paddle (OcuSoft), a cotton swab, the butt end of your jeweler's forceps, or other appropriate instrument as a backstop (after proparacaine instillation). Then apply sufficient (uncomfortable) pressure for 15 seconds in an attempt to express the glandular contents. (Expression can be enhanced by aggressively preheating the eyelids, but this is rarely practical in a busy office setting.) This procedure can be effective and usually lasts two to four months.

- *Clean the keratinized lid margins by gently removing debris from the margin and mucocutaneous junction with a golf club spud (no topical anesthesia is needed for debridement).* It feels good to the patient, serves to

open the meibomian gland orifices and improves what meibum flow is there.

This is quite helpful and should be performed on every dry eye disease patient

NEUROPATHIC EYE PAIN AND IDIOPATHIC DRY EYE

Thankfully, most dry eye patients can be helped with the myriad therapeutic approaches available. However, a small subset of patients remains symptomatic, no matter what is done. Their eyes appear healthy. That is, there is no superficial punctate keratopathy; they also have good tear lake volume, normal tear film break-up time and so on, yet their eyes are uncomfortable. What's going on?

Many of these patients have what is called somatosensory dysfunction, which accompanies such neuropathic eye pain. A yet-to-be-understood defect in the nociceptive system may be driving ocular pain in some patients with idiopathic dry eye disease.

As optometric clinicians, all this sounds pretty esoteric and daunting. Let us share a few direct quotes from the expert literature to try to wrap our heads around this relatively newly appreciated somatosensory dysfunction.

- Pain does not exist in isolation, and individuals experiencing one form of chronic pain often have other chronic pain conditions—a concept termed chronic overlapping pain conditions. Dry eye symptoms may represent a peripheral manifestation of a chronic overlapping pain condition.¹
- For a significant number of patients, there is a discordance between the signs seen on physical exam and the sensory symptoms these patients feel. Nerve sensitization, genetic susceptibility to pain, neuropathic pain mechanisms and psychological status have been proposed as mechanisms for this incongruity between signs and symptoms of dry eye disease.²
- Dry eye symptoms are not only manifestations of a local disorder, but also involve somatosensory dysfunction beyond the trigeminal system.²
- Dry eye is also strongly associated with depression, post-traumatic stress syndrome and anxiety, providing further evidence of centralized pain disorder.¹
- Quantitative sensory testing at a site remote from the eye, mainly at the forearm, implicates central sensitization as a mechanism modulating aberrant sensations in a subset of patients with ocular neuropathic pain.²

These patients may best be served by neurologists or pain management clinics. Of course, we need to exhaust all reasonable, prudent therapeutic interventions before defaulting to such tertiary measures.

1. Galor A, Levitt RC, McManus KT, et al. Assessment of somatosensory function in patients with idiopathic dry eye symptoms. *JAMA Ophthalmol.* 2016 Nov 1;134(11):1290-8.
 2. Rosenblatt MI. Remote quantitative sensory testing and neuropathic ocular pain. *JAMA Ophthalmol.* 2016 Nov 1;134(11):1298.



TESTING FOR DED IN PATIENTS WITH SJÖGREN'S SYNDROME

Be mindful that a few of our patients may be harboring subclinical Sjögren's syndrome (SS)—with dry eye symptoms being just the tip of the iceberg. As such, we should be cognizant of several key points. These excerpts from a recent article serve to bring to our attention this entity.¹

- Early detection of SS is important because patients who are started on biological agent treatment within the first five years of onset may be more likely to respond to treatment than those with delayed initiation of therapy.
- The majority of patients first seek medical care for dry eye symptoms, but many are misdiagnosed as having non-autoimmune-related dry eye.
- Eye care physicians are severely hampered by the absence of evidence-based screening tools that reliably distinguish SS-related from non-SS-related dry eye patients, resulting in under-referrals and increased delays in the diagnosis of Sjögren's syndrome.
- Although many clinicians commonly use fluorescein staining of the cornea in their dry eye evaluation, few routinely assess ocular surface staining of the conjunctiva.

• Lissamine green staining of intrapalpebral conjunctiva was the most important ocular sign in distinguishing SS from non-SS dry eye.

• These results highlight the importance of including conjunctival staining when screening dry eye patients, as significant positive staining is associated with two of the non-ocular diagnostic criteria for SS (positive labial salivary gland biopsy and serology) and therefore are highly suggestive of Sjögren's syndrome.

• Given the strong association between SS and lymphoproliferative disease, eye care physicians serve an integral role in screening for this debilitating and potentially life-threatening syndrome.

We all should be attentive to the real possibility that we can serve a vital role in screening for Sjögren's syndrome. While the Sjögren diagnostic test (Bausch + Lomb) is readily available and is virtuous, something as simple as attentive observation of the intrapalpebral bulbar conjunctiva stained with lissamine green vital dye could help us identify this small subset of patients harboring preclinical Sjögren's syndrome.

1. Bunya VY, Bhosai SJ, Heidenreich AM, et al. Association of dry eye test with extraocular signs among 3514 participants in the Sjögren's syndrome international registry. *Am J Ophthalmol.* 2016 Dec;172:87-93.

at every visit. There is no CPT code for this maneuver, but it only takes about 10 to 15 seconds per eyelid.

• *Place all of your dry eye patients on a premium-quality omega-3 fish oil supplement at 2,000mg per day.* Let them know it can take four to six months to slowly build up to a meaningful degree. For the subset of patients who have difficulty swallowing these relatively large capsules, two good liquid (and quite palatable) supplements that can be used are Coromega Orange Squeeze (coromega.com) and Nordic Naturals (nordicnaturals.com). We recommend these be taken with breakfast, or certainly by lunch.

For those patients with advanced meibomian gland disease, with or without advanced rosacea blepharitis, it may be that concurrent use of 50mg of doxycycline daily for about three to four months would more effectively jump-start the fatty acid metabolism enhancement within the meibomian glands. Doxycycline needs to be taken with breakfast or lunch, not near bedtime, to reduce the small risk of gas-

troesophageal reflux. Bear in mind that some women rapidly develop vaginal yeast infections when on antibiotics, so be sure to discuss this possibility with your female patients. And patients should be warned about photosensitivity, which can occur at this low dose. The monohydrate salt is slightly more patient-friendly than the hyclate salt form, but this is rarely a big deal. For the patient who is allergic or intolerant

to doxycycline, perhaps a trial of oral azithromycin could be initiated.

• *Start every dry eye disease patient on a lipid-based artificial tear and instruct them to use it as often as they care to, up to four to six times a day initially.* We prefer either Soothe XP (Bausch + Lomb) or Systane Balance (Alcon) because our mentor and friend, Donald Korb, OD, a world-recognized expert in the area of meibomian gland



In our 2016 *Guide*, we introduced a new technology then in development called intranasal lacrimal neurostimulation (ILN), a battery-powered, handheld device used to stimulate lacrimation. The device, now called TrueTear, was recently FDA approved and is marketed by Allergan. We are intrigued with this novel approach, and are hopeful it will be beneficial. We look forward to using TrueTear in the care of some of our dry eye patients.

As the tear film is essentially three-layered, and lacrimal stimulation is thought to enhance the watery layer, it will be critical to protect this augmented aqueous layer with a robust lipid layer.

Photo: Allergan

DESICCATING STRESS IN SJÖGREN'S SYNDROME

A recent study evaluated the response of the lacrimal function unit in Sjögren's syndrome (SS)-associated dry eye patients exposed to two simulated daily life environmental conditions. Here's what the researchers reported:

- Sjögren's syndrome is a chronic, systemic autoimmune disease characterized by lymphocytic infiltration of the exocrine glands and mucosal epithelium.
- Concentrations of some tear molecules in severe dry eye patients are consistently different from those of healthy subjects.
- Inflammation plays a major role in dry eye disease. Although the exact etiopathogenesis of dry eye disease is not yet completely understood, there is global agreement regarding its inflammatory nature.

Our take: This is why we are quick to start patients with moderate-to-severe disease on loteprednol for two to four weeks; it is based on rock-solid science.

- It has been previously demonstrated that spontaneous blink rate while reading is lower compared to other actions (such as conversation).
- Meibomian gland disease was found in the vast majority of Sjögren's syndrome patients.
- Even a short exposure to a desiccating environment can produce a significant deterioration of the lacrimal function unit in female SS dry eye patients. The often-unnoticed exposure to these conditions during daily life may increase inflammatory activity rapidly, triggering an ocular surface deterioration.

López-Miguel A, Tesón M, Martín-Montañez V, et al. Clinical and molecular inflammatory response in Sjögren syndrome-associated dry eye patients under desiccating stress. *Am J Ophthalmol.* 2016 Jan;161:133-41.e1-2.

RISK FACTORS FOR SEVERE DRY EYE

Here is a summary of literature findings about risk factors for severe dry eye.

- Patients with neuropathic pain-like symptoms (hot/burning ocular pain and sensitivity to light and wind) had a more persistent and severe course of dry eye symptoms.¹
- Most patients with severe dry eye symptoms at baseline had persistent, severe symptoms at one year.²
- Patients with neuropathic pain (spontaneous burning pain, sensitivity to light and sensitivity to wind) were associated with a chronic disease course and a decreased response to local therapy.³
- Repeated (ocular surface) stress can lead to peripheral sensitization (to corneal nociceptors), which may subsequently lead to changes in the central nervous system.³

Many risk factors and environmental stressors can set the stage for dry eye symptoms and worsening disease. These include:

- Excess screen time
- Inadequate blinking
- Meibomian gland dysfunction
- Suboptimal levels of omega-3 essential fatty acids
- Oral medicines known to affect tear function
- Sleep apnea/insomnia
- Floppy eyelid syndrome
- Exposure to dusty, drafty environments
- Pathologic hypersensitivity to pain
- Conjunctivochalasis

1. Crane AM, Feuer W, Felix ER, et al. Evidence of central sensitisation in those with dry eye symptoms and neuropathic-like ocular pain complaints: incomplete response to topical anaesthesia and generalised heightened sensitivity to evoked pain. *Br J Ophthalmol.* 2017 Jan 18. [Epub ahead of print.]

2. Ong ES, Alghamdi YA, Levitt RC, et al. Longitudinal examination of frequency of and risk factors for severe dry eye symptoms in US veterans. *JAMA Ophthalmol.* 2016 Dec 22. [Epub ahead of print.]

3. Galor A, Levitt RC, Felix ER, et al. Neuropathic ocular pain: an important yet undervalued feature of dry eye. *Eye (Lond).* 2015 Mar;29(3):301-12.

disease, recommends these. For those patients truly needing a preservative-free artificial tear formulation, OcuSoft's Retaine MGD is excellent. Such artificial tear use may well need to continue indefinitely, depending on each individual's needs.

• Again, depending upon the patient's symptomatology on a one to 10 scale, we will initiate anti-inflammatory therapy early in the disease. Suffice it to say, it is universally accepted that the foundation of dry eye symptoms is ocular surface inflammation due to exposure, so appropriate suppression of inflammation is key to gaining symptomatic relief. Nothing, absolutely nothing, suppresses ocular surface inflammation as well as a topical corticosteroid. Obviously, one would want to select an effective and relatively safe medicine such as one

of the loteprednol formulations. Such would not need to be done for all patients, as eyelid margin scraping and a lipid-based tear may suffice for most patients. Remember, no algorithm can perfectly fit all patients; what we are attempting to do here is arm our fellow clinicians with ample options from which to choose what best serves the individual needs of individual patients.

• If symptoms are moderate to advanced, we always initiate therapy with off-label use of Lotemax gel or Lotemax original suspension (loteprednol, Bausch + Lomb) QID for two weeks, then BID for two weeks. Now that Xiidra (lifitegrast 5%, Shire) is available, we can consider adding it after two weeks of Lotemax in hopes that the level of inflammation suppression with Lotemax will potentiate and enable the nonsteroidal Xiidra to keep

KIDS, SCREENS AND DRY EYE DISEASE

The multi-screen and screen-centric lifestyle is now occurring in younger children in epidemic proportions.¹ With adults, just look around—many people have their faces “glued” to some sort of digital screen. This technology is ushering in, and exacerbating, the growing epidemic of dry eye disease.

- It is well-established that visual attentive behavior suppresses the blink reflex, and thus exacerbates tear film evaporation, which results in clinical dry eye disease.²

- Note that vegetarian or vegan lifestyles may preclude adequate omega-3 essential fatty acid consumption. Supplemental flaxseed oil could likely provide adequate levels.

- One study revealed a strong positive correlation between duration of smartphone use and dry eye disease, and a negative correlation with outdoor play (more outdoor play means less likelihood of dry eye disease).² When smartphone use in the children with dry eye disease was restricted for four weeks, the children had a dramatic and significant decrease in both the signs and symptoms of dry eye disease. We do not know if a similar resiliency would be experienced in adults, whose meibomian glands may already be atrophically compromised.

- “Evaporative dry eye disease associated with smartphone use is a lifestyle disease.”¹

1. White, DE. Pediatric dry eye disease: The next generation of dry eye patients is already here. *Ocular Surgery News U.S. Edition*, January 25, 2017.

2. Moon JH, Kim KW, Moon NJ, et al. Smartphone use is a risk factor for pediatric dry eye disease according to region and age: a case control study. *BMC Ophthalmol*. 2016 Oct 28;16(1):188.



FROM THE LITERATURE

UPDATE ON OMEGA-3 ESSENTIAL FATTY ACIDS AND DRY EYE DISEASE

Any ambiguity about the benefits of omega-3 essential fatty acids (EFAs) in the care of patients with dry eye disease is put to rest with an excellent article in the January 2017 issue of *Ophthalmology*. Here are the highlights:

- A 30% reduction in the risk of dry eye disease was found for each additional gram of omega-3 essential fatty acids consumed per day.

- In fish oil, the omega-3 EFAs are stored as triacylglycerides. But in krill oil, a major component of the EPA and DHA are esterified in phospholipid form; this potentially influences their tissue distribution and bioavailability. Krill oil also contains the carotenoid antioxidant astaxanthin, which improves its stability.

- The fish oil used in this study supplied 1,000mg/day of EPA and 500mg/day of DHA. The krill oil supplied 945mg/day of EPA and 510mg/day of DHA. These were from commercially available sources.

- Study authors reported they previously found tear film break-up time to be highly sensitive (82%) and specific (94%) for diagnosing dry eye disease.

- Krill oil slightly outperformed fish oil in ameliorating the signs and symptoms of dry eye disease.

- Moderate (roughly 1,000mg EPA and roughly 500mg DHA) daily doses of both forms of long-chain omega-3 EFAs were found to significantly reduce tear osmolarity, improve tear stability and reduce ocular bulbar redness.



- The beneficial effects of omega-3 EFAs on reducing bulbar hyperemia were first apparent at day 30 and were maintained at day 90.

- Bulbar hyperemia was the first clinical

sign to demonstrate improvement with omega-3 EFA supplementation, with a significant reduction evident at day 30 compared with placebo. The observed decrease in ocular redness may relate to omega-3 EFA supplementation imparting ocular anti-inflammatory effects. Indeed, topical loteprednol 0.5%, a corticosteroid with potent anti-inflammatory properties, reduced clinical markers of inflammation, including conjunctival injection, in patients with DED over a two-week treatment period.

- This study demonstrated the beneficial effect of long-chain omega-3 EFA supplementation for reducing key clinical signs and symptoms of mild to moderate DED over a three-month treatment duration.

Our take is that probably all patients with dry eye disease should be taking a premium quality fish oil or krill oil supplement. If the dry eye disease expression is moderate to severe, consider off-label loteprednol 0.5% QID for two weeks, then BID for two more weeks to suppress the inflammatory component. Do this concurrent with the fish/krill oil, since it may take a month or two for the omega-3 essential fatty acids to build up in the tissues.

Deinema LA, Vingrys AJ, Wong CY, et al. A randomized, double-masked, placebo-controlled clinical trial of two forms of omega-3 supplements for treating dry eye disease. *Ophthalmology*. 2017 Jan;124(1):43-52.



XIIDRA: THE FIRST FOUR WEEKS ARE CRUCIAL

Lifitegrast can be quite helpful for most patients, as it was shown to significantly improve symptoms of eye dryness vs. placebo in participants with dry eye disease.¹ However, we must coach patients through the first four weeks of therapy. This is a critical time point.

In our experience, and that of our polled audiences, most patients experience one or more of three potential side effects associated with lifitegrast: instillation site irritation, dysgeusia (a metallic aftertaste) and/or blurred vision immediately following use. (Also be aware that this medication comes in a single-use vial. Instill one drop of Xiidra twice daily, approximately 12 hours apart, into each eye and then discard the single-use container immediately after using in each eye.²)

However, these annoying side effects tend to lessen after two to three weeks of consistent use. So, if we can get patients to adhere to therapy for this crucial four weeks, most achieve symptomatic relief.

Have an open conversation with all of your new starts to help keep them on track—it can yield huge benefits.

1. Holland EJ, Luchs J, Karpecki PM, et al. Lifitegrast for the treatment of dry eye disease: results of a phase III, randomized, double-masked, placebo-controlled trial (OPUS-3). *Ophthalmology*. 2017 Jan;124(1):53-60.

2. Full Prescribing Information: XIIDRAM (lifitegrast ophthalmic solution) 5%, for topical ophthalmic use. Available at www.accessdata.fda.gov/drugsatfda_docs/label/2016/208073s000lbl.pdf. Last accessed April 26, 2017.

ocular surface inflammation below symptomatic threshold while the ocular surface is rehabilitated.

- *Alternatively, there is strong scientific evidence that once the inflammation is suppressed with Lotemax (QID for two weeks, then BID for two weeks), pulse-dosing at QID for one week, once or twice a year, can maintain suppression of inflammation, provided a patient is compliant with their other therapies.* We have been using this cost-effective approach for over a decade with excellent success.

- *Another viable option for those patients with mild to moderate symptoms is to initiate anti-inflammatory therapy with Xiidra, and maintain BID therapy for as long as needed.* After twice-daily Xiidra for three to four months, the patient could try once-daily dosing (in the morning time) to see if this reduced therapy could maintain anti-inflammatory control. There are no studies to support this, but as with all medicines, every effort should be made to dose the least amount needed to achieve the desired result.

- *We have found that Xiidra achieves a much quicker onset of action—two to six weeks—vs. Restasis (cyclosporine 0.05%, Allergan) at three to six months in our clinics.* However, certain patients do report that Restasis offers some improvement sooner. Be aware that Restasis is now available in a multidose bottle, which

WHY SYMPTOMS AND SIGNS DON'T ALWAYS AGREE

Why is there discordance between symptoms and signs in patients with dry eye disease?

- There is “growing evidence that part of the dry eye population may show signs of dysfunctional somatosensory pathways, indicating neuropathic ocular pain.”
- Patients with chronic pain syndromes (CPSs) had 30% greater symptoms than signs. Important CPSs are irritable bowel syndrome, fibromyalgia, chronic pelvic pain and osteoarthritis.
- Many patients with itchy eyes also have dry eyes. “Patients with atopy or allergy have a sensitized ocular surface because of inflammatory processes influencing corneal nerves, which can lead to symptoms of dry eye even when the homeostasis of the ocular surface is minimally compromised.”

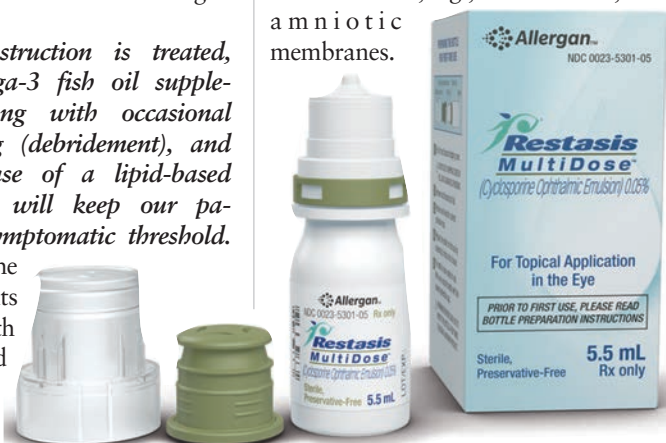Vehof J, Sillevis Smitt-Kamminga N, Nibourg SA, Hammond CJ. Predictors of discordance between symptoms and signs in dry eye disease. *Ophthalmology*. 2017 Mar;124(3):280-286.

can be easier and more convenient for patients to dispense than the single-dose vials.

- *Once obstruction is treated, we hope omega-3 fish oil supplementation along with occasional eyelid cleaning (debridement), and perhaps the use of a lipid-based artificial tear, will keep our patients below symptomatic threshold.*

However, for the tougher patients or those with more advanced disease, the decision-making process regarding therapy can be significantly more complex

and may involve advanced dry eye care considerations, e.g., scleral lenses, amniotic membranes.



Restasis now comes in both its traditional unit-dose container, but thanks to advanced technology, also comes in a preservative-free, multidose bottle.

• *A properly prescribed scleral contact lens can be a lifesaver to the small subset of dry eye patients insufficiently controlled with the other measures discussed above.* There is a growing network of highly competent colleagues prescribing scleral lenses, so intraprofessional cooperation and comanagement may well be the best approach for some patients.

• *Punctal plugs are greatly underused.* However, before considering

To help educate your patients who are just beginning Xiidra therapy, copy the handout below and give it to them.

punctal occlusion, first suppress the ocular surface inflammation so as not to counterproductively concentrate pro-inflammatory cytokines on the ocular surface, thereby risking worsening of symptoms. Quiet the ocular surface, preferably with Lotemax, then consider punctal plugs after two to four weeks in patients where lacrimal output is depressed.

• *Lacrisert dissolvable devices can be another approach to a small subset of dry eye patients for whom other, more commonly employed interventions fail to achieve satisfactory results.*

• *Keep in mind, as well, that warm soaks with a Bruder mask or a similar device that applies heat to the external lid surface can be helpful as adjunctive therapy for many patients.*

• *Last, be sure to diagnose and treat conditions such as blepharitis or Demodex, as these conditions contribute to symptoms of dry eye when they are left untreated.*

Thankfully, there are now sufficient tools readily available to help us meet the needs of most patients with symptomatic dry eye disease without becoming highly specialized. **DG**

WHAT YOU NEED TO KNOW ABOUT XIIDRA

In July 2016, the FDA approved Xiidra for treating “the signs and symptoms” of dry eyes. It is the only drug approved specifically for this purpose.

The eye drop solution is to be instilled twice daily, about 12 hours apart, and can be used indefinitely to keep your eyes comfortable.


As with most drugs, some patients experience one or more side effects with Xiidra, the most common of which are:

- Irritation upon instillation
- An unpleasant metallic aftertaste
- Blurred vision

For most all people, these side effects tend to go away within two to three weeks of consistent use, and do not cause any permanent damage.

Relief from burning, scratchy, gritty, sandy, itchy, dry-eye symptoms generally takes four to six weeks to occur.

Please read the “package insert” that comes with this medicine for complete details.



CAPITALIZE ON CORTICOSTEROIDS

The extensive benefits of these drugs considerably outweigh their potential, but rare and manageable, side effects, yet these drugs are still prescribed with unwarranted apprehension.

The eye is vulnerable to damage from intraocular inflammation. If left untreated, inflammation may lead to temporary or even permanent vision loss. Steroids suppress cellular infiltration, collagen deposition, fibroblast proliferation and scar formation. They stabilize cell membranes and block phospholipase A₂—a critical initial step in the inflammatory cascade of the arachidonic acid pathway.

Topical corticosteroids are based on two different molecular classes: ketones and esters. Ketone-based steroids (e.g., dexamethasone, prednisolone, fluorometholone) have a higher propensity over time for unwanted side effects, compared to ester-based steroids (e.g., loteprednol). Why? Our bodies have limited means to actively degrade the ketone molecules, whereas esters are rapidly broken down by physiological esterases into inert substances shortly after providing effective anti-inflammatory effects. This greatly lowers the risk for increased intraocular pressure, and there have been no reports of cataract formation with the use of loteprednol. For either category, the risks associated with short-term topical use are minimal.

Remember: Suppressing ocular inflammation early in the process substantially decreases the potential for tissue damage. Uncontrolled intraocular inflammation is much more dangerous than a steroid eye drop.

Repeat aloud: “I will not be afraid to prescribe my patient a topical steroid.” Year after year, antiquated teaching strategies focusing more on the possible side effects of oral and topical corticosteroids continue to trump the far-reaching benefits of these important drugs. In the setting of acute red eyes, we have always been strong advocates for the use of topical ophthalmic steroids, either alone or in combination with an antibiotic.

While there are plenty of clinical indications for topical steroids, the only contraindication is active epithelial herpetic infection.¹ In addition, the only precaution for using these drugs bears explanation. With a difficult-to-diagnose *Acanthamoeba* or fungal keratitis, especially in the early stages, the use of a steroid—even a combination

antibiotic/steroid—could cause the condition to worsen; however, these are exceedingly rare presentations with clinically distinct features.

In all cases of disease management, proper follow-up and careful patient education are vital. After explaining the condition and plan of action to the patient, always ask, “Do you have any more questions for me?” By doing so, the patient will have the opportunity to eliminate any misconceptions or worries about their disease or the selected therapy. Also, open discussion increases the paramount doctor-patient trust and minimizes a second opinion that can potentially further delay care.

NEED FOR FOLLOW-UP

When prescribing topical steroids, having the patient return to you in a judicious

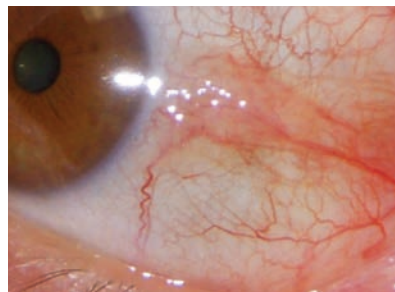
TOPICAL CORTICOSTEROID DRUGS				
BRAND NAME	GENERIC NAME	MANUFACTURER	PREPARATION	BOTTLE/TUBE
Maximum Strength Steroids				
Durezol	difluprednate 0.05%	Alcon	emulsion	5ml
Lotemax gel	loteprednol etabonate 0.5%	Bausch + Lomb	gel-drops	5g
Lotemax ointment	loteprednol etabonate 0.5%	Bausch + Lomb	ointment	3.5g
Pred Forte	prednisolone acetate 1%	Allergan + Generic	suspension	5ml, 10ml, 15ml
generic prednisolone sodium phosphate	prednisolone sodium phosphate 1%	generic	solution	5ml, 10ml, 15ml
Maxidex	dexamethasone 0.1%	Alcon	suspension	5ml
Moderate and Lesser Strength Steroids				
Alex	loteprednol etabonate 0.2%	Bausch + Lomb	suspension	5ml, 10ml
Flarex	fluorometholone acetate 0.1%	Alcon	suspension	5ml, 10ml
FML	fluorometholone alcohol 0.1%	Allergan + Generic	suspension	5ml, 10ml, 15ml
FML ointment	fluorometholone alcohol 0.1%	Allergan	ointment	3.5g
Pred Mild	prednisolone acetate 0.12%	Allergan	suspension	5ml, 10ml

and timely manner will illuminate ineffective treatments or misdiagnosed conditions. By seeing the patient back sooner rather than later, you will be able to refine the diagnosis and alter the therapy, if necessary. If you are truly concerned, get the patient's preferred telephone number and call the patient in a couple of days to check on their progress. (Patients love having their doctors call to check on them.)

For example, let's say you see a patient with a typical lesion that could be Thygeson's or herpetic. Since most red eyes are inflammatory in nature, we are inclined to initiate therapy with a steroid. However, in the uncertainty of the diagnosis, we would tell the patient something like this: "This medicine should help your eye get better quickly; however, at this time the diagnosis of your condition is not completely clear, and there is a chance your eye could actually worsen on this medicine. It is important that you let me see you again in a couple of days. I will be glad to work you in any time." As previously mentioned, this truly caring conversation is crucial for optimum patient care and rapport.

All of this is called "patient management," and is far more than just disease management alone. Trying to manage the disease without managing the patient often results in frustration for the doctor and the patient. (This not only applies to corticosteroid

treatment, but to the treatment of any eye condition.)



This inflamed pingueculum should be treated with a topical steroid. Once the inflammation is under control, the ocular surface must be kept properly lubricated to prevent further inflammatory expression.

MAXIMUM EFFICACY STEROIDS

Don't let ocular inflammation linger by hesitantly prescribing topical steroids. Rather, dose the corticosteroid frequently until the inflammation has subsided before electing to taper the medication if necessary.

Clinically, we have found the two most efficacious topical ophthalmic steroids in the last several years to be Durezol emulsion (difluprednate 0.05%, Alcon) and Pred Forte suspension (prednisolone acetate 1%, Allergan)—but not generic prednisolone acetate. (More on this below.)

Durezol. Introduced in 2008, Durezol is often used as the "big gun" of topical corticosteroids (but don't shy away from it). Because of its potency, it is typically prescribed when inflammation needs to be rapidly brought under control. Durezol is an emulsion and does not need to be shaken before use.

The drug has a long history of use in the setting of severe or non-resolving anterior uveitis, and more recently is gaining recognition as a popular post-operative drug. Clinically, we prefer it over Pred Forte for several reasons: we have found it to be more effective, it does not need to be shaken prior to instillation and it does not need to be dosed as often as Pred Forte, thereby increasing patient compliance.

Durezol's glucocorticoid binding affinity for the active metabolite difluprednate was found to be 56 times stronger than prednisolone.² A derivative of prednisolone, difluprednate's structural modifications enable it to have a stronger affinity and a more consistent potency compared with its counterpart. As a general rule, the more powerful the drug, the more potential for adverse side effects. Durezol is no exception, as it can be associated with an elevated IOP. Thus, standard of care practices must be engaged, with frequent follow-ups to monitor the condition and check IOP.

DUREZOL: UNIFORMITY FOR ALL

Steroid molecules are lipophilic in nature. Their inability to dissolve in solutions makes the majority of corticosteroids on the market available only in suspension form. But ophthalmic suspensions settle over time, causing the active ingredient to fall to the bottom. In order for homogenous distribution, patients must vigorously shake the bottle prior to instillation.

If the bottle is not shaken adequately, the patient risks subtherapeutic dosing, rendering less than desirable outcomes despite full compliance with drops. (It may be noteworthy to mention the opposite here, as well: When a patient is at the end of a tapering schedule and perhaps at the bottom of the bottle, not shaking the suspension could result in concentrations much higher than what they should be, resulting in unsuccessful tapering even though fewer drops are being administered.) Even when the bottle is shaken as directed, the particles still have tendencies to agglomerate, especially as the particle size of the drug increases. This causes dosage inconsistencies and potential frustrations for the doctor and the patient.

In 2008, the FDA approved difluprednate ophthalmic emulsion 0.05% for the treatment of inflammation and pain associated with ocular surgery. The drop was formulated as a stable oil-in-water emulsion, giving optimum dose consistency, while eliminating the need for shaking. In clinical trials, the drop showed therapeutic dose consistency far surpassing generic prednisolone acetate suspension 1% and branded prednisolone acetate suspension 1%.

Durezol's excellent uniformity and decreased dosing suggests increased compliance and more predictable results vs. other steroids in its class.

Pred Forte. While not as clinically effective as Durezol, prednisolone acetate 1% also possesses impressive anti-inflammatory efficacy. Its use is widespread in ocular inflammatory conditions and is most notably embraced postoperatively as well as in cases of anterior uveitis. Remind your patients that because the drop is a suspension, they must vigorously shake the bottle before instillation.

Some pharmacists dispense generic prednisolone acetate even when you have indicated "dispense as written." Although less expensive, the generics are considerably less effective.³ When maximum efficacy is required, nothing surpasses Durezol.

Next in clinical efficacy are Lotemax gel (loteprednol 0.5%, Bausch + Lomb), generic prednisolone sodium phosphate 1% solution (original brand name Inflamase Forte) and generic prednisolone acetate 1%. Dexamethasone, either the solution or suspension form, is also in this category.

Lotemax gel. Perhaps one of the most commonly used drugs among the corticosteroid class is loteprednol etabonate 0.5% (Lotemax, Bausch + Lomb). An ester-based steroid, its propensity to raise intraocular pressure is substantially less than its ketone-based counterparts.

Lotemax is highly lipophilic, 10 times greater than dexamethasone,

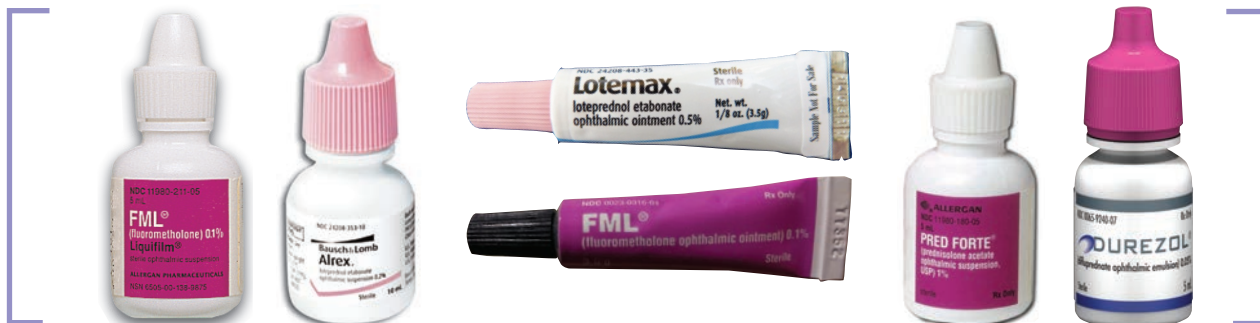thereby increasing its efficacy and penetration into cell membranes. Additionally, loteprednol etabonate 0.5% is able to undergo rapid de-esterification to an inactive metabolite after exerting its effect, minimizing the risks of drug toxicity while maintaining good clinical efficacy.

Lotemax gel is a non-settling eye drop that does not require shaking before instillation. Although labeled as a gel, once on the ocular surface it becomes a viscous liquid. (*See "Lotemax Gel vs. Lotemax Ointment," page 29.*)

We often prefer Lotemax gel as an "off-label" treatment in many of our dry eye patients, but we also use it to treat many other chronic, recurrent, inflammatory conditions such as stromal herpes simplex keratitis, Thygeson's SPK, uveitis, inflamed pinguecula and pterygia, etc.

While the drug is not quite as efficacious as prednisolone and Durezol, its ester-based derivatives also correlate to fewer unwanted side effects (e.g., subcapsular cataracts, elevated intraocular pressure). In Phase III studies for instance, only two out of 409 patients on Lotemax gel had an increase in intraocular pressure greater than 10 mmHg after 18 days of treatment.⁴ When used for post-op cataract surgery inflammation, loteprednol 0.5% suspension was as effective as prednisolone acetate, and with less effect on intraocular pressure.⁵

Prednisolone sodium phosphate 1%. Although generic, this drug remains a viable option when an inexpensive, potent steroid is needed. Unlike many of the other topical



KEEP IT LOCAL WITH LOTEMAX

A study of ocular absorption examined the clinical efficacy of loteprednol etabonate 0.5% in rabbit corneas.¹ After instillation, the researchers assessed each tissue structure in the eye. The cornea was found to have the highest ratio of metabolite to loteprednol etabonate 0.5%, followed by a much lesser concentration in each subsequent tissue posteriorly.

Most notably, the aqueous humor concentration of loteprednol etabonate 0.5% was 100 times lower than the concentration found in the cornea. By keeping high levels of the drug out of the aqueous humor, the trabecular meshwork was less affected, and the propensity to increase intraocular pressure was considerably less than other topical steroids.

Of equal significance, when the drug was absorbed systemically, it was rapidly excreted through bile and urine. The prompt de-esterification of Lotemax and its ability to be expelled promptly with any systemic absorption should make the prescribing doctor eager to apply its therapeutic effects in patient care.

1. Druzgala P, Wu WM, Bodor N. Ocular absorption and distribution of loteprednol etabonate, a soft steroid, in rabbit eyes. *Curr Eye Res.* 1991 Oct;10(10):933-7.

steroids, the drop is prepared as a solution—not a suspension—and does not need to be shaken before instillation. The drop remains an excellent choice for older patients with arthropathies, where shaking a bottle can present a challenge. It's also good for soft contact lens wearers because it won't precipitate on the lens to the extent of other drops.

Prednisolone acetate 1%. Generic prednisolone acetate suspension is a reasonable choice for mild to moderate acute inflammatory conditions, especially if cost is a concern—but not preferred in the setting of advanced anterior uveitis and episcleritis. Make sure that you indicate “brand name necessary” when prescribing for clinical situations that are potentially vision threatening. Rather than battle with the pharmacy or insurance company, perhaps prescribe Durezol to bypass such bureaucratic hassles.

MODERATE EFFICACY STEROIDS

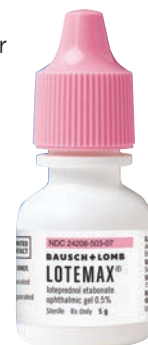The two most common topical steroids in this category are fluorometholone 0.1% suspension and Alex suspension (loteprednol 0.2%, Bausch + Lomb), both of which must be shaken prior to instillation.

• **Fluorometholone 0.1%.** There are two derivatives of fluorometholone 0.1% suspension—the alcohol (FML, Allergan, and generic) and the acetate (Flarex and Alcon). The acetate moiety gives the fluorometholone molecules some additional anti-inflammatory effectiveness over the alcohol moiety.⁶

LOTEMAX GEL VS. LOTEMAX OINTMENT

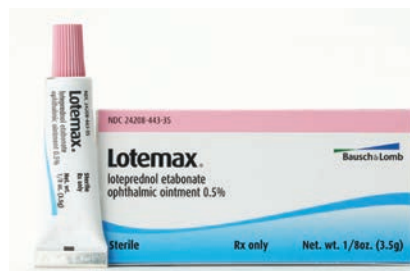Patients, practitioners and pharmacists may mix up these two medicines, so let's set the record straight.

• **Lotemax gel.** Though called a gel, this comes in a dropper bottle, like a solution. However, inside the bottle it is indeed a highly viscous, semisolid gel formulation. But, through a process called adaptive viscosity, it becomes a liquid when squeezed out of the dropper. And upon instillation in the eye, the formulation loses its gel structure altogether as the polycarboxophil polymer interacts with the electrolytes in tears. Still, the drop is rather thick upon instillation, and will cause a moment of initial blur until the gel fully converts into a liquid. We advise patients to allow the drop to spread out on the ocular surface for four to five seconds before blinking, so that the initial blink does not displace the drop onto the eyelid.



Because of the nature of this unique gel, the steroid does not settle out of the vehicle, so it does not require shaking. (It is best to tip the bottle back and forth once to make sure the drug enters the tip of the dropper prior to instillation, but no actual shaking is necessary.) Also, unlike suspensions, this delivery system provides a perfectly uniform dose at every instillation.¹

• **Lotemax ointment.**² This preparation comes in a 3.5g tube and contains inactive ingredients of white petrolatum and mineral oil. Because it is an ester-based corticosteroid and also because it is a preservative-free preparation, it may provide a safety advantage over fluorometholone ointment. Lotemax ointment is indicated for the treatment of postoperative inflammation and pain, but is also applicable in many other cases in which an ointment is useful for suppression of inflammation.



1. Marlowe ZT, Davio SR. Dose uniformity of loteprednol etabonate ophthalmic gel (0.5%) compared with branded and generic prednisolone acetate ophthalmic suspension (1%). *Clin Ophthalmol.* 2014;8:23-9.

2. Comstock TL, Paterno MR, Singh A, et al. Safety and efficacy of loteprednol etabonate ophthalmic ointment 0.5% for the treatment of inflammation and pain following cataract surgery. *Clin Ophthalmol.* 2011;5:177-86.

Fluorometholone alcohol is available generically and is thus reasonably inexpensive. While fluorometholone

does have a diminished propensity to raise intraocular pressure than other ketone steroids, we are not nearly as

TIPS FOR TAPERING

Ever had a challenge tapering a patient off a topical corticosteroid? Steroids are wonderful for short-term therapy, but carry intrinsic risks when used long-term.

Here are a couple of thoughts:

You can usually get the patient down to three or two times a day, or even once daily before a relapse occurs. If a relapse does happen, you have to increase the dosage again and try a longer, slower taper.

In addition, try adding a topical NSAID such as Prolensa (bromfenac, Bausch + Lomb) or Ilevro (nepafenac ophthalmic suspension, Novartis) once daily, or generic diclofenac or ketorolac QID as you begin the next step-down of the corticosteroid. This may offer enough supplemental anti-inflammatory support to enable the continuation of the steroid taper. Or, try the oral NSAID route: Celebrex (celecoxib, Pfizer) 100mg per day for a few weeks.

There are instances when long-term steroid use is indicated. Some patients who have had corneal transplants, stromal immune corneal disease, chronic uveitis

or recalcitrant dry eye disease may be kept on low-dose steroids for life. Some patients require one drop of steroid daily to maintain control over their condition.

While older ketone-based steroids have been used for long-term therapy in the past, we would recom-

mend ester-based loteprednol 0.5% gel off-label once daily for these protracted dosing schedules. (The ketone-based steroids seem to work well in this low-dose approach, yet it stands to reason that loteprednol, being an ester-based steroid, is preferable because of its enhanced safety profile.)

Though Lotemax gel initially can seem cost prohibitive for patients without drug coverage, most eligible commercially insured patients pay no more than a \$35 co-pay for their first prescription and eligible refills at Walgreens and other participating independent pharmacies, and discounted pricing is also available for eligible uninsured patients according

to Bausch + Lomb's website.

As well, Alcon offers various coupons for Durezol (difluprednate). And when there is no getting around cost issues for the patient, generic FML (fluorometholone 0.1%, Allergan) is another option.



comfortable using it long-term as we are with the ester-based loteprednol.

Since the lowest effective dose should be used in all cases, FML Forte

RELATIVE CLINICAL EFFICACY OF TOPICAL STEROIDS

Here, based on our clinical experience and comparative information we have available, we rate the relative efficacy of the topical steroids, starting with the most efficacious:

- Difluprednate 0.05%
- Prednisolone acetate 1%
- Loteprednol 0.5%
- Fluorometholone acetate 0.1%
- Dexamethasone 0.1%
- Fluorometholone alcohol 0.1%
- Loteprednol 0.2%
- Prednisolone 0.125%
- Hydrocortisone 1%

(fluorometholone 0.25%, ophthalmic suspension) is not recommended because fluorometholone 0.1% represents the top of the dose response curve—meaning that the 0.25% is no more efficacious than the 0.1%.

• **Alrex.** An ester-based corticosteroid, Alrex is an excellent off-label treatment option when a patient needs long-term therapy. We often use Alrex (loteprednol 0.2%) in our patients with allergic eye disease when clinical signs of conjunctival injection, chemosis or eyelid swelling accompany itching. In such cases, Alrex (or even Lotemax gel) will best help subdue the patient's condition. We typically dose Alrex (or Lotemax gel) QID for one week, then BID for one month.

Beyond awareness of the various delivery systems (suspensions, solutions, emulsions, gels and ointments), knowing the clinical efficacy of these drugs is important.

STEROID OINTMENTS

The ophthalmic ointments enjoy a wide array of clinical indications. Three steroids that merit frequent use in the ointment formulation include:

• **Lotemax ointment.** The only ester-based steroid ointment available is Lotemax ophthalmic ointment (loteprednol 0.5%, Bausch + Lomb). It is indicated for postoperative inflammation and pain, but also has many off-label clinical uses: dry eye, allergy, corneal transplant protection, blepharitis, giant papillary conjunctivitis, chronic uveitis, stromal immune herpetic keratitis, Thygeson's SPK, recurrent corneal erosion, augmentation of steroid eye drop therapy in acute advanced uveitis or episcleritis, contact dermatitis and other inflammatory conditions. Lotemax ointment is ideally suited for patients who complain of how badly their eyes feel upon awakening.

THE VIRTUE OF TOPICAL CORTICOSTEROIDS

The three main conditions in which steroids can be necessary to achieve protracted maintenance of inflammation include: chronic anterior uveitis, chronic recurrent stromal immune herpes simplex and prevention of corneal transplant rejection. Many patients afflicted with one of these conditions are said to be on the “steroids-for-life” therapeutic program.

We have had topical NSAIDs and topical cyclosporine for many years, yet they do not possess the requisite anti-inflammatory firepower to achieve the desired therapeutic outcome. Interestingly, most patients with one of these conditions use only one drop of corticosteroid per day to maintain remission of disease expression. Because of this low dose, it is exceedingly rare that these patients develop ocular hypertension or cataract formation.

Historically, prednisolone acetate has been the most commonly used drug in these situations. We would argue that loteprednol 0.5% would be a wiser choice in the care of any chronic ocular condition because you get adequate suppression of inflammation with a drug known to have a much safer therapeutic profile than prednisolone acetate.

For perspective, dry eye disease is accompanied by varying degrees of ocular surface inflammation. Therefore, a topical corticosteroid would clearly be a drug of choice to help manage this disease. Just as with the three conditions above, in cases of dry eye, steroids are used aggressively initially to achieve inflammation control; only when control is achieved can the steroid be tapered. Ultimately, the patient is maintained with an enduring low-maintenance dose, as set forth above.

The degree of tissue inflammation expression in dry eye disease is less extreme than that seen with the other three aforementioned chronic conditions. Yet, similar to the other inflammatory processes, dry eye must be treated aggressively during the first few weeks to gain control of the inflammatory process. Once inflammatory control is achieved, a lower amount of therapeutic potency is required to maintain suppression of inflammation.

Regarding dry eye disease, we know that topical NSAIDs and cyclosporine are suboptimal suppressors of inflammation. Indeed, in the case of topical cyclosporine, the FDA’s 2013 proposed draft guidance characterization of this drug was that it provides “modest efficacy.” If these two drugs (or drug classes) were continually meritorious for treating dry eye disease, we would have no need for topical steroids, or even newer drugs such as lifitegrast (Xiidra, Shire).

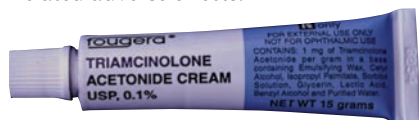We strongly argue for the safety of ester-based loteprednol, used off-label, for long-term treatment of, and maintenance control of, dry eye disease (along with a lipid-based artificial tear and omega-3 supplementation). That said, it would be desirable to embrace the general concept of “steroid-sparing” therapy. This is where lifitegrast can have a significant role in patient care. It has been our experience that once a steroid (loteprednol 0.5% or 0.2%) has achieved control of dry eye inflammation (usually within one month), lifitegrast can adequately maintain such control indefinitely.

Consider: Rheumatologists rely heavily on oral steroids to gain control of rheumatoid arthritis and systemic lupus erythematosus, but once control is achieved they try to embrace the steroid-sparing therapy of hydroxychloroquine for maintenance control. Just as in dry eye disease, some arthritis/lupus patients experience symptomatic breakthrough, and a “pulse-dose” of oral prednisone is required to regain control. In like manner with dry eye disease, if a patient using any nonsteroidal drug experiences symptomatic breakthrough, a pulse-dose of a topical corticosteroid is required to regain control. Of course, our hope is that the patient can return to a nonsteroidal maintenance of suppression of inflammation indefinitely.

We likely all have some patients whose rheumatologists have them on 2mg to 10mg of oral prednisone long-term, as that is the lowest dose that can keep these patients comfortable. Similarly, we likely all have some dry eye patients who require once-daily or twice-daily loteprednol long-term to manage their disease.

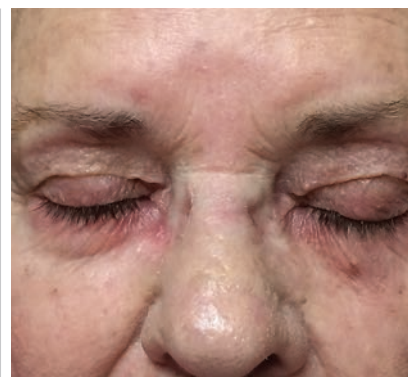Bottom line: We always seek the lowest level of intervention needed to adequately treat any condition.

• **FML Ointment.** Used much the same as Lotemax ointment, FML ophthalmic ointment (fluorometholone 0.1%, Allergan) is indicated for inflammation of the palpebral and bulbar conjunctiva, cornea and anterior segment of the globe, and any of the off-label uses mentioned above. The only minor difference is to keep a closer watch on the patient for steroid-related adverse effects.



• **Triamcinolone 0.1% cream.** This is a dermatological preparation that works well for periorcular dermatitis conditions. Triamcinolone 0.1% cream, which became generic long ago, has been our favorite drug for many years to treat contact blepharodermatitis. It comes in 15g and 30g tubes, each costing about \$10 in most markets.

Be sure to tell the patient that on the side of the tube is the statement “Not for Ophthalmic Use,” but that the drug is perfectly fine to use as we have prescribed. We explain that triamcinolone is often used by retina subspecialists for



Dermatologic triamcinolone cream can be used to treat periorcular dermatitis.

THOUGHTFUL PRESCRIBING FOR CONTROLLING INFLAMMATION

When we encounter anterior uveitis, we know it is an inflammatory condition. Certainly, there are various expressions of the disease, but for most patients most of the time, we use Durezol initially every two hours while awake. Had we used the traditional prednisolone acetate suspension, we would have to dose the patient hourly while awake, at least initially. So, we choose Durezol for two reasons: it has a more powerful molecule in a more elegant emulsion vehicle that requires no shaking, minimizes dosing frequency, and provides a protracted ocular surface residency time. Another attribute: It's BAK-free.

Does every uveitis patient require such aggressive dosing, or could a more conservative dosing schedule be used while increasing patient compliance? The answer is that there are likely cases in which a less aggressive dosing schedule would be appropriate, but since this cannot be fully known, we use a therapeutic approach shown to be highly effective in virtually all cases.

• **Inflammation in different settings.** Let's compare the suppression of inflammation in anterior uveitis to that of dry eye. A question arises: How aggressive do we need to be to suppress the inflammatory component?

Given that inflammation in the setting of dry eye disease is quantitatively less than that seen in more severe diseases such as anterior uveitis, a drug such as Durezol would be overkill—but would most certainly do the job. So, should we prescribe loteprednol 0.5%, loteprednol 0.2%, a topical NSAID, lifitegrast 5.0% or cyclosporine 0.05%? There are some patients in whom any of these would suffice—but the clinical dilemma is that we have no way of knowing which patients those are, and our primary job at this point is to adequately suppress inflammation.

Therefore, it stands to reason that prescribing loteprednol (a safety profile-enhanced, ester-based topical steroid that does not require shaking) would be rational initiation of therapy. Sound, scientific articles in peer-reviewed journals have firmly established the efficacy and safety of such a clinical approach.^{1,2} Following the consensus in the expert literature, we prescribe loteprednol 0.5% QID for two weeks, and then BID for two more weeks. At the end of a month, the inflammatory component is controlled.

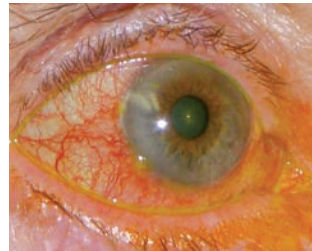
FDA-approved injection into the eye. In other words, if some of the triamcinolone cream gets into the patient's eyes, it's nothing to worry about. Doctors should be cautioned about using this only for short-term relief, as long-term use can result in skin atrophy and in some cases elevated IOP.

Corticosteroids are the most essential and highly prescribed medicines for the treatment of ocular inflamma-

tion of any stripe. Their widespread usage confirms that ocular inflammation is the most common clinical manifestation seen in eye care. It is imperative that all doctors of optometry come to terms with this reality and strive to become very comfortable caring for patients with inflammatory eye disease. **DG**

1. Easty DL, Carter C. Mechanisms of resistance and hypersensitivity in herpes simplex keratitis. *Trans Ophthalmol Soc U K* 1979 Apr;99(1):126-33.

Now, if—and that is a strong if—patients faithfully use their lipid-based artificial tears and omega-3 supplements, ocular surface inflammation should remain subclinical. Scientifically, this all makes perfectly good sense. For



most patients, there is no reason to use any eye drop once or twice a day forever. Control the inflammation upfront, and keep it controlled with omega-3 supplementation and proper ocular surface lubrication. Punctal

plugs can enhance the efficacy if needed after a month of steroid therapy to quiet the surface inflammation.

• **Other considerations.** Cost is also a significant deterrent to compliance. Simple arithmetic shows that one or two bottles of loteprednol is vastly less expensive (especially with the “pay no more than \$35” coupons with most commercial insurances) than any of the protracted, enduring, twice-daily therapies. Additionally, the patient may appreciate the short and effective therapy with pulse-dosing as needed, as opposed to indefinite therapy with other agents.

• **A final note.** Some patients do not properly adhere to their omega-3 and/or artificial tear protocols, and other patients' inflammation simply “breaks through.” In these cases, we perform the time-honored maneuver of pulse-dosing. In our practices, such symptomatic breakthroughs are controlled by off-label use of loteprednol QID for one week, then we stop (no taper is needed). A few patients will need such a “booster shot” once or twice a year. This is a safe, effective and cost-saving maneuver to help keep patients with dry eye well controlled and comfortable.

As in all clinical circumstances, thoughtful prescribing is virtuous and merits enthusiastic embrace.

1. Sy A, O'Brien KS, Liu MP, et al. Expert opinion in the management of aqueous Deficient Dry Eye Disease (DED). *BMC Ophthalmol*. 2015 Oct 13;15:133.

2. Pflugfelder SC, Maskin SL, Anderson B, et al. A randomized, double-masked, placebo-controlled, multicenter comparison of loteprednol etabonate ophthalmic suspension, 0.5%, and placebo for treatment of keratoconjunctivitis sicca in patients with delayed tear clearance. *Am J Ophthalmol*. 2004 Sep;138(3):444-57.

2. Donnenfeld ED. Difluprednate for the prevention of ocular inflammation postsurgery: an update. *Clin Ophthalmol*. 2011;5:811-6.

3. Roberts CW, Nelson PL. Comparative analysis of prednisolone acetate suspensions. *J Ocul Pharmacol Ther*. 2007 Apr;23(2):182-7.

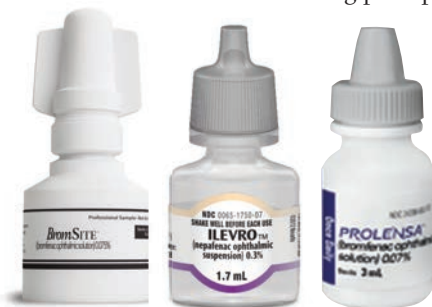4. FDA Center for Drug Evaluation and Research. Deputy Division Director Review for NDA 202-872. 2012 Sep 27. Available at: www.accessdata.fda.gov/drugsatfda_docs/nda/2012/202872Orig1s000MedR.pdf. Last accessed March 7, 2017.

5. Lane SS, Holland EJ. Loteprednol etabonate 0.5% versus prednisolone acetate 1.0% for the treatment of inflammation after cataract surgery. *J Cataract Refract Surg*. 2013 Feb;39(2):168-73.

6. Leibowitz HM, Hyndiuk RA, Lindsey C, Rosenthal AL. Fluorometholone acetate: clinical evaluation in the treatment of external ocular inflammation. *Ann Ophthalmol*. 1984 Dec;16(12):1110-5.

NSAIDs: WHAT'S NEW & WHAT'S PRUDENT

All topical NSAIDs are generally approved for treating postoperative inflammation, and as such they are used much more for perioperative care than for primary eye care.



Because of the rare, but real, potential for corneal toxicity and melting, use nonsteroidal anti-inflammatory drugs (NSAIDs) cautiously when there is preexisting corneal epithelial compromise. As a general rule, we never prescribe any topical NSAID for use beyond two weeks—except for a case of cystoid macular edema, which we treat with a topical NSAID for a month concurrently with a potent steroid.

While steroids are often initially dosed as frequently as hourly for a few days, we recommend that NSAID use not exceed the FDA-approved dosing frequency. Always remember that steroids reign supreme in inflammation control; topical NSAIDs are never an appropriate substitute when the condition merits a topical corticosteroid.

In recent years, the following NSAIDs have come to market:

- **BromSite.** Approved by the FDA in April 2016, BromSite (bromfenac 0.075%, Sun Pharma) is the first NSAID specifically indicated for preventing ocular pain in patients undergoing cataract surgery. Like other NSAIDs, it's also indicated for treating postoperative inflammation.

BromSite achieves its low 0.075% concentration due to its DuraSite delivery vehicle (developed by InSite Vision), which is believed to extend the drug's residence time on the ocular surface.

In Phase III trials, a greater number of patients treated with twice-daily BromSite

(77% to 82%) were pain-free at one day post-op compared with those given only vehicle (48% to 62%). Also, more patients given BromSite were free of inflammation at 15 days post-cataract surgery compared with patients given only the vehicle.¹

BromSite is dosed BID, preserved with benzalkonium chloride (BAK) 0.005%, and comes in a 5ml supply.

- **Prolensa.** This NSAID, Prolensa (bromfenac 0.07%, Bausch + Lomb), potentiates penetration of the bromfenac molecule thereby allowing for a slightly lower concentration (0.07%) than BromSite, yet providing once-daily dosing.

Also, Prolensa has pH of 7.8 vs. the 8.3 pH of generic bromfenac 0.09% (formerly brand-name Bromday). This pH modification enables the lower 0.07% concentration of Prolensa to clinically perform as well as the generic 0.09% concentration.

Prolensa is preserved with BAK 0.005% and comes in two quantities: 1.6ml and 3ml (both in 7.5ml bottles).

Because BromSite and Prolensa are solutions, not suspensions, shaking the bottle before use is not required.

- **Ilevro.** The other topical NSAID with once-daily dosing, Ilevro (nepafenac 0.3%, Alcon) achieves this by increasing the concentration from the earlier-generation Nevanac (nepafenac 0.1%, Alcon). Ilevro comes in a 1.7ml quantity, whereas Nevanac is dispensed as 3ml. Because Ilevro is a suspension, the bottle must be shaken before the drop is instilled. **DG**

1. BromSite [prescribing information]; Cranbury NJ: Sun Pharma Industries, Inc; Apr 2016.

EFFECTIVE ANTIVIRAL THERAPY

Herpetic eye disease remains the leading cause of corneal blindness worldwide. Early diagnosis and treatment can help dampen the impact of this disease.

The herpes virus (HSV) can manifest in a wide range of ocular conditions—from a mild vesicular lid lesion to an aggressive retinitis. Clinicians should be aware that the virus has the ability to affect every ocular tissue, and treat the patient accordingly.

HERPES SIMPLEX

The herpes simplex virus is a DNA virus primarily spread by close personal contact. Usually seen in children and young adults, the disease can be broken down into two types: herpes simplex-1 (oral/facial/ocular) or herpes simplex-2 (genital), although HSV can also cross infect between type 1 and type 2.¹

Disease expression often occurs in two phases—prodromal and outbreak. In the setting of periocular skin disease, the patient may have confined prodromal symptoms consisting of mild pain, tingling, itching or burning before the lesion potentially progresses through the following stages: macule, papule, vesicle, encrustation and healing (without scarring). Only after the skin lesions are crusted over is the primary disease no longer contagious.

In secondary ocular disease expression, the patient presents with a unilateral injected eye with a mild, watery discharge. (This is in contrast with epidemic keratoconjunctivitis, where profuse tearing is commonly observed in a much more injected eye.) A staining pattern on the cornea (early microdendrites) may resemble a

similar presentation as seen in dry eye. Remember that in early HSV, corneal lesions may not present in their classic dendrite formation. Document the corneal staining pattern carefully and monitor closely if you suspect a possible HSV infection.

Clinical pearl: Limbal dendrites are typically more recalcitrant to treatment than central dendrites because the immunological armamentarium (antibodies and leukocytes) is abundantly present in the limbal microvasculature.²

Recurrent infections may occur at any age. Up to 25% of patients with a primary infection will have a recurrence of the disease later in life. Additionally, up to 50% with a recurrent infection will have another outbreak within two to five years.³

Neurotrophic keratitis is a much more serious complication of herpes simplex keratitis (HSK) and may occur secondarily to previous keratitis outbreaks where the basement membrane was damaged. These patients are often in minimal or no pain due to the widespread damage of the corneal nerves. In essence, their corneas are now “permanently anesthetized.”

Neurotrophic keratitis is clinically seen as round defects with rolled edges, and the potential for stromal thinning and subsequent perforation is increased. It is especially important to evaluate the anterior chamber in these patients, as there is often a mild anterior iritis that accompanies the keratitis.

Because there is no active viral replication seen in neurotrophic keratitis, the

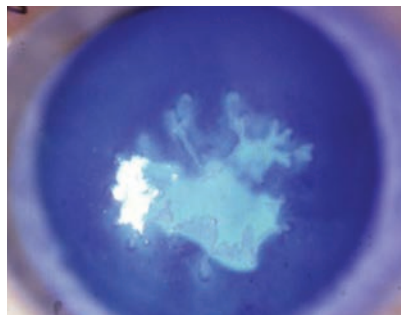
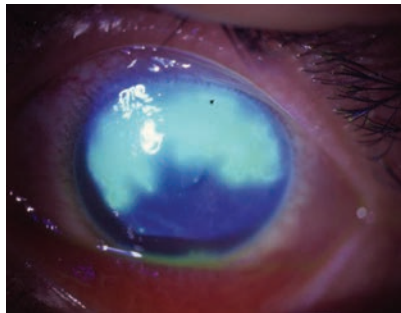
CORNEAL PRESENTATION WITH HSK

When caught early on in the infection process, herpes simplex keratitis may initially appear as nothing more than superficial punctate keratitis secondary to dry eye. However, these primarily unilateral, coarse, punctate lesions will not respond to dry eye therapy alone and are more commonly found centrally.

As the disease progresses, the lesions become early microdendrites that eventually develop into the classically recognized dendritic ulcers. These linear or branching ulcers have swollen terminal end bulbs that stain with rose bengal or lissamine green, while the necrotic cells in the center of the lesions uptake sodium fluorescein (NaFL)—keep in mind that only infected cells stain with lissamine green or rose bengal, not NaFL. (The epithelial lesions of simplex infections stain very positively with NaFL dye, whereas the epithelial lesions associated with zoster disease stain negatively and really do not mimic each other.) Occasionally, mild stromal edema can be detected directly underneath the epithelial infection (which resolves once the epithelium heals).

When misdiagnosed and treated inappropriately with a topical steroid, these fine lesions can turn into geographic ulcers.

If the diagnosis is uncertain early on, always see the patient back within a day or two for a follow-up evaluation. Artificial tears can be used in the interim.



disease is treated with a different approach. A bland antibiotic ointment can be instilled BID-QID alongside a cycloplegic agent BID. Culturing should be considered, and the potential for corneal perforation should be monitored daily. For non-healing lesions, consider consultation with a corneal specialist.

Other serious complications of HSK consist of a necrotizing stromal keratitis and necrotizing interstitial keratitis. Both can rapidly lead to stromal scarring and perforation if not treated quickly with cycloplegics, antivirals and topical steroids. Refer patients with these conditions to a corneal specialist for evaluation.

Fortunately, diagnosis of herpetic eye disease is nearly always made with a careful history and clinical

examination. The need to culture is exceedingly rare, but when in doubt, the virus can be cultured by lifting and swabbing the base of the lesion. While the disease process is self-limiting, treatment should be initiated to decrease the likelihood of corneal scarring and subsequent vision compromise.

HERPES ZOSTER

Up to 30% of patients will develop a herpes zoster outbreak in their lifetime. Better known as “shingles” to the general public, the prevalence is well-documented to be increasing over the past decade.⁴ Nearly one million Americans develop shingles every year, with

the face being the second most common site found after the trunk.⁵

Fortunately, due to the advent of the childhood Varivax vaccine (live varicella virus, Merck), which came to market in 1995, there are now generations of people who will never have shingles because they will never contract chicken pox.

This, however, is a double-edged sword. Prior to the Varivax vaccine, there were always children among us with chicken pox in various stages of contagion. This allowed the adult population to come into contact with the virus during the course of daily living, stimulating their immunity against the varicella zoster virus. Since Varivax, such immune-stimulation diminishes each year.

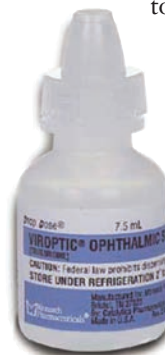Keep in mind that as we age, our immune systems become less robust and, in these underexposed individuals, some degree of shingles is even more likely to occur. Thus, we could be facing another 30 to 50 years of increased occurrence of shingles in those patients who have not had sufficient exposure to boost their immunity against it, so clinicians need to be ready to competently care for this expanding population.

FROM CHICKEN POX TO SHINGLES

The varicella virus (chicken pox) is the initial or primary infection of the herpes zoster disease process. Herpes zoster (shingles) is the reactivation of the varicella virus most commonly seen in the sixth to seventh decade of life.

When a patient is initially exposed to chicken pox, the virus becomes latent in the sensory ganglion of the trigeminal nerve. If the disease is reactivated, the virus travels down the ganglion to its respective afferent peripheral nerves and dermatome (an area of skin that is mainly supplied by a single spinal nerve).

A shingles outbreak is always unilateral, and will not



cross the midline of the patient—making it one of the most recognized disease processes in medicine. Fortunately, the recurrence of the zoster virus is rather low—less than 6%; if there is another outbreak, the patient could possibly be immunocompromised.⁶

Herpes zoster ophthalmicus (HZO) is present in up to 25% of all zoster outbreaks, and occurs when the virus affects the first branch of the trigeminal nerve (V1, or the ophthalmic branch).⁷ If the tip of the nose is involved (Hutchinson’s sign, indicating involvement of the nasociliary nerve that innervates corneal and intraocular tissues), the eye is too. With this branch innervating the structures of the eye, it is easy to see why nearly every ocular tissue can be affected by this viral reactivation.

Ocular involvement presents as inflammatory uveitis or inflammatory keratitis, or both. Uveitic involvement manifests as inflammatory cells in the anterior chamber. Corneal involvement manifests as stromal inflammation. If the trabecular meshwork is inflamed, the intraocular pressure may rise. Should the IOP be sufficiently elevated, then temporary dampening of the IOP can be best accomplished by a topical beta-blocker such as timolol or the alpha-adrenergic agonist brimonidine for a few days. To some degree, conjunctival injection accompanies these scenarios.

Treatment for ocular involvement is available in topical and oral form; now let’s look at our options.

TOPICAL THERAPY

Topical antiviral therapy for the herpes simplex virus consists of Zirgan (ganciclovir gel 0.15%, Bausch + Lomb) or Viroptic (trifluridine 1%, Pfizer, and generic).

TOPICAL ANTIVIRAL OPTIONS

Trifluridine	Ganciclovir
Viroptic (Pfizer) and generic	Zirgan (Bausch + Lomb)
Old drug	New drug
Indiscriminate cellular expression	Specific for infected cells
Potentially toxic	Minimally toxic
More frequent dosing	Less frequent dosing
Refrigerate until opened	No refrigeration needed
Thimerosal preserved	BAK preserved
Solution (7.5ml bottle)	Gel (5g tube)

is confined to the epithelium, never treat with topical steroids as that will merely enhance viral replication that can progress into a potential sight-threatening geographic ulcer. These patients need to be aggressively treated with antivirals to prevent ongoing viral replication with subsequent stromal scarring.

Viroptic ophthalmic solution is less commonly used now to treat HSK. This medication is instilled as one drop every two hours until the ulcer has re-epithelialized, then tapered down to one drop every four hours for another week. Because the drop is preserved with thimerosal, it is often found to be corneotoxic with prolonged therapy.

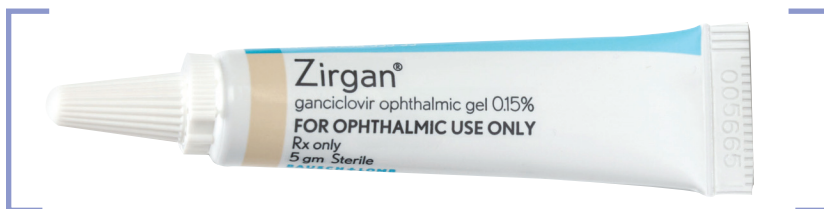A newer treatment option is Zirgan gel (preserved with benzalkonium chloride), which allows for much less frequent dosing alongside a decreased risk for toxicity. Instill one drop of this medication into the affected eye five times daily until the corneal ulcer heals, then one drop three times daily for a week. Dosed appropriately, over 95% of HSK cases resolve over the course of two weeks or less.

Zirgan’s advantages over trifluridine are many:

- The most evident benefit from the patient’s perspective is using a drop only five times a day (as opposed to every two hours with trifluridine).
- The issue of refrigeration is confusing to both patients and pharmacists (just like with latanoprost). Both trifluridine and latanoprost should be kept under refrigeration at the pharmacy; but once dispensed to the patient, these two medications can be kept at room temperature.
- The potential corneal toxicity of trifluridine is minimized with ganciclovir because ganciclovir (like all oral antivirals) is activated by viral enzymes. The potential reaction to the thimerosal-preserved trifluridine is minimized as well.

It should be evident that Zirgan is a major advance in caring for patients with herpetic epithelial keratitis and may well be so, to some degree, for adenoviral infections as well.

For patients who have ocular involvement in the setting of herpes zoster ophthalmicus, the treatment is much different. Typically, an aggressive treatment approach with cycloplegia and topical steroids is deployed. We prescribe homatropine 5% BID to QID, along with Durezol (difluprednate 0.05%, Alcon) every one to two hours for a few days until the inflammation is well controlled. Only then is tapering initiated.



Recurrent flare-ups may require maintenance therapy as a prophylactic measure. Once the inflammation is brought fully under control with Durezol, we switch the topical steroid to Lotemax gel—always trying to find the minimal therapeutic dosing to achieve the desired result. The sequence would be something like this: TID for one month, BID for two to four months and then once daily for several more months.

ORAL THERAPY

It is recognized that the herpes virus can be treated with oral as well as topical antivirals. When shingles presents as an uncomplicated skin disease, as evidenced by pain, erythema and vesicular expression, the treatment is an oral antiviral for seven to 10 days. We find two such medications equivalent in their therapeutic effectiveness (dose specified for zoster disease):

- *Acyclovir 800mg* five times daily
- *Valacyclovir 1,000mg* three times daily

These have enhanced bioavailability, which enables them to be used less frequently. If cost is a barrier to patients, acyclovir taken five times a day for a week is, by far, the least expensive therapeutic approach. As a quick rule, the strength of the antiviral drug is doubled; halved to treat simplex disease.

Remember that antiviral drugs are most efficacious during the early replicative phase of the infection (initial 72 hours). This does not mean that

after three days, the opportunity for medical intervention has passed—just that there is decreasing clinical efficacy with each day of delay in seeking care. With more virulent expressions, especially in older individuals, concurrent therapy with oral prednisone (usually 40mg to 60mg/day for a week) can help decrease the pain and inflammation, and may dampen the expression of post-herpetic neuralgia.

Oral antivirals are extremely safe and effective. Their only Achilles' heel is that they are metabolized by the kidneys. Thus, if a patient has clinically significant renal disease, the antiviral dosage needs to be reduced. Phone consultation with the patient's primary care physician or nephrologist is of utmost importance in determining the optimum dosage. Computer programs and mobile apps can calculate the proper dosage based on renal function parameters of creatine clearance and glomerular filtration rates, which the physician will have on hand. We have never had to have such a consultation, but we are certainly prepared to do so if we encounter such a patient.

As shingles can be devastatingly painful, it is satisfying to provide effective acute care to those who are suffering. The diagnosis is almost always clearly evident, and the medical intervention is straightforward in most cases. Treatment of this disease is an area in which we should all be experts, as we are likely to see more cases in the coming years.

HERPETIC EYE



FROM THE LITERATURE

THIS VIRUS HAS SOME NERVE!

By adulthood, most of the population has herpes simplex antibodies, with the majority exposed by age 12. The virus is spread by close personal contact, with an incubation period of three to nine days. Once primary infection has occurred, the virus lies dormant in the trigeminal nerve (cranial nerve 5). It is believed to be reactivated by several factors, from physiological stress to sunlight exposure (though this was never confirmed by the Herpetic Eye Disease Study). Once reactivated, the disease travels down the first branch of the trigeminal nerve (the ophthalmic branch, or V1). From here, the virus can invade any ocular tissue.

Schillinger JA, Xu F, Sternberg MR, et al. Seroprevalence and coinfection with herpes simplex virus type 1 and type 2 in the United States, 1988-1994. *J Infect Dis.* 2002 Apr 15;185(8):1019-24.

DISEASE STUDY

Originally undertaken to evaluate the usefulness of oral acyclovir in stromal HSV disease, the Herpetic Eye Disease Study (HEDS) looked at more than 700 patients with various manifestations of ocular HSV infection.⁸

The study concluded that:

TOPICAL THERAPY FOR HERPES SIMPLEX/ZOSTER					
BRAND NAME	GENERIC NAME	MANUFACTURER	PEDIATRIC USE	PREPARATIONS	DOSING
Viroptic	trifluridine 1%	Pfizer	6+	solution	8x/day
Zirgan	ganciclovir 0.15%	Bausch + Lomb	2+	gel	5x/day
ORAL THERAPY FOR HERPES SIMPLEX/ZOSTER					
BRAND NAME	GENERIC NAME	MANUFACTURER	PEDIATRIC USE	HSV DOSE	HZV DOSE
Zovirax	acyclovir	GlaxoSmithKline	Adjusted dose for infants	400mg 5x/day	800mg 5x/day
Valtrex	valacyclovir	GlaxoSmithKline	Adjusted dose for infants	500mg TID	1,000mg TID

EKC DIAGNOSIS AND TREATMENT

Acute adenoviral infection can be as devastating as shingles; in both, delay in seeking competent care magnifies the potential for bad outcomes. Improperly treated epidemic keratoconjunctivitis (EKC) can lead to visually compromising subepithelial infiltrates (SEIs), just as improperly or delayed care of shingles can lead to postherpetic neuralgia. Both conditions can be effectively and successfully managed when the diagnosis and appropriate treatment is initiated early in the disease process.

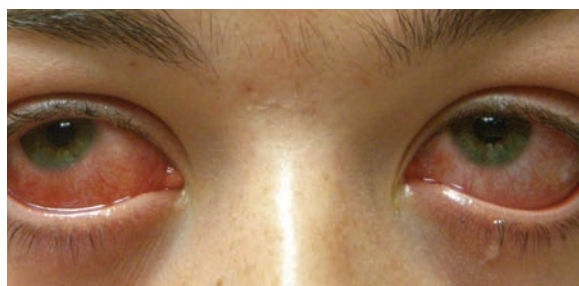Treatments for EKC and for shingles are most effective when the virus is actively replicating. If patients delay seeking care for either of these conditions, or if they receive inappropriate care, the window of opportunity may pass, and then only steroids (topically for EKC, orally for zoster) can be used to try to mitigate downstream sequelae.

The most readily available and effective chemotherapeutic agent we have against EKC-related pathogenic adenovirus is topical Betadine 5% Sterile Ophthalmic Prep Solution (povidone-iodine, Alcon).¹ We remain distressed at how the professional literature consistently ignores this medicine or poorly represents its proper clinical use.

Our awareness of Betadine use for EKC came from a 2002 article about a cornea specialist who treated 60 EKC patients with off-label Betadine 5%; all had successful outcomes. The rationale and treatment protocol sounded very reasonable to us, and more than a decade ago we began off-label use of Betadine 5% to treat EKC. We have now helped more than 100 patients with EKC over that time who would have otherwise suffered needlessly.

While relieving acute pain and distress quickly is gratifying, there is another major bonus to truncating ocular surface exposure to this virus: prevention of subepithelial infiltrates. The infiltrates are immune responses to viral antigens, and can take many weeks or months to dissipate. If the infiltrates significantly impair vision, then off-label use of Lotemax gel (loteprednol etabonate 0.5%, Bausch + Lomb) needs to be used to help clear the vision while biological attrition of the antigenic load occurs. Very generally speaking, if we were to encounter a late-presenting patient afflicted with visually significant SEIs, we would treat with off-label Lotemax gel QID for one month, then TID for one month, then BID for one month and then once daily for another month. Such a regimen may have to be modified, depending upon the individual response to the steroid.

For perspective, EKC generally follows the “rule of 8s”:



- An eight-day latency period (from the time of virus exposure until the onset of the acute red eye)
- An eight-day period of acute infectious conjunctivitis (the acute red, watery eye)
- Eight days later (if the condition is not treated), subepithelial infiltrates tend to develop

It is in the acute replicatory phase (the acute red eye phase) where Betadine can play a crucial role in disease abatement. This is the protocol we typically use:

1. Anesthetize both eyes with 0.5% proparacaine (because the Betadine stings).
2. Instill two or three drops of Betadine and have the patient roll their eyes around to enhance distribution.
3. Using a gloved hand or cotton swab, rub the excess Betadine along the lid margin to kill any resident virus.
4. After 45 to 60 seconds of Betadine exposure, lavage the eye to flush the Betadine.

By the way, Betadine is standard-of-care for ocular surface sterilization prior to cataract surgery and intravitreal injections. Such use is the only proven preventive measure against endophthalmitis. So we believe the off-label use of Betadine 5% is a rational, intelligent method of treating patients who present with EKC. Also, it is affordable—about \$20 for a 30ml container (which can be ordered from many medical supply companies).

Clinical pearl: Use empty bottles of Fluress (fluorescein sodium and benoxinate hydrochloride, Akorn) to create “single-use” Betadine droppers. We thoroughly clean these bottles and droppers with soap and water, let them air dry, keep in a sealed plastic bag until the need arises to open a new container of Betadine 5%. Whatever amount of Betadine remains from the original container is then poured into two to four of these clean Fluress bottles to have at the ready for the next patient with EKC.

1. Yazar H, Yarbog A, Balci M, et al. The effects of povidone iodine (pH 4.2) on patients with adenoviral conjunctivitis. *J Pak Med Assoc.* 2016 Aug; 66(8):968-70.

The study concluded that:

- Epithelial disease alone did not make future recurrences more likely, but stromal disease definitely did.
- With regards to patients who had epithelial dendrites, oral acyclovir did not reduce the rate of stromal disease.

- Additionally, oral acyclovir did not improve outcomes in stromal keratitis cases, nor did it prevent stromal involvement.
 - Stromal disease was best managed with topical steroids, which did not increase recurrence rate.
- As revealed in the Acyclovir Prevention Trial, oral acyclovir 400mg

dosed BID for one year resulted in a 45% decrease in the chance of recurrence for all forms of ocular involvement; however, the effect was stopped upon discontinuation of the drug.⁹ So, strongly consider lifetime treatment with oral acyclovir in patients who have two or more outbreaks in a year, or a recurrent disciform keratitis.

TAKE A SHOT ON ZOSTAVAX

Patients often ask, "Should I get the vaccine if I've already had shingles?" The answer depends on the age of the patient. The Zostavax vaccine is highly recommended to individuals over the age of 60, and reduces the risk of having shingles by 50%.

However, having a case of shingles is much more effective in preventing future flare-ups than having the shingles vaccine. A case of shingles powerfully reboots the immune system to help prevent subsequent disease outbreak. Once a patient has shingles, the risk of recurrence drops somewhere between 2% to 5%. Therefore, the Zostavax shot after shingles would only lower the risk of getting an additional outbreak to around 1% to 2.5%. As mentioned before, it is our opinion that a patient who develops shingles and is older than age 50 most likely would not benefit from the vaccine.

Be sure to remind your patient that Zostavax only provides relative immunity for about eight years, so repeat vaccinations may be in order. Such repeat vaccination is currently under evaluation. **DG**

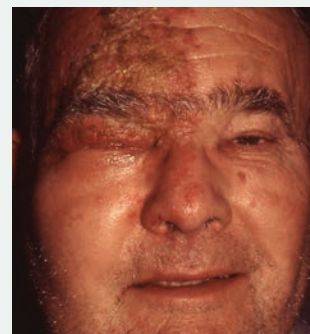1. Waggoner-Fountain LA, Grossman LB. Herpes simplex virus. *Pediatr Rev.* 2004 Mar;25(3):86-93.
2. Dua HS, Gomes JA, Singh A. Corneal epithelial wound healing. *Br J Ophthalmol.* 1994 May;78(5):401-8.
3. Liesegang TJ. Epidemiology of ocular herpes simplex. Natural history in Rochester, Minn, 1950 through 1982. *Arch Ophthalmol.* 1989 Aug;107(8):1160-5.
4. Kawai K, Gebremeskel BG, Acosta CJ. Systematic review of incidence and complications of herpes zoster: towards a global perspective. *BMJ Open.* 2014 Jun 10;4(6):e004833.
5. Harpaz R, Ortega-Sanchez IR, Seward JF; Advisory Committee on Immunization Practices (ACIP) Centers for Disease Control and Prevention (CDC). Prevention of herpes zoster: recommendations of the Advisory Committee on Immunization Practices (ACIP). *MMWR Recomm Rep.* 2008 Jun 6;57(RR-5):1-30.
6. Tseng HF, Chi M, Smith N, et al. Herpes zoster vaccine and the incidence of recurrent herpes zoster in an immunocompetent elderly population. *J Infect Dis.* 2012 Jul 15;206(2):190-6.
7. Catron T, Hern HG. Herpes Zoster Ophthalmicus. *West J Emerg Med.* 2008 Aug; 9(3): 174-6.
8. Barron BA, Gee L, Hauck WW, et al. Herpetic Eye Disease Study. A controlled trial of oral acyclovir for herpes simplex stromal keratitis. *Ophthalmology.* 1994 Dec;101(12):1871-82.
9. Herpetic Eye Disease Study Group. Acyclovir for the prevention of recurrent herpes simplex virus eye disease. *N Engl J Med.* 1998 Jul 30;339(5):300-6.



FROM THE LITERATURE

The Epidemiology of Shingles: Facts You Should Know

- About one million cases of shingles occur annually in the US.
- About one-third of American citizens will develop shingles in their lifetimes.
- Because of universal varicella (chicken pox) vaccination in the young, leading to fewer so-called booster exposures within the community to maintain cell-mediated immunity, reports predict increasing numbers of patients expected to seek treatment for this disease. Keep in mind that the first division of the trigeminal nerve (cranial nerve V: face and head distribution) is the second-most common site of expression after the trunk of the body. Thus, we need to be fully prepared to care for our patients who present with facial and ophthalmic zoster disease.
- The most common ophthalmic manifestations are keratitis, uveitis and conjunctivitis. (Do note that conjunctivitis in the setting of zoster disease is an expression of inflammation, not infection.)



Our take: *The key to a successful clinical outcome is timely presentation to a competent diagnostician and rapid institution of treatment with the proper dosage of an oral antiviral.*

- In a study at a VA medical center, the recurrence rate of shingles was about 6%, slightly more than the 4% to 5% in most other reports.
- Interestingly, in about half of cases, the site of recurrence was at a different area than the initial site.
- Recurrences were more likely in those patients with zoster-associated pain of 30 days or longer, immunocompromised status, female gender and age older than 50 at initial presentation.
- Age was not a determinant of risk of recurrence in that there was no statistically significant difference in risk of recurrence in younger versus older patients.
- The vast majority of cases occurred between the ages of 50 and 80, with highest incidence in the 60s.
- Uveitis and ocular hypertension were risk factors for both recurrent and chronic disease.
- There is biological plausibility that chronic and recurrent disease can be caused by active viral replication and infection, by an inflammatory response to the virus, or both. Studies suggest that clinical latency is not a true period of latency, but rather an active period of subclinical viral transcription and translation held in check by an intact cell-mediated immune response. As such, recurrent disease may represent an active infection, an immune response or both, and thus both antiviral and anti-inflammatory agents may be useful in the treatment of chronic and recurrent varicella zoster virus infection.

Our take: *Prompt initiation of either 800mg of acyclovir five times a day or 1,000 mg of valacyclovir three times a day for seven to 14 days is critical. Furthermore, if the globe is involved (keratitis and/or uveitis), aggressive suppression with a topical corticosteroid is equally critical.*

Tran KD, Falcone MM, Choi DS, et al. Epidemiology of herpes zoster ophthalmicus. *Ophthalmology.* 2016 Jul;123(7):1469-75.

THE COMPLEXITIES OF GLAUCOMA: NO PRESSURE

As the numbers of ophthalmologists entering the field level out, and the population of patients developing glaucoma increases, optometrists must be at the forefront of caring for this population. Here's how.

From a patient's perspective, glaucoma can be perplexing. Even with the same available data, one doctor's interpretation of the results (with subsequent initiation of therapy—or not) may vary tremendously from the approach of another clinician. How is this possible?

The answer is rarely straightforward. But remember that glaucoma is not a disease that progresses quickly, so take the time to make a careful diagnosis and a thoughtful decision regarding initiation of therapy.

With the volume of glaucoma patients rising, and numbers of new ophthalmologists entering the field staying level, management of glaucoma should be a welcomed opportunity in our offices, and referral should be rare.¹⁻³ Here, we review some best practices and reminders for a proper diagnostic glaucoma evaluation.

- *Carefully observe the optic nerve head.* This is the foundation for the rest of the glaucoma workup. Many times

glaucomatous optic neuropathy is missed because a “normal” intraocular pressure lured the clinician into complacency, and intensive study of the optic nerve head is not done.

However, this “normal” pressure, or low-tension glaucoma, can be found in 25% to 40% of patients diagnosed with the disease. Thoroughly analyzing the optic nerve with close attention to the neural retinal rim tissue is absolutely paramount to establishing this diagnosis.

- *Perform tonometry (and at different times of the day).* While the prevalence of glaucoma certainly increases with higher intraocular pressure, absolute diagnosis should almost never be made from a single reading alone.

It is good practice to get at least three readings, with at least one reading taken in the early morning. Large-scale population studies have determined that the mean intraocular pressure (IOP) is around 15.5mm Hg. Two standard deviations on either side of this value approximate a

DON'T LOSE SIGHT OF THE OPTIC DISC

Ancillary testing in glaucoma workups is crucial. While it is true that the more data you can collect the better, don't forget what glaucoma really is: a disease of the optic nerve.

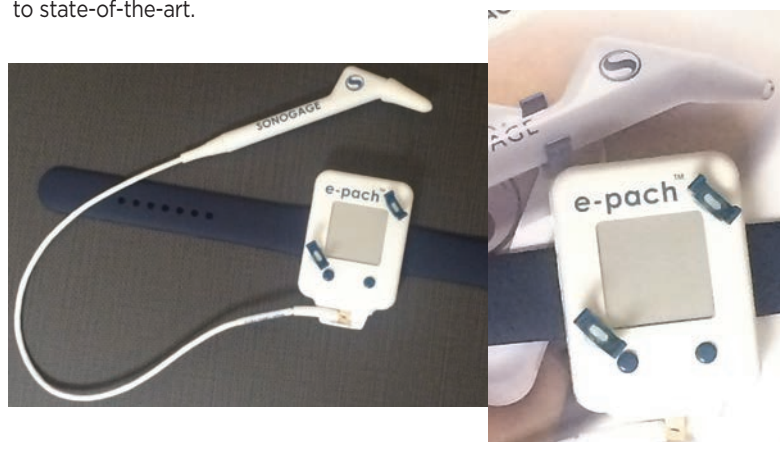The typical optic nerve head is slightly oval and more vertically oriented. Within the disc lies the optic cup, a paler central depression that is devoid of any ganglion cell axons with visibility of the lamina cribrosa.

The tissue that lies between the cup and the edges of the disc is referred to as the neural retinal rim. Subtle changes to the neural retinal rim can result in large changes in a patient's visual field, so carefully scrutinize this tissue.

Remember that the sizes of the disc and the cup are typically closely related; a larger disc will usually have a larger cup.

PACHYMETRY AND GLAUCOMA RISK ASSESSMENT

Since the 2002 Ocular Hypertension Treatment Study (OHTS) revealed the critical importance of corneal thickness (or corneal thinness) in assessing the risk of glaucoma development or progression, most eye doctors have acquired such (relatively inexpensive) technology, and use it routinely in their practices. For those who have not yet come to materially appreciate the virtues of corneal pachymetry, there is a new device now available from SonoGage. It looks and wears like a large wristwatch and is uniquely convenient. We encourage you to evaluate it at www.sonogage.com. If you do not have a corneal pachymetric instrument in your office or offices, we urge you to bring your diagnostic armamentarium up to state-of-the-art.



normal range to be between 10mm Hg to 21mm Hg.

Diurnal IOP variation is well documented to be higher in the mornings and lower in the evenings in most patients. Normal diurnal variation is less than 3mm Hg; fluctuations greater than 6mm Hg necessitate taking a few more IOP measurements to try to establish the IOP profile for such patients.

• **Check central corneal thickness. Having a pachymeter readily available is crucial in establishing a true measure of IOP.** We regularly see referrals for a glaucoma evaluation in patients who have an IOP in the mid- to upper 20s, with 0.2 or 0.3 central cups and corneal thicknesses of 620 μ m to 640 μ m. These patients most commonly have a 100% normal workup. If all optometrists would simply measure the central corneal thickness in these pseudo-ocular hypertensives, it would be an immense service to patients and our profession. According to the Ocular Hyperten-

sive Treatment Study (OHTS), central corneal thickness has a major effect on IOP readings. Without a pachymeter, IOP is relatively meaningless.

Keep in mind that a physiologically thin cornea appears to be an independent risk factor for glaucomatous optic neuropathy, and this needs to be factored into the patient risk assessment.

• **Evaluate the neuroretinal rim.** Remember the ISNT rule? It goes like this: inferior > superior > nasal > temporal. Let's refresh:

In a normal optic nerve head, the inferior tissues are usually the thickest, followed by slightly thinner superior rim tissues, then slightly thin-nasal rim, with the temporal rim being the thinnest. This is not a bullet-proof concept, but it is a good general guide.

Even in much larger cup-to-disc ratios, the focal rim tissue can still be healthy and well-perfused, with no pathological process present. If erosion of the rim tissue is found, it

is most commonly seen at the infero-temporal (macular vulnerability zone) and/or superotemporal rim tissues. This is primarily a result of the relatively sparse glial support in this area.

• **Bring up the patient's history.** Glaucoma tends to be familial. When we see patients who have glaucoma or who are labeled as high-risk glaucoma suspects, we always ask about siblings. We have found that siblings of glaucoma patients have an increased risk of developing glaucoma, with the risk increasing with age. We strongly urge our patients to recommend to their siblings that they seek an optometric glaucoma evaluation in the area where they live. Such screening has been shown to yield additional diagnoses, and to positively impact public health.

• **Check blood pressure in-office.** Carefully assess the patient's systemic conditions, especially treatment for systemic hypertension. It has been found, particularly in low-tension glaucoma patients, that when blood pressure medicines are taken in the evening or at bedtime, they can pathologically lower nocturnal blood pressure, which can exacerbate glaucomatous progression by decreasing optic nerve head perfusion.⁴ We find ourselves more and more often writing letters to primary care physicians explaining this relatively new knowledge and asking them to consider having patients take blood pressure medicines in the morning. Once the PCPs have this scientific explanation, good cooperation is generally the rule.

Along the same line, many patients with asthma can use a topical beta-blocker very successfully. However, we never prescribe a topical beta-blocker for such patients without first writing to the primary care physician for clearance, and securing written documentation from that doctor to place in our medical records attesting to such. We have, with proper consultative advice, used topical beta-blockers for a handful of patients with asthma without incident, and

TOPICAL GLAUCOMA DRUGS				
BRAND NAME	GENERIC NAME	MANUFACTURER	CONCENTRATION	BOTTLE SIZE
Beta Blockers				
Betagan	levobunolol hydrochloride	Allergan, and generic	0.25% 0.5%	5ml, 10ml 5ml, 10ml, 15ml
Betimol	timolol hemihydrate	Akorn	0.25% 0.5%	5ml 5ml, 10ml, 15ml
Betoptic-S	betaxolol hydrochloride	Alcon	0.25%	5ml, 10ml, 15ml
Istalol	timolol maleate	Bausch + Lomb	0.5%	2.5ml, 5ml
Timoptic	timolol maleate	Valeant Ophthalmics, and generic	0.25% 0.5%	5ml, 10ml, 15ml 5ml, 10ml, 15ml
Timoptic (preservative-free)	timolol maleate	Valeant Ophthalmics	0.25% 0.5%	unit-dose unit-dose
Timoptic-XE	timolol maleate	Valeant Ophthalmics, and generic	0.25% 0.5%	2.5ml, 5ml 2.5ml, 5ml
Prostaglandin Analogs				
Bimatoprost	bimatoprost	generic	0.03%	2.5ml, 5ml, 7.5ml
Lumigan	bimatoprost	Allergan	0.01%	2.5ml, 5ml, 7.5ml
Travatan Z	travoprost	Alcon	0.004%	2.5ml, 5ml
Travoprost	travoprost	generic	0.004%	2.5ml, 5ml
Xalatan	latanoprost	Pfizer, + generic	0.005%	2.5ml
Zioptan	tafluprost	Akorn	0.0015%	unit-dose
Alpha Agonists				
Alphagan P	brimonidine	Allergan	0.1%, 0.15%	5ml, 10ml, 15ml
Brimonidine	brimonidine	generic	0.15%, 0.2%	5ml, 10ml, 15ml
Carbonic Anhydrase Inhibitors				
Azopt	brinzolamide	Alcon	1%	5ml, 10ml, 15ml
Trusopt	dorzolamide	Merck, + generic	2%	5ml, 10ml
Combination Glaucoma Medications				
Combigan	brimonidine/timolol	Allergan	0.2%/0.5%	5ml, 10ml
Cosopt	dorzolamide/timolol	Akorn, + generic	2%/0.5%	5ml, 10ml
Cosopt PF	dorzolamide/timolol	Akorn	2%/0.5%	unit-dose
Simbrinza	brinzolamide/brimonidine	Alcon	1%/0.2%	8ml

Authors' Note: Be advised that this is not an exhaustive list of the topical beta-blockers. Several less commonly used drugs have been omitted for space.

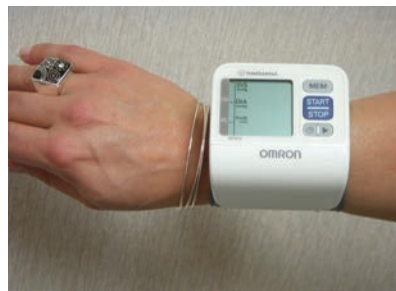successfully obtained target IOP. As an aside, we also find ourselves communicating more with rheumatologists, since many of these specialists have a proclivity to overdose patients taking hydroxychloroquine. (See "Protect Patients from Plaquenil Toxicity," page 15.) Sending a copy of the EMR is an extremely poor substitute for a brief letter.

Measuring systemic blood pressure can accomplish two key goals: screening for the epidemic of uncontrolled (or undercontrolled) systemic hypertension and fine-tuning our understanding of low-tension glaucoma,

as many of these patients have blood pressure that is too low, which can often explain progression of glaucoma despite achievement of target intraocular pressure. Small, forearm (radial) devices for measuring blood pressure are inexpensive, simple to use by ancillary personnel, and can be of enormous value to human health and to glaucoma assessment.

- *Analyze the retinal nerve fiber layer and macular ganglion cell layers, if available.* While in no way is optical coherence tomography absolutely diagnostic, the added benefits of such ancillary testing can be immense-

ly helpful in tracking any progression of glaucoma. In addition to standard retinal nerve fiber layer scans, a quick ganglion cell layer analysis through



Wrist-based blood pressure device.

KNOW YOUR TYPE OF GLAUCOMA

Type	Intraocular Pressure	Optic Nerve
Primary Open-Angle Glaucoma	Elevated	Glaucomatous
Ocular Hypertension	Elevated	Normal
Normal Pressure Glaucoma	Normal/Low	Glaucomatous
Normal Pressure Glaucoma Suspects	Normal/Low	Suspicious

The definition of glaucoma has evolved. Once thought to be exclusively a disease of high intraocular pressure, we now know that glaucomatous optic neuropathy can occur in 25% to 40% of patients with normal IOPs. Don't let a normal IOP distract you from careful nerve head observation and potentially delayed treatment.

the macula can potentially give the clinician more information than what was understood a decade ago. (See “Add Macular Assessment to Analyze Glaucoma,” below.) The latest literature suggests a growing body of evidence revealing that very early glaucomatous damage can involve the macula, specifically the inferotemporal portion of the macular ganglion cell layers. As always, the more information you collect, the more confident you can be in your decision making process.

• **Perform perimetry (repeat, if any doubt).** Ultimately, glaucoma is a disease that affects the visual field (VF). Humphrey visual field 24-2 SITA Fast testing remains our VF assessment of choice. One test result, especially in a naïve-to-visual field test patient, can be misleading unless: It is normal,

or it is abnormal but corresponds to your assessment of the optic nerve head. The problem is that many initial (and, to some degree, subsequent) VF results are just plain “noisy” and fruitless.

Once a repeatable VF defect is present, follow the patient over time with serial VFs. Nerve fiber layer analyzers are more helpful in staging risk or helping to detect early glaucoma, whereas serial VFs are optimal for following patients with established VF defects.

• **Look at the angle.** When performing gonioscopy, we recommend a four-mirror lens. This procedure can be performed relatively quickly after an anesthetic drop. While the non-contact Van Herick assessment is handy, it may not be as sensitive or as specific as gonioscopy.

ADD MACULAR ASSESSMENT TO ANALYZE GLAUCOMA

Though many clinicians assume glaucoma is a disease that affects only peripheral vision, don't pass up the opportunity to analyze the patient's ganglion cell layer in addition to retinal nerve fiber layer scans.

Research has shown that this sensitive area, specifically the inferior/temporal ganglion cells of the macula, is highly vulnerable to early glaucomatous damage.¹ These macular fibers are associated with entering the inferior portion of the optic disc, resulting in a superior “comma defect” on a 10-2 VF.¹

For glaucoma patients complaining of “hazy vision,” or if any central defects are seen on a 24-2 VF, strongly consider ganglion cell analysis in addition to a 10-2 VF. Having both types of information can greatly enhance the care of your patients.

1. Hood, DC, et. al. Glaucomatous damage of the macula. *Prog Retin Eye Res.* 2013;32C 1-21.

Gonioscopy is especially important in patients with moderate to high hyperopia, particularly if a progressive nuclear sclerotic cataract is further narrowing the iridocorneal angle.

Most patients with pigment dispersion syndrome or exfoliation are at higher risk for increased intraocular pressure due to biological debris clogging the trabecular meshwork. Screening for pigment dispersion can be accomplished by carefully examining the corneal endothelial tissues and retroilluminating the non-dilated iris to look for radial (or splotchy) iris transillumination defects. Conversely, exfoliation can be easily missed unless the pupil is pharmacologically dilated. Otherwise, deposits on the face of the lens can be obscured. Qualifying and quantifying such debris in the angle can be critically important, especially in the setting of increased or increasing intraocular pressure.

Beyond assessing the patency of the iridocorneal angle, evaluate the pigmentation of the angle tissues. This is essential to know when contemplating laser trabeculoplasty because pigments absorb the laser energy, enabling a positive therapeutic response. If there is little or no pigmentation of the trabecular meshwork tissues, there will be little or no therapeutic response to laser trabeculoplasty. Gonioscopy also should be performed to rule out causes such as angle recession, neovascularization, etc.

Clinical pearl: Laser trabeculoplasty generally is more effective in phakic eyes than in pseudophakic eyes. This is critical knowledge to enable maximum clinical patient care. We typically repeat gonioscopy about every five years, or sooner if there is an unexplained increase in intraocular pressure.

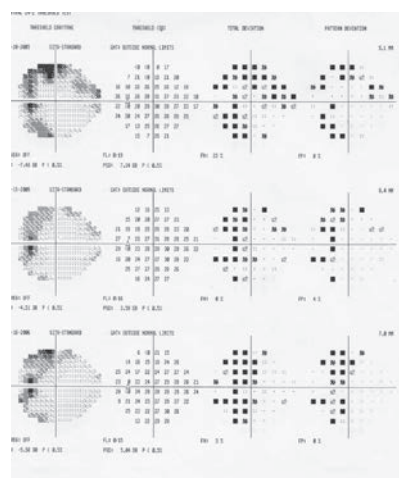
To summarize the diagnostic evaluation:

- (1) Acutely study the optic nerve with slit lamp-enabled ophthalmoscopy.
- (2) Note the intraocular pressure.
- (3) Check central corneal thickness.

DON'T DIAGNOSE GLAUCOMA FROM ONE VF

Try not to make the common mistake of diagnosing glaucoma from a single VF. There is an undeniable learning curve when taking these tests; certainly, no one wants to be told they have glaucoma with subsequent, indefinite treatment. Depending on the level of risk and concern by the doctor or patient, do your due diligence to repeat the field in a few weeks to months, looking for defect repeatability.

Also, remember that glaucomatous visual field defects are most commonly arcuate shaped. Patients can have irregularities in their fields that are not glaucomatous and, depending upon the pattern, may necessitate other routes of investigation. Once you've firmly established the diagnosis of glaucoma, the next step is initiating drop therapy. Never make a change in medical therapy



When in doubt, repeat the field.

based on the results of a single VF test, as it is well-established that repeating visual field testing three to four times is necessary before one can confirm true VF progression. Remember that glaucoma left untreated tends to progress only at a rate of approximately 3% a year.¹

Take note: Glaucoma management is like sailing—there is no wisdom in making rapid changes in course, as there is little benefit in making rushed decisions when managing this disease.

1. Quigley HA. The progression of glaucoma: it isn't what you think. In peril to the nerve — glaucoma and clinical neuro-ophthalmology. Kugler Publications; 1998: 3-11.

Beyond these three prime maneuvers, take a careful family history, especially of the brothers and sisters; obtain nerve fiber layer measurements, baseline VFs and perform gonioscopy. Lastly, check blood pressure, especially in the setting of low-tension glaucoma. By doing all these things, missing glaucoma would be nearly impossible.

THERAPEUTIC PERSPECTIVES

Currently, lowering the intraocular pressure is the only proven treatment for glaucoma. And, knowing when to initiate therapy is the Holy Grail of patient management. Equally competent doctors have different thresholds and different philosophies. By and large, there is no rush to treat because glaucoma is almost always a slowly progressive neuropathy. The decision to treat requires much care, contem-

plation and comprehensive assessment. Also, don't forget that we are not treating a condition or disease; we are treating a human patient, so involving them in the decision-making process is appropriate.

This is a drug guide, not a textbook. We assume a significant level of knowledge on the part of the reader. Remember, there can be exceptions to everything said herein, and every patient has to be cared for in a highly individualized manner. That being said, let's take a look at the various glaucoma medications we have in our armamentarium.

FIRST-LINE THERAPY

With very few exceptions, prostaglandins or timolol remain the traditional frontrunners when treating our patients with glaucoma.

Since its initial release in 1996,

latanoprost (Xalatan) paved the way for prostaglandins as first-line therapy to treat glaucoma. Prostaglandins lower IOP by elevating the presence of extracellular metalloproteinases that break down the collagen matrix, thereby enhancing uveoscleral outflow. As a result, prostaglandins commonly reduce baseline pressures by 25% to 33%.

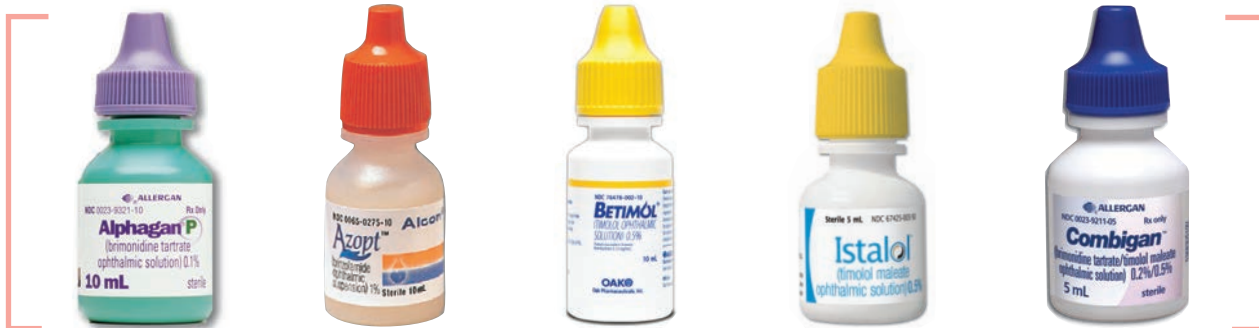Prostaglandins also have an excellent diurnal effect and are typically dosed in the evening, although any time of the day works almost as well. The difference in morning vs. evening instillation of a prostaglandin is somewhere in the vicinity of 1mm Hg, so good adherence in the morning is much preferred to poorer adherence in the evening. Additionally, prostaglandins' long duration of action can be seen for up to 72 hours, which is quite convenient in less-than-compliant patients.

Side effects, while minimal, include iris color darkening, increased eyelid pigmentation, hypertrichosis and conjunctival hyperemia. Another side effect is deepening of the superior eyelid sulcus. This is quite dramatic in some patients and is not trivial to them.

Prostaglandins can be contraindicated in patients with a history of uveitis, herpes simplex and aphakia (due to the slight increased risk of macular edema).

Generic latanoprost is a commonly prescribed glaucoma drop, and for many patients, it is often the best initial choice because of cost. However, choosing the right medicine is highly complicated due to diverse and ever-changing marketing promotions (e.g., coupons) by the companies manufacturing brand-name products. As a result, there may be situations where a brand-name-protected product, at least initially, can be less expensive.

To further complicate matters, different insurance companies have different drug formularies. You're not entirely on your own to navigate this dynamic and maddening landscape; the apps/websites GoodRx.com, Mi-



cromedex and UpToDate, for example, can assist you in your research as you make your way through this convoluted decision-making process.

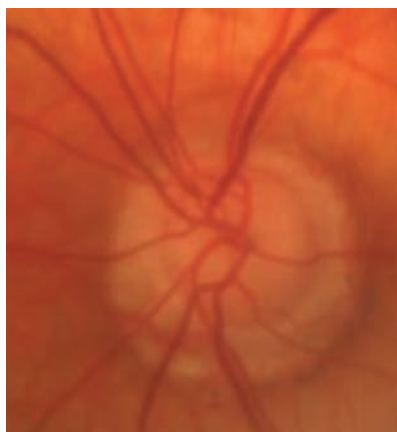
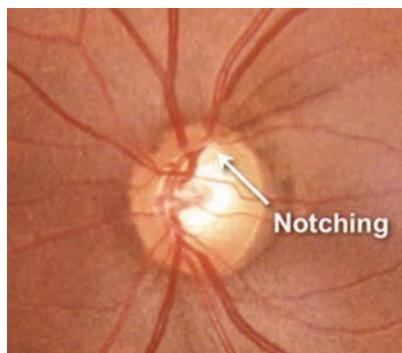
In our patients, the 0.01% formulation of Lumigan is much better tolerated with less hyperemia than the 0.03% (which is generically available), yet there is four times as much benzalkonium chloride (BAK) in the lesser concentrated formula, thus

acknowledging that BAK is not as offensive as is commonly touted. In fact, the 0.01% formulation with the higher BAK concentration was found to have better corneal penetration.

In patients who have a reaction to BAK, Travatan Z (travoprost, Alcon) is instead preserved with SofZia. However, for those rare patients who truly need a preservative-free option, Zioptan (tafluprost, Akorn) nicely

meets this need. The main downside to Zioptan is that, like latanoprost and trifluridine, it has to be stored under refrigeration at the pharmacy.

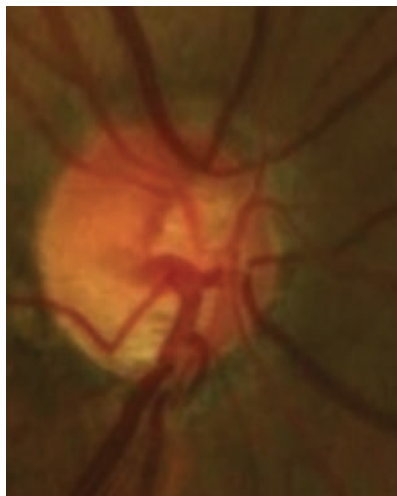
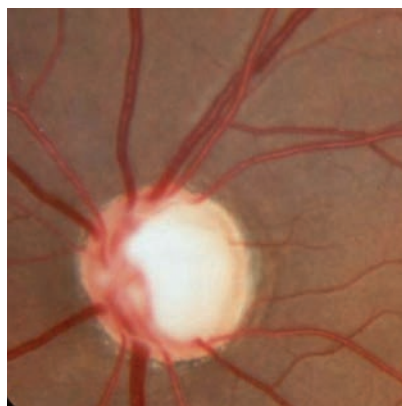
Timolol, a non-selective beta-blocker, lowers IOP by decreasing aqueous humor production. It was the first topical beta-blocker used as an ocular hypotensive for glaucoma in the United States, and for decades was considered the gold standard by



LEFT, TOP: Since the inferior and superior neural tissues have the least robust glial tissue support, they are most prone to sustain loss. Here the loss of neuroretinal rim is manifested as clinical “notching,” a hallmark observation in many glaucoma patients.

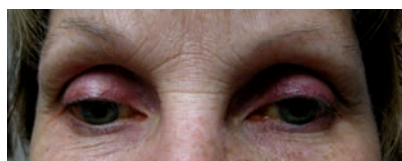
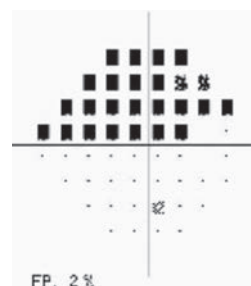
LEFT, MIDDLE: This optic nerve sustained severe loss of neural tissue, thus showing a C/D ratio of 0.8.

LEFT, BOTTOM: Side effect of prostaglandins include periorbital fat atrophy that gives rise to marked deepening of the superior lid sulcus, which can result in ptosis and enophthalmos; beyond the obvious cosmetic concerns, such altered lid/orbital anatomy can make applanation tonometry challenging.



RIGHT, TOP: This optic nerve head was judged to be 0.1 by a previous doctor, but a careful look will show a very thinned neuroretinal rim in a shallow cup. Note also the peripapillary atrophy.

RIGHT, BOTTOM: Because this patient’s IOP was 16mm Hg, we surmise the prior eye doctor failed to carefully study the optic nerve head. Note the pronounced inferior erosion of the neuroretinal rim, which manifested as a superior hemispheric visual field defect.



FROM THE LITERATURE

NEW PERSPECTIVES ON TARGET IOP

“Meta-analysis shows mean IOP reduction with prostaglandin analogues ranges from 28-33%. Slightly smaller IOP reduction is typically achieved with beta-blockers whereas alpha-agonists and carbonic anhydrase inhibitors will usually reduce IOP by 15-20%.”

Clement CI, Bhartiya S, Shaarawy T. New perspectives on target intraocular pressure. *Surv Ophthalmol.* 2014 Nov-Dec;59(6):615-26.

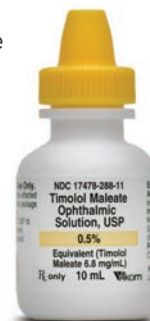which all other drops to treat glaucoma were compared.

Timolol typically lowers pressures 25% from baseline. Unlike prostaglandins, this drop is best dosed in the morning. Remember, beta-blockers act on the sympathetic nervous system, which is greatly down-regulated during sleeping hours. There is no proven benefit of dosing this drop in the evening or more than once a day. (It is important to note that, when

TIMOLOL EYE DROPS FOR MIGRAINE HEADACHE?

Acute migraine headaches may be reduced in intensity or stopped altogether with beta blocker eye drops. While the daily use of beta-blocker pills has proved effective in preventing chronic migraine headaches, they have been unsuccessful in treating acute, sudden-onset migraines. Beta-blocker eye drops, however, are absorbed more quickly than pills by tear duct drainage onto the nasal mucosa, achieving therapeutic plasma levels “within minutes.”

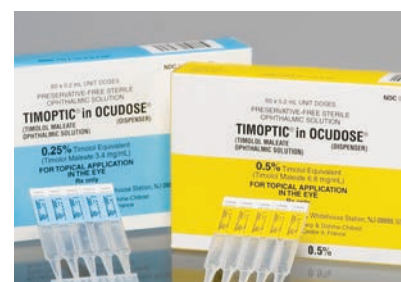Migliazzo CV, Hagan JC. Beta-blocker eyedrops for treatment of acute migraine. *Missouri Medicine.* 2014; 111(4):283-8.



prescribed in combination with other drugs, timolol must be dosed BID because of its other active ingredient. So, for example, when pairing once-a-day timolol with a BID drug such as brimonidine or dorzolamide, the beta-blocker must be dosed BID as well; but, theoretically, this overdoses the beta-blocker.)

Perhaps the greatest asset of generic timolol is its cost—at roughly \$5 for a 5mL bottle, you won’t find a better price point on the market. This cost efficiency can be critically important because cost is a well-recognized reason for patient noncompliance.

For those patients who need a preservative-free beta-blocker, Timoptic in Ocudose (a unit-dose container) is available (though, not generically).



Keep in mind that clinical management occurs within the context of patient management, and multiple factors have to be taken into account to decide which drug will best serve the patient overall.

NEW PROSTAGLANDIN ON DECK

More than 20 years after Xalatan made its debut in 1996, a new prostaglandin is on the horizon: latanoprostene bunod (LBN) is a unique, single-entity, nitric-oxide donating prostaglandin. In a 28-day head-to-head trial (VOYAGER study) with latanoprost, latanoprostene bunod demonstrated superior diurnal reductions in IOP from baseline (although the incidence of adverse effects, mostly mild, were increased with latanoprostene bunod).

Latanoprostene bunod exerts its therapeutic effect when exposed to ubiquitous esterases in the eye. The molecule is split into a prostaglandin receptor agonist and a nitric oxide moiety. Nitric oxide has been shown to relax the trabecular meshwork, enhancing the outflow of aqueous fluid.

In the VOYAGER study, four different concentrations of LBN (0.006%, 0.012%, 0.024% and 0.040%) were compared with Xalatan. All demonstrated a greater IOP reduction than Xalatan, with the higher concentrations of LBN (0.024% and 0.040%) showing the greatest IOP reduction from baseline. Because the two higher concentrations of LBN ended up having similar clinical efficacy (probably due to receptor saturation), the 0.024% dose was selected for further clinical evaluation.

Bausch + Lomb, which will market ophthalmic LBN solution as Vyzulta, expects to launch it later in 2017.

Weinreb RN, Ong T, Scassellati Sforzolini B, et al. A randomized, controlled comparison of latanoprostene bunod and latanoprost 0.005% in the treatment of ocular hypertension and open-angle glaucoma: the VOYAGER study. *Br J Ophthalmol.* 2015;99(6):738-45.

ADJUNCTIVE THERAPY

If a prostaglandin was prescribed for initial therapy, worked well, yet did not achieve the proposed target range of IOP reduction, we would then choose a beta-blocker as adjunctive therapy. We never prescribe the more expensive Timoptic-XE or generic equivalents as we have found that they don’t perform any better than the less expensive original solution.

When this new drop is added to a current one, the patient instills one drop of the beta-blocker in the affected eye(s) in the morning, and one drop of the prostaglandin in the evening. Most of the time, the incorporation of one additional drop is easily accomplished for the patient, and this

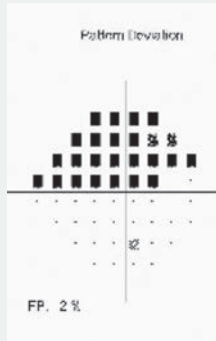


AGING ALONE CAN EXACERBATE PROGRESSION IN GLAUCOMA PATIENTS

It stands to reason that natural quantitative loss of optic nerve fibers over time can contribute to glaucomatous optic neuropathy. An article in *Ophthalmology* (December 2015) gives important insights into the impact of natural aging on visual field compromise in the setting of glaucoma progression, per these excerpts:

- “Age-related loss of neuroretinal parameters may explain a large proportion of the deterioration observed in treated patients with glaucoma and should be carefully considered in estimating rates of changes.”
- “Because there is accumulating evidence that aging in otherwise healthy subjects also results in statistically significant change, often with patterns resembling those in glaucoma, the clinical assessment of glaucomatous progression can be challenging.”
- “The effect of IOP variability on ONH parameters is probably related to changes in laminar position and prelaminar tissue compression.”
- “Because mean deviation (MD) is age adjusted, it is likely that the

In this patient, a pronounced inferior erosion of the neuroretinal rim manifested as a superior hemispheric visual field defect.



absence of normal aging effects with this parameter allows better estimates of glaucoma-related damage than with the neuroretinal parameters.”

• “Our findings indicate that aging in healthy control subjects leads to a significant reduction of neuroretinal parameters and may explain a large proportion of the deterioration observed in patients with treated glaucoma. Furthermore, both cross-sectional and longitudinal studies of healthy subjects show patterns of regional loss similar to those in patients with glaucoma, suggesting that age-related regional susceptibility may be accelerated in glaucoma. Because several previous longitudinal studies of structural progression of glaucoma lacked a control population, the observed changes were attributed to glaucoma, perhaps overestimating the rate of change in treated glaucoma. Therefore, without an understanding of the significant normal age-related changes, there could be errors in rate estimates and the diagnostic accuracy of glaucoma-related progression.”

Thankfully, there are many other metrics and parameters than just visual fields to guide us in clinical decision making. However, this article does serve to make us more analytical in considering changes in visual fields. Remember, to establish true progression, we would have to do three or four fields about every six to 12 months. This is why it is so challenging and minimally productive to micromanage the visual field component of the comprehensive glaucoma assessment.

Vianna JR, Danthurebandara VM, Sharpe GP, et. al. Importance of normal aging in estimating the rate of glaucomatous neuroretinal rim and retinal nerve fiber layer loss. *Ophthalmology*; 2015;122(12):2392-8.

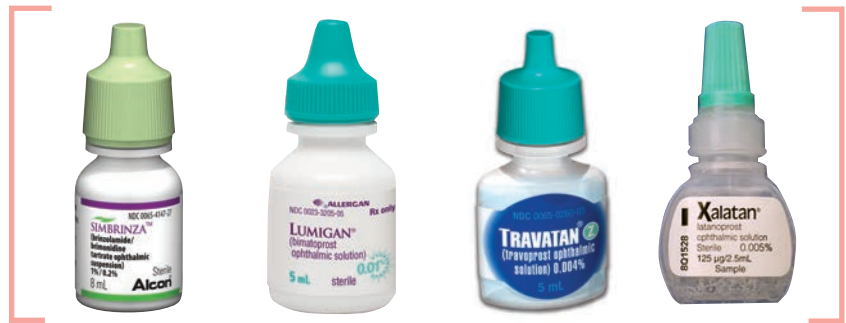combined therapy usually achieves target IOP.

If the beta-blocker is contraindicated (as in a patient with asthma), our next preferred drop is the alpha-2 selective adrenergic agonist 0.2% brimonidine. (For some unexplained reason, 0.2% brimonidine is less costly than 0.15%, although we would prefer the latter; both are generic.) While 1% apraclonidine does demonstrate a much more rapid decrease in IOP, the drop is reserved for short-term adjunctive use due to a slight propensity to cause tachyphylaxis (i.e., rapid decrease in response to a given drug after repeated administration) when used longer than one month.

Alpha-2 adrenergic agonists exert their effects by decreasing aqueous humor production and increasing uveoscleral outflow. The average IOP reduction is around 26%.⁵

One drop is instilled within 20 to 30 minutes after waking, followed by a second drop of brimonidine between 4pm and 5pm in the afternoon. Though FDA-approved dosing for the medication is TID, the use of brimonidine off-label BID as an adjunctive therapy tends to work well for about eight hours, and does very little during the sleep cycle; thus, the late afternoon instillation of the drop provides maximum therapeutic benefit.

In our experience, the addition of 0.2% brimonidine has two main limitations. The first is that the drop is dosed BID as adjunctive therapy—the patient will now be instilling a total of three drops in the affected eye per day. The second potential setback is the possibility of ocular surface allergic disease. We have found this type IV conjunctival hypersensitivity response in about 30% of patients after six to 12 months.



The drop can be prescribed as brand-name Alphagan P (0.1% brimonidine); Purite is the preservative, decreasing chances for adverse effects.

Patients may also experience an increased prevalence of dry mouth and nose while on an alpha-2 adrenergic agonist. As with prescribing any medication, the prospect of adverse side effects should be brought to the patient's attention before starting treatment.

Carbonic anhydrase inhibitors (CAIs) reduce IOP by reducing aqueous production by up to 15% when used as monotherapy, and an additional 15% when used in combination with a prostaglandin or beta-blocker. CAIs also have to be used twice daily. Both of these factors limit their clinical usefulness.

The most common side effects are mild burning and a lingering metallic taste after instillation. Although CAIs have a sulfa side chain, we have observed little or no cross-reactivity in those people who have an allergy to sulfonamide antimicrobials. Be advised that in patients with endothelial compromise, topical CAIs may hinder endothelial function, so be cautious in using these eyedrops in this setting.

This drug class is available as a solution (generic dorzolamide) and a suspension (Azopt [brinzolamide, Alcon]). Only Azopt and Simbrinza are glaucoma suspensions, which have to be shaken before instillation. Brimonidine and dorzolamide are found in combination with 0.5% timolol.

QUOTABLE

“PRIMARY OPEN-ANGLE GLAUCOMA IS DEFINED AS A MULTIFACTORIAL OPTIC NEUROPATHY IN WHICH THERE IS A CHARACTERISTIC ACQUIRED LOSS OF RETINAL GANGLION CELLS (RGC) AND ATROPHY OF THE OPTIC NERVE.”

American Academy of Ophthalmology Preferred Practice Patterns Committee Glaucoma Panel. Preferred practice patterns. Primary Open-Angle Glaucoma. San Francisco, Calif: American Academy of Ophthalmology; 2000: 1-38.



FROM THE LITERATURE

STUDY COMPARES FIRST-LINE MEDICATIONS FOR PRIMARY OPEN-ANGLE GLAUCOMA

This article in *Ophthalmology* (January 2016) definitively confirms what clinicians have witnessed over the last decade: All the prostaglandins work very similarly. Some quotes from this article provide unique insights:

- “The objective of this article is to assess the comparative effectiveness of first-line medical treatments for lowering IOP in patients with POAG or ocular hypertension through a systematic review and network meta-analysis and to provide relative rankings of these treatments. By using a systematic review and network meta-analysis, we estimated the pairwise comparative effectiveness of 14 first-line IOP-lowering drugs used in patients with POAG or ocular hypertension.”

- “Drugs in the prostaglandin class were more efficacious than drugs in other classes, although the within-class differences were generally small. Bimatoprost 0.01% is no more effective than latanoprost or travoprost in lowering IOP at three months. Brimonidine lowered IOP more than apraclonidine; and unoprostone and betaxolol lowered IOP the least.”

- “In conclusion, we found that all active first-line drugs are effective compared with placebo and that prostaglandins were more efficacious in lowering IOP at three months than beta-blockers, alpha-agonists, or carbonic anhydrase. Bimatoprost, latanoprost, and travoprost are among the most efficacious drugs, although the within-class differences were small and may not be clinically meaningful. All factors, including side effects, patient preferences and cost, should be considered in selecting a drug for a given patient.”

This final statement is a clinically practical admonishment. A key factor the authors failed to mention is frequency of administration. While cost is a pre-eminent factor, ease of use is similarly so. We find topical timolol to be cheap, simple and safe (in non-asthmatic patients), which is why we often start there in select patients. It is most definitely our go-to second-line drug when target IOP is not achieved with a prostaglandin.

Tianjing Li, Lindsley K, Rouse B, et al. Comparative effectiveness of first-line medications for primary open-angle glaucoma. *Ophthalmology*. 2016;123(1):129-40.

COMBINATION DROPS

Many patients who have glaucoma are treated with more than one drop during the duration of the disease. Three combination drops are on the market: Cosopt (0.5% timolol with

0.2% dorzolamide, Akorn), Combigan (0.5% timolol with 0.2% brimonidine, Allergan) and Simbrinza (0.2% brimonidine with 1% brinzolamide suspension, Alcon).

Simbrinza is the only suspension combination drug available to treat glaucoma, and this formulation must be shaken before use. Unlike the other combination glaucoma drops, Simbrinza does not contain a beta-blocker. Thus, for a patient with asthma or one who is nonresponsive to beta-blockers, Simbrinza would likely be an ideal add-on to a prostaglandin drug, once individual trials of both brinzolamide and brimonidine have been found to be efficacious.

EYE DROP INSTILLATION: PATIENT & PHARMACIST CORRESPONDENCE

Dear Patient,

To control the pressure inside your eyes, you have been prescribed one of these combination eye medicines circled below. This means there are two individual medicines combined into one bottle. There are many reasons we prefer the single medicine as prescribed, yet it may be more costly than the two individual medicines. There are many advantages, however, to using a single bottle over two separate bottles, and we urge you to use the single bottle prescribed.

- **Combigan**
0.5% timolol with 0.2% brimonidine
- **Cosopt**
0.5% timolol with 2% dorzolamide (both in standard bottle, and as preservative-free unit-dose)
- **Simbrinza (shake well)**
1% brinzolamide suspension with 0.2% brimonidine
(generic dorzolamide solution can be used in place of brinzolamide)

To: Pharmacist

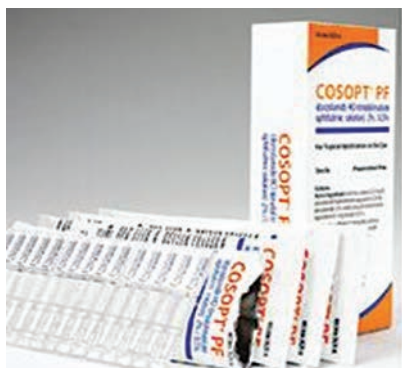If the patient prefers to use two lesser expensive medicines, then you may substitute the prescribed combination medicine for the ingredient drugs above. The *sig* is the same: For timolol, it is one drop daily, shortly after awakening. The other medicines (brimonidine, dorzolamide and brinzolamide) must be used twice daily: one drop shortly after awakening and a second drop about 4pm-5pm. Always wait about 10 minutes between any two eyedrops.

Please join us in trying to find the least expensive combination eye drop, and, if even that is too expensive, then default to the least expensive options shown above.

Thank you,

_____ OD

_____ (Date)



If your first-line therapy was with a prostaglandin and the IOP reduction fell just short of target, it is possible that adding generic brinzolamide or generic brimonidine alone will get the IOP to target, so using a more expensive combination drug may not be necessary.

Cosopt is unique in that it is available generically in a traditional bottle and as a brand-name-protected, preservative-free unit-dose product.

The carbonic anhydrase inhibitors reduce IOP by suppressing aqueous production, and do so by only about 15%. Like brimonidine, they are approved as TID products, yet we tend to use them twice daily in general clinical care. Dorzolamide is an ophthalmic solution (original brand name Trusopt), and brinzolamide is an ophthalmic suspension (original brand name Azopt). When we need to prescribe one of these, we dose twice daily: first dose in early morning, and the second drop about eight hours later (just as we do with brimonidine).

In summary, we typically initiate glaucoma therapy with a prostaglandin, and add timolol 0.25% or 0.5% once daily (in the morning) if target IOP is not reached with the prostaglandin alone.

We still regularly initiate glaucoma therapy with a beta-blocker, particularly when only a 5mm Hg to 6mm Hg reduction in IOP is needed or when we believe that cost is a critical factor in patient compliance. A 5mL bottle of timolol is widely available for about \$4. Be mindful that we have found prostaglandins generally reduce intraocular pressure by about 30%, whereas nonselective beta-blockers reduce IOP by about 25%. That's a separation of only about 1mm Hg to 3mm Hg. Do not lose sight of the fact that beta-blockers remain an excellent choice for reducing IOP.

Taking this together, it is apparent that initial therapeutic interventions are easy, but if the patient is a prostaglandin nonresponder or has active asthma, establishing a plan becomes more like a chess game; it involves considerable thought and therapeutic trials until target IOP is achieved.

Glaucoma should be readily embraced in optometric clinics. While it does remain one of the leading causes of blindness worldwide, outright blindness in developed countries (when managed appropriately) is uncommon. Optimal care necessitates appropriate ancillary testing when needed, treatment initiation

CREATIVE USE OF COMBINATION DRUGS

Treating glaucoma is like a chess game: every move has consequences. The goal for all treatment is efficacy; but cost and convenience must also be considered, because they affect compliance.

We appreciate the convenience of combination therapy and the reduction of preservative exposure, but combination medicines can also be more costly. So, if the patient has limited financial resources and simply can't afford the cost of brand name products, then judicious, critical thinking skills have to come into play to do the best we can to care for these patients.

As such, doctors sometimes have to get creative in their prescribing to finesse the best solution for the individual patient. For example, if you're considering Combigan but the patient is concerned about cost, prescribe 0.5% timolol to be used once daily in the morning, and 0.2% brimonidine to be used every morning and again in the late afternoon. Not as convenient, but less expensive for the patient and equally effective.

Two things to remember: (1) Neither timolol nor brimonidine do much (if anything) to reduce intraocular pressure during the sleep cycle; (2) the effect of brimonidine is about eight hours, so using the second drop around 4pm captures the maximum efficacy of the drug.

Likewise, when cost is of paramount importance with Simbrinza, a brand name-protected drug, prescribe generic 0.2% brimonidine to be used twice daily and

generic dorzolamide suspension (replacing the brand name-protected brinzolamide [Azopt]) with a clinically equivalent topical carbonic anhydrase inhibitor solution twice daily. No shaking is required and this option provides a cost savings from using two generics over one brand name-protected combination drug. Again, have the patient use the second set of drops about eight hours after the morning instillation and wait five to 10 minutes between drops.

Last, and perhaps most important in our experience, just a single generic drug, usually added to a prostaglandin, will sufficiently achieve target IOP. This means we can use one of the following as an additive option: 0.25% or 0.5% timolol as a once-daily add-on (our preferred choice because it's a once-daily drug and by far the least expensive), 0.2% brimonidine used twice daily, or 0.2% dorzolamide used twice daily.

Remember, a small percentage of patients are non-responders, so to blindly use a combination drug may be entirely unnecessary if one of the ingredient drugs brings nothing to the table. So, the intelligent use of any combination drug requires a therapeutic trial of the component drugs to first establish efficacy prior to even thinking of using them in a combination product.

We wish such combination drugs offered two key components: guaranteed efficacy of both ingredient drugs, and more affordable pricing. If they did, we would use them much more often.



FROM THE LITERATURE

THE MONOCULAR TRIAL: IS IT VALUABLE?

We have always embraced the value of a therapeutic monocular trial in the care of patients for whom we contemplate therapeutic intervention. Some dismiss this approach; some advocate for it. Here's some wisdom from the literature.

If a prostaglandin has a therapeutic effect on the first eye, then it almost certainly will have a therapeutic effect on the second eye, and the magnitude of this response will be similar in both eyes. This finding argues against the requirement of additional clinic visits to assess the response of treatment in the second eye.

The monocular trial of therapy is effective in accurately predicting the response of an untreated eye to monotherapy with a prostaglandin analogue at all daytime points measured. There is no requirement for patients to be seen at the same time of day after treatment has commenced. The effect in the first eye predicts both the likelihood and magnitude of an effect in the second eye at all time points during office hours, and negates the requirement for an additional visit to check the therapeutic effect when commencing therapy in the second eye.

Our take: This is in keeping with our 70-plus combined years of glaucoma patient care, and we commonly embrace the monocular therapeutic trial in most of our patients most of the time.

King AJ, Rotchford AP. Validity of the monocular trial of intraocular pressure-lowering at different time points in patients starting topical glaucoma medication. *JAMA Ophthalmol.* 2016; Jul 1;134(7):742-7.

when indicated and always a close observation of the optic nerves at every follow-up to prevent vision loss. As medical practitioners of the eye, it seems appropriate that we should be the first-line providers for the majority of glaucoma patients. **DG**

1. Tham Y-C, Li X, Wong TY, et al. Global prevalence of glaucoma and projections of glaucoma burden through 2040. *Ophthalmology.* Nov 2014;121(11): 2081-90.
2. U.S. Department of Health and Human Services Health Resources and Services Administration Bureau of Health Professions October 2006. Physician Supply and Demand: Projections to 2020. Available at: bhwh.hrsa.gov/sites/default/files/bhwh/nchwa/projections/physician2020projections.pdf. Last accessed March 7, 2017.
3. U.S. Department of Health and Human Services Health Resources and Services Administration Bureau of Health Professions December 2008. The Physician Workforce: Projections and Research into Current Issues Affecting Supply and Demand. Available at: bhwh.hrsa.gov/sites/default/files/bhwh/nchwa/projections/physiciansupplyissues.pdf. Last accessed March 7, 2017.
4. De Moraes CG. NTG: The Nocturnal Blood Pressure Factor. *Rev Ophthalmol.* 2014; 24(2):54-57.
5. Mishra D, Sinha BP, Kumar MS, et al. Comparing the efficacy of latanoprost (0.005%), bimatoprost (0.03%), travoprost (0.004%), and timolol (0.5%) in the treatment of primary open angle glaucoma. *Korean J Ophthalmol.* 2014 Oct; 28(5): 399-407.



TIMOLOL TREATMENT FOR MONOCULAR OSCILLOPSIA

Oscillopsia is a rare monocular, intermittent, rapid, small-amplitude sort of micro-tremor resulting from spastic contraction of the superior oblique muscle. Such spastic episodes typically occur multiple times on a daily basis. These spasms are not grossly visible, and are best seen at the slit lamp.

In the April 2014 issue of *Journal of Optometry*, Christopher J. Borgman, OD, described how the use of timolol 0.5% twice daily may be a sound first-choice trial for patients afflicted with this disorder.

“A localized effect with topical beta-blockers at the trochlear nerve endings and/or superior oblique tissues themselves is responsible for the treatment effect,” Dr. Borgman suggested.

Consult this superb article for a thorough discussion of this largely idiopathic condition.

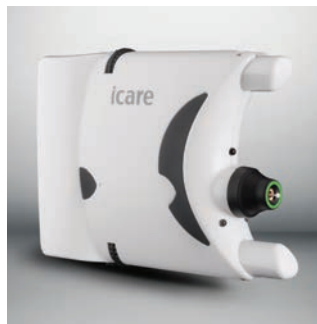Borgman CJ. Topical timolol in the treatment of monocular oscillopsia secondary to superior oblique myokymia: A review. *J Optom.* 2014;7(2):68-74.

BREAKTHROUGH IN HOME TONOMETRY

Glaucoma suspects and patients often have their highest intraocular pressure readings outside of office hours. In fact, a segment of patients go on to develop glaucoma although their office-based IOP is normal, while others demonstrate progressive visual field loss even though their in-office IOP appears to be controlled. As such, eye care professionals need information about IOP after office hours. Thankfully, technology that will provide us with such data was cleared by the FDA in March.

Most eye doctors are familiar with rebound tonometry, known by the brand name Icare tonometer. This technology has been redeveloped into a home tonometer that can be used by the patient to measure IOP at various times beyond office hours.

The Icare Home device can be successfully used by most, but not all, patients. At-home IOP assessments can offer doctors a much more complete picture of the patient's intraocular pressure profile, and will likely enhance diagnostic capabilities. The device collects IOP data, but does not disclose it to the patient (which we consider to be an excellent approach); the on-board computer covertly stores the data until downloaded by the eye doctor. For more information on this new technology, visit <http://icare-usa.com>.



PEARLS ON OCT USE IN GLAUCOMA DIAGNOSIS

- Evaluation of structural (optic nerve head) and retinal nerve fiber layer and functional (visual field) components is a mainstay of glaucoma diagnostics. Of the two, evaluation of structural changes is the initial, fundamental step.¹ Structural changes serve as the primary sign of glaucoma likelihood; they provide the basis of the initial glaucoma-diagnostic indication as to whether patients will undergo further examination or treatment. Thus, accurate evaluation of glaucomatous structural damage is indispensable for appropriate diagnosis of glaucoma.
- Despite its remarkable glaucoma-diagnostic performances confirmed in a number of studies, SD-OCT remains an ancillary glaucoma-diagnostic device rather than a stand-alone modality.²
- In reality, clinicians exercise discretion in accepting OCT results or not based on their impressions gained from clinical examination. Thus, the diagnostic role of OCT should be considered within the context of the process of clinical decision-making.
- Bottom line: Objective (and subjective) testing can be quite helpful, but only in the context of a thoughtful, comprehensive assessment by a qualified OD or MD.

1. Thomas R, Loibl K, Parikh R, et al. Evaluation of a glaucoma patient. *Indian J Ophthalmol.* 2011 Jan; 59(Suppl): S43-52.

2. Kim KE, Oh S, Jeoung JW, et al. Spectral-domain optical coherence tomography in manifest glaucoma: its additive role in structural diagnosis. *Am J Ophthalmol.* 2016; Nov;171:18-26.

SYSTEMIC MEDICINE AND IOP

Understanding associations between systemic medication use and IOP may help our management of glaucoma patients who are being treated for systemic comorbidities, a recent study recommended. A few highlights:

- “Participants taking systemic beta-blockers had lower IOPs.” If a glaucoma patient or suspect stops or decreases their systemic beta-blocker, reassess their IOP.
- “Multiple longitudinal studies show no increased risk of primary open-angle glaucoma for persons with diabetes.”
- “IOP alone is a poor tool for identifying whether an individual has glaucoma.” Glaucoma diagnosis “requires a careful assessment of all relevant risk factors, an expert examination of the optic disc and assessment of the visual field.”

Foster PJ, Khawaja AP. The association of systemic medication and disease with intraocular pressure. *JAMA Ophthalmol.* 2017 Mar 1;135(3):203-204.

