

A Supplement to

# REVIEW<sup>®</sup> OF OPTOMETRY

22nd EDITION

Ron Melton, OD  
Randall Thomas, OD, MPH  
Patrick Vollmer, OD

LIC # \_\_\_\_\_

NAME \_\_\_\_\_ D.O.B. \_\_\_\_\_

ADDRESS \_\_\_\_\_

R<sub>X</sub>

*The  
Clinical Guide to  
Ophthalmic  
Drugs*

*Dispense as written — no substitutions.*

*Refills: unlimited.*

X 

Date *May 15, 2018*



Dr. Melton



Dr. Thomas



Dr. Vollmer

Peer-to-peer  
advice to help  
boost your  
prescribing  
prowess.

Supported by an unrestricted grant from Bausch + Lomb

## DEAR OPTOMETRIC COLLEAGUES:

Welcome to the 2018 edition of our annual *Clinical Guide to Ophthalmic Drugs*. Herein, we provide updates on our collective clinical experiences and heavily season them with pertinent excerpts from the literature.

This guide is intended to bring solid, scientifically accurate and clinically relevant information to our optometric colleagues. If you want to understand how the three of us treat, and what factors led us to develop these methods, you'll find it explained here. The methods and opinions represented are our own. We recognize that other doctors may use alternative approaches. That is true in all of health care. But this three-doctor writing team has logged over 75 combined years of clinical optometry, and we bring that 'real-world' spirit to the discussions that follow. Know that, above all, we are doctors who are genuinely concerned for our patients' well-being and who endeavor to provide them the best of care, and we write from that perspective.

The two topics of greatest interest and need for most eye physicians right now are glaucoma and dry eye disease. We have devoted considerable energy to thoroughly and comprehensively discuss them within these pages. Both are making the headlines these days. In dry eye, the role of omega-3 supplementation—long considered a staple of therapy in dry eye disease—has been challenged by a major study showing no benefit. We will cover this more completely in our dry eye chapter.

The situation is more positive in glaucoma. We're always excited to have new and improved approaches to reduce intraocular pressure. Vyzulta (latanoprostene bunod ophthalmic solution 0.024%) was approved in November 2017, and the following month, rho-kinase inhibitor Rhopressa (netarsudil ophthalmic solution 0.02%) was approved. These new medicines complement our glaucoma armamentarium.

A third new product of note derives from the glaucoma world but has found a new indication. Lumify (brimonidine tartrate ophthalmic solution 0.025%), a redness reliever OTC eye drop that works on the venule tissues through a totally different mechanism of action, is now available, and should completely eclipse the old tetrahydrozoline-containing drops.

We are grateful that Bausch + Lomb and *Review of Optometry* have partnered with us for more than two decades to produce this important resource, as we endeavor to bring our profession the most up-to-date clinical information available to enhance patient care.

With best wishes,



Randall K. Thomas,  
OD, MPH, FAAO



Ron Melton,  
OD, FAAO



Patrick M. Vollmer,  
OD, FAAO

**Disclosure:** Drs. Melton and Thomas are consultants to, but have no financial interests in, the following companies: Bausch + Lomb/Valeant and Icare. Dr. Vollmer has no financial interests in any company.

Supported by an  
unrestricted grant from  
Bausch + Lomb

## CONTENTS

First-year Impressions.....	3
Glaucoma Care.....	6
Off-Label Prescribing.....	19
Dry Eye Therapy .....	22
Corticosteroid Use.....	30
Nonsteroidal Drugs .....	37
Allergy Drugs.....	38
Antiviral Therapy .....	43
Antibiotic Agents.....	48



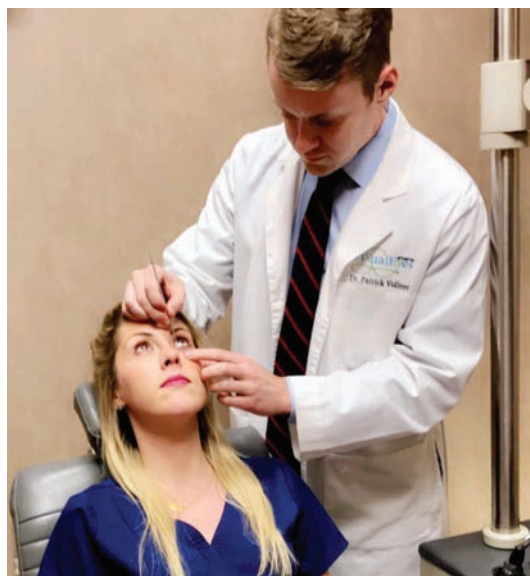A PEER-REVIEWED  
SUPPLEMENT

Note: The authors present unapproved and "off-label" uses of specific drugs in this guide.

# FIRST-YEAR IMPRESSIONS

We newcomers inherit a world of opportunity to do good, for our patients and our profession. Let's use it.

By Patrick Vollmer, OD, FAAO



Dr. Vollmer examines a patient during his first year in private practice.

**M**y rookie year in practice has been fascinating, terrifying and exhilarating, all at the same time. I believe this effect holds even truer if you are a solo practitioner, as I am. After officially being in private practice a little more than a year, I realize I do not have all (or even most) of the answers. But I can speak from experience about what I have learned so far about growing an eye care practice and moving forward in a competitive environment. Here is my advice:

- *Stop referring your patients out.*

Aside from some posterior pathology and cataract surgeries, I have only referred out one case to ophthalmology at the time of this writing. Examples of cases that I have not referred out include: *Pseudomonas* infection, other peripheral and central corneal ulcers, corneal lacerations, herpes simplex keratitis, multiple herpes zoster ophthalmicus cases with severe anterior chamber reactions, preseptal cellulitis, an eye swollen completely shut by bullous impetigo (misdiagnosed as shingles by the PCP), thermal and chemical burns, and many more.

I choose not to refer these cases out, not because I am overly confident (I lost some sleep at night initially) but because the patients came to *me* specifically to help them. Additionally, ophthalmology is a surgical discipline. None of the cases above warrant surgical procedures, nor did ophthalmology have any more access to the medicines used to treat the cases listed above (even the compounded antibiotics used to treat *Pseudomonas*).

If you want to build up your name (and your services are within the associated scope of practice), you simply need to care for these patients yourself.

- *Embrace corticosteroids.* I prescribe topical or oral steroids on a daily basis. I can confidently say that their short-lived side effects (particularly with Lotemax) are negligible compared to the enormous benefits they can provide to your patients.

Not only should you fully embrace your ability to prescribe these agents, you also should prescribe them aggressively early on in the inflammatory process. Tentatively prescribing steroids at suboptimal dosages will not bring your patient disease resolution. Out of all the cases I have treated, I have yet to have one patient not drastically improve while on corticosteroids.

- *Befriend your urgent care centers.* No secret here—urgent care hates “treating” eye-related emergencies. When the prescribed antibiotics failed to make patients’ ocular inflammation better (antibiotics do absolutely nothing for



## ADVICE TO NEW GRADS

Advice for new optometric graduates could fill a textbook, but it also can be succinct; we opt for the latter.

- Buy used equipment, and slowly upgrade to state-of-the-art as finances prudently allow.
- Do all you reasonably can to keep your overhead low.
- Get help and advice on all topics and concerns—don't go it alone! Don't be afraid to ask other successful professionals (even outside of eye care) their advice. Their success was for a reason. Model them—then improvise.
- Regarding the nightmare of insurance, every ophthalmology office has a resident authority in this area. Choose an excellent ophthalmologist to work with for surgical referrals, and in reciprocal benefit, obtain help from their insurance expert. Also, be aware that there are billing/insurance third-party companies available, many compatible with your EHR.
- You are well trained and your basic clinical knowledge is at a peak. Use this asset to keep and care for any and all patients who present to your office. Refer out with great restraint. Never in your life will you have a greater opportunity to solidify your clinical skills than during your first few years in practice.
- Remember, referring out carries a high potential for patient loss at a time when you are working to grow your practice. You have the same access to drugs that other doctors do. Your patient came to you for help. Give it to them.
- Chat with (in person or by phone) older, benevolent optometrists in your area to get their advice about any and every aspect of your business. But choose your advisors wisely. Tread carefully!
- Let your patients know you truly care about them. Rigorously adhere to the Golden Rule; such behavior will always be appreciated and rewarded.
- Be available to your patients. When a patient calls your office, you should have a number where you (or a colleague with whom you have developed a co-sharing of call responsibilities) can be reached. This is paramount.
- Dress for success. Wear nice, professional clothing, and a sharp, white lab coat that bears your name. Be proud to be an OD!

- Develop relationships with urgent care centers, pharmacy-based quick-care centers and primary care physicians. These centers and PCPs have extremely limited knowledge of eye and vision problems, and would be relieved to have someone willing to help them. Set up a time to take these colleagues to lunch, and carry business cards that make you easily accessible. Many health care providers do not realize the scope of practice and wealth of knowledge optometrists have. And always send a succinct letter documenting your findings and appreciation for any referrals.
- Assuming you have a sound skill set, use your deep courage to step up to the plate. Your professional growth will astound you.
- The first time we do anything, there is a level of uncertainty, uneasiness and anxiety. When treating a condition for which some of these emotions or concerns arise within you, simply get the patient's contact number and let them know you will be calling them in a day or two to check on them. A personal phone call to a patient makes them realize how compassionate and caring you are.
- You are not a salesperson; you are a doctor. Put your whole heart into what is absolutely best for your patients, and the revenue will follow.
- Of the big instruments/equipment (beyond the basics), you will need to acquire the following, in this order:
  1. Pachymeter
  2. Humphrey visual field unit
  3. High-quality optical coherence tomography device
  4. Icare tonometer
  5. Retinal camera
  6. Slit-lamp camera
  7. Meibography unit
  8. LipiFlow

These are but a few of many practice management pearls that can be enormously helpful to a willing practitioner. Ponder these and their potential merit thoroughly, and have the determination and courage to pursue them based on your interests and the character of the practice you hope to build.

inflammation), those cases would wind up in my office several days later.

Now, after months of frequenting their clinics, many urgent care eye cases now are referred directly to my practice without any initial treatment at all.

• *Befriend MDs and other health-care providers.* To be perfectly honest, I was met with some initial resistance here. That being said, please

don't get nervous around these folks. Medical/nursing/PA schools instruct their candidates to refer to ophthalmology. To make matters worse, a very low percentage of all these cases ever require surgery, essentially overburdening our surgical colleagues and delaying patient care.

While many primary providers are certainly well-versed in the physiology of numerous organs, the eye is just not one of them. Make yourself

available and remind them of all the services you provide.

• *Always send a follow-up letter.* If another provider refers to you, all they care about is that you treated/addressed the referred issue. If you don't send a succinct, brief follow-up letter (don't send the entire EHR exam), the referrer has no way to document that you did anything at all. This leaves no motivation to have referrals sent your way in the

future. By the way, many EHRs already have such templates available.

• **Remind your patients of all the medical services you offer.** Devote 20 seconds at the end of each patient encounter to letting them know you treat myriad ocular emergencies.

• **Be available to your patients around the clock.** I'm not sure that strictly being available during business hours represents the best of patient care. Everyone knows most conditions and emergencies happen after business hours! If your patient can't find a way to contact you, their care could be significantly delayed. Develop a way to be reached at any time.

• **Don't recommend a product or service a patient doesn't need.** While the financial aspects of consumerism are beneficial, no one wants to be upsold on something that won't benefit them. Talk with your patients to figure out what is most conducive to serving their needs. Patients will tell you that they appreciate this, and are much more likely to trust your advice in the future, and recommend family members and friends.

• **Be patient.** I think that this is the single most important piece of advice I can give a new graduate. Some days you will be slow. Don't let these lulls in patient care get you down! Spend this time reading journals or getting

out in the community to introduce yourself, rather than fretting over when you will see your next appointment. I often (unfortunately) compare myself to my other colleagues who see more than 30 patients a day, although many of those individuals have been in practice for decades and have established patient bases.

Control what you can control, and your practice will prosper. If you can commit to doing your best for all your patients, perhaps you'll look back fondly on the days when you still got a short break for lunch. **DG**

*Patrick Vollmer, OD, is owner of a practice in Shelby, NC.*

## EVOLVING TECHNOLOGY TO AID YOUR PRACTICE

### ■ ePA solutions help streamline prior authorizations for providers.

Electronic prior authorization (ePA) is the automated process of exchanging patient health and medication information, enabling health care providers to initiate PA requests after a rejection at the pharmacy or prospectively in their e-prescribing workflow.

Services such as CoverMyMeds and PARx Solutions partner with electronic health records (EHRs), health care providers, payers and pharmacies to initiate, transmit and track the status of PA requests within the clinical workflow, helping patients to more quickly receive the medications they need for therapy.

For example, health care providers can initiate and manage ePA requests using CoverMyMeds in an online portal or at the point of prescribing through one of the 500-plus EHR vendors integrated with the company's technology. Health care providers can receive electronic determinations, often within minutes, and create renewals from previously submitted requests.

In addition, PARx says its streamlined, user-friendly, full service approach is free to prescribers, combines web-based technology and personalized support, and uses a universal approach across all health plans.

### ■ App for calculating Plaquenil dosing undergoes revisions.

Hydroxychloroquine (HCQ) retinopathy (HCR) is a potentially blinding disease. Once HCR is detected, the disease often continues to progress, even when the medication is stopped. As such, primary prevention by appropriate dosing of HCQ (brand name Plaquenil) is the best way to minimize the risk of HCR. Studies show that about half of

Plaquenil patients are overdosed.<sup>1</sup>

Two somewhat competing approaches to calculating appropriate dose exist:<sup>1</sup>

- *Calculating ideal body weight (IBW):* assumes that HCQ is stored mostly in lean tissue
- *Using actual body weight (ABW):* assumes that the drug is distributed evenly in muscle, skin and fat

In an effort to solve the dilemma, a team of Massachusetts Eye and Ear ophthalmologists developed a free smartphone app—DoseChecker—that blends the two approaches. The app became available in the App Store in September 2017. Users enter the patient's height and weight, and the app calculates the proper HCQ dose.

However, the app deviated from current American Academy of Ophthalmology (AAO) screening recommendations for calculating optimal daily dosage, which is leading to a software revision in progress.<sup>2</sup> The AAO now recommends that all patients using HCQ keep daily dosage less than 5mg/kg actual body weight—not ideal body weight. Older recommendations once advised calculating dosage as 6.5mg/kg ideal body weight, but that conclusion was based on 50-year-old studies about HCQ and fat-using animals, according to an article in the April 2018 issue of *EyeNet*.<sup>3</sup>

When the revised app is available, it is expected to be endorsed by the AAO to simplify the calculation of daily HCQ dose and schedule of tablets needed to provide a proper weekly dose.<sup>3</sup>

1. Perlman EM, Greenberg PB, Browning D, et al. Solving the hydroxychloroquine dosing dilemma with a smartphone app. *JAMA Ophthalmol.* 2018 Feb 1;136(2):218-9.

2. Murray JJ, Lee MS. Re: Marmor et al.: American Academy of Ophthalmology Statement: Recommendations on screening for chloroquine and hydroxychloroquine retinopathy (2016 Revision). (*Ophthalmology* 2016;123:1386-1394). *Ophthalmology.* 2017 Mar;124(3):e28-e29.

3. Mott M. New app to tackle hydroxychloroquine dosing dilemma. *EyeNet.* 2018;22(4): 19.

# DON'T LOSE SIGHT OF GLAUCOMA

Screening should always be on the radar of an attentive optometric physician. With a multitude of diagnostic and therapeutic tools at our disposal, patient referral should be a rarity.

**G**laucoma seldom progresses quickly, so take the time to make a careful diagnosis and thoughtful decisions regarding therapy prior to treatment. Diagnosis and management of glaucoma should be a welcomed opportunity in our offices and clinics, where referral should be exceedingly rare.<sup>1-3</sup>

Let's start with some best practices and reminders for a proper diagnostic glaucoma evaluation.

- Carefully observe the optic nerve head. This is the foundation for the rest of the glaucoma workup. Many times glaucomatous optic neuropathy will be missed because a "normal" intraocular pressure (IOP) lured the clinician into complacency. However, low-tension glaucoma can be found in a sizable minority of patients, so analyze the optic nerve with close attention to the neuroretinal rim tissue.

- Perform tonometry (and at different times of the day). While the prevalence of glaucoma increases with higher IOP, absolute diagnosis should almost never be made from a single pressure reading alone. It is good practice to get at least three different readings, with at least one reading in the early morning, given the circadian variability of IOP.

Large-scale population studies have determined that the mean IOP is around 15.5mm Hg. Two standard deviations on either side of this value approximate

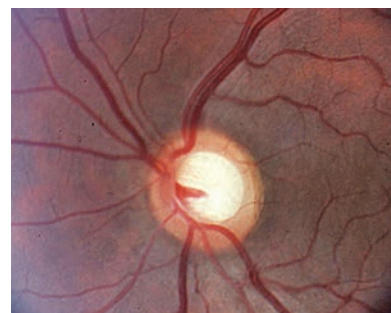
## THE OPTIC DISC

While ancillary testing in glaucoma workups can be helpful, remember that glaucoma is a disease of the optic nerve.

The typical optic nerve head is slightly oval and more vertically oriented. Within the disc lies the optic cup, a paler, central depression devoid of any ganglion cell axons with visibility of the lamina cribrosa.

The tissue that lies between the cup and the edges of the disc is referred to as the neuroretinal rim. Subtle changes to the rim can result in significant changes in a patient's visual field, so carefully scrutinize this tissue.

Remember that the size of the disc and the cup are typically closely related; a larger disc will usually have a larger cup.



**This optic nerve head, while considerably cupped, honors the ISNT rule, and therefore is highly likely physiologic cupping.**

<b>TOPICAL GLAUCOMA DRUGS</b>				
<b>BRAND NAME</b>	<b>GENERIC NAME</b>	<b>MANUFACTURER</b>	<b>CONCENTRATION</b>	<b>BOTTLE SIZE</b>
<b>Beta Blockers</b>				
Betagan	levobunolol hydrochloride	Allergan and generic	0.25% 0.5%	5ml, 10ml 5ml, 10ml, 15ml
Betimol	timolol hemihydrate	Akorn	0.25% 0.5%	5ml 5ml, 10ml, 15ml
Betoptic-S	betaxolol hydrochloride	Novartis	0.25%	5ml, 10ml, 15ml
Istalol	timolol maleate	Bausch + Lomb	0.5%	2.5ml, 5ml
Timoptic	timolol maleate	Bausch Health and generic	0.25% 0.5%	5ml, 10ml, 15ml 5ml, 10ml, 15ml
Timoptic (preservative-free)	timolol maleate	Bausch Health	0.25% 0.5%	unit-dose unit-dose
Timoptic-XE	timolol maleate	Bausch Health and generic	0.25% 0.5%	2.5ml, 5ml 2.5ml, 5ml
<b>Prostaglandin Analogs</b>				
Bimatoprost	bimatoprost	generic	0.03%	2.5ml, 5ml, 7.5ml
Lumigan	bimatoprost	Allergan	0.01%	2.5ml, 5ml, 7.5ml
Travatan Z	travoprost	Novartis	0.004%	2.5ml, 5ml
Travoprost	travoprost	generic	0.004%	2.5ml, 5ml
Vyzulta	latanoprostene bunod	Bausch + Lomb	0.024%	5ml
Xalatan	latanoprost	Pfizer, + generic	0.005%	2.5ml
Zioptan	tafluprost	Akorn	0.0015%	unit-dose
<b>Alpha Agonists</b>				
Alphagan P	brimonidine	Allergan	0.1%, 0.15%	5ml, 10ml, 15ml
Brimonidine	brimonidine	generic	0.15%, 0.2%	5ml, 10ml, 15ml
<b>Carbonic Anhydrase Inhibitors</b>				
Azopt	brinzolamide suspension	Novartis	1%	5ml, 10ml, 15ml
Trusopt	dorzolamide	Merck and generic	2%	5ml, 10ml
<b>Combination Glaucoma Medications</b>				
Combigan	brimonidine/timolol	Allergan	0.2%/0.5%	5ml, 10ml
Cosopt	dorzolamide/timolol	Akorn and generic	2%/0.5%	5ml, 10ml
Cosopt PF	dorzolamide/timolol	Akorn	2%/0.5%	unit-dose
Simbrinza	brinzolamide/brimonidine suspension	Novartis	1%/0.2%	8ml
<b>Rho Kinase Inhibitors</b>				
Rhopressa	netarsudil	Aerie Pharmaceuticals	0.02%	2.5ml

*Author's Note: Be advised that this is not an exhaustive list of the topical beta blockers. Several less commonly used drugs have been omitted for space.*

a normal range to be between 10mm Hg and 21mm Hg.

Traditionally, IOP had been thought to peak in the early morning hours, but research has revealed that IOP is highest during the sleep cycle. Normal diurnal variation is less than 3mm Hg; fluctuations greater than 6mm Hg necessitate a more attentive and closer follow-up.

- **Check central corneal thickness.** Having a pachymeter readily available is crucial to establishing a true IOP. We regularly see referrals for a glaucoma evaluation in patients who have an IOP in the mid-to-upper 20s, with 0.2 or 0.3 central cups and corneal thicknesses of 620µm to 640µm. These patients commonly have a normal workup. If

all optometrists would simply measure the central corneal thickness (CCT) in these pseudo-ocular hypertensives (with semi-annual follow-ups), it would be an immense service to patients and our profession.

According to the Ocular Hypertensive Treatment Study (OHTS), CCT has a major effect on IOP readings. Without a pachymeter, IOP is



FROM THE LITERATURE

**NEW PERSPECTIVES ON TARGET IOP**

“Meta-analysis shows mean IOP reduction with prostaglandin analogues ranges from 28-33%. Slightly smaller IOP reduction is typically achieved with beta-blockers whereas alpha-agonists and carbonic anhydrase inhibitors will usually reduce IOP by 15-20%.<sup>1</sup>”

1. Clement CI, Bhartiya S, Shaarawy T. New perspectives on target intraocular pressure. *Surv Ophthalmol*. 2014 Nov-Dec;59(6):615-26.

relatively meaningless.

Keep in mind that a physiologically thin cornea appears to be an independent risk factor for glaucomatous

**THE POSNER-SCHLOSSMAN SYNDROME**

This unilateral ocular condition—characterized by recurrent, acute attacks of mild, non-granulomatous, anterior uveitis and raised IOP—can result in chronic secondary glaucoma.<sup>1</sup> Look for:

- Anterior uveitis accompanied by markedly elevated IOP (generally 40mm Hg to 50mm Hg)
- Results from recurrent cytomegalovirus infection in the anterior chamber
- Incidence in primarily middle-age male population (although not exclusively)

Standard treatment includes topical steroids and ocular hypertensive medicines. The syndrome is an uncommon cause of glaucomatous neuropathy.

1. Megaw R, Agarwal PK. Posner-Schlossman Syndrome. *Surv of Ophthalmol* 2017;62(3):277-85.

optic neuropathy, which needs to be factored into risk assessment.

- *Evaluate the neuroretinal rim.*

Remember the ISNT rule? It goes like this: inferior > superior > nasal > temporal. Let’s refresh:

In a normal optic nerve head, the

inferior tissues are usually the thickest, followed by superior rim tissues, then nasal rim, with the temporal rim being the thinnest. This is not a bulletproof concept, but it is a good general guide.

Even with much larger cup-to-



FROM THE LITERATURE

**AGING ALONE CAN EXACERBATE PROGRESSION IN GLAUCOMA PATIENTS**

It stands to reason that natural quantitative loss of optic nerve fibers over time can contribute to glaucomatous optic neuropathy. An article in *Ophthalmology* (December 2015) gives important insights into the impact of natural aging on visual field compromise in the setting of glaucoma progression, per these excerpts:<sup>1</sup>

- “Age-related loss of neuroretinal parameters may explain a large proportion of the deterioration observed in treated patients with glaucoma and should be carefully considered in estimating rates of changes.”
- “Because there is accumulating evidence that aging in otherwise healthy subjects also results in statistically significant change, often with patterns resembling those in glaucoma, the clinical assessment of glaucomatous progression can be challenging.”
- “The effect of IOP variability on ONH parameters is probably related to changes in lamellar position and prelaminar tissue compression.”
- “Because mean deviation (MD) is age adjusted, it is likely that the absence of normal aging effects with this parameter allows better estimates of glaucoma-related damage than with the neuroretinal parameters.”
- “Our findings indicate that aging in healthy control

subjects leads to a significant reduction of neuroretinal parameters and may explain a large proportion of the deterioration observed in patients with treated glaucoma. Furthermore, both cross-sectional and longitudinal studies of healthy subjects show patterns of regional loss similar to those in patients with glaucoma, suggesting that age-related regional susceptibility may be accelerated in glaucoma. Because several previous longitudinal studies of structural progression of glaucoma lacked a control population, the observed changes were attributed to glaucoma, perhaps overestimating the rate of change in treated glaucoma. Therefore, without an understanding of the significant normal age-related changes, there could be errors in rate estimates and the diagnostic accuracy of glaucoma-related progression.”

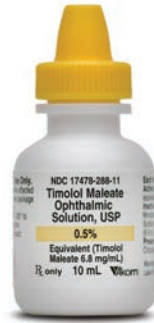Thankfully, there are many metrics and parameters to guide us in clinical decision making beyond the visual field. However, this article serves to make us more analytical in evaluating changes in the visual fields. Remember, in order to establish true progression, we would have to do three or four fields about every six to 12 months. This is why it’s so challenging and minimally productive to micromanage the visual field component of the comprehensive glaucoma assessment.

1. Vianna JR, Danthurebandara VM, Sharpe GP, et. al. Importance of normal aging in estimating the rate of glaucomatous neuroretinal rim and retinal nerve fiber layer loss. *Ophthalmology*. 2015;122(12):2392-8.



## TIMOLOL EYE DROPS FOR MIGRAINE HEADACHE?

Acute migraine headaches may be reduced in intensity or stopped altogether with beta blocker eye drops. While the daily use of beta-blocker pills has been proven effective in preventing chronic migraine headaches, they have been unsuccessful in treating acute, sudden-onset migraines. Beta-blocker eye drops, however, are absorbed more quickly than pills by tear duct drainage onto the nasal mucosa, achieving therapeutic plasma levels “within minutes.”<sup>1</sup>



1. Migliazzo CV, Hagan JC. Beta-blocker eyedrops for treatment of acute migraine. *Missouri Medicine*. 2014;111(4):283-8.

## CENTRAL CORNEAL THICKNESS

In a large study using manometric methods to record intraocular pressure, 44% of normal-tension glaucoma patients would have been reclassified as having primary open-angle glaucoma (POAG), while 35% of patients diagnosed with ocular hypertension would have been reclassified as normal after CCT was taken into account.<sup>1</sup>

To a statistically significant degree, researchers have determined that African-Americans tend to have thinner CCT measurements than Asians, Caucasians and Hispanics. This leads to a considerable underestimation of true IOP.<sup>2</sup>

Importantly, CCT is a predictor of the extent of glaucomatous damage in patients.<sup>3</sup>

1. Ehlers N, Bramsen T, Sperling S. Applanation tonometry and central corneal thickness. *Acta Ophthalmol (Copenh.)* 1975;53:34-43.

2. Shimmyo M, Ross AJ, Moy A, et al. Intraocular pressure, Goldmann applanation tension, corneal thickness, and corneal curvature in Caucasians, Asians, Hispanics, and African Americans. *Am J Ophthalmol*. 2003;136:603-13.

3. Herndon LW, Weizer JS, Stinnett SS. Central corneal thickness as a risk factor for advanced glaucoma damage. *Arch Ophthalmol*. 2004;122:17-21.



FROM THE LITERATURE

## CUP-TO-DISC ASYMMETRY IN GLAUCOMA

A study in the August 2017 *Ophthalmology* described the prevalence of vertical cup-to-disc ratio (vCDR) asymmetry in US adults and assessed the utility of vCDR asymmetry in the glaucoma diagnosis.<sup>1</sup> The researchers concluded:

- vCDR asymmetry was predictive of prevalent glaucoma, although the positive predictive value remained low even at high degrees of asymmetry.
- vCDR asymmetry should initiate a more comprehensive glaucoma workup, especially in individuals with additional risk factors, but it is not appropriate as a screening metric for glaucoma.

1. Qiu M, Boland MV, Ramulu PY. Cup-to-disc ratio asymmetry in U.S. adults: Prevalence and association with glaucoma in the 2005-2008 national health and nutrition examination survey. *Ophthalmology*. 2017 Aug;124(8):1229-36.

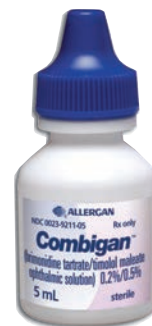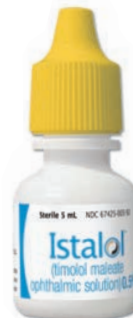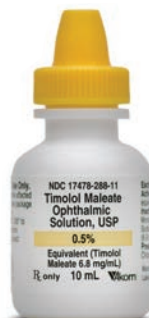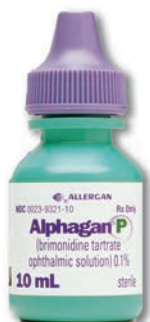disc ratios, the focal rim tissue can be healthy and well-perfused with no pathology present. Erosion of rim tissue, if found, is usually seen at the inferotemporal (macular vulnerability zone) or superotemporal areas. This is secondary to the relatively sparse glial tissue support in this area. Remember, larger optic nerves will have

larger cup-to-disc ratios.

• **Look at the patient's history.** Glaucoma tends to run in families. When we see patients who have glaucoma or who are labeled as high-risk glaucoma suspects, we always ask about siblings, as they can have a higher risk of developing glaucoma that increases with age. We urge our patients to encourage

siblings to also seek an optometric glaucoma evaluation. Such screenings have been shown to yield additional diagnoses.

• **Check blood pressure in-office.** Carefully assess the patient's systemic conditions, especially hypertension. Particularly in low-tension





FROM THE  
LITERATURE

## STUDY COMPARES FIRST-LINE MEDICATIONS FOR PRIMARY OPEN-ANGLE GLAUCOMA

This article in *Ophthalmology* (January 2016) definitively confirms what clinicians have witnessed over the last decade: All the prostaglandins work similarly.<sup>1</sup> Some quotes from this article provide unique insights:

- “The objective of this article is to assess the comparative effectiveness of first-line medical treatments for lowering IOP in patients with POAG or ocular hypertension through a systematic review and network meta-analysis and to provide relative rankings of these treatments. By using a systematic review and network meta-analysis, we estimated the pairwise comparative effectiveness of 14 first-line IOP-lowering drugs used in patients with POAG or ocular hypertension.”
- “Drugs in the prostaglandin class were more efficacious than drugs in other classes, although the within-class differences were generally small. Bimatoprost 0.01% is no more effective than latanoprost or travoprost in lowering IOP at three months. Brimonidine lowered IOP more than apraclonidine; and unoprostone and betaxolol lowered IOP the least.”
- “In conclusion, we found that all active first-line drugs are effective compared with placebo and that prostaglandins were more efficacious in lowering IOP at three months than beta-blockers, alpha-agonists, or carbonic anhydrase. Bimatoprost, latanoprost and travoprost are among the most efficacious drugs, although the within-class differences were small and may not be clinically meaningful. All factors, including side effects, patient preferences and cost, should be considered in selecting a drug for a given patient.”

This final statement is a clinically practical admonishment. A key factor the authors failed to mention is frequency of administration. While cost is a pre-eminent factor, ease of use is similarly so. We find topical timolol to be cheap, simple and safe (in non-asthmatic patients), which is why we often start there in select patients. It is most definitely our go-to second-line drug when target IOP is not achieved with a prostaglandin. Now, with the availability of Vyzulta (Bausch + Lomb), we anticipate using it first line since studies show IOP reductions of 7mm Hg to 9mm Hg and outperformance of latanoprost.<sup>2,3</sup>

1. Tianjing Li, Lindsley K, Rouse B, et al. Comparative effectiveness of first-line medications for primary open-angle glaucoma. *Ophthalmology*. 2016;123(1):129-40.

2. Prescribing Information: Vyzulta (latanoprostene bunod ophthalmic solution) 0.024%, for topical ophthalmic use. Available at: <http://www.bausch.com/Portals/69/-/m/BL/United%20States/US-Files/Package%20Inserts/Pharma/vyzulta-prescribing-information.pdf?ver=2017-12-19-122554-107> (last accessed April 24, 2018).

3. Weinreb RN, Ong T, Scassellati Sforzolini B, et al. A randomised, controlled comparison of latanoprostene bunod and latanoprost 0.005% in the treatment of ocular hypertension and open angle glaucoma: The VOYAGER study. *Br J Ophthalmol*. 2015;99:6:738-45.

glaucoma patients, blood pressure medicines taken in the evening or at bedtime can pathologically lower nocturnal blood pressure, which can accelerate glaucomatous progression by decreasing optic nerve head perfusion.<sup>4</sup> We find ourselves frequently sending letters to primary care physicians explaining this rela-

tively new knowledge and asking them to consider having patients take blood pressure medicines in the mornings.

Measuring systemic blood pressure can accomplish two goals: screening for uncontrolled (or under-controlled) systemic hypertension and fine-tuning our under-

## 24-2 OR 10-2: WHICH IS BETTER?

Researchers studied the association between quality of life (QOL) and visual function as measured by 24-2 and 10-2 VFs in patients with primary open-angle glaucoma.<sup>1</sup> They also tested the hypothesis that patients with vision-related QOL disproportionate to their 24-2 VF status may exhibit 10-2 damage overlooked by the 24-2 test.<sup>1</sup> Here are some of the findings:

- 50% of all ganglion cells were within 8 degrees of fixation.
- 90% of the visual cortex involved 10 degrees of the central VF.
- 24-2 did not sufficiently sample the central VF.
- Using only 24-2VF “may underestimate the extent, location, and implication of VF loss.”
- Macular damage can occur early in glaucoma in the macular vulnerability zone (MVZ).
- Macular glaucoma as measured by the 10-2 VF was “a strong, frequently unmeasured, explanatory variable in vision-related quality of life.”

1. Blumberg DM, De Moraes CGI, Prager AJ, et al. Association between undetected 10-2 visual field damage and vision-related quality of life in patients with glaucoma. *JAMA Ophthalmol*. 2017 Jul 1;135(7):742-7.

standing of low-tension glaucoma. Many of these patients have blood pressures that are too low, which can often explain glaucoma progression, despite achievement of target IOP. Small, forearm-worn (radial) devices for measuring blood pressure are inexpensive and easy to use by ancillary personnel, and can be of enormous value to patient health and glaucoma assessment.

In another unique group of

## KNOW YOUR TYPE OF GLAUCOMA

Type	Intraocular Pressure	Optic Nerve
Primary Open Angle Glaucoma	Elevated	Glaucomatous
Ocular Hypertension	Elevated	Normal
Normal Pressure Glaucoma	Normal/Low	Glaucomatous
Normal Pressure Glaucoma Suspects	Normal/Low	Suspicious

*The definition of glaucoma has evolved. Once thought to be exclusively a disease of high intraocular pressure, we now know that glaucomatous optic neuropathy can occur in 25% to 40% of patients with normal IOPs. Don't let a normal IOP distract you from careful nerve head observation and potentially delayed treatment.*

patients, many asthmatics can use a topical beta-blocker successfully. However, we never prescribe one before soliciting the primary care physician for clearance and written documentation attesting to such. (As an aside, we also find ourselves communicating more often with rheumatologists, since many of these specialists have a proclivity to over-dose patients taking hydroxychloroquine. Sending a copy of the EMR is an extremely poor substitute for a brief letter.)

• *Analyze the retinal nerve fiber layer (RNFL) and macular ganglion*

*cell layers.* While in no way is optical coherence tomography (OCT) absolutely diagnostic, the added benefits of such testing can be immensely helpful in tracking glaucoma progression. In addition to standard RNFL scans and a quick ganglion cell layer evaluation, analysis of the macula can potentially give the clinician additional information.

The latest literature suggests that very early glaucomatous damage can involve the macula, specifically the inferotemporal portion of the ganglion cell layers, referred to as the macular vulnerability zone. As al-

ways, the more information you collect, the more confident you can be in your decisions as you follow the disease over time.

• *Perform perimetry (repeat, if any doubt).* Ultimately, glaucoma is a disease that affects the visual field. Humphrey VF 24-2 SITA Fast testing remains our assessment of choice. One test result, especially in a naïve-to-VF test patient, can be confusing unless it is either normal or it is abnormal but corresponds to the optic nerve head assessment. The problem is that many initial (and some subsequent) VF results are “noisy” and fruitless.

Remember that central VF loss can occur early in glaucoma. Where a 24-2 VF has only four central test points, a 10-2 VF has 44 central points. While routine 10-2 testing is not considered practical, strongly consider it when one or two central defects are seen on the 24-2 VF.

Once a repeatable visual field defect is present, following the patient over time is best done with serial VFs. Nerve fiber layer analyzers are more helpful in staging risk or helping to detect early glaucoma, whereas serial VFs are optimal for following patients with established VF defects.

## OUR PERSPECTIVE ON CORNEAL HYSTERESIS

A number of researchers have tried to determine whether corneal hysteresis (CH)—a biomechanical property relating to the eye’s ability to absorb and respond to pressure—is an independent risk factor for glaucoma. Some studies have determined that low CH is associated with optic nerve and visual field damage in glaucoma, and risk of structural and functional glaucoma progression. One recent study supports the association as a risk factor for developing glaucoma, but the authors note that it was likely not a factor in therapeutic decision-making.<sup>1</sup>

We are of the same mind as the author of a 2016 *Glaucoma Today* article, who wrote at the time that he was unconvinced that CH was a valuable measurement for managing glaucoma.<sup>2</sup> He noted the following:

- “A cornea has several features that might alter hysteresis such as hydration status, thickness, curvature, and IOP. The shape of the force-time curve of the air puff could also change the hysteresis results.”<sup>2</sup>

- “A large correlation study found that corneal hysteresis is influenced by age, corneal thickness, and IOP.<sup>3</sup> This presents a problem for measuring and interpreting a result, because so many different factors interact.”
- “I remain unconvinced at this time that hysteresis is of value in the management of glaucoma.”

While glaucoma specialists continue to study the potential of this technology, we personally have found our tried-and-true methods amply sufficient for assessing ocular pressure.

1. Susanna CN, Diniz-Filho A, Daga FB, et al. A prospective longitudinal study to investigate corneal hysteresis as a risk factors for predicting development of glaucoma. *An L Ophthalmol.* 2018. Mar;187:148-152.

2. Eisenberg D. What Is the Real IOP? *Glaucoma Today.* 2016 July/August. Available at: <http://glaucomatoday.com/2016/08/what-is-the-real-iop/> (last accessed March 30, 2018).

3. Carbonaro F, Hysi PG, Fahy SJ, et al. Optic disc planimetry, corneal hysteresis, central corneal thickness, and intraocular pressure as risk factors for glaucoma. *Am J Ophthalmol.* 2014;157(2):441-446.



## FROM THE LITERATURE

### NEWS ON HOME TONOMETRY

A study in the October 2017 *JAMA Ophthalmology* of 100 patients with glaucoma or ocular hypertension found the majority could perform self-tonometry successfully and would be happy to do so in the future.<sup>1</sup> The study found:

- “Up to 75% of individuals have peak IOP outside of office hours.”
- “...73% [of patients] could perform self-tonometry using a rebound tonometer and obtain IOP measurements within 5mm Hg of a clinician. Self-tonometry was judged easy and comfortable by most patients; most were happy to perform self-tonometry in the future.”
- “A total of 56 of 79 successful or partially successful patients (71%) felt self-tonometry was easy, with 73 of 79 (92%) reporting self-tonometry to be comfortable, and a similar number happy to perform self-tonometry in the future.”



1. Pronin S, Brown L, Megaw R, et al. Measurement of intraocular pressure by patients with glaucoma. *JAMA Ophthalmol.* 2017;135(10):1030-16.

- **Look at the angle.** When performing gonioscopy, use a four-mirror lens. After administering an anesthetic drop, this procedure can be done relatively quickly. While the non-contact Van Herick assessment is helpful, it may not be as sensitive or specific as gonioscopy. This technique is especially important in moderate to high hyperopia if progressive nuclear sclerotic cataract is further narrowing the iridocorneal angle.

Most patients with pigment dispersion syndrome or pseudoexfoliation are at higher risk for increased intraocular pressure due to clogging of the trabecular meshwork by biologic debris. Screening for pigment dispersion can be accomplished by careful examination of the corneal endothelium and retroillumination of the non-dilated iris to look for radial (or splotchy) iris transillumination defects.



## FROM THE LITERATURE

### OCT IN STRUCTURAL DIAGNOSIS

A November 2016 study in *AJO* investigated the role of spectral-domain optical coherence tomography (SD-OCT) in the structural diagnosis of glaucoma.<sup>1</sup> The researchers wrote:

- “Evaluation of structural changes is the initial, fundamental step in glaucoma diagnosis. Structural changes serve as the primary sign of glaucoma likelihood; they provide the basis of initial glaucoma diagnostic indication as to whether patients will undergo further examination or treatment.”
- “In reality, clinicians exercise discretion in accepting OCT results or not based on their impressions gained from clinical examinations. Thus, the diagnostic role of OCT should be examined within the context of the process of clinical decision making.”

1. Kim KE, Oh S, Jeoung JW, et al. Spectral-domain optical coherence tomography in manifest glaucoma: its additive role in structural diagnosis. *Am J Ophthalmol.* 2016 Nov;171:18-26.

### USING THE MACULA TO ANALYZE GLAUCOMA

Don't assume that glaucoma is a disease that affects only peripheral vision, and pass up the opportunity to analyze the patient's ganglion cell layer and RNFL scans. Research has shown that this sensitive area, specifically the inferior/temporal ganglion cells of the macula, is highly vulnerable to early glaucomatous damage. Macular fibers enter the inferior part of the optic disc, resulting in a superior “comma defect” on a 10-2 VF.<sup>1</sup>

For glaucoma patients complaining of “hazy vision,” or with central defects on a 24-2 VF, strongly consider ganglion cell analysis along with a 10-2 VF.

1. Hood, DC et. al. Glaucomatous damage of the macula. *Prog Retin Eye Res.* 2013;32C 1-21.

Pseudoexfoliation can be missed if the pupil is not pharmacologically dilated, as deposits on the face of the lens may be obscured. Qualifying and quantifying such debris in the angle is vital, especially in the setting of increasing IOP.

It is also important to annotate the pigmentation of the angle tissues when contemplating laser trabeculoplasty. Pigment absorbs the laser energy to enable a positive therapeutic response. If little or no pigmentation can be found in the trabecular meshwork tissues, the patient likely won't experience a useful therapeutic response from the procedure. On the other hand, heavily pigmented angles tend to result in decreased IOP lowering effects. Gonioscopy should be performed to rule out causes such as angle recession or neovascularization.

- **Consider trabeculoplasty earlier.** Laser trabeculoplasty is more effective in phakic than in pseudophakic eyes. We typically repeat gonioscopy every five years or sooner with unexplained increasing IOP.





## FROM THE LITERATURE

### RISK FACTORS FOR RAPID PROGRESSION OF POAG

This study in the August 2017 *AJO* aimed to determine the intraocular and systemic risk factor differences between rapid and non-rapid glaucoma progressors.<sup>1</sup> It determined:

- “Cardiovascular disease is an important risk factor for rapid glaucoma disease progression irrespective of IOP control.”
- “...worse baseline mean deviation (MD), higher baseline IOP, more frequent ocular antihypertensive medication changes, and number of IOP-lowering medicines were also robust predictors for rapid progression in our cohort. Although other risk factors including lower CCT, PXF, disc hemorrhages and hypotension were more common in the rapid progression cohort, they did not have a significant effect in predicting disease progression.”

1. Chan TCW, Bala C, Siu A, et al. Risk factors for rapid glaucoma disease progression. *Am J Ophthalmol.* 2017 Aug;180:151-7.

To summarize the diagnostic evaluation:

- (1) Carefully study the optic nerve with slit lamp-enabled ophthalmoscopy.
- (2) Note the IOP.
- (3) Check CCT.

Beyond these three maneuvers, take a careful family history, obtain RNFL measurements and baseline VFs, and perform gonioscopy. Lastly, check blood pressure, especially

in the setting of low-tension glaucoma. By doing all these things, you will reduce the chance of missing glaucoma.

### THERAPEUTIC PERSPECTIVES

Currently, lowering IOP is the only proven treatment for glaucoma. Knowing when to initiate therapy is the Holy Grail of patient management. Equally competent doctors

have different thresholds and philosophies but, by and large, there is no rush to treat because glaucoma is usually a slowly progressive neuropathy.

The decision to treat requires much care, contemplation and comprehensive assessment. Also, don't forget that we are not treating a condition or disease; we are treating a person, so involving patients in the decision-making process is appropriate. Also remember: This publication is a drug guide, not a textbook. We assume a significant level of knowledge on the part of the reader. There can be exceptions to everything said herein, and every patient has to be cared for in a highly individualized manner.

Let's now look at glaucoma medications we have in our armamentarium.

### FIRST-LINE THERAPY

With few exceptions, a prostaglandin or timolol remain the frontrunners in treating patients with glaucoma.

Since its initial release in 1996, latanoprost (Xalatan) paved the way for prostaglandins as first-line



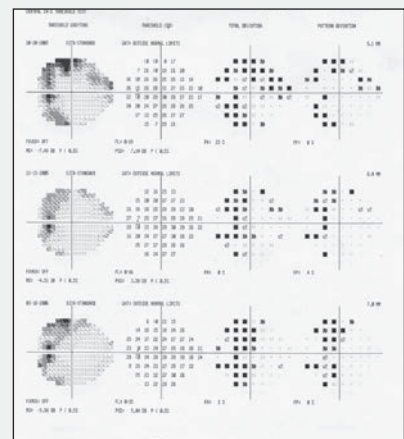
## FROM THE LITERATURE

### PROGRESSION AND FREQUENCY OF TESTING

Research published in the June 2017 *Ophthalmology* described the time required to detect statistically significant progression of different rates of VF loss using standard automated perimetry when considering different frequencies of testing.<sup>1</sup> The authors indicated:

- “Standard automated perimetry (SAP) remains the most important clinical tool for detecting progressive damage.”
- It is essential to obtain two reliable tests within a short time frame at baseline.
- “Confirming the presence of progressive loss through repeated testing is recommended to reduce the probability of incorrectly diagnosing progression.”
- “The initiation or intensification of glaucoma treatment, or even its mere diagnosis, can have a negative impact on an individual.”
- It is important to obtain semi-annual testing within the first year of follow-up.
- Tailor your care with each patient.

1. Wu Z, Saunders LJ, Daga FB, et al. Frequency of testing to detect visual field progression derived using a longitudinal cohort of glaucoma patients. *Ophthalmology.* 2017 Jun;124(6):786-92.



When in doubt, repeat the field.

**NO SINGLE VF DIAGNOSES**

Do not make the mistake of relying on a single VF to diagnose glaucoma. Depending on the level of patient risk, do your due diligence to repeat the fields in a few weeks to months, looking for defect repeatability. Also, remember that glaucomatous VF defects are most commonly arcuate and nasal in shape. Patients can have irregularities in their fields that are not glaucomatous and, depending upon the pattern, may or may not necessitate other routes of investigation.

Once a diagnosis of glaucoma is firmly established, initiation of drop therapy is the next step. Note: never make a change in medical therapy based on the results of a single visual field test, as it is established that repeating VF testing three to four times is necessary before one can confirm true progression of a VF.

therapy to treat glaucoma. Prostaglandins lower intraocular pressure by elevating the presence of extracellular metalloproteinases that break down the collagen matrix, thereby enhancing uveoscleral outflow of aqueous. This class of drugs commonly reduces baseline pressures by 25% to 33%.

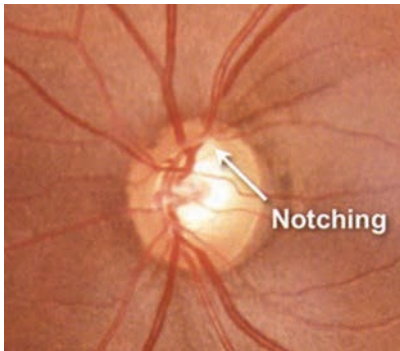
Prostaglandins also have an excellent diurnal effect. However, the

difference in morning vs. evening instillation of a prostaglandin is somewhere in the vicinity of 1mm Hg, so good adherence in the morning is much preferred to poorer adherence in the evening. Additionally, prostaglandins' long duration of action can be seen for up to 72 hours, which is convenient in less compliant patients.

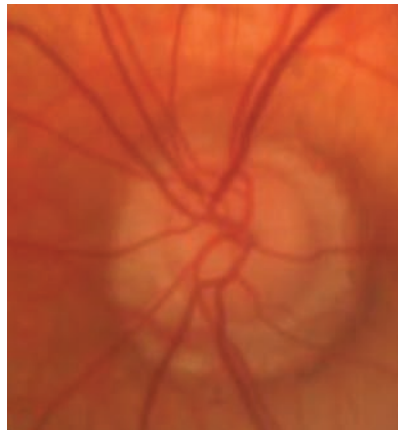
Side effects, while minimal, in-

clude iris color darkening, increased eyelid pigmentation, hypertrichosis and conjunctival hyperemia. Another side effect, superior eyelid sulcus deepening, can be dramatic in some patients.

Prostaglandins can be contraindicated in patients with a history of uveitis, herpes simplex and aphakia (due to the slight increased risk of macular edema).

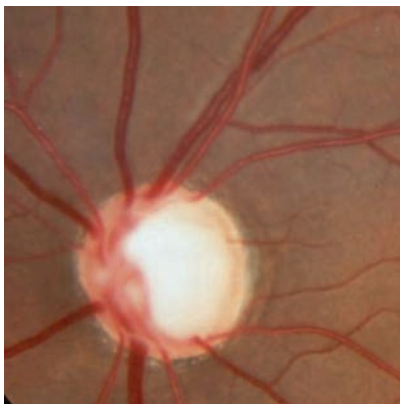


Notching

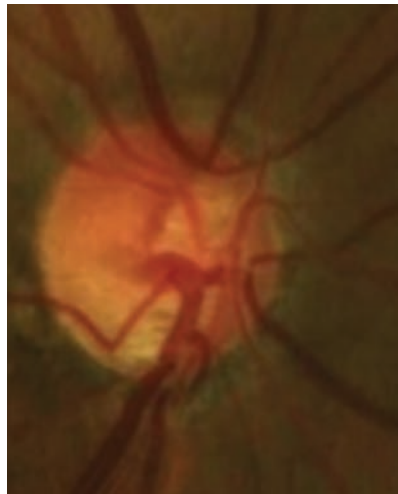


**TOP LEFT:** Since the inferior and superior neural tissues have the least robust glial tissue support, they are most prone to sustain loss. Here the loss of neuroretinal rim is manifested as clinical “notching,” a hallmark observation in many glaucoma patients.

**MIDDLE LEFT:** This optic nerve sustained severe loss of neural tissue, thus showing a C/D ratio of 0.8.

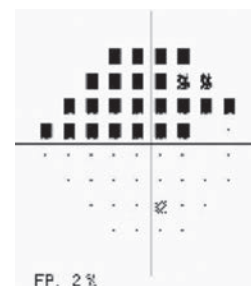


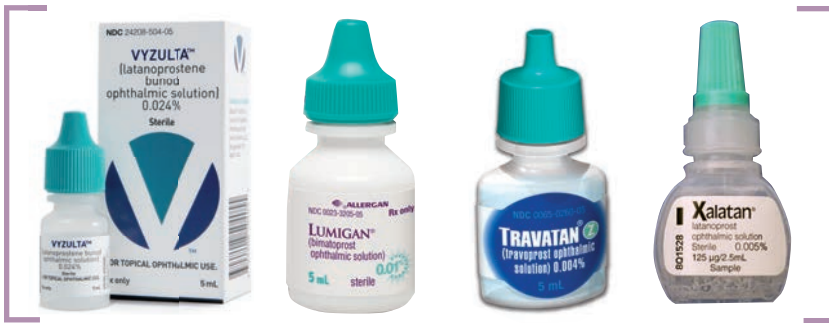**BOTTOM LEFT:** Side effect of prostaglandins include periorbital fat atrophy that gives rise to marked deepening of the superior lid sulcus, which can result in ptosis and enophthalmos; beyond the obvious cosmetic concerns, such altered lid/orbital anatomy can make applanation tonometry challenging.



**TOP RIGHT:** This optic nerve head was judged to be 0.1 by a previous doctor, but a careful look will show a very thinned neuroretinal rim in a shallow cup. Note also the peripapillary atrophy.

**BOTTOM RIGHT:** Because this patient's IOP was 16mm Hg, we surmise the prior eye doctor failed to carefully study the optic nerve head. Note the pronounced inferior erosion of the neuroretinal rim, which manifested as a superior hemispheric visual field defect.





## FROM THE LITERATURE

### RISK FACTORS FOR ANGLE CLOSURE

A study in the September/October 2017 *Survey of Ophthalmology* revealed that reasons why and how people develop acute angle-closure glaucoma are still not well-elucidated.<sup>1</sup> The researchers illuminated that:

- “Narrow anterior chamber angle, advanced age, female gender, and Asian ethnic background are considered risk factors for acute primary angle closure.”
- “...acute angle closure eventually develops in only a relatively small proportion of anatomically predisposed eyes.”
- “It remains difficult to predict and prevent acute angle closure attacks.”

1. Zhang X, Liu Y, Wang W, et al. Why does acute primary angle closure happen? Potential risk factors for acute primary angle closure. *Surv Ophthalmol*. 2017 Sep - Oct;62(5):635-47.

Generic latanoprost is a commonly prescribed glaucoma drop, and for many patients, it may be the best initial option because of cost. However, choosing the right medicine is highly complicated due to diverse and ever-changing marketing promotion. In some situations, a brand-name-protected product can be less expensive, especially with a coupon.

As well, different insurance companies have different drug formularies. To help you navigate this dynamic landscape, turn to the GoodRx, Micromedex and UpToDate web sites to help you in your decision-making.

In our patients, the 0.01% formulation of Lumigan (bimatoprost, Allergan) is much better tolerated with less hyperemia than the 0.03% (which is generically available), yet there is four times as much benzalkonium chloride (BAK) in the lesser-concentrated formula. We feel that this suggests that BAK is not as of-

### QUOTABLE

**“PRIMARY OPEN-ANGLE GLAUCOMA (POAG) IS A CHRONIC, PROGRESSIVE OPTIC NEUROPATHY IN ADULTS IN WHICH THERE IS A CHARACTERISTIC ACQUIRED ATROPHY OF THE OPTIC NERVE AND LOSS OF RETINAL GANGLION CELLS AND THEIR AXONS.”<sup>1</sup>**

1. American Academy of Ophthalmology. Preferred Practice Pattern. Primary Open-Angle Glaucoma. 2016. [www.aaojournal.org/article/S0161-6420\(15\)01276-2/pdf](http://www.aaojournal.org/article/S0161-6420(15)01276-2/pdf) (last accessed March 30, 2018).

fensive as commonly touted. In fact, we have found that the 0.01% formulation with the higher BAK concentration has better corneal penetration.

That said, for patients sensitive to BAK, Travatan Z (travoprost, Novartis) is preserved with SofZia. And for those rare individuals who truly need a preservative-free option, Zioptan (tafluprost, Akorn) nicely meets this need. The main downside is that, like latanoprost and trifluri-

### ASSESSING THE NARROW ANGLE<sup>1</sup>

- “Often, at cocktail parties, glaucoma specialists get together and say, ‘What’s wrong with the general ophthalmologists? They’re missing a lot of angle closure.’ And I usually say, ‘Well, what’s wrong with us that we haven’t been teaching them gonioscopy?’”
- “...there are a lot of cases that come from optometry where they have been referred for high pressure, and no assessments of the angle were performed.”
- Always “do gonioscopy in a completely darkened room [...]. There should be no light through the pupil.”

1. Asrani SG, et al. MD Roundtable: Expert Tips for Assessing the Narrow Angle. *Eye Net*. 2015. January.

dine, Zioptan has to be stored under refrigeration at the pharmacy.

Timolol, a non-selective beta-blocker, lowers IOP by decreasing aqueous humor production. It was the first topical beta-blocker to be used as an ocular hypotensive for glaucoma in the United States, and for decades was considered the gold standard by which all other glaucoma drops were compared. Timolol typically lowers pressures 25% from baseline.

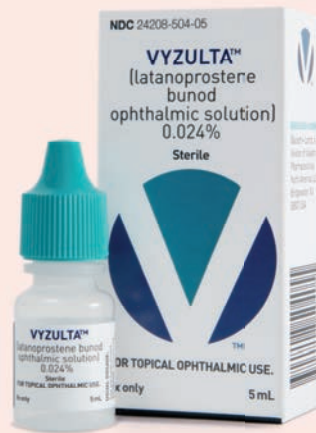**A VICTORY FOR VYZULTA**

The first new glaucoma medication in quite some time, latanoprostene bunod ophthalmic solution, 0.024% (LBN) was FDA approved in November 2017, more than 20 years after Xalatan made its debut in 1996.

LBN is the first IOP-lowering agent with a novel dual mechanism of action. Once in the eye, resident esterases cleave the molecule into latanoprost acid and butanediol mononitrate, which is further metabolized, yielding nitric oxide that appears to relax the smooth muscles of the trabecular meshwork. This outcome enhances aqueous outflow. The IOP-lowering effects were up to 7mm Hg to 9mm Hg.<sup>1</sup>

In a 28-day trial head-to-head trial (VOYAGER) against latanoprost, LBN demonstrated superior diurnal reductions in IOP from baseline.<sup>2</sup> Four concentrations of LBN (0.006%, 0.012%, 0.024% and 0.040%) were compared with Xalatan. All demonstrated a higher IOP reduction than Xalatan, with the high concentrations of LBN (0.024% and 0.040%) showing the greatest IOP reduction from baseline. Because the two higher concentrations of LBN ended up having similar clinical efficacy (probably due to receptor saturation), the 0.024% dose was selected for further clinical evaluation. In the study, Vyzulta led to an additional IOP reduction of 1.2mm Hg.<sup>2</sup>

Vyzulta is a prostaglandin analog indicated for the reduction of IOP in patients with open-angle glaucoma or ocular hypertension. Note that it is not indicated for “elevated” IOP, thus acknowledging that many patients have normal pressure glaucoma or are glaucoma suspects. Like latanoprost, the drop is stored long-term



under refrigeration until dispensed to the patient. Approved for once-daily use (in the evening) and recommended for people over age 16, Vyzulta’s main side effect is conjunctival hyperemia (about 6%). It is preserved with 0.02% BAK (just like latanoprost) and comes in a 7.5mL bottle filled to 5mL volume.

Since it is established that every millimeter reduction in IOP significantly decreases the risk of glaucoma progression, we perceive using this new medicine in at least four clinical situations:

1. First line in an attempt to drive IOP as low as possible.
2. Patients in whom target IOP is nearly achieved with any of the older generation prostaglandins. We could easily add a beta-blocker once daily, but this would require the acquisition of another topical preserved eye drop that might not be necessary.
3. Certainly, if the patient has asthma or is a beta-blocker nonresponder, Vyzulta might achieve target IOP.
4. When a prostaglandin and a beta-blocker come close but do not achieve target IOP, replacing the prostaglandin with Vyzulta might meet treatment goals.

We are pleased to have a new, dual-mechanism, single-molecule drug available that can help us achieve further IOP reduction and provide optic nerve protection, as well as potentially delay the need to add a second or third drug.

1. Prescribing Information: Vyzulta (latanoprostene bunod ophthalmic solution) 0.024%, for topical ophthalmic use. Available at: <http://www.bausch.com/Portals/69/-/m/BL/United%20States/USFiles/Package%20Inserts/Pharma/vyzulta-prescribing-information.pdf?ver=2017-12-19-122554-107> (last accessed April 24, 2018).

2. Weinreb RN, Ong T, Scassellati Sforzolini B, et al. A randomised, controlled comparison of latanoprostene bunod and latanoprost 0.005% in the treatment of ocular hypertension and open angle glaucoma: The VOYAGER study. *Br J Ophthalmol.* 2015;99:6:738-45.

Unlike the dosing of prostaglandins, it is important to dose this drop in the morning. Remember, beta-blockers act on the sympathetic nervous system, which is greatly downregulated during our sleeping hours. There is no proven benefit of dosing this drop in the evening or more than once a day.

Perhaps the greatest asset of generic timolol is its cost—under \$10 for a 5mL bottle—so you likely won’t find a better price point on the market. This is important, as

cost is a well-recognized reason for patient noncompliance. For patients who need a preservative-free beta-blocker, Timoptic (Bausch + Lomb) in ocudose (a unit-dose container) is available, though not generically.

**ADJUNCTIVE THERAPY**

If we prescribe a prostaglandin for initial therapy, and it works well but doesn’t achieve the proposed target range of IOP reduction, we would consider switching to Vyzulta before adding a beta-blocker as adjunctive

therapy (assuming no contraindications). If a second drug was needed, we would have the patient instill one drop of the beta-blocker in the affected eye in the morning, and one drop of the prostaglandin in the evening. This combined therapy usually achieves target IOP.

If the beta-blocker is contraindicated (e.g., in a patient with asthma), our next preferred drop is the alpha-2 selective adrenergic agonist 0.2% brimonidine. While 1% apraclonidine demonstrates a more rapid



## EVERY MILLIMETER COUNTS

- "...the risk reduction could be about 19% per mm Hg, confirming results from the EMGT [Early Manifest Glaucoma Trial] and Canadian Glaucoma Study, and showing that IOP reduction is highly effective, and that every mm Hg of pressure counts... These results [...] should also serve as a stimulus to the pharmaceutical industry to continue development of new and even more potent drugs."

Heijl A. Glaucoma treatment: by the highest level of evidence. *Lancet*. 2015 Apr 4;385(9975):1264-6.

- "Patients treated in the EMGT had half of the progression risk of control patients. The magnitude of initial IOP reduction was a major factor influencing outcome. Progression was also increased with higher baseline IOP, exfoliation, bilateral disease, worse mean deviation, and older age, as well as frequent disc hemorrhages during follow-up. Each higher (or lower) millimeter of mercury of IOP on follow-up was associated with an approximate 10% increased (or decreased) risk of progression."

Leske MC, Heijl A, Hussein M, et al. Factors for Glaucoma Progression and the Effect of the Treatment. *Arch Ophthalmol*. 2003 Jan;121(1):48-56.

- "...elevated IOP is a strong risk factor for glaucoma progression, with the HR [hazard ratio] increasing by 11% for every 1mm Hg of higher IOP."

Bengtsson B, Leske MC, Hyman L, et al. Fluctuation of intraocular pressure and glaucoma progression in the early manifest glaucoma trial. *Ophthalmology*. 2007 Feb;114(2):205-9.

decrease in IOP, the drop is reserved for short-term adjunctive use due to a slight propensity to cause redness and tachyphylaxis when used longer than one month. Alpha-2 adrenergic agonists exert their effects by decreasing aqueous humor production and increasing uveoscleral outflow. The average IOP reduction is around 26%.<sup>5</sup>

One drop is instilled within 20 to 30 minutes after waking, followed by a second drop of brimonidine between 4pm and 5pm in the afternoon. Though FDA-approved dosing for the medication is TID, off-label use of brimonidine BID as an adjunctive therapy tends to work well for about eight hours, and does very little during the sleep cycle; thus, late afternoon instillation provides maximum therapeutic benefit.

In our experience, the addition of 0.2% brimonidine has two main limitations. First, the drop is dosed BID as adjunctive therapy—the patient will now be instilling a total of three drops in the affected eye, per day. The second is the possibility of ocular surface allergic disease. We have found a type IV conjunctival hypersensitivity response in about 30% of patients after six to 12 months of

use. Alternatively, the therapy can be prescribed as brand-name Alphagan P (0.1% brimonidine, Allergan) with Purite as the preservative to decrease chances for adverse effects; however, this route is considerably more expensive.

While on alpha-2 adrenergic agonists, patients may experience an increased prevalence of dry mouth and nose, so potential adverse side effects should be brought to the patient's attention before starting treatment.

Carbonic anhydrase inhibitors (CAIs) reduce IOP by reducing aqueous production by up to 2mm Hg to 3mm Hg when used as monotherapy, and an additional 15% when used in combination with a prostaglandin or beta-blocker, we have found. CAIs have to be used twice daily. So we feel that such factors limit their clinical usefulness.

The most common side effects with CAIs are mild burning and a lingering metallic taste after instillation. Although CAIs have a sulfa side chain, we have observed little or no cross-reactivity in people who are allergic to sulfonamide antimicrobials since the molecular structures differ greatly. Be aware that topical CAIs may hinder endothelial function in patients with endothelial compromise, so take caution in using these eye drops in this setting.

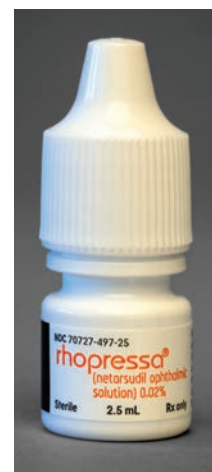## NEW GLAUCOMA CLASS OF DRUG

The trabecular meshwork is finally getting some overdue attention. A new class of drugs known as rho kinase (ROCK) inhibitors is focused on enhancing conventional outflow.

Netarsudil ophthalmic solution 0.02%, marketed under the brand name Rhopressa (Aerie Pharmaceuticals), was FDA approved in December 2017 for lowering elevated IOP in patients with open-angle glaucoma or ocular hypertension. The solution is to be used once daily. Findings from a Phase II trial comparing netarsudil to latanoprost revealed that IOP reductions were similar, and in all enrolled patients netarsudil was 1mm Hg less effective than latanoprost.<sup>1</sup> The most frequently reported adverse event with netarsudil was conjunctival/ocular hyperemia, with an incidence of about 52%.<sup>1</sup>

These rho kinase inhibitors represent a new class of IOP-lowering agents to help many glaucoma patients try to achieve target IOP. As of the time of publishing, we have not yet had access to Rhopressa to be able to assess its utility in clinical patient care.

1. Bacharach J, Dubiner HB, Levy B, et al. Double-masked, randomized, dose-response study of AR-13324 versus latanoprost in patients with elevated intraocular pressure. *Ophthalmology*. 2015;122(2):302-307.



## SYSTEMIC MEDICINE AND IOP

Understanding associations between systemic medication use and IOP may help us manage glaucoma patients being treated for systemic comorbidities, a recent study suggested.<sup>1</sup> A few highlights included that:

- “Participants taking systemic beta-blockers had lower IOPs.” If a glaucoma patient or suspect stops their systemic beta-blocker, reassess their IOP.
- “Multiple longitudinal studies show no increased risk of POAG for persons with diabetes.”
- “IOP alone is a poor tool for identifying whether an individual has glaucoma.” Glaucoma diagnosis “requires a careful assessment of all relevant risk factors, an expert examination of the optic disc, and an assessment of the visual field.”

1. Foster PJ, Khawaja AP. (Invited Commentary) The association of systemic medication and disease with intraocular pressure. *JAMA Ophthalmol.* 2017;135(3):203-4.

This drug class is available as a solution (generic dorzolamide) and a suspension (Azopt [brinzolamide, Novartis]). Only Azopt and Simbrinza (Novartis) are glaucoma suspensions, which have to be shaken before instillation.

## COMBINATION DROPS

Many glaucoma patients are treated with multiple drops during the duration of their disease. Three combination drops are on the market: Cosopt (0.5% timolol with 0.2% dorzolamide, Akorn), Combigan (0.5% timolol with 0.2% brimonidine, Allergan) and Simbrinza (0.2% brimonidine with 1% brinzolamide suspension).

Simbrinza—the only suspension combination drug available to treat glaucoma—must be shaken before use. Unlike the other combination glaucoma drops, Simbrinza does not contain a beta-blocker. So, for an asthmatic patient or one who is nonresponsive to beta-blockers, Simbrinza might be an ideal add-on to a prostaglandin drug, once trials of brinzolamide and brimonidine are found to be efficacious.

If first-line therapy with a prostaglandin just misses target IOP, it is possible that switching to Vyzulta, or adding once-daily timolol, generic dorzolamide or generic brimonidine alone might get the IOP to target, so

employing a more expensive combination drug might not be necessary.

Cosopt is unique in that it is generically available as a bottled product and also as a brand-name-protected, preservative-free unit-dose product. The carbonic anhydrase inhibitors, which reduce IOP about 15% by suppressing aqueous production, are approved as TID-dosed products (similar to brimonidine), yet they are mainly used twice daily in general clinical care. Dorzolamide is an ophthalmic solution (original brand name Trusopt) and brinzolamide is an ophthalmic suspension (original brand name Azopt).

When we need to prescribe one, we dose the medication twice daily—in early morning and about eight hours later (as with brimonidine), since effectiveness wanes after about eight hours.

## FINAL THOUGHTS

We typically initiate glaucoma therapy with a prostaglandin, and add timolol 0.25% or 0.5% once daily (in the morning) if target IOP is not reached with the prostaglandin alone.

Glaucoma therapy with a beta-blocker is often reserved until we need a 5mm Hg to 6mm Hg reduction in IOP or when we believe that cost is a factor in patient compliance. A 5ml bottle of timolol is

widely available for under \$10. Be mindful that we have found that prostaglandins generally reduce intraocular pressure by about 30%, whereas nonselective beta-blockers reduce IOP by about 25%. That’s a separation of only about 1mm Hg to 3mm Hg. Do not lose sight of the fact that beta-blockers remain an excellent choice for reducing IOP.

Initial therapeutic interventions generally are not complicated. However, if the patient is a prostaglandin nonresponder or has active asthma, establishing a therapeutic plan becomes more like a chess game, involving considerable thought and trials until target IOP is achieved.

Glaucoma should be readily embraced by more optometric offices and clinics. While the disease remains a leading cause of blindness worldwide, blindness from glaucoma in developed countries is relatively uncommon. Optimal care necessitates appropriate ancillary testing when needed, treatment initiation when indicated and a close observation of the optic nerves at follow-up visits to prevent vision loss. As medical practitioners of the eye, it seems appropriate that we should be first-line providers for the majority of glaucoma patients. **DG**

1. Tham Y-C, Li X, Wong TY, et al. Global prevalence of glaucoma and projections of glaucoma burden through 2040. *Ophthalmology.* Nov 2014;121(11):2081-90.

2. U.S. Department of Health and Human Services Health Resources and Services Administration Bureau of Health Professions October 2006. Physician Supply

and Demand: Projections to 2020. Available at: <https://bhwa.hrsa.gov/sites/default/files/bhwa/nchwa/projections/physician2020projections.pdf> (last accessed March 29, 2018).

3. U.S. Department of Health and Human Services Health Resources and Services Administration Bureau of Health Professions December 2008. The Physician

Workforce: Projections and Research into Current Issues Affecting Supply and Demand. Available at: <https://bhwa.hrsa.gov/sites/default/files/bhwa/nchwa/projections/physiciansupplyissues.pdf> (last accessed March 29, 2018).

4. De Moraes CG. NTG: The Nocturnal Blood Pressure Factor. *Rev Ophthalmol.* 2014;24(2):54-57.

5. Mishra D, Sinha BP, Kumar MS, et al. Comparing the efficacy of latanoprost (0.005%), bimatoprost (0.03%), travoprost (0.004%), and timolol (0.5%) in the treatment of primary open angle glaucoma. *Korean J Ophthalmol.* 2014 Oct;28(5):399-407.

# ON THE RECORD ABOUT 'OFF-LABEL' THERAPY

The FDA indication is only a starting point for a drug's career, and often a poor one at that. We doctors determine the proper use of any drug based on the scientific literature.

**W**hat does “off-label” really mean? The answer: little or nothing. Allow us to explain.

It is outrageously expensive to get drugs approved for their true therapeutic intent, and the idea is to get the drug to market as quickly and as inexpensively as possible. So, pharma companies choose the easiest path to approval—not necessarily the one that best showcases the drug's capabilities. Once approved, doctors can and do find other uses and we, collectively, determine its proper role in the therapeutic toolbox.

It is indeed a game—a very high-stakes game—but it should not be this way. “Conjunctivitis” and “postoperative care” are two common targets for a new drug approval purely because they are the easiest to get through, even though these conditions may have nothing to do with the true clinical intent for the new drug.

Here are a few examples corroborating this candid perspective.

The early-generation fluoroquinolones were approved to treat conjunctivitis and keratitis. The fourth-generation fluoroquinolones and the bi-halogenated quinolone besifloxacin are FDA-approved only for treatment of conjunctivitis, but are commonly and effectively used “off-label” to treat bacterial keratitis.

Years ago, a drug known as Vexol (rimexolone, Novartis) was the only topical steroid FDA-approved for postoperative care, but it never gained intended traction. Interestingly, Pred Forte (prednisolone acetate 1%, Allergan), which is widely used for this purpose, does not have a specific indication for postoperative care.

Lotemax suspension (loteprednol etabonate 0.5%, Bausch + Lomb) has a litany of anti-inflammatory indications; however, the newer drug delivery system for loteprednol, known as Lotemax gel, is only FDA approved for postoperative care, as this was simply the easiest path to approval; however, it's the exact same molecule.

## QUOTABLE

**“We recall seeing a pediatrician a few years ago with acute epidemic keratoconjunctivitis. She was miserable and in full-panic mode. We explained to her that the Betadine treatment we would recommend was off-label. She laughed and said, ‘Ninety percent of what I do is off-label; let’s get on with it!’”**

Both alpha-agonists and topical carbonic anhydrase inhibitors are FDA-approved for three-times-a-day administration, yet they are most commonly used twice daily, which is an off-label use albeit reasonable and efficacious for most patients.

Oracea (doxycycline, Galderma Laboratories) is a relatively new prescription drug containing 30mg of standard doxycycline and 10mg of time-released doxycycline. This is the only FDA-approved drug to treat rosacea. Regular doxycycline is not specifically labeled for rosacea. These drugs are clinical equivalents, but the brand-name, on-label drug is very expensive, while standard doxycycline is relatively inexpensive. So, treating rosacea blepharitis with regular doxycycline is off-label; yet over the decades we have used it ad infinitum for this very purpose, as do legions of dermatologists.

Topamax (topiramate, Janssen Pharmaceuticals) has indications for the treatment of seizure disorders and the prevention of migraine headaches, yet it is heavily used to treat obesity, bipolar disorder and some forms of eating disorders, among others.

There is no FDA-approved drug for the treatment of acute adenoviral infection, yet, based on sound scientific rationale, we have successfully used off-label Betadine 5% (povidone-iodine ophthalmic solution, Novartis) numerous times

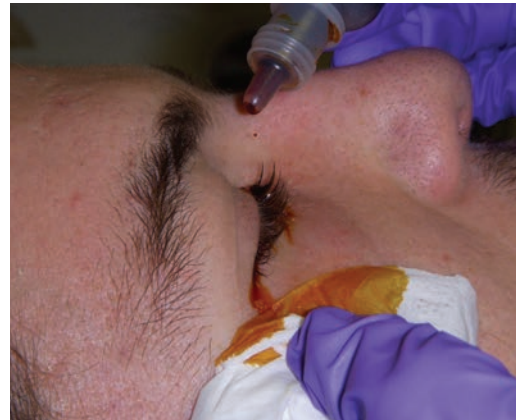over the years for this very purpose. We recall seeing a pediatrician a few years ago with acute epidemic keratoconjunctivitis. She was miserable and in full-panic mode. We explained to her that the Betadine treatment we would recommend was off-label. She laughed and said, "Ninety percent of what I do is off-label; let's get on with it!" This exemplifies the clinical virtue of off-label drug use. By the way, she was much better at her two-day follow-up visit, and was extremely appreciative of our help.

It should now be abundantly evident that off-label use of many medicines can render a significant therapeutic benefit to many patients. As stressed above, such off-label use needs to be underpinned by a scientific rationale, preferably discussed in the professional literature and should demonstrate an expected clinical outcome.

**PRUDENT AND EFFECTIVE OFF-LABEL USE**

Here are examples of intelligent, rational and patient-centric off-label uses of medications in eye care:

- Using an alpha-adrenergic receptor blocker, such as brimonidine 0.1%, 0.15% or 0.2%, or a topical carbonic anhydrase inhibitor, such as dorzolamide or brinzolamide,

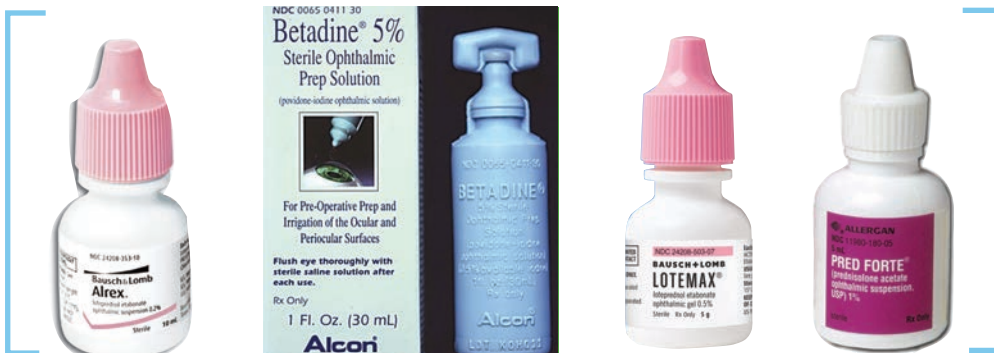

Betadine being administered to a patient.

twice daily instead of the FDA-approved TID.

- Using a fourth-generation fluoroquinolone or the bi-halogenated besifloxacin to treat a corneal ulcer when these medicines are only FDA-approved to treat bacterial conjunctivitis.
- Using Pred Forte in postoperative care, when it is not FDA-approved for such.
- Using Lotemax gel or ointment to treat dry eye disease, when its FDA-approved indication is for post-operative care. The literature consistently endorses a corticosteroid in the short term to treat dry eye disease, yet such is not FDA approved.
- Using Alrex to treat dry eye disease when its only FDA-approved indication is for treating ocular allergy.
- Betadine 5% sterile ophthalmic prep solution is intended to be used

to sterilize the ocular surface prior to surgery or intravitreal injection. However, its off-label use to treat epidemic keratoconjunctivitis is the only effective approach to quickly and inexpensively quell this virulent adenoviral affliction. Betadine for this purpose is especially





## THE GREATEST OFF-LABEL STORY EVER TOLD

The year was 2005. Genentech was prepping a new drug called Lucentis that looked to revolutionize treatment of the wet form of age-related macular degeneration (AMD) the following year. This would be the first time that eye doctors could bring back some vision that patients had lost to AMD. Everyone knew it would be a blockbuster. But then...

Bascom Palmer retina specialist Philip Rosenfeld, MD, published a study showing that the same company's drug Avastin, commonly used for the intravenous cancer therapy, could be reformulated into an intravitreal dose and used for AMD, with results comparable to Lucentis.<sup>1</sup> At a fraction of the cost: about \$50 vs. \$2,000. Lucentis did just fine in the marketplace—some MDs do prefer the on-label, factory-fresh Lucentis instead of working with a compounding pharmacy to obtain Avastin for ocular use. But Avastin was the revolution within the revolution.

A recent retrospective review of Medicare payments for anti-VEGF therapy in eye care documents the savings attributable to Avastin from 2008 to 2015 at \$17.3 billion.<sup>2</sup> That figure represents a \$13.8 billion savings to Medicare and a \$3.5 billion savings to patients, the article states. But the real number is even greater. "This amount underestimated the actual cost-savings to Medicare providers since approximately 30% of Medicare-eligible recipients received care within Medicare Advantage plans and were not included in this analysis," says the article. Also, since anti-VEGF drugs are used to treat more than just AMD, and Avastin has been used in eye care for 13 years while this study only looked at the years 2005 to 2013, surely the savings are even higher than the already eye-popping number of \$17 billion.

Now, think of who had to allow this. Retina subspecialist MDs, a very conservative group of clinicians, had to be comfortable with the idea of going outside the FDA system. Medicare had to allow this as a reimbursable expense. And in one high profile case, the Veterans Administration even condoned the use of Avastin, knowing how much money this could save, which they could then put to better use for America's vets.

Yes, it was a little risky, since it was an injectable drug. An outbreak of endophthalmitis due to poor sterilization methods at one compounding pharmacy did cause serious infections in a small number of patients. But the vast majority of patients treated with Avastin have been well served by their doctor's decision to do so.

Keep that story in mind the next time you reach for your Rx pad.

1. Rosenfeld, PJ, Moshfeghi, AA, Puliafito, CA. Optical coherence tomography findings after an intravitreal injection of bevacizumab (avastin) for neovascular age-related macular degeneration. *Ophthalmic Surg Lasers Imaging*. 2005;36:331-335.

2. Rosenfeld PJ, Windsor MA, Feuer WJ, et al. Estimating Medicare and patient savings from the use of bevacizumab for the treatment of exudative age-related macular degeneration. *Am J Ophthalmol* [ePub ahead of print.]

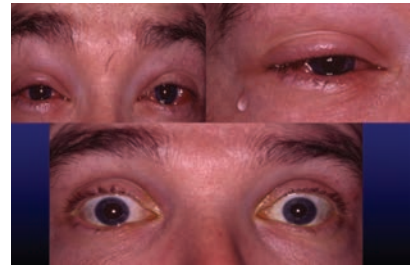
effective when the keratoconjunctivitis is caught in the early, actively replicative phase.

The bottom line: follow the peer-reviewed literature; use sound, rational, patient-centered judgment—and get on with it. Don't allow yourself to

be hampered by bureaucratic guidelines; rather, rely on community standards of care based on scientific rigor.

## WHAT THE EXPERTS SAY

The Alliance of Specialty Medicine released a position statement regard-



(Top) This male patient presented with classic EKC. (Bottom) Following our Betadine protocol, his condition was immensely improved in just three days.

ing off-label use of medical products, stating in part: "Physician-directed applications, also known as 'off-label uses,' are an integral component of the art and science of medical practice, particularly for specialty physicians."<sup>1</sup>

The Alliance of Specialty Medicine maintains that a specialty physician may prescribe or administer any legally marketed product for an off-label use within the authorized practice of medicine where the physician exercises appropriate medical judgment and it is in the best interests of the patient.

It says further that specialty physicians are limited as to what we can say in educational settings because of regulations surrounding teaching on off-label medicines, and that we must educate our colleagues the best we can within forums that allow us to discuss off-label usage.

*Our take:* Within the guidelines and perspectives set forth above, we simply want our optometric colleagues to feel completely comfortable doing what is best to serve patients with FDA-approved medicines using the most effective drugs available. **DG**

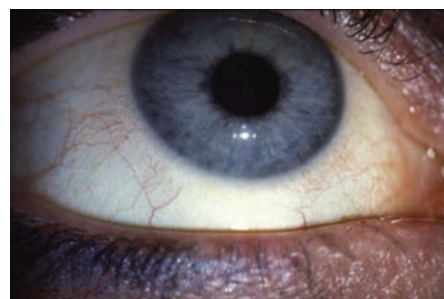1. Physician-Directed Applications: A Position Statement of the Alliance of Specialty Medicine. Available at: [www.specialtydocs.org/files/Alliance\\_Off-label\\_Statement\\_5.2.14.pdf](http://www.specialtydocs.org/files/Alliance_Off-label_Statement_5.2.14.pdf) (last accessed February 27, 2017).

# A SYSTEMATIC APPROACH TO DRY EYE DISEASE

A wealth of hands-on clinical experience and the latest wisdom from the literature are changing the way we think about, and treat, this all-too-common condition.

For many decades after dry eye was first named in the 1950s, the focus of diagnosis and treatment remained on the aqueous component of the tears produced by the lacrimal glands. This initially made sense because dry eye was first identified in a group of Sjögren’s patients. However, as far back as 1977, McCulley and Sciallis published findings of dry eye in a group with no evidence of lacrimal dysfunction.<sup>1</sup> These patients presented with reduced tear film breakup time, superficial punctate keratitis, symptoms of dryness and stagnated meibomian secretions. McCulley and Sciallis named this condition meibomian dysfunction.

Their discovery is what we now know as meibomian gland dysfunction (MGD). McCulley and Sciallis also showed that if

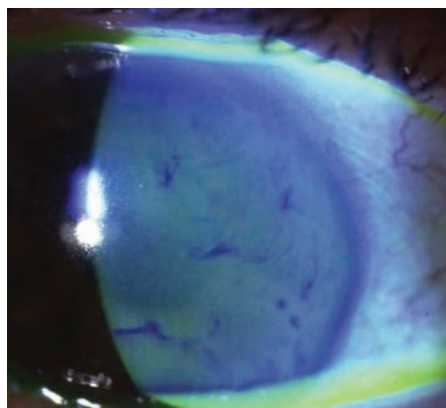


Note that this patient has a scant lacrimal lake volume.

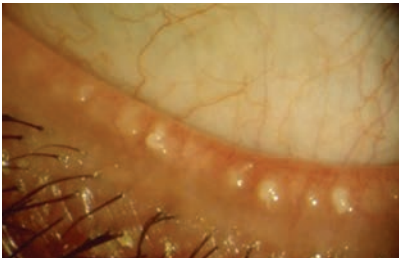
one squeezed out the meibomian gland contents, the tear film normalized and patient symptoms improved significantly. Despite this study and the hundreds that followed, all of which repeatedly evidenced that healthy meibomian gland physiology was critical to the health of the ocular surface, it took until 2011 for the scientific community to conclude that MGD was the leading cause of dry eye.<sup>2</sup>

Today, we use meibography to stage the degree of meibomian gland atrophy and make a critical diagnostic assessment. We believe the diagnostic tools LipiView and LipiScan—a combination system from TearScience, now part of Johnson & Johnson Vision—represents the pinnacle of managing and preventing dry eye disease secondary to MGD. In addition, the company’s Meibomian Gland Evaluator can help assess gland secretions during a slit lamp exam and its LipiFlow device aids in restoring function to obstructed glands.

Though TearScience has led the charge



Corneal break up with fluorescein dye is useful in quantifying the expression of tear film integrity.



**Clogged meibomian gland orifices restrict lipid secretion and lead to evaporative dry eye.**

in developing technology for MGD, other methods of assessing gland structure are available. Some topographers have meibography capabilities, and a white light transilluminator is available if you do not have access to imaging technology. And, of course, since many patients present to us at an advanced, symptomatic level of ocular surface disease, precorneal tear film breakup time and vital dye staining further quantify the extent of tissue compromise.

Unsurprisingly, we have found that about 90% of dry eye is related to MGD, and that up to 70% of our clinical population has MGD. We hypothesize that the following reasons are why MGD is so prevalent: poor blink function due to unrelenting use of digital technology, poor dietary hygiene and behaviors that actively stress the tear film, e.g., contact lens wear, cataract and refractive surgeries, and chronic use of preserved topical eye drops. Fortunately, lifestyle and blinking patterns can be addressed with education. For patients who wear contact lenses, need to undergo surgery or use preserved topical medications daily, the meibomian glands can be routinely assessed and treated as needed.

### **TREATING DRY EYE: AS EASY AS 1-2-3**

There are three somewhat fluid stages of intervention we can use to prevent the escalation of dry eye disease, each discussed in detail below.

### **PERSPECTIVE ON DRY EYE TESTING**

We share the sentiments expressed in this editorial piece from 2017 about diagnostic approaches to dry eye.<sup>1</sup> While it may not come from the peer-reviewed literature, its practical insights ring true to our ears, as busy clinicians who feel comfortable diagnosing dry eye without the need for additional testing.

- “None of the currently available methods for testing—Schirmer’s, validated questionnaires, tear osmolarity, tear breakup time, Sjô, MMP-9—are definitive.”
- “Having a numeric value to attach to dry eye became less useful when the generated number did not support the patient’s experience or exam.”
- “It was challenging trying to explain treatment plans to my patients in part based on numbers that did not make sense.”
- “...reimbursements for dry eye testing, which admittedly can vary wildly between insurance plans and geographic regions, were regularly less than the cost of the test.”
- “In the end, I base my treatment decisions on the patients’ symptoms and on a thorough slit lamp exam with staining.”
- “The best use of our patients’ resources is to give them an accurate diagnosis and a treatment that will make a noticeable difference in their dry eye disease.”
- “There is no value in spending money on a battery of tests that tell patients what they (and you) likely already know—that they have dry eyes—instead of on something that could help them mitigate or cure the problem.”
- “My patients are happier because they are using their money to address the problem, not just test it to death.”

The bottom line is this: When the tear film and eyelids fail to protect the ocular surface from exposure to desiccating stress, a cascade of events is triggered. If the exposure to desiccating stress becomes chronic, the ocular surface commonly exhibits signs and symptoms of dry eye. These are variable and frequently manifest independently, especially in the earlier stages of dry eye disease. Short-term management may involve lipid tear supplements and suppression of inflammation with loteprednol, but long-term rehabilitation requires that the eyelid function (primarily and including meibomian gland function) and patient behavior be optimized to reduce exposure to desiccating stress.

1. Toyos M. Dry Eye: Emphasis on treatment, not testing. *Ocular Surgery News*. 2017; Feb 25.

Engaging these diverse approaches can be highly variable, depending on the decade of patient presentation as well as the degree of disease severity.

The rationale behind this three-tiered approach is that we find that most patients present when their dry eye disease has advanced to the degree that several of these staged interventions may be required to help re-establish comfort and enhanced quality of life. Oftentimes, we, as clinicians, are forced to engage in tertiary care first to quiet the ocular

surface and then work back up the continuum of interventions.

The key to patient care is to understand the pathophysiology of dry eye disease so that appropriate steps can be taken, either concurrently or sequentially, to care for the patient. Let’s take a closer look at these staged interventions.

### **PRIMARY INTERVENTIONS**

Start with these, as they tend to be the easiest, cheapest and most broadly applicable.

COMMONLY USED LIPID-BASED ARTIFICIAL TEARS

Brand Name	Manufacturer	Lipid	Lubricants	Preservative
Refresh Optive Advanced	Allergan	castor oil	carboxymethylcellulose, glycerin, polysorbate 80	Purite (stabilized oxychloro complex)
Refresh Optive Advanced Preservative Free	Allergan	castor oil	carboxymethylcellulose, glycerin, polysorbate 80	none
Retaine MGD	OcuSoft	glycerol	light mineral oil, mineral oil	none
Soothe XP	Bausch + Lomb	light mineral oil, mineral oil	polysorbate 80	polyquaternium-1
Systane Balance	Alcon	mineral oil	propylene glycol	polyquaternium-1

**Blink function.** Educating patients about the importance of blinking is critical and easy to accomplish. Apps are available that teach proper blinking exercises, and we encourage our dry eye patients to avail themselves of these. For example, Donald Korb Blink Training can be downloaded for free from iTunes or Google Play. We also proactively share this education with patients at risk of meibomian gland disease (e.g., computer users, contact lens wearers, patients using preserved topical medications daily and those preparing for cataract and refractive surgeries).

Our guidance is for patients to perform these blinking exercises four times daily—at breakfast, lunch,

dinner and bedtime, as this simple maneuver helps many individuals. We recommend the orbicularis squeeze for five seconds, with a brief break before repeating the cycle for a full minute. One respected colleague shared anecdotally that having patients set hourly alarms on their smartphone or smartwatch during the work day to remind them to stop and do blink exercises is as effective as using an app.

**Oral supplementation.** While the eye care community has historically espoused omega-3 supplementation to help with dry eye disease, there



has been little Level 1 evidence to solidly support this intervention. Now, with the publication of the DREAM Study, published in the April 13

FROM THE LITERATURE

JAMA PERSPECTIVE ON RESTASIS

An interesting editorial was published in the January 2018 issue of the *Journal of the American Medical Association - Internal Medicine* about Restasis (cyclosporine ophthalmic emulsion, 0.05%, Allergan).<sup>1</sup> The following are excerpts from the paper written by the Dartmouth Institute for Health Policy and Clinical Practice-based authors:

- In addition to a court battle over efforts to halt generic versions of Restasis, “the more fundamental question has received little attention: Does Restasis work? Restasis is not approved in the European Union, Australia or New Zealand, where in 2001, registration applications were ‘withdrawn prior to approval due to insufficient evidence of efficacy.’ Although Canada approved Restasis, its national technology assessment unit, unconvinced of meaningful benefit, recommended Canada not pay for it.”
- “Given the scant evidence of efficacy, why does Restasis

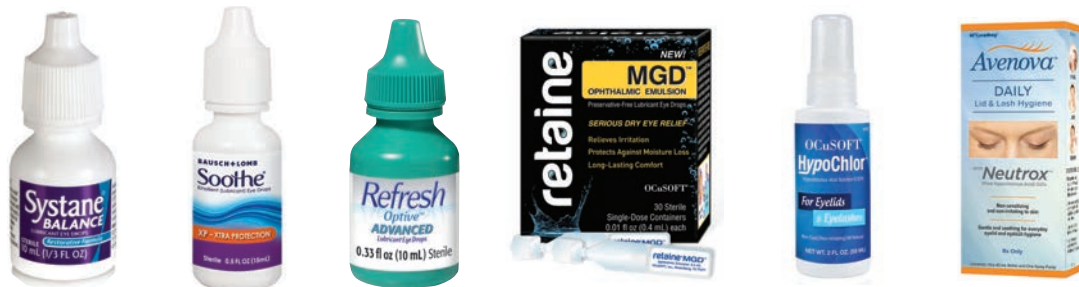have more than \$2 billion in annual sales in the United States?”

- “Clinicians typically do not learn about new products from regulatory documents; they learn from commercially sponsored, promotional efforts, such as detailing visits and events where food and beverages are provided.”

Every drug has the ability to help some people, and we have patients who have indeed been helped with Restasis; we have plenty more for whom no help was obtained. The three drugs in common use to treat ocular surface inflammation are Lotemax, Restasis and Xiidra. One of these drugs much more robustly reduces inflammation than the others. The scientific literature consistently endorses the short-term use of a steroid to address the inflammation associated with dry eye disease. Our own clinical experiences match what the science tells us, which is why we favor the use of loteprednol for most cases.

1. Schwartz LM, Woloshin S. A clear-eyed view of restasis and chronic dry eye disease. *JAMA Intern Med.* 2018;178(2):181-2.





online edition of the *New England Journal of Medicine*, we have (for better or worse) authoritative Level 1 science showing little or no evidence of a clinically meaningful effect of 3,000mg of a triglyceride-based fish oil.<sup>3</sup>

However, since the study's recent publication, a number of prominent ophthalmologists specializing in dry eye, some of whom have lead research showing the benefits of omega-3 supplementation, have raised concerns about the methodology of the study and the choice of a potentially active placebo.

They have noted, among other issues, that the manufacturer of the active dry eye therapy was not disclosed in the study, that study participants were permitted to use a wide variety of dry eye therapies concurrently and change therapies during the study, and that it's not known whether re-esterified forms of omega-3 therapies were used, which many dry eye experts have pointed out is essential for maximum absorption and bioavailability.

Critics have also expressed reservations that the controls received olive oil with fish essence, which are known anti-inflammatories and which may have included an active ingredient, given the improvements observed in controls. Yet, we were able to uncover that the olive oil was 68% oleic acid, an omega-9 fatty

acid considered to be neutral with respect to inflammation control. And, though the study olive oil had a small amount of alpha-linolenic acid (ALA), a plant-based omega-3, the total dose was 30mg, while our recommended omega-3 dosage of EPA and DHA for patients is 3,000mg, or about 1,000 times that delivered by the placebo. Furthermore, ALA conversion to EPA and DHA is not known to be efficient.

Dry eye experts have also pointed out that both groups in the study had statistically significant improvements in OSDI symptom scores, which somewhat contradicts early press reports indicating that the study found omega-3 supplementation failed to yield a beneficial response.

Whether we are at the end of an era in which such supplementary intervention has a significant role in the care of patients with dry eye disease remains to be seen. We would

like to see another study replicating these findings before we would be fully comfortable abandoning a therapeutic intervention that for many years has appeared to work. A discussion of the report can be read on our website: [www.eyupdate.com](http://www.eyupdate.com).

Moving on to orally administered doxycycline, at 50mg per day for three to four months, this drug has been shown to enhance meibomian gland function. Thus, for those patients with more ad-



## LIPIFLOW TREATMENT FOR CONTACT LENS WEARERS

Thermal pulsation of the eyelids could be a major benefit to thousands of patients struggling with contact lens comfort. A study in *Clinical Ophthalmology* found that a single LipiFlow treatment extended contact lens wearing time by four hours, with the benefit lasting for an average of three months.<sup>1</sup>

1. Blackie CA, Coleman CA, Nichols KK, et al. A single vectored thermal pulsation treatment for meibomian gland dysfunction increases mean comfortable contact lens wearing time by approximately 4 hours per day. *Clin Ophthalmol*. 2018;12:169-183.

vanced meibomian gland disease, especially when accompanied by rosacea blepharitis, a four-month course of oral doxycycline can help jumpstart the clinical response.

It is important to instruct patients to take doxycycline with food, preferably at breakfast or lunch, as some people develop gastroesophageal reflux with this therapy, which can result in erosive esophagitis when they lie down. (This is why we try to avoid evening dosing of doxycycline.) After three to four months of doxycycline therapy, enduring periodic use of warm soaks hopefully will maintain an enhanced lipid layer.

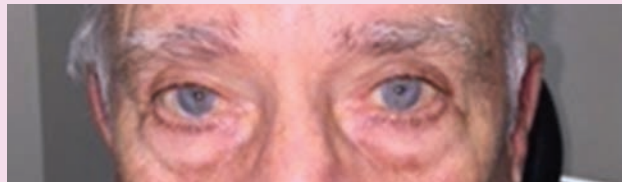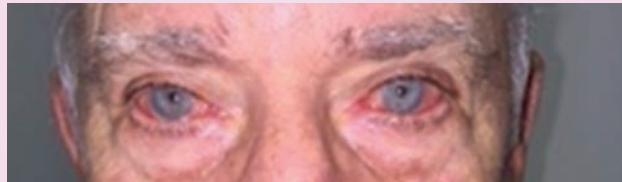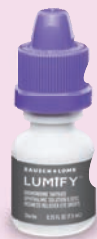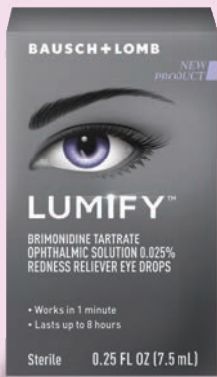**Screen usage recommendations.** Excessive screen use, either by choice or necessity, has become a way of life. Thus, educating patients on the impact of digital media use is essential. When patients understand why an activity isn't healthy, they are more apt to engage in behaviors to

## A NEW TREATMENT FOR CHRONIC RED EYE

It is widely known that millions of people purchase over-the-counter “get the red out” eye drops every year. Most of these purchases are made by individuals suffering from dry eyes, chronic allergy, blepharitis and/or exposure to smoke (e.g., tobacco, marijuana). Though tetrahydrozoline-containing eye drops have been shown to whiten eyes, they must be used chronically, which typically leads to the development of protracted and rebound hyperemia.

Now, a newly approved venule-based vascular constrictor should quickly replace tetrahydrozoline over time. This over-the-counter drop, Lumify (brimonidine tartrate ophthalmic solution 0.025%, Bausch + Lomb), is a revolutionary agent that quickly “whitens” eyes, with effects lasting several hours and without reports of rebound hyperemia.

This low-dose brimonidine is a 0.025% solution with approximately a 10-fold dilution of 0.2% brimonidine. Our impression is that people with idiopathic, untreated or undertreated secondary chronic redness might use Lumify once daily in the morning, primarily on the days when their eyes are



Here, in just 20 seconds, this patient's eyes appear whiter.

noticeably red. Since the drop, which could be used again in the afternoon or evening if needed, is not by prescription, it is our job to make patients aware of this newer-generation, more effective and longer-lasting topical vasoconstrictor.

We would never recommend such a medication as first-line therapy since redness is a secondary result of a primary problem such as dry eyes. Always try to remedy any primary conditions first, and, if other rational therapies do not relieve the redness, Lumify should be called in to handle the job.

mitigate the negative effects. We proactively tell our intensive screen users to consciously and purposefully look up and away from the screen every few minutes and to blink several times.

**Avoiding desiccating stress.** Encourage patients to minimize exposure to ceiling fans, forced air drafts from home or car heating and air-conditioning systems. Patients can also minimize low-humidity environments by using a humidifier whenever possible.

**Application of warm soaks.** Applying warm soaks using a clean washcloth, uncooked white rice in a stocking (warmed in the microwave) or a commercially available device such as a Bruder mask, can

be beneficial to enhance meibomian gland function. Patients frequently tell us that their eyes feel better following such use. The limiting factor is that patients rarely make time to use warm soaks consistently.

**Moisture-preserving eyewear.** Dry eye does not exist in 100% humidity, so anything one can do to increase the ambient humidity of the ocular surface is a step in the right direction. Moisture “goggles” have vastly improved over



Moisture-preserving eyeglasses can be a helpful intervention for highly symptomatic dry eye disease.

the years and offer us another methodology to preserve, protect and enhance ocular surface health.

While they might not make much of a fashion statement, they are much more visually acceptable now than they were years ago. Ziena Eyewear and 7eye by Panoptx feature contemporary, moisture-preserving eyeglass designs on their websites for your review and analysis.

## SECONDARY INTERVENTIONS

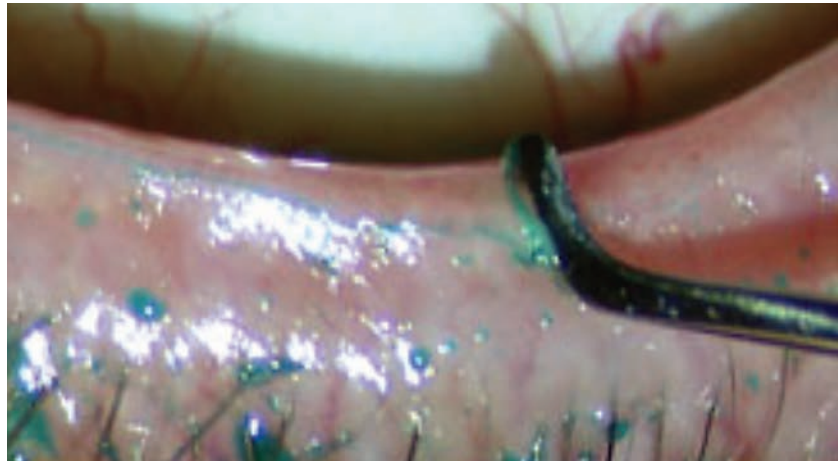Options in this class tend to be more focused on addressing a specific component of dry eye pathogenesis, such as reduced tear volume or meibomian gland obstruction.

*Lipid-based artificial tears and lubricating ointments.* Since a healthy lipid layer is critical in most all cases of dry eye disease, we start nearly all of our patients on a lipid-based artificial tear. We generally recommend either Soothe XP (Bausch + Lomb) or Systane Balance (Alcon), as both drugs were invented by Donald Korb, OD, a world-recognized expert in the area of MGD. When we need a preservative-free product, we recommend OcuSoft's Retaine MGD. Patients are generally encouraged to use artificial tears at least four times a day, although patients rarely use them as often as recommended.

A study published in the *Journal of Pharmacology and Therapeutics* reported the following:<sup>4</sup>

- "Lipid based therapies [...] are an attractive alternative to water-based artificial tears because they more closely mimic the composition of the tear film. Lipid-based therapies not only relieve patient symptoms immediately after topical administration, but may also directly improve the lipid tear film structure and thickness component in ocular surface disease, resulting in enhanced tear film stability."

- "Oil-in-water emulsions reduce the signs and symptoms of all types of dry eye, but are particularly recommended for lipid-deficient dry eye patients."



To debride the lower lid margin, we gently wipe a golf club spud repeatedly across the margin to remove debris.

- "The favorable tolerability profile and efficacy of lipid-based therapies in improving both signs and symptoms of dry eye make them a promising therapeutic option in the management of DED."

*Meibomian gland expression.* Physical/mechanical evacuation of the meibomian glands is essential. This can be done effectively only in the office. Perform manual glandular expression the old-fashioned way, using the Mastrota Meibomian Paddle (OcuSoft), the butt end of a pair of jewelers' forceps or even a cotton swab to enable adequate trans-eyelid pressure.

If expression is attempted by pressing on the lids with the globe as a backstop, sufficient pressure cannot be applied and the IOP might become pathologically high. Some advocate for heating the lids prior to expressing the glands, possibly to make the expression process a little easier. However, there are two limitations to this process: the meibomian glands cannot be adequately heated from the outside since the meibomian glands reside in the posterior portion of the eyelids, and the highly vascularized nature of the tissue in this area means that, once the heat source is removed, the tissue

rapidly returns to body temperature, negating the effect.

The gold standard for performing this highly therapeutic maneuver is the LipiFlow, which heats the meibomian glands from the tarsal conjunctival side (as opposed to the epidermal side) of the eyelid, while protecting the cornea. LipiFlow is cleared by the FDA for the safe and effective direct treatment of meibomian gland disease by addressing obstruction.

Another unique aspect of the device is that during the 12 minutes of highly specific heating, a compressive function simultaneously mechanically expresses the glandular contents. As a result, the newly formed meibum mimics natural physiology, resulting in a healthier lipid layer and enhanced tear film function. Another device, the MiBo ThermoFlo (MiBo Medical Group), delivers emissive heat to the meibomian glands.

*Debridement of lower lid margins.* It is well-established that meibomian gland obstruction is a weak link in the chain of lipid production, excretion and incorporation into the tear film. Thus, anything that enhances this process is virtuous. One effective and simple procedure that can be performed at the slit lamp is to take a



golf club spud and gently scrape back and forth, four or five times, along the top of the lower eyelids. We do this at each follow-up visit.

The procedure helps to open/de-obstruct the meibomian gland orifices and smooth the surface of the lower eyelids—particularly if there is any debris on the mucocutaneous border—and enhance the backward flow of meibum into the tear film. A topical anesthetic is not necessary for this effective 15-second procedure, which currently has no CPT code. Since meibomian gland expression devices are not yet ubiquitous due to cost, many clinicians will need to perform in-office expression, enhanced by pre-expression warm soaks.

**Consider intranasal stimulation.** With this new approach, a handheld intranasally inserted device uses electrical impulses to stimulate the trigeminal nerve and tear production. This procedure may be helpful to select patients, but as of press time, we had no clinical experience with this technique.

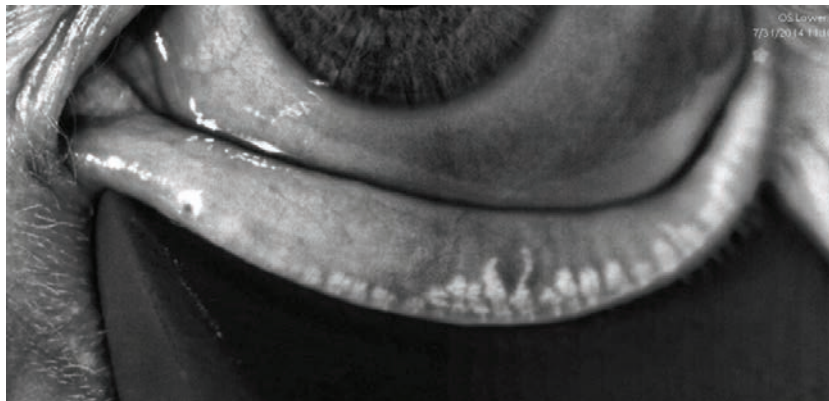### TERTIARY INTERVENTIONS

These options will be among the most effective in reducing dry eye symptoms and may require greater skill by the clinician to perform.

**Topical anti-inflammatory drops.** As previously mentioned, untreated MGD invariably leads to a cascade of events resulting in ocular surface inflammation. The most efficacious, and least expensive, intervention to suppress ocular surface inflammation is through the use of a topical corticosteroid.

Because the ester-based steroid loteprednol has become our drug of choice in such settings, we prescribe Lotemax gel-drops QID for two weeks, then BID for two more weeks. Our clinical experience reveals that the inflammatory component of dry eye disease is controlled within about four weeks for most patients.

A subset of patients may need to



This patient's lid, imaged with meibography technology, displays severe meibomian gland dysfunction.

“pulse-dose” Lotemax QID for a week, once or twice a year, should there be any breakthrough symptom recurrence. A smaller subset of patients may require once-daily Lotemax on an ongoing basis.

As patient-centric doctors, we always attempt to use the least amount of cost-valued medicine possible to meet the care needs of our patients. We have found that Lotemax gel drops are vastly less expensive than any of the BID prescription “dry eye” drops and have far superior anti-inflammatory properties.

One of the key benefits of short-term pulse-dosing of a topical corticosteroid is its ability to induce long-term cessation of DED. As an example, the TFOS DEWS II Management and Therapy Report reported the following:<sup>5</sup>

“Fifty-three patients with Sjögren syndrome were treated with topical nonpreserved 1% methylprednisolone four times a day for two weeks, and then re-evaluated and tapered off the medication until they demonstrated no corneal fluorescein staining or symptoms. Most patients were in a disease-free state for a relatively long period (57 weeks) after the first pulse therapy, and eleven individuals (21%) experienced recurrence of either symptoms or signs. After the second pulse therapy, a disease-free period of 72 weeks was observed

and only 1.9% of patients had recurrence. No serious complications (such as IOP elevation or cataract formation) were encountered during the entire follow-up period.”

Furthermore: “A recent retrospective safety study, listing 77 published studies, concluded that topical treatment with loteprednol etabonate has minimal effect on IOP when used in treatment of a wide range of ocular surface and intraocular inflammatory disorders, including ocular allergy, DED, anterior uveitis, penetrating keratoplasty, endothelial keratoplasty, and post-operative pain and inflammation following ocular surgery.”

What more could a clinician ask for?

**Punctal plugs.** Once loteprednol has been used for at least two weeks, the bulk of ocular surface inflammation usually has been suppressed. At this juncture, consideration of punctal occlusion is quite reasonable. It is important to use a steroid first, as the “plug first and steroid second” treatment regimen could actually worsen symptoms by further concentrating proinflammatory cytokines in the already hyperosmotic tear film.

**Autologous serum.** The concept of using a patient's blood-derived serum for topical drop application is not new. While a somewhat cum-



bersome process, use of autologous serum is a reasonable approach for patients suboptimally helped with other more common interventions. The drops may need to be used QID for many weeks; however, they are not to be used as simple monotherapy. Autologous serum drops are best used to supplement more comprehensive care.

**Lacrisert.** These dissolvable pellets of hydroxypropyl cellulose can provide a time-released supplemental enhancement to the tear volume. Because of their somewhat challenging insertion and cost, they are not used first-line, but some of our patients have been helped by Lacrisert more than any other intervention. Go to [www.lacrisert.com](http://www.lacrisert.com) for more details on this prescription hydration device.

**Amniotic membrane devices.** These devices can be remarkably beneficial for non-healing epithelial defects, including recalcitrant SPK. It takes some practice to insert the devices, requiring a technique similar to large-diameter contact lenses. Amniotic membranes dissolve over several days to a couple of weeks, and can play a beneficial role in resolving stubborn SPK.

**Scleral rigid contact lenses.** While these lenses have a learning curve to

## WHY SYMPTOMS AND SIGNS DON'T ALWAYS AGREE

Why is there discordance between symptoms and signs in patients with dry eye disease?

- There is “growing evidence that part of the dry eye population may show signs of dysfunctional somatosensory pathways, indicating neuropathic ocular pain.”
- Patients with chronic pain syndromes (CPSs) had 30% greater symptoms than signs. Important CPSs are irritable bowel syndrome, fibromyalgia, chronic pelvic pain and osteoarthritis.
- Many patients with itchy eyes also have dry eyes. “Patients with atopy or allergy have a sensitized ocular surface because of inflammatory processes influencing corneal nerves, which can lead to symptoms of dry eye even when the homeostasis of the ocular surface is minimally compromised.”

Vehof J, Sillevs Smitt-Kamminga N, Nibourg SA, Hammond CJ. Predictors of discordance between symptoms and signs in dry eye disease. *Ophthalmology*. 2017 Mar;124(3):280-286.

## PRIORITIZE THE MEIBOMIAN GLANDS

Because there are so many dry patients out there, there's no one template that works for everyone. However, if patients consistently use omega-3 supplements and lipid-based artificial tears, and periodically apply effective warm soaks to the eyelids, most will do quite well. The response to these therapeutic approaches is greatly enhanced if LipiFlow treatments are done initially and repeated every year or so as needed.

A portion of dry eye patients will have breakthrough of initial

Most dry eye patients are successfully managed using a variety of primary, secondary and tertiary interventions. The key is to focus on meibomian gland function enhancement, since many tertiary care maneuvers can be preempted or decreased in frequency.

Symptomatic eye disease is epidemic and will only become more prevalent in our screen-addicted world. It's our duty to arm ourselves with the knowledge, instrumentation and drug therapies to meet this clinical challenge.

Lastly, remember to assess each patient as an individual, since no algorithm can uniformly meet the needs of everyone. Bottom line: if we can adequately enhance meibomian gland function, we may not have to wait until patients present with dry eye discomfort to intervene. **DG**

1. McCulley JP, Sciallis GF. Meibomian keratoconjunctivitis. *Am J Ophthalmol*. 1977;84(6):788-93.

2. Schaumberg DA, Nichols JJ, Papas EB, et al. The international workshop on meibomian gland dysfunction: Report of the subcommittee on the epidemiology of, and associated risk factors for, MGD. *Invest Ophthalmol Vis Sci*. 2011 Mar; 52(4):1994-2005.

3. Dry Eye Assessment and Management Study Research Group. n-3 Fatty Acid Supplementation for the Treatment of Dry Eye Disease. *N Engl J Med*. 2018; Apr 13. [Epub ahead of print].

4. Garrigue JS, Amrane M, Faure MO, et al. Relevance of lipid-based products in the management of dry eye disease. *J Ocul Pharmacol Ther*. 2017 Nov;33(9):647-61.

5. Jones L, Downie LE, Korb D, et al. TFOS DEWS II Management and Therapy Report. *The Ocular Surface*. 2017;15(3):575-628.

### QUOTABLE

**“MOST DRY EYE PATIENTS ARE SUCCESSFULLY MANAGED USING A VARIETY OF PRIMARY, SECONDARY AND TERTIARY INTERVENTIONS. THE KEY IS TO FOCUS ON MEIBOMIAN GLAND FUNCTION ENHANCEMENT, SINCE MANY TERTIARY CARE MANEUVERS CAN BE PREEMPTED OR DECREASED IN FREQUENCY.”**

properly fit, they can be a lifesaver, as many patients have been helped by these devices when other approaches have failed. As such, we encourage all ODs to become adept at providing care with these lenses.

symptoms from time to time. This is when we employ pulse-dosing of Lotemax gel-drops QID for one week—a highly effective, safe and inexpensive approach to providing symptomatic relief.

# HARNESS THE POWER OF CORTICOSTEROIDS

Prudent use of these versatile, FDA-approved drugs to bring ocular inflammation under control continues to be constrained by unwarranted apprehension. Here's our tried and true approach.

The eye is vulnerable to damage from intraocular and ocular surface inflammation. Untreated, inflammation may lead to temporary, or even permanent, vision loss. Steroids suppress cellular infiltration, collagen deposition, fibroblast proliferation and scar formation. They stabilize cell membranes and block phospholipase A2—a critical initial step in the inflammatory cascade of the arachidonic acid pathway.

Topical corticosteroids derive from two different molecular classes: ketones and esters. Ketone-based steroids (e.g., dexamethasone, prednisolone, fluorometholone) have a higher propensity over time for unwanted side effects compared with ester-based steroids (e.g., loteprednol). Our bodies have limited means to actively degrade the ketone molecules, whereas esters are rapidly broken down by innate physiological esterases into inert substances shortly after providing effective anti-inflammatory action. Loteprednol has been shown to greatly lower the risk for increased intraocular pressure, with no reports of cataract formation. For either category, the risks associated with short-term topical use are minimal.

Remember: Suppressing ocular inflammation early in the disease process substantially decreases the potential for tissue damage. Uncontrolled intraocular inflammation carries far more risks than appropriate steroid therapy.

**T**he next time you encounter an acute red eye, consider the following statistic: Up to 80% of conjunctivitis cases are viral in nature.<sup>1</sup> Ocular infections cause secondary conjunctival inflammation. Doctors who solely prescribe antibiotics for acute red eyes are not keeping up with widespread research that refutes this antiquated practice. Antibiotics treat bacterial infections. Prescribing them for viral infections not only contributes to a greater antibiotic resistance profile for the patient, it also provides no benefit to the majority of patients with acute red eyes.

The irrational hesitation to prescribe corticosteroids may stem from clinical uncertainty on the part of the prescriber. For the inexperienced clinician, segregat-

ing various presentations of conjunctivitis (viral, allergic, nonspecific or bacterial) can be maddening. And bolstered by the knowledge that conjunctivitis is usually self-limiting and the notion that antibiotics are safe due to their limited side effects, antibiotics continue to be erroneously prescribed by wary physicians.

Unfortunately, this mindset can delay best practice patterns and do more harm than good, as inflammation does not go into clinical remission with antibiotics alone. Thus, in the setting of acute red eyes, we strongly advocate for the aggressive use of topical ophthalmic steroids, either as monotherapy or in combination with an antibiotic. At the same time, make sure to rule out herpetic etiology—the main contraindication to topical steroids.

### PAVLOV'S "RED EYE"

Ivan Pavlov is iconic in clinical psychology for his theory on classical conditioning, demonstrated by presenting a stimulus (food) to a dog and eliciting a predictable response (salivation). Let's translate this model to our clinics: The next time a familiar stimulus (acute red eye) ends up in your chair, take your initial evaluation (inflammation to be treated with a corticosteroid or antibiotic/steroid combination), and instead of trying to establish the necessity of a corticosteroid, present the reasons *not* to use one. This will enhance good patient care.

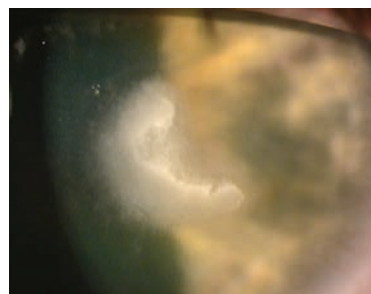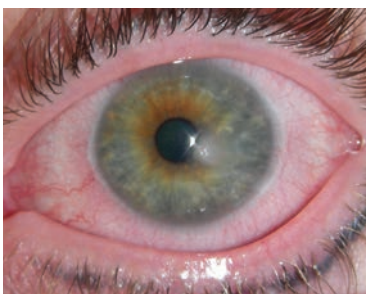If all of eye care would collectively adapt the mindset whereby a common presentation elicits a warranted therapeutic approach, it would condition our thought patterns to how acute conjunctivitis should be treated and exercise best practices in the process.

To be clear, improper use of steroids (and contact lenses) can have unwanted and damaging results for your patient. While there are plenty of indications for the use of topical steroids, there is only one contraindication: epithelial herpetic infection. There is also only one precaution:

### UPDATE ON FUNGAL KERATITIS

Thankfully, fungal keratitis is a rare occurrence in temperate climates.<sup>1</sup> However, we need to be at the ready when patients present with this dreadful condition. Most eye doctors ask the cornea subspecialist to care for these patients, but all eye doctors need to know the most up-to-date medicines to address such clinical challenges. It is well-known that natamycin (Natacyn, Novartis) has been the gold standard for treatment of fungal keratitis for decades.<sup>2</sup> Some individuals speculated whether the newer voriconazole might supersede the efficacy of natamycin; however, recent studies have firmly concluded that natamycin continues to be the drug of choice for treating most all cases of fungal infection.<sup>2</sup>

1. Nielsen E, Heegaard S, Prause JU, et al. Fungal Keratitis – Improving Diagnostics by Confocal Microscopy. *Case Rep Ophthalmol.* 2013 Sep-Dec 4(3):303-10.
2. Austin A, Lietman T, Rose-Nussbaumer J. Update on the Management of Infectious Keratitis. *Ophthalmology.* 2017 Nov;124(11):1678-89.



**Fusarium corneal ulcer. Note the feathery edges in a minimally injected eye.**

uncertainty of diagnosis. To explain, it's possible, for example, to have an *Acanthamoeba* or fungal keratitis that is difficult to diagnose, especially in the early stages. The use of a steroid—even a combination antibiotic/steroid—could cause the condition to worsen; however, such presentations

are exceedingly rare.

When prescribing steroids, the initial dosage must be sufficiently frequent to achieve symptomatic relief and expedite remission. In our practices, we suppress inflammation by “hammering” it with corticosteroids out of the gate. This approach

### TOPICAL CORTICOSTEROID DRUGS

BRAND NAME	GENERIC NAME	MANUFACTURER	PREPARATION	BOTTLE/TUBE
<b>Maximum Strength Steroids</b>				
Durezol	difluprednate 0.05%	Alcon	emulsion	5ml
Lotemax gel	loteprednol etabonate 0.5%	Bausch + Lomb	gel drops	5g
Lotemax ointment	loteprednol etabonate 0.5%	Bausch + Lomb	ointment	3.5g
Pred Forte	prednisolone acetate 1%	Allergan and generic	suspension	5ml, 10ml, 15ml
generic prednisolone sodium phosphate	prednisolone sodium phosphate 1%	generic	solution	5ml, 10ml, 15ml
Maxidex	dexamethasone 0.1%	Novartis	suspension	5ml
Vexol	rimexolone 1%	Novartis	suspension	5ml, 10ml
<b>Moderate and Lesser Strength Steroids</b>				
Alex	loteprednol etabonate 0.2%	Bausch + Lomb	suspension	5ml, 10ml
Flarex	fluorometholone acetate 0.1%	Novartis	suspension	5ml, 10ml
FML	fluorometholone alcohol 0.1%	Allergan and generic	suspension	5ml, 10ml, 15ml
FML ointment	fluorometholone alcohol 0.1%	Allergan	ointment	3.5g
Pred Mild	prednisolone acetate 0.12%	Allergan	suspension	5ml, 10ml

## OBSERVATIONS ON WHY ANTIBIOTICS ARE OVERPRESCRIBED

During our many years in clinical eye care practice, we have identified the following reasons why many doctors overprescribe antibiotic agents:

1. Many eye care providers neglect to stay abreast of current research and, consequently, get stuck in habitual practices and become therapeutically complacent.
2. Clinically differentiating between different types of conjunctivitis can be challenging. This leads providers to prescribe antibiotics “just in case” there is an underlying infection.
3. The patient perception that antibiotics are a harmless cure-all for their ailments leads many patients to frequently request prescriptions “to be safe.” To improve patient satisfaction and address potentially relentless requests, providers submit to these unfounded petitions.

## QUOTABLE

**“Most cases of acute conjunctivitis are nonbacterial in origin, and even among those with a bacterial cause, antibiotics have only a modest benefit in reducing symptom duration. The complications of acute conjunctivitis are so rare that there is no evidence from systematic reviews that antibiotics reduce rates of complications.”<sup>1</sup>**

1. Keen M, Thompson M. Treatment of Acute conjunctivitis in the United States and evidence of antibiotic overuse: isolated issue or a systematic problem? *Ophthalmology*. 2017 Aug;124(8):1096-8.

quickly controls the inflammatory cascade, after which an appropriate tapering schedule (if necessary) can be executed.

In all cases of disease management, proper follow-up is paramount. Education of patients and open discussions minimize patient misconceptions and concerns about a given condition or therapy, and strengthen

doctor-patient trust. This, in turn, reduces the likelihood of patients seeking unwarranted second opinions that delay care.

## NEED FOR FOLLOW-UP

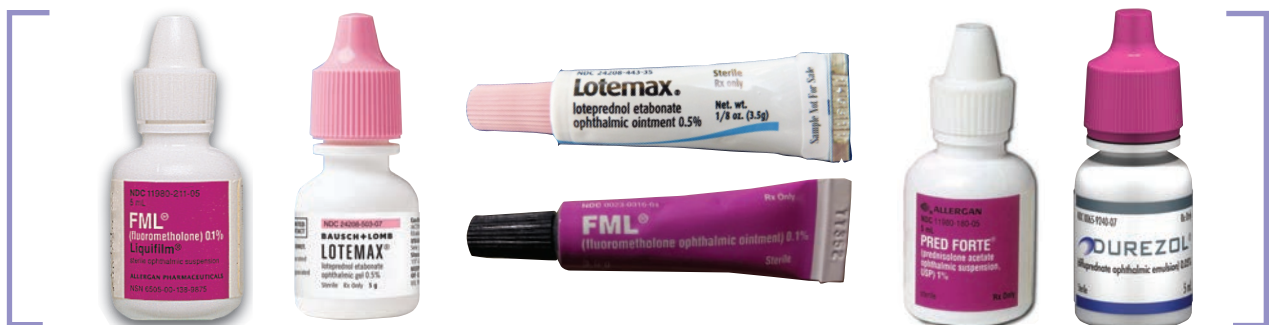Acute conjunctivitis rarely presents in textbook fashion. More often than not, the eye will just show signs of nonspecific inflammation. While this

shouldn't dampen your willingness to treat with topical steroids, having the patient return to you in a timely manner will illuminate ineffective treatments or misdiagnosed conditions. When you elect to see the patient back sooner rather than later, you position yourself to confirm your diagnosis or alter treatment if necessary. If you are truly concerned, call the patient in a couple of days to check on the therapy's progress. Patients love having their doctors call to check on them.

As one example, let's say you see a patient with typical lesions that could be Thygeson's superficial punctate keratopathy or herpetic eye disease. Since most red eyes are inflammatory in nature, we are inclined to initiate therapy with a steroid.

However, in the uncertainty of a diagnosis, we would tell the patient something like this: “This medicine should help your eye get better quickly; however, at this time the diagnosis of your condition is not completely clear, and there is a chance your eye could worsen on this medicine. It is important that you let me see you again in a couple of days. I will be glad to work you in anytime.” As previously mentioned, this caring conversation is crucial for optimal patient care and rapport.

All of this falls under the heading of “patient management” and is far more than just disease management. Trying to manage the disease without managing the patient will often result in frustration for both the doctor and patient. (This not only applies to corticosteroid treatment, but to the treatment of any eye condition.)





## DUREZOL: UNIFORMITY FOR ALL

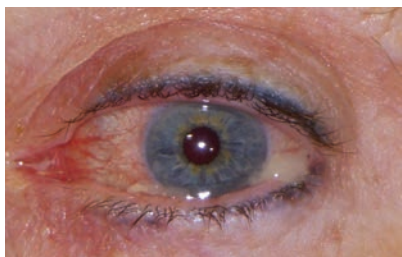
Steroid molecules are lipophilic in nature. Their inability to dissolve in solutions makes the majority of corticosteroids on the market available only in suspension form. But ophthalmic suspensions separate over time, causing the active ingredients to settle at the bottom. To ensure homogenous distribution, patients must vigorously shake the bottle prior to instillation. Otherwise, the patient risks subtherapeutic dosing, rendering less than desirable outcomes despite full compliance with drops.

Even when the bottle is shaken as directed, the particles still have a tendency to agglomerate, especially as the particle size of the drug increases. This causes dosage inconsistencies, and potential frustrations from the doctor and the patient.

In 2008, the FDA approved difluprednate ophthalmic emulsion 0.05% to treat inflammation and pain associated with ocular surgery. The drop was formulated as a stable oil-in-water emulsion, giving optimum dose consistency, while eliminating the need for shaking. In clinical trials, the drop showed therapeutic dose consistency far surpassing generic prednisolone acetate suspension 1% and branded prednisolone acetate suspension 1% in cataract surgery.<sup>1</sup>

Durezol's excellent drug uniformity and decreased dosing suggests increased compliance and more predictable results vs. other steroids in its class.

1. Donnenfeld ED, Holland EJ, Solomon KD, et al. A multicenter randomized controlled fellow eye trial of pulse-dosed difluprednate 0.05% versus prednisolone acetate 1% in cataract surgery. *Am J Ophthalmol*. 2011 Oct;152(4):609-617.e1.



This patient has a classic case of bacterial conjunctivitis as evidenced by the mucopurulent discharge and moderately inflamed conjunctiva.

## MAXIMUM EFFICACY STEROIDS

Don't let ocular inflammation linger by hesitantly prescribing topical steroids. Corticosteroids must be dosed early and often, with an appropriate tapering schedule when needed.

Clinically, we have found the two most efficacious topical ophthalmic steroids in the last several years to be Durezol emulsion (difluprednate 0.05%, Novartis) and Pred Forte (prednisolone acetate 1%, Allergan).

**Durezol.** Introduced in 2008, Durezol is often used as the heavyweight

of topical corticosteroids, and is looked upon favorably when moderate to severe inflammation needs to be rapidly suppressed. Durezol is compounded as an emulsion and does not need to be shaken before use.

The drug has a long history of use in the setting of severe or non-resolving iritis, and more recently is gaining

recognition as a popular postoperative drug. Clinically, we prefer it over Pred Forte for several reasons: We have found it to be more effective, it does not need to be shaken prior to instillation and it does not need to be dosed as often as Pred Forte, thereby increasing patient compliance.

Durezol's glucocorticoid binding affinity for the active metabolite difluprednate was found to be 56 times stronger than prednisolone.<sup>2</sup> A derivative of prednisolone, the drug's structural modifications to have a stronger binding affinity and a more consistent potency compared with its counterpart.

As a general rule, the more powerful the drug, the more potential for adverse side effects. Durezol is no exception, as it can be associated with elevated IOP. Thus, standard of care practices must be engaged, with frequent follow-ups to monitor the condition and check IOP.

**Pred Forte.** While not as clinically effective as Durezol, prednisolone acetate 1% possesses impressive anti-inflammatory efficacy. Its widespread use in ocular inflammatory conditions is most notably embraced postoperatively as well as in anterior uveitis cases. Remind your patients to

## KEEP IT LOCAL WITH LOTEMAX

A number of years ago, researchers examined the clinical efficacy of loteprednol etabonate 0.5% in rabbit corneas.<sup>1</sup> After instillation, the researchers assessed tissue structures in the eye. The cornea was found to have the highest ratio of metabolite to loteprednol etabonate 0.5%, followed by a much lesser concentration in subsequent tissues posteriorly. Strikingly, the aqueous humor concentration of the drug was 100 times lower than the concentration found in the cornea.

By keeping high levels of the drug out of the aqueous humor, the trabecular meshwork was less affected, and the propensity to increase IOP was considerably less than other topical steroids.

Of equal significance, when the drug was absorbed systemically, it was rapidly excreted through bile and urine.

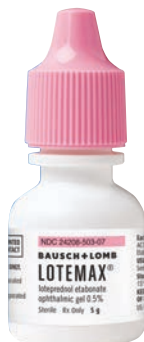The prompt de-esterification of Lotemax gel and its ability to be expelled promptly with any systemic absorption should make the prescribing doctor confident in applying its use in patient care.

1. Druzgala P, Wu WM, Bodor N. Ocular absorption and distribution of loteprednol etabonate, a soft steroid, in rabbit eyes. *Curr Eye Res*. 1991 Oct;10(10):933-7.

**LOTEMAX GEL VS. LOTEMAX OINTMENT**

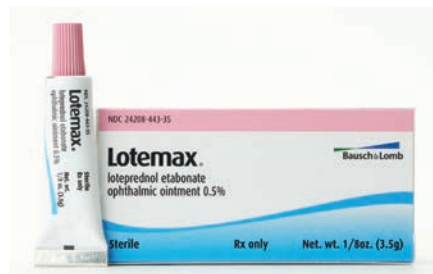Patients, practitioners and pharmacists may mix up these two medicines, so let's set the record straight.

- **Lotemax gel.** Though called a gel, this comes in a dropper bottle, like a solution. However, inside the bottle it is indeed a highly viscous, semisolid gel formulation. But, through a process called adaptive viscosity, it becomes a liquid when squeezed out of the dropper. And upon instillation in the eye (no shaking is necessary), the formulation loses its gel structure altogether as the polycarophil polymer interacts with the electrolytes in tears. Still, the drop is rather thick upon instillation and will cause a moment of initial blur until the gel fully converts into a liquid. We advise patients to allow the drop to spread out on the ocular surface for four to five seconds before blinking, so that the initial blink does not displace the drop onto the eyelid.



Because of the nature of this unique gel, the steroid does not settle out of the vehicle, so it does not require shaking. (It is best to tip the bottle back and forth once to make sure the drug enters the tip of the dropper prior to instillation, but no actual shaking is necessary.) Also, unlike suspensions, this delivery system provides a perfectly uniform dose at every instillation.<sup>1</sup>

- **Lotemax ointment.**<sup>2</sup> This preparation comes in a 3.5g tube and contains inactive ingredients of white petrolatum and mineral oil. Because it is an ester-based corticosteroid and also because it is a preservative-free preparation, it may provide a safety advantage over fluorometholone ointment. Lotemax ointment is indicated for the treatment of postoperative inflammation and pain, but is also applicable in many other cases in which an ointment is useful for suppression of inflammation.



1. Marlowe ZT, Davio SR. Dose uniformity of loteprednol etabonate ophthalmic gel (0.5%) compared with branded and generic prednisolone acetate ophthalmic suspension (1%). *Clin Ophthalmol.* 2014;8:23-9.

2. Comstock TL, Paterno MR, Singh A, et al. Safety and efficacy of loteprednol etabonate ophthalmic ointment 0.5% for the treatment of inflammation and pain following cataract surgery. *Clin Ophthalmol.* 2011;5:177-86.

vigorously shake the bottle before instillation because the drop is a suspension.

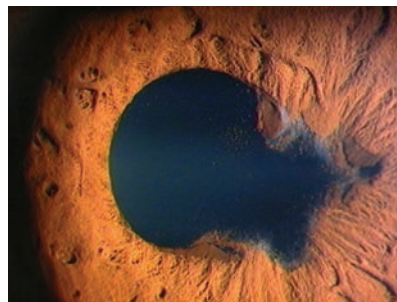
Some pharmacists will dispense generic prednisolone acetate, even when you have indicated “dispense as written.” Although less expensive, the generics are considerably less effective.<sup>3</sup> When maximum efficacy is required, Durezol is our drug of choice.

**HIGH EFFICACY STEROIDS**

Next in clinical efficacy are Lotemax gel (loteprednol 0.5%, Bausch + Lomb), generic prednisolone sodium

phosphate 1% solution (original brand name Inflamase Forte) and generic prednisolone acetate 1%. Dexamethasone, either in solution or suspension form, is also in this category. Of note, we have found that generic prednisolone sodium phosphate 1% solution does not penetrate transcorneally as effectively as the acetate moiety, but has the advantage of not requiring shaking.

**Lotemax gel.** Perhaps one of the most commonly used drugs among the corticosteroid class is loteprednol etabonate 0.5% (Lotemax gel,



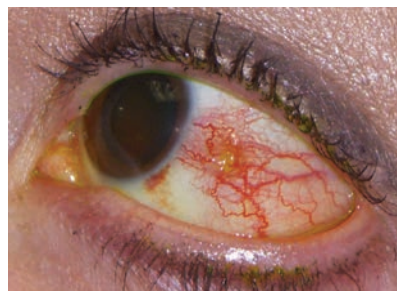
**Inflammatory synechia resulting from moderate to severe anterior uveitis.**

Bausch + Lomb). An ester-based steroid, its propensity to raise IOP is substantially less than its ketone-based counterparts.

Lotemax is highly lipophilic—10 times greater than dexamethasone—thereby increasing its efficacy and penetration across cell membranes. Additionally, loteprednol etabonate 0.5% undergoes rapid de-esterification to an inactive metabolite after exerting its effect, minimizing the risks of drug toxicity while maintaining good clinical efficacy.

Lotemax gel is a non-settling eye drop that does not require shaking before instillation. Though labeled as a gel, it becomes a viscous liquid once on the ocular surface (see “*Lotemax Gel vs. Lotemax Ointment*”).

We commonly prefer Lotemax gel as an off-label treatment in many of our dry eye patients, and also use it to treat many other chronic, recurrent, inflammatory conditions such as stromal herpes simplex keratitis, Thygeson’s SPK, uveitis, inflamed



**Inflamed pinguecula.**

## TIPS FOR TAPERING

Ever had a challenge tapering a patient off a topical corticosteroid? Steroids are wonderful for short-term therapy, but carry intrinsic risks when used long-term.

Here are a couple of thoughts:

You can usually get the patient down to three or two times a day, or even once daily before a relapse occurs. If a relapse does happen, you have to increase the dosage frequency again and try a longer, slower taper.

In addition, try adding a topical NSAID such as Prolensa (bromfenac, Bausch + Lomb) or Ilevro (nepafenac ophthalmic suspension, Novartis) once daily, or generic diclofenac or ketorolac QID as you begin the next step-down of the corticosteroid. This may offer enough supplemental anti-inflammatory support to enable the continuation of the steroid taper. Or, try the oral NSAID route: Celebrex (celecoxib, Pfizer) 100mg per day for a few weeks.

There are instances when long-term steroid use is indicated. Some patients who have had corneal transplants, stromal immune corneal disease, chronic uveitis or recalcitrant dry eye disease may be kept on low-dose steroids for life. Some patients require one drop of ste-

roid daily to maintain control over their condition.

While older ketone-based steroids have been used for long-term therapy in the past, we would recommend ester-based loteprednol 0.5% gel off-label once daily for these protracted dosing schedules. (The ketone-based

steroids seem to work well in this low-dose approach, yet it stands to reason that loteprednol, being an ester-based steroid, is preferable because of its enhanced safety profile.)

Though Lotemax gel can seem cost prohibitive for patients without drug coverage, most eligible commercially insured patients pay no more than a \$25 co-pay for their first prescription through the Access Program, and eligible refills at Walgreens and other participating independent pharmacies.

Discounted pricing is also available for eligible uninsured patients, according to Bausch + Lomb's website.

As well, Novartis offers various coupons for Durezol (difluprednate). And when there is no getting around cost issues for the patient, generic FML (fluorometholone 0.1%, Allergan) is another option. In addition, consulting [www.goodrx.com](http://www.goodrx.com) can turn up the best local prices.



pinguecula, pterygia and many other inflammatory conditions.

While we have found that the drug is not quite as efficacious as prednisolone and Durezol, its ester-based derivatives correlate to fewer unwanted side effects (e.g., subcapsular cataracts, elevated IOP).

In Phase III studies, for instance, only two out of 409 patients on Lotemax gel had an increase in IOP greater than 10mm Hg after 18 days of treatment.<sup>4</sup> When used for post-operative cataract surgery inflammation, loteprednol 0.5% suspension was shown to be as effective as prednisolone acetate, with less effect on IOP.<sup>5</sup>

**Prednisolone sodium phosphate 1%.** Although generic, this drug remains a viable option when an inexpensive, potent steroid is needed. Unlike many of the other topical steroids, the drop is prepared as a so-

lution—not a suspension—and does not need to be shaken before instillation. It remains an excellent choice for older patients with arthropathies that make shaking a bottle challenging. It's also well-suited for soft contact lens wearers because it won't precipitate on the lens to the extent of suspension drops.

**Prednisolone acetate 1%.** Generic prednisolone acetate suspension is relatively inexpensive, and a reasonable choice for mild to moderate acute inflammatory conditions—but not preferred in the setting of advanced iritis and episcleritis. Make sure that you indicate “brand name necessary” when prescribing for clinical situations that are potentially vision threatening.

Rather than battle with the pharmacy or insurance company, we recommend prescribing Durezol to bypass such bureaucratic hassles.

## MODERATE EFFICACY STEROIDS

The two most common topical steroids in this category are fluorometholone 0.1% suspension and Alrex suspension (loteprednol 0.2%, Bausch + Lomb), both of which must be shaken prior to instillation.

**Fluorometholone 0.1%.** There are two derivatives of fluorometholone 0.1% suspension: alcohol (FML, Allergan; and generic) and acetate (Flarex, Novartis; and generic). The acetate moiety gives the fluorometholone molecules some additional anti-inflammatory effectiveness over the alcohol moiety.<sup>6</sup>

Fluorometholone alcohol is available generically, so it is relatively inexpensive. While fluorometholone has less likelihood of raising IOP than other ketone steroids, we are not nearly as comfortable using it long-term as we are using ester-based loteprednol.



Since the lowest effective dose should be used in all cases, FML Forte (fluorometholone 0.25% ophthalmic suspension) is not recommended because the 0.1% concentration represents the top of the dose response curve—meaning that 0.25% is no more efficacious than 0.1%.

**Alrex.** An ester-based corticosteroid, Alrex is an excellent off-label treatment option in cases when a patient needs long-term therapy. We often use Alrex in our patients with allergic eye disease when clinical signs of conjunctival injection, chemosis or eyelid swelling accompany itching. In such cases, Alrex (or even Lotemax gel) will best help subdue the patient's condition. We typically dose Alrex (or Lotemax gel) QID for one week, then BID for one month.

Beyond awareness of the various delivery systems (suspensions, solutions, emulsions, gels and ointments), knowing the clinical efficacy of these drugs is important.

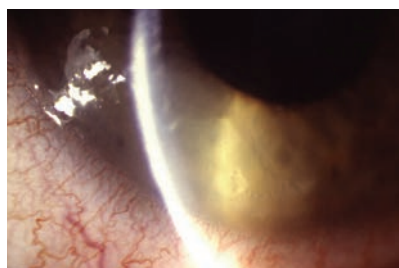
## STEROID OINTMENTS

The ophthalmic ointments enjoy a wide array of clinical indications. Three corticosteroid medicines that merit frequent clinical use are:

### RELATIVE CLINICAL EFFICACY OF TOPICAL STEROIDS

Here, based on our clinical experience and the comparative information we have available, we rate the relative efficacy of the topical steroids, starting with the most efficacious:

- Difluprednate 0.05%
- Prednisolone acetate 1%
- Loteprednol 0.5%
- Rimexolone 1%
- Fluorometholone acetate 0.1%
- Dexamethasone 0.1%
- Fluorometholone alcohol 0.1%
- Loteprednol 0.2%
- Prednisolone 0.125%
- Hydrocortisone 1%

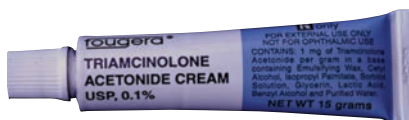

This slit-lamp view shows dense anterior stromal infiltration of leukocytes with minimal epithelial breakdown. Such findings, in our experience, always indicate an inflammatory process meriting antibiotic/steroid therapy.

**Lotemax ointment.** The only available ester-based steroid ointment, Lotemax ophthalmic ointment (loteprednol 0.5%, Bausch + Lomb), is indicated for postoperative inflammation and pain, but has many beneficial off-label clinical applications. Some examples are dry eye, allergy, corneal transplant protection, blepharitis, giant papillary conjunctivitis, chronic uveitis, stromal immune herpetic keratitis, Thygeson's SPK, recurrent corneal erosion, augmentation of steroid eye drop therapy in acute advanced uveitis or episcleritis, contact dermatitis and other inflammatory conditions. Lotemax ointment is ideally suited for patients who complain of how sandy and gritty their eyes feel upon awakening.

**FML ointment.** Used similarly to Lotemax ointment, FML ophthalmic ointment (fluorometholone 0.1%, Allergan; and generic) is indicated for inflammation of the palpebral and bulbar conjunctiva, cornea, anterior segment of the globe as well as the off-label uses mentioned earlier. The only minor difference is to keep a closer watch for steroid-related adverse effects since it is a ketone formulation.

**Triamcinolone 0.1% cream.** This is a dermatological preparation that



works well for periocular dermatitis conditions. Triamcinolone 0.1% cream, which became generic many years ago, has been our favorite medication to treat contact blepharodermatitis. It comes in 15g and 30g tubes, each costing about \$10 in most markets. We have treated hundreds of periocular contact dermatitis patients with this drug with consistent, superb, clinical outcomes.

Be sure to tell the patient that the statement "Not for Ophthalmic Use" is on the side of the tube, but that the medication is perfectly fine to use as prescribed. We explain to patients that triamcinolone is frequently used by retina subspecialists for FDA-approved injection into the eye, so if some of the triamcinolone cream gets into patients' eyes, it's nothing to be concerned about. Doctors should be cautioned to use this approach only for short-term relief, as long-term use can result in skin atrophy and, in some cases, elevated IOP (which we have never seen).

Corticosteroids are the most essential and highly prescribed drugs in the treatment of ocular inflammation of any stripe. Their widespread clinical usage confirms that ocular inflammation is the most common clinical manifestation seen in eye care. It is imperative that all doctors of optometry embrace this reality and become comfortable using these essential drugs in order to effectively care for patients with inflammatory eye disease. **DG**

1. Azari AA, Barney NP. Conjunctivitis: A systematic review of diagnosis and treatment. *JAMA*. 2013 Oct 23;310(16):1721-9.
2. Donnenfeld ED. Difluprednate for the prevention of ocular inflammation postsurgery: an update. *Clin Ophthalmol*. 2011;5:811-6.
3. Roberts CW, Nelson PL. Comparative analysis of prednisolone acetate suspensions. *J Ocul Pharmacol Ther*. 2007 Apr;23(2):182-7.
4. FDA Center for Drug Evaluation and Research. Deputy Division Director Review for NDA 202-872. 2012 Sep 27. Available at: [www.accessdata.fda.gov/drugsatfda\\_docs/nda/2012/202872Orig1s000MedR.pdf](http://www.accessdata.fda.gov/drugsatfda_docs/nda/2012/202872Orig1s000MedR.pdf) (last accessed March 21, 2018).
5. Lane SS, Holland EJ. Loteprednol etabonate 0.5% versus prednisolone acetate 1.0% for the treatment of inflammation after cataract surgery. *J Cataract Refract Surg*. 2013 Feb;39(2):168-73.
6. Leibowitz HM, Hyndiuk RA, Lindsey C, Rosenthal AL. Fluorometholone acetate: clinical evaluation in the treatment of external ocular inflammation. *Ann Ophthalmol*. 1984 Dec;16(12):1110-5.



# NSAIDs: PARAMETERS FOR BEST PRACTICES

When used judiciously, a nonsteroidal in concert with a corticosteroid can arrest postoperative cystoid macular edema formation.

Topical nonsteroidal anti-inflammatory drugs (NSAIDs), employed sparingly in the clinical setting, are mainly approved to treat pain and inflammation associated with cataract surgery, although some off-label uses exist. Additional therapy can be used to maintain mydriasis during cataract surgery and decrease pain in photorefractive keratectomy patients<sup>1,2</sup>

## INDICATIONS

NSAIDs primarily ameliorate pain on the ocular surface. When used together, NSAIDs and corticosteroids have beneficial therapeutic effects on postoperative cystoid macular edema (CME) formation. Generally, topical NSAIDs are prescribed in combination with maximal-efficacy steroids to treat postoperative CME.

Dosing ranges from QD to QID, and recommended dosing limits should be followed to minimize side effects. It may also be prudent to comanage surgical patients with cataract surgeons. Duration of use should be limited to two weeks with the exception of CME cases, for which we'll prescribe one month of a topical NSAID with a potent steroid. Note that chronic use of NSAIDs can retard corneal epithelial healing, and lead to, in very rare cases, corneal melting and perforation.<sup>3</sup>

## MORE RECENT DRUGS

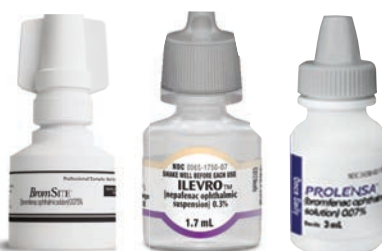Newer to the topical NSAID space are Ilevro (nepafenac ophthalmic suspension 0.3%, Novartis) and Prolensa (bromfenac ophthalmic solution

0.07%, Bausch + Lomb). FDA-approved for post-op inflammation and pain, the drugs are dosed QD.<sup>4,5</sup>

Ilevro, a prodrug, is highly permeable to the cornea and rapidly hydrolyzed to amfenac in the aqueous.<sup>4,5</sup> Prolensa, structurally similar to amfenac, contains a bromine atom, making it highly lipophilic, which increases corneal penetration and duration of action.<sup>6</sup> Since NSAIDs are fundamentally acidic, Prolensa is buffered to a pH of 8.3 for added comfort with instillation.<sup>6</sup> Amfenac is a potent inhibitor of COX-1/COX-2 isoenzymes.<sup>6</sup> Once-a-day dosing is also an option due to the increased nepafenac concentration from 0.1% to 0.3%.

Other NSAIDs include: Acular LS (ketorolac tromethamine ophthalmic solution 0.4%, Allergan), Acuvail (ketorolac tromethamine ophthalmic solution 0.45%, Allergan), Bromsite (bromfenac ophthalmic solution 0.075%, Sun Pharma) and Voltaren (diclofenac sodium topical gel 1%, Endo Pharmaceuticals).

As with all medical therapy, the availability of once-daily dosing increases patient compliance, and the right formulations are key to ensuring appropriate concentrations with each instillation. **DG**



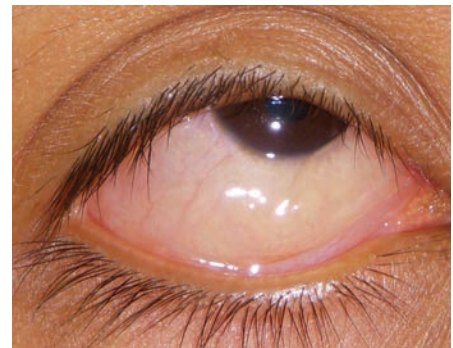
- Schalnus R. Topical nonsteroidal anti-inflammatory therapy in ophthalmology. *Ophthalmologica*. 2003;217(2):89-98.
- Eslampoor A, Ehsaei A, Abrishami M. Effect of topical diclofenac on postoperative photorefractive keratectomy pain: a randomized, controlled trial. *Clin Exp Ophthalmol*. 2014 Dec;42(9):810-4.
- Lin JC, Rapuano CJ, Laibson PR, et al. Corneal melting associated with use of topical nonsteroidal anti-inflammatory drugs after ocular surgery. *Arch Ophthalmol*. 2000;118(8):1129-32.
- Alcon. Ilevro package insert. Ft. Worth, TX, 2013.
- Bausch + Lomb. Prolensa package insert. Tampa, FL, 2013.
- Ahuja M, Dhake AS, Sharma SK, Majumdar DK. Topical ocular delivery of NSAIDs. *The AAPS Journal*. 2008;10(2):229-41.

# DON'T OVERLOOK OCULAR ALLERGIES

This common condition responds well to therapy. Start symptom suppression right away and let resolution guide your decisions, but don't miss coexisting dry eye.

Patients with ocular allergies make up a large portion of clinical encounters in daily practice. Nearly one-third of the population is affected by allergic disease, with an estimated 40% to 80% of individuals manifesting ocular involvement.<sup>1</sup> And yet, allergic eye disease is often misdiagnosed as allergic rhinitis or sinusitis, since the conditions frequently coexist, according to the American Academy of Allergy, Asthma and Immunology. As a result, sinus inflammation is routinely diagnosed, treated and managed, while ocular allergies are not.

As in all cases of an allergic response, exposure to an allergen prompts the immune system to overreact and produce immunoglobulin E (IgE) antibodies that bind to mast cells. Ongoing exposure leads to the release of chemical mediators



This is a classic presentation of acute allergic conjunctivitis. Note the bulbar conjunctival chemosis which is pathognomonic for a local hypersensitivity reaction.

that cause the symptoms of allergy and cascade of local inflammation—a process known as mast cell degranulation.

Allergic eye disease, an IgE-mediated

## IDENTIFYING COMMON TRIGGERS

The two most prevalent allergens—pollen and animal dander—cycle throughout varying seasons. In the spring, grass and tree pollen aeroallergens are most common; in the fall, ragweed is more predominant. Meanwhile, indoor pets can be the cause of allergic eye disease year-round.

The symptoms of ocular allergy are usually itching, redness and tearing. Without itching, the patient likely does not have allergic eye disease.

Allergists suggest that patients suffering from chronic and cyclical signs and symptoms caused by allergic disease should be tested to identify the offender.<sup>1</sup> Treatment is found through medicine, environment control (avoidance) or allergy injections/sublingual drops.

The next time your patient presents with a long-standing history of repeatable allergic patterns, consider the role of an allergist to further assist your management.

1. Bernstein IL, Li JT, Bernstein DI, et al. Allergy diagnostic testing: an updated practice parameter. *Ann Allergy Asthma Immunol* 100 3 Supp (2008):S1-148.

## “Do Your Eyes Itch or Burn?”

- **Itching:** If the patient tells you that itching is the primary concern, determine if it's an isolated symptom or if it's associated with parallel signs of inflammation, and then treat accordingly. Remember:

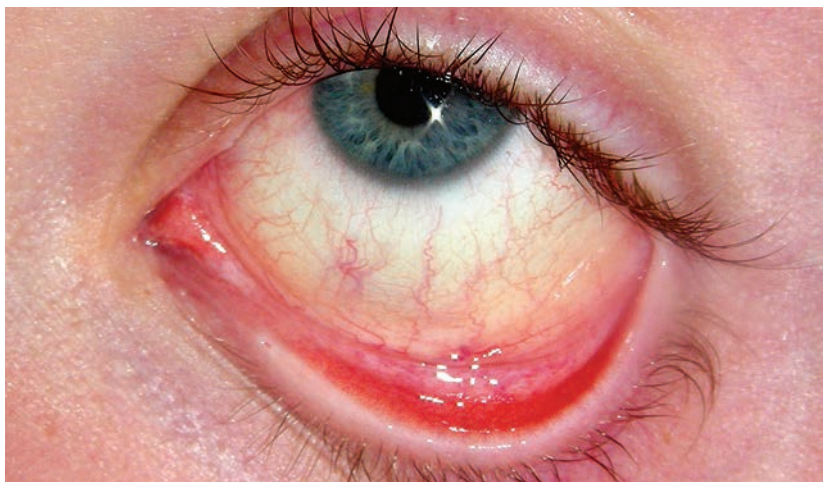*Symptoms Only:* Use an antihistamine/mast cell stabilizer

*Symptoms and Signs:* Use a steroid such as Lotemax, Alrex or FML.

- **Burning:** If the main symptom is burning, a full dry eye workup is in order for your patient. Also be sure to consider dry eye as the foundational condition, and treat accordingly.

Of course, nothing in the rulebook states that a patient can't have both of these symptoms concomitantly. Due to the prevalence of dry eye across all ages, recognize and also treat this disease whether or not it is affiliated with allergic eye disease.

response and type I hypersensitivity reaction, presents in various forms, from a persistent itch to a potentially sight-threatening corneal ulcer (vernal keratoconjunctivitis). For seasonal allergic conjunctivitis, the treatment protocols are straightforward: antihistamines/mast cell stabilizers or corticosteroids. Though the



Determine signs and symptoms by first asking, “Do your eyes burn or itch?”

therapeutic options are essentially the same, perennial allergic conjunctivitis follows a more indolent course, often requiring more attentive and persistent care by the attending doctor.

Itching is the definitive hallmark of ocular allergy. Patients should be asked: “Is itching or burning your main symptom?” Typically, their response can isolate your next step. If your patient is unable to decide which symptom distresses them the most, treatment with an ester-based steroid drop typically solves both complaints. Preferred options include Alrex (loteprednol etabonate 0.2%, Bausch + Lomb) and Lotemax (loteprednol etabonate 0.5%, Bausch + Lomb).

If patients report itching as their

predominant symptom, therapy is directed toward one of two paths, discussed below.

### SYMPTOMS ONLY

If the anterior segment exam shows minimal or unremarkable signs of allergic conjunctivitis (e.g., conjunctival chemosis, conjunctival injection, eyelid edema and/or papillae), treatment with a combination antihistamine/mast cell stabilizer is the ideal clinical choice. To date, there are six drugs in this class to choose from:

- *Alcaftadine* (Lastacaft, Allergan)
- *Azelastine* (Optivar, Meda Pharmaceuticals; generic available)
- *Bepotastine* (Bepreve, Bausch + Lomb)



### FROM THE LITERATURE

#### AN UPDATE ON PREVALENCE

According to the published findings from a series of studies conducted by the International Study of Asthma and Allergies in Childhood (ISAAC) starting two decades ago, allergic conjunctivitis has shown a worldwide trend in increasing prevalence.<sup>1</sup> This upsurge has been

attributed to climate changes, pollution, increased pollen and a heightened immunological sensitivity in response to environmental changes, among other factors.<sup>2</sup> About 40% of patients who suffer from allergies reportedly experience some form of ocular symptomology (itching, chemosis, redness).<sup>3</sup>

Of equal significance are the documented negative impacts of ocular allergies on patient quality of life,

confirming the importance of early therapeutic intervention.

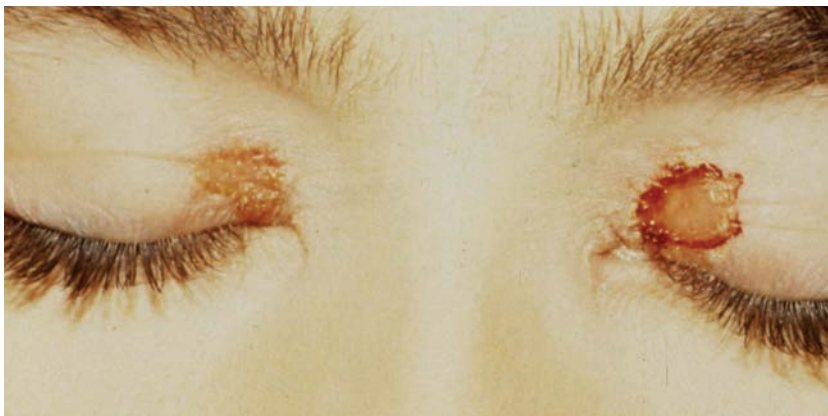1. Worldwide variation in prevalence of symptoms of asthma, allergic rhinoconjunctivitis, and atopic eczema: ISAAC. The International Study of Asthma and Allergies in Childhood (ISAAC) Steering Committee. *Lancet*. 1998 Apr;351(9111):1225-32.
2. D'Amato G, Holgate ST, Pawankar R, et al. Meteorological conditions, climate change, new emerging factors, and asthma and related allergic disorders. A statement of the World Allergy Organization. *World Allergy Organ J*. 2015; 8(1):1-52.
3. Singh K, Axelrod S, Bielory L. The epidemiology of ocular and nasal allergy in the United States, 1988-1994. *World Allergy Organ J*. 2015;8(1):25.

## OLOPATADINE: HISTORICAL GOLD STANDARD OF ALLERGY TREATMENT

The first dual-action antihistamine/mast cell stabilizer to transform ocular allergy therapy was olopatadine 0.1% (Patanol, Novartis). In 1996, the FDA approved Patanol for the treatment of signs and symptoms of allergic conjunctivitis. The drug is highly selective for the H1 receptor, and has been shown in studies to possess anti-inflammatory properties, as well the ability to inhibit the release of leukotrienes, cytokines and adhesion molecules.<sup>1</sup> Olopatadine 0.1% was the first topical drop for allergic conjunctivitis approved for BID dosing, far surpassing the second-generation antihistamines, which, in their time, had advanced to QID.

In 2010, olopatadine 0.2% (Pataday) became available with comparable efficacy and improved patient satisfaction for relief of ocular symptoms for up to 18 hours. Five years later, olopatadine 0.7% (Pazeo) made its market debut with efficacy surpassing 24-hour ocular itching relief while maintaining a similar safety profile to lesser concentrations that came before it.

1. Ackerman S, Smith LM, Gomes PJ, et al. Ocular itch associated with allergic conjunctivitis: latest evidence and clinical management. *Ther Adv Chronic Dis.* 2016 Jan; 7(1): 52-67.

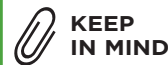

Some people rub their itchy eyelids to the point of epidermal abrasion. Topically applied Lotemax, FML or triamcinolone ointment could have prevented this. Now an antibiotic/steroid ointment is needed to restore tissue health.

- *Epinastine* (Elestat, Allergan; generic available)
  - *Ketotifen* (Zaditor, Alcon; many generics available. This drop is OTC.)
  - *Olopatadine*—branded (Pazeo/Pataday/Patanol, Novartis) and generic 0.1% olopatadine
  - *Cetirizine* (Zerviate, Nicox/Akorn)
- Of these, all are rated pregnancy category C except for Lastacaft, which is pregnancy category B. Notwithstanding other fine differences,

all of the antihistamine subtype 1 receptor blockers nicely suppress ocular itching. As well, all are dosed initially BID (except Pazeo, Pataday and Lastacaft, which are dosed QD).

After two weeks of BID therapy, consider reducing instillation to QD for maintenance dosing. Remember, as with any treatment, the lowest effective dose is always desired. In our experience, once the inflammation

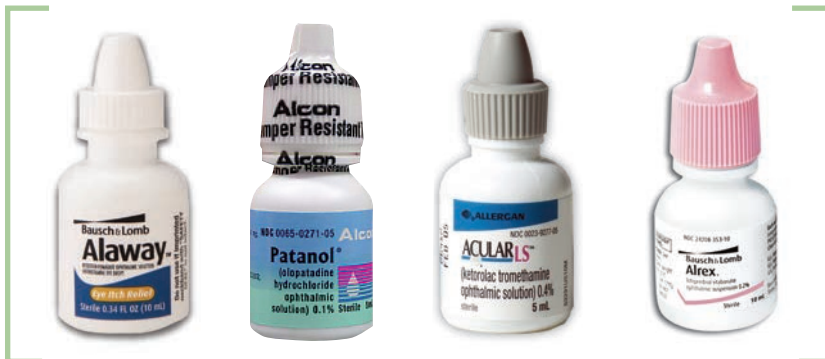

### WHEN THE ITCHY EYE IS ALSO DRY

Most patients with allergic conjunctivitis also suffer from dry eye and hyperemia, even if the dryness has not elicited symptoms of burning. Specifically, the likelihood of allergic conjunctivitis patients also having dry eye is more than twice that of patients without symptoms of itch, and the chance of these patients also experiencing redness is more than seven times that of patients with non-itchy eyes.<sup>1</sup>

These results suggest that some symptomatic patients concomitantly have features of allergic conjunctivitis and dry eye syndrome.

1. Hom MM, Nguyen AL, Bielory L. Allergic conjunctivitis and dry eye syndrome. *Ann Allergy Asthma Immunol.* 2012 Mar;108(3):163-6.





## TOPICAL ANTIHISTAMINE DOSING: IT TAKES TWO TO TANGO?

Forget about prescribing pure mast cell stabilizing drugs, according to Mark Abelson, MD, a world-renowned ocular allergist at Harvard Medical School. Dr. Abelson told us that pure mast cell stabilizing drugs have little clinical use, as their lag period and mandatory chronic dosing severely limits their clinical applicability. Rather, topical combination antihistamine/mast cell stabilizers give patients nearly instantaneous relief due to the rapid onset of action; also compelling is their affordability. Dr. Abelson explained that antihistamine/mast cell stabilizer drugs actually do a better job of stabilizing mast cell membranes than a pure mast cell stabilizer.

The cost of an OTC topical combination antihistamine/mast cell stabilizer drop is similar to a pure mast cell stabilizer. Remind your patients that transient burning and stinging upon instillation is common.

For patients who have symptomatic disease, one drop in the morning may suffice for lasting improvement throughout the day. However, a subset of patients may need to instill a second drop later in the afternoon. Which is correct? In the end, either is appropriate, as care of the symptomatic patient is a tailored, rather than a one-size-fits-all, approach.

In your patients with severe allergy expression, therapy is slightly more involved. In addition to an antihistamine/mast cell stabilizer BID, consider an ester-based corticosteroid such as Alrex (loteprednol 0.2%, Bausch + Lomb) or off-label use of Lotemax gel (loteprednol 0.5%, Bausch + Lomb) QID initially along with cold compresses.

Once the inflammation has settled down, the steroid may be discontinued, usually within two weeks, and the patient can remain on the antihistamine/mast cell stabilizer once or twice daily as needed.

is brought under control, less pharmaceutical intervention is needed to maintain suppression of symptoms. Then again, some patients still require a second additional drop later in the afternoon.

Perhaps the best news for the consumer was the loss of patent protection for Zaditor (Novartis). Since 2007, ketotifen has been available generically and over the counter. In addition to Zaditor, several brand name OTC ketotifen preparations are available, including Alaway (Bausch + Lomb), Refresh Eye Itch Relief (Allergan) and others. All come in 5ml bottles, except for Alaway and TheraTears Eye Itch Relief (Akorn), which come in 10ml bottles.

When a prescription medication is preferable, 5ml bottles of Alrex and Bepreve are only \$10 copays for the first Rx and refills through the Bausch + Lomb Access program at Walgreens and other participating independent pharmacies during

## OCULAR ALLERGY MEDICINES

BRAND NAME	GENERIC NAME	MANUFACTURER	PEDIATRIC USE	BOTTLE SIZE(S)	DOSING
<b>Acute Care Products</b>					
Acular LS	ketorolac tromethamine 0.4%	Allergan and generic	3 yrs	5ml, 10ml	QID
Alaway (OTC)	ketotifen fumarate 0.035%	Bausch + Lomb	3 yrs	10ml	BID
Alrex	loteprednol etabonate 0.2%	Bausch + Lomb	12 yrs	5ml, 10ml	QID
Bepreve	bepotastine besilate 1.5%	Bausch + Lomb	2 yrs	5ml, 10ml	BID
Elestat	epinastine HCl 0.05%	Allergan and generic	3 yrs	5ml	BID
Emadine	emedastine difumarate 0.05%	Novartis and generic	3 yrs	5ml	QID
Lastacaft	alcaftadine 0.25%	Allergan and generic	2 yrs	3ml	QD
Optivar	azelastine hydrochloride 0.05%	Meda and generic	3 yrs	6ml	BID
Pataday	olopatadine hydrochloride 0.2%	Novartis	3 yrs	2.5ml	QD
Patanol	olopatadine hydrochloride 0.1%	Novartis and generic	3 yrs	5ml	BID
Pazeo	olopatadine hydrochloride 0.7%	Novartis	2 yrs	2.5ml	QD
Zaditor (OTC)	ketotifen fumarate 0.035%	Novartis and generic	3 yrs	5ml	BID
<b>Chronic Care Products</b>					
Alocril	nedocromil sodium 2%	Allergan and generic	3 yrs	5ml	BID
Alomide	lodoxamide tromethamine 0.1%	Alcon	2 yrs	10ml	QID
Crolom	cromolyn sodium 4%	Bausch + Lomb and generic	4 yrs	10ml	QID

## AN OUNCE OF PREVENTION...

Avoidance is one of the best ways to prevent common eye allergies. Other tips from the Asthma and Allergy Foundation of America include:

- Don't touch or rub the eye(s).
- Wash hands often with soap and water.
- Use a vacuum with a HEPA filter to reduce exposure to allergens.
- Wash bed linens and pillowcases in hot water and detergent to reduce allergens.
- Use allergen covers (encasements) for pillows, comforters, duvets and mattresses, and consider using them for box springs.
- Keep pets out of the bedroom to reduce pet dander allergen in bedding.
- Wear sunglasses and a wide-brimmed hat to help keep pollen from getting into the eyes.
- Close windows during high-pollen and mold seasons. Run the air conditioner in the car and at home, and consider using a HEPA filter.

Eye Allergies (Allergic Conjunctivitis). Asthma and Allergy Foundation of America. Available at: [www.aafa.org/page/eye-allergy-conjunctivitis.aspx](http://www.aafa.org/page/eye-allergy-conjunctivitis.aspx). Accessed March 12, 2018.

allergy season (between February 15 and June 15, and August 1 through October 31); they are only \$15 co-pays for the first Rx and refills filled outside of the program's participating pharmacies during allergy season. Also consider consulting [www.goodrx.com](http://www.goodrx.com) to find the best available price in your area.

## SYMPTOMS AND SIGNS

Whenever possible, therapy for ocular allergies should be prophylactic. Therefore, in the setting of allergic conjunctivitis, initiate therapy early in the process, make sure it is sufficient to suppress the patient's signs and symptoms, and have the patient continue for long enough to prevent conversion into a chronic disease. The basis of treating any allergic eye disease remains the same: quell the

inflammation early to avoid potential late complications.

In individuals presenting with symptoms of allergy along with classic anterior segment findings, a topical, ester-based corticosteroid is a wonderful option. We recommend Alexr or off-label use of Lotemax gel (loteprednol 0.5%, Bausch + Lomb). Additionally, the generic, ketone-based corticosteroid FML ophthalmic suspension (fluorometholone 0.1%, Allergan; and generic) is a viable therapy, although we have found it has a higher propensity to increase IOP compared with its ester-based loteprednol counterparts. (Also of interest, FML, though generic, is often more expensive than the varying concentrations of loteprednol once a Bausch + Lomb coupon has been applied).

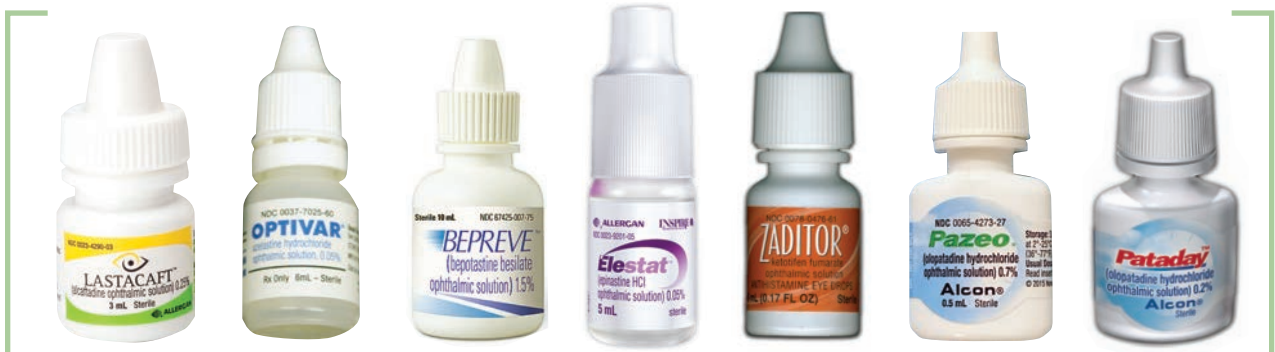Frequency of instillation is tailored to the severity of the patient's signs and symptoms. Typically, we prescribe a steroid drop Q2H for two days, then QID for one week, followed by BID for one more week. Once the signs of allergic eye disease are subdued, consider switching your patient to an antihistamine/mast cell stabilizer for ongoing symptomatic regulation.

## AN EQUAL-OPPORTUNITY DISEASE

While once considered to be a "disease of affluence," allergic conjunctivitis is now clearly recognized around the world, with increasing prevalence in countries with sustained growth and developing urban populations.<sup>2</sup> Doctors should bear in mind that, while the disease is not life-threatening, the persistent symptoms experienced by those who suffer from ocular allergies can have a profound impact on productivity and quality of life.

Remember, allergy is an expression of inflammation. In addition to the therapeutic strategies listed above, don't forget to discuss with patients palliative options such as daily cold compresses. Telling your patients to place their allergy drops in the refrigerator until it's time to instill the drop can add additional relief. **DG**

1. Kari O, Saari KM. Diagnostics and new developments in the treatment of ocular allergies. *Curr Allergy Asthma Rep.* 2012;Jun;12(3):232-9.  
2. Gomes PJ. Trends in prevalence and treatment of ocular allergy. *Curr Opin Allergy Clin Immunol.* 2014 Oct;14(5):451-6.



# VANQUISH THE VIRUS

Early recognition and appropriate therapy are crucial to maintaining the integrity of the ocular tissues when treating patients with viral eye diseases.

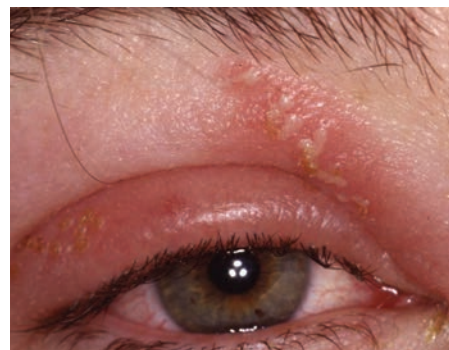**T**he herpes virus can manifest in a wide range of ocular conditions, from a mild vesicular lid lesion to an aggressive retinitis. Clinicians should be aware that the virus can affect every ocular tissue and treat the patient accordingly.

## HERPES SIMPLEX

The herpes simplex virus (HSV), characterized by its ability to remain latent in the nervous system, can impact individuals of all ages. By adulthood, almost all of the population has herpes simplex antibodies, with the majority of people having had exposure by age five. HSV, a DNA virus largely spread by close personal contact, is primarily broken down into two types: herpes simplex I (oral/facial/ocular) and herpes simplex II (genital); HSV can also cross-infect between type 1 and type 2.<sup>1</sup>

In the setting of periocular skin disease, the patient may have confined prodromal symptoms such as mild pain, tingling, itching or burning before the lesion potentially progresses to the following stages: macule, papule, vesicle, encrustation and healing (without scarring). Only after skin lesions are encrusted is the primary disease no longer contagious.

It is well known that herpes simplex disease tends to recur. With a prevalence of 150 per 100,000 people in western countries, patients have a 1% global lifetime risk of developing herpes simplex keratitis (HSK). Furthermore, 40% of patients will



Primary herpes simplex blepharodermatitis.

have between two to five relapses in their lives; an additional 11% will experience between six and 15 relapses.<sup>2</sup>

A reactivation from the ophthalmic branch of the trigeminal ganglion may result in HSK. In those who exhibit relapsing HSK, the three primary presentations of keratitis—epithelial, stromal and endothelial—can occur in isolation, combination or succession.

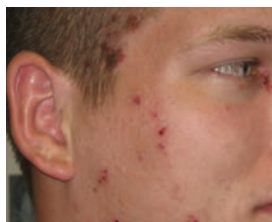With HSK, the patient will often present with unilateral injection and a mild, watery discharge. It is imperative to remember that, early on, corneal lesions may not present in their classic dendrite formation. When caught at the start of the infection process, HSK may appear merely as a superficial punctate keratitis secondary to dry eye. However, these primarily coarse punctate lesions form unilaterally (with the exception of children with atopic disease who may get bilateral

## OTHER FACES OF HSV EXPRESSION

We all are familiar with the typical clinical manifestations of primary herpes simplex expression, but there are two other presentations to recognize: herpes gladiatorum and eczema herpeticum. While both are dermatologic in nature and share a similar clinical presentation, unique differences exist between them.

### HERPES GLADIATORUM

This form is seen almost exclusively in high school or college wrestlers. The athlete develops a spontaneous primary infection, engages in wrestling activity and transmits the virus via vigorous skin-to-skin contact. Note that while spontaneous primary HSV expression is generally unilateral, this condition (as well as eczema herpeticum) can be much more diffusely dispersed. A patient history is critical to diagnosis, and both primary

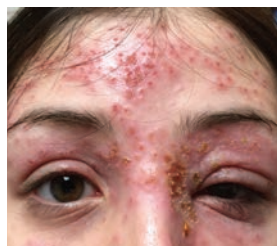

**Herpes gladiatorum as seen in the typical male wrestler.**

and gladiatorum forms are treated either with acyclovir 400mg, five times a day for seven to 10 days; valacyclovir 500mg, three times a day for seven to 10 days; or famciclovir 250mg, three times a day for seven to 10 days. Because of the easier dosing schedule of valacyclovir and famciclovir (TID), we generally prescribe one of these two drugs. Check with [www.goodrx.com](http://www.goodrx.com) to find where this medicine is the least expensive in your area.

### ECZEMA HERPETICUM

This is somewhat of an opportunistic infection, in that it is almost always seen in patients with eczema, a subset of atopic disease. As with gladiatorum, it has a rather disseminated expression that does not respect laterality. The face and neck are most commonly involved, and younger



**Eczema herpeticum.**

people are the target population. Unlike healthy gladiatorum patients, eczema herpeticum patients usually have some degree of immune system compromise, and so feel unwell with possible swollen lymph nodes.

Because of the potential for more severe disease with herpeticum, we prescribe the zoster dosage of acyclovir 800mg, five times daily; valacyclovir 1,000mg, three times daily or famciclovir 500mg, three times daily for a course of 10 to 14 days. Remember that these oral antiviral drugs are quite safe, and only moderate to severe renal disease requires a reduced dosage.

Fortunately, these patients usually present to primary care physicians or dermatologists initially, but eye doctors are often consulted with findings of any periocular involvement. With these forms of herpes simplex dermatological disease, the globe is rarely involved. Typically, only a premium-quality artificial tear would be needed for ocular involvement, as oral antiviral drugs treat the full spectrum of the disease manifestation.

Only on occasions in which secondary, concurrent or bacterial infection (mostly *Staphylococcus aureus*, but occasionally *Streptococcus pyogenes*) is suspected or determined would a topical non-ophthalmic antibiotic ointment (mupirocin, brand name Bactroban) or systemic antibiotic (cephalexin, brand name Keflex) be warranted.

All of these herpetic disease processes respond well to oral antivirals, and patients usually heal well. Our role as eye physicians is to assess the ocular tissues and inform the initial treating doctor about the eye and eyelid tissues.

disease though remaining immunocompetent), are more commonly found centrally and will not respond to dry eye therapy alone.<sup>3</sup>

In patients who develop HSK, approximately 15% will develop severe complications.<sup>4</sup> With those who have epithelial keratitis, moderate pain is the most expressed symptom, in contrast with the other two variants—stromal and endothelial—in which varying degrees of vision loss will be present. Approximately 11% of patients will have a final VA below 20/200.<sup>2</sup> Other complications of HSK can include a loss of corneal sensitiv-

ity that often leads to neurotrophic dry eye, delayed epithelial healing and persistent inflammation even when the disease is not in an active stage.

	Year 2	Year 5	Year 7
<b>Risk of HSK Relapse<sup>2</sup></b>	22%	40%	67%

**Clinical pearl:** Limbal dendrites are typically more recalcitrant to treatment than central ones because the immunological armamentarium (antibodies and leukocytes) is abundantly present in the limbal microvasculature.<sup>5</sup>

## HERPES ZOSTER VIRUS

The varicella virus (chickenpox) is the initial or primary infection of the herpes zoster virus (HSV) disease process. Herpes zoster, better known as “shingles” to the general public, is the reactivation of the varicella virus and is seen most commonly in the sixth to seventh decades of life. When an individual is initially exposed to chickenpox, the virus becomes latent in the sensory ganglion of the trigeminal nerve. If the disease is reactivated, the virus will travel down the neural pathways to its respective afferent peripheral nerves and dermatome (an



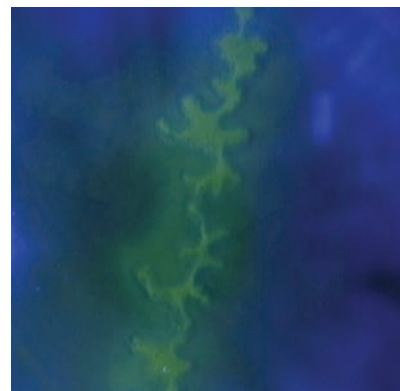
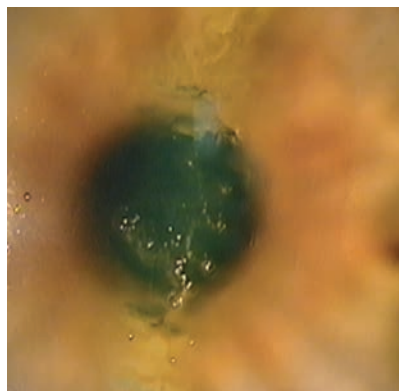
area of skin that is mainly supplied by a single spinal nerve).

A shingles outbreak is always unilateral, and will not cross the midline of the patient, thus making it one of the most recognizable disease processes in medicine. The recurrence of the zoster virus is rather low—less than 6%—as additional outbreaks could lead to the patient to become immunocompromised.<sup>6</sup>

Up to 30% of patients will develop a herpes zoster outbreak in their lifetimes. The prevalence of HZV is well-documented to have increased over the past decade.<sup>7</sup> Each year, nearly one million Americans develop shingles—with the face being the second most common site of infectious development, after the trunk.<sup>8</sup> Fortunately, due to the advent of the childhood Varivax vaccine (live varicella virus, Merck), which came to market in 1995, generations of people will never have shingles because they will never contract chickenpox.

This, however, is a double-edged sword. Prior to the Varivax vaccine, children with chickenpox in various stages of contagion came into contact with adults during the course of daily living, boosting the adult population's immunity against the varicella zoster virus. Since Varivax, such immune-stimulation has diminished each year. Thus, we face another 30 to 50 years of increasing occurrence of shingles in those underexposed patients who have not had sufficient exposure to boost their immunity against it. As such, clinicians need to be ready to competently care for this expanding population.

*Herpes zoster ophthalmicus* (HZO) is present in up to 25% of all zoster outbreaks, and occurs when the virus affects the first branch of the trigeminal nerve (V1, or the ophthalmic branch).<sup>9</sup> A long-held clinical belief has been that, if the tip of the nose is involved (Hutchinson's sign), indicating involvement of the nasociliary



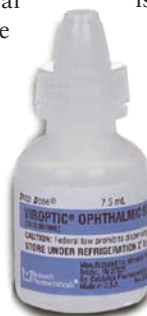Herpes simplex epithelial keratitis without (left) and with (right) cobalt blue filter. Since the location of this presentation involves the visual axis, vision will be temporarily compromised.

nerve that innervates corneal and intraocular tissues), the eye is, too. With the first branch innervating the structures of the eye, it is easy to see why nearly every ocular tissue can be affected by a viral reactivation.

Ocular involvement of HZO presents as an inflammatory keratitis, uveitis, conjunctivitis or a combination of all three. Uveitic involvement manifests as inflammatory cells in the anterior chamber, corneal involvement as stromal inflammation and conjunctival involvement as unilateral injection, to varying degrees. An elevated intraocular pressure may occur if the trabecular meshwork is inflamed. Should the IOP be sufficiently elevated, a temporary reduction can be accomplished with a topical beta-blocker such as timolol and/or the alpha-adrenergic agonist brimonidine, for a few days. Conjunctival injection will accompany these scenarios to some degree.

Treatment for ocular involvement

is available in topical and oral form; now let's look at our options.

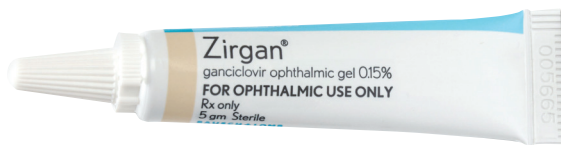

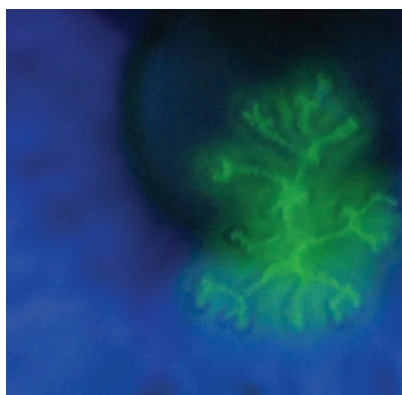
### TOPICAL THERAPY

Ocular HSV keratitis responds well to either Zigan (ganciclovir gel 0.15%, Bausch + Lomb) or Viroptic (trifluridine 1%, Pfizer and generic). If the disease is confined to the epithelium, never treat with topical steroids, as that can enhance viral replication that could progress to a potentially sight-threatening geographic ulcer.

Ganciclovir 0.15% (preserved with benzalkonium chloride) is a more advanced option than trifluridine 1%, allowing for less frequent dosing, in turn decreasing risk of toxicity. Patients should instill one drop into the affected eye five times daily until the corneal ulcer heals, then one drop three times daily for a week. Remember that ganciclovir is available as a gel only. Dosed appropriately, most HSK cases resolve over the course of two weeks or less.

For patients with ocular involvement in the setting of HZO, the strategy is quite different. Typically, an aggressive approach with cycloplegia and topical steroids is deployed. We prescribe homatropine 5% BID to QID,





Classic image of acute herpes simplex epithelial keratitis.

along with Durezol (difluprednate 0.05%, Novartis) every one to two hours for a few days until the inflammation is well controlled. Only then is tapering initiated.

Recurrent flare-ups may require maintenance therapy as a prophylactic measure. Once the inflammation is brought fully under control with Durezol, we switch the topical steroid to Lotemax gel. The sequence would be something like this: TID for one month, BID for two to four months and then once daily for several more months. The goal is to find the minimum therapeutic dosing to achieve the desired result.

It should be noted that some pharmacies in certain locations don't always stock topical antivirals, so oral therapy can be an equally effective, and less expensive, approach.

Herpes Simplex	Herpes Zoster
Acyclovir 400mg 5x/day for 7 to 10 days	Acyclovir 800mg 5x/day for 7 to 10 days
Valacyclovir 500mg TID for 7 to 10 days	Valacyclovir 1,000mg TID for 7 to 10 days
Famciclovir 250mg TID for 7 to 10 days	Famciclovir 500mg TID for 7 to 10 days

## ORAL THERAPY

When shingles presents as an uncomplicated skin disease accompanied by pain, erythema and vesicular expression, we recommend an oral antiviral for seven to 10 days. We find three such medications equivalent in their therapeutic effectiveness (dosed specifically for zoster disease):

- **Acyclovir 800mg** five times daily
- **Valacyclovir 1,000mg** three times daily
- **Famciclovir 500mg** three times daily

Interestingly, some research advocates the use of famciclovir over acyclovir and its prodrug valacyclovir in adults >65 years of age with or without reduced renal function. This is due to findings that valacyclovir and acyclovir carry an increased risk of central nervous system adverse reactions (agitation, confusion, encephalopathy) and acute renal failure compared with famciclovir.<sup>10,11</sup> Moreover, in lactose-intolerant patients, valacyclovir is preferred. In children, the oral suspension form of acyclovir is a prudent option.

The three aforementioned oral antivirals are generic. Acyclovir tends to be less expensive than valacyclovir or famciclovir, but is dosed five times a day. As a quick rule of thumb, the dosage of the antiviral drug is halved to treat simplex disease.

Remember that antiviral medications are most efficacious during the early, replicative phase of the infection (initial 72 hours). This does not mean that after three days, the opportunity for medical intervention has passed, just that there is decreasing clinical efficacy with each day of delayed care. With more virulent expressions, especially in older individuals, concurrent therapy with oral prednisone (usually 40mg to 60mg/day for a week) can be valuable in decreasing pain and inflammation, and may dampen the expression of post-herpetic neuralgia.

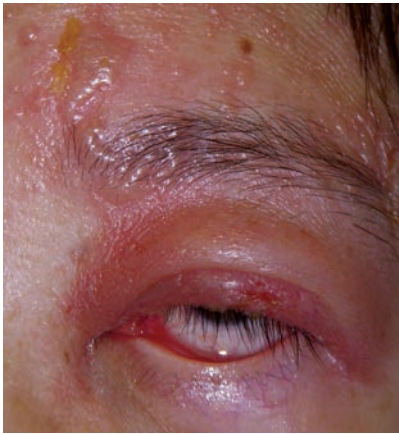Oral antivirals are extremely safe and effective. Their only Achilles' heel is that they are metabolized by the kidneys. Thus, if a patient has clinically significant renal disease, the antiviral dosage must be

## TOPICAL THERAPY FOR HERPES SIMPLEX/ZOSTER

BRAND NAME	GENERIC NAME	MANUFACTURER	PEDIATRIC USE	PREPARATIONS	DOSING
Viroptic	trifluridine 1%	Pfizer	6+	solution	8x/day
Zirgan	ganciclovir 0.15%	Bausch + Lomb	2+	gel	5x/day

## ORAL THERAPY FOR HERPES SIMPLEX

BRAND NAME	GENERIC NAME	MANUFACTURER	PEDIATRIC USE	HSV DOSE	HZV DOSE
Zovirax	acyclovir	GlaxoSmithKline	Adjusted dose for infants	400mg 5x/day	800mg 5x/day
Valtrex	valacyclovir	GlaxoSmithKline	Adjusted dose for infants	500mg TID	1,000mg TID
Famvir	famciclovir	Novartis	Adjusted dose for infants	250mg TID	500mg TID



A patient exhibiting HZO. Note the first division, trigeminal distribution, dermatological vesicles, the edema to the upper eye lid and the mild ocular inflammation. Treatment would include an oral antiviral and a topical corticosteroid. Oral prednisone (40mg) for a week could also be considered depending upon the pain level of the patient.

reduced. A phone consultation with the patient's primary care physician, nephrologist or pharmacist is of utmost importance in determining optimum dosages in the setting of renal disease.

## THE HERPETIC EYE DISEASE STUDY

Originally undertaken to evaluate the usefulness of oral acyclovir in stromal HSV disease, the Herpetic Eye Disease Study (HEDS)—which consisted of five randomized, placebo-controlled trials to determine the

best treatment options and prophylaxis against HSV keratitis—looked at more than 700 patients with various manifestations of ocular HSV infection.<sup>12</sup>

The study concluded that:

- The placebo group had a 32% cumulative probability of ocular HSV recurrence during the first 12 months.
- Epithelial disease alone did not make future recurrences more likely, but stromal disease definitely did.
- With regards to patients who had epithelial dendrites, oral acyclovir did not reduce the rate of stromal disease.
- Oral acyclovir did not improve outcomes in stromal keratitis cases, nor did it prevent stromal involvement.
- Stromal disease was best managed with topical steroids, which did not increase the rate of recurrence.

As revealed in the Acyclovir Prevention Trial, oral acyclovir 400mg dosed BID for one year resulted in a 45% decrease in the chance of recurrence for all forms of ocular involvement. However, the effect was stopped upon discontinuation of the drug.<sup>13</sup> This research points to the importance of potential lifetime treatment with oral acyclovir in patients who have two or more outbreaks in a year, or a recurrent disciform keratitis. Newer data show a parallel effect with a single 500mg dose of valacyclovir.

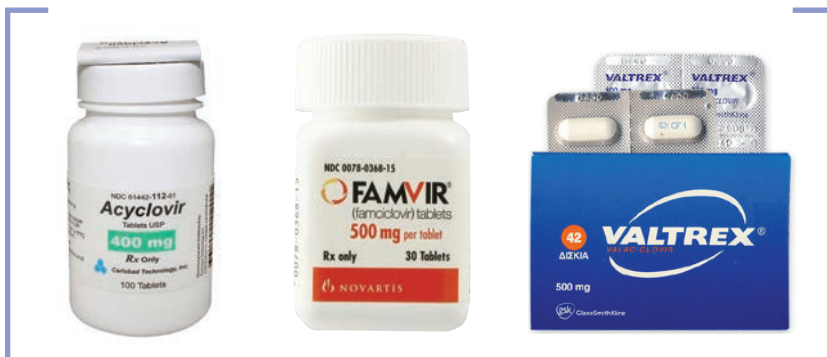While acyclovir was used in the HEDS, it is our belief that the other antivirals would have a similar

effect. We do know that a single 500mg dose of valacyclovir is equivalent to 400mg of acyclovir BID for long-term suppression therapy when needed.

## SHINGLES OUTLOOK LOOKS BRIGHT—EVENTUALLY

With the advent of the childhood Varivax vaccine, generations of people will never have shingles, as they never contracted chicken pox. This leaves a sizable majority of the adult population underexposed to the virus, diminishing their immunity and increasing the prevalence of the disease for the next several decades. It is critical that this population is swiftly and effectively treated when it arises in our offices and clinics. **DG**

1. Waggoner-Fountain LA, Grossman LB. Herpes simplex virus. *Pediatr Rev.* 2004 Mar;25(3):86-93.
2. Reynaud C, Rousseau A, Kaswin G, et al. Persistent impairment of quality of life in patients with herpes simplex keratitis. *Ophthalmology.* 2016; Nov. 15. [Epub ahead of print].
3. Souza PM, Holland EJ, Huang AJ. Bilateral herpetic keratoconjunctivitis. *Ophthalmology* 2003 Mar;110(3):493-6
4. Darougar S, Wishart MS, and Viswalingam ND. Epidemiological and clinical features of primary herpes simplex virus ocular infection. *Br J Ophthalmol.* 1985 Jan;69(1):2-6.
5. Dua HS, Gomes JA, Singh A. Corneal epithelial wound healing. *Br J Ophthalmol.* 1994 May;78(5):401-8.
6. Tseng HF, Chi M, Smith N, et al. Herpes zoster vaccine and the incidence of recurrent herpes zoster in an immunocompetent elderly population. *J Infect Dis.* 2012 Jul;206(2):190-6.
7. Kawai K, Gebremeskel BG, Acosta CJ. Systematic review of incidence and complications of herpes zoster: towards a global perspective. *BMJ Open.* 2014 Jun 10;4(6):e004833.
8. Harpaz R, Ortega-Sanchez IR, Seward JF; Advisory Committee on Immunization Practices (ACIP) Centers for Disease Control and Prevention (CDC). Prevention of herpes zoster: recommendations of the Advisory Committee on Immunization Practices (ACIP).
9. Catron T, Hern HG. Herpes Zoster Ophthalmicus. *West J Emerg Med.* 2008 Aug;9(3):174-6.
10. Asahi T, Tsutsui M, Wakasugi M, et al. Valacyclovir neurotoxicity: clinical experience and review of the literature. *Eur J Neurol.* 2009;16:457-60.
11. Adair JC, Gold M, Bond RE. Acyclovir neurotoxicity: Clinical experience and review of the literature. *South Med J.* 1994;87:1227-31.
12. Barron BA, Gee L, Hauck WW, et al. Herpetic Eye Disease Study. A controlled trial of oral acyclovir for herpes simplex stromal keratitis. *Ophthalmology.* 1994 Dec;101(12):1871-82.
13. Herpetic Eye Disease Study Group. Acyclovir for the prevention of recurrent herpes simplex virus eye disease. *N Engl J Med.* 1998 Jul;339(5):300-6.



# SMART SELECTION OF ANTIBIOTIC AGENTS

Both the topical and oral forms should be used judiciously to avoid perpetuating antibiotic resistance. Here are strategies to choose the right medicine and dose it correctly.

**R**egarded as one of the greatest discoveries in medicine, antibiotics have been used since the 1940s to treat millions of patients with infections worldwide. However, antibiotics are, in a sense, victims of their own success: dosing has become widespread and overprescribed over time. As a result, some bacteria are now resistant to antibiotics that were once highly effective.

According to a report from the Centers for Disease Control and Prevention, antibiotic resistance causes two million bacterial and fungal illnesses, and 23,000 deaths, yearly.<sup>1</sup> It also results in an annual increase in direct health care costs of \$20 billion, plus \$35 billion in lost productivity.<sup>1</sup> Though most studies on antibiotic resistance have focused on systemic antibiotics, researchers have begun to look at resistance to topical ophthalmic antibiotics.

Given this growing epidemic of antibiotic resistance across medical disciplines, researchers are under increasing pressure from the clinical world to seek out potential new drugs to treat infections.

## RED EYES ARE RARELY INFECTIOUS

We have found that acute red eyes uncommonly derive from bacterial infection. The presence of mucopurulent discharge with acute red eyes is often the result of a bacterial infection. Lacking “discharge,” the acute red eye almost

always results from some expression of inflammation. These inflammatory conditions require corticosteroids, not antibiotics, yet time and time again, clinicians will prescribe an antibiotic drug that does not improve the patient’s condition.

Let’s take a more in-depth look at this class of medicines. There are many antibiotics; however, only a few enjoy—or should enjoy—widespread use.

## BACITRACIN

Available since 1948, bacitracin is only available in ointment form, and is strictly a gram-positive antibiotic often employed in the clinical setting of staphylococcal blepharitis. After warm compresses and lid scrubs, bacitracin can be applied to the lid margins at night before the patient goes to bed for four to six days. However, since tissue inflammation invariably accompanies staphylococcal blepharitis, we more frequently have our patients apply an antibiotic-steroid combination ointment such as generic Maxitrol (dexamethasone/neomycin/polymyxin B) here.

For true bacterial corneal infections, a broad-spectrum antibiotic is always preferred. In such cases, we dose Besivance (besifloxacin ophthalmic suspension, Bausch + Lomb) by day with Polysporin ophthalmic ointment at bedtime (bacitracin/polymyxin B), as the polymyxin B is bactericidal against gram-negative pathogens.



TOPICAL ANTIBIOTIC DRUGS					
BRAND NAME	GENERIC NAME	MANUFACTURER	PREPARATION	PEDIATRIC USE	BOTTLE/TUBE
<b>Fluoroquinolones</b>					
Besivance	besifloxacin 0.6%	Bausch + Lomb	suspension	≥ 1 yr.	5ml
Ciloxan	ciprofloxacin 0.3%	Novartis and generic	sol./oint.	≥ 1 yr./ ≥ 2 yrs.	5ml, 10ml/3.5g
Moxeza	moxifloxacin 0.5%	Novartis	solution	≥ 4 mos.	3ml
Ocuflox	ofloxacin 0.3%	Allergan and generic	solution	≥ 1 yr.	5ml, 10ml
Vigamox	moxifloxacin 0.5%	Novartis	solution	≥ 1 yr.	3ml
Zymaxid	gatifloxacin 0.5%	Allergan and generic	solution	≥ 1 yr.	2.5ml
<b>Aminoglycosides</b>					
Tobrex	tobramycin 0.3%	Novartis and generic	sol./oint.	≥ 2 mos.	5ml/3.5g
Garamycin	gentamicin 0.3%	Perrigo and generic	sol./oint.	N/A	5ml/3.5g
<b>Polymyxin B Combinations</b>					
Polytrim	polymyxin B/trimethoprim	Allergan and generic	solution	≥ 2 mos.	10ml
Polysporin	polymyxin B/bacitracin	generic	ointment	N/A	3.5g
Neosporin	polymyxin B/neomycin/ gramicidin	generic	solution	N/A	10ml
	polymyxin B/neomycin/ bacitracin	generic	ointment	N/A	3.5g
<b>Other Antibiotics</b>					
AzaSite	azithromycin 1%	Akorn	solution	≥ 1 yr.	2.5ml
Ilotycin	erythromycin 0.5%	Perrigo and generic	ointment	≥ 2 mos.	3.5g
Bacitracin	bacitracin 500u/g	Perrigo	ointment	N/A	3.5g

### THE AMINOGLYCOSIDES: GENTAMICIN, NEOMYCIN AND TOBRAMYCIN

The aminoglycosides historically were a go-to drug for optometrists. However, they have taken a back seat with the advent of fluoroquinolones. Today, some clinicians may be reluctant to prescribe the aminoglycosides due to their potential to cause a type IV hypersensitivity reaction. Neomycin is broad-spectrum, but does not cover *Pseudomonas*, which is why it is always packaged with polymyxin B or an antibiotic effective against gram-negative organisms. In our experience, type IV delayed hypersensitivity dermatconjunctivokeratitis reactions are exceedingly rare when the neomycin combination is used for no more than a week.

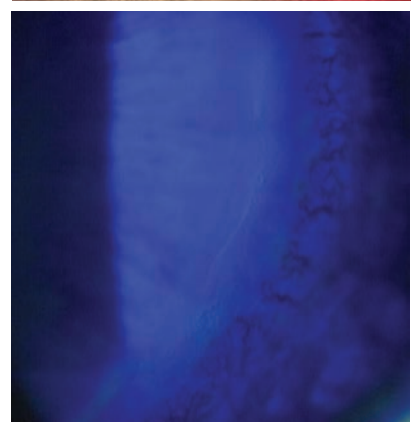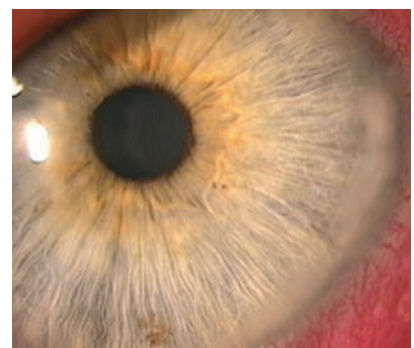### POLYMYXIN B COMBINATIONS

Combination drugs that pair polymyxin B with a complementary gram-

A somewhat atypical peripheral circumlimbal sterile leukocytic infiltrate from 2 o'clock to 5 o'clock, which only minimally stains—a classic finding in all expressions of sterile anterior stromal infiltrates. An antibiotic/steroid such as Zylet is an excellent treatment.

positive agent can extend the total antibiotic coverage achieved.

**Polytrim.** Originally marketed by Allergan and now generically available, Polytrim (polymyxin B/trimethoprim) is an effective combination antibiotic available in solution form. Polymyxin B is active only against gram-negative bacteria. Trimethoprim is broad-spectrum against many gram-positive and some gram-negative bacteria, and works by interfering with the folic acid pathway. Note that trimethoprim itself is not a sulfa drug, although it also inhibits the production of bacterial folic acid.



## CUT THE PILL—AND THE COST—IN HALF

The cost of brand name and generic drugs is continually changing, and clinicians are constantly faced with dynamic and ever-changing pricing structures. Regarding doxycycline, we have found in several instances that the 100mg units are cheaper than the 50mg units. To be more cost-effective for the patient, we will occasionally prescribe 100mg doxycycline monohydrate tablets that can be split in half. Of course, following all these ever-changing price structures can be daunting.

In reality, though, it's not used very often in clinical practice because new studies have found it to be suboptimal against methicillin-resistant staphylococcal epidermis species.

**Polysporin.** This drug, which combines polymyxin B with bacitracin, is available generically but only as an ophthalmic ointment. The pairing of polymyxin B's gram-negative and bacitracin's gram-positive action makes this an excellent, nontoxic, broad-spectrum antibiotic.

The drug is often used in pediatric eye care, and instilled along the lids and lashes, where body temperature melts the ointment and allows adequate ocular surface application of the drug. This approach obviously can be applied to patients of all ages.

In cases of bacterial keratitis or a severe bacterial conjunctivitis, Polysporin ointment can be especially useful at night for sustained antibacterial coverage.

**Neosporin.** This triple-antibiotic of neomycin, bacitracin and polymyxin B is conveniently available generically as an ophthalmic ointment and solution (the solution contains gramicidin, not bacitracin). We rarely use Neosporin in eye drop form due to the aforementioned potential type IV hypersensitivity reaction in some patients. Alternatively, we prefer generic



Polytrim (trimethoprim/polymyxin B), tobramycin or Besivance (Bausch + Lomb), depending on the nature and severity of the infectious condition, as these options are much less prone to cause any type of allergic reaction.

## THE FLUOROQUINOLONES

The options in this class have some notable differences.

**Besifloxacin.** Besivance, a unique, dual-halogenated fluoroquinolone, is the only topical ophthalmic antibiotic that comes as a suspension. As with all fluoroquinolones, Besivance provides activity against DNA gyrase and topoisomerase IV. Its broad-spectrum coverage combats gram-positive, gram-negative (including *Pseudomonas*) and anaerobic organisms, as well as methicillin-resistant *Staphylococcus aureus* (MRSA) and methicillin-resistant *Staphylococcus epidermidis* (MRSE). The latest research (i.e., the ARMOR study) has demonstrated in vitro that besifloxacin and vancomycin share very low MIC<sub>90</sub> levels against the common gram-positive ocular pathogens.<sup>2</sup> This is important in that we know

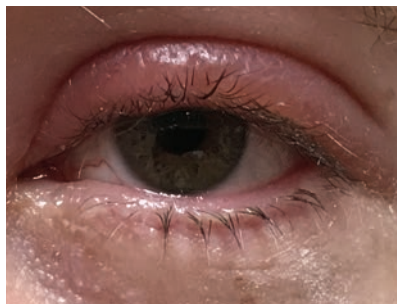how efficacious compounded vancomycin is, and would expect similar *in-vivo* performance with Besivance.

As a suspension, this thick eye drop must be shaken prior to each use. The patient also must refrain from blinking for several seconds after instillation to allow the drop to spread out across, and remain on, the ocular surface. When properly instilled, Besivance has been shown to maintain very high concentrations on the ocular surface, with minimal systemic exposure.

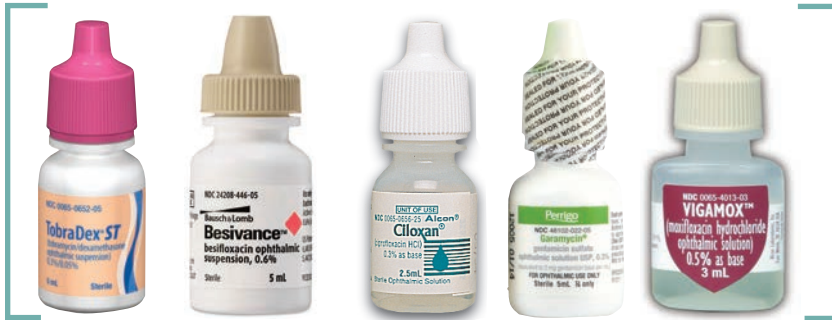An *Ophthalmology and Therapy* study finds: "Large randomized, controlled clinical trials have established the efficacy and safety of besifloxacin administered three times daily for five days for the treatment of acute bacterial conjunctivitis in both adults and children, with high rates of clinical resolution (up to more than 70% by day five) and bacterial eradication (more than 90% by day five), and a low incidence of adverse effects."<sup>3</sup>

For severe infectious processes such as microbial keratitis, we dose Besivance hourly (while awake) for one to three days, then taper the dose to every two hours for a few more days, then to four times a day for a few more days. Depending upon the severity and character of the infectious process, we may adjunctively prescribe Polysporin or Neosporin ointment at bedtime. Practically speaking, Besivance is a white viscous drop that can bother some patients, so patients should be advised of its consistency.

**Ciprofloxacin.** Ciloxan, a second-generation fluoroquinolone, remains a drug of choice against the gram-negative *Pseudomonas* species, and remains close in efficacy to the



An infected, tender LUL of four days' duration. Cephalexin (Keflex) 500mg BID was prescribed along with aggressive use of warm soaks.



fourth-generation fluoroquinolones. Note that generic forms of the drug can be less expensive for the patient.

**Moxifloxacin.** Two popular fourth-generation fluoroquinolones—topical moxifloxacin 0.5% available as Moxeza (Novartis) and Vigamox (Novartis)—function similarly. Of clinical note, Vigamox and Moxeza are the only preservative-free ophthalmic fluoroquinolone antibiotics, thus minimizing the potential for a toxic or allergic response (although such is exceedingly rare). Patients should be informed that the drop has a slight yellow color, to avoid the misconception that it has gone bad.

**Ofloxacin.** A second-generation fluoroquinolone, ofloxacin is rarely used. However, because the drug is generic, it remains a reasonable, inexpensive option for bacterial conjunctivitis. It is also available as brand-name Ocuflax (Allergan).

**Gatifloxacin.** A fairly effective fourth-generation fluoroquinolone, Zymaxid is FDA-approved to treat bacterial conjunctivitis. While useful and generically available, fourth-generation fluoroquinolones are exhibiting increasing bacterial resistance.

## SYSTEMIC AGENTS

Oral antibiotics remain wonderful options when used judiciously in patient care. Their clinical indications are vast, and can be used in short-term therapy (such as for internal hor-

deolum) to long-term or maintenance therapy (for meibomian gland disease and rosacea blepharitis).

For an acute internal hordeola, we prefer the first-generation cephalosporin, cephalexin (Keflex), at 500mg BID for one week. If the condition is severe and/or the patient is large in size, 500mg QID for one week may be indicated. This predominantly gram-positive antibiotic, along with warm soaks, has been shown to improve acute hordeola in about a week. We may also prescribe generic Maxitrol ointment at night to the lid margins to use after warm compresses and lid scrubs. This will be covered in the combination drug section.

Patients tend to have allergies to antibiotics more than other classes of drugs. Always take a careful medical history to avoid the risk of an allergic reaction. If a patient has had a true anaphylactic reaction to penicillin or penicillin-like drugs such as cephalosporins, we opt for Levaquin (500mg QD) or doxycycline (200mg QD), or Bactrim DS or Septra DS (both common brand names of trimethoprim with sulfamethoxazole) prescribed

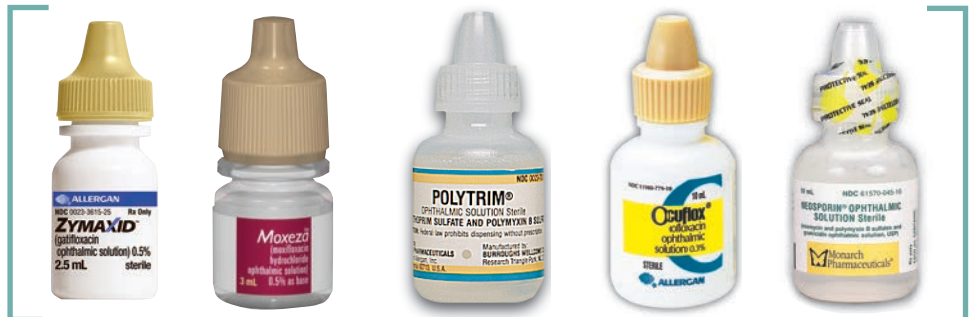as two double-strength tablets BID for one week, which is the standard, commonly prescribed dosage.

If the patient is truly allergic to penicillin and sulfa, consider oral doxycycline 100mg BID for one week, or the oral fluoroquinolone levofloxacin 500mg once daily for one week. For perspective, the risk of a cross-sensitivity reaction of a cephalosporin in a patient truly allergic to penicillin is about 0.1%—but why ever take the miniscule risk? Just prescribe an alternative class.

As well, the extremely rare occurrence of tendonitis or tendon rupture associated with oral fluoroquinolone use makes this class our last option.

Occasionally, we encounter patients who need antibiotic treatment for chronic care conditions such as meibomian gland disease or rosacea blepharitis. We prescribe doxycycline at 50mg daily for three to six months. The dichotomous nature of doxycycline (anti-infective at high dosage and anti-inflammatory at low dosage) requires customized dosing.

Though doxycycline hyclate and doxycycline monohydrate are well-tolerated, the monohydrate form appears to be a bit better tolerated. **DG**



- Centers for Disease Control and Prevention. Antibiotic Resistance Threats in the United States, 2013. Available at: <https://www.cdc.gov/drug-resistance/threat-report-2013/> (last accessed March 14, 2018).
- Asbell PA, Sanfilippo CM, Pillar CM, et al. Antibiotic resistance among ocular pathogens in the United States: Five-Year results from the antibiotic resistance monitoring in ocular microorganisms (ARMOR) surveillance study. *JAMA Ophthalmol.* 2015 Dec;133(12):1445-54.
- Mah FS, Sanfilippo CM. Besifloxacin: Efficacy and safety in treatment and prevention of ocular bacterial infections. *Ophthalmol Ther.* 2016 Jun; 5(1):1-20.



