

THERAPEUTIC REVIEW: Matching Glaucoma Drugs with Kids, p.76

REVIEW[®] OF OPTOMETRY

December 15, 2018

www.reviewofoptometry.com

SURGERY and the OD

More and more,
you make the call.
Get up to speed on
your role in modern
comanagement
strategies.



24TH ANNUAL SURGERY REPORT

Adding Minor Surgical Procedures to the Optometric Office, p. 36

The Preoperative Ocular Surface Checkup, p. 42

Understanding the Role of IOL Optics in Postoperative Vision Complaints, p. 48

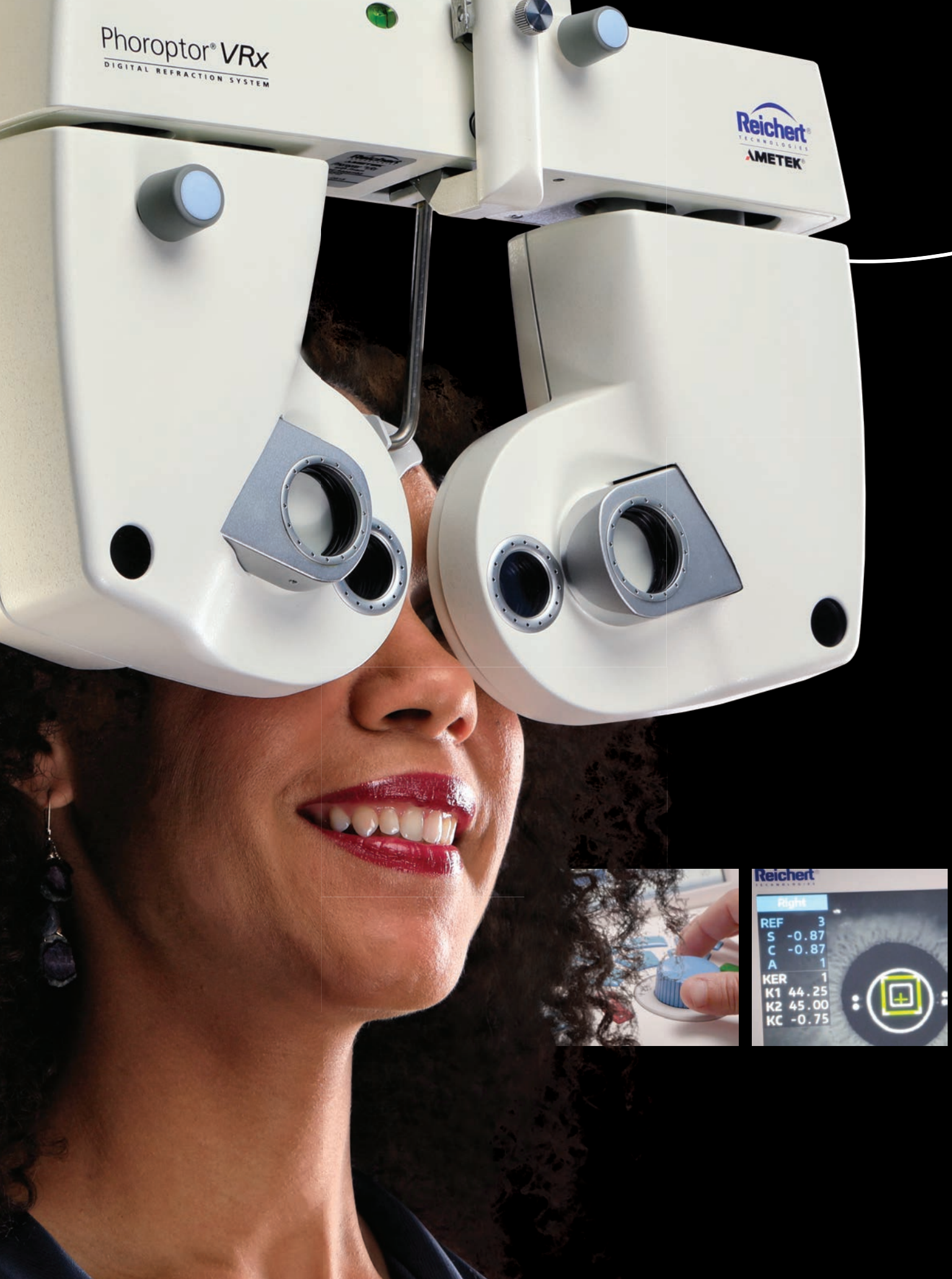How to Assess the Risk of Post-LASIK Ectasia, p. 52

MIGS: Follow the Fluid Trail, p. 58

ALSO — 2018 Income Survey: Where Do You Stand?, p.32


Phoroptor® VRx
DIGITAL REFRACTION SYSTEM

Reichert®
TECHNOLOGIES
AMETEK®



Reichert
TECHNOLOGIES

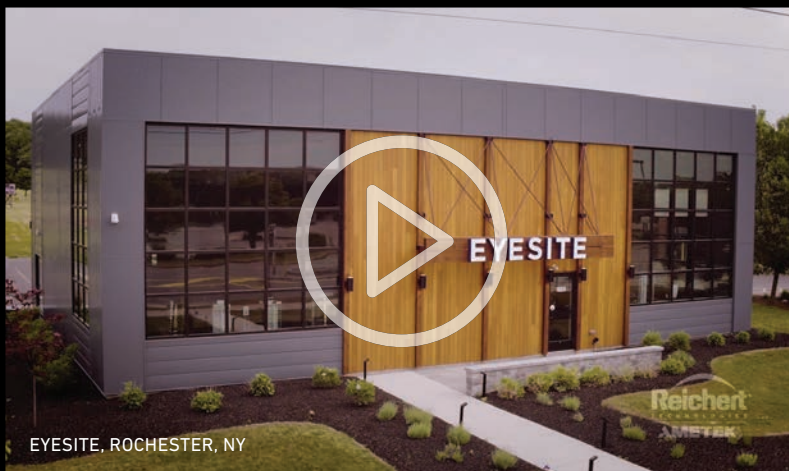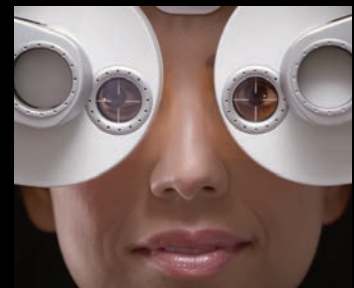Right	
REF	3
S	-0.87
C	-0.87
A	1
KER	1
K1	44.25
K2	45.00
KC	-0.75



Passionate About Eye Care!

We share your **passion for patient experience** with our complete line of digital refraction devices, featuring the most advanced Phoroptor® ever, **Phoroptor® VRx**, and our pixel-perfect **ClearChart® 4** family of digital acuity systems.

**INTRODUCING OUR 'PASSIONATE ABOUT EYE CARE VIDEO SERIES':
WATCH AT REICHERT.COM/PASSIONATE**



reichert.com

IN THE NEWS

Researchers found that arteriolar and venular **blood flow velocities may be reduced in eyes of patients with multiple sclerosis (MS)**. Because the reduction was found in patients both with and without optic neuritis history, they believe that global blood flow alterations may be a possible part of the disease process in that cohort. They concluded that relatively higher blood flow velocities could be physiologically relevant for visual function in MS.

Wang L, Kwakji O, Nguyen J, et al. Microvascular blood flow velocities measured with a retinal function imager: inter-eye correlations in healthy controls and an exploration in multiple sclerosis. *Eye Vis (Lond)*. November 2, 2018. [Epub ahead of print].

Type 2 **diabetes patients with poor metabolic control were more likely to present with dry eye disease (DED)** in a large Chinese study. The researchers found that 17.5% of the 1,360 patients were diagnosed with DED. They note that there was a significant association between the presence of DED and higher blood glucose and higher levels of glycosylated hemoglobin HbA1c.

Zou X, Lu L, Xu Y, et al. Prevalence and clinical characteristics of dry eye disease in community-based type 2 diabetic patients: the Beijing Eye Study. *BMC Ophthalmol*. 2018;18(1).

A retrospective case series 81 eyes of 48 patients who had undergone **cataract surgery more than 10 years previously** found the mean corneal **endothelial cell density (ECD) loss** rate was about **20%**. Pre-op nuclear firmness was most statistically correlated with 10-year ECD loss. The degree of postoperative corneal edema was also a significant predictive factor of 10-year ECD loss after cataract surgery.

Choi JY, Han YK. Long-term (≥10 years) results of corneal endothelial cell loss after cataract surgery. *Can J Ophthalmol* 2018 Nov 10; Epub Ahead of Print.

Schools Still Grappling With Board Scores

Overall pass rates are slightly higher but not enough to signify demonstrable progress.

By Bill Kekevan, Senior Editor

Last year, the Association of Schools and Colleges of Optometry made waves in the educational community when it released the National Board of Examiners in Optometry Yearly Performance Report for the first time publicly. The data's release left some schools in a bind to repair their reputations. A year later, new data shows slight increases in the ultimate pass rates, as well as the Part III first-time pass rates.¹

In the previous year's report, the lowest ultimate pass rate was 68.42% (Western University). This year, that institution's ultimate pass rate was 81.67%. However, this year's overall lowest score was slightly lower than last year's at 67.31% (Massachusetts College of Pharmacy and Health Sciences), down more than seven percentage points from that institution's previous numbers.

Southern College of Optometry (SCO) maintained its top spot with the same 100% ultimate pass rate as the previous year.¹ SCO (as well as University of Alabama at Birmingham) requires its optometry students to pass parts I and II of the boards, but not part III for graduation. University of Alabama at Birmingham's ultimate

pass rate this year was 97.73%. Michigan College of Optometry required parts I and II in previous years, but adjusted their requirements so that students need to take parts I, II and III, but not necessarily pass, to graduate. Nonetheless, its ultimate pass rate was 94.29%.¹

After last year's publication, administrators sought to clarify their policies regarding the board exams. For instance, Salus University's Dean Melissa Trego released an explanatory video online after the school's part I scores showed only 67.11% passing the first time.² That number is down to 55.21% this year. Dr. Trego vowed last year to end a program that allowed third-year students to work in an off-campus clinic in January to help prepare for part I of the boards. "Ultimately, when students graduate, they are able to pass part one," Dr. Trego said in that statement.² Salus's ultimate pass rate this year was 85.28%, up a bit from last year's 84.21%.¹

1. ASCO. NBOE 10/2017 – 9/2018 Institutional yearly performance report. optometriceducation.org/national-board-of-examiners-in-optometry-yearly-performance-report/. December 3, 2018. Accessed December 3, 2018.

2. National board of examiners in optometry pass rates. Salus University. www.salus.edu/Colleges/Optometry/Doctor-of-Optometry---Traditional-Program/NBEO-Pass-Rates.aspx.

NEWS STORIES POST EVERY WEEKDAY MORNING AT www.reviewofoptometry.com/news

Technology in balance



Health




Vision



Comfort

Miru 1 month: a unique family of silicone hydrogel monthly lenses.

MeniSilk™ and Nanogloss™ technologies designed to meet the demands of today's contact lens wearer.*



Material and surface technologies

MeniSilk™

- Ultra high Dk/t - 161 @ -3.00D
- Exceptional hydration
- Optimized transparency

Nanogloss™

- Super smooth surface
- Resistance to bacteria
- Excellent wettability



www.meniconamerica.com

*Menicon data on file April 2016



Elderly Need Earlier, More Regular Refractions

Doing so could help reduce vision-associated cognitive decline.

A team of Chinese researchers evaluated 3,127 elderly patients in an effort to examine and understand more about the associations between cognitive function and ophthalmological parameters.

They found that while the causal relationship remains unclear, the association of lower cognitive function with under-corrected visual acuity suggests the need for earlier and more regular refraction testing in elderly patients to ensure adequate glasses are provided and vision-associated cognitive decline is reduced.

This research—part of the population-based Beijing Eye Study—used the mini-mental state examination to assess and score cognitive function. The researchers found that the mean cognitive function score (CFS) was 26.3 \pm 3.7, with a prevalence breakdown as shown in the table.

The study authors note that bet-

Cognitive Impairment	CFS Range	Prevalence
Mild	23–19	9.6%
Moderate	18–10	3.2%
Severe	<10	0.6%

ter cognition was significantly associated with a better best-corrected visual acuity, smaller amount of under-corrected visual acuity, lower prevalence of primary angle-closure glaucoma and greater subfoveal choroidal thickness. They add that the prevalences of age-related macular degeneration, open-angle glaucoma, diabetic retinopathy, cataract, retinal vein occlusion and pseudoexfoliation were not significantly correlated with CFS.


Jonas JB, Zhu LP, Wang YX, et al. Cognitive function and ophthalmological diseases: the Beijing Eye Study. *Scientific Reports*. 2018;8(1).

Prolonged Reading Worsens Dry Eye

To demonstrate the effects of prolonged silent reading on tear film and ocular surface parameters, researchers from Johns Hopkins evaluated 177 patients with dry eye (DE) and 34 healthy patients. The team found that quantifying DE after having patients perform visually straining activities such as prolonged reading may help researchers better understand patient symptomatology. They add that evaluating tear film and ocular surface parameters at rest may cause researchers to miss clinical findings brought about by common everyday tasks, leading to discordance between patient-reported symptoms and clinician-observed signs.

In this prospective observational clinical study, the Maryland researchers first evaluated patient symptoms using the Ocular Surface Disease Index (OSDI) questionnaire. They then performed a series

Photo: Michelle M. Hassen, OD



Corneal and conjunctival staining increased after 30 minutes of reading.

of five tests—automated noninvasive tear break-up time (TBUT), surface asymmetry and regularity indices, Schirmer's testing without anesthesia, corneal staining using fluorescein and conjunctival staining using lissamine green—both before and after patients read a 30-minute validated passage silently.

The team observed that all parameters, with the exception of surface asymmetry index, worsened

after the reading task in all patients. The worsening was statistically significant for corneal and conjunctival staining in the DE group and for corneal staining in controls.

At baseline, the team found that OSDI scores correlated only with corneal and conjunctival staining scores, and among postreading measurements, with break-up time and corneal and conjunctival staining. They note that changes in TBUT and Schirmer's test correlated significantly with their respective baseline values, indicating that the more unstable the tear film and the lower the aqueous tear secretion, the worse they become after the prolonged reading task. They add that worsening in corneal staining directly correlated with the baseline conjunctival staining and surface regularity index.

Karakus S, Agrawal D, Hindman HB, et al. Effects of prolonged reading on dry eye. *Ophthalmology*. 2018;125(10):1500-5.

THE JOURNEY TO **IMPROVED VISION** STARTS WITH *YOU*

Successful cataract surgery often depends on strong collaboration between patients, optometrists, and surgeons. **Alcon is here to support YOU** in building those partnerships.

Alcon Surgical Offerings

- The AcrySof® family of IOLs has been implanted over **100 MILLION TIMES**¹ – more than any other brand – and provides exceptional quality, clarity, and stability.²⁻⁴
- Our full range of products helps you meet each individual's needs, including astigmatic and presbyopic patients.
- We provide resources to support collaborative care between the optometrist and ophthalmologist.

Visit myalcon.com/cataractresources to order resources for your patients and your practice.

Alcon A Novartis
Division

 AcrySof® IQ IOL Family

References: 1. Alcon sales data on file. 2. Wirtitsch MG, Findl O, Menapace R, et al. Effect of haptic design on change in axial position after cataract surgery. *J Cataract Refract Surg.* 2004;30(1):45-51. 3. Visser N, Bauer NJ, Nuijts RM. Toric intraocular lenses: Historical overview, patient selection, IOL calculation, surgical techniques, clinical outcomes, and complications. *J Cataract Refract Surg.* 2013;39(4):624-637. 4. Potvin R, Kramer BA, Hardten DR, Berdahl JP. Toric intraocular lens orientation and residual refractive astigmatism: An analysis. *Clin Ophthalmol.* 2016;10:1829-1836.

© 2018 Novartis 04/18 US-ODE-18-E-0547a

AcrySof® Family of Single-Piece IOLs

Important Product Information

(AcrySof® UV, AcrySof® IQ, AcrySof® IQ Toric, AcrySof® IQ ReSTOR®, and AcrySof® IQ ReSTOR® Toric IOLs)

CAUTION: Federal law restricts these devices to sale by or on the order of a physician. **INDICATION:**

The family of AcrySof® single-piece intraocular lenses (IOLs) includes AcrySof® UV-absorbing IOLs ("AcrySof® UV"), AcrySof® IQ, AcrySof® IQ Toric and AcrySof® IQ ReSTOR® and AcrySof® IQ ReSTOR® Toric IOLs. Each of these IOLs is indicated for visual correction of aphakia in adult patients following cataract surgery. In addition, the AcrySof Toric IOLs are indicated to correct pre-existing corneal astigmatism at the time of cataract surgery. The AcrySof IQ ReSTOR IOLs are for cataract patients with or without presbyopia, who desire increased spectacle independence with a multifocal vision. All of these IOLs are intended for placement in the capsular bag. **WARNINGS/PRECAUTIONS:**

General cautions for all AcrySof® and AcrySof® UV IOLs: Careful preoperative evaluation and sound clinical judgment should be used by the surgeon to decide the risk/benefit ratio before implanting any IOL in a patient with any of the conditions described in the Directions for Use that accompany each IOL. Caution should be used prior to lens encapsulation to avoid lens decentration or dislocation. Viscoelastic should be removed from the eye at the close of surgery. **Additional Cautions associated with AcrySof® IQ ReSTOR® IOLs:**

Some patients may experience visual disturbances and/or discomfort due to multifocality, especially under dim light conditions. A reduction in contrast sensitivity may occur in low light conditions. Visual symptoms may be significant enough that the patient will request explant of the multifocal IOL. Spectacle independence rates vary with all multifocal IOLs; as such, some patients may need glasses when reading small print or looking at small objects. Clinical studies indicate that posterior capsule opacification (PCO), when present, may develop earlier into clinically significant PCO with multifocal IOLs. **Additional Cautions associated with AcrySof® IQ Toric, AcrySof® UV Toric and ReSTOR® Toric IOLs:** Optical theory suggests that, high astigmatic patients (i.e. > 2.5 D) may experience spatial distortions. Possible toric IOL related factors may include residual cylindrical error or axis misalignments. Toric IOLs should not be implanted if the posterior capsule is ruptured, if the zonules are damaged, or if a primary posterior capsulotomy is planned. Rotation can reduce astigmatic correction; if necessary lens repositioning should occur as early as possible prior to lens encapsulation. Prior to surgery, physicians should provide prospective patients with a copy of the appropriate Patient Information Brochure available from Alcon informing them of possible risks and benefits associated with the AcrySof® IQ Toric, AcrySof® IQ ReSTOR® and AcrySof® IQ ReSTOR® Toric IOLs. Do not sterilize. Do not store at temperatures over 45° C. Use only sterile irrigating solutions to rinse or soak IOLs. **ATTENTION:** Refer to the Directions for Use labeling for the specific IOL for a complete list of indications, warnings and precautions.

 AcrySof® IQ IOL Family

 Alcon A Novartis Division

© 2018 Novartis 04/18 US-ODE-18-E-0547a

News Review

For more, visit www.reviewofoptometry.com/news

Eye Patch Drug Delivery System Gets Good Marks

A new drug delivery approach consisting of an eye patch with detachable microneedles that are able to penetrate the ocular surface may improve therapy results, according to a study published in *Nature Communications*.

Since ocular barriers often create challenges to drug delivery by topical administration, Singapore researchers created a flexible polymeric eye patch equipped small, detachable needles that act as implanted reservoirs for controlled drug delivery. The investigators said in their paper the patch can be readily applied by gentle and brief thumb pressure on the ocular surface, and liken it to the ease of wearing a disposable contact lens without discomfort or the need of extensive skills and training to put on and wear.

"As the micro-drug reservoirs comprise multiple compartments, they allow the release of the same drug with biphasic kinetics or sequentially release of different drugs for synergistic therapy," they added.

Investigators used corneal neovascularization in mice as the disease model. The study found the delivery of an anti-angiogenic monoclonal antibody (DC101) by the eye patch produced a 90% reduction of the

neovascular area with a single treatment of 1µg dosage. In comparison, eye drop applications—even at a much higher dosage (10µg)—failed to show significant therapeutic effect, researchers noted.

Researchers suggested their drug delivery approach could work for other eye diseases as well. These could include delivery of β-adrenergic receptor blockers or prostaglandin analogs for glaucoma, corticosteroids for anterior uveitis and fluconazole for fungal keratitis. Their eye patch system could also be used for intracorneal delivery of riboflavin to patients with keratoconus without the need of corneal epithelial scraping and debridement, which could avoid postoperative pain, infection and permanent damage often associated with traditional surgical methods, researchers said.

"In summary, the demonstrated microneedle eye patch, which implants micro-drug-reservoirs for localized, controlled and efficient ocular drug delivery in a convenient, safe and painless manner, provides a cost-effective and home-based solution for many ocular diseases," the team noted.

Than A, Liu C, Chang H, et al. Self-implantable double-layered micro-drug-reservoirs for efficient and controlled ocular drug delivery. *Nat Commun*. 2018 Nov 6;9(1):4433.

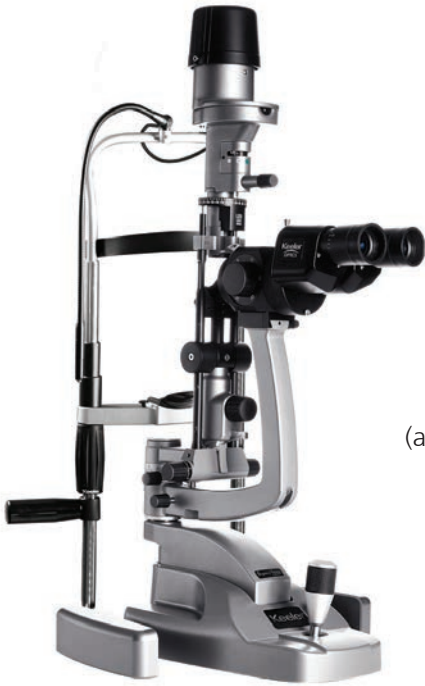Metabolic syndrome increases the risk of heart disease, stroke and diabetes. And so, it seems, of cataract development. In a large prospective study performed in Sweden, 45,049 men aged 45 to 79 years were followed routinely for 15 years, and the cohort was matched with registers of cataract extraction. Excess weight, diabetes and hypertension all correlated with cataract development. Men aged 65 years or younger at baseline with all three components had a relative risk of 2.43 for cataract extraction, the study noted.

Lindblad BE, Niclas Håkansson N, Wolk A. Metabolic syndrome and some of its components in relation to risk of cataract extraction. A prospective cohort study of men. *Acta Ophthalmologica*. Epub ahead of print, October 23, 2018.

The Keeler³ Trade In Program

Buy 3 // Trade 3 // Get 1 Free

The Power of 3. Purchase any 3 Keeler Slit Lamps and trade in 3 of your old Slit Lamps and we'll send you a 4th Keeler Slit Lamp absolutely free of charge.



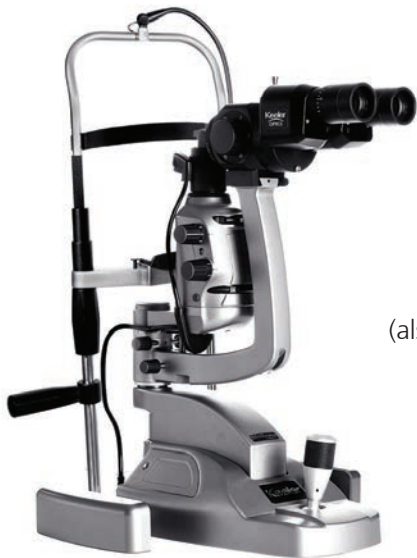KSL-H

(also in Digital Ready)



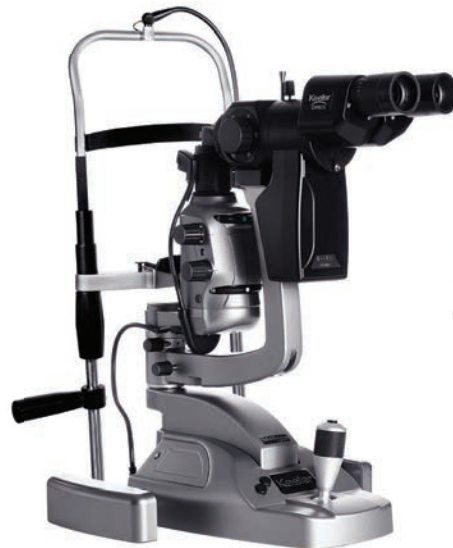KSL-H-D

(full Digital)



KSL-Z

(also in Digital Ready)



KSL-H-D

(full Digital)

Keeler
OPTICS

Keeler Instruments, Inc. • 3222 Phoenixville Pike, bldg. 50 • Malvern, PA 19355
Tel: (800) 523-5620 • Fax: (610) 353-7814 • email: keeler@keelerusa.com


Offer valid until December 31, 2018.

Contact Keeler or one of our authorized dealers for more information.

FROM THE EXPERTS IN LOTEPIEDNOL ETABONATE FOR OVER 20 YEARS

COMING SOON

BAUSCH + LOMB'S NEWEST ARRIVAL



A **NEW** LOTEPIEDNOL ETABONATE FORMULATION

BAUSCH + LOMB

Contents

Review of Optometry December 15, 2018

24TH ANNUAL SURGERY ISSUE

36 Excise and Conquer: Adding Minor Surgical Procedures to the Optometric Office

Learn the basics of these treatment options to provide patients more extensive care. BY JACKIE BURRESS, OD, RODNEY BENDURE, OD, AND LISA KEDZUF, OD

42 The Preoperative Ocular Surface Checkup

Before any invasive procedures, ODs need to clear the patient and pretreat underlying issues. BY BETH NORRIS, OD, SARA HENNEY, OD, LAUREN BARNHART, OD, AND MARIA MANDESE, OD

48 Understanding the Role of IOL Optics in Postoperative Vision Complaints

The more you know about the causes and characteristics of dysphotopsias, the better you'll be at responding to patients' concerns. BY DANIEL H. CHANG, MD, AND LAURA K. HUGGINS, OD

52 Corneal Compromise: How to Assess the Risk of Post-LASIK Ectasia

Before recommending laser vision correction, optometrists can spot patients likely to suffer complications. BY OLIVER KUHN-WILKEN, OD, AND VICTORIA ROAN, OD

58 MIGS: Follow the Fluid Trail

While promising, much remains unknown about these devices and their long-term effect on ocular anatomy.

BY KELLEN R. RICCOBONO, OD, JAN P.G. BERGMANSON, OD, AND LORENZO ANDERSON, BS

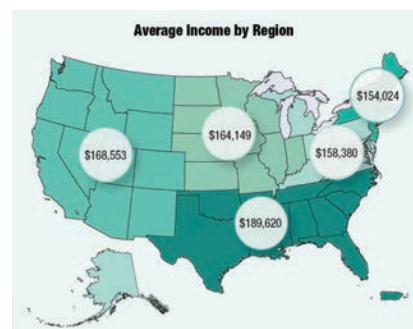


ALSO INSIDE

2018 Income Survey: Where Do You Stand?

Optometry experienced breakthroughs and setbacks this past year. Check out our report to see if you followed the trends, or bucked them.

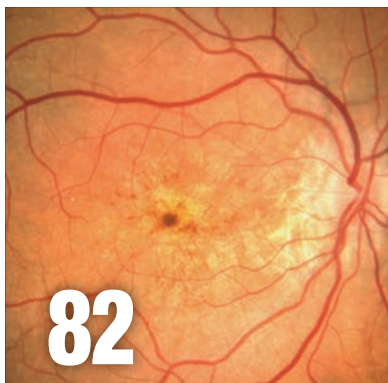
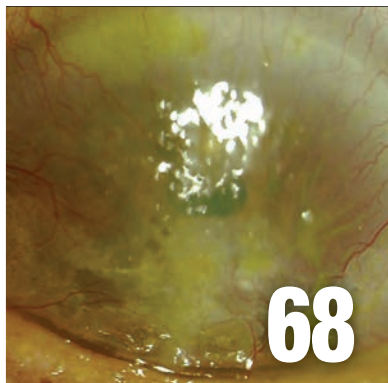
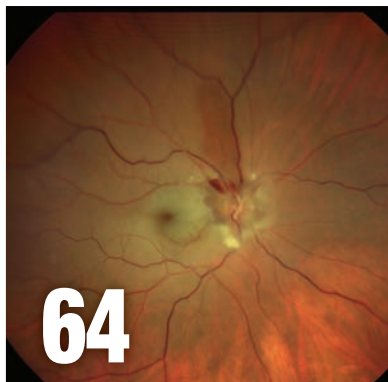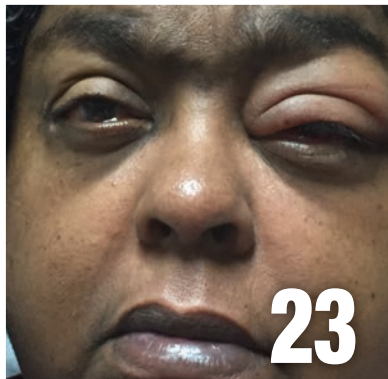BY CATHERINE MANTHORP, ASSOCIATE EDITOR **PAGE 32**



Departments

Review of Optometry December 15, 2018

- 4 News Review**
- 16 Outlook**
Minor Surgery, Major Progress
JACK PERSICO
- 18 Through My Eyes**
Surgical Success Begins with You
PAUL M. KARPECKI, OD
- 20 Chairside**
Speaking of Speaking
MONTGOMERY VICKERS, OD
- 23 Clinical Quandaries**
The Plot Thickens
PAUL C. AJAMIAN, OD
- 24 Focus on Refraction**
Blast From the Past
**MARC B. TAUB, OD, MS,
AND PAUL HARRIS, OD**
- 27 Coding Connection**
Be Precise When Coding Surgery
**JOHN RUMPAKIS, OD, MBA,
CLINICAL CODING EDITOR**
- 64 Retina Quiz**
With a Cherry on Top
**SHREYA JAYASIMHA, OD,
AND MARK T. DUNBAR, OD**
- 68 Cornea + Contact Lens Q&A**
Facts about Vaxx
JOSEPH P. SHOWLIN, OD
- 69 Classifieds**
- 73 Surgical Minute**
Spot Remover
**DESSIE WESTALL, BS, AND
LEONID SKORIN, JR., DO, OD, MS**
- 76 Therapeutic Review**
Matching Glaucoma Drugs With Kids
JOSEPH W. SOWKA, OD
- 79 Glaucoma Grand Rounds**
A Second Opinion on Surgery
JAMES L. FANELLI, OD
- 81 Advertisers Index**
- 82 Diagnostic Quiz**
Orange Crush
ANDREW S. GURWOOD, OD



REVIEW[®] OF OPTOMETRY

BUSINESS OFFICES
11 CAMPUS BLVD., SUITE 100
NEWTOWN SQUARE, PA 19073

CEO, INFORMATION SERVICES GROUP
MARC FERRARA
(212) 274-7062 • MFERRARA@JOBSON.COM

PUBLISHER
JAMES HENNE
(610) 492-1017 • JHENNE@JOBSON.COM

REGIONAL SALES MANAGER
MICHELE BARRETT
(610) 492-1014 • MBARRETT@JOBSON.COM

REGIONAL SALES MANAGER
MICHAEL HOSTER
(610) 492-1028 • MHOSTER@JOBSON.COM

VICE PRESIDENT, OPERATIONS
CASEY FOSTER
(610) 492-1007 • CFOSTER@JOBSON.COM

VICE PRESIDENT, CLINICAL CONTENT
PAUL M. KARPECKI, OD, FFAO
PKARPECKI@JOBSON.COM

PRODUCTION MANAGER
SCOTT TOBIN
(610) 492-1011 • STOBIN@JOBSON.COM

SENIOR CIRCULATION MANAGER
HAMILTON MAHER
(212) 219-7870 • HMAHER@JHIHEALTH.COM

CLASSIFIED ADVERTISING
(888) 498-1460

SUBSCRIPTIONS
\$56 A YEAR, \$88 (US) IN CANADA,
\$209 (US) IN ALL OTHER COUNTRIES.

SUBSCRIPTION INQUIRIES
(877) 529-1746 (US ONLY)
OUTSIDE US CALL: (845) 267-3065

CIRCULATION
PO Box 81
CONGERS, NY 10920
TEL: (TOLL FREE): (877) 529-1746
OUTSIDE US: (845) 267-3065



CEO, INFORMATION SERVICES GROUP
MARC FERRARA


SENIOR VICE PRESIDENT, OPERATIONS
JEFF LEVITZ

VICE PRESIDENT, HUMAN RESOURCES
TAMMY GARCIA

VICE PRESIDENT, CREATIVE SERVICES & PRODUCTION
MONICA TETTAMANZI

CORPORATE PRODUCTION DIRECTOR
JOHN ANTHONY CAGGIANO

VICE PRESIDENT, CIRCULATION
EMELDA BAREA



Discover your Opportunities

With offers available through the Premier Program, our patients are often pleasantly surprised by the value they get at our practice. It's a really nice benefit for doctors who participate.



GEOFFREY E. REYNOLDS, OD, FAAO

RONALD R. REYNOLDS, OD, INC

In an industry full of options, choose a partner that delivers more to your practice — patients, marketing, and savings. Choose Premier!

Don't lose your Premier Indicator.
The semi-annual check-in is December 31.

UNLOCK THE POSSIBILITIES AT [FAMILY.PATHTOPREMIER.COM](https://family.pathtopremier.com)



CONTRIBUTING EDITORS

PAUL C. AJAMIAN, OD, ATLANTA
AARON BRONNER, OD, KENNEWICK, WASH.
MILE BRUJIC, OD, BOWLING GREEN, OHIO
DEREK N. CUNNINGHAM, OD, AUSTIN, TEXAS
MARK T. DUNBAR, OD, MIAMI
ARTHUR B. EPSTEIN, OD, PHOENIX
JAMES L. FANELLI, OD, WILMINGTON, NC
FRANK FONTANA, OD, ST. LOUIS
GARY S. GERBER, OD, HAWTHORNE, NJ
ANDREW S. GURWOOD, OD, PHILADELPHIA
ALAN G. KABAT, OD, MEMPHIS, TENN.
DAVID KADING, OD, SEATTLE
PAUL M. KARPECKI, OD, LEXINGTON, KY.
JEROME A. LEGERTON, OD, MBA, SAN DIEGO
JASON R. MILLER, OD, MBA, POWELL, OHIO
CHERYL G. MURPHY, OD, BABYLON, NY
CARLO J. PELINO, OD, JENKINTOWN, PA.
JOSEPH PIZZIMENTI, OD, FORT LAUDERDALE, FLA.
JOHN RUMPAKIS, OD, MBA, PORTLAND, ORE.
DIANA L. SHECHTMAN, OD, FORT LAUDERDALE, FLA.
JEROME SHERMAN, OD, NEW YORK
JOSEPH P. SHOVLIN, OD, SCRANTON, PA.
JOSEPH W. SOWKA, OD, FORT LAUDERDALE, FLA.
MONTGOMERY VICKERS, OD, ST. ALBANS, W.VA.
WALTER O. WHITLEY, OD, MBA, VIRGINIA BEACH, VA.

EDITORIAL REVIEW BOARD

JEFFREY R. ANSHEL, OD, ENCINITAS, CALIF.
JILL AUTRY, OD, RPH, HOUSTON
SHERRY J. BASS, OD, NEW YORK
EDWARD S. BENNETT, OD, ST. LOUIS
MARC R. BLOOMENSTEIN, OD, SCOTTSDALE, ARIZ.
CHRIS J. CAKANAC, OD, MURRYSVILLE, PA.
JERRY CAVALLERANO, OD, PHD, BOSTON
WALTER L. CHOATE, OD, MADISON, TENN.
BRIAN CHOU, OD, SAN DIEGO

A. PAUL CHOUS, MA, OD, TACOMA, WASH.
ROBERT M. COLE, III, OD, BRIDGETON, NJ
GLENN S. CORBIN, OD, WYOMISSING, PA.
ANTHONY S. DIECIDUE, OD, STROUDSBURG, PA.
S. BARRY EIDEN, OD, DEERFIELD, ILL.
STEVEN FERRUCCI, OD, SEPULVEDA, CALIF.
MURRAY FINGERET, OD, HEWLETT, NY
IAN BEN GADDIE, OD, LOUISVILLE, KY.
PAUL HARRIS, OD, MEMPHIS, TN
MILTON HOM, OD, AZUSA, CALIF.
BLAIR B. LONSBERRY, MS, OD, MED, PORTLAND, ORE.
THOMAS L. LEWIS, OD, PHD, PHILADELPHIA
DOMINICK MAINO, OD, MED, CHICAGO
KELLY A. MALLOY, OD, PHILADELPHIA
RICHARD B. MANGAN, OD, LEXINGTON, KY.
RON MELTON, OD, CHARLOTTE, NC
PAMELA J. MILLER, OD, JD, HIGHLAND, CALIF.
BRUCE MUCHNICK, OD, COATESVILLE, PA.
MARC MYERS, OD, COATESVILLE, PA.
WILLIAM B. POTTER, OD, FREEHOLD, NJ
CHRISTOPHER J. QUINN, OD, ISELIN, NJ
MICHAEL C. RADOIU, OD, STAUNTON, VA.
MOHAMMAD RAFIETARY, OD, MEMPHIS, TN
JOHN L. SCHACHET, OD, ENGLEWOOD, COLO.
JACK SCHAEFFER, OD, BIRMINGHAM, ALA.
LEO P. SEMES, OD, BIRMINGHAM, ALA.
LEONID SKORIN, JR., OD, DO, ROCHESTER, MINN.
JOSEPH W. SOWKA, OD, FORT LAUDERDALE, FLA.
SRUTHI SRINIVASAN, PHD, BS OPTOM, WATERLOO, ONT.
BRAD M. SUTTON, OD, INDIANAPOLIS
LORETTA B. SZCZOTKA, OD, PHD, CLEVELAND
MARC TAUB, OD, MEMPHIS, TN
TAMMY P. THAN, MS, OD, BIRMINGHAM, ALA.
RANDALL THOMAS, OD, CONCORD, NC
SARA WEIDMAYER, OD, ANN ARBOR, MI
KATHY C. WILLIAMS, OD, SEATTLE
KAREN YEUNG, OD, LOS ANGELES

Hiring Optometric Staff?

More Ophthalmic &
Optometric Professionals
find jobs on Local Eye Site
than anywhere else.



Save 20% with coupon
code: **REVOPT**

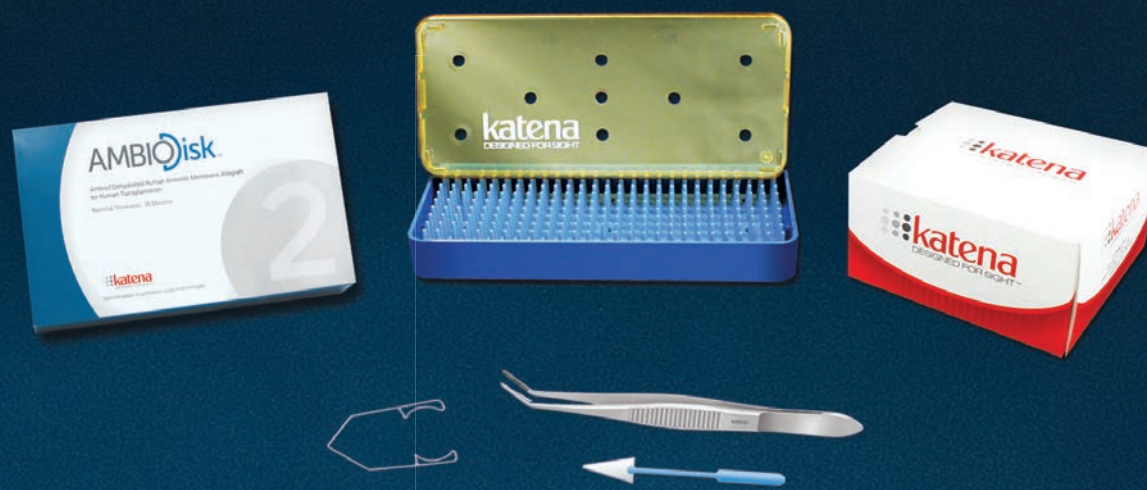
localeyesite.com



HIT THE DRY EYE MARK WITH AMBIOisk®



Launch your adoption of amniotic membrane
with the **Jump Start Kit**. *Call Katena for details!*



Amniotic membrane is considered an appropriate end stage treatment option to address conditions outlined in the DEWS II step 4 guidelines for severe dry eye.*



800.225.1195 • info@katena.com • www.katena.com

*Physicians may choose to use amniotic membrane at their discretion.
REFERENCE: Craig JP, et al., TFOS DEWS II Report Executive Summary,
The Ocular Surface (2017), <http://dx.doi.org/10.1016/j.jtos.2017.08.003>

KB-Adv-011518-Rev0



PRINTED IN USA

FOUNDING EDITOR, FREDERICK BOGER
1891-1913

EDITORIAL OFFICES
11 CAMPUS BLVD., SUITE 100
NEWTOWN SQUARE, PA 19073

SUBSCRIPTION INQUIRIES
1-877-529-1746

CONTINUING EDUCATION INQUIRIES
1-800-825-4696

EDITOR-IN-CHIEF • JACK PERSICO
(610) 492-1006 • JPERSICO@JOBSON.COM

MANAGING EDITOR • REBECCA HEPP
(610) 492-1005 • RHEPP@JOBSON.COM

SENIOR EDITOR • BILL KEKEVIAN
(610) 492-1003 • BKEKEVIAN@JOBSON.COM

ASSOCIATE EDITOR • CATHERINE MANTHORP
(610) 492-1043 • CMANTHORP@JOBSON.COM

ASSOCIATE EDITOR • MARK DE LEON
(610) 492-1021 • MDELEON@JOBSON.COM

SPECIAL PROJECTS MANAGER • JILL HOFFMAN
(610) 492-1037 • JHOFFMAN@JOBSON.COM

ART DIRECTOR • JARED ARAUJO
(610) 492-1032 • JARAUJO@JOBSON.COM

DIRECTOR OF CE ADMINISTRATION • REGINA COMBS
(212) 274-7160 • RCOMBS@JOBSON.COM

EDITORIAL BOARD

CHIEF CLINICAL EDITOR • PAUL M. KARPECKI, OD

ASSOCIATE CLINICAL EDITORS • JOSEPH P. SHOVLIN, OD;
ALAN G. KABAT, OD; CHRISTINE W. SINDT, OD

DIRECTOR OPTOMETRIC PROGRAMS • ARTHUR EPSTEIN, OD

CLINICAL & EDUCATION CONFERENCE ADVISOR
PAUL M. KARPECKI, OD

CASE REPORTS COORDINATOR • ANDREW S. GURWOOD, OD

CLINICAL CODING EDITOR • JOHN RUMPAKIS, OD, MBA

CONSULTING EDITOR • FRANK FONTANA, OD

COLUMNISTS

CHAIRSIDE • MONTGOMERY VICKERS, OD

CLINICAL QUANDARIES • PAUL C. AJAMIAN, OD

CODING CONNECTION • JOHN RUMPAKIS, OD

CORNEA & CONTACT LENS Q+A • JOSEPH P. SHOVLIN, OD

DIAGNOSTIC QUIZ • ANDREW S. GURWOOD, OD

THE ESSENTIALS • BISANT A. LABIB, OD

FOCUS ON REFRACTION • MARC TAUB, OD;
PAUL HARRIS, OD

GLAUCOMA GRAND ROUNDS • JAMES L. FANELLI, OD

NEURO CLINIC • MICHAEL TROTTINI, OD;
MICHAEL DELGIODICE, OD

OCULAR SURFACE REVIEW • PAUL M. KARPECKI, OD

RETINA DILEMMAS • DIANA L. SHECHTMAN, OD;

JAY M. HAYNIE, OD

RETINA QUIZ • MARK T. DUNBAR, OD

REVIEW OF SYSTEMS • CARLO J. PELINO, OD;
JOSEPH J. PIZZIMENTI, OD

SURGICAL MINUTE • DEREK N. CUNNINGHAM, OD;
WALTER O. WHITLEY, OD, MBA

THERAPEUTIC REVIEW • JOSEPH W. SOWKA, OD;
ALAN G. KABAT, OD

THROUGH MY EYES • PAUL M. KARPECKI, OD

URGENT CARE • RICHARD B. MANGAN, OD

JOBSON MEDICAL INFORMATION LLC



Outlook

By Jack Persico, Editor-in-Chief



Minor Surgery, Major Progress

Some ODs are quietly dropping the ‘co’ from ‘surgical comanagement.’ And they just got a surprise new ally.

This publication, founded in 1891, has advocated for scope of practice expansion literally since before the profession had settled on the name *optometry* for itself. Back when practitioners still called themselves opticians and only performed refraction and vision correction, the earliest incarnation of *Review of Optometry* began educating its readers on diagnostic screening. We were also at the front of the pack pushing for the DPA and TPA laws that re-engineered optometry into a primary eye care profession.

The next wave, of course, is surgery. Optometrists need to approach that vast sphere of eye care with caution and humility. Invasive intraocular surgery would be a bridge too far. Procedures that involve sterile ORs, sedation/anesthesia, systemic vital sign monitoring and access to emergency care all belong to the physicians trained for such responsibilities. But there are plenty of simple, low-risk procedures that patients need—and ophthalmologists aren’t always going to be available for in a timely fashion.

That’s why we’re kicking off our annual surgery issue with an article on the minor surgical procedures some ODs already perform and the rest seem destined to. We’re saying, in effect, “this is optometry now.” Not a special case to be reserved for unique circumstances, not something to be apologetic about around your MD colleagues—just plain old mainstream optometry. Of course, it comes with a huge caveat about the need to have the requisite skills, certifications and state licensing. But any OD familiar with scope of practice expansion

knows how to navigate that terrain. Be smart, heed your mentors and don’t rush or overreach.

The case for expansion just got an unexpected endorsement from the Trump administration, as a federal report on the need for increased healthcare competition explicitly advocated for it. “Even well-intentioned regulations may impose unnecessary restrictions on provider supply and, therefore, competition,” the report notes. “When state regulators impose excessive entry barriers and undue restrictions,” the report goes on, “they often are not responding to legitimate consumer protection concerns.” Instead, “healthcare professionals with overlapping skill sets” push back against scope of practice expansion “as an easy, state-sanctioned opportunity to insulate themselves from competition.”

In other words, medical lobby: quit pushing the ‘patients at risk’ canard about the work of non-MDs. The solid track record of ODs who do have expanded privileges shows the fallacy of that fear-mongering.

Still, the American Academy of Ophthalmology tried to spin the report as consistent with its own messaging about the risks of ODs performing procedures. “Nation’s eye physicians and surgeons support executive branch’s emphasis on patient safety,” reads its statement. *Of course* everyone prioritizes safety—including the optometrists who perform these procedures. Absent any evidence of higher complication rates, organized medicine’s tired old narrative is played out. Optometry’s, meanwhile, is finally getting heard. ■

COMING

SOON



©2018 Kala Pharmaceuticals
All rights reserved.
US-INV-1800012 August 2018

INVELTYS™

(loteprednol etabonate
ophthalmic suspension) 1%



Surgical Success Begins with You

Long before they enter the OR, these patients begin their journey—in your office.

By Paul M. Karpecki, OD, Chief Clinical Editor

While the MDs in our field endure decades of training to sharpen their surgical expertise and medical practice, their need to be high-volume surgeons does not allow them to put in the time to thoroughly know each patient to the same extent as their primary care optometrist.

Take me, for example. No matter what I ask a cataract surgery candidate who's referred to our practice in our 10-to-15 minute window, I'll never have the knowledge or trust that their primary care OD worked to establish over the 20+ years of knowing and treating that patient.

As our scope of practice continues to expand, an astute and proactive primary care optometrist, well-versed in the newest medical—as well as surgical—procedures, will play a critical role making early diagnoses and setting the proper sequence of care in motion. This month's annual surgery issue touches on some of those key procedures.

Advise and Consent

The primary care optometrist's role in determining the proper path for ocular surgery can be an important one. About a year ago, I experienced this key role firsthand.

I, for one, am a big fan of toric intraocular lenses (IOLs) for several reasons. When placed internally near the nodal point, they correct astigmatic cataract patients better than what we could do with glasses or contact lenses; they are often less expensive than other premium IOL

offerings, they don't move or rotate and there is minimal peripheral distortion in patients with moderate or low levels of astigmatism. When appropriate, I am inclined to discuss their benefits with a patient and speak highly of their potential.

So, when this particular cataract patient came to me, with 1.00D of with-the-rule astigmatism, I initially considered the go-to toric IOL. Just before speaking with the patient, however, I received a call from my colleague, the patient's primary, emphatically urging me not to use the toric. My colleague had previously tried toric contact lenses and, though an uncommon reaction, this patient was strongly averse to having the cylinder corrected—and of course would have felt the same after cataract surgery. This may have been due to monovision success (or at least familiarity) and the dioptric power the patient preferred.

Either way, this case proved to be a true testament to the value of knowing your patients and conveying valuable information during the referral. A primary's clinical prowess in knowing everything about the patient from ocular surface status to a potential history of HSV as well as their overall personality makes them a critical player on the patient's team of eye doctors.

A Guiding Hand

Another exciting area where a more prominent primary care optometrist role can have a positive impact is with minimally invasive glaucoma

surgery. There are many new technologies emerging ranging from the original iStent (Glaukos) to the Hydrus (Ivantis) and numerous new procedures like the Xen (Allergan) replacing far more invasive trabeculectomy procedures. With all these options comes the responsibility to not only know and understand the variety of procedures, but to know which one is truly right for each patient's unique case.

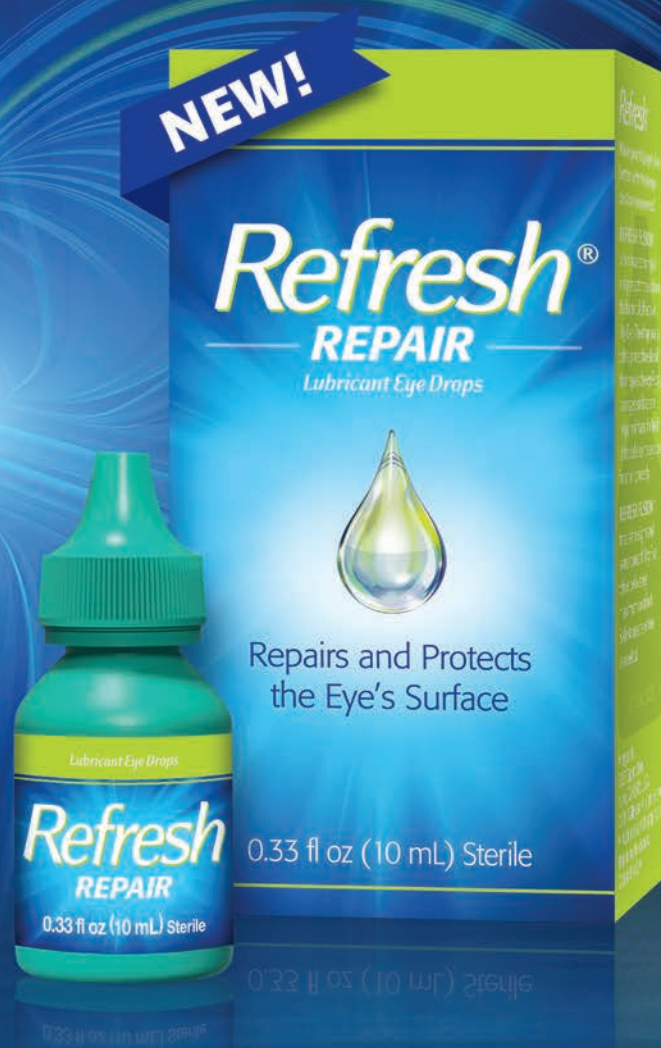Cleared for Surgery


In addition to staying on top of all the new hot tech and tools on the market, the primary care optometrist must remain sharp in all routine care, especially in evaluating the ocular surface. This may mean looking for and managing early signs of blepharitis prior to sending them off for surgery and otherwise ensuring a healthy and well-functioning ocular surface. It means continuing to express meibomian glands for diagnostic purposes, and administering treatment and hydrating compresses. And, it certainly means treating dry eye and the consequential inflammation prior to surgery.

In my practice, it's clear that optometry plays a key role in orchestrating the success of patients about to undergo ocular surgical procedures such as LASIK, cataract surgery and even cataract surgery with MIGS. Understanding this critical role and enhancing your knowledge may contribute to the success of these patients' care more than anything else. ■

INTRODUCING
REFRESH[®] REPAIR

The first and only artificial tear in the U.S.
formulated with CMC, HA,* and Osmoprotectants.



REFRESH[®] REPAIR helps promote healing of the cornea and conjunctival epithelia and improves visual performance in Dry Eye patients. Safe to use with contacts. 

refreshbrand.com/doc | 

 **Allergan.**

*HA is an inactive ingredient.

© 2018 Allergan. All rights reserved. All trademarks are the property of their respective owners. REF115212 05/18

Speaking of Speaking

Optometrists must face down fears of making a public address. Just picture the audience without their glasses on. **By Montgomery Vickers, OD**

As I write this month's column, I am preparing to make the keynote speech at the Ohio Optometric Association's amazing EastWest Eye Conference in lovely downtown Cleveland, Ohio. (My son-in-law, who grew up in Cleveland, made me say that last part.)

I have not spoken in public for many years, as I determined that preparing to speak made me crazy(ier). It was a lot easier to write this column and just fantasize that the readers were extremely entertained than it was to stand up in front of folks when there was a chance my biggest response would be the occasional snore.

They asked. Not sure what got into me, but I said yes. Hmm. OK. Now, what to say?

If These Walls Could Talk (We Wouldn't Have To)

I am not a person who is ever at a loss for words, except of course when someone wants me to get in front of a crowd to speak. Public speaking is a skill that every optometrist should gain. There is no better practice builder than getting up in front of a bunch of soccer moms and telling cute kid stories from your practice. As one of my OD mentors once prescribed, "the cornier the better."

Reminisce about that myopic kid who put on his first glasses and looked at his mom down the hallway and announced "Mom! You are pretty as a picture!" Tears will flow

and your waiting room will grow.

Join Toastmasters. Take night school classes. Read *War and Peace* cover-to-cover to your children, unless they clean up their rooms. Do whatever you have to do to get better at public speaking; it will pay off!

Any Last Words?

Now, the bad news. Public speaking is one of the top 10 greatest human fears. Recent studies rank Fear of Public Speaking at #6. This is just below #5, which encompasses the fear of spiders, rats, cockroaches, snakes, airplanes, monsters, demons, mirrors and the fear of high heels. It ranks just above # 7, the fear of death.

You heard me right. People fear *death* less than people fear PUBLIC SPEAKING.

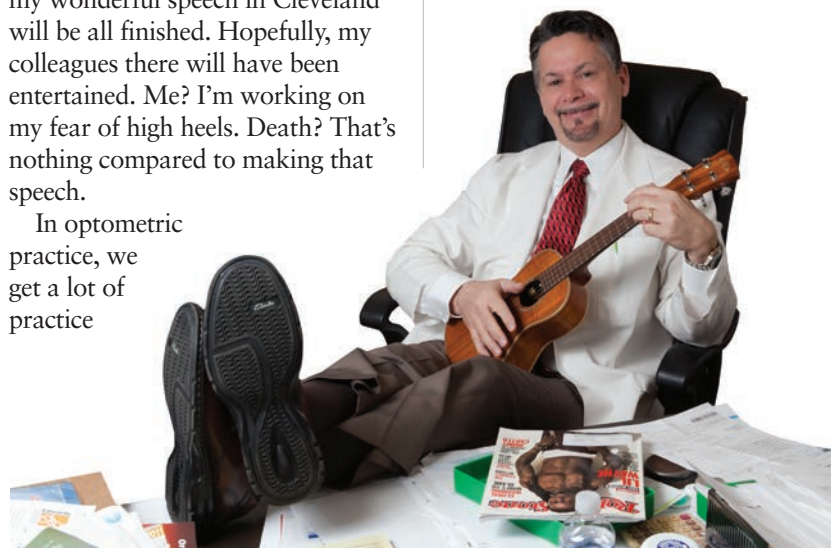By the time you read this, I guess my wonderful speech in Cleveland will be all finished. Hopefully, my colleagues there will have been entertained. Me? I'm working on my fear of high heels. Death? That's nothing compared to making that speech.

In optometric practice, we get a lot of practice

handling fear. We have the fear of misdiagnosing, the fear of the lawsuit that may follow, the fear that a patient won't like his new glasses, and, of course, the fear that we will have to leave late for our lunch hour, our greatest fear of all.

When fear grips your soul and that patient who hates you but will never leave your practice shows up to give you his or her hour of pain, just remember that it could be worse; you could have to wear high heels or make a speech in Cleveland. Death? That's a piece of cake.

On a serious note, I'd like to take this opportunity to salute the career of a wonderful colleague and friend to all, Dr. Frank Fontana. Uncle Frank was always very kind to me and I am very grateful for his words of wisdom, his hugs and his humor. Uncle Frank inspired me to be better. Rest easy, my friend. ■





I didn't realize
STARS
were little dots that twinkled

—Misty L, *RPE65* gene therapy recipient

WE'RE SEEING AMAZING RESULTS. **AND SO ARE THEY.**

Foundation Fighting Blindness is shining a light in the darkness of Inherited Retinal Degenerations. We are the world's leading organization searching for treatments and cures, and with many treatments already found, today's innovations are illuminating a future of possibilities.

Patients with Inherited Retinal Degenerations are urged to partner with us to accelerate the discovery of treatment and cures.

We have robust disease information, a national network of local chapters and support groups, local educational events, and our My Retina Tracker patient registry helps to keep your patients connected with clinical and research advancements.



Visit ECPs4Cures.org
to make a donation
to help find more cures.

FightBlindness.org

FOUNDATION **FIGHTING
BLINDNESS**

Earn up to
18-28 CE
Credits*

NEW TECHNOLOGIES
& TREATMENTS IN
2019 EYE CARE



RGVCE
REVIEW'S COMMITMENT TO
CONTINUING EDUCATION

Join us for our
2019 MEETINGS



FEBRUARY 15-19, 2019 - ASPEN, CO

Annual Winter Ophthalmic Conference

Westin Snowmass Conference Center

Program Co-chairs: Murray Fingeret, OD, and Leo Semes, OD

REGISTER ONLINE: www.skivision.com



MARCH 7-10, 2019 - ORLANDO, FL

Disney Yacht & Beach Club

Program Chair: Paul Karpecki, OD, FAAO

REGISTER ONLINE: www.reviewsce.com/orlando2019



APRIL 11-14, 2019 - SAN DIEGO, CA**

Manchester Grand Hyatt

Program Chair: Paul Karpecki, OD, FAAO



May 17-19, 2019 - NASHVILLE, TN

Gaylord Opryland

Program Chair: Paul Karpecki, OD, FAAO



NOVEMBER 1-3, 2019 - BALTIMORE, MD

Renaissance Baltimore Harborplace

Program Chair: Paul Karpecki, OD, FAAO

Visit our website for the latest information: www.reviewsce.com/events
e-mail: reviewmeetings@jhihealth.com or call: 866-658-1772

Administered by
RGVCE
REVIEW'S COMMITMENT TO CONTINUING EDUCATION



*Approval pending



Pennsylvania College of Optometry



**16th Annual Education Symposium
Joint Meeting with NT&T in Eye Care

RGVCE partners with Salus University for those ODs who are licensed in states that require university credit.
See www.reviewsce.com/events for any meeting schedule changes or updates.



The Plot Thickens

If things are not what they seem, follow your intuition and explore all options.

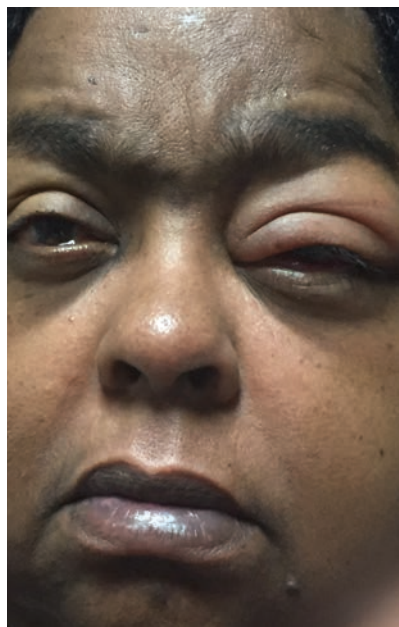Edited by Paul C. Ajamian, OD

Q One of my patients presented with a swollen left eye with lid edema. Where do I go from here?

A While there are many conditions in the differential, first ask if the patient has any prior history of trauma and has noticed any decrease in vision, pain, fever or restricted eye movements, says Jessica Schiffbauer, OD, of Virginia Eye Consultants in Norfolk, VA. “Also ask if the patient has been exposed to any chemicals or foreign materials in order to rule out an allergic reaction.”

Dr. Schiffbauer recently saw a 46-year-old African American female who reported that the left side of her face was swollen. She was seen in the ER the night before, where she was diagnosed with an abrasion. The patient complained of decreased vision and pain. Exam showed 4+ upper lid edema, 4+ chemosis of the conjunctiva and a 4mm corneal abrasion temporally. “However, on physical exam, it appeared that the left eye was proptotic, and the patient experienced significant motility restriction in all positions of gaze,” she says.

The patient was sent to the ER with an order for a CT scan of the orbits. The CT revealed a diagnosis of orbital cellulitis. The patient was admitted to the hospital and given antibiotics. This hospital did not have ophthalmology on staff, so the patient was transferred to a different location. A CT performed at the second hospital showed no signs of cellulitis but rather a significant preseptal edema. At this point, the



The patient's vision, 20/200 best corrected, had dropped from 20/30 recorded a week prior.

patient was starting to develop a corneal ulcer as well.

CT-A to the Rescue

The hospital wanted to discharge the patient back for treatment of the corneal ulcer; however, the amount of lid edema and chemosis along with the proptosis was inconsistent with the corneal ulcer alone, according to Dr. Schiffbauer. As the swelling started to develop on the opposite side of the patient's face, Dr. Schiffbauer dug deeper into the case. Her team ordered CT-angiography (CT-A). “While not a commonly used test, CT-A contrast media is used to image blood vessels and tissue in a given area, allowing for detection


of arterial and venous diseases,” Dr. Schiffbauer notes.

The CT-A results showed dilated veins in the right neck involving the external jugular venous system. The patient had severe bilateral constriction of the outflow veins from her face, backing up the blood trying to get out of her face, which then flowed through the conjunctiva and drained out of the back of the orbit into the intracranial venous sinus system. “These same issues can be seen with dialysis patients,” notes Dr. Schiffbauer.

Follow-Up

A vascular surgeon performed a balloon angioplasty to help open up the blood vessels, eliminate the occlusion that was affecting blood flow and dramatically reduce the lid edema, chemosis and swelling. The patient's vision was now 20/40 with no extraocular motility restrictions, and the proptosis had resolved. The patient reported that her pain was gone.

All findings must be considered in every patient. Doing a good external exam and confrontation field, motility and pupil testing on every patient, even emergency add-on red eyes, cannot be overemphasized. It would be easy to assume that the lid swelling was caused by the ulcer, but that would have been disastrous for the patient, Dr. Schiffbauer cautions. Look at every finding and, if it doesn't make sense, get some help, she adds. In this case, motility, proptosis and the amount of swelling didn't make sense and led to a deeper and more curious diagnosis. ■



Blast From the Past

A childhood course of VT helped slow myopia progression in this high-risk patient, but inattention to proper spectacle correction brought it back.

By **Marc B. Taub, OD, MS, and Paul Harris, OD**

If you can measure it, then you must prescribe it.

This is an aphorism that has been drilled into us since early on in our optometric careers. Correcting refractive error by prescribing from our findings seemed quite easy at first. All we needed to do was spend time upfront splitting hairs to get the axis just right and confirm that 0.25 difference between the spheres in both eyes. Then, we could take pride in writing an “accurate” prescription.

Why not just stop there and save ourselves the trouble and confusion that comes with finding other, seemingly useless, information such as phorias, base-in and base-out prism measurements and distance and near parameters? When we ask fourth years to obtain this “extra” data, many students, who should never play poker, do not even try to hide their distaste for what they think is a complete waste of time.

There seems to be a dynamic tension and an intense rivalry between those whose approaches to prescribing differ. One side believes writing prescriptions is easy and wants to get that part over with so they can move on to using the “cool” technology. The other side believes that by stripping down tests conducted to help write prescriptions, we are giving up the core of what it means to be an OD. Then, there are those of us who

believe in a middle ground, where we can embrace new technology and the expanding scope of practice of the profession to fully understand how the way we prescribe shapes a person’s future.

Patient Deloise gave me, Dr. Harris, the opportunity to take advantage of this middle ground.

Meet Deloise

In May of 1984, Deloise was 12 years old. She was referred to me by another OD. He had chosen not to give her glasses and wanted me to determine her prescription. At Deloise’s last visual evaluation 18 months earlier, no need for glasses was identified. Her chief complaints were blurring at distance and, despite sitting in the front row of her classes, having to squint to see the board.

When asked what she liked best about school, she said riding class. She did not care for math, which also happened to be the class in which she received the worst grades. She had the highest marks in tennis and was a good reader and speller. She was spending 45 to 90 minutes a day on the computer.

Deloise’s mother was about -11.50D OU, and her dad was about -9.50D OU. Her parents would do anything for their child to not end up like them.

Embrace the Middle Ground

Deloise’s unaided distance visual acuities were 20/200 OD and

20/70 OS. At near, they were 20/20 OU. Her distance subjective measurements—least minus to the first good 20/20—were -1.75 -0.25x130 OD and -1.00 -0.25x180 OS. Maybe there should have been a bit more minus than the acuities suggested, but they were not wildly off.

The base out at distance was x/5/4, and the base in at distance was x/3/-1. Knowing that the base out break should be 19D and the base in break should be 9D for a total range of 28D caused confusion over the range of 8D she showed. Her distance phoria was 3 exo.

At near, the testing broke with tradition. Because she was 20/20 OU at near and had never worn glasses, we removed the refraction noted above and started with nothing in the phoropter. A near phoria of 13 exophoria was found through plano at near, which is where it remained despite the fused cross cylinder showing +0.75. Her base out at near was x/18/12, and her base in at near was x/12/6, neither of which was concerning. Deloise’s positive relative accommodation (PRA) and negative relative accommodation (NRA) were quite revealing. The NRA was +2.25 gross lens in the phoropter, and, as the lenses transitioned to the minus direction, Deloise was unable to clear the chart at +0.25. This raised my hopes that she could be helped if

all the minus on the subjective was not yet embedded.

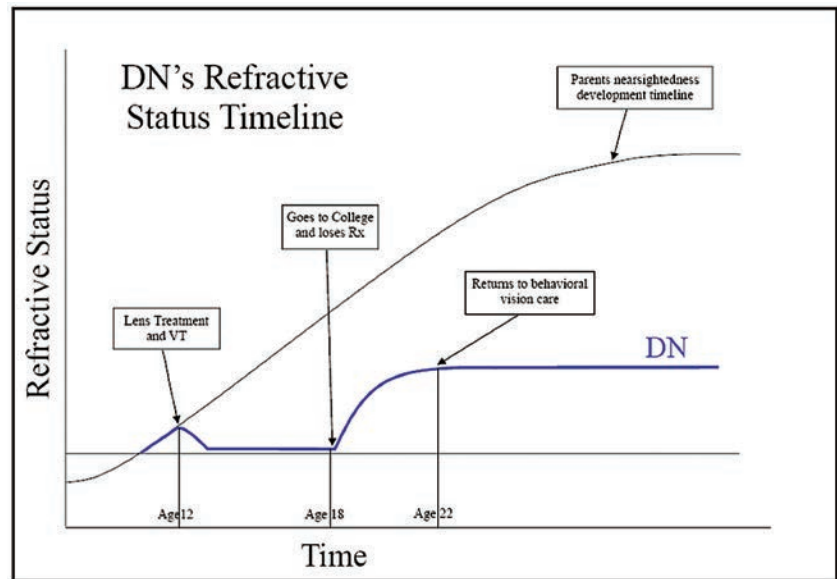
Stress-point retinoscopy, which was in its infancy at the time and not as trusted as it is now, showed that Deloise could handle +0.50 at near. Her parents wanted her to undergo vision therapy, and I agreed that this was the best option. Due to her visual acuity measures and the fact that she was squinting, a near vision correction was needed. After consulting with the referring OD, we decided on the following prescription: -0.50/+1.00 add OD and -0.50/+1.00 add OS. This would allow a good 20/40 at distance and eliminate squinting.

Deloise received her glasses and began vision therapy. She was diligent in completing therapy at home and wearing her glasses at all times in school and as she needed them at home. Her unaided visual acuities improved to 20/40 OD, 20/30 OS and 20/25 OU. Her distance subjective measurements, which were a solid 20/20 OU, were now -0.50 OD and -0.25 x 180 Plano OS.

The base out at distance improved to 8 / 14 / 8 and the base in to x / 8 / 4. The distance phoria was 2 exophoria. At near, PRA and NRA, which improved to +2.50, -2.75, saw the biggest changes. Stress-point retinoscopy showed that Deloise could now handle +1.00 at near. Since her unaided visual acuities were now better than 20/40, her glasses were changed to plano at distance with a +0.75 add OU. Deloise completed about 20 total vision therapy sessions.

Mistakes and Consequences

So, what happened to Deloise? Fortunately, she was not lost to follow-up. She remained the



This refractive timeline shows how glasses and vision therapy helped Deloise (DN) and, alternatively, what happened when she broke her glasses and was lost to follow-up for four years.

same from the conclusion of vision therapy until high school graduation and did not become more myopic over those years. That is the good news. But, she ended up going to college more than 2,500 miles away and was not seen for a few years. She broke her glasses within the first few weeks of school and never had them replaced. She returned four years later with her tail between her legs and glasses that were clearly minus lenses—they were -3.00D OU.

Using plus for near, under-prescribing at distance and providing vision therapy helped change the course of Deloise's myopia progression, allowing her to remain stable for many years—with the help of glasses for near—and see well at distance (20/20- OU unaided). Without her plus lenses during those four years of college, however, she found herself right back on the myopia progression train. Deloise finally stopped progressing at about -3.00 OU.

If you remember, Deloise liked riding. She became too big to be a jockey but had an incredible sense of time and space and became an in-demand exercise rider for top-level racehorses. She rode horses and made recommendations to the groups who wanted to invest in them. Her opinions about those horses were and are valued greatly. Oh, and Deloise got married. Her husband's refractive status? You guessed it: -9.00D OU!

Deloise's was not an exceptional or extraordinary case but an example of how the way we prescribe today has an impact on the future. By prescribing judiciously from our findings, and adding in vision therapy when necessary, we can prove to patients that they are not doomed by their genes. But, we must first take the time to listen to our patients' needs, conduct those extra tests and analyze our data to determine the appropriate treatment plan. ■

YOUR CAMPAIGN YOUR SUPPORT



Think About Your Eyes drove **3.4MM incremental eye exams** and **\$752MM in incremental industry revenue** in 2017.

These industry leaders make the campaign a reality, and to keep it going, they need your support. Show them your appreciation, and encourage other companies you do business with to join the campaign.

Think About your Eyes can get even bigger and more impactful with your help.

thinkabout
youreyes.com

Brought to you by the AOA
AMERICAN OPTOMETRIC ASSOCIATION



Be Precise When Coding Surgery

Following basic standards for performed procedures helps maintain good medical record compliance. **By John Rumpakis, OD, MBA, Clinical Coding Editor**

Adding a new service offering to your practice is exciting, whether it be OCT-A, imaging, CLIA-waived testing or a surgical procedure. As with any procedure or test, you must record medical necessity clearly if a third-party carrier will cover it. With surgical procedures, be aware of a few other medical record and coding compliance rules to ensure things are correct and to minimize any potential audit exposure.

Step 1: Minor or Major?

First identify whether the procedure is considered minor or major. The length of the global period assigned to the procedure itself determines this designation.

Although the vast majority of surgical procedures that ODs perform are minor, there are some states that currently allow ODs to perform major surgical procedures. With the expansion of scope increasing across the country, I expect this trend to continue.

Step 2: Code and Bill For the Office Visit

Perhaps the most common mistake ODs make when billing a minor surgical procedure is billing an office visit on the same day as the minor procedure. To properly identify a legitimate office visit, you must use a modifier on the office visit. The *National Correct Coding Initiative Policy Manual for Medicare Services* defines how to determine the legitimacy of a visit and whether it is proper and recognized:¹

Minor procedures: If a procedure has a global period of zero or 10 days, it is defined as a minor surgical procedure. In general, E&M services on the same date-of-service as the minor surgical procedure are included in the payment for the procedure. The decision to perform a minor surgical procedure is included in the payment for the minor surgical procedure and shall not be reported separately as an E&M service. However, a significant and separately identifiable E&M service unrelated to the decision to perform the minor surgical procedure is separately reportable with modifier -25.

The E&M service and minor surgical procedure do not require different diagnoses. If a minor surgical procedure is performed on a new patient, the same rules for reporting E&M services apply. The fact that the patient is “new” to the provider is not sufficient alone to justify reporting an E&M service on the same date-of-service as a minor surgical procedure.

Major procedures: If a procedure has a global period of 90 days, it is defined as a major surgery. If an E&M is performed on the same date-of-service as a major surgical procedure for the purpose of deciding whether to perform this surgical procedure, the E&M service is separately reportable with modifier -57. Other preoperative E&M services on the same date-of-service as a major surgical procedure are included in the global payment for the procedure and are not separately reportable.

Step 3: Use Modifiers Properly

Modifiers describe a situation where the rules are sidestepped because the circumstances are exceptional. The key to using modifiers properly is making sure you follow the definition of the modifiers as described by the *American Medical Association CPT Book*, Appendix A.

The primary modifier that ODs encounter with the greatest frequency is modifier -25. The improper use of modifier -25 is significant and has been the topic of many writings of the Office of Inspector General involving health-care fraud, as many practitioners use it to get reimbursed for an improperly billed office visit.

Step 4: The Operative Report

From a medical record standpoint, surgical procedures require a separate narrative often referred to as an operative report. This typically describes the surgical procedure, preparation of the surgical field, instruments and approach used by the surgeon and a statement of patient status at the end of the surgical procedure.

Incorporating surgical procedures into your practice is of great benefit to your patients, and knowing basic coding surgical procedures is essential to proper clinical standards. ■

Send questions and comments to rocodingconnection@gmail.com.

1. Centers for Medicare & Medicaid Services. National correct coding initiative edits. www.cms.gov/Medicare/Coding/NationalCorrectCodInitEd/index.html. Updated November 14, 2018. Accessed November 26, 2018.

The Cataract Patient Care Opportunity: Strategies to Collaborate for Successful Surgical Outcomes

Dear Reader,

The visual needs of the mature population in the U.S. is increasing dramatically. Consider that the number of diagnosed cataract cases is expected to double from 24.41 million in 2010 to roughly 50 million by 2050.¹ In fact, all baby boomers will be older than age 65 in 2030, meaning that one in every five U.S. residents will be of retirement age.² This segment will bring with it unique eye care challenges in the age of technology.

Not only are seniors staying physically active, but they are engaging with digital devices well into their 90s. Think about the visual needs of the individual who had cataract surgery 20 years earlier, and who now relies on their smart phone or tablet to stay connected to the world.

Fortunately, advanced IOL technology is now available for many individuals long before they hit their 70s or 80s, offering them the flexibility to perform their daily tasks and activities and to continue pleasurable pursuits and hobbies. Yet, data reveals that only 7% of astigmatic patients are having a toric IOL implanted during combined cataract surgery when 52% qualify as good candidates.³⁻⁵ Clearly, eye care professionals are missing an enormous opportunity.

In addition, research shows that U.S. optometrists are diagnosing and handing off to cataract surgeons about 6.5 million patients a year but only co-managing about 736,000 of them.⁶ That is a tremendous burden on ophthalmology and an unsustainable trend, especially given reports revealing a downward trend in the number of practicing ophthalmologists over time.

While many optometrists are staying abreast of and knowledgeable about the latest toric and multifocal IOL options and recommending them to patients, others are not. Some eye care professionals are making presumptions about their patients' financial willingness to embrace such technology, while still others neglect to make time during office visits to educate patients on advanced surgical solutions that can address refractive errors and even glaucoma. As a result, many patients are finding this information online or hearing about it from family members and friends.

For those proactive eye care professionals who are seeking strong patient candidates for advanced toric and multifocal IOL technology, they must identify a sur-



John Berdahl, MD
Vance Thompson Vision
Sioux Falls SD



Mitch Ibach, OD, FAAO
Vance Thompson Vision
Sioux Falls SD



Kristopher May, OD, FAAO (Moderator)
Coldwater Vision Center
Coldwater, MS



Justin Schweitzer, OD, FAAO
Vance Thompson Vision
Sioux Falls SD

Doctors are paid Alcon Consultants

gical center with shared values, and, importantly, stay in good communication with the cataract and refractive surgeon, once a referral is made. We know that true collaborative cataract patient care involves more than just handing off patients to the surgical center. Moreover, seizing the pre- and postoperative care opportunity, and addressing any preoperative dry eye or ocular surface disease are essential steps toward a successful surgical outcome.

Eye care professionals must set appropriate expectations to

increase the likelihood of high patient satisfaction for those who undergo surgery for advanced toric and multifocal IOL solutions. Though today's technology can be truly exceptional, ensuring that patients don't go into surgery expecting perfection in their visual results can help prevent the patient feeling disappointment or confusion afterward. Finally, having an exit strategy for the patient who simply can't adjust to advanced technology can preserve the doctor-patient relationship for years to come.

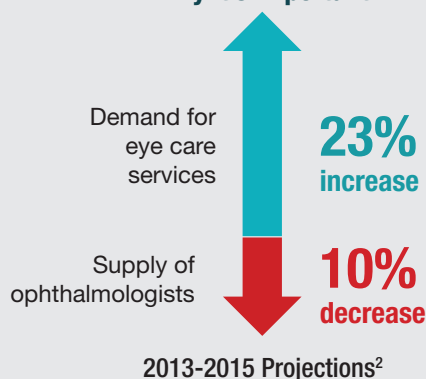
ODs POISED TO GUIDE PATIENTS TO ADVANCED IOLs

- Surveyed optometrists discuss monofocal IOLs with appropriate patients 72% of the time, but toric IOLs only 44% of the time¹
- 73% of surveyed optometrists consider themselves highly knowledgeable on cataract surgery*¹

*Based on the top two responses on a 5-point scale, ranging from "not at all" to "extremely".

1. Alcon. OD and PCP Opportunity Assessment (Survey of 108 Optometrists), 2013. 2. U.S. Department of Health and Human Services, Health Resources and Services Administration, National Center for Health Workforce Analysis. 2016. National and Regional Projections of Supply and Demand for Surgical Specialty Practitioners: 2013-2025. Rockville, Maryland.

Why it's important



Offer the Patient Advanced IOL Technology

Dr. May: Why are so few toric IOLs being implanted? Why is the uptake low?

Dr. Schweitzer: I really think it just comes down to the fact that we have to talk about them with patients, and that's not happening all the time. And we may have preconceived notions about what the patient wants. I once had a patient with some astigmatism, and I made an assumption that that patient didn't want additional advanced technology, that she didn't want to invest anymore in her eyes. The patient went and had surgery elsewhere and came back to me, and the first thing she said to me was, 'Why didn't you talk to me about all the options?' That really opened my eyes, and it was one of the most uncomfortable times I've experienced as a doctor. What was I going to say to her—I was lazy that day? Now, every time patient candidate sits in my chair, I don't make an assumption about that patient, and they get three possible options. For example, I tell the patient, 'You can have a monofocal implant if you're a candidate for it; you can have a toric implant, and we can correct your astigmatism; or you can have a multifocal implant.' And we dive into that. The reality is that patients are talking to relatives, they're talking to other patients in the community, and they're going online to learn about advanced IOLs, so they want that information. If they come into your office and they don't get it, they're going to question you about it.

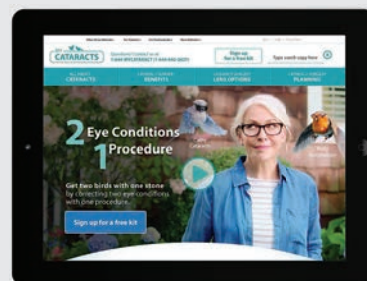
Dr. Ibach: Agreed. Many patients are coming in more educated than they ever have before, and that's something that I really like because it provides a natural opening to the conversation. If a patient comes in, whether they're talking with their optometrist, 'Dr. Google,' or maybe a family member, it shows me that they're invested. They care about the prospective surgery, and they've put skin in the game, and I think that's a good place to start.

Dr. May: Exactly. But then we start making financial assumptions for certain patients when it comes time for the surgical referral and saying things like, 'Well, there's some stuff that will cost more, you don't worry about that.' And we don't realize the opportunity that's there for that small farmer and what it can mean for his life. We really have to go back to the idea that there's no such thing as price, it's all about value.

How to Help Educate and Inform

Start the discussion. Educate patients on their condition and steps needed for cataract surgery. Alcon's campaign allows you to:

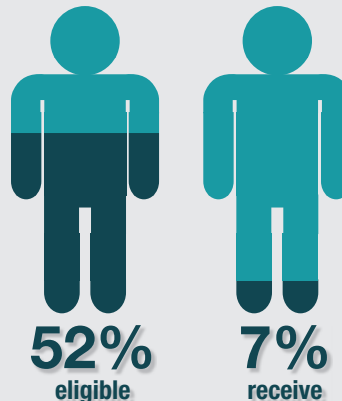
- Direct patients to the consumer website mycataracts.com.
- Refer patients to the cataract call center: 1-844-MYCATARACT
- Drive patients to the My Cataracts YouTube channel: youtube.com/mycataracts



Key Conversation You Need to Have With Your Patient

If you were to take just one thing that I think is going to help in the initial discussion with your patient about advanced IOL technology, explain that, 'Cataracts are fairly easy to diagnose, and you've got two cataracts. The surgeon is probably going to take those out, and that's not the big decision that you're going to make. The big decision is how are you going to use your eyes for the rest of your life? So between now and when you have your surgical consult, I want you to think about how you want to use your eyes. How much do you want to wear glasses? Are they a frustration for you? I'm here as your advocate and your doctor to talk through any of those things if you have questions.'—*John Berdahl, MD*

And having that conversation early makes it even more impactful. We can do so much by letting that patient digest the information and talk to family members, review resources that we provide for them. It's not one of those things where they're getting hammered with information and options, but we can help them make that decision and set our team up for success so that our patients are set for the rest of their life.— *Kristopher May, OD, FAAO*



52% of cataract patients with astigmatism are eligible for a toric IOL, yet only 7% of patients receive one.¹⁻³

1. Hill W. Distribution of corneal astigmatism in normal adult population (n=6000). Keratometry database: http://www.doctor-hill.com/iol-main/astigmatism_chart.htm. Accessed May 17, 2013.
 2. AcrySof® IQ Toric [product information]. Fort Worth, TX: Alcon Laboratories, Inc; 2009.
 3. Market Scope. Cataract: Q1-2017 cataract quarterly update; Alcon data on file 2017.

Identify the Right Candidate & Set Realistic Expectations

Dr. May: What makes for a good multifocal patient?


Dr. Ibach: The first step for me is finding a patient who's motivated to have technology that makes them less dependent on glasses at distance, intermediate, and up close. I also look for someone who understands and has realistic expectations about what the technology can do. There's an important psychological aspect to managing patients with multifocal IOLs. In addition, we want to make sure they have a pristine tear film, so eye care professionals need to work on the tear film aggressively before surgery to help us get a better outcome. I also like to understand the patients with astigmatism very well.

Dr. Schweitzer: A few things come to mind when I'm discussing multifocal implants with a patient. No. 1, set visual goals: What are the patient's visual expectations? No. 2, the patient needs to be motivated. The worst candidates are those I have to try to sell the technology to because they're not going to be happy no matter what, even with a 20/20 outcome. Obviously, there needs to be support from your staff

and the doctors, but success depends heavily upon the patient's belief in the solution. After surgery, sometimes we have to show the patient how effective a multifocal lens is working. So, for example, if I have a patient who says, 'I see great far away, but I just can't read very well,' I'll go to my trial lens kit, grab -2.50D lenses, give them a piece of reading material and put the lenses over their eyes. They say, 'I can't read anything, what did you do to me?' I pull the lenses away, and they say, 'I actually can read,' so it's just helping them understand that the technology is functioning. On day 1, they're not going to have perfect vision, on week 1, they're not going to have perfect vision; it may take up to three months, it may take up to six months. It's a process.

Dr. Berdahl: For me, the first thing patients need to understand is that multifocal technology is really, really good, but it's not perfect. I hate the term 'conversion rate'; it's like I got you to do something you didn't want to do. I prefer the term 'adoption rate' where patients choose to adopt multifocal IOLs because they understand the technology. I tell patients,

Optometrists Diagnose Many Cataracts, But Participate in Cataract Co-Management Less Often



Data based on the 2016 American Optometric Association RIC Clinical Practice Survey; Total Optometrist Counts (Supply) from 2012 National Eye Care Workforce Supply and Demand Projections. Data were then projected out to the population to estimate total patients among optometrists.

'You're going to be happy with whatever choice you make because you're well-educated, and you know what you're going to get at the end.' When talking about multifocality, I say we're going to give you increased flexibility in your vision and freedom from spectacles in exchange for a slight decrease in quality. So, if the patient says they are a bird watcher, this might not be the right lens for them. But if they don't want to pull out a pair

of reading glasses to check their phone, then maybe it is.

Dr. Schweitzer: One thing to think about with multifocal patients is that successful outcomes are dependent on the patient's postoperative satisfaction. So, in other words, the surgeon can perform a perfect procedure that reflects positively in the results section, but if we didn't set the right expectations for the patient, the satisfaction suffers.

Preoperative Ocular Surface Health & Patient Satisfaction

I have seen almost no patient who was overtreated for dry eye before cataract surgery. Maybe the eye care professional can back off of treatment after the procedure, but give me as pristine of a surface as possible to help me make a sound surgical decision. So if the eye care professional feels like there's some dryness there, they should err on the side of rehabbing the ocular surface to ensure I get accurate keratometry and biometry measurements. That way I can, ultimately, put in the best lens possible.— **John Berdahl, MD**

We can't overtreat preoperative dry eye. We have to understand that just getting a cataract out is no longer what we're calling success. When we're talking about successful outcomes, we mean refractive and postoperative patients who are just stark-ravagingly happy and highly positive. Any other results, we're just missing. Maybe we didn't do everything that we could have done.— **Kristopher May, OD, FFAO**

Communicate Better With the Surgical Practice

Dr. May: What can optometry and ophthalmology do to improve collaborative care?

Dr. Berdahl: First, we need to realize we're on the same team and not be possessive. The second thing is to be educated—to not get in a rut or stall out on our professional competencies—and grow with the technologies as they come along, so we are well-versed in the options that our patients deserve to hear about.

Dr. Schweitzer: When I was in private practice, I really cared about two things. No. 1, I wanted to get my patients back. So I identified an ophthalmologist and surgical practice that had the same values that I did—that valued co-management and that wanted me to be involved in patient care. No. 2, when my patients came back to me after surgery, I wanted to know what kind of IOL they had, what kind of surgery they had, what expectations were set by the surgical center. That way, I didn't walk into the patient exam room and wonder: What am I doing here? Is this day 1, week 1? Now, being on the other side, I love getting a short letter from referring ODs that says, 'Hey, I know this patient very well, and these are the visual goals of this patient.' That is so helpful to me because then I know what I need to talk to the patient about. In a situation where I change the plan, I make sure to call the referring optometrist and explain my decision. It's not so much

Getting the Rare Patient from Disappointed to Delighted

By **John Berdahl, MD**

Despite our best intentions, we ophthalmologists are not going to hit the refractive target every time. So it's really important to have an exit strategy. If the surgical center doesn't have an excimer laser to do LASIK enhancements, you need to establish a relationship with one that does to get the patient there and not just leave them unhappy. The ability to do an IOL exchange is critical.

Also, going back to the initial conversation I have with patients, I tell them, in full disclosure, 'I think that we've got a 95 percent chance of getting you out of your glasses and contact lenses.' That way, they understand that no procedure offers a 100% guarantee.

educational as just staying in good communication.

Dr. Berdahl: Another thing that is helpful in a note is if you say, for example, that the patient is a -2.00D and they'd love to stay -2.00D. Boy that helps me out. Because most people are going to prefer plano, but not everyone.

Dr. May: We have to find a way to communicate all of this to make sure that we're handing important information off. It should be personal and not this big, formal process. 'I just wanted to let you know Ms. Smith is coming in and has this,' and it's amazing what that communication can do. ■

Benefits to the Patient of Collaborative Cataract Care

By **Mitch Ibach OD**

Collaborative care between optometry and ophthalmology offers a lot of benefits to our patients. One of the big advantages I see is the ability to leverage the long-time relationship of the referring optometrist and patient. That continuity of care helps the surgery center understand the patient's goals, their visual demands, and their expectations going into surgery.

Second, it allows our ophthalmology colleagues more scheduling flexibility. In other words, it offers them more time to do procedures and focus on providing surgical care to the patients who need it.

1. NEI. Cataracts Defined. Available at: <https://nei.nih.gov/eyedata/cataract> (last accessed Oct. 24, 2018).
2. United States Census Bureau. Older people projected to outnumber children for first time in U.S. history. Available at: <https://www.census.gov/newsroom/press-releases/2018/cb18-41-population-projections.html> (last accessed Oct. 24, 2018)
3. Hill W. Distribution of corneal astigmatism in normal adult population (n=6000). Keratometry database: http://www.doctor-hill.com/iol-main/astigmatism_chart.htm. Accessed May 17, 2013.
4. AcrySof® IQ Toric [product information]. Fort Worth, TX: Alcon Laboratories, Inc; 2009.
5. Market Scope. Cataract: Q1-2017 cataract quarterly update; Alcon data on file 2017.
6. Data based on the 2016 American Optometric Association RIC Clinical Practice Survey; Total Optometrist Counts (Supply) from 2012 National Eye Care Workforce Supply and Demand Projections. Data were then projected out to the population to estimate total patients among optometrists.

2018 Income Survey: Where Do You Stand?

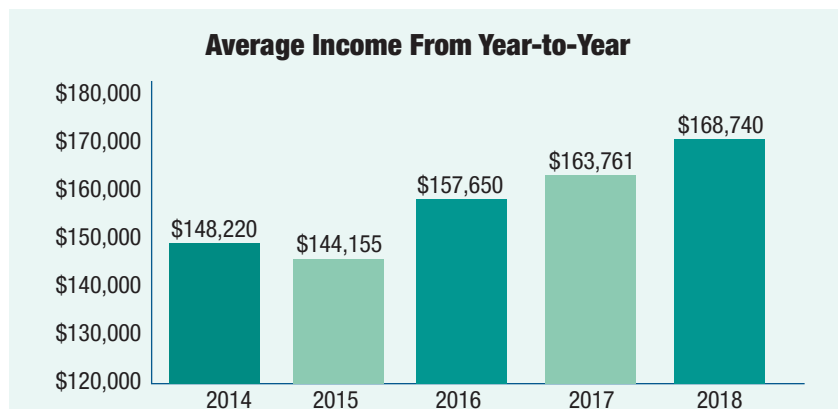
Optometry experienced breakthroughs and setbacks this past year. Check out our report to see if you followed the trends, or bucked them.

By Catherine Manthorp, Associate Editor

As the year winds down and a new one quickly approaches, let's go back and see what 2018 held for optometry financially. In this year's annual income survey, OD participation increased to more than 750 respondents—maybe it was to share the good news that their income was continuing to follow an upward trend? And it was: average income in 2018 was \$168,740, a 3% increase from 2017. While that's not as big of a jump as the 4% increase from 2016 to 2017, the declining rate at which income is rising could be leveling off—income increased by 9% from 2015 to 2016.

Specifically, full-time workers made an average of \$175,152 in 2018—a 5% increase from last year—and part-timers made \$114,146 on average, a 6% drop from 2017. The same percentages of full-time and part-time workers as last year filled out the survey—91% and 9%, respectively.

As always, be mindful that we're comparing different datasets (our 2017 and 2018 surveys included different individuals each year), and



that makes trend analysis tricky, especially among the smaller cohorts where sample sizes get lower and results more varied.

Time is Money

As a society, it's a general rule of thumb that experience determines pay—the more years you have under your belt, the more money you have in your wallet. This also holds true for optometry, to an extent.

Entry-level respondents—those with zero to 10 years of experience—made up 31% of the respondents and earned an average of \$131,236, a slight increase from the

average full-time income beginners made in 2017.

The average income leap from the zero-to-10 years of experience bracket to the next one, 10 to 20 years—25% of respondents had this intermediate level of experience—was a sizable 26% for \$165,259. This level, however, represents a 7.5% drop from the average income full-time workers at this experience level made in 2017.

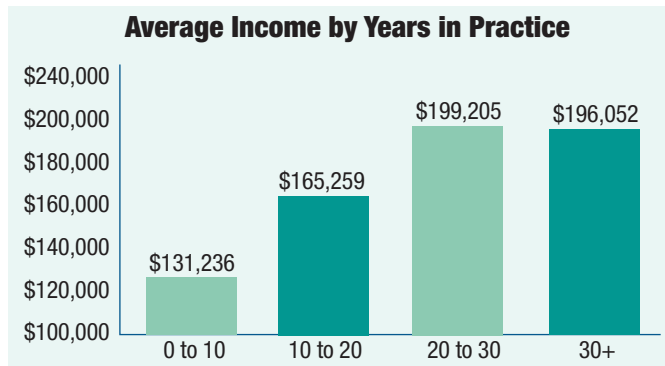
While last year's respondents reported experiencing a mid-career plateau, this year's results indicated quite the opposite occurred. Those with 20 to 30 years of experience

made up 26% of the respondents and earned an average of \$199,205, a 21% jump from the average income their counterparts with 10 to 20 years of experience earned and a 12% increase from the average full-time income workers with 20 to 30 years made in 2017.

This is where it gets confusing. The more experienced you are, the more money you make, right? While this was the trend last year's survey results followed, this year's results for respondents with the most experience run counter to that notion. Those who have been practicing for more than 30 years only earned \$196,052 on average. That's a 2% drop for 10 more years of experience and a 12% decrease from the average full-time income veterans made in 2017. Perhaps the relatively small number of respondents in this group (18%) skewed the results, or some at the top end of the experience curve are starting to reduce their time spent on the job and that easing off was reflected in the numbers.

It Pays to be Your Own Boss

Working for yourself has always seemed desirable. For the respondents of our survey, it's also profitable. While the majority of respondents (53%) are employed, those who are self-employed brought home the bigger bucks, earning an average of \$215,466, a 67% increase from the \$129,022 those who are employed make on average. The 67% difference between the two means the gap is widening



yet again—it seemed to have begun closing last year when it dropped from 58% in 2016 to 35% in 2017. Further distancing both groups, employees made 3% less than their full-time counterparts did in 2017 while self-employed workers made 20% more.

Of those who are employed, 52% work for an OD or MD, 20% for a commercial firm, 9% for a hospital/VA, 6% for an HMO or a PPO and 4% for a university. Nine percent of the respondents chose the “other” option and reported taking the private chain, private equity or corporate route to name a few.

Working for a hospital/VA was the least profitable for optometric employees, who made an average of \$115,267. This represents a 22% drop from the average full-time income hospital/VA employees


earned in our 2017 survey, when being employed by a hospital/VA was the second most profitable option. Of course, heed our earlier admonition about comparing different datasets—last year's respondents didn't necessarily get a nasty pay cut.

Similar to 2017, working for a university (\$123,747) or an OD or MD (\$124,235) were lower-paying gigs. Those who chose the “other” option made an average of \$128,163, and those who work for a commercial firm earned \$137,282 on average.

At the top of the chain, employees of an HMO or a PPO made an average of \$161,875, a 13% jump from the average income their full-time counterparts earned in 2017, when working for an HMO or a PPO was also the most profitable option.

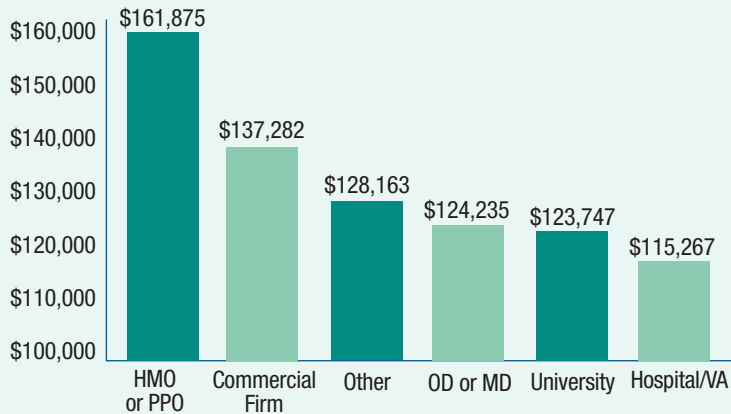
Switching gears, of those who are self-employed, 47% practice on their own, 36% are members of partnerships or groups and 14% are independent contractors. Three percent of the respondents chose the “other” option. Similarly to 2017, working as an independent contractor was the least profitable and only paid an average of \$132,542. Those

who worked on their own made \$194,975 on average, and those who worked in partnerships or groups made an average of \$264,774. While those who chose the “other” option fell into the second least profitable category in 2017, this group earned an average of \$318,833 in 2018, a 112% increase from last year, making this the most



Income Survey

Average Employed Income by Practice Setting



Average Income by Gender



profitable route to pursue. Many of those who fell into this category own their practices and have associates working for and with them.

Southern Comfort

While packing up and starting fresh somewhere entirely new isn't exactly ideal, it could do wonders for your income and mean the difference between earning less in one place and 23% more in another.

Just as it was last year, the South is the most profitable place to practice, with workers earning an average income of \$189,620, 5% more than the average full-time income respondents from the South claimed in 2017.

Earning 12% less than their southern counterparts, those in the West make the next highest income—just as they did last year—at \$168,553 on average, slightly less than 2017.

On the other end of the spectrum, practitioners in the Northeast were the least profitable, only making an average of \$154,024. This represents a 4% drop from the average income

those living in this region earned in 2017—when the region was the third most profitable—and bumps the Mid-Atlantic/Lower Great Lake region (\$158,380) and the Midwest (\$164,149) up to the fourth and third most profitable areas of the country, respectively.

Inching Toward Income Equality

The gender gap has been an issue across the board for an extremely long time now, and, unfortunately, it doesn't seem to be in a rush to go anywhere fast for optometry. Even though the 3% shrinkage in disparity between men and women from 40% in 2017 to 37% in 2018

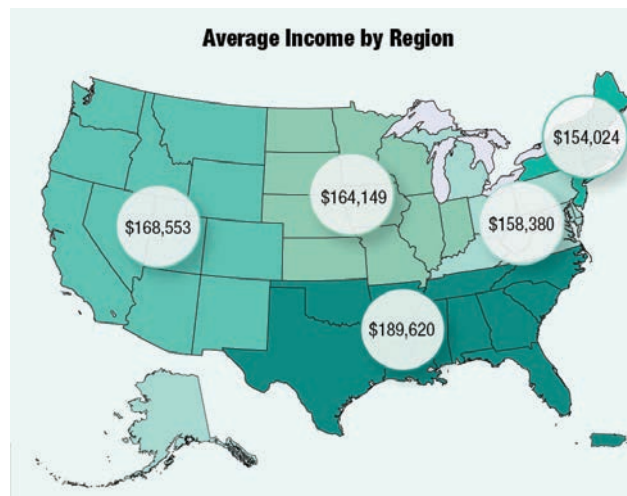
doesn't compare to the 31% drop from 68% in 2015 to 37% in 2016, it still represents a step in the right direction—the gap widened by 3% last year.

This year, men out-earned women on average \$191,256 to \$139,522, and men made up the majority of the respondents at 59%. The average incomes for males and females increased from last year, with females' increasing at a faster rate.

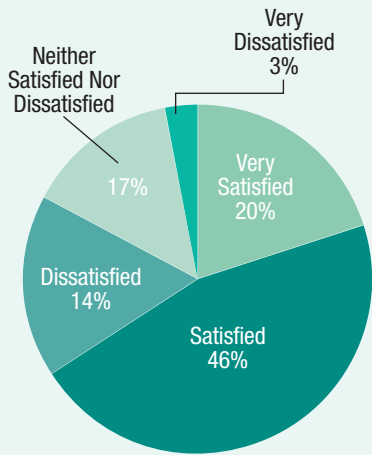
At an average income of \$190,208, men with more than 30 years of experience earned 42% more than women at the same experience level, who sat at \$134,400 on average. This represents a sizable step backwards from the 10% gap for full-time workers of both genders who had the most experience in 2017 and is the largest income disparity between men and women at each experience level this year.

The next highest income gap was between male and female novices—those with less than 10 years of experience. Men earned an average of \$176,262, 41% more than women who had the

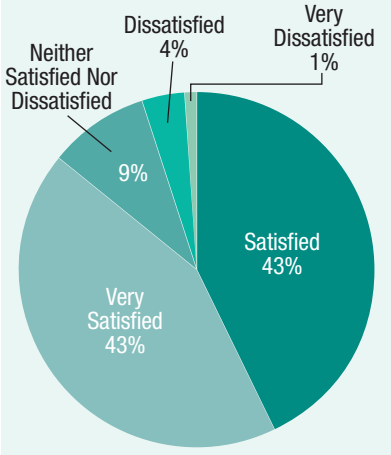
Average Income by Region



How Satisfied Are You With Your Current Income?



How Satisfied Are You With Your Career Choice?



same level of experience but only made \$124,827 on average. Again, this widening gap—it was a mere 11% for full-timers who were just starting out in 2017—represents a step in the opposite direction of where the field should be heading.

The gap between men and women with 10 to 20 years under their belts was similar, at 40%, with men earning an average of \$204,344 and women, \$146,066.

The smallest gap belonged to the group approaching the highest level of experience—20 to 30 years—at 12%, with men earning \$180,373 on average and women, \$161,369.

Optometric Optimism

Despite the mixed results we saw from the survey, the majority of respondents seemed to remain pretty positive about their income and career choice. Just over 65% reported feeling satisfied or very satisfied with their income. Respondents generally agreed that the amount of money they make allows them to save for the future, spend on other things, live comfortably and engage in the lifestyle of their choice. Many believe they are adequately compensated for their time and

work, with one respondent saying they are making “more than I ever dreamed of.” Others, however, do not think they are making as much as they should be at their level of experience and are worried about paying off student loans and saving for future plans and retirement. “I have plenty to meet my needs and am happy with my income, but my debt load for student loans and practice purchases leaves something to be desired for saving for retirement and other goals,” a respondent says.

More than 85% of respondents indicated they were satisfied or very satisfied with their career choice. Many reported that working in optometry was their dream job because they love helping patients in a dynamic field. Others said they enjoy being their own boss, naming the amount of control they have and the balance they are able to strike between their personal and professional lives as two perks. “I absolutely love and enjoy practicing optometry. I receive the benefit of helping people using my God-given skills and sound financial compensation. I truly believe that optometry is the best profession!” says one respondent.

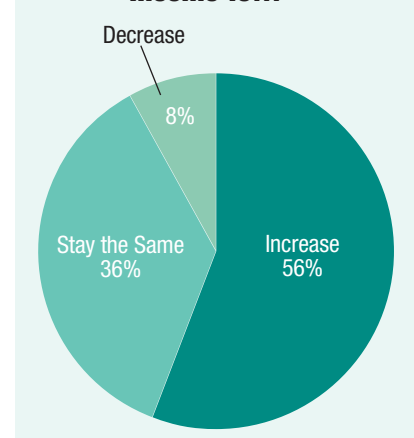
Still, many took issue with the hurdles insurers present, the emphasis on quantity over quality and the threats online retailers pose. “I love my profession but not the way I have to practice it,” one respondent says. Along the same lines, another remarks, “Insurance has started dictating the way I practice.”

While some expressed dissatisfaction, the percentages fell as the rankings did for both income and career choice—good signs all around—and many remained optimistic about the year to come. Of this year’s respondents, 56% expect their income to increase, 36% don’t expect a change and only 8% expect a decrease.

Bring on 2019

As any other year, some individuals did better than their peers in 2018. But as a whole, we saw average income increase, the mid-career plateau disappear and the gender gap narrow, among other positives. We also saw earnings decrease among those with the most experience and the gap widen between self-employed and employed ODs. The bottom line, however: optometry continues to move forward, even if it does so at a slower pace and meets some roadblocks along the way. ■

“Next Year, I Expect My Income To...”





Excise and Conquer:

Adding Minor Surgical Procedures to the Optometric Office

Learn the basics of these treatment options to provide patients more extensive care.

By Jackie Burress, OD, Rodney Bendure, OD, and Lisa Kedzuf, OD

Optometrists are the primary eye care providers for the majority of Americans, and ophthalmology services may be hours away for those in many rural areas.^{1,2} Therefore, it is incumbent on us to practice to the full scope of our licensure and training to provide our patients the best and most effective care we can. Depending on your state legislature, amending your skill set may encompass adding minor surgical procedures to your repertoire. Doing so will positively impact patients' lives, providing them access to valuable services closer to home.

Adding surgical procedures is easier than you might expect. In fact, many optometrists already perform such tasks—foreign body removal, eyelash epilation, and dilation and irrigation of the puncta—on a daily basis. Broadening optometric privileges across the country is bringing these opportunities to more optometrists than ever. Optometrists

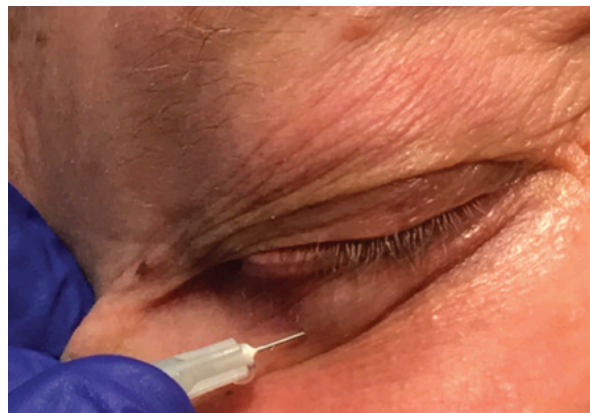

Fig. 1. When injecting anesthesia, pull the eyelid taut and ask the patient to look away from the injection site.

in Alaska, Kentucky, Louisiana, Nebraska, New Mexico, Oklahoma, Oregon and Tennessee can perform minor surgical procedures. Idaho, Montana, North Carolina, North Dakota, Utah, Virginia, West Virginia, and Wisconsin allow the use of injectable drugs for diagnostic and treatment purposes.³⁻¹¹

This article reviews the basic minor surgical procedures that you can perform in your office, though it is important to consult your state board about which are permissible

under your state's optometric law.

Medical History and Informed Consent

Best practices dictate acquiring a thorough medical history and obtaining informed consent from the patient prior to any procedure. The history should include any past or present medical conditions, drug and latex allergies and a list of all medications the patient is taking, including over-the-counter ones.

Pay special attention to any anticoagulants the patient is taking, such as aspirin, nonsteroidal anti-inflammatory drugs, warfarin, heparin, dipyridamole and clopidogrel. Anticoagulants increase the risk of bleeding and lengthen healing time. Consider speaking with the patient's primary care provider to determine if the patient can suspend treatment of the anticoagulant to have the lesion removed.

It is also important to inquire

about cardiovascular health, especially hypertension. Epinephrine, which is commonly added to anesthetics, should be used with caution in patients taking tricyclic antidepressants and beta-blockers. Epinephrine should not be used in patients with severe hypertension, hyperthyroidism and pheochromocytoma.¹²

Pregnancy is also an important screening question in all women of child-bearing age, as anesthetics may act as possible teratogens.¹²

Your informed consent discussion should give the patient the opportunity to ask questions and have them answered to their satisfaction prior to signing an acknowledgment of the risks and electing to proceed. Patients must be at least 18 and capable of independent decision-making to sign an informed consent. A parent or other legal guardian may do so for a minor or an adult incapable of making their own informed decisions.¹²

Prepare Anesthesia

Periocular injections are used for local anesthesia and/or administration of medication locally into affected tissue. Sterile, single-use disposable stainless-steel needles are used for both types of injections.¹³ Small-diameter short needles are the best choice for periocular tissues, as these provide maximum comfort and precise control.¹³ Most commonly used needles range from 3/8" to 2" in length and 27- to 30-gauge in diameter. Remember, the gauge of a needle is inversely proportional to its diameter—the higher the gauge, the smaller the diameter.¹³

There are several types of anesthetic of varying concentrations for use in periocular injections, but Xyllocaine (lidocaine hydrochloride, Astra Zeneca) and Marcaine (bupivacaine hydrochloride, Pfizer)

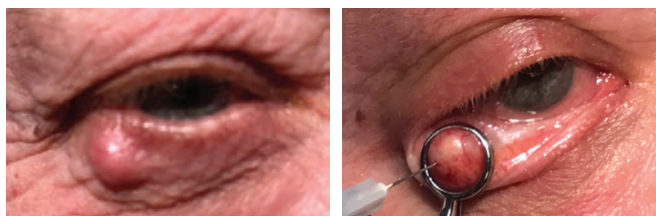
are the most common choices. Lidocaine has a shorter onset of action (two to four minutes) but only provides anesthesia

for about one

hour. While bupivacaine has a longer onset of action (10 minutes), its duration can range from four to six hours.^{13,14} Some practitioners find it useful to use a combination of both to obtain a faster onset of action with a prolonged duration.^{13,14}

A helpful addition to the anesthetic is a vasoconstrictor, such as epinephrine, which works to minimize bleeding and prevent systemic absorption of the anesthetic.¹³ In practice, we prefer to use the prepared combination of 2% lidocaine with epinephrine 1:100,000. This provides a quick anesthesia that lasts well past the amount of time required for a minor lid procedure.

A drawback of local infiltrative anesthesia is discomfort due to the anesthetic's low pH. While lidocaine's falls between 5.0 and 7.0, preservatives added by the manufacturers lower the pH of lidocaine/epinephrine to anywhere from 3.3 to 5.5. Buffering with 8.4% sodium bicarbonate at a ratio of 1 to 10 lidocaine/epinephrine 1:100,000 or 1 to 15 lidocaine/epinephrine 1:200,000 will bring the pH close to the physiologic pH, thereby reducing pain with injection.^{12,13} Adding sodium bicarbonate also shortens the duration of action of epinephrine while speeding up lidocaine's onset of anesthesia.^{12,13} Another simple step to increase comfort is to bring the temperature of the anesthetic up to body temperature prior to administration.¹⁵



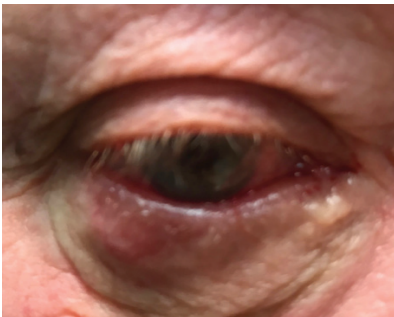
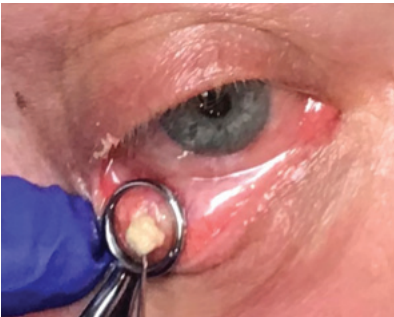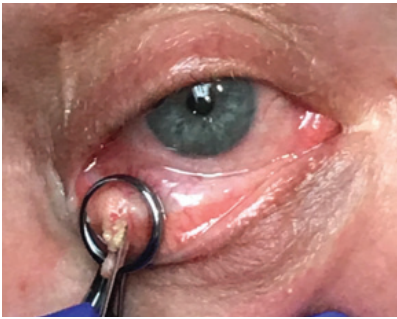Figs. 2 and 3. Before making an incision on the chalazion (left), carefully inject the anesthetic. You may use a chalazion clamp to isolate the lesion before injection (right).

Local anesthesia is not without potential side effects. Though rare, severe allergic reactions, contact dermatitis, lightheadedness, nausea, bradycardia, hypotension and seizures are possible.¹² In addition, some patients can experience psychogenic attacks due to anxiety over the procedure or fear of needles. These types of attacks often elicit a vasovagal response, which can lead to syncope.¹² For that reason, most injections are performed with the patient in a supine position.

Handle Injections With Care

The two types of injections are *subcutaneous* and *intralesional*. Subcutaneous injections are how local anesthesia is administered—below the epidermis and dermis layers—while intralesional injections are given directly into the lesion.

Subcutaneous injection for anesthesia. First, clean the top of the medication vial with an alcohol wipe. Prepare the syringe by drawing the solution from the vial using an 18-gauge needle. Then, change to a 27- to 30-gauge needle in preparation for administration. Some clinicians use a Jaeger plate or corneal shield to protect the globe during the injection. To do so, first instill ophthalmic proparacaine, then have the patient look in the opposite direction of the lid to be injected and insert the plate posterior to the lid and anterior to the globe. Pull the eyelid taut and ask the patient



Figs. 4-6. Granulomatous material will extrude from the lesion upon incision (top). Curette the chalazion (middle) upon incision. Eyelid immediately post-op (bottom) shows bruising from the procedure but overall improvement in cosmetic appearance.

to look away from the site you are injecting. Let the patient know they will feel a needle stick, and, with the bevel of the needle facing up, insert the needle in a subtle stabbing motion at a 15-degree angle to the skin into the subcutaneous layer beneath the lesion (*Figure 1*).

Slowly inject the desired amount of anesthetic, creating a bolus under the skin, and then remove the needle slowly. Depending on lesion size and

shape, it may be necessary to inject the lesion at additional sites. For increased patient comfort, it is best to go through the already anesthetized area for subsequent injections. Once the desired amount is injected and encompasses the lesion to be removed, place gauze over the area while applying gentle pressure and massage the anesthetic into the tissue. Make sure to test for numbness before beginning any procedure.¹³

Intradermal injection for chalazion. Administering 40mg/mL Kenalog (triamcinolone acetate, Bristol-Myers Squibb) provides a viable alternative to incision and curettage.^{8,13} In some instances, such as with children or when lesions are close to the lacrimal apparatus, steroid injection is actually the treatment of choice.¹³

Treatment can be performed with or without prior anesthesia. Injection approach can be made through the palpebral conjunctiva or the external eyelid. The transconjunctival approach is preferred in darkly pigmented individuals, as focal hypopigmentation can occur at an external injection site.¹³ A chalazion clamp is typically used to isolate the lesion and protect the globe.

The medication must be well-shaken before being drawn and needs to be injected soon after preparation to keep it from precipitating out of the solution. Draw 0.5mL of triamcinolone acetate into a syringe with a 25-gauge needle. Next, stand beside the patient, pull the lid taut and have the patient look opposite the area of injection. The angle to inject the needle will vary depending on the size of the chalazion but should be shallow enough to prevent full-thickness penetration of the eyelid and/or globe perforation. Insert the needle directly into the center of the lesion using a technique similar

to the one described earlier for anesthesia. Remember that some resistance may be encountered due to the wall of the chalazion. While only about 0.05mL can be injected into a chalazion, some clinicians also elect to inject 0.1mL of additional steroid paralesionally to help achieve further, albeit more gradual, penetration.

Results from triamcinolone injections can be seen between one to four weeks. If the chalazion is not completely resolved at one month, you may give an additional injection or perform incision and/or curettage.¹³ The success rate of only one injection resolving a chalazion is approximately 80%.¹⁶

An important caveat regarding the injection of intralesional corticosteroid is the potential for central retinal artery occlusion due to the retrograde passage of particulate from a periorbital artery in the eyelid into the ophthalmic artery past the point of branching of the central retinal artery. When using needles with larger diameters, inject the steroid with as little force possible and know the anatomy of eyelid and adnexal vasculature in order to minimize this risk. Adult human periorbital arterioles have average lumen diameters of 0.5mm.¹⁷ A 27-gauge needle has an external diameter of 0.41mm while a 25-gauge needle has a diameter of 0.52mm.^{18,19} While the risk of this occurring is low, there have been several documented cases of retinal artery occlusion following intranasal, forehead and eyelid corticosteroid injections.²⁰

Become a Surgical Expert

These surgical treatment options require a lot of attention to detail in order to avoid complications, such as scarring. Get these techniques down pat and learn to use the appropriate tools correctly.



OPHTHALMIC INNOVATION SUMMIT

SAVE
THE
DATE

NEW
ORLEANS

FEB 21
2019

**FACILITATING MEANINGFUL INTERACTIONS AND THE EXCHANGE OF
INFORMATION BETWEEN INDUSTRY AND CLINICAL LEADERS SINCE 2009.**

OIS has expanded our mission of highlighting innovations for the comprehensive ophthalmic community by launching the inaugural OIS@SECO. This exclusive half-day meeting is limited to the leading eye care and industry professionals to enhance networking and the exchange of insights. Attendees will experience rapid fire presentations on innovative treatments and hear lively panel discussions addressing challenges and opportunities impacting patient care.

FOR MORE INFORMATION, VISIT WWW.OIS.NET

Incision and curettage of chalazia. The definitive yet more invasive treatment for chalazia is incision and curettage (Figure 2).¹⁹ This procedure may be selected as the initial treatment option due to its high success rate or when a chalazion has failed to respond to corticosteroid injections. Instill topical proparacaine to help increase patient comfort during the procedure. Then, inject the anesthetic around the lesion externally as described previously to numb the eyelid around the chalazion (Figure 3). After several minutes, test the area for anesthesia.

Once numb, evert the eyelid and place a chalazion clamp with the open ring surrounding the lesion on the palpebral conjunctiva and the plate against the outer eyelid. Allow the clamp to hang gently from the eyelid and rest on the forehead or cheek, away from the cornea. At this point, if so desired, more anesthetic can be injected into the chalazia through the palpebral conjunctiva while remaining anterior to the tarsal plate. A sterile surgical blade is then used to make a 3mm vertical incision over the chalazion, parallel to the meibomian glands. It is best to remain 2mm to 3mm away from the lid margin to prevent notching of the eyelid.

Upon incision, granulomatous material will often erupt through the opening (Figure 4). Next, insert the curette into the incision and begin to scrape and scoop the material from the chalazion (Figure 5). You may send some of this material for pathology if desired, but always send it in any case of recurrent chalazion due to the possibility of meibomian gland carcinoma.^{13,16}

To prevent recurrence, ensure the entire sac surrounding the lesion is removed. Grasp the

sac with toothed forceps and use surgical scissors to detach it from surrounding tissue if needed. Remove the clamp and hold gauze over the lid while applying gentle pressure for hemostasis. In case of recalcitrant bleeding, a disposable thermal cautery unit can be used. Instill ophthalmic antibiotic ointment, such as erythromycin or polysporin. Some prefer to use a steroid/antibiotic combination for anti-inflammatory coverage.

Prescribe an ophthalmic antibiotic for one week post-procedure. Be sure the patient understands that drainage may occur for several days. Educate the patient to return to the clinic if any signs/symptoms of infection occur and schedule the patient for follow-up in five to seven days to ensure adequate healing is obtained (Figure 6).¹³

Snip excision. Benign lesions such as squamous papilloma, seborrheic keratosis and verruca can be removed in-office by simple snip excision (Figure 7). Signs of benign lesions include even coloration, well-defined regular borders, lack of ulceration, no induration, a history of slow growth and maintenance of normal skin structures such as lashes and glands.¹⁶ We often find patients can tolerate snip excision without anesthesia, especially for pedunculated masses. If anesthesia is desired, inject the anesthetic at the lesion base.

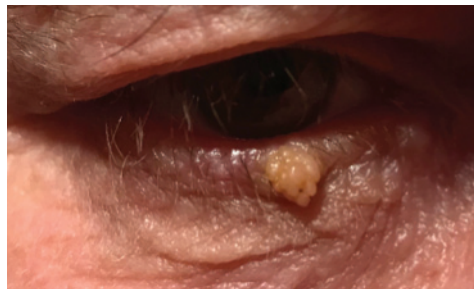


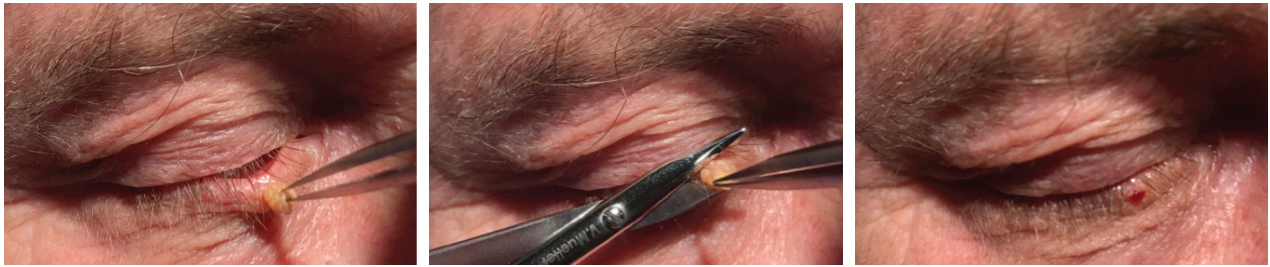Fig. 7. A squamous papilloma is a benign lesion that can be removed in the office.

Once the area is numb, grasp the mass with toothed forceps, pull it slightly away from its base and snip it free (Figures 8, 9 and 10). Light pressure with a small gauze pad for a few minutes usually stops any bleeding, but a disposable thermal cautery unit comes in handy if bleeding continues. Place the specimen in a formalin container suitable for transport to the laboratory for histologic evaluation.

Prior to releasing the patient, apply a prophylactic antibiotic ointment, such as erythromycin or polysporin, and advise them to keep the area clean and dry and apply the ointment three times daily for three days. If any signs or symptoms of infection develop, the patient should return to the office.¹³

Excision using the Ellman radio-surgical probe. Lesions that have a broader base and cannot be easily removed with a simple snip excision may be good candidates for removal with the Ellman Surgitron instrument. This device applies high-frequency radio waves to tissue to excite water molecules and generate heat, vaporizing the water and causing cell lysis. This creates a sterile cut with very clean edges. This type of surgical technique has the advantages of minimal blood loss and rapid healing.²¹

There are a few drawbacks to using the Ellman. Vaporization of the tissue produces vapor with a very strong odor and can release particles that could be inhaled (think verruca) into the air. Hence, it is important to use the compatible vacuum apparatus to remove any resultant vapor. This instrument must not be used with patients who have pacemakers, as it can interfere with the device's function. It is also important to avoid using this instrument in the presence of



Figs. 8-10. When excising a squamous papilloma, isolate with forceps to expose the base (left) and use surgical scissors to snip the lesion free at its base (middle). Note the minimal amount of blood seen after lesion removal with snip excision (right).

flammable fumes or liquids.²¹

To perform a lesion removal using the Ellman device, have the patient in a supine position with their head against the exam chair's headrest. The ground plate, necessary for transmitting the radio waves, can be placed between the patient's shoulder and the chair. The lesion and surrounding area must be prepped with a betadine swab. After several minutes, administer the anesthetic. When the patient is sufficiently numb, lesion removal can begin.

Turn on the device and allow it to warm up for at least 30 seconds. Choose the appropriate waveform and power setting. Our practice tends to use the cut and coagulation waveform with a power setting of four, though there is slight variability to each unit, and you should take time to become accustomed to the various settings on your specific device. To activate the electrode, press down the footplate. Radio waves are most effectively transferred to tissue with a high water content, so keeping the lesion surface moist with sterile gauze saturated with sterile saline in between passes of the electrode facilitates effective lesion removal. Grasp and lightly pull pedunculated lesions with tissue forceps and then use a loop electrode to cut at the base of the lesion to remove in one piece. The remaining edges can then be cleaned with passes of the

probe until a uniform appearance is achieved.

The other method, feathering, is helpful in broad-based sessile lesions and involves passing over the lesion with the electrode, removing it in layers using a brush-like motion, cleaning and re-wetting after a few passes. A ball electrode may be employed in the rare case of excessive bleeding. Once removal of the lesion is complete, clean the area with sterile saline to remove any betadine remaining. Apply a layer of topical ophthalmic antibiotic over the affected area.^{21,22} Again, have the patient apply antibiotic ointment three times per day for three to seven days to ensure proper healing.

Optometrists care for the eye and vision needs of more Americans than any other medical professional. We should seize this opportunity to provide the most efficient and state-of-the-art services and procedures possible, as taught in our professional schools and continuing education courses. Add these procedures to your professional skillset and you will be on your way to doing so. ■

Drs. Burress, Bendure and Kedzuz are all staff optometrists at the Ernest Childers VA Outpatient Clinic in Tulsa, OK, and adjunct professors at the Oklahoma College of Optometry.

1. Optometric surgical privileges improve access to care, ease financial burdens. Heallo. www.heallo.com/optometry/primary-care-optometry/news/print/primary-care-optometry-news/%7Bcb12a392-483f-41bb-8f2f-cfc3c3bc2083%7D/optometric-surgical-privileges-improve-access-to-care-ease-financial-burdens. Published January 2012. Accessed December 15, 2018.
2. An action-oriented analysis of the state of the optometric profession: 2013. Jobson Medical Information. 2013. www.aoa.org/Documents/news/state_of_optometry.pdf.
3. Governor Bill Walker signs HB 103 into law [news release]. Juneau, AK. Office of the Governor; July 11, 2018. akoa.org/news_manager.php?page=14408. Accessed December 15, 2018.
4. Eisenberg J. Kentucky expands ODs' scope of practice. *Rev Optom*. 2011;148(3):4-6
5. Louisiana Gov Jindal signs expanded scope of practice bill. AOA News. www.aoa.org/news/advocacy/louisiana-governor-jindal-signs-expanded-scope-of-practice-bill. Published June 2, 2014. Accessed December 15, 2018.
6. Kelly E. Nebraska increases scope-of-practice for ODs. *Review of Optometry*. www.reviewofoptometry.com/article/nebraska-increases-scope-of-practice-for-ods. Published May 15, 2014. Accessed December 15, 2018.
7. Murphy J. New Mexico passes minor surgery law. *Review of Optometry*. www.reviewofoptometry.com/article/new-mexico-passes-minor-surgery-law. Published May 4, 2007. Accessed December 15, 2018.
8. Fenelli J. Injection: the third method of drug administration. *Rev Optom*. 2012;149(1):32-40.
9. Oregon State Law. Chapter 683. Optometrists; Opticians. 2017 Edition. www.oregonlegislature.gov/bills_laws/ors/ors683.html. Accessed December 15, 2018.
10. Legislation in Tennessee to allow ODs to use injectable anesthetic. *Review of Optometry*. www.reviewofoptometry.com/article/legislation-in-tennessee-to-allow-ods-to-use-injectable-anesthetic. Published April 15, 2014. Accessed December 15, 2018.
11. RO staff. Virginia ODs enjoy expanded scope of practice. *Review of Optometry*. www.reviewofoptometry.com/article/virginia-ods-enjoy-expanded-scope-of-practice. April 11, 2018. Accessed December 15, 2018.
12. Robinson J, Siegel D, Hanke C, Fratila A. *Surgery of the Skin*. 3rd ed. New York: Elsevier Saunders, 2015.
13. Casser L, Fingeret M, Woodcome H. *Atlas of Primary Eyecare Procedures*. Stamford: Appleton and Lange, 1997.
14. Johnson K. *Clinical Pharmacology for Anesthesiology*. New York: McGraw-Hill, 2015.
15. Tyers A and Collin J. *Colour Atlas of Ophthalmic Plastic Surgery*. 4th ed. New York: Elsevier, 2018.
16. Bowling B and Kanski J. *Kanski's clinical ophthalmology: a systematic approach*. 8th ed. Edinburgh: Elsevier, 2016.
17. Egbert JE, Paul S, Engel WK, Summers CG. High injection pressure during intralesional injection of corticosteroids into capillary hemangiomas. *Arch Ophthalmol*. 2001;119:677-83.
18. Samimi D, Alabiad C, Tse D. An anatomically based approach to intralesional corticosteroid injection for eyelid capillary hemangiomas. *Ophthalmic Surg Lasers Imaging* 2012;43:190-5.
19. Technical Information—Gauge index. Hamilton Company. www.hamiltoncompany.com/technical-information/syringe_gauge-index?z=1. Accessed December 15, 2018.
20. Li B, Allen LH, Shiedow TG. Vision loss and vascular compromise with facial and periorcular injections. *Can J Ophthalmol*. 2015;50(2):e57-60.
21. Venkataram M. *Textbook on cutaneous and aesthetic surgery*. New Delhi: Jaypee Brothers Medical Publisher, 2012.
22. Eshraghi B, Torabi H, Kasaie A, Rajabi M. The use of radiofrequency unit for excisional biopsy of eyelid papillomas. *Ophthal Plast Reconstr Surg*. 2010;26(6):448-9.



The Preoperative Ocular Surface Checkup

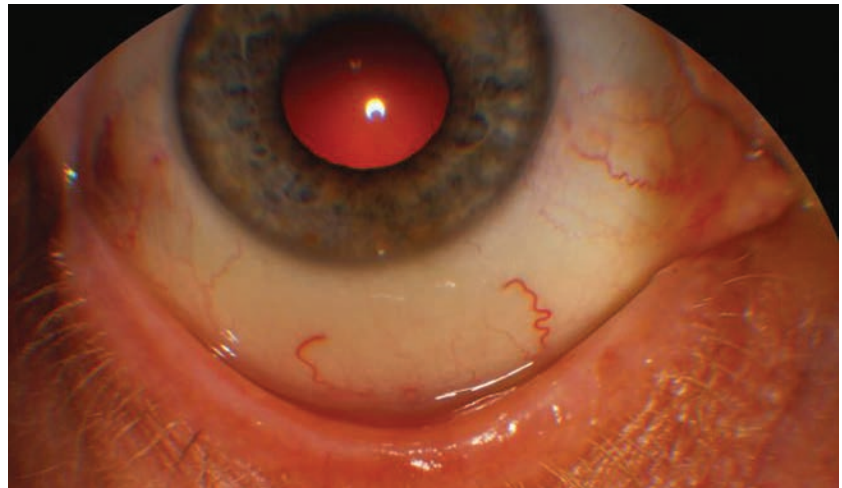
Before any invasive procedures, ODs need to clear the patient and pretreat underlying issues. **By Beth Norris, OD, Sara Henney, OD, Lauren Barnhart, OD and Maria Mandese, OD**

Ocular surface disease (OSD), including dry eye disease (DED), is among the most common post-operative complaints and should be addressed prior to any ocular surgery. Since patients are typically asymptomatic, it falls on the optometrist to evaluate all patients for signs of OSD. If any are found, optometrists should take the lead in treating and managing it prior to any procedure.

This article reviews how to spot signs of the myriad conditions that fall under the OSD umbrella—including DED, lid and lash conditions and allergies. It includes details about how these disease states can be unveiled using modern imaging technologies. Finally, it will offer treatment protocols designed to improve patients' post-operative ocular surface outcomes.

Ocular Surgery: Friend or Foe?

Refractive surgery techniques have evolved from incisional (RK) to surface ablation (PRK) to microkeratome and then femtosecond laser-assisted flap creation (LASIK)



This patient's blepharitis is caused by either bacteria or *Demodex*—a mite infestation—on the lid. Resolution of either one is necessary before surgery.

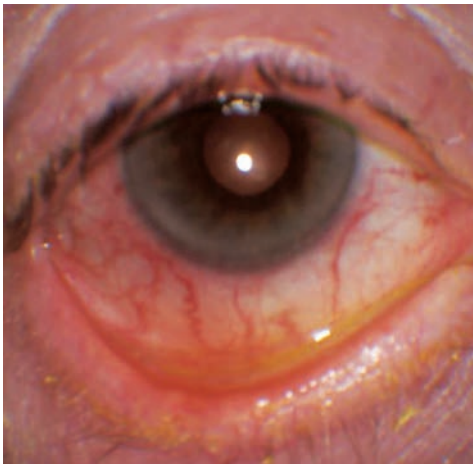
to small-incision lenticule extraction (SMILE). As these procedures evolved, the complications that affect the ocular surface have typically improved. According to a recent study, tear film dysfunction was identified as the most common reason for referral to a tertiary eye clinic following refractive surgery.¹

Research shows LASIK has an impact on tear production and, therefore, could aggravate any underlying ocular surface issues in

patients with moderate-to-severe DED.² Photorefractive keratectomy (PRK) may need to be considered in this subset of patients because it causes less progression of DED. SMILE—currently only an option for patients who are myopic (with or without astigmatism)—is a minimally invasive approach to refractive surgery due to the lack of flap creation and may better preserve the corneal integrity and nerve density compared with LASIK.³

COMBO

SELECT YOUR CHAIR



Ocular rosacea, as seen here, can lead to dry eye and blepharitis issues that complicate surgery.

Cataract surgery has evolved over the years and provides excellent visual outcomes when the ocular surface is pretreated. Treating patients' OSD and DED also helps to decrease the severity of postoperative symptoms. Research shows that corneal denervation persists up to three months with phacoemulsification.⁴ A recent study found that perioperative ocular parameters, such as high ocular surface disease index (OSDI) scores at baseline, low tear break-up time, low meibomian gland orifice obstruction scores and increased meibomian gland dropout one month after surgery were all risk factors for persistent dry eye symptoms after cataract surgery.⁵ As clinicians, we must be attuned to the variety of treatment options available and tailor them to individual patients.

Dry Eye Disease

DED is one of the most prevalent conditions in the United States, and perhaps one of the most commonly encountered diagnoses seen on a daily basis. According to a recent article based on weighted estimates, approximately 6.8% of American adults are projected to

have DED.^{6,7} The prevalence of dry eye increases with age and is more predominant in women than men.⁶ The etiology of the condition is much more complex; however, we know that ocular surface inflammation is a key component of DED.⁶ Ocular disease, infection, or autoimmune conditions can cause chronic inflammation, and environmental exposures can exacerbate it.⁸

DED is classically divided into aqueous deficient dry eye (ADDE) and evaporative dry eye (EDE) with overlap occurring between the two.⁶ The two

primary mechanisms that contribute to DED are tear hyperosmolarity and tear film instability.⁶ Hyperosmolarity results in an inflammatory cascade that damages the ocular surface and releases inflammatory mediators into the tears.⁶ Both ADDE and EDE are associated with tear hyperosmolarity.⁶ Tear film instability can arise secondary to tear hyperosmolarity, or can be the initiating event in the disease process.⁶ A reduced lipid layer in meibomian gland dysfunction can also cause tear film instability.⁶

DED Signs and Symptoms

The patient's systemic history is vital to a proper diagnosis—and that includes any medications being taken. Tear deficiency causes dryness, red eyes, irritation, burning or foreign body sensation, excessive or lack of tearing, itching, light sensitivity, blurred vision, contact lens intolerance and eyestrain.⁹ DED may be associated with no signs and only symptoms or vice-versa.⁶

Uncovering signs and symptoms requires the use of various diagnostic tools. Questionnaires such as the OSDI are designed to detect



1000-CH
Examination
Chair



1800-CH
Manual
Recline

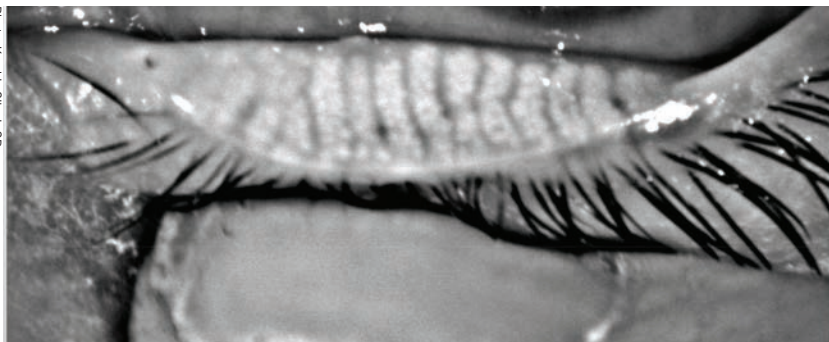


2000-CH
Cradle Tilt



2500-CH
Motorized
Recline

Photo: Kamalz Sistani, OD



This meibography image displays the glands of a patient healthy enough for surgery.

patients with symptoms of DED prior to examination. Fluorescein stains may help identify signs and fluorescein dye can help evaluate tear break-up times. Lissamine green or rose bengal stains are used to evaluate the conjunctiva. Schirmer (and phenol red thread) testing may also provide information. Tear osmolarity testing can assess the osmolarity of the tears—a key sign of DED. Abnormal values are greater than 300mOsm/ml (or greater than 8mOsm/ml of inter-eye difference).¹⁰

Matrix metalloproteinase-9 (MMP-9) testing also shows a high sensitivity and specificity in diagnosing OSD. This test is measured using InflammDry (Quidel) and is considered positive if the concentration of MMP-9 measured in the assay is higher than 40 ng/mL.¹⁰

If it is determined during a pre-operative examination a patient is experiencing early DED, preventative management should be initiated.

DED Therapies

Once diagnosed, treatment should be based on the underlying condition(s) and the disease severity. Three basic strategies exist for ADDE and EDE: increase the amount of tears on the ocular surface, decrease tear evaporation and augment the lipid content or lubricity of the tears.⁸

Topical, over-the-counter lubricants, gels and ointments—both preserved and non-preserved—is one option to enhance the tear volume and quality. However, some cases may call for punctal plugs or cautery, autologous serum and therapeutic contact lenses such as scleral lenses available.

The Tear Film & Ocular Surface Society Dry Eye Workshop II report's Diagnostic Methodology report gives us a starting point to assess DED severity as well as the diagnostic tests to perform, but DED has no one size fits all treatment. The screening DEQ-5 or OSDI confirms that a patient might have DED and triggers the diagnostic tests of noninvasive break-up time, osmolarity and ocular surface staining with fluorescein and lissamine green. On initial diagnosis, ODs must exclude conditions that mimic DED with the aid of the triaging questions and assess the risk factors that may inform management options. Over-the-counter lubricants are typically reserved for mild signs and symptoms of DED and more aggressive therapy should be initiated as necessary.¹¹

Two options include Restasis (cyclosporine, Allergan) and Xiidra (lifitegrast, Shire). Restasis is designed to help increase tear production by reducing ocular surface inflammation and directly affecting

lacrimal gland function. Xiidra is designed to block the interaction of ICAM-1 and LFA-1, which are key mediators of dry eye inflammation.¹² Short-term steroid use may also reduce inflammation.

Fish oil and flaxseed supplements—previously believed to enhance tear production and quality—failed to show such results in a controversial recent study in the *New England Journal of Medicine*.¹³ Some critics cite flaws in the methodology of this study, making conclusions difficult to draw.

DED patients must take lifestyle and environmental considerations into account to optimize their treatments. That may mean wearing protective eyewear, using a humidifier, reducing screen time and even increasing fluid intake while avoiding triggers, such as direct air flow from air conditioners, fans and heating units.

Lid Conditions

Not every compromised ocular surface is due to DED. Patients may be suffering from one (or more) of several conditions that DED therapies alone can't address. For instance, research shows blepharitis in a whopping 60% of patients prior to surgery.¹⁴ It is the most common cause of cataract surgery cancellation, since it increases the risk of endophthalmitis.¹⁵ Patients with blepharitis will complain of itching, burning and crusting of the eyelids upon awakening.

Blepharitis is an eyelid inflammation that's divided into two categories: anterior and posterior. Anterior blepharitis consists of bacteria, *Demodex*, or both, residing on the lid. Posterior blepharitis is more commonly referred to as meibomian gland disorder (MGD). Both can lead to telangiectasia, scarring of the lid margins and

COMBOCOMBINE WITH OUR
UNIQUE STAND

DED. Disruption of the anterior surface of the tear film from these conditions can cause surgical complications including infections and inflammation from causative bacteria, predominately *Staphylococcus*.¹⁶ Observation under the slit lamp is used for diagnosis of these conditions; however, noncontact meibography can be used to evaluate the integrity of the glands.¹⁷

Treatment includes cleaning the surface and glands with warm compresses and lid hygiene to reduce bacteria. A combination of steroids and antibiotic drops (or ointment) may decrease inflammation. Topical azithromycin can be used as well to decrease bacterial lipases, which degrade the normal meibum.¹⁸

Demodex—a type of mite that can cause anterior blepharitis—can be eliminated with preformulated wipes containing tea tree oil.¹⁸ You can determine the condition is resolved when expression of the meibomian glands provides a clear oil, free from milky toothpaste-like consistency.¹⁸ In office expression with thermal pulsation is available for severe or chronic obstruction.¹⁹ Systemic antibiotics such as doxycycline or minocycline have great results in clearing MGD, but should be used with caution due to contraindications and side effects.²⁰

Treatment of these conditions before surgery can increase tear film quality and the accuracy of corneal topography and keratometry, creating better accuracy for intraocular lens alignment.¹⁴ It can also reduce the amount of bacteria in the tear film, reducing risk for infection or physical injury by the patient rubbing the eyelids.²¹

MGD can lead to morphological changes to the eyelid, which can increase dry eye symptoms indefinitely after cataract surgery.²¹ Stabi-

A Peek into the Future

OSD may be on the rise, but researchers are responding with a host of new pharmaceutical agents, diagnostic and treatment technologies and approaches to managing it.

One new formulation, KPI-121 0.25% ophthalmic solution (Kala Pharmaceuticals) is undergoing phase III clinical trials in the Short Term Relief in Dry Eye (STRIDE) study for the short-term treatment of DED.¹ Another, Cequa (cyclosporine A 0.09% ophthalmic solution, Sun Pharmaceuticals) incorporates nanomicellar technology to help increase tear production in patients with DED.¹ Cequa was FDA approved earlier this year.

Anterior segment optical coherence tomography is also being used to evaluate early ocular surface changes with epithelial thickness mapping, the first non-contact quantitative measure of the corneal epithelium and stroma.²

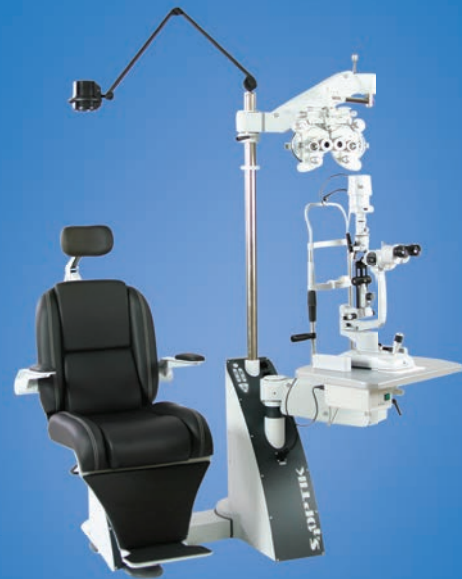Additionally, researchers are developing better diagnostic methods, such as examining biomarkers for DED. For instance, research shows the PAX-6 protein (which can be evaluated in tears) is down-regulated in patients with Sjogren's syndrome or clusterin.⁴

1. Kanellopoulos A, Asimellis G. In vivo 3-dimensional corneal epithelial thickness mapping as an indicator of dry eye: preliminary clinical assessment. *Am J Ophthalmol.* 2014;157:63-8.
2. Brooks M. FDA clears new treatment for dry eye (Cequa). *Medscape.* August 17, 2018. Accessed November 15, 2018.
3. Gupta P, Drinkwater O, VanDusen, K, et al. Prevalence of ocular surface dysfunction in patients presenting for cataract surgery evaluation. *J Cataract Refract Surg.* 2018;44(9):1090-6.
4. Clayton J. Dry eye. *N Engl J Med.* 2018;378(23):2212-23.

lizing the tear film and eyelids can result in better surgical outcome including visual function, healing time and comfort.¹⁴

Ocular Allergies

Allergic reactions, a form of atopy, can affect the conjunctiva, cornea and lids.^{22,23} They damage the surface of the eye by creating chronic inflammation.^{24,25} During and after surgery, medications, and their preservatives, can exacerbate allergies.²⁵ Current treatment methods aim to disrupt the allergic pathway.

**Effortless
instrument
positioning****Advanced
ergonomics**

An important mast cell mediator is histamines, which aid in cell growth and extracellular matrix production.²³ Release of tryptase by the mast cell in the conjunctiva activates the COX-2 pathway and fibroblast proliferation, aiding in the repair of the cornea after surgery or injury.²³

Currently, ocular allergies are a contraindication for LASIK.²⁵ Investigators have demonstrated that corneal haze and regression of myopia after PRK was more significant when allergic eye disease was left untreated.²⁶ They found 12 months after surgery, patients with continued treatment of steroids and a mast cell stabilizer with allergic conjunctivitis, had significantly less corneal haze and less myopic regression.²⁶ Another research team was able to show patients with allergic conjunctivitis had a more significant immune response after LASIK, increasing inflammation compared with a healthy individual, leading to a possible contribution of DED post surgery.²⁵

Cyclosporine A can increase tear break-up time, according to the literature.²⁴ In one study, it increased Schirmer's Type I, decreased tear osmolarity and quickened the time frame for regaining corneal sensation.²⁴ Cyclosporine A also has benefits for allergic eye disease, it inhibits interleukin (IL-II, IL-IV), and interferon gamma.²⁴ It also inhibits lymphocyte proliferation with its interactions with T-cells, protecting goblet cells, which are essential to prevent DED.²⁴

Treatment and management of ocular allergies includes removing the inciting factors and prescribing either antihistamines, mast cell stabilizers or a combination. More aggressive approaches, such as prescribing immunosuppressive therapies (i.e., steroids), cyclosporine A

and in more serious cases treatment of secondary complications may be required depending on the duration and the severity of the reaction.

More severe types of keratopathies may require surgical interventions or even amniotic membrane grafts. If left untreated, this chronic inflammation contributes to ocular surface damage and DED.^{22,25}

Research does show it is possible to reach a good visual outcome using all methods of treatment, including immunosuppressive therapies, surgical procedures and prosthetic lens placements.²⁴

Ocular Rosacea

Fifty-eight percent to 72% of patients with rosacea—a chronic skin condition characterized by flushing, erythema, papules, pustules and telangiectasia of the central and periocular facial regions—develop the disease's ocular subtype.²⁶ While women are more commonly diagnosed with cutaneous rosacea, no gender predilection is known.²⁷ Ophthalmologic findings typically present in patients between 40 and 59 years old.²⁷

The condition is associated with inflammation, hyperkeratinization, hyperosmolarity and, ultimately, damage of the ocular surface.^{26,27}

Clinical findings usually begin with eyelid abnormalities, such as lid margin erythema and telangiectasia, blepharitis, MGD, recurrent hordeola and chalazia.²⁶⁻²⁸ Tear film debris or reduced tear break-up time and interpalpebral hyperemia are common.²⁸ Cicatricial conjunctivitis, fibrosis and symblepharon can affect the superior or inferior lids and conjunctiva.²⁶ Corneal involvement occurs in up to 33% of rosacea patients in the form of superficial punctate keratitis, peripheral neovascularization, subepithelial marginal infiltrates,

recurrent corneal erosions or even stromal ulceration and perforation, with the latter causing the patient pain and vision loss.²⁶ Other forms of ocular inflammation such as iritis, episcleritis and scleritis are associated with ocular rosacea as well.²⁶

These patients present with symptoms ranging from itching, burning, foreign body sensation, redness, tearing, photosensitivity, pain and lid swelling.^{26,28} Symptoms of ocular rosacea may wax and wane and correlate to individual triggers. Aggravating factors include exposure to sun or extreme temperatures, spicy foods, alcohol, exercise, menopause and emotional distress.²⁶ Additionally, medications such as amiodarone and nasal steroids or topical irritants can exacerbate the condition.²⁶

Managing the dry eye and blepharitis aspects of the disease starts with warm compresses, digital massage and eyelid scrubs with baby shampoo or tea tree oil followed by lubrication with artificial tears.²⁶ Topical cyclosporine dosed twice daily has been shown to be advantageous due to the inflammatory component of the disease.²⁸ Nutritional supplementation with fish oil and flaxseed may benefit patients and a few studies have shown favorable results with the use of oral omega-3 fatty acids.²⁶

Oral tetracyclines given 500mg BID for two to three weeks can treat ocular rosacea.^{27,28} Doxycycline dosed 100mg QD to BID for six to 12 weeks is regularly prescribed.^{27,28} Another FDA-approved option is prescription of 40mg daily of doxycycline as a long-term treatment for ocular rosacea.^{27,28} If unsuccessful, or when tetracyclines may be contraindicated, oral azithromycin 500mg per day for two weeks can be an alternative therapy.^{27,28}

Other management tools for ocular rosacea are dependent upon the signs and symptoms of each patient. LipiFlow (TearScience) uses heat and stimulation of the eyelid to aid in meibomian gland outflow and has been helpful in addressing EDED, which usually accompanies ocular rosacea.²⁷

Other management tools for ocular rosacea are to be determined by the signs and symptoms of individual patients. Excision and drainage of chalazia and the use of punctal plugs to alleviate associated dry eye complaints may be effective.

Patients who have any form of OSD before surgery will have OSD after surgery. It is important to diagnose ocular surface disease in patients being referred for surgery and then prepare, protect, rehabilitate and maintain a healthy ocular surface. This includes patient education as well as pretreating the ocular surface.

We must take an active role in determining who is at greatest risk of developing OSD and proactively treat patients prior to surgery to provide the best overall outcome. ■

Drs. Norris, Henney, Barnhart and Mandese are staff optometrists at the VA Health Care System in Orlando.

1. Patryn E, Vrijman V, Nieuwendaal C, et al. Indications for and outcomes of tertiary referrals in refractive surgery. *J Refract Surg.* 2014;30(1):54-61.
2. Lee J, Ryu C, Kim J, et al. Comparison of tear secretion and tear film instability after photorefractive keratectomy and laser in situ keratomileusis. *J Cataract Refract Surg.* 2000;26:1326-31.
3. Kobashi H, Kamiya K, Shimizu K. Dry eye after small incision lenticule extraction and femtosecond laser-assisted LASIK: meta-analysis. *Cornea.* 2017;36(1):85-91.
4. Gomes J, Azar D, Baudouin C, et al. TFOS DEWS II iatrogenic report. *The Ocul Surf.* 2017;15:511-38.
5. Choi Y, Park S, Jun I, et al. Perioperative ocular parameters associated with persistent dry eye symptoms after cataract surgery. *Cornea.* 2018;37(6):734-9.
6. Craig J, Nichols K, Akpek E, et al. TFOS DEWS II definition and classification report. *Ocul Surf.* 2017;15:276-83.
7. Farrano F, Fridman M, Stillman I, et al. Prevalence of diagnosed dry eye disease in the United States among adults aged 18 years and older. *Am J Ophthalmol.* 2017;182:90-8.
8. Clayton J. Dry eye. *N Engl J Med.* 2018 Jun 7;378(23):2212-2223.

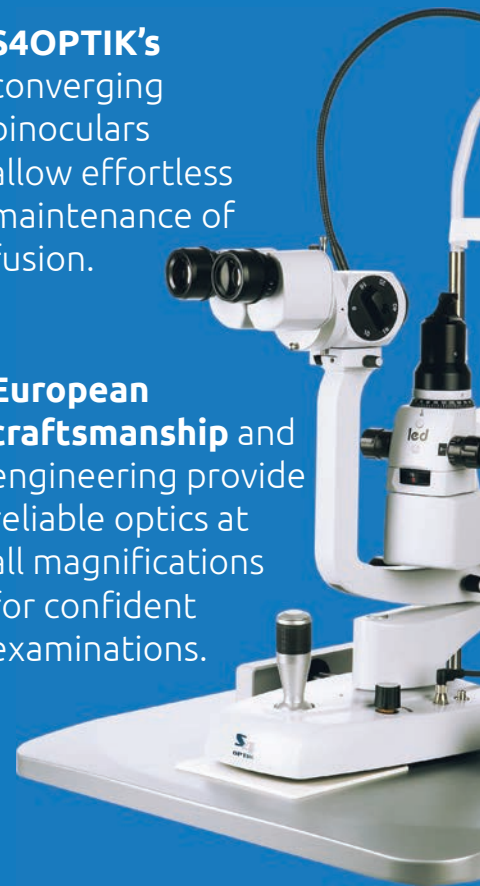9. Valim V, Trevisani V, de Sousa J, et al. Current approach to dry eye disease. *Clinical Rev Allerg Immunol.* 2015;49:288-97.
10. Gupta P, Drinkwater O, VanDusen, K, et al. Prevalence of ocular surface dysfunction in patients presenting for cataract surgery evaluation. *J Cataract Refract Surg.* 2018;44(9):1090-6.
11. Wolffson, J, Arita, R, Chalmers, R, et al. TFOS DEWS II Diagnostic Methodology report. *The Ocular Surface* 2017; 15 (3):539-74.
12. Donnenfeld E, Karpecki P, Majmudar P, et al. Safety of Lifitegrast Ophthalmic Solution 5.0% in Patients With Dry Eye Disease: A 1-Year, Multicenter, Randomized, Placebo-Controlled Study. *Cornea.* 2016;35(6):741-48.
13. Asbell P, Maguire M, Pistilli M, The Dry Eye Assessment and Management Study Research Group, et al. N-3 fatty acid supplementation for the treatment of dry eye disease. *N Engl J Med.* 2018;378:1681-90.
14. Luchs J, Buzzego C, Trattler W. Prevalence of blepharitis in patients scheduled for routine Cataract Surgery. Poster presented at ASCRS Symposium Cataract IOP and Rx Surgery. April 11, 2010. Boston MA.
15. Afsharkhamesh N, Movahedan A, Motahari H, Djililian A. Cataract surgery in patients with ocular surface disease: an update in clinical diagnosis and treatment. *J Ophthalmology.* 2014;28(3):164-7.
16. Teweldemedhin M, Gebreyesus H, Atsbaha A, et al. Bacterial profile of ocular infections: a systematic review. *BMC Ophthalmol.* 2017;17(1):212.
17. Arita R, Itoh K, Inoue K, Amano S. Noncontact infrared meibography to document age-related changes of the meibomian glands in a normal population. *Ophthalmol.* 2008;115(5):911-5.
18. Foulks G, Borchman D, Yappert M, Kakar S. Topical azithromycin and oral doxycycline therapy of meibomian gland dysfunction: a comparative clinical and spectroscopic pilot study. *Cornea.* 2013;32(1):44-53.
19. Blackie C, Carlson A, Korb D. Treatment for meibomian gland dysfunction and dry eye symptoms with a single dose vectored thermal pulsation: a review. *Curr Opin Ophthalmol.* 2015;26(4):306-13.
20. Doughty M. On the prescribing of oral doxycycline or minocycline by UK optometrists as part of management of chronic Meibomian Gland Dysfunction (MGD). *Cont Lens Anterior Eye.* 2016;39(1):2-8.
21. Park Y, Hwang H, Kim H. Observation of influence of cataract surgery on the ocular surface. *PLoS ONE.* [journals.plos.org/plosone/article?id=10.1371/journal.pone.0152460](https://doi.org/10.1371/journal.pone.0152460). October 3, 2016. Accessed November 15, 2018.
22. Kanski J. *Clinical Ophthalmology: A Systemic Approach.* 5th ed. Philadelphia: Butterworth-Heinemann, 2003.
23. Das S, Pasari A, Sangwan V. Vernal keratoconjunctivitis: culmination of management using immunosuppression, surgical, and prosthetic therapy over a quarter of a century. *BMJ Case Reports.* [casereports.bmj.com/content/2016/bcr-2016-217759.abstract](https://doi.org/10.1136/bcr-2016-217759). November 8, 2016. Accessed November 15, 2018.
24. Hamada S, Moore t, Moore J, et al. Assessment of the effect of cyclosporine-A 0.05% emulsion on the ocular surface and corneal sensation following cataract surgery. *Contact Lens and Anterior Eye.* 2016;39(1):15-9.
25. Wilson D, Schutte S, Abel S. Comparing the efficacy of ophthalmic NSAIDs in common indications: A literature review to support cost-effective prescribing. *Ann Pharmacother.* 2015;49(6):727-34.
26. Wladis E, Adam A. Treatment of Ocular Rosacea. *Surv Ophthalmol.* 2018;63(3):340-6.
27. Vieira Ana, Höfling-Lima A, Mannis M. Ocular rosacea: a review. *Arquivos Brasileiros de Oftalmologia.* 2012;75(5):363-9.
28. Arman, Aysegul, et al. "Treatment of Ocular Rosacea: Comparative Study of Topical Cyclosporine and Oral Doxycycline." *International Journal of Ophthalmology.* U.S. National Library of Medicine, 18 June 2015, [www.ncbi.nlm.nih.gov/pmc/articles/PMC4458660/](https://pubmed.ncbi.nlm.nih.gov/pmc/articles/PMC4458660/).

S4OPTIK SLIT LAMPS

SEE MORE - Exceptional Optics

S4OPTIK's
converging
binoculars
allow effortless
maintenance of
fusion.

European
craftsmanship and
engineering provide
reliable optics at
all magnifications
for confident
examinations.



Vertical and compact
configurations available.

S4OPTIK

250 Cooper Ave., Suite 100 Tonawanda NY 14150

www.s4optik.com | 888-224-6012

Sensible equipment. Well made, well priced.

For today's modern office.



Understanding the Role of IOL Optics in Postoperative Vision Complaints

The more you know about the causes and characteristics of dysphotopias, the better you'll be at responding to patients' concerns. **By Daniel H. Chang, MD, and Laura K. Huggins, OD**

Presbyopia-correcting IOLs can provide vision without glasses at all distances for patients after cataract surgery, though some compromises are expected. The optics of these IOLs have improved in recent years through the correction of optical aberrations and the clever use of diffractive optics to increase depth of field. Modern presbyopia-correcting IOLs offer ranges of options and levels of patient satisfaction not previously possible. In spite of these advances, some compromises can still be expected.

No FDA-approved IOL provides true accommodation akin to that of the human eye, and with all pseudoaccommodating IOLs, increasing depth of field is associated with dysphotopias in night vision. While some doctors avoid recommending presbyopia-correcting lenses altogether because of concerns related to possible dysphotopias, it is important to consider that *not* correcting presbyopia surgically and relying on multifocal spectacles can have its own set of risks that are more than just an annoyance.

Multifocal (bifocal, trifocal and progressive) spectacles contribute significantly to the risk of trips and falls in the elderly. One study found that multifocal spectacle wearers were more than twice as likely to fall and that multifocal glasses accounted for nearly 41% of the attributable risk for falls outside the home.¹ The

Centers for Disease Control (CDC) reports that falls are a leading cause of injury and death in older Americans. In fact, an older adult falls every second of every day, leading to seven million injuries, and over 27,000 elderly deaths (more than from breast cancer or prostate cancer) annually.² Falls also threaten the independence and quality of life of seniors.

Patients who fall do not typically go to their eye doctors; therefore, the eye care community has not appreciated the impact of these incidents on our patients. Nevertheless, since falls can be prevented, we should rethink our approach to treating presbyopia. We should at least consider prescribing separate glasses for distance and near, and we should also consider offering surgical options that reduce the need for progressive/multifocal glasses.

Fortunately, there are many good options to increase the depth of field surgically. Both referring optometrists and surgeons who may have been unhappy with the results of earlier technology should consider newer presbyopia-correcting IOL options, since they offer more advantages and fewer disadvantages compared to older designs.

consider newer presbyopia-correcting IOL options, since they offer more advantages and fewer disadvantages compared to older designs.

Approaches to Presbyopia Correction

Multifocal intraocular lenses, like multifocal contact lenses, split the focus of incoming light to increase depth of field, resulting in visual quality tradeoffs.



Fig. 1. Ideally, with contrast and brightness both at 100%, there is no blur, providing a nice, sharp optotype and a high-quality visual experience.

The first multifocal IOLs used zonal refractive technology (more akin to the design of multifocal contact lenses) to split the light to far and near foci. Subsequent lenses used diffractive IOL technology to improve depth of field while improving visual quality both in the far and near (14" to 20") ranges.

The first extended-depth-of-focus (EDOF) lens, the Tecnis Symphony (Johnson & Johnson Vision) also uses diffractive technology but includes an echelette design to correct the chromatic aberration present in the cornea for improved contrast sensitivity and to produce a pattern of light diffraction that elongates the focus. This extends the range of quality vision with a reduced amount of night vision symptoms. It also moves the region of functional near vision towards intermediate, so proper patient selection and education become important factors in the ultimate success of implantation.

Optics and Visual Quality

The visual quality or sharpness of vision is largely determined by the presence of optical aberrations, which are affected by the material, design and manufacturing of the implanted IOL. Although we often talk about monofocal IOLs as the standard for quality, there is a notable range of image quality even among monofocal lenses (Table 1). In particular, aspheric optics have been a major factor in improving visual quality in recent years. Addressing chromatic aberration with low dispersion (high Abbe number) materials can build upon this to continue improving image quality. The range of chromatic aberration among common IOL materials is comparable to the difference between crown glass and polycarbonate.




Fig. 2a-c. Increase in the transition between foreground and background causes blur as the relative sharpness at the edge decreases, making it increasingly difficult to distinguish a crisp separation.

Patients rarely complain about visual quality after cataract surgery with monofocal IOLs. However, in those who opt for presbyopia correction too, there can be concerns about quality of vision. This can happen for several reasons: first, this latter group of patients tend to be younger and demand more from their vision; second, they are expecting to function well in many activities without glasses; third, they have invested out-of-pocket money to achieve these goals; and fourth, presbyopia-correcting IOLs do make optical trade-offs to increase depth of focus, and some IOL models even induce spherical and chromatic aberrations.

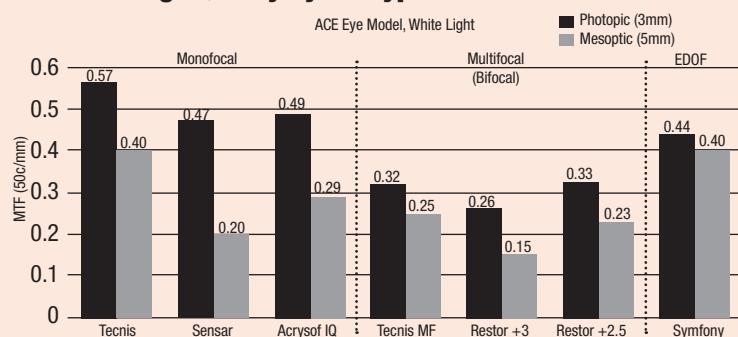
The Tecnis Symphony IOL, by correcting and minimizing chromatic aberration in addition to spherical aberration, demonstrates visual quality comparable to some monofocal IOL experiences. Petrotti et al. found no significant difference in contrast acuity or visual quality between the Tecnis Symphony and Tecnis monofocal IOLs, while patients with Symphony in fact had better uncorrected distance acuity and much lower dependence on glasses.³

Postoperative Vision Complaints

In evaluating patients who have postoperative visual complaints despite objectively good visual acuity, it is helpful to group their concerns into one of two broad categories: daytime visual quality and nighttime dysphotopsias. While the optical etiologies of these visual side effects are related, they manifest in different ways clinically.

Both daytime visual quality and nighttime dysphotopsias are related to the visual effects of light from a visual target that is not focused optimally on the macula. When light from a particular point source is not in focus, whether from being defocused or scattered, it lies off the visual axis. A small amount

Table 1. Image Quality by IOL Type



Source: Weeber HA, Chang DH, Piers PA. Evaluation of the Depth of Focus of Different IOL Designs. ESCRS, 2014




Fig. 3. Even a blurry image can be improved by magnification. Note that contrast is not reduced.




Fig. 4a-c. Here, the images remain sharp (i.e., no blur) but image resolution is reduced by lower contrast (4a), decreased lighting (4b) or both (4c).

of defocus of a large amount of energy or a large degree of defocus of a small amount of energy are the optical causes, respectively, of visual quality and dysphotopsia complaints.

Understanding Visual Quality

If patients have difficulties with daytime visual quality, they could be experiencing problems in one of two ways: blur and loss of contrast sensitivity. The difference can be illustrated by looking at the edges of optotypes on an eye chart.

When visual quality is good, an object or optotype has a clear transition from foreground to background, making it easy to identify and distinguish (*Figure 1*). As blur (or the spreading out of the transition between foreground and background) increases, the relative sharpness at the edge decreases, making it increasingly difficult to distinguish a crisp separation between foreground and background (*Figures 2a-c*). However, with a given amount of blur, magnifying the object (e.g., by moving it closer) can make it easier to distinguish (*Figures 3a-c*).

Similarly, contrast (the difference in intensity between the background and the foreground) and brightness (light) help us to discern an object or optotype. In an ideal situation, contrast and brightness are both at 100%, and there is no blur, providing a nice, sharp optotype and a high-quality visual experience (*Figure 1*). However, with lower contrast (*Figure 4a*), decreased lighting (*Figure 4b*) or both (*Figure 4c*) the optotype becomes more difficult to see. For this reason, increased light can improve quality of vision in low contrast situations.

While it is paramount for the surgeon to correct refractive error and to select IOLs with excellent optical qualities, some postoperative visual problems can be addressed by the optometrist. Post-op refractive error continues to be the most common cause of visual complaints. A careful refraction can determine if glasses, or perhaps laser vision correction, may be helpful. When refracting an EDOF lens like the Tecnis Symphony, be sure to push plus (like for a young accommodating patient); the increased depth of field can cause autorefractors to overminus by up to 1.5D. Additionally, identifying treatable medical conditions like dry eye, posterior capsular opacification (PCO) or cystoid macular edema are important.

Less commonly, after implantation of a multifocal or EDOF lens, a patient might note that letters or objects are sharp but additionally note a “fuzziness, shadow, or glow” around them (*Figure 5*). Since there is a high-contrast sharp edge present, patients with these symptoms typically can still achieve good visual acuity and visual function. While there is no quick-fix for this symptom, patients typically just need reassurance and adequate time for neuroadaptation. Uncommonly, some patients may not be able (or willing) to adapt, and thus might be candidates for IOL exchange.

Dealing with Dysphotopsia

In addition to concerns about daytime visual quality, increasing the depth of field can also lead to dysphotopsias in low-light conditions, typically resulting in symptoms with night vision. Early-generation multifocal IOLs were associated with significant halos, but subsequent improvements in recent years have reduced some of these effects. Keep in mind that even some patients implanted with monofocal IOLs complain of night vision symptoms. Indeed, dysphotopsias are the primary source of patient dissatisfaction with all IOLs.

These visual symptoms, which vary widely in etiology and appearance, are the result of defocused and scattered light hitting the retina. Although they frequently occur in combination, for clinical trials the FDA classifies dysphotopsias into three distinct categories: glare/flare, halos



Fig. 5. A multifocal or EDOF patient may complain of “fuzziness” around objects. Contrast remains high, however, so explain the process of neuroadaptation.




Fig. 6. Ask patients for as much detail as possible about any visual anomalies, and strive to use the same terminology. The above image depicts the three FDA categories of dysphotopia.




Fig. 7. Multifocal IOL patients may experience a single bright halo while those with diffractive EDOF IOLs tend to describe starbursts and fine concentric halos in a “spiderweb” pattern.

and starbursts. Each has a different appearance to the patient and can occur for different optical reasons (Figure 6).

Glare or flare, which is a smearing or blur around a point source of light, can be due to refractive error, ocular surface problems, PCO and nuclear cataracts. It is less likely to be directly associated with any particular IOL optics.

Halos, which are one or more rings around a point source of light, are commonly associated with multifocal IOLs. These lenses have two distinct focal points with a dip in energy in between. Since the halo consists of the out-of-focus energy directed at the near focal point, the size of the halo is related to add power, with larger halos associated with higher add powers.

Starbursts may be described by patients as streaks or rays of light emanating from a point source. These can occur with refractive error (especially astigmatism), ocular surface problems, posterior capsular folds, PCO or use of diffractive IOLs.

Newer presbyopia-correcting IOL designs provide new options, and trade-offs, between depth of focus and dysphotopsias. For example, while patients with diffractive multifocal IOLs tend to notice a single bright halo, patients with diffractive EDOF IOLs tend to describe starbursts and multiple fine concentric halos in a “spiderweb” pattern (Figure 7). In our practice, we have seen reduced night vision complaints with EDOF

IOLs compared to multifocal IOLs, and appropriate preoperative counseling plays a critical role in how patients perceive their symptoms after surgery.

Patient Counseling

When working to alleviate postoperative visual complaints, an ounce of prevention is worth a pound of cure. Preparing patients and setting expectations before surgery is key. Patients should be counseled that there will likely be some night vision symptoms but that they are usually tolerable.

For surgeons, it is no longer adequate simply to perform a procedure well. The ability to communicate the potential tradeoffs, to screen appropriate patients and to set proper expectations is crucial to the successful management of postoperative vision complaints.

If patients have visual complaints in the early postoperative period, it is important to diagnose the cause and to help the patient with appropriate behavioral and treatment approaches, whether that be providing more light, offering occasional reading glasses, considering refractive correction (spectacle or surgical), or treating medical conditions such as dry eye, PCO or CME.

Here, the optometrist is beginning to play an important role. Reassure patients that symptoms typically improve with time, healing and neuroadaptation for those able to do so. Referring optometrists should communicate with the surgeon if there is a significant or ongoing concern and refer back for further diagnosis and/or treatment, including lens exchange in the most refractory cases.

In conclusion, most well-chosen and fully prepped patients find the tradeoffs with modern presbyopia-correcting IOLs worthwhile and welcome the opportunity even if the initial results do not fully address every visual need. Concerns about visual quality and night vision problems, while not zero, are generally quite tolerable; and when patients are counseled appropriately before and after surgery, we maximize the chance of satisfaction with their visual outcomes. ■

Drs. Huggins and Chang are in practice at Empire Eye & Laser Center in Bakersfield, Calif. Dr. Chang is a consultant for Johnson & Johnson Vision. Contact them at (661) 325-3937 or dchang@empireeyeandlaser.com and lhuggins@empireeyeandlaser.com.

1. Lord SR. Multifocal glasses impair edge-contrast sensitivity and depth perception and increase the risk of falls in older people. *J Am Geriatr Soc* 2002; 50:1760-6.
2. Centers for Disease Control. www.cdc.gov/media/releases/2016/p0922-older-adult-falls.html (Accessed 5/31/18)
3. Pedrotti E, Bruni E, Bonacci E, et al. Comparative analysis of the clinical outcomes with a monofocal and an extended range of vision intraocular lens. *J Refract Surg* 2016;32:436-42.



Corneal Compromise: How to Assess the Risk of Post-LASIK Ectasia

Before recommending laser vision correction, optometrists can spot patients likely to suffer complications. **By Oliver Kuhn-Wilken, OD, and Victoria Roan, OD**

Laser vision correction (LVC) is the most popular elective medical procedure done in the United States, and its most feared complication is the corneal failure known as ectasia.¹ LVC includes Laser In-Situ Keratomileusis (LASIK), Photorefractive Keratectomy (PRK), Small Incision Lenticule Extraction (SMILE), and other less common forms of laser vision correction; all of these surgeries without exception carry a risk of inducing ectasia.² Optometrists have many of the skills and tools to detect at-risk patients before they ever get to the surgeon and a number of methods and technologies may help reduce the incidence.^{3,4}

This article describes the risk factors for corneal ectasia and how to evaluate patients for them.

Post-LVC Ectasia

Patients who develop this complication will experience uncorrected visual acuity (UCVA) loss, sometimes severely, and often uncorrectable with glasses.⁵ The average UCVA in post-LVC patients with ectasia is 20/400, and aberrations

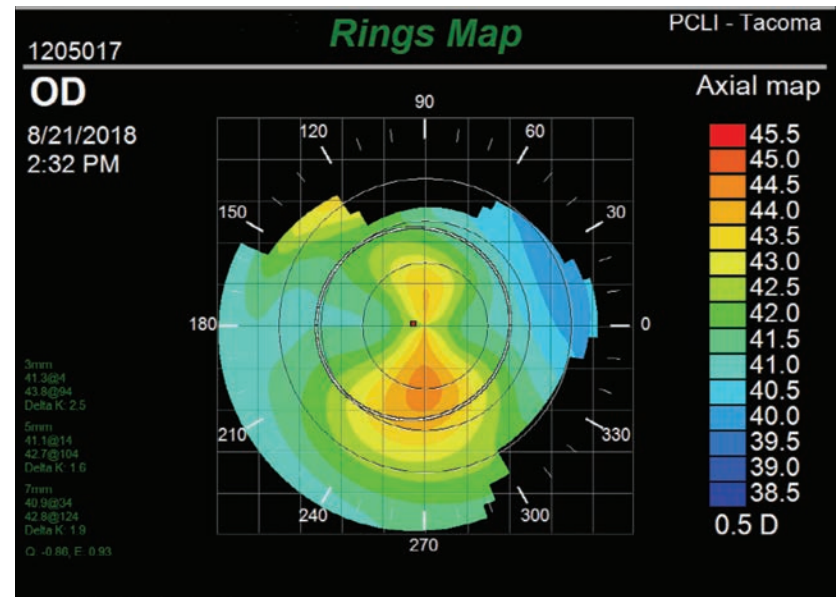


Fig. 1. A subtle case of asymmetric bowtie on topography. Scheimpflug imaging later confirmed that this 18-year-old male had early keratoconus. Notice that the scale is carefully set to 0.5D increments for good sensitivity.

reduce even their average best-corrected visual acuity (BCVA) to only 20/100.⁵

Post-LVC ectasia is a biomechanical failure of the wall of the cornea, resulting in thinning and protrusion, but without acute inflammation.⁶ After LVC, the flap

no longer contributes meaningfully to the strength of the cornea, and the untouched posterior stroma must resist any forces on its own. Within the stroma, intralamellar bonds can fracture and slip under the stress of outside forces, such as intraocular pressure (IOP), eye

rubbing, blinking and extraocular muscle forces. Though these forces are small, the damage can mount cumulatively until the cornea finally fails.⁶ Ectasia can occur from three months to six years after surgery; however, the peak incidence occurs at 12 months.²

Exam Room Clues

Post-LVC ectasia remains such an insidious threat precisely because we have no single test that can determine whether a patient is at risk; instead, we must consider a constellation of risk factors. The primary ones are the patient's refractive error, age, systemic health, retinoscopy clues, slit lamp findings, pachymetry and especially keratometry.^{1,2} Because the relative importance of these risk factors has not been definitively quantified, the presence of even one concerning finding is often enough to trigger a decision to avoid surgery.

Certain refractions place a patient at higher risk. In myopic ablations, the higher the correction required, the more stroma the laser must remove; for this reason an ablation of more than -8.00D is considered higher risk, and more than -12.00D is rarely attempted.¹ Corneal thickness can affect these calculations to some extent.

Any increasing astigmatism, or astigmatism at 90° to that of the fellow eye, increases the risk of an undetected keratoconus.

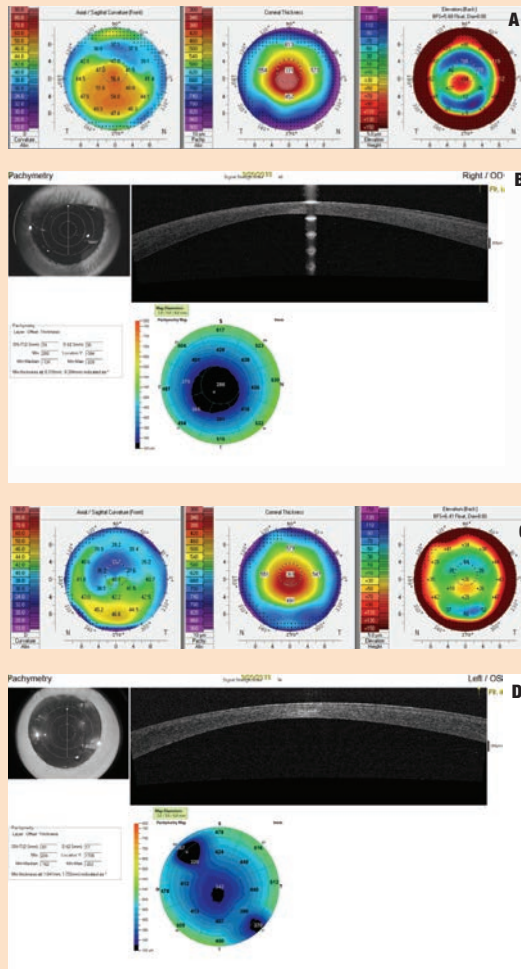
A stable refractive error over several years is a strong indication that your patient can be considered for LVC. Because refractions tend to stabilize with time, age is a crucial risk factor. A mildly concerning topographic finding can eliminate a candidate at age 20, but be regarded as benign at age 40. Keratoconus is generally detected in the early 20s, and becomes rarer after

the fourth decade.¹

Certain systemic health conditions pose an absolute contraindication.⁵ These include:

- Down syndrome (for which one in seven patients develops keratoconus).
- Turner syndrome, a genetic disorder affecting females that among many other effects also predisposes to keratoconus.
- Ehlers-Danlos syndrome, a genetic connective-tissue disorder.

A Case Example of Ectasia



A 65-year-old man presented with symptoms of decreasing best-corrected visual acuity (20/200 OD, 20/20- OS). He reported a history of LASIK in both eyes (performed in 1992).

(A) His right eye axial scan (using Pentacam) demonstrates a high level of inferior-superior asymmetry (left), and his thickness and elevation maps (center and right) show central thinning.

(B) His right eye corneal scan, performed with AS-OCT, clearly shows corneal thinning.

(C & D) His left eye scans are similar to his right, though with somewhat less severity.

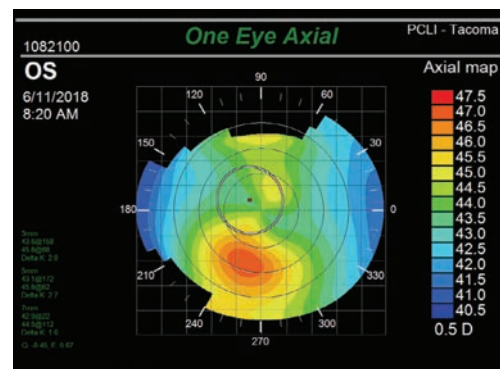


Fig. 2. A difference of greater than 1.4D when comparing equivalent points above and below the horizontal meridian classifies this cornea as high risk due to inferior steepening.

Earn up to
20 CE
Credits*

NEW TECHNOLOGIES
& TREATMENTS IN

2019
EYE CARE

RGVCE
REVIEW'S COMMITMENT TO
CONTINUING EDUCATION

Join us in

Orlando, Florida

March 7-10, 2019

Join us for *Review's* New Technologies & Treatments in Eye Care
March 7-10, 2019 in Orlando at Disney's Yacht & Beach Club.
Earn up to 20* COPE CE credits including interactive workshops!**



The program includes six (6) TQ/CEE Credits for those Optometrists licensed in Florida or other states requiring transcript quality courses for re-licensure.

EARLY BIRD SPECIAL: \$495

Registration cost: \$595 after January 25, 2019.

FACULTY



Paul Karpecki, OD, FAAO
Program Chair



Blair Lonsberry, MS, OD, MEd, FAAO



Diana Shechtman, OD, FAAO



Joseph Shovlin, OD, FAAO

DISNEY'S YACHT & BEACH CLUB

1700 Epcot Resorts Boulevard
Orlando, Florida 32830
Phone: 407-934-7000

See website for updated hotel accommodations.



3 WAYS TO REGISTER

online: www.reviewscce.com/Orlando2019

email: reviewmeetings@jhihealth.com | **phone:** 866-658-1772

**Separate registration required. RGVCE partners with Salus University for those ODs who are licensed in states that require university credit.
See event website for complete details.

Administered by
RGVCE
REVIEW'S COMMITMENT TO CONTINUING EDUCATION



*Approval pending

SALUS
UNIVERSITY
Pennsylvania College of Optometry

- Marfan syndrome, another genetic connective-tissue disorder.

Any family history of keratoconus should also be considered a red flag. Any scissoring reflex with the retinoscope or oil-drop reflex with the direct ophthalmoscope suggest keratoconus; these would likely be reinforced by other findings such as irregular topography or limited BCVA.

The clinician must be attentive to the classic slit-lamp findings associated with keratoconus. Among these, the most salient is the presence of Vogt's striae: thin folds on the endothelium, usually vertical. Other possible signs include a Fleischer ring, corneal thinning and prominent corneal nerves.

Any distortion of the manual keratometer mires will probably eliminate a patient from candidacy.

Enhancements

Because post-LVC ectasia may be subjectively indistinguishable from simple refractive regression, you should be on high alert whenever an LVC patient presents seeking an enhancement. All of the criteria discussed in this article pertain, with a high level of wariness. Keep in mind that post-LVC ectasia does not always manifest as a keratoconus-like inferior steepening and astigmatism, but may only be a suspicious progressive myopia. These cases will be evaluated with great care by any surgery center.

Topography

Placido disc topographers (e.g., Medmont, Eyesys, Atlas) use a

system of concentric rings projected onto the cornea to calculate corneal curvatures and irregularities. Whether a small-cone or large-cone system is used, these tools are extremely helpful in detecting corneal anomalies.

When scrutinizing topographies for signs of corneas at risk for ectasia, you should be on the alert for these types of topographies: normal, asymmetric bowtie, inferior steepening, skewed radial axis and abnormal.⁵

- An asymmetric bowtie will show a significantly greater area of steepening inferiorly than superiorly (Figure 1).

- Inferior steepening is defined as a difference of 1.4D or greater when comparing two equivalent points in the inferior and superior cornea (Figure 2).

- A skewed radial axis is interpreted by drawing imaginary lines to bisect the superior and inferior lobes of the bowtie; if these lines deviate from each other by greater than 30°, it is classified as skewed (Figure 3).

- Abnormal topographies include

the classic “kissing dove” and “crab claw” patterns that indicate pre-existing corneal failure, as well as anything else out of the ordinary (Figure 4).

If a patient presents with any of the warning signs listed above, order further testing as necessary to determine if they have keratoconus (snowman pattern) or pellucid marginal degeneration (kissing-doves pattern). If in doubt, simply repeat corneal measurements in four to six months, as these cases tend to be progressive.

Pachymetry

Topography alone does not tell the full story. When topography is combined with pachymetry readings, the clinician is better equipped to educate the patient on their candidacy for LVC.

One of the first risk factors noticed for post-LVC ectasia was an abnormally thin cornea. A central corneal thickness less than 500µm is roughly three standard deviations thinner than average and is abnormal; for years 500µm was considered the cut-off for a

safe procedure, and any thinner corneas were considered for PRK. This procedure does not create a flap and the ablation does not go as deep into the stroma as does LASIK.

Any incision weakens the integrity of the cornea. The residual stromal bed (RSB) is the amount of untouched corneal tissue remaining following LVC. Surgeons pay close attention to the depth of the RSB because adhesions

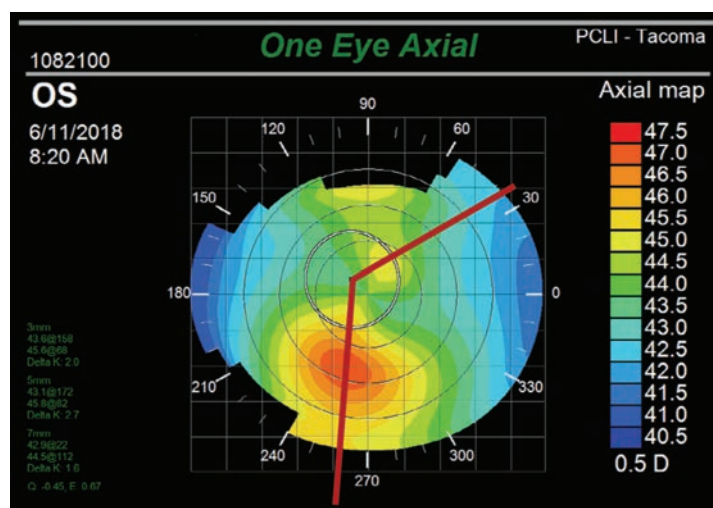


Fig. 3. This analysis of the same cornea seen in Figure 2 demonstrates a skewed radial axis. Note that lines drawn to bisect the superior and inferior lobes deviate from each other by more than 30°.

between a LASIK flap and virgin cornea are weak, and the flap is considered to no longer contribute any strength to the cornea. Once you obtain a central pachymetry measurement, you can estimate the RSB yourself. If the ablation is done over the standard diameter of 7mm, the depth of the ablation can be estimated using Munnerlyn's formula.⁷ For the diopters of correction, use the sphere plus the full astigmatic amount (See "Applying Munnerlyn's formula").

An RSB thinner than 300µm increases the patient's risk. Imprecise corneal pachymetry preoperatively and variability in the depth of the flap will impact the RSB prediction, particularly in those with already thinner than average CCT.⁸ As more tissue is altered and less virgin tissue remains, the patient's risk for ectasia increases, even if there are no other predispositions noted.⁹

Risk-scoring System

The many risk factors for ectasia are not equally significant. In 2008, Randleman introduced the Ectasia Risk Score System (ERSS), which weights the primary risk factors to help practitioners identify patients who are at the most risk for developing progressive post-keratorefractive ectasia. The system scores the categories of age, residual stromal bed thickness (RSB), preoperative corneal thickness (CT), topography and preoperative spherical equivalent manifest refraction into point intervals by order of risk for ectasia. A summation of those points by category indicates the patient's predilection for postoperative ectasia

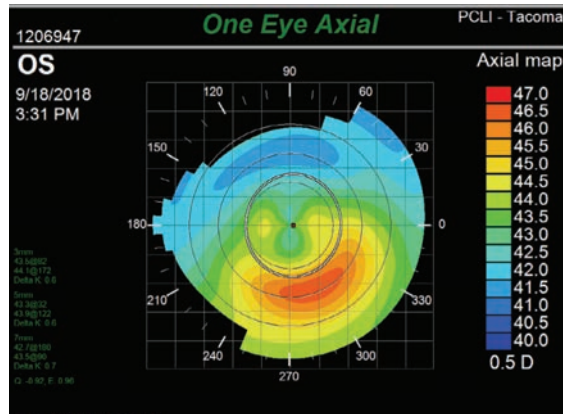


Fig. 4. The “kissing doves” sign clearly indicates early ectasia; this would be classified as abnormal topography.

with lower points corresponding to lower risk.¹⁰

The categorization of the topography is the only section requiring the physician's judgment, but also is weighted heavily as it was the most predictive factor for the eventual development of ectasia (*Tables 1 and 2*).

Despite a decade of debate, it has proven difficult to create a more robust or efficient scoring system. Any clinician with access to a topographer and pachymeter can complete this assessment independently.

New Approaches

Researchers are currently exploring ways in which subtle clues found in the posterior cornea and in global keratometry may provide

more definitive clues of an at-risk cornea. These indications can only be seen when the entire cornea is mapped, including the posterior surface. Devices using slit-scan technology, such as the Orbscan (Bausch + Lomb) and Scheimpflug imaging such as the Pentacam (Oculus) and Galilei (Ziemer Ophthalmic Systems AG) can model the cornea in three dimensions, allowing more detailed measurements of corneal elevation and pachymetry.^{3,11}

The Pentacam's Belin-Ambrosio and refractive displays focus on specific corneal measurements to alert practitioners when measurements indicate a higher risk for ectasia.¹² In addition to detecting anterior corneal anomalies, the Belin-Ambrosio interface calculates both the anterior and posterior corneal surfaces and compares them.¹² If the central posterior curvature is significantly steeper than the anterior surface, the patient is more likely to develop ectasia.¹² Asymmetry across the horizontal meridian, where the top half does not closely mirror the bottom half, is a strong indicator for an irregular surface not ideal for LVC.¹³

Undoubtedly, additional factors exist that we have yet to discover.

Applying Munnerlyn's Formula

The formula states: $Depth\ of\ ablation = optic\ zone\ diameter^2 \times diopteric\ correction \div 3$

Assuming a 7mm optic zone, the formula can be restated as 16 x diopters of full correction (sphere + full astigmatism). As the flap can be estimated at 120µm, the RSB is then easily calculated: $RSB = pre-op\ corneal\ thickness - (120\mu m\ flap\ thickness + depth\ of\ ablation)$

For patient with a 550µm cornea, undergoing standard LASIK for a refraction of -4.00 -2.00 x 180, RSB would be calculated like this:

$$RSB = 550\mu m - 120\mu m - (16 \times 6.00) = 334\mu m$$

Table 1. Randleman Risk Scoring Protocol

Parameter	Points				
	4	3	2	1	0
Topography	Abnormal	Inferior Steepening/ Skewed radial axis		Asymmetric Bowtie	Normal
RSB	<240µm	240µm to 259µm	260µm to 279µm	280µm to 299µm	≥300µm
Age		18 to 21	22 to 25	26 to 29	≥30
CT	<450µm	451µm to 480µm	481µm to 510µm		≥510µm
MRSE	>-14D	>-12D to -14D	>-10D to -12D	>-8D to -10D	-8D or less

Table 2. Scoring Recommendation on Whether or Not to Proceed with LASIK

0 to 2 (Low risk)	Proceed with LASIK or surface ablation.
3 (Moderate risk)	Proceed with caution, consider special informed consent; safety of surface ablation has not been established. Consider refractive stability, degree of astigmatism, between-eye topographic asymmetry, and family history.
4 (High risk)	Do not perform LASIK; safety of surface ablation has not been established.

For instance, researchers have shown that eyes with keratoconus have abnormal rebound when deformed, an attribute called corneal hysteresis.¹³ This quality can now be measured using a device called the Ocular Response Analyzer (Reichert), which indents the cornea with a strong jet of air and then measures its rebound reaction. Some studies suggest that this device will be a helpful tool.¹⁴

The prevalence of keratoconus in first-degree relatives is 3.34%, roughly 65 times higher than that in the general population, leading to the search for a genetic marker for ectasia risk.¹⁵ This has been complicated, but recent genome-wide linkage studies have made significant findings. Several autosomal-recessive genes have now been

implicated, including genes coding for collagens and the production of extracellular matrix. One of the most significant of these is the LOX gene, which codes for a copper-dependent enzyme responsible for the crosslinking of collagens and elastin; defects in this gene have also been linked with a predisposition to thoracic aortic aneurysms and dissections.¹⁶

Unfortunately, despite the most rigorous preoperative screening, some patients will still go on to develop visually significant ectasia. Research shows 32% of post-LVC ectasia cases have completely normal preoperative topographies, with no warning signs even in post-hoc analysis.⁸ For this reason it is crucial to be clear with each LVC candidate that we cannot eliminate

all risk, and that these elective procedures inevitably carry some risk of ectasia, as well as the other risks, such as glare, dry eyes, inaccurate outcome, inflammation, epithelial ingrowth and hastening of presbyopia. Carefully explain this to your patient, listen until they explicitly accept this risk and document the conversation in your chart. ■

Drs. Kuhn-Wilken and Roan are staff optometrists at Pacific Cataract & Laser Institute, in Tacoma, WA and Bellevue, WA, respectively.

1. Saad A, Binder P, Gatinel D. Evaluation of the percentage tissue altered as a risk factor for developing post-laser in situ keratomileusis ectasia. *J Cataract Refract Surg.* 2017;43:946-51.
2. Wolle M, Randleman J, Woodward M. Complications of refractive surgery: ectasia after refractive surgery. *Int Ophthalmol Clin.* 2016;56(2):129-41.
3. Woodward M, Randleman J, Russell B, et al. Visual rehabilitation and outcomes for ectasia after corneal refractive surgery. *J Cataract Refract Surg.* 2008;34(3):383-8.
4. Binder P, Trattler W. Evaluation of a risk factor scoring system for corneal ectasia after LASIK in eyes with normal topography. *J Refractive Surg.* 2010; 26(4):241-50.
5. Spadea L, Cantera E, Cortes M, et al. Corneal ectasia after myopic laser in situ keratomileusis: a long-term study. *Clinical Ophthalmology.* 2012;6(1): 1801-13.
6. Chan C, Saad A, Randleman J. Analysis of cases and accuracy of 3 risk scoring systems in predicting ectasia after laser in situ keratomileusis. *J Cataract Refract Surg.* 2018;44:979-92.
7. Wang M. Keratoconus & keratoectasia: prevention, diagnosis, and treatment. Thorofare NJ: SLACK Inc. 2010;51-60.
8. Binder P, Lindstrom R, Stulting R, et al. Keratoconus and corneal ectasia after LASIK. *J Cataract Refract Surg.* 2005;31(11):2035-8.
9. Chang A, Tsang A, Contreras J, et al. Corneal tissue ablation depth and the Munnerlyn formula. *J Cataract Refract Surg.* 2003 Jun;29(6):1204-10.
10. Randleman JB, Woodward M, Lynn MJ, et al. Risk assessment for ectasia after corneal refractive surgery. *Ophthalmology.* 2008;115:37-50.
11. Ambrósio R, Ramos I, Lopes B, et al. Assessing ectasia susceptibility prior to LASIK: the role of age and residual stromal bed (RSB) in conjunction to Belin-Ambrósio deviation index (BAD-D). *Revista Brasileira De Oftalmologia.* 2014;73(2):87-95.
12. Belin MW, Khachikian SS, Ambrósio Jr R, Salomão M. Keratoconus/ectasia detection with the Oculus Pentacam: Belin/Ambrósio Enhanced Ectasia Display. *Highlights of Ophthalmology.* 35:6;5-12.
13. Belin M, Holladay J, Michelson M, et al. The Pentacam: precision, confidence, results, and accurate Ks! *Cataract and Refract Surg Today.* www.pentacam.com/fileadmin/user_upload/pentacam.de/downloads/publikationen/sonderdrucke/2007-Supplement_Pentacam_AAO_2006.pdf. January 2007. Accessed November 17, 2018.
14. Galletti JG, Pförtner T, Bonthoux FF. Improved keratoconus detection by ocular response analyser testing after consideration of corneal thickness as a confounding factor. *J Refract Surg.* 2012;28:2025-208.
15. Wang Y, Rabinowitz YS, Rotter JJ, et al. Genetic epidemiological study of keratoconus: evidence for major gene determination. *Am J of Medical Genetics.* 2000; 93:403-409.
16. Bykhovskaya Y, Margines B, Rabinowitz YS. Genetics in keratoconus: where are we? *Eye and Vision.* 2016;3:16.



MIGS: Follow the Fluid Trail

While promising, much remains unknown about these devices and their long-term effect on ocular anatomy.

By Kellen R. Riccobono, OD, Jan P.G. Bergmans, OD, and Lorenzo Anderson, BS

Minimally invasive glaucoma surgery (MIGS) has taken the market by storm as a new and exciting treatment for glaucoma. Yet, as with any new category, surgeons and comanaging optometrists are still learning about efficacy, mechanism of action and optimal use, especially for procedures involving stents placed in the trabecular meshwork. These uncertainties stem, in part, from the scarcity of research capable of fully mapping the anatomy of the limbus. For example, given the size of the stents currently on the market and the measured size of the canal of Schlemm, some stents may be too large to achieve increased aqueous outflow via the traditional pathway and may be instead more akin to the uveoscleral route of outflow.

Our research at the Texas Eye Research and Technology Center, focusing on mapping the limbus in three dimensions, hopes to provide a better understanding of the limbal anatomy to improve our understanding of this structure and how MIGS interacts with the local angle structures.

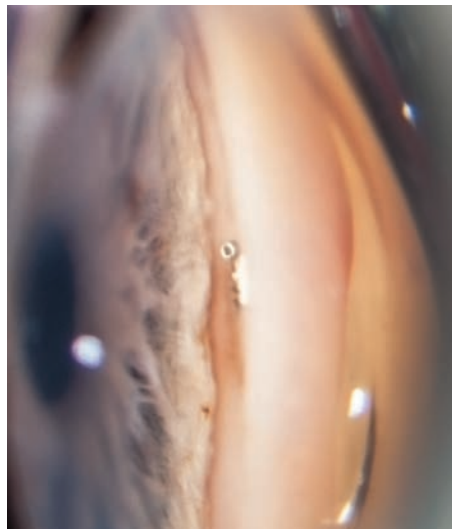


Fig. 1. A post-op gonioscopic photo shows the iStent device implanted in the trabecular meshwork during the time of cataract surgery. The iStent requires no additional port incisions to be implanted.

The Problem at Hand

Glaucoma is the leading cause of irreversible blindness worldwide and a disease that optometrists frequently manage.¹ It is a complex, multifactorial pathology involving structure as well as physiology, and the precise detailing of this disease, while generally understood, remains imperfect. The only known modifiable risk factor is elevated

intraocular pressure (IOP), and the Ocular Hypertension Treatment Study shows that topical ocular hypotensive medications are effective in delaying the development of primary open-angle glaucoma.²

Although typical first-line therapy consists of topical medications, these come with certain ocular and systemic side effects, such as change in iris color, conjunctival hyperemia, punctate epithelial erosion, bradycardia, hypotension and impaired renal function, as well as concerns regarding patient compliance.³ More invasive surgical procedures are typically reserved for patients who can no longer be managed with topical medications. Surprisingly, even with hypotensive treatments, some patients have recalcitrant high IOP or significant glaucomatous progression regardless of seemingly low IOP. Thus, the search for new and improved treatment approaches to combat glaucoma continues, most recently focusing on MIGS.

A New Solution

Three categories of MIGS procedures exist: those involving (1) the trabecular meshwork and Schlemm's canal, (2) the suprachoroidal space or (3) the subconjunctival space.

Photo: Anthony Van Alstine, OD, MS, and James M. Caruso, OD

Our research into the morphology of the limbal region and how the different structures relate to each other perhaps applies best to devices that bypass the trabecular meshwork, which in turn may impact the surrounding anatomy.

Research suggests the trabecular meshwork is the point of greatest resistance to aqueous outflow and pinpoints the internal endothelial wall of Schlemm's

canal, its basement membrane and the underlying juxtacanalicular connective tissue as the location in particular.⁴⁻⁶ Though there is still much to understand about the fluid dynamics of aqueous outflow and the other contributors of resistance to outflow, bypassing the trabecular meshwork is the primary intent of the MIGS procedures involving stents within this region of the limbal anatomy.

MIGS Questions

As promising as these procedures seem to be, they come with several concerns that warrant further investigation:

Efficacy. One challenge of studying these procedures is the FDA's approval for use when they are implanted along with cataract surgery typical of devices such as the iStent (Glaukos), iStent inject (Glaukos) and CyPass (Alcon) (Table

1).^{7,8} This concurrent use can make it difficult to determine which of the two procedures has a more profound effect on IOP. Study data suggests MIGS are helpful but may not always be the major contributor to the lowering of IOP in a dual-procedure approach.

Additionally, studies that compare the decrease in IOP from cataract surgery alone have varied outcomes. One meta-analysis shows an enormous range within 22 studies, from 0.9% to 58.95% reduction, with the weighted mean decrease being 31%.⁹

Four studies involving the iStent's concurrent placement during cataract surgery showed a statistically significant difference in IOP reduction when comparing the phacoemulsification-only group (4.7%), the phaco and iStent group (9%) and the phaco and two iStents group (27%).¹⁰ However, other studies within the meta-analysis suggest combined phaco

Table 1. MIGS Implants or Procedures Involving the Trabecular Meshwork^{7,8}

Company	Product	Size	FDA Approval	Material
Trabecular Meshwork Implants				
Glaukos	iStent inject	Length: 360µm Width: 230µm	June 2018 with cat sx	Heparin-coated, non-ferromagnetic titanium stent
Glaukos	iStent	Length: 1mm Height: 0.33mm Snorkel length: 0.25mm Snorkel bore diameter: 120µm	June 2012 with cat sx	
Ivantis	Hydrus	Length: 8mm	August 2018 with cat sx	Superelastic alloy of nickel and titanium —"nitinol" stent
Trabecular Meshwork Ablations				
Neomedix	Trabectome	N/A	April 2004 <i>unspecified</i>	N/A, electrocauterization
New World Medical	Kahook Dual Blade	N/A	TM/Schlemm's canal	Surgical grade stainless steel
Trabecular Meshwork Microcatheters				
Ellex	iTrack ABiC	Diameter: 200µm	July 2008 <i>stand alone procedure</i>	Unspecified polymer microcatheter
Sight Sciences	Visco 360	Diameter: Not available	Suprachoroidal space	Not available
Suprachoroidal Implants				
Alcon	CyPass	Length: 6.35mm Width: 0.3mm	July 2016 with cat sx <i>***voluntarily withdrawn due to endothelial compromise as of August 2018</i>	Non-conducting, non-metallic, non- magnetic polymer polyimide stent

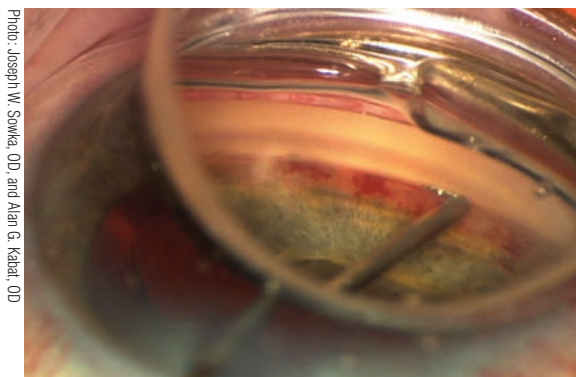


Fig. 2. Under magnification, an iStent is being inserted through the trabecular meshwork during cataract surgery.

and iStent provides a mean IOP reduction of 26%, not 9%.⁹ The meta-analysis also found the mean IOP reduction to be 26%, 18.4% and 20% when inserting one, two or three iStents along with phacoemulsification, respectively.⁹ These varying results make it difficult to estimate and predict the cumulative impact of the iStent placement. We must also consider the number of hypotensive agents used in this study—the stent(s) and the topical medications—making the independent hypotensive effect of the stents difficult to interpret without a washout period. In some cases, stent placement allowed a reduction in medication use more so than an additive IOP reduction if medication levels had been maintained.

Recently, studies of iStent placement as a stand-alone procedure have helped obtain a better understanding of its efficacy in the absence of phacoemulsification. In one study on pseudophakic eyes, a statistically significant reduction in IOP was noted with implantation of one iStent, although the mean number of postoperative hypotensive drugs used was not significantly different.¹¹ Another study—with 117 out of 119 phakic eyes undergoing iStent implantation—reports a mean reduction of 7.6mm Hg (30%) IOP

with one stent, an additional 1.6mm Hg (37% total) decrease with two stents and a 3.3mm Hg (43% total) decrease with three.¹² The data indicates that the first stent appeared to provide the majority of the hypotensive effect, though the groups with multiple stents required fewer additions of topical hypotensive agents

within the next 42 months.¹¹ The mechanism for these trends remains to be understood, as the limbal anatomy and the associated fluid dynamics become clearer with continued research.

Medication reduction. Some practitioners posit that MIGS can potentially obviate the need for topical IOP-lowering drops altogether for post-op patients. In one meta-analysis, the maximum reduction in hypotensive medication use after phaco with iStent implantation occurred between 12 and 24 months, with a non-significant reduction at six months.⁹ The previously mentioned meta-analysis calculated the weighted mean reduction of topical glaucoma drugs after phaco alone at 1.01, 1.33 with the placement of iStent and phaco and 1.1 with two iStents and phaco.⁹ Curiously, the group with two iStents had a lesser medication reduction than the group with one iStent due to the effects of averaging the results in each cohort; thus, forecasting the treatment effect in any individual patient from these studies remains untenable.

The new Hydrus (Ivantis) implant shows promise, as it significantly decreases the need for topical medications even two years after the procedure.⁸ The FDA clinical trial for this device, the HORIZON study,

shows a medication reduction of 0.4 at 24 months compared with controls.¹³ Additionally, an IOP reduction of equal to or greater than 20% was achieved in the stent group by 77.3% and in the non-stent group by 57.8%, which was found to be a statistically significant difference.¹³

Anatomical effects. Beyond issues with consistency in clinical outcomes, these procedures are performed in the filtration angle, possibly without a clear understanding of the true morphology of the limbal region, the canal of Schlemm and the trabecular meshwork. The exact dimensions and flexibility of Schlemm's canal remain obscure, with some sources suggesting a range between 141 μ m and 400 μ m in width (Table 2).^{4,14-19} While manufacturers propose that MIGS be placed within the canal of Schlemm, it is possible that this may not consistently occur. (Figures 1 and 2). Though anterior segment OCT scans can show stent penetration into Schlemm's canal, these are 2D images that make such a determination more difficult.

Adding weight to such concern, stent malpositioning is a known implantation complication for many MIGS procedures, with incidence in literature ranging from 3% to 17.6%.¹⁰ In rare cases, clinicians have been unable to locate the stent with gonioscopy after its placement. Though these complications do not lead to severe adverse events, they suggest that positioning may be an unappreciated issue. However, there is a lack of criteria defining malpositioning of the stent, as well as a lack of guidelines for the precise and correct implantation based on anatomical reference points.

Even with correct positioning, successful bypass into the canal of Schlemm is, to our knowledge, not yet confirmed. Gonioscopy in con-

junction with biomicroscopy may not produce the magnification and resolution to make a definitive determination of a successful insertion in all cases. The ports of the stent may simply drain into the extracellular tissues external to the canal of Schlemm because of the lack of uniformity in the distance between the internal surface of the trabecular meshes and the internal wall of canal of Schlemm.

Consider the difficulty posed by the triangular shape of the trabecular meshes, where the base is located peripherally adjacent to the scleral spur and the apex is centrally next to the cornea.¹⁴ Measurements in our laboratory have indicated that the base of this triangle is approximately 228.26 μ m and the apex is less than 5 μ m. The depth to which one needs to insert the catheter to find and penetrate the canal of Schlemm will vary, depending on where in the trabecular mesh the surgeon aims. Many have measured the mesh along its posterior surface facing the anterior chamber at 794.35 μ m wide;

the canal of Schlemm typically only covers half of this width, making successful insertion of a MIGS a surgical challenge.

In addition, a recent pilot study conducted in our laboratory on human cadaver eyes revealed that the canal of Schlemm has an oval shape with its long axis parallel to the ocular surface and its short axis perpendicular to the plane of the cornea (Figure 3). It measured 335.75 μ m by 33.26 μ m and appeared to extend across approximately half the width of trabecular meshes. However, in the anterior-posterior axis, our measurement of the lumen opening was 33.26 μ m, too narrow to be able to physically accept even the smallest stent at 200 μ m.

Table 2. Ocular Anatomy/Physiology Texts on Canal of Schlemm⁹⁻¹⁴

Text	Dimension(s) (μ m)	Characteristics
Duke Elder, 1961	Meridional: 282	Oval
Hogan et al, 1971	None offered	36mm circumference
Wolff, 1998	Long axis: 200-400 Short axis: 10-25	Circular tube, 36mm circumference
Oyster, 1999	None offered	—
Adler's 11th, 2011	None offered	—
Freddo, 2018	None offered	Flattened profile
Bergmanson 25th ed., 2018	Meridional: 121 \pm 45	—

Though the trabecular mesh itself has a degree of flexibility, its outer coat anterior to the canal is relatively inflexible by comparison. These uncertainties argue for additional research targeted at mechanism-of-action *in vivo*.

Possible Corneal Effects

MIGS procedures have a beneficial effect on IOP, though an understanding of their mechanism remains incomplete. Given our current research, some authors suspect these devices deliver the aqueous to the outer coat external to the canal of Schlemm, which could elevate the potential for impact on the cornea. In this location, no membrane or barrier exists to impede the continuous aqueous outflow that pressure differences dictate may allow the rich scleral and conjunctival vasculature to absorb aqueous. This pathway may function similarly to the uveoscleral aqueous outflow, where aqueous does not follow a particular vascular route but simply percolates from the anterior chamber filtration angle to the external eye.

MIGS may also affect the health of the corneal endothelium, given that the trabecular meshes are a peripheral projection of it. Research

A canal of Schlemm filled with aqueous, we predict, may expand to a range of 50 μ m to 70 μ m, which will not accommodate a stent either. In such cases, a stent could simply bypass the trabecular meshwork, juxtacanalicular tissue and canal to empty the aqueous into the outer coat external to the canal of Schlemm.




Fig. 3. Aqueous outflow facility in a 70-year-old patient. The triangle indicates canal of Schlemm, the asterisk denotes trabecular meshes and the arrow points at the angle recess. Note the triangular shape of the trabecular meshwork, which creates a non-uniform distance between the canal of Schlemm and the anterior chamber. The central (anterior) edge of the trabecular triangle is not present in this view.

shows that the endothelium is compromised in patients with glaucoma and that significant endothelial damage can occur with surgical glaucoma shunts.²⁰ However, little is known about how MIGS affects the corneal and trabecular endothelium.

The only currently published study on this particular topic found no significant difference in the change in endothelial anatomy when comparing three groups (cataract surgery alone, cataract surgery alone in a patient with glaucoma and cataract surgery and Hydrus placement in a patient with glaucoma).²¹ However, the limitation of this study was the short follow-up period of six months. It is possible that more permanent damage could occur in the already fragile endothelium of the glaucoma patient.²¹

Lending credence to this theory is the recent removal of the CyPass device from the market (*Figure 4*). Alcon voluntarily withdrew the implant due to the COMPASS–XT study results showing a statistically significant difference in endothelial cell loss five years post-implantation in patients who had the CyPass

implant during cataract surgery compared with those who only had cataract surgery.²² The company has released a statement requesting ophthalmologists discontinue use and return unused devices.²² The company plans to communicate directly with surgeons for the continued management of patients who had previous implantation of the CyPass.²²

Given that a suprachoroidal stent may be more invasive than a trabecular stent, this new discovery is a clinical indication of plausible future complications that may be revealed by continued long-term evidence-based research on the effects of MIGS on the corneal endothelium and limbal anatomy. One study noted that when two or more retention rings on the CyPass stent could be observed in the anterior chamber, endothelial cell loss was more significant, though this information may be anecdotal, as there is no citation.²³ If this is true, it may suggest that a more standardized method of insertion and implantation could decrease possible endothelial risks.

Additionally, more research regarding the differential segmental outflow of aqueous in the trabecular meshwork, inner wall endothelium of canal of Schlemm, and the episcleral veins is needed to better understand MIGS implantation into the limbal angle.⁵ One study indicates that more outflow is observed in the inferior and nasal quadrants of the trabecular meshwork because of a greater number of collector channels and an expanded trabecular meshwork in this area.⁵

While outflow was once thought to be uniformly distributed, it appears now that preferential outflow may exist. One study of bovine eyes associated higher IOP levels with a more contained path-

way of resistance to outflow at the areas closest to the collector channel ostia.²⁴ Though this research is interesting, the bovine anatomy of aqueous outflow is different than the human anatomy, as there is no Schlemm's canal but instead the aqueous plexus, a suggested equivalent counterpart.²⁵ Indeed, one study performed a complete trabeculotomy in enucleated human eyes and found a majority, but not a total reduction in resistance: 50% at a "normal" IOP of 7mm Hg and 75% at a higher IOP of 23mm Hg.

These results indicate that other areas must also contribute significant outflow resistance within the aqueous outflow pathway, though the trabecular meshwork remains a key player in resistance, especially in high IOP situations.²⁴ A better understanding of the aqueous outflow process could help surgeons place these devices more precisely to circumvent the areas of greatest resistance to aqueous outflow. Modifying and standardizing placement could create the potential for greater and more consistent efficacy in the achieved hypotensive effect.

Although MIGS treatments have gained popularity among providers, continued long-term studies of stand-alone MIGS procedures and continued research into the relevant limbal anatomy could help practitioners develop a clearer understanding of the mechanisms. We hope that research will provide an accurate anatomical basis for the intended placement and desired caliber of implants in order to help further the potential success of these MIGS procedures. ■

Dr. Riccobono is a Cornea and Contact Lens Fellow at the University of Houston College of Optometry, her almer mater.

Dr. Bergmanson is a professor



Photo: Justin Schweitzer, OD

Fig. 4. The CyPass stent was recently removed from the market due to endothelial cell loss provoked by the procedure. In this view, a cyclodialysis cleft can be observed around the edges of the stent.

of optometry at the University of Houston College of Optometry, where he is the director of the Texas Eye Research and Technology Center. He is a Foundation Fellow of the College of Optometry in the United Kingdom and a diplomate in the Cornea and Contact Lens section of the American Academy of Optometry.

Mr. Anderson is currently a third year student at the University of Houston College of Optometry.

1. Quigley HA, Broman AT. The number of people with glaucoma worldwide in 2010 and 2020. *Br J Ophthalmol.* 2006;90(3):262-7.
2. Kass MA, Heuer DK, Higginbotham EJ, et al. The ocular hypertension treatment study: a randomized trial determines that topical hypotensive medication delays or prevents the onset of primary open-angle glaucoma. *Arch Ophthalmol.* 2002;120(6):701-3.
3. Bartlett JD, Fiscella RG, Jaanus SD, Barnebey H. Ocular hypotensive drugs. In: Bartlett, Jaanus eds. *Clinical Ocular Pharmacology.* Butterworth Heinemann Elsevier; 2008:139-174
4. Dawson DG, Uebels JL, Edelhauser HF. Cornea and sclera. In: Levin LA, Nilsson SFV, ver Hoeve J, et al. *Adler's Physiology of the Eye.* 11th ed. Edinburgh: Saunders/Elsevier; 2011.
5. Cha EDK, Xu J, Gong L, Gong H. Variation in active outflow along the trabecular outflow pathway. *Exp Eye Res.* 2016;146:354-60.
6. Bill A, Svedbergh B. Scanning electron microscopic studies of the trabecular meshwork and the canal of schlemm—an attempt to localize the main resistance to outflow of aqueous humor in man. *Acta Ophthalmologica.* 1972;50(3):295-320.
7. Chen DZ, Sng CCA. Safety and efficacy of microinvasive glaucoma surgery. *J Ophthalmol.* 2017;2017:3182935.
8. iStent inject Trabecular Micro-Bypass System (Model G2-M-IS) – P170043. United States Food and Drug Administration. www.fda.gov/MedicalDevices/ProductsandMedicalProcedures/DeviceApprovalsandClearances/Recently-ApprovedDevices/ucm612792.htm. Updated July 13, 2018. Accessed October 1, 2018.
9. Malvankar-Mehhta MS, Iordanous Y, Chen YN, et al. iStent with phacoemulsification versus phacoemulsification alone for patients with glaucoma and cataract: a meta-analysis. *PLoS ONE.* 2015;10(7):e0131770.
10. Resende AF, Patel NS, Waisbourd M, Katz LJ. iStent trabecular microbypass stent: an update. *J Ophthalmol.* 2016;2016:2731856.
11. Ferguson TJ, Berdahl JP, Schweitzer JA, Sudhagani R. Evaluation of a trabecular meshwork micro-bypass stent in pseudophakic patients with open angle glaucoma. *J Glaucoma.* 2016 Nov;25(11):896-900.
12. Katz LJ, et al. Long-term titrated IOP control with one, two or three trabecular micro-bypass stents in open-angle glaucoma subjects on topical hypotensive medication: 42-month outcomes. *Clin Ophthalmol.* 2018;12:255–262
13. Samuelson TW, Chang DF, Marquis R, et al. A schlemm canal microstent for intraocular pressure reduction in primary open-angle glaucoma and cataract: The HORIZON Study. *Ophthalmology.* June 23, 2018. [Epub ahead of print].
14. Bergmanson JPG. Limbus and filtration angle. In: Bergmanson JPG, ed. *Clinical Ocular Anatomy and Physiology.* 25th ed. Houston: Texas Eye Research and Technology Center, Houston Texas;2018.
15. Duke-Elder S, Wybar KC. The cornea. In: Duke-Elder S, Wybar KC, eds. *System of Ophthalmology.* Vol 2: The Anatomy of the Visual System. St Louis: Mosby;1961.
16. Hogan MJ, Alvarado JA, Weddell JE. The cornea. In: Hogan MJ, Alvarado JA, Weddell JE, eds. *Histology of the Human Eye.* Philadelphia: WB Saunders;1971.
17. Bron AJ, Tripathi RC, Tripathi BJ. The cornea and sclera. In: Bron AJ, Tripathi RC, Tripathi BJ, eds. *Wolff's Anatomy of the Eye and Orbit.* 8th ed. London: Chapman & Hall Medical;1977.
18. Oyster CW. The cornea and the sclera. In: Oyster CW, ed. *The Human Eye: Structure and Function.* Sunderland: Sinauer Associates;1999.
19. Freddo TF, Chaum E. The anatomy of the aqueous outflow pathways. In: Freddo TF, Chaum E, eds. *Anatomy of the eye and orbit: the clinical essentials.* 1st ed. Philadelphia: Wolters Kluwer; 2018.
20. Janson BJ, Alward WL, Kwon YH, et al. Glaucoma-associated corneal endothelial damage: A Review. *Surv of Ophthalmol.* 2018;63(4):500-6.
21. Fea AM, Consolandi G, Pignata G, et al. A comparison of endothelial cell loss in combined cataract and MIGS (Hydrus) procedure to phacoemulsification alone: 6-month results. *J Ophthalmol.* 2015;2015:769289.
22. Alcon Announces Voluntary Global Market Withdrawal of CyPass Micro-Stent for Surgical Glaucoma. United States Food and Drug Administration. www.fda.gov/Safety/Recalls/ucm619109.htm. Updated August 29, 2018. Accessed October 1, 2018.
23. Sng CCA, Barton K. Minimally invasive glaucoma surgery – coming of age. *Br J Ophthalmol* 2018;102:1315-6.
24. Battista SA, et al. Reduction of the available area of aqueous humor outflow and increase in meshwork herniations into collector channels following acute IOP elevation in bovine eyes. *Invest Ophthalmol Vis Sci.* 2008;49(12): 5346–52.
25. Overby D, Gong H, Qiu G, Freddo T, Johnson M. The Mechanism of Increasing Outflow Facility during Washout in the Bovine Eye. *Invest Ophthalmol Vis Sci.* 2002;43:3455-64.



NuLids™ transformational dry eye therapy

Transforms your patients' lives



Finally... A doctor-directed at-home treatment for dry eye disease that is safe, effective and easy to use.



A multi-center study¹ showed:

- 50% decrease in dry eye symptoms
- 65% improvement in TBUT
- 80% increase in meibomian glands yielding liquid secretions.

For more information visit
www.NuSightMedical.com/ropt12
or call us at 833-368-5437

¹ Schanzlin, Olkowski, Coble, Gross. NuLids II Study, April 2018



NuLids™

Doctor prescribed, at-home dry eye relief



With a Cherry on Top

Is this unusual-looking presentation tied to the patient's sudden vision loss?

By Shreya Jayasimha, OD, and Mark Dunbar, OD

A 64-year-old Hispanic female presented for evaluation of a sudden onset of painless vision loss that started eight days earlier. While she was immediately evaluated and treated at a local hospital, her visual outcome did not improve. In fact, in the eight days since her hospital visit, additional symptoms began to manifest. These included bilateral temporal headaches with fluctuations in severity as well as diffuse scalp tenderness. She denied any pain from prolonged chewing and did not report any bouts of weight gain or recent fevers. Her medical history is positive for hypertension for the past decade, which is currently controlled with amlodipine.

On examination, best-corrected visual acuities were hand movements OD and 20/20 OS, with a prescription of $-1.50 +1.00 \times 180$ OD, $-1.75 +1.00 \times 005$ OS. Her extraocular motility for both eyes was full and extensive. Confrontation visual fields revealed a generalized depression of the right eye, while the left eye was full. Her pupils were equal, round and slowly reactive to light with a 3+ afferent pupillary defect in the right eye.

Color vision measured with Ishihara plates was severely reduced for the right eye only (0/10 OD, 10/10 OS). Her intraocular pressures were measured at 17mm Hg OD and 18mm Hg OS using the Tonopen

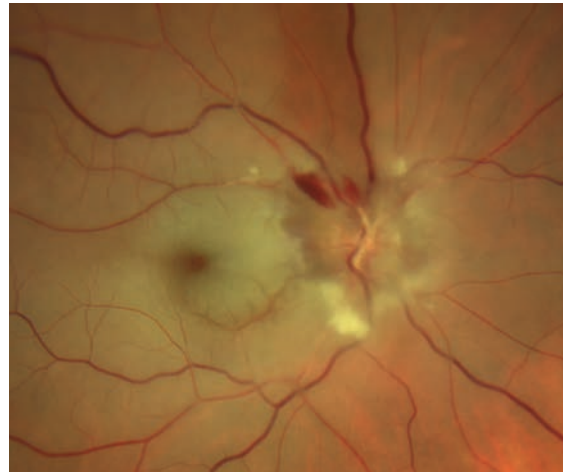

Fig. 1. This magnified, widefield image shows our patient's right eye.

(Reichert). Anterior segment health revealed 1+ nuclear sclerotic cataract in both eyes. A dilated fundus examination was performed and is available for review (*Figure 1*). Fluorescein angiography (FA) was also performed and images are available for review (*Figure 2*).

Take the Retina Quiz

- How would you characterize the images from the fluorescein angiogram at 29 seconds?
 - Patchy choroidal filling.
 - Silent choroid.
 - Delayed arterial filling.
 - Neovascularization of the disc.
- How would you describe the macular changes in the right eye?
 - Serous detachment of neurosensory retina.
 - Beaten metal appearance.
 - Cherry red spot.

d. Neuroretinitis.

- Which condition is most consistent with the fundus appearance of the right eye?
 - Branch retinal vein occlusion.
 - Branch retinal artery occlusion.
 - Central retinal artery occlusion.
 - Stargardt's macular degeneration.

4. What is the most likely underlying cause of the patient's right fundus findings?

- Elevated intracranial pressure.
- Hypertension/atherosclerosis
- Giant cell arteritis.
- Hereditary.

5. What is the most appropriate treatment for this patient?

- Counsel on proper blood pressure control and refer back to the PCP.
- Immediate initiation of oral antibiotics.
- Immediate initiation of IV and oral steroids.
- Prescribe Diamox (acetazolamide, Teva).

Diagnosis

Based on the history and clinical presentation, the patient was diagnosed with a central retinal artery occlusion of the right eye, most likely secondary to giant cell arteritis (GCA). Lab studies were ordered

which revealed an elevated erythrocyte sedimentation rate (ESR) value at 62mm/hr and an elevated CRP value at 2.6mg/L. In addition, CBC with differential revealed an elevated white blood cell count.

She was immediately sent to the hospital, where she was placed on intravenous methylprednisolone and monitored over night. The patient was discharged the next morning with a prescription of 80mg of oral prednisolone. On follow-up lab testing, she had a marked reduction in the ESR level from 62mm/hr to 17mm/hr and a reduction in the CRP value from 2.6mg/L to 1.1mg/L. While her vision did not improve, the bilateral temporal headaches and scalp tenderness significantly subsided upon initiation of the steroid treatment.

Discussion

Central retinal artery occlusion (CRAO) is an ocular emergency whereby patients present with sudden, profound, painless monocular vision loss.¹ In fact, 80% of affected individuals have a final visual acuity of counting fingers or worse.²

CRAO is classically described as a blockage of the central retinal artery responsible for supplying blood, nutrients and oxygen to the inner retinal layers of the eye. In the acute phase, 90% of CRAO cases will present with diffuse retinal whitening and a classic central cherry red spot.³ The cherry red spot is indicative of a thin and relatively transparent macula that reveals the underlying choroid.³ Additional signs of a CRAO include optic disc edema (in 22% of cases), optic disc pallor (39%) and arterial attenuation (32%).³ Unfortunately, this ischemic event causes irreversible retinal damage and profound vision loss with only mild visual recovery upon treatment.²

Diagnosis of this condition is prompted from sudden, painless vision loss coupled with the presence of diffuse retinal whitening and in most cases, a central cherry red spot.⁴ FA will show a delayed transit time followed by a patchy choroidal appearance and delayed arterial filling.⁵ This can be seen on the FA of our patient where even at 29 seconds you can see the fluorescein dye only beginning to fill the arteries (Figure 2). In a normal patient, this happens within 10 seconds.

Blockage of the central retinal artery may be caused by emboli, vasculitis or spasms.⁴ Major risk factors for a central retinal artery occlusion include hypertension, diabetes, hyperlipidemia, carotid occlusive disease and cardiac valve disease.⁴ Less common, but equally important, risk factors (especially when



NuLids™ transformational dry eye therapy

Transforms your patients' lives



Finally... A doctor-directed at-home treatment for dry eye disease that is safe, effective and easy to use.

A multi-center study¹ showed:

- 50% decrease in dry eye symptoms
- 65% improvement in TBUT
- 80% increase in meibomian glands yielding liquid secretions.

For more information visit
www.NuSightMedical.com/ropt12
or call us at 833-368-5437



¹ Schanzlin, Olkowski, Coble, Gross. NuLids II Study, April 2018



NuLids™

Doctor prescribed, at-home dry eye relief

no emboli are present) include GCA, collagen vascular disease, oral contraceptive use, sickle cell disease and syphilis.⁴

CRAO can also be classified based on the presence and extent of retinal ischemia.⁶ Non-arteritic CRAO accounts for a majority of cases and is typically caused from atherosclerotic disease.⁶ Arteritic CRAO, on the other hand, is not as common and is defined based on a large area of retinal ischemia (typically more than 10 disc diameters).⁶ For the purposes of this case, direct examination supported by the FA findings confirmed arteritic CRAO of the right eye as the correct diagnosis.

The most common cause of arteritic CRAO is GCA, a systemic vasculitis that affects medium and large-sized blood vessels in adults 50 years and older.² Systemic symptoms of GCA include fevers, temporal headaches, scalp tenderness, jaw claudication, temporary or sustained vision loss, problems with coordination, myalgias and difficulty swallowing.² Ocular manifestations of GCA include retinal, choroidal and optic nerve edema/ischemia, diplopia, eye pain or symptoms of cranial neuropathies.²

A GCA diagnosis is based largely on symptoms and physical examination. Additional testing includes lab work-up and a temporal artery biopsy.² Our patient underwent a temporal artery biopsy, which came back negative. This, however, cannot be solely used to confirm or deny the presence of GCA.

Conducting a medical work-up on patients suspected of having GCA is critical. Lab testing identifying inflammatory markers such as ESR, CRP and white blood cell counts, in conjunction with a temporal artery biopsy, becomes crucial for an accurate diagnosis of GCA. Elevated

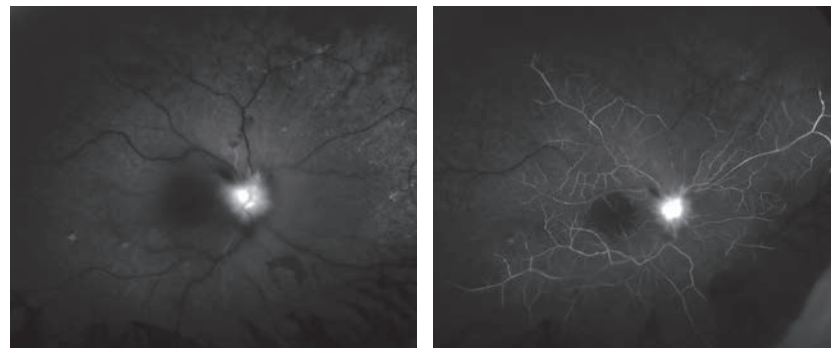


Fig. 2. This fluorescein angiogram shows the patient's right eye at 29 seconds (at left) and five minutes.

ESR and CRP levels are 97% specific for GCA.² In fact, CRP levels above 2.5mg/L are highly diagnostic of GCA.²

Treatment and Management

CRAO is an ocular analog of a cerebral stroke.¹ Immediate management is crucial to prevent further vision loss and systemic complications. Treatment options depend on the underlying cause of the CRAO and can include carbogen inhalation, acetazolamide infusion, ocular massage, anterior chamber paracentesis and various vasodilators.⁵

While such treatment can be attempted, none of these modalities definitively alter the natural history of the condition.⁶ In fact, patients who have experienced a CRAO are left with a guarded visual prognosis and minimal improvement in visual acuity from the initial encounter.⁴ An exception to the rule would be for those patients who have a cilio-retinal artery supplying the macula as it allows for visual improvement to 20/50 or better in 80% of eyes.⁴

GCA-related CRAO is typically treated with a high dose of oral steroids (typically 60mg to 80mg) or intravenous steroids followed by a course of orals.² While damage done by a GCA-related CRAO may not be reversible, aggressive treatment is needed to prevent further vision

loss and protect the good eye from a subsequent ischemic attack.²

Our patient was treated with intravenous methylprednisolone followed by a course of 80mg of oral prednisolone, which is currently being slowly tapered. Patients with CRAO need to be evaluated on a monthly (if not sooner) basis for at least the first three months to check for potential neovascularization of the retina, iris or angle.⁷ The reported prevalence of neovascularization after an episode of CRAO varies from 2.5% to 31.6%.⁷ Such complications can cause further vision loss in the affected eye and possibly lead to neovascular glaucoma (i.e., the 90-day glaucoma).⁶ ■

Dr. Jayasimha is an optometric resident at Bascom Palmer Eye Institute in Miami.

1. Beatty S, Eong K. Acute occlusion of the retinal arteries: Current concepts and recent advances in diagnosis and management. *J Accid Emerg Med.* 2000;17(5):324-9.
2. Schmidt D, Schulte-Mönting J, Schumacher M. Prognosis of central retinal artery occlusion: local intraarterial fibrinolysis versus conservative treatment. *2002;23(8):1301-7.*
3. Farris W, Waymack J. Central retinal artery occlusion. *State Pearls.* www.ncbi.nlm.nih.gov/books/NBK470354. October 27, 2018. Accessed November 15, 2018.
4. Weingeist T. Central Retinal Artery Occlusion (CRAO). *Eye Rounds.* webeve.ophth.uiowa.edu/eyeforum/atlas/pages/CRAO/index.htm. October 23, 2014. Accessed November 15, 2018.
5. Sim S, Ting D. Diagnosis and management of central retinal artery occlusion. *EyeNet.* www.aao.org/eyenet/article/diagnosis-and-management-of-crao. August 2017. Accessed November 15, 2018.
6. Varma D, Cugati S, Lee A, Chen C. A review of central retinal artery occlusion: Clinical presentation and management. *Eye (Lond).* 2013;27(6):688-97.
7. Chacko J, Chacko J, Salter M. Review of giant cell arteritis. *Saudi J Ophthalmol.* 2015 Jan-Mar;29(1):48-52.

Optometry CE Study Center



The CE You Need In 2018!

As low as
\$17.50
per Credit Hour

Buy just one 2-hour course for \$35 or buy as many as you need

Choose from over 50 individual CE courses

Includes the hard to find topics that fulfill your state requirements

All available in a convenient online format

Purchase Now!
www.reviewsce.com

The CE Study Center courses have been developed in conjunction with expert faculty from leading schools of optometry and are oriented toward clinical practice issues that are designed to assist eye care professionals in serving their patient's healthcare needs. CE Courses also appear in print monthly in Review of Optometry.

1-800-825-4696 • INFO@REVIEWSCE.COM

These COPE-Accredited CE courses are administered in partnership with an accredited school of optometry.

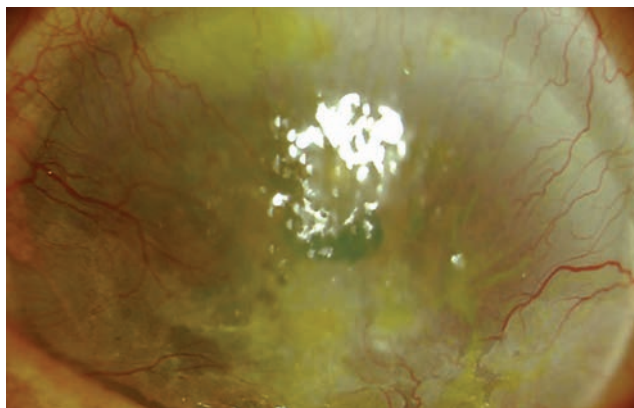




Facts about Vaxx

Newly approved vaccine Shingrix is a viable option for many elderly patients with chronic zoster. **Edited by Joseph P. Shovlin, OD**

Q I have a 55-year-old patient who has had chronic keratouveitis following a zoster outbreak for more than three and a half years. He currently uses low-dose topical steroids and Valtrex 500mg (GlaxoSmithKline) daily and has inquired about the recently approved vaccine, Shingrix (GlaxoSmithKline), for shingles. Considering his chronic ocular disease from zoster, is he a candidate for the vaccine? If so, how do we proceed?



This patient has severe corneal neovascularization and interstitial keratitis due to chronic, recurrent HZO.

A In short, this patient is indeed a candidate for the FDA-approved zoster vaccine, Shingrix—the newest zoster vaccine to be introduced to the market—says Stephanie Klemencic, OD, associate professor at the Illinois College of Optometry and the Illinois Eye Institute. Dr. Klemencic says patients are at a higher risk of developing recurrent zoster eye disease if they have not received a zoster vaccine. However, she recommends exercising caution, as episodes of herpes zoster (HZ) temporarily increase cell-mediated immunity to the varicella virus. She notes that current guidelines advise delaying vaccine use until the episode is resolved or, in the case of chronic disease, the disease is stable.¹

Weighing Your Options

Within the weeks leading up to and following zoster vaccination,

Dr. Klemencic suggests, patients with a history of herpes zoster ophthalmicus (HZO) or those who have chronic, stable HZO should undergo a dilated eye exam to ensure there is no recurrent HZO. Luckily, the risk of reactivating eye diseases is more rare with Shingrix, which does not contain live varicella virus, compared with vaccines that have the live virus, such as Zostavax (Merck), according to Dr. Klemencic.

Since Shingrix does not contain live virus, Dr. Klemencic says another plus is that there is no need to discontinue antiviral usage because these medications have no effect on the non-live vaccine virus. If a patient receives Zostavax or another vaccine with live virus, however, she notes that they must discontinue anti-viral usage at least one day before and wait to resume usage for two weeks after vaccination.²

Shingrix is also more efficacious than Zostavax—clinical trials found that the vaccine’s efficacy remained high, at 84%, over four years.³ The trials also discovered that the vaccine decreased the incidences of herpes zoster and post-herpetic neuralgia by 97% and 91% for patients in their 50s and 60s, respectively.³ For patients 70 and older, it decreased the incidences of HZ and post-herpetic neuralgia by 91% and 88.8%, respectively.⁴

“No matter how you look at it, shingles is a bad disease,” says Dr. Klemencic. “As optometrists, we can play a pivotal role in preventing this disease (or decreasing the severity of its complications) by discussing the new zoster vaccination with our patients age 50 and older.” She adds that Shingrix is considered safe and should be administered to immunocompetent adults age 50 and older. ■

1. American Academy of Ophthalmology. Recommendations for herpes zoster vaccine for patients 50 years of age and older—2018. www.aao.org/clinical-statement/recommendations-herpes-zoster-vaccine-patients-50- Published June 2018. Accessed November 15, 2018.

2. Immunization Action Coalition. Ask the Experts—Zoster (shingles). www.immunize.org/askexperts/experts_zos.asp. Published August 7, 2018. Accessed November 15, 2018.

3. Dooling KL, Guo A, Patel M, et al. Recommendations of the Advisory Committee on Immunization Practices for use of herpes zoster vaccines. *MMWR*. 2018;67(3):103-8.

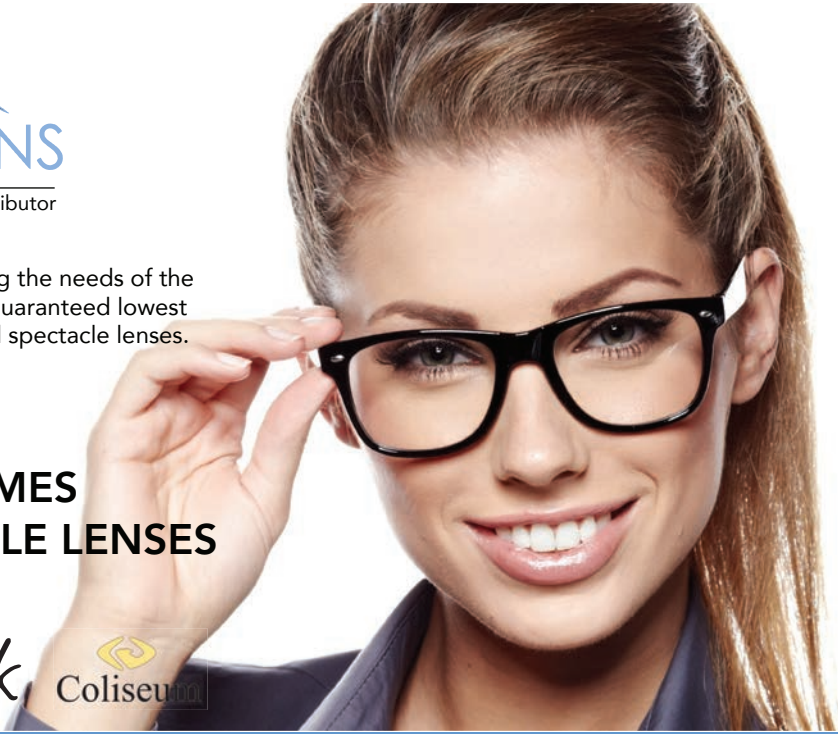
4. Cunningham AL, Lal H, Kovac M, et al. Efficacy of the herpes zoster subunit vaccine in adults 70 years of age or older. *NEJM*. 2016;375:1019-32.

Merchandise Offered



National Lens is dedicated to fulfilling the needs of the optical profession by providing the guaranteed lowest prices on contact lenses, frames, and spectacle lenses.

CONTACT LENSES
100% ITALIAN FRAMES
FINISHED SPECTACLE LENSES



GUARANTEED LOWEST PRICES | FREE FIRST CLASS SHIPPING*
*in stock products (when available)

Contact Lenses

Impressions

Color Contact Lens

Unleash your true color!

Amethyst	* Brown	* Grey	* Green	
Turquoise	* Hazel	* Honey	* Pure Hazel	* True Sapphire

Impressions colored contacts blend naturally with your patients eyes to create a beautiful look. Available in nine dazzling opaque colors of which Brown, Grey, Green, Hazel, Honey, Pure Hazel and True Sapphire are available in RX PL to -8.00. Impressions are fun, hip, fashionable and very competitively priced to help your bottom line. POP materials and posters are available upon request.

Available Exclusively at

NATIONAL LENS
 America's Leading Discount Optical Distributor
 1-866-923-5600 • 1-866-923-5601 FAX
 www.national-lens.com

Career Opportunities

30 year private optometry practice opportunity
 in Fairbanks, Alaska.
 See patients of all ages.
 Excellent leased location on busy thoroughfare.
907-978-7481
 or email virginialind@yahoo.com

Equipment and Supplies

WHY PAY RETAIL???



Pretesting Tables of all shapes and sizes at Wholesale Prices.

Search the word PRETESTING at EBAY

Save hundreds even thousands on all your pretesting needs.

Or call: 316-734-4265

Staff Optometrist Wanted

Bard Optical is a family owned full-service retail optometric practice with 22 offices (and growing) throughout Central Illinois. Bard Optical prides itself on having a progressive optometric staff whose foundation is based on one-on-one patient service. We are currently accepting CV/resumes for Optometrists to join our medical model optometric practice that includes extended testing. The practice includes but is not limited to general optometry, contact lenses and geriatric care. Salaried, full-time positions are available with excellent base compensation and incentive programs and benefits. Some part-time opportunities may also be available.

Current positions are available in Bloomington/Normal, Decatur/Forsyth, Peoria, Sterling and Canton as we continue to grow with new and established offices.

Please email your information to mhall@bardoptical.com or call Mick at 309-693-9540 ext 225. Mailing address if more convenient is:

Bard Optical
Attn: Mick Hall, Vice President
8309 N Knoxville Avenue
Peoria, IL 61615

Bard Optical is a proud Associate Member of the Illinois Optometric Association.



www.bardoptical.com

Do you have CE Programs?

CONTACT US TODAY FOR CLASSIFIED ADVERTISING

Toll free: 888-498-1460

E-mail: sales@kerhgroup.com

Practice For Sale

ARE YOU IN CONTROL?

Don't buy a job...acquire a business.

Select clients have larger practices available for outright purchase. Positive cash flow and 100% financing available. America's leading optometry business development consultancy provides support before, during and after closure.

We'll help you acquire the optometry practice of your dreams with no cost to you. See our current offerings at:

<http://www.cleinman.com/buy>
800-331-5536



Targeting Optometrists?

CLASSIFIED ADVERTISING WORKS

- JOB OPENINGS
- CME PROGRAMS
- PRODUCTS & SERVICES
- AND MORE...

Contact us today for classified advertising:

Toll free: **888-498-1460**

E-mail: sales@kerhgroup.com



Practice Sales • Appraisals • Consulting
www.PracticeConsultants.com

PRACTICES FOR SALE NATIONWIDE

Visit us on the Web or call us to learn more about our company and the practices we have available.

info@PracticeConsultants.com

800-576-6935

www.PracticeConsultants.com

GREAT OPPORTUNITY

retail optical in Beverly Hills Golden Triangle Room for exams/ in house lab/ **perfect** for retail optometric practice

Serving the community for over 50 years

Please fax all inquiries to:

(310) 276-4219

or call (310) 276 4121

Faculty**ASSISTANT PROFESSOR POSITIONS: PEDIATRICS**

Full-time non-tenure track faculty positions for the Chicago College of Optometry

RESPONSIBILITIES: Candidates are expected to be highly knowledgeable in the field of pediatric optometry and develop and teach courses and/or laboratories in the subject area. The primary care candidate must also be able to provide direct patient care and clinical instruction to professional students as well as residents, and be involved in interdisciplinary practice with other educational professionals.

Candidates must be willing to actively participate in curricular assessment, professional development, student counseling and service activities within the college, university and the scientific community. Successful candidates are also expected to be involved in research and scholarly activities, and have a sincere commitment to optometric education, community service and patient care. Primary duties include, but are not limited to:

a) Teaching

- Developing and delivering lectures and/or laboratories for related areas, as assigned;
- Embracing and enhancing the didactic philosophies in the O.D. program;
- Maintaining and expanding the high quality clinical practice environment for optometry students on rotation;
- Precepting students on clinical rotation at the Midwestern University Eye Institute where applicable;

b) Service

- Helping to maintain and grow the state of the art optometry program with a strong interdisciplinary focus that meets the needs of patients in the surrounding community; is efficient, patient friendly, and cost-effective;
- Working closely together with all optometry and ophthalmology faculty to provide a complete range of eye and vision care services;
- Participating in leadership roles in state, regional, and national optometry organizations;

- Participating on College and University committees, as assigned;
- Participating in College and University service activities.

c) Scholarly activity

- Engaging in research and scholarly activity, including presentations at scientific meetings, research, and publication in peer reviewed journals sufficient to qualify for academic advancement in a non-tenure track position.

QUALIFICATIONS: Candidates must possess a Doctor of Optometry degree from an ACOE-accredited institution, must have completed an ACOE-accredited residency, and must be eligible for an optometric state license in the state in which the college is located. Primary eye care clinical expertise is also required.

Salary will be commensurate with qualifications and experience

Review of applications will begin immediately and continue until the position is filled

CONTACT INFORMATION: Contact information: Interested applicants should apply online at www.midwestern.edu and include curriculum vitae and letter of interest specifying the position and college that he/she wishes to be considered for. Inquiries may be directed to Dr. Melissa Suckow, Dean; Midwestern University: msucko@midwestern.edu.

Midwestern University is an Equal Opportunity/Affirmative Action employer that does not discriminate against an employee or applicant based upon race, color, religion, gender, national origin, disability, or veterans status, in accord with 41 C.F.R. 60-1.4(a), 250.5(a), 300.5(a) and 741.5(a).

**ASSISTANT PROFESSOR POSITIONS: PRIMARY CARE/OPTOMETRIC THEORY AND METHODS**

Full-time non-tenure track faculty positions for the Chicago College of Optometry

RESPONSIBILITIES: Candidates are expected to be highly knowledgeable in the field of primary care optometry and optometric theory and methods and develop and teach courses and/or laboratories in the subject area. The primary care candidate must also be able to provide direct patient care and clinical instruction to professional students as well as residents, and be involved in interdisciplinary practice with other educational professionals.

Candidates must be willing to actively participate in curricular assessment, professional development, student counseling and service activities within the college, university and the scientific community. Successful candidates are also expected to be involved in research and scholarly activities, and have a sincere commitment to optometric education, community service and patient care. Primary duties include, but are not limited to:

a) Teaching

- Developing and delivering lectures and/or laboratories for related areas, as assigned;
- Embracing and enhancing the didactic philosophies in the O.D. program;
- Maintaining and expanding the high quality clinical practice environment for optometry students on rotation;
- Precepting students on clinical rotation at the Midwestern University Eye Institute where applicable;

b) Service

- Helping to maintain and grow the state of the art optometry program with a strong interdisciplinary focus that meets the needs of patients in the surrounding community; is efficient, patient friendly, and cost-effective;
- Working closely together with all optometry and ophthalmology faculty to provide a complete range of eye and vision care services;
- Participating in leadership roles in state, regional, and national optometry organizations;

- Participating on College and University committees, as assigned;
- Participating in College and University service activities.

c) Scholarly activity

- Engaging in research and scholarly activity, including presentations at scientific meetings, research, and publication in peer reviewed journals sufficient to qualify for academic advancement in a non-tenure track position.

QUALIFICATIONS: Candidates must possess a Doctor of Optometry degree from an ACOE-accredited institution, must have completed an ACOE-accredited residency, and must be eligible for an optometric state license in the state in which the college is located. Primary eye care clinical expertise is also required.

Salary will be commensurate with qualifications and experience

Review of applications will begin immediately and continue until the position is filled

CONTACT INFORMATION: Contact information: Interested applicants should apply online at www.midwestern.edu and include curriculum vitae and letter of interest specifying the position and college that he/she wishes to be considered for. Inquiries may be directed to Dr. Melissa Suckow, Dean; Midwestern University: msucko@midwestern.edu.

Midwestern University is an Equal Opportunity/Affirmative Action employer that does not discriminate against an employee or applicant based upon race, color, religion, gender, national origin, disability, or veterans status, in accord with 41 C.F.R. 60-1.4(a), 250.5(a), 300.5(a) and 741.5(a).

Continuing Education

Practice For Sale

FinalEyes CE

A Continuing Education Weekend Event
JACKSONVILLE, FLORIDA
February 15th-17th, 2019



18 COPE Approved Hours Including Florida Requirements for HIV, Medical Errors & Jurisprudence

Visit FinalEyesCE.com for More Information & to Register

PRACTICE FOR SALE

NORTHEASTERN PA.
Long established busy and very successful optometric practice grossing over \$550k for sale. The practice involves all phases of optometry with an emphasis on contact lenses. The practice includes an optical dispensary and finishing lab. Numerous vision plans are accepted including Medicare. Would be willing to work in the practice for a smooth transition. This is a great opportunity for an optometrist looking to earn a great income immediately.

Contact 1727white@gmail.com for more details.



**Do you have
CE Programs?**

**CONTACT US TODAY
FOR CLASSIFIED ADVERTISING**

Toll free: 888-498-1460
E-mail: sales@kerhgroup.com



Targeting Optometrists?

CLASSIFIED ADVERTISING WORKS

- JOB OPENINGS
- CME PROGRAMS
- PRODUCTS & SERVICES
- AND MORE...

Contact us today for classified advertising:

Toll free: 888-498-1460

E-mail: sales@kerhgroup.com





Spot Remover

Cut it, burn it, freeze it, laser it—there are plenty of ways to tackle xanthelasma.

By Dessie Westall, BS, and Leonid Skorin, Jr., DO, OD, MS

While some patients with xanthelasma ask their optometrist, “what are these yellow spots,” others may be completely unaware of the plaques that have formed. In either case, clinicians must educate patients on the systemic implications associated with these plaques.

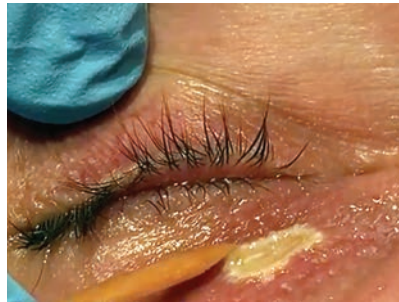Spotting the Spots

Xanthelasma, also known as xanthoma, are benign soft yellow-orange plaques. They vary in size and are often found on the eyelids but can present on any cutaneous surface. Frequently, both the upper and lower lids are involved.¹ Onset of xanthelasma typically begins during the fourth or fifth decade of life and is more prevalent in women.¹

Fifty percent of patients presenting with xanthelasma palpebrarum have hyperlipidemia.² For patients younger than 40, additional testing is indicated to rule out potential lipoprotein and apolipoprotein abnormalities.² Patients with xanthelasma are at a higher risk of atherosclerosis and should have a lipid panel completed so that their primary care provider can monitor for any underlying systemic disease.²

Therapies

Several options exist to remove xanthelasma. Methods include: traditional surgical excision, topi-



This patient chose to undergo chemical cauterization to resolve his xanthelasma.

cal trichloroacetic or bichloroacetic acid, liquid nitrogen, electrodesiccation, cauterization and several laser options.^{1,3,4}

Treatment methods using chemicals or lasers can result with permanent hypopigmentation of the skin after treatment.³ This effect is an important consideration when recommending a treatment method to a patient. These treatment options are contraindicated in individuals with darker complexion. Traditional surgical excision is the treatment of choice for these patients to optimize cosmetic outcomes.³

Bichloroacetic acid is one option for patients looking for simple, effective treatment. In a study of 25 xanthelasma plaques, 85% were resolved after initial treatment and 72% remained resolved over five years.¹ In cases where recurrence was observed, the patients had associated hyperlipidemia.¹

Case in Point

A 47-year-old Caucasian male presented with a single xanthelasma plaque on his lower right lid. The

patient had a lipid panel revealing hyperlipidemia and elevated triglycerides. Bichloroacetic acid treatment was performed to remove his lesion. The patient was given one drop of topical 0.5% proparacaine into his right lower cul-de-sac. His skin was cleaned using an alcohol wipe. Topical or local anesthetic is usually not indicated for this method of treatment. A generous amount of petroleum jelly, applied with a cotton-tip applicator, was used to protect the uninvolved healthy tissue surrounding the plaque. Bichloroacetic acid was then applied onto the surface of the plaque using a wooden applicator. Once liquification and pallor of the target tissue is observed, the chemical cauterization is complete. The petroleum jelly is then removed with a clean cotton-tip applicator.

The patient was directed to not disturb the treated tissue. The lesion will shortly become necrotic and slough off. ■

Ms. Westall is a fourth-year student at Pacific University College of Optometry.

Dr. Skorin is a consultant in the Department of Surgery, Community Division of Ophthalmology in the Mayo Clinic Health System in Albert Lea, MN.

1. Haygood LJ, Bennett JD, Brodell RT. Treatment of xanthelasma palpebrarum with bichloroacetic acid. *Am Soc Dermatol Surg*. 1998;24:1027-31.

2. Bergman R. The pathogenesis and clinical significance of xanthelasma palpebrarum. *J Am Acad Dermatol*. 1994;30:236-42.

3. Laffah Z, Al-Niaimi F. Xanthelasma: An update on treatment modalities. *J Cutan Aesthet Surg*. 2018;11:1-6.

4. Obradovic B. Surgical treatment as a first option of the lower eyelid xanthelasma. *J Craniofacial Surg*. 2017;28:678-9.



To see a video of this procedure, visit www.reviewofoptometry.com, or scan the QR code.

Earn up to
**20 CE
Credits***

ANNUAL • EST. 1976

WINTER OPHTHALMIC CONFERENCE

A REVIEW MEETING OF CLINICAL EXCELLENCE

THE LONGEST RUNNING WINTER CE MEETING IN EYE CARE!

FEBRUARY 15-19, 2019

Join us in Aspen, CO, for the 2019 Winter Ophthalmic Conference. This meeting features relevant topics in glaucoma, dry eye, external disease and retina.

WESTIN SNOWMASS CONFERENCE CENTER

100 Elbert Lane
Snowmass Village, CO 81615
Phone: 970-923-8200

CONTINUING EDUCATION:

- Earn up to 20 hours of COPE CE* credits
- **Registration cost: \$575**
- **Single day registration is available**
- Visit www.SkiVision.com for meeting agenda

THREE WAYS TO REGISTER

Online: www.SkiVision.com

E-mail: reviewmeetings@jhihealth.com

Call: 866-730-9257

See event website for all accommodations and rates.

MEETING CO-CHAIRS:



Murray Fingeret, OD, FFAO



Leo Semes, OD, FACMO, FFAO

SPEAKERS:

Jack Cioffi, MD

Mark Dunbar, OD, FFAO

Ben Gaddie, OD, FFAO

Elise Kramer, OD, FFAO

Ron Melton, OD, FFAO

Andrew Morgenstern, OD, FFAO

Jack Schaeffer, OD, FFAO

Randall Thomas, OD, MPH, FFAO

Administered by
RGVCE
REGULATORY GROUP VERIFICATION CENTER



*Approval pending

SALUS
UNIVERSITY
Pennsylvania College of Optometry

RGVCE partners with Salus University for those ODs who are licensed in states that require university credit.

ANNUAL • EST. 1976

WINTER OPHTHALMIC CONFERENCE

February 15-19, 2019 • Aspen, Colorado
Westin Snowmass Conference Center

Earn up to
20 CE Credits*

Registration Information

Today's Date _____

_____	_____	_____	
Name	Title	NPI # (NPI numbers will only be used for HCP reporting purposes)	
_____	_____	_____	
Practice Affiliation	License #/State	OE Tracker #	
_____	_____	_____	_____
Work Mailing Address	City	State	Zip Code
_____	_____	_____	_____
Work Telephone	Cell	E-mail	Fax
_____	_____	_____	_____

Name Badge Information (please print clearly)

_____	_____	_____
My Name	My Guest	Additional Guests

Payment Information

	<u>Rate per person</u>	<u>No. in party</u>	<u>Subtotal</u>
--	------------------------	---------------------	-----------------

OD Registration: \$575	\$575	x	_____	=	\$ _____
-------------------------------	-------	---	-------	---	----------

(includes up to 20 hours of CE, breakfasts, welcome reception, and the opportunity to purchase lift tickets at discounted group rates)

Please call 866-658-1772 or visit event website for daily rates.

Additional Guest(s): \$25	\$25	x	_____	=	\$ _____
----------------------------------	------	---	-------	---	----------

(12 years and older, reception only)

Check enclosed (make checks payable to Jobson Healthcare, LLC)

Charge my: American Express Mastercard Visa

CONFERENCE CANCELLATION POLICY

Full refund on registration fee until
December 30, 2018
50% refund on registration fee until
January 18, 2019
No refund past January 18, 2019

For more information or to register,
contact Lois DiDomenico at 866-658-1772
or at reviewmeetings@jhihealth.com.

Mail Form: Review Group c/o Jobson
11 Campus Blvd, Ste. 100
Newtown Square, PA 19073

Fax Form: Review Group
610-492-1039



Matching Glaucoma Drugs with Kids

Treating young patients requires special knowledge of their unique physiology.

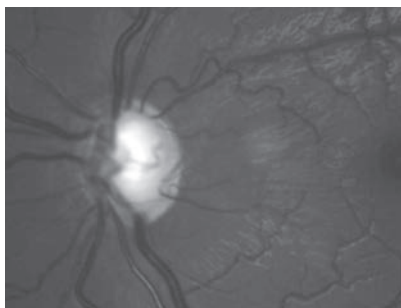
By Joseph W. Sowka, OD

A 13-year-old female was referred for reduced vision (20/40) in her left eye with a concurrent abnormal screening visual field, reportedly elevated intraocular pressure (IOP), and an afferent pupillary defect (APD). Her exam was three weeks earlier and she was previously referred to an ophthalmologist more than a year earlier, but her mother did not understand why and did not take her.

When presented with painless vision loss in a young patient with these findings, there are numerous diagnostic possibilities.

The key piece of diagnostic information was her IOP: she measured 28mm Hg OD and 43mm Hg OS by Goldmann applanation. Her pachymetry was slightly thick at 593 μ m OD and 595 μ m OS, but these values will not significantly impact an IOP of 43mm Hg. There were no biomicroscopic or gonioscopic abnormalities and both angles were open. The reason for the pronounced visual field loss, reduced vision and left APD was asymmetric glaucomatous damage. She was diagnosed with juvenile open angle glaucoma (JOAG).

Congenital and pediatric glaucoma represent a family of conditions that present, either in primary or secondary form, from birth to age 18. Congenital glaucoma is mainly addressed surgically while other pediatric forms are case dependent and may be treated either medically or surgically.¹ In such cases, know-



The left glaucomatous optic disc of the patient.

ing which medications are effective and safe is invaluable. Unfortunately, very little information is available on the pediatric safety of topical glaucoma medications. For most glaucoma drugs, pediatric use is labeled as “not recommended.”²

Here, we review what the evidence-based literature tells about the use of the most common glaucoma medications in children.

Beta-blockers

Though these were the cornerstone of management for adult primary open angle glaucoma for many years, they must be applied judiciously, even for adults, due to the systemic risks associated with them.

Many clinicians avoid them completely in children. However, the literature shows topical beta blockers can be an effective and safe therapy when used in children.³⁻⁹ One report saw 45% of children using topical timolol demonstrate a 10mm Hg reduction in IOP.³ Another study noted that, while pediatric patients experienced approximately a 25%

reduction in IOP from timolol use, no patient was controlled on this medication alone. Adverse effects in this report were low, though 7% of patients required timolol cessation.⁴

In a study involving 50 pediatric patients, only 4% developed systemic side effects.⁵ In another report that looked at 34 children with glaucoma, the addition of timolol to maximally tolerated medical therapy saw a definite improvement in 10 patients, modest or equivocal improvement in 11, and no substantial benefit in 13.⁶ In that same study, children older than five showed an average reduction in resting pulse rate of 6 BPM, but those under five years of age demonstrated no change in the resting pulse rate.⁶ Only one patient was discontinued from timolol for a possible adverse effect.⁶

Prostaglandin Analogs

These have become a favorite among practitioners due to superior efficacy and an excellent safety profile. However, they have not demonstrated similar efficacy in children.¹⁰

A 1999 study of 31 children with glaucoma saw an average IOP reduction of only 0.2mm Hg. Eighty percent of the children were non-responders (defined as experiencing a less than 15% IOP reduction with latanoprost). Of the 20% that did show response to latanoprost, those children were of an older cohort and tended to have juvenile open-angle glaucoma. In this study, latanoprost was well-tolerated both ocularly

and systemically by all children.¹¹ A 2004 report shows greater IOP reduction, but their cohort was older (12 to 18 years old).¹²

In a report on pediatric glaucoma associated with port-wine stain, investigators noted IOP control was achieved in only 50% of cases treated with latanoprost.¹³ Another research team noted that latanoprost is effective in only a minority of pediatric glaucoma cases.¹⁴ In contrast, a 2017 report found travoprost to be non-inferior to timolol in lowering IOP in patients with pediatric glaucoma or ocular hypertension.¹⁵ Travoprost was well-tolerated, and no treatment-related systemic adverse events were reported.¹⁵ Prostaglandin analogs are safe and well tolerated, but unfortunately, not particularly effective in the pediatric glaucoma population. Older children who have juvenile-onset open angle glaucoma see the most benefit.

Alpha-2 Adrenergic Agonists

Research demonstrates that the efficacy of brimonidine in children is approximately 5mm Hg reduction in IOP from baseline when used as a primary or adjunctive agent.^{16,17} However, brimonidine, a selective alpha-2 agonist, crosses the blood-brain barrier and potentially affects the central nervous system (CNS).¹⁸

This medication has an unacceptable level of adverse events in children.¹⁶⁻²¹ Local adverse reactions such as stinging and burning are common.¹⁵ The overall adverse event rate for children using brimonidine was 84% in another report.¹⁶ However, CNS effects of brimonidine are potentially more serious; the most notable of these in children has been lethargy and somnolence.¹⁶⁻²¹ The reported rate of somnolence has ranged from 17% to as much as 76%.¹⁶⁻¹⁸ One report noted that

brimonidine induced fainting in two children.²⁰ Another reported on coma being induced.²¹

Despite the efficacy of brimonidine, the side effect profile in children appears unacceptable, especially for those under age eight.

Carbonic Anhydrase Inhibitors

Modestly effective in adults, this class has had little use in the pediatric population. However, studies do demonstrate surprising results with good efficacy and tolerability of both oral and topical carbonic anhydrase inhibitors (CAIs).²²⁻²⁵ One found that topical dorzolamide did not work as well as oral acetazolamide, but did note a significant IOP reduction in the pediatric group, with dorzolamide being well tolerated.²⁴ Another noted a similar efficacy between dorzolamide and acetazolamide without any adverse effects and concluded that topical CAIs can potentially replace oral CAIs to manage pediatric glaucoma.²³

Topical dorzolamide appears tolerable, with a local adverse reaction rate of 3% in one report, and an IOP reduction of up to 23% in children younger than six.²² It seems that topical CAIs may be an unnecessarily overlooked class of medications for use in the management of pediatric glaucoma.²⁶

Pressure Relief

Based upon literature reports and personal experience, a topical CAI—and, if necessary, a beta-blocker—seem to work well for children in need of medical pressure reduction. A prostaglandin analog may work if the child is older. Brimonidine should be avoided in children, especially those younger than eight years.

In the young girl presented here, prostaglandin analogs predictably had no effect. She eventually ended up using Cosopt (dorzolamide/

timolol fixed combination, Merck), which lowered her IOP to a range of 15mm Hg to 17mm Hg in each eye.

While it may not be common to see children with glaucoma in a primary care practice, realize that the condition does exist, and patients may seek your expertise. Knowing which medications are safe and beneficial is a crucial aspect of managing these youngsters. ■

1. Tanimoto S, Brandt J. Options in pediatric glaucoma after angle surgery has failed. *Curr Opin Ophthalmol.* 2006;17(2):132-7.
2. Chung I, Bühr V. Topical ophthalmic drugs and the pediatric patient. *Optometry.* 2000;71(8):511-8.
3. Hoskins HD Jr, Hetherington J Jr, Magee SD, et al. Clinical experience with timolol in childhood glaucoma. *Arch Ophthalmol.* 1985;103(8):1163-5.
4. McMahon CD, Hetherington J Jr, Hoskins HD Jr, et al. Timolol and pediatric glaucomas. *Ophthalmology.* 1981;88(3):249-52.
5. Zimmerman TJ, Koener KS, Morgan KS. Safety and efficacy of timolol in pediatric glaucoma. *Surv Ophthalmol.* 1983;28 Suppl:262-4.
6. Boger WP 3rd, Walton DS. Timolol in uncontrolled childhood glaucomas. *Ophthalmology.* 1981;88(3):253-8.
7. Talbot AW, Russell-Eggitt I. Pharmaceutical management of the childhood glaucomas. *Expert Opin Pharmacother.* 2000;1(4):697-711.
8. van Emelen C, Goethals M, Dralands L, et al. Treatment of glaucoma in children with Sturge-Weber syndrome. *J Pediatr Ophthalmol Strabismus.* 2000;37(1):29-34.
9. Koraszewska-Matuszewska B. Pharmacotherapy of congenital glaucoma in young children. *Klin Oczna.* 1999;101(5):393-6.
10. Enyedi LB, Freedman SF. Latanoprost for the treatment of pediatric glaucoma. *Surv Ophthalmol.* 2002;47 Suppl 1:S129-32.
11. Enyedi LB, Freedman SF, Buckley EG. The effectiveness of latanoprost for the treatment of pediatric glaucoma. *J AAPOS.* 1999;3(1):33-9.
12. Urban B, Bakunowicz-Lazarczyk A, Mrugacz M, et al. The effectiveness of latanoprost for the treatment of pediatric glaucoma. *Klin Oczna.* 2004;106(1-2 Suppl):243-4.
13. Ong T, Chia A, Nischal KK. Latanoprost in port wine stain related paediatric glaucoma. *Br J Ophthalmol.* 2003;87(9):1091-3.
14. Ravinet E, Mermoud A, Brignoli R. Four years later: a clinical update on latanoprost. *Eur J Ophthalmol.* 2003;13(2):162-75.
15. Dixon ER, Landry T, Venkataraman S, et al. A 3-month safety and efficacy study of travoprost 0.004% ophthalmic solution compared with timolol in pediatric patients with glaucoma or ocular hypertension. *J AAPOS.* 2017;21(5):370-374.
16. Montero-de-Espinosa I, Morales C, Marquez-de-Aracena R. Ocular hypertension in children treated with brimonidine 0.2%. A clinical study. *Arch Soc Esp Oftalmol.* 2006;81(3):155-60.
17. Al-Shahwan S, Al-Torbak AA, Turkmani S, et al. Side-effect profile of brimonidine tartrate in children. *Ophthalmology.* 2005;112(12):2143.
18. Enyedi LB, Freedman SF. Safety and efficacy of brimonidine in children with glaucoma. *J AAPOS.* 2001;5(5):281-4.
19. Levy Y, Zadok D. Systemic side effects of ophthalmic drops. *Clin Pediatr (Phila).* 2004;43(1):99-101.
20. Bowman RJ, Cope J, Nischal KK. Ocular and systemic side effects of brimonidine 0.2% eye drops (Alphagan) in children. *Eye.* 2004;18(1):24-6.
21. Berlin RJ, Lee UT, Samples JR, et al. Ophthalmic drops causing coma in an infant. *J Pediatr.* 2001;138(3):441-3.
22. Ott EZ, Mills MD, Arango S, et al. A randomized trial assessing dorzolamide in patients with glaucoma who are younger than 6 years. *Arch Ophthalmol.* 2005;123(9):1177-86.
23. Rehurek J, Vancurova J, Trusopt, a local carboanhydrase inhibitor, in the treatment of glaucoma in children (preliminary report). *Cesk Slov Oftalmol.* 1998;54(2):82-5.
24. Portellos M, Buckley EG, Freedman SF. Topical versus oral carbonic anhydrase inhibitor therapy for pediatric glaucoma. *J AAPOS.* 1998;2(1):43-7.
25. Rehurek J, Spicarova R, Vancurova J. Effect of Trusopt on normal intraocular pressure values in children. *Cesk Slov Oftalmol.* 2000;56(6):366-9.
26. Coppens G, Stalmans I, Zeyen T, Casteels I. The safety and efficacy of glaucoma medication in the pediatric population. *J Pediatr Ophthalmol Strabismus.* 2009;46(1):12-8.

SET YOUR EYES ON WHAT'S NEXT



Look into the future of optometry at **SECO 2019**—and see all the vibrant innovations and exciting advancements that are transforming eye care today. As the leading source for world-class optometric education, SECO 2019 brings together all the experts, insights and eye-opening innovations for delivering top-notch care and running a more profitable practice. Join us in New Orleans, February 20–24, 2019—and set your sights on success.

REGISTER TODAY

SECO 2019
WHERE SIGHT MEETS VISION™
FEB. 20-24 | NEW ORLEANS, LA
ERNEST N. MORIAL CONVENTION CENTER
attendseco.com | #SECO2019



A Second Opinion on Surgery

A patient looks for a medical option to avoid an operation. **By James L. Fanelli, OD**

In late August, a 79-year-old Caucasian male presented to the office looking for a second opinion regarding his glaucoma. He was told that he should get “laser surgery,” but did not want to proceed with it until obtaining a second opinion from me. His history was significant with an approximate six-year history of glaucoma. He was medicated in both eyes with Travatan Z (travoprost ophthalmic solution, Novartis) HS and Simbrinza (brinzolamide/brimonidine tartrate ophthalmic suspension, Novartis) BID. Other systemic medications included only an unknown inhaler for chronic obstructive pulmonary disease.

He had been seeing the other provider for several years and underwent several medication changes until settling on his regimen. It was unclear exactly why further intervention was recommended; it may have been progressing structural changes to his optic nerve, progressive visual field loss, fluctuation IOP or any combination.

Diagnostic Data

His best-corrected visual acuity was 20/40-OD, OS, OU through minimally hyperopic astigmatic correction. Pupils were reactive to light, and there was mild physiological anisocoria present, along with pupillary ruff disruption in his left eye, most likely as a minor complication from cataract surgery. Extraocular muscles were full in all

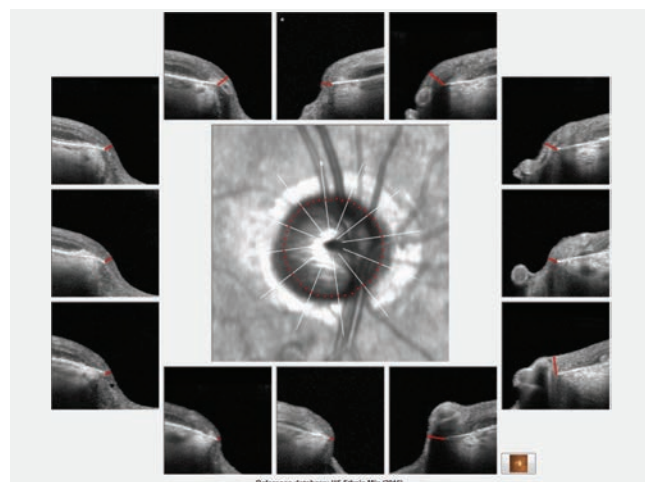


Fig. 1. The 12 o'clock hour BMO scans of the patient's right optic nerve, all of which are aberrant as compared with a reference database.

positions. Applanation tensions were 10mm Hg OD and 14mm Hg OS. Pachymetry readings were 594µm OD and 591µm OS.

The anterior segment was essentially unremarkable, with wide open angles, clear corneas, save for mild arcus OU. Posterior chamber IOLs were present in both eyes centered in the capsular bags, with clear and intact posterior capsules.

Through dilated pupils, bilateral posterior vitreous separations were visible. Stereoscopic examination of his optic nerves revealed an estimated cup-to-disc ratio of 0.90 x 0.90 OD and 0.80 x 0.90 OS. The neuroretinal rims were thin and consistent with advanced glaucomatous damage. The retinal vasculature was characterized by mild arterio-larsclerotic retinopathy in both eyes. Both maculae were characterized by having retinal pigment epithelium granulation and drusen, and mild epiretinal membranes. These macu-

lar findings were consistent with the acuities of 20/40 noted earlier. His peripheral retinal evaluations were normal.

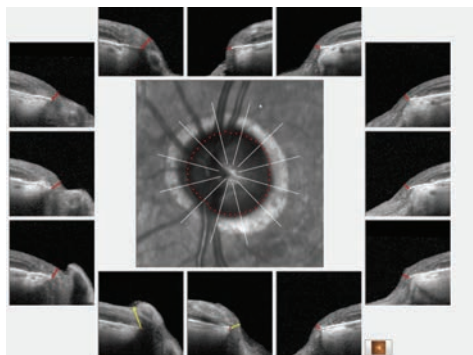
A Closer Look

Since he was after a second opinion, we needed more data about the first; in particular the rationale for recommending laser surgery. Based on the physical appearance of the optic nerves, it was clear he had advanced glaucoma, but it required further in-office evaluations.

Accordingly, on this initial visit, multimodal optic nerve images were obtained after dilation. Also, baseline Heidelberg Retina Tomograph (HRT 3) scans and optical coherence tomography (OCT) optic nerve and macular scans were obtained.

The HRT 3 scans confirmed the estimated cup-to-disc ratios seen on physical examination. His OCTs were revealing on several fronts. First, Bruch's membrane opening

Fig. 2. The left optic nerve BMO overview scan, with most sectors well outside reference database norms.



(BMO) analysis of both optic nerves demonstrated a thin neuroretinal rim, consistent with advanced disease (Figures 1 and 2).

While reference databases have their role in assessing where your patient stands amongst a reference group of similar but healthy optic nerves, they don't give a good picture, in details, of how much damage actually exists. They are simply statistical measures of where a patient exists on the bell curve.

Further examination of the OCT images demonstrated significant loss of ganglion cells in both eyes.

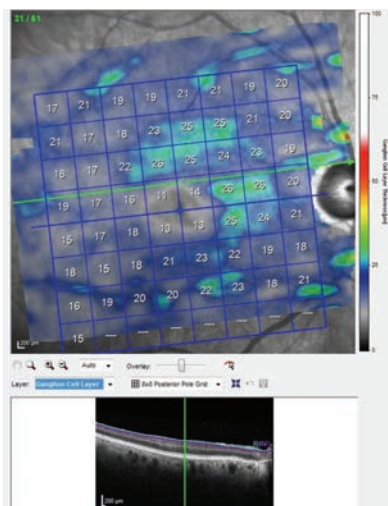


Fig. 3. Note the markedly thin ganglion cell layer in the patient's right macula. Normal ganglion cell thickness in the macular region varies, but is usually in the 30µm to 40µm range.

The OCT shows the macular scan of the right eye, with segmentation including only the ganglion cells; note the central loss of ganglion

cells in the macular region (Figure 3). Additionally, the BMO images seen earlier are an overview of the 12 major meridians around the optic nerve, but closer analysis of the minimum rim width (MRW) of the BMO readings can measure the ganglion cell thickness in the neuroretinal rim along 64 radial OCT scans. The MRW in a sector of the left eye, specifically a sector of the superior temporal neuroretinal rim, shows a ganglion cell thickness of just 65µm (Figure 4). For baseline purposes, both these data points are invaluable in determining further deterioration of the neuroretinal rim or macular ganglion cells, should the disease progress.

At the completion of the initial visit, it was clear that the patient had advanced glaucoma, and important baselines were obtained. But I still was not at the point yet where I could accurately render an opinion as to whether or not the patient should undergo further therapy. I explained that, while he did have advanced glaucoma, more information was needed. Some of that information would need to come from the previous provider, and some would be obtained on the next visit with me.

The patient was scheduled to return to my clinic in one to three weeks for visual field testing, gonioscopy, anterior chamber imaging with both OCT and UBM imaging,

as well as an important second IOP reading to get a feel for diurnal variation. At that visit, applanation tensions were 12mm Hg OD and 15mm Hg OS at 10:05am. Threshold standard automated perimetry visual fields demonstrated significant bilateral field defects consistent with the level of glaucomatous damage, with right-field defect-involving fixation. Gonioscopy demonstrated wide-open angles, with mild trabecular pigmentation OU, and the anterior segment OCT scans and the UBMs demonstrated normal anterior chamber anatomy.

Therapies

I was at a disadvantage because I could only see that he had advanced disease, but I could not determine, in two visits, if in fact he was stable or showing progression. Certainly, if a disease is progressing, something else must be done. But if a patient is stable, he could maintain the status quo. At the follow up visit, the patient made it clear he did not want to undergo any procedures.

Given this reluctance, I wondered if we do something to help mitigate his risk of progressing. We could, potentially, change his medications. Given his COPD, we needed to avoid beta blockers, and his current regimen covered the bases.

Recently, two new medications have become available: Vyzulta (latanoprostene bunod, Bausch + Lomb) and Rhopressa (netarsudil, Aerie). Both facilitate aqueous outflow through the trabecular meshwork, and Vyzulta maintains the prostaglandin-like uveoscleral outflow mechanism common to prostaglandins. I chose to proceed with Vyzulta due to the patient's insurance and the drug's performance in the APOLLO Study.¹

Advertisers Index

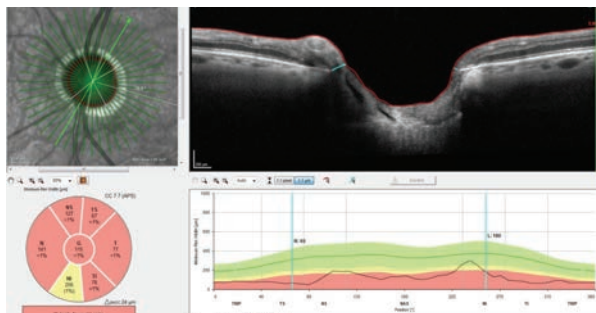


Fig. 4. Note the extreme thinning of the neuroretinal rim as measured from the edge of Bruch's membrane to the closest portion of the ganglion cells as they enter the optic nerve. In the superior temporal scan, only 65µm of tissue remains.

The challenge was incorporating it into his care. Vyzulta is essentially metabolized into a prostaglandin and nitric oxide. My experience with this medication is that it seems to give a greater reduction in IOP than a prostaglandin alone, owing, most likely, to the effects of the nitric oxide. So, I did something I rarely do—I added this to his current regimen. In other words, I did not stop the Travatan Z that he was currently taking. Here is my logic in doing so (and, yes, this can be criticized!): given he was a fragile glaucoma patient with advanced disease (but the level of frailty was not really known at the time), it would simply be easier to see the effect of the addition of a dual mechanism drug to a regimen that already includes a drug acting via one of the two mechanisms (uveoscleral outflow) in the new drug. Theoretically, there should be no further benefit of the prostaglandin that the Vyzulta generates than to the travoprost; the difference in IOP, if any, could be attributed to the nitric oxide.

When the patient returned in two weeks to see what effect this had on his IOP, applanation tensions were 9mm Hg OD and 10mm Hg OS. IOP readings six days later, after discontinuing Travatan Z, were 10mm Hg OD and OS. Is this enough to stave off further damage? Is this controlling IOP diurnal variations better than the previous combination of medications? Will this keep him from having further intervention?

I don't know the answer to these questions yet, but I will. Given that he is tolerating the medications well, with what appear to be better IOP reading with less fluctuations (as best we can tell in these few visits), we can at least buy some time before heading to further intervention. ■

1. Weinreb R, Scassellati Sforzolini B, Vittitow J, Liebmann J. Latanoprostene Bunod 0.024% versus Timolol Maleate 0.5% in Subjects with Open-Angle Glaucoma or Ocular Hypertension: The APOLLO Study. *Ophthalmol.* 2016;123(5):965-73.

For advertising opportunities contact:

Michele Barrett (215) 519-1414 or mbarrett@jobson.com
 James Henne (610) 492-1017 or jhenne@jobson.com
 Michael Hoster (610) 492-1028 or mhoster@jobson.com

Alcon Laboratories 7, 8, 28-31, 84
 Phone (800) 451-3937
 Fax (817) 551-4352

Allergan, Inc. 19
 Phone (800) 347-4500

Bausch + Lomb 10, 83
 Phone (800) 323-0000
 Fax (813) 975-7762

Kala Pharmaceuticals 17
 Phone (781) 996-5252
 Fax (781) 642-0399
 info@kalarx.com
 www.kalarx.com

Katena 15
 Phone (800) 225-1195

 www.katena.com

Keeler Instruments 9
 Phone (800) 523-5620
 Fax (610) 353-7814

Menicon 5
 Phone (800) MENICON

 information@menicon.com
 www.meniconamerica.com

NuSight Medical Operations 63, 65
 Phone (833) 468-5437

 www.NuSightMedical.com

Reichert Technologies 2-3
 Phone (888) 849-8955
 Fax (716) 686-4545
 www.reichert.com

S4OPTIK 43, 45, 47
 Phone (888) 224-6012

This advertiser index is published as a convenience and not as part of the advertising contract. Every care will be taken to index correctly. No allowance will be made for errors due to spelling, incorrect page number or failure to insert.



Orange Crush

By Andrew S. Gurwood, OD

History

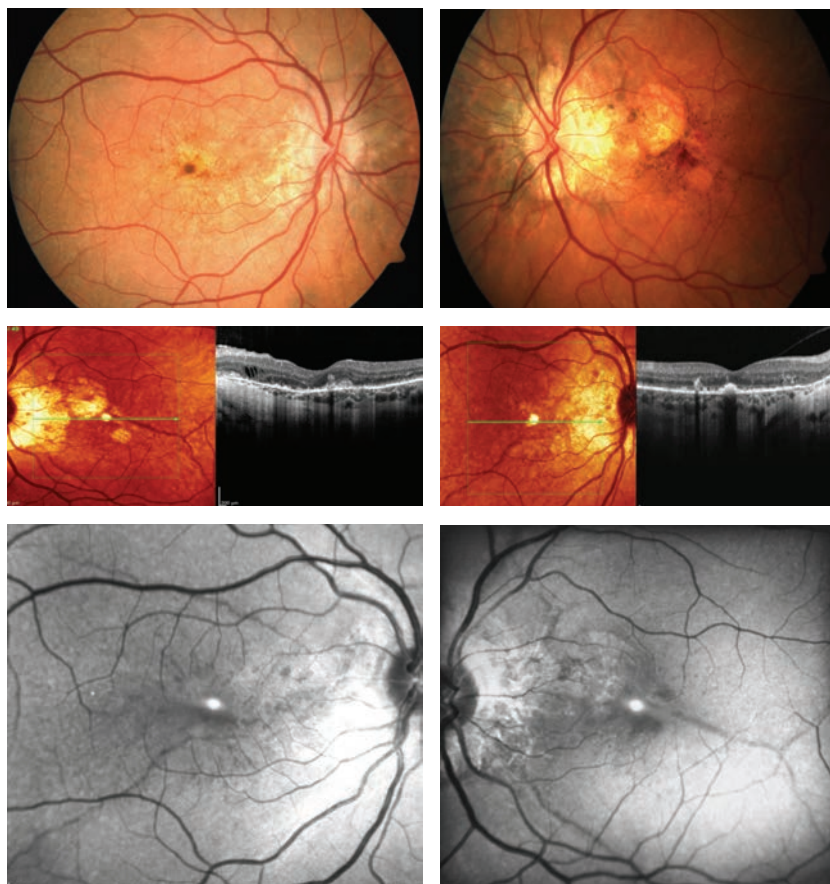A 52-year-old Caucasian female presented with a chief complaint of blurry vision in both eyes at distance and near of five months duration. She reported no trauma. While she reported having been diagnosed with pseudoxanthoma elasticum, she explained she was taking no medication for it, nor was she seeing a physician for it. She reported using bisacodyl for constipation. She denied allergies of any kind.

Diagnostic Data

Her best-corrected visual acuities were 20/80 OD and 20/150 OS. Pupils were round, equal in size, and reactive to light without an afferent pupil defect. Extraocular muscles exhibited full range of motion. Confrontation visual fields were full to finger counting OU with some blur reported using the facial Amsler.

Refraction uncovered negligible hyperopia with presbyopia, not improving visual acuity. Biomicroscopy found normal anterior segment structures with mild nuclear cataracts, both eyes.

The pertinent posterior segment findings are demonstrated in the photographs.



How can this 52-year-old patient's posterior segment findings help explain her five months of blurry vision?

Your Diagnosis

Does the case presented require any additional tests, history or information? What steps would

you take to manage this patient? What would be your diagnosis? To find out, please visit www.reviewofoptometry.com. ■

Retina Quiz Answers (from page 64): 1) c; 2) c; 3) c; 4) c; 5) c.

REVIEW OF OPTOMETRY (ISSN 0147-7633) IS PUBLISHED MONTHLY, 12 TIMES A YEAR BY JOBSON MEDICAL INFORMATION LLC, 440 9TH AVENUE, 14TH FLOOR, NEW YORK, NY 10013-1678. PERIODICALS POSTAGE PAID AT NEW YORK, NY AND ADDITIONAL MAILING OFFICES. POSTMASTER: SEND ADDRESS CHANGES TO REVIEW OF OPTOMETRY, PO BOX 81, CONGERS, NY 10920-0081. SUBSCRIPTION PRICES: US: ONE YEAR \$56; TWO YEARS \$97, CANADA: ONE YEAR \$88, TWO YEARS \$160, INT'L: ONE YEAR \$209, TWO YEARS \$299. FOR SUBSCRIPTION INFORMATION CALL TOLL-FREE (877) 529-1746 (USA); OUTSIDE USA, CALL (845) 267-3065. OR EMAIL US AT REVOPPTOMETRY@CAMBEYWEST.COM. PUBLICATIONS MAIL AGREEMENT NO: 40612608. CANADA RETURNS TO BE SENT TO BLEUCHIP INTERNATIONAL, P.O. BOX 25542, LONDON, ON N6C 6B2.



A S T I G M A T I C

S U C C E S S

— from chair —

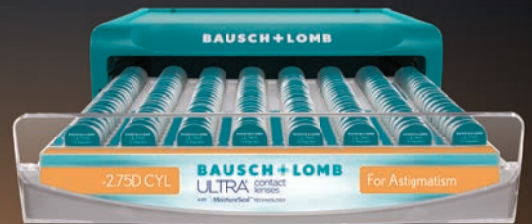T O W E A R

Bausch + Lomb ULTRA® for Astigmatism

The **only** monthly toric lens with a
-2.75D Cylinder in your fit set



Contact your representative
to request lenses for your office



®/™ are trademarks of Bausch & Lomb Incorporated or its affiliates.
©2018 Bausch & Lomb Incorporated. UFA.0115.USA.18

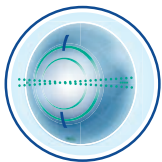
BAUSCH + LOMB
See better. Live better.

STABILITY, ANYWHERE, ANYTIME




DAILIES® AquaComfort Plus® Toric contact lenses are ahead of the curve with consistent, stable vision and refreshing comfort.

Patients can SAVE on their first annual supply at DAILIESCHOICE.com



ON-EYE STABILITY
With $\leq 5^\circ$ oscillation per blink, the PRECISION CURVE® lens design enables consistently stable lens wear.^{1*}



TEAR FILM STABILITY
Blink-activated moisture continuously refreshes the surface for excellent comfort and performance.^{2,3}



CONSISTENT COMFORT
Moisturizing agents are gradually released throughout the day for initial and all-day comfort.^{2,4,5}

Prescribe DAILIES® AquaComfort Plus® Toric contact lenses for your astigmatic patients.

References: 1. Alcon data on file, 2012. 2. Wolffsohn JS, Hunt OA, Chowdhury A. Objective clinical performance of 'comfort-enhanced' daily disposable soft contact lenses. *Contact Lens & Anterior Eye*. 2010;33(2):88-92. 3. Laboratory study release profile; Alcon data on file, 2007. 4. Winterton L, Lally J, Sentell K, Chapoy L. The elution of poly (vinyl alcohol) from a contact lens: The realization of a time release moisturizing agent/artificial tear. *J Biomed Mater Res B Appl Biomater*. 2007;80B:424-32. 5. Laboratory study release profile; Alcon data on file, 2007.

See product instructions for complete wear, care, and safety information.  © 2017 Novartis 11/17 US-DAT-17-E-2219(1)

Alcon A Novartis Division