

Take a Clinical Approach to Anterior Uveitis, p. 72 – EARN 2 CE CREDITS

REVIEW[®] OF OPTOMETRY

February 15, 2019


www.reviewofoptometry.com



Get a Glimpse of **WORK IN PROGRESS**


Five research teams share details about their efforts to build new tools for glaucoma, AMD, diabetic retinopathy and drug delivery.

Page 34



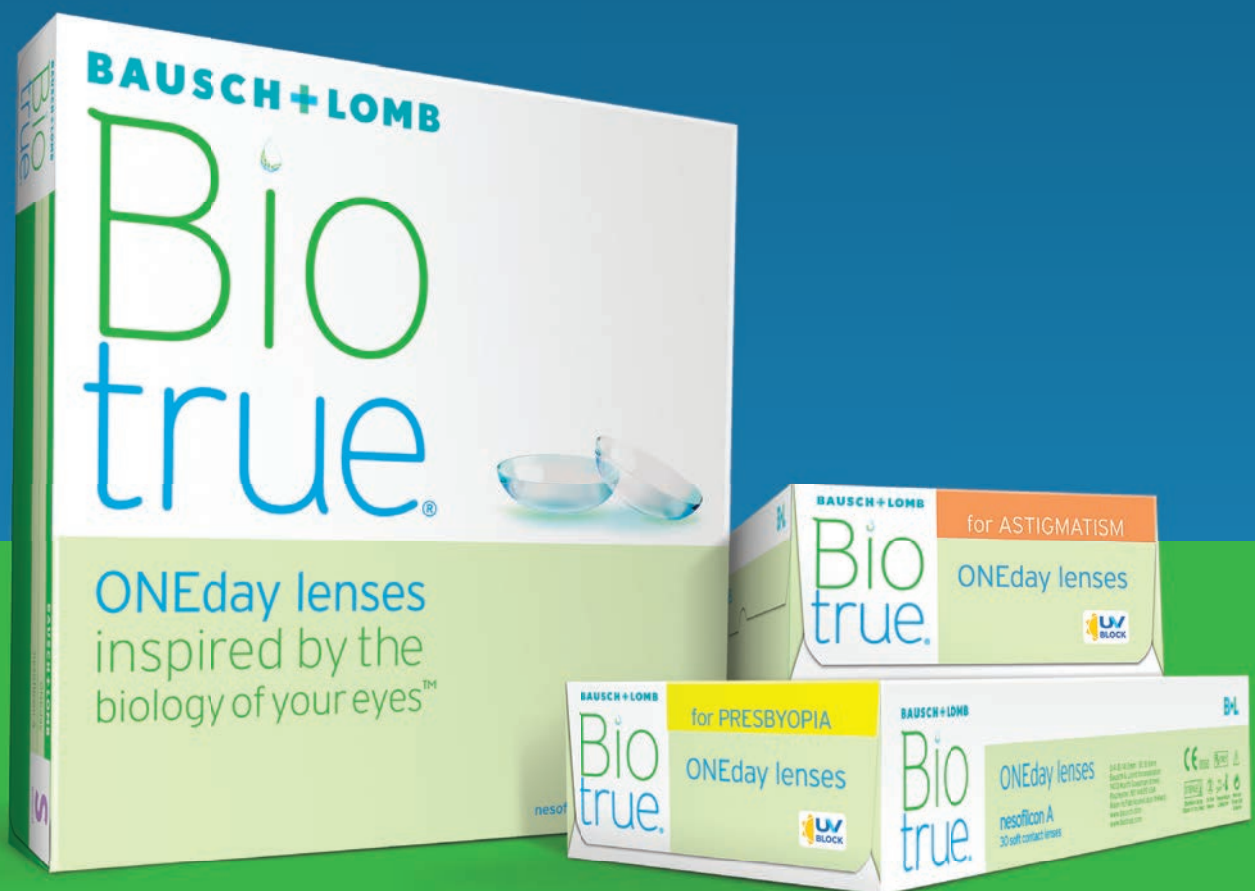ALSO: How to Succeed in Plaquenil Screenings, p. 56

Step-by-Step Neuro Exam, p. 64



TAKE A CLOSER LOOK

at Biotrue® ONEday—the lens that's growing
6X FASTER than the total daily disposable market^{1*}



§WARNING: UV-absorbing contact lenses are NOT substitutes for protective UV-absorbing eyewear, such as UV-absorbing goggles or sunglasses, because they do not completely cover the eye and surrounding area. The effectiveness of wearing UV-absorbing contact lenses in preventing or reducing the incidence of ocular disorders associated with exposure to UV light has not been established at this time. You should continue to use UV-absorbing eyewear as directed. NOTE: Long-term exposure to UV radiation is one of the risk factors associated with cataracts. Exposure is based on a number of factors such as environmental conditions (altitude, geography, cloud cover) and personal factors (extent and nature of outdoor activities). UV-blocking contact lenses help provide protection against harmful UV radiation. However, clinical studies have not been done to demonstrate that wearing UV-blocking contact lenses reduces the risk of developing cataracts or other eye disorders.

	Biotrue® ONEday	1-DAY ACUVUE MOIST	DAILIES AquaComfort Plus
Moisture content	78%	58%	69%
Oxygen level†	42 Dk/t	25 Dk/t	26 Dk/t
Spherical aberration control‡	✓		
UVA/UVB protection§	✓	✓	
Patient rebate	\$200	\$100	\$120

Give your patients who are new to daily disposable lenses a smart combination of performance and value.

*Lens sales between January 2017-December 2018.

†Oxygen levels for single vision spherical (SVS) lenses only.

‡In SVS and toric lenses only.

||Annual supply rebate as of 01 2019 for existing SVS wearers.

REFERENCE: 1. Data on file. Bausch & Lomb Incorporated. 3rd Party Industry Report. 2017-2018.

Biotrue and inspired by the biology of your eyes are trademarks of Bausch & Lomb Incorporated or its affiliates. All other products/brand names and/or logos are trademarks of the respective owners.
©2019 Bausch & Lomb Incorporated. BOD.0114.USA.19

BAUSCH + LOMB
See better. Live better.

IN THE NEWS

A study found either a **small to moderate benefit or no benefit at all to immediately prescribing glasses for young children with uncorrected moderate hyperopia**. Researchers evaluated one- and two-year-olds with hyperopia between +3.00D and +6.00D prescribed glasses or observed without correction. Three years of follow up revealed 11 of 53 failed in the glasses group and 18 of 53 failed in the observation group. The findings are inconclusive, and require further study, the study concluded.

Kulp MT, Holmes JM, Dean TW, et al. A randomized clinical trial of immediate versus delayed spectacles for moderate hyperopia in 1- and 2-year olds. *Ophthalmology*. January 4, 2019. [Epub ahead of print].

Researchers found **pigment dispersion syndrome (PDS) was diagnosed in 25.9% of patients undergoing evaluation for refractive surgery**. The study also found that Caucasian patients with blue eyes were most likely to have PDS. The researchers suggest this early diagnosis isn't a reason to cancel surgery but could be a reason to **follow these patients more closely** to monitor for conversion to pigmentary glaucoma.

Doane J, Rickstew J, Tuckfield J, Cauble J. Prevalence of pigment dispersion syndrome in patients seeking refractive surgery. *J Glaucoma*. January 15, 2019. [Epub ahead of print].

Researchers investigated the **validity and reliability of retinoscopy in screening for keratoconus** compared with the rotating Pentacam Scheimpflug camera. Two independent, masked retinoscopists screened patients for scissoring reflex and showed that **retinoscopy had 97.7% sensitivity, 79.9% specificity and 70.8% positive predictive and 98.4% negative predictive values**.

Al-Mahrouqi H, Oraba SB, Al-Habsi S, et al. Retinoscopy as a screening tool for keratoconus. *Cornea*. January 9, 2019. [Epub ahead of print].

Feeling Stressed? Dry Eye Could Be Next

Two studies link psychology with physiology.

By Jane Cole, Contributing Editor

Stress can put a whammy on your health, including manifesting into physical conditions such as high blood pressure, obesity and cardiovascular issues, to name a few. But two new studies have found that stress can also exacerbate dry eye.^{1,2}

A recent study found sleep quality may play an important role in the development of dry eye by influencing tear secretion and tear film stability and by indirectly aggravating anxiety and depression.¹

Investigators performed tear film break-up time (TBUT), corneal fluorescein staining and Schirmer I tests to evaluate dry eye in 106 patients. Subjects completed a Pittsburgh Sleep Quality Index, a patient health questionnaire and a general anxiety disorder scale survey.¹

The study found patients with dry eye had higher depression and anxiety scores compared with the control group. In the dry eye group, patients with poor sleep quality had more severe symptoms indicated by shorter TBUT and lower Schirmer I findings. Investigators found a significant correlation between sleep quality and mood status in patients with dry eye. Additionally, severe symptoms of dry eye were significantly associated with a higher level of anxiety in patients with dry eye.¹

A second study that evaluated

the prevalence and risk factors of dry eye among medical students in Korea found a correlation between increased psychological stress and dry eye symptoms.²

The study included 209 students at a medical school in Korea. Researchers assessed dry eye symptoms by using a nine-item questionnaire, the Ocular Surface Disease Index (OSDI) and the visual analog scale (VAS). The subjects also participated in a survey that included demographic data, potential risk factors for dry eye, personal habits and psychological stress.²

The study found the dry eye prevalence was 27.1%. Participants with dry eye had significantly higher VAS and OSDI scores compared with those without dry eye symptoms. Subjects who were female, wore contact lenses, were on the computer for long periods of time or had higher psychological stress scores had a significant association with dry eye symptoms.²

The researchers found symptomatic dry eye was prevalent among medical students, and increased psychological stress was associated with higher risk of dry eye.²

1. Wu M, Liu X, Han J, et al. Association between sleep quality, mood status, and ocular surface characteristics in patients with dry eye disease. *Cornea*. December 31, 2018. [Epub ahead of print].

2. Hyon JY, Yang HK, Han SB. Dry eye symptoms may have association with psychological stress in medical students. *Eye Contact Lens*. January 14, 2019. [Epub ahead of print].

NEWS STORIES POST EVERY WEEKDAY MORNING AT www.reviewofoptometry.com/news

OCT Sign Predicts LPI Success

Patients who present with evidence of previous or current primary angle closure (PAC) need a prompt laser peripheral iridotomy (LPI) to avoid sight-threatening outcomes. But what about patients with narrow angles and no other symptoms?

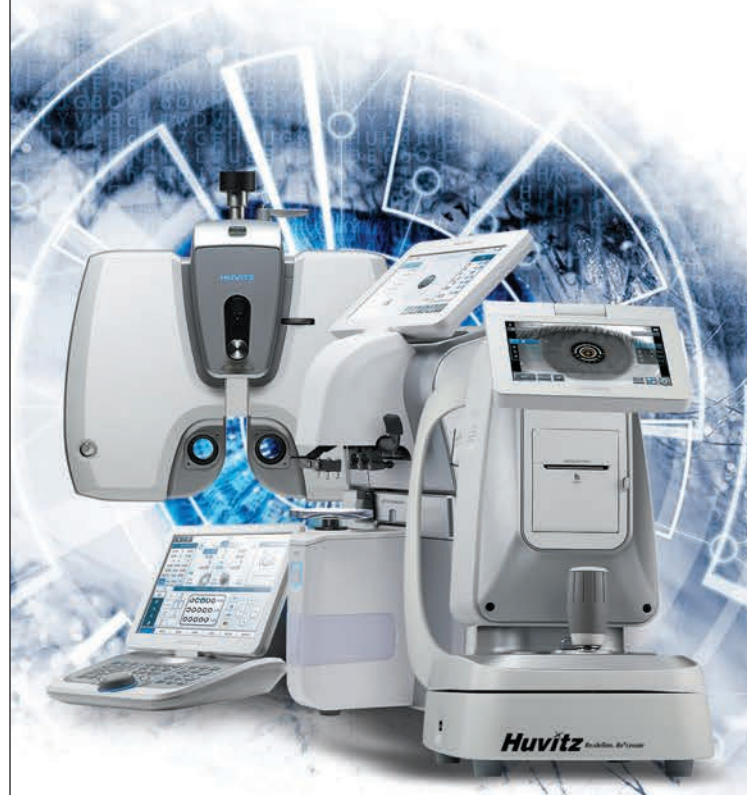A new study suggests patients with a “triple hump” sign on anterior-segment optical coherence tomography (AS-OCT) may achieve significantly lower intraocular pressure (IOP) with an LPI.

Researchers studied AS-OCT and IOP measurements in 84 eyes of 84 PAC suspects before LPI. They defined the positive triple hump group as those with “the characteristic configuration formed by the angulations between the crystalline lens’s central anterior surface and both sides of the iris pigment epithelium.” Two glaucoma specialists, masked to any other clinical data, separated AS-OCT images into positive and a negative triple hump groups.

The one-month post-LPI assessment revealed the positive triple hump group had significantly decreased IOP, with an average of 1.19mm Hg, compared with the negative triple hump group, which had no statistically significant change in IOP. For the positive triple hump group, “significant IOP reduction after one month indicated that the pressure gradient of the anterior and posterior chambers was eliminated, and pupil block resolved, by LPI,” according to the study. The negative triple hump group, however, had no change in IOP post-op, suggesting pupil block didn’t play a role in the angle closure and “a pushing mechanism might be the key contributing factor” that may warrant lens extraction.

The triple hump sign was “a useful screening tool for discriminating ‘LPI responder’ cases from ‘LPI non-responder’ cases in PAC suspect eyes,” the researchers conclude. They further speculate the new AS-OCT sign may be a beneficial screening method for discriminating pupil block and phacomorphic angle-closure in PAC suspect eyes.

KI Na, A Ha, SU Baek, et al. Predicting the therapeutic efficacy of laser peripheral iridotomy for individuals with asymptomatic narrow angle: the triple hump sign. J Glaucoma. 2019;28(2):125-30.



Wireless Diagnostic Line

Lensmeter | Digital Refractor | Auto Ref/Keratometer

Increase total practice efficiency with enhanced features such as **wireless communication** and **Hartmann sensor wavefront analysis technology**. The 9000 series is **fully compatible with all EMR systems** and equipped with a **full three year warranty**.

HRK-9000A AUTO REF/KERATOMETER

Enhanced with top-of-the-line features, the HRK-9000A offers **meibomian gland analysis** and **tear film break up time measurement**. Eliminating the need to use a slit lamp, the HRK-9000A is also **anterior segment capable**.

HDR-9000 DIGITAL REFRACTOR

Equipped with a **21 point exam package**, the HDR-9000 eliminates difficulty by displaying results for easy reading for examiners and patients. Features include **fast and silent lens loading**, as well as **enhanced functions in program modules, such as chart customization**.

HLM-9000 AUTO LENSMEETER

One of a kind, the HLM-9000 measures the harmful effects of LED screens by utilizing the **blue light filtration measurement** function. Features also include **auto recognition** and **multi-focal lens measurement**.

SECO2019
WHERE SIGHT MEETS VISION™

**BOOTH
941**



1.800.COUBURN1 | WWW.COUBURNTHECNOLOGIES.COM

Multiple Births Increases OAG Risk

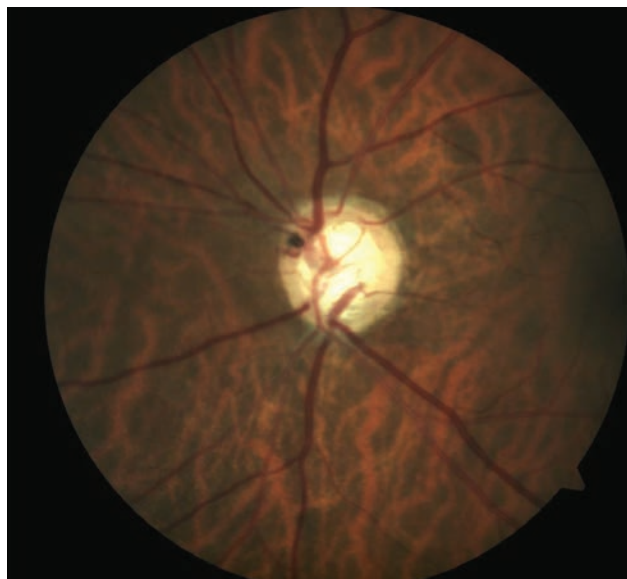
Researchers in Korea recently discovered associations between having kids and an increased risk of open-angle glaucoma (OAG), suggesting changes during pregnancy and delivery affect the development of the disease.

The study, published in the *Journal of Glaucoma*, included 1,798 postmenopausal women from the Korean National Health and Nutrition Examination Survey from 2010 to 2011. After performing a comprehensive eye exam and gathering information

on demographics, comorbidities and health-related behaviors, researchers found the prevalence of OAG was 6.42%. They also found patients who had three or more deliveries were at increased risk of OAG compared with those who had two deliveries; however, two deliveries was not associated with a higher risk than one.

“This might be because the optic disc can overcome small insults below a threshold, but the accumulation of multiple stressors could create an unfavorable environment around the optic nerve that crosses a certain threshold, initiating OAG,” according to the study.

The researchers believe hormonal changes and the effects of the birth process are both involved in the increased risk. Blood loss during



Having more than two kids could put a strain on the mother's ocular system, possibly increasing her risk of open-angle glaucoma.

delivery causes temporary systemic hypotension and decreased ocular perfusion, thus increasing the risk for glaucoma development or progression. In addition, increased oxytocin levels during labor can induce capillary constriction and decreases aqueous outflow, while stress during labor could induce the release of large amounts of epinephrine and norepinephrine, also increasing IOP.

The study also found an independent association with younger age at first childbirth and a higher risk of OAG. Patients who were between the ages of 16 and 20, as well as 21 and 23, were at a higher risk of OAG compared with those ages 24 to 26 at first delivery.

“Considering the fluctuations of hormone levels and physiology

changes during pregnancy and after delivery, younger age at first delivery seems to be more stressful physiologically and neurophysiologically, which could affect the development of OAG,” according to the study.

While the study highlights the role pregnancy and delivery may play in the pathogenesis of glaucoma, more work is necessary.

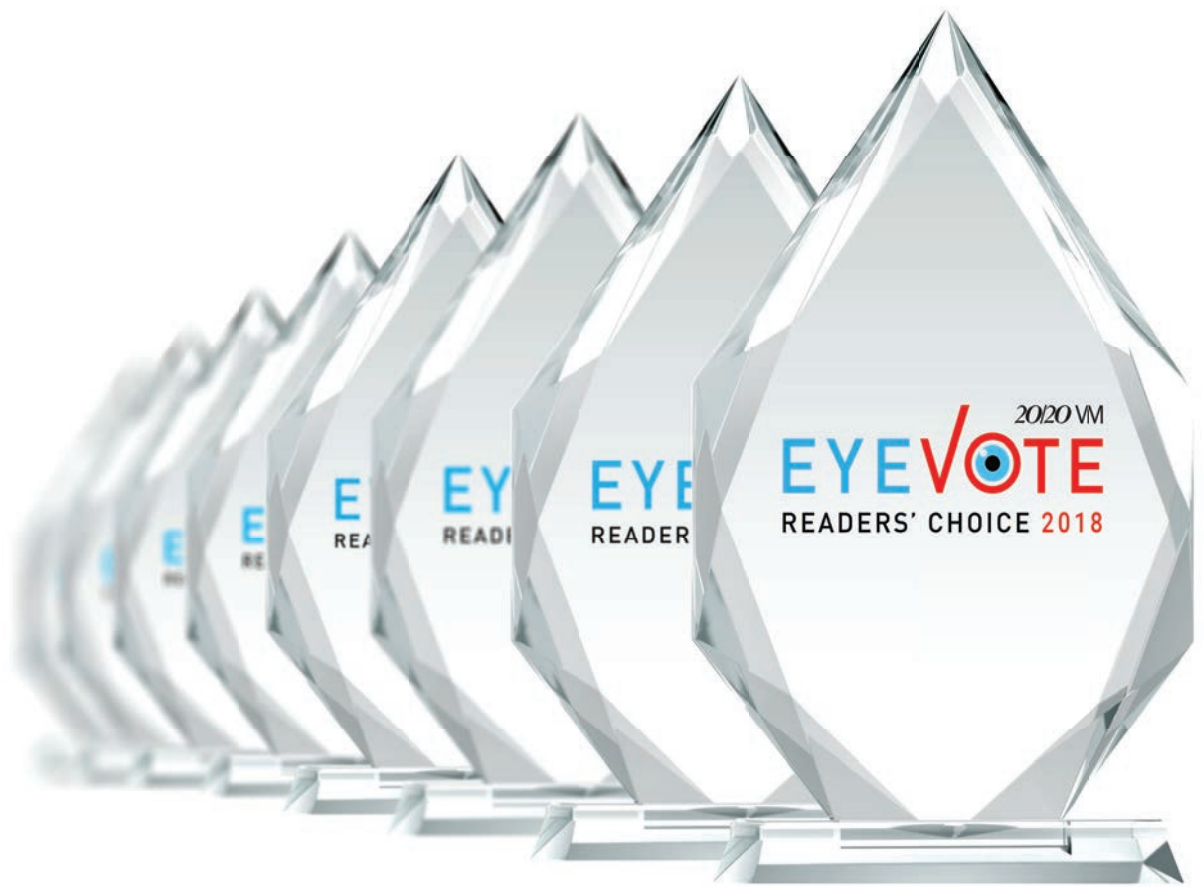“The link between parturition and glaucoma in current literature is inconclusive, and additional longitudinal studies with a more diverse population are needed to better support

the findings in this study,” says Brian D. Fisher, OD, student externship coordinator at the Villages VA Outpatient Clinic. “Despite several limitations, the results agreed with the Blue Mountains Eye Study that multiple pregnancies (>2) increases risk for glaucoma.”

“As we await further support, we can implement these findings in evaluating our glaucoma patients,” he adds. “The more risk factors we can identify, the better we can diagnose and manage our patients. Moreover, by employing these findings into clinical practice we can better educate our female patients of childbearing age and those with other established risk factors.”

JY Lee, JM Kim, SH Kim, et al. Associations among pregnancy, parturition, and open-angle glaucoma: Korea National Health and Nutrition Examination Survey 2010 to 2011. *J Glaucoma*. 2019;28(1):14-19.

Photo: Brian Fisher, OD



Still on top.

Eyefinity® is the most-awarded optical software company eight years in a row.

Leukocytes May Cause Scleral Lens Fogging

For scleral contact lens wearers, midday fogging is a frequent nuisance. To get to the bottom of this conundrum, researchers from the University of Alabama at Birmingham looked into the relation between midday fogging, ocular surface leukocytes and lens fitting characteristics.

“One of the most common modern complications we see in scleral lens wear is midday fogging. Different estimates suggest there is somewhere between 30% and 50% of scleral wearers who have midday fogging, and it’s really inconvenient,” says study investigator Jason J. Nichols, OD, MPH, PhD, associate vice president research and professor at the School of Optometry at the University of Alabama at Birmingham.

Adding to the inconvenience factor, these patients have to remove their lenses midway through the day, which means they must have solutions on hand and the ability to clean the lenses and put them back in, he adds.

Midday fogging results from particulate matter that is trapped between the ocular surface and contact lens in the post-lens tear film. As such, there’s been a great deal of speculation about the post-lens tear film and scleral lenses, he says.

With a scleral lens in place, “you have a post-lens tear film behind it, and there’s not much tear exchange,” Dr. Nichols says. “In fact, there is very little, if any, tear exchange from behind the scleral contact lens, so the tears are trapped. The question is, ‘What is it?’ People have speculated that perhaps it’s a lipid or protein or mucin.”

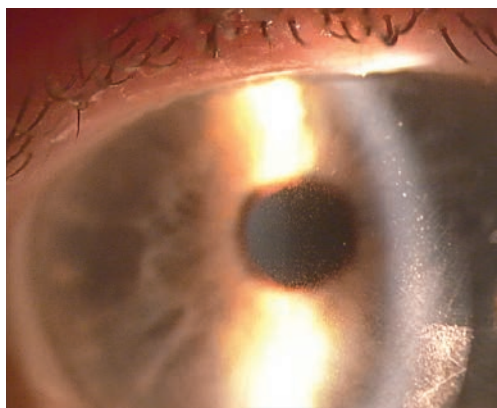


Photo: Jan P.O. Bergmansson, OD

This scleral lens wearer, a competitive tennis player, had daily midday foggings. Particulate matter is seen in direct light and over the pupil from the iris reflectant light.

The study enrolled 39 eyes including 19 fulltime scleral lens wearers, of which 46% had midday fogging issues. After at least four hours of wear, the lenses were rinsed with phosphate-buffered saline, and eyes were treated with 5mL of saline per eye. Leukocytes were counted and isolated from the wash solutions and assessed with flow cytometry. Investigators then stained the samples from the post-lens tear fluid with fluorescently labeled antibodies to detect leukocyte distributions.

Researchers found a great deal of leukocytes behind the post-lens tear film bowl of the scleral lens wearers with fogging. They also reported scleral lens corneal clearance was $246 \pm 61\mu\text{m}$ for nonfoggers compared with $308 \pm 98\mu\text{m}$ for those who had fogging. On average, the number of leukocytes collected from the scleral contact lens bowl was greater than the number of leukocytes recovered from the eyewash. Researchers noted the scleral lens corneal clearance was associated with the

presence of fogging.

“If you think about it, leukocytes are white blood cells, and the fogging is a white film that happens in the post-lens tear film. So there seems to be a connection,” explains Dr. Nichols.

As the lens vaults higher and higher, researchers saw more neutrophils and more leukocytes. “So basically, it shows if you increase the vault, you get more hypoxia and more white blood cells, and this is possibly why fogging

occurs,” he says.

While Dr. Nichols believes the study results show leukocytes could be a contributor to midday fogging in scleral lens wearers, he says there could be other factors as well.

It seems that hypoxia may be the driver for the release of the leukocytes into the tear film, investigators noted. If you keep the vault to a minimum, $200\mu\text{m}$ or less, you’ll likely get less leukocytes and less fogging, Dr. Nichols says.

Additional factors to consider would be ways to improve tear exchange and peripheral curves or by using more oxygen permeable material—factors that weren’t part of the study but still relate to hypoxia, he adds.

Dr. Nichols and his team may continue the investigation by using different materials and fits to see their impacts on white blood cells and midday fogging. ■

Postnikoff CK, Pucker AD, Laurent J, et al. Identification of leukocytes associated with midday fogging in the post-lens tear film of scleral contact lens wearers. *Invest Ophthalmol Vis Sci.* 2019;60(1):226-33.

INTRODUCING

Next Generation Hypochlorous Acid

Essential Daily Dry Eye Management

• HyClear™ is Pure.

With the antimicrobial activity* of pure hypochlorous acid .01%, HyClear™ is a non-cytotoxic, non-irritating solution.

• HyClear™ is Affordable.

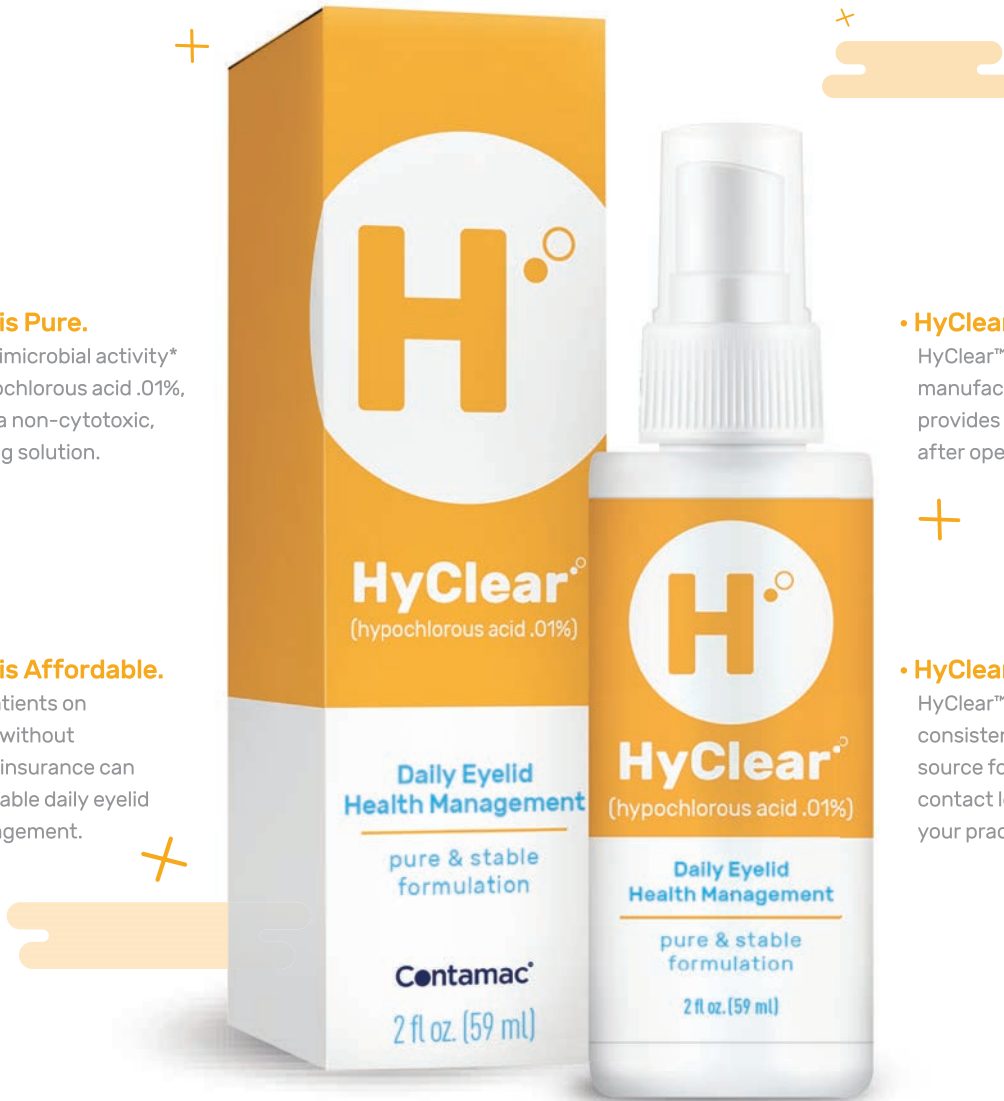Now your patients on Medicare or without commercial insurance can enjoy affordable daily eyelid health management.

• HyClear™ is Stable.

HyClear™ uses a new manufacturing process that provides up to 18 months after opening.

• HyClear™ is Profitable.

HyClear™ will provide a consistent, reliable revenue source for the dry eye and contact lens segments of your practice.



Contamac® is pleased to introduce HyClear™, the next generation Hypochlorous Acid for daily eyelid health management.

HyClear[®]

Call 833-266-8262 or visit hyclear-wholesale.com for information on how HyClear™ can improve your dry eye practice.

Contamac[®]

*in solution

Contents

Review of Optometry February 15, 2019



INNOVATION IN EYE CARE

35 Can We Lower IOP with Glasses?

Researchers are finding shocking new ways to employ electro-stimulation. BY TAYLOR LUKASIK, MD, AND IQBAL IKE K.

AHMED, MD

39 A Light in the DARC: Seeing Glaucoma Before it Strikes

This cutting-edge technology could give us a window into the disease earlier in its course—shifting treatment ahead and possibly preventing vision loss. BY MELANIE T. ALMONTE, RN, BSN, MSC, AND M. FRANCESCA

CORDEIRO, PHD, MRCP, FRCOPHTH

42 Bioengineering the Retinal Pigment Epithelium

New stem cell-based therapies are paving the way for age-related macular degeneration treatment. BY AMIR H. KASHANI, MD, PHD, DIANA HONG, BS, AND MARK S. HUMAYUN, MD, PHD

46 Iontophoresis: Wave of the Future?

A low-level electrical current may turbo-charge topical drug delivery to the eye. BY BARBARA WIROSTKO,

MD, AND MICHAEL RAIZMAN, MD

48 While You Were Sleeping

A new phototherapeutic contact lens, worn overnight, could effectively address diabetic retinopathy progression.

BY MARK DE LEON, ASSOCIATE EDITOR

ALSO INSIDE

How to Succeed in Plaquenil Screenings

The spectrum of OCT findings associated with the medication can make incorporating the 2016 guidelines harder than you think. Here's help. BY MARLON DEMERITT, OD, SHERROL REYNOLDS, OD, DIANA SHECHTMAN, OD,

AND JENNIFER DAVIDSON, OD **PAGE 56**

The Neurologic Exam, Step-by-step

This case-based review will help you assess beyond each patient's visual presentation and uncover key clinical signs of neurologic dysfunction. BY ASHLEY KAY MAGLIONE, OD, AND KELLY SEIDLER, OD **PAGE 64**

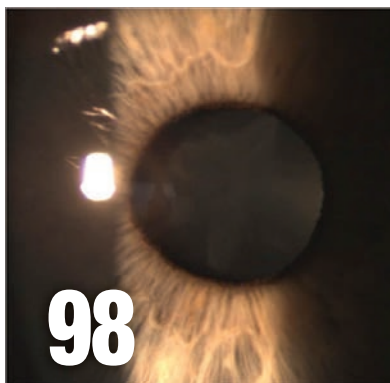
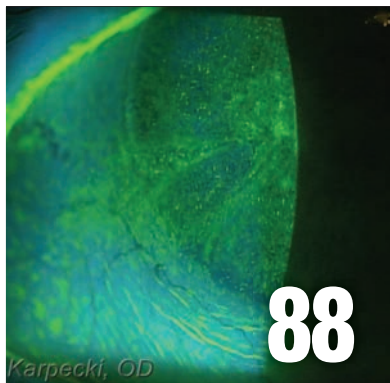
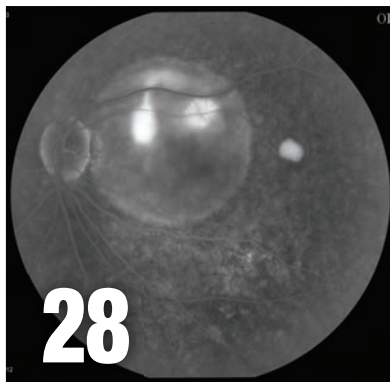

Earn 2 CE Credits: Take a Clinical Approach to Anterior Uveitis

The ultimate goal is to narrow down symptoms to effective treatment. BY DOMINICK L. OPITZ, OD **PAGE 72**

Departments

Review of Optometry February 15, 2019

- 4 News Review**
- 16 Outlook**
'Further Research is Needed'
JACK PERSICO
- 18 Through My Eyes**
Let's Get Medical
PAUL M. KARPECKI, OD
- 20 Chairside**
Summon Some Courage
MONTGOMERY VICKERS, OD
- 22 Clinical Quandaries**
Making the Grade
PAUL C. AJAMIAN, OD
- 24 Coding Connection**
The Telephone is Ringing...
JOHN RUMPAKIS, OD, MBA,
CLINICAL CODING EDITOR
- 26 Focus on Refraction**
Beyond the Phoropter
MARC B. TAUB, OD, MS,
AND PAUL HARRIS, OD
- 28 Retina Dilemmas**
Serous Problem Business
JAY HAYNIE, OD,
DIANA SCHECHTMAN, OD,
AND RASHID TAHER, MD
- 83 Cornea + Contact Lens Q&A**
Making the Leap
JOSEPH P. SHOWLIN, OD
- 84 Glaucoma Grand Rounds**
If Only They Had Asked
JAMES L. FANELLI, OD
- 88 Ocular Surface Review**
Grow Some Nerve
PAUL M. KARPECKI, OD
- 90 Retina Quiz**
What's in Your Head?
SHREYA JAYASIMHA, OD,
AND MARK T. DUNBAR, OD
- 94 Classifieds**
- 97 Surgical Minute**
Cutting Out Calcifications
KYNNDYL GIANNONATTI, BA, AND
LEONID SKORIN, JR., DO, OD, MS
- 98 Advertisers Index**
- 98 Diagnostic Quiz**
Headbanger's Flaw
ANDREW S. GURWOOD, OD



REVIEW[®] OF OPTOMETRY

BUSINESS OFFICES
11 CAMPUS BLVD., SUITE 100
NEWTOWN SQUARE, PA 19073

CEO, INFORMATION SERVICES GROUP
MARC FERRARA
(212) 274-7062 • MFERRARA@JOBSON.COM

PUBLISHER
JAMES HENNE
(610) 492-1017 • JHENNE@JOBSON.COM

REGIONAL SALES MANAGER
MICHELE BARRETT
(610) 492-1014 • MBARRETT@JOBSON.COM

REGIONAL SALES MANAGER
MICHAEL HOSTER
(610) 492-1028 • MHOSTER@JOBSON.COM

VICE PRESIDENT, OPERATIONS
CASEY FOSTER
(610) 492-1007 • CFOSTER@JOBSON.COM

VICE PRESIDENT, CLINICAL CONTENT
PAUL M. KARPECKI, OD, FFAO
PKARPECKI@JOBSON.COM

PRODUCTION MANAGER
SCOTT TOBIN
(610) 492-1011 • STOBIN@JOBSON.COM

SENIOR CIRCULATION MANAGER
HAMILTON MAHER
(212) 219-7870 • HMAHER@JHIHEALTH.COM

CLASSIFIED ADVERTISING
(888) 498-1460

SUBSCRIPTIONS
\$56 A YEAR, \$88 (US) IN CANADA,
\$209 (US) IN ALL OTHER COUNTRIES.

SUBSCRIPTION INQUIRIES
(877) 529-1746 (US ONLY)
OUTSIDE US CALL: (845) 267-3065

CIRCULATION
PO Box 81
CONGERS, NY 10920
TEL: (TOLL FREE): (877) 529-1746
OUTSIDE US: (845) 267-3065



CEO, INFORMATION SERVICES GROUP
MARC FERRARA

SENIOR VICE PRESIDENT, OPERATIONS
JEFF LEVITZ

VICE PRESIDENT, HUMAN RESOURCES
TAMMY GARCIA

VICE PRESIDENT, CREATIVE SERVICES & PRODUCTION
MONICA TETTAMANZI

CORPORATE PRODUCTION DIRECTOR
JOHN ANTHONY CAGGIANO

VICE PRESIDENT, CIRCULATION
EMELDA BAREA



it's time for patients to love their eyes

(as much as they love their screens)

The face of dry eye is changing. That's why it's super important to chat with your patients about things that can trigger their dry eye symptoms—like staring at laptop, phone, and TV screens all day.¹

Shire is here to help. We want to make sure you and your patients are feeling the eyelove. And what better way to show it than by encouraging eye health for everyone? Together, we can ensure that eyes are healthy and loved, now and in the future. That's eyelove.

Reference: 1. TFOS DEWS II Research Subcommittee. Report of the Research Subcommittee of the Tear Film & Ocular Surface Society Dry Eye WorkShop II (2017). *Ocul Surf.* 2017;15(3):269-649.

Start with some eyelove.

Join us at myeyelove-ecp.com



©2018 Shire US Inc., Lexington, MA 02421. 1-800-828-2088. All rights reserved. SHIRE and the Shire Logo are trademarks or registered trademarks of Shire Pharmaceutical Holdings Ireland Limited or its affiliates. The EYELOVE logo and marks designated ® and ™ are owned by Shire or an affiliated company. S43693 12/18

Earn up to
18-28 CE
Credits*

NEW TECHNOLOGIES
& TREATMENTS IN
2019 EYE CARE
RGVCE
REVIEW'S COMMITMENT TO
CONTINUING EDUCATION



Join us for our
2019 MEETINGS



MARCH 7-10, 2019 - ORLANDO, FL

Disney Yacht & Beach Club

Program Chair: Paul M. Karpecki, OD, FAAO

REGISTER ONLINE: www.reviewsce.com/orlando2019



APRIL 11-14, 2019 - SAN DIEGO, CA**

Manchester Grand Hyatt

Program Chair: Paul M. Karpecki, OD, FAAO

REGISTER ONLINE: www.reviewsce.com/sandiego2019



May 17-19, 2019 - NASHVILLE, TN

Gaylord Opryland

Program Chair: Paul M. Karpecki, OD, FAAO

REGISTER ONLINE: www.reviewsce.com/nashville2019



NOVEMBER 1-3, 2019 - BALTIMORE, MD

Renaissance Baltimore Harborplace

Program Chair: Paul M. Karpecki, OD, FAAO

REGISTER ONLINE: www.reviewsce.com/baltimore2019

Visit our website for the latest information: www.reviewsce.com/events
e-mail: reviewmeetings@jhihealth.com or call: 866-658-1772

Administered by
RGVCE
REVIEW'S COMMITMENT TO
CONTINUING EDUCATION



*Approval pending



Pennsylvania College of Optometry



**16th Annual Education Symposium
Joint Meeting with NT&T in Eye Care

RGVCE partners with Salus University for those ODs who are licensed in states that require university credit.
See www.reviewsce.com/events for any meeting schedule changes or updates.

CONTRIBUTING EDITORS

PAUL C. AJAMIAN, OD, ATLANTA
AARON BRONNER, OD, KENNEWICK, WASH.
MILE BRUJIC, OD, BOWLING GREEN, OHIO
DEREK N. CUNNINGHAM, OD, AUSTIN, TEXAS
MARK T. DUNBAR, OD, MIAMI
ARTHUR B. EPSTEIN, OD, PHOENIX
JAMES L. FANELLI, OD, WILMINGTON, NC
GARY S. GERBER, OD, HAWTHORNE, NJ
ANDREW S. GURWOOD, OD, PHILADELPHIA
ALAN G. KABAT, OD, MEMPHIS, TENN.
DAVID KADING, OD, SEATTLE
PAUL M. KARPECKI, OD, LEXINGTON, KY.
JEROME A. LEGERTON, OD, MBA, SAN DIEGO
JASON R. MILLER, OD, MBA, POWELL, OHIO
CHERYL G. MURPHY, OD, BABYLON, NY
CARLO J. PELINO, OD, JENKINTOWN, PA.
JOSEPH PIZZIMENTI, OD, SAN ANTONIO, TEXAS.
JOHN RUMPAKIS, OD, MBA, PORTLAND, ORE.
DIANA L. SHECHTMAN, OD, FORT LAUDERDALE, FLA.
JEROME SHERMAN, OD, NEW YORK
JOSEPH P. SHOVLIN, OD, SCRANTON, PA.
JOSEPH W. SOWKA, OD, FORT LAUDERDALE, FLA.
MONTGOMERY VICKERS, OD, LEWISVILLE, TEXAS.
WALTER O. WHITLEY, OD, MBA, VIRGINIA BEACH, VA.

EDITORIAL REVIEW BOARD

JEFFREY R. ANSHEL, OD, ENCINITAS, CALIF.
JILL AUTRY, OD, RPH, HOUSTON
SHERRY J. BASS, OD, NEW YORK
EDWARD S. BENNETT, OD, ST. LOUIS
MARC R. BLOOMENSTEIN, OD, SCOTTSDALE, ARIZ.
CHRIS J. CAKANAC, OD, MURRYSVILLE, PA.
JERRY CAVALLERANO, OD, PHD, BOSTON
WALTER L. CHOATE, OD, MADISON, TENN.
BRIAN CHOU, OD, SAN DIEGO
A. PAUL CHOUS, MA, OD, TACOMA, WASH.
ROBERT M. COLE, III, OD, BRIDGETON, NJ
GLENN S. CORBIN, OD, WYOMISSING, PA.
ANTHONY S. DIECIDUE, OD, STROUDSBURG, PA.
S. BARRY EIDEN, OD, DEERFIELD, ILL.
STEVEN FERRUCCI, OD, SEPULVEDA, CALIF.
MURRAY FINGERET, OD, HEWLETT, NY
IAN BEN GADDIE, OD, LOUISVILLE, KY.
PAUL HARRIS, OD, MEMPHIS, TN
MILTON HOM, OD, AZUSA, CALIF.
BLAIR B. LONSBERRY, MS, OD, MED, PORTLAND, ORE.
THOMAS L. LEWIS, OD, PHD, PHILADELPHIA
DOMINICK MAINO, OD, MED, CHICAGO
KELLY A. MALLOY, OD, PHILADELPHIA
RICHARD B. MANGAN, OD, LEXINGTON, KY.
RON MELTON, OD, CHARLOTTE, NC
PAMELA J. MILLER, OD, JD, HIGHLAND, CALIF.
BRUCE MUCHNICK, OD, COATESVILLE, PA.
MARC MYERS, OD, COATESVILLE, PA.
WILLIAM B. POTTER, OD, FREEHOLD, NJ
CHRISTOPHER J. QUINN, OD, ISELIN, NJ
MICHAEL C. RADOIU, OD, STAUNTON, VA.
MOHAMMAD RAFIEETARY, OD, MEMPHIS, TN
JOHN L. SCHACHET, OD, ENGLEWOOD, COLO.
JACK SCHAEFFER, OD, BIRMINGHAM, ALA.
LEO P. SEMES, OD, BIRMINGHAM, ALA.
LEONID SKORIN, JR., OD, DO, ROCHESTER, MINN.
JOSEPH W. SOWKA, OD, FORT LAUDERDALE, FLA.
BRAD M. SUTTON, OD, INDIANAPOLIS
LORETTA B. SZCZOTKA, OD, PHD, CLEVELAND
MARC TAUB, OD, MEMPHIS, TN
TAMMY P. THAN, MS, OD, BIRMINGHAM, ALA.
RANDALL THOMAS, OD, CONCORD, NC
SARA WEIDMAYER, OD, ANN ARBOR, MI
KATHY C. WILLIAMS, OD, SEATTLE
KAREN YEUNG, OD, LOS ANGELES

World Class Continuing Education + Bucket List Travel



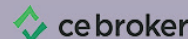
International Eye

Your Host for the Best in Destination CE

Join Us for Our 2019-2020 International CE Meetings

Registration Open at www.internationaleye.net

15 Hours Credit at each event - COPE Approval Pending. Accredited by University of Houston School of Optometry.



Florence, Italy
October 19-25, 2019

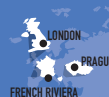

Edinburgh, Scotland
June 13-19, 2020



Paris, France
October 18-25, 2020

EXPLORE OUR 2020/2021 DESTINATIONS



CARTAGENA

Sign up for our mailing list online to get all the latest news about our destinations, speakers and agendas.



internationaleye.net



PRINTED IN USA

FOUNDING EDITOR, FREDERICK BOGER
1891-1913

EDITORIAL OFFICES
11 CAMPUS BLVD., SUITE 100
NEWTOWN SQUARE, PA 19073

SUBSCRIPTION INQUIRIES
1-877-529-1746

CONTINUING EDUCATION INQUIRIES
1-800-825-4696

EDITOR-IN-CHIEF • JACK PERSICO
(610) 492-1006 • JPERSICO@JOBSON.COM

MANAGING EDITOR • REBECCA HEPP
(610) 492-1005 • RHEPP@JOBSON.COM

SENIOR EDITOR • BILL KEDEVIAN
(610) 492-1003 • BKEDEVIAN@JOBSON.COM

ASSOCIATE EDITOR • CATHERINE MANTHORN
(610) 492-1043 • CMANTHORN@JOBSON.COM

ASSOCIATE EDITOR • MARK DE LEON
(610) 492-1021 • MDELEON@JOBSON.COM

SPECIAL PROJECTS MANAGER • JILL HOFFMAN
(610) 492-1037 • JHOFFMAN@JOBSON.COM

ART DIRECTOR • JARED ARAUJO
(610) 492-1032 • JARAJO@JOBSON.COM

DIRECTOR OF CE ADMINISTRATION • REGINA COMBS
(212) 274-7160 • RCOMBS@JOBSON.COM

EDITORIAL BOARD

CHIEF CLINICAL EDITOR • PAUL M. KARPECKI, OD

ASSOCIATE CLINICAL EDITORS • JOSEPH P. SHOVLIN, OD;
ALAN G. KABAT, OD; CHRISTINE W. SINDT, OD

DIRECTOR OPTOMETRIC PROGRAMS • ARTHUR EPSTEIN, OD

CLINICAL & EDUCATION CONFERENCE ADVISOR
PAUL M. KARPECKI, OD

CASE REPORTS COORDINATOR • ANDREW S. GURWOOD, OD

CLINICAL CODING EDITOR • JOHN RUMPAKIS, OD, MBA

CONSULTING EDITOR • FRANK FONTANA, OD

COLUMNISTS

CHAIRSIDE • MONTGOMERY VICKERS, OD

CLINICAL QUANDARIES • PAUL C. AJAMIAN, OD

CODING CONNECTION • JOHN RUMPAKIS, OD

CORNEA & CONTACT LENS Q+A • JOSEPH P. SHOVLIN, OD

DIAGNOSTIC QUIZ • ANDREW S. GURWOOD, OD

THE ESSENTIALS • BISANT A. LABIB, OD

FOCUS ON REFRACTION • MARC TAUB, OD;
PAUL HARRIS, OD

GLAUCOMA GRAND ROUNDS • JAMES L. FANELLI, OD

NEURO CLINIC • MICHAEL TROTTINI, OD;
MICHAEL DELGIODICE, OD

OCULAR SURFACE REVIEW • PAUL M. KARPECKI, OD

RETINA DILEMMAS • DIANA L. SHECHTMAN, OD;

JAY M. HAYNIE, OD

RETINA QUIZ • MARK T. DUNBAR, OD

REVIEW OF SYSTEMS • CARLO J. PELINO, OD;
JOSEPH J. PIZZIMENTI, OD

SURGICAL MINUTE • DEREK N. CUNNINGHAM, OD;
WALTER O. WHITLEY, OD, MBA

THERAPEUTIC REVIEW • JOSEPH W. SOWKA, OD;
ALAN G. KABAT, OD

THROUGH MY EYES • PAUL M. KARPECKI, OD

URGENT CARE • RICHARD B. MANGAN, OD

JOBSON MEDICAL INFORMATION LLC



Outlook

By Jack Persico, Editor-in-Chief



‘Further Research is Needed’

It’s both a mantra and a cliché—and also an important reminder to practicing clinicians.

On our website, we’ve been publishing news stories each weekday for nearly a year—check ‘em out if you hadn’t noticed! Nearly all are summaries of journal articles we feel have clinical relevance. With so much research news churning through our word processors, one phrase shows up again and again without fail: the dreaded ‘further research is needed’ to close a paper.

Well, *of course it is*. That’s pretty much the mission statement for all of science.

As an editor, that line always irks me. It feels trite to keep restating an obvious, foundational principle. Authors of journal articles shouldn’t rely on such an empty phrase; rather, they should articulate the scope of specific future work they’d like to see. Who better to say what deserves to come next than the people responsible for the original findings?

Still, maybe that cliché has some value in reminding everyone that no question is ever truly answered with absolute certainty, at least not in medicine. Although an interesting new book, *Solving Chemistry*, argues that that field has in fact wrapped up all its big issues, medicine is far more messy, intellectually speaking. Everything you do in the clinic can and should be challenged periodically, because its foundations are surprisingly shaky.

“Most physicians are largely pre-Newtonian” in their understanding of the processes that govern the body, retina specialist Mark Humayun, MD, PhD, pointed out in a

discussion we had while working on this issue (his work is featured in two of the five projects profiled in this month’s cover series).

Dr. Humayun was explaining the challenges doctors face when collaborating with engineers, whose discipline has been following clearly predictable rules ever since Newton gave them a systematic conception of the natural world. Medical researchers don’t always have fully formed, mechanistic laws to rely on. As a result, they can’t deliver to engineers the precise specifications of what to build. Doctors have a much more provisional and tentative understanding of their field, and that manifests in what people call the so-called ‘art’ of medicine.

That interplay of instinct and precision is showcased in this month’s cover focus on innovation in eye care. Breaking from our usual format, we’ve asked several research teams to share with us the work they’re engaged in now to build new tools for tomorrow.

Why care about research? It’s a fair question to ask. In your busy day, you have to prioritize the here and now. But staying attuned to the near future helps you do better in the present. Seeing all the questions being asked allows you to recognize the shortcomings and just plain guesswork you sometimes have to get by with right now. Hopefully, that reminds you to approach patient care decisions with a dose of skepticism. Following research also gives you the liberty to contemplate a better future, for you and your patients, and watch it unfold. ■

COMING 2019

Open your eyes to
what's on the
horizon in dry eye.

Sign up for updates at [TearCare.com](https://www.tearcare.com)

TearCare is indicated for the application of localized heat when the current medical community recommends the application of a warm compress to the eyelids. Such applications would include Meibomian Gland Dysfunction (MGD), Dry Eye, or Blepharitis.

©2018 Sight Sciences. All rights reserved. 06221.A



TearCare

15



Let's Get Medical

This is the year to embrace medical optometry or even consider a specialty.

By Paul M. Karpecki, OD, Chief Clinical Editor

Despite the growing need for medical eye care services, more than 70% of the average optometrist's income still comes from goods and services related to glasses and contact lenses.¹ But challenges from online vendors and the advent of virtual or automated vision screenings will make it increasingly difficult to succeed at this model.

Meanwhile, the demand for medical eye care services is expanding at a rate nearly three times that of comprehensive eye exams. Someone must care for these patients and, in many cases, this responsibility is ours.

Assess the Need

If you look at the specific areas where medical eye care services are growing, several specialties stand out:

- **Diabetes.** Diabetic retinopathy (DR) is a leading cause of vision loss.² According to the American Diabetes Association, the annual economic burden of diabetes is about \$245 billion.³ Further estimates speculate that the total cost of diabetes attributable to DR ranges anywhere from 10% to upwards of 42%.⁴ Optometrists can play a leading role in early detection and appropriate management, since many adults living with diabetes remain unaware of their condition until their DR has progressed to a stage at which treatment is difficult. For example, of an estimated 285 million people worldwide with diabetes, more than a third have signs of DR, and a third of these are afflicted with vision-threatening DR.⁵

- **Cataract.** Rising patient expectations and a growing number of surgical options have expanded the cataract pre-op evaluation. Patient selection is a primary component in achieving satisfactory visual outcomes after cataract surgery, and the results depend heavily on the quality of the ocular surface.

Ocular surface disease increases the risk of surgical complications, affects intraocular lens (IOL) measurements and impacts comfort and quality of vision. In fact, research shows that patients who have osmolarity scores within normal limits are within a half diopter of intent, whereas 17% of those with hyperosmolarity would have missed their IOL calculation by more than a diopter.⁶ For post-op care, a new formulation of loteprednol 0.38%

(Bausch + Lomb) is likely to be available soon. This drug uses key polymers and a submicron particle size to allow for higher potency and penetration with a lower concentration of drug.

- **Glaucoma.** An estimated 61 million people had glaucoma as of 2010, and the number may rise to 80 million by 2020.⁷ Fortunately, advanced technologies and new therapeutics can help with early detection and management. We now have several new drugs as well as modified or preservative-free versions of early-generation drops. Some of these affect outflow in novel ways and show significant promise for improving patient care. In addition, new surgical devices such as MIGS have improved intraocular pressure control and are a good opportunity at the time of cataract surgery.

- **AMD.** Clinical AMD is more prevalent than glaucoma and DR combined—and by the year 2050, it is estimated to double. Unfortunately, both optometrists and ophthalmologists are missing AMD about 25% of the time.⁸ It's no wonder that as many as 78% of patients are first diagnosed with AMD after having already suffered irreversible vision loss in one eye, and nearly half of them are first diagnosed with an acuity of 20/200 or worse.⁹ One of the best ways to improve these statistics is to start testing dark adaptation time. This functional test allows you to detect early AMD up to three years before it becomes clinically evident and it takes the guesswork out of AMD diagnostics so you can move forward with a plan to slow or prevent progression.

- **Dry eye.** In the United States, managing dry eye costs healthcare \$55.4 billion annually—and the demographic most likely to suffer is growing.¹⁰ A few decades ago, there wasn't much we could do to address dry eye in a meaningful way. But our options are expanding. Several years ago, a better understanding of the inflammatory process led to the introduction of two modern mainstays of dry eye therapy, cyclosporine and lifitegrast. Today, these advanced pharmaceuticals are being joined by more treatments. Cequa (cyclosporine A 0.09%, Sun Pharmaceuticals) is a preservative-free nanomicellar formulation of cyclosporine A in a stronger formulation than has been previously available. Klarity-C (cyclosporine 0.1%/

chondroitin sulfate ophthalmic emulsion) is another compounded dry eye drop that's available through Imprimis. KPI-121 (loteprednol etabonate ophthalmic suspension 0.25%, Kala Pharmaceuticals) uses a mucus-penetrating particle technology to increase the penetration of a familiar steroid. P-321 (Shire), an epithelial sodium channel inhibitor for the treatment of tear volume deficiency and the promotion of ocular surface healing, is also under investigation. Beyond pharmaceuticals, we also now have access to other efficacious dry eye and meibomian gland dysfunction treatments, including intense pulsed light, neurostimulation and thermal pulsation.

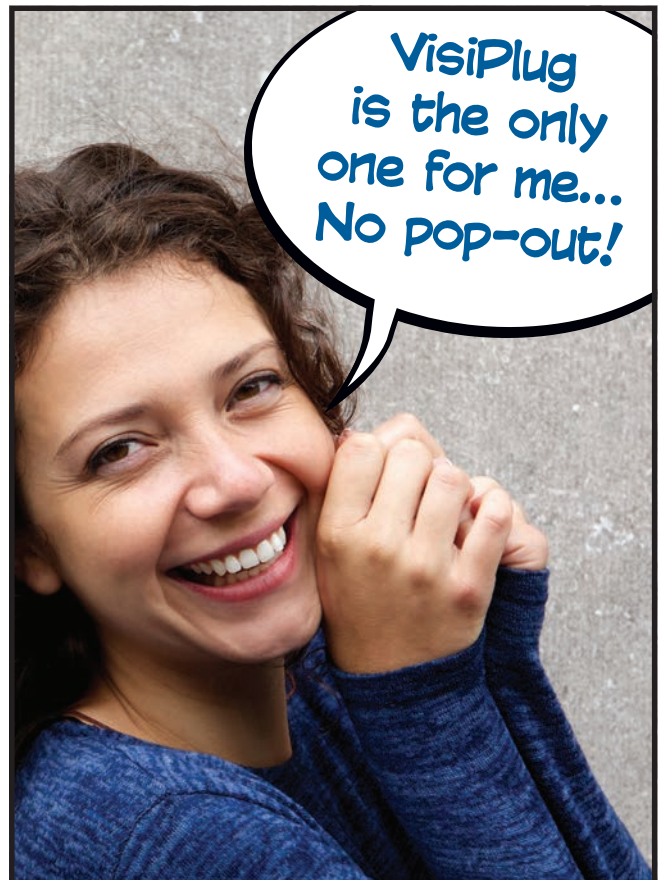Make a Difference

If you haven't embraced medical eye care, this is the year to do it. If you have, maybe consider adding a specialty to your practice. We must take a more active role when treating patients with diabetes, cataract, glaucoma, AMD and dry eye. Beyond our training as diagnosticians, we can recommend treatments that make a meaningful difference, and we can suggest lifestyle changes, diet and exercise modifications, systemic disease management, nutritional supplementation, retinal light protection and more careful follow-up.

Medical optometry will change the lives of your patients, and it will change the course of your practice in meaningful, positive ways. The top 5% of optometrists receive at least 50% of their income from medical services.¹¹ How much of your practice revenue can you attribute to medical optometry? For most of your colleagues, it's only about 17%, which leaves plenty of room to grow in a diverse list of specialties that show no signs of shrinking.¹¹ ■

Note: Dr. Karpecki consults for a number of manufacturers with products relevant to this topic.

1. AOA Excel and Jobson Medical Information. The State of the Optometric Profession. 2013.
2. Lee R, Wong TY, Sabanayagam C. Epidemiology of diabetic retinopathy, diabetic macular edema and related vision loss. *Eye Vis.* 2015;2:17.
3. American Diabetes Association. Economic costs of diabetes in the U.S. in 2012. *Diabetes Care.* 2013;36:1033-46.
4. Summers KHR, Ryan GJ. The economic impact of diabetic retinopathy and the promise of emerging therapies [CE Activity]. International Medical Press; 2007.
5. Yu JW, Rogers SL, Kawasaki R, et al. Global prevalence and major risk factors of diabetic retinopathy. *Diabetes Care.* 2012;35(3):556-64.
6. Epiropoulos AT, Matossian C, Berdy GJ, et al. Effect of tear osmolarity on repeatability of keratometry for cataract surgery planning. *J Cataract Refract Surg.* 2015;41(8):1672-7.
7. Quigley HA, Broman AT. The number of people with glaucoma worldwide in 2010 and 2020. *Br J Ophthalmol.* 2006;90:262-7.
8. Neely DC, Bray KJ, Huisinigh CE, et al. Prevalence of undiagnosed age-related macular degeneration in primary eye care. *JAMA Ophthalmol.* 2017;135(6):570-5.
9. Cervantes-Castaneda RA, Banin E, Herno I, et al. Lack of benefit of early awareness to age-related macular degeneration. *Eye.* 2007;22(6):777-81.
10. Yu J, Asche CV, Fairchild CJ. The economic burden of dry eye disease in the United States: a decision tree analysis. *Cornea.* 2011;30(4):379-87.
11. Management & Business Academy. Key Metrics: Assessing Optometric Practice Performance. 2015 Edition.



Lacrimedics' VisiPlug® has been the market leading synthetic dissolvable plug for **15 YEARS!**

VisiPlug® was the first FDA approved and CE Marked plug to provide approximately **180 days** of Occlusion Therapy.

Available for immediate delivery. Don't make your Dry Eye patients wait for relief.

**VisiPlug® –
a visibly better plug
to treat dry eye!**

See you at SECO in Booth 1840



Lacrimedics

(800) 367-8327

E-mail: info@lacrimedics.com
www.lacrimedics.com

¹Dramatization. Not a real patient.

©2017 Lacrimedics, Inc.

Summon Some Courage

Jury duty isn't so bad when you can't weasel out of it—and remember, it could always be worse. **By Montgomery Vickers, OD**

When I was born, my dad was an agent in the FBI. But when he took one look at his new little criminal, he immediately quit to become a small town lawyer. Dad taught us to always respect our law enforcement officers and the judicial system. We did and we always will. My dad was a wise man.

Do What's Right

I could never be in law enforcement, but at least when I received my Denton County, Texas, jury summons, I knew my duty as a citizen of this wonderful nation. I knew, in my heart, exactly what to do. That's right: I searched the internet for how to get out of it.

That, unfortunately, didn't pan out because I couldn't figure out how to convince the judge that I was an active duty member of the armed forces, a convicted felon (I couldn't rob somebody and also get convicted in time), a pregnant woman (again, no time, but my understanding is that this is not impossible in California), or an employee of the Texas state government (God forbid an employee of the Texas state government spends a couple of days serving the state of Texas. Against union rules, I guess.)

So, the best I could do was request a delay until mid-December, which I was granted. It seemed a logical assumption that all the judges in Denton County were completely impartial in every way but one: none of them wanted to try a case

that might screw up their Christmas plans.

It turned out fine when 220 good Americans showed up and they only needed about 80, so they never even called my name. I didn't have to rip off my shirt to reveal my new full-body tattoo of Charles Manson and the Family while being vetted by the attorneys. Hopefully I can get the tattoo artist to somehow add enough ophthalmoscopes to it so the grandkids think it's a salute to the Texas Optometry Board when we go to the beach. Turns out it's hard to remove tattoos. Who knew?

Share the Joy of Jury Duty

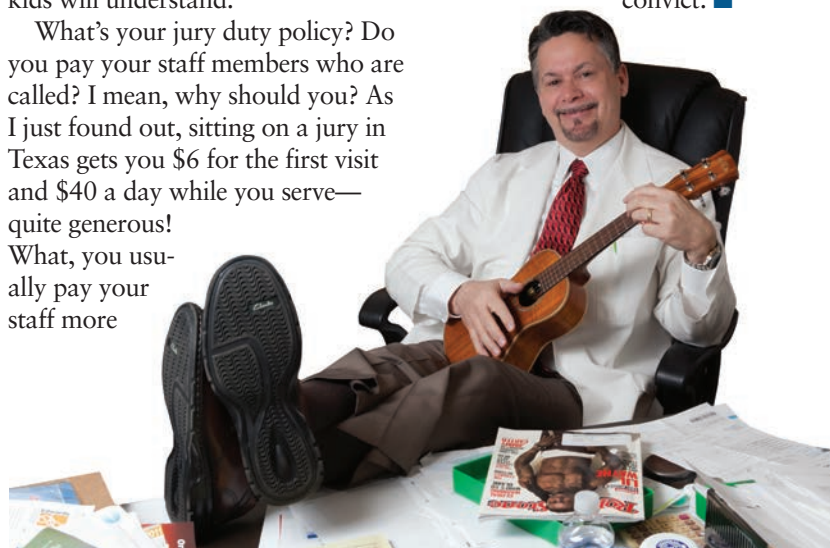Luckily, my office has a great policy in place for this; I didn't even have to come in for the afternoon, even though the jury selection was over before noon. I finally had time to finish my Christmas shopping. The kids will understand.

What's your jury duty policy? Do you pay your staff members who are called? I mean, why should you? As I just found out, sitting on a jury in Texas gets you \$6 for the first visit and \$40 a day while you serve—quite generous! What, you usually pay your staff more

than that a day? Hey, don't blame me, blame the Magna Carta. It's a slippery slope when you give rights to the commoners.

All of us civilians should be glad jury duty is all we have to do to serve our country. There are many wonderful folks who serve our country while crazy people try to hurt them. I certainly understand sitting on a jury to hear a case about a faulty AC installation isn't remotely the same. My guess is it is way more inconvenient to get shot at.

So, have the courage to make an office policy, one that shows you are grateful for our country. And when you get called, show up and do your duty. It's the least you can do. Also, none of your excuses will work... trust me, I tried. My understanding is there are very few convicted felons who are practicing optometry. Maybe optometrists are just hard to convict. ■





OPTICAL DISPENSARY MANAGEMENT

DO YOU REALLY HAVE THE RIGHT TEAM FOR THE JOB?

To make sure your optical dispensary is working efficiently, you need an experienced team.

That's why the most successful practices turn to **Vision Associates**. As a leader in *Optical Dispensary Development + Management*, we manage and grow your optical business through superior customer service, attention to detail, responsive inventory management and patient education. Let us be your team. Call for a free, no-risk assessment.

800.346.7486

visassoc.com

Visit us at SECO 2019
Booth 221

VISION

ASSOCIATES

YOUR PARTNERS IN VISION®



Making the Grade

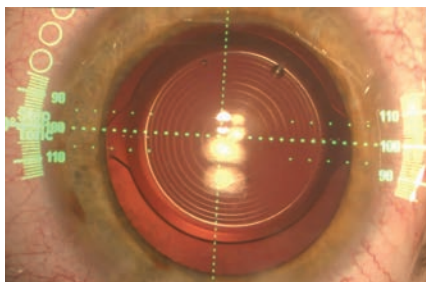
Type A personalities can get an F if their treatment expectations are not kept in check. **Edited by Paul C. Ajamian, OD**

Q I have been seeing a patient with mild cataracts for routine care, and he has been finicky about every one of his contact lens and spectacle prescriptions. I referred him for a cataract evaluation, and the surgeon implanted a multifocal lens. The patient is very unhappy. What went wrong?

A Communication, or the lack thereof, was a big problem in this case, says Paul C. Ajamian, OD, Director of Omni Eye Services of Atlanta, the nation's oldest comanagement center. "I looked back at the chart, and there was no referral letter that would have given us a heads up about our patient's personality and predilection for perfection," Dr. Ajamian notes. All his practice knew was that the patient wanted to go without glasses at distance and near. They informed the patient that he might still need to wear glasses in certain situations, but he didn't want to hear it. An initial discussion with his optometrist would have had a much greater impact. After the surgeon implanted the Restor (Alcon) lenses, the patient's vision was 20/25 and J2 OU, but he was still very unhappy.

Communication Breakdown

There is no one who knows the patient better than you. The key is to share that intel with your surgeon! It is unrealistic to expect that the surgeon will get to know your patient and assess their needs in the short period of time they have. Dr. Ajamian advises, "If you want the best outcomes, spend time counsel-



Your role in pre-op multifocal IOL counseling could mean the difference between success and failure.

ing the patient and then write a referral letter that says more than please do a cataract evaluation."

Your preoperative cataract exam should always include corneal topography to determine if the patient needs a toric lens. Irregular astigmatism usually precludes a toric IOL but also often rules out a multifocal. Surface disease, pterygia, Salzmann's nodular degeneration, map-dot-fingerprint dystrophy and LASIK are all deal-breakers for the multifocal.

Identify Type A personalities if at all possible. Be careful not to promise that the patient that they will be able to get rid of their glasses. "I tell everyone that they will be wearing glasses for some situations, even if the results are perfect," Dr. Ajamian adds. Finally, understand that anyone who pays upwards of \$3,000 for a premium lens product is going to expect perfection, and the current technology is not yet there.

Once your exam and pre-op counseling is complete, let the surgeon know what you observed, discussed and recommend. Most will take your advice, knowing that you

know the patient best.

Refining the Results

The second question, assuming the patient is a good candidate for a multifocal, is how to tailor the lens to the individual. "The Restor lens (Alcon) allows us to customize the visual correction to the patient's lifestyle," says Dr. Ajamian. If the patient spends most of their time on the computer and little time reading, Dr. Ajamian suggests the Restor Activefocus +2.5D lens. "If the patient does a lot of reading in addition to intermediate computer work, a good way to hedge your bet is to start with the +2.5D Activefocus in the dominant eye for better distance and intermediate vision." When the second eye is done two weeks later, reassess and determine if you need the slightly stronger +3.0D to assist them while reading.

Final Evaluation

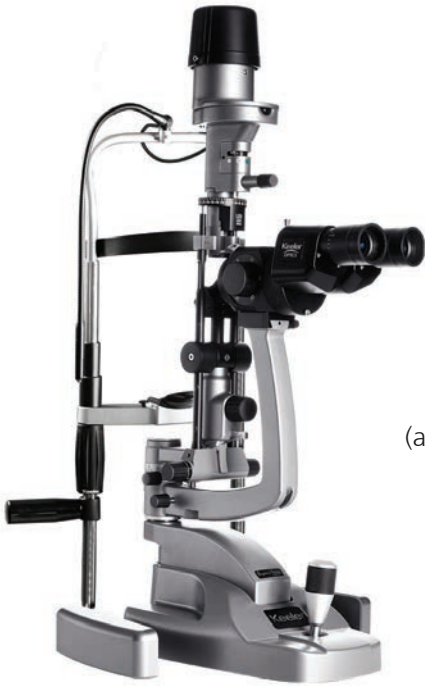Our Type A patient got a failing grade with a multifocal lens because the surgical practice didn't have the information they needed. The patient can score a better grade if optometrists take the time to counsel each patient and then pass the information they learn along to surgeons. It will make you look much better in your patient's eyes and leave for you fewer messy surprises behind to clean up post-op.

An A or an F? That depends on the extra effort you are willing to make to "school" the patient on the options available and what will work best for them. ■

The Keeler³ Trade In Program

Buy 3 // Trade 3 // Get 1 Free

The Power of 3. Purchase any 3 Keeler Slit Lamps and trade in 3 of your old Slit Lamps and we'll send you a 4th Keeler Slit Lamp absolutely free of charge.



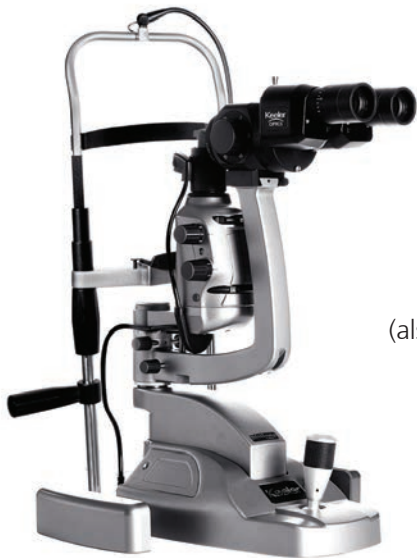KSL-H

(also in Digital Ready)



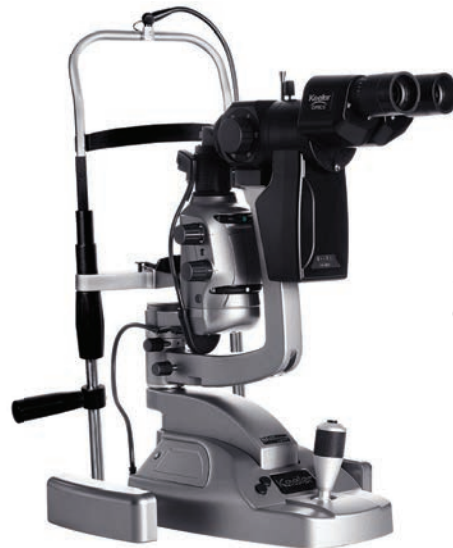KSL-H-D

(full Digital)



KSL-Z

(also in Digital Ready)



KSL-H-D

(full Digital)

Keeler
OPTICS

Keeler Instruments, Inc. • 3222 Phoenixville Pike, bldg. 50 • Malvern, PA 19355
Tel: (800) 523-5620 • Fax: (610) 353-7814 • email: keeler@keelerusa.com

Offer valid until March 31, 2019.

Contact Keeler or one of our authorized dealers for more information.



The Telephone is Ringing...

A new year brings new rules—make sure you know what your carriers expect when it comes to telehealth services. **By John Rumpakis, OD, MBA, Clinical Coding Editor**

In November 2018, CMS finalized and released the 2019 Physician Fees Schedule, which contains significant changes aimed at modernizing the healthcare system by using technology, reducing administrative burden and improving the doctor-patient relationship.^{1,2} While CMS's interpretation and implementation of telehealth is amongst the most restrictive, this latest release expands and clarifies things, at least a little.

Telehealth-delivered services under Medicare are regulated in statute by 1834(m) of the Social Security Act, which limits the use of telehealth to certain services, providers, technology (mainly live video) and patient locations (certain types of healthcare facilities in rural areas). The CMS rule expresses concern that these requirements may be limiting the coding for new kinds of services that use communication technology.

Out-of-office Care

Luckily, these restrictions only apply to professional services specified in the statutory provisions, such as office visits, professional consultations and other in-office services. Other services that can be provided remotely using communications technology are not subject to these restrictions because they are not considered "Medicare telehealth services." Because of this, optometrists need to be aware of three scenarios and the associated new codes:

- **Brief communication technology-based service, e.g. virtual check-in (HCPCS code G2012):**

This applies to check-in services used to evaluate whether or not an office visit or other service is necessary. The modalities include audio-only real-time phone interaction, in addition to synchronous, two-way audio interactions enhanced with video or other forms of data transmission. CMS pays approximately \$14 for this service (unless it is the result of a previous appointment or leads to a face-to-face appointment). CMS believes the check-ins will mitigate the need for potentially unnecessary office visits.

- **Remote evaluation of pre-recorded patient information (HCPCS code G2010):** CMS finalized the creation of a specific new code to describe remote professional evaluation of patient-transmitted information conducted via pre-recorded "store-and-forward" video or image technology. These services are not subject to the Medicare telehealth restrictions because they could not substitute for an in-person service currently separately payable under the PFS.

- **Interprofessional internet consultation (CPT codes 99452, 99451, 99446, 99447, 99448 and 99449):** These codes cover interprofessional consultations performed via communications technology such as telephone or internet. This supports a team-based approach to care that is often facilitated by electronic medical record technology.

Clinicians must understand that CMS restricts the use of the virtual check-in and the pre-recorded patient information codes, which can only be used by practitioners who furnish E/M codes.

Carrier Considerations

As technology continues to expand and drives changes in the patient journey and the quality of clinical outcomes, optometrists must stay abreast of the rule sets and changes that come at a furious pace. Pay attention to the rules of each of your contracted medical carriers, as they can differ based on whether the carrier is commercial, Medicaid, Medicare Part C (Medicare Advantage), or traditional Medicare Part B. And as always, make sure you are aware of these rules prior to providing the care—never assume that meeting the requirements of telehealth for one carrier means you meet the rules for other carriers.

Hopefully we will eventually have a universal rule set that streamlines the delivery of care by telehealth; but until then, you must maintain a separate rule set for each carrier. ■

Send questions and comments to rocodingconnection@gmail.com.

1. Centers for Medicare & Medicaid Services. Final policy, payment, and quality provisions changes to the Medicare physician fee schedule for calendar year 2019. www.cms.gov/newsroom/fact-sheets/final-policy-payment-and-quality-provisions-changes-medicare-physician-fee-schedule-calendar-year-november-1-2018. Accessed January 9, 2019.
2. Dizon R. Big changes in 2019 for Medicare telehealth policy. National Telehealth Policy Resource Center Blog. www.telehealthresourcecenter.org/big-changes-in-2019-for-medicare-telehealth-policy. November 6, 2018. Accessed January 9, 2019.



The solution? Biotrue[®] MPS contains hyaluronan to help provide up to 20 hours of moisture²

Look at the feedback from contact lens wearers who self-report dryness. They're pretty happy with Biotrue[®] MPS.



96% agree it helps prevent dryness³



97% agree lenses stay moist and comfortable all day long³



97% agree lenses stay comfortable when using digital devices³

No wonder Biotrue[®] is the #1 multi-purpose solution used in more households.* **Recommend Biotrue[®]—for up to 20 hours of moisture.²**

#1

MULTI-PURPOSE SOLUTION*



*Highest household penetration among multi-purpose solutions; IRI Data MULO 52 weeks ending 08/12/18.

REFERENCES: 1. The Multi-sponsors Survey's 2017 study of the US consumer contact lens market, December 2017. 2. In vitro studies evaluated the rate of release of sodium hyaluronate (HA), a conditioning agent in the Biotrue[®] multi-purpose solution, from both conventional and silicone hydrogel contact lenses over a twenty-hour time period. HA was adsorbed on all traditional and silicone hydrogel contact lenses tested upon soaking in the solution overnight. HA is then released from the lenses throughout at least a twenty-hour time period when rinsed with Hank's balanced salt solution at a rate mimicking tear secretions. The in-vitro performance of Biotrue[®] multi-purpose solution suggests that it will provide lens conditioning throughout a twenty-hour time period. 3. Results of an online survey of contact lens wearers with self-reported dryness on a regular basis who completed an evaluation program for Biotrue[®] multi-purpose solution (n=348). Survey results include patients who strongly agreed, agreed, or slightly agreed (on a 6-point agreement scale).

[®]/[™] are trademarks of Bausch & Lomb Incorporated or its affiliates. Any other products/brand names and/or logos are trademarks of the respective owner.

©2018 Bausch & Lomb Incorporated. BIO.0130.USA.18



Beyond the Phoropter

Are glasses always necessary? It takes more than just the numbers to make that call.

By **Marc B. Taub, OD, MS, and Paul Harris, OD**

It's not a typical day in the office without a parent asking, "Does my child really need glasses?"

When working with a patient with 2.00D of myopia, the answer is obvious, but what about when even you're not sure if you should prescribe or hold off for another year? While there are some guidelines to help us make this decision, we also have our own clinical experience to rely on when making the final call. We've included two similar cases that resulted in us taking two different actions and the reasoning behind each decision.

Case #1

A nine-year-old female came in for her routine exam, stating she had lost her glasses three months prior and had not been seeing well with them. She reported that she actually sees better without them, and her mom said her visual behavior and school performance have not declined since she lost them.

Case #2 Exam Findings

Visual Acuities (unaided)	20/25- OU, 20/20- OU at distance, 20/20 OU at near
Stereopsis (unaided)	20 seconds
Cover Test	Ortho at distance and at near
Near Point of Convergence Test	Break at 7cm, recovery at 11cm
Accommodative Amplitudes	11.00D OD, 9.00D OS
First Prescription (three years prior)	+2.25 -2.25x180 OD, +1.00 -2.25x180 OS
Previous Prescription (18 months prior)	Plano -1.00x180 OU VAs of 20/20 OU
Retinoscopy	+1.50 -150x180 OU VAs of 20/20- OU
Subjective Refraction	1.00 -1.00x180 OU VAs of 20/20 OU
Final Prescription	+0.50 -1.00x180 OU VAs of 20/15 OU at distance, 20/20 OU at near
Cover Test Through Final Prescription	6 exophoria at near
Vergence Ranges Through Final Prescription	x/20/18 for base in, x/25/12 for base out

The patient did well after receiving her first pair of glasses three years earlier and wore them at school and while doing homework. She was born full-term with no complications and met

all developmental milestones. She did not report any problems with squinting or headaches and has been receiving As and Bs in school.

Now, we refer back to the question we hear almost daily and ask ourselves whether this child needs glasses. Every patient has different visual needs, even if they happen to have similar refractive findings, so we must always be thoughtful about how we proceed.

According to our findings, this patient is a high-functioning child who is doing well in and out of school. We agreed that, if this were the patient's first examination, we would have made the straightforward decision to hold back from prescribing glasses. This is due to the fact that her

Case #1 Exam Findings

Visual Acuities (unaided)	20/20 OU at distance and at near
Stereopsis (unaided)	25 seconds
Cover Test	Ortho at distance, 4 exophoria at near
Quality of Life Test	12 (a score of 20 or higher is a red flag)
Accommodative Amplitudes	12.00D OU
Previous Prescription (18 months prior)	+1.50 -1.00x180 OU
Retinoscopy	+2.00 -1.00x180 OD, +1.25 -1.00x180 OS VAs of 20/20 OD and 20/20- OS at distance, 20/20 OU at near
Subjective Refraction	+1.50 -1.00x180 OU VAs of 20/20 OU
Damp Retinoscopy	+2.75 -1.00x180 OD, +2.00 -1.00x180 OS

hyperopia and astigmatism are right at the point when prescribing is recommended, her school performance is not a concern and her uncorrected visual function is within expected levels. Given that this was not her first examination, however, we had to look at all of the facts and discuss with the patient and her parent. Since the patient's behavior and school performance did not worsen after losing her glasses, a new prescription was not issued. If the patient were to return with near-point complaints later on, a near only would then be considered.

Case #2

A nine-year-old male presented complaining of slight trouble seeing distant objects, and his mom reported that he squints while reading. She said he has a pair of glasses but often misplaces and has never consistently worn them, even though they were prescribed three years ago. She said his grades in school fluctuate based on how much he can focus while reading.

Upon reviewing this case, we can observe that while our findings are somewhat similar to the first, this child presented under different circumstances. He exhibits erratic school performance, poor behavior and suboptimal visual function data. When his acuity is corrected, we can also see an improvement in the cover test and vergence ranges at near, which are close to expected values. Taking all of this information into account, it is obvious that prescribing in this case is less of a question. The patient's parents were on board as soon as we explained how glasses could positively impact his academics and behavior. Moving forward, we decided to cut 0.50D off the sphere component to allow for acuities similar to, if not better than, those the subjective refraction yielded.

When deciding whether to prescribe glasses, especially for a child, first gather a comprehensive patient history and conduct a complete ocular exam. So much more goes into prescribing than just the numbers.

In both of these cases, we looked to the parents to provide background information. We also relied on the non-acuity-based examination data to guide us in the decision-making process. Without the combination of parental information and visual function testing, it would have been pretty much impossible to see the full picture and decide how to proceed accordingly. ■

SECO 2019

WHERE SIGHT MEETS VISION



THE 2019 SECO SHOW DAILY!

The SECO conference, one of the premier educational events of the year, will take place February 20-24, 2019 — and *Review of Optometry* will be there! *Review's* on-site editorial staff will provide live daily coverage of important show news and events, educational highlights, product launches and more.

Attendees on-site can pick up the SECO Daily each morning for the latest news and highlights. Those at home can stay in touch, too—a digital edition of the SECO Daily will be posted online, plus an e-newsletter will be sent out each morning with the day's top stories.

Show copies will also be available at the Review of Optometry booth

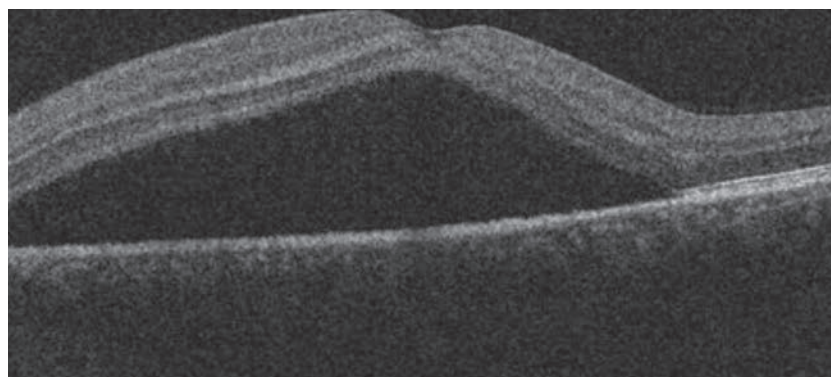


Serous Business

CSR can be treated a number of different ways—but *should* it be?

By Jay M. Haynie OD, Diana Shechtman OD, and Rashid Taher, MD

Central serous retinopathy (CSR) is thought to be an idiopathic disorder typically found in the macula, characterized by a neurosensory detachment from the retinal pigment epithelium (RPE) and a localized pigment epithelial detachment (PED). Symptoms of CSR can include a loss of central vision, a central scotoma, micropsia, metamorphopsia, reduced color vision and reduced contrast sensitivity. Visual acuity may only be reduced moderately, and the refraction tends to reveal a hyperopic shift in most cases.¹ Enhanced depth imaging optical coherence tomography (EDI-OCT), available for both spectral-domain (SD) and swept-source OCT, has demonstrated that patients with CSR tend to have thicker, larger diameter choroidal vessels (i.e., pachychoroid).



All photos: Jay M. Haynie, OD

Fig. 1. SD-OCT reveals a neurosensory detachment in the patient's left eye.

Risk factors associated with CSR include steroid use, increased caffeine consumption, higher stress levels (or a type-A personality trait), testosterone supplements, pregnancy, *Helicobacter pylori* ulcers, Viagra (Pfizer) use and obstructive sleep apnea. All of these risk factors can result in increased vascular

permeability of the choroid, causing a localized PED, an accumulation of subretinal fluid or a neurosensory detachment.

permeability of the choroid, causing a localized risk factor, especially in patients who suffer from recurrent episodes of CSR or have chronic symptoms.² In the clinical setting, CSR is classified as either acute or chronic (recurrent). In acute CSR, the visual symptoms are often self-limiting for one to four months; chronic CSR may cause more prolonged visual symptoms and a risk for permanent visual loss.

permeability of the choroid, causing a localized PED, an accumulation of subretinal fluid or a neurosensory detachment.

When asking patients about any possible exposure to steroids, be sure to question them on the use of any products that may contain steroids, such as creams, inhalants, nasal sprays and joint injections. Research shows obstructive sleep apnea is present in up to two-thirds of patients with CSR and

should be considered an associated risk factor, especially in patients who suffer from recurrent episodes of CSR or have chronic symptoms.² In the clinical setting, CSR is classified as either acute or chronic (recurrent). In acute CSR, the visual symptoms are often self-limiting for one to four months; chronic CSR may cause more prolonged visual symptoms and a risk for permanent visual loss.

Although CSR is thought to be self-limiting in most cases, treatment should be considered in some cases. These include monocular patients, those that need a more rapid recovery in visual acuity to perform work or vocational tasks, those that have had a poor visual outcome from chronic CSR in the fellow eye or persistent subretinal fluid beyond three to four months.

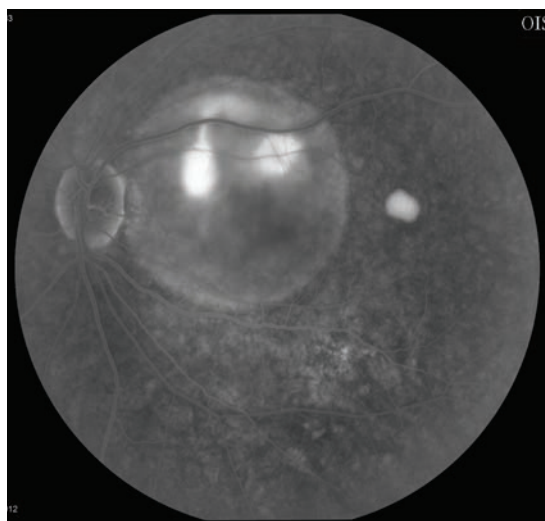


Fig. 2. Fluorescein angiography shows focal leakage and a well-defined serous PED.

rifampin; and the hormone supplement melatonin. Focal laser photocoagulation can also help with subretinal fluid absorption. Research also shows photodynamic therapy with the light-activated drug Visudyne (verteporfin, Bausch + Lomb) can be effective for CSR treatment.³

A Hairy Situation

Case by Dr. Haynie

A 42-year-old male presented to the clinic with a two-week history of vision loss in the left eye. His medical history included Kenalog (corticosteroid) injections in the scalp for the treatment of alopecia, an autoimmune disease characterized by hair loss. He reported that he developed vision loss three days after his treatment. His left eye's entering visual acuity measured 20/60 and the intraocular pressure was 14mm Hg. Dilated examination revealed a serous macular lesion. OCT confirmed a neurosensory detachment with a pachychoroid; fluorescein angiography confirmed focal leakage and a well-defined serous PED (Figures 1 and 2). He was diagnosed with acute CSR secondary to the Kenalog injections.

Following a discussion of treatment vs. observation, he elected to be treated with oral acetazolamide 250mg QHS. At follow-up three weeks later, he reported some visual recovery to a level of 20/20- and OCT imaging confirmed near complete resolution of the neurosensory detachment (Figure 3).

As part of the management of CSR, I discussed avoiding any future Kenalog injections; however, he wanted to continue the treatment for alopecia. To avoid another acute CSR episode, I treated him with acetazolamide 250mg one week prior to his Kenalog treatment, which worked well long-term

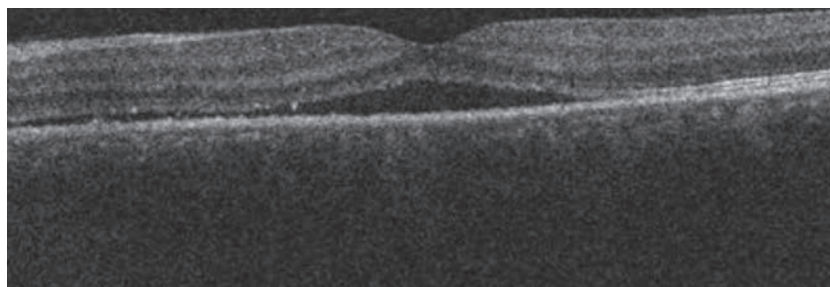


Fig. 3. The patient's neurosensory detachment was nearly resolved three weeks post-treatment.

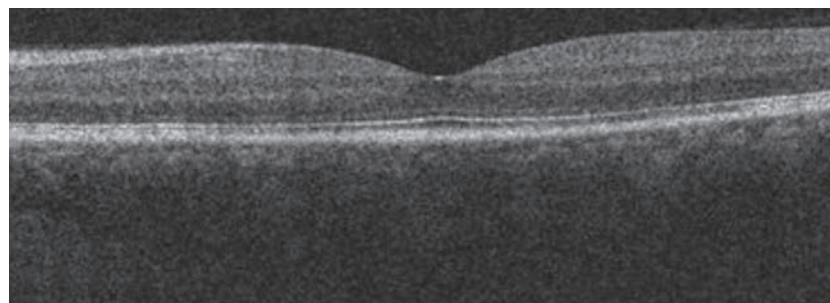


Fig. 4. SD-OCT imaging of the patient's left eye, pretreated with acetazolamide, one week after the Kenalog treatments. Note that the CSR remains inactive with no subretinal fluid detected.

(Figure 4).

Lighting the Way

Case by Dr. Haynie

A 39-year-old female was referred for a retinal consultation after noting sudden vision loss in the right eye. Her history included a similar episode of vision loss the year prior, although it recovered spontaneously over two months. Her medical history includes osteoarthritis, gastroesophageal reflux disease and migraine syndrome. Her medications included Topamax (topiramate, Janssen Pharmaceuticals), Mobic (meloxicam, Boehringer Ingelheim) and Protonix (pantoprazole, Pfizer). Her visual acuity measured 20/50- in the right eye. Dilated examination revealed serous edema in the right eye involving the macula. Fluorescein angiography confirmed focal intense leakage, indocyanine green (ICG) angiography confirmed choroidal hyper-

permeability in the peripapillary area of the choroid and SD-OCT confirmed a large neurosensory retinal detachment (Figures 5 and 6). These findings led to a diagnosis of recurrent CSR.

After discussing her treatment options, which could include observation, she elected to be treated with low-fluence photodynamic therapy based on the degree of vision loss and the recurrent nature of the condition. Six weeks following treatment, the neurosensory detachment had resolved (Figure 7). Fluorescein angiography and ICG angiography revealed cessation of the intense leakage with no evidence of activity (Figure 8). Her visual acuity improved to 20/20-.

Therapy Preferences

Commentary by Dr. Shechtman

Most CSR cases resolve spontaneously within three months without intervention. However, 30% to

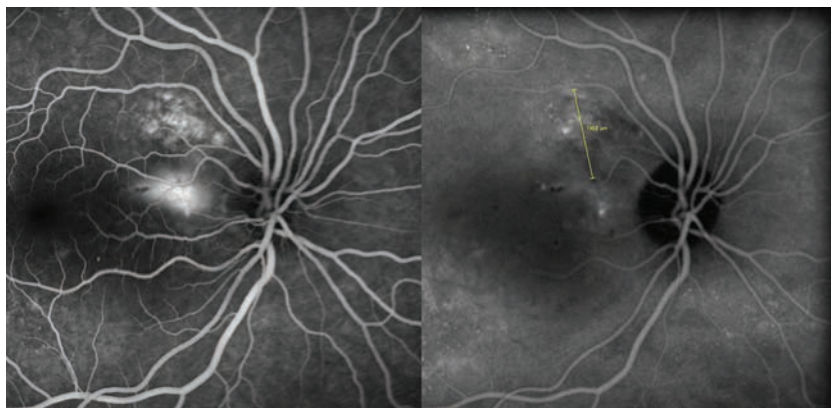

Fig. 5. This patient's ICG angiography reveals choroidal hyperpermeability.

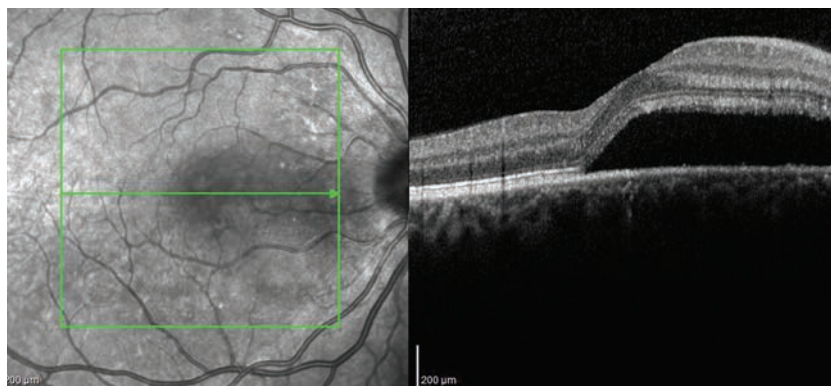


Fig. 6. SD-OCT imaging uncovers a large neurosensory retinal detachment.

50% of patients experience recurrence, which may be seen as gutturing on fundus autofluorescence. Both recurrence and chronicity may lead to RPE atrophy in these patients, with associated permanent visual disturbance, in addition to increased risk of choroidal neovascularization.

While a variety of treatment options exist for chronic or recurrent cases of CSR, we find spironolactone 50mg QD and focal laser photocoagulation most effective in our practice. Studies show a relationship between mineralocorticoid (MR) receptors and choroidal vascular dilation, which collaborate to

develop CSR. Thus, the use of an MR antagonist, such as spironolactone, can be an effective treatment option for chronic CSR. A recent study shows 83% of those treated vs. 8% of those observed had complete resolution of the CSR within two months. Given spironolactone's status as a potassium-sparing diuretic, clinicians should consider evaluating the patient's potassium level prior to its implementation.

In addition to spironolactone, focal laser photocoagulation applied to a "hot spot" seems to also be an effective option for patients with CSR. Fluorescein angiography is used to identify the presence of a hot spot, which shows up as hyperfluorescence at the site of RPE detachment. The focal RPE detachment must not involve the fovea. Although the treatment may lead to more rapid resolution, choroidal neovascularization may develop at the treatment site.

CSR can be a challenging condition to treat. Luckily, clinicians have many options that provide an opportunity to tailor therapy to the needs of each patient. ■

1. Wang M, Munch IC, Hasler PW, et al. Central serous chorioretinopathy. *Acta Ophthalmol.* 2008;86:126-45.
2. Yavas GV, Kusbeci T, Ka ikci M, et al. Obstructive sleep apnea in patients with central serous chorioretinopathy. *Curr Eye Res.* 2014;39(1):88-92.
3. Yannuzzi LA, Slakter JS, Gross NE, et al. Indocyanine green angiography-guided photodynamic therapy for treatment of chronic central serous chorioretinopathy: a pilot study. *Retina.* 2003;23(3):288-98.

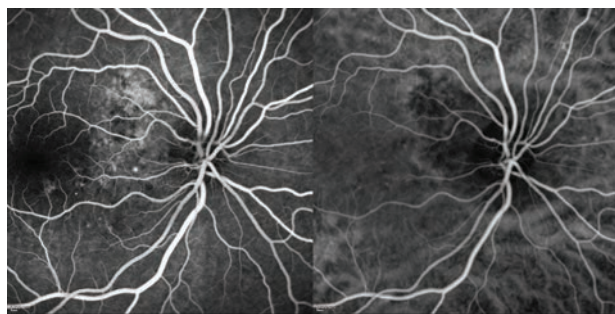


Fig. 7. Six weeks after low-fluence photodynamic therapy, the patient's neurosensory retinal detachment had resolved.

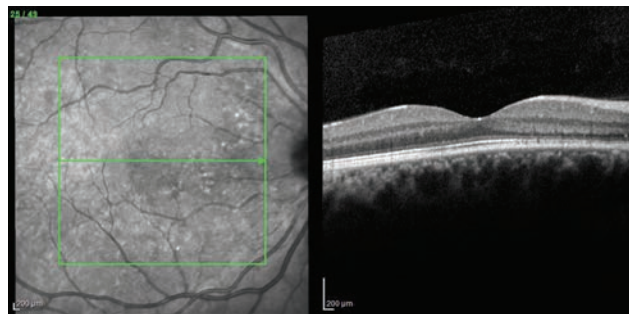


Fig. 8. Treatment stopped the intense leakage, and no activity was noted six weeks after initiating therapy.



Version Ten Now Launching!
Win/Mac Compatible
No Dongle Download
Sharper Optotypes
Up to 20/800
Patti Pics® Pediatric Chart
New Photo/Video Interface
New Macro Utility
Auto Updates Option



SLOAN / SNELLEN / NUMBERS / CONTRAST SENSITIVITY / HOTV / ALL ETDRS CHARTS / WHITE ON BLACK OPTION / VIDEO LIBRARY / SINGLE LETTER - SINGLE LINE - MULTI-LINE / 56 KEY CUSTOM REMOTE / MARCO INTEGRATION / INFINITE OR LIMITED RANDOMIZATION OPTIONS / ALL IN ONE SYSTEMS OR SOFTWARE ONLY / FREE SUPPORT/ NO ANNUAL FEES

DISASTER PROOF BY DESIGN - 580.243.1301 / ACUITYPRO.COM



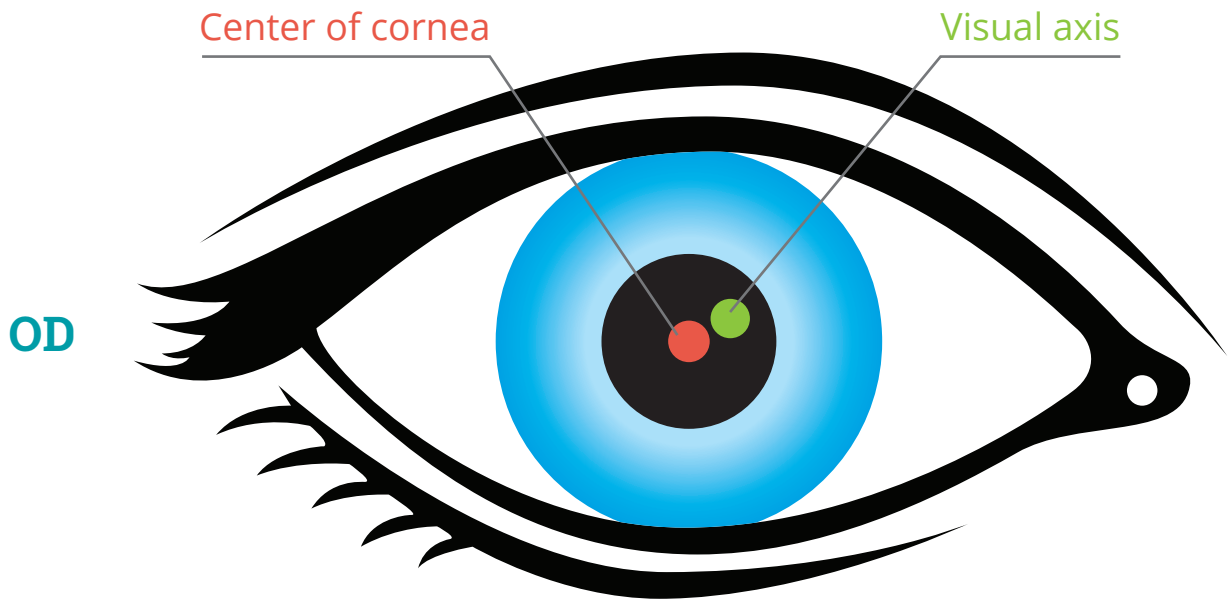
*Patti Pics® is a U.S. registered trademark of Precision Vision Inc. and are used under license from Precision Vision, Inc. The Precision Vision and Patti Pics® logos are © Precision Vision.

VISIT US AT SECO, FEBRUARY 20-24, 2019 BOOTH #1237 NEW ORLEANS, LA
VISION EXPO EAST MARCH 21-24, 2019 BOOTH #MS4611 NEW YORK, NY



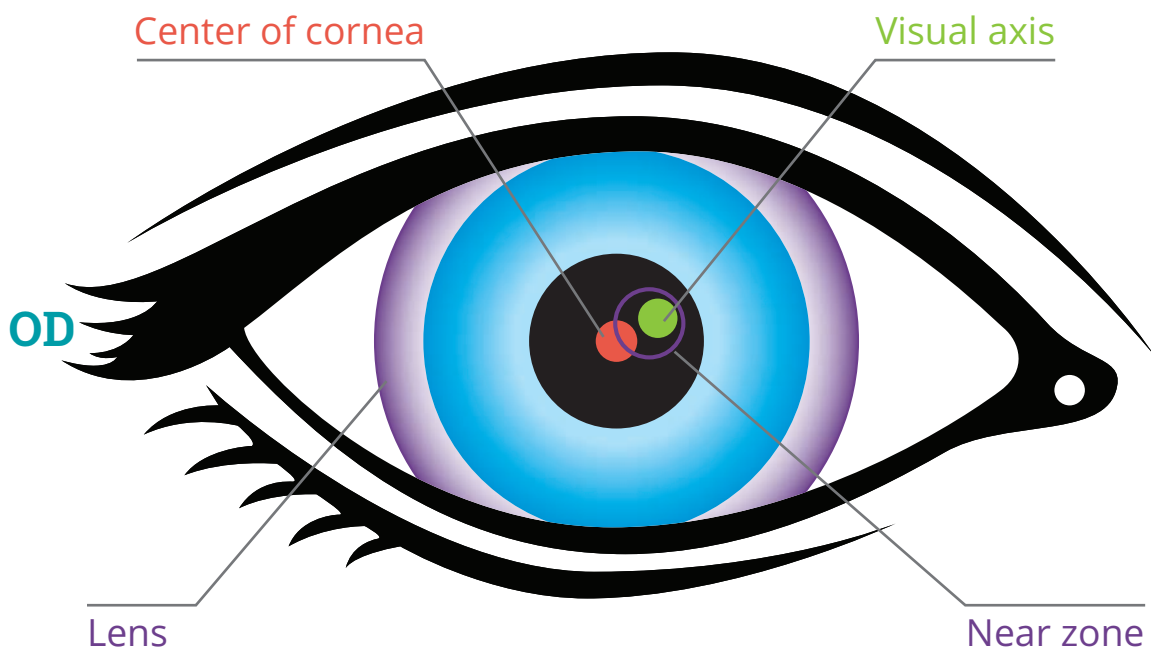
**USED ON BOARD THE
INTERNATIONAL SPACE
STATION AND IN OVER 20
COUNTRIES ON EARTH**

OFF CENTER: Visual Axis



Numerous studies have documented that the visual center (line of sight) is not centered geometrically within the pupil.

ON TARGET: Near Zone



Decentered optics align the near zone over the visual axis instead of the center of the cornea.

NEW!

Multifocal Optical Alignment for Scleral Lenses

Zen™ Multifocal

scleral lens for presbyopia

We've customized custom scleral lenses even more. For your presbyopic patients, new Zen™ Multifocal lenses align the center-near zone over the visual axis instead of the center of the cornea. In soft contact lenses, this has been shown to provide clear near vision. The result? You now have more ability to fine-tune your fitting. So if you're having trouble with multifocal scleral lenses, don't wait for the stars to align. **Align the optics.**

Parameters

- **ADD Powers:** +1.00D to +3.50D in 0.25D steps
- **Variable Center-Near Zone:** 1.5mm to 3.0mm in 0.5mm steps
- **Diameters:**
14.8mm, 15.4mm – Zen™ RC scleral lens
16.0mm, 17.0mm – Zenlens™ scleral lens

Benefits

- **SmartCurve™ technology:**
Modify only the parameters you want
- **MicroVault™ technology:**
Vault over elevations on the sclera
- **Prolate and oblate profiles:**
Fit a wide variety of corneal shapes
- **Fitting:** Uses existing Zenlens™ or Zen™ RC fitting sets

Our expert fitting consultants will help you determine the ideal lens, with unlimited lens exchanges and cancellations for 90 days.

We're there for you, every parameter of the way.

**LEARN MORE: CALL 800-253-3669
OR VISIT [BAUSCH.COM/ZENLENS](https://www.bausch.com/zenlens)**

Visit [bauschsvp.com](https://www.bauschsvp.com) for important safety information

BAUSCH+LOMB
Specialty
VISION PRODUCTS


ALDEN
OPTICAL®

Get a Glimpse of
**WORK IN
PROGRESS**

Five research teams share details about their efforts to build new tools for glaucoma, AMD, diabetic retinopathy and drug delivery.

WHAT'S INSIDE

Transcorneal stimulation of the ciliary body
Can We Lower IOP with Glasses?
Page 35

Detection of apoptosing retinal cells
**A Light in the DARC:
Seeing Glaucoma Before it Strikes**
Page 39

Stem cell implantation for RPE remodeling
**Bioengineering the Retinal Pigment
Epithelium**
Page 42

Electrically enhanced drug penetration
Iontophoresis: Wave of the Future?
Page 46

Phototherapy for diabetic retinopathy
While You Were Sleeping
Page 48

Glasses that lower IOP. An eye scan that reveals dying cells. Electrically charged drug delivery. A way to regrow RPE. And a contact lens that treats diabetic retinopathy. None are available yet, and perhaps not all will make it to market. But each breaks from the conventional wisdom, eschewing the familiar in hopes of creating something groundbreakingly new.

That's why we've selected these five research projects to highlight in this year's annual Innovation in Eye Care issue. They challenge the norms of today, but might become the ones of tomorrow.

Research need not always be groundbreaking to be worthwhile, of course. The field of eye care is sustained and strengthened each day by the release of new research papers in the scientific journals. Those are the lifeblood of clinical practice, a way to reinforce and refine the techniques you use and decisions you make everyday.

But the researchers who "think different" (to use the old Apple slogan) open up entirely new avenues of investigation—and that effort may one day change the field of eye care in meaningful ways.

In the pages to follow, the researchers themselves will share their thoughts, experiences and hopes for the work they are conducting. We hope you enjoy this glimpse behind the curtain.



Can We Lower IOP with Glasses?

Researchers are finding shocking new ways to employ electro-stimulation.

By Taylor Lukasik, MD, and Iqbal Ike K. Ahmed, MD

As eye care professionals, we diagnose patients with primary open angle glaucoma (POAG) every day in our clinics. We tell them about the disease and how the pattern of vision loss begins with the peripheral vision and slowly encroaches centrally. We tell them they will need to begin lifelong treatment with an antihypertensive drop and possibly laser therapy. The indolent progression of glaucoma often leaves patients understandably surprised by their diagnosis, as the vision loss they have experienced is hidden to them.

Patients commonly ask if there are other treatment options for their condition. We impress on our patients that drops are currently the first-line treatment for glaucoma. After their initial pressure checks, patients return to us at their six-month and one-year follow-ups describing difficulties with their drops. “I tried the drops but I didn’t like them,” “I forgot to take them,” and “they make my eyes uncomfortable” are all common explanations for non-adherence. These reasons are always troubling because for many patients, conventional treatments seem unacceptable or impractical to incorporate into their daily lives.

Over the past 15 years, glaucoma management has begun to shift. Clinicians are moving away from treating patients with topical drops to maximum medical therapy then referring for traditional filtering surgery, which is traumatic and carries significant risk. Instead, we have



Photo: Bionode

This gold coil, affixed to a contact lens, is triggered by an electromagnetic field and delivers a stimulus that, researchers speculate, could reduce IOP.

seen the rise of minimally invasive glaucoma surgeries (MIGS), which are less invasive and possess greater safety profiles than traditional glaucoma surgery.¹ Additional benefits include decreasing patients’ medication burden while maintaining intraocular pressure (IOP) control. However, little progress has been made for patients diagnosed with milder stages of disease.

The IOPTx system from Bionode is aiming to offer these patients a solution in the form of a contact lens and glasses combination designed to lower intraocular pressure. Our clinicians at the Prism Eye Institute are evaluating these efforts.

How It Works

Previous research has shown transcorneal stimulation is safe for the anterior segment and deeper structures of the globe in the treatment of retinitis pigmentosa and various optic neuropathies.²⁻⁵ Bionode has

used this research as the underlying basis in developing IOPTx, which uses transcorneal electrical stimulation that targets the aqueous inflow and outflow structures of the eye in an effort to reduce IOP.

The system consists of a lightweight pair of glasses and customized contact lenses. The spectacles have embedded electronics in addition to a circuit that delivers an electromagnetic stimulus that reduces IOP. These glasses are fitted with wound enamel copper wire-coated coils that receive electricity from an external pulse generator and battery pack attached to the coils via a USB cable. When the device is activated, the pulse generator in the spectacle coil creates an electromagnetic field directed towards the eye and induces a current in the customized contact lens.

The contact lens consists of two Alcon Air Optix hydrophilic hydrogel contact lenses (Alcon) with the gold coil embedded in an electrically insulating parylene substrate between the two lenses. The contact lens acts as a secondary coil that is stimulated by the electromagnetic field emitted from the spectacle coil inserts. The electricity generated is driven across the physiologic structures of the eye.

Another version of the IOPTx system bypasses the use of a contact lens altogether and instead uses the electromagnetic field generated by a coil on the glasses as the only neuromodulatory source to potentially lower IOP. This may be useful in patients who cannot tolerate contact lenses, although currently this



version of the device is not included in any clinical trials.

Based on animal and biomechanical studies, the purported mechanism of action is twofold. First, the primary IOP-reducing effect stems from the electrical current causing interference with the normal functioning of the ciliary epithelial ion pumps. This, in turn, decreases the quantity of aqueous humor actively transported into the posterior chamber. The secondary mechanism of action involves electrical stimulation of the ciliary body causing contraction of the muscle and opening of the drainage structures of Schlemm's Canal. Potentially, this means the device is able to modulate both the outflow and production of aqueous simultaneously.

Multicenter Clinical Trials

Clinical trials of the device are currently underway in Spain and are beginning at the Prism Eye Institute in Mississauga, Canada. The study design is a prospective multicenter double-masked randomized clinical trial. At the Mississauga site, we are hoping to enroll 20 to 30 patients with POAG or ocular hypertension. After a washout period, patients will be randomized to the Bionode and control groups. Exclusion criteria will include secondary types of glaucoma and patients with previous glaucoma surgery. Enrolled patients will undergo treatment using the Bionode IOPTx system and IOP will be measured periodically over one month. The primary objective of the study is to evaluate the safety and IOP-lowering efficacy of the IOPTx system in glaucomatous eyes. Secondary outcomes will include the longevity of IOP reduction. This trial will provide valuable information for the appropriate use and protocol for the device in patients with POAG.



Photo: Bionode

The Bionode system uses spectacles embedded with circuitry to deliver an electromagnetic stimulus designed to reduce IOP.

Difficulties with Traditional Glaucoma Treatment

Non-adherence is a long-standing problem in glaucoma management.⁶ Recent research shows that between 1995 and 2001 in the United States almost half of patients who filled one prescription discontinued their use after the first bottle and only 37% continued use at three years.⁷ Another study—one that used electronic monitoring systems—published in 2015 compared patients' self-reported medication adherence to medication event monitors at 60-day follow-up appointments. In this study, 31% overestimated their drop use when compared with their monitors.⁸ In the future, the IOPTx system could be used to address patient compliance issues and, hopefully, reduce glaucoma progression.

Ocular surface disease (OSD) is one of the most frequent comorbidities associated with glaucoma, as nearly 50% of patients treated with topical glaucoma medications have OSD.⁹ Topical medications often contain preservatives, such as benzalkonium chloride, which is

cytotoxic and can destroy normal conjunctival epithelial cell membrane, ultimately releasing proinflammatory mediators that can lead to inflammation and dryness and be a precipitating factor for OSD.¹⁰ Continual use of topical medications can lead to alterations in tear film composition and even damage to the ocular surface.¹⁰

Preservative-free medications are available to combat this problem; however, these medications are not as readily available and increase the cost to patients. They also do not address patient compliance issues. Neuromodulation may have a role in reducing rates of ocular surface disease related to topical hypotensive medication in glaucoma patients.

Another option is laser trabeculoplasty. This is an appropriate, noninvasive option as a primary or secondary treatment for POAG or in patients who have adherence issues with medication. Selective laser trabeculoplasty (SLT) can achieve 20% or greater reduction in IOP in 58% to 94% of patients at 12 months.¹¹ However, the attrition rate is high, with only 38% to 68% of eyes maintaining 20% reduction at four years.¹¹

Wearables

Recent trends in medicine have sought to develop treatment and monitoring modalities personalized to patients' needs. Some of the emerging wearable noninvasive devices aim to monitor and treat patients with glaucoma.

Triggerfish contact lens sensor (CLS) (Sensimed). This is a noninvasive wireless soft contact lens that measures IOP over a 24-hour period. The CLS sends IOP measurements wirelessly to an adhesive disposable antenna that is placed around the periorbital skin. The

Technology in balance



Health




Vision



Comfort

Miru 1 month: a unique family of silicone hydrogel monthly lenses.

MeniSilk™ and Nanogloss™ technologies designed to meet the demands of today's contact lens wearer.*



Material and surface technologies

MeniSilk™

- Ultra high Dk/t - 161 @ -3.00D
- Exceptional hydration
- Optimized transparency

Nanogloss™


- Super smooth surface
- Resistance to bacteria
- Excellent wettability



www.meniconamerica.com

*Menicon data on file April 2016





antenna is connected to a recorder the patient wears in a pouch, similar to 24-hour blood pressure monitor. The CLS measures changes in corneal curvature to estimate IOP over a 24-hour period. This device has the potential to capture the variation of a patient's IOP during their daily activities, as opposed to merely when they are in the office. This could help identify their true peak IOP, which is associated with long-term progression of their disease.¹² A recent study of this technology concluded that the CLS appears to be better than mean clinic Goldmann IOP measurements at assessing risk of glaucomatous visual field deterioration.¹³

Repetitive transorbital alternating current stimulation (rtACS). Alternating current stimulation of the brain has been shown to potentially increase excitability and synchronicity in patients with brain injury.¹⁴⁻¹⁶ This method of neuromodulation has recently been applied to the visual system in the context of optic neuropathy. A small study involving patients with non-specific optic neuropathies showed that rtACS was able to improve patients' visual fields in the treatment arm.¹⁷ This study was limited by the small number of enrolled patients (n=12) in the treatment group, but its application in glaucoma management is promising. A larger prospective randomized double blind, sham-controlled trial compared rtACS to placebo in partially blind patients with glaucoma (n=33) or other causes of optic nerve damage (n=50) and demonstrated a 24% improvement in visual fields in the treatment group.¹⁸ In the future, this technology could possibly maximize the residual visual potential of patients with glaucoma who have significant loss of visual field.

IOP modulating goggles.

Researchers suggest significant interplay between the pressure of the cerebrospinal fluid (CSF) and the optic nerve.^{19,20} A correlation also exists between low CSF pressure and the development of glaucoma.^{19,20} Although the theoretical basis behind the pathogenesis of glaucoma in this patient population is still under debate, supporters postulate that patients with low CSF pressure have an abnormally high trans-lamina cribrosa pressure difference that leads to glaucomatous nerve damage.²⁰

Balance Goggles (Equinox) attempt to balance the pressure differential by applying a negative vacuum around the orbit of the eye. The company has received funding from NASA's National Space Biomedical Research institute and are currently conducting research on up to 50 clinically normal eyes to evaluate safety and efficacy of their product. This technology may have future applications in glaucoma management as well as idiopathic intracranial hypertension, hypotony and visual impairment and intra-ocular pressure.

Innovation is never easy, but it is necessary to drive disease management forward and overcome barriers to conventional treatment. New technology is moving towards less invasive and more objective measures for chronic diseases such as glaucoma. While further research is needed, the Bionode IOPTx system has the potential to play a promising role in the glaucoma management algorithm. ■

Drs. Lukasik is a research fellow at the Prism Eye Institute.

Dr. Ahmed practices at the Prism Eye Institute, Mississauga, Canada and is a professor of ophthalmology at the University of Toronto,

Department of Ophthalmology and Vision Sciences, Toronto, Canada.

1. Pillunat LE, Erb C, Jünemann AG, Kimmich F. Micro-invasive glaucoma surgery (MIGS): a review of surgical procedures using stents. *Clin Ophthalmol.* 2017;11:1583-600.
2. Naycheva L, Schatz A, Röck T, et al. Phosphenes thresholds elicited by transcorneal electrical stimulation in healthy subjects and patients with retinal diseases. *Invest Ophthalmol Vis Sci.* 2012;53(12):7440-8.
3. Schatz A, Pach J, Gosheva M, et al. Transcorneal electrical stimulation for patients with retinitis pigmentosa: A prospective, randomized, sham-controlled follow-up study over 1 year. *Invest Ophthalmol Vis Sci.* 2017;58(1):257-69.
4. Fujikado T, Morimoto T, Kanda H, et al. Evaluation of phosphenes elicited by extraocular stimulation in normals and by suprachoroidal-transretinal stimulation in patients with retinitis pigmentosa. *Graefes Arch Clin Exp Ophthalmol.* 2007;245(10):1411-9.
5. Fujikado T, Morimoto T, Matsushita K, et al. Effect of transcorneal electrical stimulation in patients with nonarteritic ischemic optic neuropathy or traumatic optic neuropathy. *Jpn J Ophthalmol.* 2006;50(3):266-73.
6. Bloch S, Rosenthal AR, Friedman L, Caldarella P. Patient compliance in glaucoma. *Br J Ophthalmol.* 1977;61(8):531-4.
7. Nordstrom BL, Friedman DS, et al. Persistence and adherence with topical glaucoma therapy. *Am J Ophthalmol.* 2005;140(4):598-606.
8. Sayner R, Carpenter DM, Blalock SJ, et al. Accuracy of patient-reported adherence to glaucoma medications on a visual analog scale compared with electronic monitors. *Clinical Therapeutics.* 2015;37(9):1975-85.
9. Fechtner RD, Godfrey DG, Budenz D, et al. Prevalence of ocular surface complaints in patients with glaucoma using topical intraocular pressure-lowering medications. *Cornea.* 2010;29(6):618-21.
10. Mastropasqua L, Agnifili L, Mastropasqua R, Fasanella V. Conjunctival modifications induced by medical and surgical therapies in patients with glaucoma. *Curr Opin Pharmacol.* 2013;13(1):56-64.
11. Leahy KE, White AJ. Selective laser trabeculoplasty: current perspectives. *Clin Ophthalmol.* 2015;9:833-41.
12. Konstantas AGP, Quaranta L, Mikropoulos DG, et al. Peak intraocular pressure and glaucomatous progression in primary open-angle glaucoma. *J Ocul Pharmacol Ther.* 2012;28(1):26-32.
13. De Moraes CG, Mansouri K, Liebmann JM, Ritch R, Triggerfish Consortium. Association between 24-Hour intraocular pressure monitored with contact lens sensor and visual field progression in older adults with glaucoma. *JAMA Ophthalmol.* 2018;136(7):779-85.
14. Nair DG, Renga V, Lindenberg R, et al. Optimizing recovery potential through simultaneous occupational therapy and non-invasive brain-stimulation using tDCS. *Restor Neurol Neurosci.* 2011;29(6):411-20.
15. Song S, Sandrini M, Cohen LG. Modifying somatosensory processing with non-invasive brain stimulation. *Restor Neurol Neurosci.* 2011;29(6):427-37.
16. Chrysikou EG, Hamilton RH. Noninvasive brain stimulation in the treatment of aphasia: exploring interhemispheric relationships and their implications for neurorehabilitation. *Restor Neurol Neurosci.* 2011;29(6):375-94.
17. Sabel BA, Fedorov AB, Naue N, et al. Non-invasive alternating current stimulation improves vision in optic neuropathy. *Restor Neurol Neurosci.* 2011;29(6):493-505.
18. Gall C, Schmidt S, Schittkowski MP, et al. Alternating current stimulation for vision restoration after optic nerve damage: A randomized clinical trial. *PLoS ONE.* 2016;11(6):e0156134.
19. Berdahl JP, Fautsch MP, Stinnett SS, Allingham RR. Intraocular pressure in primary open angle glaucoma, normal tension glaucoma, and ocular hypertension: a case-control study. *Invest Ophthalmol Vis Sci.* 2008;49(12):5412-8.
20. Ren R, Jonas JB, Tian G, et al. Cerebrospinal fluid pressure in glaucoma: a prospective study. *Ophthalmology.* 2010;117(2):259-66.

A Light in the DARC: Seeing Glaucoma Before it Strikes

This cutting-edge technology could give us a window into the disease earlier in its course—shifting treatment ahead and possibly preventing vision loss.

By **Melanie T. Almonte, RN, BSN, MSc,** and **M. Francesca Cordeiro, PhD, MRCP, FRCOphth**

Upon initial diagnosis, a new glaucoma patient typically faces some grim realities. They learn that their neuro-ophthalmic infrastructure is already damaged—and irreversibly so—because as much as 40% of retinal ganglion cell (RGC) degeneration occurs before the condition is even clinically distinguishable through visual field changes.^{1,2} They are also highly vulnerable to further vision loss. And not a single treatment in the clinician’s arsenal can undo any of the damage.

Population-wide, the prospects are no better. Glaucoma is responsible for 15% of all blindness with over 500,000 new cases each year.^{3,4} In the United States alone, 2.9 million people are affected, representing 2.1% of the population over the age of 40.⁵ These estimates are only predicted to worsen as the population ages.

It is common to detect retinal neurodegeneration only after extensive RGC death and significant visual loss have already occurred. Given the primacy of RGCs in glau-

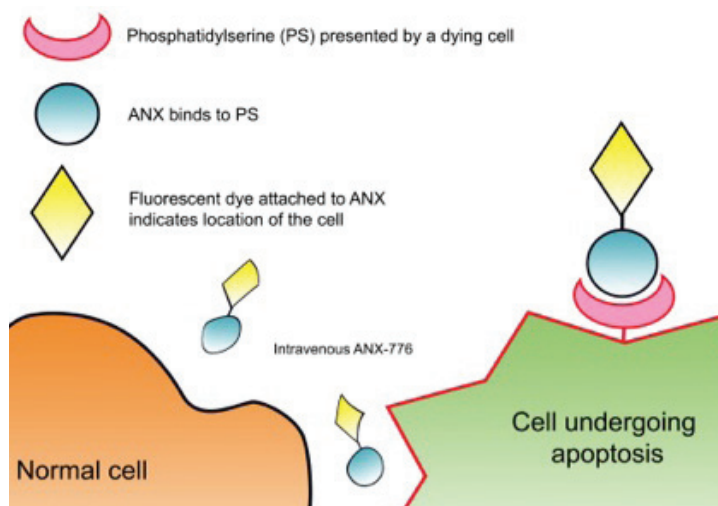


Fig. 1. This diagram shows where annexin-5 binds to an apoptosing cell compared with a normal cell.

coma’s story, our research team has been working on a promising new diagnostic approach to improve early diagnosis that detects glaucomatous changes at a cellular level.

Detecting Cell Death

Recent advances in OCT technology have given clinicians the ability to measure retinal nerve fiber layer (RNFL) and ganglion cell complex (GCC) thickness, but of course the process begins earlier than that, at the cellular level. What we see in RNFL or GCC dropout is axonal loss. But, what of the cells themselves? Our approach images the process of apoptosis, or “programmed cell death” as it occurs. In

so doing, we hope to provide the eye care community with tools to identify clinically modifiable targets before RNFL loss happens, possibly even allowing us to stave off that previously unavoidable consequence.

Apoptosis occurs in all multicellular organisms, permitting cell death without necrosis and subsequent inflammation. However, pathogenic altered rates of this

process are implicated in hematologic, cardiovascular, neurodegenerative (Alzheimer’s, Parkinson’s) and retinal (AMD) diseases.⁶⁻¹⁴ In early apoptosis, the cell membrane changes its structure, and phosphatidylserine, a membrane phospholipid, moves from within the cell to the outer surface. The protein annexin-A5 has been extensively used in cell biology to assess apoptosis in cancer, stroke and heart disease.¹⁵ It contributes to the regulation of membrane permeability and repair, making it an ideal marker of cellular predisposition to apoptosis.

We have developed a novel technique called DARC (detection of apoptosing retinal cells) to monitor



this process of retinal cell death *in vivo*. Using a fluorescently labeled variant of annexin-A5, a protein that binds to the exposed phosphatidylserine, and because the eye is transparent, we were able to visualize the fluorescence and identify individual apoptosing cells (*Figure 1*). The eye is unique in this ability due to the transparent nature of the optical media.

This led to the DARC project, a unique collaboration between Imperial College London and University College London, funded through the Wellcome Trust. In the Phase I clinical trial, safety and tolerability of DARC was assessed; however, we also wanted to compare whether there was a different signal between healthy controls and those who had progressing glaucoma. Sixteen subjects—eight healthy volunteers and eight with early, progressing glaucoma—were included in the trial.

Annexin-776 (ANX776), especially created for this application, was intravenously administered similar to the procedure used for

a fluorescein or indocyanine green angiogram.¹⁵ Before and following injection with ANX776, real-time images using near-infrared confocal scanning laser ophthalmoscopy captured retinal images at zero, 15, 30, 60, 120, 240 and 360 minutes. To establish dose safety and efficacy, we administered ascending doses of 0.1mg, 0.2mg, 0.4mg and 0.5mg in four single-dose groups of patients. Retinal imaging and pharmacokinetic studies were performed over six hours. The resultant images displayed hyperfluorescent spots appearing on the retina, thought to represent individual apoptosing retinal cells.

As far as we are aware, this milestone was the first experiment of its kind to visualize *in vivo* retinal apoptosis in humans. Importantly, ANX776 was found to be safe and well-tolerated with a short half-life of 30 minutes.

A Phase II trial has now been performed in patients with glaucoma, AMD, optic neuritis (multiple sclerosis), Down's syndrome (who display similar pathological features as in Alzheimer's disease) and healthy volunteers to further characterize the differences in spot count, distribution and morphology between diseases (*Figure 2*). These four diseases all lack techniques to achieve early diagnosis and monitor disease activity, a barrier to developing effective neuroprotective treatments.

Particular to glaucoma, there is also an unmet clinical need for a surrogate marker to predict future disease

progression. Results from the Phase II study should be reported soon.

Future Practice Implications

DARC offers a unique imaging technique that is able to use the eyes as a 'window' into the central nervous system in order to characterize events at a cellular level. This novel technique could potentially provide a powerful new tool to identify patients with pre-perimetric glaucoma, enabling early treatment, which may prevent or delay irreversible visual loss.

Just enabling early therapy initiation by conventional pressure-lowering means would be a benefit we hope to see DARC bring to light. But the treatment effect of neuroprotective agents, such as brimonidine, memantine and glutamate, can all be documented via DARC imaging. The quest to achieve a viable neuroprotective treatment is a Herculean task, and we hope our efforts to develop DARC might assist in the undertaking.

This new technology platform also opens the possibility of directly observing the effect of treatments in neurodegenerative disease using an endpoint based on the direct assessment of retinal cell death, therefore serving as a surrogate biomarker in clinical trials.

The hope is that with the results from further work in other conditions, DARC may also improve diagnosis and provide treatment options in a variety of neurodegenerative conditions, for which there are no effective cures.

These are early days for sure, but we on the research team are optimistic and excited about where we're heading. ■

Ms. Almonte is the research nurse at Imperial College Ophthalmic Research Group, Imperial College London.

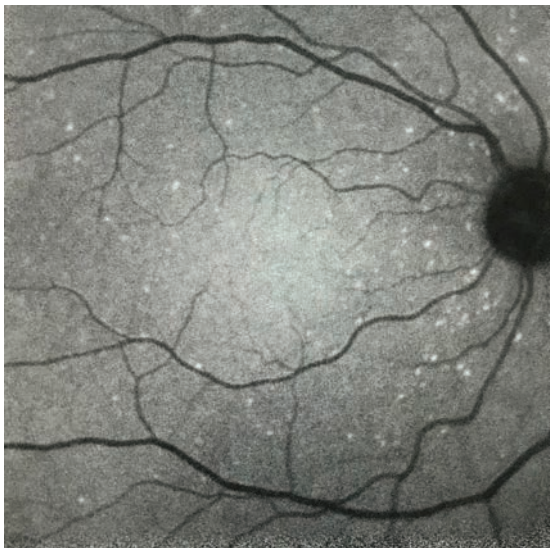


Fig. 2. This retinal image was acquired using the DARC technique during the DARC Phase II trial. The individual apoptosing retinal nerve cells (bright spots) are clearly distinguishable.



Extraordinary view - Great price!

Diamond series ophthalmic lenses

Exceptional optics

- Anti-reflective coating
- Low distortion & high resolution
- Superior small pupil performance

Ergonomic, durable design

- Lightweight construction
- "Sure Grip" handling ring
- Evaporated diamond hard coating (scratch resistance)

NEW!

Contact lenses: \$150.00 per lens

Diagnostic lenses



K31-1002
3 mirror*



K31-1005
4 mirror*

Diagnostic & laser lens (PRP)



K31-1330
Retina 200

Bi-aspheric non-contact lenses: \$125.00 per lens

Diagnostic lenses (slit lamp)



K31-2360
60D



K31-2355
78D



K31-2350
90D

Diagnostic & laser lenses



K31-2370
20D



K31-2365
28D

*3 mirror and 4 mirror lenses do not require anti-reflective or evaporated diamond coatings



800-225-1195 • www.katena.com

KL-Adv-080218A-Rev 0



Dr. Cordeiro is professor of glaucoma and retinal neurodegeneration studies at University College London, professor of ophthalmology and director of the ophthalmology research group at Imperial College London, and consultant ophthalmologist at Western Eye Hospital.

1. Kerrigan-Baumrind LA, Quigley HA, Pease ME, et al. Number of ganglion cells in glaucoma eyes compared with threshold visual field tests in the same persons. *Invest Ophthalmol Vis Sci.* 2000;41(3):741-8.
2. Zeyen T. Target pressures in glaucoma. *Bull Soc Belge Ophthalmol.* 1999;274:61-5.
3. Oliver JE, Hattenhauer MG, Herman D, et al. Blindness and

- glaucoma: a comparison of patients progressing to blindness from glaucoma with patients maintaining vision. *Am J Ophthalmol.* 2002;133(6):764-72.
4. Congdon N, O'Colmain B, Klaver CC, et al. Causes and prevalence of visual impairment among adults in the United States. *Arch Ophthalmol.* 2004;122(4):477-85.
 5. Gupta P, Zhao D, Guallar E, et al. Prevalence of glaucoma in the United States: The 2005-2008 National Health and Nutrition Examination survey. *Invest Ophthalmol Vis Sci.* 2016;57(6):2905-13.
 6. Selleri C, Maciejewski JP, Sato T, Young NS. Interferon-gamma constitutively expressed in the stromal microenvironment of human marrow cultures mediates potent hematopoietic inhibition. *Blood.* 1996;87(10):4149-57.
 7. Raza A, Mundle S, Iftikhar A, et al. Simultaneous assessment of cell kinetics and programmed cell death in bone marrow biopsies of myelodysplasias reveals extensive apoptosis as the probable basis for ineffective hematopoiesis. *Am J Hematol.* 1995;48(3):143-54.
 8. Thompson CB. Apoptosis in the pathogenesis and treatment of disease. *Science.* 1995;267(5203):1456-62.
 9. Festoff BW. Amyotrophic lateral sclerosis: current and future

- treatment strategies. *Drugs.* 1996;51(1):28-44.
10. Pollard H, Cantagrel S, Charriaud-Marlangue C, et al. Apoptosis associated DNA fragmentation in epileptic brain damage. *Neuroreport.* 1994;5(9):1053-55.
 11. Portera-Cailliau C, Sung CH, Nathans J, Adler R. Apoptotic photoreceptor cell death in mouse models of retinitis pigmentosa. *Proc Natl Acad Sci USA.* 1994;91(3):974-78.
 12. Gschwind M, Huber G. Apoptotic cell death induced by beta-amyloid 1-42 peptide is cell type dependent. *J Neurochem.* 1995;65(1):292-300.
 13. Walkinshaw G, Waters CM. Induction of apoptosis in catecholaminergic PC12 cells by L- DOPA. Implications for the treatment of Parkinson's disease. *J Clin Invest.* 1995;95(6):2458-464.
 14. Reme CE, Grimm C, Hafezi F, et al. Apoptotic cell death in retinal degenerations. *Prog Retin Eye Res.* 1998;17(4):443-64.
 15. Yap TE, Donna P, Almonte MT, Cordeiro MF. Real-time imaging of retinal ganglion cell apoptosis. *Cells.* 2018;7(6).
 16. Galvao J, Davis BM, Cordeiro MF. In vivo imaging of retinal ganglion cell apoptosis. *Curr Opin Pharmacol.* 2013;13(1):123-27.

Bioengineering the Retinal Pigment Epithelium

New stem cell-based therapies are paving the way for age-related macular degeneration treatment.

By Amir H. Kashani, MD, PhD, Diana Hong, BS, and Mark S. Humayun, MD, PhD

Over the last several decades, advances in stem cell biology have opened the door to cutting-edge clinical trials aimed at treating age-related macular degeneration (AMD), one of the leading causes of blindness in the western world.¹ Research focuses on two main categories of stem cells, human embryonic stem cells (hESC) and induced pluripotent stem cells (iPSC). hESC are derived from the early blastocyst stage of a fertilized human egg that has been donated to research. They have the ability to differentiate indefinitely and can become any cell type in the body. In contrast, iPSC are derived from adult human cells, usually skin cells. These cells are reprogrammed in the lab to revert to the pluripotent state from which they can be differentiated into almost any cell type.

While there are many differences between these two types of cells, one major distinction is that iPSC can be obtained from the same person who needs the stem cell-based therapy, thereby minimizing the chances of an immune response. However, creating iPSC can be a labor-intensive and expensive process that is not currently commercially feasible. Nevertheless, both cell types have been used to generate replacement tissue for subjects with atrophic retinal pigment epithelium (RPE) and AMD. Here we discuss the current research efforts to harness the healing powers of stem cell therapy for future AMD treatment.

Treatment Needs

AMD is classified as either neovascular (NVAMD) or non-neovascular (NNAMD), also called *wet* and *dry*,

based on the presence or absence of neovascularization, respectively.² Patients with wet AMD have several treatment options, including intravitreal injection of anti-vascular endothelial growth factor (VEGF) drugs, laser photocoagulation to ablate the neovascular membrane, surgical removal of the neovascular membrane with or without retinal translocation and photodynamic therapy.³ Applications of stem cell-based therapy in NVAMD are likely limited to cases involving RPE tears or RPE damage from recurrent sub-retinal hemorrhage.

Unlike its neovascular counterpart, dry AMD lacks therapeutic options and causes debilitating vision loss, albeit over decades. Progression and vision loss is characterized by focal loss of the RPE and atrophy of the associated overlying


neurosensory layer, a process also known as geographic atrophy (GA).⁴ In theory, being able to regenerate and replace the damaged RPE through stem cell-based treatments could delay or even reverse the consequences of GA.

Research Efforts

Over the past year, three early-phase trials have investigated the effects of replacing damaged RPE in subjects with NVAMD and NNAMD with stem cell-derived counterparts—each with exciting results.

The earliest of the three studies, reported in the *New England Journal of Medicine* in 2017, included one patient with NVAMD who had severe vision loss and was unresponsive to conventional therapy.³ As part of the trial, the patient received a transplant consisting of iPSC-RPE. A 1.3mm x 3.0mm sheet of iPSC-RPE created using the patient's skin fibroblasts was surgically placed under the fovea. Unfortunately, the researchers observed no change in visual acuity during the postoperative one-year follow-up, and retinal sensitivity also remained unchanged. However, a modest improvement on the National Eye Institute Visual Function Questionnaire 25 (VFQ-25) and a more foveal-centric fixation point showed some promise.

Further study with a second patient was hampered by several complications, beginning with the concern for potential medical risk due to genetic alterations. In addition, the cost of the iPSC-RPE differentiation procedure was prohibitive for additional studies, and despite the sophisticated surgical methods used in the study, the iPSC-RPE sheet was difficult to handle intraoperatively.



Reprinted from Keshvani AH, Lebkowski JS, Rahhal FM, et al.

Fig. 1. Above is a 3.5mm x 6.25mm sheet of hESC-RPE. Below is the same implant under high-magnification.⁶

Further analysis revealed one more complication, this time with the biocompatibility of the sheet itself. Imaging of the postoperative anatomy of the sheet showed it did not automatically conform to the anatomy of the native RPE monolayer. Despite these setbacks, the researchers felt this heroic attempt at replacing damaged RPE demonstrated the successful creation and surgical implantation of iPSC-RPE. The results provided enough information to keep investigations moving forward, as there was no evidence of transplant rejection or ill effects of the implant on the subject.

In April 2018, another study, reported in *Nature Biotechnology*, included two patients with wet AMD and severe vision loss who were treated with hESC-RPE cells.⁵ In this study, the surgeon used an artificial polymer to support the RPE monolayer, which helped with the surgical delivery of the cells into the area where the RPE had been damaged or ripped as a result of the NVAMD process. Of the 10 patients enrolled in this study, two received the transplantation and were included in published findings to date. At the one-year follow-up, spectral-domain optical coherence

tomography (SD-OCT) demonstrated proper orientation and persistence of the RPE layer relative to the surrounding tissue. The researchers also noted evidence of significant RPE migration away from the implantation site, for unclear reasons; but importantly, they saw no indication of transplant rejection. At least one subject required further surgery to repair a retinal detachment from proliferative vitreoretinopathy following implantation—a complication that illustrates the difficulty of the surgical procedure.

Most recently, our group reported preliminary results in *Science Translational Medicine* on five patients with severe vision loss from advanced dry AMD and GA.⁶ These patients were implanted with a ~3mm x 6mm sheet of hESC-RPE on a biosynthetic substrate that mimics the native Bruch's membrane in several aspects (*Figure 1*). Most importantly, this substrate has permeability properties that allow nutrients and oxygen to diffuse back and forth between the retina, RPE and choriocapillaris. The interim results of this phase 1/2a study demonstrated that the procedure was well-tolerated and three of the five subjects showed signs of visual function improvement. While the small sample size hinders our ability to determine whether the improvement is statistically or clinically significant, one patient maintained a 17-letter improvement, as well as improved fixation, over three follow-up visits.

Postoperative OCT imaging demonstrated a monolayer of RPE that is quite similar to the native anatomy of the hosts' RPE, suggesting the implant is integrating with or supporting the overlying host retina



where viable photoreceptor inner and outer segments are present at the edge of the GA (Figure 2).⁷ This preliminary data suggests short-term safety of the implant, as well as its potential efficacy.

The study is still ongoing, with 16 subjects currently enrolled. Similar

to the two previous studies, we have noted no evidence of transplant rejection or ill effects on the subjects, although we have yet to report on the final, long-term results.

Surgical Concerns

The surgical methods involved in these studies can be challenging, and proper patient selection is critical to their success.⁴ Subjects with GA have generally had longstanding disease and atrophy of the photoreceptor layer in addition to the RPE. This often causes the remaining retina to be highly adherent to the underlying aberrant Bruch's membrane, making surgical separation of the retina formidable. Careful surgical planning, patient selection and innovative surgical tools are needed to avoid potentially serious complications such as proliferative vitreoretinopathy, which has confounded previous submacular surgeries as is described in the submacular surgery trials for NVAMD.⁵

With the advent of modern, small-gauge vitreoretinal surgery and equipment, the success rates have increased, while complication rates for surgery have dramatically decreased over the past few decades. In all of the studies reported here, custom surgical instruments were designed and implemented for delivery of the RPE implants. It is likely that the current challenges facing stem cell-derived RPE implantation will be overcome with the aid of technological advances.

The results of these exciting studies lay the groundwork for a promising future in AMD treatment using stem cell-derived therapies. The lack of serious and unanticipated adverse events

suggests that the cell-based therapies, when done correctly, are well-tolerated and a feasible therapeutic modality.

The efficacy of these treatments remains to be proven, and several research hurdles remain. Therefore, follow-up studies will look closely at the data to determine the correct patient selection criteria, as well as what clinical criteria may define efficacy. For example, because GA patients often have chronic disease and overlying retinal atrophy, improvements in traditional visual acuity may be limited in these end-stage cases. Despite this limitation, three subjects in our study still showed signs of improvement. The favorable outcomes suggest these subretinal procedures may be warranted, even in later stages of the disease. Therefore, achievable clinical end-points other than acuity must be identified to guarantee a benefit to potential prospective patients.

Overall, the future of stem cell-based retinal therapy is bright, and a great deal of hope exists for patients suffering from what is currently an untreatable and blinding disease. ■

Dr. Kashani is an assistant professor at the University of Southern California's (USC) Roski Eye Institute and Keck School of Medicine of USC. He is a member of the Institute for Biomedical Therapeutics.

Ms. Hong, a medical student at the California Northstate University, is interested in pursuing ophthalmology and is doing a research year elective at the USC Roski Eye Institute.

Dr. Humayun is a professor of ophthalmology and biomedical engineering at the USC Roski Eye Institute and Keck School of Medicine of USC. He is co-director of the USC Roski Eye Institute and director of the Institute for Biomedical Therapeutics.

Reprinted from Kashani AH, Lebkowski JS, Rahhal FM, et al.

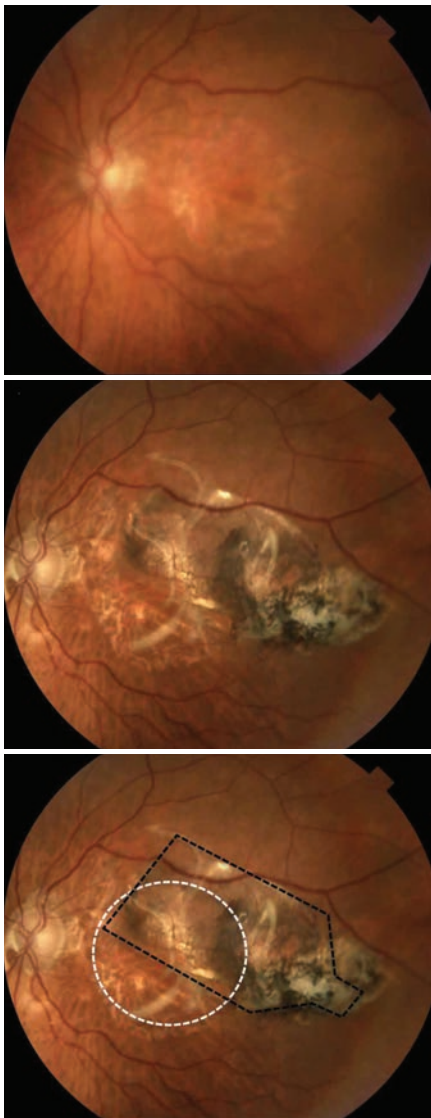


Fig. 2. Above, the study subject's pre-op fundus photo shows large areas of RPE loss, consistent with GA. Middle, the fundus photo 180 days after implantation with a sheet of hESC-RPE.⁶ Bottom, the annotated post-op image shows the location of GA (white dashed line) and the implant (black dashed lines).

LOMBART

SERVICE SOLUTIONS



A CONFIDENT DIAGNOSIS STARTS WITH YOUR EQUIPMENT

We have dedicated, factory-trained technicians across the country available to service your instruments. Additionally, our Clinical Support team can remotely access your advanced technology products to troubleshoot quickly. Reduce downtime and keep your instruments working like-new.

INSTRUMENT REPAIRS

Our certified ophthalmic Service Technicians conduct on- and off-site repairs nationwide, helping you minimize downtime and treat your patients. Our extensive parts inventory enable us to get you up and running quickly, oftentimes in only one visit. We're here for you – if we sell it, we service it.

PREVENTATIVE MAINTENANCE

Improve performance and extend the life of your instruments by having us check functionality, clean, calibrate, and complete a general service of your equipment at regular intervals. We complete multi-point inspection checklists to fine-tune your lane from top to bottom.

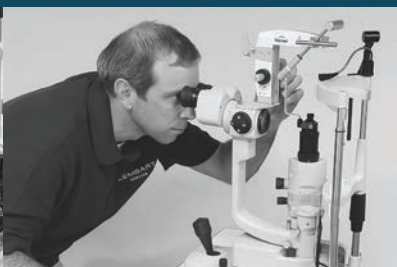PHOROPTER CLEANING

A phoropter cleaning is not simply wiping down the external lenses. We break the instrument down and clean/lubricate every piece, repair/replace all worn parts, align all cylinder lenses, cross cylinder lens axes, and readout scales, then perform a complete functional performance check against OEM specifications.

RELOCATION SERVICES

Office moves can be hectic and complicated. It's not worth the risk of damaging your expensive instruments – we can help. Our trained service technicians safely pack, move, reinstall, and recalibrate your instruments. We also provide temporary storage solutions in some cases – just ask!

ASK US ABOUT COMPREHENSIVE PROTECTION PLANS
FOR YOUR ENTIRE OFFICE. [800.LOMBART](https://www.800.lombart.com)





Financial disclosure: The sponsor, Regenerative Patch Technologies (RPT), and the California Institute for Regenerative Medicine provided grant support to USC. Dr. Humayun has intellectual property related to this study.

1. Rein DB, John S. Wittenborn JS, Zhang X; Vision Health

Cost-Effectiveness Study Group. Forecasting age-related macular degeneration through the year 2050—the potential impact of new treatments. *Arch Ophthalmol.* 2009;127(4):533-40.

2. Nazari H, Zhang L, Zhu D, et al. Stem cell based therapies for age-related macular degeneration: The promises and the challenges. *Progress in Retinal and Eye Research.* 2015;48:1-39.

4. Kashani AH. Stem cell therapy in nonneovascular age-related macular degeneration. *Invest Ophthalmol Vis Sci.* 2016;57(5):ORSFm1-9.

3. Mandai M, Watanabe A, Kurimoto Y, et al. Autologous induced stem-cell-derived retinal cells for macular degeneration. *N Engl J Med.* 2017;376(11):1038-46.

5. da Cruz L, Fynes K, Georgiadis O, et al. Phase 1 clinical study of an embryonic stem cell-derived retinal pigment epithelium patch in age-related macular degeneration. *Nat Biotechnol.* 2018;36(4):328-37.

6. Kashani AH, Lebkowski JS, Rahhal FM, et al. A bioengineered retinal pigment epithelial monolayer for advanced, dry age-related macular degeneration. *Science Translational Medicine.* 2018;10(435).

7. Kashani AH, Chen CL, Gahm JK, et al. Optical coherence tomography angiography: A comprehensive review of current methods and clinical applications. *Progress in Retinal and Eye Research.* 2017;60:66-100.

Iontophoresis: Wave of the Future?

A low-level electrical current may turbo-charge topical drug delivery to the eye.

By Barbara Wirostko, MD, and Michael Raizman, MD

For years, researchers looked for ways to maximize the effects of topical treatments for chronic ocular conditions such as dry eye and uveitis. While eye drops are simple in theory, in practice they come with a host of issues that hamper their efficacy. Eye drops deliver a volume of 30µl to 50µl of medication to the eye, most of which drains into the nasolacrimal system or spills onto the lower lid—meaning only 1% to 5% of the drug is actually absorbed by the eye upon instillation.¹ This necessitates more

frequent dosing, which often results in poor compliance, reduced treatment effect, local tolerability issues and negative outcomes.

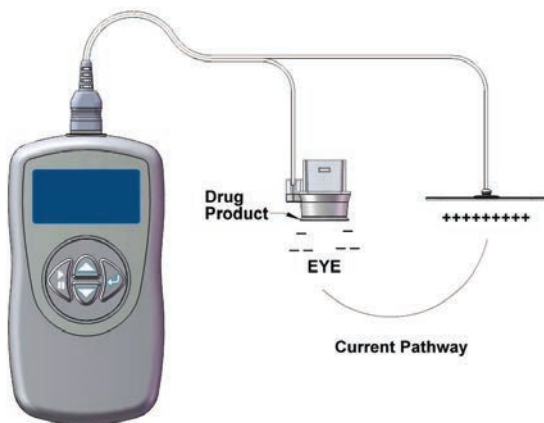
A novel drug delivery system that uses a small electrical current—known as iontophoresis—may soon reduce these limitations by allowing eye care practitioners to achieve topical delivery of concentrated medication through a simple, in-office process.

As the current (Dr. Wirostko) and former (Dr. Raizman) chief medical officers of EyeGate Pharmaceuticals—the company developing this technology—we have had the privilege of helping bring this exciting concept closer to realization as a commercially viable product. Here, we share what we have learned and where we anticipate the technology going.

1900s, only within the last few years have controlled clinical studies tested its efficacy.² Iontophoresis is a non-invasive process that allows a greater bioavailability of a drug to reach the anterior and posterior segments than is normally possible with topical application.³ It is also safer than systemic dosing, which exposes patients to a higher risk of system-wide adverse effects, and intravitreal injection, which is invasive and increases the risk of infection.³

Ocular drug delivery through iontophoresis follows the principle that like charges repel and opposite charges attract.⁴ This allows more effective penetration through ocular tissues by promoting the movement of a charged drug across biological membranes and enabling the delivery of negatively or positively charged therapeutics through tissues to targeted areas.^{3,4}

The amount of the drug that enters the eye can be controlled in two ways: the strength of the current and the duration of the treatment. By controlling the drug amount, the clinician can deliver therapeutic levels of the drug into the eye while minimizing systemic absorption.³ In a Phase III trial in anterior uveitis



The EyeGate II includes an applicator placed on the conjunctiva and a generator connected to an electrode attached to the patient's forehead.

A Shocking Discovery

While the concept of iontophoresis dates back to the early

patients, iontophoresis drug delivery reduced application of conventional topical drugs by almost 98%—two iontophoretic treatments were equivalent to 154 eye drops.⁵

Going Electric

The system developed by EyeGate Pharmaceuticals, called EyeGate II, uses an electrical field generated by a low-level current to enhance the mobility of charged particles.³ The device combines an applicator placed on the conjunctiva at the limbus and a generator connected to an electrode attached to the patient's forehead.³ The generator creates an electric field inside the applicator and an opposite charge on the electrode. The drug resides in the applicator and is propelled through the conjunctiva and sclera during the periods of electrical stimulation.³

The therapeutic agent, EGP-437, is a 40mg/mL dexamethasone phosphate (DP) formulation specifically developed for use in iontophoresis to treat inflammatory conditions such as anterior uveitis.⁵ This drug and the EyeGate II drug delivery system are under investigation.⁵

Study Notes

Upon assessing the safety and efficacy of EGP-437 in dry eye treatment, researchers found that ocular iontophoresis of the drug demonstrated statistically and clinically significant improvements in signs and symptoms within a controlled adverse environment model.⁶

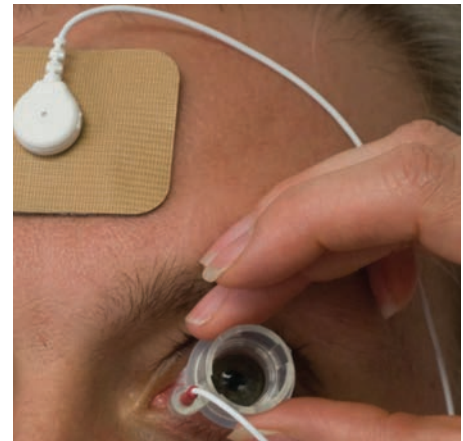The participants (103 dry eye patients) were randomly divided into three groups—low-dose, high-dose and placebo arms—with the following characteristics: 7.5mA/minute at 2.5mA with DP in the reservoir, 10.5mA/minute at 3.5mA with DP in the reservoir and 10.5mA/minute at 3.5mA with no DP in the reservoir.⁶ Patients were assessed seven

times over a three-week period prior to and following treatment with the EyeGate II system.

Although the primary endpoints concerning improvement in signs and symptoms at the fifth visit were not achieved, both therapeutic groups showed some statistically significant gains at various other time points.⁶ The low-dose protocol appeared more effective than the high-dose regimen; the researchers proposed that this may be because the high-dose application drove the therapeutic agent too deeply into the globe, reducing efficacy relative to the lower-dose effect.

The low-dose group also exhibited statistically significant improvements in corneal staining, ocular protection index and ocular discomfort during follow-up visits.⁶ Clinical findings show that treatment-emergent adverse events (AEs) were experienced by 87% of patients and were consistent across all treatment groups.⁶ Most were mild, and no severe AEs were observed.⁶

Researchers from EyeGate also evaluated the toxicokinetics and tolerability of DP by transscleral iontophoretic delivery to rabbit eyes in a study that ultimately found repeated treatments might be safe to treat inflammatory ocular disorders that require prolonged or repeated corticosteroid therapy.⁷ Subjects received EGP-437 transsclerally once biweekly for 24 consecutive weeks at doses of 10mA/minute, 14mA/minute and 20mA/minute.⁷ The regimen was well-tolerated, and side effects either were expected reactions to the ocular applicator or the iontophoresis process or arose from factors unlikely related to the treatment.⁷ They note that there was no effect on intraocular pressure (IOP), electroretinography or histopathol-



The drug residing in the applicator is propelled through the conjunctiva and sclera during electrical stimulation.

ogy attributable to the medication or the iontophoresis treatment.⁷

One such circumstance requiring repeated corticosteroid use that may benefit from iontophoresis is post-cataract surgery. Visual recovery after cataract surgery can be delayed by inflammation, which can be caused by topical corticosteroids. In an effort to learn whether iontophoresis can help, a study presented at ARVO 2017 by Dr. Wirostko sought to determine the safety and efficacy of EGP-437 in managing post-surgical inflammation and pain.⁸

The study found that patients receiving the 4.5mA/minute and the 14mA/minute doses exhibited the best results, with 20% to 30% achieving an anterior chamber cell count of zero at day seven and 70% to 80% at day 28, 70% of 4.5mA/minute patients and 90% of 14mA/minute patients reporting no pain on day one and 0% experiencing elevated IOP.⁸ Post-op pain and inflammation were managed as early as days one and seven, respectively.⁸ The study concluded that the iontophoretic delivery of EGP-437 is a safe and effective way to deliver adequate amounts of steroids and has the potential to eliminate the daily



need for corticosteroid eye drops in post-cataract surgery patients.⁸

EyeGate researchers also looked into iontophoresis for anterior uveitis to establish safe, effective dose levels of EGP-437 and evaluate the systemic pharmacokinetic profile after a single iontophoresis administration of EGP-437 to 40 subjects at four different doses.⁹ The team found that following a single treatment with EGP-437, half of the patients achieved an anterior chamber cell count of zero within two weeks and the majority by day 28, requiring no further treatment.⁹ IOP and best-corrected visual acuities were not affected, and there was actually a lower incidence of increased IOP.⁹ While patients experienced low, short-term systemic exposure to dexamethasone following treatment, the researchers did not observe any corticosteroid mediated effects and add that the majority of AEs were mild.⁹

To date, roughly 2,000 EGP-437 iontophoretic treatments have been delivered to patients with anterior segment inflammation, posterior retinal edema or both, demonstrating the safety and utility of this product.

More recently, a team of researchers conducted the first-in-human, randomized, double-masked, dose-escalating study of iontophoretic administration of DP for scleritis, suggesting the iontophoretic delivery of corticosteroids to be a promising, well-tolerated and safe potential treatment.¹⁰ They found the lowest dose (1.2mA/minute at 0.4mA) to be the most efficacious, with five out of seven eyes meeting the primary efficacy outcome within 28 days.¹⁰

Commercialization Nears

After more than a decade of R&D, some of these efforts are approaching commercialization. EyeGate completed the second Phase III study in mid-2018 looking at the application of the EGP-437 in anterior uveitis and is continuing to assess the next steps toward approval. Once clinicians have access to the EyeGate II system, the eye care community will be able to learn more about its real-world performance and, ultimately, where it fits in the overall treatment armamentarium. ■

Dr. Wirostko is the chief medical officer of EyeGate Pharmaceuticals and an adjunct professor at the Uni-

versity of Utah. She practices at the John A. Moran Eye Center at the University of Utah.

Dr. Raizman is a consultant for the Ophthalmic Consultants of Boston, the director of the Cornea Fellowship and the Cornea and Cataract Service at the New England Eye Center, Tufts Medical Center and a professor at the Tufts University School of Medicine. He was the former chief medical officer of EyeGate Pharmaceuticals.

1. Novack GD. Ophthalmic drug delivery: development and regulatory considerations. *Clin Pharmacol Ther.* 2009;85(5):539-43.
2. Myles ME, Neumann DM, Hill JM. Recent progress in ocular drug delivery for posterior segment disease: emphasis on transscleral iontophoresis. *Adv Drug Deliv Rev.* 2005;57(14):2063-79.
3. Than TP, Chaglasian EL. Ocular drug delivery—pressing forward. *RCCL.* 2013;150(7):12-3.
4. Eljarrat-Binstock E, Domb AJ. Iontophoresis: a non-invasive ocular drug delivery. *J Control Release.* 2006;110(3):479-89.
5. EyeGate Pharma. www.eyegatepharma.com. Accessed January 10, 2019.
6. Patane MA, Cohen A, From S, et al. Ocular iontophoresis of EGP-437 (dexamethasone phosphate) in dry eye patients: results of a randomized clinical trial. *Clin Ophthalmol.* 2011;2011(5):633-43.
7. Patane MA, Schubert W, Sanford T, et al. Evaluation of ocular and general safety following repeated dosing of dexamethasone phosphate delivered by transscleral iontophoresis in rabbits. *J Ocul Pharmacol Ther.* 2013;29(8).
8. Wirostko BM, Assang CM, Mann B, et al. Efficacy and safety of an iontophoresis platform to manage post-cataract inflammation and pain. Poster. ARVO. 2017.
9. Patane MA, Cohen A, Assang CM, et al. Randomized, double-masked study of EGP-437 in subjects with non-infectious anterior segment uveitis. Poster. AAO. 2010.
10. O'Neil EC, Huang J, Suhler EB, et al. Iontophoretic delivery of dexamethasone phosphate for non-infectious, non-necrotizing anterior scleritis, dose-finding clinical trial. *Br J Ophthalmol.* 2018;102(8):1011-3.

While You Were Sleeping

A new phototherapeutic contact lens, worn overnight, could effectively address diabetic retinopathy progression.

By Mark De Leon, Associate Editor

Ocular involvement in diabetes is a near certainty as time goes on. Already, more than four million Americans experience some form of visual impairment from diabetic retinopathy (DR), and with the rates of diabetes steadily rising,

eye care practitioners can expect far more cases.¹ As in so many chronic conditions, therapy is often hampered by patient compliance issues, diminished efficacy over time and adverse effects.

Right now, the therapies retina specialists turn to are rather crude:

burning the peripheral retinal with laser photocoagulation to reduce the metabolic demands that give rise to new vessel growth, or injecting anti-VEGF roughly every six weeks to arrest angiogenesis. Neither of these therapies are patient-friendly nor particularly effective long-term. An

“

Because the **VeraPlug FlexFit** is so comfortable, **my patients are happier** — and with the easy insertion, the FlexFit has become my **plug of choice** for treating dry eye patients. ”

Yun Jin Kim, M.D. | EyeCare Medical, Los Angeles, CA

The word is out

Doctors are praising the **VeraPlug™FlexFit™** for its simple sizing, ease of insertion and excellent patient comfort.



A FRESH PERSPECTIVE™

lacrivera.com (855) 857-0518

2500 Sandersville Rd • Lexington KY 40511 USA

© 2019 Lacriversa, a division of Stephens Instruments. All rights reserved.



LACRIVERA®



interdisciplinary team of ophthalmologists and engineers have their sights set on reducing this treatment burden and are developing a new method of phototherapy using contact lenses that could improve outcomes and reduce the adverse effect profile of long-term management.

“The big problem with diabetes in the retina is that the hyperglycemic state influences the endothelial cells and pericytes and really starts to affect blood flow, and this results in ischemia,” says Mark A. Humayun, MD, PhD, professor of ophthalmology and biomedical engineering at the University of Southern California. His research team is partnering with engineers from California Institute of Technology led by Yu-Chong Tai, professor of electrical engineering and medical engineering. The groups have collaborated to design and test a glow-in-the-dark contact lens for patients to wear overnight.

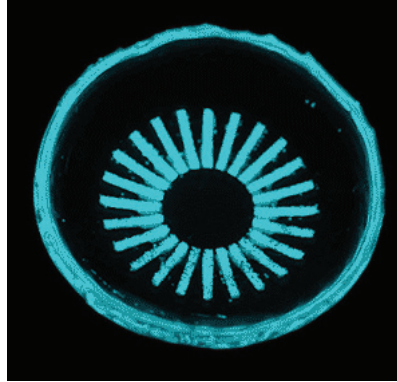
“The thought came to us—could we modulate ischemia? In the retina, you have a wonderful opportunity to do so during the nighttime period when it’s very metabolically active and requires a lot of oxygen,” says Dr. Humayun.

Gas Guzzlers

The impaired vision in low light conditions that marks the beginning of visual loss in people with diabetes suggests that DR affects rod function first.² This has subsequently been linked to increased oxygen consumption during dark adaptation, as well as retinal hypoxia and metabolic overload.³⁻⁶ This hypoxia upregulates VEGF and provokes the microvascular changes associated with the disease.

In the dark, rods consume more oxygen than any other cell in the body. When O₂ is reduced, rod sensitivity decreases.⁷ If retinal disease constrains oxygen availability as a

Photo: Caltech



This glow-in-the-dark contact lens could help reduce DR-related damage from nighttime rod cell metabolism.

result of decreased retinal circulation, or the relative demand for oxygen increases due to metabolic stress, an imbalance will lead to hypoxia in both the inner and outer retina.⁷

“We wanted to modulate the activity of the retina and therefore not outstrip the oxygen supply of the retina in a diabetic patient, where it is already compromised,” Dr. Humayun says.

Research suggests that preventing dark adaptation by delivering 507nm light to the retina during the night might reduce the risk of DR progression.² In 2017, PolyPhotonix Medical introduced the Noctura 400 Sleep Mask for treatment of late-stage DR patients and as a preventative measure for those at the early stages of the condition. The mask’s organic light emitting diodes (OLED) produce wavelengths that interact with the photoreceptors of the rods, but not those of the cones, at night, ensuring that it would not disturb the user’s sleep. The company suggested the OLED sleep masks would prevent the extra consumption of oxygen in dark adaptation while sleeping, which would then reduce inner retinal vascular stress.⁸

Published in *The Lancet Diabetes & Endocrinology* in early 2018,

the CLEOPATRA study assessed the two-year outcomes of using the Noctura in non-central diabetic macular edema (DME). The results show that the light mask was not an effective option. While it significantly reduced DME and visible cysts in outer ETDRS zones at 12 months, the effect did not translate to significant change in retinal thickness and it was not sustained, suggesting that any positive morphological effects are transient and minimal.⁹ The study also found compliance waned over time and 75% reporting adverse effects, primarily related to disturbed sleep.¹⁰

While the study did note that the light mask was not an effective option to treat non-central DME, it was still worth evaluating other phototherapeutic techniques of rod suppression in DR and DME, a pursuit in which the interdisciplinary team has taken great lengths to engage.

See the Light

According to a paper Dr. Tai presented at an engineering conference (MEMS 2018), a key factor likely contributing to disturbed sleep from phototherapy is the amount of time-varying stimuli on the retina that inevitably results from trans-eyelid illumination. Differential transmission of light through the eyelid, which varies in thickness, results in a spatially heterogeneous illumination field.¹¹ Since the eye moves with respect to this field, photoreceptors experience a time-varying illumination, to which the visual system is highly attuned.

If it were possible to fix the illumination field with respect to the eye—not the eyelid—the perception of the light stimuli would rapidly decay through a neural adaptation process known as the Troxler effect.¹² This would likely make phototherapy

more tolerable to patients. A second major limitation of trans-eyelid phototherapy is the uncertainty of photon dosing to the retina. Eyelid transmissivity is known to vary across the human population.¹³ Also, the eye rolls backward during sleep, which affects retinal dosage from the illumination source.

“We believe there are clear benefits to providing phototherapy from a source under the eyelid and immobilized with respect to the eye—and this is where contact lenses play a key role,” Dr. Tai wrote in his MEMS 2018 paper.¹¹ So, the team recently constructed a phototherapeutic contact lens that may help to manage DR by suppressing the dark current in the rod and reducing retinal metabolism.

Making Contact

Given that retinal hypoxia drives VEGF expression, the research team aimed to create a phototherapeutic contact lens that increased the minimum retinal oxygen tension by 100%. They used a silicone-based contact lens embedded with a ring of gaseous tritium light sources providing continuous illumination over the lifetime of the lens. Currently, the lens is made up of approved polymers that give it acceptable wettability, comfort and fouling resistance.

Using the 1D retinal model on theoretical estimation of retinal oxygenation during retinal artery occlusion, the team found that suppressing rod metabolism to 132mm Hg/s was necessary to double the minimum value of retinal oxygen tension. They then estimated that metabolic suppression required retinal irradiance of 30 photons/s/μm².¹¹

When designing the lighting system, the team took into account the limitations of a contact lens package size, reliability and safety. They ultimately decided to use radiolumi-

nescent gaseous tritium light sources (GTLS) to satisfy the design conditions. These light sources are composed of tritium gas encapsulated in a phosphor-coated glass shell, similar to those used in glow-in-the-dark markers seen on wristwatches.

The tritium emits a high-energy electron that strikes and excites the phosphor, leading to highly reliable light emission. The light sources’ minute profile (300μm D × 2000μm L) enables integration into thin contact lens designs. Dr. Tai’s team selected a green emitting phosphor to maximize stimulation of rod cells at 498nm peak absorbance. The sources have a 12-year half-life and do not emit any ionizing radiation outside the glass shell, making them remarkably safe and reliable. However, the team recommends the lens be replaced after one year of use.¹¹

According to Colin Cook, PhD, a researcher who worked closely with the contact lens engineering team in Dr. Tai’s lab during his doctoral program, fouling of the lens material due to repeated use is the limiting factor for the product’s lifetime.

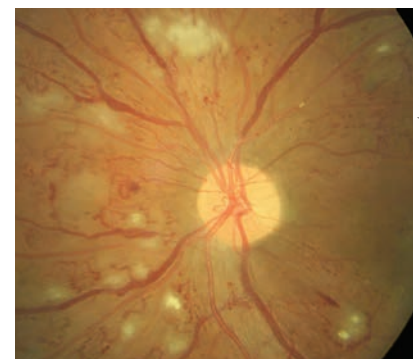The design has the GTLS arranged in an evenly spaced radial pattern starting at a radius of 1.5mm and ending at 3.5mm. “This annular arrangement of light sources provides an unobstructed view during photopic vision when the pupil is constricted, while directing the complete phototherapeutic dose through the dilated pupil under scotopic vision or sleep,” Dr. Tai explained in his paper.¹¹

Testing the design with a human eye ensured that this annular arrangement provided a sufficient artificial pupil under photopic, or well lit, vision, while the GTLS could pass light through the dilated pupil under scotopic, or low light, vision. The wearer reported the disappearance of the light stimuli within

several seconds since the contact lens was stationary on the eye under scotopic conditions; however, the patient could discern the light stimuli if the contact lens was manually repositioned on the eye.¹¹ “Given the stability of the lens on the eye, the speed and completeness of the Troxler effect is remarkable,” Dr. Cook says.

Dr. Cook and the rest of Dr. Tai’s team transferred the prototypes over to Dr. Humayun’s group who then investigated the bioactivity of the lens through electroretinogram (ERG) flash response recordings in rabbits. The analyzed recordings revealed that both the amplitude and implicit time of the b-wave in the treated eye was found to be significantly shorter than in the untreated eye, a noted characteristic of suppressed dark adaptation.¹⁴ Regarding the difference in b-wave amplitude, the phototherapeutic contact lens caused an average suppression of rod cell dark adaptation to 32 ± 2% of full dark adaptation.¹¹ Adjusting for likely human response would put the expected rod cell suppression in diabetes patients at approximately 50%, exceeding the design specification but well within a tunable range.¹¹

According to Dr. Humayun, they will need to collect human ERG



A light-emitting contact lens could potentially help slow down pathogenesis in early proliferative diabetic retinopathy.



data when possible to confirm or revise these estimates. He is also looking forward to verify and validate the lens on human test subjects as a baseline to understand what modifications and revisions need to be done in each future step. He encourages his colleagues to avoid over-engineering a prototype prior to human trials. “You have to do it safely, but there is a sense of urgency,” Dr. Humayun explains. “There are patients at the end of the day who could benefit from this.”

Ortho-K to the Rescue

Oxygen transmissivity of the lens has emerged as a key requirement to prevent corneal hypoxia during sleep. The FDA recommends a transmissivity of 125Fatt for overnight contact lenses.¹⁵ The 500 μ m thick lens has a transmissivity (Dk/t) of around 130Fatt, satisfying the FDA’s recommendation.

While many wear contact lenses in the daytime, the development of extended-wear lenses and orthokeratology (ortho-K) lenses has led to a better understanding of the requirements for overnight wear, including oxygen transmission.

Dr. Cook believes the key to ensuring long-term compliance with phototherapy for DR is coupling

it with ortho-K myopia correction. Thus, the patient is motivated to wear the lens nightly for their daily vision correction, but in doing so helps prevent retinopathy from developing. Dr. Cook has so far been able to produce lenses with dual phototherapy and corneal refractive therapy functionality.

Since completing his doctoral program at Caltech, Dr. Cook has founded Retinox Medical to help continue his work translating phototherapy technology out of the lab and into the clinic. Currently, he has built functioning prototypes that rely on the same phototherapeutic principle but differ in their mechanism of light generation. There is a light-emitting diode (LED) variant that provides the ability to control light intensity and allow photon dosage to be fine-tuned for patients. Dr. Cook has also built a chemiluminescent version that could provide a disposable option similar to daily contact lenses.

Night Moves

Dr. Humayun believes that the contact lens, if validated by human trials, could most likely be used with mild nonproliferative DR patients to prevent progression. However, he says, “if severe nonproliferative, or even patients at the proliferative stages, can benefit somewhat from using the contact lens, the patient’s current injection intervals could be prolonged and they could reduce the number of injections in a year.”

Dr. Humayun sees the contact lens working in both scenarios, but it is too early to tell because they have yet to demonstrate how much the lens can actually modulate metabolic function in a severely compromised eye. “If we can modulate only a little bit, then obviously it will work on the milder form of the disease, but if we can modulate a fair amount,

then can we work with the moderate and severe forms; in the latter two, it would be in combination with existing therapies,” Dr. Humayun notes.

Phototherapy represents a promising noninvasive preventative measure for diabetic retinopathy, and likely other hypoxic eye diseases such as macular edema and age-related macular degeneration. Incorporating a glow-in-the-dark light source for phototherapy inside an overnight lens could provide constant illumination to the retina while maintaining sleep quality. The lens may also combat patient compliance issues, as it minimally impacts the patient’s habits and quality of life. ■

1. Klein R, Klein BEK, Moss SE, et al. The Wisconsin epidemiologic study of diabetic retinopathy. *Arch Ophthalmol*. 1984;102(4):520-32.
2. Sivaprasad S, Arden G. Spare the rods and spoil the retina: revisited. *Eye (Lond)*. 2016;30(2):189-192.
3. Arden GB, Wolf JE, Tsang Y. Does dark adaptation exacerbate diabetic retinopathy? Evidence and a linking hypothesis. *Vision Res* 1998; 38: 1723-1729.
4. Drasdo N, Chiti Z, Owens DR, North RV. Effect of darkness on inner retinal hypoxia in diabetes. *Lancet*. 2002;359: 2251-2253.
5. Harris A, Arend O, Danis RP, et al. Hyperoxia improves contrast sensitivity in early diabetic retinopathy. *Br J Ophthalmol*. 1996;80:209-13.
6. Kurtenbach A, Maysner HM, Jagle H, Fritsche A, Zrenner E. Hyperoxia, hyperglycemia, and photoreceptor sensitivity in normal and diabetic subjects. *Vis Neurosci* 2006;23:651-661.
7. Arden GB, Ramsey DJ. Diabetic retinopathy and a novel treatment based on the biophysics of rod photoreceptors and dark adaptation. In: Kolb H, Fernandez E, Nelson R, ed. *Webvision: The Organization of the Retina and Visual System*. Salt Lake City, UT: University of Utah Health Sciences Center; 2015.
8. PolyPhotonix. Noctura 400 media pack: a new approach to the management of diabetic retinopathy. <https://noctura.com/wp-content/uploads/2017/12/Noctura-400-Media-Pack-20171214-01-1.pdf>. December 12, 2017. Accessed January 9, 2019.
9. Sivaprasad S, Vasconcelos JC, Prevost AT, et al. Clinical efficacy and safety of a light mask for prevention of dark adaptation in treating and preventing progression of early diabetic macular oedema at 24 months (CLEOPATRA): a multicentre, phase 3, randomised controlled trial. *Lancet Diabetes Endocrinol*. 2018;6:382-91.
10. Sahni JN, Czanner G, Gutu T. Safety and acceptability of an organic light-emitting diode sleep mask as a potential therapy for retinal disease. *Eye*. 2017;31(1):97-106.
11. Cook CA, Martinez-Camarillo JC, Yang Q, et al. Phototherapeutic contact lens for diabetic retinopathy. Paper presented at: 2018 IEEE Micro Electro Mechanical Systems; January 21-25, 2018; Belfast, UK.
12. Troxler IPV. Über das Verschwinden gegebener Gegenstände innerhalb unseres Gesichtskreises. *Ophthalmologische Bibliothek*. 1804;2(2).
13. Bierman A, Figueiro MG, Reg MS. Measuring and predicting eyelid spectral transmittance. *J Biomed Opt*. 2011;16(6):67011.
14. Cameron A, Mahroo O, Lamb T. Dark adaptation of human rod bipolar cells measured from the b-wave of the scotopic electroretinogram. *J Physiol*. 2006;575(2):507-26.
15. Harvit DM, Bonanno JA. Re-evaluation of the oxygen diffusion model for predicting minimum contact lens Dk/t values needed to avoid corneal anoxia. *Optom Vis Sci*. 1999;76(10):712-9.

Kids These Days

The contact lens format in general may not be suitable for all DR patients, but is particularly well suited to adolescents and young adults. Type 1 diabetes specifically affects juveniles, who must manage the condition for the rest of their life. Given the near universal onset of retinopathy within 15 years of diabetes, they represent a particularly vulnerable group. Also, adolescents represent a unique subpopulation from a compliance perspective, as they are under the supervision of parents who are likely to enforce adherence to the preventative regimen.

Hypochlorous Acid Solution
NOW Available Without a Prescription

zenoptiq™
Hypochlorous Acid Solution

zenoptiq™
0.01% Hypochlorous Acid

Daily Eyelid
& Eyelash Hygiene
Solution

Gentle | Soothing | All Natural



3.38oz (100mL)

zenoptiq™
0.0085% Hypochlorous Acid

Daily Eyelid
& Eyelash Hygiene
Solution

Gentle | Soothing | All Natural



2.0oz (60.0mL)

Daily Eyelid & Eyelash Cleanser

- Naturally removes foreign matter
- Nontoxic, nonirritating
- Has been shown in studies to reduce bacteria/microbes
- Formulated to relieve symptoms of MGD, Blepharitis and Dry Eye
- Available in 0.01 % HOCL spray and 0.0085% HOCL gel

LEARN MORE AT
zenoptiq.com



(866) 752-6006 – FocusLaboratories.com

Trademarks: Zenoptiq™ (Paragon BioTech, Inc.) | Copyright © 2018 Paragon BioTech, Inc. All Rights Reserved.

Earn up to
18 CE
Credits*

NEW TECHNOLOGIES
& TREATMENTS IN
2019 EYE CARE

RGVCE
REVIEW'S COMMITMENT TO
CONTINUING EDUCATION



Nashville

RECEIVE \$75 OFF
BEFORE MARCH 15, 2019

PROGRAM CHAIR



Paul M. Karpecki, OD, FAAO



Ben Gaddie, OD, FAAO



Jay M. Haynie, OD, FAAO

ABOUT

MAY 17-19, 2019

Join Review's *New Technologies & Treatments in Eye Care* May 17-19, 2019, at the *Gaylord Opryland* in Nashville.

This meeting provides up to **18*** COPE CE credits including interactive workshops!**

LOCATION

Gaylord Opryland

2800 Opryland Drive
Nashville, TN 37214
Reservations: 615 889-1000
DISCOUNTED RATE: \$209.00/night

Identify yourself as a participant of "*New Technologies and Treatments Nashville*" for discounted rate. Rooms limited.

REGISTRATION

Registration Cost: \$495

Early Bird Special: \$420
Special pricing ends March 15, 2019

ONLINE:
www.reviewsce.com/nashville2019

PHONE:
1-866-658-1772

E-MAIL:
reviewmeetings@jhihealth.com

REGISTER ONLINE: WWW.REVIEWSCE.COM/NASHVILLE2019

Administered by
RGVCE
REVIEW'S COMMITMENT TO
CONTINUING EDUCATION

cope[®]

*Approval pending

SALUS
UNIVERSITY
Pennsylvania College of Optometry

Partially supported by an
unrestricted educational grant from
Bausch & Lomb

RGVCE partners with Salus University for those ODs who are licensed in states that require university credit.
**Subject to change, separate registration required. See event website for complete details.

Registration Form

New Technologies & Treatments in Eye Care
May 17-19, 2019 • Nashville, Tennessee

Earn up to
**18 CE
Credits***

Registration Information

Today's Date _____

Name	Title	NPI # (NPI numbers will only be used for HCP reporting purposes)	
Practice Affiliation		License #/State	OE Tracker #
Work Mailing Address	City	State	Zip Code
Work Telephone	Cell	E-mail	Fax

Name Badge Information (please print clearly)

My Name	My Guest	Additional Guests
---------	----------	-------------------

Payment Information

OD Registration: \$495 (\$420 if registered by March 15, 2019)
(includes up to 18 hours of CE, breakfasts, lunches, and welcome reception)
Call 866-658-1772 for daily and student rates.

Rate per person	No. in party	Subtotal
_____	x 1	= \$ _____

Additional Guest(s): \$45 (12 years and older, welcome reception only) \$45 x _____ = \$ _____

Complimentary Workshops: simultaneous, separate registration required

- | | |
|---|---|
| <input type="checkbox"/> Dry Eye Disease (Sat. May 18, 2pm - 4pm) | <input type="checkbox"/> Retina Management (Sat. May 18, 4pm - 6pm) |
| <input type="checkbox"/> Glaucoma Management (Sat. May 18, 2pm - 4pm) | <input type="checkbox"/> Blepharitis/MGD (Sat. May 18, 4pm - 6pm) |

Check enclosed (make checks payable to *Jobson Healthcare, LLC*)

Charge my: American Express Mastercard Visa

Credit Card Number _____ Exp Date _____

Cardholder (print name) _____

Signature _____

CONFERENCE CANCELLATION POLICY

Full refund on registration fee until
March 15, 2019

50% refund on registration fee until
April 15, 2019

No refund past April 15, 2019

Mail Form: Review Group Meetings c/o Jobson
11 Campus Blvd, Ste. 100
Newtown Square, PA 19073

Fax Form: Review Group
610-492-1039

For more information or to register:
Call: 866-658-1772
E-mail: reviewmeetings@jhihealth.com

REGISTER BY E-MAIL: REVIEWMEETINGS@JHIHEALTH.COM OR CALL 866-658-1772

Administered by
RGVCE
REVIEW GROUP CONFERENCE
REGISTRATION VOUCHER

COPE
*Approval pending

SALUS
UNIVERSITY
Pennsylvania College of Optometry

Partially supported by an
unrestricted educational grant from
Bausch & Lomb

Visit www.reviewscce.com/events for any meeting changes or updates.

How to Succeed in Plaquenil Screenings

The spectrum of OCT findings associated with the medication can make incorporating the 2016 guidelines harder than you think. Here's help.

By Marlon Demeritt, OD, Sherrol Reynolds, OD, Diana Shechtman, OD, and Jennifer Davidson, OD

Plaquenil (hydroxy-chloroquine sulfate, Sanofi-Aventis) and the less-used chloroquine are antimalarial drugs with anti-inflammatory properties that are used for the management of a spectrum of inflammatory conditions. Plaquenil is less toxic than chloroquine; however, long-term use of either drug can result in macular toxicity, leading to devastating irreversible vision loss. The mechanism of this toxicity is not clearly understood, though it is believed that the drug molecule binds to melanin in the retinal pigment epithelium (RPE).¹ This leads to disruption and damage to the photoreceptors and outer nuclear and plexiform layer, sparing the foveal center and resulting in the “bull’s eye” appearance in the late stage of the disease. Binding of the drug to melanin in the RPE contributes to, or prolongs, its toxic effects.²

Plaquenil toxicity is typically asymptomatic in early stages, but over time can lead to severe vision loss and retinal damage. The risk of retinal toxicity was initially believed to be less than 1% after long-term (or a cumulative dosage of 1,000mg).³ The toxicity would double by 10 years, resulting in a 20% prevalence after 20 years.⁴ However, research now shows toxicity continues

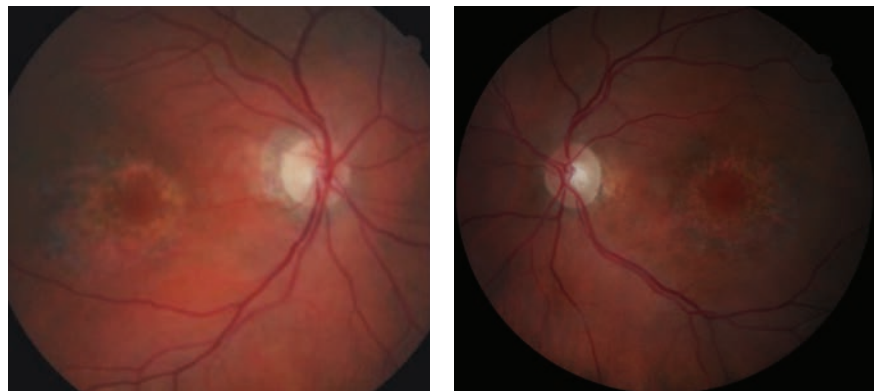
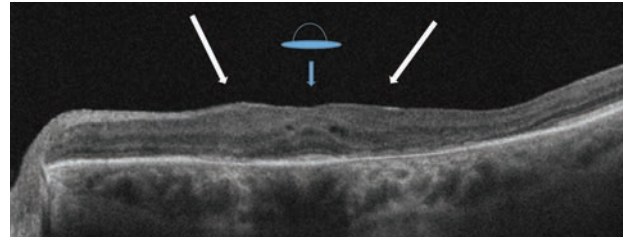
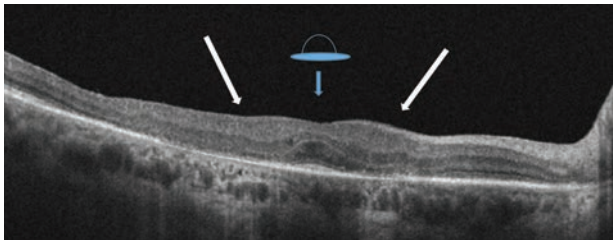


Fig. 1a and 1b. These fundus photos, of the right and left eyes respectively, reveal parafoveal ring-shaped “bull’s eye” RPE defects.

even after cessation of the drug.⁵ Thus preventing and detecting early effects of retinal toxicity prior to irreversible complications is key.⁶

Follow the Guides

The latest screening guidelines were published in 2016 by the American Academy of Ophthalmology (*Table 1*). The most important risk factors are dosage and duration of use. Dosage greater than 5.0mg/kg over five years dramatically increases the risk of retinal toxicity, and high doses can be exceedingly dangerous. As opposed to the 2011 guidelines, “real weight” is now considered a better indicator than “ideal weight” for calculating dosage for most patients. For example, for the maximum safe



Figs. 2a. and 2b. OCT of the right eye reveals a “flying saucer sign” of the macula with associated loss of the parafoveal IS/OS junction. Displacement of the inner retinal structures with loss of foveal contour unveils the “sinkhole sign” (see white arrows).

dose of 5.0mg/kg, the threshold dose would be 400mg/day for a patient weighing 175 pounds. Other major risk factors include concomitant renal disease, concomitant retinal disease and the use of tamoxifen (Table 2).^{7,8}

Currently, one of the primary functional screening tests recommended for the evaluation of Plaquenil retinal toxicity is 10-2 white stimulus automated visual fields; however, research shows Asian patients benefited from 24-2 or 30-2 visual fields, given that toxicity often manifests changes beyond the macula in these patients.⁹ Because spectral-domain optical coherence tomography (SD-OCT) is readily accessible and able to detect early structural damage prior to clinical funduscopic findings, it is now one of the primary objective screening tests. However, variable SD-OCT findings related to Plaquenil retinal toxicity can make the screening data challenging to interpret; thus, it is important that clinicians become familiar with the spectrum of SD-OCT findings.

Although multifocal electroretinogram (mfERG) and fundus autofluorescence (FAF) are not currently primary tests used in the evaluation of Plaquenil retinal toxicity, they may be beneficial when the diagnosis or findings are enigmatic or an adjunct test is warranted.

A review of the various OCT and visual field findings associated with retinal toxicity, as well as case presentations and illustrations, can help you be prepared when a patient on Plaquenil presents for an eye exam.

Case One

An 87-year-old Caucasian female presented complaining of blurred vision while reading with her current prescription. Her medical history revealed age-related macular degeneration that was diagnosed approximately 30 years ago (for which she uses AREDS2 supplements) and cataract surgery in both eyes with posterior chamber intraocular lens (IOL) implementation 10 years prior. Her medical history was remarkable for hypertension, hypocholesteremia and rheumatoid arthritis. She was currently taking an unknown beta-blocker and statin QD.

Her best-corrected acuities were 20/40+ OD and 20/30- OS. All preliminary testing, including pupils, extraocular motilities and confrontation fields, were unremarkable. Slit lamp exam only revealed posterior chamber IOLs OU. Intraocular pressures were 14mm Hg OU. A dilated fundus exam revealed unremarkable optic discs and normal physiological cupping. Parafoveal ring-shaped “bull’s eye” RPE defects in the macula of both eyes were also noted (Figures 1a and 1b). The vessels and peripheral exam did not reveal any abnormal findings in either eye. SD-OCT revealed “flying saucer” sign of the macula area with associated loss of the parafoveal IS/OS junction in both eyes, but intact subfoveally (Figures 2a and 2b). No associated drusen was noted.

The findings were suspicious for retinal toxicity, and the patient did reveal a history of Plaquenil use starting at age 30 and lasting for 15 years. She also recalled being asked to discontinue the medication due to an unspecified “retinal problem.” She was asked to return to clinic for 10-2 visual field testing and diagnosis and management were explained.

Case Two

A 26-year-old black female presented in office for her annual comprehensive eye exam. Her medical history was significant for Plaquenil therapy spanning 12 years with a daily dose of 200mg twice daily. She presented with a best-corrected visual acuity of 20/20 OD and 20/20 OS. All preliminary testing revealed normal findings. Slit lamp examination was unremarkable; however, her ancillary testing revealed macular changes compatible with early toxicity. Her SD-OCT reflected localized parafoveal thinning (Figures 3a and 3b). The Humphrey visual field 10-2 (white stimulus) was reliable, showing bilateral, although asymmetric, patchy parafoveal visual field defects (Figures 4a and 4b).

She was educated on the ocular effects of Plaquenil and the continuous monitoring and management. The corresponding prescribing physician was also advised on the findings.

Table 1. 2016 Risk Factors Associated with Retinal Toxicity

Major
Dosage: >5.0mg/kg real weight
Duration of use: >5 years, assuming no other risk factors
Renal disease: Subnormal glomerular filtration rate
Concomitant drugs: Tamoxifen use
Macular disease: May affect screening and susceptibility to Plaquenil and chloroquine
Lesser
Age, liver disease and genetic factors can be associated with retinal toxicity

Screening Protocol

Proper protocol implementation requires knowing when to evaluate patients on Plaquenil and what ancillary tests to perform. To start, have patients complete a questionnaire that answers the following:

- Are you currently taking Plaquenil? If yes, when did you start?
- What is your current dosage?
- What is your current weight?
- Have you previously had baseline ophthalmic testing?
 - Are you currently under the care of another optometrists or ophthalmologist?
 - How often do you see your rheumatologist?
 - Are you being treated for kidney disease?
 - Are you also taking tamoxifen?

See page 63 for a sample questionnaire; it is also available for download in the online version of this article at www.reviewofoptometry.com. To properly screen patients for Plaquenil toxicity, you should have SD-OCT and automated visual fields; it is also beneficial to include FAF and mfERG. Although the latest guidelines suggest that Amsler grid, color vision and fundus photography are not considered necessary for screening patients on Plaquenil, they can still provide useful information.

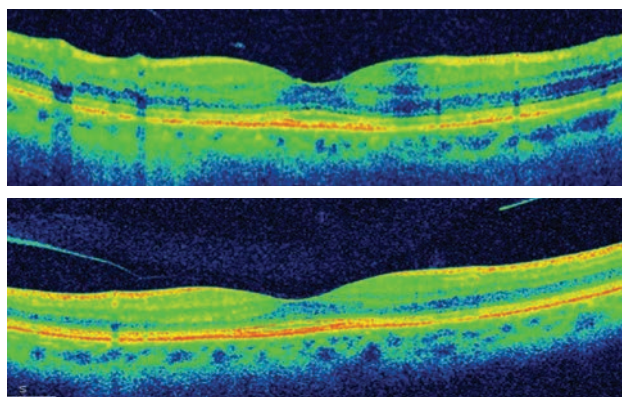
What tests do you need to perform during their baseline screening? During their baseline screening, you should perform Humphrey visual field testing 10-2 (white stimulus) for non-Asian patients to detect paracentral and central scotomas.⁹ For Asian patients, perform a 24-2 or 30-2 visual field to detect extramacular defects with a retest using 10-2 if any defects are detected.⁹ SD-OCT allows early detection of damage to the IS/OS junction before you observe retinal findings. Because early toxicity changes can be revealed on SD-OCT, it is prudent to perform a baseline screening of patients taking Plaquenil. Multifocal ERG has the

ability to detect early macular dysfunction, so it should be included as part of baseline screening. A maximum daily dose of Plaquenil of 5.0mg/kg real weight is recommended. Communication with the prescribing physician is also key to proper treatment and management of your patient.

Signs

Eyes affected by Plaquenil toxicity can be diagnosed based on one or more of several possible telltale presentations ranging from structural changes visible on imaging equipment to functional changes detectable via testing. These include:

OCT. The classic retinal toxicity has been described as “bull’s-eye maculopathy,” with the appearance of a ring of parafoveal RPE depigmentation that spares the fovea (see case presented). The presence of bull’s-eye maculopathy indicates the disease has been progressing for years, resulting in foveal thinning and likely vision loss.⁸ SD-OCT is a highly sensitive and reproducible imaging modality used in the detection of Plaquenil retinal toxicity. The preferential loss of photoreceptor IS/OS junction makes SD-OCT an ideal tool to identify early



Figs. 3a. and 3b. High-resolution OCT demonstrating localized parafoveal thinning in a patient with early Plaquenil toxicity.

Table 2. 2016 Screening Guidelines for Plaquenil Retinal Toxicity

Recommended Tests	Newer Tests of Possible Value in Future	Not Recommended for Screening
<i>Primary tests (do both):</i> <ul style="list-style-type: none"> Automated visual fields SD-OCT 	<ul style="list-style-type: none"> Microperimetry Adaptive optics retinal imaging 	<ul style="list-style-type: none"> Fundus examination Time-domain OCT Fluorescein angiography Full-field ERG Amsler grid Color testing EOG
<i>Other objective tests (as needed):</i> <ul style="list-style-type: none"> mfERG FAF 		

changes associated with Plaquenil retinal toxicity. Due to the capabilities of SD-OCT to enhance the structural assessment of the retina, it has allowed for the detection of early damage prior to fundoscopic clinical findings. Yet, there are variable SD-OCT findings associated with Plaquenil retinal toxicity.

The earliest finding is disruption of the parafoveal photoreceptor inner segment/outer segment (IS/OS) junction, also known as ellipsoid zone or photoreceptor integrity line (Figure 5).¹⁰ This disruption is considered one of the strongest indications of early retinal toxicity.¹⁰ Early loss of the IS/OS parafoveal junction may be denoted as the attenuation of the homogenous IS/OS junction reflectivity line. This loss may also correlate with a localized parafoveal thinning in the topographical map (Figure 6). In addition, this may correlate to the paracentral scotomas often seen in patients with early toxicity. (Figure 4a and 4b)

The more moderate stage of toxicity may be followed by diffuse parafoveal outer nuclear layer (ONL) with inner plexiform layer (IPL) changes (Figure 7).¹⁰⁻¹² Inner retina damage is often a consequence of outer retinal damage.

Disruption and loss of the external limiting membrane (ELM) may also be an early OCT finding (Figure 6).¹³ The ELM is theorized to play an important role in maintaining homeostasis of the photoreceptors and outer nuclear layer.¹⁴ Patients with an intact ELM at diagnosis of toxicity had a better prognosis and were unlikely to progress, whereas those with ELM disruption were more likely to show progressive changes on SD-OCT.



The Future Is **Now**
 The Ophthalmic Industry
 Is Going Digital
 And for Good Reason.

1. Greater Efficiency & Accuracy.
2. Large Return on Investment.
3. Increased Capabilities, Integration and Connectivity.

**Focus on the Patient,
 Not Repetitive Data Entries**

- Dual cross cylinder
- Programmable sequences
- Wireless interface with pre-test equipment.

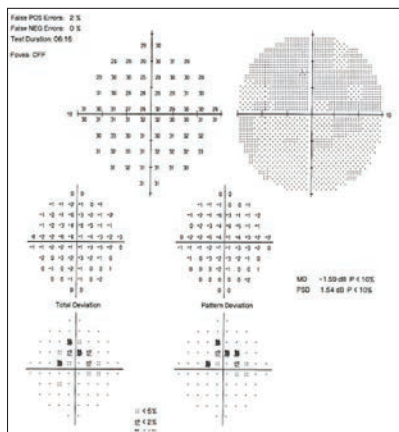

Don't Get Left Behind

IT'S TIME TO GO DIGITAL

Contact Us Today

Veatch Ophthalmic Instruments

www.VOI2020.com | 800.447.7511



Figs. 4a. and 4b. Visual fields of the right and left eyes reveal paracentral scotoma consistent with Plaquenil toxicity.

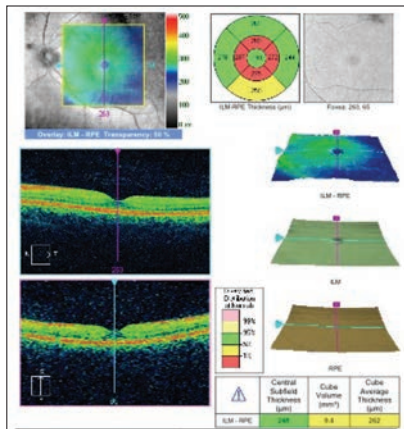


Fig. 5. Early SD-OCT finding showing disruption of the parafoveal photoreceptor inner segment/outer segment junction.

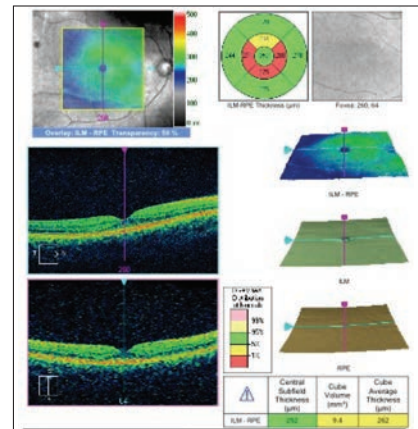


Fig. 6. Localized parafoveal thinning noted in the topographical map often correlates with IS/OS defects early in the disease course.

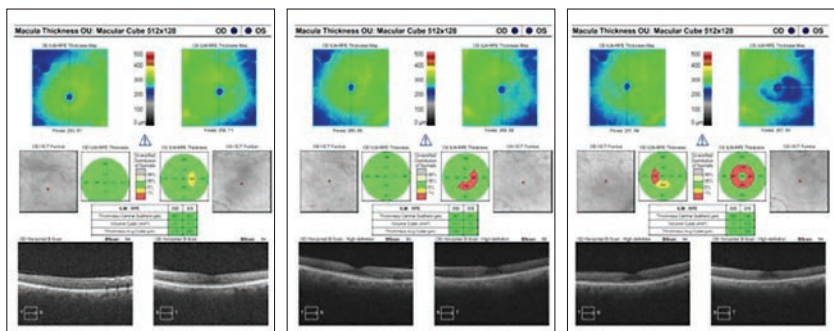


Fig. 7. High-definition OCT reveals moderate plaquenil-related damage with diffuse parafoveal ONL and IPL changes.

Increased thickness of the RPE-Bruch's membrane complex in Plaquenil patients has also been reported as an early sign. As the drug binds to melanin in the RPE, it causes degenerative changes, which leads to alteration in RPE metabolism that contributes to the changes in the RPE-Bruch's complex.¹⁵ Investigators believe that thickening of the outer band results from thickening of Bruch's membrane.

The "Sinkhole" sign (Figure 2a and 2b) shows displacement of the inner retinal structures toward the retinal RPE with variable loss of the foveal contour.¹⁵ A gap between the ONL (due to ONL thinning) associated with an intact external limiting membrane contributes to a sinkhole appearance and preservation of subfoveal outer layer. The subfoveal IS/OS junction is not affected in the late stage of the disease and associated with severe loss.¹⁶

The "Flying saucer" sign. (Figure 2a and 2b) this clas-

sic representation of Plaquenil toxicity is a preservation of the outer retinal layers subfoveally with perifoveal loss of the IS/OS junction on both sides of the fovea. Perifoveal IS/OS junction loss is associated with perifoveal outer retinal thinning, resulting in an ovoid appearance in the central retina, creating the flying saucer sign. The description of this sign was helpful in identifying retinal toxicity as presented in our cases.

Ganglion cell complex (GCC) defect and peripapillary NFL defects (Figures 8 and 9). A 2008 report described anatomical changes associated with GCC loss within the parafoveal region, in particular within the inferior temporal region. Hence, the perifoveal thinning noted on GCC may be attributed to selective thinning of the ganglion cell layer and inner plexiform layer.¹⁷

Visual fields. In early cases of Plaquenil toxicity, an early indicator of damage is the appearance of a paracentral scotoma seen on automated visual field testing

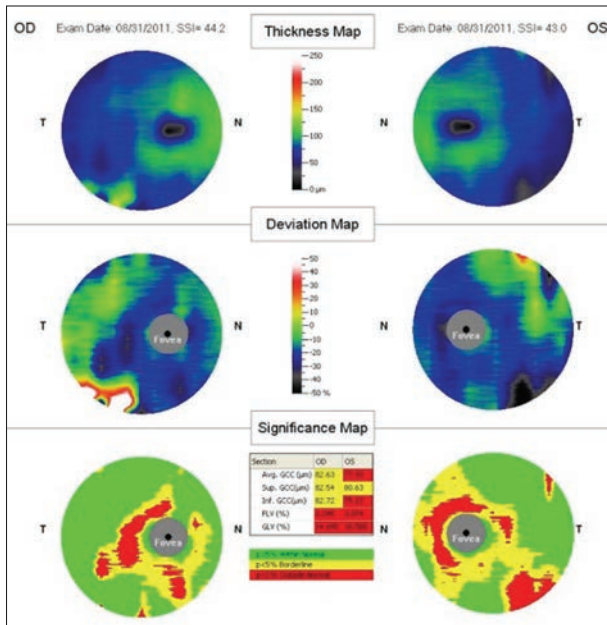


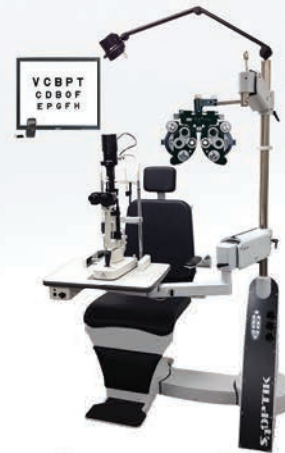Fig. 8. High-definition OCT revealing disruption and loss of the external limiting membrane as early OCT findings.

in the absence of fundus changes.¹⁸ Each of the testing strategies can be used to detect early toxicity changes, but the presentation of the visual field effects will vary. Due to the central area being depressed in the 24-2 and 30-2 testing strategies, it is difficult to discern the central 2-degree field of sparing seen in the 10-2 tests. You can conceivably misinterpret the visual field if the 24-2 or 30-2 testing strategies are used, because the scotoma may appear as a small central defect as opposed to a paracentral ring scotoma.

When using the larger testing strategies, a strong indication of Plaquenil toxicity is the presentation of a scotoma in the central 4 degrees of fixation.

Researchers suggest that one central point in both eyes indicates toxicity and one should have a low threshold with regards to any defects.¹⁹ The misinterpreted visual field defect using the larger testing strategies could potentially delay the diagnosis of Plaquenil toxicity resulting in irreversible vision loss. Due to the possibility of missing the scotoma while evaluating the greyscale, observation of the total deviation and pattern deviation could help elucidate if there is early retinal toxicity.

Similar to the 24-2 and 30-2 visual fields, where the central 4 degrees are affected by Plaquenil toxicity, the area of risk on a 10-2 is two degrees to six degrees from center.¹⁹ Due to the inevitability of missed subtle defects, deviation plots should be reviewed. In the



Exam Lane Packages

*Opening a new practice?
Looking to upgrade your equipment?*

**Veatch exam lanes are an investment
in your patients, your equipment
and your business.**

Bundled Packages: Save Time and Money

- Visual acuity system
- Manual or Digital Refractor
- Exam chair & stand

The Quality Tools You Need At A Price You Can Afford

Don't Get Left Behind

IT'S TIME TO GO DIGITAL

Contact Us Today

Veatch Ophthalmic Instruments

www.VOI2020.com | 800.447.7511

literature, it has been suggested that the superior visual field is affected first.²⁰ Those findings were corroborated in 2011, when researchers noted the superior visual field was affected more in seven out of 15 patients.¹⁹ Evaluation of the greyscale will reveal a paracentral ring scotoma, but a subtle abnormality may be easier to detect on the pattern deviation. The choice of HVF 10-2 with the red stimulus or without the red stimulus is controversial.

The 10-2 HVF with red stimulus was touted as the testing strategy of choice due to its 91% sensitivity for detection of Plaquenil toxicity; however, there is only a 57% specificity.¹⁸ On the converse, the 10-2 white stimulus testing strategy has a lower sensitivity of 78%, but it has a better specificity of 84%.

Eye care specialists provide a valuable service when screening for Plaquenil retinal toxicity and advising the treating physician or rheumatologist with regards to the patient's risk, safe dosing and appropriate screening procedures. With the updates of the new guidelines regarding screening for Plaquenil-related retinal toxicity, we must be more vigilant in the aggressive and thorough imaging and interpretation of such diagnostic tests. Hence, it is imperative that we become familiar with recognizing the spectrum of HVF and SD-OCT

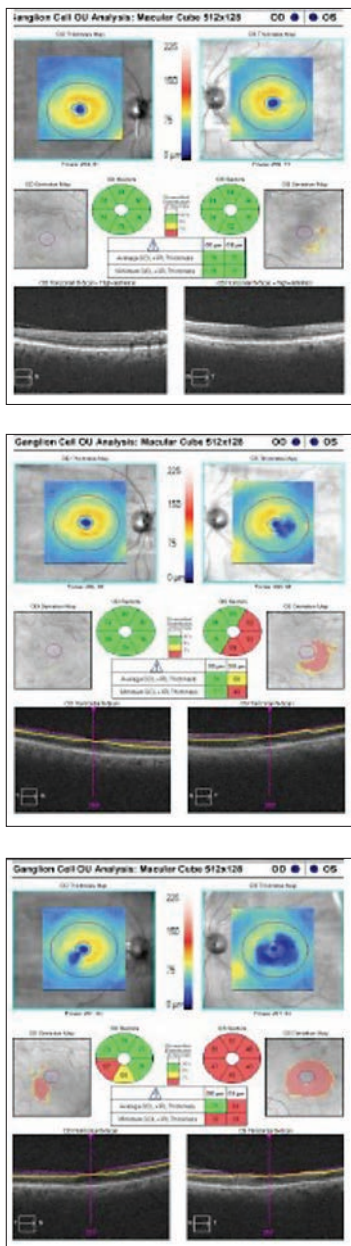


Fig. 9 Cirrus SD-OCT demonstrating progressive GCC damage within the parafoveal and temporal region.



Facing page: This questionnaire is designed to help identify patients with Plaquenil toxicity. Feel free to photocopy it and use it in your own practice. To download a PDF, read this article online at www.reviewofoptometry.com or scan the QR code.

findings associated with Plaquenil retinal toxicity. Of note, SD-OCT, in combination with Humphrey visual field testing, is critical for the early detection of Plaquenil retinal toxicity. ■

Dr. Demeritt is an assistant professor at Nova Southeastern University College of Optometry.

Dr. Reynolds is an associate professor of optometry at Nova Southeastern University College of Optometry.

Dr. Shechtman is a professor of optometry at Nova Southeastern University College of Optometry.

Dr. Davidson is a locum optometrist and 2016 graduate of Nova Southeastern University.

- Sundelin SP, Terman A. Different elements of chloroquine and hydroxychloroquine on lysosomal function in cultured retinal pigment epithelial cells. *APMIS*. 2002;100:481-9.
- Gamanu (Panca) A, Popa-Cherecheanu A, Marinescu B, et al. Retinal toxicity associated with chronic exposure to hydroxychloroquine and its ocular screening. *Review. J Med Life*. 2014;7(3):322-6.
- Bernstein H. Ocular safety of hydroxychloroquine sulfate (Plaquenil). *South Med J*. 1992;85(3):274-9.
- Marmor M, Kellner U, Lai T, et al. Revised recommendations on screening for chloroquine and hydroxychloroquine retinopathy. *Ophthalmol*. 2011;118(2):415-22.
- Melles R, Marmor M. The risk of toxic retinopathy in patients on long-term hydroxychloroquine therapy. *JAMA Ophthalmol*. 2014;132(12):1453-60.
- Michaelides M, Niam H, Stover P, et al. Retinal toxicity associated with hydroxychloroquine and chloroquine risk factors, screening, and progression despite cessation of therapy. *Arch Ophthalmol*. 2011;129(1):30-9.
- Marmor M. Comparison of screening procedures in hydroxychloroquine toxicity. *Arch Ophthalmol*. 2012;130(4):461-9.
- Marmor M, Kellner U and Lai T. Recommendations on screening for chloroquine and hydroxychloroquine retinopathy. *Ophthalmol*. 2016;123(6):1386-94.
- Melles R, Michael F, Marmor M. Pericentral retinopathy and racial differences in hydroxychloroquine toxicity. *Ophthalmol*. 2015;122(1):110-6.
- Lally D, Heier J, Baurnal C, et al. Expanded spectral domain-OCT findings in the early detection of hydroxychloroquine retinopathy and changes following drug cessation. *Int J Retina Vitreous*. 2016;2:18.
- Korah S, Kuriakose T. Optical coherence tomography in a patient with chloroquine-induced maculopathy. *Indian J Ophthalmol*. 2008;56(6):511-3.
- Kellner S, Weinitz S, Kellner U. Spectral domain optical coherence tomography detects early stages of chloroquine retinopathy similar to multifocal electroretinography, fundus autofluorescence and near-infrared autofluorescence. *Br J Ophthalmol*. 2009;93(11):1444-7.
- Uslu H, Gurler B, Yildirim A, et al. Effect of hydroxychloroquine on the retinal layers: A quantitative evaluation with spectral-domain optical coherence tomography. *J Ophthalmol*. 2016:2016.
- Abramoff M, Garvin M, Sonka M. Retinal imaging and image analysis. *IEEE Trans Med Imaging*. 2010;3(7):169-208.
- Chen E, Brown D, Benz M, Fish R. Spectral domain optical coherence tomography as an effective screening test for hydroxychloroquine retinopathy (the "flying saucer" sign) *Clin Ophthalmol*. 2010;4:1151-8.
- Mittelteil M, Wong B, Brenner M, Bryar P. Progression of hydroxychloroquine toxic effects after drug therapy cessation: new evidence from multimodal imaging. *JAMA Ophthalmol*. 2013;131(9):1187-97.
- Rodriguez-Padilla J, Hedges T, Monson B, et al. High-speed ultra-high resolution optical coherence tomography findings in hydroxychloroquine retinopathy. *Arch Ophthalmol*. 2007;125(6):775-80.
- Easterbrook E. Ocular effects and safety of antimalarial agents. *Am J Med*. 1988;85(4 S1):23-9.
- Anderson C, Blaha GR, Marx JL. Humphrey visual field findings in hydroxychloroquine toxicity. *Eye (Lond)*. 2011;25(12):1535-45.
- Hart W, Burde R, Johnston G, Drews R. Static perimetry in chloroquine retinopathy: perifoveal patterns of visual field depression. *Arch Ophthalmol*. 1984;102:377-80.

Today's Date: ___/___/___

HCQ QUESTIONNAIRE

Name: _____ **Age:** _____ **Weight** (important for medication dosage): _____ **Date of Birth:** ___/___/___

Race: American Indian or Alaska Native Native Hawaiian or Other Pacific Islander Asian Black or African American Caucasian

Primary Care Physician: _____ **Last seen:** _____

Referring /Specialty Dr. _____ **Last seen:** _____

Are you currently under the care of an ophthalmologist or optometrist?

Yes No If yes, please include name and date last seen _____

Have you ever had ocular baseline testing done?

Yes No Unsure

Which medication are you taking that you are being monitored for ocular toxicity?

Chloroquine Hydroxychloroquine Other: _____

Dosage: _____ **Duration:** _____

Why are you taking this medication?

Lupus Rheumatoid Arthritis. Other: _____

Are you currently being treated or monitored for kidney disease?

Yes No

Any recent major weight loss?

Yes No

Are you also using the medication Tamoxifen (commonly used to prevent breast cancer)?

Yes No

Any changes in your vision or color vision?

Yes No If yes, please explain: _____

Any changes seen with your at home Amsler grid testing?

Yes No Unsure If yes, please attach Amsler with explanation _____

Signature: _____ **Date:** _____

Signature if other than patient: _____ **Date:** _____

Relationship to patient: _____

The Neurologic Exam, Step-by-step

This case-based review will help you assess beyond each patient's visual presentation and uncover key clinical signs of neurologic dysfunction.

By Ashley Kay Maglione, OD, and Kelly Seidler, OD

Because the eye is an extension of the brain, a neurologic examination can be a crucial diagnostic tool. The neuro exam allows you to assess structures neighboring those that are important to vision and can help determine the level of urgency for a patient's ocular findings such as visual field defects, cranial neuropathies, double vision, optic neuropathy, ptosis, pupillary abnormalities and loss of vision. It may increase your clinical suspicion for underlying etiologies, including stroke, space-occupying lesion and demyelinating disease, among others.

Incorporating the neurologic exam into your tool box will help you provide exceptional care to your patients. Here we show you how and provide several case examples.

The Five-step Exam

As important as the neurologic exam is, it doesn't take advanced technology to perform, and the tools are readily available in an optomet-

ric office. Clinicians can tackle the neurologic examination by breaking it into five sections:

1. Mental status. Many practitioners assess mental status at the beginning of the exam and, for healthy patients, write "A&Ox3," representing Alert and Oriented to (1) person, (2) place and (3) time. If the patient is answering your questions inappropriately and seems confused or disoriented, you may choose to perform a mini mental status exam (MMSE). This questionnaire is designed to assess different aspects of cognitive function, including orientation, recall and language. The MMSE is quick and requires no training, although it may not detect mild cognitive decline.¹

2. Cranial nerve testing. You will already have tested four of the 12 cranial nerves (CNs) during your routine eye exam: II, III, IV and VI. Before you tackle your first neurologic exam, we recommend you review the anatomical locations and pathways of the cranial nerves.

Cranial nerve testing can provide strong localizing data for a lesion. For example, if multiple cranial nerves are affected, the clinician can consider where cranial nerves share a common space, such as within the cavernous sinus (recall that CN III, IV, VI, the ophthalmic division of the trigeminal nerve, or V₁, and the maxillary division of the trigeminal nerve, or V₂, course here) or the superior orbital fissure (which contains CN III, IV, VI and the frontal, lacrimal and nasociliary branches of the trigeminal nerve). *Table 1* reviews CN functions and outlines how to test for any dysfunction during a neurologic examination. Here is a brief review of the clinical applications of testing each cranial nerve:²

CNI: This nerve is often not tested unless a frontal tumor is suspected, such as in Foster-Kennedy syndrome, which is characterized by pallor of one optic nerve due to compression and edema of the contralateral nerve due to increased intracranial pressure.

CN II: This afferent nerve is assessed during visual acuity, color vision, pupil testing with the swinging flashlight test for afferent pupillary defect and visual field testing (see “*Beyond Visual Field Testing*”).

CN III: This is routinely tested with extraocular motility. It innervates the levator palpebrae superioris (elevation of the upper eyelid) as well as four of the six extraocular muscles and is involved in elevation, depression and adduction of the eye. It is also involved in pupillary constriction. A pupil-involved CN III palsy is more concerning for an aneurysm because pupillary fibers travel on the external surface of the nerve and are subject to compression

CN IV: This is also routinely tested with extraocular motility. It innervates the superior oblique muscle involved in depression of the adducted eye, as well as intorsion. Cover testing in multiple positions of gaze demonstrates a hyper deviation worse on contralateral gaze and ipsilateral head tilt.

CN V: Reduced sensation in the distributions of V₁ and V₂ may indicate a cavernous sinus lesion, especially in cases of CN III, IV and/or VI dysfunction.

CN VI: Routinely tested with extraocular motility, CN VI innervates the lateral rectus muscle which abducts the eye. Abduction deficits may be found in cases of increased intracranial pressure.

CN VII: This is a helpful test when you note facial asymmetry or an abduction deficit. An upper motor neuron lesion of CN VII (such as a stroke) will spare the forehead and indicates damage in the cerebrum. A lower motor neuron will affect the entire half of the face.

CN VIII: In a patient with an abduction deficit, it is important to test hearing due to the close relationship of cranial nerves VI, VII and

VIII in the cerebellopontine angle. A patient with an abduction deficit and hearing loss on one side would localize to this region and would be concerning for a lesion such as an acoustic neuroma. Unilateral hearing

loss is rarely due to a central lesion within the brain due to the extensive crossing of the auditory pathway.

CN VIII is also involved in the vestibular system, which is responsible for balance, proprioception

Beyond Visual Field Testing

Visual field testing can unmask a number of associated neurologic conditions, given the expansive visual pathway. The anatomy of the visual pathway allows defects to be localized to anterior to the chiasm, the chiasm and posterior to the chiasm.

If testing reveals a bitemporal hemianopsia, the lesion can be localized to the chiasm due to the anatomical crossing of the nasal retinal fibers. A pituitary adenoma is a common pathology that causes compression of the chiasm. In these cases, you must pay careful attention to extraocular motilities, as the cavernous sinus is adjacent to the sella. Recall CN III, IV, and VI course through the cavernous sinus and may be affected if there is lateral expansion of a sellar mass. In addition, by performing a neurologic exam you can assess the remaining cranial nerves within the cavernous sinus (CN V₁ and V₂).

A homonymous hemianopia visual field defect suggests pathology posterior to the chiasm. Additional neurologic exam findings may help you to localize the lesion to the optic tract, parietal or temporal radiations, or the occipital lobe. For instance, should you detect weakness of the extremities on the same side as the patient’s hemianopia, consider an optic tract lesion. Anatomically, the optic tract runs adjacent to the crus cerebri, which carries the descending motor pathway in the midbrain. A lesion in this region is above the crossing of the motor pathway; therefore, weakness will be on the contralateral side. Thus, a patient with a right homonymous hemianopia and right-sided weakness may have a lesion affecting the left optic tract and left crus cerebri.

Moving posterior, lesions of the optic radiations within the parietal and temporal lobes often have neurologic signs. A homonymous hemianopia denser above suggests pathology to the optic radiations that course through the temporal lobe; accompanying cognitive impairment may indicate the need for an MMSE. A homonymous hemianopia denser below accompanied by language deficits may suggest a lesion within the parietal lobe. Conversely, a visual field defect in the absence of other neurologic findings often localizes to the occipital lobe.¹

1. Goodwin D. Homonymous hemianopia: challenges and solutions. *Clinical Ophthalmol.* 2014;8:1919-27.

Visual Field and Neurologic Deficits

Visual Field Defect	Localization	Additional Considerations
Bitemporal hemianopia	Optic chiasm	<ul style="list-style-type: none"> Pay attention to extraocular motilities (functions of CN III, IV and VI) and facial sensation, given the proximity of the cavernous sinus to the chiasm.
Non-congruous homonymous hemianopia	Optic tract	<ul style="list-style-type: none"> Assess motor function due to the proximity between crus cerebri and optic tract.
Homonymous hemianopia denser above	Temporal lobe	<ul style="list-style-type: none"> Perform an MMSE. Check for memory impairment.
Homonymous hemianopia denser below	Parietal lobe	<ul style="list-style-type: none"> Look for language deficits.
Quadrantanopia	Occipital lobe	<ul style="list-style-type: none"> This would elicit a normal neurologic exam.

and eye movements, including the vestibulo-ocular reflex. Disruption to this system can manifest clinically as nystagmus which may be seen in conditions such as Meniere's disease.

CN IX and X: These are not examined separately; their close anatomic relationship rarely results in isolated lesions. Dysfunction of these nerves or the structures that they innervate may be indicated by dysphonia, dysphagia or dyspnea. Pay special attention to CN IX and X in patients with diplopia, ptosis or both, as they may be involved in

myasthenia gravis, therefore raising clinical suspicion for disease of the neuromuscular junction.

CN XI: Upper motor neuron lesions will relatively spare the sternocleidomastoid muscle function and comparatively affect the trapezius muscle function more. This is also important to test in cases suspicious for myasthenia gravis.

CN XII: The tongue will deviate to the contralateral side of an upper motor neuron lesion and to the ipsilateral side with a lower motor neuron lesion. Tongue atrophy is a sign

of a lower motor neuron lesion.

Cranial nerve testing clinical case. A poorly controlled diabetes patient presented with diplopia and an abduction deficit (75% of normal capability) concerning for a CN VI palsy. Neurologic examination revealed a subtle ipsilateral facial palsy that we could have easily missed with observation alone. All other testing of cranial nerve functions was normal. Despite the patient's vasculopathic risk factor of poorly controlled diabetes, the concurrent CN VII palsy raised

Table 1. Cranial Nerve Function and Testing³

Cranial Nerve	Function	Test
I – Olfactory	<ul style="list-style-type: none"> • Sense of smell 	<ul style="list-style-type: none"> • Ask patient to occlude one nostril and close their eyes. • Present a stimulus, such as coffee, and ask the patient to identify the smell.
II – Optic	<ul style="list-style-type: none"> • Vision 	<ul style="list-style-type: none"> • Visual acuity. • Color vision. • Visual fields. • Pupillary response to light to test for an afferent pupillary defect.
III – Oculomotor	<ul style="list-style-type: none"> • Ocular motility (superior, inferior and medial recti, inferior oblique) • Lid elevation (levator palpebrae superioris) • Pupillary constriction (efferent limb of light pathway) 	<ul style="list-style-type: none"> • Routinely tested during examination with extraocular motility. • Supraduction. • Infraduction. • Adduction.
IV – Trochlear	<ul style="list-style-type: none"> • Ocular motility (superior oblique) 	<ul style="list-style-type: none"> • Routinely tested during examination with extraocular motility. Infraduction upon adduction. • Intorsion.
V – Trigeminal	<ul style="list-style-type: none"> • Facial sensation • Muscles of mastication 	<ul style="list-style-type: none"> • Test the distributions of V₁, V₂ and V₃ separately with a light touch with a cotton wisp to the forehead, upper cheek and jaw, respectively, with the patient's eyes closed. Ask the patient to compare the sensation from right to left, looking for any asymmetry • Assess the motor function of V by feeling either side of the jaw just inferior and anterior to the ear for muscle contraction while asking the patient to clench their teeth. • If indicated, test the corneal reflex (afferent limb: ophthalmic, V₁ and efferent limb, V₂) with a cotton wisp.
VI – Abducens	<ul style="list-style-type: none"> • Ocular motility (abduction) 	<ul style="list-style-type: none"> • Routinely tested during examination with extraocular motility. • Abduction.
VII – Facial	<ul style="list-style-type: none"> • Muscles of facial expression • Taste to anterior 2/3 of tongue 	<ul style="list-style-type: none"> • Ask the patient to smile, raise their eyebrows, frown, puff out their cheeks and squeeze their eyelids tightly together while looking for any asymmetry or weakness.
VIII – Vestibulocochlear	<ul style="list-style-type: none"> • Auditory and vestibular systems 	<ul style="list-style-type: none"> • Hearing can be grossly checked by rubbing your fingers together near a patient's ear and asking if they can identify which ear hears the sound and if they notice any asymmetry in the volume of the sound.
IX – Glossopharyngeal X – Vagus	<ul style="list-style-type: none"> • Palate elevation, gag reflex/ swallowing • Speaking 	<ul style="list-style-type: none"> • Ask the patient to open their mouth and say "ahh" and look for any asymmetry in the palate or deviation of the uvula.
XI – Accessory	<ul style="list-style-type: none"> • Sternocleidomastoid and trapezius muscle 	<ul style="list-style-type: none"> • Ask the patient to turn their head side-to-side and shrug their shoulders looking for any asymmetry or weakness.
XII – Hypo-glossal	<ul style="list-style-type: none"> • Muscle action of the tongue 	<ul style="list-style-type: none"> • Ask the patient to stick their tongue out and note if it deviates to one side.

ADDRESS CONTACT LENS PROBLEMS BEFORE IT'S TOO LATE



By Paul M. Karpecki,
OD, FAAO

In the United States alone, 40.9 million adults wear contact lenses.¹ That seems like a lot, but this number would be far greater if contact lens dropout rates were not so high. Contact lens dropout continues to plague our industry and can negatively affect our practices and our relationships with our patients.

Over the years, lens manufacturers have endeavored to improve materials and encourage patients to move to daily disposable options, yet dropout rates are currently estimated to be at around 15.9%.² In other words, not all of our patients' problems can be overcome by switching lenses.

A broader view of the patient and his or her contact lens wearing experience is required. Fortunately, we now have better tools to achieve this. Bruder Healthcare recently announced the immediate availability of the Eyeleve™ Contact Lens Compress, the first and only compress clinically proven to increase comfortable contact lens wear time by up to 3 hours daily.² Read on for more about why this compress is so effective and for details on how you can position it in your contact lens practice to help drive growth and satisfaction.

Compresses Work Well for Contact Lens Wearers

In 2013, the International Workshop on Contact Lens Discomfort report concluded that the primary reasons for contact lens intolerance are discomfort and dryness.³ More recently, a 2017 study in *Contact Lens & Anterior Eye* found that end-of-day discomfort is a primary reason for contact lens dropout. A first step toward resolving these problems is to determine what's causing them in the first place.

As we've seen time and again in our practices, our contact lens wearers frequently present with dry eye and signs of meibomian gland disease (MGD). As such, supporting meibomian gland function is central to promoting a healthy lens wearing experience and will ultimately lead to improvements in comfort. Warm compresses are a mainstay clinical therapy for MGD generally⁴ and can be particularly helpful in contact lens wearers specifically.² However, it is imperative that your patient selects an effective compress. Compresses must maintain the right temperature for 8 to 10 minutes to increase meibum secretion and result in clinically meaningful improvement. Currently, only Bruder masks can achieve these clinical goals.

The Bruder Moist Heat Eye Compress underwent a clinical study at the School of Optometry at the University of Alabama in Birmingham.² The study found that subjects using the Bruder Compress daily had significantly improved meibomian gland function and experienced steeper declines in their overall Eye Discomfort Assessment scores. In fact, they ultimately increased comfortable wear time of their contact lenses by up to 3 hours.



Bruder

Choose Your Compress Wisely

As stated earlier, not all compresses are created equal. Compresses that contain gel, silica gel beads, or grains can dry out and deliver uneven heat, causing hot spots that are dangerous and reduce product performance. Only Bruder compresses contain patented MediBeads® Technology. MediBeads® provide clean, uniform heat. Their unique, honeycomb molecular structure encourages complete absorption of water molecules and, when microwaved, releases moist heat in a controlled and consistent manner. These unique benefits helped make the Bruder Mask the #1 doctor recommended moist heat eye compress. But, as we know, contact lens wearers have unique needs that even the Bruder mask was not initially designed to address.

For example, contact lens wearers have three times the usual levels of certain bacteria than the eyes of non-wearers. For this reason, the Eyeleve Contact Lens Compress utilizes an anti-microbial EyeOnic™ fabric material that has anti-microbial threads woven into the fabric of the compress to help reduce the risk of infections. Together with silver ion MediBeads®, this helps address eyelid hygiene and further reduces the risk of corneal infection. In addition, Eyeleve features a contoured comfort stitch to alleviate pressure off the eyes and avoid heat to the cornea.

Support and Grow Your Practice

Thanks to this addition to our armamentarium, we are better equipped to prevent patients from dropping out of lens wear. More importantly, we have a compress that was specifically designed to address the unique needs and concerns of a population that is otherwise likely to become disenchanted due to clinical challenges that, historically, we've been unable to overcome.

Fortunately, we can now proactively offer a compress that's proven to be clinically beneficial and to offer a meaningful benefit to contact lens patients. This can and should become an integral part of our initial dispensing visit. We can likewise present this more complete approach to patients who've been wearing their contacts for a while—especially as they age and are at greater risk of developing ocular surface problems.

For new contact lens wearers and for those who may already be experiencing discomfort, Eyeleve is a welcome addition. By recommending Eyeleve and suggesting it be part of our patients' daily contact lens routine, we are offering something that online retailers can't—a protocol and a partnership.

Product information is available at www.eyeleve.com, or contact Bruder Healthcare at 888-827-8337 to learn more.

1. Cope JR, Collier SA, Rao MM, et al. Contact Lens Wearer Demographics and Risk Behaviors for Contact Lens-Related Eye Infections, United States, 2014. 2015; <http://www.cdc.gov/mmwr/preview/mmwrhtml/mm6432a2.htm>. Accessed September 16, 2015.
2. 2018 UAB Study: The Effect of the Bruder Eye Hydrating Compress on Contact Lens Discomfort in Contact Lens Wearers
3. 2017 Contact Lens & Anterior Eye. Factors in the Success of New Contact Lens Wearers.
4. Olson MC, Korb DR, Greiner JV. Increase in tear film lipid layer thickness following treatment with warm compresses in patients with meibomian gland dysfunction. *Eye Contact Lens*. 2003;29(2):96-9.

suspicion for an alternative etiology. Given the close association between cranial nerves VI and VII within the pons and as they exit the brainstem, simultaneous dysfunction suggests a lesion in that region. We referred the patient for additional testing, including an MRI of the brain, which resulted in the diagnosis of metastatic cancer and referral to oncology for further evaluation.

3. Motor/reflex examination.

This begins with observation. You should first look for any involuntary movement such as tremors suggestive of basal ganglia disease (e.g. Parkinson's) or muscle atrophy. Next, check for weakness of the upper and lower extremities by asking the patient to flex, extend, abduct and adduct their arms and legs against resistance. Compare the strength and ability of each muscle group with the contralateral side, looking for any asymmetry (Figure 1).

Weakness may be subtle and can be further elucidated with specific tasks. Ask a patient to hold both arms out in front of them with their palms facing upward and close their eyes. A slow, downward drift and pronation of one arm suggests weakness. Additionally, check fine movements by asking the patient to rapidly tap a finger or alternate their hand in a palm-up, palm-down fashion. Deep tendon reflexes may be diminished, such as in patients with Adie's tonic pupil, or abnormally increased, such as in patients with multiple sclerosis.³

Motor/reflex examination case.

A 66-year-old patient presented emergently with complaints of double vision. The patient had poorly controlled diabetes and blood pressure was elevated at the time of the exam. The patient denied any associated neurologic symptoms such as weakness, paresthesia or headache. Examination revealed

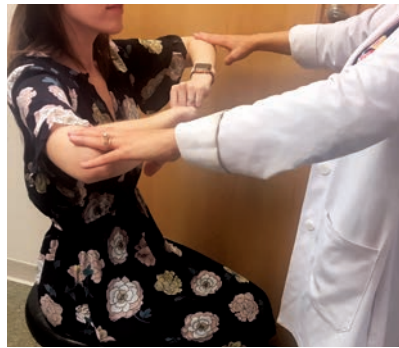

Fig. 1. Demonstration of upper extremity strength assessment.

a right abduction deficit concerning for a CN VI palsy, but the eye examination was otherwise normal. A neurologic exam revealed a previously unknown upper extremity, left-sided weakness. All other aspects of the neurologic exam were normal. An abduction deficit with contralateral weakness is concerning for a lesion in the brainstem, specifically referred to as Raymond's syndrome. The patient was referred immediately to the hospital where neuroimaging revealed an infarction of the right ventral pons.

These first two cases discussed highlight the importance of performing a neurologic examination on patients with diplopia. The presence of additional neurologic

symptoms (cranial neuropathy and weakness) that the patient may or may not be aware of should prompt you to pursue a more urgent work-up. If this patient had been evaluated from purely an ophthalmic standpoint, the CN VI palsy may have been presumed ischemic or vasculopathic, given the poor control of systemic disease. However, the discovery of a concurrent new-onset neurologic symptom raised significant concern and warranted immediate neuroimaging. While a cranial nerve palsy may be secondary to vasculopathic risk factors, it is important to consider that a diagnosis of exclusion.

4. Coordination/gait. The first indication of cerebellar dysfunction may be observed as the patient walks to the exam room. Those with the condition may exhibit an ataxic, or clumsy, gait. You can also ask the patient to walk heel-to-toe in a straight line. Wheelchair-bound patients can slide their heel along their contralateral shin toward their foot. Inability to perform any of these tasks indicates potential cerebellar dysfunction or intoxication.

The presence or absence of ataxia may also be detected by asking the patient to quickly touch their finger

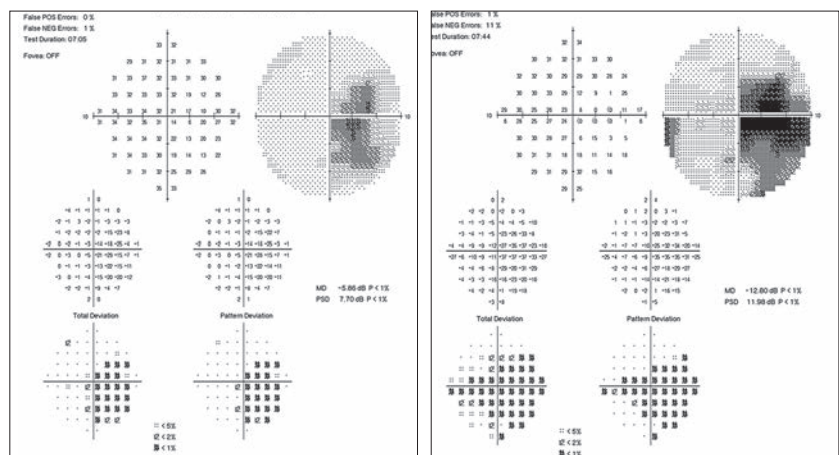


Fig. 2. Humphrey 10-2 visual fields OS and OD show a more severe visual loss in the left eye compared with the right.

**The BEST piece of equipment you don't own yet.
Now is the BEST time to complete your practice!**

EyeResTM
Digital Imaging Systems

A Versatile System:

*Anterior-segment imaging,
Retinal imaging, and Functional
Meibography all from a slit lamp.*

Save time . . .

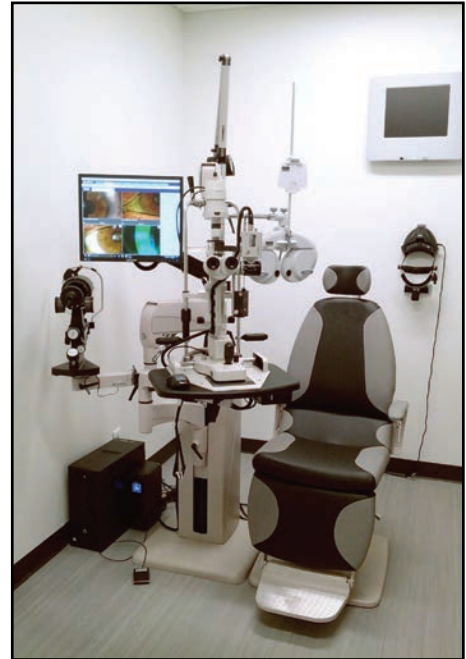Just tap the foot pedal and your images are permanently saved. No clicking!
Network ready for EHR.

Increase income . . .

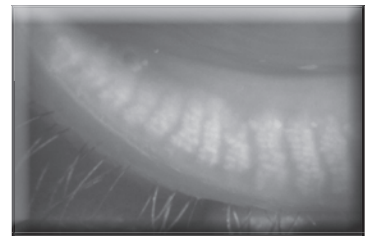
Revenue from Anterior Segment Photography can more than cover the equipment cost.

Save space . . .

The Platinum EyeRes System takes very little space without crowding you or your patient.



The Platinum EyeRes system is compatible with most slit lamps.



Optional module for Functional Meibography

Reap the many benefits of owning an **EyeRes**TM imaging system from TelScreen.
Finance for as little as \$270/month. Quantity Discounts available.

Call **800.769.4933** today.

TelScreen. It's worth it!
www.TelScreen.com



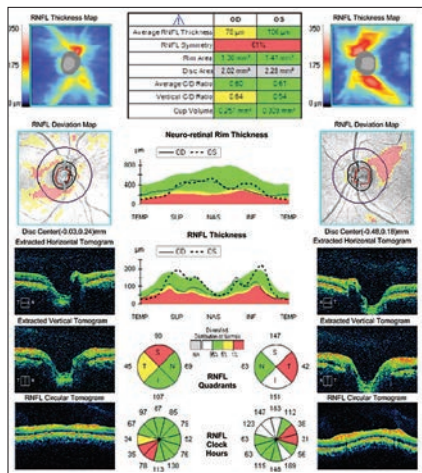


Fig. 3. OCT of the optic nerves reveal temporal retinal nerve fiber layer thinning flagged on the deviation map.

from their nose to your fingertip an arm's length away. Any hesitation, overshoot or undershoot, shaking or difficulty when they are about to touch your finger may indicate ataxia. Stand far enough away so that these patients have to fully extend their arm to reach your finger. You can move your finger to different areas to increase difficulty.

To assess rapid alternating movements, ask the patient to tap the palm of their hand on their leg repeatedly and quickly. Then ask them to flip their hand from palm to the back of the hand on their leg. Inability to do so is known as dysdiadochinesia and is often a sign of

cerebellar disease, including stroke and atrophy.

The classic ocular manifestation of cerebellar dysfunction is nystagmus, with other potential ocular complications such as abnormal pursuits and optokinetic response. However, nystagmus is not only caused by cerebellar disease and can be due to vestibular dysfunction as well as other etiologies such as albinism and medication use (such as anti-seizure medications). Therefore, performing a neurologic exam on patients with nystagmus and paying special attention to their coordination and gait can help increase or decrease your clinical suspicion for a lesion within the cerebellum.

Coordination/gait case. A 31-year-old woman presented with complaints of glare and reduced vision. Her best-corrected visual acuity was 20/25- OD and 20/100 OS. She demonstrated a 0.3 log unit relevant afferent pupillary defect of the left eye and reduced color vision (12/14 Ishihara plates OD, 3/14 Ishihara plates OS) (Figures 2 and 3). Fundus examination revealed bilateral temporal pallor OS>OD (Figure 4). A neurologic exam revealed tandem gait ataxia and a positive Romberg test, suggestive of cerebellar dysfunction. She also demonstrated fine motor weakness

affecting the left hand more than the right. Records of recent lab work demonstrated significant vitamin B12 and folate deficiencies, which supported a nutritional optic neuropathy diagnosis.

This case highlights how a neuro exam helps to refine your differential diagnosis of an optic neuropathy. Potential causes of bitemporal pallor include inflammatory, infectious, nutritional and toxic conditions. Anemia is a common early symptom of vitamin B₁₂ deficiency, while neurologic symptoms are typically found later. Neurologic symptoms arise due to demyelination and can include cerebellar ataxia and limb weakness.^{4,5} In this case, our neurological findings helped narrow our differential and avoid additional tests such as laboratory testing and neuroimaging.

5. General sensory exam. Pain, temperature, proprioception, two-point touch, light touch, pressure and vibratory sense are all general sensations. The stimulus travels from the site of stimulation to the cerebral cortex. Depending on the sensation, the pathway decussates, or crosses, the midline in either the low medulla or spinal cord. Lesions below the decussation cause ipsilateral loss of sensation. In general, lesions within the brainstem or the brain cause contralateral loss of sensation.

We recommend integrating tests of sensation with other elements of the neurologic exam. While the patient has their arms outstretched with closed eyes to test for pronator drift, lightly touch the backside of one of their hands and ask them to identify which hand was touched. Touch one hand, then the other and then both simultaneously while asking the patient to note any asymmetry. You may also touch a cool transilluminator on each of the

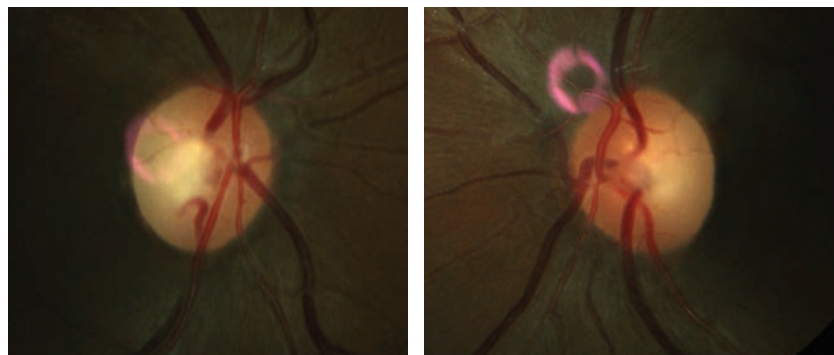


Fig. 4. Note the pallor of the temporal rim in the patient's fundus photo of the right optic disc and left optic disc (please disregard the pink artifact).

patient's arms to assess for asymmetry in temperature sensation.

Proprioception can be assessed by asking the patient to stand with their feet touching, known as the Romberg test. Patients can usually keep their balance with their eyes open due to visual cues; however, if they are unable to maintain their balance with their eyes closed—a positive test—they may have loss of proprioception. This test may also indicate cerebellar dysfunction.

Sensory exam case. A 62-year-old male presented with tearing affecting the left eye more than the right, a left-sided, non-congruous, homonymous hemianopia and intermittent diplopia. He reported a history of a hemorrhagic stroke affecting the right side of his brainstem. Neuro exam revealed left-sided weakness of the left upper and lower extremities. He also demonstrated notable sen-

sory defects and a left-sided facial palsy that was not grossly evident by observation alone. By correlating our findings with the anatomical location of the stroke, we attributed his presentation to the prior stroke of the right pons, therefore avoiding any further testing or work-up. His previous MRI report was remarkable for gliosis involving the right optic tract, which corresponded with his visual field defect.

These cases highlight many important clinical implications of the neurologic exam, hopefully inspiring you to incorporate it into your practitioner's toolbox. Ultimately, a neurology consult is often indicated, but an in-office screening may help narrow a list of differentials to help develop a sense of urgency. With practice, the neurologic exam can be performed and

interpreted quickly and efficiently, with significant implication for patient care. ■

Dr. Maglione is an assistant professor at the Pennsylvania College of Optometry at Salus University and clinical instructor in the primary care and neuro-ophthalmic disease services at The Eye Institute.

Dr. Seidler graduated from the Pennsylvania College of Optometry at Salus University. She is currently completing a two-year advanced residency program at The Eye Institute in neuro-ophthalmic disease.

1. O'Bryant SE, Humphreys JD, Smith GE, et al. Detecting dementia with the mini-mental state examination (MMSE) in highly educated individuals. *Arch Neurol.* 2008;65(7):963-7.
2. Finsterer J, Grisold W. Disorders of the lower cranial nerves. *J Neurosciences in Rural Practice.* 2015;6(3):377-91.
3. Campbell W, DeJong's The Neurologic Examination. 7th ed. Philadelphia: Wolters Kluwer; 2015.
4. Ralapanawa DMPUK, Jayawickreme KP, Ekanayake EMM, Jayalath WATA. B12 deficiency with neurological manifestations in the absence of anaemia. *BMC Research Notes.* 2015;8:458.
5. Ashizawa T, Xia G. Ataxia. *Continuum: Lifelong Learning in Neurology.* 2016;22(4):1208-26.

“I want to practice **my way.**”

Dream it. Do it.



At IDOC, we are committed to your success as an independent optometrist. You will get the personalized attention and customized business support your practice needs—plus advanced performance analytics, peer networking and exclusive vendor discounts.

IDOC
independent. together.™

Call 203-853-3333
or visit IDOC.net to join now.

Attending SECO? Visit IDOC at Booth #1741



TAKE A CLINICAL APPROACH TO ANTERIOR UVEITIS

The ultimate goal is to narrow down symptoms to effective treatment.

By **Dominick L. Opitz, OD**

Anterior uveitis (AU) causes frustration for patients and clinicians alike. The inconvenient onset and often severe symptoms result in urgent office visits, disrupting the patient's daily life as well as the provider's office and clinic flow. The rigorous treatment, frequency of follow-up visits and risk for recurrence can fur-

ther add to the frustration. Failure of timely diagnosis as well as inefficient and/or ineffective treatment can have serious sight-threatening complications.

Following a logical, clinical approach to AU will help the primary eye care provider effectively and efficiently manage anterior uveitis (*Figure 1*).

Clinical Examination

Anterior uveitis is inflammation that arises in the anterior segment, including the iris and anterior ciliary body. AU is the most common form of uveitis, accounting for 50% to 60% of all uveitis, and is the most common type of ocular inflammation optometrists will encounter.¹⁻⁴

An estimated 30% to 52% of AU

Release Date: February 15, 2019
Expiration Date: February 15, 2022
Estimated Time to Complete Activity: 2 hours

Jointly provided by Postgraduate Institute for Medicine (PIM) and RGVCE



Educational Objectives: After completing this activity, the participant should be better able to:

- Demonstrate knowledge of the ocular signs and symptoms, as well as systemic associations, related to anterior uveitis.
- Use common lab tests to help localize the etiology of the uveitis.
- Perform a dilated fundus examination for all patients who present with anterior uveitis.
- Define the appropriate topical or systemic anti-inflammatories and, importantly, the frequency of dosing for managing anterior uveitis.
- Describe the use of cycloplegia to reduce pain, prevent synechiae formation and re-establish the blood-aqueous barrier.

Target Audience: This activity is intended for optometrists engaged in the care of patients with uveitis.

Accreditation Statement: In support of improving patient care, this activity has been planned and implemented by the Postgraduate Institute for Medicine and RGVCE. Postgraduate Institute for Medicine is jointly accredited by the Accreditation Council for Continuing Medical Education, the Accreditation Council for Pharmacy Education, and the American Nurses Credentialing Center, to provide continuing education for the healthcare team. Postgraduate Institute for Medicine is accredited by COPE to provide continuing education to optometrists.

Faculty/Editorial Board: Dominick L. Opitz, OD, associate professor, the Illinois College of Optometry.

Credit Statement: This course is COPE approved for 2 hours of CE credit. Course ID is **60776-AS**. Check with your local state licensing board to see if this counts toward your CE requirement for relicensure.

Disclosure Statements:

Dr. Opitz: Consulting fees from Valeant/Bausch + Lomb and fees for non-CME/CE services from Valeant/Bausch + Lomb.

Managers and Editorial Staff: The PIM planners and managers have nothing to disclose. The RGVCE planners, managers and editorial staff have nothing to disclose.

cases have an underlying systemic etiology, and the primary eye care provider is often the first health care provider to aid in the systemic disease.⁴ Effective treatment and management of uveitis should include controlling the signs and symptoms of the disease, preventing ophthalmic complications and identifying any systemic underlying etiology.

The symptoms of AU include pain, redness, reduced vision and photophobia, but these vary depending on the clinical course (acute vs. chronic) of the uveitis.⁵

The Standardization of Uveitis Nomenclature (SUN) Working Group developed descriptors of uveitis to clarify the onset, duration and course.⁶ The onset is described as either sudden or insidious, whereas duration is defined as limited (≤ 3 months duration) or persistent (≥ 3 months duration).⁶ These descriptors are then used to define the clinical course—acute, recurrent or chronic.

Acute uveitis occurs with sudden onset and limited duration.⁶ Recurrent uveitis is characterized by repeated episodes separated by periods of inactivity without treatment for three or more months.⁶ Chronic uveitis describes cases in which relapses occur less than three months after discontinuing treatment.⁶

The pathophysiology of uveitis refers to the type of inflammatory cells produced, either granulomatous or non-granulomatous.

Granulomatous inflammation is characterized by inflammatory cells of the mononuclear phagocyte system that take the form of macrophages, epithelial cells and multinuclear giant cells.⁷ This form of inflammation is commonly a manifestation of infectious, toxic, autoimmune or neoplastic origin.⁷ Granulomatous inflammations can also be a critical sign of chronic inflammation as seen with chronic

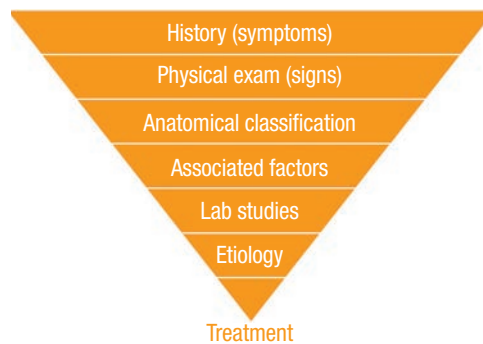


Fig. 1. Following this chart may offer an effective approach to the diagnosis and management of anterior uveitis where the ultimate goal is to narrow down symptoms to effective treatment.

systemic autoimmune conditions.

Non-granulomatous inflammation allows protein and white blood cells to enter into the aqueous humor, causing the classic signs of anterior chamber cells and flare. AU resulting from non-granulomatous inflammation is more commonly seen in non-infectious underlying etiologies.

The clinical signs associated with AU—manifested in the conjunctiva, cornea, anterior chamber and iris—are a direct result of inflammation in the anterior segment that results in a breakdown of the blood-aqueous barrier. Inflammation of the conjunctiva in anterior uveitis is often described as perilimbal injection or circumlimbal injection.⁵ If the inflammation is granulomatous, conjunctival nodules may develop. These nodules are collections of inflammatory material within the bulbar and/or palpebral conjunctiva.

Corneal findings associated with anterior uveitis may include corneal edema, but the most common corneal finding is keratic precipitates (KPs). These are collections of inflammatory cells that accumulate on the endothelium.⁸ New KPs are typically white in color with smooth borders. As KPs become more chronic, they may appear pigmented with irregular borders.

KPs can be classified as granulo-

matous or non-granulomatous. Granulomatous KPs are large with a waxy or “mutton fat” appearance (*Figure 2*).⁵ Their presence is highly suggestive of an underlying infectious etiology, but they can also be seen in chronic autoimmune conditions such as sarcoidosis. In contrast, non-granulomatous KPs are small, fine and white, and found more in non-infectious etiologies.

The hallmark sign of AU is the presence of anterior segment inflammatory cells.⁵ These are white blood cells that circulate in the aqueous humor. The SUN Working Group developed a uniform grading scheme for anterior chamber cells (*Table 1*).⁶

The presence of hypopyon in AU is highly suggestive of diseases associated with human lymphocyte antigen B27 (HLA-B27), Behcet’s disease or infectious endophthalmitis.

Anterior chamber flare occurs from an influx of protein from the uveal blood vessels into the anterior chamber, which results from increased vascular permeability of the uveal vasculature in the anterior chamber.⁹ Flare is graded according to the SUN grading scale: no flare is grade 0; faint/barely present is grade 1+; moderate with iris and lens details clear is grade 2+; marked with iris and lens details hazy is grade 3+; intense with formed fibrin or plastic aqueous humor is grade 4+.⁶

Table 1. Anterior Chamber and Vitreous Cell Grading*

Grade	Number of Cells
0	no cells
0.5+	1-10
1+	10-20
2+	20-30
3+	30-100
4+	>100

*Using a high-intensity 1mm x 1mm slit beam based on the Standardization of Uveitis Nomenclature Working Group.⁶

When anterior chamber inflammation is severe and there is significant breakdown of the blood-aqueous barrier, extensive protein leakage occurs, which causes the development of fibrin membrane across the pupil when the flare is 4+ (*Figure 3*).

With AU, changes to the iris—such as miosis, iris nodule formation and iris synechia—may occur. Miosis typically occurs from spasms to the iris sphincter or from distension of iris blood vessels.¹⁰ Iris nodules are accumulations of inflammatory cells and may occur at the iris margin of the pupil or in the iris stroma. Nodules at the pupil margin are termed Koeppe nodules and are found in both granulomatous and non-granulomatous inflammation whereas Busacca nodules are found in granulomatous inflammation and are located in the iris stroma.⁵ Other iris findings in AU may include irido-corneal adhesions, termed peripheral anterior synechia.^{5,8}

Posterior synechia are adhesions of the iris and anterior lens that generally develop from Koeppe nodules or a thickened iris due to inflammation. Localized diffuse or sectoral iris atrophy may also occur in AU and is more common in chronic and recurrent uveitis or when the underlying etiology is viral in nature.

Intraocular pressure (IOP) is historically described as low in anterior uveitis—but IOP may be normal,

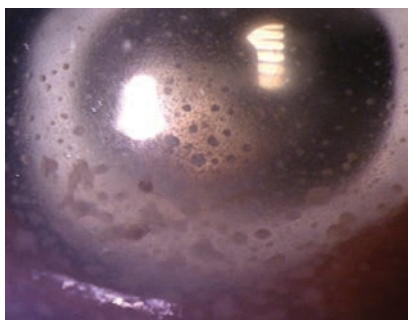

Fig. 2. Example of granulomatous or mutton-fat KP on the endothelium of a patient with sarcoidosis.

low or high depending on the underlying cause, the clinical course and/or the number of inflammatory cells affecting the outflow of aqueous humor through the trabecular meshwork (TM).^{5,8} It is more common for IOP to be low during an acute phase due to secretory hypotony of the ciliary body. Elevated IOP is more likely to occur in chronic AU when the TM becomes overwhelmed with inflammatory material or pigment. If the underlying etiology is due to herpetic eye disease, trabeculitis frequently occurs, which affects outflow and causes elevated IOP.

Although vitreous cells are the hallmark sign of intermediate uveitis, it is possible to have anterior chamber cells “spill over” into the anterior vitreous. These vitreous cells, like anterior vitreous cells, are inflammatory cells that arise from a breakdown of the blood-aqueous barrier. They are best visualized in a dilated eye at the slit lamp. Use the SUN grading scheme for vitreous cells (*Table 1*).⁶

Clinical examination of a patient with anterior uveitis should include visual acuity, slit lamp exam, IOP assessment and a dilated fundus exam.¹⁰ If IOP is elevated, gonioscopy may add valuable clues to the clinical course (acute vs chronic). The purpose of the dilated exam is to ensure the anatomical location of uveitis is confined to the anterior segment and that there are no posterior segment complications such as cystoid macular edema, cataracts (specifically posterior subcapsular cataracts) or glaucoma. If posterior uveitis or panuveitis is present, suspicion for underlying etiology increases and management changes. If you find that the anatomical location of the uveitis is isolated to the anterior chamber, determine whether the inflammation is granulomatous vs non-granulomatous based on clinical signs as discussed above.

Further, clinical signs, symptoms and history should enable classification of the clinical course (acute, chronic, or recurrent). For instance, a patient with acute AU will likely complain of sudden onset of redness, pain and light sensitivity, whereas a patient with chronic anterior uveitis may have few to no symptoms.

Based on the clinical course, clinical signs and pathophysiology of inflammation, narrow your differential underlying etiology to infectious vs non-infectious.

Treatment

In general, the goals for treatment of AU are to eliminate ocular inflammation to preserve vision, relieve pain and prevent ocular complications, as well as identify any possible underlying etiology.

For acute AU, initial treatment includes topical corticosteroids and cycloplegic agents in an effort to reduce and/or eliminate intraocular inflammation. The dosing of topical corticosteroids often depends on the severity and clinical course of the anterior uveitis as well as the type of corticosteroid used.

Prednisolone acetate 1% is the most commonly prescribed corticosteroid used for treating AU, followed by dexamethasone 0.1%.^{1,4,11-13} For acute AU, the typical dosing is one drop every one to two hours while awake for a minimum of one week. Dosing for chronic AU may be less.

Difluprednate 0.05% emulsion is generally dosed QID and has been found to have similar efficacy to that of prednisolone acetate 1% when dosed eight times daily.^{11,14} The lesser dosing regimen of difluprednate 0.05% may offer better patient adherence, but has been shown to cause higher risk of steroid-induced IOP elevation compared with prednisolone acetate 1%.¹⁵

Loteprednol 0.5% is often

reserved for patients in whom IOP spikes are a concern, but its efficacy is less than that of prednisolone acetate 1% or difluprednate 0.05%.¹⁶

Cycloplegia is generally used as an adjunctive therapy to corticosteroids. Cycloplegia decreases pain and photophobia by paralyzing the ciliary body and by preventing posterior synechiae.^{1,4,11-13} Immobilizing the ciliary body also helps to re-establish the blood-aqueous barrier. The dosing of the cycloplegic agent varies depending on the medication. Traditional treatment included homatropine 5% or scopolamine 0.25% or 0.5%, but due to their limited access it is becoming common to use atropine 1.0%. Cyclopentolate 1.0% is another topical cycloplegic option.

Although signs and symptoms may improve after initiation of topical corticosteroids and cycloplegia, continue treatment until inflammatory anterior chamber cells have resolved. This may take from one week to one month or more, depending on the underlying etiology. In rare cases, inflammatory cells may persist for years.

The typical follow-up for acute AU is five to seven days, at which time the anterior chamber cells should be reduced by at least 50% since the initial presentation.^{1,4,11} Patients should be re-examined weekly without altering corticosteroid and cycloplegia dosing until there are five or fewer cells per high-powered field as viewed by slit lamp. Visual acuity, slit lamp biomicroscopy, IOP and fundus examination should be performed at each follow-up visit. Additional testing may be indicated if ophthalmic complications arise, such as reduced vision or cystoid macular edema.

Once inflammatory cells of five or fewer per high-powered field are visible in the anterior chamber, prednisolone acetate 1% dosing may be reduced from every one hour to

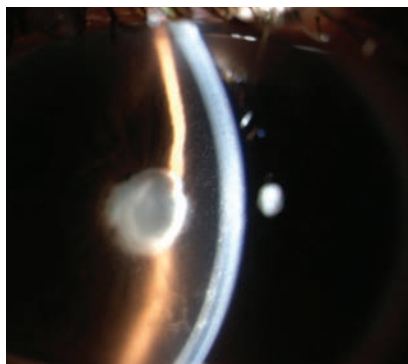


Fig. 3. This patient has a fibrin membrane across the pupil with 4+ flare, 3+ cells and endothelial keratic precipitates.

every two hours, provided patient symptoms have resolved.^{1,4,11-13} Follow-up visits may be extended to every two weeks and tapering steroids may continue, provided signs and symptoms do not increase.

Underlying Etiologies

Although the majority of uveitis is undifferentiated or idiopathic (48% to 70%), infectious and non-infectious causes occur.^{17,18} Consider systemic etiologies when the AU is bilateral, recurrent, chronic or granulomatous in nature and when patients are younger than 15 years of age. Careful review of systems and lab testing are required to help narrow the differential diagnosis and ultimately identify the systemic condition.⁹ Failure to properly diagnose and treat systemic disease may result in ophthalmic treatment failure, ophthalmic complications, loss of vision, or even loss of life.

Uveitis-specific questionnaires—such as the Ocular Inflammation Disease Review of Systems Questionnaire—allow for a critical review of systems that guides the lab testing.⁴ In general, labs are withheld for initial acute episodes that are unilateral and non-granulomatous and if the

uveitis responds to treatment.

If the AU is chronic, recurrent, bilateral, granulomatous and recalcitrant to treatment, laboratory testing is indicated; however, lab tests should be specific to the suspected underlying etiology (*Table 2*).¹⁰ Once the underlying etiology is identified, ocular management may change from topical therapy to disease-specific systemic treatment, especially for infectious conditions such as Lyme disease, syphilis, herpes and tuberculosis.

Non-infectious Etiologies

The most common non-infectious underlying etiology for AU is caused by a group of inflammatory disorders collectively termed the seronegative spondyloarthropathies, which account for up to 50% of acute and recurrent anterior uveitis.¹⁹

The seronegative spondyloarthropathies are negative for rheumatoid factor (RF) and anti-nuclear antibodies (ANA), but may be positive for HLA-B27, a class I major histocompatibility complex.¹⁹⁻²³

The conditions associated with HLA-B27 seronegative spondyloarthropathies include ankylosing spondylitis, reactive arthritis syndrome, psoriatic arthritis and inflammatory bowel disease, including Crohn's and ulcerative colitis. An estimated 50% of patients with acute anterior uveitis

Tapering Steroids in Anterior Uveitis

A reasonable tapering schedule of topical corticosteroids for anterior uveitis is one drop every two hours for two weeks, one drop QID for two weeks, one drop TID for two weeks, one drop BID for two weeks, one drop a day for two weeks, and then topical therapy should be discontinued.^{1,4,10} This schedule may need to be altered depending on the individual patient, past history, underlying etiologies, and complications and/or adverse events from the steroids.

If the disease flares at any time during the follow-up process or inflammation increases, the corticosteroid dosing may need to be increased, followed by a slower taper.¹⁰⁻¹³

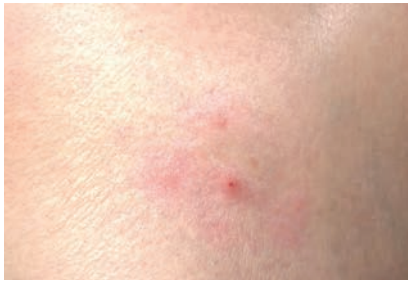

Fig. 4. This patient has erythema migrans four days after a tick bite and was treated with 100mg doxycycline for 21 days.

test positive for HLA-B27, and half of those patients go on to develop one of the seronegative spondyloarthropathies.²⁴

Uveitis associated with HLA-B27 is typically recurrent unilateral, bilateral or alternating non-granulomatous AU and may have fine endothelial KPs.¹⁹⁻³² Symptoms associated with HLA-B27-positive acute AU are typically extreme and include eye pain, photophobia and intense injection of the bulbar conjunctiva.

Treatment includes topical corticosteroids and cycloplegia. For patients with non-infectious etiologies who don't respond to topical therapy or for patients with recurrent AU, consider systemic treatment with oral corticosteroids or disease-modifying antirheumatic drugs such as methotrexate or hydroxychloroquine.

Other, less common non-infectious etiologies of AU include juvenile idiopathic arthritis (JIA), sarcoidosis, Behcet's disease and systemic lupus erythematosus (SLE).

• **Juvenile idiopathic arthritis.**

JIA-related uveitis accounts for 20% to 40% of pediatric uveitis patients.²⁵ JIA has many different subcategories, but the majority of JIA-associated uveitis patients have oligoarticular onset JIA (78% to 90%), while 7% to 14% have polyarticular JIA.^{10,26}

The onset of JIA uveitis is typically insidious; many patients are asymptomatic with a white and quiet eye. Further, the arthritis often manifests

before the uveitis is detected. The uveitis can become chronic, causing ocular complications such as cataracts, posterior synechia, band keratopathy, glaucoma and macular edema in 37.3% of patients with JIA-related AU.²⁷

Because uveitis in JIA can present in a quiet eye, screening is recommended at three months for high-risk JIA patients, six months for moderate-risk JIA patients, and 12 months for low-risk JIA patients.^{26,28}

Patients with JIA typically present with an acute recurrent unilateral or bilateral non-granulomatous AU.²⁹ Work-up for children or adolescents suspected of JIA-related AU should include ANA, HLA-B27, and RF. A positive ANA increases the risk for AU, whereas a positive HLA-B27 increases the risk for developing ankylosing spondylitis later in life.

JIA-associated uveitis is often chronic, requiring long-term treatment. Systemic "steroid-sparing" therapeutic options include antimegakalins and other biologic agents.²⁵

• **Sarcoidosis.** This is a multisystem disease of unknown origin that predominantly affects the lungs. Ocular involvement is present in up to 50% of patients.³⁰⁻³³ The hallmark sign of sarcoidosis is non-caseating granulomas caused by granulomatous inflammation. These are composed of epithelioid and giant cells that secrete angiotensin converting enzyme (ACE).

Anterior uveitis in sarcoidosis is typically bilateral, chronic and granulomatous with large mutton-fat KPs, TM inflammation and iris nodules.³⁰⁻³³ Up to 25% of patients with ocular sarcoidosis develop posterior segment involvement.³⁰⁻³³ Laboratory tests for patients suspected of sarcoidosis AU may include serum ACE levels, serum lysozyme, chest X-ray or CT, tissue biopsy or gallium scan.

In addition to topical ophthalmic treatment for anterior uveitis, sys-

temic treatment may include oral corticosteroids.

• **Systemic lupus erythematosus.**

Like sarcoidosis, SLE is a multisystem autoimmune disease. While antibodies in the normal immune system protect against pathogens such as viruses and bacteria, ANA—a type III hypersensitivity reaction—attack cell nuclei triggering inflammation in patients with SLE.^{34,35} ANA levels are elevated in 97% of SLE patients. Although anterior uveitis can occur in SLE, it is most commonly associated with scleritis, episcleritis, secondary Sjögren's syndrome, lupus retinopathy and choroidopathy.^{34,35} Anterior uveitis seldom occurs in isolation and is more commonly associated with scleritis or posterior uveitis.

• **Behcet's disease.**

This is a chronic, multisystem, relapsing inflammatory disorder of unknown etiology, characterized by the classic triad of oral and genital ulcers, ocular inflammation and skin lesions. It is associated with HLA-B51.^{36,37} The uveitis in patients with Behcet's disease is typically bilateral, non-granulomatous anterior uveitis that may be acute, recurrent or chronic. Posterior uveitis may occur due to the increased risk of vasculitis associated with Behcet's. Hypopyon is also a common finding, present in 19% to 31% of patients with AU and Behcet's disease.^{38,39}

Infectious Etiologies

Consider infectious etiologies in patients with recurrent, chronic granulomatous anterior uveitis that fails to resolve with topical corticosteroids and whose review of systems suggests infection. Further, infectious etiologies should be ruled out prior to initiating any systemic corticosteroids or immunosuppressive agents.

Pathogens commonly causing anterior uveitis include bacteria and viruses. Fungal infections such as histoplasmosis and parasitic infections

such as toxoplasmosis typically cause intermediate and posterior uveitis.

Bacterial Etiologies

Some of the more common bacterial etiologies of AU include syphilis, Lyme disease and tuberculosis (TB).

- **Syphilis.** This is a multisystem, chronic bacterial infection caused by the spirochete bacterium, *Treponema pallidum*. Syphilis accounts for 1% to 2% of uveitis cases but is considered the “Great Masquerader” due to the different stages it may progress through if left untreated.⁴⁰⁻⁴² Primary syphilis is the first stage, which initially presents as erythematous papules at the inoculation site that later erode to a painless ulceration called a

chancre, which may be present from two to six weeks.

If left untreated, primary syphilis leads to secondary syphilis. The latter occurs four to 10 weeks after infection, and the systemic treponemal load is largest in this stage. Secondary syphilis is characterized by a disseminated maculopapular rash on the palms of hands and soles of feet and lymphadenopathy. Constitutional symptoms may include high fever, malaise, headache, nausea, anorexia, hepatitis and meningitis. Approximately 10% of cases with secondary syphilis present with uveitis.⁴⁰⁻⁴²

Following secondary syphilis, patients progress to latent syphilis in which no systemic disease is appar-

ent. Early latent syphilis occurs within one year of initial infection; late latent syphilis occurs after one year of infection. Most cases have been reported to remain at the latent stage, but 30% will progress to tertiary syphilis, the most common stage in syphilis for uveitis to develop.⁴³⁻⁴⁵

Tertiary syphilis may cause cardiovascular-syphilis, neuro-syphilis or benign-tertiary syphilis. AU in syphilis patients can occur in secondary, latent and tertiary stages of syphilis, but not present in primary syphilis. The uveitis may be unilateral or bilateral, granulomatous or non-granulomatous and with or without iris nodules, dilated iris vessels and iris atrophy.

Patients with syphilis may present with posterior uveitis such as diffuse or focal chorioretinitis, neuroretinitis, necrotizing retinitis, retinal vasculitis, intermediate uveitis or panuveitis.⁴³⁻⁴⁵

The diagnosis of syphilis is confirmed through serology testing and includes non-treponemal and treponemal tests. The non-treponemal tests include RPR and VDRL and treponemal tests include FTA-ABS or MHA-TP.

If the non-treponemal tests indicate active disease, determining the stage of syphilis will determine the systemic treatment protocol. Primary, secondary or early latent stage treatment includes a single intramuscular (IM) injection of penicillin.⁴⁶ Late latent or tertiary stage requires weekly IM penicillin injections for a total of three doses, whereas neurosyphilis requires intravenous penicillin.⁴⁶

Systemic treatment of syphilis-associated uveitis should occur in conjunction with ocular treatment with topical corticosteroids.

- **Tuberculosis.** This is a granulomatous infection caused by *Mycobacterium tuberculosis*. The classic presentation of an active TB infection includes chronic cough, fever, night sweats and weight loss. Granulomatous inflammation in TB causes granulomas to develop in the lungs, but granulomas may also develop on the iris, angle or choroid.

Uveitis may present in both active TB and in patients without systemic TB symptoms.⁴⁷ The most common uveitis seen in TB is disseminated chorioretinitis, but it can also present as acute anterior uveitis, chronic granulomatous anterior uveitis, intermediate uveitis, vitritis or endophthalmitis.⁴⁸⁻⁵²

Making the diagnosis of TB requires lab tests. The purified protein derivative (PPD) skin test can identify past exposure but does not indicate if the disease is active. Chest

Table 2. Common Laboratory Tests^{1,3-5,8,10,18}

Test	Diagnostic Use with Anterior Uveitis
Complete Blood Count (CBC with diff)	Underlying bacterial or viral etiology
Erythrocyte sedimentary rate (ESR)	Measure of generalized inflammations. Non-specific to disease
C-reactive protein (CRP)	Marker of inflammation
Antinuclear antibody (ANA)	SLE or JIA
Rheumatoid Factor (RF)	Rheumatoid arthritis
Human leukocyte antigen B27 (HLA-B27)	IBD (Crohn's, ulcerative colitis), ankylosing spondylitis, reactive arthritis
Human leukocyte antigen B51 (HLA-B51)	Behcet's disease
Fluorescent treponemal antibody absorption (FTA-ABS)	Syphilis (current or past infection)
Microhemagglutination assay-treponema pallidum (MHA-TP)	Syphilis (current or past infection)
Rapid plasma regain (RPR)	Syphilis (screen for active disease)
Venereal disease research laboratory (VDRL)	Syphilis (screening for active disease)
Lyme Titers	Lyme Disease
Enzyme-linked immunosorbent assay (ELISA)	Lyme Disease
Angiotensin-converting enzyme (ACE)	Sarcoidosis
Serum Lysozyme	Sarcoidosis
Quatiferon gold	Tuberculosis
Purified protein derivative skin test (PPD)	Tuberculosis
Chest X-ray (CXR)	Sarcoidosis; Tuberculosis

CT/X-ray and sputum cultures are performed to determine if the infection is active. Blood tests, called interferon-gamma release assays, indicate TB infection.

- **Lyme disease.** This is a multi-system disorder caused by the spirochete *Borrelia burgdorferi* infection, which is transmitted via tick bites.

There are three stages of Lyme disease: early, disseminated and persistent. In the early stage of the disease, 60% to 80% of patients present with erythema migrans rash (*Figure 4*) that may take a bull's-eye pattern at the site of the tick bite within two to 28 days after the bite.⁵³ Associated symptoms in the early stage may include fever, malaise, fatigue, arthralgia and myalgia.

All forms of uveitis may be present in the later stages of the disease (weeks to months after the initial infection), including AU, intermediate uveitis, posterior uveitis, neuroretinitis, retinal vasculitis, choroiditis and panuveitis.⁵⁴⁻⁵⁸

If Lyme disease is suspected, immunofluorescence assay (IFA) or enzyme immunoassay (EIA) are performed first. If either test is positive or equivocal, IgM and IgG Western blot series are performed if signs or symptoms are ≤ 30 days. IgG Western blot is performed if signs or symptoms are > 30 days.⁵⁹

Doxycycline 100mg every 12 hours for 10 to 21 days is the recommended treatment for non-pregnant adults. Amoxicillin is 500mg TID for 14 to 21 days for pregnant adults and in children 50mg/kg divided into three doses per day for 14 to 21 days.⁵⁹ Ocular treatment includes topical steroids in conjunction with systemic treatment.

Viral Etiologies

The most common infectious underlying etiology of anterior uveitis is caused by viruses—most commonly herpes simplex (HSV), varicella

zoster virus (VZV) and cytomegalovirus (CMV). The diagnosis of HSV anterior uveitis is often made based mainly on clinical features—50% to 90% of cases have elevated IOP, iris atrophy, KPs, and unilateral presentation.⁶⁰

Herpesvirus 1 (HSV-1) is implicated in anterior uveitis that is granulomatous, unilateral, and often with increased IOP due to concomitant trabeculitis.⁶⁰ Although HSV-associated AU is granulomatous, the KPs are usually fine and medium sized vs the mutton-fat appearance of other granulomatous etiologies.⁶⁰ HSV anterior uveitis recurs an estimated 71% of the time, which increases the likelihood of iris atrophy.⁶¹⁻⁶³

Herpesvirus 3—varicella zoster virus (VZV)—causes chickenpox. Following the initial infection, VZV remains dormant in neural ganglia. When VZV is reactivated, it causes herpes zoster (HZV), which typically manifests with unilateral pain in a dermatomal distribution accompanied by a maculopapular vesicular rash. When reactivated along the trigeminal nerve, it is termed herpes zoster ophthalmicus.⁶³⁻⁶⁷

Treat HSV- or VZV-associated AU with topical corticosteroids. Because chronic and/or recurrent AU is common, concomitant oral antiviral medication is often also required. Acyclovir 400mg (800mg for VZV) five times per day, valacyclovir 500mg (1,000mg for VZV) three times per day or famciclovir 500mg three times per day are all acceptable dosages to effectively treat patients with active herpes infection and ocular inflammation.⁶⁰⁻⁶⁸ Antiviral coverage can be reduced to two times per day for acyclovir or one time per day for valacyclovir or famciclovir once the ocular inflammation shows signs of reduction and the patient's corticosteroid therapy has been tapered to one drop three times per day.⁶⁰⁻⁶⁸

Herpesvirus 5—cytomegalovirus

(CMV)—is ubiquitous in humans and can cause major morbidity and mortality especially in immunocompromised patients; for instance, CMV retinitis is the most common ocular manifestation seen in patients with HIV/AIDS. CMV has been recognized as a cause of AU in patients who are HIV negative, accounting for 22.8% of cases associated with AU and raised IOP.⁶⁹ CMV-associated AU in immunocompetent individuals may present with unilateral ocular hypertension, chronic or recurrent uveitis with patchy or diffuse iris atrophy, few fine KPs and mild anterior chamber cells. CMV-associated AU is thought to be the cause of Posner-Schlossman syndrome.⁶⁹ Treatment for CMV-associated AU includes topical ganciclovir as a first-line treatment due to good tolerability and minimal side effects, in conjunction with topical corticosteroids.^{60,69,70}

Anterior uveitis is a common condition that all primary eye care providers encounter. To effectively manage AU, the clinician must know not just the signs and symptoms associated with AU, but also the underlying etiologies that often cause it. Narrowing the etiology first requires identifying the AU as acute, chronic or recurrent. Past and current clinical signs and symptoms often guide this determination.

Further, one must know the different types of clinical signs associated with granulomatous vs non-granulomatous inflammation. Based on laterality (unilateral vs. bilateral vs alternating), clinical course (acute, chronic or recurrent), type of inflammation (granulomatous vs. non-granulomatous) and review of systems, the clinician should be able to differentiate any underlying etiology as infectious vs non-infectious. This will then allow the clinician to obtain any necessary laboratory tests

to help support or confirm the suspected underlying etiology.

Once the underlying etiology is determined, a more targeted treatment of the ocular inflammation can be initiated through concomitant systemic management. ■

Dr. Opitz is an associate professor in the Department of Clinical Education at the Illinois College of Optometry and is the senior director of Ophthalmology Services and Practice Development for the Illinois Eye Institute.

1. Huang JJ, Gau PA. Ocular Inflammatory Disease and Uveitis Manual Diagnosis and Treatment. Philadelphia: Lippincott Williams & Wilkins; 2010:1-9.
2. Snell RS, Lemp MA. The eyeball. In: Snell RS, Lemp MA, eds. Clinical Anatomy of the Eye. 2nd ed. Malden, MA: Blackwell Science; 1998:140-156.
3. Rao NA, Forster DJ. Basic principles. In: Podos SM, Yanoff M, editors. The Uvea, Uveitis, and Intraocular Neoplasms. Vol. 2. New York: Gower Medical Publications; 1992:1-17.
4. Foster CS, Vitale AT. Diagnosis and Treatment of Uveitis. 2nd ed. New Delhi: Jaypee Brothers Medical Publishers Ltd; 2013:20-32.
5. Agrawal RV, Murthy S, Sangwan V, Biswas J. Current approach in diagnosis and management of anterior uveitis. Indian J Ophthalmol. 2010;58(1):11-9.
6. Jabs DA, Nussenblatt RB, Rosenbaum JT. Standardization of Uveitis Nomenclature (SUN) Working Group. Standardization of uveitis nomenclature for reporting clinical data. Results of the First International Workshop. Am J Ophthalmol. 2005;140(3):509-16.
7. Williams GT, Williams WJ. Granulomatous inflammation—a review. J Clin Pathol. 1983;36(7):723-33.
8. Herbert CP. Appraisal, workup and diagnosis of anterior uveitis: a practical approach. Middle East Afr J Ophthalmol. 2009;16(4):159-67.
9. Yanoff M, Duker JS. Ophthalmology. 2nd ed. St Louis: Mosby; 2004.
10. Harthan JS, Opitz DL, Fromstein SR, Moretlin CE. Diagnosis and treatment of anterior uveitis: optometric management. Clin Optom (Auckl). 2016 Mar 31;8:23-35.
11. Foster CS, Davanzo R, Flynn TE, et al. Durezol (difluprednate ophthalmic emulsion 0.05%) compared with Pred Forte 1% ophthalmic suspension in the treatment of endogenous anterior uveitis. J Ocul Pharmacol Ther. 2010;26(5):475-83.
12. Freeman WR, Green RL, Smith RE. Echographic localization of corticosteroids after periorbital injection. Am J Ophthalmol. 1987;103(3 Pt 1):281-8.
13. Smith RE, Nozik RA. Uveitis: A Clinical Approach to Diagnosis and Management. Baltimore: Williams & Wilkins; 1989:51-76.
14. Sheppard JD, Toyos MM, Kempen JH, Foster CS. Difluprednate 0.05% versus prednisolone acetate 1% for endogenous anterior uveitis: a phase III, multicenter, randomized study. Invest Ophthalmol Vis Sci. 2014;55(5):2993-3002.
15. Kusne Y, Kang P, Fintelmann RE. A retrospective analysis of intraocular pressure changes after cataract surgery with the use of prednisolone acetate 1% versus difluprednate 0.05%. Clin Ophthalmol. 2016 Nov 23;10:2329-36.
16. Controlled evaluation of loteprednol etabonate and prednisolone acetate in the treatment of acute anterior uveitis. Loteprednol Etabonate US Uveitis Study Group. Am J Ophthalmol. 1999;127(5):537-44.
17. Gutteridge IF, Hall AJ. Acute anterior uveitis in primary care. Clin Exp Optom. 2007;90(2):70-82.
18. Griz DC, Wong IG. Incidence and prevalence of uveitis in Northern California; the Northern California Epidemiology of Uveitis Study. Ophthalmology. 2004;111(3):491-500.
19. Rosenbaum JT. Characterization of uveitis associated with spondyloarthritis. J Rheumatol. 1989;16(6):792-6.
20. Rudwaleit M, van der Heijde D, Landewé R, et al. The Assessment of SpondyloArthritis International Society classification criteria for peripheral spondyloarthritis and for spondyloarthritis in general. Ann Rheum Dis. 2011;70(1):25-31.
21. Rudwaleit M, Landewé R, van der Heijde D, et al. The development of Assessment of SpondyloArthritis International Society classification criteria for axial spondyloarthritis (part I): classification of paper patients by expert opinion including uncertainty appraisal. Ann Rheum Dis. 2009;68(6):770-6.
22. Rudwaleit M, van der Heijde D, Landewé R, et al. The development of Assessment of SpondyloArthritis International Society classification

- criteria for axial spondyloarthritis (part II): validation and final selection. Ann Rheum Dis. 2009;68(6):777-83.
23. Rosenbaum JT. Characterization of uveitis associated with spondyloarthritis. J Rheumatol. 1989;16(6):792-6.
24. Wakefield D, Chang JH, Amjadi S, et al. What is new HLA-B27 acute anterior uveitis? Ocul Immunol Inflamm. 2011;19(2):139-44.
25. Rabinovich CE. Treatment of juvenile idiopathic arthritis-associated uveitis: challenges and update. Curr Opin Rheumatol. 2011;23(5):432-6.
26. Hofer M, Southwood TR. Classification of childhood arthritis. Best Pract Res Clin Rheumatol. 2002;16(3):379-96.
27. Sabri K, Saurenmann RK, Silverman ED, Levin AV. Course, complications, and outcome of juvenile arthritis-related uveitis. J AAPOS. 2008;12:539-545.
28. Cassidy J, Kivlin J, Lindsley C, Nocton J. Ophthalmic examinations in children with juvenile rheumatoid arthritis. Pediatrics. 2006;117(5):1843-1845.
29. Burgos-Vargas R, Pacheco-Tena C, Vázquez-Mellado J. The juvenile-onset spondyloarthritis: rationale for clinical evaluation. Best Pract Res Clin Rheumatol. 2002;16(4):551-72.
30. Birnbaum AD, Oh FS, Chakrabarti A, et al. Clinical features and diagnostic evaluation of biopsy-proven ocular sarcoidosis. Arch Ophthalmol. 2011;129(4):409-13.
31. Jabs DA, Johns CJ. Ocular involvement in chronic sarcoidosis. Am J Ophthalmol. 1986;102(3):297-301.
32. Karma A, Huhti E, Poukkula A. Course and outcome of ocular sarcoidosis. Am J Ophthalmol. 1988;106(4):467-72.
33. Crick RP, Hoyle C, Smellie H. The eyes in sarcoidosis. Br J Ophthalmol. 1961;45(7):461-81.
34. Gold DH, Morris DA, Henkind P. Ocular findings in systemic lupus erythematosus. Br J Ophthalmol. 1972;56(11):800-4.
35. Silpa-archa S, Lee JJ, Foster CS. Ocular manifestations in systemic lupus erythematosus. Br J Ophthalmol. Br J Ophthalmol. 2016;100(1):135-41.
36. Ando K, Fujino Y, Hijikata K, et al. Epidemiological features and visual prognosis of Behçet's disease. Jpn J Ophthalmol. 1999;43(4):312-7.
37. Nussenblatt RB. Uveitis in Behçet's disease. Int Rev Immunol. 1997;14(1):67-79.
38. Mishima S, Masuda K, Izawa Y, et al. The eighth Frederick H. Verhoeff Lecture, presented by Saichi Mishima, MD. Behçet's disease in Japan: ophthalmologic aspects. Trans Am Ophthalmol Soc. 1979;77:225-279.
39. Baer JC, Raizman MB, Foster CS. Ocular Behçet's disease in the United States. Clinical presentation and visual outcome in 29 patients. In: Masahiko U, Shigeaki O, Koki A, eds. Proceedings of the Fifth International Symposium on the Immunology and Immunopathology of the Eye; Tokyo, New York: Elsevier Science; 1990:383.
40. Barile GR, Flynn TE. Syphilis exposure in patients with uveitis. Ophthalmology. 1997;104(10):1605-9.
41. Margo CE, Hamed LM. Ocular syphilis. Surv Ophthalmol. 1992;37(3):203-20.
42. Deschenes J, Seamone CD, Baines MG. Acquired ocular syphilis: diagnosis and treatment. Ann Ophthalmol. 1992;24(4):134-8.
43. Tamesis RR, Foster CS. Ocular syphilis. Ophthalmology. 1990;97(10):1281-7.
44. Mendelsohn AD, Jampol LM. Syphilitic retinitis. A cause of necrotizing retinitis. Retina. 1984;4(4):221-4.
45. McLeish WM, Pulido JS, Holland S, et al. The ocular manifestations of syphilis in the human immunodeficiency virus type 1-infected host. Ophthalmology. 1990;97(2):196-203.
46. 2015 Sexually Transmitted Diseases Treatment Guidelines. Centers for Disease Control and Prevention website. July 27, 2016. www.cdc.gov/std/tg2015/syphilis.htm. Accessed September 3, 2018.
47. Suzuki J, Oh I, Kezuka T, Sakai J, Goto H. Comparison of patients with ocular tuberculosis in the 1990s and the 2000s. Jpn J Ophthalmol. 2018;54(1):19-23.
48. Cutrufello NJ, Karakousis PC, Fishler J, Albini TA. Intraocular tuberculosis. Ocul Immunol Inflamm. 2010;18(4):281-91.
49. Gupta A, Bansal R, Gupta V, et al. Ocular signs predictive of tubercular uveitis. Am J Ophthalmol. 2010;149(4):562-70.
50. Gupta A, Sharma A, Bansal R, Sharma K. Classification of intraocular tuberculosis. Ocul Immunol Inflamm. 2015;23(1):7-13.
51. Madge SN, Prabhakaran VC, Shome D, et al. Orbital tuberculosis: a review of the literature. Orbit. 2008;27(4):267-77.
52. Rosen PH, Spalton DJ, Graham EM. Intraocular tuberculosis. Eye (Lond) 1990;4(pt 3):486-92.
53. Guidelines for laboratory evaluation in the diagnosis of Lyme disease. American College of Physicians. Ann Intern Med. 1997;127(12):1106-8.
54. Isogai E, Isogai H, Kotake S, et al. Detection of antibodies against Borrelia burgdorferi in patients with uveitis. Am J Ophthalmol. 1991;112(1):23-30.
55. Karma A, Viljanen M, Pirttila T, et al. Ocular Lyme borreliosis. Duodecim. 1993;109(1):35-42.
56. Karma A, Seppala I, Mikkila H, et al. Diagnosis and clinical characteristics of ocular Lyme borreliosis. Am J Ophthalmol. 1995;119(2):127-35.
57. Mikkila H, Karma A, Viljanen M, Seppala I. The laboratory diagnosis of ocular Lyme borreliosis. Graefes Arch Clin Exp Ophthalmol. 1999 Mar;237(3):225-30.
58. Flach AJ, Lavoie PE. Episcleritis, conjunctivitis, and keratitis as ocular manifestations of Lyme disease. Ophthalmology. 1990;97(8):973-5.
59. Lyme Disease – Health Care Providers – Diagnosis, Treatment and

Testing. Centers for Disease Control and Prevention website. December 21, 2018. www.cdc.gov/lyme/healthcare/index.html. Accessed September 3, 2018.

60. Jap A, Chee SP. Viral anterior uveitis. Curr Opin Ophthalmol. 2011;22(6):483-8.
61. North RD, Pavan-Langston D, Geary P. Herpes simplex virus types 1 and 2: therapeutic response to antiviral drugs. Arch Ophthalmol. 1976;94(6):1019-21.
62. Pavan-Langston D, Grene B. Herpes simplex ocular disease. Compr Ther. 1984;10(6):30-6.
63. Pavan-Langston D. Herpes simplex and herpes zoster keratouveitis: diagnosis and management. Bull N Y Acad Med. 1977;53(8):731-48.
64. Pavan-Langston D. Varicella-zoster ophthalmicus. Int Ophthalmol Clin. 1975;15(4):171-85.
65. Pavan-Langston D. Ocular viral infections. Med Clin North Am. 1983;67(5):973-90.
66. Pavan-Langston D. Herpes zoster ophthalmicus. Neurology. 1995;45(12 Suppl 8):S50-1.
67. Wornack LW, Liesegang TJ. Complications of herpes zoster ophthalmicus. Arch Ophthalmol. 1983;101(1):42-5.
68. A controlled trial of oral acyclovir for iridocyclitis caused by herpes simplex virus. The Herpetal Eye Disease Study Group. Arch Ophthalmol. 1996;114(9):1065-72.
69. Chee SP, Bacsal K, Jap A, et al. Clinical features of cytomegalovirus anterior uveitis in immunocompetent patients. Am J Ophthalmol. 2008;145(5):834-40.
70. Chee SP, Jap A. Cytomegalovirus anterior uveitis: outcome of treatment. Br J Ophthalmol. 2010;94:1648-52.

OSC QUIZ

You can obtain continuing education credit through the Optometric Study Center. Complete the test form and return it with the \$35 fee to: Jobson Healthcare Information, LLC, Attn.: CE Processing, 395 Hudson Street, 3rd Floor New York, New York 10014. To be eligible, please return the card within three years of publication. You can also access the test form and submit your answers and payment via credit card at RGVCE online, www.reviewsc.com.

You must achieve a score of 70 or higher to receive credit. Allow four weeks for processing. For each Optometric Study Center course you pass, you earn 2 hours of credit from Pennsylvania College of Optometry and double credit toward the AOA Optometric Recognition Award—Category 1.

Please check with your state licensing board to see if this approval counts toward your CE requirement for relicensure.

1. A patient with new onset pain, redness and photophobia has anterior uveitis with no past history of uveitis. What best describes the patient's clinical course?

a. Acute anterior uveitis.



TAKE THE TEST ONLINE TODAY!
<http://www.reviewsc.com>

OSC QUIZ

- b. Chronic anterior uveitis.
c. Recurrent anterior uveitis.
d. Undifferentiated anterior uveitis.
2. All of the following are suggestive of an infectious etiology of anterior uveitis, *except*.
a. Recurrent granulomatous uveitis.
b. Chronic granulomatous uveitis.
c. Acute non-granulomatous uveitis.
d. Chronic bilateral uveitis.
3. Which of the following is most suggestive of an infectious underlying etiology?
a. 44-year-old white male with chronic bilateral anterior uveitis with increased IOP, iris atrophy and large mutton-fat KPs on the endothelium.
b. 12-year-old white male with acute anterior uveitis of the left eye.
c. 49-year-old Hispanic male with recurrent alternating anterior uveitis of the left eye and fine KPs on the endothelium.
d. 34-year-old black male with acute bilateral anterior uveitis.
4. Which of the following is a clinical sign of non-granulomatous inflammation?
a. Bussaca nodules.
b. Mutton-fat KPs.
c. Fine white KPs.
d. Bulbar conjunctival nodules.
5. You count 15 anterior chamber cells in a 1 mm x 1 mm slit beam. Based on classification by the SUN Working Group, what grade of cells does your patient have?
a. 1+.
b. 2+.
c. 3+.
d. 5+.
6. A 58-year-old black female presents with a complaint of a blurry left eye for the past two weeks. She also reports redness and seven out of 10 pain that is progressing. Upon clinical exam, you note 3+ anterior chamber cells with 2+ flare. She has posterior synechiae at 2:00 and 5:00. You diagnose the patient with acute anterior uveitis. Which treatment is the most appropriate for this patient?
a. Difluprednate q1hr OS.
b. Prednisolone acetate 1% every two hours and homatropine 5% BID OS.
c. Prednisolone acetate 1% QID OS.
d. Atropine 1% QID OS.
7. What is the standard dosing frequency of difluprednate 0.05% to treat acute anterior uveitis?
a. Every one to two hours.
b. 12 times/day.
c. Four times/day.
d. Once daily.
8. Which topical corticosteroid should be considered first for a patient with steroid-induced IOP spikes?
a. Dexamethasone 0.1%.
b. Prednisolone acetate 1%.
c. Loteprednol 0.5%.
d. Difluprednate 0.05%.
9. When should you begin to taper topical corticosteroids?
a. Once fewer than five cells per high-powered field are visible in the anterior chamber.
b. After three months of treatment.
c. After laboratory tests confirm no infection.
d. Tapering of corticosteroids is not required with anterior uveitis.
10. A child has anterior uveitis and you suspect JIA. All of the following blood tests should be performed, *except*.
a. ANA.
b. HLA-B27.
c. Rheumatoid factor.
d. Polymerase chain reaction.
11. All of the following are conditions associated with HLA-B27, *except*.
a. Ankylosing spondylitis.
b. Reactive arthritis.
c. Psoriatic arthritis.
d. Rheumatoid arthritis.
12. What is the most common non-infectious underlying etiology for anterior uveitis?
a. Sarcoidosis.
b. HLA-B27 spondyloarthropathy.
c. Systemic lupus erythematosus.
d. Behcet's disease.
13. Which of the following is true of the HLA-B27 spondyloarthropathies?
a. HLA-B27 uveitis is non-granulomatous and non-infectious.
b. Patients with HLA-B27 test positive for rheumatoid factor.
c. Ankylosing spondylitis is caused from past exposure to certain bacterial infections.
d. Psoriatic arthritis has the triad of uveitis, plaque psoriasis and abdominal cramping.
14. You are treating a 37-year-old white male for acute, recurrent, alternating non-granulomatous anterior uveitis. When developing your differential diagnosis, which underlying etiology is at the top of your list?
a. Cytomegalovirus.
b. HLA-B27.
c. Herpes simplex virus.
d. Varicella zoster virus.
15. All of the following systemic conditions are correctly paired with a matching lab test, *except*.
a. Syphilis – MHA-TP.
b. Tuberculosis – Interferon gamma.
c. Sarcoidosis – ANA.
d. Ulcerative colitis – HLA B27.
16. What is the systemic treatment for early latent syphilis?
a. A daily intramuscular injection of penicillin for three days.
b. A weekly intramuscular injection of penicillin for three weeks.
c. A single intramuscular injection of penicillin.
d. Intravenous penicillin every four hours for 10 days.
17. What is the recommended treatment for an adult with Lyme disease?
a. Amoxicillin 100mg for 21 days.
b. Doxycycline 100mg for 21 days.
c. Valacyclovir 1,000mg for 14 days.
d. Amoxicillin 500mg for 21 days.
18. What is the most common infectious underlying etiology for anterior uveitis?
a. Bacteria.
b. Viruses.
c. Syphilis.
d. Tuberculosis.
19. Which underlying etiology condition best describes a patient with recurrent anterior uveitis, elevated IOP and iris atrophy that occurs only in one eye?
a. Herpes simplex virus.
b. Tuberculosis.
c. Juvenile idiopathic arthritis.
d. Psoriatic arthritis.
20. Treatment of a patient with acute HSV-associated uveitis should include:
a. Doxycycline 100mg.
b. Valacyclovir 500mg TID.
c. Acyclovir 800mg BID.
d. Single intramuscular injection of penicillin.

Examination Answer Sheet

Take a Clinical Approach to Anterior Uveitis

Valid for credit through February 15, 2022

Online: This exam can be taken online at www.reviewscce.com. Upon passing the exam, you can view your results immediately and download a real-time CE certificate. You can also view your test history at any time from the website.

Directions: Select one answer for each question in the exam and completely darken the appropriate circle. A minimum score of 70% is required to earn credit.

Mail to: Jobson Healthcare Information, LLC, Attn.: CE Processing, 395 Hudson Street, 3rd Floor New York, New York 10014

Payment: Remit \$35 with this exam. Make check payable to Jobson Healthcare Information, LLC.

Credit: This course is COPE approved for 2 hours of CE credit. Course ID is 60776-AS.

Jointly provided by Postgraduate Institute for Medicine and RGVC.

Salus University has sponsored the review and approval of this activity.

Processing: There is a four-week processing time for this exam.

Answers to CE exam:

1. (A) (B) (C) (D)
2. (A) (B) (C) (D)
3. (A) (B) (C) (D)
4. (A) (B) (C) (D)
5. (A) (B) (C) (D)
6. (A) (B) (C) (D)
7. (A) (B) (C) (D)
8. (A) (B) (C) (D)
9. (A) (B) (C) (D)
10. (A) (B) (C) (D)
11. (A) (B) (C) (D)
12. (A) (B) (C) (D)
13. (A) (B) (C) (D)
14. (A) (B) (C) (D)
15. (A) (B) (C) (D)
16. (A) (B) (C) (D)
17. (A) (B) (C) (D)
18. (A) (B) (C) (D)
19. (A) (B) (C) (D)
20. (A) (B) (C) (D)

Post-activity evaluation questions:

Rate how well the activity supported your achievement of these learning objectives:

1=Poor, 2=Fair, 3=Neutral, 4=Good, 5=Excellent

21. Demonstrate knowledge of the ocular signs and symptoms, as well as systemic associations, related to anterior uveitis. (1) (2) (3) (4) (5)
22. Use common laboratory tests to help localize the etiology of the uveitis. (1) (2) (3) (4) (5)
23. Perform a dilated fundus examination for all patients who present with anterior uveitis. (1) (2) (3) (4) (5)
24. Define the appropriate topical or systemic anti-inflammatories and, importantly, the frequency of dosing, for managing anterior uveitis. (1) (2) (3) (4) (5)
25. Describe the use of cycloplegia to reduce pain, prevent synechiae formation and re-establish the blood-aqueous barrier. (1) (2) (3) (4) (5)
26. Based upon your participation in this activity, do you intend to change your practice behavior? (choose only one of the following options)
 - (A) I do plan to implement changes in my practice based on the information presented.
 - (B) My current practice has been reinforced by the information presented.
 - (C) I need more information before I will change my practice.
27. Thinking about how your participation in this activity will influence your patient care, how many of your patients are likely to benefit? (please use a number):

28. If you plan to change your practice behavior, what type of changes do you plan to implement? (check all that apply)

- (a) Apply latest guidelines (b) Change in pharmaceutical therapy (c) Choice of treatment/management approach (d) Change in current practice for referral (e) Change in non-pharmaceutical therapy (f) Change in differential diagnosis (g) Change in diagnostic testing (h) Other, please specify: _____

29. How confident are you that you will be able to make your intended changes?

- (a) Very confident (b) Somewhat confident (c) Unsure (d) Not confident

Please retain a copy for your records. Please print clearly.

First Name

Last Name

E-Mail

The following is your: Home Address Business Address

Business Name

Address

City State

ZIP

Telephone # - -

Fax # - -

By submitting this answer sheet, I certify that I have read the lesson in its entirety and completed the self-assessment exam personally based on the material presented. I have not obtained the answers to this exam by any fraudulent or improper means.

Signature _____ Date _____

Lesson 117642

RO-OSC-0219

30. Which of the following do you anticipate will be the primary barrier to implementing these changes?

- (a) Formulary restrictions (b) Time constraints (c) System constraints (d) Insurance/financial issues (e) Lack of interprofessional team support (f) Treatment related adverse events (g) Patient adherence/compliance (h) Other, please specify: _____

31. Additional comments on this course:

Rate the quality of the material provided:
 1=Strongly disagree, 2=Somewhat disagree, 3=Neutral, 4=Somewhat agree, 5=Strongly agree

32. The content was evidence-based.

- (1) (2) (3) (4) (5)

33. The content was balanced and free of bias.

- (1) (2) (3) (4) (5)

34. The presentation was clear and effective.

- (1) (2) (3) (4) (5)

35. Based upon your participation in this activity, do you intend to change your practice behavior?

- (1) (2) (3) (4) (5)

Earn up to
20 CE
Credits*

NEW TECHNOLOGIES
& TREATMENTS IN
2019 EYE CARE

RGVCE
REVIEW'S COMMITMENT TO
CONTINUING EDUCATION

Join us in

Orlando, Florida

March 7-10, 2019

Join us for *Review's* New Technologies & Treatments in Eye Care March 7-10, 2019 in Orlando at Disney's Yacht & Beach Club. Earn up to 20* COPE CE credits including interactive workshops!**



The program includes six (6) TQ/CEE Credits for those Optometrists licensed in Florida or other states requiring transcript quality courses for re-licensure.

REGISTRATION COST: \$595

FACULTY



Paul M. Karpecki, OD, FAAO
Program Chair



Doug Devries, OD



Blair Lonsberry, MS, OD, MEd, FAAO



Diana Shechtman, OD, FAAO



Joseph Shovlin, OD, FAAO

DISNEY'S YACHT & BEACH CLUB

1700 Epcot Resorts Boulevard
Orlando, Florida 32830
Phone: 407-934-7000

See website for updated hotel accommodations.



3 WAYS TO REGISTER

online: www.reviewscce.com/Orlando2019

email: reviewmeetings@jhihealth.com | **phone:** 866-658-1772

**Separate registration required. RGVCE partners with Salus University for those ODs who are licensed in states that require university credit. See event website for complete details.

Administered by
RGVCE
REVIEW'S COMMITMENT TO CONTINUING EDUCATION



*Approval pending



SALUS
UNIVERSITY
Pennsylvania College of Optometry

Partially supported by an
unrestricted educational grant from
Bausch & Lomb



Making the Leap

Avoiding corneal touch whenever possible when fitting scleral lenses helps minimize the risk of long-term ocular damage. **Edited by Joseph P. Shovlin, OD**

Q I struggle with the concept of achieving complete cornea clearance in every patient fit with scleral lenses. For years, we've accepted some apical touch in keratoconus patients who wear corneal lenses, especially in those with especially steep apical areas. Should we try to completely avoid touch in these patients or is some touch acceptable?

A “One of the foundational concepts of scleral lens fitting is complete corneal clearance,” says Jason Jedlicka, OD, associate professor at the Indiana University School of Optometry and chief of the school's Cornea and Contact Lens Service. He adds that part of what defines a scleral lens is that all the lens bearing occurs on the sclera, hence the name. Dr. Jedlicka notes that some may question whether it is necessary for scleral lenses to fully vault the cornea or if optometrists can fit these lenses with some bearing of the lens on

the cornea and still achieve good results. The answer, he says, is it is possible, but not without taking on some risk.

“The idea of a fully vaulting, touch-free corneal lens is appealing to specialty lens practitioners who want to prevent scarring, which leads to vision loss,” Dr. Jedlicka notes. He adds that if a scleral lens were to touch the corneal apex, over time the same risk of chronic staining that leads to irritation and photophobia—and eventually scarring and vision loss—would also be present.

Weighing Your Options

Scleral lenses can touch the cornea anywhere on the surface, increasing the risk of visual and ocular health complications if persistent. According to Dr. Jedlicka, this can happen when a scleral lens is fit too shallow. When this occurs peripherally, he says epithelial bullae formation could occur, likely from mechanical forces on the epithelial tight junctions (Figure 1).¹ On the other hand, when this occurs centrally, he notes that the result is similar to what happens during corneal gas permeable lens use—staining and potentially scarring (Figure 2).

Corneal touch can also

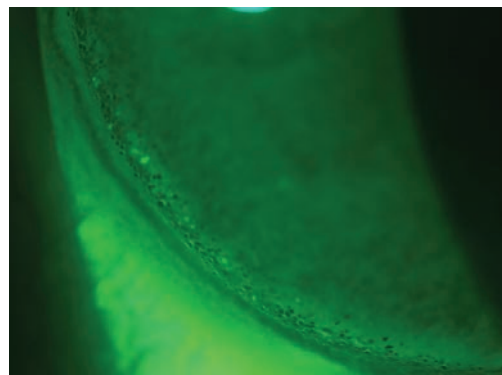


Fig. 1. Epithelial bullae from a scleral lens land and bear on the peripheral cornea.

lead to difficult lens removal, says Dr. Jedlicka. Adhesion forces between a contact lens and an eye increase as the lens surface and the eye surface become increasingly close over a larger surface area, he adds. When fitted with proper vault over the entire cornea and limbal zone, he notes that a scleral lens should not exhibit adhesion—though it may exhibit “suction”—and, therefore, should not be as challenging to remove.

While we see many instances in which scleral lenses end up with corneal contact that does not lead to any complications, Dr. Jedlicka says the risks increase when touch occurs. He recommends making every attempt to avoid corneal touch when fitting scleral lenses to minimize these risks and prevent long-term damage. ■

1. Nixon AD, Barr JT, VanNasdale DA. Corneal epithelial bullae after short-term wear of small diameter scleral lenses. *Cont Lens Anterior Eye*. 2017;40(2):116-26.

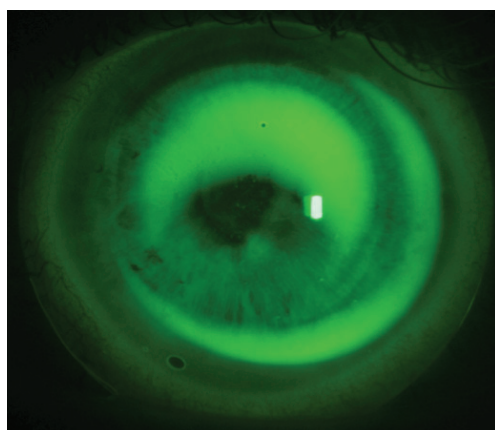


Fig. 2. This scleral lens was fit with corneal touch. Note the corneal staining on the apex.



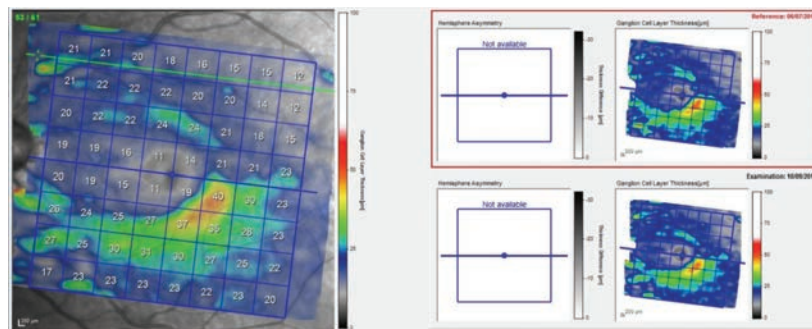
If Only They Had Asked

Complications can and do occur, though some can be averted. **By James L. Fanelli, OD**

A 63-year-old Caucasian female presented to the office as a new patient in June seeking a second opinion. She had presented to an eye clinic earlier in the year with complaints of gradually decreasing vision. The patient attributed this to normal decline in her vision, and felt that her eyeglasses needed to be updated. She was told that she did have a change in her prescription and that new glasses were warranted, but also that she needed to see a glaucoma specialist for a “laser procedure.”

She ordered new eyeglasses, and shortly thereafter she made her way to an ophthalmic surgeon who performed a laser procedure on both eyes that same day. Approximately two weeks after the procedure, she developed moderate pain, with photophobia and a headache lasting a couple of days as well as difficulty seeing out of the left eye. She subsequently reported back to the surgeon who performed the laser procedure, and was put on drops (the patient did not know which ones specifically, but she remembered she was to shake the drops vigorously before instillation) for what was about five days, during which time the pain seemed to resolve, but her vision remained blurry. She reported back to the surgeon who then referred her to retina.

Apparently when seen at retina, blood work was ordered and the patient was told that she may have had a “stroke” in the eye. In a sub-



This OCT shows our patient’s left macula, highlighting the ganglion cells. Note the significant loss of ganglion cells superiorly as compared with inferiorly, and the lack of change seen as compared with the baseline. This is consistent with chronic phase ganglion cell loss, as opposed to acute loss.

sequent follow-up with retina, the patient was told the blood work was normal and the residual effects on vision to her left eye are permanent. She was then sent to my office.

Examination

When seen by me for the first time, she was only taking lisinopril, and had been so for several years, and she was taking no topical medications. Her best-corrected visual acuities were 20/20-1 OD and 20/50 OS. Her pupils were round and reactive to light, and there was a 2+ afferent pupillary defect in her left eye. Confrontation fields demonstrated an altitudinal defect in the left eye and were normal in the right.

A slit lamp examination of her corneas was unremarkable. Both anterior chamber angles appeared somewhat narrow at the slit lamp using the Van Herick technique. Her right eye had a laser peripheral iridotomy (LPI) at 12 o’clock, and in

the left there were two LPIs, one at 3 o’clock and the other at 9 o’clock. Her anterior chambers were quiet with no cells or flare. Applanation tensions at 3:45pm were 23mm Hg OD and 24mm Hg OS. Pachymetry readings were 598µm OD and 594µm OS.

Threshold visual fields were entirely normal in the right eye. The left was characterized by a field defect extending from the blind spot to fixation, greater below the horizontal than above. The findings were consistent with an optic nerve infarct and with the confrontation field findings.

The patient was dilated in the usual fashion. Through dilated pupils, her crystalline lenses were characterized by mild nuclear sclerosis in both eyes.

The cup-to-disc ratio in her right eye was 0.3x0.3 and that of the left was 0.4x0.4. The neuroretinal rim in the right was plush and well per-

fused, whereas that of the left was pale and atrophic from 12 o'clock to 4 o'clock. Both maculae were healthy. Her retinal vascular details were also unremarkable. The peripheral retina was characterized by scattered areas of cystoids degeneration in both eyes. Post dilation pressures were 22mm Hg OD and OS, with open angles.

OCT imaging of the optic nerves was consistent with a chronic appearance of non-arteritic ischemic optic neuropathy (NAION) in the left eye; the OCT imaging of the right optic nerve was unremarkable. Neuro OCT imaging of the left optic nerve demonstrated a reduced papillomacular bundle, consistent with the findings of NAION.

History

Much of the history on the initial visit was from the patient's perspective, and I've learned over the years that, sometimes what actually happens is different than what is portrayed in the history. Subsequent to our first visit together, I was able to obtain relevant medical records, and the patient's interpretation of the series of events was fairly accurate.

One of my initial questions at the first visit centered around what transpired during the laser procedure. It was my interpretation from the history, and later confirmed by review of the medical records, that the patient was only given two drops in each eye of Iopidine (apraclonidine, Novartis) in the office, and was discharged on a regimen of Pred Forte (prednisolone acetate, Allergan) to use for three days. No follow-up was scheduled.

On the follow-up visit after the patient experienced pain and blurred vision, she was again prescribed Pred Forte QID and was scheduled to see a retina specialist. There was no mention of the status of the anterior

chamber at that visit, and IOPs were 20mm Hg OD and OS.

Diagnosis

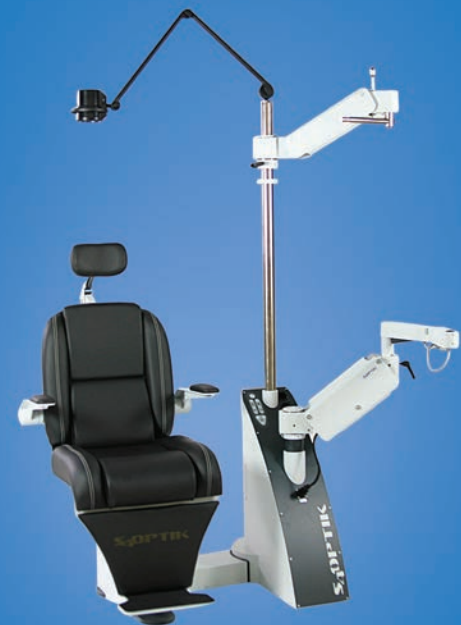The retinologist diagnosed an ischemic optic neuropathy and the patient was ultimately sent to me. As best as I can tell, sometime following the LPI, most likely within the first few days, the left optic nerve infarcted. Did the LPI contribute to that? Possibly, though we'll never know for certain. But the timeframe fits. Could she have experienced an exaggerated inflammatory response in the left eye that underwent two LPI procedures? Could she have had a concurrent IOP spike post LPI in the left eye? What did that eye look like in the immediate post LPI period? The answers to these questions are unknown, as no follow-up was performed until after the patient developed symptoms.

This is an important reminder that, following LPI, the patient must be examined several days later for some of the common side effects from the procedure, such as inflammation and IOP elevation, not to mention what effect it has on opening the angles and reducing the risk of angle closure. And therein lies the rub in this unfortunate situation.

Imaging

Standard protocol in my office when I am examining patients with narrow or slightly narrow angles is to obtain an ultrasound biomicroscopy (UBM) image of the anterior segment. While the angle itself can be visualized in a variety of ways, namely, at the slit lamp, during gonioscopy, and with anterior segment OCT imaging, there are times when UBM gives us important details. And one of the situations where UBM gives us more data than the aforementioned procedures is in the case of plateau iris configuration.

Optimize space and functionality.



Affordable, space-saving chair & stand solutions.

Small footprint
41.2" x 34.2"

REGISTER NOW

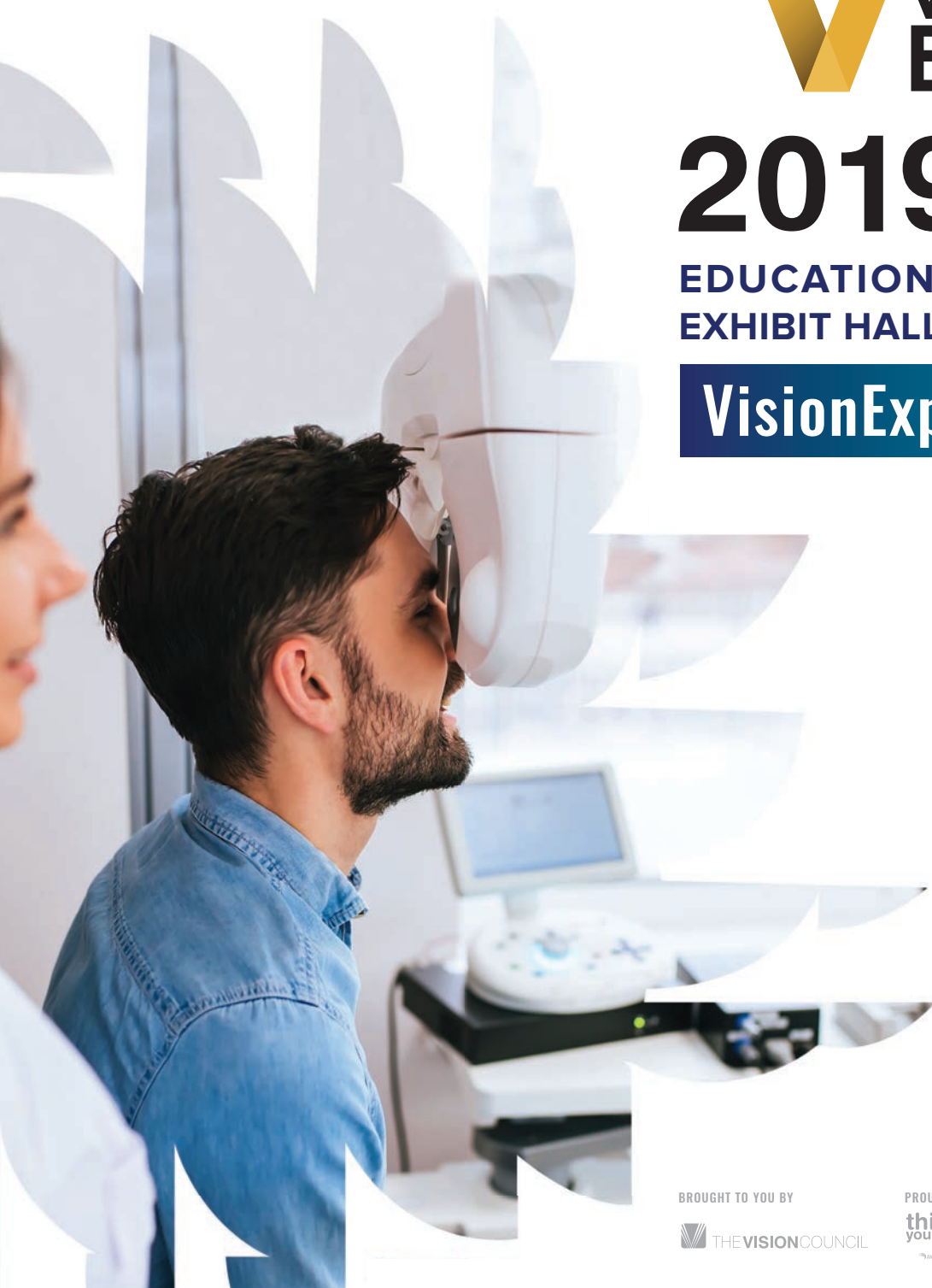JOIN US IN NEW YORK CITY AT THE COMPLETE EVENT FOR OPHTHALMIC PROFESSIONALS. COME SEE WHERE EYECARE MEETS EYEWEAR AND EDUCATION, FASHION, INNOVATION AND BUSINESS MINGLE.

V VISION
EXPO

2019 NYC

EDUCATION MARCH 21-24
EXHIBIT HALL MARCH 22-24

VisionExpoEast.com



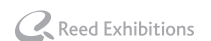BROUGHT TO YOU BY

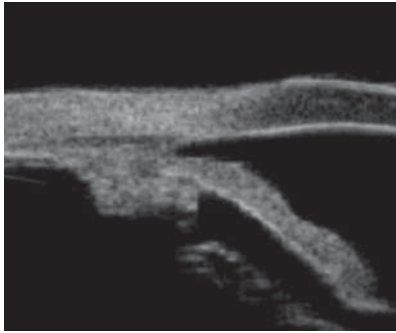

PROUD SUPPORTER OF



PRODUCED BY





Note the relative anterior positioning of the ciliary body posterior to the iris root, and the subsequent anterior displacement of the iris root. This can be seen on slit lamp as a narrow angle, but without the ciliary body being visible on slit lamp exam, the diagnosis of plateau iris configuration cannot be made.

In plateau iris configuration, the ciliary body and ciliary processes are positioned more anteriorly, and therefore result in the iris being positioned more anteriorly, especially toward the iris root. The iris may appear non-bowed on clinical examination. The mechanism of angle closure in plateau iris syndrome is different than in normal anatomically narrow angles, where typically pupillary block results in elevation of IOP in the posterior chamber, which in turn forces the iris root more anteriorly.

The benefit of LPI in cases of narrow angles and pupillary block glaucoma is well documented. However, LPIs have little effect in reducing the potential closure of the angle in cases of plateau iris configuration.

Plateau iris syndrome is essentially a form of angle closure glaucoma, but with a mechanism different than outlined above, and with the appearance of narrow angle glaucoma.¹ UBM plays an important role in differentiating anatomically narrow angles from plateau iris configuration.^{2,3}

Treatment

Because a plateau iris configuration lends itself to a different mechanism of subsequent angle closure, the treatment options are different. The treatment of choice in plateau iris situations is a laser iridoplasty.¹ In argon laser peripheral iridoplasty, laser energy is applied to the peripheral iris in a circumferential pattern. The thermal energy applied to the iris causes contracture of the iris, and a somewhat posterior planar movement of the peripheral iris away from the cornea and trabecular meshwork.

Researchers suggest that, when an LPI is performed and there is no opening of the anterior chamber angle, plateau iris configuration be considered.¹ And that is exactly what happened in this case; post LPI, the angle configuration had not changed. Of course hindsight is always 20/20, but pre-surgical evaluation with UBM can facilitate the diagnosis before intervention is performed.

What is doubly unfortunate in this case is that the ophthalmic surgeon who performed the LPI does not have a UBM unit. We do, and the surgeon knows that we do. How many times has that surgeon sent a patient to this OD for that procedure? Precisely zero. One of the other things I've learned throughout the years is that some ophthalmic surgeons give lip service to working with optometry, when in fact their actions sometimes speak louder than words. Someone is still fighting the old battles between the professions. And unfortunately, it is the patient who invariably loses. ■

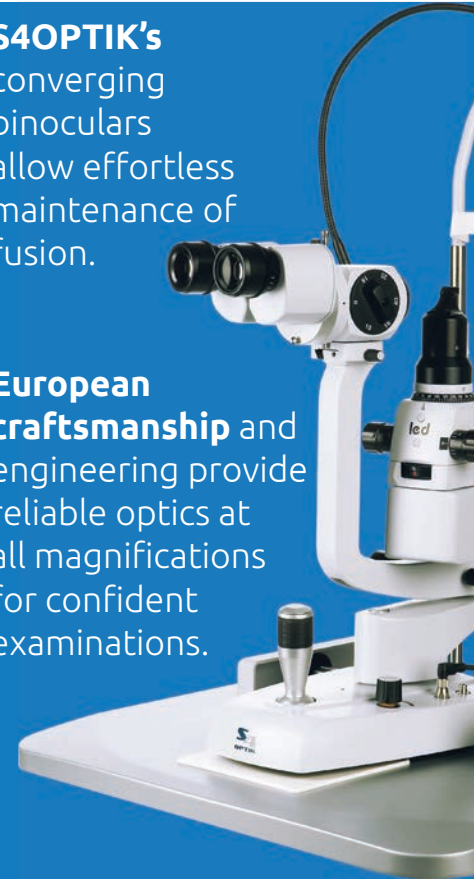1. Stefan C, Iliescu D, Batras M, et al. Plateau iris – diagnosis and treatment. *Rom J Ophthalmol.* 2015;59(1):14-8.
2. Kumar G, Bali S, Panda A, et al. Prevalence of plateau iris configuration in primary angle closure glaucoma using ultrasound biomicroscopy in the Indian population. *Indian J Ophthalmol.* 2012;60(3):175-8.
3. Parc C, Laloum J, Berges O. Comparison of optical coherence tomography and ultrasound biomicroscopy for detection of plateau iris. *J Fr Ophthalmol.* 2010;33(4):266:e1-3.

SLIT LAMPS

EXCEPTIONAL OPTICS

S4OPTIK's converging binoculars allow effortless maintenance of fusion.

European craftsmanship and engineering provide reliable optics at all magnifications for confident examinations.



Vertical and compact configurations available.



Grow Some Nerve

A new treatment holds promise for helping patients with neurotrophic keratitis.

By Paul M. Karpecki, OD

Neurotrophic keratitis (NK) is a corneal degenerative disease characterized by reduced corneal sensation, chronic superficial keratopathy (SPK), persistent epithelial defects and other corneal changes. Although an “orphan disease” affecting fewer than five people out of every 10,000, NK is quite challenging to manage when it presents. Untreated or undertreated, it can have serious consequences for vision and quality of life.^{1,2}

NK Basics

The cornea and corneal epithelium are densely innervated by nerves originating from the ophthalmic branch of the trigeminal (fifth cranial) nerve. In fact, the cornea has 7,000 nerve receptors per square millimeter, making it one of the most sensitive structures in the body.¹ Those nerves are responsible for nociception (pain perception) and sensation of cold and pressure. They are part of complex feedback loops that signal tear production, the blink reflex, the production of trophic factors that provide nutrition to the cornea and the release of immune factors into the tears.¹

Infrequent blinking and reduced tear production in NK exacerbate the condition, leading to an inflamed ocular surface and further epithelial damage. When epithelial healing is compromised, the exposed stroma becomes more vulnerable to enzymatic degradation and, eventually, ulceration or even perforation.³

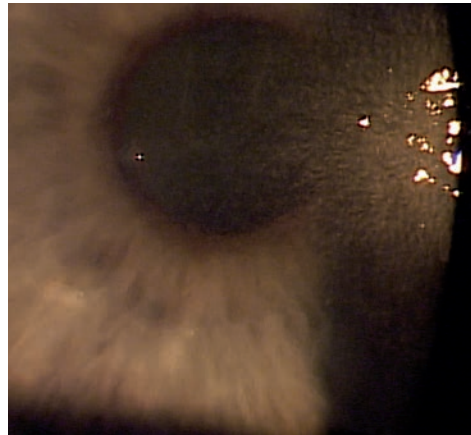


Fig. 1. Neurotrophic keratitis in a patient with herpes simplex keratitis.

NK is most commonly associated with herpetic keratitis (either herpes zoster or herpes simplex), post-neurosurgical nerve damage and diabetes (*Figure 1*).^{1,4} It may also be caused by chemical burns, contact lens misuse, long-term exposure to preserved medications, overuse of topical anesthetics and, less commonly, with tumors, leprosy and certain genetic conditions.¹

Presentation and Examination

One study recently proposed a simplified classification of NK: *mild*, denoted by epithelium and tear film changes; *moderate*, accompanied by a non-healing epithelial defect; or *severe*, in which stromal melting and perforation occur.¹ These three stages are clinically useful for understanding the severity of disease and potential treatments.

In patients presenting with early to mid-stage NK, it is common to

see significant staining or SPK and epithelial defects that don't heal properly, as well as rapid tear break-up time and reduced or fluctuating visual acuity. However, patients will often be far less symptomatic than you would expect due to the reduced corneal sensation. As the disease progresses, corneal thinning, ulceration and even perforation occur.

In patients presenting with these signs and symptoms, optometrists should carefully evaluate the lid anatomy

and function, including closure and blink rate. If you suspect NK, assess corneal sensation by using either a cotton wisp or acrylic dental floss applied to the cornea. You could also use an esthesiometer. Staining with vital dyes is important for visualizing ocular surface damage (*Figure 2*). Suspicion of underlying brain pathology or systemic disease may warrant a referral to internal medicine or neurology.

Treatment

NK has always been a challenging condition to treat. Until recently, we have had few good options, especially for patients with moderate disease in particular.

As a first step, clinicians should minimize ocular irritants. Eliminate all preserved topical drops (if possible) by reducing medications or switching to non-preserved forms.⁵ Regular use of artificial tears and

other lubricants, punctal occlusion, increased humidity and dietary omega fatty acids can all be helpful as well. Research shows autologous serum drops (e.g., Vital Tears) improve signs and symptoms and significantly shorten healing time for, and recurrences of, corneal defects.⁶ Clinicians may need to debride any thickened or rolled edges of epithelial defects.⁷ A bandage contact lens can be helpful but also increases the risk of infection.² A better option might be amniotic membrane. One study using Prokera (BioTissue) showed a statistically significant improvement in nerve density and sensitivity when analyzing the corneal nerves under confocal microscopy.⁸ These patients also showed improvement in corneal staining, symptoms of pain and SPEED scores.⁸

Nonsurgical eyelid closure with tape, pressure patching or temporary ptosis with botulinum toxin can help to protect loose epithelium and while epithelial defects heal.

It is also important to treat concurrent infection, inflammation or meibomian gland dysfunction with appropriate therapies, such as antibiotics, cyclosporine, lid expression and lid hygiene.

In more advanced stages of the disease, a number of strategies can help to restore corneal integrity or, for the most extreme stages, prioritize globe integrity over vision. These include temporary or permanent tarsorrhaphy, use of corneal tissue glue, amniotic membrane graft, Boston keratoprosthesis, lamellar or penetrating keratoplasty and a partial or total conjunctival flap (Figure 2).⁹ Eyes with NK have a higher than usual rate of failure for corneal surgery.²

Treatment Advances

The FDA recently approved a new treatment for NK that is expected to launch commercially in early 2019. Oxervate (cenegermin-bkbj ophthalmic solution 0.002%, Dompé) is a recombinant form of human nerve growth factor that targets the nerve pathology.¹⁰ In two randomized double-masked controlled trials, 151 subjects received cenegermin or vehicle six times daily for eight weeks. Complete corneal healing was demonstrated in 70% of the 101 patients treated with Oxervate compared with only 28% of those treated with the control drop.^{11,12}

The most common adverse reaction was eye pain following instillation, which was reported in approximately 16% of patients. Other adverse reactions included corneal deposits, foreign body sensation, ocular hyperemia, ocular inflammation and tearing.^{12,13}

Oxervate will be somewhat more challenging for patients to administer than the average topical medication. A week's supply of the medication, frozen, must be shipped directly to patients, who will thaw one of the seven multidose vials

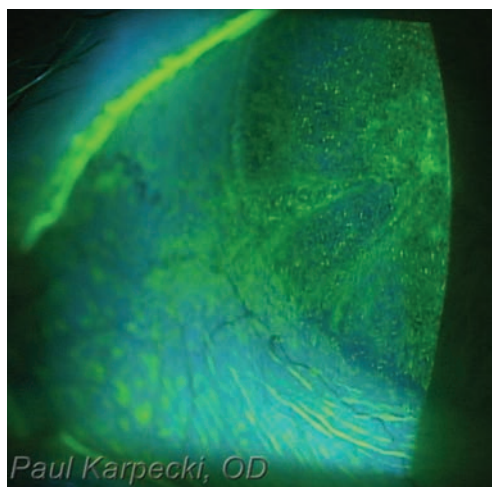


Fig. 2. Vital dyes are key diagnostic tools to help clinicians visualize ocular surface damage from neurotrophic keratitis.

each day and store in the refrigerator between doses. Instructions will be provided for attaching an adapter to the vial, cleaning the adapter with a sterile wipe, attaching a special pipette with a plunger mechanism, and then releasing the drop from the plunger to administer one drop every two hours, six times a day.¹³ Although the steps may be cumbersome, mastering them is worthwhile, considering cenegermin holds greater potential than most of the treatment options we have for NK.

There are several other biologics and other therapies in practice and in the pipeline, including Xiidra (lifitegrast 5%, Shire), regenerating matrix therapy agent cacicol-20, thymosin beta 4, coenzyme Q10, substance P, netrin-1 and Nexagon (CoDa Therapeutics), an antisense oligonucleotide.

With these new therapies, we can be far more encouraged than ever before about our ability to successfully manage patients with NK. ■

1. Dua HS, Said DG, Messmer EM, et al. Neurotrophic keratopathy. *Prog Retin Eye Res.* 2018;66:107-31.
2. Srinivasan S, Lyall DAM. Neurotrophic keratopathy. In: *Ocular Surface Disease: Cornea, Conjunctiva, and Tear Film.* Holland EJ, Mannis MJ, Lee WB, eds. Philadelphia: Elsevier; 2013.
3. Fini ME, Cook JR, Mohan R. Proteolytic mechanisms in corneal ulceration and repair. *Arch Dermatol Res.* 1998;290(Suppl 1):S12-23.
4. Allen VD, Malinovsky V. Management of neurotrophic keratopathy. *Cont Lens Anterior Eye.* 2003;26(3):161-5.
5. Gomes JAP, Azar DT, Baudouin C, et al. FOS DEWS II iatrogenic report. *Ocul Surf.* 2017;15:511-37.
6. Guadilla AM, Balado P, Baeza A, Merino M. Effectiveness of topical autologous serum treatment in neurotrophic keratopathy. *Arch Soc Esp Ophthalmol.* 2013;88(8):302-6.
7. Katzman LR, Jeng BH. Management strategies for persistent epithelial defects of the cornea. *Saudi J Ophthalmol.* 2014;28:168-72.
8. John T, Tighe S, Sheha H, et al. Corneal nerve regeneration after self-retained cryopreserved amniotic membrane in dry eye disease. *J Ophthalmol.* 2017;2017:6404918.
9. Bonini S, Rama P, Olzi D, et al. Neurotrophic keratitis. *Eye.* 2003;17:989-95.
10. Bonini S, Lambiase A, Rama P, et al., REPARO Study Group. Phase I trial of recombinant human nerve growth factor for neurotrophic keratitis. *Ophthalmology.* 2018;125(9):1468-71.
11. Sacchetti M, Bruscolini A, Lambiase A. Cenegermin for the treatment of neurotrophic keratitis. *Drugs Today (Barc).* 2017;53(11):585-95.
12. Bonini S, Lambiase A, Rama P, et al., REPARO Study Group. Phase II randomized, double-masked, vehicle-controlled trial of recombinant human nerve growth factor for neurotrophic keratitis. *Ophthalmology.* 2018;125(9):1332-43.
13. Oxervate Prescribing Information (PI). www.accessdata.fda.gov/drugsatfda_docs/label/2018/761094s000lbl.pdf. Accessed January 14, 2019.



What's in Your Head?

How can this patient's presentation and MRI explain his vision loss?

By Shreya Jayasimha, OD, and Mark Dunbar, OD

A 57-year-old Caucasian male presented with a complaint of gradually decreasing vision in his left eye for the past eight to nine months. He denied any ocular pain, headaches, tinnitus or transient visual obscuration associated with his vision loss. His ocular history is positive for a cataract surgery performed three years earlier in both eyes. His medical history is positive for hypertension, diabetes and sleep apnea, which are medically controlled with lisinopril, metformin and a continuous positive airway pressure machine, respectively. He denied smoking, alcohol or illicit drug use.

On examination, his best-corrected visual acuities were 20/20 OD and counting fingers at three feet in his left eye with a prescription of -1.25 +0.75 x 035 OD, -2.50 +1.00 x 005 OS. Confrontation visual fields were full for the right eye, but revealed a generalized constriction for the left eye. Threshold visual field testing was performed and showed an enlarged blind spot in the right eye and severe depression in the left eye. Extraocular motility was full for both eyes and pupils were equal, round and minimally reactive to light with a trace afferent pupillary defect in the left eye. Color vision, measured with Ishihara plates, was full for the right eye and completely diminished for the left eye (10/10 OD, 0/10 OS).

Intraocular pressures were measured at 15mm Hg and 17mm Hg for the right and left eye, respec-

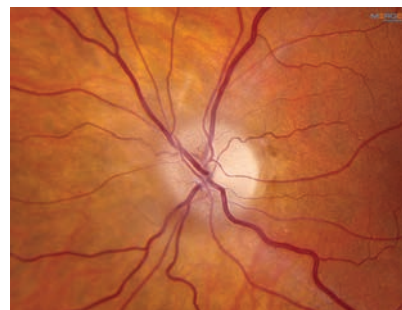
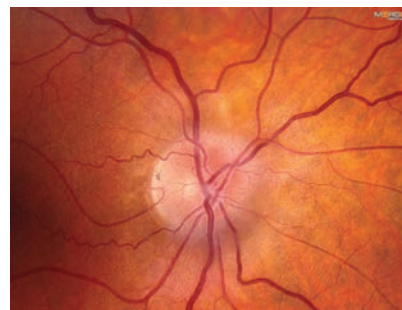
Fig. 1. These are the fundus images of the right and left eyes of our patient. What can they tell you about the cause of the patient's symptoms?

tively. Anterior segment health was unremarkable for both eyes. The dilated fundus exam for both eyes shows a clear vitreous. Images of the optic nerve of each eye are available for review (*Figure 1*). The macula and periphery were unremarkable. Magnetic resonance imaging (MRI) was performed and is available for review (*Figure 2*).

Take the Retina Quiz

- How would you describe the optic nerve appearance in our patient?
 - Normal, distinct margins OU.
 - Optic disc pallor in the left eye.
 - Optic disc edema in the right eye and optic disc pallor in the left.
 - Grade 1 disc edema in both eyes with temporal pallor in the left.
- What does the MRI reveal?
 - A mass in the frontal lobe.
 - A mass in the parietal lobe.
 - An infarct in the occipital lobe.
 - A chiasmal lesion.
- Based on the testing and images, which is the correct diagnosis?

- Guillain-Barré syndrome.
 - Anterior ischemic optic neuropathy.
 - Foster Kennedy syndrome.
 - Pseudo-Foster Kennedy syndrome.
- How should this patient be managed?
 - Observation.
 - IV steroids.
 - Neurosurgical consult.
 - Optic nerve sheath decompression.

Diagnosis

Our patient has subtle grade 1 disc edema in both eyes. What's more, the left eye also has as obvious temporal pallor. This is evident when you compare the coloration of the neuroretinal rim in each eye.

This presentation alone should raise a red flag for possible Foster Kennedy syndrome, which presents as disc edema in one eye and optic nerve pallor in the other.

Foster Kennedy syndrome is characterized by a sub-frontal

meningioma, resulting in compressive optic neuropathy and increased intracranial pressure (ICP).¹ This, in turn, causes optic nerve atrophy and pallor ipsilateral to the tumor and optic disc edema contralateral to the tumor as a result of increased ICP.²

Researchers believe Foster Kennedy syndrome represents 1% to 2.5% of all intracranial masses.⁴ The conditions three clinical presentations include:

- Type 1: Optic atrophy on one side with contralateral disc edema.
- Type 2: Papilledema with unilateral optic atrophy.
- Type 3: Papilledema with bilateral optic atrophy.

Each presentation is dependent upon the location of the tumor and when symptoms are detected. Symptoms include progressive vision loss, ipsilateral anosmia (loss of smell), diplopia, headaches, nausea and vomiting.¹ While its primary location is in the sub-frontal region, it can also present in the olfactory groove, falx cerebri and sphenoid wing, all of which result in a different constellation of signs and symptoms.⁴ An optimal way of diagnosing this condition is through fundoscopic examination coupled with MRI.

One key differential is pseudo-Foster Kennedy syndrome, which is defined as optic nerve pallor in one eye and disc edema in the contralateral eye in the absence of an intracranial mass.⁵ The two most common causes of this condition include, but are not limited to, a bilateral sequential ischemic optic neuropathy or optic neuritis.³ Other, less common causes include a prior papillitis or a secondary optic atrophy from trauma, infectious, inflammatory or infiltrative origins.³ Interestingly, pseudo-Foster Kennedy syndrome is another clinical possibility to consider in our patient. This rare occurrence is defined as

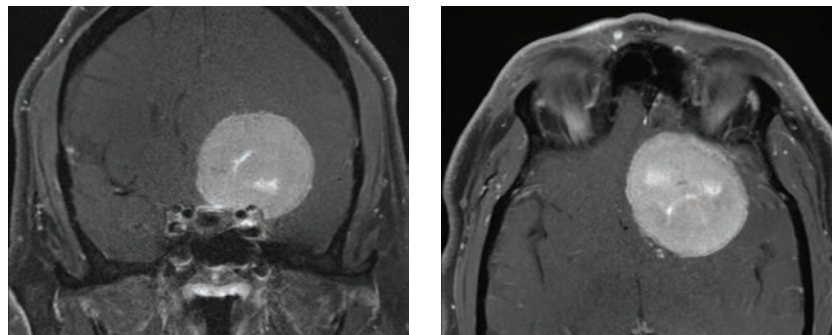


Fig. 2. At left, the coronal view of the MRI. At right, the axial view of the MRI.

the presence of both an intracranial mass and an ischemic event that results in the same clinical picture as Foster Kennedy syndrome.³ Apart from visual field testing and OCT a brain and orbital MRI must be performed to correctly differentiate between these syndromes and make an accurate diagnosis.

The MRI of the brain in our patient revealed a large left-sided meningioma of the anterior cranial fossa measuring 7x7x6mm with diffuse enhancement. There is an extension of this mass to the left optic canal as well as to the superior portions of the left cavernous sinus with no effect on the left extraocular muscles of the orbit. In contrast, the right optic nerve and the right optic canal appears to be intact with no mass effect. These findings confirmed our suspicion of Foster Kennedy syndrome.

Management

Treatment for patients with Foster Kennedy syndrome can be divided into medical and surgical management. Initial medical management for symptomatic brain tumors includes oral corticosteroids, which may help to reduce edema surrounding the tumor as well as decrease ICP.⁵ Radiotherapy or radiosurgery is also a non-surgical way to shrink the tumor and prevent further growth and expansion.^{1,5}

The most effective and primary course of treatment is surgical resection to reduce the mass effect and relieve the elevated ICP.⁵ In cases where tumors are not resectable or do not benefit from radiotherapy, hydroxyurea chemotherapy may be modestly beneficial.⁵ However, further studies are required to establish its clinical significance.⁵

The prognosis for these types of cases is variable, depending on factors such as the chronicity of the condition, the size of the tumor and the age of the patient. Nevertheless, early recognition of the signs and symptoms along with an accurate diagnosis of Foster Kennedy syndrome is critical to a patient's quality of life and final visual prognosis.

Our patient was immediately referred to a neurosurgeon and he had emergent surgery. He continues to be followed closely. ■

Dr. Jayasimha is an optometric resident at Bascom Palmer Eye Institute in Miami.

1. Lai A, Chiu S, Lin I, Sanders M. Foster Kennedy syndrome. *J Neuro-Ophthalmol.* 2014;34(1):92-4.
2. Sadun A. Foster-Kennedy syndrome. *Science Direct.* www.sciencedirect.com/topics/medicine-and-dentistry/foster-kennedy-syndrome. July 03, 2008. Accessed January 16, 2019.
3. Vickers L, Bhatti T, El-Dairi M. Diagnose and manage pseudo-Foster Kennedy syndrome. www.aao.org/eyenet/article/diagnose-manage-pseudofoster-kennedy-syndrome-2. January 2014. Accessed January 16, 2019.
4. Walia H, Grumbine F, Sawhney G, et al. An aggressive sphenoid wing meningioma causing Foster Kennedy syndrome. *Hindawi.* www.hindawi.com/journals/criopm/2012/102365. May 17, 2012. Accessed January 16, 2019.
5. Zhou Y, Vickers A, Ponce C, et al. Foster Kennedy vs pseudo-Foster Kennedy. eyewiki.aao.org/Foster-Kennedy_vs_Pseudo-Foster-Kennedy. January 14, 2018. Accessed January 16, 2019.

Earn up to
**28 CE
Credits***

NEW TECHNOLOGIES
& TREATMENTS IN
2019 EYE CARE
RGVCE
REVIEW'S REFRACTIVE SOCIETY

OCCRS
OPTOMETRIC CORNEA, CATARACT
AND REFRACTIVE SOCIETY

SAN DIEGO

APRIL 11-14, 2019

We invite you to attend a unique joint meeting held at the Manchester Grand Hyatt.

Review's New Technologies & Treatments in Eye Care and Optometric Cornea, Cataract and Refractive Society's annual meetings are combined to provide you with up to 28* COPE CE credits in one weekend.



Manchester Grand Hyatt
1 Market Place
San Diego, CA 92101
Phone: 619-232-1234

A limited number of rooms have been reserved at **\$269 per night**, plus tax. Please make reservations with the hotel directly at 1-888-421-1442. For group rate, mention "Review's New Technologies & Treatments in Eye Care".

The Premier Waterfront Downtown San Diego Hotel

Discover the vibrant culture and natural beauty of Southern California when you stay at Manchester Grand Hyatt San Diego. Conveniently located near downtown San Diego, Manchester Grand Hyatt offers a spectacular waterfront resort-like setting, complete with shopping, dining, and entertainment venues.

- *Relax and soak up the sun at one of 2 rooftop pools.*
- *Maintain your fitness routine at the 24-hour fitness center.*
- *Eight on-site dining options including the 40th floor "Top of the Hyatt"*

REGISTER ONLINE: WWW.REVIEWSCE.COM/SANDIEGO2019

Administered by
RGVCE
REVIEW'S REFRACTIVE SOCIETY

cope
*Approval pending

SALUS
UNIVERSITY
Pennsylvania College of Optometry

New Technologies & Treatments
conference is partially supported by an
unrestricted educational grant from

Bausch & Lomb

Program Chairs:

Paul M. Karpecki, OD, FAAO
Review Program Chair

David Friess, OD, FAAO
President, OCCRS

THREE WAYS TO REGISTER

Call: 866-658-1772 • E-mail: reviewmeetings@jhihealth.com

Online: www.reviewsce.com/sandiego2019

Convenient opportunities to register for one or both meetings.**

See event website for
early bird pricing!

New Technologies & Treatments in Eye Care Faculty



Program Chair:
Paul M. Karpecki, OD, FAAO



A. Paul Chous, MA, OD, FAAO, CDE



Doug Devries, OD



Robert Prouty, OD, FAAO



Optometric Cornea, Cataract and Refractive Society Faculty



Program Chair:
David Friess, OD, FAAO



Melissa Barnett, OD, FAAO, FSLs



Clark Chang, OD, FAAO



Douglas Devries, OD



Chris Freeman, OD, FAAO



David Geffen, OD, FAAO



Whitney Hauser, OD, FAAO



Mitch Ibach, OD, FAAO



Josh Johnston, OD, FAAO



Linda Morgan, OD, FAAO



Andrew Morgenstern, OD, FAAO



Jim Owen, OD, FAAO



Bobby Saenz, OD, MS



Justin Schweitzer, OD, FAAO



Valerie Seligson, OD, FAAO



Tracy Swartz, OD, MS, FAAO



William Tullo, OD, FAAO

EMAIL: REVIEWMEETINGS@JHIHEALTH.COM

CALL: 866-658-1772

Administered by
RGVCE
REVIEW GRANT COMMITTEE

COPE
*Approval pending

SALUS
UNIVERSITY
Pennsylvania College of Optometry

New Technologies & Treatments
conference is partially supported by an
unrestricted educational grant from

Bausch & Lomb

**Additional registration fees if attending both meetings. Agenda subject to change.

Merchandise Offered



Contact Lens Special Offer

Offer Code: HNY2019



\$59.49



\$39.49



\$51.49



\$29.49



NATIONAL LENS
 America's Leading Discount Optical Distributor
 1-866-923-5600 • 1-866-923-5601 FAX
 www.national-lens.com

Faculty



**ASSISTANT PROFESSOR POSITIONS:
 PEDIATRICS, PRIMARY CARE/OPTOMETRIC THEORY AND METHODS**

Full-time non-tenure track faculty positions for the Chicago College of Optometry

Responsibilities: Candidates are expected to be highly knowledgeable in the field of pediatric or primary care and optometric theory and methods and develop and teach courses and/or laboratories in the subject area. The primary care candidate must also be able to provide direct patient care and clinical instruction to professional students as well as residents, and be involved in interdisciplinary practice with other educational professionals.

Candidates must be willing to actively participate in curricular assessment, professional development, student counseling and service activities within the college, university, and the scientific community. Successful candidates are expected to be involved in research and scholarly activities, and have a sincere commitment to optometric education, community service, and patient care. Primary duties include but are not limited to:

- | | | |
|--|--|--|
| <p>a) Teaching</p> <ul style="list-style-type: none"> • Developing and delivering lectures • and/or laboratories for related areas, as assigned; • Embracing and enhancing the didactic philosophies in the O.D. program; • Maintaining and expanding the high quality clinical practice environment for optometry students on rotation; • Precepting students on clinical rotation at the Midwestern University Eye Institute where applicable; | <p>b) Service</p> <ul style="list-style-type: none"> • Helping to maintain and grow the state of the art optometry program with a strong interdisciplinary focus that meets the needs of patients in the surrounding community; is efficient, patient friendly, and cost-effective; • Working closely together with all optometry and ophthalmology faculty to provide a complete range of eye and vision care services; • Participating in leadership roles in state, regional, and national optometry organizations; | <ul style="list-style-type: none"> • Participating on College and University committees, as assigned; • Participating in College and University service activities. <p>c) Scholarly activity</p> <p>Engaging in research and scholarly activity, including presentations at scientific meetings, research, and publication in peer reviewed journals sufficient to qualify for academic advancement in a non-tenure or tenure track position.</p> |
|--|--|--|

Qualifications: Candidates must possess a Doctor of Optometry degree from an ACOE-accredited institution, must have completed an ACOE-accredited residency, and must be eligible for an Illinois optometric state license. Primary eye care clinical expertise is also required.

**Salary will be commensurate with qualifications and experience
 Review of applications will begin immediately and continue until the position is filled**

Contact information: Interested applicants should apply online at www.midwestern.edu and include curriculum vitae and letter of interest specifying the position and college that he/she wishes to be considered for. Application packet should include curriculum vitae and letter of interest. Inquiries may be directed to Dr. Melissa Suckow, Dean; Midwestern University: msucko@midwestern.edu.

Midwestern University is an Equal Opportunity/Affirmative Action employer that does not discriminate against an employee or applicant based upon race, color, religion, gender, national origin, disability, or veterans status, in accord with 41 C.F.R. 60-1.4(a), 250.5(a), 300.5(a) and 741.5(a).

Practice For Sale

ARE YOU IN CONTROL?

Don't buy a job...acquire a business.

Select clients have larger practices available for outright purchase. Positive cash flow and 100% financing available. America's leading optometry business development consultancy provides support before, during and after closure.

We'll help you acquire the optometry practice of your dreams with no cost to you. See our current offerings at:

<http://www.cleinman.com/buy>
800-331-5536



Equipment and Supplies

WHY PAY RETAIL???



Pretesting Tables of all shapes and sizes at Wholesale Prices.

Search the word PRETESTING at EBAY

Save hundreds even thousands on all your pretesting needs.

Or call: 316-734-4265

Do you have CE Programs?

CONTACT US TODAY
FOR CLASSIFIED ADVERTISING
Toll free: 888-498-1460
E-mail: sales@kerhgroup.com



Practice Sales • Appraisals • Consulting
www.PracticeConsultants.com

**PRACTICES FOR SALE
NATIONWIDE**

Visit us on the Web or call us to learn more about our company and the practices we have available.

info@PracticeConsultants.com

800-576-6935

www.PracticeConsultants.com

PRACTICE FOR SALE

NORTHEASTERN PA.

Long established busy and very successful optometric practice grossing over \$550k for sale. The practice involves all phases of optometry with an emphasis on contact lenses. The practice includes an optical dispensary and finishing lab. Numerous vision plans are accepted including Medicare.

Would be willing to work in the practice for a smooth transition.

This is a great opportunity for an optometrist looking to earn a great income immediately.

Contact 1727white@gmail.com for more details.

Career Opportunities

Staff Optometrist Wanted

Bard Optical is a family owned full-service retail optometric practice with 22 offices (and growing) throughout Central Illinois. Bard Optical prides itself on having a progressive optometric staff whose foundation is based on one-on-one patient service. We are currently accepting CV/resumes for Optometrists to join our medical model optometric practice that includes extended testing. The practice includes but is not limited to general optometry, contact lenses and geriatric care. Salaried, full-time positions are available with excellent base compensation and incentive programs and benefits. Some part-time opportunities may also be available.

Current positions are available in Bloomington/Normal, Decatur/Forsyth, Peoria, Sterling and Canton as we continue to grow with new and established offices.

Please email your information to mhall@bardoptical.com or call Mick at 309-693-9540 ext 225. Mailing address if more convenient is:

Bard Optical
Attn: Mick Hall, Vice President
8309 N Knoxville Avenue
Peoria, IL 61615

Bard Optical is a proud Associate Member of the Illinois Optometric Association.



www.bardoptical.com

30 year private optometry practice opportunity

in Fairbanks, Alaska.

See patients of all ages.

Excellent leased location on busy thoroughfare.

907-978-7481

or email.virginialind@yahoo.com



Targeting Optometrists?

CLASSIFIED ADVERTISING WORKS

- JOB OPENINGS
- CME PROGRAMS
- PRODUCTS & SERVICES
- AND MORE...

Contact us today for classified advertising:

Toll free: **888-498-1460**

E-mail: sales@kerhgroup.com



Continuing Education

Dr. Travel Seminars, LLC
 In Partnership With The NJ Society of Optometric Physicians
Dalmatian Coast Cruise
 Celebrity Constellation - Sailing from Venice to Rome
 June 28 - July 8, 2019 (10 Night Cruise)
 Sailing to Slovenia, Croatia, Montenegro, Malta, Sicily & Italy

*Optional Private
Group Tours*

All Programs Are in Partnership
With The New Jersey Society of
Optometric Physicians

*Optional Pre & Post Cruise
Copenhagen Hotel Stay*

Dr. TRAVEL SEMINARS, LLC
is a COPE approved provider
Course approved for 16 CE

Choose free: \$300 Onboard Credit, Drinks, or Internet

“A Contemporary look at Patient Eye Care”
 Presented by Randall Thomas, O.D., M.P.H., F.A.A.O.

Additional Seminar Cruises (12-16 CE):
Baltic Sea Cruise: July 22 - 31, 2019 - Leo Semes, OD, FAAO, Professor Emeritus, UAB
 Round Trip Copenhagen - Norwegian 'Getaway' - Special Free Amenities
Christmas Week: December 22-29, 2019 - Royal Caribbean's 'Allure of the Seas'
 Eastern Caribbean Sailing - Edward Paul, Jr., OD, PhD, FIAAJS
President's Week: February 15 - 22, 2020 - Royal Caribbean's 'Symphony of the Seas'
 Western Caribbean Sailing - Whitney Hauser OD, FAAO

www.DrTravel.com 800-436-1028

**American Academy of Optometry
 New Jersey Chapter**
17th Annual Educational Conference
April 3-7, 2019
Myrtle Beach, South Carolina
Hilton Embassy Suites at Kingston Plantation

Dr. Jerome Sherman, OD, FAAO
 Dr. James Fanelli, OD, FAAO

**16 HOURS
COPE CE**

Registration: \$500
 One, Two or Three Bedroom Suites
 Accommodations Include a Daily Breakfast Buffet
 and Evening Cocktail Reception
PACK YOUR CLUBS!
Golf details to follow.
 For Accommodation and Additional Information, contact:
Dennis H. Lyons, OD, F.A.A.O.
 Phone: (732) 920-0110
 E-Mail: dhl2020@aol.com

Place Your Ad Here!
 Toll free: **888-498-1460**
 E-mail: sales@kerhgroup.com

Professional Opportunities

DID YOU KNOW?
 Low Vision is a cash service
 Has Low Financial Risk
 Is Professionally Satisfying
 And Easy to Incorporate into Your Practice

The International Academy of Low Vision Specialists
has the following Territories Available:

Northern California	South Carolina	Connecticut	Maine
Southern Missouri	Massachusetts	Oklahoma	Iowa
Southern Georgia	West Virginia	San Diego	Ohio

*Members of
 The International Academy of Low Vision Specialists
 have an 18 year proven history of success
 throughout the USA and Canada.*

Learn how to profitably incorporate low vision care
 into your practice at:
www.OptometricPracticeConsultants.com
 or contact
 Richard J. Shuldiner, OD, FAAO
 President, IALVS and Low Vision Diplomate, AAO
 888 567 2020 / Doctor@LowVisionCare.com

Targeting Optometrists?

CLASSIFIED ADVERTISING WORKS

- JOB OPENINGS • CME PROGRAMS
- PRODUCTS & SERVICES • AND MORE...

Contact us today for classified advertising:
 Toll free: **888-498-1460**
 E-mail: sales@kerhgroup.com



Cutting Out Calcifications

Concretions don't often need excision, but here's what to expect when they do.

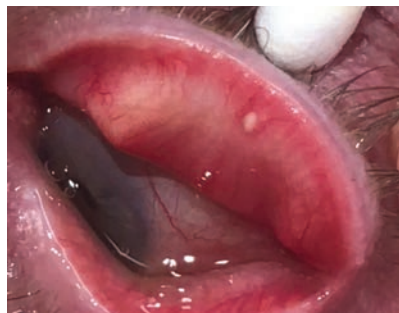By Kynndyl Giannonatti, BA, and Leonid Skorin, Jr., DO, OD, MS

Concretions—calcified deposits embedded within the palpebral conjunctiva—are often small and do not cause irritation. However, if they are large or prominent, they may rub against the bulbar conjunctiva or cornea, resulting in irritation, pain and foreign body sensation. For these, clinicians should consider surgical excision for immediate relief.

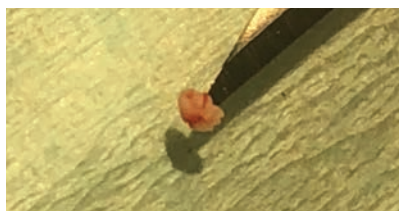Presentation

Concretions are often an incidental finding during anterior segment evaluation. They are more prevalent with age and in those with chronic inflammation. They appear as small yellow or white deposits that are usually less than 1mm. These deposits arise from epithelial cells, protein, mucin and other debris trapped in the fornix that calcifies over time.¹ Concretions are most commonly located in the inferior palpebral conjunctiva.^{1,2}

Patients with concretions are often asymptomatic and usually only require observation. But large or elevated concretions, especially in the upper lid, are more likely to rub the bulbar conjunctiva or cornea during the blinking process. These patients may complain of irritation and a foreign body sensation. In these cases, the concretions should be removed surgically for patient comfort.²



Palpebral view of concretion near the lid margin.



Concretion in curette after excision.

Excision: Step-By-Step

Removal is typically performed under local anesthesia using no sedation. The patient is placed in a supine position, and lidocaine hydrochloride 3.5% gel is placed into the superior cul-de-sac. The upper lid is everted and xylocaine 2% with 1 to 100,000 epinephrine is injected adjacent to the concretion. This is done for local anesthesia and vasoconstriction to reduce bleeding during the procedure. The eye is prepped with one drop of povidone iodine 5% ophthalmic solution, and the face is covered with a sterile fenestrated drape. Prior to surgery, the site is tested to ensure anesthesia has taken effect. Once this is confirmed, the surgeon makes a horizontal incision through the palpebral conjunctiva

above the concretion, then scrapes and removes the concretion with a curette. Next, pressure is applied over the incision with a sterile cotton applicator for hemostasis. After hemostasis is achieved, topical antibiotic ointment is applied for prophylaxis. Cauterization and suturing of the surgical site are not usually necessary. The incisions are small and will stop bleeding with applied pressure and heal by secondary intention (deliberately leaving the wound open, allowing the body to heal on its own).³

Post-op Considerations

This procedure is typically well tolerated, and patients will heal in a few days without complications. The eyelid may be tender with slight swelling. Patients are given topical antibiotic ointment with instructions to apply it to the surgical area two times per day for a week. A follow-up appointment is usually unnecessary, although patients should return if they notice discharge, pain, redness, swelling or other signs of infection. ■

Mrs. Giannonatti is a fourth-year student at Pacific University College of Optometry.

Dr. Skorin is a consultant in the Department of Surgery, Community Division of Ophthalmology in the Mayo Clinic Health System in Albert Lea, MN.



To see a video of this procedure, visit www.reviewofoptometry.com, or scan the QR code.

1. Bowling B. Kanski's Clinical Ophthalmology, A Systemic Approach, 8th ed. Philadelphia: Elsevier; 2016:131-66.
2. Mannis M, Holland E. Cornea, 4th ed. Philadelphia: Elsevier; 2017:856-74.
3. Skorin L, Genereux L. Secondary intention healing of graft donor site wound dehiscence following ectropion repair with autologous graft. Clin Surg Ophthalmol. 2014;32(4):101-2.



Headbanger's Flaw

By Andrew S. Gurwood, OD

History

A 33-year-old white female presented with a chief complaint of blurry vision in her left eye more so than in her right for three months.

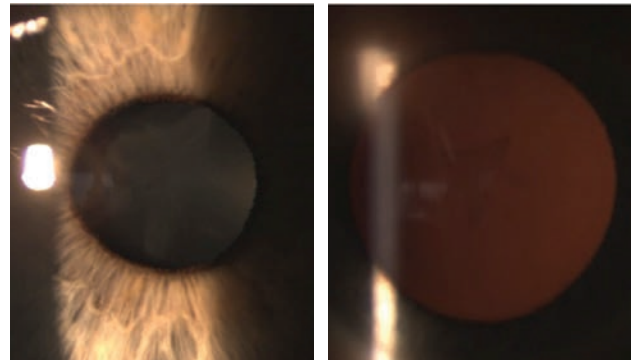
She reported that the persistent blur developed after an auto accident. She reported that, during the accident, she hit one side of her head on the back of the passenger seat, in a slow-moving vehicle while not wearing a seat belt.

Her previous ocular and systemic histories were unremarkable and she denied any known allergies to medications or other substances.

Diagnostic Data

Her best-corrected entering visual acuity was 20/20 OD and 20/30 OS at distance and near. Refraction revealed hyperopia of +0.75D OD and +1.50D OS with no improvement in vision. The pertinent biomicroscopic findings are illustrated in the photographs. Her intraocular pressures were measured at 15mm Hg OD and 18mm Hg OS using Goldmann applanation tonometry.

The patient's dilated fundus examination revealed no significant posterior pole or peripheral retina findings: the nerves were distinct with cup-to-disc ratios of 0.3/0.35 OD and OS.



This 33-year-old patient experienced blurred vision three months after an automobile accident in which she sustained head trauma. Can you identify the cause?

Your Diagnosis

Does the case presented require any additional tests, history or information? What steps would you take to manage this patient? Based on the information provided, what would be your diagnosis? What is the patient's most likely prognosis? To find out, please visit us online at www.reviewofoptometry.com. ■

Retina Quiz Answers (from page 90): 1) d; 2) a; 3) c; 4) c.

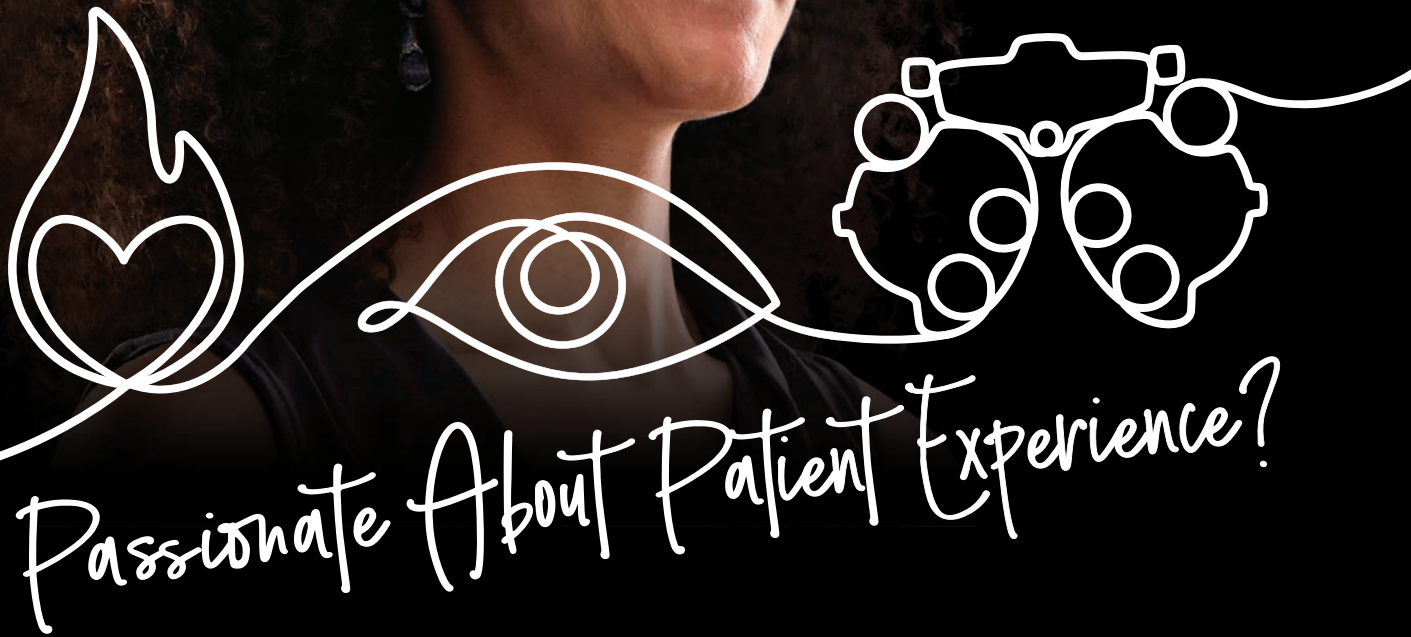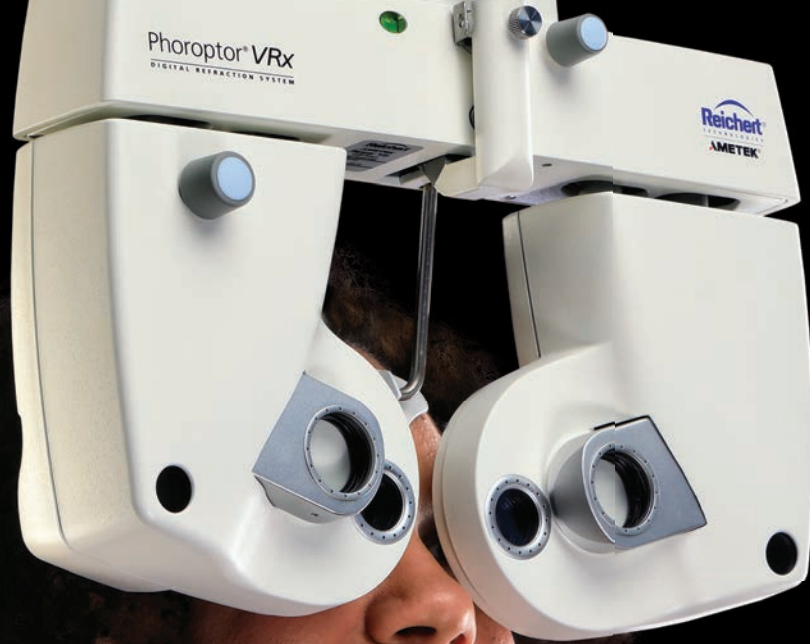Advertisers Index

Acuity Pro/VisionScience Software, Inc. 31
Phone (877) 228-4890 or (580) 243-1301
Fax (580) 243-1377
..... info@acuitypro.com
Alcon Laboratories 100
Phone (800) 451-3937
Fax (817) 551-4352
Bausch + Lomb 2-3, 25, 32-33
Phone (866) 246-8245
..... www.bausch.com
Bruder Ophthalmic Products 67
Phone (888) 827-8337
..... eyes@bruderophthalmic.com
Coburn Technologies 5
Phone (800) 262-8761
..... www.coburntechnologies.com
Contamac 9
..... www.contamac.com
Eyefinity 7
Phone (800) 269-3666
Focus Laboratories, Inc. 53
Phone (866) 752-6006

Fax (501) 753-6021 www.focuslaboratories.com
Icare USA 10	Phone (888) 389-4022
..... www.icare-usa.com	
IDOC 71	Phone (203) 853-3333
..... info@idoc.net optometry.idoc.net/learnmore
International Eye 15	Phone info@internationaleye.net
..... www.internationaleye.net	
Katena 41	Phone (800) 225-1195
..... www.katena.com	
Keeler Instruments 23	Phone (800) 523-5620
Fax (610) 353-7814	
Lacrimedics, Inc 19	Phone (800) 367-8327
Phone (253) 964-2699	Fax info@lacrimedics.com
..... www.lacrimedics.com	
Lacrivera 49	Phone (855) 857-0518
..... www.lacrivera.com	
Lombart Instruments 45	

Phone (800) 446-8092	Fax (757) 855-1232
Menicon 37	Phone (800) MENICON
..... information@menicon.com www.meniconamerica.com
Reichert Technologies 99	Phone (888) 849-8955
Fax (716) 686-4545 www.reichert.com
S4OPTIK 85, 87	Phone (888) 224-6012
Shire Ophthalmics 13 www.shire.com
Sight Sciences 17	Phone (877) 266-1144
..... info@sightssciences.com www.sightssciences.com
TelScreen 69	Phone www.TelScreen.com
..... DryEye@TelScreen.com	
Veatch 59, 61	Phone (800) 447-7511
Fax (602) 838-4934	
Vision Associates 21	Phone (800) 346-7486
..... www.visassoc.com	

This advertiser index is published as a convenience and not as part of the advertising contract. Every care will be taken to index correctly. No allowance will be made for errors due to spelling, incorrect page number or failure to insert.



Passionate About Patient Experience?

OF COURSE YOU ARE.







Exceed their expectations with our complete line of digital refraction devices. Set your practice apart with the most advanced Phoroptor® ever, **Phoroptor® VRx**, and our pixel-perfect **ClearChart® 4** family of digital acuity systems.



WATCH OUR NEW SERIES AT:
PASSIONATEABOUTEYECARE.COM

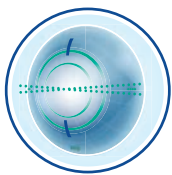
Reichert
TECHNOLOGIES
PASSIONATE ABOUT EYE CARE

AMETEK


© 2019 AMETEK, Inc. & Reichert, Inc. (02-2019) Phoroptor and ClearChart are registered trademarks of Reichert, Inc. · Phoroptor and ClearChart are designed & assembled in USA      

STABILITY, ANYWHERE, ANYTIME

DAILIES® AquaComfort Plus® Toric contact lenses are ahead of the curve with consistent, stable vision and refreshing comfort.



ON-EYE STABILITY
With $\leq 5^\circ$ oscillation per blink, the PRECISION CURVE™ lens design enables consistently stable lens wear.^{1*}



TEAR FILM STABILITY
Blink-activated moisture continuously refreshes the surface for excellent comfort and performance.^{2,3}



CONSISTENT COMFORT
Moisturizing agents are gradually released throughout the day for initial and all-day comfort.^{2,4}

**Prescribe DAILIES®
AquaComfort Plus® Toric
contact lenses for your
astigmatic patients.**

*Based on investigator assessment of lens rotation, at one week (n=181 lenses); using investigational lenses with -0.75, -1.50 cylinder powers (D).

References: 1. Alcon data on file, 2010. 2. Wolffsohn JS, Hunt OA, Chowdhury A. Objective clinical performance of 'comfort-enhanced' daily disposable soft contact lenses. *Contact Lens & Anterior Eye*. 2010;33(2):88-92. 3. Laboratory study release profile; Alcon data on file, 2007. 4. Winterton L, Lally J, Sentell K, Chapoy L. The elution of poly (vinyl alcohol) from a contact lens: The realization of a time release moisturizing agent/artificial tear. *J Biomed Mater Res B Appl Biomater*. 2007;80B:424-32.

See product instructions for complete wear, care, and safety information.

© 2017 Novartis 1/19 US-DAT-17-E-2219(2)

Alcon A Novartis
Division