



# REVIEW<sup>®</sup> of OPTOMETRY

APRIL 15, 2021 • www.reviewofoptometry.com

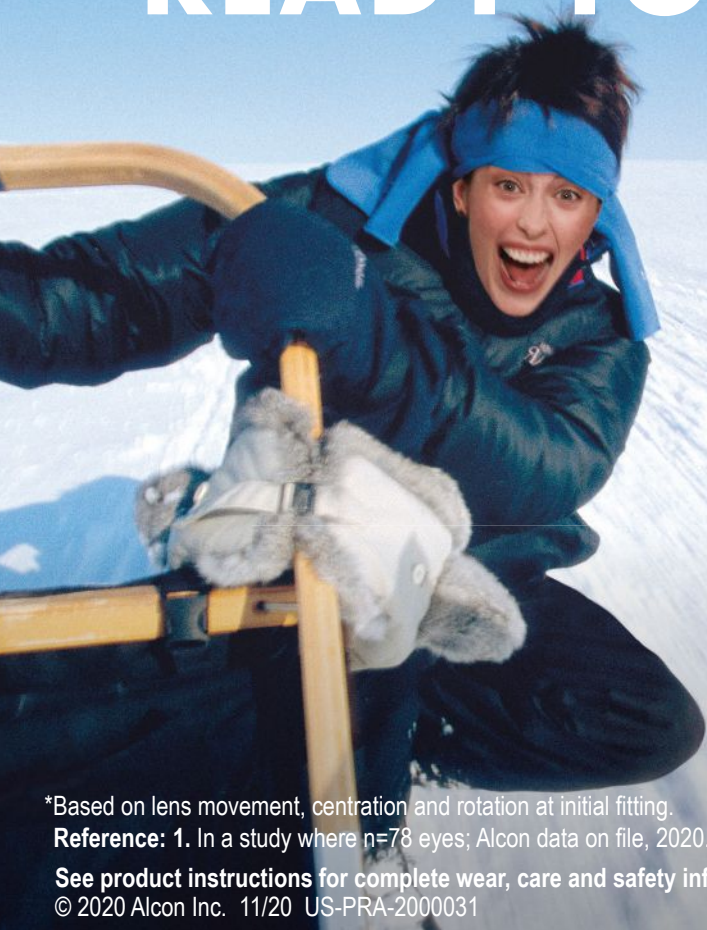Leadership in clinical care

KEEPING UP WITH KERATITIS

Page 62

CORNEOSCLERAL CONCERNS:  
TROUBLE AT THE BORDER

## PRECISION1<sup>®</sup> FOR ASTIGMATISM READY TO PRESCRIBE




Born from the Water  
Gradient Technology  
of DAILIES TOTAL1<sup>®</sup>

- Featuring the proven **PRECISION BALANCE 8|4<sup>®</sup>** lens design
- **99%** first-lens fit success rate<sup>1\*</sup>
- **Easy** to handle

**All at a mainstream price.**

Fit your patients in  
PRECISION1<sup>®</sup> for Astigmatism.

\*Based on lens movement, centration and rotation at initial fitting.  
Reference: 1. In a study where n=78 eyes; Alcon data on file, 2020.

See product instructions for complete wear, care and safety information. 

© 2020 Alcon Inc. 11/20 US-PRA-2000031

**Alcon**





Glaucoma Grand Rounds: Spot the Subtleties, *P. 98* | Focus on Refraction: Pointers on Yoked Prism, *P. 31*

# REVIEW<sup>®</sup> *of* OPTOMETRY

APRIL 15, 2021 • [www.reviewofoptometry.com](http://www.reviewofoptometry.com)

Leadership in clinical care

Annual  
Cornea  
Report



## KEEPING UP WITH KERATITIS

Page 62

## CORNEOSCLERAL CONCERNS: TROUBLE AT THE BORDER

Page 70

## SKIP THE SCALPEL? A MEDICAL APPROACH TO ENDO RECOVERY

Page 76

## THE MANY LAYERS OF CORNEA COMANAGEMENT

Page 80

## A NEW CONSENSUS ON KERATOCONUS

— EARN 2 CE CREDITS

Page 86

### PICTURED:

Honeycomb edema, a new clinical entity. See *p. 76*

### ALSO INSIDE:

Myopia Management: Translating Science into Practice, *P. 36*

Five Questions on Dry AMD Monitoring and Management, *P. 44*

A Glaucoma Starter Kit, Part 2: The Patient in Your Chair, *P. 52*



**VYZULTA**

(latanoprostene  
bunod ophthalmic  
solution), 0.024%

# THE HORSEPOWER YOU NEED TO LOWER IOP

**Powerful IOP reduction with excellent tolerability<sup>1,2</sup>**

VYZULTA delivered **up to 9.1 mmHg mean IOP reduction** from baseline in pivotal trials.<sup>1,2\*</sup>

**TAKE A TEST RIDE AT [VYZULTAHCP.COM](http://VYZULTAHCP.COM)**

\*Pivotal study designs: Two Phase 3, randomized, multicenter, parallel-group studies, APOLLO and LUNAR, evaluating noninferiority of once-daily VYZULTA vs twice-daily timolol maleate 0.5% in patients with open-angle glaucoma or ocular hypertension. Primary endpoint was IOP measured at 9 assessment time points in study eye. APOLLO (VYZULTA, n=284; timolol, n=133) and LUNAR (VYZULTA, n=278; timolol, n=136).<sup>2,3</sup>

## INDICATION

VYZULTA® (latanoprostene bunod ophthalmic solution), 0.024% is indicated for the reduction of intraocular pressure (IOP) in patients with open-angle glaucoma or ocular hypertension.

## IMPORTANT SAFETY INFORMATION

- Increased pigmentation of the iris and periorbital tissue (eyelid) can occur. Iris pigmentation is likely to be permanent
- Gradual changes to eyelashes, including increased length, increased thickness, and number of eyelashes, may occur. These changes are usually reversible upon treatment discontinuation
- Use with caution in patients with a history of intraocular inflammation (iritis/uveitis). VYZULTA should generally not be used in patients with active intraocular inflammation
- Macular edema, including cystoid macular edema, has been reported during treatment with prostaglandin analogs. Use with caution in aphakic patients, in pseudophakic patients with a torn posterior lens capsule, or in patients with known risk factors for macular edema
- There have been reports of bacterial keratitis associated with the use of multiple-dose containers of topical ophthalmic products that were inadvertently contaminated by patients
- Contact lenses should be removed prior to the administration of VYZULTA and may be reinserted 15 minutes after administration
- Most common ocular adverse reactions with incidence  $\geq 2\%$  are conjunctival hyperemia (6%), eye irritation (4%), eye pain (3%), and instillation site pain (2%)

For more information, please see Brief Summary of full Prescribing Information on adjacent page.

**References:** **1.** VYZULTA Prescribing Information. Bausch & Lomb Incorporated. **2.** Weinreb RN, Scassellati Sforzolini B, Vittitow J, Liebmann J. Latanoprostene bunod 0.024% versus timolol maleate 0.5% in subjects with open-angle glaucoma or ocular hypertension: the APOLLO study. *Ophthalmology*. 2016;123(5):965-973. **3.** Medeiros FA, Martin KR, Peace J, Scassellati Sforzolini B, Vittitow JL, Weinreb RN. Comparison of latanoprostene bunod 0.024% and timolol maleate 0.5% in open-angle glaucoma or ocular hypertension: the LUNAR study. *Am J Ophthalmol*. 2016;168:250-259.

VYZULTA and the V design are trademarks of Bausch & Lomb Incorporated or its affiliates. Any other product/brand names and/or logos are trademarks of the respective owners. ©2021 Bausch & Lomb Incorporated or its affiliates. All rights reserved. VYZ.0258.USA.20

**BAUSCH + LOMB**



## BRIEF SUMMARY OF PRESCRIBING INFORMATION

This Brief Summary does not include all the information needed to use VYZULTA safely and effectively. See full Prescribing Information for VYZULTA.

**VYZULTA®** (latanoprostene bunod ophthalmic solution), 0.024%, for topical ophthalmic use.

Initial U.S. Approval: 2017

### 1 INDICATIONS AND USAGE

VYZULTA® (latanoprostene bunod ophthalmic solution) 0.024% is indicated for the reduction of intraocular pressure (IOP) in patients with open-angle glaucoma or ocular hypertension.

### 4 CONTRAINDICATIONS

None

### 5 WARNINGS AND PRECAUTIONS

#### 5.1 Pigmentation

VYZULTA® (latanoprostene bunod ophthalmic solution), 0.024% may cause changes to pigmented tissues. The most frequently reported changes with prostaglandin analogs have been increased pigmentation of the iris and periorbital tissue (eyelid).

Pigmentation is expected to increase as long as latanoprostene bunod ophthalmic solution is administered. The pigmentation change is due to increased melanin content in the melanocytes rather than to an increase in the number of melanocytes. After discontinuation of VYZULTA, pigmentation of the iris is likely to be permanent, while pigmentation of the periorbital tissue and eyelash changes are likely to be reversible in most patients. Patients who receive prostaglandin analogs, including VYZULTA, should be informed of the possibility of increased pigmentation, including permanent changes. The long-term effects of increased pigmentation are not known.

Iris color change may not be noticeable for several months to years. Typically, the brown pigmentation around the pupil spreads concentrically towards the periphery of the iris and the entire iris or parts of the iris become more brownish. Neither nevi nor freckles of the iris appear to be affected by treatment. While treatment with VYZULTA® (latanoprostene bunod ophthalmic solution), 0.024% can be continued in patients who develop noticeably increased iris pigmentation, these patients should be examined regularly [see Patient Counseling Information (17) in full Prescribing Information].

#### 5.2 Eyelash Changes

VYZULTA may gradually change eyelashes and vellus hair in the treated eye. These changes include increased length, thickness, and the number of lashes or hairs. Eyelash changes are usually reversible upon discontinuation of treatment.

#### 5.3 Intraocular Inflammation

VYZULTA should be used with caution in patients with a history of intraocular inflammation (iritis/uveitis) and should generally not be used in patients with active intraocular inflammation as it may exacerbate this condition.

#### 5.4 Macular Edema

Macular edema, including cystoid macular edema, has been reported during treatment with prostaglandin analogs. VYZULTA should be used with caution in aphakic patients, in pseudophakic patients with a torn posterior lens capsule, or in patients with known risk factors for macular edema.

#### 5.5 Bacterial Keratitis

There have been reports of bacterial keratitis associated with the use of multiple-dose containers of topical ophthalmic products. These containers had been inadvertently contaminated by patients who, in most cases, had a concurrent corneal disease or a disruption of the ocular epithelial surface.

#### 5.6 Use with Contact Lens

Contact lenses should be removed prior to the administration of VYZULTA because this product contains benzalkonium chloride. Lenses may be reinserted 15 minutes after administration.

### 6 ADVERSE REACTIONS

The following adverse reactions are described in the Warnings and Precautions section: pigmentation (5.1), eyelash changes (5.2), intraocular inflammation (5.3), macular edema (5.4), bacterial keratitis (5.5), use with contact lens (5.6).

#### 6.1 Clinical Trials Experience

Because clinical trials are conducted under widely varying conditions, adverse reaction rates observed in the clinical trials of a drug cannot be directly compared to rates in the clinical trials of another drug and may not reflect the rates observed in practice.

VYZULTA was evaluated in 811 patients in 2 controlled clinical trials of up to 12 months duration. The most common ocular adverse reactions observed in patients treated with latanoprostene bunod were: conjunctival hyperemia (6%), eye irritation (4%), eye pain (3%), and instillation site pain (2%). Approximately 0.6% of patients discontinued therapy due to ocular adverse reactions including ocular hyperemia, conjunctival irritation, eye irritation, eye pain, conjunctival edema, vision blurred, punctate keratitis and foreign body sensation.

### 8 USE IN SPECIFIC POPULATIONS

#### 8.1 Pregnancy

##### Risk Summary

There are no available human data for the use of VYZULTA during pregnancy to inform any drug associated risks.

Latanoprostene bunod has caused miscarriages, abortion, and fetal harm in rabbits. Latanoprostene bunod was shown to be abortifacient and teratogenic when administered intravenously (IV) to pregnant rabbits at exposures  $\geq$  0.28 times the clinical dose. Doses  $\geq$  20  $\mu$ g/kg/day (23 times the clinical dose) produced 100% embryofetal lethality. Structural abnormalities observed in rabbit fetuses included anomalies of the great vessels and aortic arch vessels, domed head, sternebral and vertebral skeletal anomalies, limb hyperextension

and malrotation, abdominal distension and edema. Latanoprostene bunod was not teratogenic in the rat when administered IV at 150 mcg/kg/day (87 times the clinical dose) [see Data].

The background risk of major birth defects and miscarriage for the indicated population is unknown. However, the background risk in the U.S. general population of major birth defects is 2 to 4%, and of miscarriage is 15 to 20%, of clinically recognized pregnancies.

##### Data

##### Animal Data

Embryofetal studies were conducted in pregnant rabbits administered latanoprostene bunod daily by intravenous injection on gestation days 7 through 19, to target the period of organogenesis. The doses administered ranged from 0.24 to 80 mcg/kg/day. Abortion occurred at doses  $\geq$  0.24 mcg/kg/day latanoprostene bunod (0.28 times the clinical dose, on a body surface area basis, assuming 100% absorption). Embryofetal lethality (resorption) was increased in latanoprostene bunod treatment groups, as evidenced by increases in early resorptions at doses  $\geq$  0.24 mcg/kg/day and late resorptions at doses  $\geq$  6 mcg/kg/day (approximately 7 times the clinical dose). No fetuses survived in any rabbit pregnancy at doses of 20 mcg/kg/day (23 times the clinical dose) or greater. Latanoprostene bunod produced structural abnormalities at doses  $\geq$  0.24 mcg/kg/day (0.28 times the clinical dose). Malformations included anomalies of sternum, coarctation of the aorta with pulmonary trunk dilation, retrosophageal subclavian artery with absent brachiocephalic artery, domed head, forepaw hyperextension and hindlimb malrotation, abdominal distension/edema, and missing/fused caudal vertebrae.

An embryofetal study was conducted in pregnant rats administered latanoprostene bunod daily by intravenous injection on gestation days 7 through 17, to target the period of organogenesis. The doses administered ranged from 150 to 1500 mcg/kg/day. Maternal toxicity was produced at 1500 mcg/kg/day (870 times the clinical dose, on a body surface area basis, assuming 100% absorption), as evidenced by reduced maternal weight gain. Embryofetal lethality (resorption and fetal death) and structural anomalies were produced at doses  $\geq$  300 mcg/kg/day (174 times the clinical dose). Malformations included anomalies of the sternum, domed head, forepaw hyperextension and hindlimb malrotation, vertebral anomalies and delayed ossification of distal limb bones. A no observed adverse effect level (NOAEL) was established at 150 mcg/kg/day (87 times the clinical dose) in this study.

#### 8.2 Lactation

##### Risk Summary

There are no data on the presence of VYZULTA in human milk, the effects on the breastfed infant, or the effects on milk production. The developmental and health benefits of breastfeeding should be considered, along with the mother's clinical need for VYZULTA, and any potential adverse effects on the breastfed infant from VYZULTA.

#### 8.4 Pediatric Use

Use in pediatric patients aged 16 years and younger is not recommended because of potential safety concerns related to increased pigmentation following long-term chronic use.

#### 8.5 Geriatric Use

No overall clinical differences in safety or effectiveness have been observed between elderly and other adult patients.

### 13 NONCLINICAL TOXICOLOGY

#### 13.1 Carcinogenesis, Mutagenesis, Impairment of Fertility

Latanoprostene bunod was not mutagenic in bacteria and did not induce micronuclei formation in the *in vivo* rat bone marrow micronucleus assay. Chromosomal aberrations were observed *in vitro* with human lymphocytes in the absence of metabolic activation.

Latanoprostene bunod has not been tested for carcinogenic activity in long-term animal studies. Latanoprost acid is a main metabolite of latanoprostene bunod. Exposure of rats and mice to latanoprost acid, resulting from oral dosing with latanoprost in lifetime rodent bioassays, was not carcinogenic.

Fertility studies have not been conducted with latanoprostene bunod. The potential to impact fertility can be partially characterized by exposure to latanoprost acid, a common metabolite of both latanoprostene bunod and latanoprost. Latanoprost acid has not been found to have any effect on male or female fertility in animal studies.

#### 13.2 Animal Toxicology and/or Pharmacology

A 9-month toxicology study administered topical ocular doses of latanoprostene bunod to one eye of cynomolgus monkeys: control (vehicle only), one drop of 0.024% bid, one drop of 0.04% bid and two drops of 0.04% per dose, bid. The systemic exposures are equivalent to 4.2-fold, 7.9-fold, and 13.5-fold the clinical dose, respectively, on a body surface area basis (assuming 100% absorption). Microscopic evaluation of the lungs after 9 months observed pleural/subpleural chronic fibrosis/inflammation in the 0.04% dose male groups, with increasing incidence and severity compared to controls. Lung toxicity was not observed at the 0.024% dose.

U.S. Patent Numbers: 7,273,946; 7,629,345; 7,910,767; 8,058,467.

VYZULTA is a trademark of Bausch & Lomb Incorporated or its affiliates.

© 2020 Bausch & Lomb Incorporated or its affiliates.

##### Distributed by:

Bausch + Lomb, a division of

Bausch Health US, LLC

Bridgewater, NJ 08807 USA

Based on 9612403 (Folded), 9612303 (Flat) 5/2019

VYZ.0109.USA.20 Issued: 5/2020

# NEWS REVIEW

Clinical, legislative and practice development updates for ODs.



Get the latest at  
[www.reviewofoptometry.com/news](http://www.reviewofoptometry.com/news)  
Stories post every weekday

TELEMEDICINE BARRIERS IN GLAUCOMA, P.6 >> MYOPIA DURING LOCKDOWN P.10 >> AOA CHANGES MEETING LOCATION P.10 >> PSYCH EFFECTS OF DELAY BETWEEN CATARACT SURGERIES, P.12 >> ACNE AND MGD LINKED, P.12

## Missed Neuro Diagnoses Lead to Patient Harm

*About a quarter of mistaken cases experienced some kind of adverse impact on health.*

Neuro-ophthalmologists commonly encounter high rates of diagnostic error in the cases referred to them, which could lead to unnecessary or even inappropriate tests and treatments. To assess the impact, researchers decided to evaluate the extent to which patients were misdiagnosed prior to the neuro-ophthalmology referral and whether they suffered harm as a result. The findings offer a sobering look at the gap between generalist and specialist care in neuro-ophthalmic cases.

In this prospective cross-sectional study, researchers collected data from 496 patients regarding demographics, prior care, referral diagnosis, final diagnosis, diagnostic testing, treatment, patient disposition and impact of the neuro encounter.

Referral diagnosis was incorrect in almost half the cases—49%, which is

consistent with prior studies' results. Furthermore, 26% of misdiagnosed patients suffered harm, which could have been prevented by earlier referral to neuro-ophthalmologists. Patients experienced inappropriate laboratory testing, diagnostic imaging or treatment prior to referral in 23% of cases, with higher rates for patients misdiagnosed prior to referral (34% of patients vs. 13% with a correct referral diagnosis.)

Seventy-six percent of inappropriate referrals were misdiagnosed,

compared to 45% of appropriate referrals. The most common reasons for referral were optic neuritis or optic neuropathy, papilledema, diplopia or cranial nerve palsies and unspecified vision loss.

The most common sources of diagnostic error involved the physical exam, history taking, use or interpretation of diagnostic testing, and the generation and consideration of the differential diagnosis.

“These results emphasize the value of subspecialty-trained neuro-ophthalmologists in diagnosing and managing these potentially devastating conditions,” the authors noted in their study, published in *Ophthalmology*. “In almost all cases, these harms could potentially have been avoided with earlier access to neuro-ophthalmic consultation.”

But there's one silver lining to the study: optometrists were no worse than general ophthalmologists at neuro assessment. The study notes that there was “no meaningful difference between rates of misdiagnosis or rates of harm” between the two professions. ◀

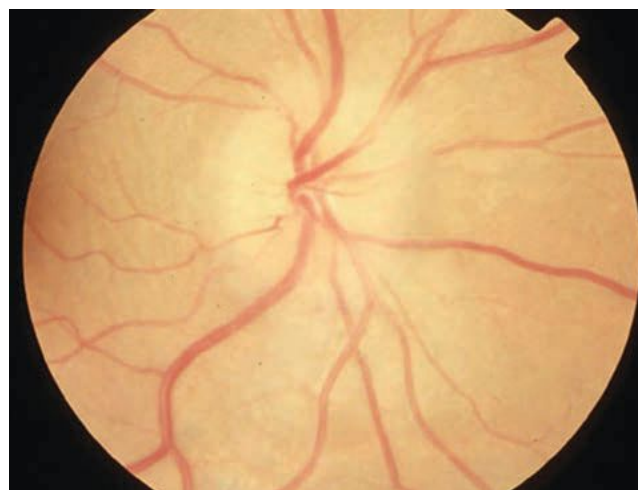

Photo: Joseph W. Sowka, OD, and Alan G. Kahan, OD

**The most common reasons for referral were optic neuritis or optic neuropathy, papilledema, diplopia or cranial nerve palsies and unspecified vision loss.**

Stunkel L, Sharma RA, Mackay DD, et al. Patient harm due to diagnostic error of neuro-ophthalmologic conditions. *Ophthalmology*. March 10, 2021. [Epub ahead of print].

### IN BRIEF

**Tear film breakup patterns in patients with thyroid eye disease appear to be different than those found in individuals with dry eye alone**, new research published in *Scientific Reports* suggests. The

incidence of each breakup pattern was similar in patients with simple dry eye without thyroid eye disease. On the other hand, among those with the condition, line breaks were the most frequently observed pattern (52%), followed by random patterns (23%), spots

(19%) and dimple breaks (7%).

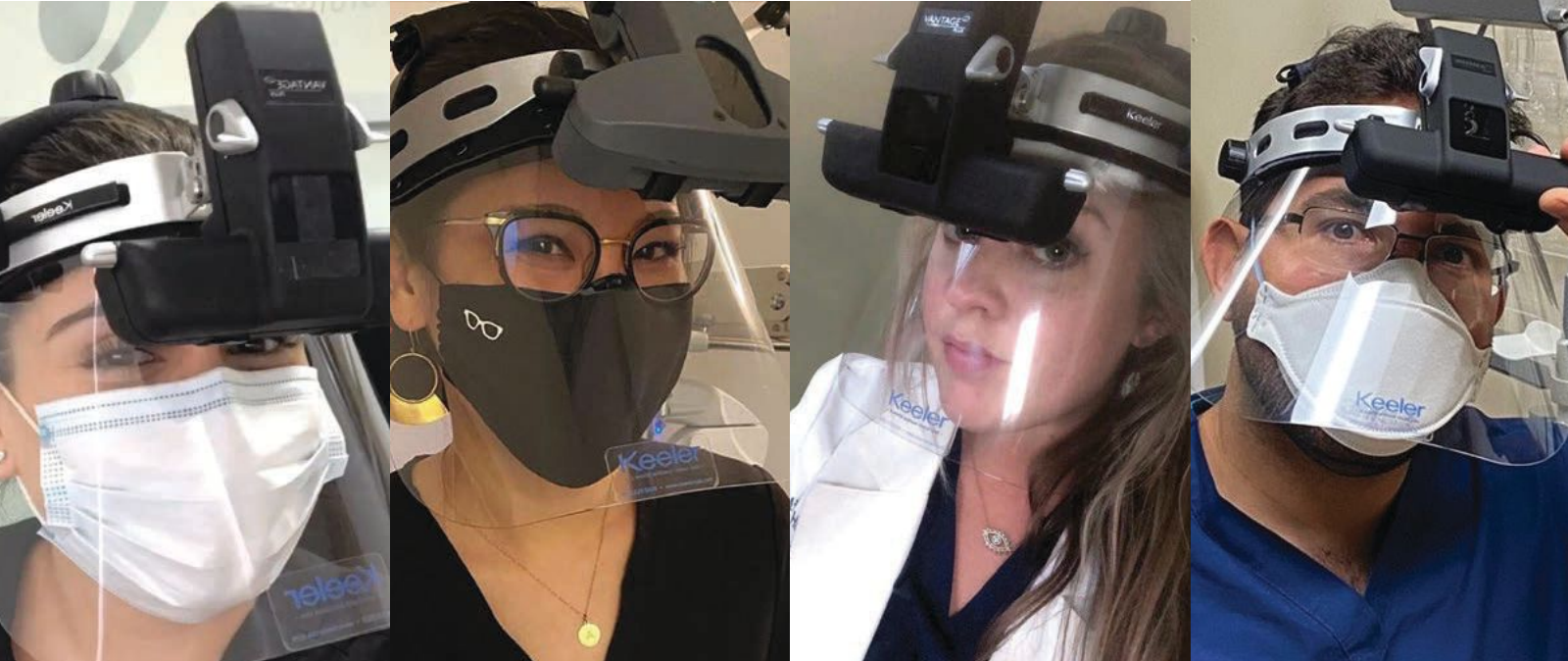These findings indicate that **thyroid eye disease frequently induces aqueous-deficient dry eye, probably due to lacrimal gland involvement**. But, it was found to be relatively mild. However, the

severity of thyroid eye disease was not associated with tear film breakup pattern.

Takahashi Y, Lee PAL, Vaidya A, et al. Tear film break-up patterns in thyroid eye disease. *Scientific Reports*. March 5, 2021. [Epub ahead of print].



# Helping Heroes See Clear And Stay Safe



The Vantage BIO is great for ROP screening! It's lightweight, has settings for different pupil sizes, a cool, white LED light and the longest battery ever!!"

**Dra. Paulina Ramirez Neria**



I'm a big fan of the All Pupil BIO. I had issues with other models so when I started [my practice], I knew the All Pupil would be my go-to BIO...I greatly appreciate the new custom fit Keeler BIO shields as an added safety layer."

**Dr. Annie Bacon**



I chose my [Vantage Plus] for the optics and value...with other brands, I had difficulty focusing up close during my dilated fundus exams. [The oculars] made my eyes feel more relaxed, and I felt like my view was better."

**Dr. Michelle Hammond**



[I've] been seeing emergent and urgent cases every day during the COVID19 pandemic. I really like [the Vantage BIO] because [it's a] very good quality and provides a super clear view."

**Dr. Reza Moradi**

Choose one of the programs below when you purchase a BIO\*  
**(Expires June 30, 2021)**

\*this program is valid for our wireless indirects: All Pupil II and Vantage Plus

1

RECEIVE A

**\$850**

credit towards any PPE



2

24-MONTH

**0%**

lease as low as \$128/month\*

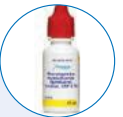\*All Pupil II: \$127.92/month; Vantage Plus: \$155/month (shipping and taxes not included).

3

RECEIVE

**10 FREE**

bottles of phenylephrine  
2.5%, 15mL



**\*Leasing may also be combined with the PPE credit OR the phenylephrine option.**

Contact us at 800-523-5620 or [customerservice@keelerusa.com](mailto:customerservice@keelerusa.com) to learn more or place your order. This promo cannot be combined with any other Keeler offers.

**Keeler**  
— A world without vision loss —

www.keelerusa.com • 3222 Phoenixville Pike - Bldg. #50 • Malvern, PA 19355  
Tel No: 1-610-353-4350 • Toll Free: 1-800-523-5620 • Fax: 1-610-353-7814

  
A Halma company

# CDC Aims to Break Down Telemed Barriers in Glaucoma

Telemedicine was emerging in optometry long before COVID, but the spring 2020 lockdown prompted even some virtual-visit naysayers to rethink their position in order to ensure continuity of care.

One year later, practices are back open for business, prompting the question of whether telemedicine will retain as strong a role in optometry going forward, especially concerning ocular diseases such as glaucoma that often require in-person attention.

Still, others have already been sold on the advantages of virtual formats and are launching long-term telemedicine initiatives.

## Academia Test-drives Telemed Glaucoma Screenings

In an effort to better engage at-risk and vulnerable populations and those least likely to have access to eye care, the CDC recently provided funding to Columbia University, the University of Michigan and the University of Alabama at Birmingham for five-year pilot investigations, collectively known as the Screening and Interventions for Glaucoma and Eye Health Through Telemedicine (SIGHT) studies.

The investigators are assessing the usefulness of community health workers in conducting on-site vision screenings, “patient navigators and glaucoma coaches” and telehealth to ensure follow-up eye care for those diagnosed with glaucoma and other eye diseases.

MI-SIGHT, the University of Michigan’s phase of the study, seeks to identify whether telemed eye health screening programs in local community clinics that serve higher risk glaucoma populations can detect the condition at a higher rate than the 2% found in the general population, explains researcher Paula Anne Newman-Casey, MD, MS, education director at the Kellogg Eye Center for eHealth and assistant

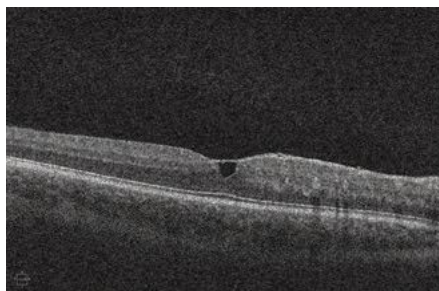


Photo: David Schaeffer, OD, and Mark T. Dunbar, OD

**Many ODs wonder how one could administer an OCT scan online.**

professor and interim associate chair for research in the Department of Ophthalmology and Visual Sciences at the University of Michigan.

Through MI-SIGHT, ophthalmic techs will conduct vision screenings at two community clinics—the Hope Clinic, a free facility in Ypsilanti, and the Hamilton Community Health Network, a federally qualified health center in Flint. Each testing room is equipped with a vision chart, autorefractor, phoropter, trial lens set, Finhoff transilluminator, pachymeter, iCare tonometer and fundus/SD-OCT camera.

Once the tech has completed the eye health history and taken all of the requisite measurements, the data is securely sent to a university-based ophthalmologist for review. Ophthalmologists will then send their recommendations back to the tech, who will educate patients about their diagnoses and dispense and fit glasses as needed.

If a participant screens positive for glaucoma or suspected glaucoma, they will be randomized to either receive standard education or personalized glaucoma coaching to determine which approach helps more patients return for their recommended follow-up.

Fifty percent of people with glaucoma do not know they have the condition and are currently undiagnosed, Dr. Newman-Casey says. Adding to that sobering statistic, the need for glaucoma screening in underserved and

at-risk populations, including those of African American descent and lower incomes, is great, she adds.

“The public health need to detect and treat glaucoma more effectively among people of African ancestry is critical in mitigating needless vision loss from glaucoma. In the MI-SIGHT program, we are testing whether using a telemedicine approach to embed glaucoma screening programs in trusted community clinics can help bridge this critical gap,” she says.

The MI-SIGHT study has great replication potential in other community clinics, Dr. Newman-Casey believes.

The purpose of using telemedicine is to provide eye health and glaucoma screening in trusted community clinics, since trust is one important barrier to engaging underserved populations in glaucoma screening, she says.

## Private Practice Poses Glaucoma Screening Challenges

“I think telemedicine can play a part in glaucoma screening and management, which was particularly evident during the early days of the COVID-19 pandemic,” says Ian Gaddie, OD. However, he predicts that post-pandemic, telemedicine for glaucoma management will decrease as in-person visits return to normal.

“There are limits today governing the feasibility of telemedicine in glaucoma,” he explains. “How do you take a threshold field and have comparative data? How do you administer an OCT online? Equally important, how do you measure IOP by telemedicine?”

“Telemed could be a viable approach for glaucoma screening if a trained technician performs the appropriate testing from a remote location and the images are then sent to an eye care practitioner for a diagnosis,” says James Fanelli, OD.

*(Continued on page 9)*



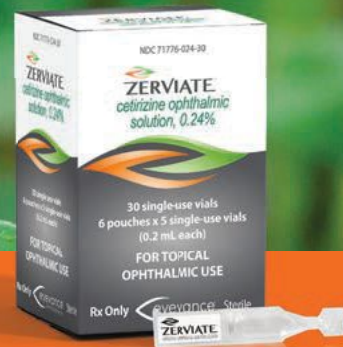# NO PAZEO\*? NO PROBLEM!

For ocular itch associated  
with allergic conjunctivitis

# INITIATE ZERVIAE®

Choose the topical prescription  
treatment that delivers the  
proven power of cetirizine  
(active ingredient in ZYRTEC®)<sup>1</sup>

- Provides fast-acting, long-lasting relief that lubricates with every drop<sup>2,3</sup>
- Covered on most commercial and Medicare Part D plans



Available by  
prescription only

Formulated with HYDRELLA™ for comfort.<sup>1</sup>  
Visit [MyZERVIAE.com](http://MyZERVIAE.com) for more information.

References: 1. ZERVIAE [package insert]. Fort Worth, TX: Eyeavance Pharmaceuticals LLC; 2018. 2. Malhotra RP, Meier E, Torkildsen G, et al. Safety of cetirizine ophthalmic solution 0.24% for the treatment of allergic conjunctivitis in adult and pediatric subjects. *Clin Ophthalmol.* 2019;13:403-413. 3. Meier EJ, Torkildsen GL, Gomes PJ, et al. Phase III trials examining the efficacy of cetirizine ophthalmic solution 0.24% compared to vehicle for the treatment of allergic conjunctivitis in the conjunctival allergen challenge model. *Clin Ophthalmol.* 2018;12:2617-2628.

## INDICATIONS AND USAGE

ZERVIAE® (cetirizine ophthalmic solution) 0.24% is a histamine-1 (H1) receptor antagonist indicated for treatment of ocular itching associated with allergic conjunctivitis.

## IMPORTANT SAFETY INFORMATION

### ADVERSE REACTIONS

The most commonly reported adverse reactions occurred in approximately 1%-7% of patients treated with either ZERVIAE or vehicle. These reactions were ocular hyperemia, instillation site pain, and visual acuity reduced.

Please see brief summary of Full Prescribing Information on the adjacent page.



© 2021 Eyeavance Pharmaceuticals LLC. All rights reserved.  
ZERVIAE® is a registered trademark and HYDRELLA™ is a trademark of Eyeavance Pharmaceuticals LLC.  
\*All other trademarks are the property of their respective owners. ZER-21-AD-106-02

## ZERVIAE™ (cetirizine ophthalmic solution) 0.24%

### Brief Summary

#### INDICATIONS AND USAGE

ZERVIAE (cetirizine ophthalmic solution) 0.24% is a histamine-1 (H1) receptor antagonist indicated for treatment of ocular itching associated with allergic conjunctivitis.

#### DOSAGE AND ADMINISTRATION

**Recommended Dosing:** Instill one drop of ZERVIAE in each affected eye twice daily (approximately 8 hours apart). The single-use containers are to be used immediately after opening and can be used to dose both eyes. Discard the single-use container and any remaining contents after administration. The single-use containers should be stored in the original foil pouch until ready to use.

#### CONTRAINDICATIONS

None.

#### WARNINGS AND PRECAUTIONS

**Contamination of Tip and Solution:** As with any eye drop, care should be taken not to touch the eyelids or surrounding areas with the dropper tip of the bottle or tip of the single-use container to avoid injury to the eye and to prevent contaminating the tip and solution. Keep the multi-dose bottle closed when not in use. Discard the single-use container after using in each eye.

**Contact Lens Wear:** Patients should be advised not to wear a contact lens if their eye is red.

ZERVIAE should not be instilled while wearing contact lenses. Remove contact lenses prior to instillation of ZERVIAE. The preservative in ZERVIAE, benzalkonium chloride, may be absorbed by soft contact lenses. Lenses may be reinserted 10 minutes following administration of ZERVIAE.

#### ADVERSE REACTIONS

**Clinical Trials Experience:** Because clinical trials are conducted under widely varying conditions, adverse reaction rates observed in the clinical trial of a drug cannot be directly compared to rates in the clinical trials of another drug and may not reflect the rates observed in practice.

In 7 clinical trials, patients with allergic conjunctivitis or those at risk of developing allergic conjunctivitis received one drop of either cetirizine (N=511) or vehicle (N=329) in one or both eyes. The most commonly reported adverse reactions occurred in approximately 1%–7% of patients treated with either ZERVIAE or vehicle. These reactions were ocular hyperemia, instillation site pain, and visual acuity reduced.

#### USE IN SPECIFIC POPULATIONS

##### Pregnancy

###### *Risk Summary*

There were no adequate or well-controlled studies with ZERVIAE in pregnant women. Cetirizine should be used in pregnancy only if the potential benefit justifies the potential risk to the fetus.

###### *Data*

##### Animal Data

Cetirizine was not teratogenic in mice, rats, or rabbits at oral doses up to 96, 225, and 135 mg/kg, respectively (approximately 1300, 4930, and 7400 times the maximum recommended human ophthalmic dose (MRHOD), on a mg/m<sup>2</sup> basis).

##### Lactation

###### *Risk Summary*

Cetirizine has been reported to be excreted in human breast milk following oral administration. Multiple doses of oral dose cetirizine (10 mg tablets once daily for 10 days) resulted in systemic levels (Mean C<sub>max</sub> = 311 ng/mL) that were 100 times higher than the observed human exposure (Mean C<sub>max</sub> = 3.1 ng/mL) following twice daily administration of cetirizine ophthalmic solution 0.24% to both eyes for 1 week. Comparable bioavailability has been found between the tablet and syrup dosage forms. However, it is not known whether the systemic absorption resulting from topical ocular administration of ZERVIAE could produce detectable quantities in human breast milk.

There is no adequate information regarding the effects of cetirizine on breastfed infants, or the effects on milk production to inform risk of ZERVIAE to an infant during lactation. The developmental and health benefits of breastfeeding should be considered along with the mother's clinical need for ZERVIAE and any potential adverse effects on the breastfed child from ZERVIAE.

**Pediatric Use:** The safety and effectiveness of ZERVIAE has been established in pediatric patients two years of age and older. Use of ZERVIAE in these pediatric patients is supported by evidence from adequate and well-controlled studies of ZERVIAE in pediatric and adult patients.

**Geriatric Use:** No overall differences in safety or effectiveness have been observed between elderly and younger patients.

#### NONCLINICAL TOXICOLOGY

##### **Carcinogenesis, Mutagenesis, Impairment of Fertility**

###### *Carcinogenicity*

In a 2-year carcinogenicity study in rats, orally administered cetirizine was not carcinogenic at dietary doses up to 20 mg/kg (approximately 550 times the MRHOD, on a mg/m<sup>2</sup> basis). In a 2-year carcinogenicity study in mice, cetirizine caused an increased incidence of benign liver tumors in males at a dietary dose of 16 mg/kg (approximately 220 times the MRHOD, on a mg/m<sup>2</sup> basis). No increase in the incidence of liver tumors was observed in mice at a dietary dose of 4 mg/kg (approximately 55 times the MRHOD, on a mg/m<sup>2</sup> basis). The clinical significance of these findings during long-term use of cetirizine is not known.

###### *Mutagenesis*

Cetirizine was not mutagenic in the Ames test or in an *in vivo* micronucleus test in rats. Cetirizine was not clastogenic in the human lymphocyte assay or the mouse lymphoma assay.

###### *Impairment of Fertility*

In a fertility and general reproductive performance study in mice, cetirizine did not impair fertility at an oral dose of 64 mg/kg (approximately 875 times the MRHOD, on a mg/m<sup>2</sup> basis).

#### PATIENT COUNSELING INFORMATION

**Risk of Contamination:** Advise patients not to touch dropper tip to eyelids or surrounding areas, as this may contaminate the dropper tip and ophthalmic solution. Advise patients to keep the bottle closed when not in use. Advise patients to discard single-use containers after each use.

**Concomitant Use of Contact Lenses:** Advise patients not to wear contact lenses if their eyes are red. Advise patients that ZERVIAE should not be used to treat contact lens-related irritation. Advise patients to remove contact lenses prior to instillation of ZERVIAE. The preservative in ZERVIAE solution, benzalkonium chloride, may be absorbed by soft contact lenses. Lenses may be reinserted 10 minutes following administration of ZERVIAE.

**Administration:** Advise patients that the solution from one single-use container is to be used immediately after opening. Advise patients that the single-use container can be used to dose both eyes. Discard the single-use container and remaining contents immediately after administration.

##### **Storage of Single-use Containers:**

Instruct patients to store single-use containers in the original foil pouch until ready to use.

#### Rx Only

**Distributed by:** Eyevance Pharmaceuticals LLC, Fort Worth, TX 76102



© 2020 Eyevance Pharmaceuticals LLC. All rights reserved.  
ZERVIAE™ is a trademark of Eyevance Pharmaceuticals LLC.  
ZER-04-20-MS-44



# ODs Discuss Telemedicine's Role in Eye Care

(Continued from page 6)

"Glaucoma is amenable to telemedicine as far as screening is concerned, but it's a bit different with management because there are instances where you need to see the eye *in vivo*," he says.

On the other hand, out of the plethora of conditions seen in a primary care clinic, glaucoma is one of the more amenable diseases for telemedicine management, although not exclusively, Dr. Fanelli adds. "A patient can't be solely managed by telemedicine. Glaucoma screening lends itself to telemedicine because of the imaging capabilities we have. That would be a very different answer, for example, if we were talking about corneal ulcers."

A patient sitting at home can't be managed long-term for glaucoma, nor is there any screening capability from a home use perspective, he notes.

Unless the practice gives the patient a home tonometer or the practice has access to an online visual field instrument, Dr. Gaddie doesn't see much utility in telemedicine for glaucoma. The exception is to see how the patient is tolerating medications or if refills are needed, he notes.

As for screening high-risk populations and those without access to eye care, Dr. Gaddie believes telemedicine could have some impact in environments specially designed with glaucoma testing capabilities. "This would be great in theory, but we have significant gaps to close to make this a mainstream reality," he says.

## Telemed Extends Beyond Glaucoma in Private Practice

Telemedicine can be supplemental to a practice, but it shouldn't be used in isolation, says optometrist Kelsey Moody Mileski. In certain instances, the modality could be ideal for follow-up visits with established patients, and this approach may be more personal than a telephone call if a video chat format is used, she says. However, telemedicine isn't practical if the evaluation requires

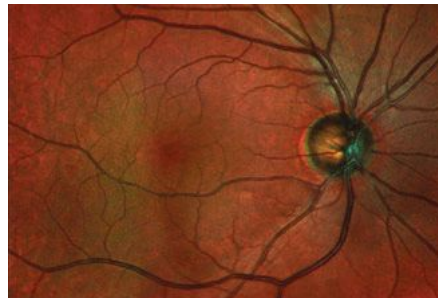


Photo: Ryan Schott, OD

### Could fundus imaging sent electronically during a telehealth screening match the value of an in-person exam?

equipment that isn't available in a virtual format, she explains.

A traditional video-based telemed visit would be an option for minor ocular emergencies, such as a hordeolum or a subconjunctival hemorrhage.

Personally, Dr. Moody Mileski has found telemedicine visits to be helpful for dry eye patients after they have started a new therapy. If a fundus camera is available, additional screenings can be performed during a telemedicine visit, she says. "This is a wonderful option for patients who are seen in the emergency department (ED) or in another provider's office, like neurology or endocrinology practices, where an eye care provider is not available," she adds.

In this setting, an ED provider could obtain information that would not otherwise be available on a traditional video-based exam, such as visual acuity, pupil assessment and IOP. In this scenario, patients could be quickly diagnosed with more concerning and life-threatening conditions such as papilledema, retinal artery occlusion and/or diabetic retinopathy, she explains.

Still, telemedicine poses challenges,

including time constraints, since virtual visits need to be scheduled, just like in-person exams. She suggests scheduling virtual visits at the beginning or end of the day, and for the same amount of time as an in-office visit. However, if the clinic is running behind, a patient may only wait a few minutes before leaving the video call, in which case the entire exam may be missed.

Another telemedicine challenge is technology. Although patients are becoming more familiar with Zoom and FaceTime during the pandemic, technology can still pose difficulties, particularly in older patients. Also, internet accessibility has to be considered for patients in underserved areas, she adds.

Dr. Moody Mileski offered telemedicine exams when her clinics were closed for routine care at the beginning of the pandemic. Still, she found few patients opted for a video-based exam, and instead preferred an initial phone consult.

Even though she currently isn't using telemedicine, as she believes the exams are too limiting, Dr. Moody Mileski thinks virtual visits could play a secondary role in patient care.

A future directive for telemedicine in optometry could include eye care providers engaged in virtual consultations with other healthcare providers, such as those in the ED. In this modality, exam information and imaging such as fundus photography could be sent to the eye care provider for review." ◀

De Moraes CG, Hark LA, Saadine J. Screening and interventions for glaucoma and eye health through telemedicine (SIGT) studies. *J Glaucoma*. January 7, 2021 [Epub ahead of print].

## IN BRIEF

**Chronic rhinosinusitis** can be debilitating for patients and cause obvious symptoms in the nose and throat, but this condition **may also adversely impact the eye**. An investigative team found **the condition appears to cause thinning of the choroid and RNFL**, especially in

the superior and inferior quadrants and ganglion cell-inner plexiform layer (GCIPL). The GCIPL was thinner in all sectors in rhinosinusitis patients, with significantly lower values noted in all sectors except the inferior segment.

Karakahya RH, Korkmaz M, Korkmaz H. Decreased retinal nerve fiber and choroidal thickness in chronic rhinosinusitis. *Eur Arch Otorhinolaryngol*. March 11, 2021. [Epub ahead of print].

## Myopic Progression Accelerated During Lockdown

The COVID-19 lockdown last spring prompted many individuals across the globe to pause routine health care. Looking into how this impacted eye care, a new study found an acceleration of myopia progression in Chinese children and teenagers during this time period; however, the trend was reversed after lockdown, suggesting that both accommodative spasm and structural change may have been contributing factors.

The investigation included 59,000 eyes of 30,000 participants. Refractive error was estimated through noncycloplegic autorefraction, and the spherical equivalent refraction (SER) was calculated as a sphere power of +0.5 cylinder power. Myopia of one eye was defined as SER of -0.5D or less, and high myopia was defined as SER of -6.0D or less. Myopic progression was defined as greater negative SER in the same eye.

The rates of myopia and high myopia at rounds one through four were 48%, 53.2%, 73.7% and 67.9% and 1.3%, 1.9%, 2.8% and 2.7%, respectively—a general upward trend with a slight decrease at round four.




Photo: Julie Tyler, OD, and Heidi Wagner, OD, MPH

### Increased screen time may have caused accommodative spasm during this period.

The mean rates of SER change during the first three periods were -0.030D, -0.074D and 0.016D per month, respectively, which reflected negative deviations in the first two and a positive shift in the last.

Considering age and gender, the differences in myopic proportion and SER were significant in rounds three and four but not in round two. In round three, a greater risk of high myopia was noted; however, younger age and male gender were linked to a lower risk of myopia progression. Rounds one and two showed equal prevalence rates for myopia and SER, while round three curves were notably more myopic. The differences between rounds were more

pronounced in younger students.

Additionally, the difference in SER change across the three survey periods was more remarkable in younger students, which indicated these individuals were more sensitive to myopic progression during the lockdown.

Also, the rate of myopic progression was greater during period two, followed by a hyperopic progression during period three. “We speculate that this may be explained by accommodative spasm during lockdown,” the researchers wrote in their paper. They suggest the impact of restricted outdoor time, increased screen time and limited indoor space on accommodative spasm.

At round four, about half a year after the lockdown was lifted, the accommodative spasm reversed, and the refractive state consequently became more hyperopic.

Exercise caution when interpreting evidence in other populations that live in different areas, the investigators suggested. ◀

Chang P, Zhang B, Lin L, et al. Comparison of the myopic progression before, during and after COVID-19 lockdown. *Ophthalmology*. March 16, 2021 [Epub ahead of print].

## AOA Moves Annual Meeting to Denver

The American Optometric Association (AOA) announced today plans to move forward with an in-person format for Optometry’s Meeting this summer, but in a new location. Rather than host the annual conference in Anaheim, CA, as originally scheduled, the meeting will now take place in Denver, CO.

The dates will remain the same, June 24 through 26.

The AOA chose Denver due to the health and safety protocols put in place there and accreditations received from several certifying bodies, “all of which go beyond what is required by public health experts,” AOA President William Reynolds, OD, and Ameri-

can Optometric Student Association (AOSA) President Alex Bennet wrote in a letter to members. “Rest assured, we will continue to work closely with the convention center, government and local health officials leading up to the event and communicate any updates accordingly,” their letter stated.

For over a year, the optometry profession has had to be nimble in the face of changing circumstances, and the AOA feels this move is in keeping with that larger trend.

“The optometry community faced the growing challenge of the COVID-19 pandemic in 2020 through a dedicated approach of adapting, overcoming and advancing, always

delivering the highest level of safe care for patients nationwide throughout the crisis,” the AOA statement said.

The AOA reaffirmed the organization’s commitment to hosting an in-person event. “It’s finally time to come together, and we are taking the same approach to convene our optometry community and leaders for AOA/AOSA Optometry’s Meeting in 2021, to celebrate the incredible resilience and compassion demonstrated by our members, as well as look forward and plan for an even brighter future.”

Pre-registration is now open online. The AOA says it asks for patience as it continues to work through details and ensure a safe meeting for all. ◀



# SEE THE DIFFERENCE IN THE SMALLEST DETAIL.

PROVIDE YOUR PATIENTS A CONTACT LENS WITH  
AN OPTIMAL FIT, DOWN TO THE MILLIMETER.



NOW  
AVAILABLE IN  
**8.5 AND 8.8**  
BASE CURVES



As one of the few contact lenses available in two base curves, **8.5mm and 8.8mm** — **Unity BioSync® with HydraMist®** continues to provide patients exceptional comfort, high oxygen supply, outstanding vision and the most convenient daily wearing schedule. Choose the optimal fit for your patients with **the only contact lens exclusive to the VSP network**, and provide them the freedom to focus on everyday's best moments.



To learn more, scan the code  
or visit [unitybiosync.com](http://unitybiosync.com).

©2021 Plexus Optix, Inc. Unity BioSync and HydraMist are registered trademarks of Plexus Optix, Inc.

All other brands or marks are the property of their respective owners. Use of these marks, names, logos, and/or brands does not imply endorsement.

# Delay Between Cataract Surgeries Impacts Mental Health

The visual debilitation brought on by cataract development has been linked to depression, and the authors of a recent study wanted to dive deeper and investigate the effect of surgery on the need for medical interventions to alleviate psychological distress. A team from Taiwan assessed usage of mental health consults for depression and anxiety associated with both first- and second-eye surgeries, and sought to determine whether the time interval between procedures affects outcomes of psychological treatment.

A national database of claims was the basis of a cohort study spanning 10 years on 585,422 patients who received cataract surgeries for both eyes. The rates of mental health inpatient and outpatient consultations were analyzed with different time intervals between surgeries (less than three months, three to six months, six to 12 months and more than 12 months).

With patients who had previously sought mental health treatment before their first eye surgery, the number of mental health care consultations decreased postoperatively. This study also found that the decrease in number of mental health consults was less pronounced in patients who had not yet received second-eye surgery and those who received their

second procedure more than three months after their first.

The number of mental health consultations was lowest among patients with a time interval of three months or less. For patients with an interval of more than 12 months, the predicted number of mental health consultations increased.

“In our results, mental health care utilization was most reduced in the group with time intervals of less than three months, suggesting that for patients more active in seeking medical help, the benefits of cataract surgery for reducing mental health care consultations are notable,” the authors noted in their paper.

“A plausible explanation for our results is that the effects of the surgeries for both eyes are compounded when surgeries are received within a short time interval. For patients with longer time intervals, benefits may be obtained only from surgery on the first eye. Thus, patients with longer time intervals continue to have various degrees of visual dysfunction resulting from the unoperated cataract of the second eye.”

The authors also note there were some limitations of this study. For example, increases in the number of health consultations are not necessarily equivalent to a greater severity of clinical mental illness. “Although considering the actual number of mental health service consultations has merits, future studies should analyze the frequency of mental health consultations in combination with the actual mental health severity on a single study population,” the authors concluded. ◀

Hou C, Chen K, Lee J, et al. Effect of the time interval between cataract surgery for both eyes on mental health outcome: a cohort study of 585,422 patients. *BMC Ophthalmol.* March 1, 2021. [Epub ahead of print].

## ACNE MAY AFFECT MEIBOMIAN GLANDS

It's not just an unfortunate rite of passage for many teenagers—acne may make people who suffer from the condition more susceptible to meibomian gland damage and tear instability, a recent paper published in *Clinical and Experimental Optometry* suggests. The research team from Turkey hypothesized that since acne vulgaris is a disease of the sebaceous glands, it could have potential effects on the ocular surface and tear homeostasis.

The investigation enrolled the right eyes of 70 individuals (34 patients with acne vulgaris and 36 healthy controls). Testing included tear breakup time (TBUT), Schirmer's test, impression cytology from conjunctiva samples and meibography of the upper and lower eyelid meibomian glands.

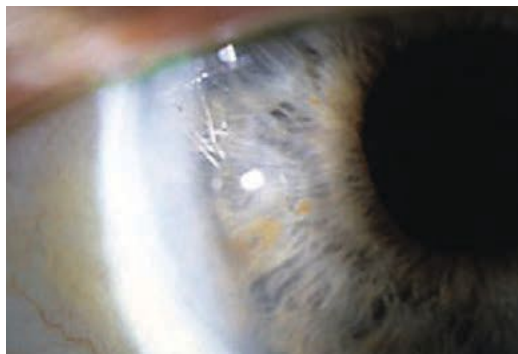
The researchers found that TBUT was significantly lower in the study group, but the conjunctival impression cytology results were similar between both the subjects with acne and the healthy volunteers. Additionally, the investigators did not observe any grade three cytological changes in either group.

Meibomian gland loss in the upper eyelid of patients with acne vulgaris was about 19% compared with roughly 9% in the controls. Meibomian gland loss in the lower eyelid of the individuals with acne was also greater at approximately 16% compared with about 8% in the healthy participants. Individuals with acne vulgaris had a collective gland loss of 35% in both eyes.

In light of the study's findings, a detailed ophthalmologic exam should be performed in patients with acne, the researchers suggested. Additionally, optometrists should remain vigilant for ocular surface pathologies when prescribing glasses or contact lenses for the visual rehabilitation of these young patients, they added.

Muhafiz E, Öztürk M, Erten M. Ocular surface characteristics in acne vulgaris. *Clin Exp Optom.* March 15, 2021. [Epub ahead of print].

Photo: Maria Fabrykowska, OD and Matthew Gaston, OD



**Keep the interval between first- and second-eye procedures under three months, study says.**

## BRIEF SUMMARY OF PRESCRIBING INFORMATION

This Brief Summary does not include all the information needed to use LOTEMAX® SM safely and effectively. See full prescribing information for LOTEMAX® SM.

## LOTEMAX® SM (loteprednol etabonate ophthalmic gel) 0.38%

For topical ophthalmic use

Initial U.S. Approval: 1998

### INDICATIONS AND USAGE

LOTEMAX® SM is a corticosteroid indicated for the treatment of post-operative inflammation and pain following ocular surgery.

### DOSAGE AND ADMINISTRATION

Invert closed bottle and shake once to fill tip before instilling drops. Apply one drop of LOTEMAX® SM into the conjunctival sac of the affected eye three times daily beginning the day after surgery and continuing throughout the first 2 weeks of the post-operative period.

### CONTRAINDICATIONS

LOTEMAX® SM, as with other ophthalmic corticosteroids, is contraindicated in most viral diseases of the cornea and conjunctiva including epithelial herpes simplex keratitis (dendritic keratitis), vaccinia, and varicella, in mycobacterial infection of the eye and fungal diseases of ocular structures.

### WARNINGS AND PRECAUTIONS

**Intraocular Pressure (IOP) Increase:** Prolonged use of corticosteroids may result in glaucoma with damage to the optic nerve, defects in visual acuity and fields of vision. Steroids should be used with caution in the presence of glaucoma. If this product is used for 10 days or longer, intraocular pressure should be monitored.

**Cataracts:** Use of corticosteroids may result in posterior subcapsular cataract formation.

**Delayed Healing:** The use of steroids after cataract surgery may delay healing and increase the incidence of bleb formation. In those diseases causing thinning of the cornea or sclera, perforations have been known to occur with the use of topical steroids. The initial prescription and renewal of the medication order should be made by a physician only after examination of the patient with the aid of magnification such as slit lamp biomicroscopy and, where appropriate, fluorescein staining.

**Bacterial Infections:** Prolonged use of corticosteroids may suppress the host response and thus increase the hazard of secondary ocular infections. In acute purulent conditions of the eye, steroids may mask infection or enhance existing infection.

**Viral Infections:** Employment of a corticosteroid medication in the treatment of patients with a history of herpes simplex requires great caution. Use of ocular steroids may prolong the course and may exacerbate the severity of many viral infections of the eye (including herpes simplex).

**Fungal Infections:** Fungal infections of the cornea are particularly prone to develop coincidentally with long-term local steroid application. Fungus invasion must be considered in any persistent corneal ulceration where a steroid has been used or is in use. Fungal cultures should be taken when appropriate.

**Contact Lens Wear:** Contact lenses should not be worn when the eyes are inflamed.

### ADVERSE REACTIONS

Because clinical trials are conducted under widely varying conditions, adverse reaction rates observed in the clinical trials of a drug cannot be directly compared to rates in the clinical trials of another drug and may not reflect the rates observed in practice. Adverse reactions associated with ophthalmic steroids include elevated intraocular pressure, which may be associated with infrequent optic nerve damage, visual acuity and field defects, posterior subcapsular cataract formation, delayed wound healing and secondary ocular infection from pathogens including herpes simplex, and perforation of the globe where there is thinning of the cornea or sclera. There were no treatment-emergent adverse drug reactions that occurred in more than 1% of subjects in the three times daily group compared to vehicle.

### USE IN SPECIAL POPULATIONS

**Pregnancy:** Risk Summary: There are no adequate and well controlled studies with loteprednol etabonate in pregnant women. Loteprednol etabonate produced teratogenicity at clinically relevant doses in the rabbit and rat when administered orally during pregnancy. Loteprednol etabonate produced malformations when administered orally to pregnant rabbits at doses 4.2 times the recommended human ophthalmic dose (RHOD) and to pregnant

rats at doses 106 times the RHOD. In pregnant rats receiving oral doses of loteprednol etabonate during the period equivalent to the last trimester of pregnancy through lactation in humans, survival of offspring was reduced at doses 10.6 times the RHOD. Maternal toxicity was observed in rats at doses 1066 times the RHOD, and a maternal no observed adverse effect level (NOAEL) was established at 106 times the RHOD. The background risk of major birth defects and miscarriage for the indicated population is unknown. However, the background risk in the U.S. general population of major birth defects is 2 to 4%, and of miscarriage is 15 to 20%, of clinically recognized pregnancies. Data: *Animal Data.* Embryofetal studies were conducted in pregnant rabbits administered loteprednol etabonate by oral gavage on gestation days 6 to 18, to target the period of organogenesis. Loteprednol etabonate produced fetal malformations at 0.1 mg/kg (4.2 times the recommended human ophthalmic dose (RHOD) based on body surface area, assuming 100% absorption). Spina bifida (including meningocele) was observed at 0.1 mg/kg, and exencephaly and craniofacial malformations were observed at 0.4 mg/kg (17 times the RHOD). At 3 mg/kg (128 times the RHOD), loteprednol etabonate was associated with increased incidences of abnormal left common carotid artery, limb flexures, umbilical hernia, scoliosis, and delayed ossification. Abortion and embryofetal lethality (resorption) occurred at 6 mg/kg (256 times the RHOD). A NOAEL for developmental toxicity was not established in this study. The NOAEL for maternal toxicity in rabbits was 3 mg/kg/day. Embryofetal studies were conducted in pregnant rats administered loteprednol etabonate by oral gavage on gestation days 6 to 15, to target the period of organogenesis. Loteprednol etabonate produced fetal malformations, including absent innominate artery at 5 mg/kg (106 times the RHOD); and cleft palate, agnathia, cardiovascular defects, umbilical hernia, decreased fetal body weight and decreased skeletal ossification at 50 mg/kg (1066 times the RHOD). Embryofetal lethality (resorption) was observed at 100 mg/kg (2133 times the RHOD). The NOAEL for developmental toxicity in rats was 0.5 mg/kg (10.6 times the RHOD). Loteprednol etabonate was maternally toxic (reduced body weight gain) at 50 mg/kg/day. The NOAEL for maternal toxicity was 5 mg/kg. A peri-/postnatal study was conducted in rats administered loteprednol etabonate by oral gavage from gestation day 15 (start of fetal period) to postnatal day 21 (the end of lactation period). At 0.5 mg/kg (10.6 times the clinical dose), reduced survival was observed in live-born offspring. Doses  $\geq$  5 mg/kg (106 times the RHOD) caused umbilical hernia/incomplete gastrointestinal tract. Doses  $\geq$  50 mg/kg (1066 times the RHOD) produced maternal toxicity (reduced body weight gain, death), decreased number of live-born offspring, decreased birth weight, and delays in postnatal development. A developmental NOAEL was not established in this study. The NOAEL for maternal toxicity was 5 mg/kg.

**Lactation:** There are no data on the presence of loteprednol etabonate in human milk, the effects on the breastfed infant, or the effects on milk production. The developmental and health benefits of breastfeeding should be considered, along with the mother's clinical need for LOTEMAX® SM and any potential adverse effects on the breastfed infant from LOTEMAX® SM.

**Pediatric Use:** Safety and effectiveness of LOTEMAX® SM in pediatric patients have not been established.

**Geriatric Use:** No overall differences in safety and effectiveness have been observed between elderly and younger patients.

### NONCLINICAL TOXICOLOGY

**Carcinogenesis, Mutagenesis, Impairment of Fertility:** Long-term animal studies have not been conducted to evaluate the carcinogenic potential of loteprednol etabonate. Loteprednol etabonate was not genotoxic *in vitro* in the Ames test, the mouse lymphoma tk assay, or in the chromosomal aberration test in human lymphocytes, or *in vivo* in the mouse micronucleus assay. Treatment of male and female rats with 25 mg/kg/day of loteprednol etabonate (533 times the RHOD based on body surface area, assuming 100% absorption) prior to and during mating caused preimplantation loss and decreased the number of live fetuses/live births. The NOAEL for fertility in rats was 5 mg/kg/day (106 times the RHOD).

**Distributed by:** Bausch + Lomb, a division of Bausch Health US, LLC, Bridgewater, NJ 08807 USA

**Manufactured by:** Bausch & Lomb Incorporated, Tampa, FL 33637 USA  
U.S. Patent Number: 10,596,107

LOTEMAX is a trademark of Bausch & Lomb Incorporated or its affiliates.  
© 2021 Bausch & Lomb Incorporated or its affiliates.

Based on 9669601 (Folded) 9669701 (Flat)  
LSM.0032.USA.21

Revised: 4/2020  
Issued: 2/2021





# SUBMICRON STRONG

for

POTENCY + PROVEN STRENGTH<sup>1,2</sup>

2× greater inflammation clearance  
as compared to vehicle<sup>2\*</sup>

## SM TECHNOLOGY™

- Engineered with SM Technology™ for efficient penetration at a low BAK level (0.003%)<sup>1,3</sup>
- ~2× greater penetration to the aqueous humor than LOTEMAX® GEL (loteprednol etabonate ophthalmic gel) 0.5%<sup>3</sup>

Clinical significance of these preclinical data has not been established.

## LOTEMAX® SM

(loteprednol etabonate  
ophthalmic gel) 0.38%

SMALL & MIGHTY  
SUBMICRON PARTICLES

### \*PROVEN STRENGTH

- 30% of LOTEMAX® SM patients had complete ACC resolution vs vehicle (15%) at Day 8 (N=371, P<0.0001)<sup>1,2†</sup>
- 74% of LOTEMAX® SM patients were completely pain-free vs vehicle (49%) at Day 8 (N=371, P<0.0001)<sup>1,2‡</sup>

<sup>†</sup>Pooled analysis of Phase 3 clinical studies. **Study 1:** 29% LOTEMAX® SM (N=171) vs 9% vehicle (N=172). **Study 2:** 31% LOTEMAX® SM (N=200) vs 20% vehicle (N=199); P<0.05 for all.

<sup>‡</sup>Pooled analysis of Phase 3 clinical studies. **Study 1:** 73% LOTEMAX® SM (N=171) vs 48% vehicle (N=172). **Study 2:** 76% LOTEMAX® SM (N=200) vs 50% vehicle (N=199); P<0.05 for all.

## Indication

LOTEMAX® SM (loteprednol etabonate ophthalmic gel) 0.38% is a corticosteroid indicated for the treatment of post-operative inflammation and pain following ocular surgery.

## Important Safety Information

- LOTEMAX® SM, as with other ophthalmic corticosteroids, is contraindicated in most viral diseases of the cornea and conjunctiva including epithelial herpes simplex keratitis (dendritic keratitis), vaccinia, and varicella, and also in mycobacterial infection of the eye and fungal diseases of ocular structures.
- Prolonged use of corticosteroids may result in glaucoma with damage to the optic nerve, defects in visual acuity and fields of vision. Steroids should be used with caution in the presence of glaucoma. If LOTEMAX® SM is used for 10 days or longer, IOP should be monitored.
- Use of corticosteroids may result in posterior subcapsular cataract formation.

## Important Safety Information (cont.)

- The use of steroids after cataract surgery may delay healing and increase the incidence of bleb formation. In those with diseases causing thinning of the cornea or sclera, perforations have been known to occur with the use of topical steroids. The initial prescription and renewal of the medication order should be made by a physician only after examination of the patient with the aid of magnification such as slit lamp biomicroscopy and, where appropriate, fluorescein staining.
- Prolonged use of corticosteroids may suppress the host response and thus increase the hazard of secondary ocular infections. In acute purulent conditions, steroids may mask infection or enhance existing infections.
- Employment of a corticosteroid medication in the treatment of patients with a history of herpes simplex requires great caution. Use of ocular steroids may prolong the course and may exacerbate the severity of many viral infections of the eye (including herpes simplex).
- Fungal infections of the cornea are particularly prone to develop coincidentally with long-term local steroid application. Fungus invasion must be considered in any persistent corneal ulceration where a steroid has been used or is in use. Fungal cultures should be taken when appropriate.
- Contact lenses should not be worn when the eyes are inflamed.
- There were no treatment-emergent adverse drug reactions that occurred in more than 1% of subjects in the three times daily group compared to vehicle.

You are encouraged to report negative side effects of prescription drugs to the FDA. Visit [www.fda.gov/medwatch](http://www.fda.gov/medwatch) or call 1-800-FDA-1088.

Please see brief summary of Prescribing Information on adjacent page.

**References:** 1. LOTEMAX SM Prescribing Information. Bausch & Lomb Incorporated. 2. Data on file. Bausch & Lomb Incorporated. 3. Cavet ME, Glogowski S, Lowe ER, Phillips E. Rheological properties, dissolution kinetics, and ocular pharmacokinetics of loteprednol etabonate (submicron) ophthalmic gel 0.38%. *J Ocul Pharmacol Ther.* 2019. doi: 10.1089/jop.2019.35(5):291-300.

## BAUSCH + LOMB

©/TM are trademarks of Bausch & Lomb Incorporated or its affiliates.  
© 2021 Bausch & Lomb Incorporated or its affiliates. All rights reserved. LSM.0041.USA.21

Discover more at  
[www.LOTEMAXSM.com](http://www.LOTEMAXSM.com)

**LOTEMAX® SM**  
(loteprednol etabonate  
ophthalmic gel) 0.38%

# FEATURES

REVIEW OF OPTOMETRY • Vol. 158, No. 4 • APRIL 15, 2021



CATCH UP ON THE LATEST NEWS

- ▶ Stories post online every weekday
- ▶ Weekly recap emailed every Sunday

## Annual Cornea Report

### 62 Keeping Up With Keratitis

Corneal infections move fast—and you should, too. Here's advice on how to mobilize a defense of the eye that yields swift results.

*By Suzanne Sherman, OD,  
and Christina Cherny, BS*

### 76 Skip the Scalpel? A Medical Approach to Endo Recovery

Combine your clinical observations and knowledge with detailed imaging to put together the full picture of the diagnosis.

*By Aaron Bronner, OD, and Huy Do, OD*

### 86 **EARN 2 CE CREDITS**

### A New Consensus on Keratoconus

Collagen crosslinking has prompted a more interventional approach to this condition. *By Mitch Ibach, OD*

### 70 Corneoscleral Concerns: Trouble at the Border

The limbal junction is key in protecting and preserving the ocular surface. Here are a few conditions that can disrupt its equilibrium.

*By Megan Mannen, OD*

### 80 The Many Layers of Cornea Comanagement

The urgency of clinical scenarios in this area often has optometrists setting expectations—and the relationship dynamic, too.

*By Catlin Nalley, Contributing Writer*

### 36 Myopia: Translating Science into Practice

With the prevalence of this condition skyrocketing, it's more important now than ever to understand its mechanism and management.

*By Nathan Cheung, OD*

### 44 Five Questions on Dry AMD Monitoring and Management

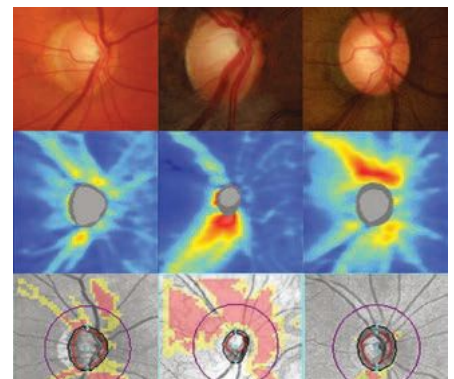
Address these concerns and observing these patients will be more effective.

*By Jessica Haynes, OD*

### 52 A Glaucoma Starter Kit: The Patient in Your Chair

Applying personalized medicine to this chronic disease is critical to ensure the best outcomes.

*By Jack Phu, OD, PhD,  
and Henrietta Wang, BOptom, BSc*



# DEPARTMENTS

REVIEW OF OPTOMETRY • APRIL 15, 2021

4

NEWS REVIEW

20

LETTERS TO THE EDITOR

22

OUTLOOK

## A Case of Nerves

ODs may hesitate to embrace neuro-ophthalmic cases, but you can be an essential player in care without shouldering it all.

*Jack Persico, Editor-in-Chief*

24

THROUGH MY EYES

## New Options, Front to Back

Take a look at promising treatments for the cornea and retina, ready now or on the horizon.

*Paul M. Karpecki, OD*

26

CHAIRSIDE

## Let's Take a Gander at Gaps

We all have them in our schedules—worse now than ever. Don't deny it.

*Montgomery Vickers, OD*

28

CLINICAL QUANDARIES

## Pass the Salt

Guide patients through the initial healing window of RCE and future episodes may be minimized.

*Paul C. Ajamian, OD*

31

FOCUS ON REFRACTION

## Make Way For Yoked Prism

This option has improved the lives of many patients; two are highlighted here.

*Marc B. Taub, OD, MS, Paul Harris, OD, and Alicia Groce, OD*

34

CODING CONNECTION

## Biological Alternative

Amniotic membranes could be the best corneal treatment option in a number of cases.

*John Rumpakis, OD, MBA*

96

CORNEA AND CONTACT LENS Q+A

## Operation Risk Reduction

It's up to us to help mitigate the factors that can contribute to corneal infection.

*Joseph P. Shovlin, OD*

98

GLAUCOMA GRAND ROUNDS

## Spot the Subtleties

Pay close attention to your results, as smaller changes could mean the difference between glaucoma progression and simple testing variability.

*James L. Fanelli, OD*

102

SURGICAL MINUTE

## Build Back Better

When the epithelium is compromised, sometimes the best approach is to let the eye start over with a clean slate.

*Ethan Zimmerman, OD, Derek N. Cunningham, OD, and Walter O. Whitley, OD, MBA*

104

THERAPEUTIC REVIEW

## Scratching the Surface

Doing a thorough job with corneal abrasions helps greatly.

*Joseph W. Sowka, OD*

108

OCULAR SURFACE REVIEW

## End of the Line for EBMD

More than just an annoyance, this condition can alter refractive status in ways that complicate outcomes for surgical patients.

*Paul M. Karpecki, OD*

109

ADVERTISERS INDEX

110

CLASSIFIED ADVERTISING

112

PRODUCT REVIEW

114

DIAGNOSTIC QUIZ

## Elevator Going Up

Does this atypical retinal presentation suggest a sight-threatening pathology, or something benign?

*Andrew S. Gurwood, OD*



VISIT US ON SOCIAL MEDIA

Facebook: [www.facebook.com/revoptom](http://www.facebook.com/revoptom)

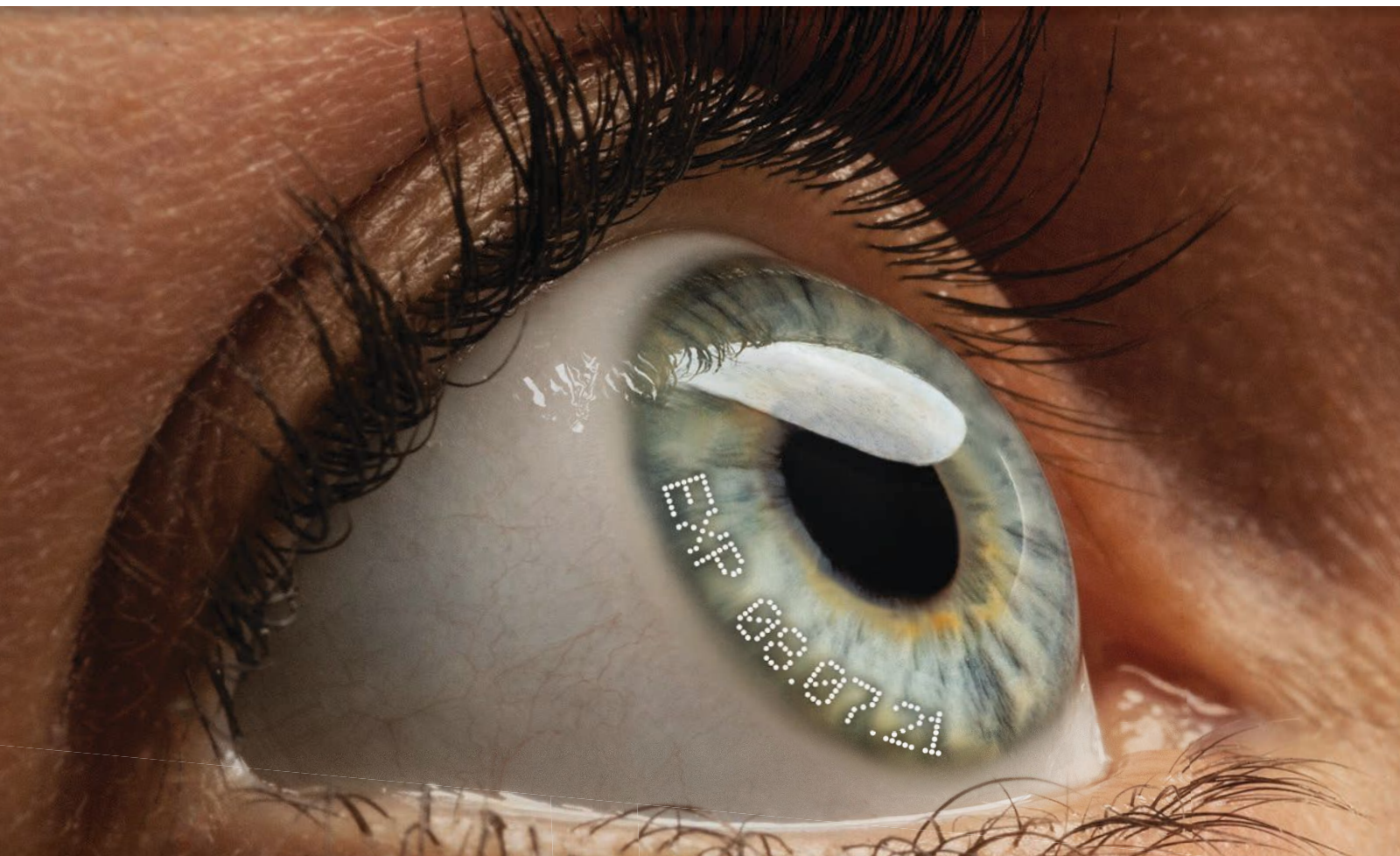Twitter: [twitter.com/revoptom](http://twitter.com/revoptom)

Instagram: [www.instagram.com/revoptom](http://www.instagram.com/revoptom)





Using Photrexa® Viscous (riboflavin 5'-phosphate in 20% dextran ophthalmic solution), Photrexa® (riboflavin 5'-phosphate ophthalmic solution), and the KXL® system, the iLink™ corneal cross-linking procedure from Glaukos is the only FDA-approved therapeutic treatment for patients with progressive keratoconus and corneal ectasia following refractive surgery.\*1



# GET THERE IN TIME

When you see patients with signs of keratoconus, don't hesitate. Refer them for iLink™ — the only FDA-approved cross-linking procedure that slows or halts disease progression and is eligible for commercial insurance coverage with over 95% of commercially covered lives.

Connect with an iLink™ expert today. Visit [iLinkExpert.com](http://iLinkExpert.com)

#### INDICATIONS

Photrexa® Viscous (riboflavin 5'-phosphate in 20% dextran ophthalmic solution) and Photrexa® (riboflavin 5'-phosphate ophthalmic solution) are indicated for use with the KXL System in corneal collagen cross-linking for the treatment of progressive keratoconus and corneal ectasia following refractive surgery. Corneal collagen cross-linking should not be performed on pregnant women.

#### IMPORTANT SAFETY INFORMATION

Ulcerative keratitis can occur. Patients should be monitored for resolution of epithelial defects. The most common ocular adverse reaction was corneal opacity (haze). Other ocular side effects include punctate keratitis, corneal striae, dry eye, corneal epithelium defect, eye pain, light sensitivity, reduced visual acuity, and blurred vision. These are not all of the side effects of the corneal collagen cross-linking treatment. For more information, go to [www.livingwithkeratoconus.com](http://www.livingwithkeratoconus.com) to obtain the FDA-approved product labeling. You are encouraged to report all side effects to the FDA. Visit [www.fda.gov/medwatch](http://www.fda.gov/medwatch), or call 1-800-FDA-1088. \*Photrexa® Viscous and Photrexa® are manufactured for Avedro. The KXL® system is manufactured by Avedro. Avedro is a Glaukos company.

REFERENCE: 1. Photrexa [package insert] Waltham, MA: Glaukos, Inc. 2016.

MA-02164A  
PM-US-0427

iLink™ is a trademark of Glaukos Corporation. Photrexa®, Photrexa® Viscous, and the KXL® system are registered trademarks of Avedro, a Glaukos company. All rights reserved. ©2021





**Business Offices**

19 Campus Boulevard, Suite 101  
Newtown Square, PA 19073  
Subscription inquiries (877) 529-1746 (USA only)  
outside USA, call (847) 763-9630

PUBLISHER  
**MICHAEL HOSTER**  
(610) 492-1028  
mhoster@jobson.com

EXECUTIVE DIRECTOR  
**JAMES HENNE**  
(610) 492-1017  
jhenne@jobson.com

REGIONAL SALES MANAGER  
**MICHELE BARRETT**  
(610) 492-1014  
mbarrett@jobson.com

REGIONAL SALES MANAGER  
**JONATHAN DARDINE**  
(610) 492-1030  
jdardine@jobson.com

PRODUCTION MANAGER  
**FARRAH APONTE**  
212-274-7057 faponte@Jobson.com

PRODUCTION MANAGER  
**KAREN LALLONE**  
(610) 492-1010 klallone@Jobson.com

**CLASSIFIED ADVERTISING**  
(888)-498-1460

**SUBSCRIPTIONS**  
\$63 PER YEAR, \$99 (US) IN CANADA,  
\$158 (US) IN ALL OTHER COUNTRIES  
revoptometry@cambeywest.com

**CIRCULATION**  
PO BOX 71, CONGERS, NY 10920-0071  
(877) 529-1746  
OUTSIDE USA: (845) 267-3065

SENIOR CIRCULATION MANAGER  
**HAMILTON MAHER**  
(212) 219-7870  
hmaher@jhihealth.com

CEO, INFORMATION GROUP SERVICES  
**MARC FERRARA**

SENIOR VICE PRESIDENT, OPERATIONS  
**JEFF LEVITZ**

VICE PRESIDENT, HUMAN RESOURCES  
**TAMMY GARCIA**

VICE PRESIDENT, CREATIVE SERVICES & PRODUCTION  
**MONICA TETTAMANZI**

CORPORATE PRODUCTION DIRECTOR  
**JOHN ANTHONY CAGGIANO**

VICE PRESIDENT, CIRCULATION  
**JARED SONNERS**

Jobson Health Information/WebMD  
395 Hudson Street, 3rd Floor, New York, NY 10014

## CLINICAL EDITORS

**CHIEF CLINICAL EDITOR** ~ PAUL M. KARPECKI, OD

**ASSOCIATE CLINICAL EDITORS** ~ JOSEPH P. SHOVLIN, OD, CHRISTINE SINDT, OD

## CONTRIBUTING EDITORS

**PAUL C. AJAMIAN, OD**, ATLANTA  
**DEREK N. CUNNINGHAM, OD**, AUSTIN, TEXAS  
**MARK T. DUNBAR, OD**, MIAMI  
**JAMES L. FANELLI, OD**, WILMINGTON, NC  
**ANDREW S. GURWOOD, OD**, PHILADELPHIA  
**PAUL HARRIS, OD**, MEMPHIS, TENN.  
**PAUL M. KARPECKI, OD**, LEXINGTON, KY.  
**BISANT LABIB, OD**, ELKINS PARK, PA.

**RICHARD B. MANGAN, OD**, BOULDER, COLO.  
**JOHN RUMPAKIS, OD, MBA**, PORTLAND, ORE.  
**JOSEPH P. SHOVLIN, OD**, SCRANTON, PA.  
**JOSEPH W. SOWKA, OD**, FORT LAUDERDALE, FLA.  
**MARC TAUB, OD**, MEMPHIS, TENN.  
**MONTGOMERY VICKERS, OD**, DALLAS, TEXAS  
**WALTER O. WHITLEY, OD, MBA**, VIRGINIA BEACH, VA.

## EDITORIAL ADVISORY BOARD

**JEFFREY R. ANSHEL, OD**, ENCINITAS, CALIF.  
**JILL AUTRY, OD, RPH**, HOUSTON  
**SHERRY J. BASS, OD**, NEW YORK  
**EDWARD S. BENNETT, OD**, ST. LOUIS  
**MARC R. BLOOMENSTEIN, OD**, SCOTTSDALE, ARIZ.  
**AARON BRONNER, OD**, KENNEWICK, WASH.  
**MILE BRUJIC, OD**, BOWLING GREEN, OHIO  
**CHRIS J. CAKANAC, OD**, MURRYSVILLE, PA  
**JERRY CAVALLERANO, OD, PhD**, BOSTON  
**WALTER L. CHOATE, OD**, MADISON, TENN.  
**BRIAN CHOU, OD**, SAN DIEGO  
**MICHAEL CHAGLASIAN, OD**, CHICAGO  
**A. PAUL CHOUS, MA, OD**, TACOMA, WASH.  
**GLENN S. CORBIN, OD**, WYOMISSING, PA  
**MICHAEL DELGIODICE, OD**, CLIFTON, NJ  
**ANTHONY S. DIECIDUE, OD**, STROUDSBURG, PA  
**S. BARRY EIDEN, OD**, DEERFIELD, ILL.  
**ARTHUR B. EPSTEIN, OD**, PHOENIX  
**STEVEN FERRUCCI, OD**, SEPULVEDA, CALIF.  
**MURRAY FINGERET, OD**, HEWLETT, NY  
**IAN BEN GADDIE, OD**, LOUISVILLE, KY  
**GARY S. GERBER, OD**, HAWTHORNE, NJ  
**PAUL HARRIS, OD**, MEMPHIS, TENN.  
**MILTON HOM, OD**, AZUSA, CALIF.  
**DAVID KADING, OD**, SEATTLE  
**JEROME A. LEGERTON, OD, MBA**, SAN DIEGO  
**THOMAS L. LEWIS, OD, PhD**, PHILADELPHIA

**BLAIR B. LONSBERRY, MS, OD, MED**, PORTLAND, ORE.  
**DOMINICK MAINO, OD, MED**, CHICAGO  
**KELLY A. MALLOY, OD**, PHILADELPHIA  
**RICHARD B. MANGAN, OD**, BOULDER, COLO.  
**DANICA MARRELLI, OD**, HOUSTON, TEX.  
**RON MELTON, OD**, CHARLOTTE, NC  
**PAMELA J. MILLER, OD, JD**, HIGHLAND, CALIF.  
**BRUCE MUCHNICK, OD**, COATESVILLE, PA  
**MARC MYERS, OD**, COATESVILLE, PA  
**CARLO J. PELINO, OD**, JENKINTOWN, PA  
**JOSEPH PIZZIMENTI, OD**, FORT LAUDERDALE, FLA.  
**CHRISTOPHER J. QUINN, OD**, ISELIN, NJ  
**MICHAEL C. RADOIU, OD**, STAUNTON, VA  
**MOHAMMAD RAFIETARY, OD**, MEMPHIS, TENN.  
**JOHN L. SCHACHET, OD**, ENGLEWOOD, COLO.  
**JACK SCHAEFFER, OD**, BIRMINGHAM, ALA.  
**LEO P. SEMES, OD**, BIRMINGHAM, ALA.  
**DIANA L. SHECHTMAN, OD**, FORT LAUDERDALE, FLA.  
**JEROME SHERMAN, OD**, NEW YORK, NY  
**LEONID SKORIN, JR., OD, DO**, ROCHESTER, MINN.  
**JOSEPH W. SOWKA, OD**, FORT LAUDERDALE, FLA.  
**BRAD M. SUTTON, OD**, INDIANAPOLIS  
**LORETTA B. SZCZOTKA, OD, PhD**, CLEVELAND  
**MARC TAUB, OD**, MEMPHIS, TENN.  
**TAMMY P. THAN, MS, OD**, BIRMINGHAM, ALA.  
**RANDALL THOMAS, OD**, CONCORD, NC  
**SARA WEIDMAYER, OD**, ANN ARBOR, MICH.  
**KAREN YEUNG, OD**, LOS ANGELES





# TALKING PRESBYOPIA

## ANATOMY OF AN EFFECTIVE PATIENT CONVERSATION

Presbyopia is a prevalent condition that affects nearly everyone at some point, typically beginning around age 40 and worsening with age.<sup>1</sup> About 128 million Americans are currently affected, and the numbers continue to increase with the aging population.<sup>1-3</sup> A progressive condition that reduces the eye's ability to focus on near objects,<sup>1</sup> presbyopia impacts patients' daily activities and health-related quality of life.<sup>4,5</sup>

### Patient frustration is also prevalent

Modern technology and extended screen time have changed the demands and needs of presbyopia patients. Despite the variety of surgical and nonsurgical treatment options, the results of a survey of 1339 patients, aged 40 to 55, found that 90% were frustrated or irritated with presbyopia.<sup>4</sup>

The survey also showed that 79% of presbyopes who saw an eye care professional (ECP) initiated a discussion about their near vision loss symptoms, but only half got the information they needed.<sup>4</sup> Clearly, there is an opportunity to enhance interactions with these patients to improve satisfaction.

**Awareness Gap** → Presbyopes are more frustrated with their vision and current treatment options than is often realized.<sup>4</sup>

### Surprising results of recent patient dialogue research

With the objective of uncovering opportunities for better engagement with patients, 42 in-office dialogues were analyzed to understand the nature of discussions between ECPs and patients with presbyopia.<sup>6</sup>

The research focused on topics either associated with presbyopia as a condition or treatment options and expectations.

### Insight #1: Presbyopia was often downplayed in many ways<sup>6</sup>

- **Short/sparse** conversations, with the average presbyopia discussion lasting less than 2 minutes
- **Lack of probing** beyond the initial expression of impaired near vision
- **Minimizing language** used regarding reading glasses
- **Humor** used to dispel any notion of pathology, but with the unintended consequence of presenting presbyopia as a nonserious burden patients must bear

*ECP: "You are right on time...welcome to the club."*

*ECP: "The only thing that causes this is the candles on your birthday cake."*

### Insight #2: Patient education on presbyopia was limited<sup>6</sup>

- There was **little uniformity in explaining presbyopia**, and ECPs rarely talked about the physical changes in the eye that lead to the condition

Only **1 out of 5** nonspecific dialogues\* involved an ECP explaining presbyopia in depth.



- Presbyopia was **described as an unavoidable, natural part of aging** that is progressive
- ECPs and patients **struggled to find vocabulary** to describe vision changes, with metaphors like "trouble reading" or "needing reading glasses" consistently used instead of "presbyopia"

\*Dialogue not specific to presbyopia or not with a currently known presbyope.

*ECP: "What are you doing? Are you doing readers or what are you using to see?"*

*Patient: "I really don't do anything. I have a little magnifying glass."*

Continued on back.



### Insight #3: Quality-of-life (QoL) concerns were not fully addressed<sup>6</sup>

ECPs tended to present the need for reading glasses as a simple fact of aging, whereas dependency on glasses was a common QoL concern for patients. Framing the discussion around “reading glasses” may prevent patients from thinking about or addressing presbyopia in the context of other activities where close distance/near vision is needed, such as screen usage, fishing, or threading a needle.

### Insight #4: OTC reading glasses recommended the most<sup>6</sup>

Reading glasses were the default treatment option for presbyopia, but limited support was provided. Most ECPs suggested specific magnification levels, but usually a range and rarely a single strength. Although reading glasses are OTC products, patients still wanted guidance. When other treatment options were presented, the advantages of reading glasses were reinforced: cost, simplicity, and noninvasiveness.

*Patient: “So, what’s the best way to pick reading glasses... is it just trial and error?”*

*ECP: “It’s totally trial and error.”*

## Best practices to improve patient engagement

### Conduct deeper presbyopia discussions

More meaningful discussions can raise the importance of presbyopia to a level worth treating.

- **Initiate intentional conversations** about presbyopia
- **Probe patients** to share their concerns
- **Avoid minimizing** and downplaying presbyopia

### Increase the educational content of presbyopia discussions

Explaining presbyopia in a way that is easily understood can empower patients to make informed treatment decisions.

- **Use clear, consistent language** and specific keywords
- **Describe the aging eye** and the cause
- Assure patients that, while unavoidable, **presbyopia can be treated**

### Make QoL concerns a key part of the discussion

Gaining a full understanding of patients’ concerns can help guide treatment decisions.

- Discuss the **day-to-day impact** on patients’ lives
- **Acknowledge frustrations** patients are experiencing
- **Ask patients about activities** beyond reading where close distance/near vision is needed

### Explore and discuss treatment options in depth

Setting realistic expectations about treatment can increase patient satisfaction.

- **Ask questions** to identify the best option for each patient’s lifestyle
- Guide patients in making an **informed decision**
- **Discuss potential pros and cons** of each treatment option

## Enhancing patient interactions can help minimize frustrations

The presbyopia population and its needs are shifting, presenting both challenges and opportunities for raising the bar in patient satisfaction. Adopting the presbyopia dialogue strategies presented here can create better engagement with patients and minimize the frustration factor.

**References:** 1. Care of the Patient with Presbyopia. American Optometric Association. 2011. 2. Zebardast et al. *Am J Ophthalmol.* 2017;174:134-144. 3. U.S. Census Bureau. Table 9. Washington: Population Division. 2014. 4. Data on file, Allergan; Full Quantitative Summary. 5. McDonnell et al. *Arch Ophthalmol.* 2003;121(11):1577-1581. 6. Data on file, Allergan; Verilogue Presbyopia Dialogue Insights Report.

# Optometric Glaucoma Symposiums

SPRING | MAY 7–8, 2021

WINTER | DECEMBER 10–11, 2021



VIRTUAL EVENTS

## INTERACTIVE VIRTUAL CONFERENCES

The Optometric Glaucoma Symposiums, brought to you by Review Education Group and MedscapeLIVE!, come to you virtually in 2021! The OGS conferences are long-running and trusted programs for optometrists managing patients with glaucoma.

## REGISTRATION

Earn up to 12 LIVE COPE credits\* when you register for a single conference, or bundle together to save \$50 off the registration fee and double your credit!

**Flat rate bundled discount: \$248**

Super early single conference: \$149

## PROGRAM CO-CHAIRS



### Murray Fingeret, OD, FAAO

Chief of the Optometry Section  
Brooklyn/St. Albans Campus  
Department of Veterans Administration  
New York Harbor Health Care System  
Clinical Professor  
SUNY, College of Optometry



### Robert N. Weinreb, MD

Chair and Distinguished Professor  
of Ophthalmology  
Director, Shiley Eye Institute  
Director, Hamilton Glaucoma Center  
Morris Gleich, M.D. Chair in Glaucoma  
Board Certification in Ophthalmology

\*Earn up to 24 LIVE COPE Credits

To register visit:

[www.ReviewEdu.com/OGS2021](http://www.ReviewEdu.com/OGS2021)

e-mail: [ReviewMeetings@MedscapeLIVE.com](mailto:ReviewMeetings@MedscapeLIVE.com)



\*Approval pending

Review Education Group partners with Salus University for those ODs who are licensed in states that require university credit.



# LETTERS TO THE EDITOR

Feedback and ideas from the optometric community.

## SHARE YOUR THOUGHTS

Letters are welcome.

Write to:

[editor@reviewofoptometry.com](mailto:editor@reviewofoptometry.com)

### ► VISION THERAPY SNUB UNWARRANTED

I was very discouraged to see one of the major optometric journals publish an article about amblyopia (“The Generalist’s Guide to Amblyopia,” January 2021) without mentioning vision therapy as a treatment option. While VT may not be common practice for most eyecare professionals (though it should be the first line of treatment), it should be worth mentioning in an article about amblyopia.

It concerns me that optometry has aligned itself with the medical model and vision has been simplified to no more than a concern for visual acuity.

We appear to have

ignored our history and the principles that our unique profession was founded on; namely, the function of vision and the pinnacle of vision function, binocularity. Current research clearly shows that functional amblyopia exists because the two eyes cannot be fused in the brain. To truly solve amblyopia, one must solve the binocular problem at the brain level. How is patching a child with amblyopia (making them monocular) going to improve binocular vision? It cannot be that training an amblyopic eye independently rather than the visual system as a unit constitutes best practices.

It astounds me that optometry will consult and/or refer to ophthalmology but we do not refer (or even recognize) those within our own profession who successfully treat amblyopia daily. When will mismanagement of amblyopia be held to the same standards as mismanagement of glaucoma or a retinal condition?

Therapy for amblyopia has advanced much further than managing the condition with an eye patch alone. Let’s stop simplifying vision and thereby degrading our profession. The profession has expanded but let us not move the profession away from our roots: the diagnosis and treatment of functional vision problems.

—Megan Lott, OD, FCOVD  
Belle Vue Specialty Eye Care, Hattiesburg, MS

### ► YOUNG ODs CAN REINVIGORATE ESTABLISHED PRACTICES

I read with interest the February editorial (“Can’t Get There From Here”) on the plight of new graduates struggling to find positions that use their skills to the fullest.

There are—or should be—plenty of opportunities for young doctors to expand private practices by offering their more robust skill set to established offices. Many older ODs did not have the outstanding education that’s offered today

in our training programs. These senior doctors can bring newer services into their practices simply through a hire rather than extensive training on their own part.

In addition to your example of glaucoma, newly minted optometrists have the potential to offer an established practice skills in any of the following realms: AMD, night vision complaints, diabetes and diabetic retinopathy, dry eye and MGD, computer-related visual symptoms, concussion and head trauma, cataract comanagement, eyelid lumps and bumps, blepharochalasis and ptosis, identification of retinal lesions, ocular safety of systemic meds, neurological conditions like MS or Parkinson’s, and specialty contact lenses, which are enjoying a renaissance thanks to sclerals.

Established ODs who say they can’t afford to pay the new grads should consider the tremendous increase in revenue these services will bring to their practices just among the established patients already being seen in their offices, let alone new ones. Some creative salary structuring can minimize the liability, such as a compensation plan giving the new OD a somewhat smaller base salary and 30% to 50% of the new fees that are collected. Both parties win! Finally, the established OD finds an eventual buyer for their practice—something they frequently complain is not available.

For the young OD, benefits are equally desirable, including income growth potential that’s absent in corporate positions, the career satisfaction of using all the skills and training that they invested their time in developing, and the security in knowing that an equity share provides a valued asset when the time comes to retire.

—George E. White, OD, FAAO  
Residency director (ret.), Pennsylvania College of Optometry


### ► CORRECTIONS

#### Eso or exo?

A figure in the February article, “An Action Plan for Assessing Double Vision,” incorrectly described the results of Maddox rod testing as an eso deviation when it was an exo. The corrected caption appears in the online version.

#### Visual field not so bad

A perimetry report in the February article, “Breaking Down Visual Fields in Glaucoma,” printed incorrectly, suggesting more end-stage disease than was present in the case. The online version has been updated and the correct result is reproduced here as well. ■





**WIDELY AVAILABLE**



## **Sustained Delivery with DuraSite<sup>®</sup> Technology**

**AKORN** | EYE CARE



MyAkornEyeCare.com  
for office resources

#### Editorial Offices

19 Campus Blvd., Suite 101  
Newtown Square, PA 19073

#### EDITOR-IN-CHIEF

**JACK PERSICO**

(610) 492-1006 • jpersico@jobson.com

#### SENIOR EDITOR

**JULIE SHANNON**

(610) 492-1005 • jshannon@jobson.com

#### ASSOCIATE EDITOR

**CATHERINE MANTHORP**

(610) 492-1043 • cmanthorp@jobson.com

#### ASSOCIATE EDITOR

**MARK DE LEON**

(610) 492-1021 • mdeleon@jobson.com

#### SPECIAL PROJECTS MANAGER

**JILL GALLAGHER**

(610) 492-1037 • jgallagher@jobson.com

#### ART DIRECTOR

**JARED ARAUJO**

(610) 492-1032 • jaraujo@jobson.com

#### DIRECTOR OF CE ADMINISTRATION

**REGINA COMBS**

(212) 274-7160 • rcombs@jobson.com

#### Clinical Editors

Chief Clinical Editor • Paul M. Karpecki, OD

#### Associate Clinical Editors

Joseph P. Shovlin, OD, Christine W. Sindt, OD

#### Clinical & Education Conference Advisor

Paul M. Karpecki, OD

Case Reports Coordinator • Andrew S. Gurwood, OD

Clinical Coding Editor • John Rumpakis, OD, MBA

#### Columnists

*Chairside* – Montgomery Vickers, OD

*Clinical Quandaries* – Paul C. Ajamian, OD

*Coding Connection* – John Rumpakis, OD

*Cornea and Contact Lens Q+A* – Joseph P. Shovlin, OD

*Diagnostic Quiz* – Andrew S. Gurwood, OD

*The Essentials* – Bisant A. Labib, OD

*Focus on Refraction* – Marc Taub, OD, Paul Harris, OD

*Glaucoma Grand Rounds* – James L. Fanelli, OD

*Ocular Surface Review* – Paul M. Karpecki, OD

*Retina Quiz* – Mark T. Dunbar, OD

*Surgical Minute* – Derek Cunningham, OD, Walter Whitley, OD

*Therapeutic Review* – Joseph W. Sowka, OD

*Through My Eyes* – Paul M. Karpecki, OD

*Urgent Care* – Richard B. Mangan, OD



Jobson Medical Information, LLC  
395 Hudson Street, 3rd Floor, New York, NY 10014

Subscription inquiries: (877) 529-1746  
Continuing Education inquiries: (800) 825-4696

Printed in USA



BY JACK PERSICO  
EDITOR-IN-CHIEF  
**OUTLOOK**

# A Case of Nerves

*ODs may hesitate to embrace neuro-ophthalmic cases, but you can be an essential player in care without shouldering it all.*

It's a white-knuckle situation for sure. A patient presents with what appears to be a swollen optic disc and complaints of nausea. Or maybe it's a case of double vision that doesn't fit the mold for strabismus. Perhaps, instead, an OCT scan suggests you have optic neuritis on your hands.

In any of these—and a dozen more—the pressure's on.

So, it's no surprise that neuro-ophthalmic diagnoses by generalists often don't go well. As reported in this month's news section, a prospective study of 496 patients sent to neuro-ophthalmologists found the referral diagnosis was incorrect 49% of the time. Misdiagnosed patients suffered harm in 26% of cases, and unfortunately these adverse effects could have been prevented by earlier referral to neuro-ophthalmology in nearly every case.

Those harms were as serious as it gets, including death due to delay in tumor diagnosis, failure to recognize TIA, progression of permanent vision loss, spontaneous CSF leak, irreversible strabismus and others of equal magnitude.

With all that in the air while a patient's in your chair, the urge to refer out immediately has to be strong. And, indeed, in many cases that's exactly what you should do. Not everyone can or should try to be a neuro-ophthalmic specialist—that seems to be underlying message of this study.

But an equally strong message is that there's a dearth of those specialists out there. "Improving access to neuro-ophthalmologists has the potential to prevent patient harm, which is made challenging by the current shortage of neuro-ophthalmologists," the

researchers wrote in their paper on the study. "Improving incentives to attract trainees to subspecialize in neuro-ophthalmology will allow expanded access to patients who need care for these complex conditions."

That's not your problem—leave it for ophthalmology teaching institutions to sort out. What you can do, though, is hone your skills in triaging these cases to make sure they get a timely and accurate referral. The assessment stage, patient counseling and write-up of referral notes all seem like fertile ground for improvement of clinical and communication skills.


In the above-mentioned study, the most common sources of error involved deficiencies in the physical exam (36%), generation of a complete differential diagnosis (24%), history taking (24%) and use or interpretation of diagnostic testing (13%). That's all bread-and-butter optometry at this point.

You may have noticed that we're in the middle of a six-part series on comanagement (see this month's article about cornea care on page 80). The connective tissue among the whole series is optometric leadership in screening patients and directing the effort.

As luck would have it, next month's topic is neuro-ophthalmic care. I encourage you to make time for that one, and even to send us any thoughts on what could help you do a better job in neuro care out there in the trenches. We'll work it into our coverage for later this year and beyond. Kindly drop me a line at [editor@reviewofoptometry.com](mailto:editor@reviewofoptometry.com) with any anecdotes, frustrations or longstanding problems you experience when conducting neuro workups. As the kids say, my DMs are open. ■

INTRODUCING  
ACUVUE® OASYS  
**MULTIFOCAL**  
WITH PUPIL OPTIMIZED DESIGN

**NEW**



## Designed for Superior Performance<sup>†</sup>



### CRISP, CLEAR VISION

**Pupil Optimized Design:** 100% of parameters tailored to pupil size variations across age and refraction vs <2% for the leading competitor<sup>†</sup>



### PRECISE FIT

**Hybrid Back Curve** includes an aspheric center to help keep the optics **in the right shape**, and a spherical periphery to help keep optics **in the right place**<sup>2</sup>



### NEVER BEATEN IN COMFORT

The ACUVUE® OASYS 2-week Brand Family has **never been beaten in comfort in 25 clinical studies**<sup>\*\*</sup>

Same design, parameters and simple fit process as  
**1-DAY ACUVUE® MOIST Brand Multifocal Contact Lenses.**  
**Talk to your sales representative today.**

take COMFORT in  
**ACUVUE®**

<sup>†</sup>Compared to prior JJV multifocal design; technology optimized for both the parameters of refractive error and add power for a multitude of viewing distances and light levels.

<sup>\*</sup>Compared to leading competitors' designs; technology optimized for both the parameters of refractive error and ADD power.

<sup>\*\*</sup>[www.clinicaltrials.gov](http://www.clinicaltrials.gov) is a website maintained by the NIH. The 25 clinical studies evaluated subjective comfort as a primary or secondary endpoint for ACUVUE® OASYS Brand 2-weekly and ACUVUE® OASYS with Transitions™ Light Intelligent Technology™. Review conducted as of November 12, 2020.

**References: 1.** JJV Data on File 2020. ACUVUE® PUPIL OPTIMIZED DESIGN TECHNOLOGY: JVC Contact Lenses, Design Features, and Associated Benefits. **2.** JJV Data on File 2014. 1-DAY ACUVUE® MOIST MULTIFOCAL Designed for the Aging Eye.

**Important Safety Information:** ACUVUE® Contact Lenses are indicated for vision correction. As with any contact lens, eye problems, including corneal ulcers, can develop. Some wearers may experience mild irritation, itching or discomfort. Lenses should not be prescribed if patients have any eye infection, or experience eye discomfort, excessive tearing, vision changes, redness or other eye problems. Consult the package insert for complete information. Complete information is also available from Johnson & Johnson Vision Care, Inc. by calling 1-800-843-2020, or by visiting [JNVISIONPRO.com](http://JNVISIONPRO.com).

© Johnson & Johnson Vision Care, Inc. 2021 | PP2021AVO4115v2 | MB-00545





BY PAUL M. KARPECKI, OD  
CHIEF CLINICAL EDITOR

## THROUGH MY EYES

# New Options, Front to Back

Take a look at promising treatments for the cornea and retina, ready now or on the horizon.

This month's issue showcases recent strides in cornea care, a somewhat sleepy category that doesn't always get the attention it deserves. Among the other topics covered in this issue, dry AMD stands out as another perhaps overlooked area where optometrists can really shine if we put our minds to it.

## Cornea-copia

Keratoconus is such a difficult condition because of its progressive nature, effects on vision and higher failure rates after transplants. Having new, more patient-friendly treatment options is greatly needed.

Imagine being able to treat keratoconus topically or crosslink the eye with just a scleral lens. Both concepts are in clinical trials. The first, a drug called IVMed-80 (iVeena), showed in its Phase II data a 1.8D mean reduction in K readings compared to placebo, an 11.3 letter improvement in BCVA over baseline and no treatment-related adverse events. The second concept, a scleral lens known as CXLens (TecLen), includes a built-in transducer that allows energy emission to crosslink the cornea. Riboflavin would be placed in the bowl of the lens and procedure would be completed in the optometrist's office.

Although a very sound and comprehensive clinical study known as SCUT showed that using topical steroids in bacterial keratitis did not show greater vision loss, and actually improved outcomes in more severe cases, there are safeguards to keep in mind. First, be

sure the patient has bacterial keratitis—avoid if there is a chance it could be fungal or HSV. Second, steroids are not recommended within 48 hours (preferably 72) if the infection may be caused by *Pseudomonas* (e.g., in contact lens wearers). Next, confirm the antibiotic you are using is working by clinical improvement, re-epithelialization or culture results that confirm the pathogen is susceptible to the antibiotic.

“Optometrists see 85% of all comprehensive eye exams in the US, and patients frequently ask us what options exist for dry AMD.”

Limbal stem cell deficiency (LSCD), although rare, can be somewhat easy to overlook. Damage to the limbal stem cells or to their microenvironment leads to LSCD. As a result, the corneal epithelium is replaced with conjunctival epithelial cells. A good history that identifies a previous trauma—such as a chemical burn, contact lens overwear, Stevens-Johnson Syndrome or aniridia—will help in the diagnosis.

Presentations vary but LSCD typically manifests superiorly with corneal staining and sometimes haze, epithelial irregularity, poor healing and recurrent erosion. Treatments range from biologics like amniotic membrane (Prokera, BioTissue; Apollo, Atlas Ocular) and autologous serum (Vital Tears) to cytokine extract drops (Regener-Eyes),

lubricants and inflammation control. Scleral lenses can be effective. In severe cases, a limbal stem cell transplant can deliver unbelievable results.

## Owning AMD

Shifting gears from cornea, I can't state enough how much I feel optometry needs to be the primary provider of dry AMD management. Optometrists see 85% of all comprehensive eye exams in the United States, and patients frequently ask us what options exist for this devastating condition. Five potential treatments are going through FDA trials for geographic atrophy, but much can also be done now.

Early detection can help a patient begin carotenoid supplementation. The most illuminating diagnostic for early AMD, with over 90% sensitivity and specificity, is dark adaptometry, which can now be performed with a device that resembles a virtual reality headset (AdaptDx Pro, Maculogix) and doesn't require a separate room. If the patient has progressed to intermediate stage AMD (i.e., a least one large drusen), AREDS2 formulations are proven to slow progression.

To monitor the disease, at-home testing (Notal Vision) can help encourage patient buy-in due to its convenience. Don't forget to recommend high quality sunglasses, as well as a healthy diet and avoidance of smoking. Dry AMD treatments involving the complement system could be on their way, but now is the time to be active in management, as this condition is more common than glaucoma and DR combined.

It's an exciting time to be in practice with so many new tools in the development pipeline, but waiting for FDA approvals before you begin managing these conditions will leave you behind, as there are many treatment and management options available today. ■

About  
Dr. Karpecki

Dr. Karpecki is medical director for Keplr Vision and the Dry Eye Institutes of Kentucky and Indiana. He is the Chief Clinical Editor for *Review of Optometry* and chair of the New Technologies & Treatments conferences. A fixture in optometric clinical education, he consults for a wide array of ophthalmic clients, including ones discussed in this article. Dr. Karpecki's full disclosure list can be found in the online version of this article at [www.reviewofoptometry.com](http://www.reviewofoptometry.com).

# Adapt. Evolve. Grow.



As you **adapt** to the changes our industry is facing, you'll find there is also opportunity.

Discover how dark adaptation testing with AdaptDx Pro® guided by Theia™ can help you **evolve** your approach to AMD care. Become an AMD Center of Excellence® and unlock your potential to **grow** your practice revenue.

**AdaptDx®**  
**PRO**  
Guided by Theia™

**Special Subscription Offer:**  
\$99/month for 1st six months  
Learn more at [maculogix.com/6months](https://maculogix.com/6months)



# Let's Take a Gander at Gaps

*We all have them in our schedules—worse now than ever. Don't deny it.*

**D**on't lie. Each of you also has COVID-related gaps in your schedule. It's inevitable. And if you claim you don't, then just whom exactly did you pre-appoint during the shut down when the pandemic blew up?

No appointments for the larger part of 2020 must have impacted your ability to pre-appoint. And if you didn't pre-appoint to begin with, I will never understand why. I can think of a few reasons though:

- It doesn't work.
- It results in no-shows.
- Patients don't know what their schedule will be a whole year from now.
- I myself don't know what my schedule will be a whole year from now.
- There may be a pandemic.

That last one hits a little too close to home, I guess.

But if any of those reasons rings a bell, I guess you are actually used to gaps in your schedule, unless you work for the prison system or VA. Both have similar scheduling software, or so it seems.

I myself never had gaps in my appointment book when, as a student at the Pennsylvania College of Optometry, I volunteered to work in the eye clinic at Holmesburg Prison in Philadelphia. All the inmates were so bored that when the "screws" (prison lingo, you wouldn't understand) asked

on "the block" (again, don't try to understand) if anyone had an eye problem, guess what? They all said they did, even if they had to scratch their eye with their fingernail on purpose. Hope you're feeling better, Bob.

They'd come in wearing their "Jailhouse Schoolboys," which were glasses they made in metal shop with windowpanes as lenses. Not good during riots—don't ask me how I know that. I still regret not buying a pair for posterity, but \$20 was a lot of money to a starving student in 1977. Still is.

Anyway, gaps exist. So, the question: what should you do about them? The answer: something that will fill them as quickly as possible. I want to present some good ideas and some bad ones. Hope these help:

1. Ask any patient who schedules an appointment if they would like to go ahead and get their kids in since they missed their annual exam last year. Good idea.
2. Ask any patient who schedules an appointment if they would be willing to buy a bunch of stuff when they come in to your office. Bad idea.

3. Make sure your office hours are convenient for your patients (especially for homebound workers). Offer some appointments early in the morning, at lunchtime and in the evening. Maybe even consider the weekend. Yuck! Good idea, even the last part.

4. Make sure you are open 24/7 just in case a patient happens to wander in. Bad idea.

5. Have an open bar. My task force is still debating the goodness or badness of this idea. Stay tuned; we'll get back to you.

6. Office drive-through? Good idea.

7. Petting zoo? Bad idea.

8. Free contact lens delivery? Good idea.

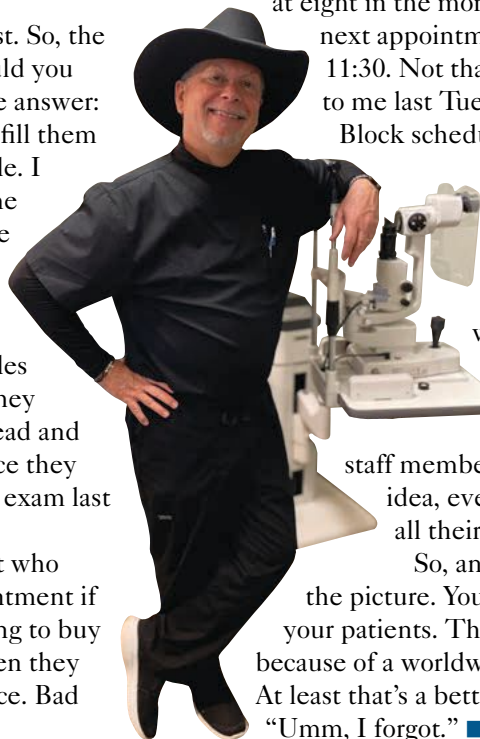
9. Free pizza delivery? Bad idea.

10. Block scheduling? Great idea. (I feel the need to remind you, and by "you" I mean my staff members, that no doctor in his or her right mind wants to see an appointment at eight in the morning when the next appointment isn't until 11:30. Not that this happened to me last Tuesday or anything.

Block scheduling means all appointments must be physically touching one another, with respect of course, on the schedule.)

11. Blaming staff members for stuff? Bad idea, even if it's literally all their fault. Just sayin'.

So, anyway, you get the picture. You have to get after your patients. They are past due because of a worldwide pandemic. At least that's a better excuse than, "Umm, I forgot." ■



About  
**Dr. Vickers**

**Dr. Vickers** received his optometry degree from the Pennsylvania College of Optometry in 1979 and was clinical director at Vision Associates in St. Albans, WV, for 36 years. He is now in private practice in Dallas, where he continues to practice full-scope optometry. He has no financial interests to disclose.



# New Parameters, New Possibilities.

Raising the bar once again. The most prescribed<sup>1</sup>  
and complete toric portfolio is growing<sup>2</sup>.




**Biofinity® XR toric**

**COMING SOON**



Sphere powers expanding to  $\pm 20.00D$ , bringing the total number of unique prescription options to nearly 33,000.



**MyDay® toric**

**COMING JULY 2021**



Adding around-the-clock axes and 0.25D steps in plus powers, covering 95% of Biofinity® toric prescriptions.

1. CooperVision data on file, 2017–2019. Based on number of US soft contact lens fits. Includes CooperVision branded and customer-branded equivalent lenses. US industry reports and internal estimates. 2. CVI data on file 2020. Kubic masked online survey; n=404 US ODs who prescribe toric soft CLs. 77% CVI, 31% Alcon, 40% B+L, 41% J&J; p<0.05). ©2021 CooperVision 10654 03/21





EDITED BY PAUL C. AJAMIAN, OD

## CLINICAL QUANDARIES

# Pass the Salt

*Guide patients through the initial healing window of RCE and future episodes may be minimized.*

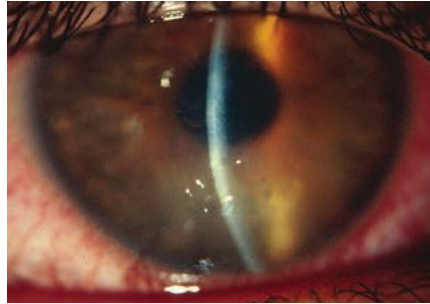
**Q** I recently saw a 38-year-old woman with a long history of recurrent corneal erosion (RCE) well-controlled with Muro 128 drops (sodium chloride 5%, Bausch + Lomb). A month ago, she began experiencing excruciating pain again. What's going on?

**A** “Severe eye pain upon waking is a symptom with a relatively small differential, and first on that list is RCE,” says Aaron Bronner, OD, of Pacific Cataract and Laser Institute. It’s thought that RCE is caused by irregularities in the extracellular architecture that keeps normal epithelial cells firmly adherent to their neighboring cells. Aberrant and absent anchoring junctions make the corneal epithelium more prone to sloughing. This results in both macroform RCE—large erosions that typically require medical management—and the smaller and self-limiting microform RCE.

### Vicious Cycle

Though shearing forces to the epithelium occur with each blink, epithelial sloughing with RCE is most common at night. This is likely due to a combination of subtle epithelial edema from lid closure during sleep and decreased tear turnover at night. Then, during REM sleep or upon waking, the epithelium is eroded and the patient experiences marked pain, photophobia and lacrimation.

“This process creates a vicious cycle where the epithelium heals within hours or days, but anchoring filament reorganization takes as long as a few months,” Dr. Bronner says. “This re-



**RCE may recur after the epithelium has healed.**

sults in periods where the patient may feel normal, but the epithelium can slough again without warning, and the process begins again.” In cases caused by scars or dystrophies, the anchoring filaments may never fully recover without surgical intervention.

If the patient goes through a window of two to three months without recurrence, they may never have another episode. But for those who recur or whose case arises from a traumatic or dystrophic source, the potential for recurrence persists for years.<sup>1</sup>

### Management Options

To heal the acute epithelial defect, consider debridement and either a bandage soft contact lens (BSCL) or an amniotic membrane (AM). “Pair either of these with topical antibiotics while the epithelial defect is present,” Dr. Bronner says. Once the defect heals, he recommends continuing BSCL use for as long as three months.

Given its role in promoting corneal wound healing and its anti-inflammatory effects, an AM may be even more effective in the acute stage

of the disease than a BSCL.<sup>2</sup> However, it would probably need to be replaced with a bandage lens following initial AM removal when the epithelium has healed to support anchoring junction development.

Our patient had stopped the Muro 128 a month prior because she no longer found it available. A few weeks later, she began experiencing the same pain that first brought her in. “Eventually many patients will, whether directed to or not, discontinue the ‘salt water,’” Dr. Bronner warns. “Some of these patients may never have another episode, but in cases like our patient, RCE recurs shortly after cessation.” While she was in the office, we confirmed that both the Muro drops and ointment were available online. She restarted therapy and has since experienced total relief.

For those patients wishing to come off conservative therapy, anterior stromal micropuncture (ASP), debridement with diamond burr polishing (DBP) and phototherapeutic keratectomy (PTK) may be considered in select cases. “My personal experience is that ASP and DBP have higher rates of recurrence following their use,” Dr. Bronner says. “So, I currently recommend PTK for cases not curable with conservative management.”

As with all problems, there is no one RCE treatment that’s right for everyone. For those considering surgical intervention, the risks of pain, infection, poor wound healing and corneal scarring will have to be balanced with how they perceive conservative therapy’s effectiveness or inconvenience. ■

1. Das S, Seitz B. Recurrent corneal erosion syndrome. *Surv Ophthalmol.* 2008;53(1):3-15.

2. Dua H, Gomes JAP, King AJ, Maharajan VS. The Amniotic membrane in ophthalmology. *Surv Ophthalmol.* 2004; 49(1):51-77.

About  
Dr. Ajamian

**Dr. Ajamian** is the center director of Omni Eye Services of Atlanta. He currently serves as general chairman of the education committee for SECO International. He has no financial interests to disclose.

# UPLIFTED

Give Ptosis Patients an EYE-OPENING Lift With a Daily Drop of Upneeq® (oxymetazoline hydrochloride ophthalmic solution), 0.1%<sup>1</sup>

The only FDA-approved prescription eyedrop proven to lift upper eyelids in adults with acquired blepharoptosis (low-lying lids)<sup>1</sup>

**Learn more at [Upneeq.com](http://Upneeq.com).**

## INDICATION

Upneeq® (oxymetazoline hydrochloride ophthalmic solution), 0.1% is indicated for the treatment of acquired blepharoptosis in adults.

## IMPORTANT SAFETY INFORMATION

### WARNINGS AND PRECAUTIONS

- Alpha-adrenergic agonists as a class may impact blood pressure. Advise Upneeq patients with cardiovascular disease, orthostatic hypotension, and/or uncontrolled hypertension or hypotension to seek medical care if their condition worsens.
- Use Upneeq with caution in patients with cerebral or coronary insufficiency or Sjögren's syndrome. Advise patients to seek medical care if signs and symptoms of potentiation of vascular insufficiency develop.
- Upneeq may increase the risk of angle closure glaucoma in patients with untreated narrow-angle glaucoma. Advise patients to seek immediate medical care if signs and symptoms of acute narrow-angle glaucoma develop.
- Patients should not touch the tip of the single patient-use container to their eye or to any surface, in order to avoid eye injury or contamination of the solution.

## ADVERSE REACTIONS

Adverse reactions that occurred in 1-5% of subjects treated with Upneeq were punctate keratitis, conjunctival hyperemia, dry eye, blurred vision, instillation site pain, eye irritation, and headache.

## DRUG INTERACTIONS

- Alpha-adrenergic agonists, as a class, may impact blood pressure. Caution in using drugs such as beta blockers, anti-hypertensives, and/or cardiac glycosides is advised. Caution should also be exercised in patients receiving alpha adrenergic receptor antagonists such as in the treatment of cardiovascular disease, or benign prostatic hypertrophy.
- Caution is advised in patients taking monoamine oxidase inhibitors which can affect the metabolism and uptake of circulating amines.

**To report SUSPECTED ADVERSE REACTIONS or product complaints, contact RVL Pharmaceuticals at 1-877-482-3788. You may also report SUSPECTED ADVERSE REACTIONS to the FDA at 1-800-FDA-1088 or [www.fda.gov/medwatch](http://www.fda.gov/medwatch).**

**Please see next page for Brief Summary of full Prescribing Information.**

**Reference: 1.** Upneeq® (oxymetazoline hydrochloride ophthalmic solution), 0.1%. [Prescribing Information].

**RVL**  
PHARMACEUTICALS, INC.

Distributed by: RVL Pharmaceuticals, Inc.  
Bridgewater, NJ 08807  
Customer Service 1-866-600-4799  
Upneeq is a registered trademark of RVL Pharmaceuticals, Inc.  
©2021 RVL Pharmaceuticals, Inc.  
PM-US-UPN-0197 01/21

Learn more at [Upneeq.com](http://Upneeq.com)



**UPNEEQ®**  
(oxymetazoline hydrochloride  
ophthalmic solution), 0.1%\*

\*Each mL of Upneeq contains 1 mg of oxymetazoline hydrochloride, equivalent to 0.09 mg (0.09%) of oxymetazoline free base.

*Eye-Opening Possibilities*



**UPNEEQ® (oxymetazoline hydrochloride ophthalmic solution), 0.1%, for topical ophthalmic use**

\*Each mL of UPNEEQ contains 1 mg of oxymetazoline hydrochloride, equivalent to 0.09 mg (0.09%) of oxymetazoline free base.

**BRIEF SUMMARY: The following is a brief summary only; see full Prescribing Information at <https://www.upneeq.com/Upneeq-PI.pdf> for complete information.**

## 1 INDICATIONS AND USAGE

UPNEEQ is indicated for the treatment of acquired blepharoptosis in adults.

## 2 DOSAGE AND ADMINISTRATION

Contact lenses should be removed prior to instillation of UPNEEQ and may be reinserted 15 minutes following its administration.

If more than one topical ophthalmic drug is being used, the drugs should be administered at least 15 minutes between applications.

## 4 CONTRAINDICATIONS

None.

## 5 WARNINGS AND PRECAUTIONS

### 5.1 Potential Impacts on Cardiovascular Disease

Alpha-adrenergic agonists may impact blood pressure. UPNEEQ should be used with caution in patients with severe or unstable cardiovascular disease, orthostatic hypotension, and uncontrolled hypertension or hypotension. Advise patients with cardiovascular disease, orthostatic hypotension, and/or uncontrolled hypertension/hypotension to seek immediate medical care if their condition worsens.

### 5.2 Potentiation of Vascular Insufficiency

UPNEEQ should be used with caution in patients with cerebral or coronary insufficiency, or Sjögren's syndrome. Advise patients to seek immediate medical care if signs and symptoms of potentiation of vascular insufficiency develop.

### 5.3 Risk of Angle Closure Glaucoma

UPNEEQ may increase the risk of angle closure glaucoma in patients with untreated narrow-angle glaucoma. Advise patients to seek immediate medical care if signs and symptoms of acute angle closure glaucoma develop.

### 5.4 Risk of Contamination

Patients should not touch the tip of the single patient-use container to their eye or to any surface, in order to avoid eye injury or contamination of the solution.

## 6 ADVERSE REACTIONS

### 6.1 Clinical Trials Experience

Because clinical trials are conducted under widely varying conditions, adverse reaction rates observed in the clinical trials of a drug cannot be directly compared to rates in the clinical trials of another drug and may not reflect the rates observed in practice.

A total of 360 subjects with acquired blepharoptosis were treated with UPNEEQ once daily in each eye for at least 6 weeks in three controlled Phase 3 clinical trials, including 203 subjects treated with UPNEEQ for 6 weeks and 157 subjects treated with UPNEEQ for 12 weeks. Adverse reactions that occurred in 1-5% of subjects treated with UPNEEQ were punctate keratitis, conjunctival hyperemia, dry eye, blurred vision, instillation site pain, eye irritation, and headache.

## 7 DRUG INTERACTIONS

### 7.1 Anti-hypertensives/Cardiac Glycosides

Alpha-adrenergic agonists, as a class, may impact blood pressure. Caution in using drugs such as beta-blockers, anti-hypertensives, and/or cardiac glycosides is advised.

Caution should also be exercised in patients receiving alpha adrenergic receptor antagonists such as in the treatment of cardiovascular disease, or benign prostatic hypertrophy.

### 7.2 Monoamine Oxidase Inhibitors

Caution is advised in patients taking MAO inhibitors which can affect the metabolism and uptake of circulating amines.

## 8 USE IN SPECIFIC POPULATIONS

### 8.1 Pregnancy

#### Risk Summary

There are no available data on UPNEEQ use in pregnant women to inform a drug-associated risk for major birth defects and miscarriage. In animal reproduction studies, there were no adverse developmental effects observed after oral administration of oxymetazoline hydrochloride in pregnant rats and rabbits at systemic exposures up to 7 and 278 times the maximum recommended human ophthalmic dose (MRHOD), respectively, based on dose comparison. [see Data]. The estimated background risks of major birth defects and miscarriage for the indicated population are unknown. All pregnancies have a background risk of birth defect, loss, or other adverse outcomes. In the U.S. general population, the estimated background risk of major birth defects and miscarriage in clinically recognized pregnancies is 2-4% and 15-20%, respectively.

#### Data

##### Animal Data

Effects on embryo-fetal development were evaluated in rats and rabbits following oral administration of oxymetazoline hydrochloride during the period of organogenesis. Oxymetazoline hydrochloride did not cause adverse effects to the fetus at oral doses up to 0.2 mg/kg/day in pregnant rats during the period of organogenesis (28 times the MRHOD, on a dose comparison basis). Oxymetazoline hydrochloride did not cause adverse effects to the fetus at oral doses up to 1 mg/kg/day in pregnant rabbits during the period of organogenesis (278 times the MRHOD, on a dose comparison basis). Maternal toxicity, including decreased maternal body weight, was produced at the high dose of 1 mg/kg/day in pregnant rabbits and was associated with findings of delayed skeletal ossification.

In a rat prenatal and postnatal development study, oxymetazoline hydrochloride was orally administered to pregnant rats once daily from gestation day 6 through lactation day 20. Maternal toxicity was produced at the high dose of 0.2 mg/kg/day (28 times the MRHOD, on a dose comparison basis) in pregnant rats and was associated with an increase in pup mortality and reduced pup body weights. Delayed sexual maturation was noted at 0.1 mg/kg/day (14 times the MRHOD, on a dose comparison basis). Oxymetazoline hydrochloride did not have any adverse effects on fetal development at a dose of 0.05 mg/kg/day (7 times the MRHOD, on a dose comparison basis).

### 8.2 Lactation

#### Risk Summary

No clinical data are available to assess the effects of oxymetazoline on the quantity or rate of breast milk production, or to establish the level of oxymetazoline present in human breast milk post-dose. Oxymetazoline was detected in the milk of lactating rats. The developmental and health benefits of breastfeeding should be considered along with the mother's clinical need for UPNEEQ and any potential adverse effects on the breastfed child from UPNEEQ.

### 8.4 Pediatric Use

Safety and effectiveness of UPNEEQ have not been established in pediatric patients under 13 years of age.

### 8.5 Geriatric Use

Three hundred and fifteen subjects aged 65 years and older received treatment with UPNEEQ (n = 216) or vehicle (n = 99) in clinical trials. No overall differences in safety or effectiveness were observed between subjects 65 years of age and older and younger subjects.

## 10 OVERDOSAGE

Accidental oral ingestion of topical intended solutions (including ophthalmic solutions and nasal sprays) containing imidazoline derivatives (e.g., oxymetazoline) in children has resulted in serious adverse events requiring hospitalization, including nausea, vomiting, lethargy, tachycardia, decreased respiration, bradycardia, hypotension, hypertension, sedation, somnolence, mydriasis, stupor, hypothermia, drooling, and coma. Keep UPNEEQ out of reach of children.

## PATIENT COUNSELING INFORMATION

Advise the patient to read the FDA-approved patient labeling (Instructions for Use).

**RVL**  
PHARMACEUTICALS, INC.

Manufactured for: RVL Pharmaceuticals, Inc.  
Bridgewater, New Jersey 08807  
©2021 RVL Pharmaceuticals, Inc.  
UPNEEQ is a registered trademark of RVL Pharmaceuticals, Inc.  
PM-US-UPN-0203 01/21



EDITED BY MARC B. TAUB, OD, MS, AND PAUL HARRIS, OD

## FOCUS ON REFRACTION

# Make Way For Yoked Prism

*This option has improved the lives of many patients; two are highlighted here.*

BY MARC B. TAUB, OD, MS, PAUL HARRIS, OD,  
AND ALICIA GROCE, OD  
MEMPHIS

Over the past five years, this column has covered many topics related to lenses and prisms, but it has not yet discussed yoked prisms in detail. As we all learned in optometry school, a prism shifts light, and the person shifts their eye in response. Specifically, yoked prisms shift images the same direction and amount in both eyes.

If you stick with the basic understanding of prisms as chiefly ray shifters (1.00cm for every 1.00m traveled per 1.00D of prism), you will miss their true power. Besides their ability to shift light and eyes, yoked prisms initiate spatial shifts, or shifts in a person's center of gravity, causing an observed postural change, which triggers a shift and/or rotation in the pelvis.<sup>1</sup> These changes have the potential to alter behavior and attention.

In the field of neuro-optometric rehabilitation, we use horizontal yoked prisms in the treatment of cases of homonymous hemianopsia, midline shift, neglect and sometimes unilateral spatial inattention. In patients with nystagmus who have a null point that requires a head turn, yoked prisms sometimes allow for

the patient to maintain a straighter head position, alleviating future spinal issues.

Vertically oriented yoked prisms are used most often to improve behavior and attention. While the exact mechanisms are not fully understood, we know these prisms transform space beyond the shifts in the chief ray in the direction of the apex of the prism. Other spatial transformations are complex but understood.<sup>1</sup> We find that patients on the autism spectrum, as well as those with attention difficulties, often respond positively to vertical yoked prisms.

The goal with prism is to improve and enhance looking behavior and to extend how long a patient is able to pay attention. This column focuses on the use of vertically oriented yoked prisms and includes two stories of success.



**This patient is wearing base-up yoked prism.**

### Case One

A six-year-old girl had an eye exam several weeks prior, but her father was concerned that she was still moving her body instead of her eyes while writing. The patient's medical history included ADHD and autism. She uses both Focalin (dexamethylphenidate, Novartis) and guanfacine. She was born on time and has been meeting all developmental milestones but is mildly delayed. She is not currently reading and receives speech and occupational therapy several times per week. Her father described her as "very clumsy" and said she bumps into things a lot at home.

The patient was able to see 20/15 OD, OS and OU, had 20 seconds of stereo and was orthophoric at distance and near. Retinoscopy was +0.50 -0.50x090 OU. The monocular estimated method response through plano was +0.50 with fluctuations. Through +0.50, the response was plano with fewer fluctuations. A test of gross eye movement demonstrated significant issues on both pursuits and saccades, showing significant

body overflow and head movement. When we were able to get her to sit down, the patient was fidgety in the chair, and she was jumpy otherwise.

We decided to trial 2.00D of base-up yoked prism. Interacting with the hanging Marsden ball, the patient's attention was more focused with the yoked prism and she was better able to catch the ball. Her father commented that he had never seen his daughter so focused

#### About Drs. Taub and Harris

Dr. Taub is a professor, chief of the Vision Therapy and Rehabilitation service and co-supervisor of the Vision Therapy and Pediatrics residency at Southern College of Optometry (SCO) in Memphis. He specializes in vision therapy, pediatrics and brain injury. Dr. Harris is also a professor at SCO. Previously, he was in private practice in Baltimore for 30 years. His interests are in behavioral vision care, vision therapy, pediatrics, brain injury and electrodiagnostics. They have no financial interests to disclose.

and with such good hand-eye coordination.

We prescribed +0.25D of sphere with the 2.00D of base-up yoked prism OU and initiated a course of vision therapy focusing on eye and body movements. The patient is currently on her 10th session and progressing wonderfully.

### Case Two

A minimally verbal four-year-old boy with autism was referred by his occupational therapist for a visual evaluation due to difficulty with visual attention to tabletop tasks and moving targets, as well as visual motor integration concerns. He receives occupational therapy services for sensory processing, visual motor integration, fine motor skills, bilateral integration, gross motor skills and difficulty with daily activities. He also receives speech therapy.

The patient had a limited attention span, so only the basic examination components and some modified visual perceptual tests were performed. He was able to see 20/20 OU at distance and 20/25- OU at near with Lea symbols. He did not like either eye being covered, so monocular acuities were not evaluated. His eye movements showed no restrictions but were jerky in nature and consisted of small microsaccades instead of a smooth saccade or pursuit movement.

His visual attention to our target was very limited (about one to two seconds at a time). His cover test revealed orthophoria at distance and near, and his near point of convergence was to the nose on two attempts; after that, he lost interest and attention. His distance retinoscopy was plano OD and OS, and his just-look retinoscopy showed bright, equal reflexes with a near retinoscopy finding of +0.50D of sphere OD



The patient, while wearing base-up yoked prisms, catches a ball during a visual performance assessment.

and OS for the brightest, most stable reflex.

We chose to trial a higher amount of prism than usual to see if there was a positive response, since the patient's visual attention was so fleeting. He wore 5.00D of base-up yoked prism and then 5.00D of base-down yoked prism while walking and interacting with the Marsden ball and other various objects around him. He walked in a straighter line and was more attentive to his surroundings with the base-up yoked prism; however, his attention was still limited. With the base-down yoked prism, he had an immediate negative response, was very anxious and ripped the glasses off.

At the following visit, we attempted testing again but did not get the response we had hoped for. During basic perceptual testing, the patient looked at each object for one to two seconds before looking away and then had to be redirected to where the object was on the table several times before he would visually attend.

We trialed a lower amount of prism this time (2.00D OU), and the response was instantaneous. The patient's attention improved and he completed tasks that were previously challenging. We prescribed +0.25D

of sphere with the 2.00D of base-up yoked prism OU.

The patient was re-evaluated two months later. His mom noted that he had been wearing his glasses at school, during occupational therapy and occasionally on the weekends at home when doing near tasks. He was able to perform several perceptual tests that he previously could not complete. Since he was already involved in so many other therapies, we decided to hold off

on vision therapy. We monitor his progress every three to six months.

### Takeaways

In patients with ADHD or autism who may benefit from yoked prism, we often try smaller amounts (1.00D to 5.00D) of base-up and base-down yoked prism per eye. The goal is to provide the smallest amount of yoked prism to create a positive change in awareness and a subsequent response. Higher amounts can also be trialed, but the goal remains the same. Typically, 1.00D to 3.00D of prism per eye is prescribed.

While seeing these patients can be challenging, you have the skill and knowledge to succeed. Not only can you improve the clarity of sight, but you can also enhance vision and encourage development of the visual process through the use of vertically oriented yoked prism. ■

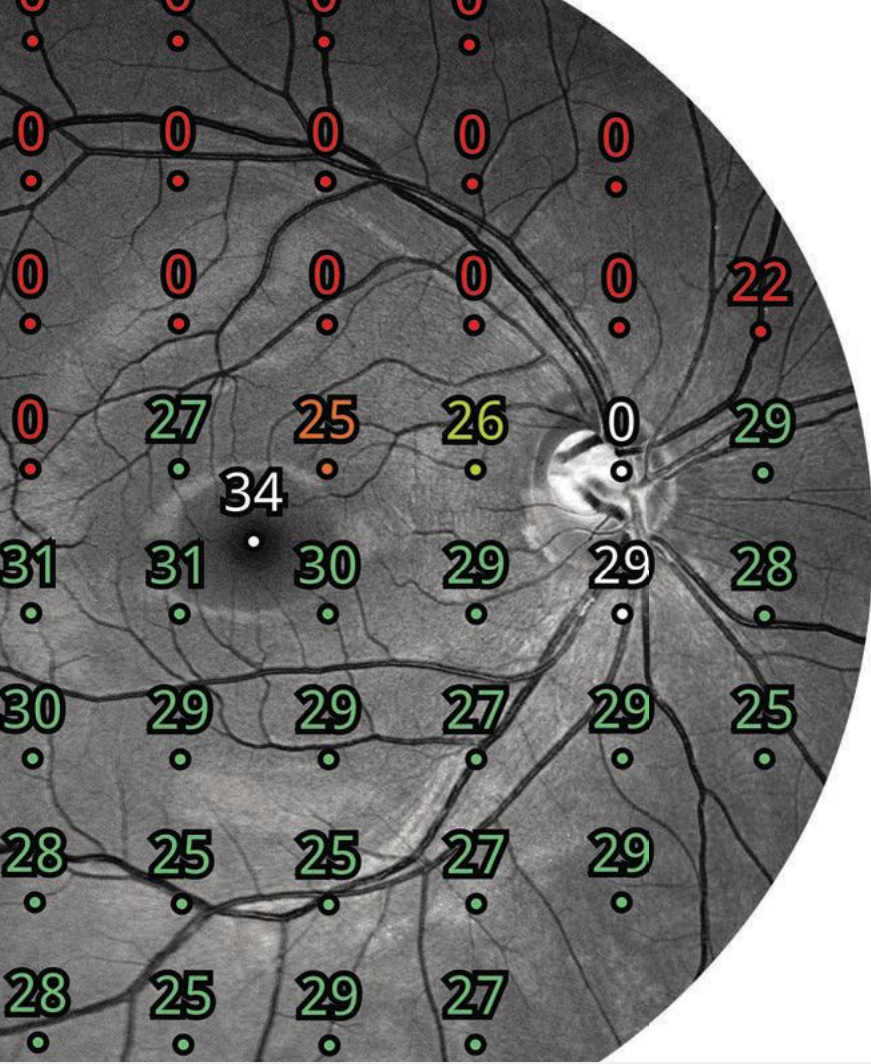
1. Harris J. The use of lenses to improve quality of life following brain injury. In: Suter PS, Harvey LH, eds. Vision Rehabilitation: Multidisciplinary Care of the Patient Following Brain Injury. Oxfordshire, England: Routledge; 2011.

### ABOUT THE AUTHOR



Dr. Groce is an assistant professor and the residency supervisor for the Vision Rehabilitation and Brain Injury Residency at SCO. She also sees patients in the Eye Center's pediatrics, teen and vision therapy clinics. She has no financial interests to disclose.

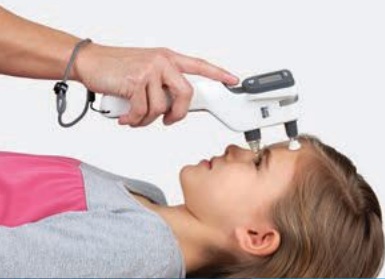
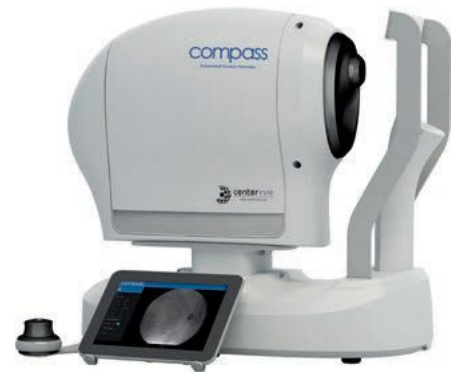


## iCare COMPASS

### Fundus automated perimetry

- + Real-time retinal tracking
- + Imaging & Perimetry in one device
- + TrueColor confocal retinal imaging
- + No trial lens required
- + Significantly less variable than Standard Perimetry



## iCare IC200

### 200 degrees of tonometry

- + Supine, elevated & seated operation
- + No corneal disruptions
- + Suitable for every patient
- + Single use probes to exceed infection control guidelines

Keeping the world  
visible for all.  
Together.



**Trade-in  
available**  
for any  
Visual Field!



For more information, scan,  
call 888.422.7313, or email  
infoUSA@icare-world.com  
[www.icare-world.com/USA](http://www.icare-world.com/USA)

For better perception **icare**



BY JOHN RUMPAKIS, OD, MBA  
CLINICAL CODING EDITOR

## CODING CONNECTION

# Biological Alternative

*Amniotic membranes could be the best corneal treatment option in a number of cases.*

In today's clinical conversations, we can't talk about treating the cornea without discussing amniotic membranes as a clinical option. While the code for amniotic membranes for ocular use has gone through a few iterations as far as definition is concerned, it currently is defined as:

- 65778: Placement of amniotic membrane on the ocular surface; without sutures.

It is considered a surgical code and application, even though the definition indicates "without sutures." This category follows a different set of rules when creating the medical record and coding for application and follow-up visits.

There are additional considerations to keep in mind. All amniotic membranes may not be created equally, as the CMS has noted in a recent Local Coverage Determination (LCD):

"Amnion can be prepared for implantation a number of ways. Heat- or air-dried amniotic membrane loses some of its biologic properties and is not ideal for ocular surface rehabilitation."

However, "the cryopreservation method allows for greater retention of the membrane's structural, physiological and biochemical properties responsible for its dramatic healing and easier handling intraoperatively."

## Covered Indications

Amniotic membrane transplant for ocular conditions is considered medically reasonable and necessary for the following indications (the full list can

be found in the online version):

- Failure of standard therapy for severe ophthalmological conditions demonstrated by ocular surface cell damage or failure and/or underlying inflammation, scarring or ulceration of the underlying stroma.

“ This category follows a different set of rules when creating the medical record and coding for application and follow-up visits. ”

- Circumstances where there is a severe condition requiring acute treatment with amniotic membrane such as chemical, thermal or radiation injuries, or Stevens-Johnson syndrome or limbal stem cell failure.

- Band keratopathy after treatment with other therapy such as surgery, topical medications, bandage contact lens or patching.

- Bullous keratopathy associated with an epithelial defect.

- Scleral melting.

- Corneal ulcer following initiation of anti-infective therapy and demonstration of clinical response for the purpose of healing the persistent epithelial defect.

While I realize that using an amniotic membrane for dry eye is a commonplace occurrence, many carriers will not cover dry eye as a diagnosis, but will cover the corneal sequelae caused by moderate to severe dry eye.

## Other Considerations

Coding for a minor surgical procedure is not difficult, but realize that, in accordance with minor surgical rules, an office visit (either 920XX or 992XX) is generally not separately billable when performed on the same date of service as CPT code 65778. Reimbursement for the 65778 code itself already includes compensation for the office visit related to the decision to perform this minor surgical procedure. So, it would be the rare occasion to append modifier -25 to an E/M office visit performed on the same day as the application of an amniotic membrane.

Make sure that your medical record contains an operative report that specifies the details of the procedure and discharge instructions for the patient.

The global period for 65778 is zero days, so the postoperative period expires at the end of the day the service was performed. All follow-up examinations beginning on the day after the procedure was performed are separately billable. Another notable characteristic of the code is:

**Bilateral/unilateral status.** As with many surgical codes, this is a bilateral 150% procedure, meaning if you perform it bilaterally on the same day, you will get 100% for the first procedure and 50% for the fellow eye.

While reimbursement looks enticing, don't let it guide your clinical decisions. Having amniotic membranes as part of your treatment arsenal is a big boon to your practice. Establish appropriate and proper medical necessity for the procedure to ensure that you survive an audit. ■

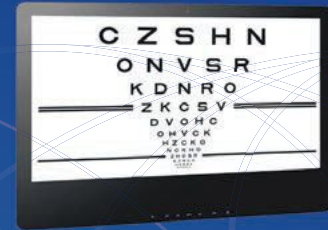Send your coding questions to [rocodingconnection@gmail.com](mailto:rocodingconnection@gmail.com).

1. CMS. Local coverage determination (LCD): amniotic membrane-sutureless placement on the ocular surface (L36237). [www.cms.gov/medicare-coverage-database/details/lcd-details.aspx?lcdid=36237](https://www.cms.gov/medicare-coverage-database/details/lcd-details.aspx?lcdid=36237). Last updated November 21, 2019. Accessed March 15, 2021.

About  
Dr. Rumpakis

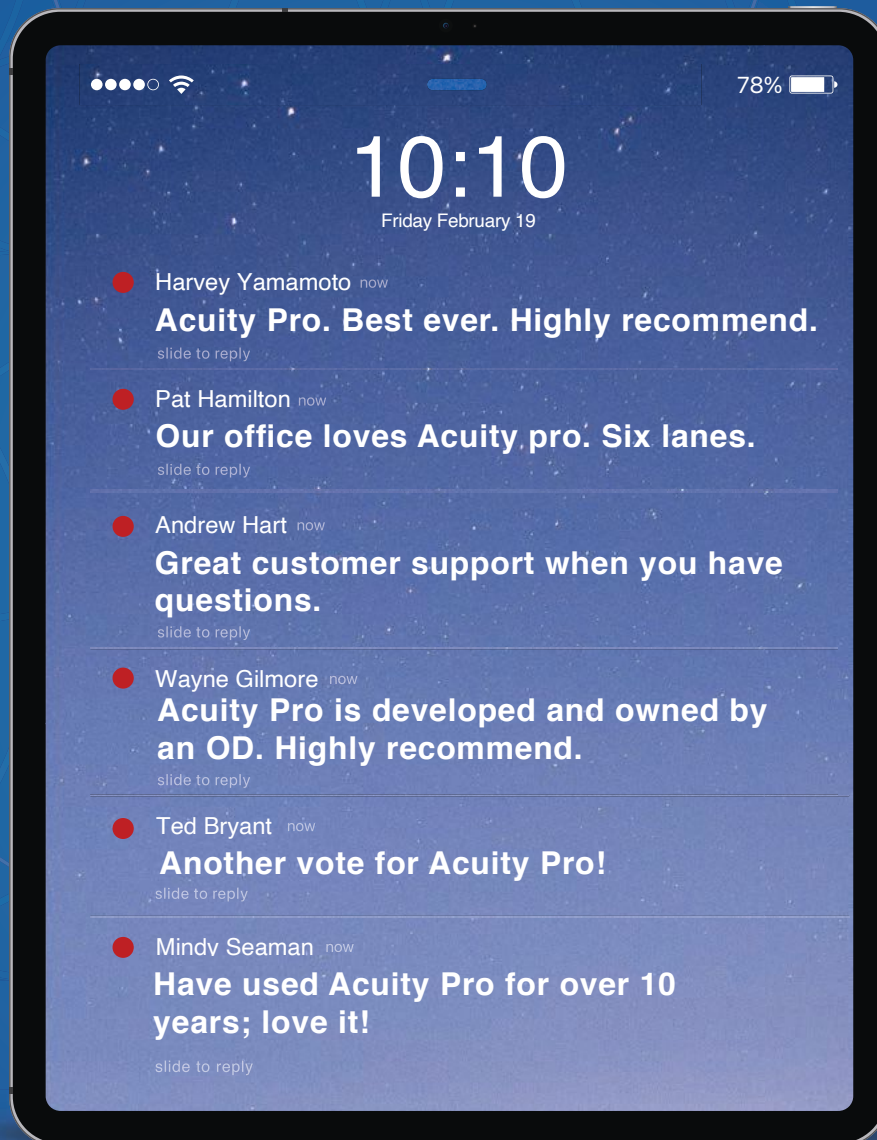
Dr. Rumpakis is president and CEO of Practice Resource Management, a firm that provides consulting, appraisal and management services for health care professionals and industry partners. As a full-time consultant, he provides services to a wide array of ophthalmic clients. Dr. Rumpakis's full disclosure list can be found in the online version of this article at [www.reviewofoptometry.com](http://www.reviewofoptometry.com).





Over 20 years of  and  !

I'm looking for a reputable solution for a digital acuity system – any suggestions?



Disaster proof by design | [acuitypro.com](http://acuitypro.com) / 580-243-1301

Sloan / Snellen / Numbers / Contrast / ETDRS / White On Black Option / Randomize  
Custom Remote / Marco Integration / Free Support / No Annual Fees



# MYOPIA: TRANSLATING SCIENCE INTO PRACTICE

With the prevalence of this condition skyrocketing, it's more important now than ever to understand its mechanism and management.



BY NATHAN CHEUNG, OD  
DURHAM, NC

**M**yopia control has been growing in popularity over the last two decades worldwide. In 2002, only 10 randomized control trials were published.<sup>1</sup> To date, there are now over 170 peer-reviewed articles on myopia control.<sup>1</sup> The growing interest in this topic, more so in certain populations and countries around the world than others, likely reflects the increasing incidence and prevalence of myopia. In 2000, there were an estimated 1.406 billion people in the world with myopia.<sup>2</sup> By 2050, predictions estimate that number will grow to 4.758 billion.<sup>2</sup> With global numbers on the rise, the myopia epidemic is quickly increasing in severity.

Although global numbers are increasing overall, myopia disproportionately affects some ethnicities more than others. For example, the Multi-Ethnic Pediatric Eye Disease Study

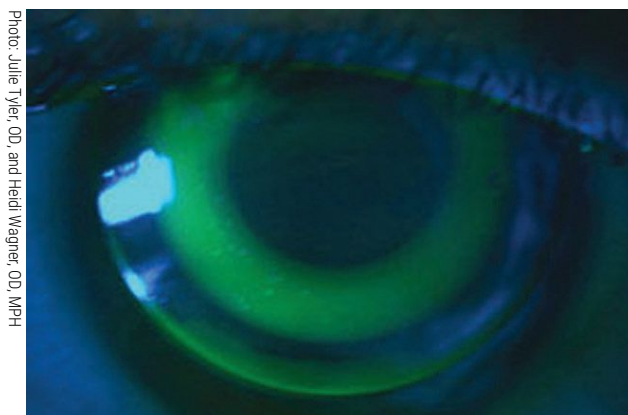


Photo: Julie Tyler, OD, and Heidi Wagner, OD, MPH

**Ortho-K is one lens option for patients undergoing myopia management.**

(MEPEDS) group showed small variations in myopia prevalence among preschool-aged children in the United States (1.2% non-Hispanic whites, 3.7% Hispanics, 3.98% Asians, 6.6% African Americans).<sup>3</sup> In comparison, school-aged children in Hong Kong had a myopia prevalence of 18.3% in six-year-olds and 61.5% in 12-year-olds.<sup>4</sup> Another paper illustrates that in east and southeast Asian countries, 80% to 90% of young adults are myopic.<sup>4</sup> Even within the same country, differences exist in the prevalence of

myopia between urban and rural settings.

There are many risk factors that affect the global trend of myopia, including high educational pressures and limited time outdoors.<sup>5</sup> A recent cross-sectional study in China showed a myopic shift after home confinement due to COVID-19. The myopia prevalence increased 1.4-fold to three-fold in 2020 compared with the previous five years.<sup>6</sup>

Why should we be concerned about increasing levels

of myopia? High myopia is associated with an increased risk of retinal detachment, cataract, glaucoma and myopic degeneration. Rhegmatogenous retinal detachment (RRD) results from axial elongation, vitreous liquefaction, posterior vitreous detachment and vitreoretinal degeneration, and affects 6.3 to 17.9 per 100,000 people.<sup>7</sup> Independent of age, an eye with a spherical equivalent refractive error of -1.00D to -3.00D has a 4x increased risk of RRD compared with an emmetropic eye.<sup>7</sup>

## About the author

**Dr. Cheung** received his optometry degree from UC Berkeley and completed his pediatric residency at the Cincinnati Children's Hospital. He is on faculty at Duke University in the Department of Pediatric Ophthalmology. He is the director of community education and the director of the pediatric optometry residency at Duke. He has no financial interests to disclose.

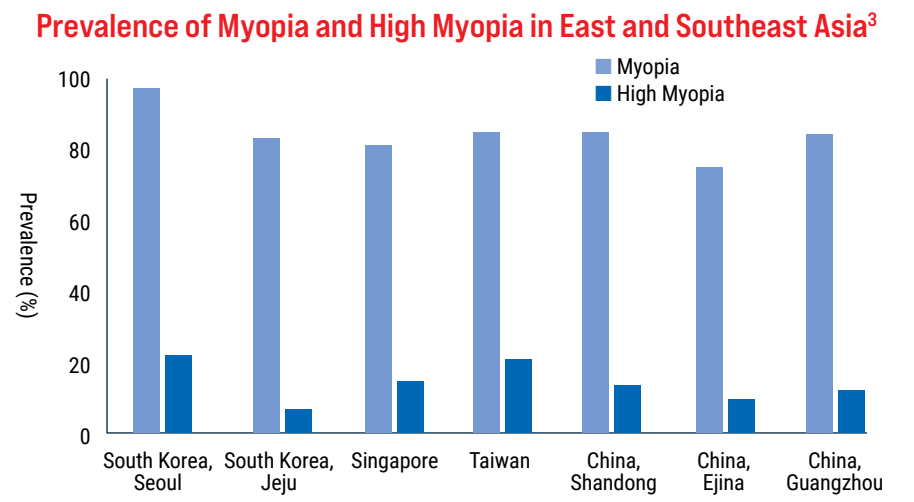
An eye with a refractive error greater than -3.00D has a 10x increased risk.<sup>7</sup> Patients with a longer axial length are more likely to have denser nuclear sclerosis and need cataract surgery.<sup>8</sup> Myopia is associated with an increased prevalence of all forms of open-angle glaucoma and ocular hypertension.<sup>9</sup> Myopic degeneration can lead to choroidal neovascularization and macular edema. Due to the increased risk of developing these sight-threatening conditions, researchers and clinicians alike have sought to more thoroughly understand myopia, including its process and progression.

### The Basics

Myopia is caused by a complex, multifactorial interplay between many genetic and environmental factors. The extent of the influence of genetics is not fully understood. Myopia is highly heritable and has a 60% to 80% chance of being passed down.<sup>10</sup> Additionally, almost 200 genetic loci have been identified to date as causing refractive error and myopia.<sup>10</sup> Despite the scientific discoveries and advances we have made in the area of myopia genetics, genetic epidemiology and epigenetics, there is still much more research and knowledge to be gained.

The Homeostasis of Eye Growth and the Question of Myopia and the IMI—Report on Experimental Models of Emmetropization and Myopia studies provide a comprehensive and exhaustive review of many key animal studies that have established how we currently understand how the eye develops.<sup>11,12</sup> It is assumed, like many other organs in the human body, that the eye undergoes both visually guided and non-visually guided regulations regarding eye growth. The axial length of the eye changes by either increasing the rate of growth of the entire eye or remodeling the sclera at the posterior pole.<sup>13,14</sup> Additionally, the retina pulls back within the eye through choroidal thinning.<sup>15</sup>

**Local mechanisms.** In animal studies, myopia is commonly induced by two mechanisms. The first involves creat-



ing an optical defocus with a minus lens. When a minus lens is placed in front of the eye, the image focuses behind the retina, causing the eye to grow. Conversely, when a plus lens is placed in front of the eye, the image focuses in front of the retina, causing the eye to inhibit its growth. This phenomenon is true of many animal species.<sup>11</sup>

The second mechanism to induce myopia is through form deprivation. One study demonstrated that if only half of the visual field is occluded, myopia and axial elongation occur only in the hemiretinal area that is form-deprived.<sup>16</sup> The same was true with full-field lenses.<sup>16</sup> In addition, if diffusers or negative lenses cover half of the retina, only that half of the eye will become myopic and enlarged.<sup>17</sup> Conversely, if positive lenses cover half of the retina, only that half will show inhibited eye growth.<sup>17</sup> Even in eyes with a severed optic nerve or blocked action potential of the nerve, myopia can still be induced through form deprivation.<sup>18-20</sup> These studies revealed that local ocular mechanisms can also be responsible for eye growth, rather than a neurological feedback loop involving the brain.

**Peripheral defocus.** The central 10° of our visual field contributes to 50% to 60% of the striate cortex.<sup>21</sup> Researchers hypothesize whether the macula has more of an influence on the peripheral retina for eye growth. When the

central retina was photoablated by a laser, and negative lenses were placed in front of the eye to induce hyperopic defocus, the magnitude of myopia produced in animal models was only slightly smaller in the foveal-ablated group compared with the control group.<sup>22</sup> Therefore, the fovea is only responsible for a small amount of refractive development, and peripheral defocus likely plays a larger role.

**Light levels.** This factor plays an important part in emmetropization and decreasing the incidence of myopia. Outdoor light levels range from 30,000 lux to 130,000 lux, while indoor light levels are typically lower than 500 lux. Even on cloudy days, lux levels can measure between 10,000 and 20,000. Raising light levels in animal studies has been shown to increase retinal dopamine activity, which alters gene expression in the retina and reduces signals that produce axial elongation.<sup>23</sup> Chicks that were raised in cages with 10,000 lux on a 12-hour light/12-hour dark cycle emmetropized normally.<sup>23</sup> However, those raised in 500 lux became slightly myopic by 90 days (0.03D), and those raised in 50 lux became fully myopic by 90 days (-2.40D).<sup>23</sup>

Human studies support the findings in animal studies when it comes to sunlight exposure. One report studied Chinese children in grades one through 12. The study compared six schools that added a 40-minute period

of outdoor activities with six schools that continued with a normal schedule. The three-year cumulative incidence of myopia was significantly different. The children who had more outdoor activity had an incidence of myopia of 30.4% compared with 39.5% for the children who did not.<sup>24</sup> When it comes to light exposure and myopia progression, the data has not yet arrived at a clear consensus.

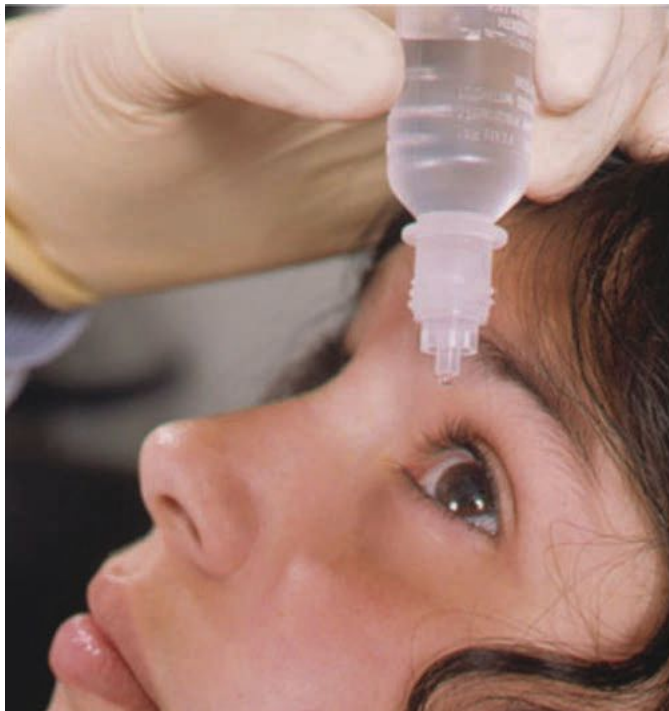### Treatment Options

To date, the most viable myopia control options are atropine drops, soft multifocal contact lenses and orthokeratology (OK) lenses.

**Atropine.** These drops arguably have the most randomized control trial evidence for myopia control, namely from the landmark study Atropine in the Treatment of Myopia (ATOM).<sup>25,26</sup> Initially, atropine was thought to slow the progression of myopia due to its cycloplegic effect on the smooth muscle fibers in the ciliary muscle. However, this theory no longer holds, as atropine is also capable of exhibiting myopia control effects on chicks. Atropine is a nonspecific muscarinic, cholinergic antagonist. Accommodation and light response in chicks are mediated by nicotinic receptors, rather than muscarinic receptors.<sup>12</sup> Additionally, atropine may have a nonmuscarinic mode of action based on: “(1) the generally high dose of atropine required to prevent myopia in animal models, (2) its continued effect following ablation of cholinergic amacrine cells and (3) its effectiveness in inhibiting proteoglycan synthesis in isolated scleral cells.”<sup>12</sup>

In summary, atropine affects eye growth through cellular mechanisms that do not involve accommodation or ciliary muscle activity. The precise mechanism of action of muscarinic and nonmuscarinic pathways are not fully known or understood at this point.

Photo: Joseph W. Sowka OD, and Alan G. Kabat, OD



**Low-dose atropine has shown clinical efficacy in myopia management.**

The ATOM studies demonstrated that atropine eye drops reduce myopia progression and axial elongation in children in a dose-related way.<sup>25,26</sup> Atropine drops have no serious adverse or systemic effects. High doses of atropine (1%), however, have been shown to cause pupil dilation, accommodation loss and near vision blur to the point where the treatment was not previously accepted in the US. Additionally, a significant rebound effect has been seen with higher concentrations. Low-dose atropine (0.01%) has the best therapeutic index, with clinically few, relatively insignificant amounts of pupil dilation and near vision and accommodation loss.

More recently, the Low-Concentration Atropine for Myopia Progression (LAMP) study evaluated the efficacy and safety of 0.05%, 0.025% and 0.01% atropine eye drops over two years to determine the optimal concentration for longer-term myopia control. Over the study period, 0.05% atropine was more effective at slowing myopia progression compared with 0.01% atropine. It is important to note that the 0.01% atropine in the ATOM 2

study had similar effects to the 0.05% atropine in the LAMP study with regard to changes in spherical equivalent. Additionally, only 0.63D of accommodation was lost in 0.01% atropine patients in the LAMP study compared with 6.41D loss of accommodation at the 24-month mark with the 0.01% atropine in the ATOM 2 study.


The vast difference in accommodation loss between the two studies at the same 0.01% atropine dose calls into question the efficacy of the atropine drops used in the LAMP study. In my opinion, I would start off with 0.01%, and if the patient demonstrates progression, increase dosage to 0.025% or 0.05%.<sup>27,28</sup>

**Contact lenses.** Numerous multifocal contact lens and OK studies have been published to date. The most recent multifocal study was the Bifocal Lenses in Nearsighted Kids (BLINK) randomized clinical trial. The objective of the study was to determine whether center-distance soft multifocal contact lenses (Biofinity, CooperVision) slow myopia progression in children compared with single-vision lenses and whether high add power (+2.50D) slows myopia progression more than medium add power (+1.50D) over a three-year period.<sup>29</sup> The study concluded that high add power multifocal contact lenses significantly reduce the rate of myopia progression compared with single-vision contact lenses of the same power and medium add power multifocal lenses.<sup>29</sup>

The results of two OK meta-analyses confirm the effectiveness of this modality for myopia control.<sup>30,31</sup> A recent study specifically compared multifocal OK with conventional OK and demonstrated that patients who were treated with the former modality showed significantly less axial length progression.<sup>32</sup>



# For myopia management, Lenstar Myopia is head of the class.



## Introducing Lenstar Myopia.

Track myopia. Educate. Slow the progression in young patients.



When myopia is undiagnosed or untreated it can lead to more serious issues. With the new Lenstar Myopia from Haag-Streit, featuring EyeSuite™ Myopia software, you can accurately measure axial length, and track the progression of myopia in young patients. The measurements you take now can make a big impact later.

- Developed in conjunction with leading myopia experts.
- Track precise axial length measurements for early detection of myopia onset, using growth curves from myopia experts.
- State-of-the-art graphical visualizations for easy education.
- EyeSuite software can be added to your existing Lenstar.

866.766.1517 | [lenstarmyopia.com](http://lenstarmyopia.com)

© 2021 Haag-Streit USA. All Rights Reserved.

Be among the first to own one.



Although various studies have shown myopia control efficacy for both multifocal contact lenses and OK lenses, each used different multifocal and OK lenses. To date, there hasn't been a study comparing the different soft multifocal contact designs within either lens category.

These lenses create an optical defocus in the peripheral retina of the myopic patient. Multifocal contact lenses do so by additional correction incorporated into the lens, which is typically a center-distance design. OK lenses temporarily flatten the central cornea, allowing patients to see clearly during the day without correction. In addition, the peripheral cornea creates an optical defocus on the retina to control the patient's myopia.

### Management Approaches

My myopia treatment strategy includes encouraging patients to spend more time outdoors (at least two hours each day), place limits on screen time and take frequent breaks from electronic screens. As far as atropine drops go, I start my patients on 0.01% atropine and increase to 0.025% or 0.05% if progression is demonstrated. My patients who are ready for contact lenses are fitted into soft multifocal contact lenses (center-distance design) or OK lenses depending on patient and parent preference. The type of soft multifocal contact lens used depends on the patient's refractive error and whether or not they have astigmatism.

Treatment-specific tests and frequency of follow-ups are often determined by the modality of treatment. For example, a patient on atropine would have their pupil size, pupil function and accommodation evaluated; whereas, a patient using an OK lens would have corneal topography performed.

In my opinion, cycloplegic refraction and axial length measurements must be performed at least once a year regardless of treatment modality. Subjective dry refraction often yields varying results, but autorefractometry is more repeatable and objective. It may

be worthwhile to conduct both. Accommodation must be neutralized in order to obtain an accurate reading of the refractive error. The only way to truly quantify progression is to obtain objective cycloplegic refractions and axial length measurements. In the case of OK lenses, it is difficult to gauge myopia progression via refractive error. For these patients, axial length measurements are your best guide in determining rate of progression and effectiveness

of treatment. In all cases, it is helpful to know a patient's rate of progression before treatment so the patient can serve as their own control.

For treatment with contact lenses, most practitioners opt to continue wear until the patient is out of the myopia progression phase, which typically occurs during their late teens or early twenties. Reasons for early discontinuation include adverse ocular health events or the patient's desire to stop treatment. The World Health Organization currently recommends atropine drops be used for two years. Personally, I keep my patients on atropine until they're out of the myopia progression phase.

Treatment should be stopped or switched if it is not sufficiently controlling progression as expected over the course of a year. While treatment does not halt myopia progression, I would consider a 50% reduction in progression to be sufficient. Additionally, treatment should be altered if there is

### Follow-up Schedule by Treatment Modality<sup>34</sup>

<b>Atropine</b>	<ul style="list-style-type: none"> <li>• Baseline: comprehensive exam with cycloplegic retinoscopy, refraction and axial length measures</li> <li>• Four to seven days: VA, accommodation, side effects, check in with parents, light sensitivity</li> <li>• One month: VA, accommodation, side effects, check in with parents</li> <li>• Three months: VA, accommodation, side effects, check in with parents]</li> <li>• Six months: cycloplegic retinoscopy, axial length</li> </ul>
<b>Orthokeratology</b>	<ul style="list-style-type: none"> <li>• Baseline: comprehensive exam with cycloplegic retinoscopy, refraction and axial length measures</li> <li>• One day: lens follow-up, corneal topography</li> <li>• Four to seven days: lens follow-up, corneal topography</li> <li>• One month: VA, accommodation, side effects, check in with parents, corneal topography</li> <li>• Three months: VA, accommodation, side effects, check in with parents, corneal topography</li> <li>• Six months: cycloplegic retinoscopy, axial length, corneal topography</li> </ul>
<b>Multifocal Contact Lenses</b>	<ul style="list-style-type: none"> <li>• Baseline: comprehensive exam with cycloplegic retinoscopy, refraction and axial length measures</li> <li>• Four to seven days: lens follow-up</li> <li>• Three months: VA, side effects, check in with parents</li> <li>• Six months: cycloplegic retinoscopy, axial length</li> </ul>

a problem with compliance, safety or tolerance of visual side effects.


It is possible to augment contact lens treatment with low-dose atropine or vice-versa, as long as it is at the benefit of the patient. A recent study looking into the efficacy of combined OK lenses and 0.01% atropine found that axial length elongation was more prevalent in the OK group compared with the combination therapy group.<sup>33</sup> The combination group was also 28% more effective in slowing myopia progression.<sup>33</sup>

### Clinical Takeaways

In the coming years, research and studies will lead to an increase in science- and evidence-based medicine that will serve as the guiding principles to help solidify clinical guidelines for myopia control. Above all, we should always act in the best interests of our patients, which means finding the most optimal treatment, while also ensuring health and safety. ■

TREAT OCULAR INFLAMMATION  
AND INFECTION, AND...

TURN ON  
RELIEF



**TobraDex<sup>®</sup> ST**  
(tobramycin/dexamethasone  
ophthalmic suspension)  
0.3%/0.05%  
FORMULATED WITH **XanGen<sup>™</sup>**

PRESCRIBE TOBRADEX<sup>®</sup> ST to control ocular inflammation with risk of bacterial infection



Rapid relief from blepharitis/  
blepharoconjunctivitis symptoms<sup>1,a</sup>



XanGen<sup>™</sup> suspension technology  
provides increased viscosity  
for improved ocular bioavailability  
of drug and consistent delivery<sup>2</sup>



TOBRADEX ST contains half the  
dexamethasone as TobraDex<sup>®</sup>,  
yet similar ocular tissue exposure<sup>2,b</sup>

Eligible patients could pay as little as \$45 for TOBRADEX ST  
LEARN MORE AT MYTOBRADEXST.COM

## Indications and Usage

For steroid responsive inflammatory ocular conditions of the palpebral and bulbar conjunctiva, cornea, and anterior segment of the globe and chronic anterior uveitis, corneal injury from chemical, radiation or thermal burns, or penetration of foreign bodies for which a corticosteroid is indicated and where the risk of superficial bacterial ocular infection is high or where there is an expectation that potentially dangerous numbers of bacteria will be present in the eye.

## Important Safety Information

### CONTRAINDICATIONS:

Most viral disease of the cornea and conjunctiva including epithelial herpes simplex keratitis (dendritic keratitis), vaccinia, and varicella, and also in mycobacterial infection of the eye and fungal disease of ocular structures. Hypersensitivity to any components of the medication.

### WARNINGS & PRECAUTIONS:

- **IOP increase** – Prolonged use may result in glaucoma with damage to the optic nerve, defects in visual acuity and fields of vision. IOP should be monitored.
- **Aminoglycoside sensitivity** – Sensitivity to topically applied aminoglycosides may occur.
- **Cataracts** – Posterior subcapsular cataract formation may occur.
- **Delayed healing** – May delay healing and increase the incidence of bleb formation. Perforations of the cornea or sclera have occurred. Slit lamp biomicroscopy, and fluorescein staining should be conducted.
- **Bacterial infections** – May suppress host response and increase secondary ocular infections. In acute purulent conditions, steroids may mask infection or enhance existing infection. If signs and symptoms fail to improve after 2 days, the patient should be re-evaluated.

- **Viral infections** – Use with history of herpes simplex requires great caution. The course and severity of many viral infections of the eye (including herpes simplex) may be exacerbated.
- **Fungal infections** – Fungal infections of the cornea may occur and should be considered in any persistent corneal ulceration.
- **Use with systemic aminoglycosides** – Total serum concentration of tobramycin should be monitored.

### ADVERSE REACTIONS:

The most frequent adverse reactions (<4%) to topical ocular tobramycin are hypersensitivity and localized ocular toxicity, including eye pain, eyelid pruritus, eyelid edema, and conjunctival hyperemia.

The reactions due to the steroid component are increased intraocular pressure with possible development of glaucoma, and infrequent optic nerve disorder; subcapsular cataract; and impaired healing.

The development of secondary infection has occurred. Fungal infections of the cornea may occur. Secondary bacterial ocular infection following suppression of host responses also occurs.

Non-ocular adverse events (0.5% to 1%) included headache and increased blood pressure.

**Please see Brief Summary of Full Prescribing Information on the adjacent page.**

<sup>a</sup>Randomized, investigator-masked, active-controlled, parallel-group trial conducted at 7 private practice clinical sites in the United States with 122 adult patients who had moderate to severe blepharitis/blepharoconjunctivitis.<sup>1</sup>

<sup>b</sup>Multicenter, double-blind, parallel-group, single-dose study of 987 patients receiving a single dose of TOBRADEX ST or TobraDex ophthalmic suspension.<sup>2</sup>

**References:** 1. Torkildsen GL, Cockrum P, Meier E, et al. *Curr Med Res Opin.* 2011;27(1):171-178. 2. Scooper SV, Kabat AG, Owen GR, et al. *Adv Ther.* 2008;25(2):77-88.





## **TOBRADEX® ST (tobramycin/dexamethasone ophthalmic suspension) 0.3%/0.05%**

### **Brief Summary**

**This Brief Summary does not include all the information needed to use TOBRADEX ST safely and effectively. Please see Full Prescribing Information for TOBRADEX ST at MyTobraDexST.com.**

### **INDICATIONS AND USAGE**

TOBRADEX ST is a topical antibiotic and corticosteroid combination for steroid-responsive inflammatory ocular conditions for which a corticosteroid is indicated and where superficial bacterial ocular infection or a risk of bacterial ocular infection exists.

Ocular steroids are indicated in inflammatory conditions of the palpebral and bulbar conjunctiva, cornea and anterior segment of the globe where the inherent risk of steroid use in certain infective conjunctivitis is accepted to obtain a diminution in edema and inflammation. They are also indicated in chronic anterior uveitis and corneal injury from chemical, radiation or thermal burns, or penetration of foreign bodies.

The use of a combination drug with an anti-infective component is indicated where the risk of superficial ocular infection is high or where there is an expectation that potentially dangerous numbers of bacteria will be present in the eye.

### **DOSAGE AND ADMINISTRATION**

**Recommended Dosing:** Instill one drop into the conjunctival sac(s) every four to six hours. During the initial 24 to 48 hours, dosage may be increased to one drop every 2 hours. Frequency should be decreased gradually as warranted by improvement in clinical signs. Care should be taken not to discontinue therapy prematurely.

### **CONTRAINDICATIONS**

**Nonbacterial Etiology:** TOBRADEX ST is contraindicated in most viral diseases of the cornea and conjunctiva including epithelial herpes simplex keratitis (dendritic keratitis), vaccinia, and varicella, and also in mycobacterial infection of the eye and fungal diseases of ocular structures.

**Hypersensitivity:** Hypersensitivity to any component of the medication.

### **WARNINGS AND PRECAUTIONS**

**IOP increase:** Prolonged use of corticosteroids may result in glaucoma with damage to the optic nerve, defects in visual acuity and fields of vision. IOP should be monitored.

**Aminoglycoside sensitivity:** Sensitivity to topically applied aminoglycosides may occur.

**Cataracts:** May result in posterior subcapsular cataract formation.

**Delayed healing:** May delay healing and increase the incidence of bleb formation after cataract surgery. In those diseases causing thinning of the cornea or sclera, perforations have been known to occur with the use of topical steroids.

**Bacterial infections:** May suppress the host response and thus increase the hazard of secondary ocular infections. In acute purulent conditions, steroids may mask infection or enhance existing infection. If signs and symptoms fail to improve after 2 days, the patient should be re-evaluated.

**Viral infections:** Treatment in patients with a history of herpes simplex requires great caution. Use of ocular steroids may prolong the course and may exacerbate the severity of many viral infections of the eye (including herpes simplex).

**Fungal infections:** Fungal infections of the cornea are particularly prone to develop with long-term use. Fungal invasion must be considered in any persistent corneal ulceration.

**Use with systemic aminoglycosides:** Use with systemic aminoglycoside antibiotics requires monitoring for total serum concentration of tobramycin.

### **ADVERSE REACTIONS**

The most frequent adverse reactions to topical ocular tobramycin (TOBEX®) are hypersensitivity and localized ocular toxicity, including eye pain, eyelids pruritis, eyelid edema, and conjunctival hyperemia. These reactions occur in less than 4% of patients. Similar reactions may occur with the topical use of other aminoglycoside antibiotics.

Non-ocular adverse events occurring at an incidence of 0.5% to 1% included headache and increased blood pressure.

The reactions due to the steroid component are: increased intraocular pressure (IOP) with possible development of glaucoma, and infrequent optic nerve disorder; subcapsular cataract; and impaired healing.

Secondary Infection.

The development of secondary infection has occurred. Fungal infections of the cornea are particularly prone to develop with long-term use. Fungal invasion must be considered in any persistent corneal ulceration. Secondary bacterial ocular infection following suppression of host responses also occurs.

### **USE IN SPECIFIC POPULATIONS**

#### **Pregnancy and Nursing Mothers**

There are no adequate and well controlled studies in pregnant women. TOBRADEX® ST ophthalmic suspension should be used during pregnancy only if the potential benefit justifies the potential risk to the fetus. Caution should be exercised when TOBRADEX® ST is administered to a nursing woman.

**Pediatric Use:** Safety and effectiveness in pediatric patients below the age of 2 years have not been established.

**Geriatric Use:** No overall differences in safety or effectiveness have been observed between elderly and younger patients.

#### **Rx Only**

**Distributed by:** Eyevance Pharmaceuticals LLC.  
Fort Worth, TX 76102



# Feature MYOPIA CONTROL

- Wolffsohn JS, Flitcroft DJ, Gifford KL, et al. IMI—myopia control reports overview and introduction. *Invest Ophthalmol Vis Sci.* 2019;60(3):M1-19.
- Holden BA, Fricke TR, Wilson DA, et al. Global prevalence of myopia and high myopia and temporal trends from 2000 through 2050. *Ophthalmology.* 2016;123(5):1036-42.
- Multi-Ethnic Pediatric Eye Disease Study Group. Prevalence of myopia and hyperopia in 6- to 72-month-old African American and Hispanic children: the multi-ethnic pediatric eye disease study. *Ophthalmology.* 2010;117(1):140-7.
- Lam CSY, Lam CH, Cheng SCK, et al. Prevalence of myopia among Hong Kong Chinese schoolchildren: changes over two decades. *Ophthalmic Physiol Optics.* 2012;32(1):17-24.
- Morgan IG, French AN, Ashby RS, et al. The epidemics of myopia: aetiology and prevention. *Prog Retin Eye Res.* 2018;62:134-49.
- Wang J, Li Y, Musch DC, et al. Progression of myopia in school-aged children after COVID-19 home confinement. *JAMA Ophthalmol.* January 14, 2021. [Epub ahead of print].
- Mitry D, Charteris DG, Fleck BW, et al. The epidemiology of rhegmatogenous retinal detachment: geographical variation and clinical associations. *Br J Ophthalmol.* 2010;94(6):678-84.
- Kubo E, Kumamoto Y, Tsuzuki S, et al. Axial length, myopia, and the severity of lens opacity at the time of cataract surgery. *Arch Ophthalmol.* 2006;124(11):1586-90.
- Shen L, Melles RB, Metlapally R, et al. The association of refractive error with glaucoma in multiethnic population. *Ophthalmology.* 2016;123(1):92-101.
- Tedja MS, Haarman AEG, Meester-Smoor MA, et al. IMI—myopia genetics report. *Invest Ophthalmol Vis Sci.* 2019;60:M89-105.
- Wallman J, Winawer J. Homeostasis of eye growth and the question of myopia. *Neuron.* 2004;43(4):447-68.
- Troilo D, Smith EL III, Nickla DL, et al. IMI—report on experimental models of emmetropization and myopia. *Invest Ophthalmol Vis Sci.* 2019;60:M31-88.
- Gentle A, McBrien NA. Modulation of scleral DNA synthesis in development of and recovery from induced axial myopia in the tree shrew. *Exp Eye Res.* 1999;68(2):155-63.
- Nickla DL, Wildsoet C, Wallman J. Compensation for spectacle lenses involves changes in proteoglycan synthesis in both the sclera and choroid. *Curr Eye Res.* 1997;16(4):320-6.
- Wallman J, Wildsoet C, Xu A, et al. Moving the retina: choroidal modulation of refractive state. *Vision Res.* 1995;35(1):37-50.
- Smith EL III, Huang J, Hung LF, et al. Hemiretinal form deprivation: evidence for local control of eye growth and refractive development in infant monkeys. *Invest Ophthalmol Vis Sci.* 2009;50:5057-69.
- Wallman J, Gottlieb MD, Rajaram V, et al. Local retinal regions control local eye growth and myopia. *Science.* 1987;237(4810):73-7.
- Norton TT, Essinger JA, McBrien NA. Lid-suture myopia in tree shrews with retinal ganglion cell blockade. *Vis Neurosci.* 1994;11(1):143-53.
- Troilo D, Gottlieb MD, Wallman J. Visual deprivation causes myopia in chicks with optic nerve section. *Curr Eye Res.* 1987;6(8):993-9.
- Wildsoet CF, Pettigrew JD. Experimental myopia and anomalous eye growth patterns unaffected by optic nerve section in chickens: evidence for local control of eye growth. *Clin Vis Sci.* 1988;3(2):99-107.
- McFadzean R, Brosnahan D, Hadley D, et al. Representation of the visual field in the occipital striate cortex. *Br J Ophthalmol.* 1994;78:185-90.
- Smith EL III, Hung LF, Huang J. Relative peripheral hyperopic defocus alters central refractive development in infant monkeys. *Vision Res.* 2009;49(19):2386-92.
- Norton TT. What do animal studies tell us about the mechanism of myopia—protection by light? *Optom Vis Sci.* 2016;93(9):1049-51.
- He M, Xiang F, Zeng Y, et al. Effect of time spent outdoors at school on the development of myopia among children in China. *JAMA Ophthalmol.* 2015;33(11):1142-8.
- Chua WH, Balakrishnan V, Chan YH, et al. Atropine for the treatment of childhood myopia. *Ophthalmology.* 2006;113(12):2285-91.
- Chia A, Chua WH, Cheung YB, et al. Atropine for the treatment of childhood myopia: safety and efficacy of 0.5%, 0.1%, and 0.01% doses (Atropine for the Treatment of Myopia 2). *Ophthalmology.* 2012;119(2):347-54.
- Yam JC, Jiang Y, Tang SM, et al. Low-Concentration Atropine for Myopia Progression (LAMP) study: a randomized, double-blinded, placebo-controlled trial of 0.05%, 0.025%, and 0.01% atropine eye drops in myopia control. *Ophthalmology.* 2018;126(1):113-24.
- Yam JC, Li FF, Zhang X, et al. Two-year clinical trial of the Low-Concentration Atropine for Myopia Progression (LAMP) study: phase 2 report. *Ophthalmology.* 2020;127(7):910-9.
- Walline JJ, Walker MK, Mutti DO, et al. Effect of high add power, medium add power, or single-vision contact lenses on myopia progression in children: the BLINK randomized clinical trial. *JAMA Ophthalmol.* 2020;324(6):571-80.
- Si JK, Tang K, Bi HS, et al. Orthokeratology for myopia control: a meta-analysis. *Optom Vis Sci.* 2015;92(3):252-7.
- Sun Y, Xu F, Zhang T, et al. Orthokeratology to control myopia progression: a meta-analysis. *PLoS One.* 2015;10:e0124535.
- Loertscher M, Backhouse S, Phillips JR. Multifocal orthokeratology versus conventional orthokeratology for myopia control: a paired-eye study. *J Clin Med.* 2021;10(3):447.
- Kinoshita N, Konno Y, Hamada N, et al. Efficacy of combined orthokeratology and 0.01% atropine solution for slowing axial elongation in children with myopia: a 2-year randomized trial. *Scientific Reports* 2020;10:12750.
- Gifford KL, Richdale K, Kang P, et al. IMI—clinical management guidelines report. *Invest Ophthalmol Vis Sci.* 2019;60:M184-203.

## A NEW WAY TO EXPERIENCE REVIEW OF OPTOMETRY

Follow us on Instagram at @revoptom for striking clinical images, daily news headlines, issue previews and great content from the magazine—all formatted for mobile

The collage displays a variety of content from the @revoptom Instagram account:

- Instagram Profile:** The top left shows the @revoptom profile icon and name.
- Stories (3-26-21):** A series of story screenshots including:
  - "Missed Neuro Diagnoses Common, Can Lead to Patient Harm" with a text overlay: "Study finds 63% of all refractive were incorrect and one in four of those incorrect were kind of adverse impact on health."
  - "CDC Aims to Break Down Tangled Barriers in Glaucoma" with a text overlay: "These researchers are looking for a streamlined investigation into the location and clinical value of various structures."
  - "Thyroid Eye Disease Increases Risk of Optic Nerve Damage" with a text overlay: "A clinical study requires screening of the optic and ganglion cell layers, breaking the clinical chain of progression to irreversible optic neuropathy."
- Clinical Images:** Several posts show eye examinations, including fundus photography and OCT scans. One post shows "Choroidal folds coming with RPE anomalies (red line)" and another shows "High myopia with a bifurcated and thin choroid (red line), RPE disruption (gray line), and hyperreflective material (purple line) — all associated with myopic CNV."
- Survey Results:** A post titled "DRY EYE READER SURVEY RESULTS" shows a bar chart with categories: "What percent of your patients in each of these categories suffer from dry eye?" and "What percent of your patients in each of these categories suffer from dry eye?"
- Articles and Previews:** Posts for "CLINICAL FEATURES OF COMMON SECONDARY CONDITIONS ASSOCIATED WITH GLAUCOMA" (with a table), "MAY 2021 Dry Eye Issue" (with a cover image), "FAST FACTS ON CLRAO", and "Localization of Common Etiologies Causing Diplopia" (with a diagram).
- Case Studies:** Posts like "Addition studies that might yield disproportionately pertinent data" and "Case Outcome" provide detailed clinical information.

# FIVE QUESTIONS ON DRY AMD MONITORING AND MANAGEMENT

Address these concerns and observing these patients will be more effective.



BY JESSICA HAYNES, OD  
MEMPHIS

**A**ge-related macular degeneration (AMD) is the leading cause of vision loss in patients over the age of 65.<sup>1</sup> As there is no cure for AMD, current management focuses on reducing risk of conversion to advanced stages with formation of geographic atrophy (GA; advanced non-exudative AMD) or choroidal neovascularization (CNV; advanced exudative AMD). In addition, early detection of CNV is crucial in obtaining best visual outcomes for those who develop exudative AMD.

Development of advanced-stage disease poses the greatest threat of acuity reduction and significant loss of central vision, but even those without advanced disease may suffer visual deficits such as reduction in dark adaptation and loss of contrast sensitivity.<sup>2-6</sup>

Optometrists can manage patients with dry AMD from a medical perspective while also providing optical and low vision services to meet their visual needs. This article will focus on the medical management of those with non-exudative AMD by answering five common questions.

## How Can I Tackle Compliance?

This perennial problem in many spheres of care is certainly a factor in AMD as well.

**Knowledge is key.** Patients who understand their condition and reason for being monitored are more apt to adhere to a mutual agreement. Those who are completely asymptomatic may not understand why they are monitoring their vision at home or why they are having periodic follow-ups when they have no visual symptoms.

On the other hand, those with reduced visual function may not understand why they are required to have office visits periodically when nothing is being done to “cure” their disease. They must understand the limitations that exist when managing AMD and the reason why we are monitoring them and making certain recommendations in order for them to adhere to follow-up.

A conversation about AMD and CNV may start off like this:

*“AMD is a degenerative condition of the retina where the retina ages more quickly than it should. This accelerated aging can lead to loss of visual function as the retina structures weaken and no longer function normally.”*

*“There is no cure for AMD, but I am going to make specific recommendations that will decrease your risk of vision loss. Many patients with AMD maintain functional vision for a lifetime, and while AMD can affect your central vision, it does not make you go completely blind because peripheral vision is still intact.”*

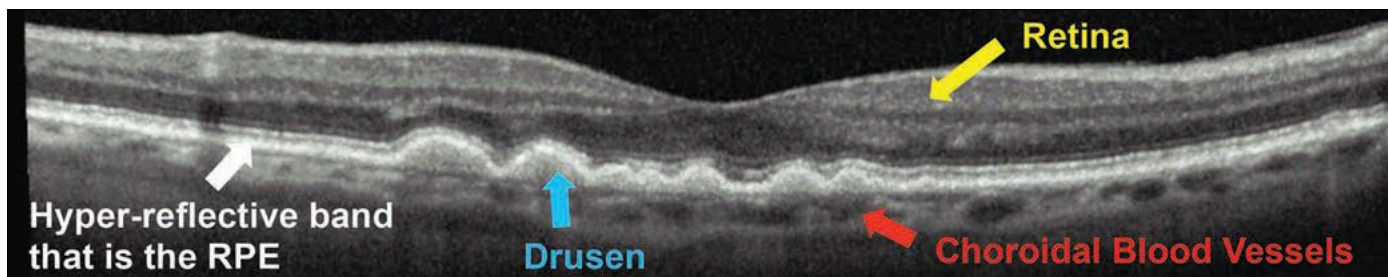
**Visualize the problem.** It is very useful for patients to be able to visualize alterations to their macula. Show them their fundus photographs or optical coherence tomography (OCT) images and walk them through the abnormalities that exist. Consider comparing them with normal photos or OCT scans.

I show patients with drusen their OCT images and point out that AMD affects the bottom layer of the retina (showing them the hyper-reflective band that is the retinal pigmented epithelium [RPE]), causing buildup of waste products (showing them areas of drusen). I explain that this layer of the retina is a barrier between the retina above and blood vessels (the choroid) underneath. This layer is weakened in patients with AMD, and these blood vessels can grow through and start to leak or bleed, causing a sudden and severe decline in vision (*Figure 1*).

### About the author

Dr. Haynes is a consultative optometrist at the Charles Retina Institute and consulting faculty at Southern College of Optometry in Memphis, TN. She is a paid speaker for Heidelberg Engineering and a consultant for Notal Vision.





**Fig. 1. Teach your patient the retina basics. Show them imaging of their retina to help them understand their disease.**

Although this is very simplified pathophysiology, it can help patients understand why they must be monitored daily for conversion to wet AMD, even though they may be asymptomatic.

In patients who have GA, fundus autofluorescence (FAF) can demonstrate how certain areas of the retina have atrophied, causing the vision to have “good spots” and “bad spots” (Figure 2). Patients can understand visual deficits better and see that, while they may see 20/20 on the acuity chart, there are areas of the vision in with scotomas. On FAF, regions of GA will appear dark or hypo-autofluorescent.<sup>7</sup>

In addition to traditional diagnostic imaging, the AdaptDx Pro is an FDA-approved instrument from Maculogix that can demonstrate altered function of the retina.<sup>8,9</sup> This may help both the patient and the physician understand how the retina is functioning in those with good visual acuity but significant visual complaints. It can also convince those who mistakenly feel that their vision is fine. Dark adaptation may also be altered prior to any clinical findings.<sup>8</sup>

**Keep an eye on them.** Until recently, we had no way of monitoring our patients outside of their scheduled follow-ups. We could send them home with an Amsler grid but couldn’t determine whether they were using it or if they understood how to use it. Now there is an FDA-approved at-home monitoring system for those who have intermediate AMD, the ForeseeHome system from Notal Vision. It takes the guesswork out of vision monitoring. Patients test their vision at home daily with a physician-prescribed monitoring device. Algorithms use hyperacuity to detect visual changes consistent with conversion to exudative AMD.

One report showed that 94% of eyes using ForeseeHome maintained 20/40 vision or better after conversion to exudative AMD vs. only 62% using current standard-of-care methods such as the Amsler grid.<sup>10</sup> This is due to earlier detection with ForeseeHome. If conversion is detected, the prescribing physician will be alerted to contact the patient immediately. Physicians can access testing history through a portal or an app on their phone to know how often patients are testing, keeping them accountable (Figure 3).

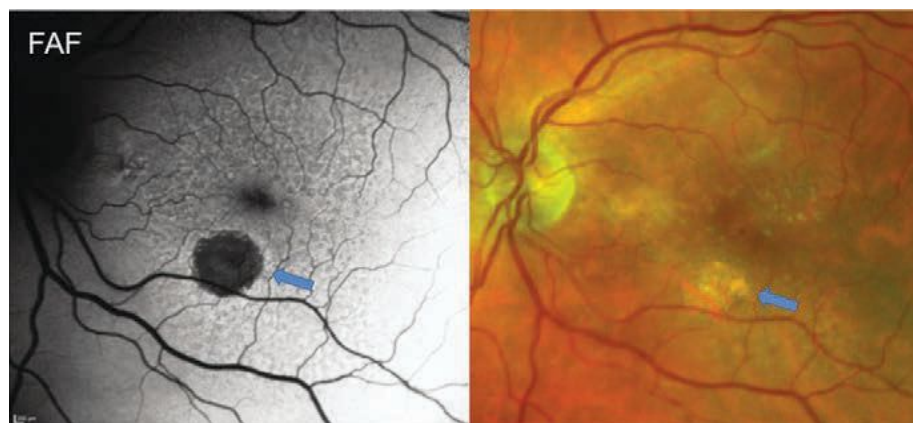
### When Should I Employ an Amsler Grid or Other At-home Monitoring Options?

Conversion to wet AMD remains the greatest risk for severe vision loss in those with AMD. Even with anti-VEGF injections, earlier detection of CNV leads to better visual outcomes. We rely heavily on home monitoring techniques and self-reporting to catch these conversions that can happen

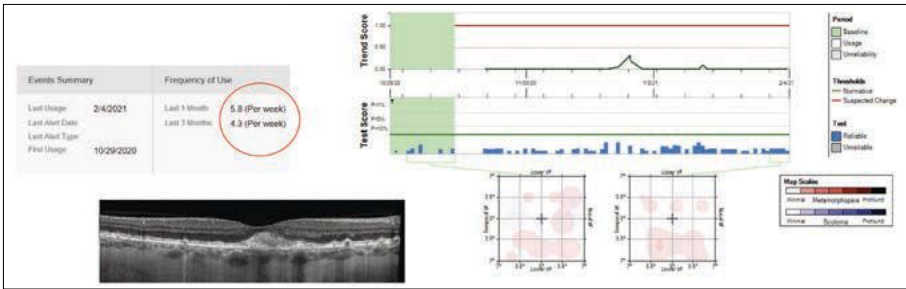
between visits. Educate patients with any stage of AMD about at-home vision monitoring with tools such as the Amsler grid. Those with intermediate AMD also qualify for the at-home vision monitoring system, ForeseeHome. Heavily consider that option for those with intermediate AMD.

Patients may ask, “Do I really need this device at my stage?” This is a major checkpoint to determine whether patients truly understand why they are being monitored. Introduce the program as AMD insurance. You hope to never use it, but it is there if you need it.

Figure 4 shows conversion to wet AMD that occurred less than three weeks after a scheduled monitoring appointment in a patient being followed for advanced non-exudative AMD. This well-educated patient noticed new-onset visual distortion of her Amsler grid and called our office. She was immediately brought in that afternoon where OCT confirmed



**Fig. 2. Fundus autofluorescence and fundus photo of a patient with reticular pseudodrusen and GA. FAF highlights a hypo-autofluorescent region of GA (blue arrows) and shows diffuse RPE alterations from RPD. FAF in patients with RPD often shows more diffuse disease than can be seen clinically with a reticular pattern of circular areas of hypo-autofluorescence often with a hyper-autofluorescent center.**



**Fig. 3.** On this ForeseeHome system report, a patient was testing regularly with almost six tests performed per week in the last month (red circle). I felt more comfortable then to extend his follow-up to six months.

presence of exudation, and treatment with anti-VEGF was initiated.

Anecdotal stories and images may be useful to share with other AMD patients. By sharing your personal experiences in managing AMD, it makes the disease seem much more relatable and less abstract for the newly diagnosed patient. It also emphasizes the importance of at-home monitoring.

**When Should I Decide to Discuss Lifestyle Interventions?**

Simply put, the sooner the better. Recommending healthy diet, exercise, smoking cessation and UV protection is generally a positive thing for any patient, but especially those with risk factors such as family history of AMD, systemic vascular disease, poor nutrition and history of smoking. Discuss with them how such factors increase risk of macular degeneration and how lifestyle modifications can decrease it.

Smoking remains the most important modifiable risk factor for development and progression of AMD.<sup>11,12</sup> Many patients know that smoking can be bad for their heart or for their lungs, but it often comes as a surprise that it can also increase their risk of losing vision.

Making dietary recommendations can be daunting for those who are not used to this type of conversation. Even simple recommendations can spark a change for patients. One easy recommendation for patients can be to eat more naturally sourced food. Real, whole, unprocessed foods with a focus on brightly colored fruits and vegetables is a good place to start.

Additional suggestions may include

observing a Mediterranean-type diet that involves intake of fatty fish rich in omega-3 oils at least twice per week and incorporating whole grain forms of rice, pasta and bread.<sup>13</sup> For those with complicated systemic health, consider comanagement with the primary care physician or a nutritionist to facilitate dietary improvements.

Educate patients on the correlation between AMD and a sedentary lifestyle, obesity and vascular diseases such as hypertension, diabetes and hyperlipidemia.<sup>14</sup> Consider making or using a quick reference sheet of the AMD lifestyle do’s and don’ts to give to your patients as shown in *Figure 5*.

**When Should I Recommend Vitamin Supplementation?**

Nutritional supplementation remains controversial. So, unfortunately, there is not an easy or straightforward answer. For a disease with no cure and very limited treatment options, there is a desire to do everything possible for a patient. This has to be appropriately balanced with current evidence. Recommendations for vitamin supplementation must always consider potential adverse effects alongside potential benefits.

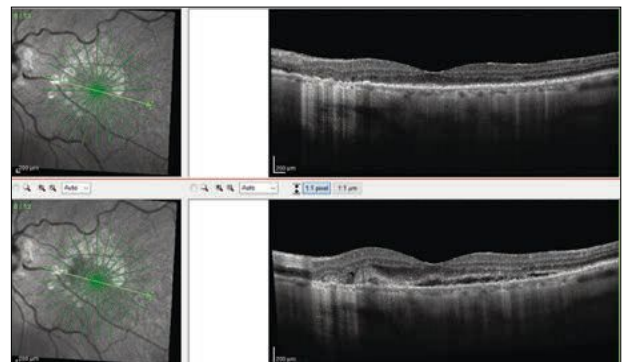
The following is quoted from the American Academy of Ophthalmology’s Preferred Practice Patterns: “Antioxidant vitamin and mineral supple-

mentation as per the Age-Related Eye Disease Study (AREDS II) should be considered in patients with intermediate or advanced AMD. There is no evidence to support the use of these supplements for patients who have less than intermediate AMD and no evidence of any prophylactic value for family members without signs of AMD.”<sup>15</sup>

The authors of the AREDS I trial concluded that clinicians should recommend AREDS-type supplementation only for those with intermediate AMD.<sup>16</sup> Because there has yet to be a separate conclusive body of evidence that any type of supplementation reduces the risk of AMD progression or development in those with early AMD or those who do not yet have AMD, most guidelines still adhere to this recommendation.

The AREDS II trial concluded that use of supplements containing the following should be recommended for patients with intermediate AMD: 10mg lutein/2mg zeaxanthine, 500mg vitamin C, 400 IU vitamin E, 80mg zinc and 2mg copper.<sup>17</sup> While AREDS II did not find benefit of docosahexaenoic acid and eicosapentaenoic acid, there is other evidence that shows potential benefits of omega-3 fatty acids.<sup>18-20</sup> Many over-the-counter supplements do contain these ingredients.

Discussing whether to recommend a particular vitamin supplement of the optometrist’s choosing to patients who



**Fig. 4.** A patient with advanced dry AMD was seen with 20/20 OS. Less than three weeks later, the patient self reported visual changes and was brought into the clinic. OCT confirmed conversion to wet AMD OS and 20/25 vision (bottom).





# Individually Designed for Premium Performance

Individually designed to each patient's unique ocular anatomy utilizing Ks, HVID and Refraction to personalize precise lens parameters.

Premium-Performance Vision • Premium-Performance Fit • Premium-Performance Profitability





Single Vision & Multifocal Extended Depth of Focus\*

## This Breakthrough Lens is Already Delivering Results for Practices\*\*

**84%** First Lens Dispense

**89%** Fits Completed in 1-2 Lenses Per Eye  
(adjustment primarily for power)

 Streamlined Empirical Fitting

 Retained Revenue & Profitability  
(only available from IECPs)

### Learn More About SynergEyes iD

[SynergEyes.com/Professional](http://SynergEyes.com/Professional)  
877.733.2012 option 5

\*EDOF design powered by the Brien Holden Vision Institute.  
\*\*OD feedback based on over 400 patients fit. Data on file.





the optometrist's choosing to patients who have intermediate AMD may go like this:

*"There is evidence, for your stage of macular degeneration, that vitamin supplements do help to reduce the risk of developing more advanced stages of macular degeneration by 25%. I am going to recommend a supplement for you. This does not take the place of a healthy diet and lifestyle that involves wearing sunglasses and discontinuing smoking, which are equally important!"*

**What about those with early AMD or at-risk patients?** While there is no substantial proof that vitamin supplementation reduces the risk of AMD progression or development in those with early-stage disease or at-risk patients such as those whose family members have AMD, there are multiple trials that suggest benefit to macular pigment optical density as well as both objective and subjective measures of visual function including visual acuity, contrast sensitivity and electroretinography with various types of vitamin supplementation.<sup>21-29</sup>

Supplementation with carotenoids such as lutein, zeaxanthin and meso-zeaxanthin seems reasonable in this patient population, particularly in those with poor nutrition or visual limitations such as difficulty seeing at night.

The discussion with this patient population about vitamin supplementation may go as follows:

*"While there is limited evidence that vitamin supplementation slows down the development/progression of macular degeneration at your stage, there is evidence to show that these vitamins may help the retina function more normally. I am going to recommend a supplement for you."*

### How Should I Modify the Follow-up Schedule in Response to Presentation?

To plan follow-ups for your AMD patients, determine which clinical, OCT and FAF findings suggest increased risk for conversion to advanced AMD.

**Healthy Body, Healthy Eyes**  
Protect Your Eyes from Macular Degeneration

STOP!

**STOP SMOKING!** Smoking and tobacco use is the number one risk factor for development and progression of age related macular degeneration (AMD).

---

START

**PROTECTING YOUR EYES FROM THE SUN.** Just as the sun ages your skin, it also ages your eyes. Wear UV blocking lenses to prevent damage from long term sun exposure.

---

START

**EATING A HEALTHY DIET.\*** Nutrients from our foods can protect our eyes from damage.

- Eat fresh, whole, unprocessed foods
- Reach for brightly colored fruits and vegetables
- Eat fatty fish rich in omega-3 oils at least twice per week (salmon, sardines, mackerel)
- Choose whole grain pastas, rices, and breads over their "white" counterparts

---

START

**A REGULAR EXERCISE ROUTINE.\*** Sedentary lifestyle and obesity are linked to increased risk of the development and progression of AMD

---

START

**TAKING CONTROL OF VASCULAR RISK FACTORS.** Vascular diseases such as high blood pressure, diabetes, and high cholesterol have been linked to development and progression of AMD.

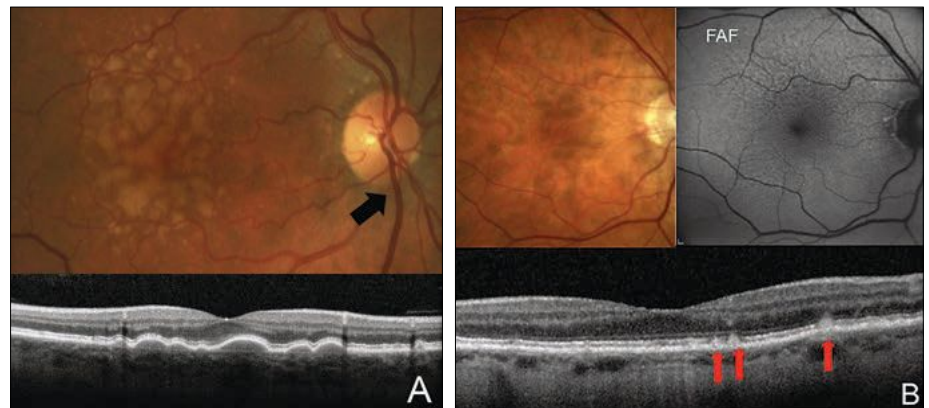
\*Please consult your medical doctor or primary care physician before beginning any new workout or nutritional program

**Fig. 5. Give your patients a reference sheet of AMD lifestyle modifications such as this one.**

DOWNLOAD AVAILABLE: Read the online version of this article at [www.reviewofoptometry.com](http://www.reviewofoptometry.com) to download a full-size PDF of this for use in your own practice.

A suggested follow-up and management depending on the stage of disease is shown in *Table 1*.

It has been well documented that patients with any large-sized drusen 125nm or larger or with pigmentary changes on clinical exam are at increased risk for conversion to advanced AMD. This is approximately the width of a major retinal vein as it crosses the disc margin (*Figure 6a*). Those with



**Fig. 6. Look out for the following clinical findings: large soft drusen (A) and RPD (B). Soft drusen are the width of a major retinal vein as it crosses the disc (black arrow). RPDs are more evident on FAF and OCT. On OCT, they present as hyper-reflective deposits on top of the RPE (red arrows).**

both of these findings in each eye have a 50% chance of converting to advanced AMD in the next five years.<sup>30</sup> The presence of either of these findings automatically puts a patient in the intermediate AMD category. It is highly important to make this distinction for three reasons.<sup>31</sup> First, this is the point at which vitamin supplementation with full AREDS II-type vitamins is well accepted. Second, this is also when to use an at-home monitoring system. Third, it is pertinent to educate these patients and monitor them more carefully due to their increased risk of developing advanced AMD.

OCT imaging can be useful in visualizing small- to large-sized drusen and getting a sense of the size of the drusen deposits. In addition, it can help to detect a particular high-risk phenotypical variant of drusen deposition called reticular pseudodrusen (RPD), also known as subretinal drusenoid deposits. This variation is difficult to distinguish clinically and presents as small- to intermediate-sized drusen. On OCT, they appear as hyper-reflective deposits sitting on top of the RPE. Although small in size, patients with these deposits are even more likely than patients with large-sized drusen to develop advanced AMD.<sup>32-38</sup>

Also, these patients tend to be more symptomatic with worse visual function than other AMD phenotypes.<sup>39-41</sup>

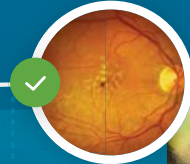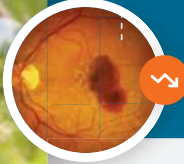# AMD Standard of Care is Not Enough



IRIS REGISTRY

**20/83 VA**

Average at wet AMD diagnosis according to IRIS Registry real-world data<sup>1</sup>



HOME STUDY

**≥20/40 VA**

Average at wet AMD diagnosis with ForeseeHome<sup>2</sup>



## Early Detection Helps Preserve Vision

ForeseeHome is a **remote monitoring** program for at-risk dry AMD patients that helps **detect wet AMD earlier** and alerts you of changes.



**ForeseeHOME™**  
AMD Monitoring Program

**Remote patient monitoring leads to better outcomes and stronger optometric practices**

- ✓ FDA Cleared
- ✓ Medicare Covered

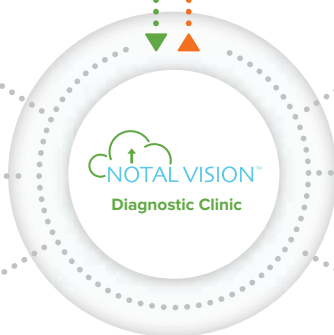- Differentiate your practice
- Solidify long-term relationships with your patients
- No cost to your practice
- Strengthen your referral relationships with qualified wet AMD referrals

## The Key to Successful Home Monitoring

**NOTAL VISION DIAGNOSTIC CLINIC**



Engagement & Education  
Benefits Verification & Authorization  
Continuous Monitoring



Practice Workflow Implementation  
Remote Patient Management  
Vision Alert Management



**GET STARTED TODAY**

**1-855-600-3112**

Mon-Fri, 8 AM to 6 PM EST

[www.foreseehome.com/hcp](http://www.foreseehome.com/hcp)

ForeseeHome is a registered trademark, and the ForeseeHome AMD Monitoring Program and logo and the Notal Vision logo are trademarks of Notal Vision. © 2020 Notal Vision, Inc. All rights reserved.

References: 1. Rao P et al. *Ophthalmology*. 2018;125(4):522-528. 2. Domalpally A, Clemons TE, Bressler SB, et al. *Ophthalmol Retina*. 2019;3(4):326-335.

See website for FDA Indication for Use.

SM-068.02



**TABLE 1. AMD FOLLOW-UP AND MANAGEMENT DEPENDING ON STAGE**

AMD Stage	Fundus Findings	Management
Age-related changes/at-risk patient	None, visible or only rare small drusen	<ul style="list-style-type: none"> <li>Reduce systemic and environmental risks.</li> <li>Monitor yearly.</li> </ul>
Early AMD	Significant small drusen or any medium-sized drusen	<ul style="list-style-type: none"> <li>Reduce systemic and environmental risks.</li> <li>Recommend home monitoring with techniques such as the Amsler grid.</li> <li>Discuss option of carotenoid supplementation.</li> <li>Monitor six to 12 months, depending on risk.</li> </ul>
Intermediate AMD	Significant medium-sized drusen, any large drusen or pigmentary alterations	<ul style="list-style-type: none"> <li>Reduce systemic and environmental risks.</li> <li>Discuss benefits of AREDS II.</li> <li>Consider home monitoring device.</li> <li>Monitor every four to six months, depending on risk.</li> </ul>
Advanced AMD	Presence of GA or CNV	<ul style="list-style-type: none"> <li>Reduce systemic and environmental risks.</li> <li>Discuss benefits of nutritional supplementation.</li> <li>Recommend home monitoring.</li> <li>Immediate referral for possible anti-VEGF injections for those with CNV.</li> <li>Monitor GA every six to 12 months, depending on risk.</li> <li>Consider low vision referral if appropriate.</li> </ul>

Patients with RPD should be more heavily educated regarding increased risk of progression, need for nutritional and lifestyle modifications and need for more careful monitoring. FAF can also help to identify RPD (Figure 6b).

### Key Clinical Takeaways

Optometrists often have the training, the knowledge and the access to all the tools necessary to manage patients with non-exudative AMD. Proper patient education, appropriate lifestyle, nutritional and nutraceutical recommendations, identification of risk factors and emphasis of both in-office and at-home monitoring can all lead to better visual outcomes for our patients with AMD. ■

1. Klein R, Peto T, Bird A, Vannewkirk MR. The epidemiology of age-related macular degeneration. *Am J Ophthalmol*. 2004;137(3):486-495.
2. Pondorfer SG, Wintergerst MWM, Gorgi Zadeh S, et al. Association of visual function measures with drusen volume in early stages of age-related macular degeneration. *Investig Ophthalmology Vis Sci*. 2020;61(3):55.
3. Enger C, Alexander MF, Fine SL. Contrast sensitivity in age-related macular degeneration. *Arch Ophthalmol*. 1988;106(1):55-7.
4. Faria BM, Duman F, Zheng CX, et al. Evaluating contrast sensitivity in age-related macular degeneration using a novel computer-based test, the Spaeth/Richman contrast sensitivity test. *Retina*. 2015;35(7):1465-73.
5. Loshin DS, White J. Contrast sensitivity: the visual rehabilitation of the patient with macular degeneration. *Arch Ophthalmol*. 1984;102(9):1303-6.
6. Chung STL. Reading in the presence of macular disease: a mini-review. *Ophthalmic Physiol Opt*. 2020;40(2):171-86.
7. Ly A, Nivison-Smith L, Assaad N, Kalloniatis M. Fundus autofluorescence in age-related macular degeneration. *Optom Vis Sci*. 2017;94(2):246-59.

8. Owsley C, McGwin G, Clark ME, et al. Delayed rod-mediated dark adaptation is a functional biomarker for incident early age-related macular degeneration. *Ophthalmology*. 2016;123(2):344-51.
9. Jackson GR, Scott IU, Kim IK, et al. Diagnostic sensitivity and specificity of dark adaptometry for detection of age-related macular degeneration. *Invest Ophthalmol Vis Sci*. 2014;55(3):1427-31.
10. Chew EY, Clemons TE, Bressler SB, et al; AREDS2-HOME Study Research Group. Randomized trial of a home monitoring system for early detection of choroidal neovascularization home monitoring of the Eye (HOME) study. *Ophthalmology*. 2014;121(2):535-44.
11. Makrynioti D, Zagoriti Z, Koutsojannis C, et al. Ocular conditions and dry eye due to traditional and new forms of smoking: a review. *Cont Lens Anterior Eye*. 2020;43(3):277-84.
12. Velilla S, García-Medina JJ, García-Layana A, et al. Smoking and age-related macular degeneration: review and update. *J Ophthalmol*. 2013;2013:895147.
13. Carneiro Â, Andrade JP. Nutritional and lifestyle interventions for age-related macular degeneration: a review. *Oxid Med Cell Longev*. 2017;2017:6469138.
14. Al-Zamil WM, Yassin SA. Recent developments in age-related macular degeneration: a review. *Clin Interv Aging*. 2017;12:1313-30.
15. AAO. Preferred Practice Pattern Guidelines. Age-Related Macular Degeneration. American Academy of Ophthalmology. 2019.
16. Kassoff A, Kassoff J, Buehler J, et al. A randomized, placebo-controlled, clinical trial of high-dose supplementation with vitamins C and E, beta carotene and zinc for age-related macular degeneration and vision loss: AREDS report no. 8. *Arch Ophthalmol*. 2001;119(10):1417-36.
17. Chew EY, Clemons TE, SanGiovanni JP, et al. Lutein + zeaxanthin and omega-3 fatty acids for age-related macular degeneration: the Age-Related Eye Disease Study 2 (AREDS2) randomized clinical trial. *JAMA*. 2013;309(19):2005-15.
18. SanGiovanni JP, Agrón E, Meleth AD, et al. ω-3 long-chain polyunsaturated fatty acid intake and 12-y incidence of neovascular age-related macular degeneration and central geographic atrophy: AREDS report 30, a prospective cohort study from the Age-Related Eye Disease Study. *Am J Clin Nutr*. 2009;90(6):1601-7.
19. Mance TC, Kovacević D, Alpeza-Dunato Z, et al. The role of omega-6 to omega-3 ratio in development and progression of age-related macular degeneration. *Coll Antropol*. 2011;35(2):307-10.
20. Lawrenson JG, Evans JR. Omega 3 fatty acids for preventing or slowing the progression of age-related macular degeneration. *Cochrane Database Syst Rev*. 2015;2015(4):CD010015.

21. Ma L, Dou HL, Huang YM, et al. Improvement of retinal function in early age-related macular degeneration after Lutein and zeaxanthin supplementation: a randomized, double-masked, placebo-controlled trial. *Am J Ophthalmol*. 2012;154(4):625-34. e1.
22. Beatty S, Chakravarthy U, Nolan JM, et al. Secondary outcomes in a clinical trial of carotenoids with coantioxidants versus placebo in early age-related macular degeneration. *Ophthalmology*. 2013;120(3):600-6.
23. Richer S, Devenport J, Lang JC. LAST II: differential temporal responses of macular pigment optical density in patients with atrophic age-related macular degeneration to dietary supplementation with xanthophylls. *Optometry*. 2007;78(5):213-9.
24. Richer S, Stiles W, Statkute L, et al. Double-masked, placebo-controlled, randomized trial of lutein and antioxidant supplementation in the intervention of atrophic age-related macular degeneration: the Veterans LAST study (Lutein Antioxidant Supplementation Trial). *Optometry*. 2004;75(4):216-29.
25. Evans JR, Lawrenson JG. Antioxidant vitamin and mineral supplements for slowing the progression of age-related macular degeneration. *Cochrane Database Syst Rev*. 2017;2017(7):CD000254.
26. Parravano M, Tedeschi M, Manca D, et al. Effects of Macuprev supplementation in age-related macular degeneration: a double-blind randomized morpho-functional study along six months of follow-up. *Adv Ther*. 2019;36(9):2493-2505.
27. Falsini B, Piccardi M, Iarossi G, et al. Influence of short-term antioxidant supplementation on macular function in age-related maculopathy: a pilot study including electrophysiologic assessment. *Ophthalmology*. 2003;110(1):51-60.
28. Corvi F, Souied EH, Falfoul Y, et al. Pilot evaluation of short-term changes in macular pigment and retinal sensitivity in different phenotypes of early age-related macular degeneration after carotenoid supplementation. *Br J Ophthalmol*. 2017;101(6):770-3.
29. Bartlett H, Eperjesi F. Age-related macular degeneration and nutritional supplementation: a review of randomised controlled trials. *Ophthalmic Physiol Opt*. 2003;23(5):383-99.
30. Ferris FL, Davis MD, Clemons TE, et al. A simplified severity scale for age-related macular degeneration: AREDS Report no. 18. *Arch Ophthalmol*. 2005;123(11):1570-4.
31. Ferris FL, Wilkinson CP, Bird A, et al. Clinical classification of age-related macular degeneration. *Ophthalmology*. 2013;120(4):844-51.
32. Joachim N, Mitchell P, Rochtchina E, et al. Incidence and progression of reticular drusen in age-related macular degeneration: findings from an older Australian cohort. *Ophthalmology*. 2014;121(4):917-25.
33. Gil JQ, Marques JP, Hogg R, et al. Clinical features and long-term progression of reticular pseudodrusen in age-related macular degeneration: findings from a multicenter cohort. *Eye (Lond)*. 2017;31(3):364-71.
34. Pumariega NM, Smith RT, Sohrab MA, et al. A prospective study of reticular macular disease. *Ophthalmology*. 2011;118(8):1619-25.
35. Marsiglia M, Boddu S, Bearely S, et al. Association between geographic atrophy progression and reticular pseudodrusen in eyes with dry age-related macular degeneration. *Invest Ophthalmol Vis Sci*. 2013;54(12):7362-9.
36. Xu L, Blonska AM, Pumariega NM, et al. Reticular macular disease is associated with multilobular geographic atrophy in age-related macular degeneration. *Retina*. 2013;33(9):1850-62.
37. Finger RP, Wu Z, Luu CD, et al. Reticular pseudodrusen: a risk factor for geographic atrophy in fellow eyes of individuals with unilateral choroidal neovascularization. *Ophthalmology*. 2014;121(6):1252-6.
38. Sawa M, Ueno C, Gomi F, Nishida K. Incidence and characteristics of neovascularization in fellow eyes of Japanese patients with unilateral retinal angiomatous proliferation. *Retina*. 2014;34(4):761-7.
39. Ooto S, Ellabban AA, Ueda-Arakawa N, et al. Reduction of retinal sensitivity in eyes with reticular pseudodrusen. *Am J Ophthalmol*. 2013;156(6):1184-91. e2.
40. Ooto S, Suzuki M, Vongkulsiri S, et al. Multimodal visual function testing in eyes with non-exudative age-related macular degeneration. *Retina*. 2015;35(9):1726-34.
41. Querques G, Massamba N, Srour M, et al. Impact of reticular pseudodrusen on macular function. *Retina*. 2014;34(2):321-9.





# WORKING TOGETHER to relieve dry eyes

Clinically proven to reduce the signs and symptoms of dry eyes<sup>1</sup>

**47%**  
improvement  
in symptoms

**20%**  
improvement  
in tear breakup time

**67%**  
reduction  
in number of  
glands blocked

**40%**  
improvement  
in meibum quality

Critical **first steps** to treating dry eye symptoms include ocular lubricants, lid hygiene and dietary modifications such as oral fatty acid supplementation.<sup>2</sup>  
-2017 DEWS II Report



**RESTORES**



**CLEANSES**



**NOURISHES**



More than eye drops,  
dry eye therapy™

[theratears.com/professionals](http://theratears.com/professionals)



**References:** 1. Ngo W, Srinivasan S, Houtman D, Jones L. The relief of dry eye signs and symptoms using a combination of lubricants, lid hygiene and ocular nutraceuticals. *J Optom.* 2017 Jan-Mar;10(1):26-33. 2. Jones L, Downie L, Korb D, et al. TFOS DEWS II Management and Therapy Report. *Ocul Surf.* Jul 2017;15:575-628.  
© 2020 Akorn Consumer Health | A Division of Akorn, Inc. | M16-040-01

Part 2 of 2

# A GLAUCOMA STARTER KIT: THE PATIENT IN YOUR CHAIR

Applying personalized medicine to this chronic disease is critical to ensure the best outcomes.



BY JACK PHU, OD, PhD, AND  
HENRIETTA WANG, BOptom, BSc  
KENSINGTON, NSW, AUSTRALIA

**G**laucoma is a significant public health problem but represents an opportunity for doctors to make a positive impact in long-term eye care. In Part 1 last month, we outlined some of the reasons why an OD would pursue a glaucoma-focused clinic. New technologies and a renaissance of established techniques provide doctors with an incredible arsenal of testing to comprehensively care for patients, to prevent vision loss and quality of life reduction arising from glaucoma.

In Part 2, we take a step into the consulting room and describe the diagnostic and management processes involved in glaucoma.

## The Diagnosis Paradigm

The process of identifying glaucoma is complex, with no single cut-off criterion for diagnosis, unlike other lesion-based diagnoses like age-related macular degeneration and diabetic retinopathy. Although glaucoma is the most common optic neuropathy, it

shares several features with other conditions that also manifest with visual field (VF) defects, loss of neural tissue or changes at the optic nerve. Glaucoma remains a diagnosis of exclusion when assessing suspected optic nerve head disease. Careful inspection of the nerve and surrounding features can help differentiate these conditions.

The common mimickers of glaucoma and their clinical features that overlap with or differentiate each entity from glaucoma are shown in *Table 1*.

To aid this process, we recommend four key considerations in the differential diagnosis of glaucoma:

**1. Patient profile, ocular and medical history.** For example, consider a history of trauma in the context of a pale but intact neuroretinal rim with neural tissue thinning and a VF defect, which points toward a traumatic optic neuropathy rather than glaucoma. Similarly, the patient's age is also helpful, as several optic neuropathies mimicking glaucoma often manifest in younger patients and may point clinicians toward a hereditary or congenital cause instead.

**2. Longitudinal data.** Glaucoma is a progressive optic neuropathy; thus

documented stability in the presence of untreated structural or functional loss precludes glaucoma as a diagnosis. In cases such as myopic optic neuropathy where there is significant overlap in the clinical presentation, longitudinal data is key for differentiating between these disease entities and can prevent unnecessary treatment.<sup>1</sup>

**3. "Characteristic" changes to the optic nerve and peripapillary region.** A defining feature of glaucoma is presence of neuroretinal rim thinning. As such, loss of neural tissue (*e.g.*, nerve fiber layer thinning) in the absence of visible optic nerve head changes points towards a non-glaucomatous etiology.<sup>2</sup> Pallor of the nerve head is also not a classic feature of glaucoma and warrants investigation into other causes of optic atrophy. These signs should signal the need for further neuro-ophthalmic assessment, such as color vision.

Optical coherence tomography angiography (OCT-A) is also useful in evaluating non-glaucomatous optic neuropathies, as it can highlight vascular changes that are not visible using traditional OCT or funduscopically. Although glaucoma has been shown

### About the authors

**Dr. Phu** is a clinician-scientist with academic and clinical positions at the Centre for Eye Health in Kensington, New South Wales, Australia, and the School of Optometry and Vision Science, University of New South Wales. He is a Fellow of the American Academy of Optometry and a Diplomate in glaucoma. **Dr. Wang** is a research and clinical staff optometrist at the Centre for Eye Health. She is a Fellow of the AAO. They have no financial interests to disclose.

to result in a reduction in OCT-A parameters such as vessel density, this typically does not occur until later in the disease process. A marked reduction in vessel density in the presence of shallow neuroretinal rim loss points to an ischemic or congenital condition rather than glaucoma (*Figure 1*).

**4. The pattern of structural and functional loss.** Retrograde degeneration presents with classic patterns of both structural and functional loss, which allow for retinotopic mapping to the location of insult. Carefully scrutinize patients presenting with midline respecting structural or functional loss for a non-glaucomatous etiology and consider neuroimaging to investigate other diseases of the visual pathway.<sup>3</sup>

Paradigm shifts in glaucoma diagnosis have arisen with the changing availability of specific devices or techniques such as fast VF testing and progression analysis, high resolution structural examination and intraocular pressure (IOP) profiling. Improved understanding of the multifactorial pathophysiology of glaucoma has also underscored the need to perform other non-ocular assessments to rule out contributions from systemic and non-ocular comorbidities.

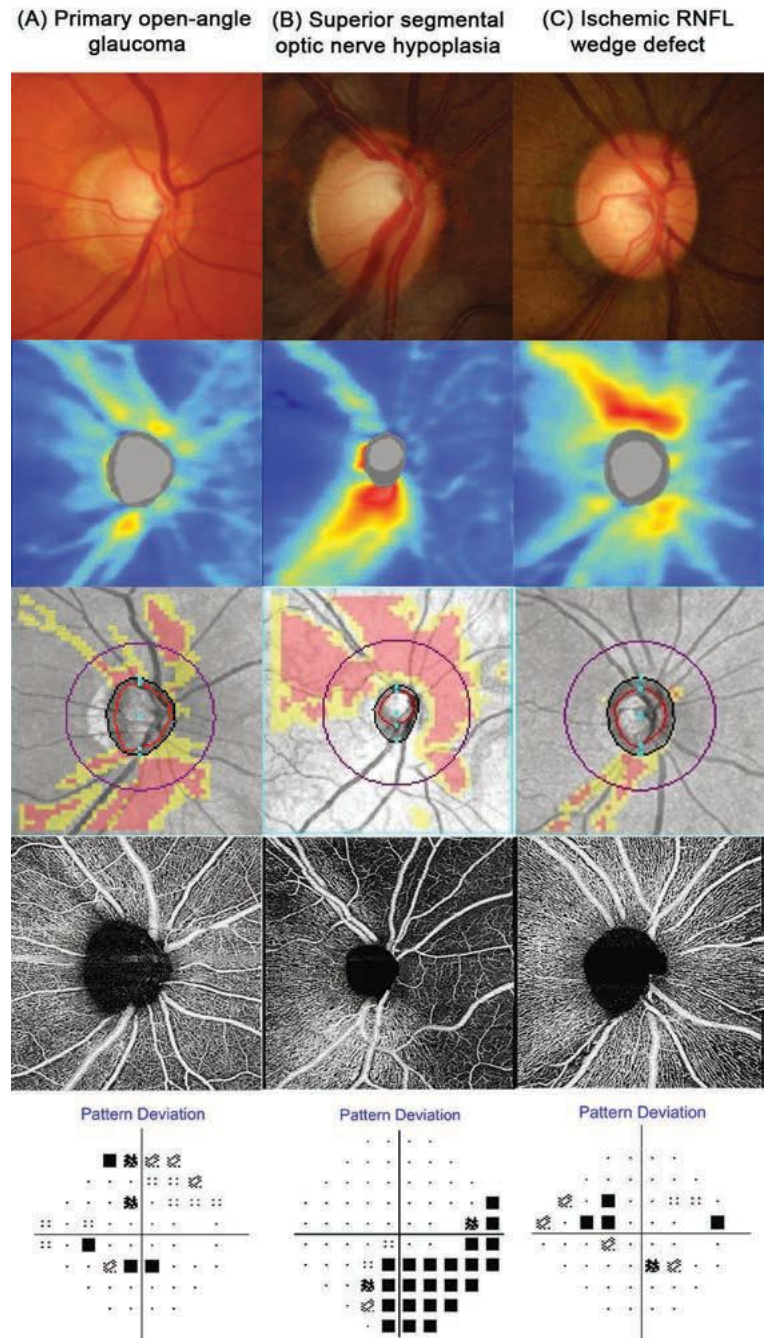
## Personalized Medicine

After a diagnosis is made, the doctor should then develop a management plan with the patient and the rest of the health care team.<sup>4</sup> A commonly deployed treatment algorithm in the past is shown in *Figure 2A*, which demonstrates the concept of treatment escalation with increasingly invasive IOP-lowering therapies. A more recent stepwise algorithm that we have suggested is shown in *Figure 2B*. In the updated algorithm, several significant changes to clinical care are highlighted:

1. Determining the need for treatment.
2. Preservative-free drops as primary therapy.
3. Primary laser (or non-drop) therapy.
4. Emerging surgical options as first-line treatment.

**Does the patient even require treatment?** One of the biggest changes in recent years is the concept of the need for therapy. The trajectory of glaucoma differs for each patient. The seminal Early Manifest Glaucoma Trial gave clinicians important information about the natural history of glaucoma.<sup>5</sup> From those results we know that pseudoexfoliative glaucoma tends to progress the quickest, followed by high-tension glaucoma and then normal-tension glaucoma as the slowest. However, even within the separate groups of glaucoma subtypes, there is significant variability. Therefore, it is incumbent on the clinician to determine the trajectory of their individual patient.

The importance of disease trajectory lies in the fundamental reasons for treating glaucoma: to preserve vision and maintain quality of life. In cases where the patient's disease trajectory is not likely to significantly

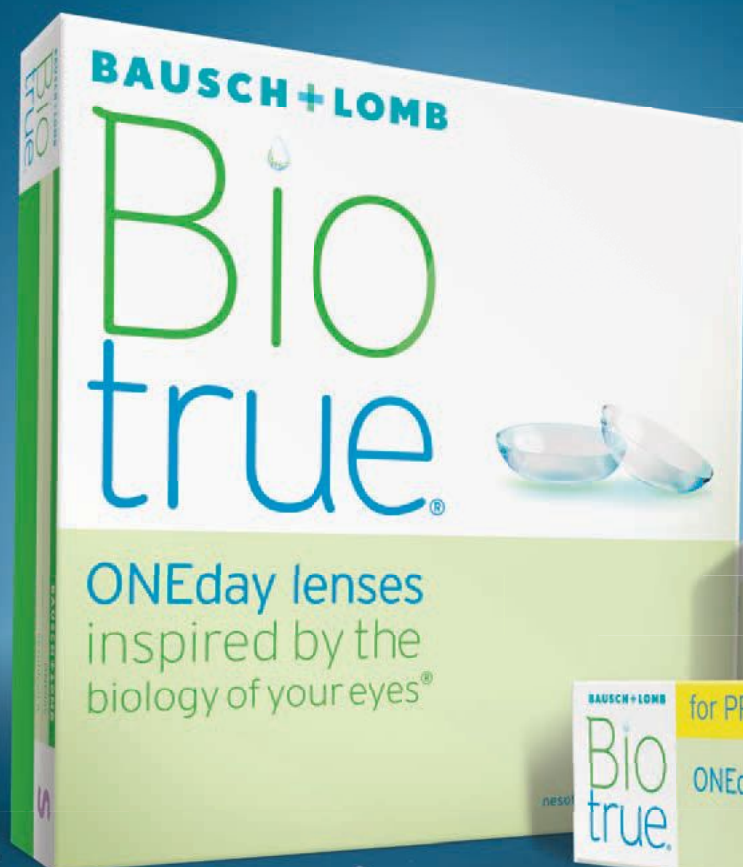

**Fig. 1. Funduscopy and OCT findings for three contrasting patients:**  
**(A)** A patient with classic primary open-angle glaucoma. This disc appears cupped with a gradient of retinal nerve fiber layer loss and a shallow reduction in perfusion on OCT-A.  
**(B)** A patient with superior segmental optic nerve hypoplasia. This disc has a sharply delineated absence of neural tissue in the superior rim, with a marked loss of nerve fiber layer, perfusion and visual function. The sectoral nature of the loss in addition to the attenuation and absence of retinal vasculature is indicative of a congenital vascular anomaly rather than glaucoma.  
**(C)** A patient with an ischemic retinal nerve fiber layer defect. Unlike in patient A, the neuroretinal rim appears intact and is thus incompatible with glaucoma. Supplementary imaging using OCT-A confirms a very deep and focal loss of perfusion that is not typical in early glaucoma as implied by the shallow VF defect and little neural loss.



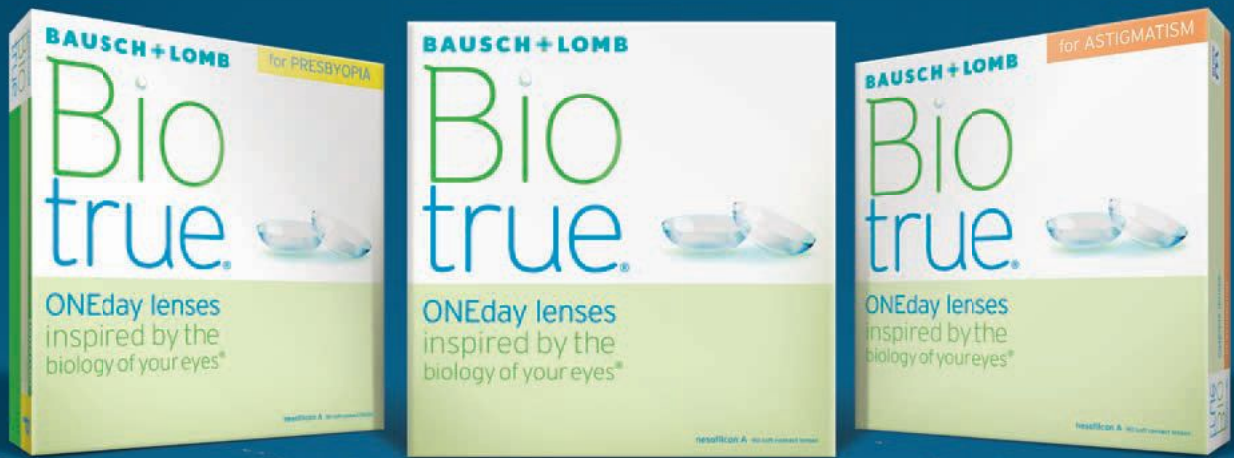# DISCOVER THE LENS WITH THE

# MOST



Biotrue® ONEday—The daily disposable with the **most moisture** and **toric parameters** among leading brands, with a family of lenses that offer **exceptional performance and value.**





Look no further than Biotrue® ONEday—the lens with a smart combination of performance and value.

	Biotrue® ONEday	DAILIES AquaComfort Plus	1-DAY ACUVUE MOIST
MOISTURE CONTENT	78%	69%	58%
TEAR FILM STABILITY <sup>1</sup>	18.9 sec	12.5 sec	13.6 sec
Dk/t*	42	26	25
SPHERICAL ABERRATION CONTROL <sup>†</sup>	✓		
STANDARD -2.75 CYLINDER OFFERING	✓		
CONSISTENT \$200 REBATE FOR ALL PATIENTS <sup>‡</sup>	✓		

\*Oxygen levels for single vision (SVS) lenses only.

†In SVS and toric lenses only.

‡Based on total rebate amount offered to customers ordering an annual supply of Biotrue® ONEday for 3 consecutive years. Terms and conditions apply. See full terms and conditions at [www.BauschRewards.com](http://www.BauschRewards.com).

REFERENCE: 1. Results of a randomized, masked evaluation of the non-invasive tear break-up time (NITBUT) measured using an Oculus Keratograph 5M after 10 hours of wear. Twelve subjects wore one pair of lenses per day on 6 individual days. Data represents the mean of measured "average" NITBUT.

Biotrue and inspired by the biology of your eyes are trademarks of Bausch & Lomb Incorporated or its affiliates.

Any other products/brand names and/or logos are trademarks of the respective owners.

©2021 Bausch & Lomb Incorporated or its affiliates. BOD.0030.USA.21

**BAUSCH + LOMB**  
See better. Live better.

**TABLE 1. CLINICAL FEATURES OF OPTIC NEUROPATHIES THAT MIMIC THE APPEARANCE OF GLAUCOMA**

CONDITION	OVERLAPPING FEATURES WITH GLAUCOMA	DIFFERING FEATURES WITH GLAUCOMA
<b>Myopic optic neuropathy</b>	<ul style="list-style-type: none"> <li>- Loss of the neuroretinal rim with associated nerve fiber layer and ganglion cell thinning</li> <li>- Concordant VF defect(s)</li> </ul>	<ul style="list-style-type: none"> <li>- Nonprogressive</li> </ul>
<b>Traumatic optic neuropathy</b>	<ul style="list-style-type: none"> <li>- Typically unilateral nerve fiber layer and ganglion cell thinning</li> <li>- Concordant VF defect(s)</li> </ul>	<ul style="list-style-type: none"> <li>- History of trauma</li> <li>- Intact but pale neuroretinal rim</li> <li>- Non-progressive</li> </ul>
<b>Ischemic optic neuropathies</b>	<ul style="list-style-type: none"> <li>- Optic disc cupping (common in anterior ischemic optic neuropathy)</li> <li>- Nerve fiber and ganglion cell layer thinning can be focal or diffuse</li> <li>- Concordant VF defect(s)</li> </ul>	<ul style="list-style-type: none"> <li>- Current or previous disc edema</li> <li>- Neuroretinal rim pallor or chalky white disc</li> <li>- Marked reduction in capillary density using OCT-A</li> <li>- Nonprogressive</li> </ul>
<b>Hereditary optic neuropathies</b>	<ul style="list-style-type: none"> <li>- Bilateral nerve fiber and ganglion cell layer thinning</li> <li>- Concordant VF defect(s)</li> </ul>	<ul style="list-style-type: none"> <li>- Positive family ocular history</li> <li>- Early onset—atypical patient profile</li> <li>- Neuroretinal rim pallor</li> </ul>
<b>Congenital optic neuropathies</b>	<ul style="list-style-type: none"> <li>- Loss of the neuroretinal rim with associated nerve fiber layer and ganglion cell thinning</li> <li>- Concordant VF defect(s)</li> </ul>	<ul style="list-style-type: none"> <li>- Nonprogressive</li> <li>- Topless disc appearance</li> <li>- Sharp demarcation between normal and abnormal VF</li> <li>- Marked reduction in vessel density using OCT-A</li> </ul>
<b>Retrograde degeneration</b>	<ul style="list-style-type: none"> <li>- Nerve fiber and ganglion cell layer thinning</li> </ul>	<ul style="list-style-type: none"> <li>- Vertical midline respecting pattern of loss</li> <li>- Neuroretinal rim pallor</li> </ul>
<b>Compressive/infiltrative</b>	<ul style="list-style-type: none"> <li>- Nerve fiber and ganglion cell layer thinning</li> </ul>	<ul style="list-style-type: none"> <li>- Current or previous disc edema</li> <li>- Peripapillary hemorrhages or exudates</li> <li>- Neuroretinal rim pallor</li> <li>- Meningeal and optic nerve enhancement with orbit MRI</li> </ul>
<b>Inflammatory</b>	<ul style="list-style-type: none"> <li>- Nerve fiber and ganglion cell layer thinning</li> </ul>	<ul style="list-style-type: none"> <li>- Neuroretinal rim pallor</li> <li>- Current or previous disc edema</li> <li>- Relative afferent pupillary defect</li> </ul>

affect their quality of life, any activated treatment may conversely lead to a reduction in quality of life. Other considerations include the costs of treatment. In such cases, there may be a reason to monitor without treatment to mitigate these issues.

**Preserved or non-preserved?** Traditionally, topical therapy has been the mainstay, first-line treatment for glaucoma, with prostaglandin analogs preferred

due to their convenient once-daily dosing and favorable safety profile.

However, benzalkonium chloride in glaucoma drugs is known to detrimentally affect the ocular surface, especially with long-term use.<sup>6,7</sup> Preservative-free formulations have been suggested as an alternative. Recent studies have shown that preservative-free medications are similarly effective.<sup>8-10</sup> Therefore, clinicians should weigh the potential

advantages and disadvantages of both formulations before proceeding.

**SLT as first-line.** In suitable patients, selective laser trabeculoplasty (SLT) may be a viable first-line treatment that addresses fundamental issues with topical therapy such as compliance and adverse effects.<sup>11</sup> While the benefits of SLT are clear, doctors should remember that, in patients with IOP lower than 21mm Hg (*i.e.*, normal-tension glaucoma), the amount of IOP reduction achieved using SLT was lower. Some studies have shown that at pressure levels below 15mm Hg, the probability of success is less than 30%.<sup>12-14</sup>

Compared with medical therapy, SLT runs the risk of being an episodic point-of-care that may lead to patient non-adherence to follow-up.<sup>15</sup> Remind patients of the importance of review appointments, even if everything seems fine from their perspective.

### Referrals and Communication

A successful glaucoma practice involves effective communication intra-professionally and inter-professionally.<sup>16,17</sup> Clinicians who are just starting off may find it useful to obtain feedback from their optometry or ophthalmology peers, especially with unusual presentations or complex cases.<sup>18</sup> Establishing a glaucoma clinic requires forging relationships with glaucoma specialists and understanding the services that they may offer. Even the patient’s primary care physician requires regular updates on the patient’s ocular status.

Our top tips for referrals and communications within and between professions are shown in *Table 2*.

### Monitoring Visits

Typically, review periods may range from three months to one year, depending on the individual’s risk of progression.<sup>19-21</sup> Rubrics for assessing risk or risk calculators (such as from the Ocular Hypertension Treatment Study) are accessible, but remember that individuals do not necessarily fall into the typical mold.<sup>22</sup> Examples of considerations for clinicians in risk titration include:



**Demographics:** Age, ethnicity and gender may not match the clinical trial or guideline that you are deploying.

**Financial constraints:** Are patients able to financially afford frequent review visits?

**Travel/distance constraints:** Are patients able to practically attend appointments during typical work hours?

**Clinic workflow and capacity constraints:** Does the clinic have the capacity to review these patients on a more frequent basis?

**Risk of glaucoma-related consequences:** What is the patient's risk of vision loss and impairment of quality of life? Where does this stand relative to other factors such as morbidity and mortality?

**Medication prescriptions:** Typically, six-month review periods are recommended in many clinics due to the need for repeat prescriptions—however, can this be done in other ways?

The goal of these follow-up visits is to identify significant disease progression. There needs to be a balance between the anticipated diagnostic yield (more likely to see the “right patient at the right time”) and having potentially wasteful and costly review appointments.

## Follow-up Consultation

Tests that identify markers of progression should include both structural and functional components, as patients may show progression on either or both indices.<sup>23,24</sup> Be prepared to take an updated medical history to identify contributory risk factors for glaucoma. These may include new diagnoses of other concurrent systemic disease, new meds and newly discovered family history of glaucoma.

IOP measured at follow-up visits may provide additional data regarding the patient's IOP profile.

Fluctuations or significant elevations may signal the need for closer monitoring or earlier intervention.

Guidelines for repeating gonioscopy or anterior chamber angle assessment also provide a broad range of recommendations. It is fairly well-established that the anterior chamber angle narrows with age, increasing the risk of angle closure.<sup>25</sup> Pseudoexfoliation, the most common identifiable cause of secondary open-angle glaucoma, also has a tendency to increase in prevalence with age.<sup>26</sup> Since it is unlikely that these issues manifest within a short time frame, it would be appropriate to repeat gonioscopy about every two years, with routine screening at visits in between.

Be vigilant for any changes that may signal the need for treatment plan modifications. Examples could include:

**Unreliable VF results at the last visit:** The key is to identify repeatable VF progression at the next visit.

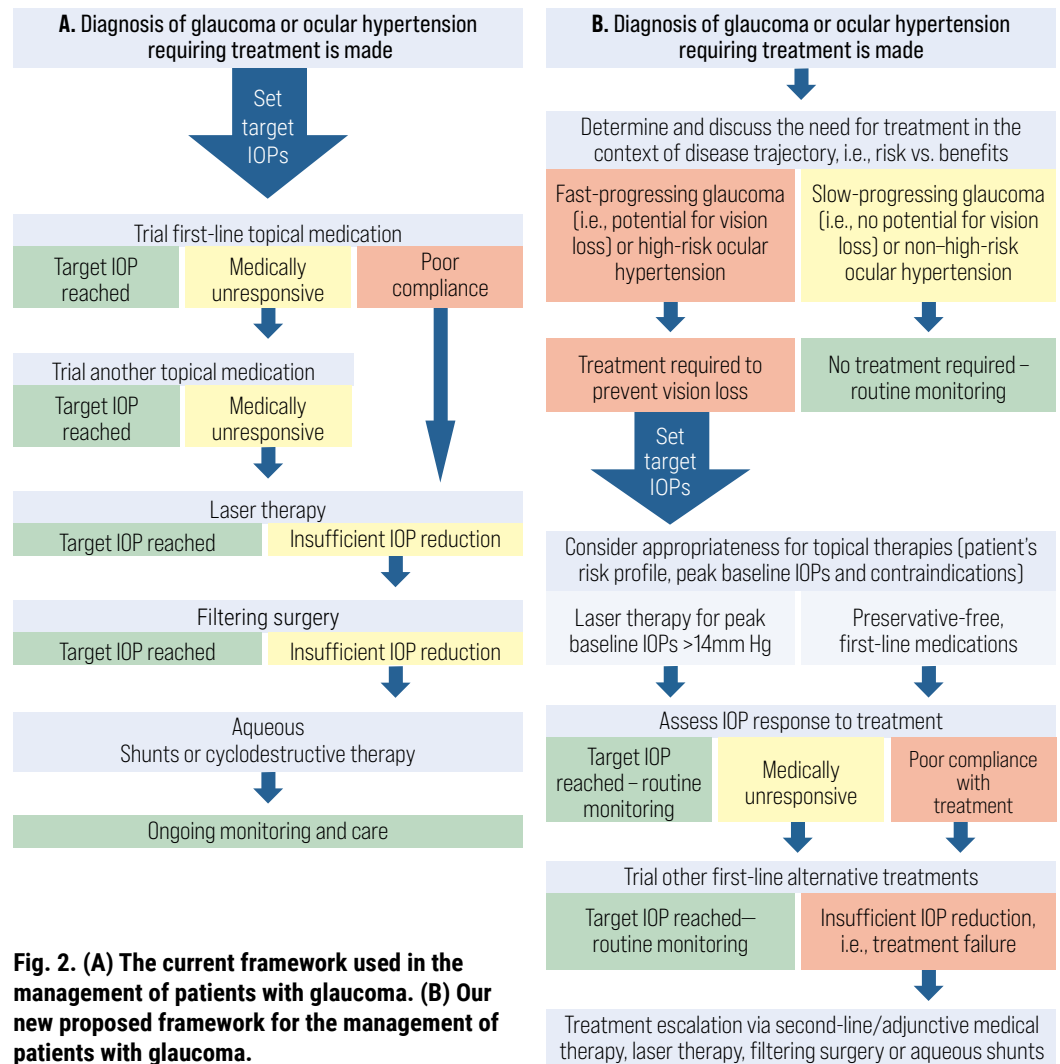
**A disc hemorrhage at the previous visit:** The next visit will specifically target the identification of consequent structural or functional loss.

**IOP was not quite meeting target, but there was no structural or functional progression:** The next visit may be to reassess to see if target pressure is met.

## Progression Analysis

An advantage of quantitative assessment techniques such as standard automated perimetry and OCT is the ability to quantify changes and perform regression analyses to identify statistically significant progression over time.

Although quantitative values are a useful indicator to identify trends, as with all similar measurements there are



**Fig. 2. (A) The current framework used in the management of patients with glaucoma. (B) Our new proposed framework for the management of patients with glaucoma.**

**TABLE 2. TOP TIPS FOR REFERRALS AND COMMUNICATION WITHIN AND BETWEEN PROFESSIONS**

TIP	RECOMMENDATION	EXAMPLE OF EFFECTIVE COMMUNICATION	EXAMPLE OF POOR COMMUNICATION
<b>Write clearly.</b>	Avoid ambiguity in handwriting. Having proformas with highlighted relevant sections and bolded headings can make it easier to read, with subsequent clinicians being able to target specific information.	Clear headings at the beginning of your letter: “Diagnosis: Glaucoma Management plan: Initiated therapy with latanoprost both eyes Review period: Six weeks”	Buried text somewhere in the middle or bottom of the letter: “The patient has high pressures, so I have initiated therapy with latanoprost BE. I will review in 6/52.”
<b>Include all relevant investigations.</b>	Sometimes a patient will have long historical records. Have a concise presentation of records for subsequent clinicians. Initially, it may include the progression analysis and the latest cross-sectional data up to that point, but a clinician may request older data sets.	Including the progression analysis of the OCT circumpapillary retinal nerve fiber layer scans, as well as those from today’s visit.	Not including any scan results because printing is expensive, especially with color.
<b>Referral and communications should be contemporaneous.</b>	Clinicians are busy, but clinical records are best when they are contemporaneous. Communications should be reflective of these investigations.	Sending letters within a few days of the consultation, as well as ensuring that the content is reflective of the day’s results.	Waiting months to send a letter, and forgetting important information because it has been so long since the consultation.
<b>For referrals, include a management arrangement.</b>	For early-career optometrists, it is sometimes tempting to discharge or be wary about being proactive in communication. To enhance your glaucoma clinic have a proactive approach in developing a plan for patients.	At the bottom of the referral letter: “I have discussed this diagnosis with Patient X and have recommended SLT as a treatment option. I would be happy to review their pressures, discs and fields after they undergo the procedure with you.”	At the bottom of the referral letter: “I have discussed this diagnosis with Patient X and hence I am referring them to you for treatment.”
<b>Avoid unnecessary abbreviations or jargon for non-ophthalmic practitioners.</b>	The health care team may include non-ophthalmically-trained practitioners. Instead of defaulting to abbreviations that may be eye-specific, it may be more effective to spell out communications where relevant, so there are fewer ambiguities.	“Diagnosis: right primary open-angle glaucoma.” “The right neuroretinal rim was thin, superiorly worse than inferiorly.”	“Dx: POAG RE” “The OD NRR was thin, sup>inf.”
<b>Promote evidence-based practice in communications.</b>	As the field is rapidly evolving, it may be useful to include references to the latest and/or pertinent literature to demonstrate your attentiveness and adherence to evidence-based practice.	“The results of the recently published ZAP trial suggest that this primary angle-closure suspect can be monitored instead of treated at this stage.”	“I feel that this patient can be monitored at this stage.”

sources of variability that may confound the final result. Many clinicians complain about VF testing for being highly subjective and therefore variable. Sources of variability include intra-session fatigue, inter-session learning and the patient’s mental state.<sup>27,28</sup> However, although OCT may be more objective than perimetry, it also has sources of variability that manifest in the form of artifacts: either instrument-related (internal noise), acquisition-related or patient-related.<sup>29</sup>

Aside from these sources of variability, spacing out tests and monitoring of a patient over a long period of time introduces aging to the progression analysis. The clinician needs to be able to identify a significant change

that overcomes the normal age-related decline in both VF sensitivity and neural thickness. One strategy is to use the output rate of change and put it in context of the patient’s age: at this rate of progression, will the patient likely lose significant vision in their lifetime, and when might this happen?

Aside from quantitative analyses of VF sensitivity and retinal thickness data, comparisons of serial fundus photos may also be useful for qualitative identification of structural change. Fundus photography may also reveal the presence or absence of a disc hemorrhage.

Whilst disc hemorrhages have been considered to be a marker for glaucoma progression, disc hemorrhages have

been recognized to occur spontaneously or as part of the natural history of glaucoma, not necessarily representing a more aggressive course of the disease.<sup>30</sup> Thus, these patients require more monitoring for identifying realized structural and functional loss.

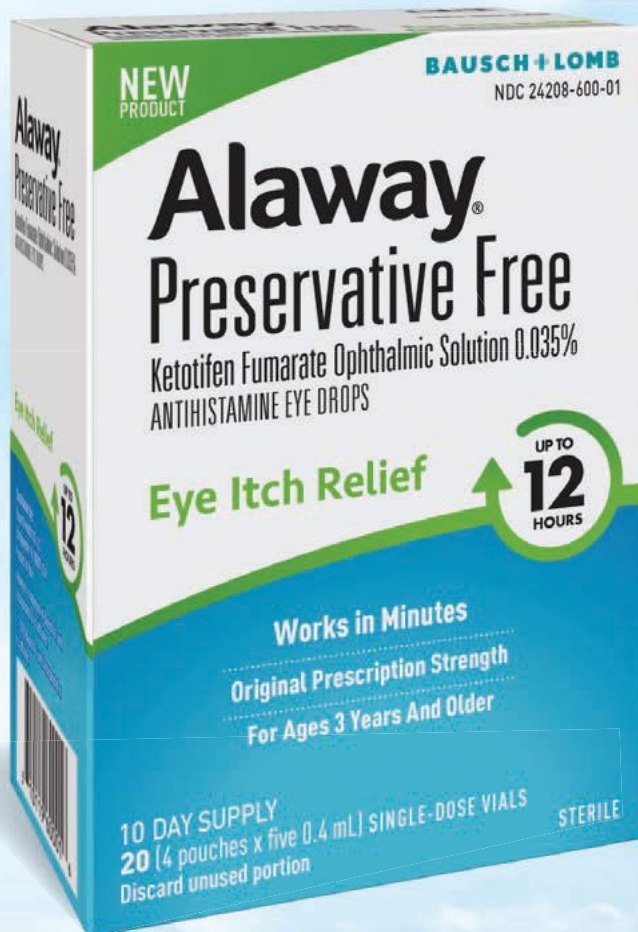Remember, structural and functional examination results indicate the endpoints for glaucoma. IOP control is best described as a predictor for risk of future progression. IOP reductions that have not met target, or are in isolation, are not indicators of disease progression, but they must be considered in the context of structure and function. In some cases, over-aggression of IOP control may not be required in a stable glaucoma patient.

**NEW!**

# ONE-OF-A-KIND

## PRESERVATIVE-FREE

# EYE ITCH RELIEF



The **FIRST** and **ONLY**  
FDA-approved OTC  
*preservative-free*  
antihistamine eye drops

- ✓ RELIEVES SYMPTOMS AT THE SOURCE, WITH LESS IRRITATION<sup>1</sup>
- ✓ WORKS IN MINUTES, LASTS UP TO 12 HOURS<sup>1,2</sup>
- ✓ ORIGINAL PRESCRIPTION STRENGTH

**Recommend ALAWAY Preservative Free!**

Now available at Amazon, CVS, Walgreens, & Walmart.

Visit [alaway.com](http://alaway.com) for more information. | Call **800-871-1103** for patient coupons.

References: 1. Torkildsen GL, et al. *Clin Ther*. 2008;30(7):1272-1282. doi:10.1016/j.clinther.2008.08.005-3 2. Data on file.  
Alaway is a trademark of Bausch & Lomb Incorporated or its affiliates. © 2021 Bausch & Lomb Incorporated or its affiliates. PN09876 APF0015.USA.21

**BAUSCH + LOMB**



Similar to diagnosis, progression analysis requires a combinatorial approach to identify the “tipping point” at which a patient converts from a glaucoma suspect to manifest glaucoma, or is identified as a glaucoma progressor. Unfortunately, identification of progression may be as much an art as it is a science. Often, a single test within a suite is insufficient to convince a clinician that a change in treatment plan is required, especially when that test is known to have variable results. Several research groups have suggested that changes occurring in glaucoma may appear in different tests, depending on the stage of the disease.<sup>31</sup> Broadly, in early glaucoma OCT has been suggested to be superior to perimetry, and in late glaucoma perimetry, especially 10-2, may be more useful. However, there is an overall lack of consensus regarding what constitutes significant change.

However, if a clinician considers that the goal of glaucoma treatment is to prevent irreversible blindness and impairment to quality of life, there may be a rationale for emphasizing perimetric changes over structural loss. This philosophy stems from the notion that VF results are better reflective of the patient’s functional vision and quality of life, and thus represents the “real-world” impact of the disease.

In the present clinical environment, how might one confidently identify perimetric loss, given its notoriety for variability? Recent developments in automated perimetry have targeted more efficient ways of testing, with strategies such as reduced test time, scotoma targeting and seeding with structural data.<sup>32-34</sup> Some of these strategies have arrived in clinical practice, and fast testing methods allow clinicians to perform more examinations per visit, thereby overcoming the variability arising from having fewer data points.

## Changing Management Strategy

Once change has been satisfactorily identified using the tools available in your office, you might wonder what the next step for the patient is. Many

authoritative guidelines have provided guidance on management algorithms. For example, a typical flowchart approach might begin with either a first-line topical medication or SLT; treatment escalation would be followed by topical medications in a step-wise approach of intensity, before arriving at surgical intervention.

Clinicians need to be aware of the side effect profiles of each treatment paradigm, as the decision to escalate should involve a balancing of the potential threat to vision against detriments to quality of life potentially arising from more intense therapy.

## Takeaways

In this two-part article, we have provided an overview of the steps required for the beginner to start a glaucoma clinic. Hopefully, this has demonstrated that whilst there are a lot of considerations in glaucoma, it is also potentially intellectually stimulating. Most importantly, the doctor becomes an integral caregiver for the patient, who in turn can become a long-term, loyal attendee of the practice. ■

1. Hsu CH, Chen RI, Lin SC. Myopia and glaucoma: sorting out the difference. *Curr Opin Ophthalmol*. 2015;26(2):90-5.
2. Leaney JC, Nguyen V, Miranda E, et al. Bruch’s membrane opening minimum rim width provides objective differentiation between glaucoma and nonglaucomatous optic neuropathies. *Am J Ophthalmol*. 2020;218:164-72.
3. Zangerl B, Whatham A, Kim J, et al. Reconciling visual field defects and retinal nerve fiber layer asymmetric patterns in retrograde degeneration: an extended case series. *Clin Exp Optom*. 2017;100(3):214-26.
4. Phu J, Agar A, Wang H, et al. Management of open-angle glaucoma by primary eye-care practitioners: toward a personalised medicine approach. *Clin Exp Optom*. 2020.
5. Heijl A, Bengtsson B, Hyman L, et al. Natural history of open-angle glaucoma. *Ophthalmology*. 2009;116(12):2271-6.
6. Fogagnolo P, Torregrossa G, Tranchina L, et al. Tear film osmolarity, ocular surface disease and glaucoma: a review. *Curr Med Chem*. 2019;26(22):4241-52.
7. Boimer C, Birt CM. Preservative exposure and surgical outcomes in glaucoma patients: the PESO study. *J Glaucoma*. 2013;22(9):730-5.
8. Aptel F, Pfeiffer N, Schmickler S, et al. Noninferiority of preservative-free vs. BAK-preserved latanoprost-timolol fixed combination eye drops in patients with open-angle glaucoma or ocular hypertension. *J Glaucoma*. 2019;28(6):498-506.
9. Aptel F, Choudhry R, Stalmans I. Preservative-free vs. preserved latanoprost eye drops in patients with open-angle glaucoma or ocular hypertension. *Curr Med Res Opin*. 2016;32(8):1457-63.
10. Day DG, Walters TR, Schwartz GF, et al. Bimatoprost 0.03% preservative-free ophthalmic solution versus bimatoprost 0.03% ophthalmic solution (Lumigan) for glaucoma or ocular hypertension: a 12-week, randomised, double-masked trial. *Br J Ophthalmol*. 2013;97(8):989-93.
11. Gazzard G, Konstantakopoulou E, Garway-Heath D, et al. Selective laser trabeculoplasty versus eye drops for first-line treatment of ocular hypertension and glaucoma (LiGHT): a multicentre

- randomised controlled trial. *Lancet*. 2019;393(10180):1505-16.
12. Pillunat KR, Spoerl E, Elfes G, Pillunat LE. Preoperative intraocular pressure as a predictor of selective laser trabeculoplasty efficacy. *Acta Ophthalmol*. 2016;94(7):692-6.
13. Mao AJ, Pan XJ, Mollrath I, et al. Development of a prediction rule to estimate the probability of acceptable intraocular pressure reduction after selective laser trabeculoplasty in open-angle glaucoma and ocular hypertension. *J Glaucoma*. 2008;17(6):449-54.
14. Martow E, Hutnik CM, Mao A. SLT and adjunctive medical therapy: a prediction rule analysis. *J Glaucoma*. 2011;20(4):266-70.
15. Clement CI. Initial treatment: prostaglandin analog or selective laser trabeculoplasty. *J Curr Glaucoma Pract*. 2012;6(3):99-103.
16. Cheng J, Beltran-Agullo L, Trope GE, Buys YM. Assessment of the quality of glaucoma referral letters based on a survey of glaucoma specialists and a glaucoma guideline. *Ophthalmology*. 2014;121(1):126-33.
17. Tobin-Schnittger P, O’Doherty J, O’Connor R, O’Regan A. Improving quality of referral letters from primary to secondary care: a literature review and discussion paper. *Prim Health Care Res Dev*. 2018;19(3):211-22.
18. Gagliardi A. Use of referral reply letters for continuing medical education: a review. *J Contin Educ Health Prof*. 2002;22(4):222-9.
19. National Health and Medical Research Council. Guidelines for the screening, prognosis, diagnosis, management and prevention of glaucoma. Internet: Commonwealth of Australia, 2010.
20. National Institute for Health and Care Excellence. Glaucoma: diagnosis and management. London, UK: National Institute for Health and Care Excellence; 2019.
21. Prum BE, Jr., Lim MC, Mansberger SL, et al. Primary open-angle glaucoma suspect preferred practice pattern guidelines. *Ophthalmology*. 2016;123(1):P112-51.
22. Ocular Hypertension Treatment Study G, European Glaucoma Prevention Study G, Gordon MO, et al. Validated prediction model for the development of primary open-angle glaucoma in individuals with ocular hypertension. *Ophthalmology*. 2007;114(1):10-9.
23. Medeiros FA. Biomarkers and Surrogate Endpoints: Lessons learned from glaucoma. *Invest Ophthalmol Vis Sci*. 2017;58(6):B1020-6.
24. Ohnell H, Heijl A, Brenner L, et al. Structural and functional progression in the early manifest glaucoma trial. *Ophthalmology*. 2016;123(6):1173-80.
25. Phu J, Tong J, Zangerl B, et al. Cluster analysis reveals patterns of age-related change in anterior chamber depth for gender and ethnicity: clinical implications. *Ophthalmic Physiol Opt*. 2020;40(5):632-49.
26. Ekstrom C, Winblad von Walter L. Incidence and baseline risk factors for pseudoxfoliation in Sweden: a long-term follow-up study. *Acta Ophthalmol*. 2020;98(3):310-4.
27. Marra G, Flammer J. The learning and fatigue effect in automated perimetry. *Graefes Arch Clin Exp Ophthalmol*. 1991;229(6):501-4.
28. Hudson C, Wild JM, O’Neill EC. Fatigue effects during a single session of automated static threshold perimetry. *Invest Ophthalmol Vis Sci*. 1994;35(1):268-80.
29. Li A, Thompson AC, Asrani S. Impact of artifacts from optical coherence tomography retinal nerve fiber layer and macula scans on detection of glaucoma progression. *Am J Ophthalmol*. 2021;221:235-45.
30. Kim KE, Park KH. Optic disc hemorrhage in glaucoma: pathophysiology and prognostic significance. *Curr Opin Ophthalmol*. 2017;28(2):105-12.
31. Medeiros FA, Zangwill LM, Bowd C, et al. The structure and function relationship in glaucoma: implications for detection of progression and measurement of rates of change. *Invest Ophthalmol Vis Sci*. 2012;53(11):6939-46.
32. Turpin A, Morgan WH, McKendrick AM. Improving Spatial Resolution and Test Times of Visual Field Testing Using ARREST. *Transl Vis Sci Technol*. 2018;7(5):35.
33. Chong LX, Turpin A, McKendrick AM. Targeted spatial sampling using GOANNA improves detection of visual field progression. *Ophthalmic Physiol Opt*. 2015;35(2):155-69.
34. Phu J, Khuu SK, Agar A, Kalloniatis M. Clinical Evaluation of Swedish interactive thresholding algorithm-faster compared with Swedish interactive thresholding algorithm-standard in normal subjects, glaucoma suspects and patients with glaucoma. *Am J Ophthalmol*. 2019;208:251-64.

INTRODUCING

# ACUVUE® OASYS MULTIFOCAL

WITH PUPIL OPTIMIZED DESIGN

## A New Solution for a Growing Issue: Innovative Multifocal Contact Lens for Patients with Presbyopia



You know the vision changes presbyopia brings, but do your patients understand what they're experiencing? While you know multifocal contact lenses are a great vision-correcting option, patients have low awareness of the condition of presbyopia and even lower knowledge of their options. They don't know to ask you about those options, and the impact is real: over 50% of wearers over the age of 45 will discontinue use of contact lenses within the first year of wear as they develop presbyopia!<sup>1</sup>

Performance and comfort with a quick and easy fit is now within reach with new ACUVUE® OASYS MULTIFOCAL with PUPIL OPTIMIZED DESIGN. This 2-week reusable contact lens combines three unique technologies designed to deliver crisp, clear, reliable vision. Pupil Optimized Design is the ONLY technology that uniquely optimizes the optical design to the pupil size according to age AND refractive power, making the optics the right size.<sup>2</sup> The hybrid back curve design includes an aspheric center to keep the complex front-surface optics in the right shape, and a spherical periphery to keep optics in the right place.<sup>3</sup> Plus, patients get all the comfort you'd expect from the ACUVUE® OASYS Brand family, which has never been beaten in comfort across 25 clinical studies.\*

"When patients struggle with ocular discomfort and need multifocal correction, we rely on ACUVUE® technology... the material really makes a difference," shared Shane Kannarr,<sup>4</sup> O.D. and owner of Kannarr Eye Care in Pittsburg, Kansas.

And now, Pupil Optimized Technology is available on both the #1 selling daily disposable and reusable contact lens

brands in the world – 1-DAY ACUVUE® MOIST and ACUVUE® OASYS 2-Week – with the same simple fit process across both brands.<sup>†</sup> Just use the **ACUVUE® MULTIFOCAL Fit Guide** to achieve over a 94% success rate in two pairs of lenses of less!<sup>§4,5</sup>

"We want success early in fitting multifocal lenses and we see the swiftest and best success with ACUVUE® products and their tools, such as the multifocal fit guide and digital fit calculator,<sup>‡</sup> which lets us find what works for the patient quicker," Dr. Kannarr continued.

Using the calculator for a quick and easy fit and having the option of daily disposable or reusable modalities enables providers to prescribe according to the patient's needs. **Now, you can fit the multifocal lens to the patient, since 100% of parameters are tailored to pupil size variations across age and refraction vs. <2% for the leading competitor.\*\*2**

"It's easier to have those conversations when I have a lens that my OASYS 2-Week patients can more easily graduate into. This is a better option for my price-sensitive patients that should satisfy the majority of their vision-correction needs long-term," finished Dr. Kannarr.

Check out how the newest multifocal innovation can impact your presbyopic patients' lives. ACUVUE® OASYS MULTIFOCAL with PUPIL OPTIMIZED DESIGN contact lenses are now available. Talk to your Johnson & Johnson Vision sales representative today!

\* www.clinicaltrials.gov is a website maintained by the NIH. The 25 clinical studies evaluated subjective comfort as a primary or secondary endpoint for ACUVUE® OASYS Brand 2-week and ACUVUE® OASYS with Transitions™ Light Intelligent Technology™. Review conducted as of November 12, 2020.

<sup>†</sup> Euromonitor International: Eyewear 2021 Edition; Value sales at RSP, all retail channels, 2019 data.

<sup>‡</sup> Euromonitor International Limited: based on research conducted in August 2020, "world" and "globally" represent markets accounting for 76% of total daily disposable contact lenses in 2019 (retail sales).

<sup>§</sup> Four total lenses.

<sup>‡</sup> Disclaimer: The Calculator is provided to clinicians for educational and convenience purposes only, in conjunction with the labeling for 1-DAY ACUVUE® MOIST and ACUVUE® OASYS MULTIFOCALS. Johnson & Johnson Vision Care, Inc. does not engage in the practice of prescribing and this Calculator is not a substitute for appropriate professional education and training or for the exercise of independent professional judgement. Johnson & Johnson Vision Care, Inc. cannot warrant the accuracy or completeness of information that this Calculator provides. Each clinical situation should be considered unique to each patient, and all treatments individualized accordingly. Johnson & Johnson Vision Care, Inc. does not endorse or recommend any particular technique beyond what is contained in the product labeling, and other techniques may be appropriate in a clinician's judgement.

<sup>\*\*</sup> Compared to leading competitors' designs: technology optimized for both the parameters of refractive error and ADD power.

<sup>4</sup> Dr. Kannarr is a paid consultant of Johnson & Johnson Vision.

1. JJV Data on File 2018. Growth Levers analysis base on IPSOS Global Incidence Tracker, retail outlet consumption data and national census population data covering the United States, United Kingdom, Russia, Japan, South Korea and China.

2. JJV Data on File 2020. ACUVUE® PUPIL OPTIMIZED DESIGN TECHNOLOGY. JVC Contact Lenses, Design Features, and Associated Benefits.


3. JJV Data on File 2014. 1-DAY ACUVUE® MOIST MULTIFOCAL Designed for the Aging Eye.

4. JJV Data on File 2020. ACUVUE® OASYS MULTIFOCAL Fit and Performance Claims.

5. JJV Data on File 2015. 1-DAY ACUVUE® MOIST MULTIFOCAL Fit and Performance.

**Important Safety Information:** ACUVUE® Contact Lenses are indicated for vision correction. As with any contact lens, eye problems, including corneal ulcers, can develop. Some wearers may experience mild irritation, itching or discomfort. Lenses should not be prescribed if patients have any eye infection, or experience eye discomfort, excessive tearing, vision changes, redness or other eye problems. Consult the package insert for complete information. Complete information is also available from Johnson & Johnson Vision Care, Inc. by calling 1-800-843-2020, or by visiting JNVISIONPRO.com.





# KEEPING UP WITH KERATITIS

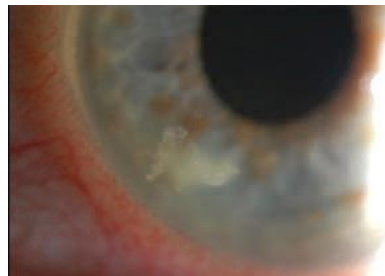Corneal infections move fast—and you should, too. Here’s advice on how to mobilize a defense of the eye that yields swift results.



BY SUZANNE SHERMAN, OD, AND CHRISTINA CHERNY, BS  
NEW YORK CITY

**M**icrobial keratitis is a generally painful and sight-threatening condition often associated with ocular trauma, ocular surface disease and contact lens wear.<sup>1,2</sup> While the spectrum of pathogens and predisposing factors varies with geography and climate, the condition remains a prominent cause of ocular morbidity.<sup>1,3,4</sup> Approximately 30,000 cases occur annually in the US, the preponderance of which are of bacterial origin.<sup>5</sup> Fungal and *Acanthamoeba*-based infections are more rare but can be even more debilitating. Viral corneal infections are predominantly herpetic in origin and more easily recognized clinically.

Traditional first-line therapy of infectious ulcers involves the use of empiric treatment with topical antibiotics.<sup>4,6-8</sup> The role of microbial culture remains perplexing for many practitioners who wonder if they should withhold therapy until results are in, and the use of certain adjunctive therapies, such as topical corticosteroids, is controversial.<sup>4,8</sup>



**This patient developed bacterial keratitis from sleeping in their contact lenses.**

Let’s review the detailed management of microbial keratitis—emphasizing bacterial patterns of infection—including differential diagnosis, culture, treatment strategy and the role of adjunctive therapies.

## Diagnosing Infectious Keratitis

When a patient presents with a corneal ulcer, judicious consideration of clinical signs and symptoms is paramount in order to discern the etiology and begin appropriate therapy. Clinical signs associated with bacterial origin may include epithelial defects overlying a single stromal infiltrate, indistinct infiltrate edges, corneal edema with white cell infiltration of nearby stroma, anterior chamber reaction, hypopyon,

inferior corneal location, older patient age and—though rarely seen—wreath infiltrates and epithelial plaques.<sup>1,6,9-11</sup>

According to a review of 300 bacterial keratitis cases, risk factors for bacterial corneal ulcers include, in order of descending importance: contact lens wear, ocular surface disease, acute corneal trauma and corneal surgery.<sup>1</sup> Additional risk factors include systemic diseases, immunosuppression and lack of prior topical antibiotic use.<sup>1,9,11</sup> Gram-positive microbes are predominantly cultured from bacterial ulcers, particularly in instances of ocular surface disease and corneal trauma.<sup>1,12</sup> Eye care practitioners, however, identify gram-negative *Pseudomonas* keratitis more readily, which is often associated with less defined, suppurative infiltrates.<sup>1,12</sup> Further defining characteristics of gram-negative keratitis include severe anterior chamber inflammation, greater size of infiltrates and more rapid progression.<sup>1</sup>

While proper classification of other bacterial keratitis strains has been modest, practitioners accurately discriminate bacterial ulcers from their fungal counterparts 66% of the time.<sup>6,12</sup> Clinical features associated with fungal

### About the authors

**Dr. Sherman** is an assistant professor of optometric sciences (in ophthalmology) and the director of optometry at Columbia University Medical Center. She specializes in complex and medically necessary contact lens fittings and ocular disease. She is a fellow of the American Academy of Optometry. **Ms. Cherny** is a 2021 optometry candidate at SUNY and will be completing her ocular disease/contact lens residency at Mass Eye and Ear. They have no financial interests to disclose.



**TABLE 1. RISK FACTORS FOR BACTERIAL CORNEAL ULCERS**

Corneal Abnormalities	Ocular Adnexal Dysfunction	Systemic Disease	Exogenous Factors
<ul style="list-style-type: none"> <li>• Hypoesthesia</li> <li>• Bullous keratopathy</li> <li>• Erosive disorders</li> <li>• Viral keratitis</li> </ul>	<ul style="list-style-type: none"> <li>• Misdirection of lashes</li> <li>• Blepharitis</li> <li>• Abnormal lid anatomy</li> <li>• Tear deficiencies</li> <li>• Conjunctivitis</li> <li>• Neuropathy involving cranial nerves III, V and VII</li> <li>• Canaliculitis</li> <li>• Dacryocystitis</li> </ul>	<ul style="list-style-type: none"> <li>• Diabetes mellitus</li> <li>• Collagen vascular disorders</li> <li>• Exfoliative skin disease</li> <li>• Atopic dermatitis</li> <li>• Vitamin A or B deficiency</li> <li>• Immunocompromised status</li> <li>• Substance abuse</li> </ul>	<ul style="list-style-type: none"> <li>• Contact lens use, particularly extended wear</li> <li>• Contaminated contact lens cases and solutions</li> <li>• Ocular trauma: foreign body, chemical and thermal injury</li> <li>• Previous ocular surgery, including loose sutures</li> <li>• Medicamentosa</li> <li>• Contaminated medications</li> <li>• Contaminated make-up</li> <li>• Systemic corticosteroids</li> <li>• Topical immunosuppressive agents</li> <li>• Systemic chemotherapy</li> </ul>

keratitis include the following:<sup>6,9,10</sup>

- satellite lesions
- infiltrates with feathery, fluffy, irregular or serrated margins
- dry, raised or necrotic infiltrates
- infiltrates pigmented with a color other than yellow
- endothelial rings
- longer history of symptoms

Compared with bacterial etiology, fungal ulcers show no significant difference in occurrence of keratic precipitates, immune rings, radial keratoneuritis, endothelial plaques or anterior chamber reactions.<sup>10</sup>

Although corneal scrapings rarely yield parasitic organisms such as *Acanthamoeba*, a greater number of clinically differentiating features exist for *Acanthamoeba* keratitis (AK) relative to bacterial and fungal etiologies.<sup>9</sup> Clinical signs characteristic of AK include pseudodendrites, perineural infiltrates, ring-shaped infiltrates, a predilection for the corneal epithelium early in the disease course, younger age, longer duration of symptoms prior to initiation of treatment and history of prior topical antibiotic use.<sup>9</sup> Of note, although ring infiltrates have been documented for fungal and bacterial ulcers (as well as herpetic disease), their presence is significantly more indicative of late-presenting *Acanthamoeba* etiology.<sup>9,12</sup> Conversely, satellite lesions—a feature often noted for fungal kerati-

tis—occur at a similar frequency in both *Acanthamoeba* and fungal infections.<sup>9</sup>

**When to Culture**

Once an infectious corneal ulcer is identified, it is imperative to promptly select an effective treatment in order to relieve symptoms and ensure best visual outcomes—and therein lies the problem. Which one? Matching drug efficacy to the infectious organism can yield better outcomes than just choosing a broad-spectrum antibiotic and hoping for the best.

Studies have shown that clinicians aren't as accurate in identifying uncommon organisms or infectious ulcers that present without the classic characteristics, with many practitioners demonstrating difficulty in discriminating fungal from bacterial ulcers solely based on clinical appearance.<sup>10,12</sup> Corneal specimen culture is the gold standard for identifying etiological origins of ulcers.<sup>6-8,12,13</sup> Culturing yields information

that can help modify treatment of ulcers refractory to empiric therapy, prevent progression of corneal ulcers, reduce antibiotic resistance and minimize medication toxicity from superfluous medications.<sup>7,11</sup> For example, in cases of AK, proper treatment is often delayed due to misdiagnosis, and the use of specimen culture may help avoid a long and toxic treatment course.<sup>9</sup>

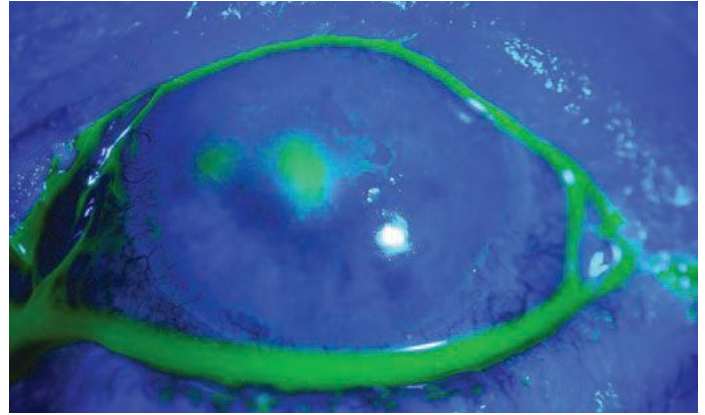
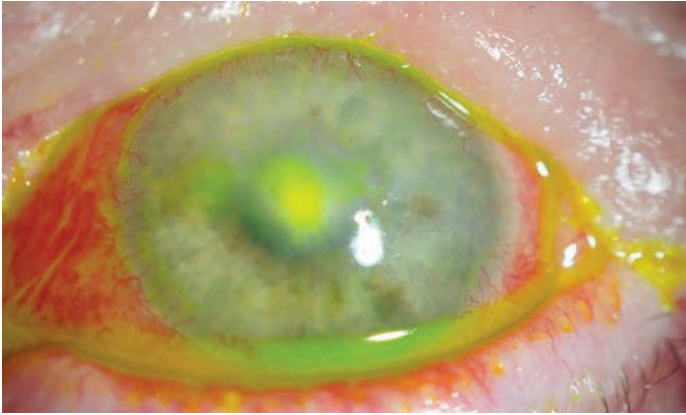
Although some sources have advocated for culture of all infectious corneal ulcers, current staining and culturing methodologies have several limitations, including low sensitivity in bacterial, fungal and viral keratitis cases; protracted turnaround time; low bacterial yield during culture; and time, cost and availability limitations.<sup>7,12,14,15</sup> Furthermore, in many instances, culture results do not change clinical management; most cases of bacterial keratitis resolve with empiric broad-spectrum fluoroquinolone therapy initiated either in the absence of microbial culture or prior to receipt of culture results.<sup>6,7,11,12,16</sup> Given these limiting factors, a selective approach for culturing has been suggested.<sup>7,11,14</sup>

According to the current bacterial keratitis Preferred Practice Pattern published by the American Academy of Ophthalmology, smears and cultures of infectious corneal ulcers are recommended when any of the following circumstances are present:<sup>11</sup>

- size >2mm and centrally located
- accompanied by significant stromal melting
- unresponsive to empiric antibiotic therapy
- chronic, multiple or diffuse in number of infiltrates
- accompanied by characteristics suggestive of amoebic, mycobacterial or fungal infection

**TABLE 1. EXPECTED TRAJECTORY DURING ANTIMICROBIAL THERAPY**

<i>S. aureus</i> , <i>S. pneumonia</i>	<i>S. epidermidis</i>	<i>P. aeruginosa</i>	<i>Mycobacterium</i> , Filamentous fungi
<ul style="list-style-type: none"> <li>• Rapid improvement after 24 to 48 hours</li> <li>• Organisms generally eliminated in 7-10 days</li> </ul>	<ul style="list-style-type: none"> <li>• Rapid improvement after 24-48 hours</li> <li>• Organisms generally eliminated in seven to 10 days</li> </ul>	<ul style="list-style-type: none"> <li>• Worsened appearance at 24 hours</li> <li>• Organisms may persist for 14 days or longer</li> </ul>	<ul style="list-style-type: none"> <li>• Slow response to therapy</li> <li>• May persist for weeks</li> </ul>



**This 56-year-old female had a persistent epithelial defect secondary to trichiasis (caused by squamous cell carcinoma lid surgery). She wore a bandage contact lens for pain and developed an ulcer.**

- found in eyes with a history of corneal surgery

It is important to note that, although most cases of infectious keratitis are treated empirically, the recovery of organisms via culture may be more difficult to perform if treatment has already been initiated.<sup>14</sup>

### How to Culture

Appropriate culturing technique is critical to maximize yield of organisms (the cornea has a relatively low pathogenic load) and a positive culture. Growth and identification of microorganisms from corneal ulcers may occur in as few as 40% to 60% of cultured cases.<sup>6</sup> To increase probability of recovering sufficient microorganisms for a positive culture, multiple samples should be collected and inoculated on various growth media.<sup>15</sup>

During the procedure, a topical anesthetic is instilled, preferably proparacaine due to its lower bactericidal properties relative to other anesthetics, such as tetracaine.<sup>11,14,17</sup> If available, non-preserved topical anesthetic may be used to improve culture yield, and sterile gloves are recommended.<sup>11,14,17</sup> The patient should be situated within the slit lamp, as culture is best performed under magnification.<sup>11,14,17</sup>

A scrape of the corneal ulcer is obtained at the base and advancing edge of the infiltrate from the periphery into the center.<sup>11,14,17</sup> Avoid purulent material, as it is less likely to yield sufficient microbial load. However, cultures of

contact lenses—cases and solutions—may provide useful information.<sup>11,17</sup> Recommended tools for scraping include a 21-gauge needle, a sterilized spud or blade, jeweler's forceps, a calcium alginate swab or a heat-sterilized Kimura platinum spatula.<sup>11,14,17</sup>

The material is first smeared onto glass slides if performing gram stain or potassium hydroxide mount, and then inoculated directly onto appropriate agar plates and liquid media (transport media may be used if direct inoculation is not possible).<sup>11,14,17</sup> Scrapings should be repeated several times with fresh blades or flame sterilization of the same blade.<sup>14,17</sup> Keep cultures at room temperature or incubated if possible, and promptly transport to a laboratory with appropriate labels.<sup>11,14,17</sup>

Lab reports may come back in as little time as several hours for gram stains, one to two days for bacterial growth or up to two weeks in the case of fungal infections.<sup>17</sup> Antimicrobial sensitivity reports may also be obtained from the laboratory.<sup>17</sup> Once a culture has been performed and sent out, immediately begin empiric antimicrobial therapy based on clinical signs and history, if you haven't already.<sup>6,17</sup> In the case of a negative culture, cessation of antibiotic therapy for 12 to 24 hours may be considered to increase pathogen yield.<sup>11</sup>

### Treatment of Corneal Ulcers

When initiating treatment of keratitis, corneal infiltrates must first be classified as sterile or infectious in nature.<sup>18</sup>

**Sterile keratitis.** These infiltrates are described as minor defects, usually less than 1mm to 1.5mm in size, and are associated with negligible pain, discharge, conjunctival inflammation and anterior chamber reaction, as well as with absent or minimal epithelial involvement.<sup>18,19</sup> The majority of sterile infiltrates are subepithelial or anterior stromal and are found in the mid-peripheral to peripheral cornea within approximately 4mm from the limbus.<sup>18,19</sup> Sterile infiltrates may be associated with contact lens wear, particularly in cases of extended wear and poor hygiene, and tend to occur in the superior corneal quadrant in the setting of extended contact lens wear.<sup>18,19</sup>

Initial treatment options for presumed sterile infiltrates include discontinuation of lens wear followed by topical antibiotics, fortified topical antibiotics, antibiotic-steroid combo agents, topical steroids alone or simply observation. Microbial culture is not indicated in cases of sterile infiltrates.<sup>18</sup> Topical antibiotic-steroid combinations have been shown to resolve sterile infiltrates in less time than topical antibiotics alone.<sup>19</sup> If a distinct epithelial defect develops along with pain and ocular inflammation, a bacterial ulcer may be underlying and requires prompt treatment with antibiotic therapy, with initial avoidance of steroid use.<sup>18,19</sup>

**Infectious keratitis.** When you see stromal infiltrates in the presence of epithelial disruption, particularly in cases of bacterial disease, you're

# See the retina from a **Safe Distance.**

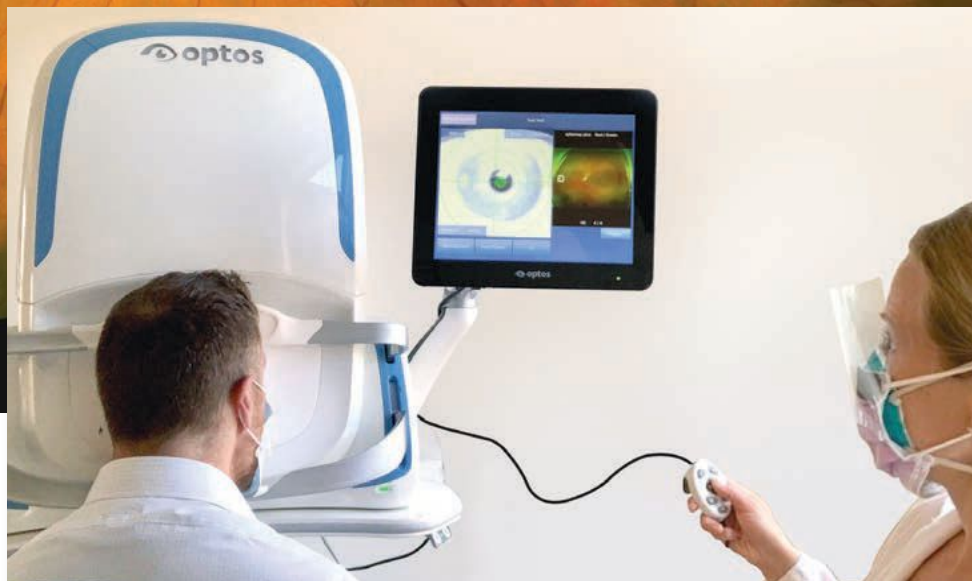- 200° single-capture
- Multi-mode
- Easy to clean

Optos helps you see and document the retina with no face-to-face interaction.


**optomap**® single capture UWF imaging has been shown to increase practice flow and patient engagement.

**Keep your staff and patients safer with optomap**

Contact us today to put the power, efficiency and safety of **optomap** in your practice  
800-854-3039 [www.optos.com](http://www.optos.com)







quite likely dealing with an infectious etiology.<sup>4,5,7</sup> Patients with infectious corneal ulcers are typically acutely symptomatic for pain, photophobia, decreased vision, conjunctival injection and mucopurulent discharge.<sup>4,7,11</sup> Severe cases may result in stromal thinning, ulceration, corneal perforation, endophthalmitis, vision loss secondary to stromal scarring or even loss of the eye.<sup>3,5,8,11</sup>

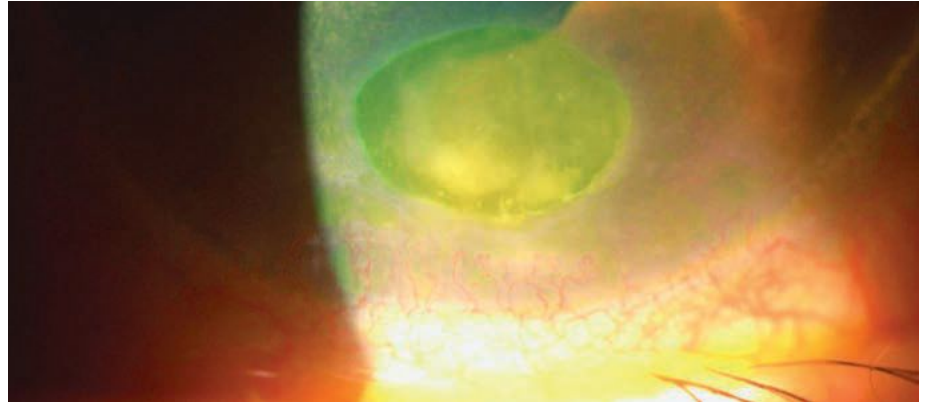
Prompt empiric treatment is generally necessary when culture and/or sensitivity testing is unavailable or hasn't yet been performed.<sup>3,11</sup> The regimen should consist of topical broad-spectrum antibiotics, such as fluoroquinolones or fortified aminoglycosides, with a cephalosporin or vancomycin.<sup>7</sup> Consider geography, and local bacterial prevalence and antibiotic sensitivity, when selecting the antibiotic of choice.<sup>3,5</sup>

While a large number of clinical trials have been published, there is currently no unanimous treatment regimen detailing which antibiotics should be used for bacterial keratitis.<sup>3</sup> Numerous sample regimens have been detailed, and are subdivided based on microorganism characteristics (see *Table 1*).<sup>3</sup> Presently, ciprofloxacin 0.3%, levofloxacin 1.5% and ofloxacin 0.3% are FDA-approved to treat bacterial keratitis.<sup>11</sup>

In cases of large or sight-threatening ulcers, particularly if accompanied by a hypopyon or deep stromal involvement, fortified topical antibiotics are beneficial, and a loading dose every five to 15 minutes followed by hourly application is recommended.<sup>11</sup> Subconjunctival injection, systemic therapy or hospitalization may be necessary in severe cases.<sup>3,11</sup> Adjuvant cycloplegics also may be considered in instances of significant anterior chamber reaction and/or severe pain due to their palliative and anti-inflammatory properties.<sup>11</sup>

### Steroid Therapy

While topical antibiotic therapy remains the mainstay treatment of bacterial keratitis, adjunctive corticosteroid use may also prove beneficial for clinical outcomes, although use of



**This patient had ruptured bullae and subsequently developed a bacterial ulcer.**

topical steroids for microbial keratitis remains controversial.<sup>4,5,8</sup> Proponents contend that steroids mitigate tissue damage from the host inflammatory response by decreasing severity of stromal melting, neovascularization and scarring.<sup>4,5,8</sup> Furthermore, steroids may improve patient compliance with antibiotic treatment by alleviating pain and discomfort.<sup>5</sup> Conversely, steroid therapy may delay epithelial healing and potentiate bacterial keratitis, leading to stromal thinning and melting.<sup>4,5,20</sup>

Four clinical trials, including one randomized, placebo-controlled, double-masked trial known as SCUT, have compared clinical outcomes in bacterial keratitis treated with antibiotics and steroids vs. antibiotics alone.<sup>5,21</sup> While the first three smaller trials evidenced neither harm nor benefit associated with topical steroid use, subgroup analysis within SCUT found that patients with low vision, or deep or central ulcers, at baseline experienced better visual improvement at three months when compared with placebo, as did patients with invasive *Pseudomonas* strains.<sup>5,21</sup> No significant difference in adverse effects was noted between steroid and placebo arms.<sup>5,20,21</sup>

Timing and dosage are important concerns, as patients who began steroids after only two to three days of antibiotic use, particularly with potent agents administered six times daily, experienced better visual outcomes than those in the placebo arm. Patients with later steroid use experienced neutral or worse acuity vs. placebo.<sup>5,20,22</sup>

A 12-month follow-up of the SCUT trial also demonstrated superior visual outcomes in patients with ulcers not caused by *Nocardia* keratitis (NK).<sup>23</sup> Patients with NK, however, have been found to experience larger infiltrates and scars with corticosteroid therapy, despite no difference in vision, re-epithelialization or corneal perforation. Poor outcomes with steroid use have also been associated with fungal and *Acanthamoeba* infections.<sup>22,24</sup>

To minimize adverse effects, it is prudent to administer topical steroids after 24 to 48 hours of antibiotic therapy, following evidence of ulcer improvement and microorganism identification via culture.<sup>4,5,11</sup> Avoidance of topical steroids in cases of atypical keratitis, as well as in NK, fungal and *Acanthamoeba* etiologies, is critical.<sup>5,11</sup>

### Adjuvant Therapy

In addition to traditional antibiotic therapy, several adjuvant options for bacterial keratitis have been described. A randomized, controlled trial demonstrated that low-concentration topical povidone-iodine 1.25% may perform with equal efficacy as topical antibiotics in the treatment of bacterial keratitis, and has the added benefit of considerably lower cost.<sup>25</sup> Collagen crosslinking, a procedure which treats corneal ectatic conditions by strengthening stromal tissue, has been shown to be of potential benefit for recalcitrant infectious keratitis by halting corneal melting, resolving ulcers resistant to treatment and improving patient symptoms.<sup>8</sup>

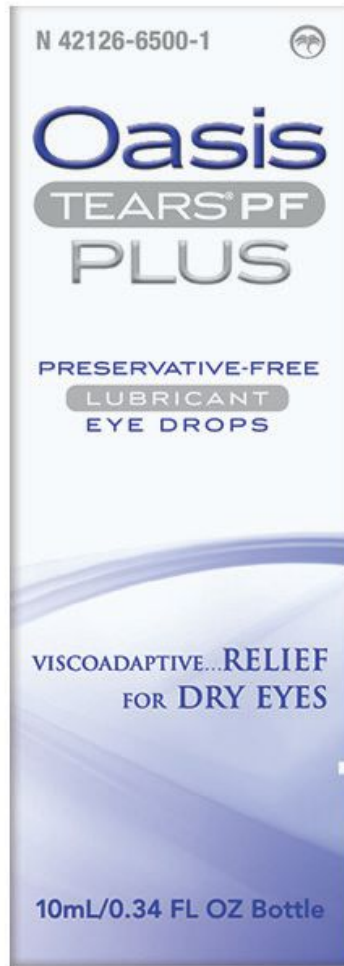
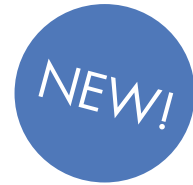AVAILABLE MAY 2021

Introducing

# Oasis TEARS® PF PLUS

Preservative-Free  
Lubricant Eye Drops

Part number OT6500



Oasis TEARS® PF PLUS is a preservative-free viscoadaptive lubricating eye drop to moisten and relieve dry eye symptoms.

Dry eye symptoms can range from gritty (foreign body sensation), burning, itching, irritation, and watery eyes. The formulation is delivered through a proprietary bottle that keeps the content sterile for multi-use.

Visit OASIS, Booth 722  
at SECO International 2021



Also available on



Oasis TEARS® PF PLUS will also be available on the MY OASIS™ cyber platform for a seamless patient experience.

Register for MY OASIS™ to expand your outreach, provide direct delivery of all OASIS solutions to your dry eye community, maintain compliance of care, gain insights and more. **Ask us how to get started. Email: [oasis@oasismedical.com](mailto:oasis@oasismedical.com)**

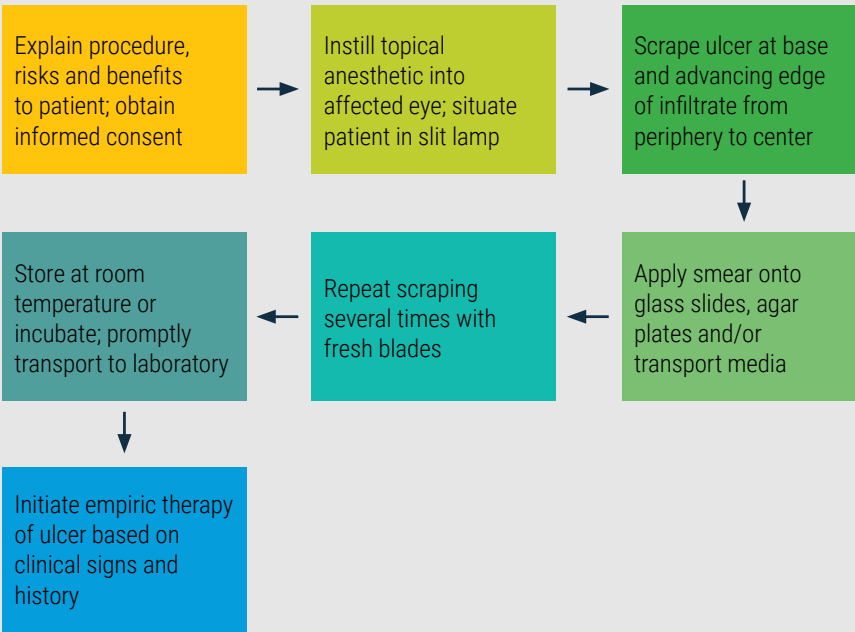


OTC Solutions from OASIS

ORDER NOW (844) 820-8940 [customerservice@oasismedical.com](mailto:customerservice@oasismedical.com) [www.oasismedical.com](http://www.oasismedical.com)



## OVERVIEW OF MICROBIAL CULTURE PROTOCOL



The use of tetracyclines such as doxycycline has been suggested due to their antimetalloproteinase properties, which may lessen the risk of severe complications of infectious keratitis, such as corneal perforation.<sup>8</sup> Other adjunctive therapies proposed for bacterial keratitis include amniotic membranes, antibiotic-soaked soft contact lenses, collagen shields, mitomycin-C, hyperbaric oxygen therapy, autologous serum eye drops and cryotherapy, although the beneficial effects of these therapies are not universally established.<sup>11,26</sup>

### When to Change Therapy

Monitoring clinical response to treatment is critical to success—we need to establish if the therapy is working and whether modification is necessary.<sup>8,11</sup> Lack of clinical response or worsening of signs and symptoms within 48 hours, particularly in cases of vision-threatening ulcers, may warrant initiating a more aggressive antibiotic regimen (e.g., switching to fortified broad-spectrum antibiotics if initial treatment consisted of fluoroquinolone therapy), considering less common microorganisms, performing a re-culture or referring to a cornea specialist.<sup>7,8,11,27</sup>

In cases of unlikely compliance, disease extension into adjacent tissues or threat of corneal perforation, systemic antibiotics or hospitalization may be necessary.<sup>11</sup> Also consider that drug toxicity may be mistaken for lack of clinical improvement, and reduction of therapy may be warranted at times in order to assess healing.<sup>8,11</sup>

Bacterial keratitis remains a prominent cause of vision loss worldwide. Precise clinical identification of underlying etiology is critical for effective treatment, and may be aided by proper microbial culture. Although antibiotic therapy remains first-line for bacterial ulcers, adjuvant treatments have been described, and corticosteroid therapy may play an essential role in improved visual outcomes. ■

1. Bourcier T, Thomas F, Borderie V, Chaumeil C, Laroche L. Bacterial keratitis: predisposing factors, clinical and microbiological review of 300 cases. *Br J Ophthalmol*. 2003;87(7):834-838.
2. Ballouz D, Maganti N, Tuohy M, Errickson J, Woodward MA. Medication burden for patients with bacterial keratitis. *Cornea*. 2019;38(8):933-937.
3. McDonald EM, Ram FS, Patel DV, McGhee CN. Topical antibiotics for the management of bacterial keratitis: an evidence-based review of high quality randomised controlled trials. *Br J Ophthalmol*. 2014;98(11):1470-7.
4. Ni N, Srinivasan M, McLeod SD, Acharya NR, Lietman TM, Rose-Nussbaumer J. Use of adjunctive topical corticosteroids in bacterial keratitis. *Curr Opin Ophthalmol*. 2016;27(4):353-357.
5. Palioura S, Henry CR, Amescua G, Alfonso EC. Role of steroids in the treatment of bacterial keratitis. *Clin Ophthalmol*. 2016;10:179-186.

6. Dalmon C, Porco TC, Lietman TM, et al. The clinical differentiation of bacterial and fungal keratitis: a photographic survey. *Invest Ophthalmol Vis Sci*. 2012;53(4):1787-1791.
7. Moshirfar M, Hopping GC, Vaidyanathan U, Liu H, Somani AN, Ronquillo YC, Hoopes PC. Biological staining and culturing in infectious keratitis: controversy in clinical utility. *Med Hypothesis Discov Innov Ophthalmol*. 2019;8(3):145-151.
8. Austin A, Lietman T, Rose-Nussbaumer J. Update on the management of infectious keratitis. *Ophthalmology*. 2017;124(11):1678-1689.
9. Mascarenhas J, Lalitha P, Prajna NV, Srinivasan M, Das M, D'Silva SS, Oldenburg CE, Borkar DS, Esterberg EJ, Lietman TM, Keenan JD. Acanthamoeba, fungal, and bacterial keratitis: a comparison of risk factors and clinical features. *Am J Ophthalmol*. 2014;157(1):56-62.
10. Thomas PA, Leck AK, Myatt M. Characteristic clinical features as an aid to the diagnosis of suppurative keratitis caused by filamentous fungi. *Br J Ophthalmol*. 2005;89(12):1554-8.
11. Lin A, Rhee MK, Akpek EK, Amescua G, Farid M, Garcia-Ferrer FJ, Varu DM, Musch DC, Dunn SP, Mah FS. Bacterial keratitis preferred practice pattern. *Ophthalmology*. 2019;126(1):P1-P55.
12. Dahlgren MA, Lingappan A, Wilhelmus KR. The clinical diagnosis of microbial keratitis. *Am J Ophthalmol*. 2007;143(6):940-944.
13. Levey SB, Katz HR, Abrams DA, Hirschbein MJ, Marsh MJ. The role of cultures in the management of ulcerative keratitis. *Cornea*. 1997;16(4):383-6.
14. Gupta N, Tandon R. Investigative modalities in infectious keratitis. *Indian J Ophthalmol*. 2008;56(3):209-213.
15. Pakzad-Vaezi K, Levasseur SD, Schendel S, Mark S, Mathias R, Roscoe D, Holland SP. The corneal ulcer one-touch study: a simplified microbiological specimen collection method. *Am J Ophthalmol*. 2015;159(1):37-43.
16. McLeod SD, Kolahdouz-Isfahani A, Rostamian K, Flowers CW, Lee PP, McDonnell PJ. The role of smears, cultures, and antibiotic sensitivity testing in the management of suspected infectious keratitis. *Ophthalmology*. 1996;103(1):23-8.
17. Robinson J, Ellen J, Hadel B, Lighthizer N. Collecting a corneal culture. *Rev Optometry*. 2016; 153(4):64-71.
18. Baum J, Dabeszies OH. Pathogenesis and treatment of "sterile" midperipheral corneal infiltrates associated with soft contact lens use. *Cornea*. 2000;19(6):777-781.
19. Donshik PC, Suchecki JK, Ehlers WH. Peripheral corneal infiltrates associated with contact lens wear. *Trans Am Ophthalmol Soc*. 1995;93:49-64.
20. Green M, Hughes I, Hogden J, Sara S, Apel A, Stapleton F. High-dose steroid treatment of bacterial keratitis. *Cornea*. 2019;38(2):135-140.
21. Srinivasan M, Mascarenhas J, Rajaraman R, et al. Steroids for Corneal Ulcers Trial Group. Corticosteroids for bacterial keratitis: the steroids for corneal ulcers trial (SCUT). *Arch Ophthalmol*. 2012 Feb;130(2):143-50.
22. Ray KJ, Srinivasan M, Mascarenhas J, Rajaraman R, Ravindran M, Glidden DV, Oldenburg CE, Sun CQ, Zegans ME, McLeod SD, Acharya NR, Lietman TM. Early addition of topical corticosteroids in the treatment of bacterial keratitis. *JAMA Ophthalmol*. 2014;132(6):737-41.
23. Srinivasan M, Mascarenhas J, Rajaraman R, et al. The steroids for corneal ulcers trial (SCUT): secondary 12-month clinical outcomes of a randomized controlled trial. *Am J Ophthalmol*. 2014;157(2):327-333.
24. Lalitha P, Srinivasan M, Rajaraman R, et al. Nocardia keratitis: clinical course and effect of corticosteroids. *Am J Ophthalmol*. 2012 Dec;154(6):934-939.
25. Isenberg SJ, Apt L, Valenton M, Sharma S, Garg P, Thomas PA, Parmar P, Kalliamurthy J, Reyes JM, Ong D, Christenson PD, Del Signore M, Holland GN. Prospective, Randomized Clinical Trial of Povidone-Iodine 1.25% Solution Versus Topical Antibiotics for Treatment of Bacterial Keratitis. *Am J Ophthalmol*. 2017 Apr;176:244-253.
26. Dakhil TAB, Stone DU, Gritz DC. Adjunctive therapies for bacterial keratitis. *Middle East Afr J Ophthalmol*. 2017;24(1):11-17.
27. Weiner, Gabrielle. Confronting Corneal Ulcers. *American Academy of Ophthalmology*, 2012. [www.aaopt.org/eyenet/article/confronting-corneal-ulcers](http://www.aaopt.org/eyenet/article/confronting-corneal-ulcers).



# NEW HEALTH AND SAFETY GUIDELINES AT SECO 2021

VISIT [ATTENDSECO.COM](http://ATTENDSECO.COM) FOR MORE INFORMATION

## REGISTRATION AND HOUSING NOW OPEN

# SECO 2021



WHERE SIGHT MEETS VISION™  
APRIL 28–MAY 2 | ATLANTA, GA

## Forget hindsight—this year, it's foresight that's 2021.

Get a first look at the research, technology and techniques that are evolving patient care and propelling the optometric profession forward. Whether you're looking for the latest in clinical advancements or business solutions you'll find the speakers, education, solutions and connections you need to stay on the cutting edge.

### DESIGNED FOR:

Optometrists  
Ophthalmologists  
Opticians  
Ophthalmic Technicians  
Paraoptometrics  
Practice Administrators

### CAN'T ATTEND IN PERSON? NEW! SECO 2021 VIRTUAL EDUCATION

Select speakers presenting to full classrooms onsite in Atlanta will be streaming live through the SECO 2021 LIVE CE platform for accredited education for the virtual attendee.


LEARN MORE AND REGISTER BY VISITING  
**[attendseco.com](http://attendseco.com)**

SECO 2021 is offering registration refund insurance for attendees to provide peace of mind when planning your participation.

For more details on refund insurance, please visit [www.attendseco.com/registration](http://www.attendseco.com/registration)



PRODUCED BY  
**SECO INTERNATIONAL**  
WORLD-CLASS EDUCATION FOR OPTOMETRY



# CORNEOSCLERAL CONCERNS: TROUBLE AT THE BORDER

The limbal junction is key in protecting and preserving the ocular surface. Here are a few conditions that can disrupt its equilibrium.



BY MEGAN MANNEN, OD  
CLINTON, UT

**T**he corneoscleral limbus is a unique and critical ocular structure responsible for barrier protection, corneal regeneration and wound repair. These functions are pivotal in maintaining corneal transparency and ocular surface integrity. In addition, the limbus contains vascular and lymphatic vessels that serve to provide nutrients and cytokines to the surrounding structures. This makes the peripheral cornea more susceptible to immune-mediated inflammation and ensuing structural changes.

The corneal epithelium is in a constant state of remodeling. The layer of surface cells, wing cells and basal cells. Surface cells are made up of non-keratinized, stratified squamous cells.<sup>1</sup> The conjunctival epithelium, in contrast, is made up of non-keratinized, stratified columnar cells with mucin-containing goblet cells.<sup>2</sup> As surface corneal epithelial cells are shed, the basal lamina encourages new cell proliferation. Only cells in contact with the basal layer of the epithelium can divide.<sup>3</sup>

The corneal epithelium is thought to repair itself in a centripetal fashion.<sup>4</sup> Differentiation and replenishment of the epithelium from basal cells to surface cells takes approximately seven to 14 days to complete.<sup>5</sup>

The limbus marks the junction where the corneal epithelium meets the conjunctival epithelium. In the basal lamina at the limbus, stem cells can be found in the palisades of Vogt.<sup>6-8</sup> These are critical for cell proliferation and migration following an insult to the corneal epithelium. Limbal stem cells also provide a barrier to conjunctival epithelial cells, keeping them from migrating onto the cornea. When limbal stem cells are damaged, the cornea can become “conjunctivalized.” Conjunctivalization is evident through neovascularization, the presence of goblet cells and an unstable epithelium.<sup>9</sup> This transformation of cell tissue can lead to chronic inflammation, neovascularization, persistent epithelial defects and possible opacification.

The cornea has angiogenic and immune privilege, both of which are necessary to retain transparency. The process of maintaining corneal avascularity is ongoing. When the cornea is

injured, anti-angiogenic factors are up-regulated, while pro-angiogenic factors are downregulated. This equilibrium ensures no corneal neovascularization ensues. When the limbal tissue is compromised, balance is disrupted and angiogenic factors prevail, leading to new blood vessel growth.<sup>10-12</sup>

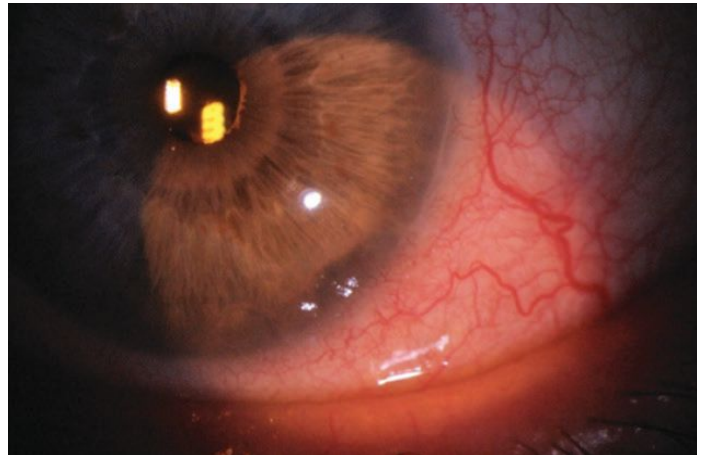
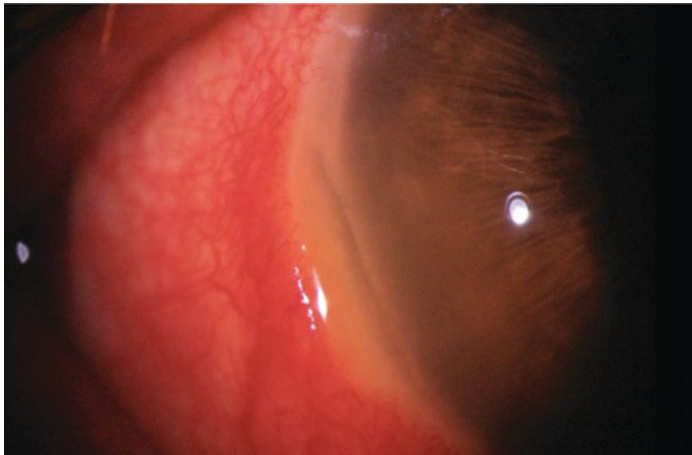
This article highlights several limbal diseases, to which we should pay particularly close attention.

## Deficiency Processes

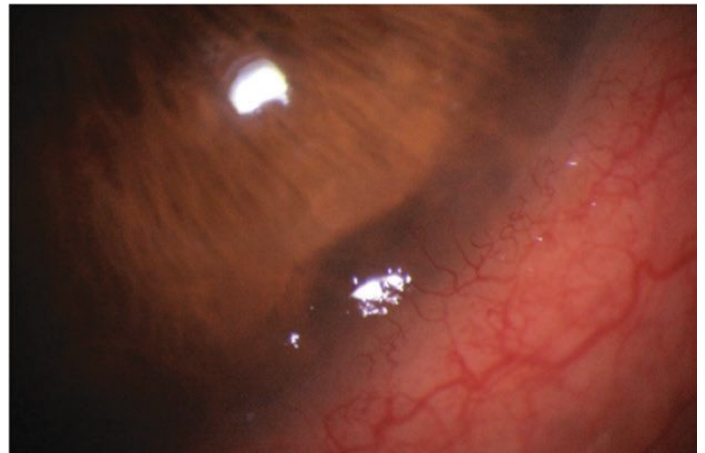
Disease or trauma can bring on a state of *limbal stem cell deficiency (LSCD)*. This condition results from dysfunction, damage or destruction of limbal stem cells. Destruction can be caused by chemical or thermal burns, Stevens-Johnson syndrome, multiple ocular surgeries, contact lens (CL) wear or severe microbial keratitis.<sup>13</sup> Gradual loss of stem cell function may be due to a variety of genetic or acquired conditions. Genetic causes of LSCD include aniridia, congenital erythrokeratoderma and multiple endocrine deficiency.<sup>8,13</sup> Acquired gradual loss can be stimulated by neurotrophic keratitis, vernal conjunctivitis or peripheral inflammatory keratitis, to name a few.<sup>13,14</sup>

### About the author

Dr. Mannen practices at a private optometry and ophthalmology clinic in Northern Utah. She completed her residency at the Walla Walla Veteran Affairs Medical Center and Pacific Cataract and Laser Institute. She is a Fellow of the American Academy of Optometry. She has no financial interests to disclose.



**Bilateral Mooren's ulcer in a 72-year-old white male. The right eye shows limbal melt from 7 to 9 o'clock, while the left eye shows limbal melt from 4 to 5 o'clock. Although scleritis was present in the right eye, this patient tested negative for collagen vascular disease. Due to the bilateral nature and absence of rheumatologic disease, Mooren's was the working diagnosis rather than peripheral ulcerative keratitis, although both were differentials.**



When corneal conjunctivalization and persistent epithelial defects are present, consider LSCD. Fluorescein pooling is often evident in areas of conjunctivalization due to thin, irregular tissue with a loss of tight junctions.<sup>15</sup> This staining can take on a whorl-like pattern and be sectoral or more widespread depending on the severity of LSCD.<sup>16</sup> Fibrovascular pannus, scarring and calcification are also often observed. LSCD patients are highly susceptible to epithelial erosions and report chronic pain, blurred vision and photophobia.<sup>15</sup> In advanced disease, corneal melt or perforation is possible.

Topical steroids are considered the first-line therapy in early stages of LSCD. Additionally, frequent administration of preservative-free artificial tears is recommended to treat underlying ocular surface disease. Restasis (cyclosporine, Allergan) or Xiidra (lifitegrast, Novartis) can help decrease inflammation. A bandage lens, scleral lens or amniotic membrane can promote epithelial healing. In cases where some limbal stem cells are still functional, debride the abnormal epithelium. This allows the remaining functional stem cells to repopulate the surface with normal corneal epithelium.

In extensive or complete LSCD, limbal stem cell transplantation (LSCT) is often required, as these patients do not typically respond well to traditional keratoplasty.<sup>9,13</sup> To improve surgical outcomes, control inflammation prior to transplantation. In unilateral LSCD, autologous limbal tissue can be transplanted from the fellow eye. There is no risk of rejection in an autologous transplant, leading to a higher success rate. Bilateral LSCD, which most commonly occurs secondary to burns, requires allogenic transplantation or cultivated oral mucosal transplantation. Amniotic membranes are used to transplant tissue onto the host cornea.<sup>16</sup> The risk of rejection in allogenic LSCT is a significant concern, necessitating the use of HLA typing and long-term immunosuppression.<sup>15,16</sup>

Common adverse effects of LSCT include recurrent or persistent epithelial erosions and increased intraocular pressure. Administer the same therapies used in early disease post-transplantation to reduce inflammation, suppress the immune system and optimize the ocular surface.

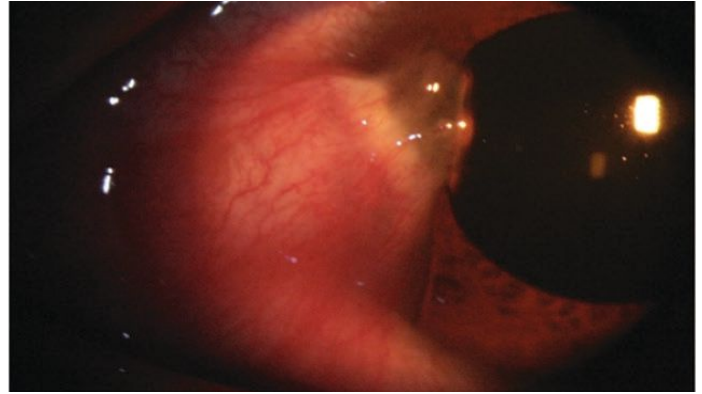
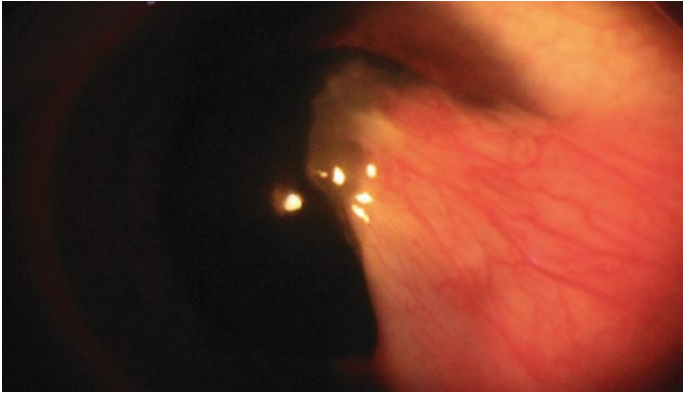

## Mechanical Processes

The ocular surface is continuously buffeted by internal and external forces and can succumb when overtaxed.

**CL-mediated issues.** Lens wear can lead to limbal dysfunction via mechanical wear, decreased tear exchange and corneal hypoxia. Additionally, injury is possible with improper lens insertion or removal techniques. These factors open the door to possible microbial infection and progressive compromise to the limbal tissue. CL wear and care accounts for 15% of all LSCD cases.<sup>17</sup>

Monitor the superior cornea carefully for staining due to increased friction between the superior lid and lens.<sup>16</sup> Also monitor the periphery for neovascularization, which indicates hypoxia. Ask the patient heed their replacement schedule and consider reduced wear time and/or daily disposables to keep the risk of CL-related limbal complications low. In the case of lens-associated LSCD, discontinue lens wear indefinitely.





**Bilateral thick pterygia in a 33-year-old Hispanic male. Pterygium excision with a conjunctival allograft was recommended in the right eye secondary to the degree of encroachment on the line of sight and significant irregular astigmatism induced by the pterygium.**

**Superior limbic keratoconjunctivitis (SLK).** This is thought to be caused by a poor interaction between the superior eyelid and the superior bulbar conjunctiva.<sup>18-20</sup> It may also be influenced by a localized tear deficiency.<sup>20</sup> SLK is much more common in females and may be accompanied by concurrent thyroid disease in up to 50% of cases.<sup>21</sup>

SLK is marked by superior bulbar injection, especially near the limbus, with thickening or redundancy of the conjunctival tissue. Fine papillae can be observed on the superior tarsus, and punctate erosions can be seen on the superior cornea, limbus and bulbar conjunctiva. Superior filaments often develop, and dry eye disease is a common comorbidity. Patients with SLK often present with adjunctive lid findings, such as superior lid swelling, blepharospasm and inflammatory ptosis.<sup>21</sup>

Initial therapy may include frequent lubrication, punctal occlusion and a therapeutic soft CL. Also consider autologous serum, cyclosporine A and topical mast cell stabilizers. SLK responds poorly to topical steroids.<sup>18</sup> More aggressive treatments include 0.5% to 1% silver nitrate application to the conjunctiva following a topical anesthetic, which chemically debrides the inflamed conjunctival tissue. Take extreme caution to avoid burning the cornea. Additionally, conjunctival resection or thermal cautery of the superior bulbar conjunctiva can improve the conjunctival interface.<sup>21</sup>

**Dellen.** This is a painless area of thinning caused by ocular surface dryness.

It often develops adjacent to elevated areas. It can also occur near conjunctival chemosis, episcleritis, pingueculae or pterygia. The presenting location is often temporal near the limbus.

Dellen commonly present following cataract surgery, strabismic surgery or glaucoma-filtering surgery.<sup>22</sup> Patients may report mild discomfort or foreign body sensation. Look for a saucer-like depression at the slit lamp. Corneal dellem represent thinning of the epithelium, Bowman's layer and the anterior stroma. They typically resolve within a few days but in some cases may last weeks.<sup>23</sup> Treatment consists of frequent lubrication, patching if necessary and possibly a prophylactic antibiotic ointment. In more resistant cases, reducing the adjacent elevation may be required.

### Immune-mediated Processes

Aberrations in the immune response can affect the limbal region.

**Phlyctenulosis.** Phlyctenular keratoconjunctivitis is an immune-mediated condition in which the cornea becomes sensitized to a microbial antigen during a delayed hypersensitivity reaction. With repeated exposure to this antigen, phlyctenules can develop on the corneal or conjunctival side of the limbus. *Staphylococcus* is the most common stimulus; however, historically, phlyctenulosis commonly occurred in response to tuberculo-protein.<sup>24</sup> As antigens infiltrate the surface, exotoxins are released, causing the corneal epithelium to break down.<sup>25</sup> This condition is more common in teenagers and has a higher

predilection for females.<sup>24</sup>

A phlyctenule is a 1mm to 2 mm fleshy white nodule often accompanied by conjunctival injection. Symptoms include foreign body sensation, tearing, increased light sensitivity and possible itching. Phlyctenules on the cornea increase the severity of symptoms and have the ability to ulcerate, causing scarring and neovascularization. Corneal ulceration frequently results in a triangular-shaped anterior stromal scar. Phlyctenules can be recurrent and often occur at the edge of previous neovascularization sites.<sup>24</sup>

Some cases of phlyctenular keratoconjunctivitis are self-limiting, but topical steroids dosed QID are the treatment of choice. If a corneal epithelial defect is present, a broad-spectrum antibiotic is recommended prior to steroid initiation. Due to the risk of recurrence, it is critical to treat concurrent blepharitis. This can be achieved with lid hygiene, antibiotic ointment or even a course of oral doxycycline (if the patient is older than eight and not nursing or pregnant).

Differentials of phlyctenulosis include Salzmann's nodules, Horner-Trantas dots in vernal keratoconjunctivitis, pingueculitis and nodular episcleritis. In episcleritis and pingueculitis, the nodules do not ulcerate. Corneal phlyctenules often resemble infectious ulcers, so it is important to rule out microbial keratitis. If suspicions of an infectious etiology arise, culturing should be performed.

**Staph marginal keratitis.** This com-

mon immune-mediated limbal disorder is considered a type III hypersensitivity reaction to resident *Staphylococcus aureus*, which is often present on the lids and lashes.<sup>24</sup> It occurs peripherally due to its close proximity to limbal lymphatic vessels. Symptoms include pain, light sensitivity, foreign body sensation and conjunctival injection.

The condition is marked by one or often multiple small white subepithelial infiltrates 1mm to 2mm from the limbus, with a clear cornea in between. These infiltrates tend to be located in areas where the lid interacts with the corneal tissue. Ulceration is possible and indicated by sodium fluorescein staining over an infiltrate. Neovascularization can ensue in cases of ongoing inflammation.

It is treated similarly to phlyctenulosis, as it responds quickly to topical steroids. If an epithelial defect is present, add a broad-spectrum antibiotic. Additionally, lid hygiene and possibly topical or oral antibiotics are critical to reduce the likelihood of recurrence.

**Mooren's ulcer.** This rare, painful peripheral corneal ulceration is marked by a wavy pattern. It is associated with non-perfusion of the superficial vascular plexus.<sup>26,27</sup> Mooren ulcers are idiopathic in etiology but thought to be immune-mediated.<sup>28</sup> There are three known forms:<sup>26</sup>

- Type 1, or a unilateral Mooren, is a painful, progressive form found in patients older than 60.
- Type 2, a bilateral, aggressive Mooren, occurs in younger patients and progresses circumferentially.
- Type 3, a bilateral, indolent Mooren, is marked by slow, progressive peripheral corneal guttering in middle-aged patients.

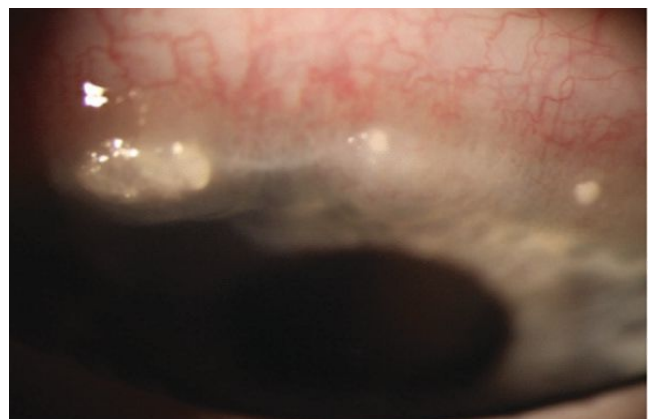
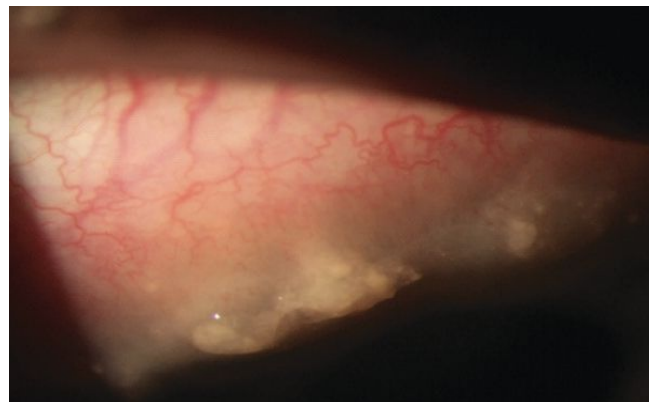
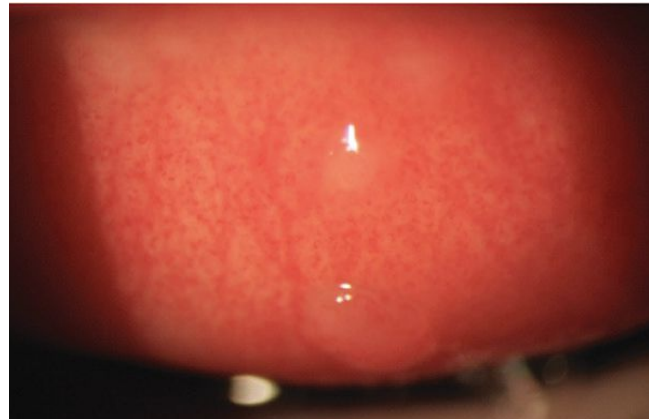Behind the slit lamp, a swollen gray area of cornea that tends to furrow rapidly can be visualized.<sup>26</sup> An epithelial defect and stromal thinning can also be observed. In Types 1 and 2, limbal inflammation is significant and marked by swelling and neovascularization. The ulceration often starts focally at the nasal or temporal limbus and spreads circumferentially and centrally.

Therapy depends on the severity and type of ulceration. Start with an aggressive topical steroid course and a prophylactic antibiotic.<sup>26,29</sup> Use topical cyclosporine therapy QID as adjunctive therapy.<sup>30</sup> In any form of epithelial defect, frequent lubrication is recommended to reduce eyelid friction and inflammatory cytokines.

Type 2 often requires IV immunosuppression with methylprednisolone followed by oral steroids. In any form, the goal of treatment is re-epithelialization and decreased inflammation. Shallow ulceration can be repaired with amniotic membrane transplantation, conjunctival resection or a conjunctival flap. For deeper ulcers, partial or total lamellar keratoplasty may be required.<sup>31</sup>

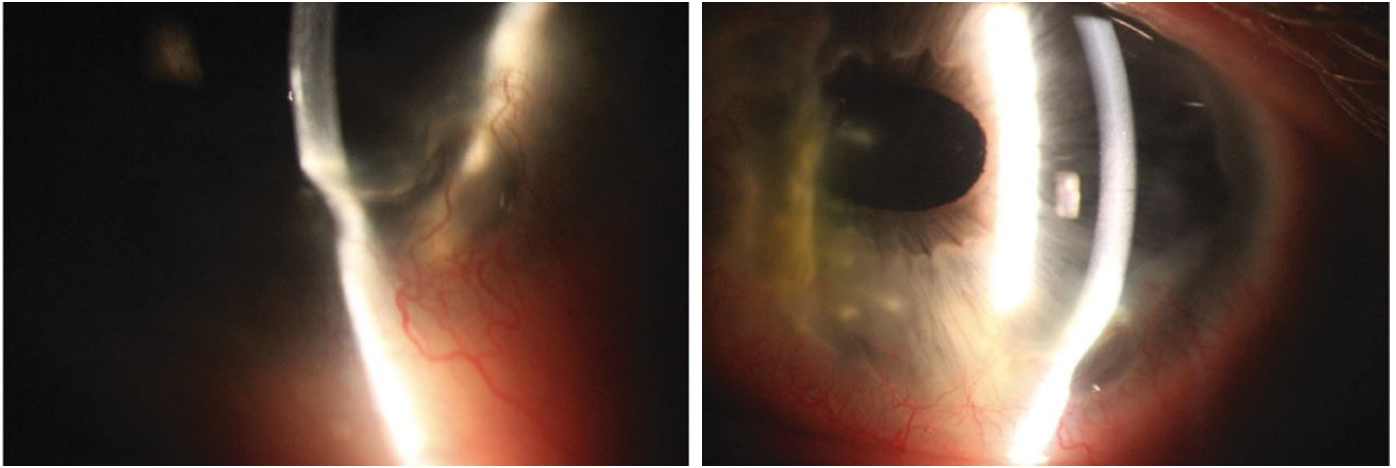
**Vernal keratoconjunctivitis (VKC).** This severe, bilateral and chronic allergic condition is most prominent in young boys living in warmer climates. Common comorbidities include asthma and allergic rhinitis.<sup>32</sup> VKC is thought to be an IgE-mediated hypersensitivity, but IgG, basophil and cellular delayed-type hypersensitivities may also be involved.<sup>33</sup>

Patients usually report severe itching, photophobia, thick mucus discharge, tearing, burning, foreign body sensation, pain and possibly blurred vision. Symptoms tend to be most common in the spring. On slit lamp exam, giant



**VKC with two giant cobblestone papillae and extensive Horner-Trantas dots in a nine-year-old white male. The patient responded well to treatment with topical steroids, but limbal scarring did result upon resolution.**

cobblestone papillae can be observed on the superior palpebral conjunctiva. In addition, focal white infiltrates (Horner-Trantas dots) and sectoral conjunctival and episcleral hyperemia can be seen at the superior limbus. Corneal shield ulcers are also a possible, yet uncommon, clinical manifestation. They are sterile in nature and result from mechanical rubbing of cobblestone papillae on the cornea.<sup>33</sup>



**PUK in a 47-year-old white male. This patient had a history of prior perforation requiring a patch graft, which can be viewed on the nasal cornea. The cornea shows 70% thinning infratemporally with significant neovascularization. He required treatment with oral prednisone, slowly tapered over many months, and cyclophosphamide administered by a rheumatologist.**

First-line treatment includes topical antihistamines and mast cell stabilizers. Topical steroids can also be considered, especially in more severe cases. In addition, calcineurin inhibitors, NSAIDs and oral antihistamines can be employed. Avoid triggers such as eye rubbing, wind, heat and sunlight. Artificial tears and cool compresses can provide some supportive relief. In the case of corneal shield ulcers, recommend a broad-spectrum antibiotic QID until the epithelium heals.<sup>34</sup>

Kids often outgrow VKC with time, but it can take years to run its course. Vision loss is possible secondary to corneal neovascularization and subsequent scarring, but this outcome is rare.

**Peripheral ulcerative keratitis (PUK).** This is a broad diagnostic term used to describe peripheral corneal thinning caused by a variety of collagen vascular conditions. These autoimmune conditions include rheumatoid arthritis, polyarteritis nodosa, Wegener's granulomatosis, inflammatory bowel disease and systemic lupus erythematosus, to name a few. Rheumatoid arthritis is by far the most common of these etiologies to cause PUK.

PUK is a unilateral condition consisting of an epithelial defect, crescent-shaped stromal inflammation with thinning and accompanying episcleritis or necrotising scleritis.<sup>35</sup> In advanced disease, perforation can ensue, which is why prompt diagnosis and treatment

is critical. PUK is the initial symptom of collagen vascular disease in 50% of cases.<sup>36</sup>

If PUK is observed in a patient with no known collagen vascular disease, thorough personal and family history and lab testing is recommended. A typical lab workup includes complete blood count with differentials, erythrocyte sedimentation rate, rheumatoid factor, antinuclear antibody, antineutrophil cytoplasmic antibodies, chest X-ray examination and liver enzymes. If associated collagen vascular disease is detected, direct therapy at managing the systemic condition with the help of a rheumatologist.

Topical steroids can be used in early disease, but often systemic immunosuppressive agents are required. First-line therapy involves systemic corticosteroids and often a cytotoxic agent.<sup>35</sup> Common immunosuppressants include cyclophosphamide, methotrexate, azathioprine and oral cyclosporine.<sup>37</sup> Biologics can also be considered. In addition, frequent lubrication with preservative-free tears and possibly a bandage CL can improve the corneal microenvironment, as there is a high rate of concurrent dry eye disease in these patients. In more severe disease, surgical intervention may be required. Surgical techniques include tissue adhesive, lamellar graft, tectonic corneal grafting and amniotic membrane transplantation.<sup>35</sup>

### Neoplastic/Deposition Processes

Accumulations of tissue or other material form yet another threat to limbal health and function.

**Pterygia.** These are marked by fibrovascular tissue extending onto the cornea, caused primarily by UV exposure. The fibers are thought to develop from damaged fibroblasts. Pterygia destroy Bowman's layer, and an iron line can often be observed at the leading edge, which consists of a flat gray zone.<sup>22</sup>

Pterygia are most common nasally. Symptoms include foreign body sensation, irritation and photophobia. These growths can induce irregular astigmatism, leading to a decrease in best-corrected visual acuity, especially as they encroach on the visual axis. Frequent lubrication is recommended for symptomatic pterygia, and topical NSAIDs or steroids can be used in cases of active inflammation. Perform surgical excision if the line of sight becomes threatened.

**Band keratopathy,** caused by deposition of calcium in Bowman's, is often stimulated by chronic uveitis or hypercalcemic conditions such as chronic kidney failure. Band keratopathy begins peripherally on the nasal or temporal side and is marked by a gray opacity that can become white and chalky. The edge of the opacity is often separated from the limbus by a lucent zone. This is thought to be caused by an absent Bowman's layer or inability of limbal vessels to prevent calcium deposition.<sup>22</sup>



Band keratopathy can break through the epithelium in later stages of disease. Also in advanced presentations, calcific deposition can extend horizontally across the cornea from limbus to limbus. Additionally, hyaline material and fibrous neovascularization can surround the calcified lesion. Thankfully, these lesions progress slowly.

If the etiology is unknown, lab testing should include serum calcium, phosphorus, uric acid and renal function. Hyperparathyroid and sarcoid testing with PTH and ACE, respectively, should also be considered. Also, ask patients about vitamin and calcium supplement intake.

Band keratopathy is asymptomatic in its early stages, but patients can experience decreased acuity, foreign body sensation, tearing and light sensitivity in more advanced disease. Early stages only require management of the underlying etiology. Surgical intervention is indicated if the deposition is encroaching on the line of sight or if the deposits are causing surface discomfort. First-line surgical therapy is epithelial debridement followed by the administration of EDTA, a chelating agent. Phototherapeutic keratectomy is also effective. Amniotic membranes can be used following deposit removal to speed up the rate of healing.<sup>22</sup>

## Degenerative Processes

Breakdown of corneal structures typically manifests slowly and subtly. Let's look at two affecting the limbus.

### *Terrien's marginal degeneration.*

This rare, asymptomatic and bilateral peripheral degeneration is idiopathic in nature and progresses slowly. It occurs most commonly in 20- to 40-year-old men and presents with a largely white and quiet eye. The degeneration begins superonasally with superficial neovascularization, punctate opacities and a gutter between the opacities and the limbus.<sup>22</sup> The epithelium remains intact but Bowman's and Descemet's are disrupted. Over the course of years, the stroma continues to thin. As it does, aqueous pockets and possibly a yellow-white lipid zone can be observed.

There are two forms of this degeneration: a quiet one seen in older patients, which yields little to no symptoms, and an inflammatory form in younger patients.<sup>22</sup> The latter is often accompanied by episodes of episcleritis or scleritis, which can be treated with steroids.<sup>38</sup> Many cases don't require treatment, but in the rare event of perforation, consider lamellar or eccentric grafts.<sup>22</sup>


***Pellucid marginal degeneration.*** This painless condition with no observable inflammation is marked by bilateral inferior corneal thinning. It often causes high amounts of irregular or against-the-rule astigmatism. It tends to progress slowly and can be diagnosed with corneal topography, which commonly reveals a "kissing birds" or "crab claw" pattern. Specialty CLs such as sclerals may be indicated for optimal visual acuity.

## Takeaways

The corneoscleral limbus is crucial for barrier protection, prompt corneal healing and corneal transparency maintenance. The limbus aids in fighting off infection, injury and inflammation. Maintain integrity by preserving limbal stem cells, keeping conjunctival tissue at bay and ensuring a hydrated, stable corneal surface. Restoring healthy limbal function includes adequately lubricating the ocular surface, minimizing inflammatory responses and avoiding mechanical damage. In cases of severe limbal compromise, consider amniotic membranes, grafts or LSCT to restore corneal structure and function. ■

- Sangwan VS. Limbal stem cells in health and disease. *Biosci Rep*. 2001;21(4):385-405.
- Meller D, Tseng SC. Conjunctival epithelial cell differentiation on amniotic membrane. *Invest Ophthalmol Vis Sci*. 1999;40(5):878-86.
- Lavker RM, Dong G, Cheng SZ, et al. Relative proliferative rates of limbal and corneal epithelia. Implications of corneal epithelial migration, circadian rhythm, and suprabasally located DNA-synthesizing keratinocytes. *Invest Ophthalmol Vis Sci*. 1991;32:1864-75.
- Thoft RA, Friend J. The X, Y, Z hypothesis of corneal epithelial maintenance. *Invest Ophthalmol Vis Sci*. 1983;24(10):1442-3.
- Hanna C, Bicknell DS, O'Brien JE. Cell turnover in the adult human eye. *Arch Ophthalmol*. 1961;65:695-8.
- Davenger M, Evensen A. Role of the pericorneal peripapillary structure in renewal of corneal epithelium. *Nature*. 1971;229(5286):560-1.
- Schermer A, Galvin S, Sun TT. Differentiation-related expression of a major 64K corneal keratin in vivo and in culture suggests limbal location of corneal epithelial stem cells. *J Cell Biol*. 1986;103(1):49-62.
- Kruse FE. Stem cells and corneal epithelial regeneration. *Eye (Lond)*. 1994;8(Pt 2):170-83.

- Dua HS, Azuara-Blanco A. Limbal stem cells of the corneal epithelium. *Surv Ophthalmol*. 2000;44(5):415-25.
- Lim P, Fuchsluger TA, Jurkunas UV. Limbal stem cell deficiency and corneal neovascularization. *Semin Ophthalmol*. 2009;24(3):139-48.
- Azar DT. Corneal angiogenic privilege: angiogenic and antiangiogenic factors in corneal avascularity, vasculogenesis, and wound healing (an American Ophthalmological Society thesis). *Trans Am Ophthalmol Soc*. 2006;104:264-302.
- Chang JH, Gabison EE, Kato T, et al. Corneal neovascularization. *Curr Opin Ophthalmol*. 2001;12(4):242-9.
- Puangricharem V, Tseng SC. Cytologic evidence of corneal diseases with limbal stem cell deficiency. *Ophthalmology*. 1995;102(10):1476-85.
- Sangwan VS, Jain V, Vemuganti GK, et al. Vernal keratoconjunctivitis with limbal stem cell deficiency. *Cornea*. 2011;30(5):491-6.
- Sejpal K, Bakhtiar P, Deng SX. Presentation, diagnosis and management of limbal stem cell deficiency. *Middle East Afr J Ophthalmol*. 2013;20(1):5-10.
- Conto JE. A review of limbal stem cell deficiency. *J Dry Eye Ocul Sur Dis*. 2019;2(1):4-11.
- Donisi PM, Rama P, Fasolo A, et al. Analysis of limbal stem cell deficiency by corneal impression cytology. *Cornea*. 2003;22(6):533-8.
- Nelson JD. Superior limbic keratoconjunctivitis (SLK). *Eye (Lond)*. 1989;3(Pt 2):180-9.
- Cher I. Superior limbic keratoconjunctivitis: multifactorial mechanical pathogenesis. *Clin Exp Ophthalmol*. 2000;28:181-4.
- Goto E, Shimura S, Shimazaki J, et al. Treatment of superior limbic keratoconjunctivitis by application of autologous serum. *Cornea*. 2001;20(8):807-10.
- Driebe WT Jr, Sakhalkar MV. Superior limbic keratoconjunctivitis. In: Krachmer JH, Mannis MJ, Holland EJ, eds. *Cornea: Fundamentals, Diagnostic, Management*. 3rd ed. St Louis, MO: Elsevier; 2011, 623-27.
- Chang RI, Ching S. Corneal and conjunctival degenerations. In: Krachmer JH, Mannis MJ, Holland EJ, eds. *Cornea: Fundamentals, Diagnostic, Management*. 3rd ed. St Louis, MO: Elsevier; 2011, 907-15.
- Accorinti M, Gilardi M, Giubilei M, et al. Corneal and scleral dellen after an uneventful pterygium surgery and a febrile episode. *Case Rep Ophthalmol*. 2014;5(1):111-5.
- Chung G. Phlyctenular keratoconjunctivitis and marginal staphylococcal keratitis. In: Krachmer JH, Mannis MJ, Holland EJ, eds. *Cornea: Fundamentals, Diagnostic, Management*. 3rd ed. St Louis, MO: Elsevier; 2011, 1143-8.
- Smolin G. Hypersensitivity reactions. In: Smolin G, ed. *Ocular Immunology*. 2nd ed. Boston, MA: Little, Brown; 1986.
- Watson PG. Management of Mooren's ulceration. *Eye (Lond)*. 1997;11(Pt 3):349-56.
- Garg P, Sangwan VS. Mooren's ulcer. In: Krachmer JH, Mannis MJ, Holland EJ, eds. *Cornea: Fundamentals, Diagnostic, Management*. 3rd ed. St Louis, MO: Elsevier; 2011, 1149-53.
- Kafkala C, Choi J, Zafirakis P, et al. Mooren ulcer: an immunopathologic study. *Cornea*. 2006;25(6):667-73.
- Sangwan VS, Zafirakis P, Foster CS. Mooren's ulcer: current concepts in management. *Indian J Ophthalmol*. 1997;45(1):7-17.
- Tandon R, Chawla B, Verma K, et al. Outcome of treatment of Mooren ulcer with topical cyclosporine A 2%. *Cornea*. 2008;27(8):859-61.
- Yang L, Xiao J, Wang J, et al. Clinical characteristics and risk factors of recurrent Mooren's ulcer. *J Ophthalmol*. 2017;2017:8978527.
- Bozkurt MK, Bozkurt B, Artac H, et al. Vernal keratoconjunctivitis—a rare but serious comorbidity of allergic rhinitis and eustachian tube dysfunction. *Int J Pediatr Otorhinolaryngol*. 2010;74(1):60-3.
- Bonini S, Bonini S, Lambiase A, et al. Vernal keratoconjunctivitis revisited: a case series of 195 patients with long-term followup. *Ophthalmology*. 2000;107(6):1157-63.
- Cetinkaya A, Akova YA, Yursun D, et al. Topical cyclosporine in the management of shield ulcers. *Cornea*. 2004;23(2):194-200.
- Yagci A. Update on peripheral ulcerative keratitis. *Clin Ophthalmol*. 2012;6:747-54. 36. Tauber J, Sainz de la Maza M, Hoang-Xuan T, et al. An analysis of therapeutic decision making regarding immunosuppressive chemotherapy for peripheral ulcerative keratitis. *Cornea*. 1990;9(1):66-73.
- Cao Y, Zhang W, Wu J, et al. Peripheral ulcerative keratitis associated with autoimmune disease: pathogenesis and treatment. *J Ophthalmol*. 2017;2017:7298026.
- Austin P, Brown SI. Inflammatory Terrien's marginal corneal disease. *Am J Ophthalmol*. 1981;92(2):189-92.



# SKIP THE SCALPEL? A MEDICAL APPROACH TO ENDO RECOVERY

In time, rho kinase inhibitors could become a revolutionary way to treat corneal endothelial disease.



**BY AARON BRONNER, OD**  
KENNEWICK, WA  
**HUY DO, OD**  
PORTLAND, OR

It is unusual for a treatment algorithm to be dramatically re-written for ophthalmic pathology. This occurred in the early 2000s with anti-VEGF medications taking over as the treatment of choice for wet macular degeneration and subsequently most retinal vascular issues. At the same time, posterior lamellar transplants began replacing penetrating keratoplasty (PK) as the surgical treatment of choice for all forms of endothelial decompensation. We may currently be in the initial stages of another such shift in the clinical management of corneal endothelial disease with the use of rho kinase (ROCK) inhibitors.

A relatively new ophthalmic class, ROCK inhibitors have been around for a few years in the form of Rhopressa (netarsudil, Aerie) and Rocklatan (netarsudil/latanoprost, Aerie) in the field of glaucoma. The revelation that a glaucoma med might be repurposed for an altogether different condition involving an unrelated ocular struc-

ture could, if validated by large-scale studies, emerge as one of this decade's biggest success stories.

## Grow Your Own

The mechanism of ROCK inhibitors for IOP control has to do with the molecules' influence on cytoskeleton and intracellular adhesions. These cytostructural changes result in a decrease in resistance to aqueous outflow at the point of the trabecular meshwork. Beyond the specific influence of ROCK inhibition, Rhopressa also targets norepinephrine transport, which secondarily reduces production of aqueous and reduced IOP.<sup>1,2</sup>

The two netarsudil-containing medications offer a nice, once-daily adjunct to the medical management of glaucoma and, depending on out-of-pocket patient expense, are near the front of the therapeutic options here. However, evidence is continuing to mount that the role of ROCK inhibitors in the treatment of endothelial-based corneal edema could be even more profound.

Given that the corneal endothelium is arrested in the cell cycle and

therefore not mitotic, any process that damages these cells can only be treated via transplanting new ones into the eye. Currently, the standard practice with any form of endothelial decompensation resulting in corneal edema—regardless of specific etiology—is essentially a period of “handholding” until the patient is so bothered by reduced vision that they require surgical intervention.

Though the threshold to consider transplant surgery for endothelial decompensation has dropped significantly since the advent and widespread adoption of lamellar procedures like Descemet's stripping automated endothelial keratoplasty (DSAEK) and Descemet's membrane endothelial keratoplasty (DMEK), these techniques still present significant hardships for patients. These may include:

- potential long travel to a surgery center for those who do not live near a surgeon
- the need for the patient to remain in a supine position the first few days postoperatively
- the possibility of graft detachment and need for a subsequent re-bubble

### About the authors

**Dr. Bronner** is an attending optometrist at Pacific Cataract and Laser Institute in Kennewick, WA. **Dr. Do** completed his residency in ocular disease and surgical comanagement at Georgia Eye Partners in Atlanta. He currently practices at Kaiser Permanente Northwest in Portland, OR. He is a Fellow of the American Academy of Optometry. They have no financial interests to disclose.

- ongoing risk of transplant rejection
- the potential sequelae of topical corticosteroid use needed to reduce risk of rejection

- failure of the graft over time and the need to re-transplant, as these grafts have a finite life expectancy

The ability to avoid or at least postpone these transplant-based issues led to the development of the Descemet's stripping-only (DSO) procedure, also known as Descemetorhexis without endothelial keratoplasty (DWEK). In DSO, patients with substantial central and localized Fuchs' dystrophy have the central zone of endothelium and Descemet's membrane removed and then are left to allow their normal peripheral endothelial cells to migrate in and fill this zone without the light-scattering effects of guttata.

While DSO avoids many of the issues that develop with transplants, it is a niche surgery and only reasonable for a select population of patients with endothelial disease. In reality, it is likely more of a temporizing measure, as removing diseased endothelium does nothing to avoid long-term decompensation. Further, issues such as inducement of irregular astigmatism, deep scarring and non-clearing corneal edema, may also develop.<sup>3</sup>

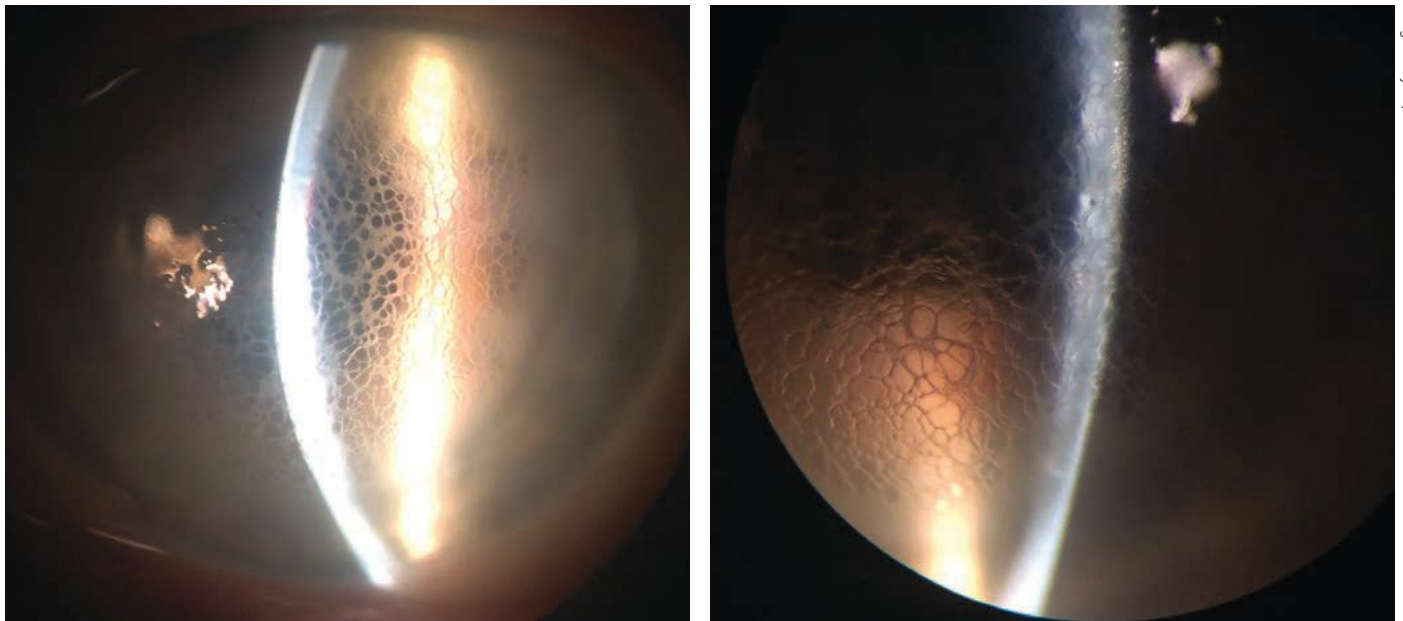
Enter ROCK inhibitors. The mechanism of ROCK inhibition on cellular and intracellular adhesions is not limited to the trabecular meshwork. Within the cornea, these molecules seem to promote migration and spread of corneal endothelium, which perhaps enhances the normal spread of endothelium following injury and localized cellular loss. It also prevents cellular apoptosis, a laudable effect that is critical for preserving existing endothelium. This can be initiated in Fuchs' dystrophy secondary to the physical strain placed on the cell walls of endothelium adjacent to guttata.<sup>1,2,4</sup>

Most exciting of all, there is some evidence that ROCK inhibitors may promote endothelial proliferation, which given the non-mitotic status of these cells, has enormous clinical potential.<sup>2,4,6</sup> If ROCK inhibition truly does promote controlled proliferation of endothelium, the algorithm for the management of endothelium-mediated corneal edema may be re-written. These agents can also serve as important components of effective cultivation methods to propagate endothelial cells for use in cell-based therapies.

To date, the use of ROCK inhibition in corneal disease has been more complementary than revolutionary.

Its first broad use in corneal disease was as adjunctive therapy to speed and facilitate recovery within DSO patients. More recently, as clinicians have become more comfortable with the use of these agents for corneal disease, case reports of ROCK inhibition prior to corneal surgery have been published. One small series in particular demonstrated the effect of ROCK inhibition in corneal edema secondary to a broad range of pathologies. The author of this series was quick to point out that not all patients with corneal edema will respond positively to ROCK inhibition, and even includes a case of treatment failure to illustrate the point—it can be impossible to predict at this point who will and won't respond. Notably, this case series only had a treatment duration of a month, and its effect, when successful, was maintained even after cessation of netarsudil.<sup>7</sup>


All that said, the use of ROCK inhibitors for corneal endothelial disease is a subfield in its infancy. It is possible further research will show less efficacy than hoped for and its use may remain a purely secondary therapy—promoting both graft survival or recovery from DSO. However, it's also possible that as we become better at predicting



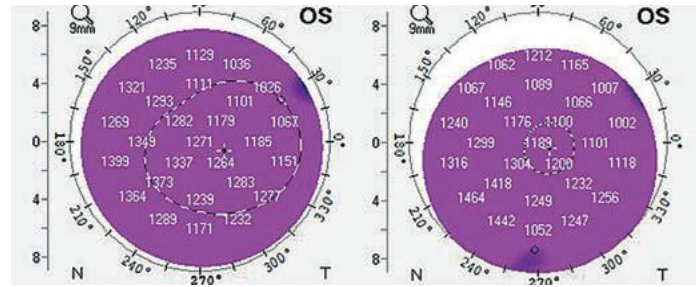
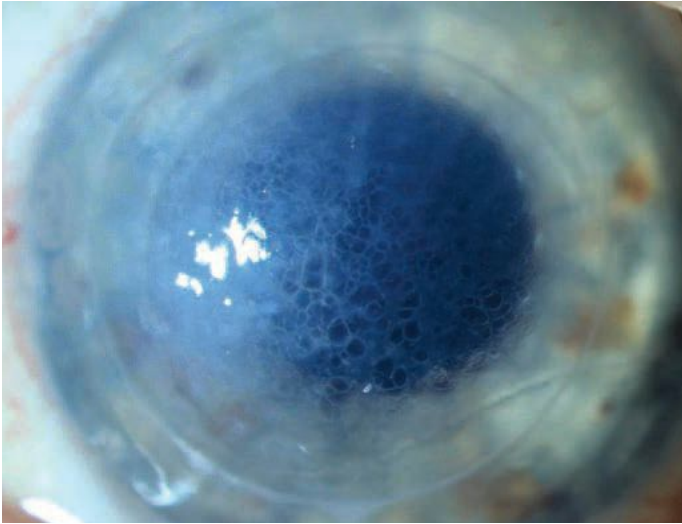
Images: Hiv Do, MD

**Left:** Diffuse honeycomb corneal edema in a post-DSAEK eye. This patient is taking Rhopressa once daily. **Right:** Optic section of same patient. Note the honeycomb is confined to the epithelial layer.





Images: Aaron Bonner, OD



**Left:** Honeycomb edema in a patient using off-label Rhopressa once daily as a medical tamponade in a failed DSAEK under PK.

**Above:** These are pachymetries before and after initiation of Rhopressa for the patient. Despite the development of honeycomb edema, the pachymetries are actually thinner following addition of Rhopressa. Further medical treatment with Rhopressa is ongoing.

the effectiveness of the agents or we develop more effective and targeted agents, ROCK inhibition may periodically or even widely replace corneal transplantation. Regardless, we are standing on the precipice in the management of corneal endothelial disease. Time will tell where we go from here, but for now, it's worth keeping a close eye on the research.

### A New Clinical Entity

Regardless of how far the application of ROCK inhibitors goes in corneal endothelial disease, we are left with one lasting effect of the drug: the potential of these meds to produce a totally new clinical manifestation called *honeycomb corneal edema*, alternately known as both *macrocytic epithelial edema* and *reticular bullous epithelial edema*.

Honeycomb edema is characterized by profoundly diffused but clearly delineated “cells” of epithelial edema that makes it wildly different in appearance from typical microcystic epithelial edema. This fascinating entity is related entirely to the use of ROCK inhibition in eyes with stromal edema or compromised endothelial health and is extremely common among that narrow population, but should not occur in eyes with healthy corneas using the medication for glaucoma.

Its mechanism likely has nothing to do with the endothelial effects of the drug—as our own experience with the medication suggests—where we have

seen eyes develop honeycomb edema despite significant reduction in corneal thickness. Rather, honeycomb edema is probably a manifestation of the ROCK inhibitor-induced changes in how the epithelium responds to the strain of corneal edema through alterations in its intracellular adhesions.

It has been well documented that ROCK inhibitors increase the permeability of tight junctions.<sup>8</sup> Tight junctions in the corneal epithelium promote maintenance of transparency by impairing passage of sodium ions and subsequent fluid into epithelial cells. Perhaps the honeycomb-shaped epithelial edema phenomenon is a result of ROCK inhibitors weakening corneal epithelial tight junctions, leading to an increased passage of fluid into these squamous, polygonal-shaped basal and surface epithelial cells in the setting of stromal edema—resulting in a clinical appearance resembling a honeycomb.

However, this is all still a theory and speculative, as cellular studies need to be conducted. According to the review cited earlier, all patients with stromal edema on ROCK-inhibitor therapy will develop honeycomb edema, and importantly, its development does not portend long-term treatment success or failure.<sup>8</sup> In eyes that respond positively to the drug, the honeycomb edema will fade over time. In those that fail to respond to ROCK inhibition, edema will persist until the medication is discontinued at which point it will clear.<sup>2,8</sup>

### Watch this Space

Though much more robust research is required prior to declaring ROCK inhibitors a front-line therapy in the clinical management of corneal edema, their use does hold promise even though this field is in its infancy. It's also not every day a brand new clinical entity manifests, which is what ROCK inhibitors have created with honeycomb epithelial edema in patients with pre-existing stromal edema. While much can change with further research, its apparent we should all keep a close eye on the research with ROCK inhibition in corneal edema and make ourselves familiar with the complication, however benign, of its use in this population—honeycomb epithelial edema. ■

1. Moshifar M, Parker L, Birdsong OC, et al. Use of rho kinase inhibitors in ophthalmology: a review of the literature. *Med Hypothesis Discov Innov Ophthalmol.* 2018;7:101-11.
2. Syed Za, Rapuano CJ. Rho kinase (ROCK) inhibitors in the management of corneal endothelial disease *Curr Opin Ophthalmol.* 2021;31.
3. Davies E, Jurkunas U, Pineda R. Predictive factors for corneal clearance after descemetorhexis without endothelial keratoplasty. *Cornea.* 2018;37(2):137-140.
4. Kinoshita S, Colby K, Kruse FE. A close look at the clinical efficacy of rho-associated protein kinase inhibitor eye drops for Fuchs endothelial corneal dystrophy. *Cornea.* 2021.
5. Okumura N, Koizumi N, Kay EP, et al. The rock inhibitor eye drop accelerates corneal endothelial wound healing. *Invest Ophthalmol Vis Sci.* 2013; 54:2493-2502.
6. Koizumi N, Okumura N, Ueno M, et al. Rho-associated kinase inhibitor eye drop treatment as a possible medical treatment for Fuchs corneal dystrophy. *Cornea.* 2013; 32:1167-70.
7. Davies E. Case series: novel utilization of rho-kinase inhibitor for the treatment of corneal edema. *Cornea.* 2021; 40:116-20.
8. Yin J, Yu FX. Rho kinases regulate corneal epithelial wound healing. *AM J Physiol Cell Physiol* 2008;295:C378-87.

# New Technologies & Treatments in Eye Care

JUNE 11–12, 2021

 VIRTUAL EVENT

## OVERVIEW

New Technologies & Treatments in Eye Care, brought to you by Review Education Group and MedscapeLIVE, comes to you virtually in 2021!

NT&T's long-running and trusted program for optometrists serves to keep you up-to-date with the latest diagnosis, treatment and management in the areas of dry eye, glaucoma, and retinal disease.

## CHAIR



**Paul M. Karpecki, OD, FAAO**  
Director of Cornea  
Kentucky Eye Institute

## PLANNING PANEL

Aaron Bronner, OD, FAAO  
Danica Marrelli, OD, FAAO  
Walter Whitley, OD, FAAO

\*Earn up to 12 LIVE COPE Credits

To register visit:

[www.ReviewEdu.com/NTT2021](http://www.ReviewEdu.com/NTT2021)

e-mail: [ReviewMeetings@MedscapeLIVE.com](mailto:ReviewMeetings@MedscapeLIVE.com)



\*Approval pending

Review Education Group partners with Salus University for those ODs who are licensed in states that require university credit.

Partially supported by unrestricted educational grants from Aerie, Alcon, Kala Pharmaceuticals, Oyster Point, and Sun Pharmaceuticals.

**REVIEW**  
Education GROUP



# THE MANY LAYERS OF CORNEA COMANAGEMENT

The urgency of clinical scenarios in this area often has optometrists setting expectations —and the relationship dynamic, too.

**BY CATLIN NALLEY**  
CONTRIBUTING WRITER

**T**he practice of medicine is a collaborative effort and optometry is no exception. As we discussed in the first installment of this series, comanagement plays a critical role in healthcare delivery and, as primary eyecare providers, ODs should be at the helm of the referral relationship.

While comanaging cornea cases is not as commonplace as with cataract patients, it remains an important relationship that every optometrist should have in their network. Understanding how to leverage collaborative efforts is beneficial for both patients and practice.

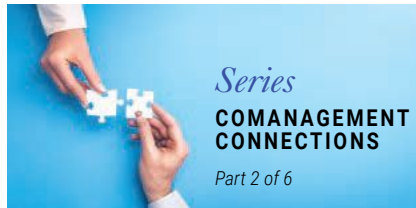First and foremost is the convenience for patients. In many cases, the best cornea specialist is not always the closest. Comanagement ensures patients receive specialized care while also having the support of their primary optometrist, eliminating the need for unnecessary travel.

“Comanagement allows patients to obtain the most specialized care while maintaining a meaningful relationship with their local optometrist, who has fostered their care for years,” notes Katelyn Lucas, OD, of Price Vision Group, a large cornea specialty practice in Indianapolis. “It also allows the optometrist to see the cornea in the early phase so that they can better determine if issues arise such as rejection, wound dehiscence, increased inflammation or other problems that can occur over time.

“With cornea surgeries, especially transplants, lack of follow-up can lead to loss of graft and even permanent vision loss due to steroid induced glaucoma, immunologic

rejections or infections,” she continues. “Getting in for a timely exam when problems arise is critical in taking care of corneal transplants, and having a doctor convenient to their location allows for prompt medical attention.”

This second installment of our comanagement series will delve into cornea management and ways to help ODs enhance their referral relationships. We will take a closer look at the role of optometry in closing the practice gaps that often exist in this category. Comanagement is not only a way to provide comprehensive patient care; when done successfully, it also can elevate individual practices and the profession as a whole.



## Optimizing Cornea Management

Cornea care encompasses a host of conditions and therapeutic interven-

tions; therefore, comanagement can vary greatly depending on the patient’s individual needs. However, no matter the procedure, optimal patient outcomes depend on effective collaboration.

“Surface procedures, such as phototherapeutic keratectomy (PTK), superficial keratectomy and corneal crosslinking (CXL), lend themselves well to comanagement between optometry and ophthalmology,” notes Mitch Ibach, OD, of Vance Thompson Vision, a large anterior segment surgical practice in Sioux Falls, SD. “Patients are still going to need some type of vision rehabilitation afterwards and optometrists are in the position to take the lead following surgery.

Intraocular corneal surgeries (or, more broadly, transplants) do not follow the path of traditional comanagement, he explains. “The majority of early post-op management—the first three months or more—occurs at the surgical center due to the delicate nature of the follow-up care. The





**Foreign body cases are one area where it's crucial for optometrists to take the lead in initiating urgent care to the full extent of their skills and scope of practice. This is a patient's cornea immediately after removal of a metallic foreign body but prior to rust ring removal. The object was superficial enough that it was removed with a sterile cotton swab after anesthetizing the patient's eye.**

primary referring OD often takes over post-op care in most cases later than in other, less invasive procedures.”

When a corneal transplant patient returns to their optometrist can vary and usually depends on how the surgical center handles postoperative care. However, the optometrist's work begins well before surgery. Preparing the ocular surface for corneal surgery is an important preoperative step in maximizing healing, notes Dr. Ibach.

“Careful documentation of preoperative acuities is essential as well as a detailed assessment of the corneal condition,” says Joseph Shovlin, OD, also at a large multi-specialty practice with emphasis on anterior segment care. “Optometrists should report any other comorbidities or potential problems.

“A lot of these patients will have secondary issues, such as glaucoma,” he explains. “Some patients have lid disease that may be the driver for the corneal problem; therefore, careful documentation of the cornea and adnexa is key.”

One of the most important responsibilities of the OD is managing patient expectations. “You don't want someone

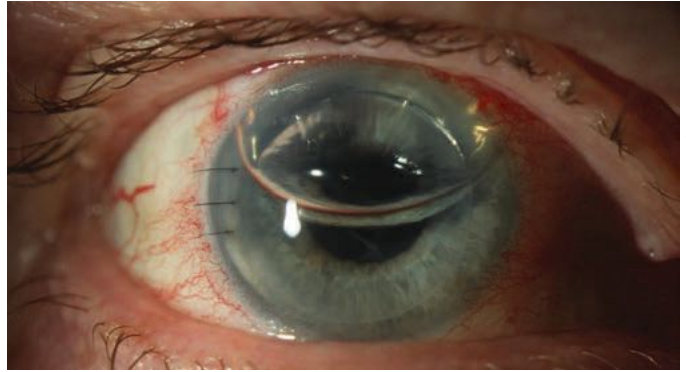
## INVESTING IN TECHNOLOGY

Comprehensive cornea care and comanagement of these conditions depends on a number of factors, including having the right tools at your disposal.

“Corneal topography or tomography should be the next equipment primary optometrists embrace,” notes Dr. Ibach. “Cornea care should be in the hands of optometry and that is much easier to do when you have the right tools.”

It is imperative that ODs have a way to measure the curvature of the cornea, according to Dr. Ibach, who suggests some type of auto or manual keratometry if they do not have a topographer.

Other tools that could be helpful, but don't necessarily need to be available at your practice, include a specular microscope and, on rare occasions, confocal microscopy, according to Dr. Shovlin. “These are not essential to your practice, but they can be very helpful and may be something you want available to you through your referral source.”



**This is a patient one day post-DSAEK. For both DSAEK and DMEK, the transplants are supported by the air bubble in the anterior chamber. Both transplant types require supine positioning that can be difficult for people with spinal problems, and they suffer from periodic early dislocation of the graft, but in this case the eye and transplant are healing well.**

going to a cornea specialist expecting a 20/20 outcome when that might not be possible,” notes Dr. Shovlin.

“Given their longstanding relationship, patients trust their optometrists to prepare them for any procedure, but this is especially important for an intimidating surgery like corneal transplant.”

While the surgical center will be more involved in post-operative care for corneal transplants and other invasive procedures, optometrists have an important role to play and should be included in all aspects of care.


“All corneal transplants need to be followed on a regular basis to monitor for rejection and steroid response which can be done with the comanaging optometrist,” says Dr. Lucas. “This helps ensure the success of optometry practices and improves the doctor-patient bond.

“Early post-op visits done with an optometrist also allows for a ‘second objective opinion,’” she notes. “A good comanaging surgeon values this as they can be unconsciously biased from seeing a complication in their work.”

Infection is always a concern postoperatively, notes Dr. Shovlin. “Depending on when you see the patient, you always have to make sure that the cornea is compact, and be sure to look for signs of early infection and rejection,” he says. “As time goes on, graft failure is a concern and it's very important to monitor intraocular pressures as well as monitor for lens changes with needed prolonged steroid use.”

Dr. Lucas recommends reviewing the ophthalmology practice's comanagement packet, which typically contains instructions for post-op visit frequency, necessary testing and medication changes. Familiarizing yourself with medication schedules and tapers from the surgical center helps improve consistency and outcomes, emphasizes Dr. Ibach.

No matter the type of procedure, communication between providers is essential. “Effective comanagement requires regular communication between the referring OD and the surgeon, especially if there are any questions,” Dr. Lucas reiterates. “There's no such thing as a stupid



question. Optometrists need to feel comfortable enough to be able to ask questions about the care of their shared patients or how to handle a particular group of patients.”

Open lines of communication also help ensure the necessary follow-up occurs. “Failure to return for follow up visits is a risk; however, regular communication between physicians as well as improved understanding of one another’s scheduling preferences can help combat this issue,” Dr. Lucas suggests.

### Taking the Lead

As the ranks of optometrists grow, ODs are in the position to take even more of a leadership role across the continuum of eye care. Beyond surgical procedures, there are other areas of cornea care that can often be handled solely by the optometrist.

There are a variety of ways ODs can take the lead, but two in particular are dry eye and corneal erosions, suggests Dr. Ibach. “Dry eye is definitely a space where optom-

etrists want to do absolutely as much medical treatment as they can for those patients,” he says. “More specific to cornea, recurrent erosions are another.”

If a patient has a corneal erosion, it could be trauma- or dry eye-induced and a one-time event, he explains. “An optometrist can treat that patient in the office with topical antibiotics, lubrication and anti-inflammatories; often, a bandage contact lens or amniotic membrane will help for healing, too.” If it begins to become recurrent, then a referral may be necessary, but “if it’s just the first corneal abrasion or erosion, you don’t always have to send that off for a superficial keratectomy or PTK, especially if the optometrist is comfortable with these conditions.”

A number of clinical entities, such as microbial keratitis, require medical intervention rather than surgery and are well within an optometrist’s scope of practice. Why might an OD opt to send these cases to a specialist? For many, it comes down to what they are comfortable with and their experience with these cases.

“Comanagement looks different depending on your practice. Some generalists are comfortable managing an array of issues—ranging from corneal debridement for patients who have recurring erosion to treating corneal infections—and will only refer when they need a corneal transplant or lamellar surgery,” says Dr. Shovlin. “On the other end of the spectrum are optometrists who prefer to refer any cornea-related issues for confirmation of a diagnosis and appropriate treatment.

“Confidence comes with experience,” he notes. “It’s a matter of seeing enough patients with a particular condition to feel comfortable managing their care. Spend time observing and learning so you can take on cases that are within your scope of practice. I would welcome anyone to come to our practice and spend a day or two with me and our corneal specialists.” Dr. Shovlin practices in Scranton, PA.

### Continuing Education

Whether you’re an OD who wants to start expanding your cornea care or a seasoned clinician looking to take your expertise to the next level, there are number of ways to enhance your practice and become more comfortable caring for these patients.

“Optometrists should actively seek continuing education on current corneal practices, specifically with corneal specialists within their geographic area,” suggests Dr. Lucas. “These events are a good way to hear about new developments in their practice regarding patient care or new technology being used.”

In the time of COVID-19, there is no shortage of online offerings, notes Dr. Ibach. “I always recommend our national meetings, such as the American Academy of Optometry or American Optometric Association. There are also myriad regional meetings and focused optometric groups,” he says. “Many groups have a virtual library of accredited courses that can help you improve your practice.”

### HOW TO WRITE A REFERRAL LETTER

Providing detailed patient information lays the foundation for effective comanagement. Here is an example of a referral letter that will set you, your patient and the ophthalmologist up for success.

April 5, 2021

RE: patient Randolph Duke

Dear Dr. Winthorpe,

Please allow this letter to introduce my above-named patient, a 17yo white male, who has recently shown signs of progressive keratoconus on both his slit lamp exam and corneal topography. His best corrected acuity is OD 20/30+ and OS 20/25- with a moderate amount of myopia and oblique astigmatism that has increased significantly the past four months.

He shows mild apical thinning, posterior corneal stress lines and what appears to be faint iron lines inferiorly in both eyes. His topographic findings include inferior steepening in both eyes. He shows many of the discouraging signs of progressive keratoconus. The remainder of his ocular exam is normal, including a dilated fundus exam and intraocular pressures.

I’d like for you to evaluate the patient’s suitability for corneal crosslinking at this time.

Be assured that by way of introduction, I have provided sufficient information about corneal crosslinking, including expectations, potential risks and alternatives to this treatment option.

I am glad to provide any additional information you might find helpful. Thanking you in advance for seeing this pleasant young man.

Sincerely,

William R. Valentine, OD

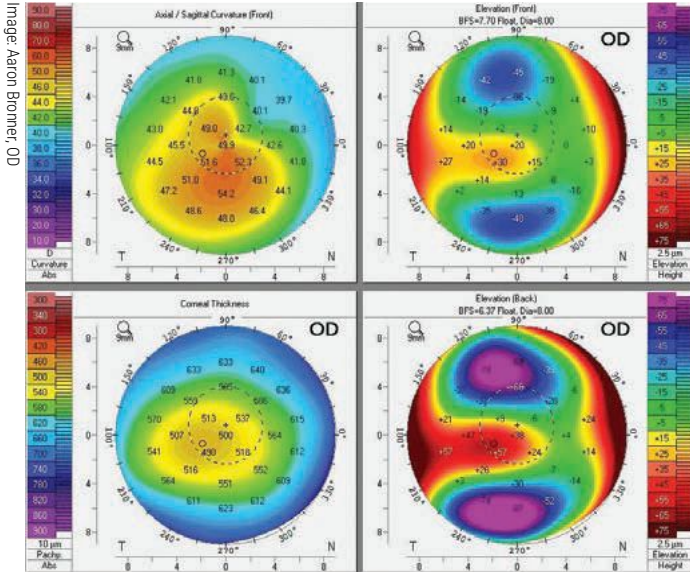


Image: Aaron Bonner, OD

Despite moderate keratoconus, this eye sees relatively well with glasses at 20/25-. Fortunately for the patient, the primary OD was suspicious for keratoconus due to high astigmatism and a reduction in best-corrected acuity and sent them for evaluation. The Pentacam shows deviations with topography, pachymetry, and anterior and posterior elevations that makes the diagnosis clear cut. The patient was able to be crosslinked and maintains good acuity because their primary OD managed the eye perfectly.

A strong relationship with the surgical practice you refer to can also be beneficial to your professional growth. “Oftentimes, just jumping on the phone or even going in and spending a couple hours with the surgeon can be an excellent way to learn,” Dr. Ibach explains.

“Given the broad range of potential cornea conditions and procedures, everyone is not going to be comfortable comanaging every single one,” Dr. Shovlin states. “It is important to know your comfort level and not overextend yourself because that’s not good for you or the patient.”

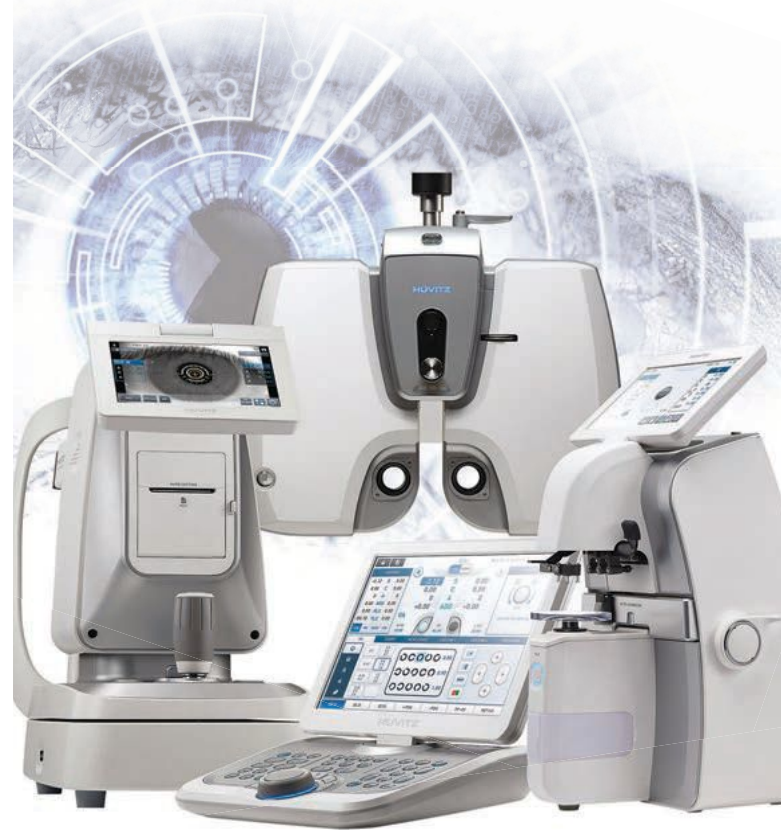That being said, “don’t be afraid to expand your knowledge and skills,” he continues. “Find a colleague—this can be a specialist or a local optometrist who has a special interest in the cornea—who can help guide you clinically so next time you see that particular condition you are more comfortable managing the patient.”

### Addressing Gaps in Care

While advances in cornea management continue, challenges remain, and optometrists are uniquely positioned to tackle these difficulties and fill any gaps in care.

One area where optometrists can have significant impact is keratoconus. With the advent of corneal crosslinking, these patients now have an available intervention that could change the course of their disease. However, many patients are not receiving this treatment as soon as they could.

“With corneal crosslinking being an emerging area in the field, focusing our attention on diagnosing



## ELEVATE PATIENT EXPERIENCE

### THE 9000 HUVITZ SYSTEM

#### HRK-9000A

AUTO REFRACTOR/  
KERATOMETER

- Meibography
- Tear film breakup time
- VA, contrast sensitivity and glare tests

#### HDR-9000

DIGITAL REFRACTOR

- WiFi connectivity
- Large swiveling screen
- Split Jackson Crossed-Cylinder Test

#### HLM-9000

AUTO LENSMETER

- Blue light detection
- High Prism 20D
- Auto paper cutter

FREE INSTALLATION AND EMR INTEGRATION  
3 YEAR WARRANTY

**THE LATEST TECHNOLOGY  
AT A MUCH LOWER PRICE**  
CALL 1-800-COBURN1 TO LEARN MORE


1.800.COBURN1



WWW.COBURNTHECNOLOGIES.COM

CUSTOMERCARECENTER@COBURNTHECNOLOGIES.COM





keratoconus as early as possible and providing treatment will ensure the best possible outcomes for patients,” says Aaron Bronner, OD, of Pacific Cataract and Laser Institute, a large OD-MD multidisciplinary practice in the Northwest. “This requires a shift in professional screening for this disease. We have usually just let them develop organically because there hasn’t been a way to stop progression.

“When keratoconus gets bad enough it becomes apparent and the diagnosis is easy, but what we want to do at this point is identify the condition before it becomes really apparent,” he continues, noting that this requires the appropriate screening tools. “The Pentacam (Oculus) is a very good device that can diagnose keratoconus at stages way before the patient has symptoms.”

If an optometrist has a patient with findings consistent with the condition, such as dramatically increasing astigmatism or not correcting to 20/20 with glasses, they can use this device to confirm their suspicions, suggests Dr. Bronner, who acknowledges this technology may not be available in every optometry practice due to cost constraints.

“If you don’t have the device at your clinic, you can send them to the surgery center that comanages with you for testing only,” he notes. “It doesn’t have to be a full referral and is a cost-effective approach to diagnosing a problem.”

Another potentially challenging but important aspect of care is knowing when to make a referral, particularly when it comes to a procedure like corneal transplant. “Although there have been improvements thanks to DSEK/DMEK, corneal transplants are still challenging procedures with a greater risk of complication than routine procedures like cataract surgery,” says Dr. Bronner. “Therefore, you wouldn’t recommend this surgery at the first signs of endothelial disease. Instead, waiting for the condition to progress somewhat is important.”

“Keep in mind, the risk of DSAEK and DMEK are lower than traditional PK, but higher than say cataract surgery. Because of that, you’ll want to see a bit more VA reduction prior to a surgical referral than you would for a routine cataract operation,” he explains. “Of course, any

### KEY TAKEAWAYS

While cornea comanagement can vary greatly depending on the condition and procedure, it is an essential aspect of care. Here are a few takeaways to help you partner with surgeons more effectively:

- Maintain open lines of communication with the surgical team.
- Provide a comprehensive referral letter with recommendations and patient details.
- Educate your patients and position yourself as a trusted source of information.
- Use continuing education and a strong referral relationship to grow your skills.
- Take the lead on corneal cases that are within your scope of practice.

### CLINICAL PEARLS

- For corneal crosslinking, PTK and superficial keratectomy patients, the first decision is when the epithelial defect has resolved and timing of the bandage contact lens removal.
- Among CXL patients, it is very common to see a thinning/condensing of the pachymetry after treatment with an initial steepening of corneal topography in the first one to six months. This is expected due to epithelial remodeling and shouldn’t cause concern, according to Dr. Ibach.
- Contact lenses play an important role in vision recovery after penetrating and deep anterior lamellar keratoplasties, Dr. Lucas notes. “Fitting specialty contact lenses can be lucrative for optometry practices and help increase contact lens referrals from cornea specialists.”

corneal comanagement center will be happy to see your patient as early in the disease process as you like, but one of the most critical aspects of comanagement is the patient hearing a consistent message from both the referring doctor and the surgery center. Therefore, early referrals should be accompanied by more guarded recommendations for surgery.”

Depending on how you handle comanagement, it can have a positive or negative impact on your patient relationships. “An important part of the patient relationship is the long-term trust that’s been built over time,” notes Dr. Ibach. “That can be put in jeopardy if you don’t thoroughly educate a patient on your findings prior to referring to a specialist.”

For instance, if a patient is “diagnosed” with basement membrane dystrophy or keratoconus at the surgical center, but they were referred for a different condition, it can cause them to doubt their primary eye care provider and be hesitant to return to their practice for postoperative care, according to Dr. Ibach. “Oftentimes, the OD did see and diagnose this problem, but didn’t discuss it with the patient prior to referral,” he explains. “As a result, there is potential for trust to breakdown between the patient and maybe even the comanaging ophthalmologist.”

An ongoing commitment to growing as a healthcare provider, both individually and in collaboration with ophthalmologists, is invaluable to not only for patients, but the profession at large.

“Our ophthalmology colleagues are staying pretty even in number while the patients who need care only continues to grow,” notes Dr. Ibach. “The more that we as optometrists can help facilitate pre- and postoperative management, the more opportunity we’re going to have for our surgical partners to take care of patients from a surgical standpoint.

“Comanagement is also a practice builder. Providing exceptional care can lead to referrals not just from patients, but also the ophthalmologists you work with,” he concludes. “Collaboration, when done well, elevates both patients and their providers.” ■



# VISION EXPO

EDUCATION: JUNE 2-5  
EXHIBIT HALL: JUNE 3-5

ORANGE COUNTY CONVENTION CENTER | ORLANDO, FL




EAST.VISIONEXPO.COM  
#VISIONEXPO

ONE VISION  
ONE FOCUS  
ONE FUTURE

REGISTER NOW

[VEE2021.COM/REGISTER](http://VEE2021.COM/REGISTER)





Earn 2 CE Credits  
(COPE APPROVED)

# A NEW CONSENSUS ON KERATOCONUS

Collagen crosslinking has prompted a more interventional approach to this condition.

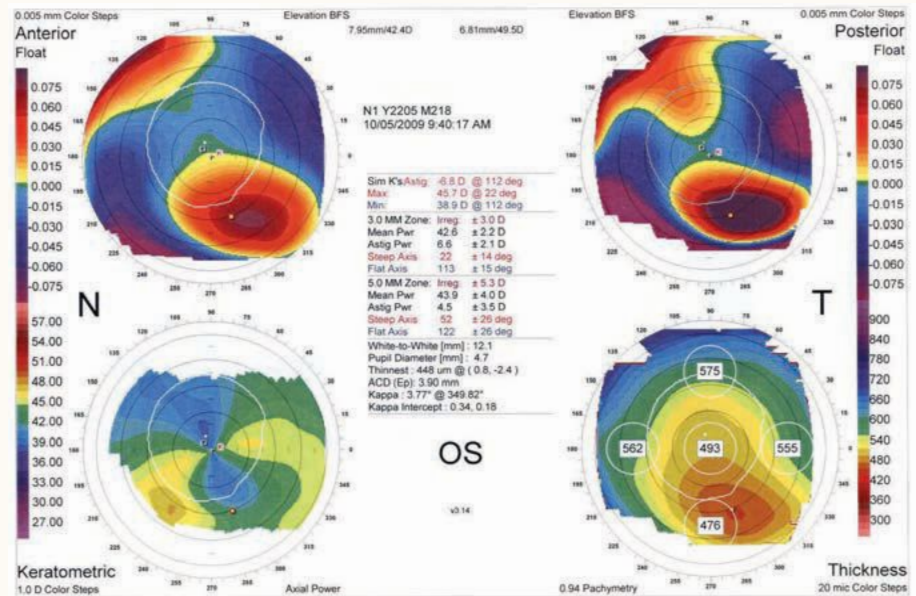


BY MITCH IBACH, OD  
SIOUX FALLS, SD

Imagine encountering a progressive, vision-threatening ocular disease like glaucoma and recommending a treatment plan focused on monitoring, while temporarily improving acuity with glasses and contact lenses, and reserving treatment for only the most end-stage cases. Up until five years ago, this was the standard management approach for patients with keratoconus.

As eye care providers, how do we stop keratoconus, a disease that causes irreversible vision loss, before it gets to the final surgical option? This article presents a new paradigm in keratoconus management that focuses on early diagnosis and earlier intervention, to first catch and then halt this ocular disease.

The standard of care for keratoconus management should shift away from a “monitoring” approach and instead embrace an “interventional”



**Fig. 1. Corneal topography showing a classic inferior steepening to the anterior float. Note the thinned corneal pachymetry in the bottom right.**

one. The new mantra should prioritize new technology to facilitate earlier diagnosis united with early treatment to stop disease progression. The current staple in halting disease progression by strengthening the corneal biomechanics is corneal collagen crosslinking (CXL).

Once the cornea is stabilized, this opens the practitioner’s refractive toolbox of glasses, contact lenses, intrastromal corneal ring segments (ICRS) and topography-guided photorefractive keratectomy. Optometrists play a key role in all three phases of the keratoconus patient life cycle, starting

**About the author** Dr. Ibach is a residency trained optometrist at Vance Thompson Vision in Sioux Falls, SD. He serves as an adjunct clinical faculty for the Illinois College of Optometry and the Pikesville College of Optometry. He receives consulting fees, fees for non-CME/CE services and conducts research with Glaukos.

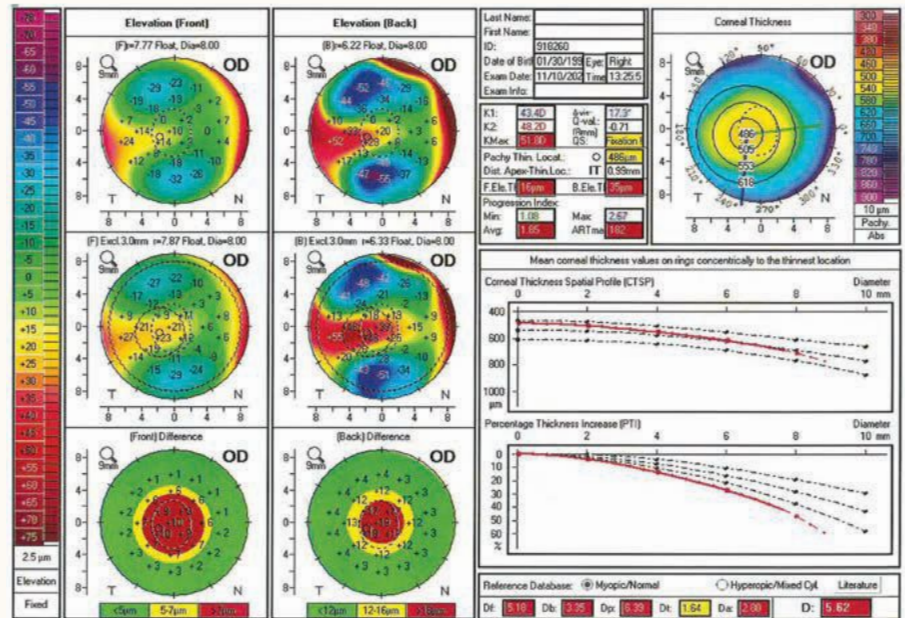


with diagnosis, because many keratoconus patients initially present to optometric practices. After stabilizing treatment (second phase), optometrists are the key providers for optical rehabilitation, the final phase.

## Prompt Diagnosis

Advancements in diagnostic technologies have simplified diagnosis for practitioners, especially in the early or pre-clinical keratoconus patient. Even if your practice doesn't have these new tools, you can still be a master diagnostician. For example, honing in on a "scissoring" reflex with retinoscopy can approach tomography in sensitivity and specificity for diagnosis.<sup>1</sup> In keratoconus patients, the retinoscope reflex bending or bowing is a sign of corneal irregularity. Critically analyzing refractive increases in myopic spherical equivalent and or cylinder increases can raise red flags for early ectasia. An adolescent patient who has yearly continued increases in myopic spherical equivalent greater than 1.00D deserves further testing.

Diagnostic technology can be subdivided into tools for definitive diagnosis where clinical keratoconus is present and diagnostic tools for pre-clinical disease. Assessing corneal curvature with topography and tomography is a mainstay in keratoconus management. A non-symmetric elevation pattern or bowtie, most commonly displaying



**Fig. 2. Pentacam Belin-Ambrosio Enhanced Ectasia Display showing early keratoconus. Note how the corneal percentage thickness increase (lower right graph) is outside normal limits. Also, the color-coded "front" and "back" differences, comparing this patient to a best-fit sphere, are a cause for concern.**

inferior steepening on topography, is pathognomonic for corneal ectasia (Figure 1). Corneal topography is an analysis of the anterior corneal curvature which reports two simulated keratometry values (steep and flat K), corneal astigmatism and the corneal shape/symmetry pattern. Topographers most commonly apply placido disc imaging techniques, but scanning slit technique (Orbscan, Bausch + Lomb) does allow posterior corneal measurements.

Advanced technology is giving practitioners more sensitive data that can allow for earlier interventions. While these new tools are valuable additions to the optometrist's arsenal, clinicians can still diagnose keratoconus even if they do not have access to these technologies. Corneal tomographers employ Scheimpflug imaging which uses a rotating camera to analyze slit beams at different angles.<sup>2</sup> This technique is best suited for a non-planar surface like the cornea.

**Release Date:** April 15, 2021

**Expiration Date:** April 15, 2024

**Estimated Time to Complete Activity:** 2 hours

Jointly provided by Postgraduate Institute for Medicine (PIM) and Review Education Group

**Educational Objectives:** After completing this activity, the participant should be better able to:

- Review the impact of advancing diagnostics.
- Discuss the current standard of care for keratoconus.
- Recognize the role of corneal crosslinking.
- Determine when CXL is an appropriate treatment option.

**Target Audience:** This activity is intended for optometrists engaged in routine eye care and ocular surface disease management.

**Accreditation Statement:** In support of improving patient care, this activity has been planned and implemented by the Postgraduate Institute for Medicine




and Review Education Group. Postgraduate Institute for Medicine is jointly accredited by the Accreditation Council for Continuing Medical Education, the Accreditation Council for Pharmacy Education, and the American Nurses Credentialing Center, to provide continuing education for the healthcare team. Postgraduate Institute for Medicine is accredited by COPE to provide continuing education to optometrists.

**Faculty/Editorial Board:** Mitch Ibach, OD, Vance Thompson Vision, of Sioux Falls, SD.

**Credit Statement:** This course is COPE approved for 2 hours of CE credit. Course ID is 71974-AS. Check with your local state licensing board to see if this counts toward your CE requirement for relicensure.

**Disclosure Statements:** *Authors:* Dr. Ibach receives consulting fees, fees for non-CME/CE services and conducts research with Glaukos. *Managers and Editorial Staff:* The PIM planners and managers have nothing to disclose. The Review Education Group planners, managers and editorial staff have nothing to disclose.



Corneal tomography summarizes anterior corneal shape, posterior corneal shape and corneal pachymetry mapping, and can enroll advanced analyses specifically designed for corneal ectasias like the Belin-Ambrosio Enhanced Ectasia Display (*Figure 2*). Tomography has become the diagnostic gold standard for management of the irregular cornea in today's research and clinical practice.<sup>3</sup> Anterior segment optical coherence tomography (AS-OCT) is another tool that fits more likely as an adjunctive diagnostic for definitive keratoconus diagnosis. AS-OCT provides a high-definition cross-section of the corneal shape.

In the pursuit of earlier diagnosis,

evolving tools for pre-topographic detection of keratoconus are gaining traction. Epithelial mapping uses specialized OCT, which is able to measure and map the most anterior corneal layer. Specifically comparing keratoconic eyes vs. normal, a keratoconus patient's exhibit thinner central epithelium, thinner minimum epithelial thickness, thinner inferior temporal epithelium and a greater difference in superior to inferior epithelial mapping.<sup>4</sup> Summarizing these findings, the epithelium drifts toward thinning directly over the area of posterior corneal bulging, which corresponds to the apex of the cone, and can precede topographic findings.<sup>4</sup>

Although familial history shows a scattered genetic pattern, patients with a positive keratoconus familial history are at a higher risk of developing the disease.<sup>5</sup> Having a first-degree relative with keratoconus is an established risk factor for the disease.<sup>6</sup> Thus, genetic testing is a blossoming method for determining a patient's risk. AvaGen (Avellino Labs) is an in-office cheek swab that examines 75 genes with over 1,000 variants to quantify a patient's relative risk for keratoconus.<sup>7</sup> In genetically high-risk patients, this data may spur practitioners and patients to tighten their follow-up schedule, seek genetic counseling or consider interventional treatment at an earlier stage.

### What is Keratoconus?

The condition is a non-inflammatory, bilateral, often asymmetric corneal degeneration that leads to corneal thinning and steepening (ectasia). In the early stages, patients will lose uncorrected visual acuity, followed by increases in myopic spherical equivalent and regular astigmatism, and finally lose best-corrected visual acuity (BCVA) due to irregular corneal astigmatism.

The prevalence of keratoconus is debatable and inarguably increasing in published literature and among several demographic groups. A now outdated but heavily referenced study for US rates of keratoconus revealed that about one in 1,835 people were affected by the disease.<sup>25</sup> More recent global estimates of keratoconus reported a worldwide prevalence of about one in 750.<sup>26</sup> Most recently, the Raine Study looked at a cohort of 1,259 patients from Western Australia and found that the prevalence of keratoconus to be 1.2%, or one out of every 84 people.<sup>27</sup> This rise in reported prevalence isn't because keratoconus has suddenly become transmissible or contagious, but rather is likely due to improved diagnostic technologies and increased patient awareness driven by the availability of new treatment options.

A keratoconus patient's risk profile can vary based on family history and environmental factors. Overall, the disease shows weak genetic linkages in both autosomal dominant and autosomal recessive genes.<sup>5,28,29</sup> First, systemic diseases showing increased risk of keratoconus include Down syndrome, Ehlers-Danlos syndrome, osteogenesis imperfecta and mitral valve prolapse among others to a lesser extent.<sup>29,30</sup> Studies have shown that patients with Down syndrome have anatomically thinner and steeper corneas, an increased likelihood of aggressive eye rubbing and a keratoconus prevalence at least 10 times higher than non-Down syndrome patients.<sup>30</sup>

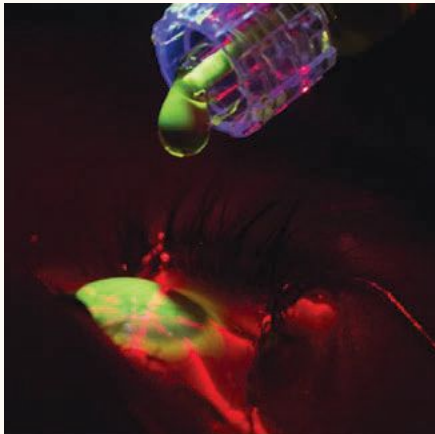
Mechanical eye-rubbing is a modifiable risk factor for the development and progression of keratoconus.<sup>29,30</sup> Ocular atopies (including allergic/vernal conjunctivitis and atopic dermatitis), floppy eyelid syndrome, dry eye disease, blepharitis, digital eyestrain and poorly fitting contact lenses can all lead to the stimulus to rub. Treating these comorbid ocular conditions is an important adjunctive approach for keratoconus. The painless nature of keratoconus, combined with the relative ease of maintaining adequate visual acuity with stronger optical devices, may cause delays in the detection of ectasia.

### Early Intervention

After diagnosis, the next step in keratoconus management is to prevent further progression. Currently, the only treatment aimed at halting corneal ectasia progression with long-term efficacy is CXL. Optometrists play a key role in pre-op education and referral. They are also instrumental in collaborative care including vision rehabilitation with optical devices.

A timely referral for intervention is critical because vision loss due to corneal warpage is often irreversible. In many cases as an early keratoconus patient progresses, changing the prescription in glasses or contact lenses can improve acuity but mask worsening disease. Since patients aren't born with the disease, all keratoconus patients had progression at one point, but younger patients and patients who are aggressive eye rubbers have been shown to have a greater risk of keratometry steepening/worsening.<sup>8</sup> The right patient for CXL is any patient showing progression to this ectatic disease who can safely receive treatment.

Concerning the question, "Which comes first: crosslinking or specialty contact lenses?" I prefer to crosslink these corneas first. After the cornea has been stabilized, specialty contact lenses should provide years of



**Fig. 3. Procedural view during CXL.**

improved visual acuity. However, if a patient has reduced visual function at work or is unable to drive due to vision loss, a specialty contact lens may bridge the gap and greatly improve their quality of life. It's imperative to remember despite improved visual acuity, these patients still have a biomechanically unstable cornea.

The main contraindication to CXL is pregnancy. This patient subset was not studied in the FDA clinical trials.<sup>9</sup> Relative contraindications include individuals under the age of 14 or older than 65 years.<sup>9</sup> More commonly patients under age 14, but in both groups, CXL has been safely performed and can be of tremendous benefit. Patients with active infectious keratitis should be avoided as this is currently off-label, but studies suggest potential benefit and are ongoing.

Epithelium-off CXL was approved by the FDA in 2016 for the treatment of progressive keratoconus and post-refractive surgery ectasia. CXL is a medical procedure that combines riboflavin (vitamin B2) photosensitizer with ultraviolet light (365nm to 370nm) to stiffen the cornea. The coupling of riboflavin and UVA light forms free radicals and singlet oxygen molecules creating covalent bonds or "crosslinks" in the corneal lamellae.<sup>10,11</sup> This chemical reaction leads to a shortening, thickening and stiffening of the corneal tissue.<sup>10,11</sup> The currently approved Dresden protocol starts with epithelium removal followed by a 30-minute riboflavin soak before

UVA irradiation for another 30 minutes (Figure 3).<sup>12</sup>

The pivotal trial for epithelium-off CXL in the US was a prospective, randomized, controlled clinical trial that examined 205 patients with progressive keratoconus.<sup>9</sup> Patients were randomized into a treatment group, which underwent CXL with the Dresden protocol, and a sham control group, which received the photosensitizer but no epithelial debridement or UV exposure.<sup>12</sup> The primary outcome was the mean change in maximum keratometry (Kmax) value at 12 months post treatment.<sup>9</sup> At 12 months, the sham group steepened 1.0D on Kmax while the CXL group showed Kmax flattening of 1.6D.<sup>9</sup>

A crucial step in the CXL referral process is patient education and setting realistic expectations. Epithelium-off crosslinking is FDA approved and, when progression is well documented, commercial insurance coverage for patients is now quite good (Figure 4). Compared with 2017, when only three insurance carriers covered CXL, today 96% of commercially insured patients have coverage for CXL.<sup>13</sup>

Epithelium-off CXL's primary goal is to freeze the cornea in place, and large improvements in corneal flattening or visual acuity can't be overpromised.

Optometrists referring patients for CXL can help prepare patients by telling them two things: initially vision will be worse for about a week before it moves back to baseline, and the surgical eye will have a mild to moderate amount of pain, discomfort and photophobia for three to four days.

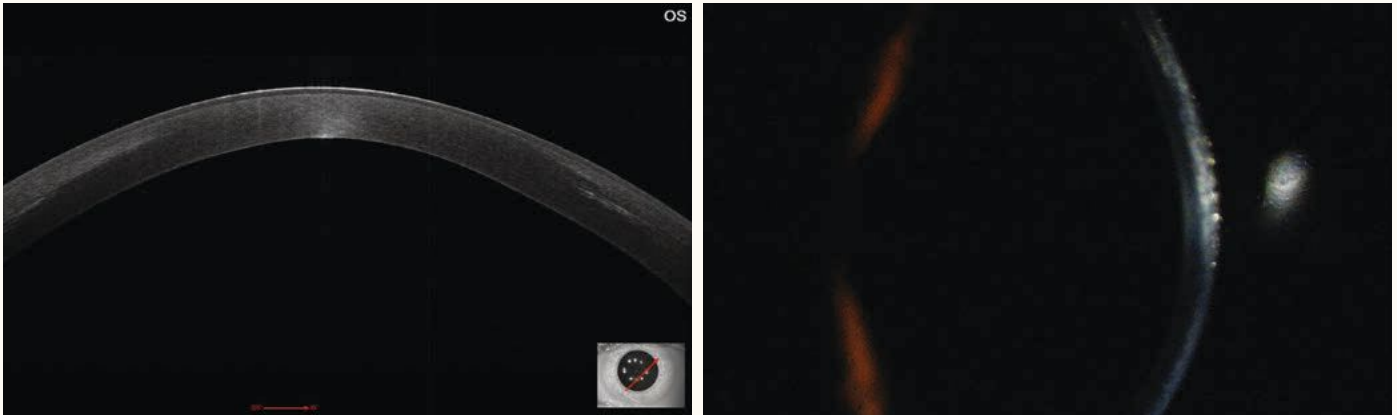

Although pre-op CXL education should focus on the goal of stability, a clinical trial showed on average patients achieved Kmax flattening plus a bonus of mild improvement to BCVA.<sup>9</sup> The most frequent adverse event in the treatment group was corneal haze, but only three eyes had retained haze/scarring at one year, and only two of those showed a decrease in BCVA.<sup>9</sup> Long-term, CXL has shown continued corneal stability out to seven and 13 years in two separate studies.<sup>14,15</sup> One study had a Kmax progression in 0% of cases, while the other had a 7% failure rate at 13 years.<sup>14,15</sup>

The future is also promising for accelerated epithelium-on CXL (ACXL) in the US. ACXL speeds up the procedure and healing for patients and may allow more patients to be treated. Two hurdles in the epithelium-on quest are the barrier function of the epithelium and the CXL reaction requirement of surplus oxygen.<sup>16</sup> Epithelium-on CXL is not currently approved, but FDA trials are underway.

Crosslinking	
MET	REQUIREMENTS
<input type="checkbox"/>	Progressive KCN
<input type="checkbox"/>	Corneal Ectasia after refractive surgery
One of the above diagnoses along with one or more of the below requirements for commercial payers	
<input type="checkbox"/>	An increase of 1 D in steepest keratometry value
<input type="checkbox"/>	An increase of 1 D in reg. astigmatism
<input type="checkbox"/>	A Myopic shift of 0.50 D on subjective manifest
<input type="checkbox"/>	A decrease $\geq 0.1$ mm in the back optical zone radius in rigid contact lens wearers where other information was not available.
<input type="checkbox"/>	Failed conservative treatment (e.g., spectacle correction, rigid contact lenses) (BCBS MN)
<b>Arch Programs:</b> All the below programs need to have documented progressive keratoconus.	
1.) Medicaid Assistance	For patients with Medicaid only. Business office will need to know how many people in household, and patient will need to submit income documentation. This can be faxed to 605-371-7199
2.) Low Reimbursement	Only for commercial payers. Nothing needed prior to surgery
3.) No Insurance	For patients with no insurance. Business office will need to know how many people in household, and patient will need to submit income documentation. This can be faxed to 605-371-7199

**Fig. 4. Example of progression parameters that can be helpful for insurance reimbursement.**





**Fig. 5. Patient one month post-CXL with anterior corneal haze. Note the demarcation/hyperreflective line on OCT.**

Optimizing post-op care for CXL requires a collaborative approach between the referring practitioner and the surgical practice. CXL has no global period, so follow-up care providers should bill office visits and ancillary testing accordingly. Similar to photorefractive keratectomy (PRK), an important early healing step is achieving corneal epithelialization and deciding when to remove the bandage contact lens.

Immediately following the procedure, we can educate patients that their vision will be worse, slowly improving to functional vision around one week and back to baseline at post-op month one to three. If a topography/tomography is performed at one- or three-months post-op, it is not uncommon to see steepening/worsening secondary to epithelial remodeling, and the most informative keratometry stability measurements are nine to 12 months postoperatively. Similarly, corneal pachymetry often measures thinner post-op. Stromal corneal haze is an expected finding at one- and three-months post-op and predictably will fade over time (*Figure 5*). This haze is visually insignificant and resolves without further intervention.<sup>17</sup>

Since CXL is not a refractive procedure, patients may be anxious for new glasses or contact lenses. Depending on patient function, the Rx can be predictably updated at three months post-op. For patients with exceptional needs, prescription or re-fitting may

occur sooner than three months with the expectation that significant adjustments may be necessary in the near-term as the cornea stabilizes.

### Vision Rehabilitation

The proposed third step in our new mantra for keratoconus management is vision rehabilitation, an area where optometrists should be front and center. Once the cornea is biomechanically, and largely refractively stabilized, a myriad of options opens up in the refractive toolbox. In reviewing these options, all have their individual “pros” and “cons,” and they are commonly employed together.

No matter the severity of the keratoconus, it is important that patients have an updated glasses prescription. At minimum glasses provide a “contact lens break” in patients who are heavily reliant on these lenses. If a patient’s keratoconus is mild and glasses correction satisfies their visual needs, this is a great option because patient convenience and safety is unmatched. Unfortunately, in moderate to severe ectatic disease where more corneal warpage has occurred, higher-order aberrations like glare, starbursts and ghosting aren’t corrected by spectacle lenses. If a keratoconus patient has developed ectasia-induced scarring—for example, a patient with a history of corneal hydrops (*Figure 6*)—glasses will be of little visual benefit.

Contact lenses for keratoconus can be divided into “soft disposable lenses” and “specialty hard lenses.”

### General Post-op Guidelines for Corneal Crosslinking\*

#### Day 1: This visit is optional for some providers

- Assure bandage lens is in place
- Discuss pain management and postoperative medications
- Central epithelial defect will be present
- Vision often significantly worse than pre-op

#### Day 4-7: Main decision is whether to remove bandage lens

- Epithelialization usually complete
- Pain should be improving
- Review postoperative medications
- Vision still decreased from baseline, but functional

#### Day 30:

- Finished or finishing postoperative medications
- Vision approaching or at baseline
- Slit lamp shows early corneal haze
- May release temporary spectacle prescription, if needed

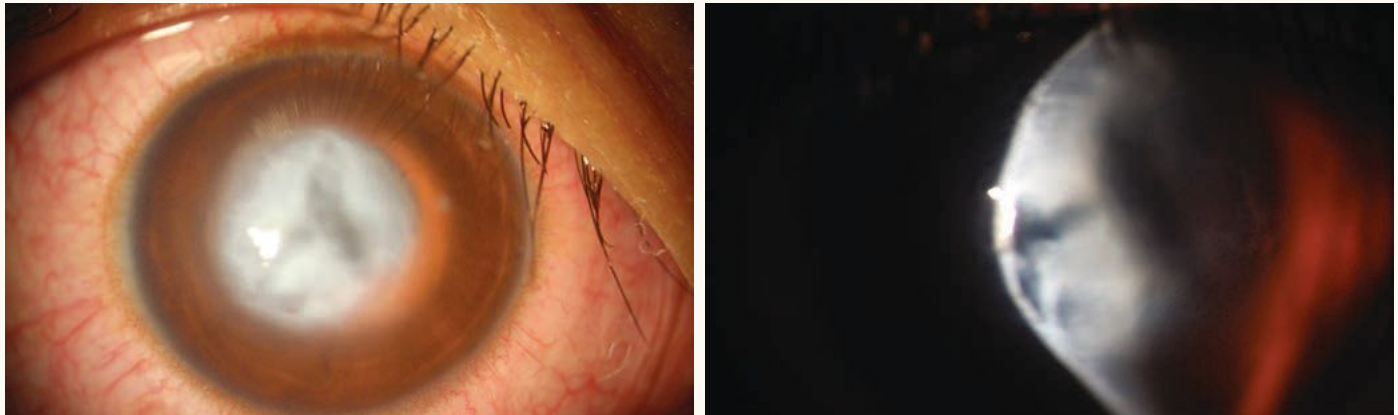
#### Day 90:

- Corneal haze improving
- May begin contact lens fitting
- Release new spectacle Rx

#### Annually:

- Update topography/tomography to confirm stability

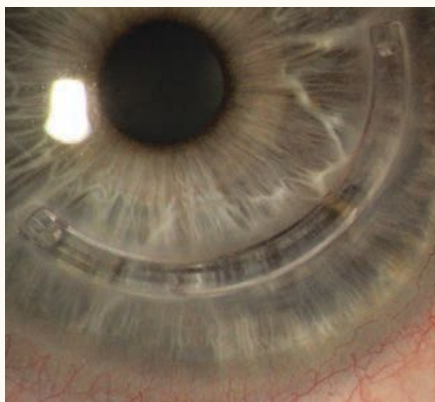
\*May vary by provider and practice.



**Fig. 6. Acute corneal hydrops in a patient with severe keratoconus.**

In large part, disposable soft contact lenses provide similar vision quality in ectatic corneas compared to glasses because the soft disposable lenses mold to the irregular anterior corneal shape. Specialty soft lenses, which are dispensed in more mild disease, are designed for the irregular cornea and feature an increased lens center thickness to help retain their shape over an irregular cornea thereby providing more optimal vision correction.

Gas permeable (GP) contact lens designs are more frequently used for patients spanning all levels of keratoconic disease because the tear prism under the lens masks the irregular anterior refractive surface. By minimizing higher order aberrations (glare, ghosting, starbursts) in ectatic corneas, the vision improvement with GP lenses can be life-changing for patients. There are a variety of gas permeable lens options available from smaller corneal and limbal designs



**Fig. 7. Inferior Intacs ring placed in a patient with an inferiorly decentered cone.**

to larger diameter scleral lenses. If the optics of a gas permeable lens are desirable, hybrid lenses (GP center and soft lens skirt) are also an option for the irregular cornea patient.

Specialty contact lenses not only improve patient visual function, but by masking corneal irregularities, they also likely delay or prevent corneal transplantation surgeries for patients.<sup>18-20</sup> One of the newest studies compared the rates of keratoplasty in patients who wore either no lenses, soft lenses, corneal gas permeable lenses or scleral lenses for vision rehabilitation in keratoconus. This study concluded that GP corneal lens or scleral lens wear significantly lowered the risk of undergoing keratoplasty.<sup>20</sup>

In specialty lenses, specifically scleral lenses, innovations in lens Dk (oxygen permeability), solutions and coatings have improved patient comfort, wear time and negative visual symptoms. Increasing a lenses Dk in simple terms means increasing the oxygen transmissibility from the environment to the cornea. Studies have suggested increasing Dk to a value of 150 or higher, but physicians must balance higher Dk lenses with the potential for less wettability and increased lens debris deposition.<sup>21</sup>

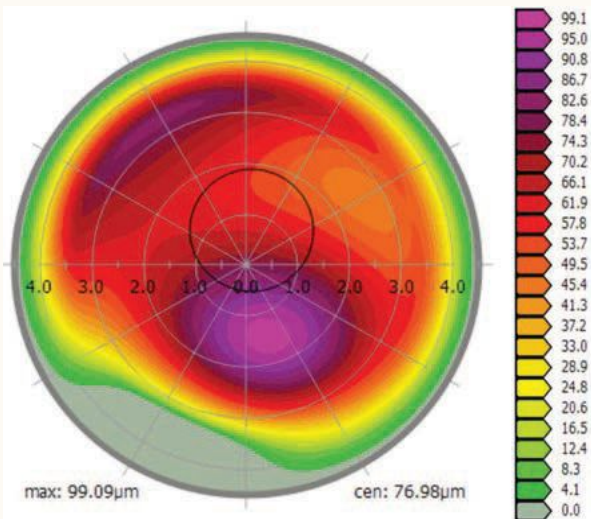

Hydra-PEG (Tangible Science) is a novel biocompatible polymer that creates a more consistent and durable lens coating. Hydra-PEG surface treatment has been shown to increase lens comfort, decrease lens deposits and decrease lens fogging.<sup>22</sup> A third

expanding area is scleral lens insertion solutions. Buffered vs. non-buffered products, single-use vials and the addition of electrolytes among others have all been additions to practitioner options.

A final addition in scleral lenses is impression-fit lenses. Analogous to a dentist using impression molds to make dental implants with a precision fit, these impression-based scleral lenses can be customized to a patient's cornea and sclera. Impression-based lenses can serve all types of patients, but commonly they are reserved for highly irregular corneas with more advanced pathology.<sup>23</sup>

In the surgical space for keratoconus vision rehab, there are both addition procedures and subtraction procedures. First, addition procedures revolve around using either biocompatible PMMA intrastromal ring segments (*Figure 7*) or allogenic ring segments inserted into the deep stroma.

Intrastromal ring segments aim to flatten and reshape the ectatic cornea while concurrently mechanically supporting the cornea. By mechanically centering the steep irregular cone, ICRS have the ability to decrease myopia and astigmatism, leading to better vision in glasses and disposable contact lenses. In our practice, our usage of Intacs most commonly is sequential to corneal crosslinking. When a patient's best-corrected glasses vision is less than 20/40, or a patient is unable or unwilling to wear specialty contact lenses, these are the most frequent



**Fig. 8. Topography-guided PRK ablation profile for a keratoconic patient 12 months post-CXL. Note the inferior increased amount of planned laser energy.**

scenarios in which our team deploys Intacs.

Finally, topography-guided PRK (TG-PRK) offers laser vision correction for keratoconus patients who have previously been told such procedures are contraindicated. Topography-guided treatments base the laser ablation profile on shape data from each patient’s specific corneal shape/topography. Topography-guided laser vision correction is FDA-approved for normal corneas, but some surgeons are using the technology off-label for highly irregular corneas. Two differentiators for TG-PRK treatments are, first, the Contoura (Alcon) placido disc topographer’s ability to measure highly aberrated corneas and plan a surgical treatment and, second, the platform’s ability to do more focal ablations. In keratoconus patients, this often means delivering more laser energy to the inferior steep cone and minimizing superior ablation energy, resulting in a regularization of the anterior corneal shape (Figure 8).

A key in setting expectations for TG-PRK in keratoconus patients is to change the definition of “success” from total glasses and contact lens independence to alleviating the dependence on specialty lenses, therefore gaining good visual quality in glasses and contact lenses.

Optometry’s role in the management of keratoconus is preserving patients’ visual potential and rehabilitating visual acuity to maintain a higher quality of life. Innovations in treatment allow practitioners to deviate from “monitoring the bend until it breaks,” to a more interventional mindset.

Researchers studied quality of life in keratoconus patients and, not surprisingly, BCVA in the better-seeing eye was the number one factor in quality of life.<sup>24</sup> Early diagnosis and earlier inter-

vention align beautifully with the goal of saving BCVA. CXL also contributes to higher quality of life scores in both early and late stages of keratoconus.<sup>24</sup>

Adopting a management approach where early diagnosis leads to intervention with CXL allows the practitioner to follow-up with a number of options for vision rehabilitation. This shifts patients away from a cycle of “watch and wait” and toward the new paradigm of “intervene and treat”—a more proactive approach that any eye care practitioner can support. ■

1. Al-Mahrouqi H, Oraba S, Al-Habsi S, et al. Retinoscopy as a screening tool for keratoconus. *Cornea*. 2019;38(4):442-5.
2. Greenwald MF, Scruggs BA, Vislisis JM, et al. Corneal imaging: an introduction. *EyeRounds.org*. Posted October 19, 2016; Available from: <http://EyeRounds.org/tutorials/corneal-imaging/index.htm>.
3. Belin MW, Villavicencio OF, Ambrósio RR. (2014). Tomographic parameters for the detection of keratoconus: suggestions for screening and treatment parameters. *Eye Contact Lens*. 2014;40(6):326-30.
4. Pircher N, Schwarzhans F, Holzer S, et al. Distinguishing keratoconic eyes and healthy eyes using ultrahigh-resolution optical coherence tomography-based corneal epithelium thickness mapping. *Am J Ophthalmol*. 2018;189:47-54.
5. Wheeler J, Hauser MA, Afshari NA, et al. The genetics of keratoconus: a review. *Reprod Syst Sex Disord*. 2012;(Suppl 6):001.
6. Lapeyre G, Fournie P, Vernet R, et al. Keratoconus prevalence in families: a french study. *Cornea*. 2020;39(12):1473-9.
7. Trattler W, Kramer E. (2020, October). Identifying, treating, and monitoring the progression of keratoconus. *Cataract and Refractive Surgery Today*. 2020;20(10):35-6.
8. Ferdi A, Nguyen V, Gore D, et al. Keratoconus natural progression: a systematic review and meta-analysis of 11,529 Eyes. *Ophthalmol*. 2019;126(7):935-45.


9. Hersh PS, Stulting RD, Muller D, et al. United States multicenter clinical trial of corneal collagen crosslinking for keratoconus treatment. *Ophthalmol*. 2017;124(9):1259-70.
10. Bradford SM, Mikula ER, Juhasz T, et al. Collagen fiber crimping following in vivo UVA-induced corneal crosslinking. *Exp Eye Res*. 2018;177:173-80.
11. Wollensak G, Iomdina E. Long-term biomechanical properties of rabbit cornea after photodynamic collagen crosslinking. *Acta Ophthalmologica*. 2009;87(1):48-51.
12. Belin M, Lim L, Rajpal R, Hafezi F, et al. Corneal Cross-Linking: current USA status: report from the cornea society. *Cornea*. 2018;37(10):1218-25.
13. Living with Keratoconus. [www.livingwithkc.com](http://www.livingwithkc.com).
14. Vinciguerra R, Pagano L, Borgia A, et al. Corneal cross-linking for progressive keratoconus: up to 13 years of follow-up. *J Refract Surg*. 2020;36(12), 838-43.
15. O’Brart D, Patel P, Lascaratos G, et al. Corneal cross-linking to halt the progression of keratoconus and corneal ectasia: seven-year follow-up. *Am J Ophthalmol*. 2015;160(6):1154-63.
16. Hill J, Liu C, Deardorff P, et al. Optimization of oxygen dynamics, UV-A delivery, and drug formulation for accelerated epi-on corneal crosslinking. *Curr Eye Res*. 2020;45(4):450-8.
17. Greenstein SA, Fry KL, Bhatt J. Natural history of corneal haze after collagen crosslinking for keratoconus and corneal ectasia. *J Cataract Refract Surg*. 2010;36(12):2105-14.
18. DeLoss KS, Fatteh NH, Hood CT. Prosthetic Replacement of the Ocular Surface Ecosystem (PROSE) scleral device compared to keratoplasty for the treatment of corneal ectasia. *Am J Ophthalmol*. 2014;158(5):974-82.
19. Koppen C, Kreps EO, Anthonissen L, et al Scleral Lenses Reduce the Need for Corneal Transplants in Severe Keratoconus. *Am J Ophthalmol*. 2018;185:43-47.
20. Ling J, Mian S, Stein J, et al. Impact of scleral contact lens use on the rate of corneal transplantation for keratoconus. *Cornea*. 2021;40(1):39-42.
21. Michaud L, van der Worp E, Brazeau D, et al. Predicting estimates of oxygen transmissibility for scleral lenses. *Cont Lens Anterior Eye*. 2012;5(6):266-71.
22. Mickles CV, Harthan JS, Barnett M. Assessment of a novel lens surface treatment for scleral lens wearers with dry eye. *Eye Contact Lens*. 2020; doi: 10.1097/ICL.0000000000000754.
23. Nau A, Shorter ES, Harthan JS, et al. Multicenter review of impression-based scleral devices. *Cont Lens Anterior Eye*. 2020;S1367-0484(20)30193-4.
24. Panthier C, Moran S, Bourges JL. Evaluation of vision-related quality of life in keratoconus patient, and associated impact of keratoconus severity indicators. *Graefes Arch Clin Exp Ophth*. 2020;258(7):1459-68.
25. Kennedy RH, Bourne WM, Dyer JA. A 48-year clinical and epidemiologic study of keratoconus. *Am J Ophthalmol*. 1986;101(3):267-73.
26. Hashemi H, Heydarian S, Hooshmand E, et al. The prevalence and risk factors for keratoconus: a systematic review and meta-analysis. *Cornea*. 2020;39(2):263-70.
27. Chan E, Chong EW, Lingham G, et al. Prevalence of keratoconus based on Scheimpflug imaging: The Rainie Study. *Ophthalmology*. 2020; S0161-6420(20)30838-1.
28. Nowak, D. M., & Gajecka, M. (2011). The genetics of keratoconus. *Middle East Afr J Ophthalmol*. 2011;18(1):2-6.
29. Wagner H, Barr J, Zadnik K. Collaborative longitudinal evaluation of keratoconus (CLEK) study: methods and findings to date. *Cont Lens Anterior Eye*. 2007;30(4):223-32.
30. Alio J, Vega-Estrada A, Sanz P, et al. Corneal morphologic characteristics in patients with down syndrome. *JAMA Ophthalmol*. 2018;136(9):971-8.



## OPTOMETRIC STUDY CENTER QUIZ

To obtain continuing education credit through the Optometric Study Center, complete the test form on the following page and return it with the \$35 fee to: Jobson Healthcare Information, LLC, Attn.: CE Processing, 395 Hudson Street, 3rd Floor New York, New York 10014. To be eligible, please return the card within three years of publication. You can also access the test form and submit your answers and payment via credit card online at [revieweducationgroup.com](http://revieweducationgroup.com). You must achieve a score of 70 or higher to receive credit. Allow four weeks for processing. For each Optometric Study Center course you pass, you earn 2 hours of credit from Pennsylvania College of Optometry. Please check with your state licensing board to see if this approval counts toward your CE requirement for relicensure.

- The prevalence of keratoconus is on the rise due to increased detection. A recent Australian study showed the highest rate at approximately what level?**
  - 1 in 1,000.
  - >1 in 100.
  - 1 in 500.
  - <1 in 1,000.
- Which of the following systemic diseases is associated with an increased risk of keratoconus?**
  - Parkinson's disease.
  - Lyme disease.
  - Ehlers-Danlos syndrome.
  - Legionnaires' disease.
- Which of the following conditions can lead to increased eye rubbing?**
  - Eye strain.
  - Allergic conjunctivitis.
  - Atopic dermatitis.
  - All of the above.
- When counseling patients on the effects of corneal crosslinking, the portrayed goal should be?**
  - To help patients immediately see better after CXL.
  - To halt corneal progression, flatten the keratometry values and improve contact lens fits.
  - To halt keratometric progression.
  - To set patients up for the ability to have topography-guided laser vision correction.
- When comparing normal eyes to early keratoconic eyes, the epithelial OCT maps of keratoconus patients show which change?**
  - Thinner minimum epithelial thickness.
  - Increased superior epithelial thickness.
  - Thinning in the midperipheral cornea.
  - No difference.
- Genetic testing for keratoconus traits can now examine approximately how many genes?**
  - 70.
  - 85.
  - 99.
  - 125.
- Which function do specialty contact lenses for keratoconus best serve?**
  - Altering corneal biomechanics.
  - Rehabilitating visual function.
  - Strengthening corneal lamellae.
  - Reducing eye rubbing.
- Which of the following is true regarding the FDA clinical trials for epithelium-off corneal crosslinking?**
  - The control group received riboflavin and epithelial debridement.
  - The treatment group was treated following the Dresden protocol.
  - The control group received riboflavin, but nothing else.
  - Answers B and C.
- What was the primary outcome in the FDA clinical trial for corneal crosslinking?**
  - Change in steep keratometry/Kmax at 12 months.
  - Improvement in best-corrected visual acuity.
  - Prevention of corneal transplantation.
  - Improvement in uncorrected visual acuity.
- What was the most common adverse event in the FDA clinical trial for corneal crosslinking?**
  - Infectious keratitis.
  - Corneal haze.
  - Permanent reduction in BCVA.
  - Corneal staining.
- For coding requirements, how long is the global period for epithelium-off corneal crosslinking procedures?**
  - 10 days.
  - 30 days.
  - 90 days.
  - There is no global period.
- After CXL, it is common for the topography/tomography to look \_\_\_\_\_ for the first few months, and the for the pachymetry to become \_\_\_\_\_.**
  - improved, thicker.
  - improved, thinner.
  - worse, thinner.
  - worse, thicker.
- In more advanced keratoconus, glasses are less effective for patients due to \_\_\_\_\_.**
  - High amounts of myopia.
  - Lower-order aberrations.
  - Higher-order aberrations.
  - Regular astigmatism.
- Increasing the Dk of a contact lens material serves what purpose?**
  - Increase the oxygen transmissibility.
  - Decrease the deposition formation.
  - Steepen the base curve.
  - Decrease the wear time.
- Which of the following specialty contact lens options represents the highest level of customization for a keratoconus patient?**
  - Corneal gas permeable lenses.
  - Scleral lenses.
  - Impression-molded lenses.
  - Specialty soft lenses.
- What is the goal of additive surgical procedures for keratoconus?**
  - Reshape the ectasia.
  - Stop progression of the ectasia.
  - Making specialty contact lens fits easier.
  - Give patients freedom from glasses and contacts.
- Intrastromal corneal ring segments are inserted into which corneal layer?**
  - Anterior stroma.
  - Bowman membrane (anterior limiting lamina).
  - Descemet's membrane.
  - Deep stroma.
- Topography-guided laser vision correction creates the ablation profile from which source?**
  - Corneal topography maps.
  - Higher-order aberration profiles.
  - Manifest refraction data.
  - The base curve of a corneal lens.
- In a recent study on keratoconus patient quality of life, which factor correlated most closely with improvement?**
  - Contact lens wear.
  - BCVA in the better-seeing eye.
  - Avoiding corneal transplantation.
  - Rubbing their eyes.
- An updated paradigm in the management of keratoconus consists of which of the following sequence of steps?**
  - Diagnosis, monitoring, optical rehabilitation, referral for corneal crosslinking.
  - Diagnosis, optical rehabilitation, monitoring.
  - Diagnosis, referral for crosslinking, optical rehabilitation, monitoring.
  - Diagnosis, referral for keratoplasty, optical rehabilitation.



### Examination Answer Sheet

*A New Consensus on Keratoconus*  
Valid for credit through April 15, 2024

**Online:** This exam can be taken online at [revieweducationgroup.com](http://revieweducationgroup.com). Upon passing the exam, you can view your results immediately and download a real-time CE certificate. You can also view your test history at any time from the website.

**Directions:** Select one answer for each question in the exam and completely darken the appropriate circle. A minimum score of 70% is required to earn credit.

**Mail to:** Jobson Healthcare Information, LLC, Attn.: CE Processing, 395 Hudson Street, 3rd Floor New York, New York 10014

**Payment:** Remit \$35 with this exam. Make check payable to Jobson Healthcare Information, LLC.

**Credit:** This course is COPE approved for 2 hours of CE credit. Course ID is 71974-AS.

**Processing:** There is a four-week processing time for this exam.

*Jointly provided by Postgraduate Institute for Medicine and Review Education Group. Salus University has sponsored the review and approval of this activity.*

**Answers to CE exam:**

- 1. (A) (B) (C) (D)
- 2. (A) (B) (C) (D)
- 3. (A) (B) (C) (D)
- 4. (A) (B) (C) (D)
- 5. (A) (B) (C) (D)
- 6. (A) (B) (C) (D)
- 7. (A) (B) (C) (D)
- 8. (A) (B) (C) (D)
- 9. (A) (B) (C) (D)
- 10. (A) (B) (C) (D)
- 11. (A) (B) (C) (D)
- 12. (A) (B) (C) (D)
- 13. (A) (B) (C) (D)
- 14. (A) (B) (C) (D)
- 15. (A) (B) (C) (D)
- 16. (A) (B) (C) (D)
- 17. (A) (B) (C) (D)
- 18. (A) (B) (C) (D)
- 19. (A) (B) (C) (D)
- 20. (A) (B) (C) (D)

**Post-activity evaluation questions:**

Rate how well the activity supported your achievement of these learning objectives. 1=Poor, 2=Fair, 3=Neutral, 4=Good, 5=Excellent

- 21. Review the impact of advancing diagnostics. (1) (2) (3) (4) (5)
- 22. Discuss the current standard of care for keratoconus. (1) (2) (3) (4) (5)
- 23. Recognize the role of corneal crosslinking. (1) (2) (3) (4) (5)
- 24. Determine when CXL is an appropriate treatment option. (1) (2) (3) (4) (5)
- 25. Based upon your participation in this activity, do you intend to change your practice behavior? (Choose only one of the following options.)
  - (A) I do plan to implement changes in my practice based on the information presented.
  - (B) My current practice has been reinforced by the information presented.
  - (C) I need more information before I will change my practice.
- 26. Thinking about how your participation in this activity will influence your patient care, how many of your patients are likely to benefit? (please use a number):
- 27. If you plan to change your practice behavior, what type of changes do you plan to implement? (Check all that apply.)
 

(A) Apply latest guidelines	(D) Change in current practice for referral	(G) More active monitoring and counseling
(B) Change in diagnostic methods	(E) Change in vision correction offerings	(H) Other, please specify: _____
(C) Choice of management approach	(F) Change in differential diagnosis	
- 28. How confident are you that you will be able to make your intended changes?
  - (A) Very confident
  - (B) Somewhat confident
  - (C) Unsure
  - (D) Not confident
- 29. Which of the following do you anticipate will be the primary barrier to implementing these changes?
- 30. Additional comments on this course: \_\_\_\_\_
 

(A) Formulary restrictions	(D) Insurance/financial issues	(G) Patient adherence/compliance
(B) Time constraints	(E) Lack of interprofessional team support	(H) Other, please specify: _____
(C) System constraints	(F) Treatment related adverse events	

**Please retain a copy for your records. Please print clearly.**

First Name

Last Name

E-Mail

The following is your:  Home Address  Business Address

Business Name

Address

City  State

ZIP

Telephone #  -  -

Fax #  -  -

OE Tracker Number

**Rate the quality of the material provided:**  
1=Strongly disagree, 2=Somewhat disagree, 3=Neutral, 4=Somewhat agree, 5=Strongly agree

31. The content was evidence-based.  
(1) (2) (3) (4) (5)

32. The content was balanced and free of bias.  
(1) (2) (3) (4) (5)

33. The presentation was clear and effective.  
(1) (2) (3) (4) (5)

By submitting this answer sheet, I certify that I have read the lesson in its entirety and completed the self-assessment exam personally based on the material presented. I have not obtained the answers to this exam by any fraudulent or improper means.

Signature \_\_\_\_\_ Date \_\_\_\_\_ Lesson 121098 RO-OSC-0421

## Optometry CE Study Center



The CE You  
Need in 2021

As low as  
**\$17.50**  
per Credit Hour

Buy just one 2-hour course for \$35 or buy as many as you need

Choose from over 50 individual CE courses

Includes the hard to find topics that fulfill your state requirements

All available in a convenient online format

Visit [www.ReviewEdu.com](http://www.ReviewEdu.com) for additional information and purchasing options.

The CE Study Center courses have been developed in conjunction with expert faculty from leading schools of optometry and are oriented toward clinical practice issues that are designed to assist eye care professionals in serving their patient's healthcare needs. CE Courses also appear in print monthly in *Review of Optometry*.

1-800-825-4696 • [INFO@REVIEWSCE.COM](mailto:INFO@REVIEWSCE.COM)

These COPE-Accredited CE courses are administered in partnership with an accredited school of optometry.







EDITED BY JOSEPH P. SHOVLIN, OD

# Operation Risk Reduction

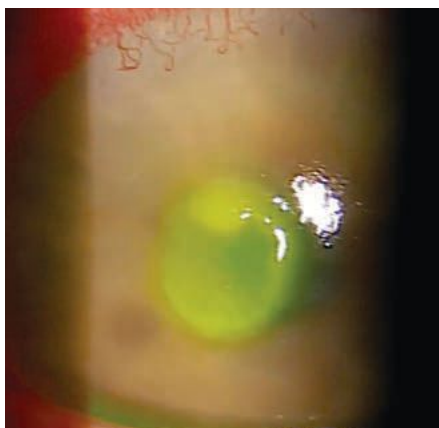
*It's up to us to help mitigate the factors that can contribute to corneal infection.*

**Q** Even though contact lens designs and materials have improved, the rate of corneal infection in wearers hasn't changed in over two decades. What are the most common causes of infection? How can we limit them? Are there any barriers?

**A** “The ocular surface is resilient to infectious events,” according to optometrists Mile Brujic and David Kading, who practice in Ohio and Washington, respectively. However, it is not immune to infection. Contact lens abuse can challenge the ocular surface and increase a patient's chance of developing microbial keratitis.

Interestingly, there is a difference in pathogens between corneal infections that are secondary to contact lens wear vs. those that are not. A recent study demonstrated that the causative pathogen in cultured contact lens-related ulcers was predominately *Pseudomonas* species (44%), followed by gram-positive (33%) organisms, fungi (13%), other gram-negative (6%) bacteria and *Acanthamoeba* (5%).<sup>1</sup> Cultured non-contact lens-related ulcers were primarily caused by gram-positive (64%) and gram-negative (26%) organisms, as well as fungi (11%).<sup>1</sup>

Among the many risk factors, overnight wear of contact lenses and failure to wash and dry hands prior to lens insertion are known to increase the chance of infection. Poor storage hygiene also increases the risk of infectious keratitis. The lens modality is another important factor and can influence corneal infection, with the lowest risk of severe disease occur-



**Central corneal ulcer secondary to contact lens abuse.**

ring in daily disposable and rigid gas permeable lens wearers.<sup>2</sup>

## Infection Origins

Understanding there are risk factors that are modifiable and conveying them to patients is critical to ensure contact lens success and avoid corneal infection, Drs. Brujic and Kading note. Continuous lens wear through the day and overnight creates the greatest risk of corneal infection. Educating patients on the destructive nature of this habit and helping them steer clear of it makes a world of difference in ocular health.

Upon determining an appropriate wear schedule, patients must learn how to properly wash and dry their hands prior to lens handling to avoid introducing any harmful substances into the ocular environment. For the same reason, appropriately cleaning and replacing the case and storing the lenses is equally as important. This

last risk factor can be mitigated by prescribing options that eliminate the need for storage cases, such as daily disposable lenses, as long as they are available in the patient's prescription and able to be prescribed. This modality also takes overnight wear out of the equation.

## Patient Hurdles

Of course, patient compliance presents a challenge—even when the stakes are as high as the potential for risk of corneal infection, Drs. Brujic and Kading say. While this is a factor we can't control once the lens is dispensed and the patient leaves our office, it is one we can attempt to influence. Although daily disposables reduce the risk of disease, some patients may not be able to pursue this modality due to financial restrictions or prescription unavailability. As a result, the lenses they are prescribed require the use of a case for storage and sanitation purposes.

While appropriate patient and lens hygiene may seem easy, this part of the process is often the most neglected by patients. Offer clear and concise education on the steps patients should take. If they fail to follow your advice, consequences will come into play.

## Clinical Takeaways

Corneal infection is destructive, but also avoidable in most cases of contact lens wear. Educating ourselves on how to appropriately manage any relevant risk factors and then passing on our knowledge to our patients is key. By doing our part, we've given our patients the tools they need to do it on their own. ■

1. Bennett L, Hsu HY, Tai S, et al. Contact lens versus non-contact lens-related corneal ulcers at an academic center. *Eye Contact Lens*. 2019;45(5):301-5.

2. Stapleton F. Contact lens-related corneal infection in Australia. *Clin Exp Optom*. 2020;103(4):408-17.

About  
Dr. Shovlin

**Dr. Shovlin**, a senior optometrist at Northeastern Eye Institute in Scranton, PA, is a fellow and past president of the American Academy of Optometry and a clinical editor of *Review of Optometry* and *Review of Cornea & Contact Lenses*. He consults for Kala, Aerie, AbbVie, Novartis, Hubble and Bausch + Lomb and is on the medical advisory panel for Lentechs.

 **MYOPIA**  
INNOVATION SHOWCASE

29  
APR

 **DIGITAL**  
INNOVATION SHOWCASE

20  
MAY

 **ISRAEL**  
INNOVATION SHOWCASE

10  
JUN

 **RETINA**  
INNOVATION SHOWCASE

1  
JUL

 **EUROPEAN**  
INNOVATION SHOWCASE

22  
JUL

 **DIAGNOSTICS**  
INNOVATION SHOWCASE

30  
SEPT

 **GLAUCOMA**  
INNOVATION SHOWCASE

21  
OCT

 **DRUG DELIVERY**  
INNOVATION SHOWCASE

11  
NOV

 **YEAR IN  
REVIEW**

2  
DEC



**2021  
SPONSORSHIP  
PROPOSAL**





# Spot the Subtleties

*Pay close attention to your results, as smaller changes could mean the difference between glaucoma progression and simple testing variability.*

**A** 76-year-old Caucasian female with moderately advanced open-angle glaucoma, OD>OS, was initially seen in 2007, at which point she was undiagnosed. At that visit, her optic nerve appearances warranted further evaluation, which confirmed she was a glaucoma suspect without frank structural and functional glaucomatous damage.

In 2012, I noted structural changes to both optic nerves, OD>OS, that showed circumpapillary retinal nerve fiber layer (RNFL) thinning OU and affected the neuroretinal rims.

After a trial period of glaucoma medications, we settled on a prostaglandin analog dosed at one drop OU HS. The patient remained on that regimen until 2017, at which time she was switched to Zioptan (tafluprost, Merck) OU HS for toxicity-related ocular surface issues.

The patient presented most recently in February 2021. She reported good compliance with the Zioptan and no resultant irritation. Her other medications included amlodipine, iberisartan, simvastatin and over-the-counter supplements. She is allergic to sulfa medications.

The patient's entering visual acuities were 20/25- OD and 20/30- OS. Her last refraction was approximately nine months earlier, which yielded similar acuities. Her pupils were equally round and reactive to light and accommodation, with no afferent pupillary defect. Her extraocular muscles were full OU.

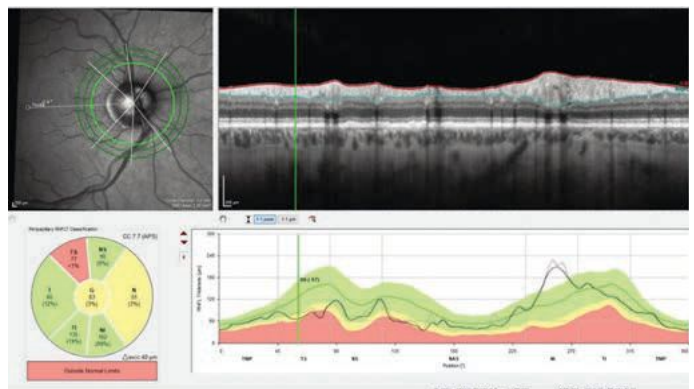
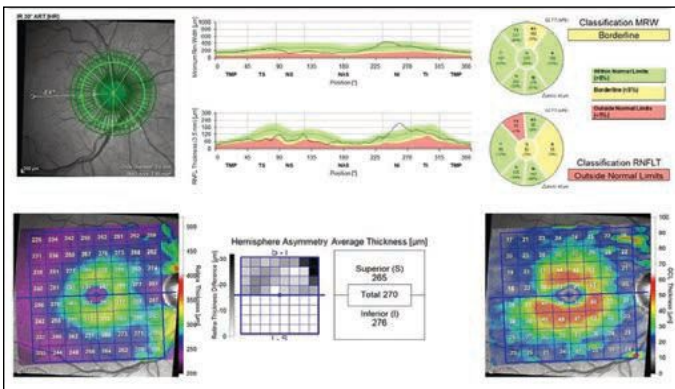
Slit lamp examination of the anterior segments was essentially normal. There were bilateral (mild) Salzmann's nodules off the visual axis OU. Her angles were open OU. Her crystalline lenses were characterized

by mild/moderate nuclear sclerosis and cortical spoking to a degree consistent with her visual acuities.

To obtain quality HRT-3 (Heidelberg) and OCT images, the patient was dilated in the usual fashion. Her cup-to-disc ratios were 0.75/0.80 OD and 0.65/0.70 OS. The nerve appearances were consistent with her previous visits over the past few years. The neuroretinal rim OD was thinnest in the superior temporal sector; whereas, the rim OS was thinnest in the inferior temporal sector.

Both macular evaluations were consistent with normal age-related changes centrally and characterized by mild retinal pigment epithelium granulation. There was a small epiretinal membrane along the superior arcade OS, not involving the foveal avascular zone. Her peripheral retinal evaluations at previous visits were normal.

The patient's average intraocular pressures on Zioptan were 15mm Hg OD and OS. Central corneal thicknesses were 553µm OD and 565µm OS. Applanation tensions were 13mm Hg OD and 15mm Hg OS at 10:30 in the morning.



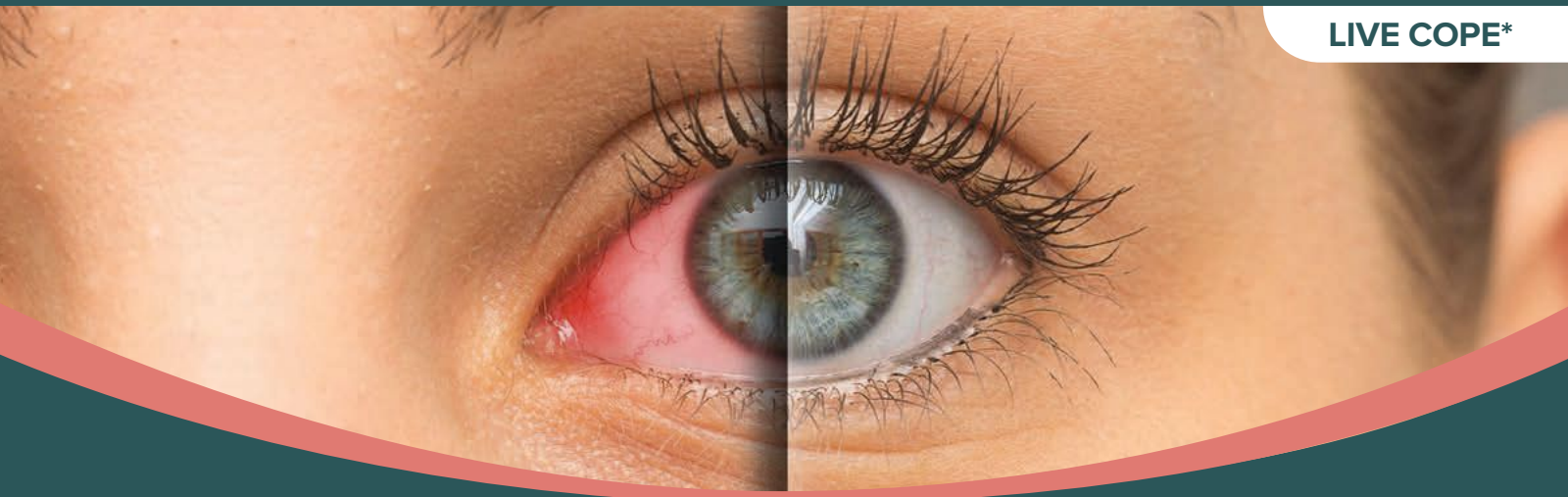
**Here's an overview of the three areas to observe when monitoring for disease progression: the neuroretinal rim, circumpapillary RNFL and macular region. Existing damage in this case can be readily seen in both the macular ganglion cell layer and the superior temporal RNFL.**

**The 3.5mm circumpapillary RNFL scan shows loss of tissue at the 10:30 position in the superior temporal sector compared with baseline, indicating progression. In this case, the damage (progression) first occurs and is more visible in the RNFL.**

**About Dr. Fanelli**

Dr. Fanelli is in private practice in North Carolina and is the founder and director of the Cape Fear Eye Institute in Wilmington, NC. He is chairman of the EyeSki Optometric Conference and the CE in Italy/Europe Conference. He is an adjunct faculty member of PCO, Western U and UAB School of Optometry. He is on advisory boards for Heidelberg Engineering and Glaukos.





# Dry Eye Colloquium

## Improving Diagnosis, Treatment, and Patient Outcomes

Step into the offices of Drs. Bloomenstein and Devries for comprehensive, virtual demonstrations of the latest in dry eye technology! Diagnosis and treatment devices will be reviewed with live patient demos. Effective patient management, indications for use, and much more will be discussed over the course of this 4 hour program with ample opportunity for Q&A.

**SUNDAY, APRIL 18, 2021**

**11:00 AM – 3:15 PM ET**

**(8:00 AM – 12:15 PM PT)**



**VIRTUAL EVENT**

### SPEAKERS



**Marc Bloomenstein, OD, FAAO**  
Director of Optometric Services  
Schwartz Laser Eye Center



**Douglas K. Devries, OD**  
Co-Founder  
Eye Care Associates of Nevada

\*Earn up to 4 LIVE COPE Credits for \$39.99

To register visit:

[www.ReviewEdu.com/DryEyeColloquium2021](http://www.ReviewEdu.com/DryEyeColloquium2021)

e-mail: [ReviewMeetings@MedscapeLIVE.com](mailto:ReviewMeetings@MedscapeLIVE.com)

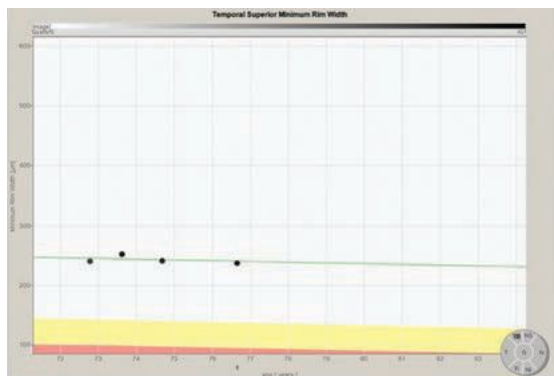


\*Approval pending

Review Education Group partners with Salus University for those ODs who are licensed in states that require university credit.

Partially supported by unrestricted educational grants from Alcon, Bausch & Lomb, Johnson & Johnson Vision, Kala Pharmaceuticals, and Sun Pharmaceuticals.





**Progression analysis of the superior temporal sector of the neuroretinal rim over four scans spanning four years. The progression follows the expected gradual decline over time as noted by the green line. This indicates a normal situation and not significant glaucoma progression.**

**Discussion**

Periodic follow-ups for glaucoma patients are necessary to identify a variety of problems, with the most important being progression. Stability, or lack thereof, is determined by different testing methodologies, primarily by evaluating structural and functional indices. As we see glaucoma patients over the course of several years, it becomes somewhat easier to determine stability, as we now have multiple points of comparison. Aberrations or declines in structural or functional stability become readily evident with the accumulation of data points. Also with time, the protocols we follow for glaucoma management become almost second nature in stable patients.

Therein lies a caution: just because a glaucoma patient has remained stable for many years doesn't mean they will always be stable. While gross changes or deterioration are easily detectable, subtle changes can be overlooked if we become complacent. On the other hand is the difficulty in determining progression vs. inter-testing variability. This is especially true in evaluating OCT findings that are measured in microns. While OCT technology has revolutionized glaucoma care, it can be challenging to detect early, subtle progression.

OCT instruments offer a plethora of information, much of which cannot

fit in a simple 8.5x11 inch printout. It is helpful for me to have access to all the information obtained when a patient is scanned. Namely, it allows me to evaluate all areas where there may be progression. I have access to a progression analysis tool for OCT scans that not only plots progression in the RNFL and the neuroretinal rim, but also in each sector of both areas.

It is incumbent on us to know the nuances and limits of our imaging technologies, both what they tell us and what they don't. Understanding each particular technology

will help you decipher results from instrument to instrument and from test to test.

In this particular patient, previous visual field studies remained stable, with bilateral arcuate defects and nasal step formation. Her most recent visit aimed to determine structural stability. Along these lines, we need to keep a couple of points in mind. First, we must identify exactly where the disease has manifested. In early conversion or early disease, the damage may be isolated to one of three areas: the macular ganglion cell layer, circum-papillary RNFL or neuroretinal rim; whereas in advanced disease, damage can be seen in all three locations. The inferior temporal and superior temporal sectors of the neuroretinal rim and RNFL are typically affected first.

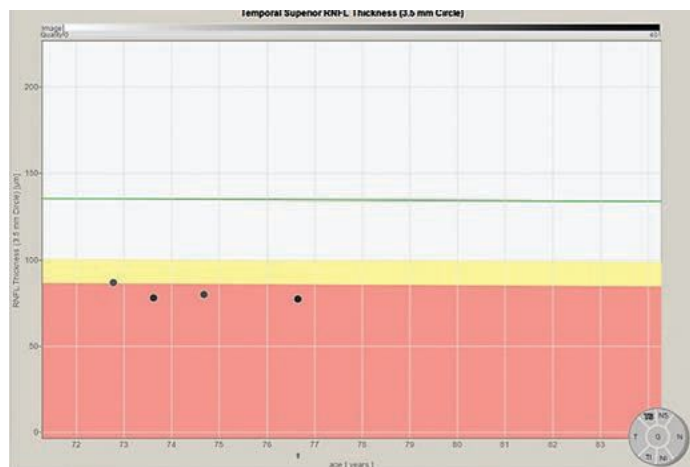
Next, we must remember how each patient first converted from a glaucoma suspect to a frank glaucoma patient. You may not know this information, especially if you

inherited a long-standing glaucoma patient from a different provider. But a good rule of thumb to keep in mind is that wherever or however the initial signs of damage manifested, progression is likely to be seen in the same location or manner.

Which brings us back to this particular case. This patient initially converted to glaucoma as evidenced by changes in her neuroretinal rim (as imaged by the HRT-3) and the peripapillary RNFL (as imaged by OCT). In her right eye, the initial changes were seen in the superior temporal sectors of each. I pay particularly close attention to the areas that were first compromised, despite the fact that progression can occur anywhere.

So, is the glaucoma worsening in this case? It certainly appears so. If we glossed over the case findings, the patient's subtle progression may have easily been missed. After all, what's 17µm? Well, it's 17µm that are no longer there. It's not going to get better, only worse.




Now we must decide what to do with this information. Is that enough of a change to warrant an adjustment in therapy? Or should we reassess again in a few months? That is where clinical decision-making comes into play. Our technology may help guide us, but the decision is ultimately up to you. Missing the details and doing nothing, however, is not an option. ■



**Progression analysis of the superior temporal sector of the RNFL using a 3.5mm scan, showing a subtle decline over a four-year period. This is suggestive of subtle progression.**

# Find the best talent for your practice

Accelerate your hiring process with Eyes On Eyecare's industry-leading solutions. We've helped hundreds of private practices and large organizations find qualified optometrists, techs, opticians, and ophthalmologists.

-  **Post a job on eyecare's #1 job board**
-  **Leverage our skilled recruiters**
-  **Build your brand with recruitment marketing**

## The largest eyecare partner network

We're pleased to partner with Jobson Optical Group to extend the reach of your job listings. Jobs are automatically shared across 12+ eyecare and hiring websites.







EDITED BY DEREK N. CUNNINGHAM, OD,  
AND WALTER O. WHITLEY, OD, MBA

## SURGICAL MINUTE

# Build Back Better

*When the corneal epithelium is compromised, sometimes the best approach is to let the eye start over with a clean slate.*

BY ETHAN ZIMMERMAN, OD  
AUSTIN, TX

**W**e try our best to protect the ocular surface from the onslaught of forces that can disrupt it, but sometimes the superficial cornea just isn't amenable to repair. If so, superficial keratectomy (SK) can greatly improve visual quality. This minimally invasive procedure removes the epithelium down to Bowman's membrane, then uses a corneal hoe or beaver blade to remove deposits, opacities or diseased tissue. A diamond burr polishes Bowman's, ensuring a smooth surface for new corneal epithelial cells to migrate over and proliferate.

The overall goal is to create a more regular corneal surface by allowing new epithelial growth to proceed uniformly.

Since many cases can be comanaged by optometrists, it's important for ODs to be knowledgeable about SK's indications and well-versed in the procedure to tackle any post-op complications. Diseases treated with SK include:

- Salzmann's nodular degeneration, in which superficial, elevated, blue-white lesions appear in Bowman's immediately behind the epithelial basement membrane. The pathogenesis is unclear, but these typically occur after chronic inflammation to the ocular surface, which can be brought on by longstanding dry eye disease.
- Anterior basement membrane dystrophy, an inherited disorder and the

most common corneal dystrophy, occurs when areas of the basement membrane thicken and protrude, causing raised areas and irregularities. It's typically diagnosed from significant negative fluorescein staining on the epithelium. Severe cases can induce irregular astigmatism, decreasing quality of vision.

- Recurrent erosion, which occurs from poor hemidesmosomal connection between epithelial cells and their basement membrane. This causes epithelium to slough off in specific areas, which can be quite painful when located close to corneal nerves.

- Pterygium, or abnormal scleral tissue growth that extends over the cornea. This is a protective response usually seen from increased UV light exposure. When significant, it can cause extensive irregular astigmatism.

- Band keratopathy, due to calcium salt deposits in Bowman's, is usually not visually significant but can be removed if cosmetically unappealing.

Since mild forms of these diseases are managed with various dry eye treatments and topical steroids, SK is typically reserved for more moderate-to-severe cases. However, it may be considered for milder ones that cause only minor irregularities if there is a need for detailed refractive measurements (*e.g.*, prior to cataract extraction surgery).

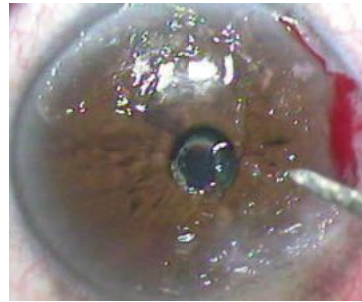

Photo: Dell Laser Consultants

**Superficial keratectomy involves the manual removal of superficial corneal scar tissue.**

## Postoperative Care

Immediately following the procedure, a bandage contact lens is placed on the eye, sometimes with an amniotic membrane under the lens to aid re-epithelialization. The patient is often prescribed a topical antibiotic, steroid and artificial tear. Discomfort the night after the procedure, as well as the next day, is common. If needed, an oral pain medication can also be prescribed. Vision is also expected the first week as the cornea re-epithelializes and slowly improves over the next few weeks.

Follow-up schedule includes a one-day post-op visit to evaluate comfort, look for signs of inflammation and confirm the bandage lens has remained centered. Next, the patient usually returns one week later to ensure the cornea has re-epithelialized. If so, the lens is removed and the antibiotic is discontinued. Lastly, the patient returns for a one-month post-op visit to ensure vision has improved and stabilized.

Keep in mind that a patient may need to undergo multiple SKs in their lifetime due to the recurrent nature of things like Salzmann's nodules. The conditions listed can worsen with chronic dry eye, which is more prevalent with age. This procedure is not meant to be a "cure," but rather a long-term maintenance of the patient's condition. It's important to articulate this to your patients to ensure realistic expectations. ■

## ABOUT THE AUTHOR



Dr. Zimmerman is an ocular disease resident at Dell Laser Consultants in Austin, TX. He has no financial disclosures.

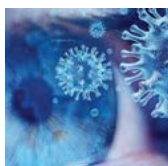For a video of the procedure, read this article online at [www.reviewofoptometry.com](http://www.reviewofoptometry.com).

**About Drs. Cunningham and Whitley**

**Dr. Cunningham** is the director of optometry at Dell Laser Consultants in Austin, TX. He has no financial interests to disclose. **Dr. Whitley** is the director of professional relations and residency program supervisor at Virginia Eye Consultants in Norfolk, VA. He is a consultant for Alcon.

Register for an upcoming CE conference  
from Review Education Group!

 VIRTUAL EVENTS

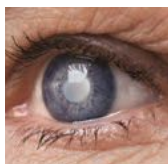


**COVID Combat Conference**

**APRIL 24, 2021**

EARN UP TO 8\* LIVE COPE CREDITS

Register: [www.ReviewEdu.com/CovidCombat](http://www.ReviewEdu.com/CovidCombat)

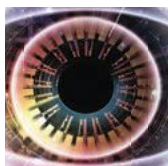

**Optometric Glaucoma Symposium**

**SPRING | MAY 7-8, 2021**

EARN UP TO 12\* LIVE COPE CREDITS

Register: [www.ReviewEdu.com/OGS2021](http://www.ReviewEdu.com/OGS2021)

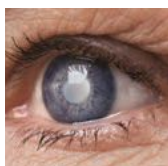

**New Technologies & Treatments in Eye Care**

**SUMMER | JUNE 11-12, 2021**

EARN UP TO 12\* LIVE COPE CREDITS

Register: [www.ReviewEdu.com/NTT2021](http://www.ReviewEdu.com/NTT2021)



**Optometric Glaucoma Symposium**

**WINTER | DECEMBER 10-11, 2021**

EARN UP TO 12\* LIVE COPE CREDITS

Register: [www.ReviewEdu.com/OGS2021](http://www.ReviewEdu.com/OGS2021)

For additional information visit

[www.ReviewEdu.com/Events](http://www.ReviewEdu.com/Events)

e-mail: [ReviewMeetings@MedscapeLIVE.com](mailto:ReviewMeetings@MedscapeLIVE.com)



\*Approval pending



Review Education Group partners with Salus University for those ODs who are licensed in states that require university credit.





BY JOSEPH W. SOWKA, OD

## THERAPEUTIC REVIEW

# Scratching the Surface

*Doing a thorough job with corneal abrasions helps greatly.*

A recent stint on call for emergencies brought home the importance of properly handling a common condition. The first patient was a 34-year-old man who had been playing with his daughter and cat. His daughter spooked the cat, which then accidentally scratched the man's left eye. The second was a 47-year-old woman who had a mishap involving a child's fingernail scratch to her left eye.

They presented within an hour of each other. Both had the classic appearance of a person with a corneal abrasion: they were driven in by a family member, held a washcloth across the injured eye and were in such discomfort with tearing and photophobia that they had difficulty engaging throughout the exam. The main difference I found was that the man had been injured an hour earlier, while the woman had been the previous day.

She sought care at a local emergency room, where she got temporary relief with anesthetic. The remainder of the exam involved the physician using fluorescein dye and a cobalt blue filter to correctly diagnose a corneal abrasion, after which she was prescribed a topical antibiotic and discharged. However, the antibiotic did little to relieve her discomfort once the anesthetic wore off; hence, her presentation to seek treatment and relief after not being able to sleep the night before. Adding insult to injury (literally), she incurred a very substantial bill for her ER visit.

Corneal abrasions are one of the most common ocular emergencies, encountered and treated by optom-



**This man had received a corneal abrasion as a result of being scratched by his cat.**

etrists, ophthalmologists, ER physicians, physician assistants and nurse practitioners.<sup>1,2</sup> However, it is the eye care professional who is poised to offer the best therapy.

## Breaking the Cornea Down

Patients typically present, to varying degrees, with acute pain, photophobia, pain upon blinking and eye movement, lacrimation, foreign body sensation and blurry vision following direct ocular trauma. Biomicroscopy of the injured eye often reveals diffuse corneal edema and epithelial disruption.

In severe cases, folds in Descemet's membrane may be visible. Cobalt blue light following instillation of sodium fluorescein dye will illuminate the damaged, denuded epithelium with bright green dye accumulation within the abrasion.<sup>3</sup> The initial trauma potentially creates a mild anterior chamber reaction (iritis or iridocyclitis).<sup>3</sup>

The corneal epithelium is comprised of the stratified surface epithelium (whose microvilli increase surface area and permit adherence of the tear film by interacting with its mucus layer), the wing cell layer (containing the corneal nerves) and the mitotically active basement membrane.

Bowman's membrane prevents penetrating injuries.<sup>4</sup> Superficial abrasions do not involve Bowman's, while deep abrasions penetrate this structure but do not rupture Descemet's membrane. Abrasions result from numerous causes, including foreign bodies, chemicals, fingernails, hairbrushes and tree branches, to name a few.

The cornea has remarkable healing properties.<sup>5</sup> The healthy epithelium adjacent to the abrasion expands and fills in the defect, typically within 24 to 48 hours.<sup>6</sup> Lesions that are purely epithelial in nature often heal quickly and completely, without intervention or subsequent scarring. Lesions that extend below Bowman's membrane leave scars. Stromal opacification after corneal trauma is often due to myofibroblasts and chemokines forming a disorganized extracellular matrix that these cells and their chemokines produce.<sup>7</sup>

## Treatment

Management begins with visual acuity and then proceeds from adnexal to fundus examination, if necessary. If blepharospasm precludes an acuity measurement, administer one drop of topical anesthetic and measure the acuity immediately thereafter (pinhole, if necessary). Depending on the nature of the injury, evert the eyelids and examine and flush the fornices to rule out foreign material. Instill fluorescein dye (without anesthetic) to identify the extent of the corneal defects.

Consider a Seidel test (painting of the wound with fluorescein dye

About  
Dr. Sowka

Dr. Sowka is an attending optometric physician at Center for Sight in Sarasota, FL, where he focuses on glaucoma management and neuro-ophthalmic disease. He is a consultant and advisory board member for Carl Zeiss Meditec and Bausch Health.





SAVE THE DATE:  
REGISTRATION OPENS JUNE 1ST



*See you there!*

Visit [AcademyMeeting.org](https://AcademyMeeting.org) for more information.



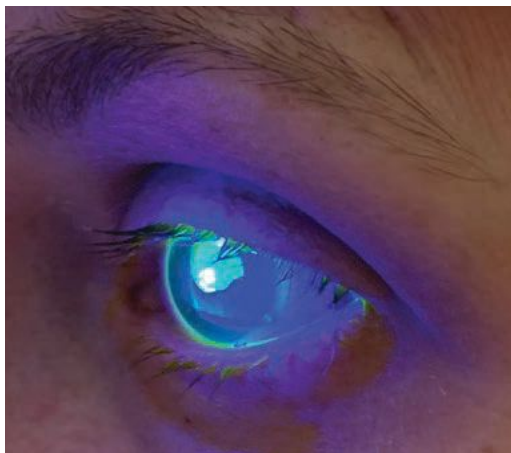to observe for aqueous leakage) if the injury was high speed with any possibility of full-thickness damage. Clean the abrasion and scrutinize it for foreign matter.

If there are loose or ragged edges of epithelium, these devitalized tissues will impede wound healing and should be removed with a cotton-tipped applicator or forceps following instillation of topical anesthesia. Observe the anterior chamber for any evidence of inflammation. A dilated examination may be completed to rule out any posterior effects from the trauma, if indicated.

Prescribe topical antibiotics to prevent infection in cases of corneal abrasion. An inexpensive topical fluoroquinolone or equivalent may be prescribed QID until the cornea has healed. Keep in mind that antibiotics in abrasions is merely prophylactic and will do little to provide healing or comfort. Unfortunately, this is where most non-eye care practitioners end management—with correct diagnosis and prophylaxis but falling short of thorough management. Use topical cycloplegia to put the uvea at rest. This will greatly ameliorate a patient's pain and photophobia.

Unfortunately, the number of available cycloplegics has been greatly reduced over the years. One drop of 1% atropine or three to five drops of 1% Cyclogyl (cyclopentolate-hydrochloride ophthalmic solution, Alcon) in-office is usually sufficient and typically does not need to be prescribed. For patients who are in a great deal of pain, a topical non-steroidal anti-inflammatory drug (NSAID) can be given for acute corneal pain.<sup>8</sup> Generic ketorolac or diclofenac can be prescribed BID to QID for a short period of time. Avoid topical anesthetics for these patients due to the potential for misuse, with subsequent neurotrophism. Cold compresses, artificial tears and over-the-counter analgesics such as ibuprofen and acetaminophen can be used to relieve acute pain.

Pressure patching, while no longer commonly used, is still useful for larger abrasions.<sup>9</sup> Patching has been commonly replaced by the use of



**This woman received her corneal abrasion as a result of being scratched by her child's fingernail.**

bandage contact lenses, and these have been shown to greatly increase patient comfort, especially when employed with the previously mentioned pharmaceuticals. In cases of corneal abrasion occupying more than 15% of the corneal area, prescribe a thin, low water content, low-powered, high oxygen, extended-wear soft bandage contact lens.<sup>10</sup> In cases where there is significant anterior chamber inflammation, a topical steroid or steroid-antibiotic combination agent can be employed; however, the risks of secondary superinfection must be weighed against the benefits.

Topical steroids increase the efficiency of corneal wound healing by suppressing inflammatory enzymes.<sup>11</sup> Such use of steroids merits close follow-up. Reevaluate patients every 24 to 48 hours until the abrasion has significantly re-epithelialized. If a bandage lens is employed, the doctor should remove it at the first follow-up using topical anesthesia and thorough irrigation to float the lens off, to not disturb the healing epithelium. It is often prudent to do this at the biomicroscope with forceps rather than digitally to not damage the cornea further. If necessary, a new bandage contact lens can be reapplied if the abrasion is not adequately filled in at the first follow-up.

### To Sum Up

Both patients presented here had a similar appearance with corneal

abrasions and no evidence of infection.

Following examination, they were cyclopleged in-office with 1% Cyclogel and prescribed a generic fluoroquinolone antibiotic QID. A low-powered, soft extended wear soft contact lens was inserted for each patient, and both were reappointed to be seen by the next day. Since the woman had been injured for a longer period and had more discomfort and inflammation, a topical NSAID was added to her regimen QID as well. Upon presentation the following day, both patients felt much better, their bandage lenses were removed and each had nearly 95% resolution of their abrasions.

The woman did inquire about the reasons the emergency room personnel didn't do as much to make her feel better. It was explained that there are procedures best left to eye care professionals and that, while her treatment was not incorrect and she didn't get a corneal infection, it didn't adequately address her pain and discomfort. ■

1. Kumar NL, Black D, McClellan K. Daytime presentations to a metropolitan ophthalmic emergency department. *Clin Exp Ophthalmol.* 2005;33(6):586-92.
2. Wipperman JL, Dorsch JN. Evaluation and management of corneal abrasions. *Am Fam Physician.* 2013;87(2):114-20.
3. Wilson SA, Last A. Management of corneal abrasions. *Am Fam Physician.* 2004;70(1):123-8.
4. Dua HS, Faraj LA, Said DG, et al. Human corneal anatomy redefined: a novel pre-Descemet's layer (Dua's layer). *Ophthalmology.* 2013;120(9):1778-85.
5. Griffith GL, Kasus-Jacobi A, Lerner MR, et al. Corneal wound healing, a newly identified function of CAP37, is mediated by protein kinase C delta (PKCδ). *Invest Ophthalmol Vis Sci.* 2014;55(8):4886-95.
6. Griffith GL, Russell RA, Kasus-Jacobi A, et al. CAP37 activation of PKC promotes human corneal epithelial cell chemotaxis. *Invest Ophthalmol Vis Sci.* 2013;54(10):6712-23.
7. Torricelli AA, Wilson SE. Cellular and extracellular matrix modulation of corneal stromal opacity. *Exp Eye Res.* 2014;129:151-60.
8. Thiel B, Sarau A, Ng D. Efficacy of topical analgesics in pain control for corneal abrasions: a systematic review. *Cureus.* 2017;9(3):e1121.
9. Menghini M, Knecht PB, Kaufmann C, et al. Treatment of traumatic corneal abrasions: a three-arm, prospective, randomized study. *Ophthalmic Res.* 2013;50(1):13-8.
10. Gilad E, Bahar I, Rotberg B, et al. Therapeutic contact lens as the primary treatment for traumatic corneal erosions. *Isr Med Assoc J.* 2004;6(1):28-9.
11. Wang L, Tsang H, Coroneo M. Treatment of recurrent corneal erosion syndrome using the combination of oral doxycycline and topical corticosteroid. *Clin Experiment Ophthalmol.* 2008;36(1):8-12.

# COVID Combat Conference

SATURDAY, APRIL 24, 2021

 VIRTUAL EVENT

An interactive, one-day, multi-course CE meeting focused on infection control, prescribing and screening modifications, patient and staff safety, and effectively restarting and growing your practice in a peri- and post-COVID world.

## PROGRAM CHAIR



**Paul M. Karpecki, OD, FAAO**  
Kentucky Eye Institute  
Lexington, KY

Earn up to 8 LIVE COPE Credits\*

To register visit:

[www.ReviewEdu.com/COVIDCombat](http://www.ReviewEdu.com/COVIDCombat)

e-mail: [ReviewMeetings@MedscapeLIVE.com](mailto:ReviewMeetings@MedscapeLIVE.com)



\*Approval pending

Review Education Group partners with Salus University for those ODs who are licensed in states that require university credit.







BY PAUL M. KARPECKI, OD  
CHIEF CLINICAL EDITOR

## OCULAR SURFACE REVIEW

# End of the Line for EBMD

*More than just an annoyance, this condition can alter refractive status in ways that complicate outcomes for surgical patients.*

**E**pithelial basement membrane dystrophy (EBMD) is the most common of the anterior corneal dystrophies and one of the most likely etiologies of recurrent corneal erosion syndrome (RCE).<sup>1,2</sup> More than 2% of the population is affected.<sup>3</sup>

The condition typically develops between ages 20 and 50.<sup>1</sup> Although considered an age-dependent corneal degeneration, it also seems to have an autosomal dominant method of inheritance.<sup>1,4,5</sup> EBMD stems from an inherent dysfunction in basal epithelial cells that results in secretion of abnormal basement membrane extending into the epithelium, as well as accumulation of fibrillogranular material between Bowman's and the basement membrane and also within the epithelium.<sup>3</sup>

Over the years our understanding of EBMD has matured, as has our ability to diagnose and manage it. Here, we review causes, symptoms and treatments.

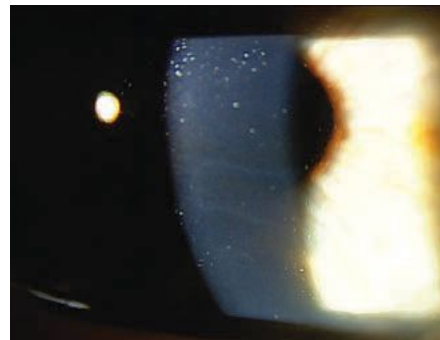
## Diagnosing EBMD

EBMD is characterized by an abnormal basement membrane that protrudes into the epithelium and the presence of intraepithelial microcysts.<sup>1</sup>

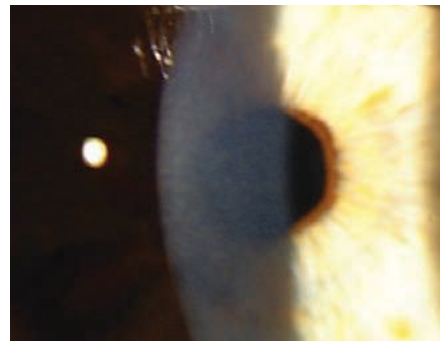
Diagnosis begins with a careful history and review of symptoms. EBMD is usually asymptomatic, but patients may present with dryness, fluctuating vision, grittiness or photophobia.<sup>1</sup> In fact, EBMD patients are often misdiagnosed with dry eye.<sup>6</sup>

Approximately 10% of patients develop painful, recurrent epithelial erosions.<sup>1,3</sup> On slit lamp exam, EBMD

is characterized by bilateral (and frequently asymmetric) subepithelial fingerprint lines, geographic map-like lines and epithelial microcysts.<sup>1</sup>



**An EBMD patient before (top) and after (bottom) epithelial debridement and amniotic membrane application.**



An obvious feature is the presence of a thickened basement membrane, easily detectable on OCT.<sup>1</sup> This thickening can be either localized or diffuse; when substantial, it can account for the corneal surface irregularity, blurred vision and pain that sometimes can accompany EBMD.<sup>1</sup> Corneal epithelial cystic lesions appear as hyperreflective dots on OCT and range in size from 20µm to 1000µm.<sup>1</sup>

## EBMD in Cataract Patients

Intervention is important in all EBMD patients, but it's of particular concern in cataract surgery candidates since accurate keratometry and biometry depend on a clear cornea and smooth surface.<sup>7</sup> Any corneal lesion, including EBMD, can have an adverse effect on the reliability of such measurements.<sup>7</sup> This, in turn, can impact IOL selection and postoperative visual outcomes.<sup>7</sup>

In a small retrospective review of EBMD, cataract patients were pre-emptively treated with superficial keratectomy or phototherapeutic keratectomy (PTK) to evaluate the impact of treatment on biometry, IOL power prediction and suggested IOL toricity.<sup>7</sup> Researchers found that spherical IOL power decreased for 18 eyes and increased for three.<sup>7</sup> The decrease in power was more than 1.0D for four eyes, 1.0D for seven eyes and 0.5D for seven eyes.<sup>7</sup> There were two instances of power increase by 0.5D and one by 3.0D.<sup>7</sup> Approximately 67% of patients eligible for toric IOLs had adjustments to the recommended IOL cylinder power after intervention, with a mean change of 1.2D.<sup>7</sup>

These findings speak to how essential corneal surface optimization is and the difference it can make. For every degree of misaligned toric power, there is a 3.3% loss of correcting effect of the cylindrical power.<sup>8</sup> Considering that this study found a mean absolute change of more than 39 degrees of the axis of astigmatism, toric IOL alignment inaccuracies could be quite significant.<sup>7</sup>

## Treating EBMD

First-line therapies for mild asymptomatic cases include artificial tears, ointments, punctal plugs and bandage contact lenses.<sup>3,9</sup> More advanced options such as autologous serum eye

About  
Dr. Karpecki

**Dr. Karpecki** is medical director for Keplr Vision and the Dry Eye Institutes of Kentucky and Indiana. He is the Chief Clinical Editor for *Review of Optometry* and chair of the New Technologies & Treatments conferences. A fixture in optometric clinical education, he consults for a wide array of ophthalmic clients, including ones discussed in this article. Dr. Karpecki's full disclosure list can be found in the online version of this article at [www.reviewofoptometry.com](http://www.reviewofoptometry.com).

drops, corticosteroids and cryopreserved amniotic membrane also may be used.<sup>9</sup> Medically refractory cases are recommended for surgical treatments, including epithelial debridement before applying amniotic membrane.<sup>3</sup> Both debridement with diamond-dusted burr polishing and PTK ablation to the level of Bowman's have proven effective.<sup>3,10-14</sup>

We have long been aware of the risks EBMD can pose in LASIK patients: severe corneal epithelial sloughing, epithelial ingrowth (73%), diffuse lamellar keratitis (55%), flap micro-folds (18%) and flap melting (36%).<sup>15,16</sup> Knowing this, take great care to detect subclinical EBMD prior to elective refractive procedures. Although we also endeavor to diagnose all forms of RCE prior to cataract surgery, sometimes the necessity of the procedure will lower our treatment threshold. But as co-managing optometrists, we must be on

the lookout for EBMD in all anterior segment surgical patients. By treating them to the best of our ability prior to referral, we help overcome significant risks, and at the very least, we reduce the likelihood that eager surgical candidates will experience disappointment when their procedure is delayed. ■

1. El Sanharawi M, Sandali O, Basli E, et al. Fourier-domain optical coherence tomography imaging in corneal epithelial basement membrane dystrophy: a structural analysis. *Am J Ophthalmol.* 2015;159(4):755-763.
2. Lin SR, Aldave AJ, Chodosh J. Recurrent corneal erosion syndrome. *Br J Ophthalmol.* 2019;103(9):1204-1208.
3. Lee WS, Lam CK, Manche EE. Phototherapeutic keratectomy for epithelial basement membrane dystrophy. *Clin Ophthalmol.* 2016;11:15-22.
4. Werblin TP, Hirst LW, Stark WJ, Maumenee IH. Prevalence of map-dot-fingerprint changes in the cornea. *Br J Ophthalmol.* 1981;65(6):401-409.
5. S. Boutboul, G.C. Black, J.E. Moore, et al. A subset of patients with epithelial basement membrane corneal dystrophy have mutations in TGFBI/BIGH3. *Hum Mutat.* 2006;27(6):553-557.
6. Wolffsohn JS, Arita R, Chalmers R, et al. TFOS DEWS II Diagnostic Methodology report. *Ocul Surf.* 2017;15(3):539-574.
7. Goerlitz-Jessen MF, Gupta PK, Kim T. Impact of epithelial basement membrane dystrophy and Salzmann nodular

degeneration on biometry measurements. *J Cataract Refract Surg.* 2019;45(8):1119-1123.

8. Bauer NJC, de Vries NE, Webers CAB, Hendrikse F, Nuijts RMMA. Astigmatism management in cataract surgery with the AcrySof toric intraocular lens. *J Cataract Refract Surg* 2008;34:1483-1488.
9. Miller DD, Hasan SA, Simmons NL, Stewart MW. Recurrent corneal erosion: a comprehensive review. *Clin Ophthalmol.* 2019;13:325-335.
10. Reidy JJ, Paulus MP, Gona S. Recurrent erosions of the cornea: epidemiology and treatment. *Cornea.* 2000;19(6):767-771.
11. Orndahl MJ, Fagerholm PP. Phototherapeutic keratectomy for map-dot-fingerprint corneal dystrophy. *Cornea.* 1998;17(6):595-599.
12. Geggel HS. Successful treatment of recurrent corneal erosion with Nd:YAG anterior stromal puncture. *Am J Ophthalmol.* 1990;110(4):404-407.
13. Tzelikis PF, Rapuano CJ, Hammersmith KM, Laibson PR, Cohen EJ. Diamond burr treatment of poor vision from anterior basement membrane dystrophy. *Am J Ophthalmol.* 2005;140(2):308-310.
14. Pogorelov P, Langenbacher A, Kruse F, Seitz B. Long-term results of phototherapeutic keratectomy for corneal map-dot-fingerprint dystrophy (Cogan-Guerry) *Cornea.* 2006;25(7):774-777.
15. Rezende RA, Uchoa UC, Cohen EJ, et al. Complications associated with anterior basement membrane dystrophy after LASIK. *J Cataract Refract Surg* 2004;30(11):2328-31.
16. Perez-Santonja JJ, Galal A, Cardona C, et al. Severe corneal epithelial sloughing during LASIK as a presenting sign for silent epithelial basement membrane dystrophy. *J Cataract Refract Surg* 2005;31(10):1932-7.

## ADVERTISER INDEX

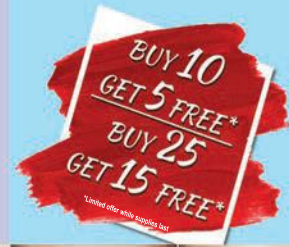*This index is published as a convenience and not as part of the advertising contract. Every care will be taken to index correctly. No allowance will be made for errors due to spelling, incorrect page number, or failure to insert.*

<b>Acuity Pro</b> .....	<b>35</b>	<b>Bausch + Lomb</b> .....	<b>59</b>	<b>Johnson &amp; Johnson Surgical Vision, Inc.</b> .....	<b>23</b>
.....(580) 243-1301		.....(800) 871-1103		.....	<a href="http://www.jnjvisionpro.com">www.jnjvisionpro.com</a>
..... <a href="mailto:info@acuitypro.com">info@acuitypro.com</a>		..... <a href="http://www.alaway.com">www.alaway.com</a>		<b>Johnson &amp; Johnson Surgical Vision, Inc.</b> .....	<b>61</b>
..... <a href="http://www.acuitypro.com">www.acuitypro.com</a>		<b>Bausch + Lomb</b> .....	<b>54-55</b>	.....	<a href="http://www.jnjvisionpro.com">www.jnjvisionpro.com</a>
<b>Akorn Pharmaceuticals</b> .....	<b>21</b>	..... <a href="http://www.bausch.com">www.bausch.com</a>		<b>Keeler Instruments</b> .....	<b>5</b>
..... <a href="http://www.MyAkornEyeCare.com">www.MyAkornEyeCare.com</a>		<b>Bausch + Lomb</b> .....	<b>115</b>	.....(800) 523-5620	
<b>Akorn Consumer Health</b> .....	<b>51</b>	..... <a href="http://www.bausch.com">www.bausch.com</a>		..... <a href="http://www.keelerusa.com">www.keelerusa.com</a>	
..... <a href="http://www.theratears.com/professionals">www.theratears.com/professionals</a>		<b>Coburn Technologies</b> .....	<b>83</b>	<b>MacuLogix</b> .....	<b>25</b>
<b>Alcon Laboratories</b> .....	<b>116</b>	..... <a href="http://www.coburntechnologies.com">www.coburntechnologies.com</a>		..... <a href="http://www.maculogix.com/6months">www.maculogix.com/6months</a>	
..... <a href="http://www.AlconClearFit.com">www.AlconClearFit.com</a>		<b>CooperVision</b> .....	<b>27</b>	<b>Notal Vision</b> .....	<b>49</b>
<b>Alcon Laboratories</b> .....	<b>Cover Tip</b>	..... <a href="http://www.coopervision.com">www.coopervision.com</a>		.....(855) 600-3112	
..... <a href="http://www.alcon.com">www.alcon.com</a>		<b>Eyevance</b> .....	<b>7 &amp; 8</b>	..... <a href="http://www.foreseehome.com/hcp">www.foreseehome.com/hcp</a>	
<b>Allergan, Inc.</b> .....	<b>Insert</b>	..... <a href="http://www.MyZerviate.com">www.MyZerviate.com</a>		<b>Oasis Medical - Oasis Medical Corporate</b> .....	<b>67</b>
..... <a href="http://www.allergan.com">www.allergan.com</a>		<b>Eyevance</b> .....	<b>41 &amp; 42</b>	.....(844) 820-8940	
<b>Bausch + Lomb</b> .....	<b>13 &amp; 14</b>	..... <a href="http://www.mytoBradexst.com">www.mytoBradexst.com</a>		..... <a href="mailto:customerservice@oasismedical.com">customerservice@oasismedical.com</a>	
..... <a href="http://www.lotemaxsm.com">www.lotemaxsm.com</a>		<b>Glaukos</b> .....	<b>17</b>	..... <a href="http://www.oasismedical.com">www.oasismedical.com</a>	
<b>Bausch + Lomb</b> .....	<b>2 &amp; 3</b>	..... <a href="http://www.iLinkExpert.com">www.iLinkExpert.com</a>		<b>Optos</b> .....	<b>65</b>
..... <a href="http://www.vyzultahcp.com">www.vyzultahcp.com</a>		<b>Haag-Streit USA</b> .....	<b>39</b>	.....(800) 854-3039	
		.....(866) 766-1517		..... <a href="http://www.optos.com">www.optos.com</a>	
		..... <a href="http://www.lenstarmyopia.com">www.lenstarmyopia.com</a>		<b>RVL Pharmaceuticals, Inc.</b> .....	<b>29 &amp; 30</b>
		<b>Icare USA</b> .....	<b>33</b>	.....(866) 600-4799	
		.....(888) 422-7313		..... <a href="http://www.Upneeq.com">www.Upneeq.com</a>	
		..... <a href="mailto:infoUSA@icare-world.com">infoUSA@icare-world.com</a>		<b>Synergy Eyes</b> .....	<b>47</b>
		..... <a href="http://www.icare-world.com/USA">www.icare-world.com/USA</a>		.....(877) 733-2012	
				..... <a href="http://www.SynergyEyes.com/Professional">www.SynergyEyes.com/Professional</a>	
				<b>VSP</b> .....	<b>11</b>
				..... <a href="http://www.unitybiosync.com">www.unitybiosync.com</a>	

Contact Lenses

# Impressions

Color Contact Lens



*Unleash your true color!*

Impressions colored contacts blend naturally with your patients eyes to create a beautiful look. Available in nine dazzling opaque colors of which Brown, Grey, Green, Hazel, Honey, Pure Hazel and True Sapphire are available in RX PL to -8.00. Impressions are fun, hip, fashionable and very competitively priced to help your bottom line. POP materials, posters, and trial kits are available upon request.

Available Exclusively at

**NATIONAL LENS**  
 1-866-923-5600  
 www.national-lens.com

CALL US FOR ALL MAJOR BRANDS OF CONTACTS

Practice For Sale

Practice Sales • Appraisals • Consulting  
 www.PracticeConsultants.com  
**PRACTICES FOR SALE  
 NATIONWIDE**  
 Visit us on the Web or call us to learn more about our company and the practices we have available.  
 info@PracticeConsultants.com  
**925-820-6758**  
 www.PracticeConsultants.com

**Successful  
 Optometric Practice For Sale.**  
 48 year old established practice is located in Burlington, Kansas.  
 All furniture, optical equipment, inventory and patient charts included.  
 Attractive building is leased in a desirable location.  
 Owner willing to finance at no interest.  
 Contact Dr. Dale Herder, OD  
 @ 620-364-2994  
 or [drdaleherder@yahoo.com](mailto:drdaleherder@yahoo.com)

Equipment & Supplies

**WHY PAY RETAIL?**



Electric power lift table and adjusts from 25" to 50" Tabletop is 20" X 52" Tabletop will accommodate three instruments. Push button switch control. NEW IN BOX. Wholesale Price \$1,195.00 Call 800-522-2275

**Do you have Products and Services for sale?**

CONTACT US TODAY FOR CLASSIFIED ADVERTISING  
 Toll free: 888-498-1460  
 E-mail: [sales@kerhgroup.com](mailto:sales@kerhgroup.com)

**Do you have CE Programs?**

**CONTACT US TODAY FOR CLASSIFIED ADVERTISING**

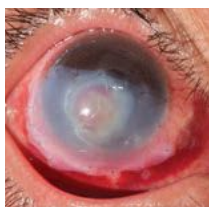Toll free: 888-498-1460  
 E-mail: [sales@kerhgroup.com](mailto:sales@kerhgroup.com)

Place Your Ad Here!

Toll free: 888-498-1460  
 E-mail: [sales@kerhgroup.com](mailto:sales@kerhgroup.com)



Register for an upcoming CE webinar  
from Review Education Group!



**Insane in the Membrane**

Practical Applications of Amniotic Membranes

**TUESDAY, APRIL 20, 2021 | 8:00 PM ET**

SPEAKER: Osama Said, OD

Register: [www.ReviewEdu.com/InsaneInTheMembrane](http://www.ReviewEdu.com/InsaneInTheMembrane)



**Genetic Testing**

A New Frontier in Management of Inherited Retinal Diseases

**TUESDAY, MAY 18, 2021 | 8:00 PM ET**

SPEAKER: Mohammad Rafieetary, OD, FAAO

Register: [www.ReviewEdu.com/GeneticTesting](http://www.ReviewEdu.com/GeneticTesting)



**What's Next in Glaucoma Diagnostics?**

**WEDNESDAY, JUNE 9, 2021 | 8:00 PM ET**

SPEAKERS: Anupam Laul, OD, FAAO and Daniel Epshtein, OD, FAAO

Register: [www.ReviewEdu.com/GlaucomaDiagnostics](http://www.ReviewEdu.com/GlaucomaDiagnostics)

Earn 1 LIVE COPE Credit for \$19.99\*

For additional information visit

[www.ReviewEdu.com/Events](http://www.ReviewEdu.com/Events)

e-mail: [ReviewMeetings@MedscapeLIVE.com](mailto:ReviewMeetings@MedscapeLIVE.com)



\*Approval pending

Review Education Group partners with Salus University for those ODs who are licensed in states that require university credit.



# PRODUCT REVIEW

New items on the market to improve clinical care and strengthen your practice.

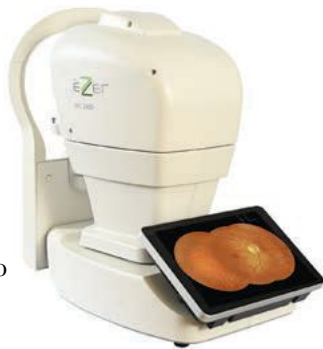

**ONLINE FIRST:**  
GET THE LATEST  
PRODUCT NEWS AT  
[www.reviewofoptometry.com](http://www.reviewofoptometry.com)

## ► DIAGNOSTIC EQUIPMENT

### ***New Non-Myd Camera Aims for Ease***

Practices looking for a new retinal camera without a steep learning curve might want to consider the Ezer EFC-2600, says manufacturer US Ophthalmic. Autofocus allows anyone to perform photography successfully, and the intuitive interface and large touchscreen enable straightforward operation, according to the company.



The EFC-2600 captures 12-megapixel retinal images at a field of view up to 100°, without the need for pupil dilation. It works for anterior segment photography, too. For mosaic imaging, the operator can choose up to 10 fixation targets and the device will combine several results to produce a widefield of view of the retina. The touchscreen can also double as a display capable of side-by-side image view for serial analysis of change between visits.

DICOM compatibility allows images and reports to be easily transferred or integrated with other patient software, US Ophthalmic says. All electronic patient files and reports can be stored on the device and shared with specialists via cloud or email.

### ***New Language Options Enhance AMD Screenings***

If you've recently added the AdaptDx Pro for dark adaptation screening to your practice, or are considering it, bear in mind that the device's on-board intelligent assistant, Theia, now speaks multiple languages, Maculogix announced. Theia guides patients through the test with instructions and cues to maintain attention. Your tech can operate the device in one language while selecting a different one for the patient to experience, Maculogix says.

Language options now include English, North American Spanish, European Spanish, French, Italian, German and Canadian French. Theia is also available with a British and Australian accent. Tailoring patient instructions to their native language improves communication, understanding and trust, Maculogix says.



## ► REFRACTION SYSTEMS

### ***Digital Refractor Empowers Staff, Speeds Exams***

You can give your manual phoropter a rest and speed up practice efficiency with the newest version of the Visionix Eye Refract system, which comes with an array of upgrades based on user feedback, manufacturer Luneau says. The device combines a digital phoropter, wavefront-based auto-refractometry and keratometry, a digital acuity short chart and integrated lens analyzer in a footprint of just eight square feet, according to a company press release.

Among the new features in the second-gen product, clinicians and techs can now use K readings to fit soft contact lenses without having to run the patient through another instrument, and the device can quickly identify the patient's refractive "comfort zone." Additional improvements were made to the algorithm and wavefront laser, resulting in faster and more accurate results on a wider diversity of challenging patient demographics, the press release states.

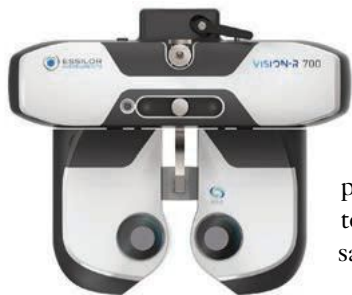Luneau staff train new users to follow a scripted, tablet-driven process that generates recommended final prescriptions in about four minutes, the company says. Visionix's algorithm-guided interface allows even novice users to obtain consistently accurate recommended final prescriptions and K-readings in the pre-test area, the company says, so ODs can focus their patient consult time on more robust medical consultations or other growth opportunities to transform their practice. The final review and approval process remains with the doctor, but they can focus on more challenging patient cases that require use of a manual phoropter to complete the subjective portion, Luneau suggests.



### ***Fast Phoropter Offers Three-Minute Refractions***

If you're in the market for a manual phoropter but want the benefits of speed and digital assistance that conventional models lack, the new Vision-R 700 from Essilor Instruments may fit the bill, according to the company.

The Vision-R 700 uses a unique optical module with variable focus and a new cylinder-search method, a company press release explains. These allow simultaneous and continuous variations of sphere power, cylinder axis and cylinder power by automatically compensating for the effect that any change in sphere, cylinder and axis has on the other dimensions. Essilor calls this "digital infinite refraction" and believes it offers great potential for advancements in



refraction methods. The company says its new lens module and use of refraction algorithms cuts time from the refraction process—potentially down to three minutes—without sacrificing accuracy.

Essilor also says the Vision-R 700 offers a wider field of

view, which eliminates the need for superposition of lenses as in traditional phoropters, giving the patient a more comfortable viewing experience without the effect of tunnel vision. Another nice feature: the ability to incorporate a patient response of “I don’t know” when presented with Rx choices.

### **Vision Tester Fine-Tunes Eye Misalignment**

To help binocular vision patients who need prism, as well as others who find near vision work taxing to their eyes and bodies, this summer Neurolens will be introducing a new version of its testing equipment called the Neurolens Measurement Device Gen 2 (NMD2).

Neurolens says the NMD2 is an objective and thus more accurate way to measure binocular vision because it doesn’t rely on the patient’s subjective feedback, which also allows it to be operated by a tech at any experience level.

The new version’s eye tracking system can identify misalignment as small as 0.1 prism diopters, according to the manufacturer. The diagnostic data from the NMD2 is used to prescribe custom lenses that vary the amount of prism from top to bottom to account for differing visual needs as focal length changes. Neurolens calls this concept “contoured prism” and says it offers ergonomic benefits to patients by allowing better posture during near vision tasks like computer use.

The NMD2 is 80% smaller than the original device, making it easier to incorporate into any practice space, the company says. It’s also 35% faster, which the company says can improve pre-test efficiency and overall patient flow. Finally, the new device also supports faster eye tracking and increased fields of vision, allowing for additional testing capabilities.

The NMD2 will be commercially available on July 1, but the company will take orders immediately as part of a pre-sale offer.



### **▶ CONTACT LENSES**

#### **Two-Week Multifocal Allows Pupil-Independent Fits**

If you have successful Acuvue Oasys patients who are reaching presbyopic age, now you can offer them a correction in the same lens family, as Johnson & Johnson Vision recently introduced Acuvue Oasys Multifocal in the same material (senofilcon) and also for two-week replacement. The new product uses the pupil optimized design of the 1-Day Acuvue Moist Multifocal, which J&J says allows the lens to be fit independent of pupil size.

The design uses a hybrid back curve: an aspheric center allows the lens to drape across the cornea without creating distortion while a spherical skirt holds the lens in place, J&J explains. Like other Acuvue Oasys lenses, it embeds polyvinylpyrrolidone in the matrix, which mimics the mucins found in tear film to help support a stable tear film, according to the company. J&J calls this wetting agent “Hydraclear Plus.”

The Acuvue Oasys Multifocal is available in sphere powers from -9.00D to +6.00D and three add power ranges: low (+0.75D to +1.25D), mid (+1.50D to +1.75D) and high (+2.00D to +2.50D).



#### **Smaller Sclerals, Bigger Benefits**

The BostonSight Scleral is now available in 16mm, 16.5mm and 17mm diameters, in addition to the original 18mm, 18.5mm and 19mm diameters introduced in 2017. Each series is part of a diagnostic set that includes three diameter options, right and left anatomical designs to address unique scleral shape profiles, and a fitting guide, the company says.

Unique design features the company points to include:

- oval optic zones for better lens centration and more predictable fitting endpoints
- independence among parameters like base curve, vault and optic zone to allow for easier changes
- ventilating channels that allow fitting lenses over anatomical obstacles, promote tear exchange and minimize suction
- built-in front surface eccentricity and custom HOA correction for optimal vision

BostonSight says that 90% of fits achieve optimal vision, 75% are achieved with the go-to standard lens from the from the diagnostic set and 65% of fits don’t require haptic design change. ■





# Elevator Going Up

*Does this atypical retinal presentation suggest a sight-threatening pathology, or something benign?*

**A** 62-year-old female presented to the office with a chief complaint of floating spots in the right eye of four weeks' duration. Her systemic and ocular histories were unremarkable for treatable disease. She denied taking medications and reported no allergies of any kind.

## Diagnostic Data

Her best-corrected visual acuity was 20/20 at distance and near OU. Her

confrontation fields were full-to-finger-counting. Pupils were equal and normally reactive with no afferent defect. Refraction uncovered hyperopia with presbyopia OU. Biomicroscopy demonstrated normal anterior segment structures with intraocular pressures measuring 16mm Hg OD and 17mm Hg OS. The photographs illustrate the pertinent posterior segment finding.

Additional studies included photodocumentation and three-mirror

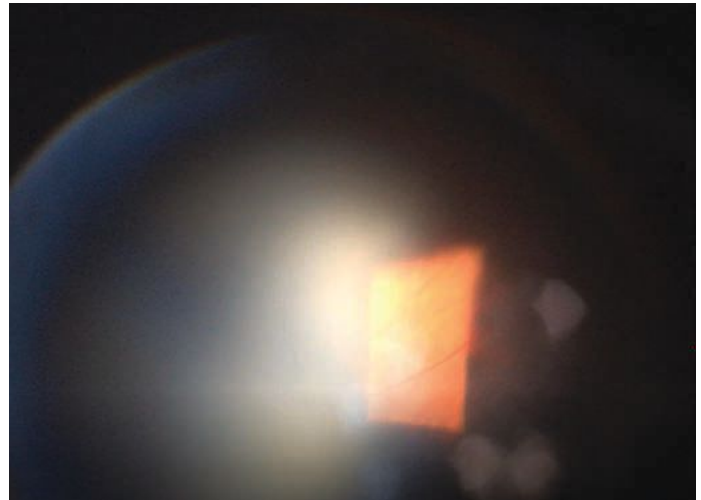
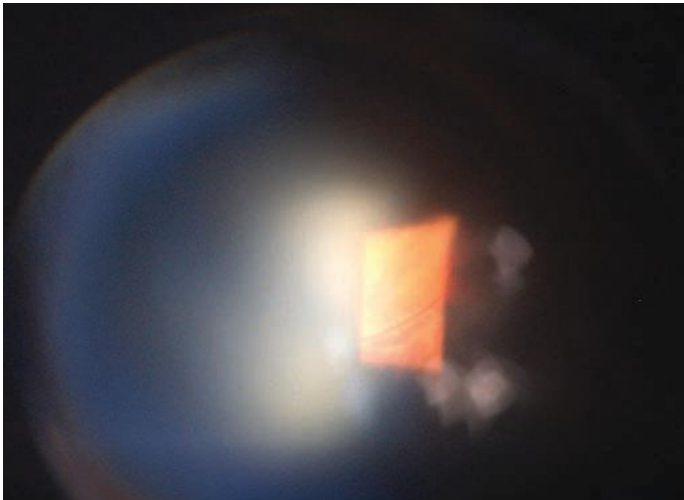
evaluation with and without scleral depression.

Ophthalmic ultrasonography may also be helpful in confirming the diagnosis. If uncertain, the clinician may opt for a referral to retinology, where further tests may include deep field optical coherence tomography, additional ultrasound testing, color doppler flow imaging or retinal angiographic testing.

## Your Diagnosis

What would be your diagnosis in this case? What is the patient's likely prognosis? To find out, please read the online version of this article at [www.reviewofoptometry.com](http://www.reviewofoptometry.com). ■

*Dr. Gurwood thanks Nick Karbach, OD, for contributing this case.*



**What might these unusual fundus images reveal about our patient? Left: lesion with off-axis 90° view. Right: lesion with digital pressure applied to the globe.**

**About Dr. Gurwood** Dr. Gurwood is a professor of clinical sciences at The Eye Institute of the Pennsylvania College of Optometry at Salus University. He is a co-chief of Primary Care Suite 3. He is attending medical staff in the department of ophthalmology at Albert Einstein Medical Center, Philadelphia. He has no financial interests to disclose.

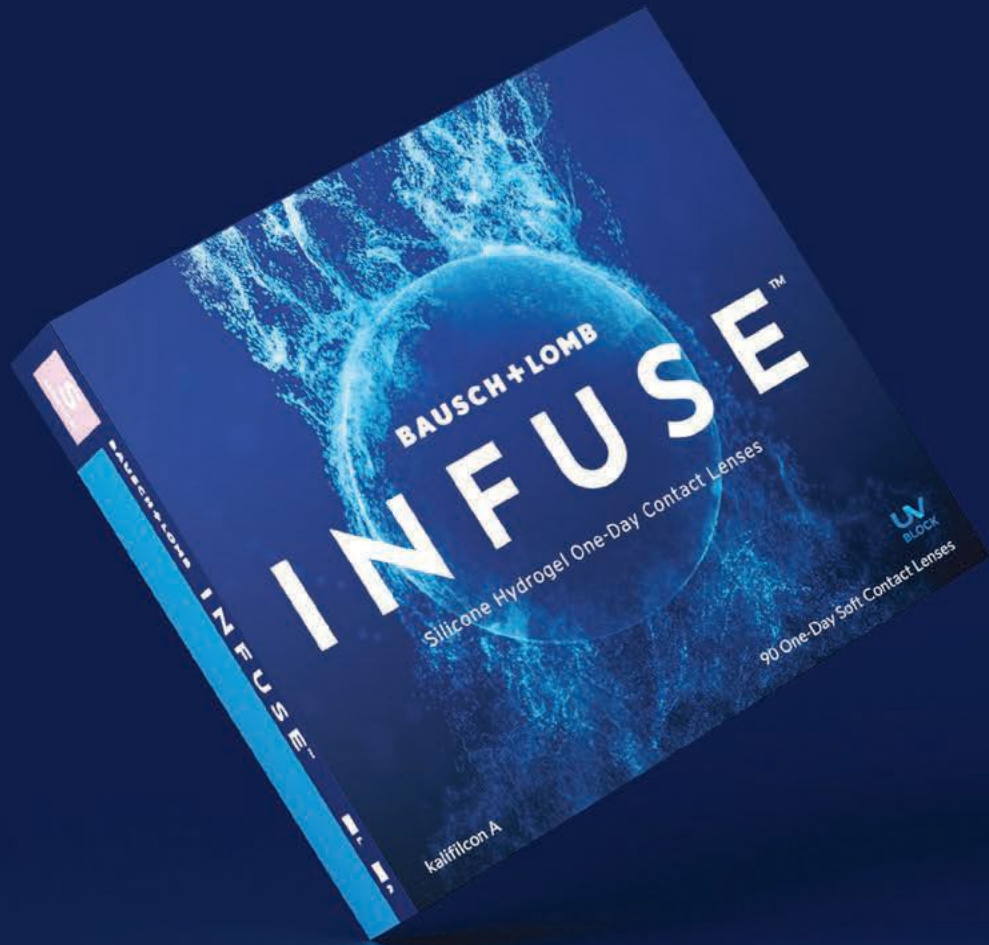**NEXT MONTH IN THE MAG**

In May, we present our annual pharmaceuticals report. Articles will include:

- Effective Use of Antibiotics to Treat Anterior Seg Infections
- Ocular Complications of Systemic Meds to Watch For
- Miotics & Mydriatics: Old, New and Future Uses
- Anti-virals for HZO: What You Need to Know
- How to Make Glaucoma Meds as Patient-Friendly as Possible

*Also included in May:*

- Take the Fear Out of Handling Neuro Cases



# INFUSED FOR BALANCE

Next-generation material + ProBalance Technology™  
working together to help maintain ocular surface homeostasis  
to aid in minimizing symptoms of contact lens dryness.<sup>1</sup>



Next-Generation Material



Ocular Surface  
Homeostasis



ProBalance Technology™

Find balance at [BauschInfuseECP.com](https://www.BauschInfuseECP.com)

REFERENCE: 1. Data on file. Bausch & Lomb Incorporated, Rochester, NY.

\*™ are trademarks of Bausch & Lomb Incorporated or its affiliates.  
©2020 Bausch & Lomb Incorporated or its affiliates. INF.0243.USA.20

**BAUSCH + LOMB**

See better. Live better.

ALCON MULTIFOCAL CONTACT LENSES

# EXCEPTIONAL COMFORT AND SEAMLESS VISION NEAR THROUGH FAR<sup>1-3</sup>


**96% FIT SUCCESS** WITH 2 LENSES OR LESS PER EYE with the latest fitting process for Alcon multifocal contact lenses<sup>4,5</sup>

To learn more visit: [www.AlconClearFit.com](http://www.AlconClearFit.com)



**Prescribe DAILIES TOTAL1® MULTIFOCAL,  
the World's First and Only Water Gradient Lens,  
for your presbyopic patients today**

**References:** **1.** Lemp J, Kern J. Alcon multifocal contact lenses for presbyopia correction. Presented at the Canadian Association of Optometrists Congress; June 28-30, 2017; Ottawa, ON. **2.** Kern J, Kannarr S, Miller J. Clinical Outcomes for Dailies Total1 Multifocal Lens in Symptomatic Patients. Poster presented at the Annual Clinical Conference & Exhibition of the British Contact Lens Association (BCLA); June 9-11, 2017; Liverpool, UK. **3.** Alcon data on file, 2016. **4.** Bauman E, Lemp J, Kern J. Material effect on multifocal contact lens fitting of lenses of the same optical design with the same fitting guide. Poster presented at the British Contact Lens Association (BCLA) Clinical Conference and Exhibition, June 9-11, 2017. Liverpool, UK. **5.** Merchea M, Evans D, Kannarr S, et al. Assessing a modified fitting approach for improved multifocal contact lens fitting success. Presented at the American Optometric Association Annual Meeting, June 21-25, 2018. Denver, CO.

See product instructions for complete wear, care, and safety information. 

© 2020 Alcon Inc. 07/20 US-DTM-2000064

**Alcon**