

REVIEW[®] of OPTOMETRY

December 15, 2021 • reviewofoptometry.com

Leadership in clinical care

ANNUAL
INCOME SURVEY

Back on the
Playing Field

PAGE 34

27TH ANNUAL

THEIR GENES GAVE THEM BUTTON NOSES, BROWN HAIR, AND **VISION LOSS**

To date, science has discovered more than 270 genes related to **inherited retinal diseases**.¹ With the evolution of genetic testing comes the ability to more precisely diagnose your patients. More answers may uncover more possibilities.

MOVE FORWARD WITH MORE ANSWERS

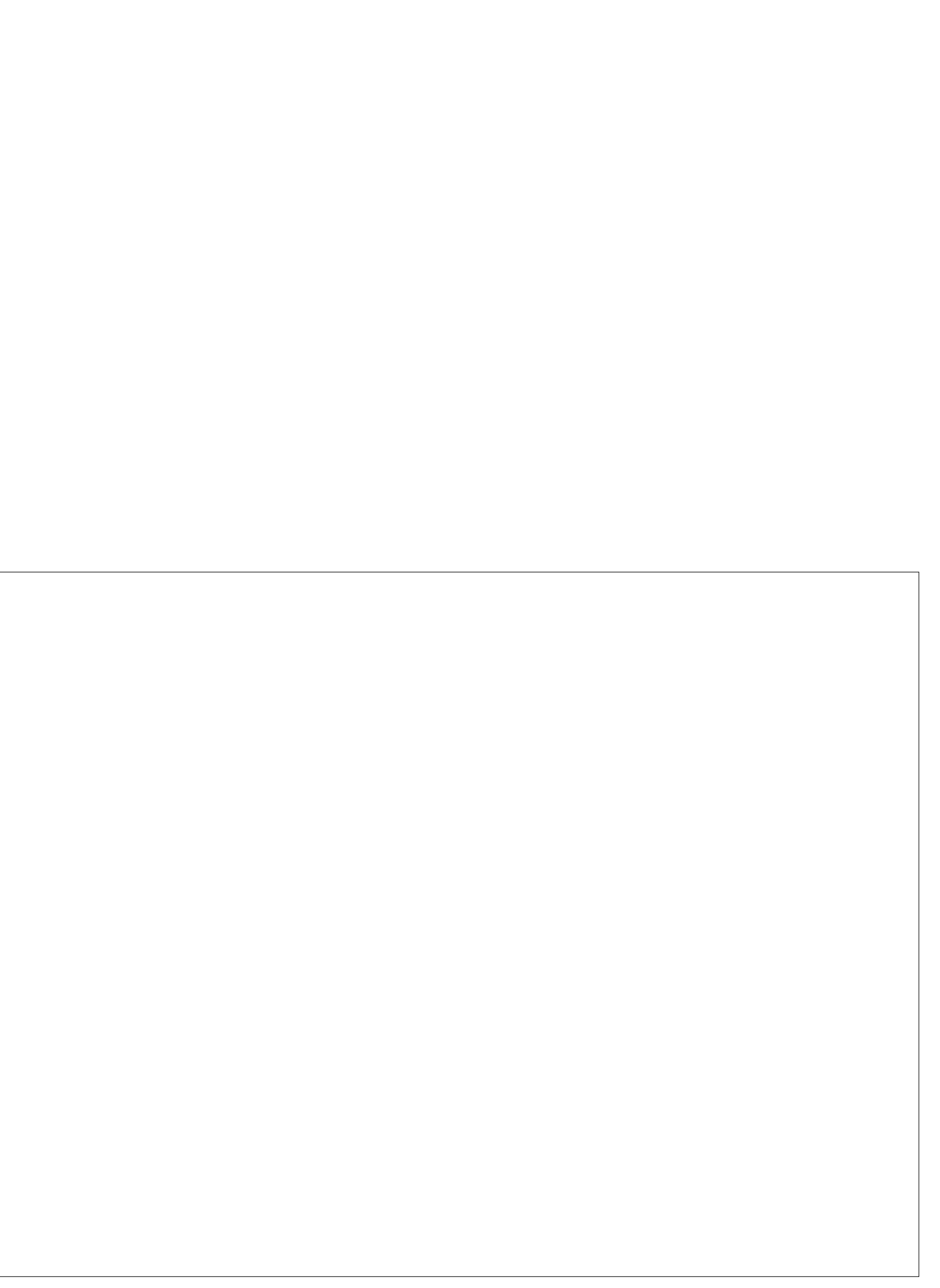


Scan to find more answers about genetic testing and retesting at EyesOnGenes.com.

Reference: 1. Branham K, Schlegel D, Fahim AT, Jayasundera KT. Genetic testing for inherited retinal degenerations: triumphs and tribulations. *Am J Med Genet C Semin Med Genet.* 2020;184(3):571-577.

© Janssen Pharmaceuticals, Inc. 2021 09/21 cp-250095v1

janssen  PHARMACEUTICAL COMPANIES OF 



Plaquenil Toxicity: How to Avoid this Bullseye, *P. 56* • Therapeutic Review: Neuroretinitis, *P. 66*

REVIEW[®] *of* OPTOMETRY

December 15, 2021 • reviewofoptometry.com

Leadership in clinical care

ANNUAL
INCOME SURVEY

Back on the
Playing Field

PAGE 34

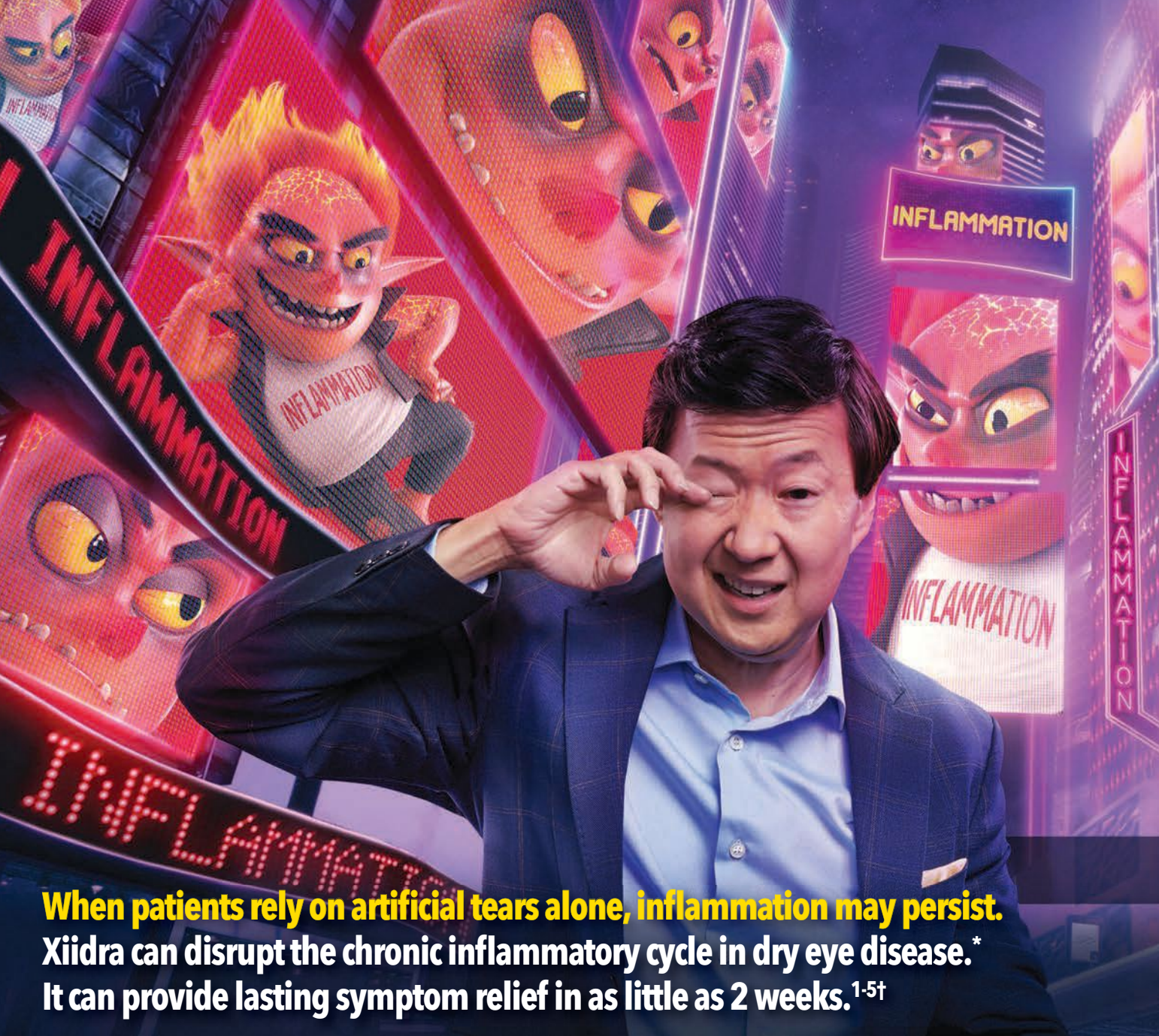27TH ANNUAL

SURGERY REPORT

The Key to Happy Refractive Patients, *P. 40*

Real-World Performance of Newer Intraocular Lenses, *P. 46*

A Step-by-Step Guide to Cataract Post-op Care, *P. 52*



When patients rely on artificial tears alone, inflammation may persist. Xiidra can disrupt the chronic inflammatory cycle in dry eye disease.* It can provide lasting symptom relief in as little as 2 weeks.^{1-5†}

*Xiidra blocks LFA-1 on T cells from binding with ICAM-1 that may be overexpressed on the ocular surface in dry eye disease and may prevent formation of an immunologic synapse which, based on in vitro studies, may inhibit T-cell activation, migration of activated T cells to the ocular surface, and reduce cytokine release. The exact mechanism of action of Xiidra in DED is not known.^{1,2,5}

†The safety and efficacy of Xiidra were assessed in four 12-week, randomized, multicenter, double-masked, vehicle controlled studies (N=2133). Patients were dosed twice daily. The mean age was 59 years (range, 19-97 years). The majority of patients were female (76%). Use of artificial tears was not allowed during the studies. The study end points included assessment of signs (based on Inferior fluorescein Corneal Staining Score [ICSS] on a scale of 0 to 4) and symptoms (based on patient-reported EDS on a visual analogue scale of 0 to 100). Effects on symptoms of dry eye disease: a larger reduction in EDS favoring Xiidra was observed in all studies at day 42 and day 84. Xiidra reduced symptoms of eye dryness at 2 weeks (based on EDS) compared to vehicle in 2 out of 4 clinical trials. Effects on signs of dry eye disease: at day 84, a larger reduction in ICSS favoring Xiidra was observed in 3 out of the 4 studies.¹

Indication

Xiidra® (lifitegrast ophthalmic solution) 5% is indicated for the treatment of signs and symptoms of dry eye disease (DED).

Important Safety Information

- Xiidra is contraindicated in patients with known hypersensitivity to lifitegrast or to any of the other ingredients.



Novartis Pharmaceuticals Corporation
East Hanover, New Jersey 07936-1080



KEN JEONG,
REAL DRY EYE PATIENT.


xiidra®
(lifitegrast
ophthalmic solution) 5%
Dry eyes deserve a change

Important Safety Information (cont)

- In clinical trials, the most common adverse reactions reported in 5-25% of patients were instillation site irritation, dysgeusia and reduced visual acuity. Other adverse reactions reported in 1% to 5% of the patients were blurred vision, conjunctival hyperemia, eye irritation, headache, increased lacrimation, eye discharge, eye discomfort, eye pruritus and sinusitis.
- To avoid the potential for eye injury or contamination of the solution, patients should not touch the tip of the single-use container to their eye or to any surface.
- Contact lenses should be removed prior to the administration of Xiidra and may be reinserted 15 minutes following administration.
- Safety and efficacy in pediatric patients below the age of 17 years have not been established.

For additional safety information about XIIDRA®, please refer to the brief summary of Prescribing Information on adjacent page.

References: 1. Xiidra [package insert]. East Hanover, NJ: Novartis Pharmaceuticals Corp; June 2020. 2. Bron AJ, de Paiva CS, Chauhan SK, et al. TFOS DEWS II Pathophysiology Report. *Ocul Surf.* 2017;15(3):438-510. 3. US Food and Drug Administration. Code of Federal Regulations, Title 21, Volume 5 (21CFR349). Accessed May 25, 2021. <https://www.accessdata.fda.gov/scripts/cdrh/cfdocs/cfcfr/CFRSearch.cfm?CFRPart=349&showFR=1> 4. Jones L, Downie LE, Korb D, et al. TFOS DEWS II Management and Therapy Report. *Ocul Surf.* 2017;15(3):575-628. 5. Pflugfelder SC, Stern M, Zhang S, Shojaei A. LFA-1/ICAM-1 interaction as a therapeutic target in dry eye disease. *J Ocul Pharmacol Ther.* 2017;33(1):5-12.

XIIDRA, the XIIDRA logo and ii are registered trademarks of Novartis AG.

XIIDRA® (lifitegrast ophthalmic solution), for topical ophthalmic use
Initial U.S. Approval: 2016

BRIEF SUMMARY: Please see package insert for full prescribing information.

1 INDICATIONS AND USAGE

Xiidra® (lifitegrast ophthalmic solution) 5% is indicated for the treatment of the signs and symptoms of dry eye disease (DED).

4 CONTRAINDICATIONS

Xiidra is contraindicated in patients with known hypersensitivity to lifitegrast or to any of the other ingredients in the formulation [see *Adverse Reactions* (6.2)].

6 ADVERSE REACTIONS

The following serious adverse reactions are described elsewhere in the labeling:

- Hypersensitivity [see *Contraindications* (4)]

6.1 Clinical Trials Experience

Because clinical trials are conducted under widely varying conditions, adverse reaction rates observed in clinical trials of a drug cannot be directly compared to rates in the clinical trials of another drug and may not reflect the rates observed in practice.

In five clinical trials of DED conducted with lifitegrast ophthalmic solution, 1401 patients received at least one dose of lifitegrast (1287 of which received lifitegrast 5%). The majority of patients (84%) had less than or equal to 3 months of treatment exposure. One hundred-seventy patients were exposed to lifitegrast for approximately 12 months. The majority of the treated patients were female (77%). The most common adverse reactions reported in 5%-25% of patients were instillation-site irritation, dysgeusia, and reduced visual acuity.

Other adverse reactions reported in 1%-5% of the patients were blurred vision, conjunctival hyperemia, eye irritation, headache, increased lacrimation, eye discharge, eye discomfort, eye pruritus, and sinusitis.

6.2 Postmarketing Experience

The following adverse reactions have been identified during post-approval use of Xiidra. Because these reactions are reported voluntarily from a population of uncertain size, it is not always possible to reliably estimate their frequency or establish a causal relationship to drug exposure.

Rare serious cases of hypersensitivity, including anaphylactic reaction, bronchospasm, respiratory distress, pharyngeal edema, swollen tongue, urticaria, allergic conjunctivitis, dyspnea, angioedema, and allergic dermatitis have been reported. Eye swelling and rash have also been reported [see *Contraindications* (4)].

8 USE IN SPECIFIC POPULATIONS

8.1 Pregnancy

Risk Summary

There are no available data on Xiidra use in pregnant women to inform any drug-associated risks. Intravenous (IV) administration of lifitegrast to

pregnant rats, from pre-mating through gestation day 17, did not produce teratogenicity at clinically relevant systemic exposures. Intravenous administration of lifitegrast to pregnant rabbits during organogenesis produced an increased incidence of omphalocele at the lowest dose tested, 3 mg/kg/day (400-fold the human plasma exposure at the recommended human ophthalmic dose [RHOD], based on the area under the curve [AUC] level). Since human systemic exposure to lifitegrast following ocular administration of Xiidra at the RHOD is low, the applicability of animal findings to the risk of Xiidra use in humans during pregnancy is unclear [see *Clinical Pharmacology* (12.3) in the full prescribing information].

Data

Animal Data

Lifitegrast administered daily by IV injection to rats, from pre-mating through gestation day 17, caused an increase in mean pre-implantation loss and an increased incidence of several minor skeletal anomalies at 30 mg/kg/day, representing 5,400-fold the human plasma exposure at the RHOD of Xiidra, based on AUC. No teratogenicity was observed in the rat at 10 mg/kg/day (460-fold the human plasma exposure at the RHOD, based on AUC). In the rabbit, an increased incidence of omphalocele was observed at the lowest dose tested, 3 mg/kg/day (400-fold the human plasma exposure at the RHOD, based on AUC), when administered by IV injection daily from gestation days 7 through 19. A fetal no observed adverse effect level (NOAEL) was not identified in the rabbit.

8.2 Lactation

Risk Summary

There are no data on the presence of lifitegrast in human milk, the effects on the breastfed infant, or the effects on milk production. However, systemic exposure to lifitegrast from ocular administration is low [see *Clinical Pharmacology* (12.3) in the full prescribing information]. The developmental and health benefits of breastfeeding should be considered, along with the mother's clinical need for Xiidra and any potential adverse effects on the breastfed child from Xiidra.

8.4 Pediatric Use

Safety and efficacy in pediatric patients below the age of 17 years have not been established.

8.5 Geriatric Use

No overall differences in safety or effectiveness have been observed between elderly and younger adult patients.

Distributed by:
Novartis Pharmaceuticals Corporation
One Health Plaza
East Hanover, NJ 07936
T2020-87



Online Vendors Get Better at Spectacle Rx Results

One-tenth of current orders had optical quality issues, compared with 45% in a 2011 study.

While companies like Warby Parker continue to try and expand their spectacle Rx footprint, a recent investigation found that about one in 10 prescriptions filled by three online vendors failed to meet national standards for optical quality, a result that was greatly improved over a 2011 investigation that reported roughly 45% of spectacles failed at least one optical parameter or impact testing.^{1,2}

“Despite this improvement in spectacle prescription accuracy, other lens design elements impacting visual performance and ocular protection cannot be determined by the prescription alone,” the authors wrote in their paper.

Spectacle prescription numbers, such as sphere, cylinder and axis, don’t provide the additional information necessary to optimize visual function and performance of the eyewear for an individual patient, they added.

Paid participants with no optical training and who were masked to the study’s objectives ordered spectacle lenses from the Internet. The prescription powers ordered (sphere, cylinder and axis) were statistically sampled from 1,000 previously filled prescriptions. A total of 100 orders were placed with three online vendors, and the orders included a range of high- and low-powered single vision lenses, progressive addition lenses and duplicate orders to assess repeatability. An independent

Photo: Getty Images



The quality and prescription accuracy of spectacle orders filled through online vendors is improving with time.

certified testing lab was contracted to assess the products’ conformance with voluntary consensus standards and FDA drop-ball safety testing. Lenses not meeting these standards were counted as failures.

The overall failure rate for the three vendors was 11.2±3.2% (Vendor A), 8.0±2.7% (Vendor B) and 8.2±2.8% (Vendor C). The repeatability for 20 prescriptions ordered five times from each vendor was high, at over 90%.

Additionally, the researchers didn’t find any lens impact failures in the current study.

Despite these improved findings, there is a risk of decreased visual performance and potential harm to individuals ordering spectacles online, as they are likely to be unaware that their prescriptions do not meet national standards.¹ When eyewear is ordered from an eye care professional, the finished lenses are assessed, and

any lenses not meeting national standards are re-ordered, the investigators explained in their paper on the study, published in *Optometry & Vision Science*.

“The consumer does not have the equipment or expertise to assess the accuracy or quality of ordered lenses. The potential risks are decreased visual effectiveness in the workplace, educational settings, recreational activities and driving, which

may increase the risk of decreased vision performance, visual asthenopia, accidents or falls,” the authors wrote.

The lower failure rates reported in the study could be due to several factors, including the fact that lens fabricating technology is now widely available and quality control processes may have improved since the earlier study.¹ Additionally, the 2011 study sampled a larger number of online vendors (10) with fewer orders per vendor (20) vs. the present study.

“It is our view that specific recommendations by an eye care professional who understands the unique visual tasks and lifestyle needs of a patient are required in most cases to produce an optimal eyewear design,” the researchers wrote. ◀

1. Gordon A, Twa M, Cutter G, Kleinstein RN. Accuracy and repeatability of internet-ordered spectacle lenses. *Optom Vis Sci*. October 20, 2021. [Epub ahead of print].

2. Citek K, Torgersen DL, Endres JD, Rosenberg RR. Safety and compliance of prescription spectacles ordered by the public via the Internet. *Optometry*. 2011;82:549-55.

CRAO Possible After Cosmetic Procedure

Facial filler injections have a small but devastating potential to occlude the ophthalmic artery, leading to embolic events.

When individuals undergo cosmetic procedures such as facial filler injections, they're not expecting to be exposed to risk an ophthalmic artery occlusion or brain infarction. They would mostly be right, as this devastating, blinding complication is quite rare. Only a few cases of iatrogenic ophthalmic artery occlusion (IOAO) and concomitant brain infarction have been reported, and the exact pathologic mechanism is still unclear.

However, researchers at Seoul National University recently reported a new case of unilateral blindness caused by IOAO and accompanied by bilateral brain infarction after a cosmetic facial filler injection. They say it's important that patients be informed of this potential complication, even though it's extremely rare.

In this case, a 39-year-old woman with no underlying disease presented with vision loss and ocular pain in her left eye. She also had motor weakness of her right upper and lower limbs immediately following hyaluronic acid facial filler injection into her glabella, the smooth part of the forehead above and between the eyebrows.

She underwent ophthalmic and neurologic examination, which included fundoscopic examination, slit lamp examination, fundus fluorescein angiography (FA), brain diffusion MRI and MRA.

The tests revealed the following:

- CRAO with choroidal ischemia
- cataract, corneal edema
- total ophthalmic artery occlusion
- complete ptosis and total ophthalmoplegia
- numerous high-signal intensity lesions in both cerebral hemispheres

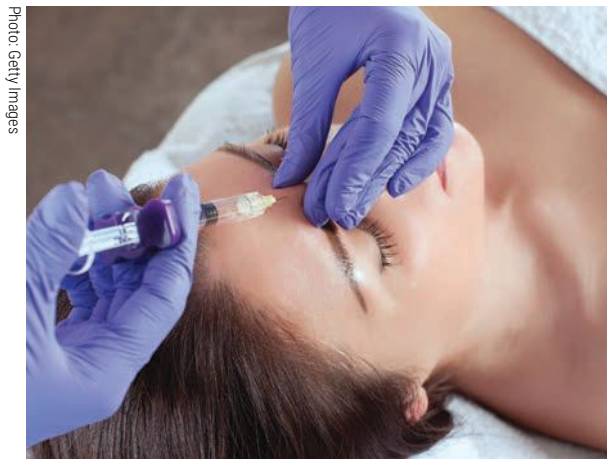


Photo: Getty Images

Facial fillers cause rare ocular complications such as CRAO, this study shows.

- multiple territorial cerebral infarction lesions involving the cerebral cortex of embolic etiology

Based on these findings, the researchers wrote, the embolism caused by filler injection was most likely the culprit behind the patient's embolic cerebral infarction.

She underwent follow-up diffusion MRI seven days later, which revealed extensive hemorrhagic transformation. This was categorized as parenchymal hematoma, which had been noted in previous infarcted foci. Her visual field examination showed a right inferior quadrantanopia with macular sparing, which the researchers said was likely due to left occipital lobe infarction.

A review of previous literature on IOAO associated with cosmetic facial filler injection showed four cases with bilateral embolic events. Three of these were unilateral IOAO and bilateral cerebral infarction, and one was IOAO without cerebral infarction.

There are two routes through which an embolism can reach

the bilateral arterial system after facial filler injection, the researchers noted—the anterior communicating artery and the cutaneous collaterals in the midline area. “In our case, IOAO occurred only on the left side,” the authors wrote in their paper on the findings, published in the *Journal of Neuro-ophthalmology*. “According to the clinical manifesta-

tions and fundus FA findings, the embolic material caused the occlusion of the proximal part of the ophthalmic artery and could reach the internal carotid artery.”

The researchers also noted that retrograde spreading of embolic materials is currently considered the most reasonable mechanism explaining IOAO. “Embolic material (typically autologous fat or hyaluronic acid) that's accidentally injected into facial cutaneous arterioles fills the lumen of the involved vessel and may be pushed proximally against arterial flow with great injecting pressure,” they wrote.

“Embolic material that reaches any branching point of the ophthalmic artery is disseminated at the branching point and is delivered to the distal portion, obstructing the distal part of the ophthalmic artery and its branches,” the study notes. “If the amount of injected filler and injection pressure are sufficient, the embolic material can be pushed into the internal carotid artery and involve any cerebral arteries.”

(Continued on p. 8)



WISHING YOU AND YOUR PRACTICE THE
HAPPIEST OF HOLIDAYS AND THE
JOY OF SUCCESS IN 2022

The VSP Global® Premier Program supports the long-term success of private practice providers. See how we're investing in practice support and new ways to help boost practice profitability and patient flow.

PartneringWithPremier.com 

Case Report of CRAO After Cosmetic Procedure

(Continued from p. 6)

In the other possible pathway, “The frontal branches of the superficial temporal artery and the supra-trochlear or supraorbital artery form a network of cutaneous collateral channels,” they explained. “Especially in the glabella and forehead area, numerous arterial anastomoses between the right and left cutaneous arterioles are known to exist. However, according to this hypothesis, the reason why the right cerebral infarction occurred without the right IOAO cannot be explained.”

The study authors noted that in four of the published cases, includ-

ing their own, on unilateral IOAO with bilateral brain infarction, the anterior communicating artery was the most likely pathway.

“In our case, no treatment was performed for reperfusion of the ophthalmic artery because of severe clinical features, including cerebral infarction, suggesting that a large amount of filler material caused extensive obstruction of the ophthalmic artery and its branches,” they wrote. “It was suspected that the viability of the retina was lost, and cerebral infarction with mental change was a more serious problem. Hyaluronidase could be an addition-

al treatment option. However, its effectiveness has not been proven in previous reports. Ischemic damage to the anterior segment and extra-ocular muscles could recover due to the relatively good collateral blood circulation and viability of tissues, which are better than those of the retina.”

The researchers concluded that clinicians should be suspicious of brain infarction, especially contralateral embolic events, in severe cases of IOAO after such procedures. ◀

Lee JS, Kim JY, Woo JS. Unilateral blindness with bilateral brain infarction after cosmetic facial filler injection. *J Neuroophthalmol* 2021;41:e566-71.

Alcohol Heightens Geographic Atrophy Risk

Scientists continue to explore risk factors for a variety of health conditions, including how genetics may help predict the development of disease. A recent study that relied on genetic evidence suggests alcohol consumption may lead to geographic atrophy (GA), while smoking habits could be tied to a greater risk of advanced age-related macular degeneration (AMD).

The UK-based study used a Mendelian randomized framework to assess 16,000 individuals with AMD and 18,000 controls to explore potential causal associations between the risk of advanced AMD and the following modifiable risk factors: smoking, alcohol consumption, BMI, blood pressure and glyce- mic traits.

“We found genetic evidence supporting a potential causal association between smoking initiation and advanced AMD risk consistent with prior observational studies,” the authors wrote in *JAMA Ophthalmology*.

This association was stronger for wet AMD than for GA, and similar results were found for lifetime

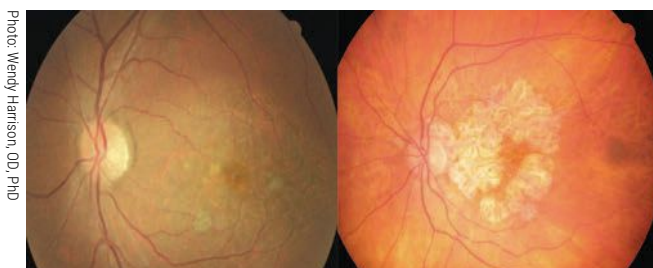


Photo: Wendy Harrison, OD, PhD

Consuming alcohol, as well as smoking, increases risk of GA development.

smoking behavior, they added. Additionally, smoking cessation was associated with a decreased risk of advanced AMD, specifically wet AMD, compared with persistent smoking.

“We also found suggestive evidence for a possible causal association between increased alcohol consumption and risk of advanced AMD that was likely driven by a strong association with GA,” the authors wrote.

As there are currently no known treatments for GA, this finding has important public health implications, the investigators suggested. These results also support previous observational studies associating

smoking behavior with risk of advanced AMD, reinforcing existing public health messages regarding the risk of blindness associated with smoking, they added.

The researchers found a one-SD increase in log odds of genetically predicted smoking initiation and a higher risk of advanced AMD. On the other hand, they observed a one-SD increase in log odds of genetically predicted smoking cessation (former vs. current smoking) and a lower risk of advanced AMD.

Considering other possible risk factors, the authors found insufficient evidence to suggest that genetically predicted blood pressure, BMI and glyce- mic traits were associated with advanced AMD. ◀

Kuan V, Warwick A, Hingorani A, et al. Association of smoking, alcohol consumption, blood pressure, body mass index, and glyce- mic risk factors with age-related macular degeneration: a mendelian randomization study. *JAMA Ophthalmol*. November 4, 2021. [Epub ahead of print].

VERONA
SUPREMA

In the WARMTH of the exam room

More often than not, we invest a majority of our money in the front end of our store, forgetting about the backend: **the most essential component of taking care of our patients.**

As time flies by, our exam rooms become outdated and old, full of scaring looking equipment. Make your patients feel at home with a more warm, modern, and comfortable exam room. By doing so, your patients will spread positive feedback to others, attracting more customers to your practice.

scan video



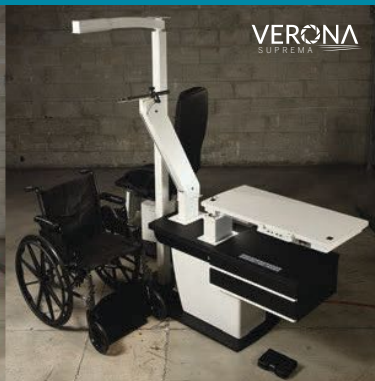**MAKE IT YOUR OWN AND PERSONALIZE YOUR UNIT
BY CHOOSING FROM A LARGE VARIETY OF FINE WOODS**



FIRENZE



VENEZIA



VERONA
SUPREMA



MILANO



USO
US OPHTHALMIC®

WWW.USOPHTHALMIC.COM.
PH: 1.888.881.1122
INFO@USOPHTHALMIC.COM
9990 NW 14TH STREET,
UNIT #105, DORAL,
FL 33172 | USA

Cataracts May Increase Vascular Mortality Risk

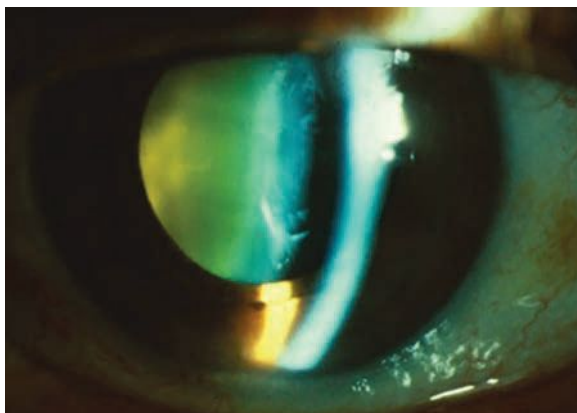Still, patients with this ocular condition didn't appear to be more likely to die from cancer, respiratory or renal disease or Alzheimer's, study finds.

Patients with cataracts may face up to a 36% increased risk of vascular mortality, according to a new study published in the *British Journal of Ophthalmology*. The investigation also found a positive association between self-reported cataract surgery and all-cause mortality based on a large-scale, population-centered sample.

A total of 14,918 participants were included in the study's analysis of National Health and Nutrition Examination Survey data from 1999 to 2008. A self-reported history of cataract surgery was considered a surrogate for the presence of clinically significant cataract surgery, and mortality data were verified from National Death Index records. After roughly 10 years, approximately 19% of the participants had died.

Overall, the researchers found that individuals with self-reported cataract surgery were more likely to die from all causes and specific causes (vascular disease, cancer, accident, Alzheimer's disease, respiratory disease, renal disease and others) compared with individuals without cataract. Still, no significant association was observed specifically between self-reported cataract surgery and cancer,

Photo: Julie Tyler, OD



Cataracts increase a patient's risk of vascular mortality.

respiratory disease, renal disease, Alzheimer's disease, accidents or other cause-related mortality.

There have been a few hypotheses explaining the association between cataract and vascular mortality, including oxidative stress, which has been implicated in the pathogenesis of both cataract and atherosclerosis, the study authors noted. Additionally, previous studies of human lens epithelial cells found that the senescence of lens cells, triggered by oxidative stress-induced DNA damage and telomere shortening, contributed to cataract formation.

Oxidative stress affects vascular reactivity and oxidized low-density

lipoproteins promote atherogenesis; therefore, the presence of cataract may be an indicator of high levels of cumulative oxidative damage resulting from physiological and pathological aging, the researchers explained in their report.

Another alternative hypothesis is that crystallins are also involved in regulating apoptosis,

cell survival and responses to stressors such as inflammation and ischemia, not only at an ocular level but also at a systemic level, they added.

The authors also found that participants of the study who had a history of bilateral cataract surgery were more than twice as likely to die from renal disease. A plausible mechanism linking cataract and renal disease-related mortality could be increased oxidative stress, which is implicated in both cataracts and chronic kidney disease, the investigators said. ◀

Chen Y, Wang W, Liao H, et al. Self-reported cataract surgery and 10-year all-cause and cause-specific mortality: findings from the National Health and Nutrition Examination Survey. *Br J Ophthalmol*. October 25, 2021. [Epub ahead of print].

IN BRIEF

Ten years ago, results were released from the Age-Related Eye Disease Study (AREDS), which concluded as one of its many findings that cataract surgery was not found to increase the risk of late age-related macular degeneration (AMD). Following its report of this first study, a research team analyzed data from AREDS2, a follow-up of AREDS, which included AMD patients in 82 clinics across the United States. **The analysis of**

the updated study detected no increased risk for late AMD in patients who underwent cataract surgery.

Included participants were 50 to 85 years old with bilateral large drusen or unilateral late AMD with up to 10 years of follow-up. Late AMD was characterized by the presence of geographic atrophy or neovascular AMD observed on fundus photography (or indicated in medical records).

A total of 1,767 eyes (1,195 participants) in the AREDS2 study had received cataract

surgery, and 1,981 eyes (1,524 participants) developed late AMD. Researchers found no association between cataract surgery and development of late AMD after performing Cox regression models, a matched-pairs analysis and logistic regression models.

"Of the matched pairs, **late AMD was identified in 412 eyes that received cataract surgery and in 433 phakic controls,** resulting in an odds ratio of 0.92," the researchers wrote in their paper. "The risk of late AMD after cataract surgery from the logistic

regression model was not statistically significant."

As the research continues to support, cataract surgery is not shown to increase the risk of late AMD in patients. **Presenting clinical data from studies such as this one to patients who are potential candidates for cataract surgery may help to ease any concern.**

Bhandari S, Vitale S, Agrón E, et al. The AREDS2 research group. cataract surgery and the risk of developing late age-related macular degeneration: the age-related eye disease study 2 report number 27. *Ophthalmology*. November 9, 2021. [Epub ahead of print].



Recapture lost revenue and give your mature patients the quality of life they desire.

Estimated

826 million

suffer from vision impairment caused by unaddressed presbyopia*

The number of people with presbyopia is projected to increase from 1.8 billion in 2015, to 2.1 billion in 2030*. With presbyopes living longer and engaging in more active lifestyles, contact lenses are an excellent choice, recreating youthful vision without the use of glasses.

X-Cel's portfolio of presbyopia contact lenses give patients the freedom, flexibility, and confidence they deserve. *From sclerals to corneal GPs and custom soft, we have your patients covered.*

Available in Paragon materials



Contact X-Cel Specialty Contacts to learn more.
800.241.9312 | xcelfinfo@xcelspecialtycontacts.com

COVID-19 Can Cause Corneal Neuropathy

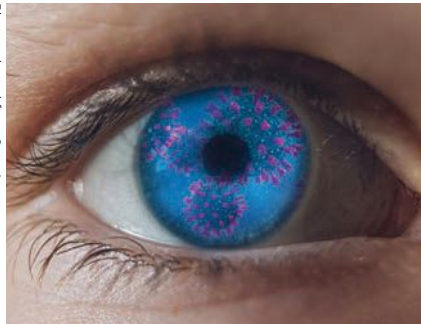
This infection shares similar symptomatology and morphological landmarks of dry eye disease and diabetic neuropathy, study finds.

C COVID-19 patients' corneas resemble those of DED and diabetic patients, a recent study revealed.

To date, there has been no published evidence of sensory alterations in the cornea after Sars-CoV-2 virus infection. Researchers in Spain recently used in vivo confocal microscopy (IVCM) to evaluate the morphological changes in the sensory subbasal plexus of the cornea after Sars-CoV-2 infection. They discovered that morphological alterations in corneas of COVID-19 patients are similar to those in diabetic corneas and dry eye disease (DED) and are accompanied by functional loss and alteration in sensitivity.

The observational, retrospective study recruited 23 patients who had overcome COVID-19. The control group consisted of 46 uninfected volunteers. The researchers used IVCM to obtain images of corneal subbasal nerve fibers and study the presence of neuroma-like structures, axonal beadings and dendritic cells. The study used the Ocular Surface Disease Index (OSDI) questionnaire and Schirmer tear test as indicators of DED and ocular surface pathology.

Photo: adapted from Getty Images



Neuroma-like findings were present in the corneal subbasal nerve fibers.

The researchers found alterations of the corneal subbasal plexus and corneal tissue consistent with small fiber neuropathy in 21 patients (91.3%). Eight patients reported increased sensation of ocular dryness after COVID-19 infection and had positive DED indicators. The study also found beaded axons in 82.6% of cases, mainly in patients reporting ocular irritation.

Neuroma-like images were found in 65.2% patients, more frequently in those with OSDI scores greater than 13. Dendritic cells were found in 69.6% of patients and were more frequent in younger asymptomatic patients. The researchers believe the presence of morphological alterations in patients

up to 10 months after recovering from Sars-CoV-2 infection points to the chronic nature of the neuropathy.

“Our results demonstrate morphological changes in subbasal nerves of the COVID-19 group associated with the generation of DED symptoms,” the researchers wrote. “The severity of morphological changes was related with worsening of DED symptoms: discomfort, irritation and mild pain.”

Another finding: “Our study showed high coincidence between the presence of neuromas at IVCM examination and loss of smell during Sars-CoV-2 infection. While all patients reporting anosmia recovered total olfactory functionality, corneal morphological changes remained at least the time elapsed between infection and ophthalmological exam,” they reported.

The researchers also concluded that their results add new evidence for the use of IVCM technology in the diagnosis and follow-up COVID-19 and associated complications, as well as in the study of small fiber neuropathies. ◀

Barros A, Queiruga-Piñeiro J, Lozano-Sanroma J, et al. Small fiber neuropathy in the cornea of Covid-19 patients associated with the generation of ocular surface disease. *Ocul Surf.* 2021;23:40-4.

IN BRIEF

The data is sparse to guide clinical management of primary angle-closure suspect (PACS), with no quantitative method to identify high-risk patients. However, researchers believe **anterior segment OCT measurements of angle width and iris curvature are predictive of progression, whereas gonioscopy grades are not.**

A team recently used data from the Zhongshan Angle Closure Prevention (ZAP) trial to assess biometric risk factors for progression from PACS to primary angle-clo-

sure (PAC) or acute angle-closure (AAC) and to develop statistical models that could help stratify patients with early angle-closure at risk for more severe disease.

The investigators analyzed 643 mainland Chinese patients with PACS (609 nonprogressors, 34 progressors). PACS was defined as an inability to visualize pigmented trabecular meshwork in two or more quadrants based on static gonioscopy. PAC itself was defined as development of intraocular pressure above 24mm Hg or peripheral anterior synechiae. Progression was defined as development of PAC or an AAC attack.

The researchers then determined the odds ratio (OR) for various patient characteristics. They found that **narrower horizontal angle-opening distance of 500µm from the scleral spur** (OR: 1.10 per 0.01mm decrease), **flatter horizontal iris curvature** (OR: 1.96 per 0.1mm decrease), **older age** (OR: 1.11 per one-year increase) and **iris curvature** (OR: 2.48) were significantly associated with progression.

Gonioscopy scores, however, were not predictive of progression. The researchers noted that OCT measurements of biometric parameters could help identify pa-

tients with early angle-closure who are at higher risk of progression to more severe disease.

“AS-OCT measurements may provide a more clinically useful measure of angle width than gonioscopy grades, at least for predicting progression from PACS to PAC or AAC, and disagreements between the two could reflect inherent limitations of gonioscopy for evaluating eyes with PAC disease,” the researchers concluded.

Xu BY, Friedman DS, Foster PJ, et al. Ocular biometric risk factors for progression of primary angle closure disease. *Ophthalmology.* October 8, 2021. [Epub ahead of print].



DON'T WAIT FOR TOO LATE

When pressure builds, surgery isn't usually the first step in treating patients with mild to moderate glaucoma. But **minimally invasive glaucoma surgery (MIGS)** might be the best option for both your cataract and post-cataract surgery glaucoma patients.

Often more effective than drops and less invasive than traditional surgery, MIGS may be a treatment option worth considering sooner.

Keep Glaucoma In The Deep
ConsiderMIGSEarly.com

Amer. Indian, Alaskan Natives Have Higher DR Rate

Roughly 29% of these individuals had the condition, with older age, male gender and geographic location appearing to be risk factors, research shows.

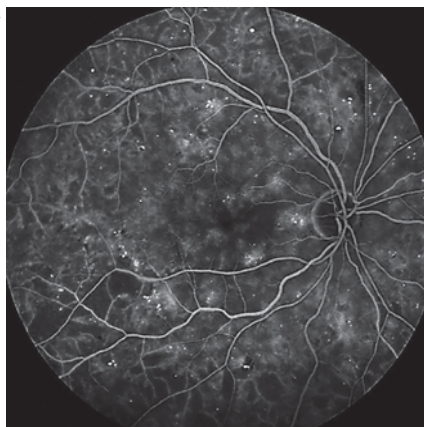
Individuals who are American Indian or Alaskan natives may have a higher burden of diabetes and complications from the condition than any other race/ethnic group in the US, according to a new study in *Ophthalmic Epidemiology*. The investigation also reported that ultra-widefield imaging is a good tool to detect early diabetic retinopathy (DR) in these patients.

The research paper—a retrospective analysis of 53,900 patients who were examined with ultra-widefield imaging—investigated the prevalence of DR and diabetic macular edema (DME) in American Indian and Alaskan natives served by the Indian Health Services’ (IHS) teleophthalmology program. Patients were approximately 56 years old with an A1c of 68mmol/mol, and slightly more than half had diabetes for at least five years.

Prevalence of “any DR” was found in 29% of the participants, while presence of “any DME” or sight-threatening disease was detected in 3%.

In patients with mild non-proliferative DR, predominant peripheral lesions were seen about 25% of the time, with these lesions suggesting a more severe level of DR in about 9% of subjects.

Photo: Jay M. Haynie, OD



Ultra-widefield imaging is an effective method of detecting DR in patients such as American Indian and Alaskan natives who are at higher risk.

Additionally, a patient’s age, gender and geographic location appeared to factor into disease rates. Both DR and DME cases increased with age, while males and individuals in the Nashville IHS area had more diabetic eye disease.

Despite the high case rate in Nashville, there are fewer IHS clinics there compared with other regions. This implies that Nashville area clinics need to focus on more surveillance of diabetic eye conditions, education and recruitment of eye care special-

ists to mitigate significant disease, the investigators suggested.

The study’s findings may have policy implications for the IHS, since its budget is less than other federal programs, yet the diabetes burden is higher for American Indian and Alaskan natives than other race/ethnic groups in the country, the researchers said.

“Also, the location of IHS ambulatory care facilities in rural areas means access to specialty care is difficult for many patients. Thus, accurate and current measures of disease, including diabetic eye disease, are critical for planning the allocation of limited resources and for IHS budget justifications to Congress,” the study authors wrote in their paper.

The updated prevalence estimates reported in the study show that diabetic eye disease is lower than in previous decades, but the burden is still substantial to American Indian and Alaskan natives served by the IHS, they added. ◀

Fonda SJ, Bursell SE, Lewis DG, et al. Prevalence of diabetic eye diseases in American Indians and Alaska natives (AI/AN) as identified by the Indian Health Service’s national teleophthalmology program using ultrawide field imaging (UWFI). *Ophthalmic Epidemiol.* November 2, 2021. [Epub ahead of print].

IN BRIEF

Research has suggested a **link between AMD and several systemic health issues, including cardiovascular, cerebrovascular and chronic kidney diseases, in addition to diabetes, hypertension, dyslipidemia and neurodegenerative disorders.** Looking into whether systemic meds may contribute to this sight-threatening condition, a team of investigators from Finland found that the use of second-generation calcium channel blockers—which are typically used to treat high

blood pressure—appeared to be tied to an increased risk of wet AMD. Based on the study’s findings, the authors reported that **individuals with hypertension may be predisposed to develop wet AMD.**

On the other hand, patients who took the blood pressure-lowering drug ramipril or digoxin—a medication that works to prevent congestive heart failure and arrhythmias—seemed to be less likely to develop the eye disease.

The retrospective study included roughly 260,000 individuals who received care from 2001

to 2017. Half the participants had diabetes, while the other half were healthy controls. The study analyzed the potential association between 85 generic systemic drugs and incidence of wet AMD.

At the investigation’s 10-year follow-up, approximately **2,960 participants had developed wet AMD, and the incidence rate was 1.15 per 1,000 persons/year.** The authors also observed an increased AMD risk in patients exposed to calcium channel blockers amlodipine (internal rate of return: 1.33) and felodipine (1.24). Similarly, bicalutamide

(2.14), estradiol (1.20) and atorvastatin (1.22) were all linked to higher AMD risk, while digoxin and ramipril were linked to a lower incidence of wet AMD (0.75 and 0.80, respectively).

Investigators suggest a **renin-angiotensin system blocker, such as an angiotensin-converting enzyme inhibitor or an angiotensin receptor blocker, which can normalize hydrostatic pressure by causing postcapillary dilation.**

Loukovaara S, Auvinen A, Haukka J. Associations between systemic medications and development of wet age-related macular degeneration. *Acta Ophthalmologica.* November 14, 2021. [Epub ahead of print].

MyDay®
daily disposable
multifocal

OptiExpert™
Contact Lens
Calculator

Hey, presbyopia. Meet your match.

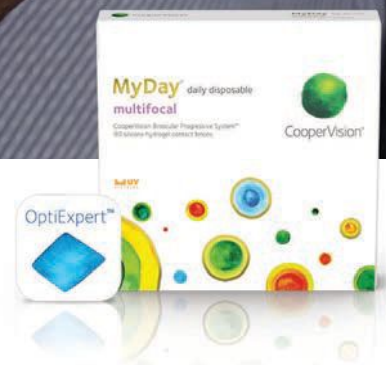Josh Rajasansi, OD
Experts on Sight | Gilbert, AZ



The ultimate play to defeat presbyopia has finally arrived—and it's the winning move to keep your presbyopic patients in contact lenses. MyDay® multifocal is a silicone hydrogel 1-day multifocal contact lens that is patient-preferred over DAILIES TOTAL1® Multifocal for vision¹ and comfort.² Plus, successfully fit 98% of patients with two pairs of lenses or fewer when following the fit guide or OptiExpert™ app.³ It's the game changer you've been waiting for.

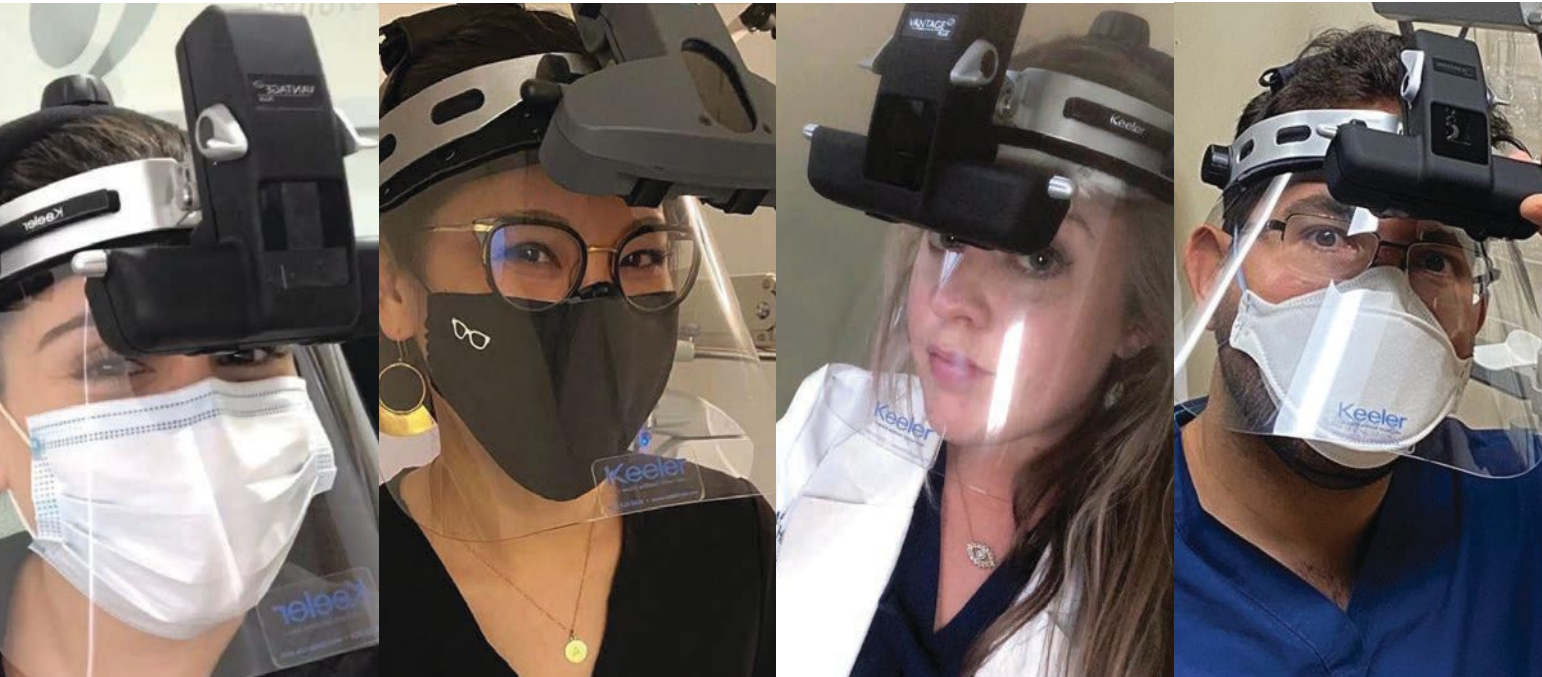Prescribe MyDay® multifocal to your presbyopic patients and help them see like they used to.

Game on, presbyopia.



1. 3.5 times more patients preferred MyDay® multifocal for overall vision clarity than with DAILIES TOTAL1® Multifocal. Strongly prefer/slight prefer MyDay® multifocal 58.6%, DAILIES TOTAL1® Multifocal 17.2%, no preference 24.1%; p=0.002. For statistical analysis, "no preference" response evenly distributed between two products.] [REF: CVI data on file 2021. Prospective, subject-masked, randomized, bilateral, two-week cross-over dispensing study at 5 US sites with MyDay® multifocal and DAILIES TOTAL1® Multifocal; n=58 habitual multifocal contact lens wearers. 2. CVI data on file 2021. Prospective, subject-masked, randomized, bilateral, two-week cross-over dispensing study at 5 US sites with MyDay® multifocal and DAILIES TOTAL1® Multifocal; n=58 habitual multifocal contact lens wearers. 3. CVI data on file 2020. Prospective, double-masked, bilateral, one-week dispensing study UK with MyDay® multifocal; n=104 habitual multifocal contact lens wearers; CVI data on file 2021. Prospective, subject-masked, randomized, bilateral, two-week dispensing study at 5 US sites with MyDay® multifocal; n=58 habitual multifocal contact lens wearers. 11082A

Helping Heroes See Clear And Stay Safe



The Vantage BIO is great for ROP screening! It's lightweight, has settings for different pupil sizes, a cool, white LED light and the longest battery ever!!"

Dr. Paulina Ramirez Neria



I'm a big fan of the All Pupil BIO. I had issues with other models so when I started [my practice], I knew the All Pupil would be my go-to BIO...I greatly appreciate the new custom fit Keeler BIO shields as an added safety layer."

Dr. Annie Bacon



I chose my [Vantage Plus] for the optics and value...with other brands, I had difficulty focusing up close during my dilated fundus exams. [The oculars] made my eyes feel more relaxed, and I felt like my view was better."

Dr. Michelle Hammond



[I've] been seeing emergent and urgent cases every day during the COVID19 pandemic. I really like [the Vantage BIO] because [it's a] very good quality and provides a super clear view."

Dr. Reza Moradi

Choose option #1 or #2 below when you purchase (or lease) a BIO*
(Expires December 31, 2021)

*Valid for wireless indirects: Vantage Plus and/or All Pupil II

1



RECEIVE A

\$850

credit towards any PPE

2

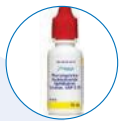24-MONTH

0%

lease as low as \$128/month*

*All Pupil II: \$127.92/month; Vantage Plus: \$155/month (shipping and taxes not included).

3



RECEIVE

10 FREE

bottles of phenylephrine
2.5%, 15mL

***If you lease the BIO, you may also choose the PPE credit OR the phenylephrine option.**

Contact us at 800-523-5620 or customerservice@keelerusa.com to learn more or place your order. This promo cannot be combined with any other Keeler offers.

Keeler
— A world without vision loss —

www.keelerusa.com • 3222 Phoenixville Pike - Bldg. #50 • Malvern, PA 19355
Tel No: 1-610-353-4350 • Toll Free: 1-800-523-5620 • Fax: 1-610-353-7814


A Halma company

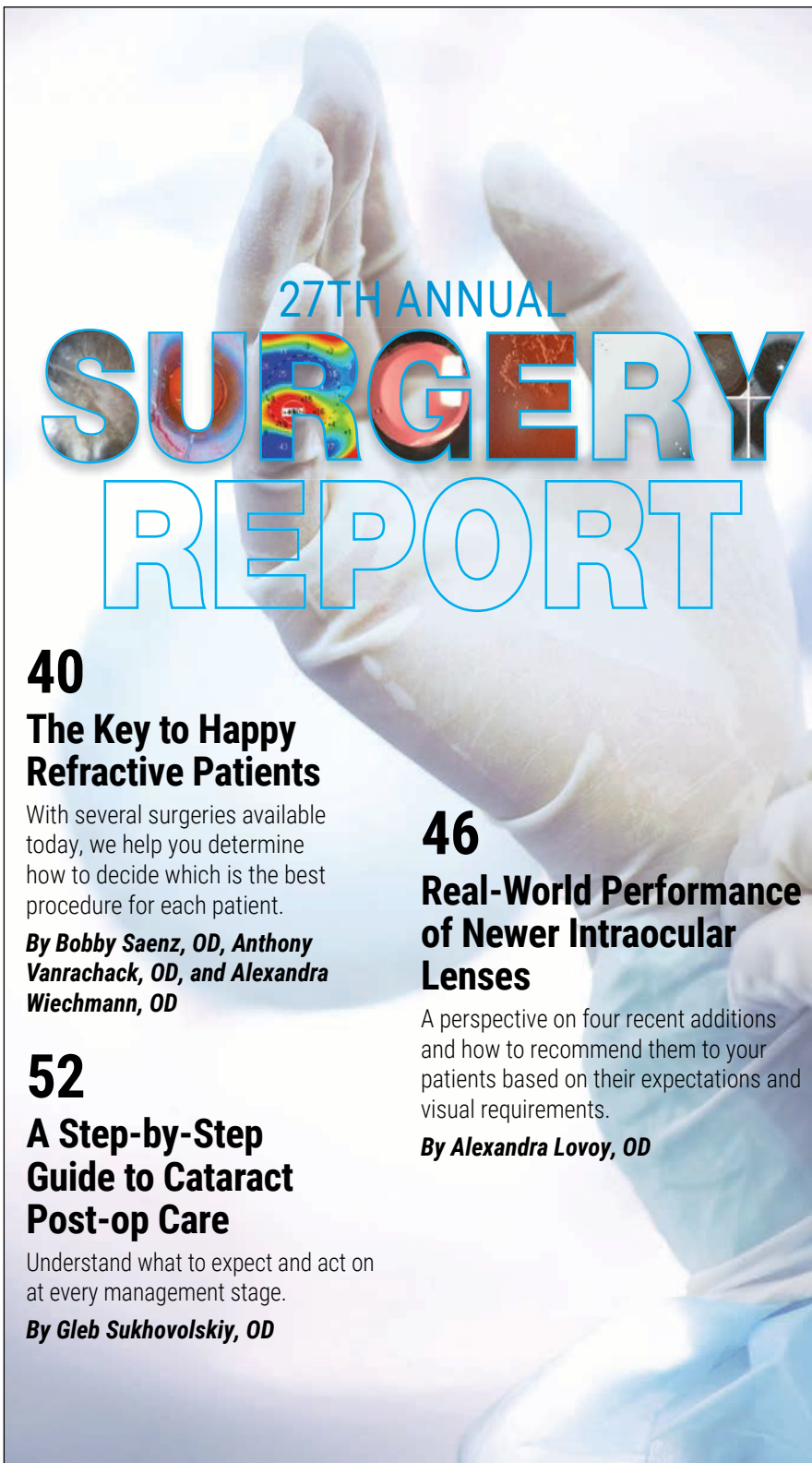FEATURES

REVIEW OF OPTOMETRY • Vol. 158, No. 12 • DECEMBER 15, 2021



CATCH UP ON THE LATEST NEWS

- ▶ Stories post online every weekday
- ▶ Weekly recap emailed every Sunday



27TH ANNUAL

SURGERY REPORT

40

The Key to Happy Refractive Patients

With several surgeries available today, we help you determine how to decide which is the best procedure for each patient.

By Bobby Saenz, OD, Anthony Vanrachack, OD, and Alexandra Wiechmann, OD

52

A Step-by-Step Guide to Cataract Post-op Care

Understand what to expect and act on at every management stage.

By Gleb Sukhovolskiy, OD

46

Real-World Performance of Newer Intraocular Lenses

A perspective on four recent additions and how to recommend them to your patients based on their expectations and visual requirements.

By Alexandra Lovoy, OD

34

2021 Income: Back on the Playing Field

COVID-19 is here to stay, but optometry made significant financial strides this year to show it's not going anywhere either.

By Catherine Manthorp, Senior Associate Editor

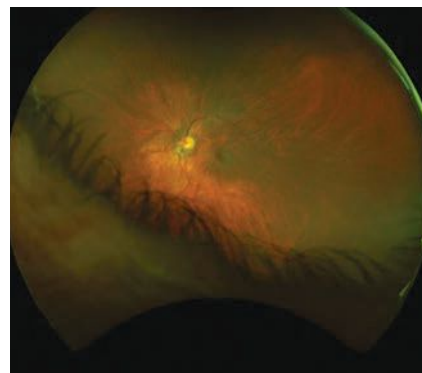


56

Plaqueul Toxicity: How to Avoid This Bullseye

Learn the clinical indicators, risk factors and screening guidelines to properly monitor for this irreversible, rare condition in patients on this drug.

By Luanne Chubb, OD



DEPARTMENTS

REVIEW OF OPTOMETRY • DECEMBER 15, 2021



VISIT US ON SOCIAL MEDIA

Facebook: www.facebook.com/revoptom

Twitter: twitter.com/revoptom

Instagram: www.instagram.com/revoptom

5

NEWS REVIEW

22

OUTLOOK

Back to Where You Once Belonged

The pandemic took its toll, financially and otherwise, but the profession is rebounding.

Jack Persico, Editor-in-Chief

24

THROUGH MY EYES

Prepare for Presbyopia

Get to know the first drug to improve near vision.

Paul M. Karpecki, OD

26

CHAIRSIDE

Hierarchy of Emotions

There are six major ones, but happiness ranks first.

Montgomery Vickers, OD

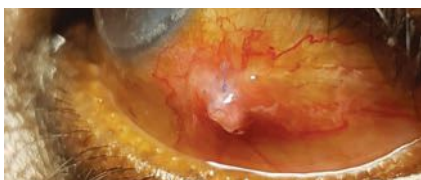
28

CLINICAL QUANDARIES

Keep it PG

These growths are often easily managed.

Paul C. Ajamian, OD



30

CODING CONNECTION

It's a Wrap

Prepare your practice for an exciting New Year.

John Rumpakis, OD, MBA

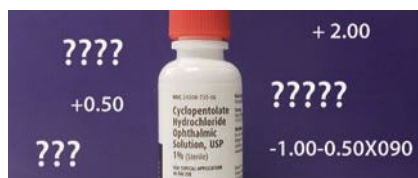32

FOCUS ON REFRACTION

Less is Not More

One fundamental of prescribing involves using all of your data points, not limiting yourself to one.

Marc B. Taub, OD, MS, and Paul Harris, OD



64

CORNEA AND CONTACT LENS Q+A

Step Up to LK

There are several treatment options for lipid keratopathy, some of which achieve better results than others.

Joseph P. Shovlin, OD

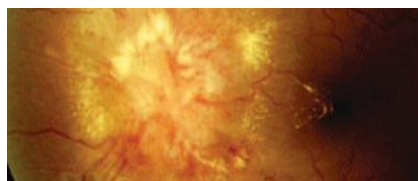
66

THERAPEUTIC REVIEW

The Bite of Something Wild

Anticipating a good outcome in cat scratch disease might require prompt treatment.

Joseph W. Sowka, OD



68

OCULAR SURFACE REVIEW

Neurological DED

Management in Action

Promising new treatments consider a different route to alleviation of symptoms.

Paul M. Karpecki, OD, and Diana Driscoll, OD

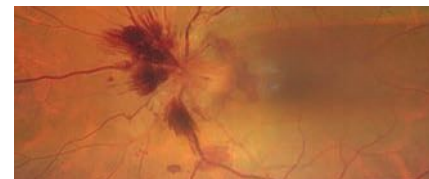
72

RETINA QUIZ

Stop the Swelling

A complex condition is the culprit.

Mark Dunbar, OD



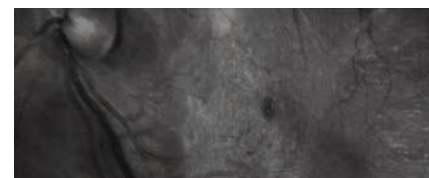74

GLAUCOMA GRAND ROUNDS

The Specialists of Eye Care

It's up to us to manage the global ocular health of our patients, even when other providers are involved, too.

James L. Fanelli, OD



78

SURGICAL MINUTE

On the Bubble

Silicone vitrectomy helps save eyes with severe trauma.

**Derek N. Cunningham, OD,
and Walter O. Whitley, OD, MBA**

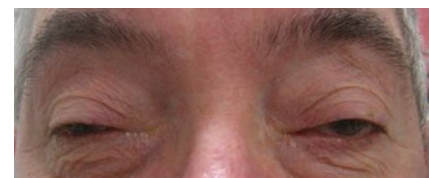82

DIAGNOSTIC QUIZ

Nothing's Up

What could this case of prominent ptosis signify?

Andrew S. Gurwood, OD



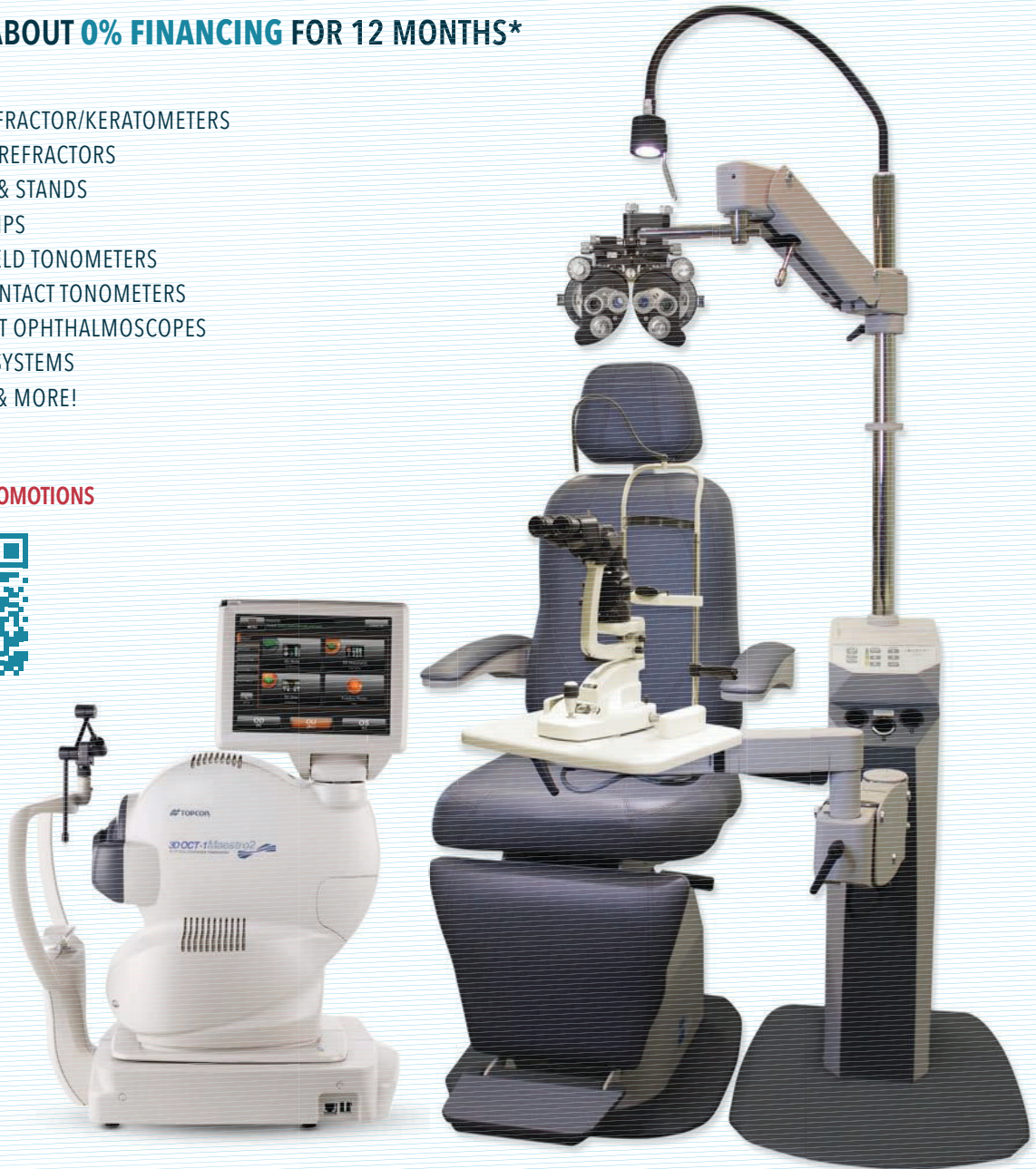MAJOR SAVINGS ON EQUIPMENT WITH OUR YEAR-END PROMOTIONS!

PLUS take advantage of your section 179 tax deduction by ordering before Dec. 31, 2021.

ASK US ABOUT 0% FINANCING FOR 12 MONTHS*

- OCTS
- AUTOREFRACTOR/KERATOMETERS
- DIGITAL REFRACTORS
- CHARIS & STANDS
- SLIT LAMPS
- HANDHELD TONOMETERS
- NON-CONTACT TONOMETERS
- INDIRECT OPHTHALMOSCOPES
- ACUITY SYSTEMS
- LASERS & MORE!

VIEW ALL PROMOTIONS



**HAAG-STREIT • HEINE • KEELER • MARCO • REICHERT • RELIANCE
S4OPTIK • TOPCON • WELCH-ALLYN • ZIESS & MORE**

*Subject to credit approval and documentation. Eligible for equipment purchases over \$5,000. Orders must be received and shipped by December 31, 2021. Consult your tax advisor for details regarding Section 179 tax deductions.

CLINICAL EDITORS

CHIEF CLINICAL EDITOR ~ PAUL M. KARPECKI, OD

ASSOCIATE CLINICAL EDITORS ~ JOSEPH P. SHOVLIN, OD, CHRISTINE SINDT, OD

CONTRIBUTING EDITORS

PAUL C. AJAMIAN, OD, ATLANTA, GA

ALISON BOZUNG, OD, MIAMI, FL

DEREK N. CUNNINGHAM, OD, AUSTIN, TX

MARK T. DUNBAR, OD, MIAMI, FL

JAMES L. FANELLI, OD, WILMINGTON, NC

ANDREW S. GURWOOD, OD, PHILADELPHIA, PA

PAUL HARRIS, OD, MEMPHIS, TN

PAUL M. KARPECKI, OD, LEXINGTON, KY

BISANT LABIB, OD, ELKINS PARK, PA

JOHN RUMPAKIS, OD, MBA, PORTLAND, OR

JOSEPH P. SHOVLIN, OD, SCRANTON, PA

JOSEPH W. SOWKA, OD, FORT LAUDERDALE, FL

MARC TAUB, OD, MEMPHIS, TN

MONTGOMERY VICKERS, OD, DALLAS, TX

WALTER O. WHITLEY, OD, MBA, VIRGINIA BEACH, VA

EDITORIAL ADVISORY BOARD

JEFFREY R. ANSHEL, OD, ENCINITAS, CALIF.

JILL AUTRY, OD, RPH, HOUSTON

SHERRY J. BASS, OD, NEW YORK

EDWARD S. BENNETT, OD, ST. LOUIS

MARC R. BLOOMENSTEIN, OD, SCOTTSDALE, ARIZ.

ALISON BOZUNG, OD, MIAMI, FL

AARON BRONNER, OD, KENNEWICK, WASH.

MILE BRUJIC, OD, BOWLING GREEN, OHIO

CHRIS J. CAKANAC, OD, MURRYSVILLE, PA

JERRY CAVALLERANO, OD, PhD, BOSTON

WALTER L. CHOATE, OD, MADISON, TENN.

BRIAN CHOU, OD, SAN DIEGO

MICHAEL CHAGLASIAN, OD, CHICAGO

A. PAUL CHOUS, MA, OD, TACOMA, WASH.

GLENN S. CORBIN, OD, WYOMISSING, PA

MICHAEL DELGIODICE, OD, CLIFTON, NJ

ANTHONY S. DIECIDUE, OD, STROUDSBURG, PA

S. BARRY EIDEN, OD, DEERFIELD, ILL.

ARTHUR B. EPSTEIN, OD, PHOENIX

STEVEN FERRUCCI, OD, SEPULVEDA, CALIF.

MURRAY FINGERET, OD, HEWLETT, NY

IAN BEN GADDIE, OD, LOUISVILLE, KY

GARY S. GERBER, OD, HAWTHORNE, NJ

PAUL HARRIS, OD, MEMPHIS, TENN.

MILTON HOM, OD, AZUSA, CALIF.

DAVID KADING, OD, SEATTLE

JEROME A. LEGERTON, OD, MBA, SAN DIEGO

THOMAS L. LEWIS, OD, PhD, PHILADELPHIA

BLAIR B. LONSBERRY, MS, OD, MED, PORTLAND, ORE.

DOMINICK MAINO, OD, MED, CHICAGO

KELLY A. MALLOY, OD, PHILADELPHIA

DANICA MARRELLI, OD, HOUSTON, TEX.

RON MELTON, OD, CHARLOTTE, NC

PAMELA J. MILLER, OD, JD, HIGHLAND, CALIF.

BRUCE MUCHNICK, OD, COATESVILLE, PA

MARC MYERS, OD, COATESVILLE, PA

CARLO J. PELINO, OD, JENKINTOWN, PA

JOSEPH PIZZIMENTI, OD, FORT LAUDERDALE, FLA.

CHRISTOPHER J. QUINN, OD, ISELIN, NJ

MICHAEL C. RADOIU, OD, STAUNTON, VA

MOHAMMAD RAFIETARY, OD, MEMPHIS, TENN.

JOHN L. SCHACHET, OD, ENGLEWOOD, COLO.

JACK SCHAEFFER, OD, BIRMINGHAM, ALA.

LEO P. SEMES, OD, BIRMINGHAM, ALA.

DIANA L. SHECHTMAN, OD, FORT LAUDERDALE, FLA.

JEROME SHERMAN, OD, NEW YORK, NY

LEONID SKORIN, JR., OD, DO, ROCHESTER, MINN.

JOSEPH W. SOWKA, OD, FORT LAUDERDALE, FLA.

BRAD M. SUTTON, OD, INDIANAPOLIS

LORETTA B. SZCZOTKA, OD, PhD, CLEVELAND

MARC TAUB, OD, MEMPHIS, TENN.

TAMMY P. THAN, MS, OD, BIRMINGHAM, ALA.

RANDALL THOMAS, OD, CONCORD, NC

SARA WEIDMAYER, OD, ANN ARBOR, MICH.

KAREN YEUNG, OD, LOS ANGELES



Business Offices

19 Campus Boulevard, Suite 101
Newtown Square, PA 19073
Subscription inquiries (877) 529-1746 (USA only)
outside USA, call (847) 763-9630

PUBLISHER

MICHAEL HOSTER

(610) 492-1028

mhoster@jobson.com

EXECUTIVE DIRECTOR

JAMES HENNE

(610) 492-1017

jhenne@jobson.com

SENIOR MANAGER, STRATEGIC ACCOUNTS

MICHELE BARRETT

(610) 492-1014

mbarrett@jobson.com

REGIONAL SALES MANAGER

JONATHAN DARDINE

(610) 492-1030

jdardine@jobson.com

PRODUCTION MANAGER

FARRAH APONTE

212-274-7057 faponte@Jobson.com

PRODUCTION MANAGER

KAREN LALLONE

(610) 492-1010 klallone@Jobson.com

CLASSIFIED ADVERTISING

(888)-498-1460

SUBSCRIPTIONS

\$63 PER YEAR, \$99 (US) IN CANADA,
\$158 (US) IN ALL OTHER COUNTRIES
revoptometry@cambeywest.com

CIRCULATION

PO BOX 71, CONGERS, NY 10920-0071

(877) 529-1746

OUTSIDE USA: (845) 267-3065

SENIOR CIRCULATION MANAGER

HAMILTON MAHER

(212) 219-7870

hmaher@jhihealth.com

CEO, INFORMATION GROUP SERVICES

MARC FERRARA

SENIOR VICE PRESIDENT, OPERATIONS

JEFF LEVITZ

VICE PRESIDENT, HUMAN RESOURCES

TAMMY GARCIA

VICE PRESIDENT, CREATIVE SERVICES & PRODUCTION

MONICA TETTAMAZI

CORPORATE PRODUCTION DIRECTOR

JOHN ANTHONY CAGGIANO

VICE PRESIDENT, CIRCULATION

JARED SONNERS

Jobson Health Information/WebMD
395 Hudson Street, 3rd Floor, New York, NY 10014

**YOU
PRESCRIBE
OUR TORIC
SO MUCH,
WE MADE IT
TWICE.**



The same optical design features of Biofinity® toric, the # 1 most prescribed toric contact lens in the US¹, are replicated in MyDay® toric.

With lenses available to prescribe in a monthly and a daily disposable,

IT'S TORIC 2 WAYS.

COOPERVISION.COM/TORIC

Founded 1891
Founding Editor, Frederick Boger

EDITOR-IN-CHIEF
JACK PERSICO
(610) 492-1006 • jpersico@jobson.com

SENIOR EDITOR
JULIE SHANNON
(610) 492-1005 • jshannon@jobson.com

SENIOR ASSOCIATE EDITOR
CATHERINE MANTHROP
(610) 492-1043 • cmanthorp@jobson.com

SENIOR ASSOCIATE EDITOR
MARK DE LEON
(610) 492-1021 • mdeleon@jobson.com

ASSOCIATE EDITOR
LEANNE SPIEGLE
(610) 492-1026 • lspiegle@jobson.com

SPECIAL PROJECTS MANAGER
JILL GALLAGHER
(610) 492-1037 • jgallagher@jobson.com

SENIOR ART DIRECTOR
JARED ARAUJO
(610) 492-1032 • jaraujo@jobson.com

DIRECTOR OF CE ADMINISTRATION
REGINA COMBS
(212) 274-7160 • rcombs@jobson.com

Clinical Editors

Chief Clinical Editor • Paul M. Karpecki, OD

Associate Clinical Editors
Joseph P. Showlin, OD, Christine W. Sindt, OD

Clinical & Education Conference Advisor
Paul M. Karpecki, OD

Case Reports Coordinator • Andrew S. Gurwood, OD

Clinical Coding Editor • John Rumpakis, OD, MBA

Columnists

Chairside – Montgomery Vickers, OD

Clinical Quandaries – Paul C. Ajamian, OD

Coding Connection – John Rumpakis, OD

Cornea and Contact Lens Q+A – Joseph P. Showlin, OD

Diagnostic Quiz – Andrew S. Gurwood, OD

The Essentials – Bisant A. Labib, OD

Focus on Refraction – Marc Taub, OD, Paul Harris, OD

Glaucoma Grand Rounds – James L. Fanelli, OD

Ocular Surface Review – Paul M. Karpecki, OD

Retina Quiz – Mark T. Dunbar, OD

Surgical Minute – Derek Cunningham, OD, Walter Whitley, OD

Therapeutic Review – Joseph W. Sowka, OD

Through My Eyes – Paul M. Karpecki, OD

Urgent Care – Alison Bozung, OD

Editorial Offices

19 Campus Blvd., Suite 101 • Newtown Square, PA 19073



Jobson Medical Information/WebMD
395 Hudson Street, 3rd Floor, New York, NY 10014

Subscription inquiries: (877) 529-1746
Continuing Education inquiries: (800) 825-4696

Printed in USA



BY JACK PERSICO
EDITOR-IN-CHIEF
OUTLOOK

Back to Where You Once Belonged

The pandemic took its toll, financially and in countless other ways, but the profession is rebounding.

Fans of classic rock—and dysfunctional interpersonal dynamics—spent our post-Thanksgiving time peering into the inner workings of late-era Beatles in the eight-hour documentary *Get Back*, watching the band stagger in fits and starts toward their final concert and penultimate album. Though it may be a time capsule from half a century ago, the shambolic proceedings seem the perfect counterpart to pandemic life, too. We see the bandmates flourishing creatively one moment, bickering and bored the next. Throughout, there's a pervasive sense that something that once held them together has been lost, something they're trying to... well, get back.

Much of 2021 was consumed the world over by a desire to “get back” to pre-pandemic life, personally and professionally. At least within optometry, there are clear signs that's happening.

This issue's annual income survey shows that earnings bounced back from the low-water mark of 2020, as average income jumped from \$160,000 last year to over \$180,000 in 2021. As always, ODs who are self-employed fared the best, with an average income of nearly \$250,000. Employed optometrists were down around \$139,000, but still up from their 2020 numbers.

Encouragingly for a profession that is now majority female, the gender gap looks to be narrowing. In 2020, there was an abysmal 47% imbalance between the incomes of male and female optometrists. In 2021, that shrank to just 14%. The gains for women

ODs showed up across the board, too, regardless of years of experience. And in perhaps a sign of things to come, female optometrists in the 11-20 years bracket actually out-earned their male counterparts, the first time such a finding showed up in our survey.

Furthermore, a solid majority (70%) of everyone who replied felt satisfied with their 2021 earnings, and 68% expect their income to increase in 2022.

Another positive signal of optometry's recovery is the much more robust plans for continuing education we saw while compiling this year's *Conference Planner* supplement, a compendium of upcoming CE events we publish each December. There are over 260 meetings planned for 2022, and the vast majority will happen in person (some with a streaming component, too).

Despite new worries about COVID and intractable problems elsewhere in society, things are definitely looking up.

In the end, the Beatles never really got back the mojo that suffused their early, firing-on-all-cylinders days. But optometry at the tail end of 2021 has all the makings of a profession about to come roaring back. As the band themselves would say: I've got a feeling.

On a positive note for us, we're excited to announce that Alison Bozung, OD, a rising star at Bascom Palmer and in the profession, has joined the *Review* editorial board. She'll take over the Urgent Care column next month and will also make important contributions to our content development process. ■

Chill out your patients



regenereyes.com | 877-206-0706

© 2021 Regener-Eyes®, All rights reserved





BY PAUL M. KARPECKI, OD
CHIEF CLINICAL EDITOR

THROUGH MY EYES

Prepare for Presbyopia

Get to know the first FDA-approved drug to improve near vision.

Of the 128 million Americans between the ages of 40 and 70, about 70% report wearing some sort of vision correction, and the vast majority have issues with current presbyopia-correcting options. One reason is that we can't yet restore natural accommodation, so proper expectations must be set. There are numerous effective options, including spectacles, contact lenses, surgical procedures and, now, therapeutic agents.

Presbyopes are growing at 10 times the rate of the pre-presbyopic population. The typical patient's frustration concerns how presbyopia interferes with everyday activities such as shopping, texting and reading a menu. Comments in surveys state that reading glasses are inconvenient, embarrassing and make wearers feel old.

Knowing their motivation, understanding this population and educating them on why they are losing their near vision (without getting into every scientific detail) will increase your success in presbyopia management.

Components of Accommodation

Recall the triad that occurs with accommodation: convergence, pupil constriction and lens flexure. This becomes the model of what you need to measure in presbyopic patients.

Binocular function is extremely important. Patients with convergence insufficiency (CI) tend to develop presbyopia earlier and may do better with certain spectacles but not others. For example, patients with digital eye-strain from prolonged device use but also exophoria with CI may not do as

well with progressive lenses unless the minor eye misalignment is corrected first. Consider brushing up on binocular vision testing or purchasing a Neuro-lens diagnostic device.

“
Vuity is 1.25% pilocarpine in a formulation that the manufacturer says will allow the acidic pH to quickly equilibrate once placed in the eye to minimize discomfort.
”

Pupil testing is critical, as many significant conditions ranging from Horner's syndrome to glaucoma can be determined this way. Obtaining a good baseline with a device such as the EyeKinetix (Konan Medical) will not only uncover potential issues related to the pupil using miotic agents but could also anticipate why a patient—*e.g.*, one whose pupils don't constrict enough—might fail with therapeutic drops.

Finally, an effective fundus exam that includes the peripheral retina should be documented before prescribing presbyopia drops. Some new technologies like confocal retinal imaging (iCare DRSplus/Eidon) may allow for more realistic color reproduction.

Endless Options

Surgically, the best options focus on the lens—why treat the cornea when the lens is the problem? The most recent trifocal and extended depth of focus IOLs have improved results, with less night vision disturbances. The Light Adjustable Lens (RxSight) has the abil-

ity to adjust the lens power after surgery, increasing accuracy and allowing more patients to succeed with blended vision options.

Newer presbyopic contact lens materials that maintain 95% of their water content after 16 hours of wear (Bausch + Lomb Ultra for Presbyopia) may greatly help those that experience concomitant dry eye issues.

Newly FDA-approved Vuity (Allergan) is 1.25% pilocarpine in a formulation that the manufacturer says will allow the acidic pH to quickly equilibrate once placed in the eye to minimize discomfort. In clinical studies, a statistically greater number of treated patients achieved three lines of distance-corrected near vision compared to placebo. The pivotal study showed the drug effect peaked after one hour, when 37.3% of patients in the pilocarpine group achieved three lines of reading compared to 12.1% of those on vehicle. The effects declined over time, with 16.3% in the pilocarpine group and 9.9% in the placebo group achieving this outcome at six hours. Patients improved in presbyopia coping mechanisms and reading the study questionnaire, among other tasks.

Opportunity Knocks

Since Vuity is a prescription drug, it could bring a large underserved population into optometric offices for a comprehensive exam, where patients will not only be offered many options for presbyopia correction but may also be diagnosed with previously undetected systemic or ocular diseases. A therapeutic eye drop will hopefully benefit many patients needing help with reading a menu or a scorecard at a sporting event. Within the next few years, as many as seven other therapeutic drugs for presbyopia may enter the market, so now is the time to get ready! ■

About
Dr. Karpecki

Dr. Karpecki is medical director for Keplr Vision and the Dry Eye Institutes of Kentucky and Indiana. He is the Chief Clinical Editor for *Review of Optometry* and chair of the New Technologies & Treatments conferences. A fixture in optometric clinical education, he consults for a wide array of ophthalmic clients, including ones discussed in this article. Dr. Karpecki's full disclosure list can be found in the online version of this article at www.reviewofoptometry.com.

THE FUTURE OF AMD CARE STARTS NOW

By combining structural and functional assessments, optometry has conquered glaucoma. It's time to do the same for AMD!

Your optometric peers are implementing the AdaptDx Pro[®] guided by Theia[™], as the functional complement to structural imaging to better detect and monitor AMD. Discover how our AMD Excellence Program[®] empowers you to change the future of AMD care for your patients and your practice.

AdaptDx[®]
PRO
Guided by Theia[™]



GET THE LATEST MUST-HAVE AMD RESOURCE:

19 of your peers share their experiences in making dark adaptation testing a reality in their offices.
maculogix.com/ebook

Hierarchy of Emotions

There are six major ones, but happiness ranks first, trust me.

As medical professionals, we optometrists tend to believe that every move we make is determined by science, training and experience. Our patients also believe that all doctors are consistently guided by these same three pillars that give us the amazing honor to provide care to them and their families.

Certainly, science, training and experience are very important. But, my dear patient, I need to remind you that all your doctors are, first and foremost, human beings. Well, the vast majority are... there are always a few autobots out there. We call them the CDC. But the rest of us, I can assure you we have emotions.

In 1970, Dr. Paul Ekman applied his considerable experience as a psychologist to determine that there are six major emotions: happiness, surprise, sadness, fear, anger and obviously, my favorite, disgust, *i.e.*, no-shows.

Now, just because you are human doesn't mean you should let your emotions take over completely. On the other hand, sometimes our patients do deserve to see that we are just like them... crazy.

I've ranked the six major emotions by order of importance. This is my opinion, which is, well, true. Here is the list:

1. **Happiness.** If you are not happy at work, your patients and employees won't be either. These folks are your mirrors. If you hate what you do, they will hate what you do and what they do, too. Not good. I know a ton of optometrists, and the good ones smile

and laugh a lot. It could be chemically induced, but whatever works. I have considered pumping just a tiny amount of nitrous oxide into our air filtration system at the office, but the Board says no.

2. **Surprise.** I know you are smart. After all, that's what you told me. I know you know what you are doing. That's also what you told me. However, be open to the beauty of mystery. I love it when I learn something new even if it is because I am not that smart and do not always know what I am doing. When sufficiently surprised, I just refer to #1 first, and then I learn. Well, maybe I do get depressed for a few weeks first, but that's beside the point.

3. **Sadness.** Maybe the surprise thing was worse than I thought. Heck, a good cry just makes my contacts feel better. The glass is half full.

4. **Fear.** I have grown to love that little nugget of dread. When we see a symptom, a spot, a bump, a 20/20 OD with a 20/30 OS, we should take a moment to thank our lucky stars that we have a built-in radar called fear. Fear keeps you out of a lot of dark alleys, right? Fear means you are human. The darkness of fear helps you recognize the bright flash of joy when it finally shows up, as in, "You're kidding,


Those bifocal contacts are working?" Fear leads to insomnia, which leads to watching reruns of *Breaking Bad* at 4am. That's the worst it can do.

5. **Anger.** Don't fight fear with anger. Leave that to the patients who lose their minds because a screw came out of the hinge and they think you are going to blame them. I know, you cannot always avoid a touch of anger. Just take a deep breath when you feel it coming and at least take a moment to realize you are an optometrist which means just about anybody under age 97 can whoop you so do not escalate. Instead, try smiling. It's hard to be angry when you smile. Wait, though! If it's not you but the patient who is angry, **DO NOT SMILE.** Unless of course your kid is an oral surgeon who can replace the teeth Mrs. Jones knocks out of your grin. (Mine is. Therefore, I smile.)

6. **Disgust.** It's so easy to be disgusted, right? I mentioned no-shows.

Yuck. My lab has supply chain issues with the AR we like. Yuck. I had a patient who was a 62-year-old chemical engineer with an Rx of Plano -2.25x124 with a +2.25 add, and he could never wear any glasses from any doctor he ever saw before me. He wanted to try contacts for the first time because his 24-year-old daughter who had an Rx of -3.00 OU really loved her contact lenses. Double yuck. I referred him to my partner... the one who drank my diet soda last week.

I feel better. Now, back to happiness! ■



About Dr. Vickers

Dr. Vickers received his optometry degree from the Pennsylvania College of Optometry in 1979 and was clinical director at Vision Associates in St. Albans, WV, for 36 years. He is now in private practice in Dallas, where he continues to practice full-scope optometry. He has no financial interests to disclose.

When the Big 4 sold out to online disruptors, they forgot about one minor detail...

EYERIS

“MERRY CHRISTMAS YA FILTHY ANIMALS!”

To start defending your practice against online disruption, visit myeyeris.com/doctor-sign-up to get your fit kit today!



EDITED BY PAUL C. AJAMAN, OD

CLINICAL QUANDARIES

Keep it PG

These growths, seen in both children and adults, are often easily managed.

Q I have a 12-year-old patient who presented with a “growth” on the conjunctiva. What is it, and what can I do about it?

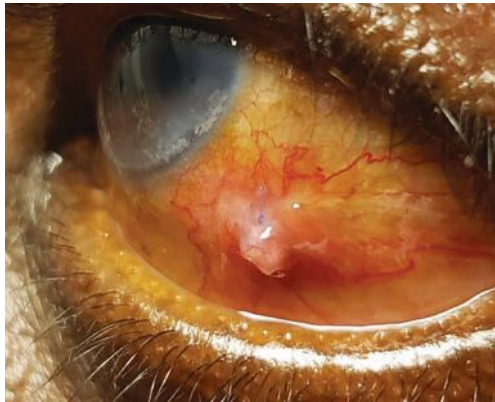A Pyogenic granuloma (PG) is a benign, acquired, vascular lesion that is part of an aberrant wound healing process. After an insult to tissue, such as trauma or inflammation, an exaggerated fibrovascular response occurs. Histologically, PG is composed of chronic inflammatory cells and capillaries. “The term pyogenic granuloma is a misnomer, as the lesion is neither pyogenic (pus-producing) nor a true granuloma,” says Stephanie Jian, OD, of the Vanderbilt Eye Institute in Nashville.

Clinically, PG appears as a fleshy, elevated, red-pink mass. Its shape is variable: round, ovoid or lobular. The shape is categorized as either pedunculated (attached via a stalk/peduncle) or sessile (flat and without a stalk/peduncle). PG can grow on cutaneous or mucosal surfaces. “They often grow rapidly, which can help differentiate pyogenic granuloma from more malignant lesions,” Dr. Jian notes.

Ocular PGs are most commonly seen on the palpebral and bulbar conjunctiva. They can also grow on the external eyelid surface. Rare cases of corneal PG have been reported in the literature.

PG and Children

Pyogenic granuloma are common in children. There is a definite relation-



PG can be treated by the primary care OD without a referral.

ship between chalazion and the development of pyogenic granuloma, with a chalazion preceding 42% of PG cases.¹ There is also a strong relationship between ocular surgery and the development of PG, as 40% are preceded by ocular or adnexal surgery.¹ Dr. Jian states that PG is not uncommon after strabismus surgery. Approximately 2% of patients who have strabismus surgery develop PG.² “They typically develop a few weeks after eye muscle surgery near the area of sutured conjunctiva,” she observes.

According to Dr. Jian, topical steroids and/or surgical excision are the traditional treatment option for PG. Smaller PG are more likely to respond to topical treatment. One study found a 90% success rate when treating pyogenic granuloma with topical steroids.²

Topical timolol has been recently used to successfully treat ocular PG. Timolol solution or gel was dosed twice a day in adult and pediatric patients with ocular PG, with high

resolution rates ranging from 88% to 100%.^{3,4,5} In these studies, timolol was dosed twice a day for two to six weeks. “Many cases in the dermatological literature have demonstrated successful treatment of cutaneous PG using topical timolol, often in children,” Dr. Jian says.

Beta-blockers have been used, topically and systemically, to treat capillary hemangiomas. It is hypothesized that beta blockers cause vasoconstriction within the hemangioma, subsequently inhibiting VEGF and promoting apoptosis. Beta blockers’ mechanism of action in treating PG, another vascular lesion, is likely similar.

“There are many advantages to considering timolol treatment for PG, especially in pediatric patients,” Dr. Jian says. Timolol has a lower side effect profile than topical steroids. Both topical steroid eye drops and timolol are noninvasive and avoid local/general anesthesia.” Timolol is also less expensive than topical steroids. Lastly, timolol is instilled less frequently than a topical steroid.

“Bottom line, PG are common in children as well as adults and can be treated by the primary care optometrist effectively and without a referral,” she says. ■

1. Ferry, AP. Pyogenic granulomas of the eye and ocular adnexa: a study of 100 cases. *Trans Am Ophthalmol Soc.* 1989;87:327-47.

2. Espinoza GM, Lueder GT. Conjunctival pyogenic granulomas after strabismus surgery. *Ophthalmology.* 2005;112(7):1283-6.

3. Oke I, Alkharashi R, et al. Treatment of ocular pyogenic granuloma with topical timolol. *JAMA Ophthalmol.* 2017;135(4):383-5.

4. Demaria LN, Silverman NK, Shinder R. Ophthalmic pyogenic granulomas treated with topical timolol—clinical features of 17 cases. *Ophthalmic Plast Reconstr Surg.* 2018;34(6):579-82.

5. Nair AG, George RJ, Natarajan S, Jain V. Topical timolol for the treatment of conjunctival pyogenic granulomas: outcomes and effect on intraocular pressure. *Indian J Ophthalmol.* 2020;17(1):2170-4.

About Dr. Ajaman

Dr. Ajaman is the center director of Omni Eye Services of Atlanta. He currently serves as general chairman of the education committee for SECO International. He has no financial interests to disclose.

SIZE MATTERS



NANO DR[○]PPER

95% of ODs say Bigger is **NOT** Better*

*Ask us how less is more for your patients
...and your clinic's bottom line*

www.nanodropper.com | support@nanodropper.com | (507) 405-5676

Use discount code REVIEWOPTO10 for 10% off your first order!

*According to a survey conducted by Nanodropper in April 2021 out of the 300+ ODs, more than 95% said their patients would benefit from smaller eyedrops.



BY JOHN RUMPAKIS, OD, MBA
CLINICAL CODING EDITOR

CODING CONNECTION

It's a Wrap

Prepare your practice for an exciting New Year.

With 2021 nearly in the books, let's evaluate how your practice is going to prepare for the changes that come with the New Year. For some, this time is perfect to implement change. Many carriers change coverage, utilization and reimbursement policies during this period, so be prepared; it is always better to be proactive with your internal policies. So, here are some simple but timely things to do before 2022 arrives.

Get Organized

Create a repository that indexes all of your provider agreements (contracts) for all of your contracted insurance carriers, both refractive and medical.

- Create two sections—one for refractive carriers and another for your medical carriers.
- Find copies of your contract, and put them in the notebook alphabetically.
- If you don't have current copies of these documents, create a form letter/email requesting your provider agreement from each carrier. Send this to the plan administrator or to the Provider Relations department.

Do this each and every year, as your carriers typically have the ability to *unilaterally* change your provider agreement without notification, leaving you in the dark about your and their obligations under the contract.

Update References and Tools

If you are looking at your CPT, HCPCS, Category III and ICD-10 code books and they don't say 2022 on them, then you need to update your

references. All of the codes we use to describe the patient-physician encounter, procedures or special diagnostic testing, modifiers and patient diagnoses are all subject to change every year. The rules of how we apply or use the codes can also change, so please make sure that your reference guides are up-to-date.

“Stay informed by updating your resources and in-office tools to make your life easier.”

For those of you who rely upon your EHR to make all of the updates, understand that they may not automatically update. It could require a manual update, and even then you are only getting part of the information you need by simply updating the code itself.

Analyze and Update Your Fees

While the FTC won't allow me to tell you how to set your fees specifically, most practices leave hard-earned revenues on the table because they haven't evaluated their fee structure objectively and analytically—charging less than what contracted third-party payers are willing to pay. Worse yet, many of you are only updating fees annually or every couple of years.

Fees should be analyzed and evaluated at least once per quarter. Using a tool like the Fee Schedule Analyzer in CodeSafePlus (www.codesafeplus.com) automatically evaluates your fee structure and makes educated business decisions about your fees.

Increases in both gross and net income are generally realized when you pay attention to your professional service revenues. After all, it is “free money,” as you are simply increasing your reimbursements for professional services for the same work performed.

Pick Your Battles

Claim denials are commonplace in just about every practice. Understanding the rules helps avoid inappropriate denials. Likewise, learn how to use an ABN properly in conformance with each contracted plan to legally transfer the financial liability for services to the patient. If a carrier denies something that you believe should be covered, know more than they do. The more you know about the rules and guidelines, the better a position you are in to argue your case to a third-party carrier.

Carriers generally have to follow the same set of rules we do in coding and medical record compliance. Your operating agreement governs your rights and remedies should you have a claim or dispute with your carrier. Using reference tools like CodeSafePlus to help you keep up with these things can be so very helpful in fighting denials.

Embrace Change

Make 2022 *your* year to embrace the changes that come with being an essential health care provider. Stay informed by updating your resources and in-office tools to make your life easier. Have a plan to integrate and implement these changes into your practice. And most importantly, make 2022 *your* best year ever—as we come to realize that the most reliable constant that we have in life is change. Anticipate it, embrace it and direct it to your benefit. Have a great 2022! ■

Send your coding questions to rocodingconnection@gmail.com.

About
Dr. Rumpakis

Dr. Rumpakis is president and CEO of Practice Resource Management, a firm that provides consulting, appraisal and management services for healthcare professionals and industry partners. As a full-time consultant, he provides services to a wide array of ophthalmic clients. Dr. Rumpakis's full disclosure list can be found in the online version of this article at www.reviewofoptometry.com.

SMART MIRROR 4 PRO OPTICIAN'S FAVORITE DISPENSING TOOL

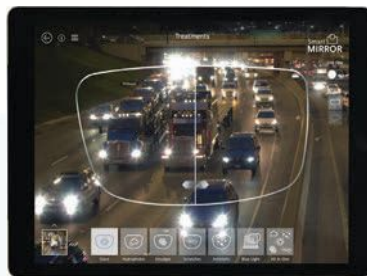

ENGAGING - UNIQUE - HIGH TECH - SAFE

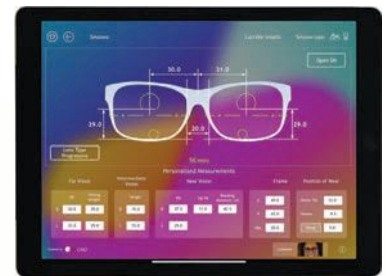Eyewear Shopping Experience



Help your patients choose the right frame faster



Realistic and crystal-clear lens presentations



Accurate and precise measurements

Contact ACEP USA today to schedule a personal demonstration

888 989 4227

info@acep.tech
www.acep.tech


USA



Less is Not More

One of the fundamentals of prescribing involves using all of your data points, not limiting yourself to one, to arrive at a solution.

Data! It all comes down to data. The decision of whether to begin treatment for glaucoma depends on visual fields, OCT, intraocular pressures, nerve appearance, family history, expected patient compliance and more. The decision of whether or not to fit a keratoconic cornea with a specific lens design depends on the refraction, topography, visual acuity, available lens materials and a host of other concerns. The decision to refer to a specialist is based on the accumulation of data as well.

So, why should determining a lens prescription be any different? Why

should one finding alone be all that is used? The answer: it shouldn't.

The More the Merrier

In a recent online discussion, a clinician posted patient data with a fairly high hyperopic astigmatism correction and asked for opinions on an appropriate prescription to give the child. There was a decent amount of data provided on which to form an opinion in this case. I (Dr. Taub) typically let these questions go, but I jumped into the fray after seeing the same response a few times: prescribe the entire cycloplegic and nothing less. A lightbulb went off in my head;

why would we base the entire endpoint of the examination—in this case, glasses—on one data point?

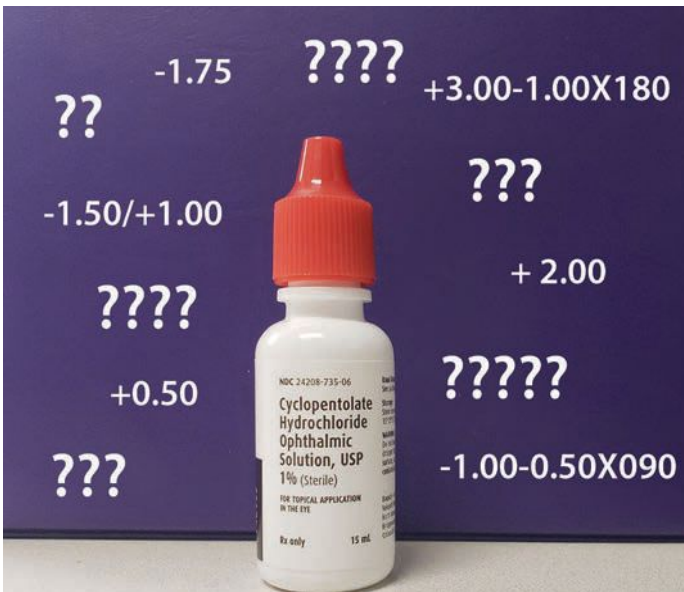
Over the past six years of this column, we have introduced many aspects for potential use in the clinical examination. We have discussed several data points on which to base the success

of a near vision plus prescription, including the MEM, Groffman visual tracing and NPC. We have talked about the Van Orden star, NRA/PRA, retinoscopy at distance and near and different methods for assessing visual acuity. We have presented cases in which the prescription was “cut” to provide better comfort and binocular vision. So, why do so many of us jump at the concept that we must prescribe the full cycloplegic and nothing but the cycloplegic? Why does that data point, of the many we gather, seem to rule over all the others like the one Ring of Mordor?

Perhaps the American Optometric Association's *Evidence-based Clinical Practice Guidelines on Comprehensive Pediatric Eye and Vision Examination* can point us in the right direction.¹ Released in 2017, it includes over 250 references. In the refraction component of the vision testing sections for both pre-school and school-aged children, the following is stated, “...the results of a refraction do not provide all of the information needed to determine an optical prescription. The refractive error measurement should be analyzed with other testing data and the patient's visual needs obtained during the in-person examination. This information is used to determine if, and in what amount, an optical correction is needed to provide optimal vision and comfort for all viewing distances.”

There are several things that stand out in this statement:

(1) The refraction is a piece of the puzzle, not the most or only important piece. Going further into the binocular vision, ocular motility and accommodation component of the guidelines, the document specifically encourages examining all of the data



Cycloplegia is effective in evaluating pediatric patients and quantifying refractive error but this finding needs to be balanced against other sources of data before determining an approach to visual correction.

About Drs. Taub and Harris Dr. Taub is a professor, chief of the Vision Therapy and Rehabilitation service and co-supervisor of the Vision Therapy and Pediatrics residency at Southern College of Optometry (SCO) in Memphis. He specializes in vision therapy, pediatrics and brain injury. Dr. Harris is also a professor at SCO. Previously, he was in private practice in Baltimore for 30 years. His interests are in behavioral vision care, vision therapy, pediatrics, brain injury and electrodiagnostics. They have no financial interests to disclose.

without relying on a single finding to make a diagnosis.

(2) The data, whether by static distance retinoscopy, cycloplegic retinoscopy, autorefractor or subjective refraction, does not stand alone and must be considered with all of the other data, including the patient's history and visual needs.

(3) The piece of data collected should be used to figure out if correction is needed and to help in determining an appropriate amount that provides good vision and comfort.

Perhaps it is time to tackle the concept of balancing optimal vision and comfort head on. Over the years, on a fairly regular basis we have seen children with a need for significant refraction correction return for an appointment either without their glasses or with them in their mother's purse. When questioned why, typically the response is that the glasses don't work well, make things worse or feel funny when in use. When we examine the correction, it is usually inevitably high in some manner and an amount that was fully given or based on a cycloplegic refraction, showing the supposed "true prescription." When the strength is reduced and trial framed, we see similar visual acuity, a more efficient visual system and improved comfort. This harkens back to the concept of prescribing using all of the data points collected and not just one. This concept must be at the forefront of all cases.

So, what does the concept of the true prescription that everyone pulls out of the air in defense of giving every 0.25D found with cycloplegia really tell us? We should start by admitting that many factors get in the way of determining a refractive endpoint, including accommodation, binocular vision and ocular motility. So, when we use cycloplegia, is our goal to determine the true endpoint devoid of, well, all of the other aspects of vision? If our goal is to determine the most appropriate prescription for the visual system, we

must examine part of it with all of the noise in the system still present. This is how the patient functions in their everyday lives outside of the optometrist's office. Does the cardiologist or orthopedist immobilize the heart and knee, respectively, to take measurements? Seems like an odd question but makes for a great analogy.

Another argument for providing the full cycloplegic amount is that we don't want to leave the patient amblyopic. In looking at the American Optometric Association's *Clinical Practice Guidelines on Amblyopia*, revised in 2004, we see that the organization lists the following as amblyogenic factors: isometropia-astigmatism $>2.50D$, hyperopia $>5.00D$, myopia $>8.00D$ and anisometropia-astigmatism $>1.50D$, hyperopia $>1.00D$, myopia $>3.00D$ and anisometropia.² So, if the cycloplegic endpoint is determined to be 7.00D OU, you are well within the factor limit if you prescribe only half, or 3.50D. If the prescription shows anisometropia, as long as you reduce the correction within the amblyogenic factor limits, there is no reason to worry about leaving the patient amblyopic or even causing amblyopia in the first place.

Yet another point of discussion is the need to force the patient to wear the full power determined from the cycloplegic. We have seen online posts and had discussions with colleagues in which they state that they make their patients suffer for weeks so that they adapt. Could you imagine an orthodontist saying the same thing? In advertisements for online teeth straightening, they send you a kit of about 20 variations of molds to help guide the process; they don't just send the final one and say, "suck it up."

In prescribing, we must accept the concept that it is a process and a negotiation between the doctor, patient and surrounding world in which we live. It is perfectly acceptable to give less than the highest values found to

aid in the process of wearing glasses and adapting to them, and then revisiting the prescription at a later date. The prescription will impact the patient and visual system in many ways, so let the patient be part of the process.

Going a little further into the American Optometric Association's guidelines, the committee states, "There is a lack of published research to support or refute the use of this recommendation."¹ The recommendation, by consensus of the committee members, is that cycloplegia is the preferred procedure for evaluating children and that it is necessary to quantify significant refractive error in the presence of visual conditions such as strabismus, amblyopia and anisometropia.

We find "necessary" to be a very strong word in this case and have not found this to be true, or the consensus of optometrists who see children and provide vision therapy services. Can cycloplegia "enhance the ability to evaluate and diagnose eye and vision problems" as the committee suggests? Yes, but the committee stops short of saying that it is the most important data point.

Takeaways

We have all been taught how the visual system works and how we must weigh all of our examination data to determine the correct diagnosis and appropriate treatment. Being beholden to one data point goes against that concept.

Collect any data that you want, just be aware of how it all comes together to aid in your decision-making process and, ultimately, the treatment you provide. ■

1. Comprehensive pediatric eye and vision examination. AOA Evidence-Based Clinical Practice Guideline. February 12, 2017. www.aoa.org/AAADocuments/Practice%20Management/Clinical%20Guidelines/EBO%20Guidelines/Comprehensive%20Pediatric%20Eye%20and%20Vision%20Exam.pdf. Accessed November 10, 2021.

2. Rouse M, Cooper JS, Cotter S, et al. Care of the patient with amblyopia. AAO Optometric Clinical Practice Guideline. February 12, 2017. www.aoa.org/AAADocuments/Practice%20Management/Clinical%20Guidelines/Consensus-based%20guidelines/Care%20of%20Patient%20with%20Amblyopia.pdf. Accessed November 10, 2021.

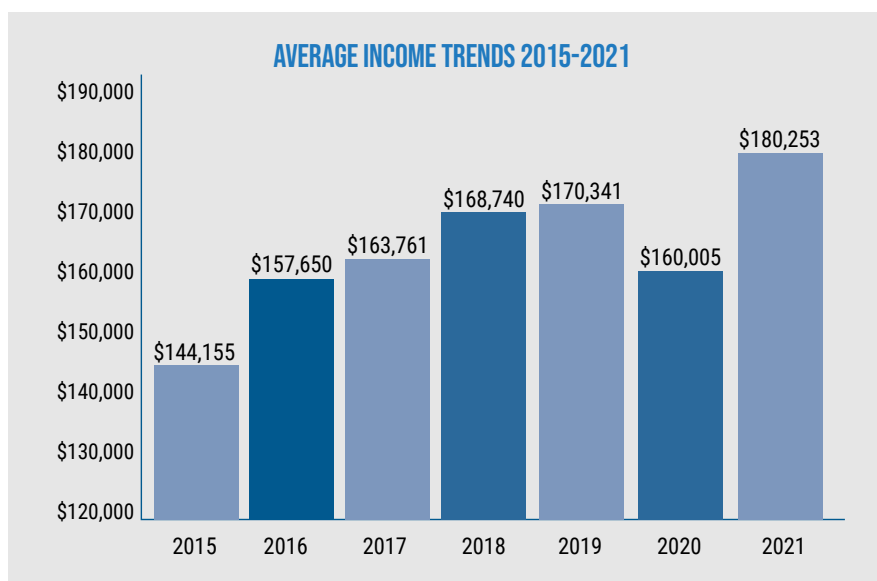
2021 INCOME: BACK ON THE PLAYING FIELD

COVID-19 is here to stay, but optometry made significant financial strides this year to show it's not going anywhere either.

BY CATHERINE MANTHORP
SENIOR ASSOCIATE EDITOR

With COVID-19 now an established part of everyday life, optometry like every other profession was forced to adjust and find its way in the “new normal”—or be left behind. Luckily, only 25% of ODs who responded to our annual income survey felt COVID had more of a financial impact this year than last—due to factors like temporary practice closures, decreased patient volume and corresponding exam fee revenues, reduced product sales, increased expenses for PPE, disinfection and added cost of staff training and rehiring—with just 32% noting that their income decreased as a result.

Well over a year and a half after the onset of COVID-19, optometry seems to have found its footing and made it to more solid ground, according to this year’s annual income survey. A record 1,600 optometrists responded this year. The topline finding: average income increased by 13% in 2021 over 2020, to \$180,253. This is the highest annual income the survey has recorded and puts optometry back on track with pre-COVID numbers.



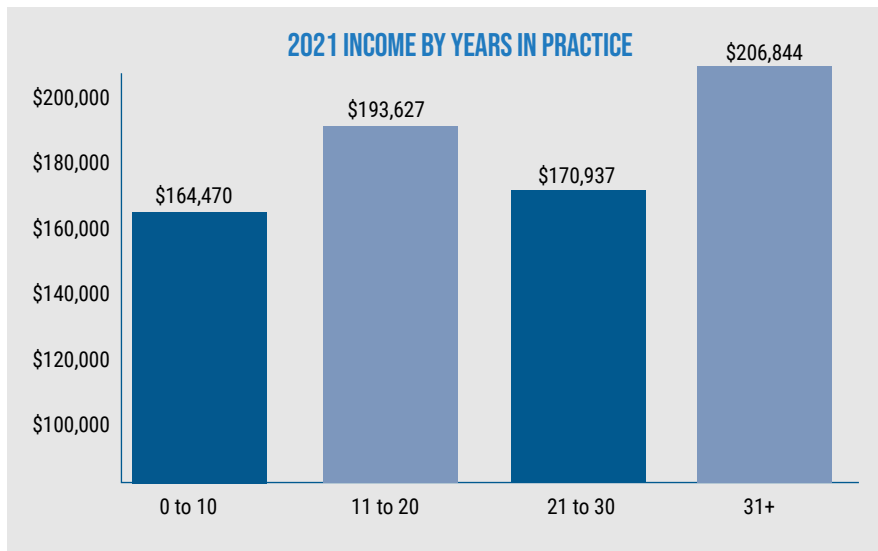
Following suit, the 87% of respondents who identified as full-time noted a 9% increase in their average income to \$185,453 in 2021. Part-timers experienced a 63% rise, to \$145,005, likely by picking up more hours. Both groups fared especially well, considering their take-homes dipped last year by as much as 30% for those putting in part-time hours.

Editor's note: As always, be mindful that while we ask the same survey questions, the responses we compare from year to year come from different individuals, making trend analysis tricky, especially

“ I love what I do and consider myself privileged to make such a good living. ”

among a smaller cohort. The results offer a representative look at the profession but aren't considered statistically rigorous, particularly year-over-year comparisons.

In addition, while we recorded 1,600 responses this year, we omitted a small number of outliers that produced misleading data to improve the overall accuracy of the findings.



Employment Experience

Regardless of the number of years spent practicing optometry, this year's survey cohort showed increases in income—some more notable than others—across the board, with the exception of one experience bracket. Luckily, the more seasoned optometrists seemed to make up for this shortcoming.

Survey respondents with up to 10 years of experience made an average of \$164,470 this year, up 29% from 2020.

Those with 11 to 20 years of experience earned 18% more than their newer counterparts, at \$193,627. This represents another 7% yearly increase for this group.

Financial progress stalled in this next experience bracket (21 to 30 years of experience). These respondents of the 2021 survey earned 12% less than the previous group, at \$170,937—a 3% decrease over the last year.

Getting back on track and earning 21% more than their colleagues with

10 fewer years of experience, the more veteran optometrists—those with over 30 years of experience—reported an average of \$206,844 in 2021, up 19% from 2020. This is in line with the notion that more experience equates to higher earnings, which wasn't always the case in past income surveys.

Worker Wages

Being your own boss continued to benefit survey respondents in 2021. While only 37% are self-employed, these optometrists earned an average of \$249,405, or 80% greater than those who are employed and make \$138,861 on average. While this gap widened over the course of the year, both groups saw a rise in their

take-homes, 22% for self-employed workers and 9% for those who are employed.

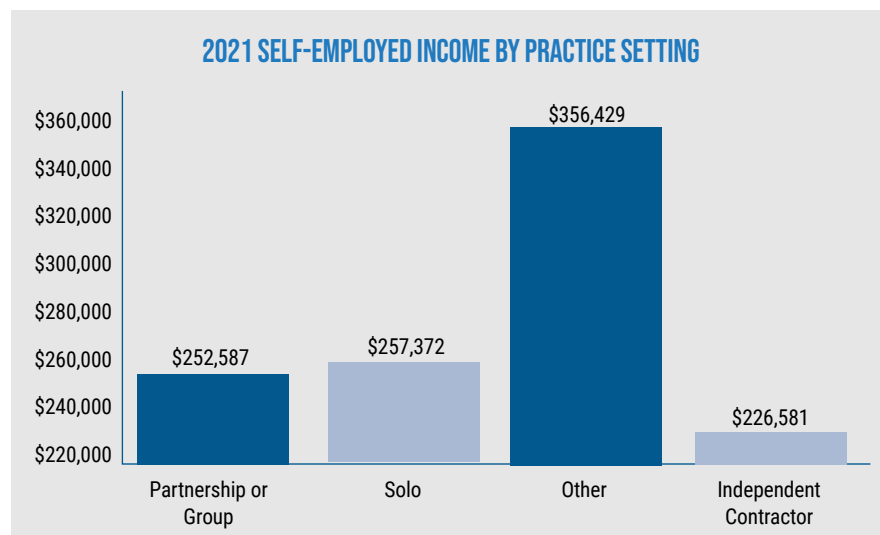
Of those who are employed, 32% work for another OD or MD, 23% for a commercial firm, 23% for a hospital or VA, 10% for an HMO or PPO, 7% for a university and 5% for another institution. This breakdown is similar to years past.

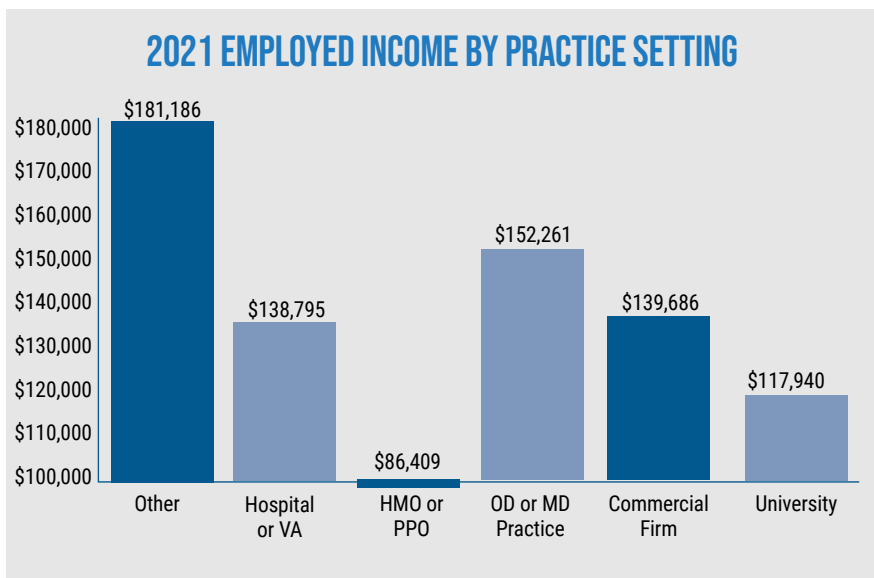
Working for an HMO or PPO fell a few rankings from 2020 to sit at the bottom of the totem pole this year, with optometrists in this category reporting an average income of \$86,409. These workers continued to suffer financially in 2021, making 37% less than their counterparts last year, who also reported a loss in profitability.

University staff ODs rose one notch in the rankings, from the least profitable in 2020, and employees of a hospital or VA fell several ranks to comprise two of the more lower-paying gigs. University optometrists reported an annual income of \$117,940, 2% less than last year. Those who work in a hospital or VA made an average of \$138,795 in 2021, down 1% from 2020.

Rising in ranks from 2020 to 2021 were commercial firm workers (earning 16% more than last year at \$139,686) and optometrists who work under another OD or MD (25% more at \$152,261) to make up two of the more financially attractive ventures.

“Income should be higher given our degree, cost of education, time spent in school and impact we make on society.”





“ I am grateful to be healthy and able to work and support my family, all while being of service to my patients at a time when much of the world continues to struggle with the pandemic, economy and climate. ”

optometry in the country lies a 44% financial gap. Each region reported an increase in average annual income over the last year, some at more disproportionate rates than others to further widen the regional financial divide.

Stealing the spotlight for the second year in a row were optometrists who chose the “other” employment option. This group reported an average yearly income of \$181,186 in 2021, up 25% over the past year.

On the other hand, looking at self-employed workers, 38% are members of a partnership or group, 36% practice on their own, 25% are independent contractors and 1% chose the “other” option. Again, a similar breakdown of self-employed work as preceding years, with each category enjoying a more profitable year than last.

Mirroring what seems to have become a trend, working as an independent contractor was the least profitable self-employment route, with optometrists making an average of \$226,581, though still more than each of the employed categories and up 84% from 2020.

Optometrists who are members of a partnership or group fell from the top-ranked category in 2020 (6% more than last year at \$252,587), and those who practice on their own held onto

their status as runners-up (26% more at \$257,372) to comprise two of the more intermediate-paying self-employment gigs this year.

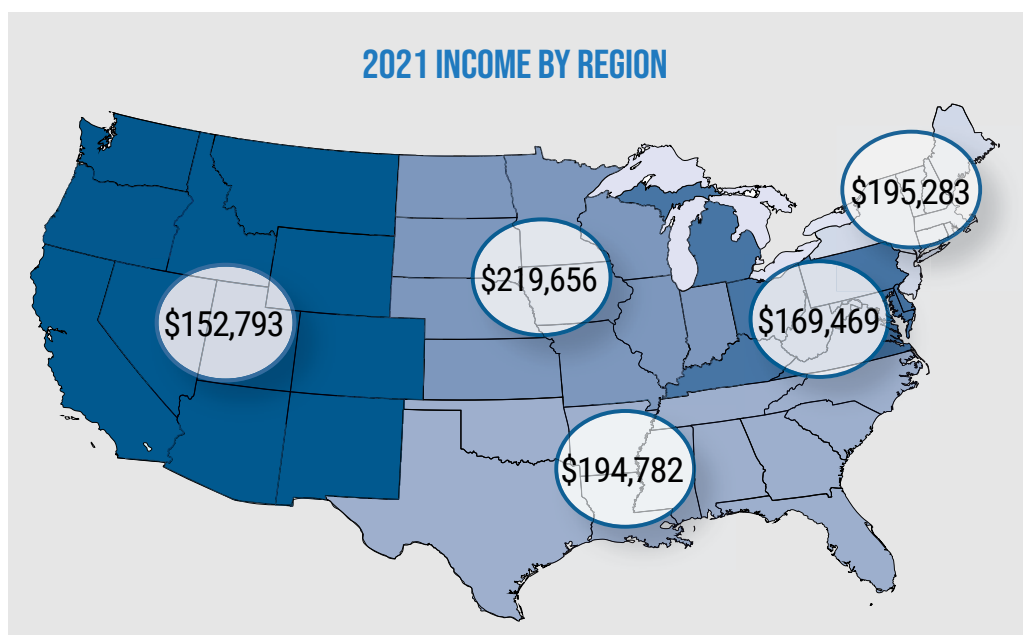
Moving up a few rankings to the top of the chain in 2021 and bringing in a whopping 119% more than last year were self-employed ODs who chose the “other” option and make an average of \$356,429.

Regional Riches

Distance isn’t the only thing separating each continental region of the United States; from the least to the most profitable region to practice

Optometrists in the West remained the least profitable this year but still managed to make 9% more than 2020, at \$152,793. The Mid-Atlantic/Lower Great Lakes region moved down a ranking over the last year to the second smallest take-home category in 201, at \$169,469, up 2% from 2020. The South dropped from its place in the lead last year to become one of the more intermediate-paying regions to practice optometry in the country (\$194,782) but still managed to bring home 9% more than 2020.

Both the Northeast and the Midwest moved up to become two



ACUVUE® OASYS MULTIFOCAL

WITH PUPIL OPTIMIZED DESIGN

A Solution for a Growing Issue: Innovative Multifocal Contact Lenses for Patients with Presbyopia



You know the vision changes presbyopia brings, but do your patients understand what they're experiencing? While you know multifocal contact lenses are a great vision-correcting option, patients have low awareness of the condition of presbyopia and even lower knowledge of their options. They don't know to ask you about those options, and the impact is real: over 50% of wearers over the age of 45 will discontinue use of contact lenses within the first year of wear as they develop presbyopia!¹

Performance and comfort with a quick and easy fit is within reach with ACUVUE® OASYS MULTIFOCAL with PUPIL OPTIMIZED DESIGN. This 2-week reusable contact lens is a unique fusion of three technologies designed to deliver crisp, clear, reliable vision. Pupil Optimized Design is the ONLY technology that uniquely optimizes the optical design to the pupil size according to age AND refractive power, making the optics the right size.² The hybrid back curve design includes an aspheric center to keep the complex front-surface optics in the right shape, and a spherical periphery to keep optics in the right place.² Plus, patients get all the comfort you'd expect from the ACUVUE® OASYS Brand family, which has never been beaten in comfort across 25 clinical studies.*

"When patients struggle with ocular discomfort and need multifocal correction, we rely on ACUVUE® technology... the material really makes a difference," shared Shane Kannarr,^Δ O.D. and owner of Kannarr Eye Care in Pittsburg, Kansas.

Pupil Optimized Technology is available on both the #1 selling daily disposable and reusable contact lens brands in the world – 1-DAY ACUVUE® MOIST and ACUVUE® OASYS 2-Week – with the same simple fit process across both brands.** Just use the **ACUVUE® MULTIFOCAL Fit Guide** to achieve over a 94% success rate in two pairs of lenses of less!^{§,3,4}

"We want success early in fitting multifocal lenses and we see swift success with ACUVUE® products and their tools, such as the multifocal fit guide and digital fit calculator,[‡] which lets us find what works for the patient quicker," Dr. Kannarr continued.

Using the calculator for a quick and easy fit and having the option of daily disposable or reusable modalities enables providers to prescribe according to the patient's needs. **You can fit the multifocal lens to the patient, since 100% of parameters are tailored to pupil size variations across age and refraction vs. <2% for the leading competitor.**^{**2}

"It's easier to have those conversations when I have a lens that my OASYS 2-Week patients can more easily graduate into. This is a better option for my price-sensitive patients that should satisfy the majority of their vision-correction needs long-term," finished Dr. Kannarr.

¹ www.clinicaltrials.gov is a website maintained by the NIH. The 25 clinical studies evaluated subjective comfort as a primary or secondary endpoint for ACUVUE® OASYS Brand 2-week and ACUVUE® OASYS with Transitions™ Light Intelligent Technology™. Review conducted as of October 29, 2021.

² Euromonitor International, Eyewear 2022 Edition, Value sales at RSP, all retail channels, 2020 data.

³ Euromonitor International Limited, based on research conducted in August 2020, "world" and "globally" represent markets accounting for 76% of total daily disposable contact lenses in 2019 (retail sales).

⁴ Four total lenses.

[‡] Disclaimer: The Calculator is provided to clinicians for educational and convenience purposes only, in conjunction with the labeling for 1-DAY ACUVUE® MOIST and ACUVUE® OASYS MULTIFOCALS. Johnson & Johnson Vision Care, Inc. does not engage in the practice of prescribing and this Calculator is not a substitute for appropriate professional education and training or for the exercise of independent professional judgement. Johnson & Johnson Vision Care, Inc. cannot warrant the accuracy or completeness of information that this Calculator provides. Each clinical situation should be considered unique to each patient, and all treatments individualized accordingly. Johnson & Johnson Vision Care, Inc. does not endorse or recommend any particular technique beyond what is contained in the product labeling, and other techniques may be appropriate in a clinician's judgement.

^{**} Compared to leading competitors' designs, technology optimized for both the parameters of refractive error and ADD power.

^Δ Dr. Kannarr is a paid consultant of Johnson & Johnson Vision.

¹ JJV Data on File 2018. Growth Levers analysis base on IPSOS Global Incidence Tracker, retail outlet consumption data and national census population data covering the United States, United Kingdom, Russia, Japan, South Korea and China.

² JJV Data on File 2020. ACUVUE® PUPIL OPTIMIZED DESIGN TECHNOLOGY. JJV Contact Lenses, Design Features, and Associated Benefits.

³ JJV Data on File 2020. ACUVUE® OASYS MULTIFOCAL Fit and Performance Claims.

⁴ JJV Data on File 2015. 1-DAY ACUVUE® MOIST MULTIFOCAL Fit and Performance.

Important Safety Information: ACUVUE® Contact Lenses are indicated for vision correction. As with any contact lens, eye problems, including corneal ulcers, can develop. Some wearers may experience mild irritation, itching or discomfort. Lenses should not be prescribed if patients have any eye infection, or experience eye discomfort, excessive tearing, vision changes, redness or other eye problems. Consult the package insert for complete information. Complete information is also available from Johnson & Johnson Vision Care, Inc. by calling 1-800-843-2020, or by visiting JNVISIONPRO.com.



of the top-paying regions this year. Optometrists up North reported an average income of \$195,283, up 31% from 2020, and those further West made \$219,656, 32% more than last year, to claim the title as the most profitable place to practice optometry in 2021.

Earning Equality

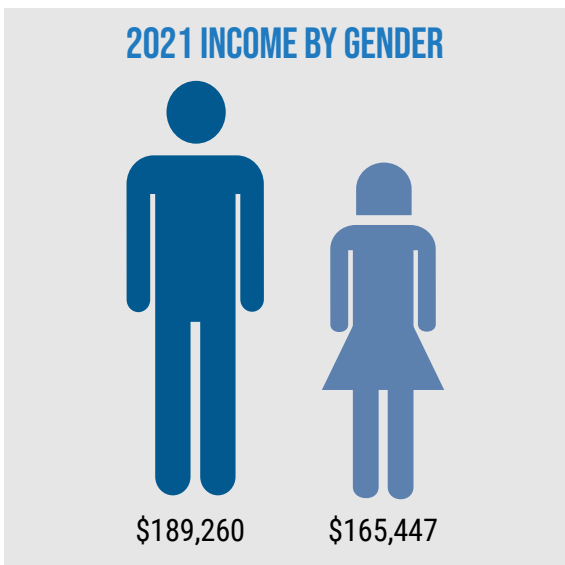
Adding to the stream of good news flowing from optometry's financial picture this year, the gender gap closed by 42% over 2021 to a new low of 14% since the development of this annual income survey. Men (60% of survey respondents) brought home 3% less in 2021 than 2020, for an average of \$189,260 on the year and women earned a significant 33% more than last year, at \$165,447, to close the divide by a large enough amount to put optometry on the right path when it comes to earning equality across genders.

“I don't see much opportunity for my income to keep up with inflation at the current reimbursement rates.”

Also, women at each experience level enjoyed a better year than last, despite experiencing a mid- to late-career plateau.

Men with zero to 10 years of experience in the field reported an average income of \$179,721 in 2021, 24% more than female entry-level workers who made \$144,536. This gap decreased by 32% over the last year, with men in this experience bracket making 7% more in 2021 than 2020 and women making 34% more, for a closing of the divide.

The group with 11 to 20 years of optometric experience was the only one that saw women out-earn their male counterparts, \$205,820 to \$176,567. Female optometrists in this bracket closed last year's male-domi-



nated gap by 45% to zero it out, then widened it by 17% in their favor. Women with this intermediate level of experience earned 38% more than last year and men made 18% less, to flip the disparity.

Men with 21 to 30 years of experience practicing optometry reclaimed the upper edge, out-earning their female counterparts in this bracket by 32%, down 24% from 2020. Male optometrists made \$193,179, down 9% from last year, and women made \$146,103, up 8%, to turn the tables.

The most veteran male optometrists brought in 20% more than their female counterparts; luckily, however, this represents a sizeable 69% shift in the right direction. Men in this category earned 14% more this year (\$209,988) and women reported an average of \$174,598, up a significant 79% from 2020, to level out the playing field.

Practitioner Positivity

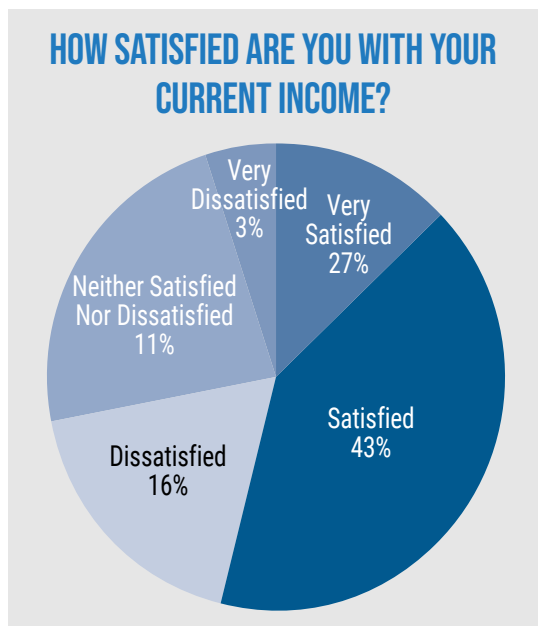
Despite the growing pains that come from continuing to adjust to the new COVID-19 era, the majority of optometrists appeared to be focusing on the positives, with 70% reporting feeling satisfied or very satisfied with their income

this year (up from 54% in 2020). Many survey respondents cited their annual take-home for their ability to pay off debts while still saving for the future. “I'm able to live the way I want to live and save a little along the way, while paying down practice and student loans,” said one respondent. Others appreciated the work-life balance and schedule flexibility the profession makes possible. A lot of optometrists had the stable nature of the field to thank for consistent promotions, bonuses and raises, especially under the shaky circumstances that have been a constant for almost two years

now since the onset of the pandemic.

Those who didn't fare as well financially named COVID-19 as the top culprit. Many noted increased workloads, staffing shortages, inconvenient mandates and reduced hours as the main work-related downsides of the virus. “The impact of COVID-19 on income has been correspondingly reduced,” a respondent summarized.

Still, many are just happy to have kept their job and remained in good health during such a trying time. “In light of all the challenges with COVID mandates and hiring, I am



“Compared with the past, this year’s efforts are much more than before. The epidemic is beyond my control, but I have worked hard and I have been rewarded.”



happy to have a solid income,” said one optometrist.

Looking to the future, 68% of survey respondents expect their income to increase in the coming year (in line with last year’s findings). Many seemed to see the light at the end of the tunnel, sharing a similar mindset: things can only go up from here and continue to improve as the world gets an even better handle on COVID-19.

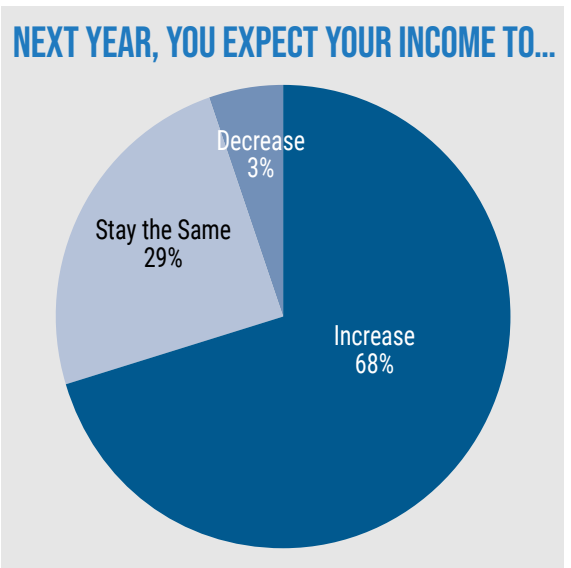
Forward Focused

As is to be expected, some optometrists fared better financially than others this year, taking into account

experience, employment, location and gender.

Many, however, seemed to reap the benefits in one way or another of a financially rewarding year for optometry as a whole.

With the majority of survey respondents indicating that their goal remains to continue making more money in the years to come, they’ve outlined ideas to increase their profitability. Potential plans include expanding offices, staffing and hours to increase patient volume, adding technology and specialty services such as myopia management, dry eye and specialty contact lenses to appeal to different patient demographics and increasing marketing and telemedicine efforts to reach a larger population of people.



Optometry certainly felt the effects of COVID-19 last year but seems to have spent 2021 settling in nicely to this new way of life, adopting new strategies and adapting as necessary along the way for a more profitable year for the profession. ■

From the experts

Why encourage blepharitis patients to follow an eye hygiene regimen?

Answered by Dr. Josh Johnston, OD, FAAO



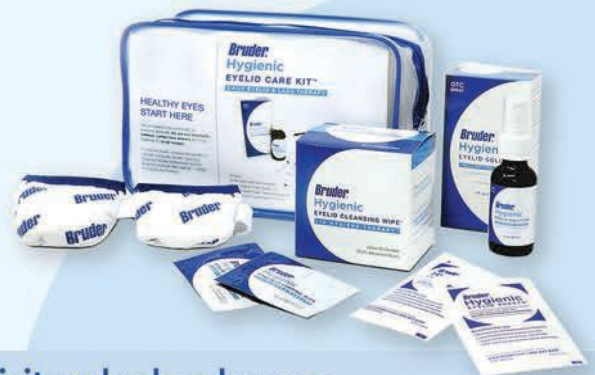Bruder
Better. By Design.

“A 3-step hygiene routine helps address the range of lid and ocular surface issues that exacerbate blepharitis.”

— Dr. Josh Johnston, Georgia Eye Partners

Encourage your patients to Wipe-Spray-Warm.

The **Bruder Hygienic Eyelid Care Kit** makes it easy! First, the gentle wipe removes build up, oil, dirt, pollen, and debris. Next, pure 0.02% HOCl solution helps reduce bacteria and inflammation. Finally, a moist heat compress naturally unclogs meibomian glands and relieves associated dry eye symptoms.



Ready to bring relief to your patients? Visit order.bruder.com.

Have a question or want to learn more? Give us a call at 888-827-8337 or email eyes@bruder.com

THE KEY TO HAPPY REFRACTIVE PATIENTS

With several surgeries available today, we help you determine how to decide which is the best procedure for each patient.



BY BOBBY SAENZ, OD,
ANTHONY VANRACHACK, OD, AND
ALEXANDRA WIECHMANN, OD
SAN ANTONIO, TX

One of the most common questions we get from referring doctors regarding refractive surgeries is, “Which surgery is best for my patient?” Historically, this was not a difficult question, as all patients who had laser vision correction either underwent LASIK or PRK. Now, it’s become somewhat challenging with several procedures available today, from small-incision lenticule extraction (SMILE), implantable collamer lenses (ICL) and toric ICLs to the anticipated release of the Evo ICL, the trifocal IOLs, extended depth of focus IOLs and the light-adjustable lens (LAL) IOL.

The evaluation of a patient is vital and allows us to determine which procedure is most fitting, and then we set expectations. If we have a patient with great results but even higher expectations, we could end up with an unhappy patient. These

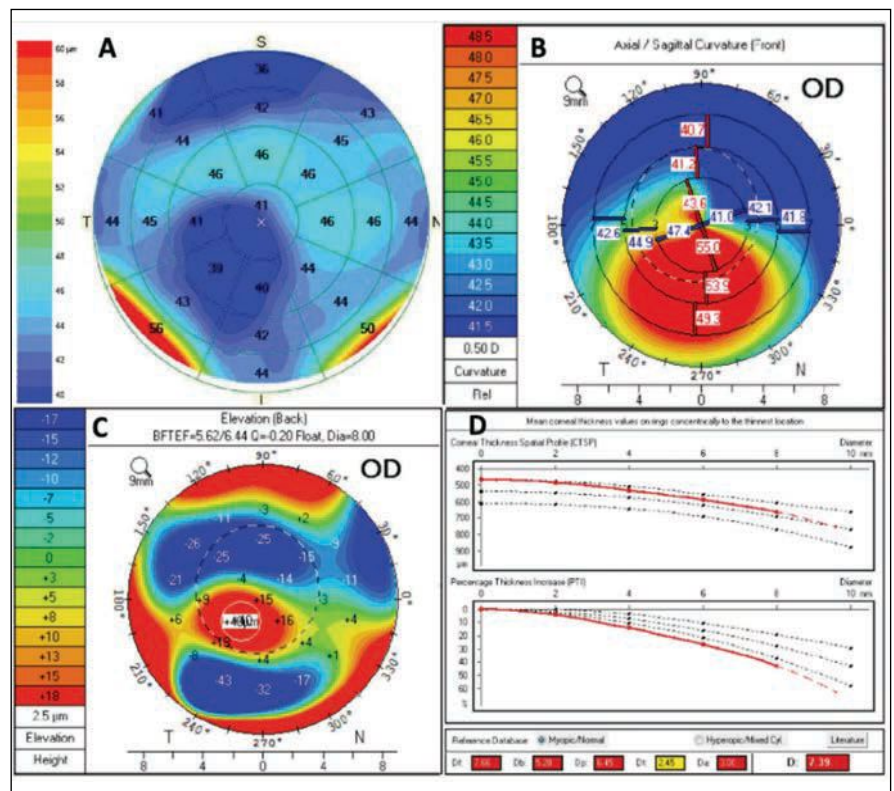


Fig. 1. This patient with keratoconus presented for a refractive surgery consult. OCT epithelial thickness (A) mapping showed thinning of the epithelium that corresponded with inferior steepening (B) and posterior float (C) on the pentacam image. The Belin/Ambrosio deviation display shows an abnormal “D” value consistent with keratoconus.

About the authors

Dr. Saenz is the residency director and clinic director at Parkhurst NuVision and president of the Bexar County Optometric Society. He is a speaker for Biotissue, Zeiss, Johnson & Johnson, Lumenis and Glaukos, a researcher for Ocular Therapeutix, Novartis, Sun Pharma and Sight Sciences, and a consultant for LensAR and Quidel. **Dr. Vanrachack** and **Dr. Wiechmann** are assistant adjunct clinical professors at the University of the Incarnate Word Rosenberg School of Optometry and faculty of the Refractive Surgery Alliance Grands Rounds Collaborative Care Series. All three practice at Parkhurst NuVision, an OD-MD integrated care practice that specializes in refractive surgery, and are Fellows of the American Academy of Optometry.

procedures can have up to a 95% to 99% patient satisfaction rate.¹⁻⁵

Let's take a deeper dive into how to determine the best procedure for the patient, the current results we are getting for these different procedures and how to set expectations to have the happiest refractive surgery patients.

How Do We Choose?

In our clinic, we categorize every patient into one of the three milestones of vision development based on age:

- 18-40 years old: ocular adulthood/maturity. Most refractive errors have stabilized.
- 40-60 years old: dysfunctional lens syndrome/presbyopia. The midlife loss of near vision.
- 60 years old and up: cataracts.

Once a patient can identify which milestone they've reached, their visual goals are assessed, along with refractive error and ocular anatomy to determine their options. For example, a 24-year-old -6D patient whose myopia has fully stabilized is in their first ocular milestone. A patient like this has several options based on their anatomy and desires, including LASIK, SMILE, ICL and PRK.

So, how do we choose? The initial examination of these patients includes a dry and wet refraction, as well as a topography/tomography image with pachymetry and anterior chamber depth assessments.

When looking at the corneal tomography image, we assess the overall K values and look for any inferior steepening, thin pachymetry (<490 μ m) or abnormal posterior elevation (>15 μ m), any of which could be indicative of keratoconus or another corneal ectasia. Remember, in early keratoconus the posterior cornea protrudes forward, oftentimes preceding anterior corneal changes. Other factors to help rule out keratoconus patients for laser vision correction would be the Belin/Ambrosio enhance ectasia factor on the Pentacam (Oculus) or epithelial thickness mapping (Figure 1).

OCTs now have the ability to measure the thickness of the epithelium.

Multiple studies have shown that the epithelium compensates for stromal changes, which means in keratoconus patients, thinning of the epithelium will occur. If we see any signs of inferior steepening, posterior float, abnormal Belin/Ambrosio enhance ectasia display thinning of the epithelium where the apex of the cone is, with thin pachymetry (<490 μ m), then we may wait on a vision correction surgery and instead consider crosslinking for this patient.

First milestone: ocular maturity

What surgery would we pick if this same 24-year-old -6D patient had a great corneal shape but had a corneal thickness of 475 μ m or less? In our practice, we would often rule out LASIK or SMILE because we prefer to see pre-op pachymetry greater than 480 μ m and a predicted residual stromal bed (RSB) thickness greater than 250 μ m. Some surgeons will use a RSB >300 μ m for LASIK patients to avoid the rare risk of inducing ectasia. If the patient has a cornea thinner than 480 μ m, we could consider PRK. With PRK, we prefer to maintain a RSB >400 μ m.

Another parameter we consider in our PRK algorithm is magnitude of myopia being treated. We are reluctant to treat myopia over -5D with PRK due to the increased risk of haze, even with using mitomycin-C during the surgery, not to mention the slower recovery time.⁶⁻⁸ Next, we look at the anterior chamber depth to determine if this patient could be a candidate for an ICL. The ICL can treat anywhere from 3D to 16D of myopia, and base-

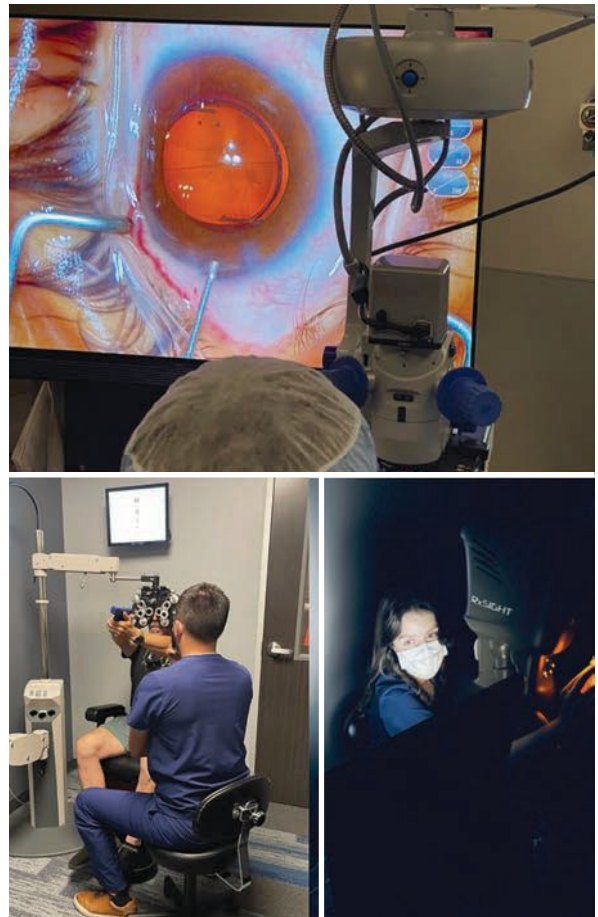

Fig. 2. Light-adjustable lens implantation (top) during cataract surgery allows for patients to adjust their refractive target after surgery. For example, a patient could want more near vision, and the light treatment may help them see their front sights for competitive shooting (bottom left), which is then locked in (bottom right).

line corneal thickness is not a factor. ICLs are also approved for myopic reduction from -16 to -20D and can treat four diopters of cylinder. The ICL may be our leading option in this case. Other cases when to consider using an ICL would be abnormal topography, predicted RSB thickness <250 μ m, considerable preoperative dry eye disease and/or contact lens intolerance.

Second milestone: presbyopia

If a patient has passed their second milestone, we have two main sets of procedures to choose from: blended vision and refractive lens exchange. Blended vision is accomplished by correcting one of the eyes primarily for far, and the other eye is blended for middle and near depending on the



Fig. 3. A slit lamp photo shows the Evo ICL, which has a central port and will allow patients to have the ICL procedure without the need for an iridotomy. This will hopefully be approved soon by the FDA.

residual accommodative amplitude we have to work with. Blended vision can be done with LASIK, SMILE, ICL and/or PRK.

Refractive lens exchange can be done with any of the current types of IOLs. The most popular lenses chosen for this are the trifocal or trifocal-like lenses (Synergy, Johnson & Johnson Vision; Panoptix, Alcon) that cover a complete range from near to far in both eyes. Trifocal lenses allow most patients to see better than 20/25 at distance, intermediate and near.⁴ Other patients consider using the extended depth of focus (EDOF) lenses (Eyhance, Johnson & Johnson Vision; Vivivity, Alcon) which provide approximately 1.3 to 1.5D add.⁶

Patients sometimes choose to have one EDOF lens for distance (plano target) which achieves distance and intermediate range of vision, and the other blended (-0.50 to -1.25D target) to allow for the other eye set to see intermediate and near (Figure 2). The benefit of EDOF lenses is that the incidence of halos is less at the six-month mark compared to multifocal IOLs, especially those of the past. A study showed approximately 65% of patients reported little to no halos with the trifocal lens compared to approximately 85% of patients who re-

ported little to no halos with EDOF lenses.⁹ If the patient is looking to be spectacle-independent as much as possible, the trifocal lenses are the way to go. Patients with trifocal lenses in both eyes are spectacle-independent 92% to 96% of the time, compared to 72% with EDOF lenses.¹⁰

With all of our refractive procedures, the

assessment includes evaluating the overall media and a thorough retinal examination. The myopic patients that have retinal lesions could be at risk for rhegmatogenous retinal detachment (RRD). Refractive lens exchange (RLE) involves taking out the crystalline lens and putting in an IOL even in the absence of cataract. This could lead to volumetric changes in the eye—the crystalline lens is thicker than the IOL—leading to vitreous degeneration and movement that can predispose a patient to RRD. The risk of RRD after RLE is thought to be between 2% and 8% with a higher incidence found in patients who had preoperative retinal lesions, capsular tear during surgery or lack of a PVD.¹¹ For those who have retinal lesions, identifying these lesions preoperatively and recommending prophylactic treatment is best for the patient.¹² Similar to with cataract surgery, these patients need regular follow-up postoperatively to evaluate their retina.

Third milestone: cataracts

Cataract surgery is still the most common refractive surgery we perform. With modern laser refractive cataract surgery, we have the ability to remove the cataract and improve vision by correcting astigmatism and presbyopia

at the same time. If a patient wants to have cataract surgery to reduce their dependency on lenses, we use the same strategy with IOLs that we discussed with RLE procedures.

Refractive Surgery Evaluation

It's important to understand the patient's visual demands, hobbies and complete eye anatomy when performing an evaluation. Is the myopic presbyopic patient who takes their glasses off to read really only wanting to correct their distance vision? Does the emerging emmetropic presbyope want perfect vision at all distances? Is the patient an up-and-coming MMA fighter who wants a LASIK alternative? Understanding the patient's occupation and desires for what they want out of a treatment is very important. If they are wanting a procedure with a quick visual recovery, they should consider LASIK, SMILE or ICL instead of PRK, for example.

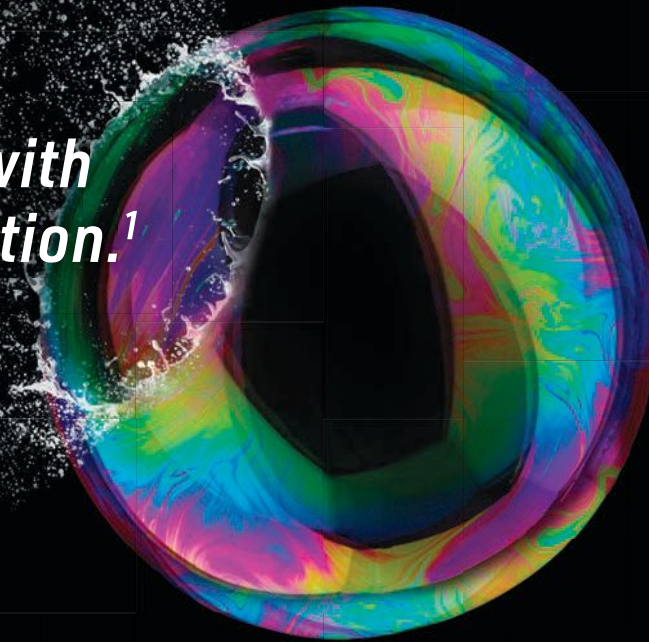
After getting a detailed history from the patient, the comprehensive anterior segment examination is next. The most common thing we see that changes the surgical plan are scars on the cornea from contact lenses. If a corneal opacity is present, a deeper LASIK interface could be employed. PRK could be performed and potentially remove some of the scar, or we could bypass touching the cornea altogether and consider an ICL.

ICLs are a great procedure for those with moderate to high amounts of myopia, especially when considering their future vision milestones. We know everyone will get cataracts if they live long enough. When a -9D patient has LASIK, the question is: will they be a candidate for a trifocal lens when they get cataracts several decades down the road? What would the spherical aberrations of the cornea measure after -9D LASIK? Some would think that due to the corneal appearance/aberrations, they would not be a candidate for a trifocal lens. In our practice, moderate to severe myopic patients typically choose ICLs because when they get cataract surgery as they get older, they

tyrvaya™
(varenicline solution)
nasal spray 0.03 mg

NOW APPROVED

*Dry eye starts with
tear film disruption.¹*




*Treat by activating
tear film production.²*

INTRODUCING A WHOLE NEW WAY TO TREAT DRY EYE DISEASE.²

Tyrvaya™, the first and only nasal spray approved to treat the signs and symptoms of dry eye, is believed to activate the trigeminal parasympathetic pathway via the nose, resulting in increased tear film production.² The exact mechanism of action is unknown at this time.

Watch Tyrvaya in action at Tyrvaya-pro.com.



INDICATION

Tyrvaya™ (varenicline solution) Nasal Spray is indicated for the treatment of the signs and symptoms of dry eye disease.

Please see Brief Summary of Prescribing Information on the adjacent page and the full Prescribing Information at Tyrvaya-pro.com.

IMPORTANT SAFETY INFORMATION

Adverse Reactions

The most common adverse reaction reported in 82% of patients was sneezing. Events that were reported in 5-16% of patients were cough, throat irritation, and instillation-site (nose) irritation.

References: 1. Craig JP, Nelson JD, Azar DT, et al. *Ocul Surf.* 2017;15(4):802-812. 2. Tyrvaya. Prescribing Information. Oyster Point Pharma; 2021.

© 2021 Oyster Point Pharma, Inc. Oyster Point™, the Oyster Point logo, Tyrvaya™ and the Tyrvaya logo are trademarks of Oyster Point Pharma, Inc. All rights reserved. OP-TYR-000867 10/21



BRIEF SUMMARY: Consult the full Prescribing Information for complete product information available at www.tyrvaya-pro.com.

INDICATIONS AND USAGE

TYRVAYA™ (varenicline solution) nasal spray is a cholinergic agonist indicated for the treatment of the signs and symptoms of dry eye disease.

ADVERSE REACTIONS

Clinical Trials Experience: Because clinical trials are conducted under widely varying conditions, adverse reaction rates observed in the clinical trials of a drug cannot be directly compared to rates in the clinical trials of another drug and may not reflect the rates observed in practice.

In three clinical trials of dry eye disease conducted with varenicline solution nasal spray, 349 patients received at least 1 dose of TYRVAYA. The majority of patients had 31 days of treatment exposure, with a maximum exposure of 105 days.

The most common adverse reactions reported in 82% of TYRVAYA treated patients was sneezing. Other common adverse reactions that were reported in >5% of patients include cough (16%), throat irritation (13%), and instillation-site (nose) irritation (8%).

USE IN SPECIFIC POPULATIONS

Pregnancy: Risk Summary: There are no available data on TYRVAYA use in pregnant women to inform any drug associated risks. In animal reproduction studies, varenicline did not produce malformations at clinically relevant doses.

All pregnancies have a risk of birth defect, loss, or other adverse outcomes. In the US general population, the estimated background risk of major birth

defects and miscarriage in clinically recognized pregnancies is 2% to 4% and 15% to 20%, respectively.

Data: Animal Data: Pregnant rats and rabbits received varenicline succinate during organogenesis at oral doses up to 15 and 30 mg/kg/day, respectively. While no fetal structural abnormalities occurred in either species, maternal toxicity, characterized by reduced body weight gain, and reduced fetal weights occurred in rabbits at the highest dose (4864 times the MRHD on a mg/m² basis).

In a pre- and postnatal development study, pregnant rats received up to 15 mg/kg/day of oral varenicline succinate from organogenesis through lactation. Maternal toxicity, characterized by a decrease in body weight gain, was observed at 15 mg/kg/day (1216 times the MRHD on a mg/m² basis). Decreased fertility and increased auditory startle response occurred in offspring at the highest maternal dose of 15 mg/kg/day.

Lactation: Risk summary: There are no data on the presence of varenicline in human milk, the effects on the breastfed infant, or the effects on milk production. In animal studies varenicline was present in milk of lactating rats. However, due to species-specific differences in lactation physiology, animal data may not reliably predict drug levels in human milk.

The lack of clinical data during lactation precludes a clear determination of the risk of TYRVAYA to an infant during lactation; however, the developmental and health benefits of breastfeeding should be considered along with the mother's clinical need for TYRVAYA and any potential adverse effects on the breastfed child from TYRVAYA.

Pediatric Use: Safety and efficacy of TYRVAYA in pediatric patients have not been established.

Geriatric Use: No overall differences in safety or effectiveness have been observed between elderly and younger adult patients.

Feature REFRACTIVE SURGERY

can have the ICL and cataract removed, leaving an otherwise unaltered cornea. This maintains all options for any type of presbyopia-correcting IOL the patient may desire in the future.

“What would you do for a 9D myopic presbyope or emerging presbyope?” Remember that the ICL goes in front of the crystalline lens in the ciliary sulcus. Hence, we don't see any posterior segment changes in volume, movement of the vitreous humor or resultant traction of the peripheral retina at the vitreous base. Refractive lens exchange in a -9D 41-year-old could potentially cause vitreoretinal changes; consequently, we typically choose the ICL for these patients, especially if they are younger than 50 with long axial lengths and increased risk for peripheral retinal pathology.

Setting Expectations

“Will I see 20/20 after the procedure? Will I go blind?” These are other common questions patients ask us. As far as visual acuity expectations, LASIK has come a long way the past 30 years and we have yet to find a case of someone going blind from LASIK. Way back in 1999, the data presented to the FDA to gain approval for LASIK showed a 50% chance of getting a patient to 20/20 vision. Fast-forward to the use of modern techniques and laser systems and nearly all patients can expect to achieve 20/20 uncorrected vision. In a recent study, 95% of patients were 20/20 after LASIK.¹³ SMILE is no different, with 95% of patients 20/20 one-day post-op.¹³ In our data presented at Optometry's Meeting 2021, we observed that the patient's vision was the same for the ICL procedure one day after surgery as well.¹⁴

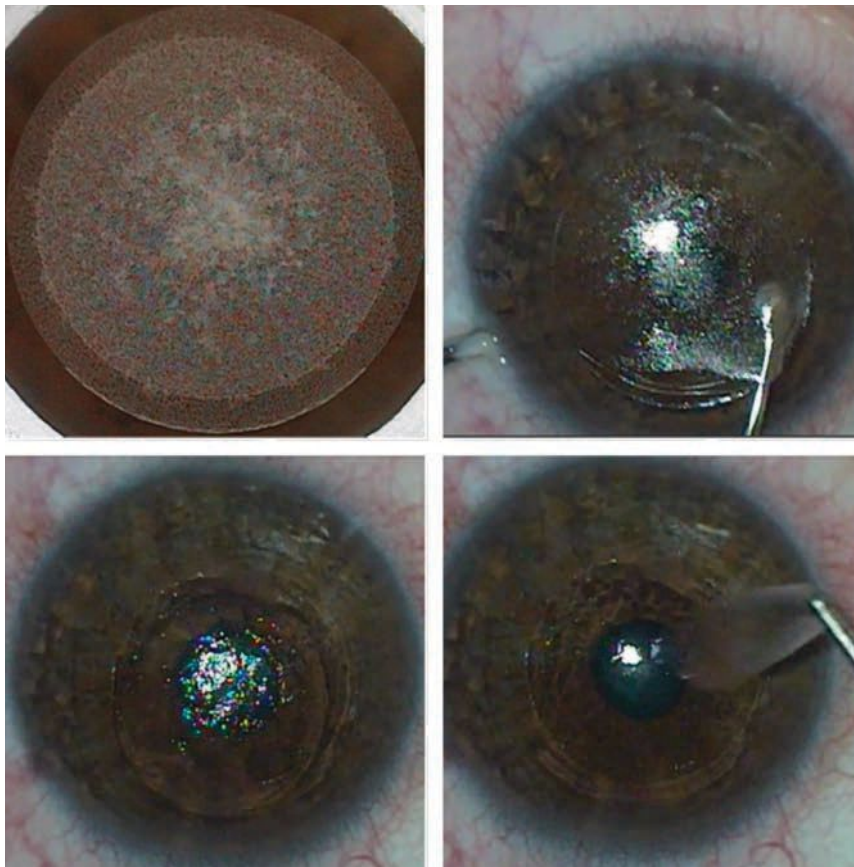
Despite these incredibly safe and predictable outcomes with modern technology, managing post-op expectations is still very important. If a patient is not given proper expectations, they may think they are dealing with complications when in fact what they're experiencing is a completely normal part of the recovery.

For our laser procedures, transient dryness is the most common symptom in the early preoperative period. Interestingly, the PROWL study found that patients are



Manufactured for: Oyster Point Pharma, Inc. 202 Carnegie Center, Suite 109, Princeton, NJ 08540
For more information visit www.tyrvaya-pro.com.
To report an adverse event, contact 1-877-EYE-0123.
Tyrvaya™, the Tyrvaya logo, Oyster Point™ and the Oyster Point logo are trademarks of Oyster Point Pharma Inc.
©2021 Oyster Point Pharma, Inc. All Rights Reserved.
Issued: Oct 2021

OP-TYR-000867 10/21



The SMILE procedure creates (top left), dissects (top right) and removes a lenticule (bottom left and right) to correct myopia and myopic astigmatism.

actually three times more likely to see improvement in dry eyes with modern LASIK compared to baseline in contact lenses.² While this seems shocking at first, it is ultimately not surprising because we see patients coming in who seek an alternate solution for their vision due to dryness and intolerance to contact lens wear very commonly.

That said, dryness after LASIK—especially short-term—is the number one complaint we hear during the early post-op period. When treating the ocular surface appropriately both preoperatively and postoperatively, patients can obtain great outcomes as the tear film continues to improve during the first three to six months. Overall, we typically see less dryness with SMILE and ICL compared to LASIK, potentially due to less nerves being impacted during the procedure.¹³

Another benefit of SMILE is that the post-op restrictions are minimal due to use of a small incision, which limits loss

of cornea integrity. Whereas we typically advise LASIK patients to stay out of public swimming water, avoid getting sweat in their eyes and avoid face makeup for at least a week, SMILE has almost no restrictions and patients are able to go back to all of those activities by the first day post-op.

Of all the different procedures in this group, the one that takes the longest to heal with the most hand-holding and reassurance is PRK. Patients need to know about recovery restrictions and plan to take a few days off from work during the first several days while the epithelium repopulates the surface of the cornea.

For our presbyopic patients, expectations around time needed for neuroadaptation is critical to success. For example, in our RLE and cataract patients, we inform them about the halos they can see at night from the diffractive rings of trifocal IOLs. The halos will continue to improve

over time, generally within three to six months. Once they get used to headlight halos, these are some of the happiest patients we see. This clinical observation was evaluated in one study where functional MRI was used to assess neuroadaptation to multifocal IOLs.¹⁵ The study found that neuroadaptation occurred over time and was consistent with decreases in questionnaire symptom scores.¹⁵

Takeaways

Ultimately, we want happy patients. We know that as long as we take care of patients while managing their expectations, they will be ecstatic with the outcome. Marrying the right procedure and the right expectations with the right patient is the key to their happiness. ■

1. Price MO, Price DA, Bucci FA, Jr., et al. Three-year longitudinal survey comparing visual satisfaction with LASIK and contact lenses. *Ophthalmology*. 2016;123(8):1659-66.
2. Eydelman M, Hilmantel G, Tarver ME, et al. Symptoms and satisfaction of patients in the patient-reported outcomes with laser in situ keratomileusis (PROWL) studies. *JAMA Ophthalmol*. 2017;135(1):13-22.
3. Solomon KD, Fernandez de Castro LE, et al. LASIK world literature review: quality of life and patient satisfaction. *Ophthalmology*. 2009;116(4):691-701.
4. Ferreira TB, Ribeiro FJ, Silva D, et al. Comparison of refractive and visual outcomes of three presbyopia-correcting intraocular lenses. *J Cataract Refract Surg*. July 21, 2021. [Epub ahead of print.]
5. Sarver EJ, Sanders DR, Vukich JA. Image quality in myopic eyes corrected with laser in situ keratomileusis and phakic intraocular lens. *J Refract Surg*. 2003;19(4):397-404.
6. Gambato C, Ghirlando A, Moretto E. Mitomycin C modulation of corneal wound healing after photorefractive keratectomy in highly myopic eyes. *Ophthalmology*. 2005;112(2):208-18.
7. Carones F, Vigo L, Scandola E, Vacchini L. Evaluation of the prophylactic use of mitomycin-C to inhibit haze formation after photorefractive keratectomy. *J Cataract Refract Surg*. 2002;28(12):2088-95.
8. Shalaby A, Kaye GB, Gimbel HV. Mitomycin C in photorefractive keratectomy. *J Refract Surg*. 2009;25(1 Suppl):S93-7.
9. Rampat R, Gatinel D. Multifocal and extended depth-of-focus intraocular lenses in 2020. *Ophthalmology*. 2021;128(11):e164-85.
10. Rodov L, Reitblat O, Levy A. Visual outcomes and patient satisfaction for trifocal, extended depth of focus and monofocal intraocular lenses. *J Refract Surg*. 2019;35(7):434-40.
11. Rosen E. Risk management for rhegmatogenous retinal detachment following refractive lens exchange and phakic IOL implantation in myopic eyes. *J Cataract Refract Surg*. 2006;32(5):697-701.
12. Arevalo JF, Lasave AF, Torres F, Suarez E. Rhegmatogenous retinal detachment after LASIK for myopia of up to -10 diopters: 10 years of follow-up. *Graefes Arch Clin Exp Ophthalmol*. 2012. 250(7):963-70.
13. Hamilton DR, Chen AC, Khorrami R, et al. Comparison of early visual outcomes after low-energy SMILE, high-energy SMILE, and LASIK for myopia and myopic astigmatism in the United States. *J Cataract Refract Surg*. 2021;47(1):18-26.
14. Saenz B, Mueller B, Abraham N, Parkhurst G. Toric ICL: early United States experience 2018. Poster. *Optometry's Meeting 2021*.
15. Rosa AM, Miranda AC, Patricio MM, et al. Functional magnetic resonance imaging to assess neuroadaptation to multifocal intraocular lenses. *J Cataract Refract Surg*. 2017;43(10):1287-96.

REAL-WORLD PERFORMANCE OF NEWER INTRAOCULAR LENSES

A perspective on four recent additions and how to recommend them to your patients based on their expectations and visual requirements.



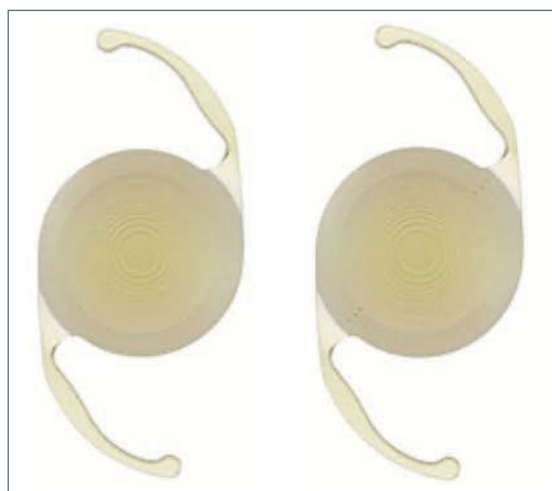BY ALEXANDRA LOVOY, OD
BELLAIRE, TX

Cataracts are one of the leading causes of blindness in the United States and the world, and a diagnosis we—as optometrists—likely encounter daily.¹ When educating patients on their diagnosis and logistics of cataract surgery, patients can become easily overwhelmed, and that's before even mentioning they have multiple intraocular lens (IOL) options. If cost is no object, when presented with the option of wearing glasses postoperatively vs. being glasses-free (or at least less dependent on them), most patients pick the latter. Luckily, improvements in IOL technology are helping us to deliver on that desire.

Along with keratometry and biometry measurements, a carefully executed, complete eye exam is an important step that can guide a physician in recommending a particular lens. Starting the conversation with patients begins by knowing how regular their ocular

surface is, and whether there are conditions present that can impact post-op visual acuity and patient satisfaction.

Here, I'll offer my perspective on five of the newest IOLs available today: Alcon AcrySof IQ PanOptix Trifocal IOL, Johnson & Johnson Vision Tecnis Synergy IOL, Alcon AcrySof IQ Vivity Extended Vision IOL, Johnson & Johnson Tecnis Eyhance IOL and the Light Adjustable Lens made by RxSight. These are my anecdotal impressions based on our patient base.



PanOptix and PanOptix Toric IOL.

PanOptix

PanOptix was the first trifocal IOL and FDA-approved in 2019; it can correct 1.03D to 2.57D of corneal astigmatism.² It is designed to allow for clear distance, intermediate and near-vision. The manufacturer says optics behind the lens involve diffractive rings imprinted on the surface that bend and split light to allow all ranges of vision.³ The rings cause side effects such as glare and halos, which can be a problem while driving at night due to oncoming headlights and stoplights. Postoperative visual acuity is generally in the range of 20/20 to 20/25 while measuring the eyes independently, 20/20 with both eyes at distance and J1-J1+ at near.

Although patients can function without glasses, when one eye is working to see distance, intermediate and near the quality of the vision may be marginally worse than with a monofocal lens at whatever target it was intended to correct. Habitual hyperopes and high myopes are generally ecstatic with the quality of their

About the author

Dr. Rojas graduated cum laude from University of the Incarnate Word Rosenberg School of Optometry. She completed her residency in ocular disease and refractive surgery at Eye Center of Texas in Houston and practices at Slade & Baker Vision, a refractive and cataract surgery practice in Houston. She has no financial disclosures.


near-vision, but myopes who were -2.00 D to -4.00 D preoperatively need to be educated that they will lose their “superpower near.”

In my experience, naturally near-sighted patients are still happy with the PanOptix lens, but more often than not they comment that they could see slightly clearer without their glasses preoperatively.

Although near acuity is great in the right environment, the PanOptix lens struggles in dim environments and/or when reading small, fine print. An example I give to patients is while reading a menu at a nice but dim restaurant, they may need to use a low-powered pair of readers. If patients are receptive to these sacrifices for a large degree of glasses independence, the PanOptix IOL is a fantastic option.

The aforementioned glare and halos are a side effect that, if not discussed preoperatively, has the potential to create an unhappy patient postoperatively. Most patients mention the dysphotopsias in the interim between their two surgeries. Once the lens is implanted in both eyes, the brain tends to adapt to the change over time and few patients mention them past one-month post-op. The ones who do notice them long-term are generally so happy with the quality of their uncorrected vision that the glare and halos are a sacrifice they're willing to make.

If the patient is still happy with the idea of the PanOptix IOL after mentioning the expected vision and side effects, the rest of their ocular health needs to be essentially pristine with regular topography and normal macular and optic nerve OCT scans. Unfortunately, patients with history of LASIK, photorefractive keratectomy (PRK), radial keratotomy (RK) and any other refractive surgeries are also not great candidates for the PanOptix IOL. Every case is different, but typically once the cornea has been permanently altered, it makes choosing the power of the IOL more difficult and acuity more unpredictable. The Optiwave Refractive Analysis system (ORA) is a tool to improve postoperative results by



The Synergy IOL can correct 1.03D to 2.57D of corneal astigmatism.

measuring the refractive power of the eye in its aphakic state. The ORA can reduce the unpredictability of picking the lens power; however, I still err on the side of caution in recommending the PanOptix to patients with history of refractive surgery.

About 80% of every cataract evaluation I see also has some form of dry eye disease. It is imperative to treat dry eye prior to surgery to ensure the most accurate keratometry and biometry measurements. I typically keep patients on therapy for four to six weeks, then have them return to repeat measurements before the final lens is picked for surgery, ensuring the best outcomes. Depending on the patient and the degree of dry eye, I either recommend autologous serum tears or Restasis (cyclosporine A ophthalmic emulsion 0.05%, Allergan)/ Xiidra (lifitegrast ophthalmic solution 5%, Novartis) in combination with a steroid.

Even if a patient seems like the perfect PanOptix candidate on paper, it's important to ensure they have realistic expectations. Those who demand high-quality distance vision, such as pilots, truck drivers and engineers, should steer clear of a trifocal lens due to the side effects. Patients who seem hesitant about the glare and halos should also select a different IOL because they will be more sensitive to being bothered postoperatively.

Although there are situations when the PanOptix is not the best choice, it

is still the first premium lens I recommend to patients who are the right candidates. The “wow” factor at the day one postoperative visit and the quality of the vision are hard to question.

Synergy

The Tecnis Synergy IOL was FDA-approved in April of 2021 and is the newest IOL from Johnson & Johnson Vision that incorporates technology of its family members, the Tecnis Multifocal and the Tecnis Symphony, that the manufacturers says will allow for improved near visual acuity and less nighttime glare and halos.⁴ The Toric Synergy lenses can correct 1.03D to 2.57D of corneal astigmatism. According to the company, the Synergy allows for the widest range of continuous vision with best near, continuous vision defined as a visual acuity of 20/32 or better.⁵

In practice, I find postoperative acuity to be similar to what the company states and competitive with that of the PanOptix lens. I've found the improved near visual acuity is a benefit to the -2.00D to -4.00D myopes who may be disappointed with the quality of near vision with the PanOptix.

The Synergy's older sister, the Symphony, had a problem with nighttime photopic phenomena, including “spiderweb” effects that made it difficult to drive at night. The Synergy lens is said to have mitigated this effect from the combination of the echelette surface design and “achromatic technology,” which are said to reduce the intensity and incidence of glare and halos.⁵

Although my sample size is small because the IOL is so new, around half the patients I've seen have mentioned trouble driving at night even after the one-month post-op visit. However, most who had complaints were not good candidates for the Synergy due to mild refractive amblyopia, untreated dry eye or similar concerns. As previously mentioned, picking an ideal candidate for a multifocal lens is important for post-

op success. Although I've had more experience with the PanOptix, I'm looking forward to managing more Synergy patients in the future.

Vivity

Alcon's Vivity IOL was FDA approved in 2020 and is the first non-diffractive extended depth-of-focus (EDOF) lens. Vivity Toric IOLs can correct between 1.03D to 2.06D of corneal astigmatism.⁶ The extended vision comes from a design feature Alcon calls "X-Wave technology," which adds a one micron elevated smooth plateau centrally that behaves like a monofocal lens.⁶ The non-diffractive nature of the lens greatly diminishes the incidence of nighttime photopic phenomena of the PanOptix and Synergy lens, with the sacrifice of less near visual acuity. Uncorrected distance visual acuity is comparable to that of a monofocal distance lens, intermediate acuity is 20/20 to 20/25, but the J1 acuity expected out of a PanOptix or Synergy, is J4-J5 with the Vivity.

Although the near acuity isn't as impressive, the Vivity serves patients with a high-distance demand, such as truck drivers and hunters, extremely well due to the clarity of vision at distance and minimal glare and halos. On the other hand, patients who read often or work with numbers need to be educated that reading glasses will likely be required for those tasks.

Where the Vivity lens truly shines is in the presence of mild ocular disease and patients with history of refractive surgery. Given the absence

of diffractive rings that split light, this lens is more forgiving for conditions such as mild glaucoma with a non-central visual field defect, mild dry age-related macular degeneration and mild Fuchs' endothelial dystrophy. Because the Vivity has similar optics to a monofocal lens, most every patient who is a candidate for a monofocal is also a candidate for the Vivity.

In my experience, patients have been extremely happy with the range that the Vivity allows. The positive feedback has influenced me to recommend it to any patient who is not a candidate for a trifocal lens as long as they are counseled appropriately.

Eyhance

Johnson & Johnson's Eyhance was FDA approved in February 2021; it is a monofocal lens designed to slightly extend depth of focus compared with the Tecnis monofocal ZCB00.⁷ Eyhance Toric IOLs can correct between 1.03D to 4.11D of corneal astigmatism, according to J&J.⁷ The lens is designed with an aspheric anterior surface that creates a continuous increase in power within the central 1mm diameter. Distance vision is equivalent to a monofocal lens, but patients can appreciate an increase in intermediate vision.

A study comparing the Eyhance to the Symphony found uncorrected monocular and binocular distance vision and binocular intermediate vision to be the same between the two.⁸ The Symphony lens had improved uncorrected near vision, but also had more incidence of halos and glare.⁸

Eyhance would benefit patients who cannot afford an EDOF lens, especially those that have high intermediate vision demands.

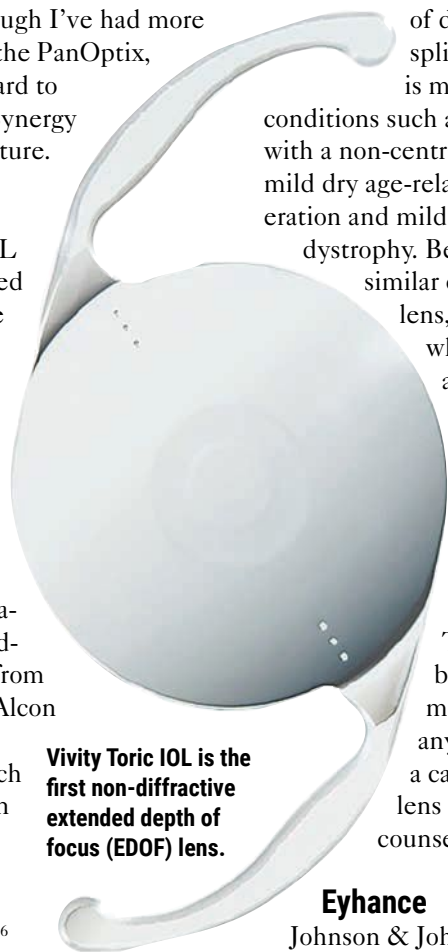
Light Adjustable Lens

RxSight's Light Adjustable Lens (LAL) was FDA approved in 2017 and is the only IOL that can be adjusted after cataract surgery to optimize uncorrected visual acuity.⁹ Because it is a monofocal, all astigmatism and any residual spherical correction is treated postoperatively. The lens is composed of ultraviolet (UV) light-sensitive polymers that the manufacturer says migrate when exposed to UV, changing the shape of the lens and allowing physicians to treat myopia, hyperopia and astigmatism.⁹

The company's Light Delivery Device (LDD) is used to deliver the treatment, the first adjustment generally occurring two to three weeks after cataract surgery, with each subsequent adjustment occurring in three-day increments. Between three to five treatments can be made, each lasting 40 to 120 seconds. For the lens to maintain its shape between adjustments, patients must wear UV-blocking glasses while indoors and sunglasses while outdoors during all waking hours. Optometrists are able to handle this step.

With each LDD adjustment, physicians can treat -2.00D to +2.00D sphere and up to 2.00D of astigmatism. Once desired refraction is achieved, the patient will receive either one or two lock in treatments, in which the UV-sensitive macromers will be used to prevent refractive changes in the future.⁹

The biggest advantage to the LAL is spelled out in its name: the ability to adjust the lens. Practitioners who have trouble measuring consistent keratometry and biometry readings in patients who have had refractive surgery, especially RK, can pick the IOL power with more peace of mind knowing it can be adjusted. If a patient is not a candidate for an EDOF or multifocal implant, the LAL—although a monofocal—can help give patients some degree of spectacle independence through a monovision approach.



Vivity Toric IOL is the first non-diffractive extended depth of focus (EDOF) lens.

EYE PROMISE

together, we can make a difference

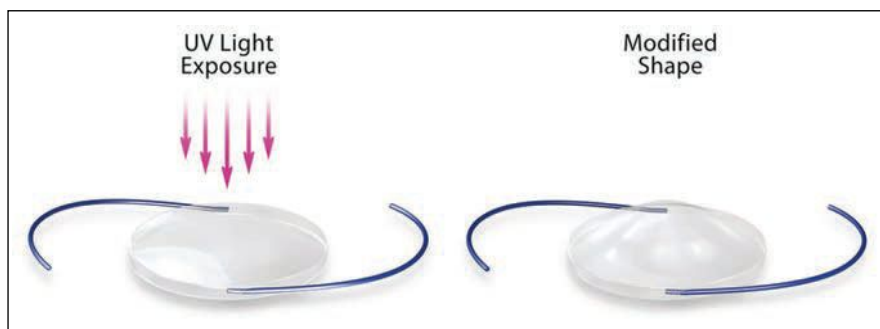The ability to see is a powerful gift. With it, life is full of potential. Without it, people around the world struggle to hold a job and provide for a family.

The ability to give sight to someone is even more powerful. Please consider supporting the most basic of human rights. We cannot transform lives through better vision without your generosity.

Please visit givingsight.org to help us continue the fight against preventable blindness.



OPTOMETRY
giving sight



RxSight's Light Adjustable Lens (LAL) is composed of UV light-sensitive polymers. An advantage to LALs is that ODs have the ability to adjust the lens postoperatively.

I hesitate to set a patient's target to monovision if they have not had success in the past with contact lenses due to problems with adaptation. The ability to adjust the prescription makes it easier to ease a patient into monovision and gives us the opportunity to switch back to a distance or near target with poor adaptation. In my experience, most patients tolerate monovision and end up somewhere around 20/20 and J1 at distance and near, respectively.

Because the IOL is susceptible to UV light, patients must wear UV-blocking glasses full-time indoors and outdoors until their prescription is locked in. If patients are not compliant with the glasses, the polymers in the lens can move and make the subsequent light adjustments more difficult to achieve. This can lead to poor uncorrected visual acuity. So, if patients are hesitant about the glasses, it may be more beneficial to steer them toward a different option.

Patients must also be aware that their visual acuity prior to any treatments will be limited by their uncorrected astigmatism. If a patient requires excellent visual acuity within one-week post-op for whatever reason, the LAL is not the best option.

Although many are candidates for the LAL, there are several situations in which a candidate is not eligible to receive it. Patients taking systemic medications that can increase sensitivity to UV light such as tetracyclines, amiodarone, hydroxychlorothiazide are not candidates for the LAL due to potential phototoxic effects to

the eye.⁹ Similarly, patients taking medication that can be toxic to the retina, such as tamoxifen, are at risk for retinal damage during light treatments. Those with a history of ocular herpes simplex virus are at risk of reactivation from UV light exposure, and patients with nystagmus may not be able to fixate during treatments which can lead to poor uncorrected visual acuity.

Due to the amount of follow-up appointments and necessity for UV-blocking glasses full-time in the postoperative period, I recommend the LAL most often to patients who have had RK. As previously mentioned, their amount of astigmatism is unpredictable. Through use of the LDD, data shows only 1.3% of patients are left with uncorrected visual acuity of 20/32 or worse, compared to 10.9% with the Tecnis toric and 16.6% with the AcrySof toric.¹⁰⁻¹² Time spent in office with adjustments can be a burden to the patient as well.

I must carefully refract the patient and, if trialing monovision, ensure they are happy with their vision with a trial frame. After the patient and I are happy with the target, the pupils must be dilated to 7mm to receive full treatment, which can sometimes take two or three doses of mydriatic drops. Although the time in front of the LDD is only minutes, on a busy clinic day the patient can be in the office for up to three hours. If a patient is a candidate for any of the other options discussed, I have a hard time recommending the LAL due to the demanding post-op care.

Takeaways

With the advent of new IOLs, many cataract patients can live a life less dependent on glasses. As the practitioner who generally spends more time with patients, it is our responsibility to ensure they know what their options are and what lens you recommend for them based on their lifestyle, personality and needs. Communicating that information to the surgeon will help make the sometimes stressful process easier and faster.

As long as patients are educated appropriately and expectations are set up for what to expect before surgery, there is no reason to avoid recommending these lenses. ■

1. Causes of blindness and vision impairment in 2020 and trends over 30 years: evaluating the prevalence of avoidable blindness in relation to Vision 2020: the Right to Sight: an analysis for the Global Burden of Disease Study. *Lancet Glob Health*. 2021;9(2):e144-60.

2. AcrySof IQ PanOptix Trifocal and Toric Trifocal Intraocular Lens. U.S. Food and Drug Administration. www.fda.gov/medical-devices/recently-approved-devices/alcon-laboratories-inc-acrysof-iq-panoptix-trifocal-intraocular-lens-model-hfnt00-and-acrysof-iq. September 19, 2019. Accessed November 30, 2021.

3. Sudhir RR, Dey A, Bhattacharyya S, Bahulayan A. AcrySof IQ PanOptix intraocular lens vs. extended depth of focus intraocular lens and trifocal intraocular lens: a clinical overview. *Asia Pac J Ophthalmol (Phila)*. 2019;8(4):335-49.

4. Tecnis Synergy Intraocular Lenses—P980040/S124. U.S. Food and Drug Administration. www.fda.gov/medical-devices/recently-approved-devices/tecnis-synergym-intraocular-lens-iol-model-zfr00v-tecnis-synergym-toric-iol-models-zfw150. Accessed November 30, 2021.

5. J&J Vision. Tecnis Synergy IOL. www.jnjvisionpro.com/synergy. Accessed November 30, 2021.

6. Alcon Vivity EDof Lens starts its rollout in the United States. *Rev Ophthalmol*. www.reviewofophthalmology.com/article/alcon-vivity-edof-lens-starts-its-rollout-in-the-united-states. February 12 2021. Accessed November 30, 2021.

7. J&J Vision. Tecnis Eyhance IOL. www.jnjvisionpro.com/eyhance. Accessed November 30, 2021.

8. Corbelli E, Iuliano L, Bandello F, Fasce F. Comparative analysis of visual outcome with three intraocular lenses. *J Cataract Refract Surg*. May 26, 2021. [Epub ahead of print.]

9. RxSight. www.rx sight.com/us. Accessed November 30, 2021.

10. RxSight P160055: FDA Summary of Safety and Effectiveness Data. www.accessdata.fda.gov/cdrh_docs/pdf16/P160055B.pdf. Accessed November 30, 2021.

11. Tecnis Toric PMA P980040/S039: FDA Summary of Safety and Effectiveness Data. www.accessdata.fda.gov/cdrh_docs/pdf/P980040S039B.pdf. Accessed November 30, 2021.

12. AcrySof Toric P930014/S45: FDA Summary of Safety and Effectiveness Data. www.accessdata.fda.gov/cdrh_docs/pdf/P930014S045B.pdf. Accessed November 30, 2021.

13. Ajamian PC. Near and Far. *Rev Optom*. 2021;158(1):26.

SECO **2022**

WHERE SIGHT MEETS VISION™
MARCH 9-13 | NEW ORLEANS

TITLE PARTNER **Alcon**
SEE BRILLIANTLY



THE EDUCATION DESTINATION

Get a first look at the research, technology, and techniques that are evolving patient care and propelling the optometric profession forward. Whether you are looking for the latest in clinical advancements or business management solutions, you will find the speakers, education, solutions, and connections you need to stay on the cutting edge.

MARCH 9-13
NEW ORLEANS
ERNEST N. MORIAL CONVENTION CENTER

REGISTER TODAY AT
attendseco.com

A STEP-BY-STEP GUIDE TO CATARACT POST-OP CARE

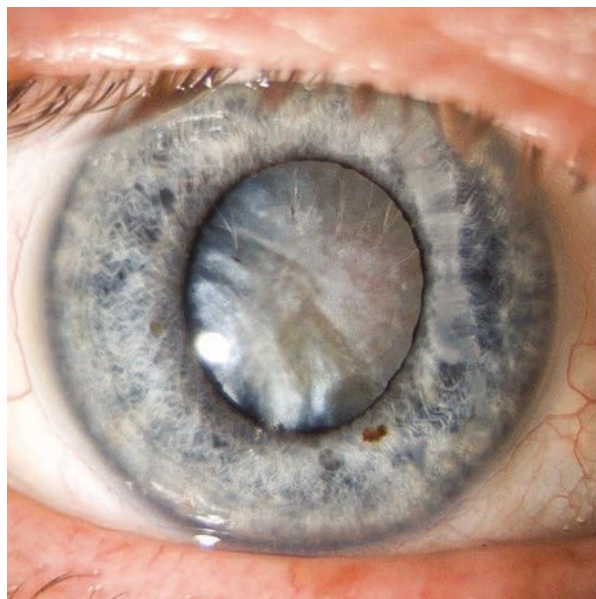Understand what to expect and act on at every management stage.



GLEB SUKHOVOLSKIY, OD
TACOMA, WA

Many optometrists are active in the comanagement of cataract surgery. A multitude of surgical practices around the country involve the patients' primary optometrists in the postoperative process. Receiving post-op care in a familiar setting by a doctor they know and trust allows the patient to feel comfortable during such a stressful event in their life. It also results in a smoother transition back to their routine eye care, where the management of patients' other eye conditions can be continued without much interruption.

In order to maintain patients' trust and confidence, optometrists must continue to be well-versed in the postoperative management of cataract surgery. Fortunately, many of the issues that arise during the postoperative process do not require surgical intervention and can be successfully



ODs can contribute to post-op cataract care by adopting a few simple procedures to allow for appropriate observation.

addressed by optometrists. This article will act as a short step-by-step guide to help you stay up-to-date and be able to anticipate postoperative issues in the order they generally arise.

Early Post-op Period (One to Four Days)

Some studies have questioned the need for a one-day post-op visit after

uncomplicated cataract surgery, given the expected low risk of complications.¹ However, it is still part of many surgeons' postoperative protocols. There are several important things that need to be assessed at this early visit.

First, evaluate the eye for a wound leak. Cataract surgery may be performed through either a corneal, limbal or scleral incision. Clear corneal incisions (CCIs) have become a lot more common than scleral tunnel incisions over the last two decades.² While CCIs have their advantages, they are inherently weaker and are more likely to be leaky.³ "Painting" the incision site with a fluorescein strip to check for a Seidel sign would help identify a leaky wound. Mild leaks that are present a day after surgery often seal themselves.

Temporarily stopping steroid drops, adding an aqueous suppressant and placing a bandage contact lens over the eye may help the incision seal quicker. In more severe cases, such as when intraocular pressure (IOP) is in the low single digits or the anterior

About
the author

Dr. Sukhovolskiy is a staff optometrist at Pacific Cataract and Laser Institute, practicing in Tacoma, WA. He has no financial disclosures.

chamber is flat or shallow, sending the patient back to the surgeon for wound resuturing is indicated.

Corneal edema may occasionally be present early on after cataract surgery. While it resolves on its own in the majority of cases, it can be a cause for concern for patients, many of whom expect better vision immediately post-op. Complicated surgery, advanced cataracts, underlying endothelial dystrophy, uveitis and endothelial trauma all can increase the risk of post-surgical corneal edema.⁴ Reassure patients regarding the temporary nature of this issue. It is safe and effective to use 5% sodium chloride as an adjunct for faster corneal recovery.⁵

A common early complication of cataract surgery is IOP spike. This is generally a self-limiting phenomenon and often resolves within 24 to 48 hours after surgery. Patients with healthy optic nerves tolerate these IOP spikes well without any noticeable optic nerve damage. Patients who have glaucoma tend to experience postoperative IOP spikes more frequently and are very susceptible to additional nerve damage.⁶ Generally, if IOP is 30mm Hg or above, initiate ocular anti-hypertensive medications (such as brimonidine, timolol and/or dorzolamide). Use oral acetazolamide in cases of extremely high IOP. Monitor the patient in the clinic to make sure the IOP is decreasing and then give them IOP-lowering drops to use at home. In most cases, IOP-lowering medication is not needed past a week and is discontinued at the next follow-up after control over IOP is achieved.

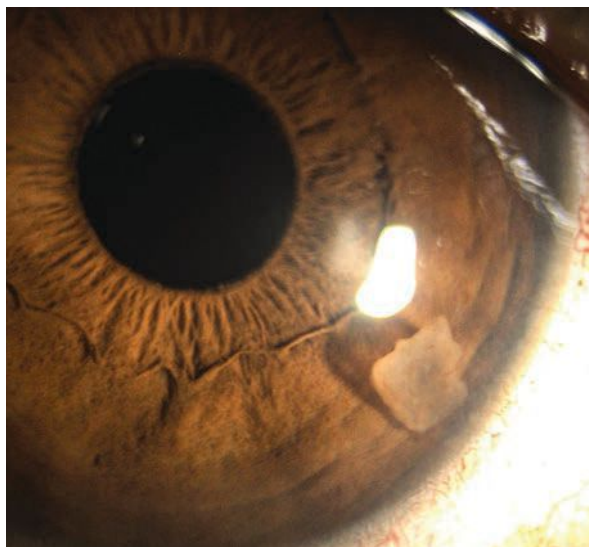A day-one post-op visit is also useful because it offers another opportunity to go over postoperative precautions, medication regimen and allows the patient to ask questions while being in the thick of it. Patients may report some discomfort in the first few days after the surgery. Some soreness and tenderness might be present for a day or two, usually improving noticeably with every sleep. If discomfort is significant, a short course of

oral acetaminophen or ibuprofen may be helpful. Inflammation can cause light sensitivity, so recommend sunglasses for when outside. Strenuous physical activity, makeup use and exposure to sitting water and other unclean environments should be avoided.

A typical postoperative medication regimen varies somewhat clinic to clinic but generally includes an antibiotic, a steroid and a non-steroidal anti-inflammatory (NSAID). These medications are commonly prescribed to patients in the form of eye drops, though they can also be administered via injection into the eye during the surgery. Referring optometrists should familiarize themselves with the medication regimen preferred by the surgical center that they work with in order to maintain good continuity of care.

In uncomplicated cases, the additional use of an NSAID drop may not bring about much benefit over using steroids alone, but in more complex cases, such as in patients with diabetes, uveitis and retinal and epiretinal issues, an NSAID may lower risk of cystoid macular edema (CME).⁷ Antibiotic drops are usually used for one week, while anti-inflammatory drops are usually continued for three to four weeks. Some practices initiate a steroid taper a couple of weeks after the surgery, while others recommend that the patient maintain initial frequency until the end.

Ocular surface discomfort, ranging from foreign body sensation to stinging, may last for two to four weeks, gradually improving. This generally results from the surgical stress to the eye and is more pronounced in patients with pre-existing dry eye issues. Copious artificial tears will help mediate such symptoms. Educate



Nuclear fragments post-op require surgical removal.

patients that cataract surgery may cause a temporary worsening of their dry eye. A course of cyclosporine or liftegrast may be helpful to get symptoms under control.

Subconjunctival hemorrhages are also common, especially with scleral tunnel incisions, where conjunctival tissue is altered. In patients who take blood thinners or have a clotting disorder, the hemorrhages may be more pronounced. These do not require treatment apart from reassurance and education, and are usually fully resolved after two weeks.

Intermediate Post-op Period (Five to 14 Days)

One of the most serious complications of cataract surgery, endophthalmitis, usually presents seven to eight days postoperatively.⁸ The incidence of acute endophthalmitis after cataract surgery has been steadily decreasing over the last few decades, and though it is incredibly rare, there has been an uptick with transition from scleral tunnel to clear corneal incisions.⁹

Patients who have acute postoperative endophthalmitis typically present with symptoms of blurry vision, red eye and severe pain. Dilated examination is important when such symptoms are reported. Vitreous inflammation will be obvious upon examination. A hypopyon is also present

in many cases.¹⁰ If endophthalmitis is suspected, notify the cataract surgeon immediately and refer to a retinal specialist for urgent treatment.

Occasionally, a small bit of lens may be left in the eye after the surgery. It may not be apparent at first, hiding behind the iris, but later may make its way into the anterior chamber. If the fragment is white and very fluffy, it is likely cortical. Small cortical fragments may resolve on their own with increased anti-inflammatory regimen. Increasing the steroid drop to every two hours schedule for a week or two may help resolve this issue. If the fragment larger or made of nuclear material (more yellow/brown and smooth), surgical removal is necessary. Whenever lens fragments are found, it is best to check with the surgeon regarding further management.

If a patient had significant corneal astigmatism, they may have received a toric intraocular lens (IOL). Toric IOLs have a small risk of rotation after the surgery, potentially resulting in subpar vision. The rotation is most likely to occur in the first week after the surgery.¹¹ It is best to verify toric IOL positioning one to two weeks postoperatively with a dilated exam. If the lens is in the right position, it

is unlikely to rotate in the future. If the patient's uncorrected vision is blurry and significant residual astigmatism is present, the patient should be sent back to the surgeon for an IOL rotation. IOL rotations are best performed within the first few weeks after the initial cataract

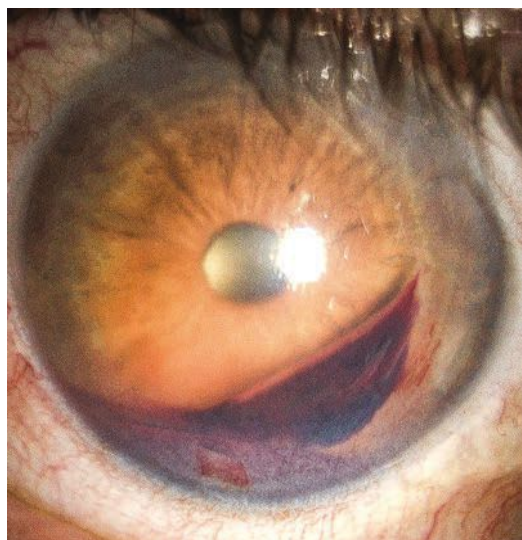Late Post-op Period (Two Weeks or More)

A complication with a more delayed onset is postoperative CME (also known as Irvine-Gass syndrome). It occurs about 1% to 2% of the time and usually takes several weeks after the surgery to develop.¹²

The risk of CME is higher in eyes with history of epiretinal membrane, retinal surgery, uveitis and in eyes that undergo a more complicated cataract surgery. It is best detected with a macular OCT and is usually identified when patient's vision does not seem to match pre-surgery potential acuity. In the majority of cases, a combination of topical steroid and topical NSAID will result in complete resolution within a few weeks.

Dilate all patients at the monthly follow-up to rule out CME, as well as any retinal tears or detachments.

Dysphotopsia is a term to describe a range of unwanted visual phenomena that result from light reflecting off the IOL onto the retina.¹³ Dysphotopsias can be positive, such as bright artifacts, flickering lights or halos, or negative, such as shadows or dark areas of visual field. Dysphotopsias are most noticeable in the temporal field of vision and are often



If hypema is mild, increasing the steroid dosage may help it clear faster.

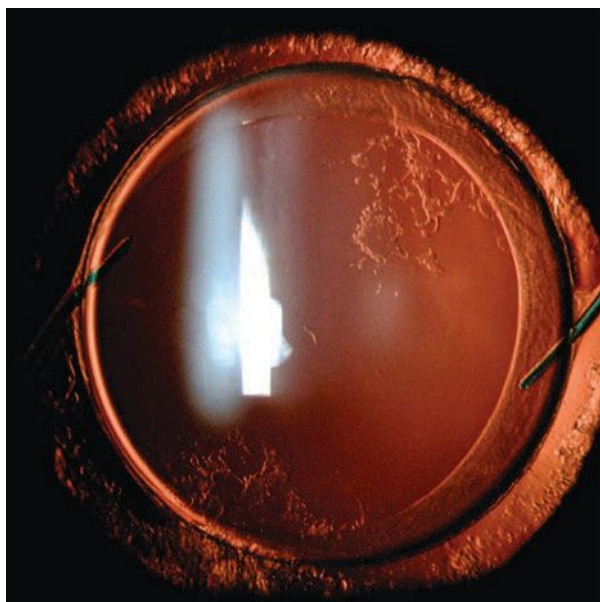
described by patients as a crescent, line or hair.

While dysphotopsias are commonly noted in the first few weeks after cataract surgery, they rarely persist long-term.¹⁴ This is largely due to neuroadaptation, when neural plasticity of the visual cortex allows it to ignore unwanted visual phenomena.¹⁵ The management of such symptoms mostly consists of education and reassurance that the visual disturbances will disappear on their own; however, the process of neuroadaptation may take up to six months.

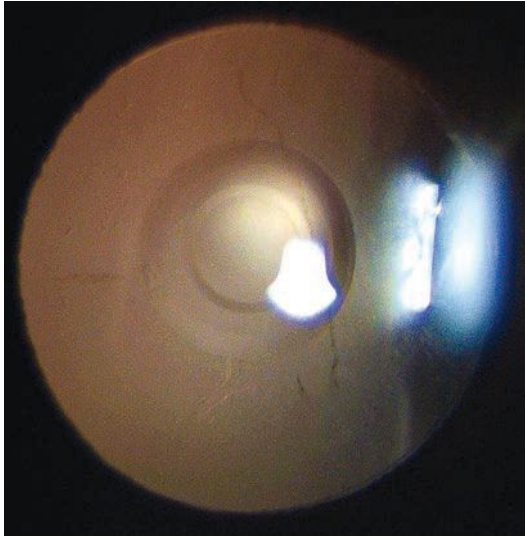
In a small number of people, dysphotopsia may remain bothersome months after cataract surgery. In those cases, send the patient back to the surgeon for consultation and discussion of options, which may include additional surgical treatment.

Minimally Invasive Glaucoma Surgeries (MIGS)

Cataract surgery is becoming increasingly intertwined with glaucoma procedures. Given that a large number of cataract patients also have glaucoma, these conditions are tightly aligned. Multiple MIGS procedures that are performed at the time of cataract surgery range from device implantation, such as the iStent Inject (Glaukos) or



Posterior capsular opacification may present months or years after cataract surgery and require YAG laser capsulotomy.



The Vivity IOL is one newer option for patients who want to limit their dependence on spectacles.

the Hydrus (Ivantis), to canaloplasties, such as the Omni surgical system (Sight Sciences) and iTrack (Ellex).

Evaluate physically implanted devices with gonioscopy one to two weeks postoperatively, to make sure appropriate stent positioning. Trabecular meshwork-bypass stents are most commonly placed in the nasal quadrant, due to a higher concentration of collector channel entrances in that area.¹⁶ It is best to avoid gonioscopy in the first week post-op to avoid applying pressure on the eye.

Causes of stent occlusion may include blood clots early after surgery or peripheral anterior synechiae in the months after the procedure. After surgery, it is recommended to remove glaucoma medications one by one in order to arrive at the minimum amount of drops necessary to maintain IOP at target.

Hyphema is not uncommon in the first week after the procedure.¹⁷ If hyphema is mild, no additional treatment is necessary. If hyphema is severe, a washout of anterior chamber may be needed, so further management of these patients should be discussed with the surgeon.

Presbyopia-correcting IOLs

An increasing number of patients opt for presbyopia-correcting IOLs in

order to have greater spectacle independence after cataract surgery. The last few years have witnessed a wave of new IOL designs becoming available in the United States: the Symphony and Synergy IOLs by Johnson & Johnson Vision and the Pan-Optix IOL and Vivity IOL by Alcon. Performance of presbyopia-correcting IOLs has improved drastically and more patients are candidates for such lenses, but there are still a few things to watch for.

The success of premium IOLs depends more on education and counseling prior to surgery than on postoperative

measures. Postoperatively, these patients may have higher expectations. It can take between one and four weeks for the visual acuity to reach optimal levels.

Each IOL has unique characteristics and differentiating between them is a topic for another article. To sum it up, most multifocal or extended depth-of-focus (EDOF) IOLs have diffractive rings designs, which may cause patients to see halos around lights in the dark. These are much less bothersome than those experienced with older generation lenses but can still cause issues for a small percentage of patients. Reassure patients that halos improve with neuroadaptation and encourage them to give it some time. Such symptoms greatly diminish over four to six months after the surgery.

The most common causes of dissatisfaction in patients with presbyopia-correcting IOLs are residual refractive error, dry eyes and halos, in that order.¹⁸ Refractive outcome is usually determined a month after the surgery. Manifest refraction should be done if the visual outcome is unsatisfactory. If significant residual refractive error is detected, send the patient back to be evaluated for surgical options—either a refractive procedure or an IOL exchange.

Takeaways

Optometrists are increasingly involved in the postoperative management of cataract surgery. Due to the continually evolving nature of this field, the onus is on us to keep up with best practices, technological advancements in order to serve our patients better. ■

1. Kessel L, Andresen J, Erngaard D, et al. Safety of deferring review after uneventful cataract surgery until two weeks postoperatively. *J Cataract Refract Surg.* 2015;41(12):2755-64.
2. Matossian C, Makari S, Potvin R. Cataract surgery and methods of wound closure: a review. *Clin Ophthalmol.* 2015;9:921-8.
3. Nichamin LD, Chang DF, Johnson SH, et al. ASCRS White Paper: What is the association between clear corneal cataract incisions and postoperative endophthalmitis?. *J Cataract Refract Surg.* 2006;32(9):1556-9.
4. Sharma N, Singhal D, Nair SP, et al. Corneal edema after phacoemulsification. *Indian J Ophthalmol.* 2017;65(12):1381-9.
5. Tzamalīs A, Deremenoudi M, Diafas A, et al. Safety and efficacy of hypertonic saline solution (5%) vs. placebo in the treatment of postoperative corneal edema after uneventful phacoemulsification: a randomized double-blind study. *Int Ophthalmol.* 2020;40(9):2139-50.
6. Tranos P, Bhar G, Little B. Postoperative intraocular pressure spikes: the need to treat. *Eye (Lond).* 2004;18(7):673-9.
7. Juthani VV, Clearfield E, Chuck RS. Non-steroidal anti-inflammatory drugs versus corticosteroids for controlling inflammation after uncomplicated cataract surgery. *Cochrane Database Syst Rev.* 2017;7(7):CD010516.
8. Cao H, Zhang L, Li L, Lo S. Risk factors for acute endophthalmitis following cataract surgery: a systematic review and meta-analysis. *PLoS One.* 2013;8(8):e71731.
9. Taban M, Behrens A, Newcomb RL, et al. Acute endophthalmitis following cataract surgery: a systematic review of the literature. *Arch Ophthalmol.* 2005;123(5):613-20.
10. Marmalis N. Endophthalmitis. *J Cataract Refract Surg.* 2002 May; 28(5):729-30.
11. Miyake T, Kamiya K, Amano R, et al. Long-term clinical outcomes of toric intraocular lens implantation in cataract cases with preexisting astigmatism. *J Cataract Refract Surg.* 2014; 40(10):1654-60.
12. Chu, Colin J. et al. Risk Factors and Incidence of Macular Edema after Cataract Surgery. *Ophthalmology* 2016, 123(2): 316-23.
13. Hood CT, Sugar A. Subjective complaints after cataract surgery: common causes and management strategies. *Curr Opin Ophthalmol.* 2015; 26:45-9.
14. Tester R, Pace NL, Samore M, Olson RJ. Dysphotopsia in phakic and pseudophakic patients: incidence and relation to intraocular lens type. *J Cataract Refract Surg.* 2000; 26:810-6.
15. Kershner RM. Neuroadaptation and premium IOLs: What does the brain think? *Ophthalmol Manage.* 2011; 15(12):51-4.
16. Hann CR, Bentley MD, Vercnocke A, Ritman EL, Fautsch MP. Imaging the aqueous humor outflow pathway in human eyes by three-dimensional micro-computed tomography (3D micro-CT). *Exp Eye Res.* 2011;92(2):104-11.
17. Vinod K, Gedde SJ. Safety profile of minimally invasive glaucoma surgery. *Curr Opin Ophthalmol.* 2021;32(2):160-8.
18. Gibbons A, Ali TK, Waren DP, Donaldson KE. Causes and correction of dissatisfaction after implantation of presbyopia-correcting intraocular lenses. *Clin Ophthalmol.* 2016;10(10):1965-70.

PLAQUENIL TOXICITY: HOW TO AVOID THIS BULLSEYE

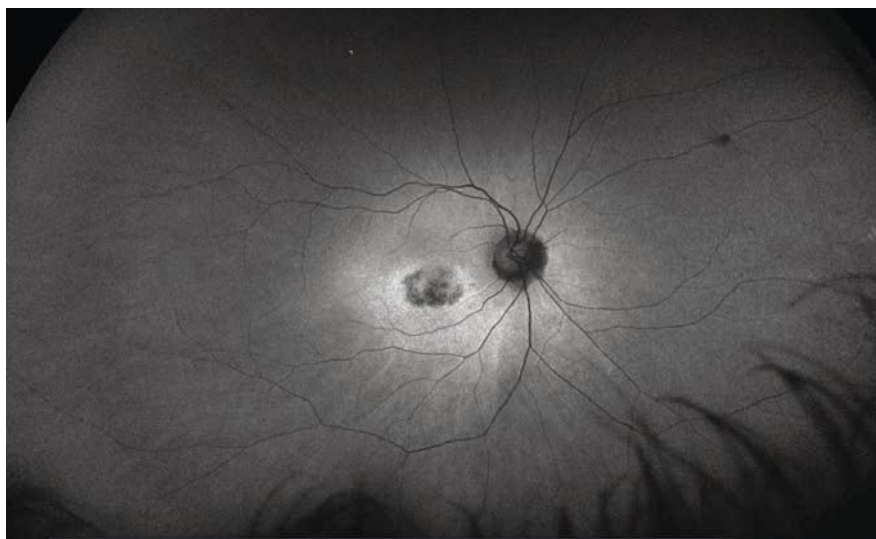
Learn the clinical indicators, risk factors and screening guidelines to properly monitor for this irreversible, rare condition in patients on this drug.



BY LUANNE CHUBB, OD
CHESTER COUNTY, PA

Plaquenil (hydroxychloroquine) is a disease-modifying anti-rheumatic drug used to treat patients with various inflammatory conditions through modulation of the immune system. Despite its reputable safety profile, you could still end up with the occasional patient in your chair who develops Plaquenil-induced toxicity, an untreatable condition that poses a serious threat to vision.

Hydroxychloroquine (HCQ) was developed from its predecessor chloroquine in 1946 to be a more effective and less toxic alternative for the treatment of malaria.¹⁻³ Its anti-inflammatory properties were recognized when improvement was noted in soldiers with autoimmune skin diseases and rheumatoid arthritis (RA).^{2,3} The agent is now commonly used in rheumatology for non-organ-specific autoimmune diseases, RA, mixed connective tissue disorders and related dermatological conditions in both adults and children.^{1,4,5} HCQ may also be beneficial for use in oncology, endocrinology (for diabetes) and cardiology.^{1,4,5} It may be



This image, taken five years after discontinuation of HCQ, shows abnormal FAF in the right eye of a patient who had been on the drug for over a decade.

used as an adjunct medication with biologic therapies, reducing the doses required of more toxic biologic drugs.^{1,6}

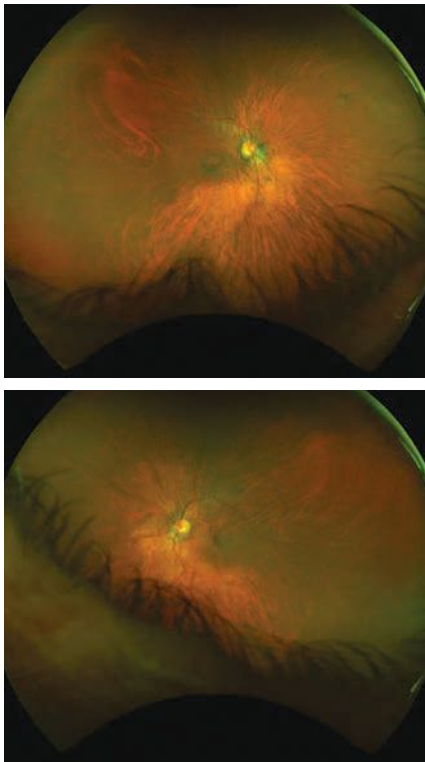
HCQ has a lipophilic base, allowing it to cross cell membranes easily. This quality enables the suppression of antigen presentations, along with the production of prostaglandin and cytokine.⁷ The drug's beneficial properties include antithrombotic, antifibrotic, antihyperglycemic, lipid reduction and immune suppressive properties.^{6,7} It

lowers the risk of pregnancy complications in females who might require its use with systemic lupus erythematosus (SLE).^{6,8-10} Although the therapeutic is generally well tolerated, the adverse effects of HCQ include neuro-myotoxicity and cardiotoxicity in addition to its well-known risk for retinal toxicity.^{6,10}

Screening guidelines for HCQ monitoring and testing strategies have changed over the past 20 years, helping us to better detect early retina changes

About the author

Dr. Chubb is currently employed as a staff optometrist at the Michael J. Crescenz VA Medical Center in Philadelphia. She is also a fellow of the American Academy of Optometry. Dr. Chubb has no financial interests to disclose.



Five years after this patient stopped taking Plaquenil, the fundus images highlight some of the damage it left behind (OD, top; OS, bottom). Note the incomplete bullseye maculopathy OD.

before they are visible in the fundus. Visual field testing and spectral-domain optical coherence tomography (SD-OCT) are now the primary screening tests. Widefield testing is indicated for patients of Asian descent to detect the changes that develop more commonly beyond the central retina. New objective tests include multifocal electroretinogram (mfERG) to confirm visual field findings and fundus autofluorescence (FAF) to show fundus damage. Understanding the most recent guidelines allows us to identify those patients at high risk of toxicity, monitor for early signs of toxicity and discontinue medication before vision is affected.

A Toxic Case

For this 55-year-old, a negative outcome was avoided through proper and timely screening and intervention. The African-American female had presented to the eye clinic for a comprehensive examination and visual

TABLE 1. INDICATIONS FOR HCQ TREATMENT^{1,2,8}

Rheumatological disorders	Systemic lupus erythematosus Rheumatoid arthritis Sjögren's syndrome Antiphospholipid syndrome Osteoarthritis Dermatomyositis Juvenile idiopathic arthritis Psoriatic arthritis Chemotherapy-related arthropathy
Dermatological disorders	Porphyria cutanea tarda (unlicensed use) Discoid lupus Cutaneous sarcoidosis Granuloma annulare Lichen planus (erosive) Lichen planopilaris Lichen sclerosus Cutaneous pseudolymphoma Atopic dermatitis Scleromyxedema Systemic sclerosis
Oncology	Graft vs. host disease Non-small cell lung cancer Chronic lymphocytic leukemia Adjuvant use as inhibitor of autophagy
Pediatrics	Interstitial lung disease in children (unlicensed use) Systemic lupus erythematosus Discoid lupus

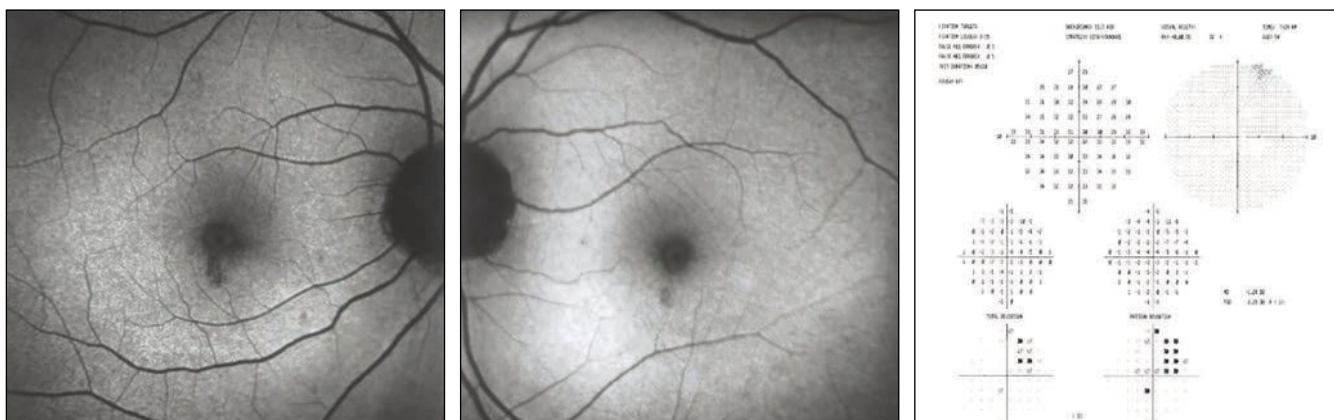field testing. Her medical history was remarkable for episodic use of HCQ 400mg/daily from 1998 to 2012 and 200mg/day from 2014 to 2015, the second period of which was during the time of her visit.

The patient's best-corrected visual acuities were 20/20 OD and 20/25 OS. Her external examination was normal, her confrontational visual fields were full and there was no afferent defect. Biomicroscopy uncovered normal anterior segment structures with Goldmann applanation pressures of 16mm Hg OU. A dilated fundus examination was remarkable for macular pigment mottling OU. SD-OCT showed loss of the IS/OS line and localized thinning of the outer nuclear layer, and FAF testing showed an area of hypo-fluorescence greater in the right eye than the left. Humphrey visual field (HVF) 10-2 showed defects in both eyes greater in the right than the left. These structural and functional changes were consistent with HCQ macular toxicity, and her

rheumatologist was promptly notified that day with the recommendation to discontinue HCQ use. Subsequent yearly SD-OCT testing showed continued mild thinning of the outer nuclear layer and loss of the IS/OS line and increased hypo-fluorescence on FAF testing, demonstrating this drug's ability to have lingering ocular effects even in less severe cases of toxicity.

HCQ in Action: Mechanisms and Clinical Effects

HCQ is the mainstay of treatment in SLE, RA and a number of other related inflammatory rheumatic and dermatological conditions.^{2,4,7,10} It reduces the severity of SLE and its acute inflammatory events by 50%, delays the onset of SLE in patients with undifferentiated connective tissue disease and improves the overall survival rate of people diagnosed with the disease.^{2,6-10} It reduces the risk of congenital heart block in females with positive anti-Ro/SSA antibody and reduces the risk of



Initial visit FAF area of hypofluorescence (OD, left; OS, middle) indicating loss of RPE and corresponding to paracentral visual field defects 2' HCQ toxicity (right).

seizures and thromboses.^{7,9} It is not recommended by the manufacturer for use during pregnancy and is listed as a schedule C pregnancy category medication.^{6,8} However, its use during pregnancy has been widely studied and has been shown to improve pregnancy outcomes in patients with SLE with no evidence of fetal harm.^{6,8,9}

“ The drug’s sneaky ability to remain in the body for an extended period of time is a key reason why early screening and monitoring these patients regularly are so critical. ”

HCQ has a 70% to 80% bioavailability after oral administration with a half-life of 50 days, one characteristic that gives it the potential to cause lasting damage for up to several years even after drug discontinuation.^{2,6} Stable blood levels are reached within three to six months, and deposition in tissue may linger for as long as five years.^{2,6}

The amount of drug measured in whole blood is almost five times higher than in plasma, making the assessment of therapeutic and toxic levels difficult.^{2,6} It is not retained in fatty tissue and is cleared predominantly by the kidneys (and to a lesser degree by the liver).^{1,5,11,12} The drug’s sneaky ability to remain in the body for an extended period of time is a key reason why early screening and monitoring these

patients regularly to watch for signs of macular toxicity are so critical.

The common side effects of HCQ include gastrointestinal symptoms, nausea, diarrhea and vomiting that may resolve with continued use or require dose reduction.^{2,8,11,12} Cutaneous blue-gray pigmentations on the body are common, occurring in up to 25% of patients. Although pigmentation may persist, it is not associated with other adverse outcomes.^{6,8,11,12}

Hemolytic anemia with glucose-6-phosphate dehydrogenase (G6PD) is a rare adverse effect that is only found in patients taking an amount that exceeds recommended doses; therefore, routine G6PD-deficiency screening is not indicated.^{6,8}

Myopathy affecting the skeletal and heart tissue may occur but is rare.^{6,11,12} Myopathy will improve after HCQ is discontinued but may continue for weeks due to the long half-life of the drug.^{6,8} Cardiac involvement is extremely rare and presents as restrictive myopathy or conduction abnormalities.^{6,8,11,12} Discontinuation of HCQ may result in recovery, but death has also been reported.^{6,8} Annual electrocardiograms have been suggested to monitor potential adverse cardiac events, but there are no current guidelines for cardiotoxicity screening.⁸

Although safer than chloroquine, HCQ possesses risk for toxic retinopathy and irreversible vision loss.^{2,3,6,13} Vortex keratopathy associated with drug deposition into the cornea occurs

in less than 5% of individuals taking 400mg/day.^{3,7} Corneal deposits may appear within two to three weeks of starting treatment and usually resolve when the drug is discontinued. Drug deposition into the cornea is not an indicator for those at risk for retinal damage and is not associated with vision loss.^{3,5}

Retinal Toxicity

It is not clear why the photoreceptors in the parafoveal/perifoveal are susceptible to damage, and the mechanism of retinal toxicity is not well understood.^{1,3,4,17,18} HCQ strongly binds to tissues containing melanin, especially retinal pigment epithelial (RPE) cells.^{1,4,17,18} Some studies suggest that HCQ prevents lysosomal degradation and endocytosis of the RPE, which in turn stops the degradation of the old outer segments of photoreceptors. Additionally, HCQ’s binding to melanin may lead to delayed chronic toxicity, resulting in lipofuscin accumulation and impaired photoreceptor function.^{3,4,12,17,19-22}

The outer segment of the photoreceptors is initially affected, followed by secondary degeneration of the RPE.^{1,4,12,17,19,20} Identifying early retinopathy before RPE damage occurs and discontinuing HCQ will limit progression and risk of vision loss. If early toxicity is not recognized or bullseye maculopathy is present at the time of exam, progression may continue for years with subsequent loss of vision despite having discontinued the drug.^{5,17}



A NEW WAY TO EXPERIENCE REVIEW OF OPTOMETRY

Follow us on Instagram at @revoptom for striking clinical images, daily news headlines, issue previews and great content from the magazine—all formatted for mobile



REVIEW OF OPTOMETRY
NEW FEED • THE NEWS FEED • THE NEWS FEED • THE NEWS FEED • THE NEWS FEED

Stories for 3-26-21

Missed Neuro Diagnosis Common, Can Lead to Patient Harm
Daily, subtle hint of mild refractive error suggested, but one in four of 12000 eyes were either some kind of adverse lesion on health.

CDC Aims to Break Down Telling Barriers in Oculocoma
These unexplained eye findings for a two-year investigation since the incidence and clinical value of ocular keratoma.

Thyroid Eye Disease Increases Risk of Optic Nerve Damage
A recent study showed that the risk of optic nerve damage is increased in patients with thyroid eye disease.

Read today at www.reviewofoptometry.com/news

REVIEW OF OPTOMETRY

High myopia with a tessellated and thin choroid (red line), RPE disruption (gray line), DDF (yellow line), DDF (green line) indicates photoreceptors (blue line) will vary. Subtle and hyper-refractive corneal (purple line) of contact with myopia (D).

Choroidal folds causing sub-RPE indentations (red lines).

From "Get More OCT to a 100% New Level" by Sam Brinkman, OD available at www.reviewofoptometry.com/issue/march-19-2021

REVIEW OF OPTOMETRY

DRY EYE READER SURVEY RESULTS

What percent of your patients in each of these categories suffer from dry eye?

Category	0%	10%	20%	30%	40%	50%	60%	70%
Adults and teens	0	10	20	30	40	50	60	70
Adults 41-60 years old	0	10	20	30	40	50	60	70
Adults 61 and older	0	10	20	30	40	50	60	70
Contact lens wearers	0	10	20	30	40	50	60	70
Men	0	10	20	30	40	50	60	70
Women	0	10	20	30	40	50	60	70
Post-menopausal women	0	10	20	30	40	50	60	70

From "Dry Eye Prevalence Trends, Status and Long-Q" available at www.reviewofoptometry.com/issue/march-19-2021

REVIEW OF OPTOMETRY

Reflex associated with a subconjunctival hemorrhage.

From "The Eye Remains New and True and True" by Alan Tapp, OD and Brian Linnemann, OD available at www.reviewofoptometry.com/issue/march-19-2021

REVIEW OF OPTOMETRY

CLINICAL FEATURES OF COMMON SECONDARY CONDITIONS ASSOCIATED WITH GLAUCOMA

CONDITION	CLINICAL FEATURES	OPHTHALMIC FINDINGS
Systemic hypertension	Systemic hypertension or ocular hypertension (e.g., elevated intraocular pressure and/or optic disc edema)	Asymmetric optic disc edema, asymmetric optic disc pallor, asymmetric optic disc cupping, asymmetric optic disc hemorrhage
Diabetic retinopathy	Diabetic retinopathy, diabetic macular edema, diabetic proliferative retinopathy, diabetic neovascularization, diabetic vitreous hemorrhage, diabetic retinal detachment, diabetic cataract	Asymmetric optic disc edema, asymmetric optic disc pallor, asymmetric optic disc cupping, asymmetric optic disc hemorrhage
Systemic lupus erythematosus	Systemic lupus erythematosus, anterior uveitis, posterior uveitis, vitreous hemorrhage, retinal detachment, cataract	Asymmetric optic disc edema, asymmetric optic disc pallor, asymmetric optic disc cupping, asymmetric optic disc hemorrhage
Systemic sclerosis	Systemic sclerosis, scleritis, episcleritis, keratitis, vitreous hemorrhage, retinal detachment, cataract	Asymmetric optic disc edema, asymmetric optic disc pallor, asymmetric optic disc cupping, asymmetric optic disc hemorrhage
Systemic amyloidosis	Systemic amyloidosis, corneal keratic precipitates, vitreous hemorrhage, retinal detachment, cataract	Asymmetric optic disc edema, asymmetric optic disc pallor, asymmetric optic disc cupping, asymmetric optic disc hemorrhage
Systemic mastocytosis	Systemic mastocytosis, corneal keratic precipitates, vitreous hemorrhage, retinal detachment, cataract	Asymmetric optic disc edema, asymmetric optic disc pallor, asymmetric optic disc cupping, asymmetric optic disc hemorrhage

From "The Eye Remains New and True and True" by Alan Tapp, OD and Brian Linnemann, OD available at www.reviewofoptometry.com/issue/march-19-2021

REVIEW OF OPTOMETRY

MAR 2021
Dry Eye Issue

From "The Eye Remains New and True and True" by Alan Tapp, OD and Brian Linnemann, OD available at www.reviewofoptometry.com/issue/march-19-2021

REVIEW OF OPTOMETRY

AVAILABLE MARCH 19, 2021
www.reviewofoptometry.com

REVIEW OF OPTOMETRY

CLINICAL CORRELATION: A 51-year-old female presented with a red eye, a painful eye of the lower lid and eyelid. What do you think is happening and how would you treat it?

From "The Eye Remains New and True and True" by Alan Tapp, OD and Brian Linnemann, OD available at www.reviewofoptometry.com/issue/march-19-2021

REVIEW OF OPTOMETRY

From "The Eye Remains New and True and True" by Alan Tapp, OD and Brian Linnemann, OD available at www.reviewofoptometry.com/issue/march-19-2021

REVIEW OF OPTOMETRY

Additional studies that might yield diagnostically pertinent data:
• 30-70 lux for peripheral choroid
• 100-200 lux for peripheral choroid
• 100-200 lux for peripheral choroid
• 100-200 lux for peripheral choroid

From "The Eye Remains New and True and True" by Alan Tapp, OD and Brian Linnemann, OD available at www.reviewofoptometry.com/issue/march-19-2021

REVIEW OF OPTOMETRY

Localization of Common Etiologies Causing Diplopia

Diagnosis	Location	Notes
Strabismic diplopia	Extraocular muscles	• 100% of cases are due to extraocular muscle dysfunction
Refractive diplopia	Refractive error	• 100% of cases are due to refractive error
Optic nerve disease	Optic nerve	• 100% of cases are due to optic nerve disease
Brain disease	Brain	• 100% of cases are due to brain disease

From "The Eye Remains New and True and True" by Alan Tapp, OD and Brian Linnemann, OD available at www.reviewofoptometry.com/issue/march-19-2021

REVIEW OF OPTOMETRY

From "The Eye Remains New and True and True" by Alan Tapp, OD and Brian Linnemann, OD available at www.reviewofoptometry.com/issue/march-19-2021

REVIEW OF OPTOMETRY

From "The Eye Remains New and True and True" by Alan Tapp, OD and Brian Linnemann, OD available at www.reviewofoptometry.com/issue/march-19-2021

REVIEW OF OPTOMETRY

FAST FACTS ON CLRD

- only present in approximately one in three people
- provides a secondary blood supply to the inner layers of the macula
- comprises only 3.3% to 7.1% of all retinal artery occlusions
- has been associated with embolism, hypertension, atherosclerosis, diabetes, pregnancy and systemic hypertension
- can present in three ways (1) with ischemic optic neuropathy in giant cell arteritis, (2) with concomitant central retinal vein occlusion or (3) isolated

Management and prognosis:
• BSCA: Critical to arrange for some dry eye and eye care and to ensure that the patient is not at risk of retinal detachment.
• CVD: Treatment focuses on macular edema and neovascularization. Better prognosis, as the vein occlusion tends to be non-neovascular.
• If isolated: Treatment can include macular photocoagulation, intravitreal thrombolysis and laser photocoagulation.

From "The Eye Remains New and True and True" by Alan Tapp, OD and Brian Linnemann, OD available at www.reviewofoptometry.com/issue/march-19-2021

REVIEW OF OPTOMETRY

From "The Eye Remains New and True and True" by Alan Tapp, OD and Brian Linnemann, OD available at www.reviewofoptometry.com/issue/march-19-2021

REVIEW OF OPTOMETRY
NEW FEED • THE NEWS FEED • THE NEWS FEED • THE NEWS FEED • THE NEWS FEED

Stories for 3-26-21

Missed Neuro Diagnosis Common, Can Lead to Patient Harm
Daily, subtle hint of mild refractive error suggested, but one in four of 12000 eyes were either some kind of adverse lesion on health.

CDC Aims to Break Down Telling Barriers in Oculocoma
These unexplained eye findings for a two-year investigation since the incidence and clinical value of ocular keratoma.

Thyroid Eye Disease Increases Risk of Optic Nerve Damage
A recent study showed that the risk of optic nerve damage is increased in patients with thyroid eye disease.

Additional studies that might yield diagnostically pertinent data:

REVIEW OF OPTOMETRY

Additional studies that might yield diagnostically pertinent data:

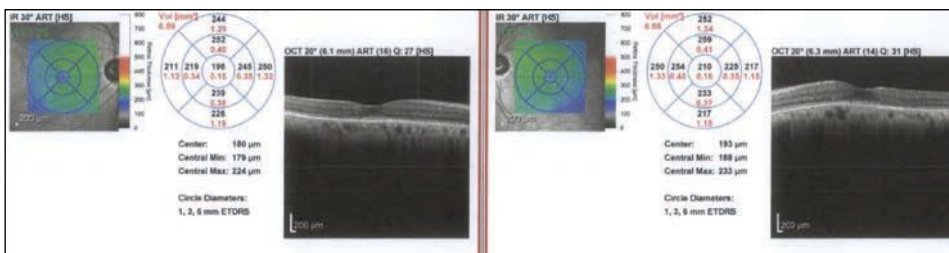
REVIEW OF OPTOMETRY

ANTERIOR CEMENT FACTORS IN GLAUCOMA

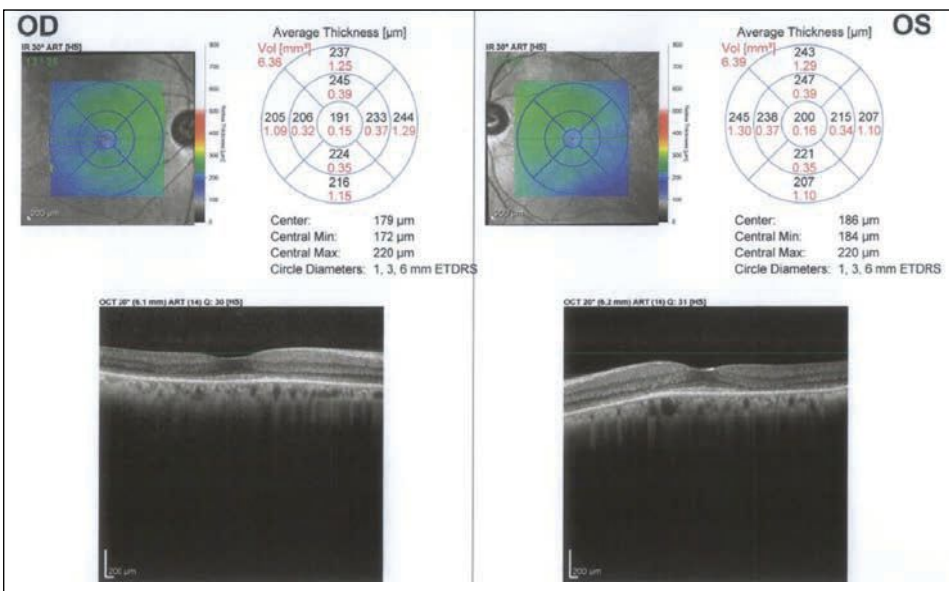
Set of 4 - Anterior segment inflammation
L: Pigmentation on the anterior lens capsule associated with anterior angle.
W: Larger application of pigment in anterior lens capsule surface suggestive

REVIEW OF OPTOMETRY

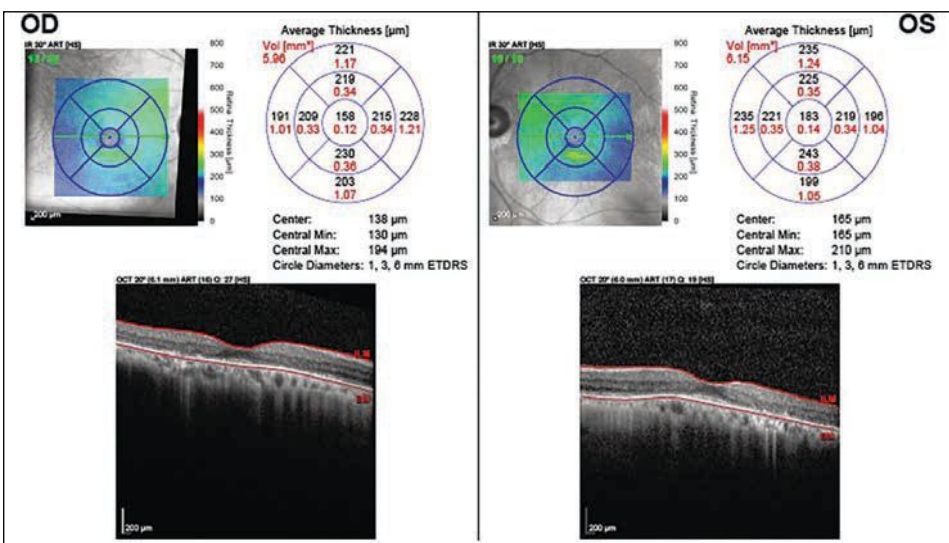
From "The Eye Remains New and True and True" by Alan Tapp, OD and Brian Linnemann, OD available at www.reviewofoptometry.com/issue/march-19-2021



SD-OCT of the patient's initial visit showing loss of the IS-OS junction and outer nuclear layer.



SD-OCT one year after discontinuation of HCQ showing continued loss of the IS-OS junction and outer nuclear layer.



Five years after discontinuation showing loss of the IS-OS junction, outer nuclear layer and RPE.

HCQ retinopathy occurs predominantly in the parafoveal area in Caucasians, Hispanics and African-Americans.^{5,23,24} A pericentral area or mixed pattern may rarely occur in Hispanics

and African-Americans.^{5,23,24} Patients with retinopathy may initially be asymptomatic.^{2,16} The fundus appearance can look normal despite the presence of a scotoma.¹⁶ Initial complaints occur

as a result of central or paracentral scotomas affecting night vision, reading and other fine visual functions, metamorphopsia and glare.^{3,16} Early scotomas are more common superiorly within 10° of fixation and may enlarge and multiply. Reduced visual acuity occurs if fixation becomes involved.¹⁶

Irregularity of macular pigmentation and decreased foveal reflexes are the earliest retinal findings.¹⁶ A concentric, horizontally oval area of hypopigmentation develops greater inferiorly and surrounds the macular irregularity.¹⁶ The paracentral depigmentation develops into the characteristic bullseye maculopathy pattern which signifies advanced severe damage.¹⁶ Generalized pigmentary changes may progress for a minimum of three years with continued thinning of the fovea and loss of EZ length and architecture despite cessation of the drug making it difficult to distinguish from cone-rod dystrophy.^{14,16-18}

Improper Dosing and Other Risk Factors

The 2011 American Academy of Ophthalmology (AAO) guidelines identified a cumulative dose of >1000g for increased risk of retinopathy.^{1,15} The 2011 guideline recommended that the daily dose of HCQ be no more than 400mg and that lower doses be calculated based on ideal body weight in the range of 6.5mg/kg for thin patients and those of short stature.^{14,15} It was also noted that obese patients can be dosed based on height if weight is not known.¹⁵

In 2016, the AAO revised the 2011 HCQ/chloroquine screening standards in response to new scientific data that identified specific risk factors for toxicity.⁵ A retrospective case-controlled study by Melles and Marmour that included 2,361

patients who used HCQ for at least five continuous years demonstrated a higher risk of retinal toxicity based on daily dose, duration of use and kidney disease.^{5,6,13} Risk factors identified included HCQ daily dose >5mg/kg actual body weight, use for greater than five years, reduced glomerular filtration rate, concurrent use of tamoxifen and pre-existing maculopathy.^{1,5}

Although patients older than 60 years were previously thought to be at a higher risk of retinal toxicity, studies suggested that age alone was not a risk factor.^{5,13} However, since elderly patients are more likely to have decreased renal function or macular disease, their risk of toxicity is increased.^{1,5,13} Additionally, very thin patients were identified as having increased risk when dosing was based on ideal body weight.^{5,13}

By identifying the retinal changes that occur earlier than the classic bull's-eye maculopathy pattern, researchers found a 7.5% risk for patients using long-term HCQ therapy, which is three times higher than the risk previously reported.^{10,13} The authors suggested a revised dose calculation to ≤5mg/kg/day using actual body weight, but no more than 400mg total daily.^{5,6,13} The subsequent risk of toxicity at this recommended dose is <1% up to five years, ≤2% at 10 years but then increases to almost 20% after 20 years.⁵ A patient who has no toxicity after 20 years has approximately a 4% risk of converting in the subsequent year.^{5,13}

In addition to dosage, other factors increase the risk of toxicity. Kidney disease markedly increases the risk of retinopathy.^{1,2,5,13} A 50% decrease in kidney glomerular filtration rate will double the risk of ocular toxicity; the prevalence increases to greater than 50% in doses higher than 5mg/kg when used longer than 20 years.^{1,2,5,13} While HCQ is partially cleared by the liver, organ disease has not been reported to increase the risk of retinal toxicity.^{1,2,5} Tamoxifen, a non-steroidal estrogen antagonist used in the treatment of breast cancer, has its own risk of toxic retinopathy.^{11,13,15,16} The use of both

HCQ and tamoxifen has an adverse synergy which increases the risk of retinopathy.¹³ Patients who are on both medications are at significantly higher risk of developing toxic retinopathy.^{1,2,11,13,16}

A comprehensive medical history to review for the above risk and calculating the HCQ mg/kg actual (or real) body weight at each eye examination will provide the information needed to decide how often your patient should return for testing.

Screening Guidelines

The AAO's revised guideline for HCQ screening from 2016 included automated visual field testing, SD-OCT, FAF and mfERG.⁵ All patients should have a baseline retinal exam within the first year of administration to evaluate for other pre-existing ocular conditions or tissue damage that might interfere with the interpretation of screening tests.⁵ Baseline visual fields and SD-OCT are useful but not critical unless retinal abnormalities are present.⁵

Annual screening may be deferred until five years of drug use in those patients who have no major risk factors such as pre-existing ocular disease, maculopathy, concurrent tamoxifen use, renal disease or taking a dose >5mg/kg actual body weight.⁵ More frequent screening is recommended when major risk factors are present,

but for every patient, it is important to check the dose relative to weight at every visit.

Routine screening recommendations include both objective (SD-OCT) and subjective (visual fields) testing. A white SITA 10-2 visual field with pattern deviation is recommended and preferred over the red isopters. Early damage occurs more frequently infratemporal with a corresponding superonasal field defect. Questionable results on visual fields should be repeated for consistency of loss and ideally confirmed with objective testing (SD-OCT, FAF or mfERG) before suggesting that treatment be altered or discontinued.⁵ However, treatment may be discontinued if consistent visual field defects are attributed to HCQ use.

Retinal damage on the SD-OCT is seen as loss of the IS/OS junction line and parafoveal thinning of the outer nuclear layer.¹⁴ FAF can show increased autofluorescence in early parafoveal or extramacular photoreceptor damage before thinning can be observed on SD-OCT. Late RPE loss will be dark in appearance, indicating reduced autofluorescence.⁵ The mfERG is the most sensitive objective test and may detect early signs of toxicity prior to visual or structural changes on OCT.^{2,5,26} However, its availability is often limited to specialized clinics.^{2,5}

TABLE 2. 2016 REVISED RECOMMENDATIONS FOR HCQ AND CHLOROQUINE SCREENING⁵

Recommended Screening Tests	<ul style="list-style-type: none"> • Visual fields: white SITA testing with pattern deviation plots <ul style="list-style-type: none"> »10-2 for non-Asian patients »24-2 or 30-2 for Asian patients • Spectral-domain OCT (widefield for Asian patients) • Other objective tests <ul style="list-style-type: none"> »FAF (widefield for Asian patients) »Multifocal electroretinogram
Newer Screening Tests in the Future	<ul style="list-style-type: none"> • Microperimetry • Adaptive optics retinal screening
Not Recommended for Screening	<ul style="list-style-type: none"> • Fundus examination • Time-domain OCT • Fluorescein angiography • Full-field ERG • Amsler grid • Color testing • Electro-oculogram

A pericentral pattern involving the peripheral extramacular retina near the arcades is common in the Asian population.^{23,24,27} The mechanism for this finding is unclear, but it is more likely to be missed using only standard screening methods.^{6,13,23,27} Recommended adjustments for Asian patients include SD-OCT wide volume scans (12x9mm) or 30° scans for the purpose of being able to capture peripheral ellipsoid loss.^{4,23,27} An ultra-widfield FAF will capture 200° or 82% of the retina in contrast to the 30° to 50° evaluated on a conventional FAF.^{23,27} In addition to a 10-2 visual field, a 30-2 visual field would be appropriate for use on these patients to capture the more peripheral defects.^{23,24,27}

Future screening tests may include OCT angiography, microperimetry and adaptive optics retinal imaging.^{21,25,28} Additionally, further development in genetic testing may help us eventually be able to identify those patients with a predisposition to a higher risk of retinal toxicity.^{5,9,29}

These revised guidelines provide optometrists with the information needed to develop appropriate management plans and testing strategies for patients based on daily dose, cumulative dose, pre-existing ocular and systemic disease, concurrent medication risk and nationality.

Clinical Takeaways

HCQ retinal toxicity is not treatable and is characterized by irreversible damage to the photoreceptor and/or RPE when the drug is taken for a long enough time that toxic levels of the compound build up in retinal tissues.^{3,13,23} Toxicity is not rare with patients on long-term therapy, and the

risk is highly dependent on the daily dose, duration of dose as well as major systemic risk factors such as renal disease and concurrent use of tamoxifen. Pre-existing retinal and macular disease makes accurate interpretation of the screening tests more challenging to identify early toxicity suggesting that HCQ use be avoided in these patients. Lesser risk factors include age, liver disease and genetics, which all merit consideration though studies do not attribute a significant contribution to toxicity from these factors.⁵

Recommended dosing guidelines changed in 2016 and now state to use actual (real) body weight instead of ideal body weight to reduce risk of overdose, especially for thin patients.^{5,13} Lower risk occurs with doses ≤5mg/kg actual body weight. Patients of Asian descent may show early ellipsoid loss more peripherally and earlier in the arcade region rather than centrally.⁴ Studies show that 55% of Asian patients vs. 2% of Caucasian patients will develop a peripheral pericentral toxicity pattern instead of the well-known parafoveal pattern.⁴ For these patients, testing strategies must include the use of a widefield OCT, widefield FAF and enlarged visual field testing (24-2 or 30-2).^{23,24}

With appropriate screening, central vision can be protected before changes occur in the RPE.^{5,13,18,24} Be sure to consistently question patients on their use of medication and know when screening is necessary to detect for disease before it's too late. ■

1. Yusuf IH, Sharma S, Luqmani R, Downes SM. Hydroxychloroquine retinopathy. *Eye (Lond)*. 2017;31(6):828-45.
2. Abdulaziz N, Shah AR, McCune WJ. Hydroxychloroquine: balancing the need to maintain therapeutic levels with ocular safety: an update. *Curr Opin Rheumatol*. 2018;30(3):249-255.
3. Tehrani R, Ostrowski RA, Hariman R, Jay WM. Ocular toxicity of hydroxychloroquine. *Sem Ophthalmol*. 2008;23(3):201-9.
4. Corradetti G, Violanti S, Au A, Sarraf D. Wide-field retinal imaging and the detection of drug-associated retinal toxicity. *Int J Retin Vit*. 2019;5(26).
5. Marmor MF, Kellner U, Lai TYY, et al. Recommendations on screening for chloroquine and hydroxychloroquine retinopathy (2016 revision). *Ophthalmol*. 2016;123(6):1386-94.
6. Shippey EA, Wagler VD, Collamer AN. Hydroxychloroquine: an old drug with new relevance. *Cleve Clin J Med*. 2018;85(6):459-67.
7. Ding HJ, Denniston AK, Rao VK, Gordon C. Hydroxychloroquine-related retinal toxicity. *Rheum*. 2016;55(6):957-67.



8. Fernandez AP. Updated recommendations on the use of hydroxychloroquine in dermatologic practice. *J Am Acad Dermatol*. 2017;76(6):1176-82.
9. Petri M, Elkhalfi M, Li J, et al. Hydroxychloroquine blood levels predict hydroxychloroquine retinopathy. *Arthritis Rheumatol*. 2020;72(3):448-53.
10. Jorge AM, Melles RB, Zhang Y, et al. Hydroxychloroquine prescription trends and predictors for excess dosing per recent ophthalmology guidelines. *Arthritis Research and Therapy*. 2018(20):133.
11. Schrezenmeier E, Dörner T. Mechanisms of action of hydroxychloroquine and chloroquine: implications for rheumatology. *Rheum*. 2020;16(3):155-66.
12. Nirk EL, Reggiori F, Mauthe M. Hydroxychloroquine in rheumatic autoimmune disorders and beyond. *EMBO Mol Med*. 2020;12(8):e12476.
13. Melles RB, Marmor MF. The risk of toxic retinopathy in patients on long-term hydroxychloroquine therapy. *JAMA Ophthalmol*. 2014;132(12):1453-60.
14. Mititelu M, Wong BH, Brenner M, et al. Progression of hydroxychloroquine toxic effects after drug therapy cessation: new evidence from multimodal imaging. *JAMA Ophthalmol*. 2013;131(9):1187-97.
15. Marmor MF, Kellner U, Lai TYY, et al. Recommendations on screening for chloroquine and hydroxychloroquine retinopathy. *Ophthalmol*. 2011;118(2):415-22.
16. Ringeisen AL, Mititelu M. Retinal toxicity of systemically administered drugs. In: *Ophthalmology*. 5th ed. Elsevier. 2019.
17. deSisternes L, Hu J, Rubin DL, Marmor MF. Localization of damage in progressive hydroxychloroquine retinopathy on and off the drug: inner versus outer retina, parafovea versus peripheral fovea. *IOVS*. 2015;56(5):3415-26.
18. Marmor MF, Hu J. Effect of disease stage on progression of hydroxychloroquine retinopathy. *JAMA Ophthalmol*. 2014;132(9):1105-12.
19. Cakir A, Ozturan SG, Yildiz D, et al. Evaluation of photoreceptor outer segment length in hydroxychloroquine users. *Eye (Lond)*. 2019;33(8):1321-6.
20. Bulut M, Kazim M, Toslak D, et al. A new objective parameter in hydroxychloroquine-induced retinal toxicity screening test: macular retinal ganglion cell-inner plexiform layer thickness. *Arch Rheumatol*. 2017;33(1):52-8.
21. Bulut M, Akidan M, Gözkaya O, et al. Optical coherence tomography angiography for screening of hydroxychloroquine-induced retinal alterations. *Graefes Arch Clin Exp Ophthalmol*. 2018;256(11):2075-81.
22. Lee MG, Kim SJ, Ham D, et al. Macular retinal ganglion cell-inner plexiform layer thickness in patients on hydroxychloroquine therapy. *IOVS*. 2015;56(1):396-402.
23. Ahn SJ, Joung J, Lim HW, Lee BR. Optical coherence tomography protocols for screening of hydroxychloroquine retinopathy in Asian patients. *Am J Ophthalmol*. 2017;184:11-18.
24. Melles RB, Marmor MF. Pericentral retinopathy and racial differences in hydroxychloroquine toxicity. *Ophthalmol*. 2015;122(1):110-6.
25. Dahrouj M, Young L. Hydroxychloroquine retinopathy in the era of advanced imaging modalities. *Int Ophthalmol Clin*. 2020;60(1):73-83.
26. Chang WH, Katz BJ, Warner JEA, et al. A novel method for screening the multifocal electroretinogram in patients using hydroxychloroquine. *J Retina Vit Dis*. 2008;28(10):1478-86.
27. Ahn, SJ, Joung J, Lee BR. Evaluation of hydroxychloroquine retinopathy using ultra-widfield fundus autofluorescence: peripheral findings in the retinopathy. *Am J Ophthalmol*. 2020;209:35-44.
28. Goker YS, Ucgul AC, Tekin K, et al. The validity of optical coherence tomography angiography as a screening test for the early detection of retinal changes in patients with hydroxychloroquine therapy. *Curr Eye Res*. 2019;44(3):311-15.
29. Wang G, Zhuo N, Liao Z, Qi W. Retinal toxicity caused by hydroxychloroquine in patients with systemic lupus erythematosus: a case report. *Med (Baltimore)*. 2021;100(22):e25688.

TABLE 3. DOSING GUIDELINES

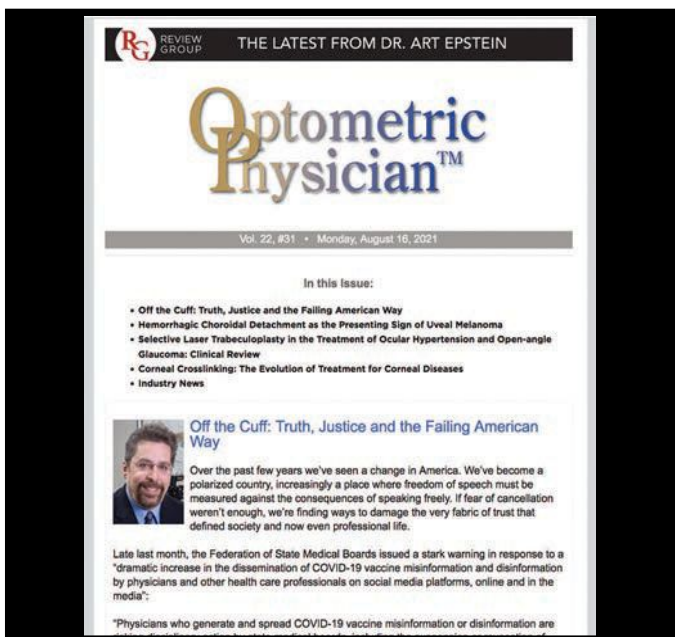
Dose: maximum daily HCQ use of ≤5mg/kg actual (real) body weight, e.g.:

237 pounds = 107.5kg

400mg/107.5kg = 3.72mg/kg



Read the Latest from Dr. Art Epstein



If you aren't already a subscriber, please be sure to sign up for Dr. Art Epstein's weekly e-journal, *Optometric Physician*, distributed by *Review of Optometry*.

Join the thousands of ODs, MDs and ophthalmic industry readers who turn to *Optometric Physician* each week for Dr. Epstein's very direct—and sometimes controversial—take on eye care and the world. You will also keep up with the latest, most relevant clinical studies, condensed and curated for quick reference, as well as a current digest of industry news.

Visit: **JMI | Newsletter Signup**
www.jhihealth.com/globalemail/
to sign up for *Optometric Physician*, and other e-newsletters distributed by Jobson Medical Information.

OPTOMETRIC PHYSICIAN:

Reaches 42,000 ODs weekly

Content: Clinical information & Industry news

Metrics: 18.45% average opens

FOR ADVERTISING OPPORTUNITIES, PLEASE CONTACT

Michael Hoster: Mhoster@jobson.com
610-492-1028

Michele Barrett: Mbarrett@jobson.com
215-519-1414

Jon Dardine: Jdardine@jobson.com
610-492-1030



EDITED BY JOSEPH P. SHOVLIN, OD

Step Up To LK

There are several treatment options for lipid keratopathy, some of which achieve better results than others.

Q I have a patient with marked vascularization and progressive lipid keratopathy (LK) in one eye. What treatment options are available today?

A “LK is a progressive disease characterized by an accumulation of fat deposits with adjacent abnormal vascularization in the cornea,” says Larae Zimprich, OD, of Vance Thompson Vision. “This condition, whether idiopathic or secondary to corneal or systemic disease, typically opacifies and can interfere with visual acuity.”

Dr. Zimprich notes that LK treatment aims to prevent new blood vessel formation. Current options include corticosteroids, photodynamic therapy (PDT), anti-VEGF

antibodies, argon laser treatment, needlepoint cautery and penetrating keratoplasty (PKP).¹

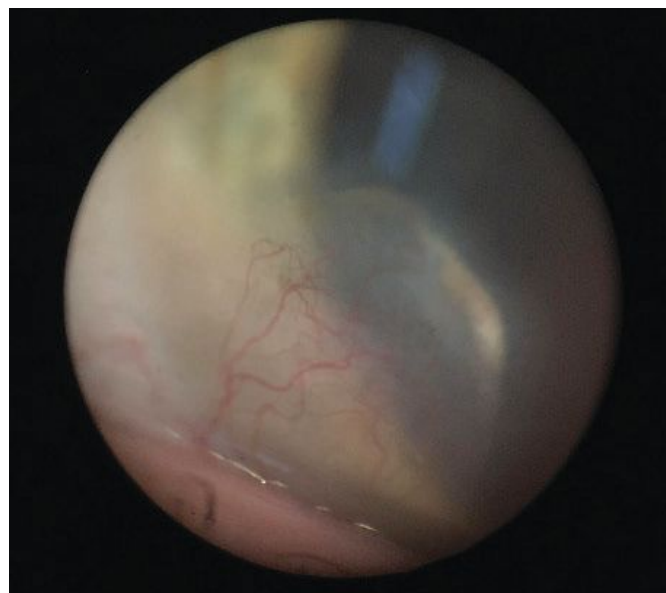
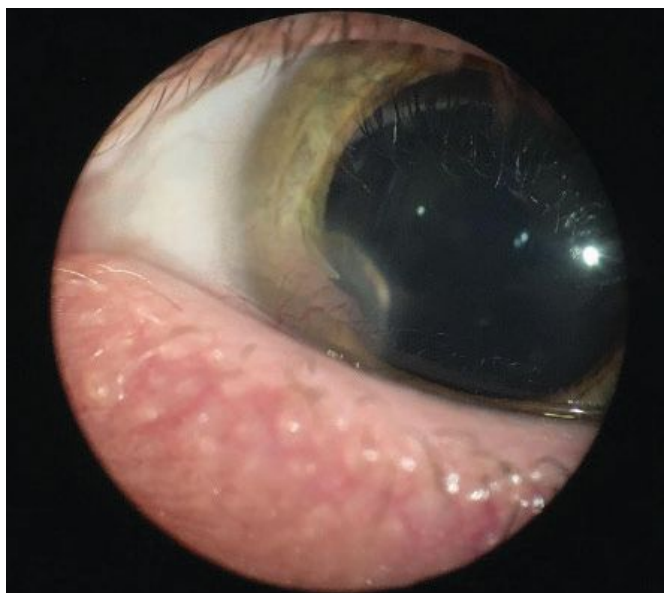Ophthalmic Options

Topical corticosteroids are commonly used due to their anti-inflammatory properties.¹ However, Dr. Zimprich notes that neovascularization can form in the absence of inflammation; therefore, if the etiology is not inflammatory, then corticosteroids will not be effective. She adds that prolonged steroid use also has well-known side effects, including increased risk of developing cataracts and glaucoma. Due to these reasons, there may be better treatment alternatives.

PDT, first introduced to ophthalmology in 2000, uses a vascular-selective, light-sensitive substance, such as verteporfin or dihematoporphyrin, in combination with a low-power infrared laser.² It is commonly used to treat vascular issues in the retina and choroid.

While treating LK, verteporfin or dihematoporphyrin is injected into the cornea, leading to endothelial damage, microvascular thrombosis and blood vessel occlusion.¹ This therapy can be repeated if needed, although Dr. Zimprich says one major disadvantage is the higher cost to patients.

Administration of anti-VEGF antibodies, such as bevacizumab and ranibizumab, through topical, subconjunctival or intracorneal injections has also proven to be effective, according to Dr. Zimprich. VEGF is a key mediator in angiogenesis; therefore, these antibodies block new VEGF-mediated vessel formation, she adds.



Fat deposits with adjacent abnormal vascularization in the cornea are characteristic of LK.

About Dr. Shovlin

Dr. Shovlin, a senior optometrist at Northeastern Eye Institute in Scranton, PA, is a fellow and past president of the American Academy of Optometry and a clinical editor of *Review of Optometry* and *Review of Cornea & Contact Lenses*. He consults for Kala, Aerie, AbbVie, Novartis, Hubble and Bausch + Lomb and is on the medical advisory panel for Lentechs.

Multiple studies have shown that VEGF increases vessel permeability, which could account for lipid leakage and LK development.¹ When used as topical medication, 1.0% ranibizumab QID for three weeks proved to be slightly more effective than 1.0% bevacizumab with the same drop regimen in reducing neovascularization.³ Otherwise, use of subconjunctival and intrastromal injections of bevacizumab can regress deep neovascularization.¹

Argon laser treatment works to occlude pathologic vessels by directing a beam of light and utilizing heat energy.¹ Dr. Zimprich says that laser-induced tissue destruction can cause more harm than good in some cases, with worse neovascularization due to the intense inflammatory response and potential subsequent hemorrhaging, corneal thinning and iris atrophy.

Another treatment option is electrolysis needle cauterization, which

uses direct thermal cautery to target the small, fine vessels.¹ The cauterization may have to be repeated multiple times to reduce the neovascularization and lipid deposits, Dr. Zimprich notes. When other therapies cannot achieve desirable results, a PKP may be indicated.¹ The prognosis may be guarded in severe cases with dense neovascularization, as the risk of rejection increases in these circumstances, she adds.

Future Outlook

All of the previously discussed treatment modalities have proven effective against LK, with newer management options on the horizon.

One promising up-and-coming development, currently in its early stages of research, is mitomycin intravascular chemoembolization (MICE).¹ This procedure consists of intra-arterial infusion of mitomycin-C with an artificial embolus to cause

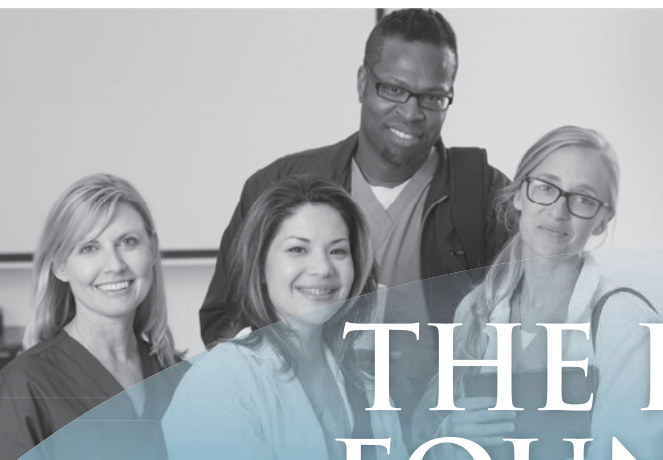
vessel occlusion. Successful occlusion could eliminate or prevent LK in early stages of the disease. Unfortunately, MICE is somewhat time-consuming, as it can be difficult to target afferent vessels, and infusing efferent vessels can worsen LK.¹ Studies are currently in progress to determine proper technique, efficacy and safety.

Luckily, what's available today gives practitioners plenty of viable options and offers patients the chance to experience successful visual outcomes. Stay up-to-date and informed on the latest LK treatment offerings to provide the best care to this demographic. ■

1. Hall MN, Moshirfar M, Amin-Javaheri A, et al. Lipid keratopathy: a review of pathophysiology, differential diagnosis, and management. *Ophthalmol Ther.* 2020;9(4):833-52.

2. Rishi P, Agarwal V. Current role of photodynamic therapy in ophthalmic practice. *Sci J Med Vis Res Foun.* 2015;XXIII:97-9.

3. Stevenson W, Cheng SF, Dastjerdi MH, et al. Corneal neovascularization and the utility of topical VEGF inhibition: ranibizumab (Lucentis) vs bevacizumab (Avastin). *Ocul Surf.* 2012;10(2):67-832.



THE RICK BAY FOUNDATION
for Excellence in Eyecare Education

**Support the Education of Future
Healthcare & Eyecare Professionals**

THE RICK BAY FOUNDATION

for Excellence in Eyecare Education

Scholarships are awarded to advance the education of students in both **Optometry** and **Ophthalmology**, and are chosen by their school based on qualities that embody Rick's commitment to the profession, including integrity, compassion, partnership and dedication to the greater good.

**INTERESTED IN BEING
A PARTNER WITH US?**

www.rickbayfoundation.org

(Contributions are tax-deductible in accordance with section 170 of the Internal Revenue Code.)

(The Rick Bay Foundation for Excellence in Eyecare Education is a nonprofit, tax-exempt organization under section 501(c)(3) of the Internal Revenue Code.)



BY JOSEPH W. SOWKA, OD

THERAPEUTIC REVIEW

The Bite of Something Wild

Anticipating a good outcome in cat scratch disease might require prompt treatment.

A 42-year-old woman presented with a sudden, painless loss of vision in her left eye of three days duration. It began as a mild dimming but rapidly dropped off. Her corrected visual acuity was 20/20 OS and 20/400 OS with no pinhole improvement. Her pupils were reactive to light and accommodation with a mild (grade 1) relative afferent defect OS. Confrontation visual fields were full in each eye and there was a central scotoma present on Amsler grid. Biomicroscopy was normal in each eye and her intraocular pressure was 18mm Hg OD and 19mm Hg OS.

Funduscopy examination was normal in her right eye, but there was a prominently swollen optic disc with associated macular star of exudates in her left eye. She was specifically questioned about her health history and any recent changes. She denied any risk factors for HIV infection and was otherwise healthy with no diagnosed medical conditions. She reported no other neurological signs or symptoms.

When specifically asked, she did report a bad flu-like illness with lymphadenopathy about three weeks before (This occurred prior to COVID-19, so that was not a consideration). She spent no significant time outdoors and did not live in a Lyme disease-endemic area. She could not recall any animal scratches or tick or flea bites, but she did volunteer at an animal shelter.

Given the appearance and history, she was medically evaluated for syphilis, Lyme disease, tuberculosis, toxoplasmosis, toxocariasis, HIV and connective tissue disorders, all of which came back normal. She did test positive for high titers of *Bartonella henselae*, which confirmed the diagnosis of infectious optic neuropathy, specifically benign lymphoreticulosis, better known as cat scratch disease neuroretinitis.

Sources of Great Vision Loss

Neuroretinitis typically presents as a unilateral (rarely bilateral), acute, painless loss of vision. It rarely presents without vision loss. Acuity may be as low as finger-counting level.^{1,6} The typical visual field loss is a central or cecocentral scotoma.²

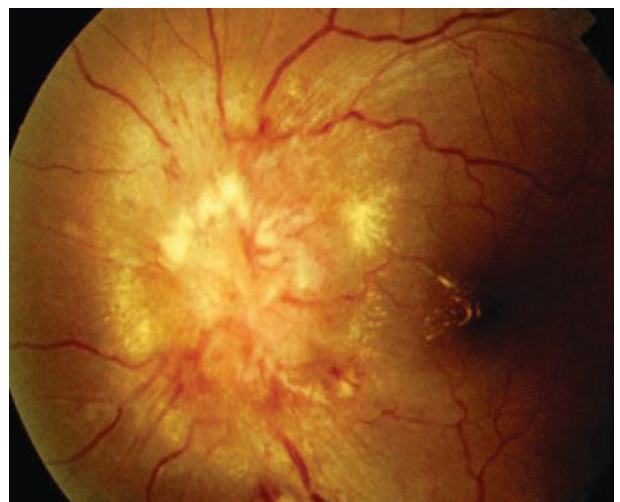
A funduscopy will reveal a markedly edematous disc. There may also be peripapillary hemorrhages due to venous stagnation. Occasionally, there will be a mild vitritis overlying the disc. Initially, there will be a serous retinal detachment extending from the disc to the macula.

The key diagnostic feature in well-devel-

oped neuroretinitis is the presence of macular exudates in the form of a macular star.¹⁻⁶ However, this finding may not occur for up to several weeks after onset of visual symptoms, making the diagnosis more challenging. The serous retinal detachment within the posterior pole in association with disc edema is highly suspicious for early neuroretinitis with the macular exudates ensuing later.¹

Numerous conditions have been seen in association with neuroretinitis including toxoplasmosis, toxocariasis, measles, syphilis, Lyme disease, herpes simplex and zoster, mumps, tuberculosis, malignant hypertension, ischemic optic neuropathy and leptospirosis.⁷⁻¹⁴ However, the most common cause by far is *Bartonella henselae*, the organism responsible for cat scratch disease.^{1,3,14} Occasionally, cat scratch disease will be caused by *B. quintana*.¹⁵

In cat scratch disease neuroretinitis, there may be an antecedent history of fever, malaise and/or lymphadenopathy occurring several weeks preceding the visual loss. There may also be an antecedent history of a cat scratch or flea bite.^{16,17}



Neuroretinitis from cat scratch disease is typically a self-limiting condition with an excellent prognosis.

About
Dr. Sowka

Dr. Sowka is an attending optometric physician at Center for Sight in Sarasota, FL, where he focuses on glaucoma management and neuro-ophthalmic disease. He is a consultant and advisory board member for Carl Zeiss Meditec and Bausch Health.

As neuroretinitis is primarily due to infectious etiologies, it is likely that cell invasion with proinflammatory activation and suppression of apoptosis occurs.¹⁸ Visual loss is predominately more from the retinal edema rather than optic nerve dysfunction. This is evidenced by the fact that the visual field defects reflect a retinal cause as well as the relative mild degree (or absence) of an afferent pupil defect in the face of profound vision loss.^{2,14}

After development of the disc and retinal edema, there will be spontaneous resolution and fluid resorption. The aqueous phase of the edema resolves the fastest, leaving the accumulated lipid exudates within the outer plexiform layer, forming the characteristic macular star.¹⁹

Diagnosis and Treatment

When encountering neuroretinitis, medically consider and evaluate patients for all possible infectious causes and do not immediately default to cat scratch disease. A history should be elicited for exposure to cats, flea and tick bites, travel to Lyme-endemic areas, exposure to sexually transmitted disease, lymphadenopathy, skin rashes, malaise, myalgia and fever. As dictated by the history, order the following tests: Lyme titer, toxoplasmosis titer, toxocariasis titer, purified protein derivative skin testing, fluorescent treponemal antibody absorption test, reactive plasma reagin and chest x-ray for tuberculosis. The most common cause is infection by *B. henselae* or *B. quintana* from a cat scratch.²⁰

Optical coherence tomography (OCT) may be a valuable adjunctive diagnostic test. Subretinal fluid not visible on clinical examination or fluorescein angiography may be readily identified with OCT, making it an adjunctive imaging tool in the diagnosis and follow-up of patients with cat scratch-related neuroretinitis.^{21,22}

When encountering neuroretinitis or any presumed infectious optic neuropathy, targeted antimicrobial agents should be instituted in cases due to specific etiologies (e.g., syphilis, Lyme

disease, toxoplasmosis, tuberculosis). Neuroretinitis from cat scratch disease is typically a self-limiting condition with an excellent prognosis. Most patients will have a return to normal or near normal vision without treatment. Antimicrobial therapy may be used to hasten recovery. Successful oral agents include rifampin, ciprofloxacin, doxycycline, sulfamethoxazole and trimethoprim.^{23,24}

A commonly used therapy is doxycycline 100mg PO BID for two to four weeks.^{23,24} Alternately, azithromycin 250mg to 500mg PO BID for two to four weeks may be used. Frankly, the absence of controlled clinical studies and lack of consensus makes pretty much every standard course of oral antibiotics a possible therapy.

Oral steroids may also be used to mitigate inflammation.^{25,26} Intravitreal injection of Avastin (bevacizumab, Genentech) has been shown to improve both visual acuity as well as decrease macular edema.²⁵ However, the overall good prognosis of neuroretinitis may not justify this treatment, especially since this information comes from case reports and not from controlled clinical trials. Those who are immunocompromised should be given strong consideration for antibiotic treatment.

For the patient presented here, her poor vision and anxiety made for the choice to initiate a four-week course of doxycycline 100mg BID PO. When she missed her scheduled two-week follow up appointment, she was called and, over the phone, she stated that she recently stopped taking the medication because it upset her stomach. Her vision was improving, though there was no way to quantify. She was offered a different antibiotic, but declined. She was reappointed for one week but was lost to follow-up after the phone call.

Takeaways

When encountering neuroretinitis from suspected cat scratch disease, it may help to remember this rhyme: “When the vision loss great and the APD mild, it’s often the bite of something wild.” ■

1. Wade NK, Levi L, Jones MR, et al. Optic disk edema associated with peripapillary serous retinal detachment: an early sign of systemic *Bartonella henselae* infection. *Am J Ophthalmol.* 2000;130(3):327-34.
2. Ghauri RR, Lee AG. Optic disk edema with a macular star. *Surv Ophthalmol.* 1998;43(3):270-4.
3. Suhler EB, Lauer AK, Rosenbaum JT. Prevalence of serologic evidence of cat scratch disease with neuroretinitis. *Ophthalmology.* 2000;107(5):871-6.
4. Pérez G J, Munita S JM, Araos B R, et al. Cat scratch disease associated neuroretinitis: clinical report and review of the literature. *Rev Chilena Infectol.* 2010;27(5):417-22.
5. Biancardi AL, Curi AL. Cat-scratch disease. *Ocul Immunol Inflamm.* 2014;22(2):148-54.
6. Ksiazia I, Abroug N, Mahmoud A, et al. Update on Bartonella neuroretinitis. *J Curr Ophthalmol.* 2019;31(3):254-61.
7. Moreno RJ, Weisman J, Waller S. Neuroretinitis: an unusual presentation of ocular toxoplasmosis. *Ophthalmologie.* 1980;215:53-8.
8. Arruga J, Valentines J, Mauri F, et al. Neuroretinitis in acquired syphilis. *Doc Ophthalmol.* 1986;64:23-9.
9. Karma A, Stenborg T, Summanen P, et al. Long-term follow-up of chronic Lyme neuroretinitis. *Retina.* 1996; 16(6):505-9.
10. Margo CE, Sedwick LA, Rubin ML. Neuroretinitis in presumed visceral larva migrans. *Retina.* 1986;6(2):95-8.
11. Neppert B. Measels retinitis in an immunocompetent child. *Klinische Monatsblätter für Augenheilkunde.* 1994;205:156-60.
12. Foster RE, Lowder CY, Meisler DM, et al. Mumps neuroretinitis in an adolescent. *Am J Ophthalmol.* 1990;110(1):91-3.
13. Stechschulte SU, Kim RY, Cunningham ET Jr. Tuberculous neuroretinitis. *J Neuro-Ophthalmol.* 1999;19(3):201-4.
14. Donnio A, Buestel C, Ventura E, et al. Cat-scratch disease neuroretinitis. *J Fr Ophtalmol.* 2004;27(3):285-90.
15. George JG, Bradley JC, Kimbrough RC, et al. Bartonella quintana associated neuroretinitis. *Scand J Infect Dis.* 2006;38(2):127-8.
16. Brazis PW, Stokes HR, Ervin FR. Optic neuritis in cat scratch disease. *J Clin Neuroophthalmol.* 1986;6(3):172-4.
17. Chrousos GA, Drack AV, Young M, et al. Neuroretinitis in cat scratch disease. *J Clin Neuroophthalmol.* 1990;10(2):92-4.
18. Dehio C. Molecular and cellular basis of bartonella pathogenesis. *Annu Rev Microbiol.* 2004;58:365-90.
19. Matsuo T, Kato M. Submacular exudates with serous retinal detachment caused by cat scratch disease. *Ocul Immunol Inflamm.* 2002;10(2):147-50.
20. Flexman JP, Chen SC, Dickeson DJ, et al. Detection of antibodies to *Bartonella henselae* in clinically diagnosed cat scratch disease. *Med J Aust.* 1997;166(10):532-5.
21. Hahot-Wilner Z, Zur D, Goldstein M, et al. Macular findings on optical coherence tomography in cat-scratch disease neuroretinitis. *Eye (Lond).* 2011;25(8):1064-8.
22. Cruzado-Sánchez D, Tobón C, Lujan V, et al. Neuroretinitis caused by *Bartonella henselae*: a case with follow up through optical coherence tomography. *Rev Peru Med Exp Salud Publica.* 2013;30(1):133-6.
23. Rosen B. Management of *B. henselae* neuroretinitis in cat-scratch disease. *Ophthalmology.* 1999;106(1):1-2.
24. Rosen BS, Barry CJ, Nicoll AM, et al. Conservative management of documented neuroretinitis in cat scratch disease associated with *Bartonella henselae* infection. *Aust N Z J Ophthalmol.* 1999;27(2):153-6.
25. Cakir M, Cekiç O, Bozkurt E, et al. Combined intravitreal bevacizumab and triamcinolone acetonide injection for idiopathic neuroretinitis. *Ocul Immunol Inflamm.* 2009;17(3):221-3.
26. Fairbanks AM, Starr MR, Chen JJ, Bhatti MT. Treatment strategies for neuroretinitis: current options and emerging therapies. *Curr Treat Options Neurol.* 2019;21(8):36.



EDITED BY PAUL M. KARPECKI, OD
CHIEF CLINICAL EDITOR

OCULAR SURFACE REVIEW

Neurological DED Management in Action

Promising new treatments consider a different route to alleviation of symptoms.

BY PAUL M. KARPECKI, OD,
AND DIANA DRISCOLL, OD

We are fortunate to have numerous interventions designed to address the ocular symptoms and local inflammatory component of chronic dry eye disease (DED), but treatment options for the neurological control of tear production have been lacking.

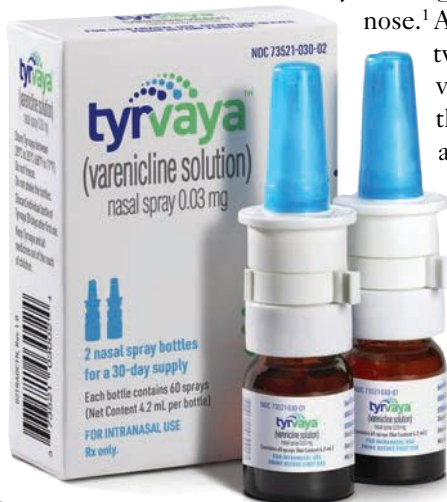Tear production is an autonomic function that relies primarily on the parasympathetic nervous system, and employing efforts that support proper functioning of the parasympathetic nervous system is a new approach to DED that can result in an increase in the patient's normal tears. Below we discuss two new treatments for neurological DED that could offer patients much-needed relief.

(Editor's note: Dr. Driscoll developed and has a financial interest in Parasymp Plus Eyes, which is discussed in this article.)

Tyrvaya

This recently FDA-approved nasal spray is a preservative-free formulation that stimulates the nicotinic acetylcholine receptors in the terminal branches of the ophthalmic trigeminal nerve within the lower nasal cavity (a localized approach to DED), according to the company. This is a natural way to stimulate tears as one-third of basal tear production is initiated

by inhaling air through the nose.¹ Administered twice a day, Tyrvaya is applied to the lower nasal area—the inside of where the lower crease on the nose is located. This may decrease some of the side effects such as throat irritation, coughing or sneezing.



Clinical trials showed a statistically significant increase in Schirmer scores and eye dryness symptoms compared to placebo at week four and sustained through week 12. Studies showed a positive tear production response with few side effects, and could be adjunctive to other treatments or potentially replace artificial tears with patients' more natural tear production.

Parasymp Plus Eyes

This second option approaches neurological dry eye both ocularly (locally) and systemically. Taking on DED as a systemic disorder addresses both inflammation and tear production simultaneously by supporting the autonomic nervous system.

Parasymp Plus Eyes is an over-the-counter supplement that supports acetylcholine

for both the nicotinic receptors of the vagus nerve and the muscarinic receptors of the lacrimal functional unit.

Stimulation of the vagus nerve helps control inflammation, and stimulation of the nerves serving the lacrimal functional unit promotes tear production. This new supplement stimulates both nicotinic and muscarinic receptors and works around genetic issues and potential nutrient deficiencies involving acetylcholine production. It does not depend upon functioning nerves to work; it depends upon the receptors themselves.



About the authors

Dr. Karpecki is medical director for Keplr Vision and the Dry Eye Institutes of Kentucky and Indiana. He is the Chief Clinical Editor for *Review of Optometry* and chair of the New Technologies & Treatments conferences. A fixture in optometric clinical education, he consults for a wide array of ophthalmic clients, including ones discussed in this article. Dr. Karpecki's full disclosure list can be found in the online version of this article at www.reviewofoptometry.com.

Dr. Driscoll's work encompasses postural orthostatic tachycardia syndrome (POTS), chronic dry eye, vagus nerve disorders and Ehlers-Danlos syndrome. She is the founder and president of Genetic Disease Investigators and the clinical director of POTS Care. An inventor with three patents to date, she is also the founder and president of TJ Nutrition, makers of Parasymp Plus Eyes.

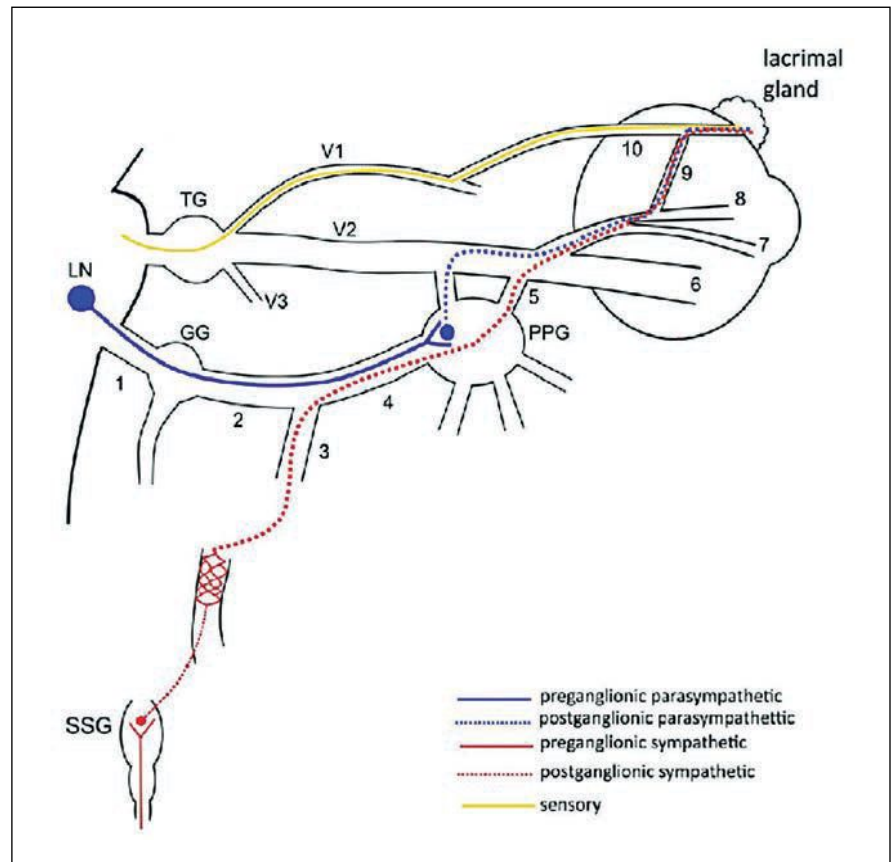
Studies showed patients notice improvement in dry eye within weeks and additional symptoms of low acetylcholine also respond (brain fog, constipation and fatigue often respond in one day).

Dry eye is a multifactorial disease and all conditions contributing to its manifestation, both local and systemic, need to be identified for proper resolution of symptoms.² As practitioners, we understand that we need to control the inflammatory response, as well as support tear production in DED. Both functions are under control of the autonomic nervous system and can be addressed neurologically. This is a new concept in chronic DED and when recognized and treated appropriately, patients not only experience improved ocular symptoms, but increased systemic wellness as well.

Inflammation and DED

We are familiar with the inflammatory component of DED and recognize autoimmune conditions such as Sjögren’s syndrome, lupus erythematosus and rheumatoid arthritis that cause systemic inflammation, ultimately affecting the eyes. In these cases, systemic treatment, in addition to ocular treatment, is often necessary for associated DED.³ Hormone fluctuations, menopause and low androgenic hormone levels are also inflammatory, may contribute to DED and should be addressed.^{4,5}

Beyond these well-understood conditions, however, chronic, systemic inflammation is rarely addressed, particularly by optometrists, due to the paucity of diagnostic and treatment options. Yet, chronic inflammation is not uncommon. Normal aging, for example, is an inflammatory state characterized by increased inflammatory cytokines that contribute to age-related illness (deemed “inflammaging”).⁶ Metabolic syndrome,



The neuroanatomy of tear production.

endocrine disorders and even inflammatory bowel disease are systemic inflammatory conditions that can contribute to DED.^{7,8,9} Recognizing chronic, systemic inflammation in our patients is important because of the damage it causes, both to the eye and systemically.

Inflammation and the Vagus Nerve

A normal, healthy body controls the inflammatory response via the autonomic nervous system. Specifically, the vagus nerve acts as the anti-inflammatory regulator of the body.^{10,11}

The vagus nerve releases acetylcholine, which controls the development and circulation of inflammatory cytokines and chemokines. When the release of acetylcholine is inhibited or the vagus nerve is damaged,

it is no longer able to control inflammation, resulting in chronic inflammation and the continued release of damaging inflammatory mediators.¹² Yet, despite its importance, testing for systemic and localized inflammatory cytokines and chemokines is quite limited in practice. It is difficult for practitioners to know if localized ocular inflammation reflects chronic, systemic inflammation because of these limitations.

As the anti-inflammatory nerve, the vagus nerve helps control inflammation throughout the body—including the eyes. This nerve also controls digestion, including stomach acid production, the pyloric valve at the base of the stomach, gastric motility, gallbladder and pancreas function, and the sphincter of Oddi, which allows release of bile and

digestive enzymes into the intestines.¹³ When not working well, inflammation increases and digestion suffers. The vagus nerve is a parasympathetic nerve and uses acetylcholine as its neurotransmitter. If this neurotransmitter is not properly released or if it is broken down prematurely, nerve function declines.

Neurology of Basal Tear Production

Autonomic basal tear production is primarily the responsibility of the parasympathetic nervous system and involves the neurotransmitters acetylcholine and vasoactive intestinal peptide. These parasympathetic nerves use acetylcholine as their neurotransmitter and receptors are primarily muscarinic.¹⁴

The neurology of tear production depends upon functioning nerves, receptors, and the proper levels of the neurotransmitter acetylcholine that allows the nerves to communicate. If the patient's neuroanatomy fails at any level, tear production declines.

Acetylcholine Ties It All Together

The vagus nerve uses acetylcholine as its neurotransmitter. Basal tear production stimulated by the parasympathetic nervous system also utilizes acetylcholine as its neurotransmitter. DED often involves both low tear production and inflammation and both can be affected by a single neurotransmitter—acetylcholine. Although the vagus nerve does not innervate the eye, acetylcholine is the commonality that can tie together both of these autonomic functions.

If acetylcholine is not released properly for any reason, inflammation increases and tear production decreases. Parasympathetic nerve function can decline for several reasons: damage to the nerves themselves, ingestion of medications that break down acetylcholine (*e.g.*, anti-

“ If acetylcholine is not released properly for any reason, inflammation increases and tear production decreases. ”

cholinergics such as Benadryl) and genetics can all affect its production. Some inflammatory cells—and the chemokines they release—can also block the release of acetylcholine. In Sjögren's syndrome, for example, lymphocytes and chemokines begin to affect the release of acetylcholine, contributing to development and perpetuation of dry eye disease, prior to damage to the acinar cells.¹⁵

Recognizing Low Acetylcholine Levels

Acetylcholine cannot be measured through a blood test because acetylcholine breaks down very easily. Anticholinergic medications destroy acetylcholine (such as atropine and diphenhydramine) resulting in anticholinergic syndrome.

We can look at these symptoms for more subtle signs that this is affecting our patients, including increased body temperature, mydriasis (often with light sensitivity), dry eyes and mouth, flushed face and delirium, as well as orthostatic hypotension, brain fog, fatigue and a fast heart rate. Patients may be forgetful, moody, frequently constipated or easily fatigued. Dry eyes, often accompanied with dry mouth, may be assumed to be Sjögren's syndrome despite normal testing results.

The majority of patients diagnosed with chronic fatigue syndrome/myalgic encephalomyelitis also display the majority of these symptoms, but this aspect of the illness can be overlooked without a diagnostic blood test.¹⁶ If the parasympathetic receptors are still viable in these patients, we have a new treatment option for this presentation in the form of Parasymp Plus Eyes.

New Possibilities

This newfound ability to address neurological dry eye in our patients should be able to give us greater control over DED's manifestations in our patients. These unique therapies that provide neurological support offer practitioners new avenues for effective DED management and have the potential to dramatically improve our DED patients quality of life. ■

- Gupta, A, Heigle T, Pflugfelder SC. Nasolacrimal stimulation of aqueous tear production. *Cornea*. 1997;16(6):645-8.
- Calonge M, Enriquez-de-Salamanca A, Diebold Y, et al. Dry eye disease as an inflammatory disorder. *Ocul Immunol Inflamm*. 2010;18(4):244-53.
- Henrich CF, Ramulu PY, Akpek EK. Association of dry eye and inflammatory systemic diseases in a tertiary care-based sample. *Cornea*. 2014;33(8):819-25.
- Nguyen CQ, Peck AB. Unraveling the pathophysiology of Sjogren syndrome-associated dry eye disease. *Ocul Surf*. 2009;7(1):11-27.
- Truong S, Cole N, Stapleton F, Golebiowski B. Sex hormones and the dry eye. *Clin Exp Optom*. 2014;97(4):324-36.
- De Martinis M, Franceschi C, Monti D, Ginaldi L. Inflamm-aging and lifelong antigenic load as major determinants of ageing rate and longevity. *FEBS Lett*. 2005;579(10):2035-9.
- Tang YL, Cheng YL, Ren YP, et al. Metabolic syndrome risk factors and dry eye syndrome: a Meta-analysis. *Int J Ophthalmol*. 2016;9(7):1038-45.
- Chopra R, Chander A, Jacob JJ. The eye as a window to rare endocrine disorders. *Indian J Endocrinol Metab*. 2012;16(3):331-8.
- Mrugacz M, Sredzińska-Kita D, Cyra-Jarocka E, Bakunowicz-Lazarczyk A. Dry eye syndrome and cataract as ocular manifestations of Crohn's disease. *Klin Oczna*. 2005;107(7-9):509-10.
- Pavlov VA, Tracey KJ. Controlling inflammation: the cholinergic anti-inflammatory pathway. *Biochem Soc Trans*. 2006;34(6):1037-40.
- Pavlov VA, Wang H, Czura CJ, et al. The cholinergic anti-inflammatory pathway: a missing link in neuroimmunomodulation. *Mol Med*. 2003;9(5-8):125-34.
- Czura CJ, Tracey KJ. Autonomic neural regulation of immunity. *J Intern Med*. 2005;257(2):156-66.
- Rogers RC, McTigue DM, Hermann GE. Vagal control of digestion: modulation by central neural and peripheral endocrine factors. *Neurosci Biobehav Rev*. 1996;20(1):57-66.
- Dartt DA. Neural regulation of lacrimal gland secretory processes: relevance in dry eye diseases. *Prog Retin Eye Res*. 2009;28(3):155-77.
- Zoukhri D, Kublin CL. Impaired neurotransmitter release from lacrimal and salivary gland nerves of a murine model of Sjögren's syndrome. *Invest Ophthalmol Vis Sci*. 2001;42(5):925-32.
- Driscoll D. Correcting the missing piece in chronic fatigue syndrome – part 1: discovery. www.vagusnervesupport.com/wp-content/uploads/2017/11/Chronic-Disease-Digest-Text-Correcting-the-Missing-Piece-in-Chronic-Fatigue-Syndrome.pdf. January 2016. Accessed December 1, 2021.



“ I didn't realize
STARS
were little dots that twinkled ”

—Misty L, *RPE65* gene therapy recipient

**WE'RE SEEING
AMAZING RESULTS.
AND SO ARE THEY.**

At the Foundation Fighting Blindness our mission is everybody's vision. Our work shines a light on the darkness of inherited retinal diseases (IRDs).

We're the world's leading organization searching for treatments and cures. We need your help to fuel the discovery of innovations that will illuminate the future for so many. We have robust disease information, a national network of local chapters and support groups, local educational events, and our My Retina Tracker® Registry to help keep your patients connected with clinical and research advancements.

Help accelerate our mission
by donating at ECPs4Cures.org.

**FOUNDATION
FIGHTING
BLINDNESS**

FightingBlindness.org

Stop the Swelling

A complex condition is the culprit.

A 58-year-old Hispanic male presented with blurry vision in his left eye for approximately two weeks. His medical history is significant for having chronic kidney disease which resulted in a kidney transplant one year earlier and is currently undergoing dialysis. His blood pressure is now under control. He has been maintained on oral prednisone 10mg as well as tacrolimus. He was also on ethambutol 400mg TID for two months because of a “spot” that was found on his lung.

Upon examination, his uncorrected distance visual acuities measured 20/40 in each eye but corrected to 20/20 with a mild astigmatic correction. Confrontation visual fields were full to careful counting in the right eye, but the left eye had a significant depression inferior nasal. His pupils were equally round and reactive to

light; there was no afferent pupillary defect (APD). His extraocular motility was full and cover test was ortho at distance. His anterior segment was unremarkable. Tensions were 14mm Hg with Tonopen (Reichert).

On dilated fundus exam, the vitreous in both eyes was clear. The right eye looked completely normal and the left eye he had obvious fundus changes (*Figure 1*). An OCT was performed and is available for review.

Take the Retina Quiz

1. *What additional testing is necessary?*

- Visual field.
- Sedimentation rate and C-reactive protein test.
- CT/MRI.
- All of the above.

2. *What is the most likely diagnosis for this patient?*

- Malignant hypertension.
- Toxic optic neuropathy.
- Infiltrative optic neuropathy.
- AION.

3. *What is the likely cause?*

- Ethambutol.
- Tacrolimus.
- Focal ischemia to the optic nerve from vascular disease.
- Large blood vessel inflammation.

4. *How should this be managed?*

- Observation.
- Stop the medications.
- Increase prednisone dosage.
- B or C.

Discussion

It was surprising to see that our patient had significant disc swelling in the left eye with surrounding flame hemorrhages and subretinal hemorrhage. What’s more, he still has excellent visual function being correctable to 20/20. A 24-2 full threshold visual field was performed and showed an enlarged blind spot in addition to an inferior nasal defect in the left eye,

which is not surprising considering the amount of disc swelling that was present. The right eye was completely normal.

So, what is going on with our patient? Does this represent ethambutol toxicity? Indeed, he was on ethambutol for a “spot” on his lung which turned out to be from mycobacterium avium complex. Ethambutol is a bacteriostatic antimicrobial agent that is used as a first-line agent against

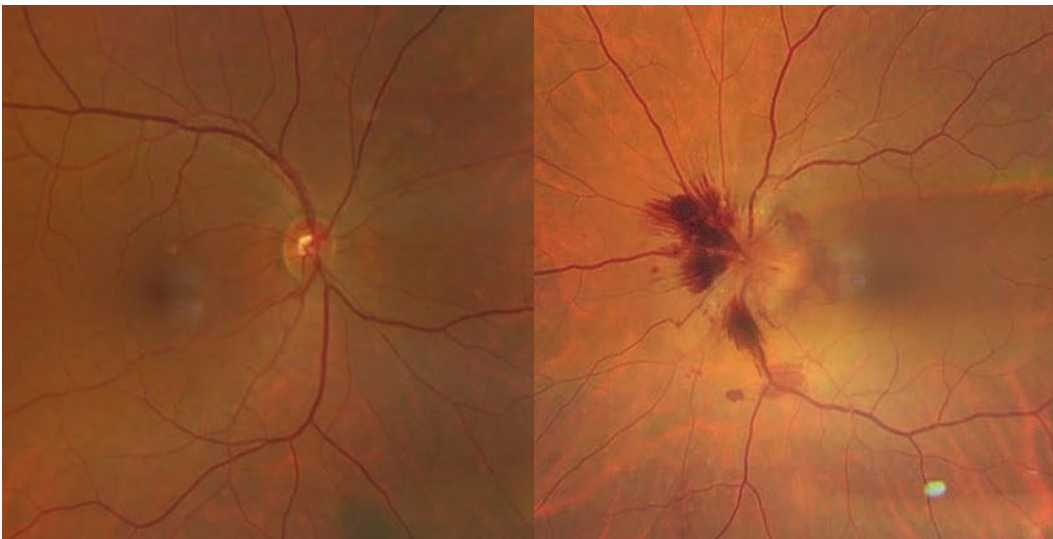

Fig. 1. Images of the right and left eyes. Note the appearance of the left eye with obvious fundus changes.

About Dr. Dunbar

Dr. Dunbar is the director of optometric services and optometry residency supervisor at the Bascom Palmer Eye Institute at the University of Miami. He is a founding member of the Optometric Glaucoma Society and the Optometric Retina Society. Dr. Dunbar is a consultant for Carl Zeiss Meditec, Allergan, Regeneron and Genentech.

tuberculosis. It acts as a chelating agent that disrupts one of several metal-containing enzyme systems in the nucleic acid structure of mycobacteria. Unfortunately, ethambutol has the potential to cause a toxic optic neuropathy, even at doses that are considered appropriate. In the optic nerve, the agent is thought to chelate copper. The reduced copper levels impair mitochondrial activity, thus reducing axon transport leading to a toxic optic neuropathy.¹

Patients with ethambutol toxicity may have reduced acuity, visual field defects (cecocentral or bitemporal defects) as well as reduced color vision, even in the presence of a normal appearing optic nerves. Over time, the optic nerves develop pallor.

We decided this was not from ethambutol toxicity, but rather from an anterior ischemic optic neuropathy (AION). Ethambutol toxicity is bilateral, and patients generally don't get disc swelling like our patient had. With AION, patients present with an acute painless loss of vision in one or both eyes. Disc swelling and/or pallor is present, which is often segmental. Patients will also have visual field loss—often an altitudinal defect—and an APD. Note that our patient did not have an APD, which may have been because he still had good visual function, or it's possible the APD was subtle and could have been missed when doing pupillary testing.

Most patients with AION have underlying vascular disease, such as hypertension, diabetes or hypercholesterolemia, which puts them at a greater risk for stroke, heart attack and even death from their vascular disease. Our patient did have chronic hypertension from his longstanding kidney disease but he is now controlled. Sleep apnea is also a significant risk factor for developing AION.

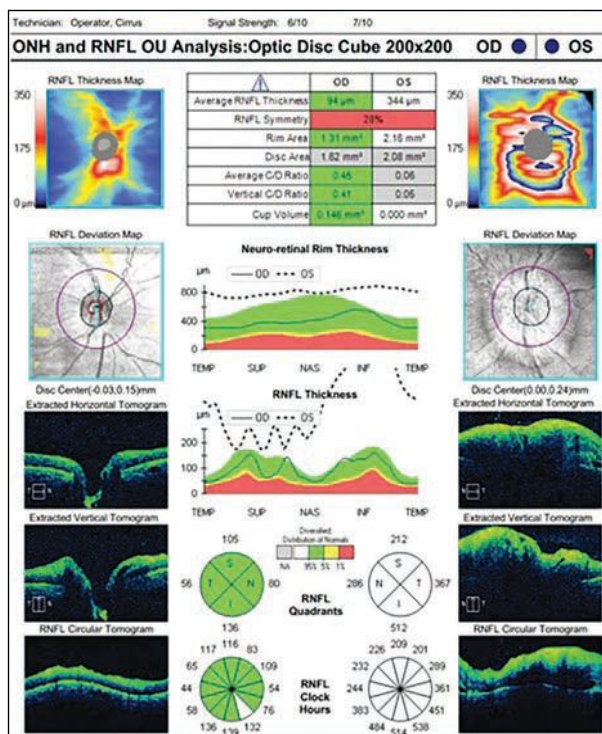


Fig. 2. OCT of the right and left eyes. How do you explain the RNFL findings in the left eye?

He denied a history of snoring or sleep apnea.

Some medications have been linked to the development of AION. In particular, erectile dysfunction medications have been known to increase the risk of AION, especially in those with “disc at risk” configurations. Those are optic nerves that are smaller or crowded with minimal or absent cups. Looking at the fellow eye can often provide a clue in determining if the affected eye has a “disc at risk.” The nerve in the fellow eye of our patient did not seem to fit this configuration with a cup-to-disc ratio of around 0.4.

Our patient was not on any erectile dysfunction medications, but he was on tacrolimus, which is primarily used as an immunosuppressant medication after organ transplants to prevent rejection. Although it is well-tolerated, AION has been reported as a rare but serious complication from this drug.²⁻⁴ It is not understood why patients develop this, but several theories have been postulated including vasoconstriction and ischemia to the optic

nerve that occurs from the tacrolimus or possibly from a direct neurotoxic effect of the drug.

In our patient, it is difficult to know if the AION was caused by tacrolimus use or if it was just a chance occurrence in an at-risk vasculopathic individual. Nonetheless, an extensive work-up including complete blood count, comprehensive metabolic panel, toxoplasmosis and Toxocara titers were performed, as well as a rapid plasma reagin for syphilis screening, fluorescent treponemal antibody-absorption, bartonella, anti-mitochondrial antibody, and an erythrocyte sedimentation rate (ESR) and C-reactive protein (CRP) was obtained. Everything was negative with the exception of an elevated ESR and CRP. A CT scan was

also obtained and came back normal, but we were not able to use contrast because of his kidney transplant, nor were we able to do an MRI because he had a defibrillator.

The transplant team was notified of these findings and it was recommended that he stop the ethambutol. We increased his dosage of prednisone to 30mg per day with a tapering dose and he was followed closely. At his three month follow-up, the disc swelling was significantly reduced and his vision was still 20/20, although he still had an inferior nasal visual field defect. We decreased prednisone back to 10mg and he continues to be followed. ■

1. Melamud A, Kosmorsky GS, Lee MS. Ocular ethambutol toxicity. *Mayo Clin Proc.* 2003;(11):1409-11.
2. Brazis PW, Spivey JR, Bolling JP, Steers JL. A case of bilateral optic neuropathy in a patient on tacrolimus (FK506) therapy after liver transplantation. *Am J Ophthalmol.* 2000;129(4):536-8.
3. Kessler L, Lucescu C, Pinget M, et al. Tacrolimus-associated optic neuropathy after pancreatic islet transplantation using a sirolimus/tacrolimus immunosuppressive regimen. *Transplantation* 2006;81(4):636-7.
4. Yun J, Park KA, Oh SY. Bilateral ischemic optic neuropathy in a patient using tacrolimus (FK 506) after liver transplantation. *Transplantation.* 2010;89:1541-2.



BY JAMES L. FANELLI, OD

GLAUCOMA GRAND ROUNDS

We are the Specialists of Eye Care

It's up to us to manage the global ocular health of our patients, even when other providers are involved, too.

A 58-year-old female self-referred to another provider, but eventually made it back to my office—with more issues than she left with.

Diagnostic Data

In late 2017, a new patient presented for a comprehensive evaluation secondary to blurred vision OS>OD. She reported that her vision had been blurrier OU over the past 12 months. Medications included an antibiotic, a nasal spray and an oral steroid, as she was dealing with chronic sinusitis. She had an allergy to sulfa drugs.

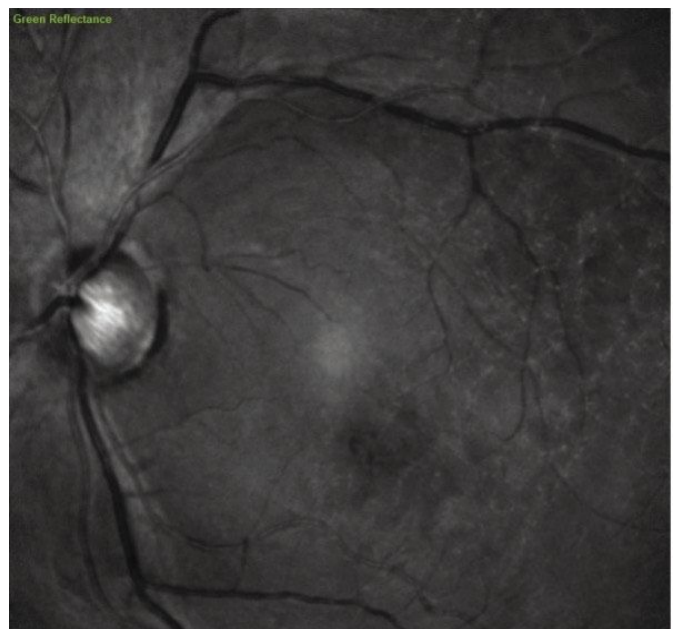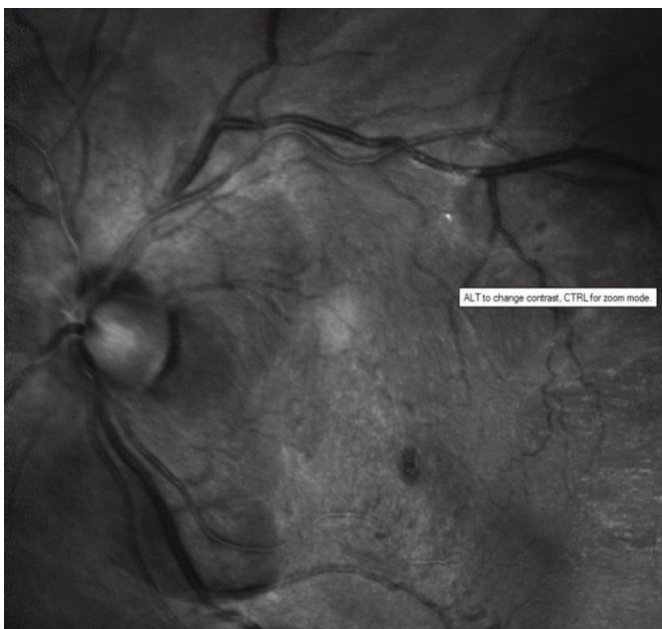Her entering uncorrected distance visual acuities were 20/25- OD and 20/50- OS. Pupils were ERRLA with no afferent pupillary defect. EOMs were full in all positions of gaze. She wore OTC readers. Best-corrected acuities through minimally hyperopic and astigmatic correction were 20/20 OD and 20/40-OS.

A slit lamp examination of the patient's anterior segments was unremarkable OU. Applanation tensions were 19mm Hg OD and OS. The anterior chamber angles were wide open, and her anterior chambers were quiet. Upon dilation, her crystalline

lenses were clear OU. The vitreous cavity OD was essentially unremarkable, whereas the left showed a partial PVD. She denied flashes and floaters.

Through dilated pupils, her posterior pole was remarkable for slightly large discs OU with concurrent large cups OS>OD. Cup-to-disc ratios were 0.55 x 0.6 OD and 0.55 x 0.7 OS. The right macula was clear; the left was characterized by a distinct ERM with what appeared to be a macular pseudohole. There were no concurrent macular diseases present. The retinal vasculature was healthy, with no abnormalities noted. Her peripheral retinal evaluation was unremarkable OU except for the partial PVD with remaining peripheral retinal vitreomacular adhesion (VMA).

Based on these findings, fundus photos and posterior pole OCT images were obtained at the initial visit. Macular OCT confirmed ERM along with pseudohole secondary to mild VMA. The patient was asked



Note the initial central macular and foveal distortion.

Here we see significant reduction in distortion post-vitrectomy.

About Dr. Fanelli

Dr. Fanelli is in private practice in North Carolina and is the founder and director of the Cape Fear Eye Institute in Wilmington, NC. He is chairman of the EyeSki Optometric Conference and the CE in Italy/Europe Conference. He is an adjunct faculty member of PCO, Western U and UAB School of Optometry. He is on advisory boards for Heidelberg Engineering and Glaukos.

OPHTHALMIC Product Guide



Hold your mobile device over the code to view reviewofoptometry.com/publications/archive.



Innovative products to enhance your practice

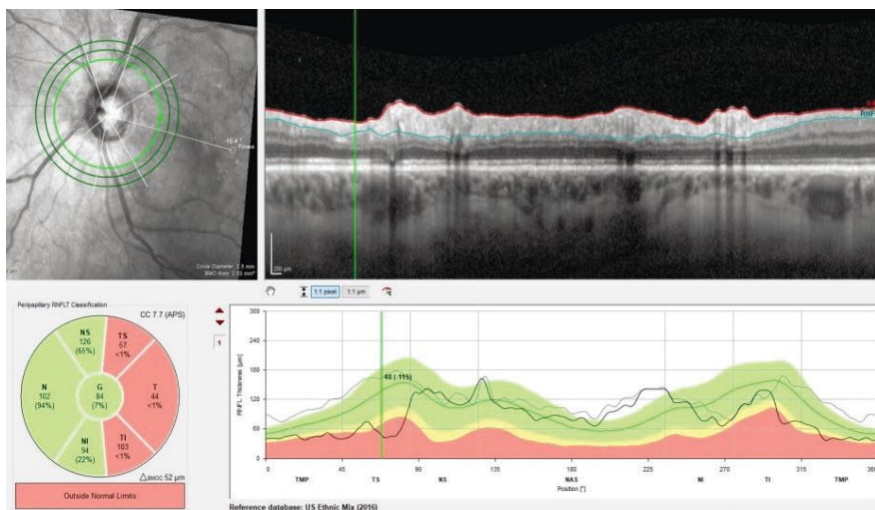
Experience Review's Product Guide in print or digital. Simply select the products, devices or services you'd like to be contacted about for more information.

www.reviewofoptometry.com/publications/archive

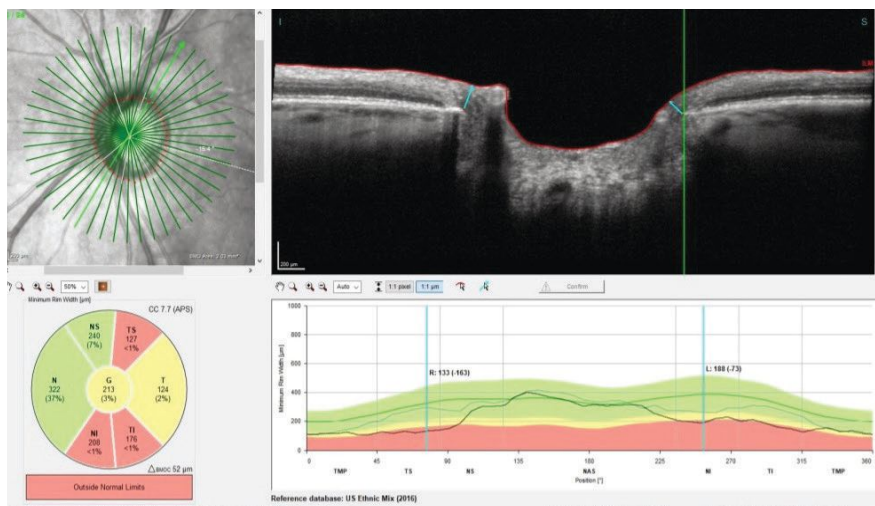
NEW IN 2021: E-BLAST PRODUCT SHOWCASE!



This year, in addition to mailing the print edition and hosting the digital versions of the Product Guide on our website, we will be blasting each company's listings to our OD email database! Each company will have a designated product showcase deployment day following distribution of the print editions, providing an additional opportunity to receive more information on all the items you want!



Follow-up RNFL circle OCT scans OS compared with baseline. Note in the area marked on the TSNIT graph a 115µm decrease in thickness from baseline. In conjunction with the last image, it is clear that this is glaucomatous change.



Radial scans of the neuroretinal rim, measuring the BMO-MRW. Note that this is a follow-up scan compared with baseline, and in the superotemporal sector indicated, there is a 163µm decrease in neuroretinal rim width. This is not related to VMA release.

to return in six to eight weeks for a dilated exam to follow-up on the partial PVD and subsequent VMA, as well as the presence of suspicious discs.

The patient followed up as asked, and optic nerve and macular OCTs were obtained. The OCT of the left eye was unchanged from the baseline scan. The optic nerve OCT demonstrated slightly larger discs and a slightly thinned though statistically normal neuroretinal rim OS on BMO-MRW radial scans. Her circumpapillary RNFL scans were

normal. Applanation tensions at this visit were 21mm Hg OD and 20mm Hg OS. She was asked to follow-up in six months to reassess the maculae and the optic nerves.

She presented at this visit with complaints of “somewhat blurrier” vision OS. Visual acuities OD were unchanged, whereas those of the left eye had decreased to 20/50, with no pinhole improvement. Applanation tensions were 20mm Hg OD and 21mm Hg OS. On dilated fundus examination, it was clear that the VMA had released, leaving behind

a slightly increased presence of an ERM. This was confirmed on OCT imaging. Her optic nerves were stable on OCT, both from a peripapillary RNFL and BMO radial scan perspective.

We discussed her options for improving vision in the left eye vs. passive monitoring. She indicated she would prefer to see how things progressed over the next six months. When she returned at that time, her acuities and OCTs were stable, as were her complaints of decreased vision OS and she seemed content. At this point, we were in mid-2019, and she was asked to return in six months.

Compliance with patient care can always be an issue, whether it is related to glaucoma medication schedules or follow-ups. This patient, though initially compliant with scheduled visits, ultimately chose to see a retinologist related to her decreased vision OS.

She presented back to me in late spring of 2021 with complaints of worsening vision in the left eye. She reported that the retinologist did a “procedure” on her left eye in early 2020 that resulted in some improvement in vision OS, but she said it seemed to be worsening. The retinologist discharged her and told her he had done all he could for her vision at that point. She last saw him in early 2021.

At her first visit back with me, the right eye was unchanged. The left eye, however, had reduced visual acuity to 20/80-, best-corrected to 20/50- through a moderately myopic correction. Upon slit lamp examination, she had 2+ nuclear sclerosis OS; the crystalline lens of the right eye was clear. On dilated fundus examination, she had a vitrectomy and membrane peel OS, and the macular appearance had improved compared with pre-retinal surgery. However, there was a significant change in both her RNFL circle scans as well as the BMO radial optic nerve scans. Essentially, there was significant thinning to the RNFL and the neuroretinal rim OS. There

were no optic nerve changes seen *in vivo* or on OCT imaging of the right eye.

Clearly, the reduced visual acuity OS was primarily due to the cataract, which is common post-vitreotomy. However, of more concern was the significant thinning of the RNFL and the neuroretinal rim OS on OCT.

Discussion

This case makes two major points, the latter being the most important.

Point 1. Typically, as glaucoma progresses we will observe thinning in three areas of the posterior segment OCT scans: the macular ganglion cell layer, circumpapillary RNFL and BMO radial scans of the neuroretinal rim. That said, concurrent macular disease can interfere with our interpretation of the ganglion cell layer and the circumpapillary RNFL. In these cases, where there is an ERM with or without VMA or vitreomacu-

lar traction (VMT), the RNFL in particular can be distorted and measures of RNFL thickness can be artificially elevated. Furthermore, following membrane peels or release of VMT or VMA, those once-thicker RNFL readings may subsequently measure thinner. This doesn't necessarily indicate glaucomatous progression on OCT; you may be looking at changes in the RNFL (and ganglion cell layer to a lesser degree) due to the concurrent macular disease. Remain cautious of what your OCT is telling you, and also what it's not telling you.

In this case, however, while there is significant RNFL thinning, the large majority is occurring in the inferotemporal and superotemporal sectors, both of which are where glaucomatous damage is seen. Furthermore, there is progressive thinning of the neuroretinal rim, which is not affected by the patient's VMA or ERM. OCT makes it clear the patient has devel-

oped significant glaucomatous changes OS since last seen pre-vitreotomy.

Point 2. Unfortunately, all too often my fellow OD colleagues mention they are not going to give a patient who is seeing a retinologist a complete exam. They assume the other ophthalmic provider is a "specialist" and therefore has all of the aspects of care under control. That can be a slippery slope. This is a good example of that scenario. The retinologist did what retinologists do: a vitrectomy and a membrane peel. But he didn't deal with the cataract that was forming (our job) or the glaucoma that developed following surgery (definitely our job).

We are the specialists in eye care. We are charged with managing the global eye health of our patients correctly. You are responsible for the patient in your chair, even for conditions they may already be undergoing treatment for with another provider. ■

ADVERTISER INDEX

This index is published as a convenience and not as part of the advertising contract. Every care will be taken to index correctly. No allowance will be made for errors due to spelling, incorrect page number, or failure to insert.

ABS Smart Mirror.....	31
.....(888) 989-4227	
..... info@acep.tech	
..... www.acep.tech	
Bruder Ophthalmic Products.....	39
.....(888) 827-8337	
..... eyes@bruderophthalmic.com	
..... order.bruder.com	
CooperVision.....	15
..... www.coopervision.com	
CooperVision.....	21
..... www.coopervision.com	
Eyeris.....	27
.....(833) 439-3747	
..... www.myeeris.com/doctor-signup	
Glaukos.....	84
.....(800) 452-8567	
..... www.ilinkExpert.com	
Johnson & Johnson.....	37
..... www.jnvisionpro.com	
Johnson & Johnson.....	83
..... www.jnvisionpro.com	
Johnson & Johnson.....	Cover Tip
..... www.eyesongenes.com	

Keeler Instruments.....	16
.....(800) 523-5620	
..... www.keelerusa.com	
Lombart : Advancing Eyecare.....	19
.....(800) Lombart	
..... www.lombartinstrument.com	
MacuLogix.....	25
..... www.maculogix.com	
Nanodropper.....	29
.....(507) 405-5676	
..... support@nanodropper.com	
..... www.nanodropper.com	
Novartis Pharmaceuticals.....	2, 3 & 4
..... www.novartis.com	
Oyster Point.....	43 & 44
..... www.tyrvaya-pro.com	
Omni.....	13
..... www.considerMIGSEarly.com	
RegenerEyes.....	23
.....(877) 206-0706	
..... www.regenereyes.com	
US Ophthalmic.....	9
.....(888) 881-1122	
..... www.usophthalmic.com	
VSP.....	7
..... www.partneringWithPremier.com	
Xcel Specialty.....	11
.....(800) 241-9312	
..... xcelinfo@xcel specialtycontacts.com	
..... www.xcelspecialtycontacts.com	



EDITED BY DEREK N. CUNNINGHAM, OD,
AND WALTER O. WHITLEY, OD, MBA

SURGICAL MINUTE

On the Bubble

Silicone vitrectomy helps save eyes with severe globe trauma.

When treating patients with ocular trauma, we need to know how to triage appropriately, assess the situation, evaluate and treat the condition and refer if indicated. In cases of severe globe trauma, the majority will likely be seen in the emergency room or at the specialist's office. Nonetheless, we should be prepared to assist.

Severe globe trauma occurs when the integrity of one or more membranes of the eye is disrupted by blunt or penetrating force. It represents one of the biggest challenges eye surgeons will face. Historically, severe globe trauma would often result in removal of the eye.

Significant surgical advancements have allowed us to save more eyes and reconstruct if necessary, but the concept of regaining any vision was not reasonable. Through the continued refinement of surgical techniques and remarkable efforts from retinal surgeons, we are able to witness surgeries like silicone vitrectomies.

Repairing a Rupture

The presented case is trauma is from a nail injury, which caused a posterior rupture. Initial evaluation showed very little chance that the eye could be

saved, but an exploratory vitrectomy/lensectomy was attempted. Upon initial presentation, a proper assessment of the posterior pole was not possible due to excessive bleeding in the vitreous cavity. Once the vitreous hemorrhage was cleared, a reasonable amount of salvageable retina was discovered amongst overwhelming scar tissue.

In this procedure, a 360° retinectomy was performed to free up the retina so it was not tethered to one position for accessibility. The surgeon then attempted to atraumatically remove as much subretinal scar tissue as possible.

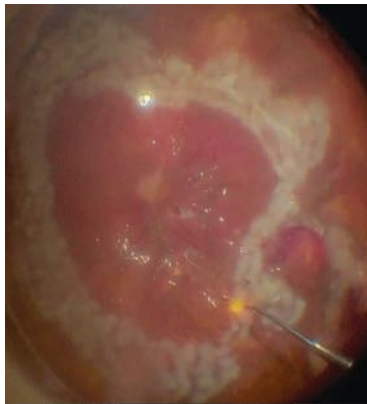


Photo: Derek Cunningham, OD

Subretinal scar tissue is removed during a silicone vitrectomy.

The surgeon must keep a fine balance, as the more scar tissue that is removed, the greater the likelihood of choroidal hemorrhage. In this case, the surgeon was able to delaminate most of the subretinal scar tissue, greatly aiding in its removal.

The next step is to create a bubble with perfluorocarbon liquid that slowly and carefully increases the bubble size to flatten the retina. Once the retina is reasonably flat, a brush is used to manipulate the retinal tissue into position and also to try and remove remaining retinal folds. While this gentle flattening and smoothing is being done, more perfluorocarbon is added to the space. The surgeon must take exceptional care during manipulation of the retina with

physical tools, as a retinal break or tear can easily happen at this stage.

Several rows of barricade laser are added around the periphery of the retina to keep it in place. An air fluid exchange is performed, and the vitreous cavity is filled with silicone oil, which acts as a reliable tamponade for the retina and is often used for complex retinal detachment surgeries.

In most cases, the oil will be removed at a later point to avoid long-term silicone oil–related complications such as glaucoma. There is a fine balance in how long to leave the oil in, though. The patient will not see as well, but it is thought that the longer the oil is left in the eye, the more you decrease risk of recurrent detachment.

Remember that even when the oil is removed, there are a significant amount of complications to watch for in addition to recurrent retinal detachment, such as emulsification, silicone oil in the anterior chamber, keratopathy, glaucoma, chronic hypotony, cataract, adherence of oil droplets to an intraocular lens, silicone oil invasion of the retina and optic nerve and unexplained visual loss following removal.

Due to the complexity of the case and potential complications, a patient like this should stay in close contact with both their optometrist and retina specialist for the remainder of their life.

This surgical case represents the extraordinary measures that can be taken to preserve a functional part of our patients' vision. If you are ever presented with an open globe, shield the eye (but don't patch it) to reduce the risk of any further trauma while the patient is transported to the hospital. Thankfully, these events don't occur frequently, but we must keep trying and working with our retina colleagues to best address our patient's vision and eye care needs. ■

For a video of the procedure, read this article online at www.reviewofoptometry.com.

About Drs. Cunningham and Whitley

Dr. Cunningham is the director of optometry at Dell Laser Consultants in Austin, TX. He has no financial interests to disclose. **Dr. Whitley** is the director of professional relations and residency program supervisor at Virginia Eye Consultants in Norfolk, VA. He is a consultant for Alcon.



I was only seeing light flashes early on, but light

FLASHES

when you've not seen anything for
so many years—it was wonderful

—Keith H, retinal prosthesis recipient

**WE'RE SEEING
AMAZING RESULTS.
AND SO ARE THEY.**

At the Foundation Fighting Blindness our mission is everybody's vision. Our work shines a light on the darkness of inherited retinal diseases (IRDs).

We're the world's leading organization searching for treatments and cures. We need your help to fuel the discovery of innovations that will illuminate the future for so many. We have robust disease information, a national network of local chapters and support groups, local educational events, and our My Retina Tracker® Registry to help keep your patients connected with clinical and research advancements.

Help accelerate our mission
by donating at ECPs4Cures.org.

**FOUNDATION
FIGHTING
BLINDNESS**

FightingBlindness.org

Practice For Sale



Practice Sales • Appraisals • Consulting
www.PracticeConsultants.com

**PRACTICES FOR SALE
NATIONWIDE**

Visit us on the Web or call us to learn more about our company and the practices we have available.
info@PracticeConsultants.com
925-820-6758

www.PracticeConsultants.com

Equipment For Sale

**Dr Retiring
Upgrade Your Office!!**

—Zeiss Cirrus OCT with 5000 software \$12,900

—Topcon NW8 Retinal Camera \$4,900

Both of these in Excellent Condition

—600 Designer/Name Brand Frames Gucci, Silhouette, Rayban, much more \$20 each, prefer to sell entire group

**325-212-9140
alanlarsen4@gmail.com**

**Do you have
CE Programs?**

**CONTACT US TODAY
FOR CLASSIFIED
ADVERTISING**


**Toll free:
888-498-1460
E-mail:**

sales@kerhgroup.com

Career Opportunities

**FLEXIBILITY.
FREEDOM.
CAREER GROWTH.**

With SightRite, there's a better way to practice optometry.




**Set your own
schedule**

Never work evenings or weekends again. We have plenty of flexible, part-time, and full-time positions available.



**Work less,
earn more**

The average SightRite optometrist works approximately 5 hours a day while earning more than most doctors make in an 8-10 hour day. Looking to earn even more? Simply increase your patient load to increase your salary.

Opportunities currently available in:
**CA, CT, DC, DE, FL,
MD, MO, NJ, NY, OH,
PA, RI, TN, VA.**

To find out more or to submit your resume go to:
sightrighte.com/careers

Email/call:
**info@sightrighte.com
212-764-0008 ext 223
www.sightrighte.com**



SightRite™
eye care services

Faculty



ASSISTANT PROFESSOR POSITIONS: PRIMARY CARE &/OR OPHTHALMIC OPTICS

Full-time non-tenure track faculty positions for the Chicago College of Optometry

Responsibilities: Candidates are expected to be highly knowledgeable in the field of primary care and/or ophthalmic optics and develop and teach courses and/or laboratories in the subject area. The primary care candidate must also be able to provide direct patient care and clinical instruction to professional students as well as residents, and be involved in interdisciplinary practice with other educational professionals.

Candidates must be willing to actively participate in curricular assessment, professional development, student counseling and service activities within the college, university and the scientific community. Successful candidates are also expected to be involved in research and scholarly activities, and have a sincere commitment to optometric education, community service and patient care. Primary duties include, but are not limited to:

a) Teaching

- Developing and delivering lectures and/or laboratories for related areas, as assigned;
- Embracing and enhancing the didactic philosophies in the O.D. program;
- Maintaining and expanding the high quality clinical practice environment for optometry students on rotation;
- Precepting students on clinical rotation at the Midwestern University Eye Institute when applicable;

b) Service

- Helping to maintain and grow the state of the art optometry program with a strong interdisciplinary focus that meets the needs of patients in the surrounding community; is efficient, patient friendly, and cost-effective;
- Working closely together with all optometry and ophthalmology faculty to provide a complete range of eye and vision care services;
- Participating in leadership roles in state, regional, and national optometry organizations;

c) Scholarly activity

Engaging in research and scholarly activity, including presentations at scientific meetings, research, and publication in peer reviewed journals sufficient to qualify for academic advancement in a non-tenure or tenure track position.

Qualifications: Candidates must possess a Doctor of Optometry degree from an ACOE-accredited institution, must have completed an ACOE-accredited residency, and must be eligible for an Illinois optometric state license. Primary eye care clinical expertise is also required.

Salary will be commensurate with qualifications and experience

Review of applications will begin immediately and continue until the position is filled

Contact information: Interested applicants should apply online at www.midwestern.edu and include curriculum vitae and letter of interest specifying the position and college that he/she wishes to be considered for. Application packet should include curriculum vitae and letter of interest. Inquiries may be directed to Dr. Melissa Suckow, Dean; Midwestern University: msucko@midwestern.edu.

Midwestern University is an Equal Opportunity/Affirmative Action employer that does not discriminate against an employee or applicant based upon race, color, religion, gender, national origin, disability, or veterans status, in accord with 41 C.F.R. 60-1.4(a), 250.5(a), 300.5(a) and 741.5(a).

REVIEW of OPTOMETRY

Targeting Optometrists?

CLASSIFIED ADVERTISING WORKS

- JOB OPENINGS
- CME PROGRAMS
- PRODUCTS & SERVICES
- AND MORE...

Contact us today for classified advertising:

Toll free: **888-498-1460**

E-mail: sales@kerhgroup.com

KERHGROUP





Nothing's Up

What could this case of prominent ptosis signify about the patient's overall systemic health?

A 64-year-old male presented to the clinic for a second opinion after he failed the binocular vision test for his commercial driver's license. The issue was preventing him from employment. He had an observable eye turn; when asked about it, he mentioned that he knew his eye lids had been "droopy" since childhood and that other members of his immediate family (father and brother) had the same thing. He denied variability of appearance or function.

The practitioner that had evaluated him initially (the first opinion), identified the issue and referred him to neuro-ophthalmology but he did not follow through. He had no other

systemic disease, was taking no meds and did not indicate any allergies.

Diagnostic Data

His best-corrected entering visual acuities through correction of -6.50 $-2.00 \times 180 / +2.50$ were 20/200 OD and 20/25 OS at distance and near with no improvement upon pinhole. The pertinent external findings are demonstrated in the photographs. Confrontation visual fields were full, less some lid-position superior constriction, and there was no afferent pupillary defect.

Cover test revealed a commitment 35 prism diopter right constant exotropia with steady temporal eccentric fixation, harmonious anomalous reti-

nal correspondence, no stereo, a deep suppressive adaptation with severe amblyopia.

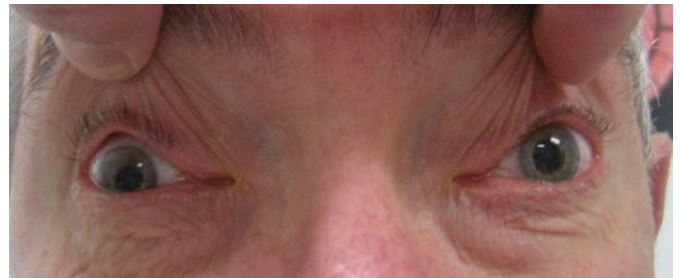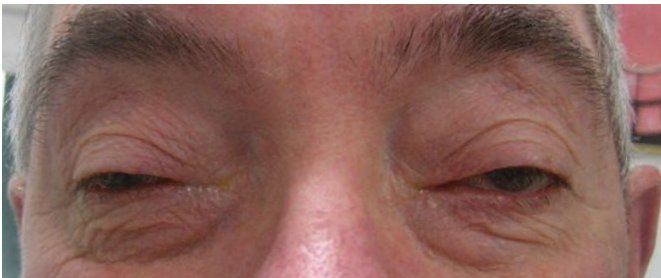Extraocular muscle motilities demonstrated limited upgaze OU with a mild adduction deficit OD. Refraction demonstrated negligible changes with minimal improvement in acuities. Biomicroscopy uncovered normal anterior segment structures and open angles OU. Goldmann intraocular pressures measured 11mm Hg OU.

The dilated fundus examination revealed mild myopic conus OU (staphyloma posticum) with no evidence of choroidal neovascularization and normal peripheries.

Your Diagnosis

What would be your diagnosis in this case? To find out, please read the online version of this article at www.reviewofoptometry.com. ■

Dr. Gurwood thanks Marc Myers, OD, for contributing this case.



What do these findings suggest about the patient? How would you approach management?

About Dr. Gurwood

Dr. Gurwood is a professor of clinical sciences at The Eye Institute of the Pennsylvania College of Optometry at Salus University. He is a co-chief of Primary Care Suite 3. He is attending medical staff in the department of ophthalmology at Albert Einstein Medical Center, Philadelphia. He has no financial interests to disclose.

Retina Quiz Answers (from page 72)—Q1: d, Q2: d, Q3: b, Q4: d

NEXT MONTH IN THE MAG

In January, we present a series on how patient-specific factors affect their relationship with you. Articles will include:

- Race & Ethnicity in Optometry: Diseases and Disparities
- A Primer on Cultural Competency and Why it Matters
- Building Stronger Ties with the Black Community

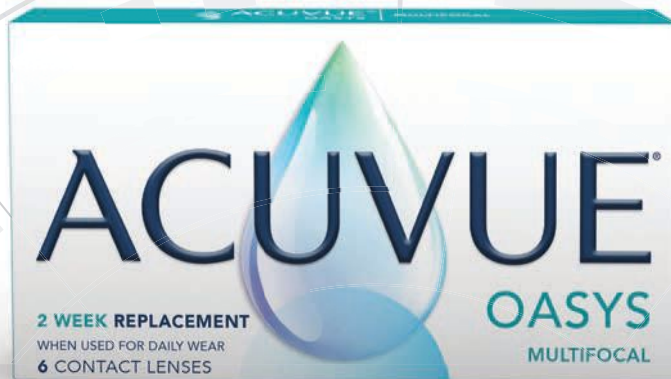- Difficult Patients: Practical Steps Toward Resolving Conflict
- Special Needs for Special Populations
- Growing Your Practice with a Focus on Pediatric Patients

Also in this issue:

- How Myopia Complicates Glaucoma Assessment
- Understanding Blue Light Risks and Remedies

ACUVUE® OASYS MULTIFOCAL

WITH PUPIL OPTIMIZED DESIGN



Designed for Superior Performance[†]



CRISP, CLEAR RELIABLE VISION

Pupil Optimized Design:
100% of parameters tailored to pupil size variations **across age and refraction** vs **<2%** for the leading competitor^{*1}



PRECISE FIT

Hybrid Back Curve includes an aspheric center to help keep the optics **in the right shape**, and a spherical periphery to help keep optics **in the right place**²



NEVER BEATEN IN COMFORT^{**}

The ACUVUE® OASYS 2-week Brand Family has **never been beaten in comfort** in **25 clinical studies**^{**}

Same design, parameters and simple fit process as
1-DAY ACUVUE® MOIST Brand Multifocal Contact Lenses.
Talk to your sales representative today.

take COMFORT in
ACUVUE®

[†]Compared to prior JJV multifocal design; technology optimized for both the parameters of refractive error and add power for a multitude of viewing distances and light levels.


^{*}Compared to leading competitors' designs; technology optimized for both the parameters of refractive error and ADD power.

^{**}www.clinicaltrials.gov is a website maintained by the NIH. The 25 clinical studies evaluated subjective comfort as a primary or secondary endpoint for ACUVUE® OASYS Brand 2-weekly and ACUVUE® OASYS with Transitions™ Light Intelligent Technology™. Review conducted as of November 12, 2020.

References: 1. JJV Data on File 2020. ACUVUE® PUPIL OPTIMIZED DESIGN TECHNOLOGY: JJVC Contact Lenses, Design Features, and Associated Benefits. **2.** JJV Data on File 2014. 1-DAY ACUVUE® MOIST MULTIFOCAL Designed for the Aging Eye.

Important Safety Information: ACUVUE® Contact Lenses are indicated for vision correction. As with any contact lens, eye problems, including corneal ulcers, can develop. Some wearers may experience mild irritation, itching or discomfort. Lenses should not be prescribed if patients have any eye infection, or experience eye discomfort, excessive tearing, vision changes, redness or other eye problems. Consult the package insert for complete information. Complete information is also available from Johnson & Johnson Vision Care, Inc. by calling 1-800-843-2020, or by visiting JNVISIONPRO.com.

© Johnson & Johnson Vision Care, Inc. 2021 | PP2021AVO4115v3 | MB-00588



We'll go first

Innovation is at the core of everything we do. At Glaukos, we push the limits of science and technology to solve unmet needs in chronic eye diseases.

Experience a world of firsts in vision care.
Learn more at [Glaukos.com](https://www.Glaukos.com).

GLAUKOS
TRANSFORMING VISION