

# REVIEW<sup>®</sup> *of* OPTOMETRY

April 15, 2022 • reviewofoptometry.com

Leadership in clinical care

TO CUT OR  
NOT TO CUT?  
Weighing Strabismus  
Surgery Referral  
PAGE 74

## 9th ANNUAL CORNEAL DISEASE

### ULTIMATE COMFORT MEETS ULTIMATE STABILITY.

The first Water Gradient toric contact lens has emerged.



Now Available.

**Great news, now there is a Water Gradient contact lens for your astigmatic patients that provides Nothing but Ultimate Comfort.<sup>1</sup>**

With our exclusive PRECISION BALANCE 8|4<sup>®</sup> design, the lens settles in an average of 37 seconds<sup>2</sup> and within 2° of ideal orientation,<sup>2</sup> for a fit so predictable, it offers 99% first-lens fit success.<sup>2\*</sup> Recommend DAILIES TOTAL1<sup>®</sup> for Astigmatism contact lenses today.



DAILIES TOTAL1<sup>®</sup> for Astigmatism. **Nothing but Ultimate Comfort.**  
Scan here and contact your Alcon Representative to learn more.

\*Based on lens movement, centration and rotation at initial fitting.

References: 1. Alcon data on file, 2021. 2. In a study where n=47; Alcon data on file, 2020.

See product instructions for complete wear, care and safety information. 

© 2022 Alcon Inc. US-DTA-2100042

**Alcon**



Letters: Genetic Testing in KCN, p. 20 • Brush Up on Your Low Vision Skills, p. 66

# REVIEW<sup>®</sup> *of* OPTOMETRY

April 15, 2022 • [reviewofoptometry.com](http://reviewofoptometry.com)

Leadership in clinical care

**TO CUT OR  
NOT TO CUT?**  
Weighing Strabismus  
Surgery Referral  
**PAGE 74**

## 9th ANNUAL CORNEAL DISEASE REPORT

*Expert advice on how to keep this  
vital structure in good health.*

- Clinical Pearls in Corneal Foreign Body Removal, **p. 32**
- Fine-Tune Your Corneal Disease Diagnostic Skills, **p. 42**
- Improving the Gold Standard for CXL, **p. 50**
- Piecing Together the HSVK Puzzle, **p. 56**

—EARN 2 CE CREDITS

Cover photo by Irving Martínez Navé  
León, Guanajuato, Mexico





**VYZULTA**

(latanoprostene  
bunod ophthalmic  
solution), 0.024%

# THE HORSEPOWER YOU NEED TO LOWER IOP

Powerful IOP reduction with excellent tolerability<sup>1,2</sup>

VYZULTA delivered **up to 9.1 mmHg mean IOP reduction** from baseline in pivotal trials.<sup>1,2\*</sup>

**TAKE A TEST RIDE AT [VYZULTAHCP.COM](http://VYZULTAHCP.COM)**

\*Pivotal study designs: Two Phase 3, randomized, multicenter, parallel-group studies, APOLLO and LUNAR, evaluating noninferiority of once-daily VYZULTA vs twice-daily timolol maleate 0.5% in patients with open-angle glaucoma or ocular hypertension. Primary endpoint was IOP measured at 9 assessment time points in study eye. APOLLO (VYZULTA, n=284; timolol, n=133) and LUNAR (VYZULTA, n=278; timolol, n=136).<sup>2,3</sup>

## INDICATION

VYZULTA® (latanoprostene bunod ophthalmic solution), 0.024% is indicated for the reduction of intraocular pressure (IOP) in patients with open-angle glaucoma or ocular hypertension.

## IMPORTANT SAFETY INFORMATION

- Increased pigmentation of the iris and periorbital tissue (eyelid) can occur. Iris pigmentation is likely to be permanent
- Gradual changes to eyelashes, including increased length, increased thickness, and number of eyelashes, may occur. These changes are usually reversible upon treatment discontinuation
- Use with caution in patients with a history of intraocular inflammation (iritis/uveitis). VYZULTA should generally not be used in patients with active intraocular inflammation
- Macular edema, including cystoid macular edema, has been reported during treatment with prostaglandin analogs. Use with caution in aphakic patients, in pseudophakic patients with a torn posterior lens capsule, or in patients with known risk factors for macular edema
- There have been reports of bacterial keratitis associated with the use of multiple-dose containers of topical ophthalmic products that were inadvertently contaminated by patients
- Contact lenses should be removed prior to the administration of VYZULTA and may be reinserted 15 minutes after administration
- Most common ocular adverse reactions with incidence  $\geq 2\%$  are conjunctival hyperemia (6%), eye irritation (4%), eye pain (3%), and instillation site pain (2%)

For more information, please see Brief Summary of full Prescribing Information on adjacent page.

**References:** **1.** VYZULTA Prescribing Information. Bausch & Lomb Incorporated. **2.** Weinreb RN, Scassellati Sforzolini B, Vittitow J, Liebmann J. Latanoprostene bunod 0.024% versus timolol maleate 0.5% in subjects with open-angle glaucoma or ocular hypertension: the APOLLO study. *Ophthalmology*. 2016;123(5):965-973. **3.** Medeiros FA, Martin KR, Peace J, Scassellati Sforzolini B, Vittitow JL, Weinreb RN. Comparison of latanoprostene bunod 0.024% and timolol maleate 0.5% in open-angle glaucoma or ocular hypertension: the LUNAR study. *Am J Ophthalmol*. 2016;168:250-259.

VYZULTA and the V design are trademarks of Bausch & Lomb Incorporated or its affiliates. Any other product/brand names and/or logos are trademarks of the respective owners. ©2021 Bausch & Lomb Incorporated or its affiliates. All rights reserved. VYZ.0258.USA.20

**BAUSCH + LOMB**



## BRIEF SUMMARY OF PRESCRIBING INFORMATION

This Brief Summary does not include all the information needed to use VYZULTA safely and effectively. See full Prescribing Information for VYZULTA.

**VYZULTA®** (latanoprostene bunod ophthalmic solution), 0.024%, for topical ophthalmic use.

Initial U.S. Approval: 2017

### 1 INDICATIONS AND USAGE

VYZULTA® (latanoprostene bunod ophthalmic solution) 0.024% is indicated for the reduction of intraocular pressure (IOP) in patients with open-angle glaucoma or ocular hypertension.

### 4 CONTRAINDICATIONS

None

### 5 WARNINGS AND PRECAUTIONS

#### 5.1 Pigmentation

VYZULTA® (latanoprostene bunod ophthalmic solution), 0.024% may cause changes to pigmented tissues. The most frequently reported changes with prostaglandin analogs have been increased pigmentation of the iris and periorbital tissue (eyelid).

Pigmentation is expected to increase as long as latanoprostene bunod ophthalmic solution is administered. The pigmentation change is due to increased melanin content in the melanocytes rather than to an increase in the number of melanocytes. After discontinuation of VYZULTA, pigmentation of the iris is likely to be permanent, while pigmentation of the periorbital tissue and eyelash changes are likely to be reversible in most patients. Patients who receive prostaglandin analogs, including VYZULTA, should be informed of the possibility of increased pigmentation, including permanent changes. The long-term effects of increased pigmentation are not known.

Iris color change may not be noticeable for several months to years. Typically, the brown pigmentation around the pupil spreads concentrically towards the periphery of the iris and the entire iris or parts of the iris become more brownish. Neither nevi nor freckles of the iris appear to be affected by treatment. While treatment with VYZULTA® (latanoprostene bunod ophthalmic solution), 0.024% can be continued in patients who develop noticeably increased iris pigmentation, these patients should be examined regularly [see Patient Counseling Information (17) in full Prescribing Information].

#### 5.2 Eyelash Changes

VYZULTA may gradually change eyelashes and vellus hair in the treated eye. These changes include increased length, thickness, and the number of lashes or hairs. Eyelash changes are usually reversible upon discontinuation of treatment.

#### 5.3 Intraocular Inflammation

VYZULTA should be used with caution in patients with a history of intraocular inflammation (iritis/uveitis) and should generally not be used in patients with active intraocular inflammation as it may exacerbate this condition.

#### 5.4 Macular Edema

Macular edema, including cystoid macular edema, has been reported during treatment with prostaglandin analogs. VYZULTA should be used with caution in aphakic patients, in pseudophakic patients with a torn posterior lens capsule, or in patients with known risk factors for macular edema.

#### 5.5 Bacterial Keratitis

There have been reports of bacterial keratitis associated with the use of multiple-dose containers of topical ophthalmic products. These containers had been inadvertently contaminated by patients who, in most cases, had a concurrent corneal disease or a disruption of the ocular epithelial surface.

#### 5.6 Use with Contact Lens

Contact lenses should be removed prior to the administration of VYZULTA because this product contains benzalkonium chloride. Lenses may be reinserted 15 minutes after administration.

### 6 ADVERSE REACTIONS

The following adverse reactions are described in the Warnings and Precautions section: pigmentation (5.1), eyelash changes (5.2), intraocular inflammation (5.3), macular edema (5.4), bacterial keratitis (5.5), use with contact lens (5.6).

#### 6.1 Clinical Trials Experience

Because clinical trials are conducted under widely varying conditions, adverse reaction rates observed in the clinical trials of a drug cannot be directly compared to rates in the clinical trials of another drug and may not reflect the rates observed in practice.

VYZULTA was evaluated in 811 patients in 2 controlled clinical trials of up to 12 months duration. The most common ocular adverse reactions observed in patients treated with latanoprostene bunod were: conjunctival hyperemia (6%), eye irritation (4%), eye pain (3%), and instillation site pain (2%). Approximately 0.6% of patients discontinued therapy due to ocular adverse reactions including ocular hyperemia, conjunctival irritation, eye irritation, eye pain, conjunctival edema, vision blurred, punctate keratitis and foreign body sensation.

### 8 USE IN SPECIFIC POPULATIONS

#### 8.1 Pregnancy

##### Risk Summary

There are no available human data for the use of VYZULTA during pregnancy to inform any drug associated risks.

Latanoprostene bunod has caused miscarriages, abortion, and fetal harm in rabbits. Latanoprostene bunod was shown to be abortifacient and teratogenic when administered intravenously (IV) to pregnant rabbits at exposures  $\geq 0.28$  times the clinical dose. Doses  $\geq 20$   $\mu\text{g}/\text{kg}/\text{day}$  (23 times the clinical dose) produced 100% embryofetal lethality. Structural abnormalities observed in rabbit fetuses included anomalies of the great vessels and aortic arch vessels, domed head, sternebral and vertebral skeletal anomalies, limb hyperextension

and malrotation, abdominal distension and edema. Latanoprostene bunod was not teratogenic in the rat when administered IV at 150 mcg/kg/day (87 times the clinical dose) [see Data].

The background risk of major birth defects and miscarriage for the indicated population is unknown. However, the background risk in the U.S. general population of major birth defects is 2 to 4%, and of miscarriage is 15 to 20%, of clinically recognized pregnancies.

##### Data

##### Animal Data

Embryofetal studies were conducted in pregnant rabbits administered latanoprostene bunod daily by intravenous injection on gestation days 7 through 19, to target the period of organogenesis. The doses administered ranged from 0.24 to 80 mcg/kg/day. Abortion occurred at doses  $\geq 0.24$  mcg/kg/day latanoprostene bunod (0.28 times the clinical dose, on a body surface area basis, assuming 100% absorption). Embryofetal lethality (resorption) was increased in latanoprostene bunod treatment groups, as evidenced by increases in early resorptions at doses  $\geq 0.24$  mcg/kg/day and late resorptions at doses  $\geq 6$  mcg/kg/day (approximately 7 times the clinical dose). No fetuses survived in any rabbit pregnancy at doses of 20 mcg/kg/day (23 times the clinical dose) or greater. Latanoprostene bunod produced structural abnormalities at doses  $\geq 0.24$  mcg/kg/day (0.28 times the clinical dose). Malformations included anomalies of sternum, coarctation of the aorta with pulmonary trunk dilation, retroesophageal subclavian artery with absent brachiocephalic artery, domed head, forepaw hyperextension and hindlimb malrotation, abdominal distention/edema, and missing/fused caudal vertebrae.

An embryofetal study was conducted in pregnant rats administered latanoprostene bunod daily by intravenous injection on gestation days 7 through 17, to target the period of organogenesis. The doses administered ranged from 150 to 1500 mcg/kg/day. Maternal toxicity was produced at 1500 mcg/kg/day (870 times the clinical dose, on a body surface area basis, assuming 100% absorption), as evidenced by reduced maternal weight gain. Embryofetal lethality (resorption and fetal death) and structural anomalies were produced at doses  $\geq 300$  mcg/kg/day (174 times the clinical dose). Malformations included anomalies of the sternum, domed head, forepaw hyperextension and hindlimb malrotation, vertebral anomalies and delayed ossification of distal limb bones. A no observed adverse effect level (NOAEL) was established at 150 mcg/kg/day (87 times the clinical dose) in this study.

#### 8.2 Lactation

##### Risk Summary

There are no data on the presence of VYZULTA in human milk, the effects on the breastfed infant, or the effects on milk production. The developmental and health benefits of breastfeeding should be considered, along with the mother's clinical need for VYZULTA, and any potential adverse effects on the breastfed infant from VYZULTA.

#### 8.4 Pediatric Use

Use in pediatric patients aged 16 years and younger is not recommended because of potential safety concerns related to increased pigmentation following long-term chronic use.

#### 8.5 Geriatric Use

No overall clinical differences in safety or effectiveness have been observed between elderly and other adult patients.

### 13 NONCLINICAL TOXICOLOGY

#### 13.1 Carcinogenesis, Mutagenesis, Impairment of Fertility

Latanoprostene bunod was not mutagenic in bacteria and did not induce micronuclei formation in the *in vivo* rat bone marrow micronucleus assay. Chromosomal aberrations were observed *in vitro* with human lymphocytes in the absence of metabolic activation.

Latanoprostene bunod has not been tested for carcinogenic activity in long-term animal studies. Latanoprost acid is a main metabolite of latanoprostene bunod. Exposure of rats and mice to latanoprost acid, resulting from oral dosing with latanoprost in lifetime rodent bioassays, was not carcinogenic.

Fertility studies have not been conducted with latanoprostene bunod. The potential to impact fertility can be partially characterized by exposure to latanoprost acid, a common metabolite of both latanoprostene bunod and latanoprost. Latanoprost acid has not been found to have any effect on male or female fertility in animal studies.

#### 13.2 Animal Toxicology and/or Pharmacology

A 9-month toxicology study administered topical ocular doses of latanoprostene bunod to one eye of cynomolgus monkeys: control (vehicle only), one drop of 0.024% bid, one drop of 0.04% bid and two drops of 0.04% per dose, bid. The systemic exposures are equivalent to 4.2-fold, 7.9-fold, and 13.5-fold the clinical dose, respectively, on a body surface area basis (assuming 100% absorption). Microscopic evaluation of the lungs after 9 months observed pleural/subpleural chronic fibrosis/inflammation in the 0.04% dose male groups, with increasing incidence and severity compared to controls. Lung toxicity was not observed at the 0.024% dose.

U.S. Patent Numbers: 7,273,946; 7,629,345; 7,910,767; 8,058,467.

VYZULTA is a trademark of Bausch & Lomb Incorporated or its affiliates.

© 2020 Bausch & Lomb Incorporated or its affiliates.

##### Distributed by:

Bausch + Lomb, a division of

Bausch Health US, LLC

Bridgewater, NJ 08807 USA

Based on 9612403 (Folded), 9612303 (Flat) 5/2019

VYZ.0109.USA.20 Issued: 5/2020



## Mask-associated Dry Eye Affects 70% of Healthcare Providers

*Given its high prevalence in light of COVID-19, efforts to address this condition are necessary.*

The pandemic has had a deleterious impact on daily life in a variety of ways, including the ongoing use of masks and other personal protective equipment—particularly for individuals working in healthcare. As a result, there has been an increased interest in understanding the negative effects of regular mask usage. In a recent prospective, cross-sectional study, researchers sought to better understand the prevalence of self-reported mask-associated dry eye in healthcare professionals and the possible risk factors for this condition.

The study authors created a web-based, self-administered questionnaire that included 12 questions about mask-associated dry eye and its risk factors. It was sent to 437 healthcare professionals; of these, 333 were included in the study. The data collected included demographic and clinical characteristics. Participants who reported at least one symptom of dry eye were deemed to potentially have mask-associated dry eye and asked to undergo a clinical evaluation.

Findings revealed that the prevalence of self-reported mask-associated dry eye among individuals working in

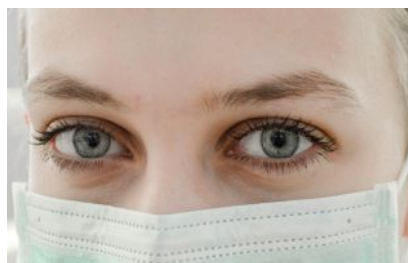

Photo: Anil Koleshi on Unsplash

**More than two-thirds of healthcare workers reported mask-associated dry eye symptoms in this study.**

healthcare was 70%. The remaining 30% said they did not feel any discomfort while wearing a mask. Additionally, 19.2% noted that they already had at least one symptom of dry eye before they started using masks. However, 90.6% of these individuals also reported that their complaints associated with dry eye were exacerbated after they began wearing masks during the pandemic.

Overall, 81.9% of the study participants with mask-associated dry eye symptoms said their work performance was affected. Of the participants who had self-reported mask-associated dry eye and agreed to a clinical examination (n=195), 30.7% had aqueous-type dryness with staining on the ocular surface with fluorescein. In terms of

potential risk factors, the researchers reported that having at least one of the symptoms of dry eye while not wearing a mask and older age were both associated with the condition.

This research suggests, according to the authors, a high prevalence of self-reported mask-associated dry eye among medical professionals, which was substantiated by clinical findings in a number of participants. These results highlight the importance of addressing this issue in eyecare practices.

“It is likely that COVID-19 will be in our lives for years to come, which would only make the problems that the healthcare professionals face, such as the mask-associated dry eye in question, worse if not addressed,” they concluded. “Hence, any symptoms of healthcare professionals to that effect should not be ignored during the period of pandemic in particular. Implementation of measures to reduce the symptoms related to dry eye will likely positively affect the work performance of healthcare professionals.”

Dag U, Çağlayan M, Öncül H, et al. Mask-associated dry eye syndrome in healthcare professionals as a new complication caused by the prolonged use of masks during COVID-19 pandemic period. *Ophthalmic Epidemiol.* March 18, 2022. [Epub ahead of print].

### IN BRIEF

**Many Seniors Miss Out on Assistive Apps for Low Vision.** Though dozens of downloadable apps are available as visual assistive aids for low vision patients, authors of a recent article determined the population most in need of these tools—adults over age 55—aren't taking advantage. Explaining the value of these aids to low vision patients may help increase rates of usage.

One review of low vision exam records from the UCLA Vision Rehabilitation Center found that 90% of low vision patients have a smartphone, yet only 6% use visual assistive apps.

To help get some answers as to why these apps are underutilized by patients over age 55, researchers are currently conducting a randomized clinical trial called Community Access through Remote EyeSight (CARE) on several free visual assis-

ive apps, including SuperVision+2, Seeing AI3 and Aira.

“The primary reason for not using these three visual assistive apps was a lack of awareness of such apps, reported by 63% of the first 50 participants in the CARE trial, whose mean age was 73,” they noted in the study.

According to the study, “The second most commonly reported reason for not using these apps was because they didn't know how and had not

received training, indicated by roughly one in five participants (21%).”

These findings suggest this patient population has a lack of awareness about visual assistive apps that leads to their underutilization. The team recommended providing specific information to visually impaired patients about the mobile accessibility apps available to them.

Uchino M, Yokoi N, Shimazaki J, et al. Adherence to eye drops usage in dry eye patients and reasons for non-compliance: a web-based survey. *J Clin Med.*



New from the makers of the #1-prescribed dry eye brand in Europe\*

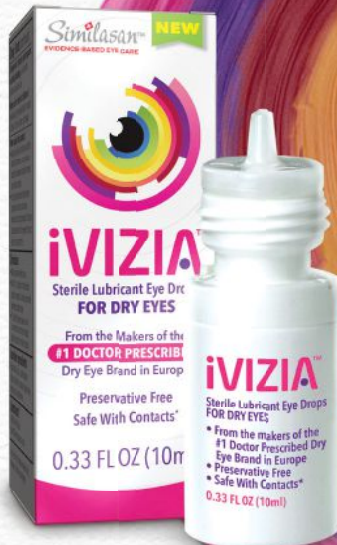# Covering the spectrum of Dry Eye Relief

Introducing preservative-free iVIZIA™ lubricant eye drops for the comprehensive combination of lasting relief and ocular surface protection.<sup>1-6</sup>

- Trehalose provides bioprotection, osmoprotection, and rehydration<sup>1-4</sup>
- Hyaluronic acid (HA) and povidone deliver lubrication with long-lasting relief<sup>5-6</sup>
- Increased tear film thickness for up to 240 minutes<sup>7</sup>
- Preservative free
- Proprietary multi-dose bottle design for calibrated dosing and contamination protection
- Suitable for all dry eye sufferers, including contact lens wearers<sup>†</sup>

Help patients see dry eye relief differently. Recommend iVIZIA OTC.

Request samples and learn more by scanning the QR code or visiting [iVIZIA.com/ECP](https://www.ivizia.com/ECP).



\*Prescription market data, Sept. 2021 – S01K without cyclosporine.

†To limit blurriness when using contact lenses, remove contacts, apply drops, then insert contacts.

**References:** **1.** Chen W, Zhang X, Liu M, et al. Trehalose protects against ocular surface disorders in experimental murine dry eye through suppression of apoptosis. *Exp Eye Res.* 2009;89(3):311-318. **2.** Aragona P, Colosi P, Rania L, et al. Protective effects of trehalose on the corneal epithelial cells. *ScientificWorldJournal.* 2014;2014:717835. **3.** Chiambaretta F, Doan S, Labetoulle M, et al. A randomized, controlled study of the efficacy and safety of a new eyedrop formulation for moderate to severe dry eye syndrome. *Eur J Ophthalmol.* 2017;27(1):1-9. **4.** Liu Z, Chen D, Chen X, et al. Trehalose induces autophagy against inflammation by activating TFEB signaling pathway in human corneal epithelial cells exposed to hyperosmotic stress. *Invest Ophthalmol Vis Sci.* 2020;61(10):26. **5.** US FDA Department of Health and Human Services. Ophthalmic drug products for over-the-counter human use. Updated October 21, 2021. Accessed January 19, 2022. <https://www.accessdata.fda.gov/scripts/cdrh/cfdocs/cfcfr/CFRSearch.cfm?CFRPart=349>. **6.** Jones L, Downie LE, Korb D, et al. TFOS DEWS II management and therapy report. *Ocul Surf.* 2017;15(3):575-628. **7.** Schmidl D, Schmetterer L, Witkowska KJ, et al. Tear film thickness after treatment with artificial tears in patients with moderate dry eye disease. *Cornea.* 2015;34(4):421-426.

# Retinal Thinning May Occur After FLACS

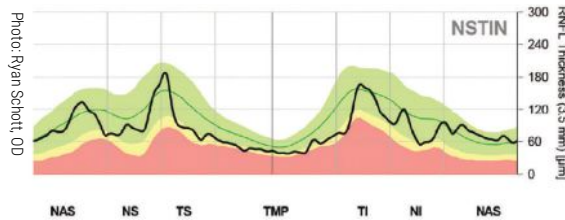
Other research found that patients with prediabetes may also suffer loss of the RNFL.

Few studies have been conducted reporting the effect of femtosecond laser-assisted cataract surgery (FLACS) on the posterior segment, and they have shown differing results. Between the surgery growing in popularity and the safety concerns it brings for the optic nerve, authors recently aimed to compare changes in the peripapillary retinal nerve fiber layer (pRNFL) after FLACS and conventional phacoemulsification cataract surgery.

A total of 261 patients with age-related cataract scheduled for FLACS (222 eyes) or conventional phaco (39 eyes) were included.<sup>1</sup> Average and quadrant pRNFL thicknesses were measured using OCT before surgery and one, three and six months post-op.

The rate of clinically significant thinning six months post-op was higher in the FLACS group (17.5%) than in the phaco group (5.1%), but there were no significant differences between the groups for any of the quadrants or for average pRNFL. According to the researchers, this may be due to the insufficiency of the statistical power to reveal differences between the groups due to the small phaco group size.

FLACS eyes demonstrated a stable decrease of average pRNFL thickness throughout and a gradual decrease in pRNFL thickness up to six months in all quadrants except the temporal quadrant where the decrease stabilized



**When assessing patients post-FLACS or those with prediabetes, stay alert for early loss of RNFL (seen here in a glaucoma patient).**

after three months. “This indicates that pRNFL thinning completes first in the temporal quadrant,” the authors wrote. “The consistent decrease in pRNFL thickness in all quadrants and in the average pRNFL of FLACS eyes suggests that pRNFL thinning may occur after surgery.”

Although no relationship was found between vacuum time and decline in pRNFL thickness, the authors aren’t ruling out the possibility that an increase in IOP during docking of the femto laser may be the primary factor influencing pRNFL thinning.

Patient pRNFL status may be another factor. “Preoperative pRNFL thickness was associated with temporal quadrant thinning, corresponding to the location where pRNFL thinning was completed,” they wrote. “This suggests that eyes with thinner pRNFL can be prone to structural damage in the temporal quadrant after FLACS, which can have important implications regarding the use of the surgery in glaucoma patients, with generally thinner pRNFL measurements.”

Researchers in another study revealed a second population at risk of retinal thinning after examining the retinas of patients with elevated blood sugar.<sup>2</sup> They observed that many showed thinning of the RNFL despite the absence of obvious vascular damage. While sometimes overlooked, diabetic retinopathy (DR) is not exclusive to patients with diabetes;

rather, DR can cause early neuroretinal changes in prediabetes patients before developing into overt retinopathy.

Fifty patients with diagnosed prediabetes and 50 healthy controls were included in the study. The researchers measured RNFL using spectral-domain OCT. Not only did prediabetic patients have thinning in the temporal quadrant, but most showed loss in all four. The difference between the RNFL thicknesses of both groups was statistically significant. The average RNFL thicknesses measured in each group are shown in Table 1.

“The prevalence of prediabetes varies between 19.8% and 34.6% and is more common than diabetes,” the authors wrote. “In about two out of three prediabetic cases, the metabolic disorder progresses to obvious diabetes in later life. However, microvascular and macrovascular complications due to diabetes may occur in prediabetics even before diabetes develops,” they noted.

As an optometrist, you have the opportunity to recognize these early signs of disease in your patients before progression or adverse outcomes occur. Be vigilant when performing retinal exams and RNFL thickness measurements on all your patients, not only those with diabetes. ◀

1. Geyer O, Ben-Shaul O, Lux C, et al. Effect of femtosecond laser cataract surgery on peripapillary retinal nerve fiber layer thickness. *J Glaucoma*. March 18, 2022. [Epub ahead of print].

2. Bilén A, Ates O, Ondas O, et al. Retinal nerve fiber layer thickness in prediabetic patients. *Eurasian J Med*. 2022;54(1):8-11.

**Table 1. Average RNFL Thicknesses in Prediabetics vs. Controls**

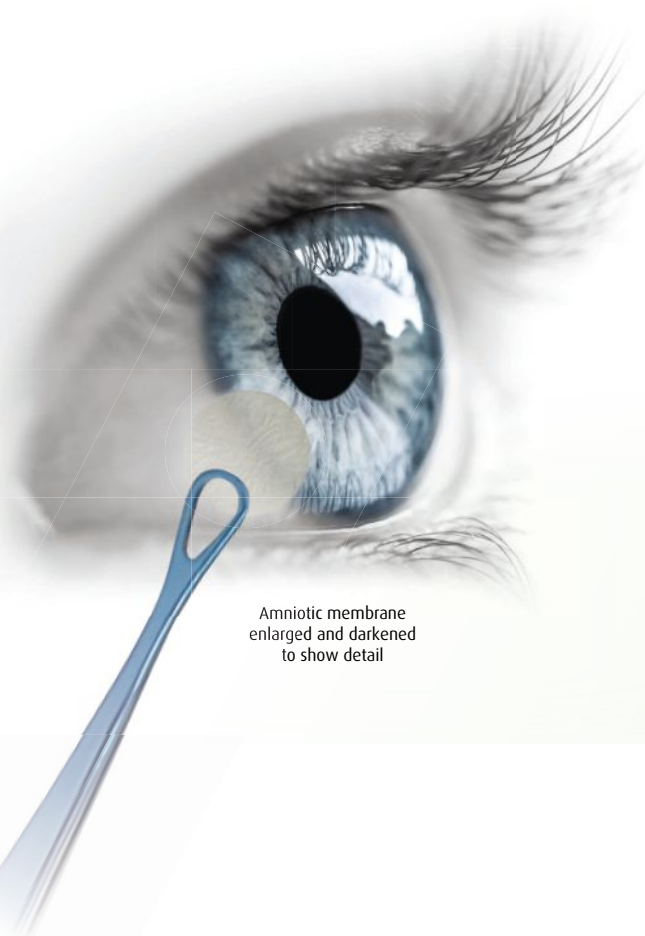	Mean RNFL Thickness	Inferior Quadrant	Superior Quadrant	Nasal Quadrant	Temporal Quadrant
Prediabetes Group	94.7µm	120µm	112.3µm	71µm	65.3µm
Control Group	98.9µm	128µm	116.3µm	77µm	71.2µm

Bilen A, Ates O, Ondas O, et al. Retinal nerve fiber layer thickness in prediabetic patients. *Eurasian J Med*. 2022;54(1):8-11.



# Need Ocular Surface Repair?\*

## We've Got You Covered!



Amniotic membrane  
enlarged and darkened  
to show detail

**ACELLFX™** ™  
Acellular Amniotic Membrane

- Air-dried, not chemically dried
- Ready for immediate use without thawing or rinsing
- Flexible membrane with no ring required
- Convenient storage at room temperature

Learn more at [AcellFX.com](https://www.AcellFX.com)



\*AcellFX is an HCT/P (human cells, tissues, and cellular and tissue-based product) that is intended for homologous use, providing protection or covering in ocular surface repair.

# Strabismus Increases Risk of Mental Illness

*A second study also showed that those with the condition reported a lower quality of life compared with visually normal children.*

Children with strabismus often have decreased visual function, including difficulties with schoolwork and sports. They have also reported problems with self-image and teasing for eye misalignment, glasses and/or patching. Researchers recently investigated whether patients with strabismus may have a higher risk of developing mental illness, reporting that this demographic has higher odds of having anxiety, schizophrenia, bipolar and depression compared with children without eye disease. There was no strong association with substance use.<sup>1</sup>

The study used data from over 12 million patients in a longitudinal commercial insurance claims database 18 years and younger at the time of their strabismus diagnosis (50.8% boys, mean age: eight years old). Adjusted odds ratios for the association of mental illnesses with strabismus were 2.01 for anxiety, 1.83 for schizophrenia, 1.64 for bipolar, 1.61 for depression and 0.99 for substance use.

The researchers noted that there was a moderate association between each strabismus type (esotropia, exotropia and hypertropia) with anxiety, schizophrenia, bipolar and depression; odds ratios ranged from 1.23 for the association between esotropia and bipolar to 2.70 for the association between exotropia and anxiety. However, they still found it unclear whether the type of strabismus has an association with the magnitude of mental illness risk.


“These results should alert ophthalmologists and optometrists to counsel children and

their caregivers regarding the risk for mental illness,” the authors concluded in their paper. “They should consider incorporating a screening tool for mental health problems for patients with strabismus and referral of pediatric patients with strabismus for mental health evaluation.”

Not only may strabismus be associated with mood disorders, but another study showed that it also has an impact on overall life satisfaction, even after surgery.<sup>2</sup>

To better understand how the condition impacts a child’s quality of life, as well as their family’s, researchers evaluated the functional vision and eye-related quality of life in children with strabismus and their parents using a recently developed and validated questionnaire called the Pediatric Eye Questionnaire (PedEyeQ). The answers revealed that strabismus has an important impact on affected children and their families. Scores were significantly lower in children with

Photo: Marc B. Taulu, OD, MS, and Paul Harris, OD



**Children with strabismus may be more prone to developing mental health issues.**

strabismus compared with healthy children. Interestingly, children with prior successful corrective strabismus surgery also had worse PedEyeQ scores.

The PedEyeQ was applied to non-operated children with strabismus (n=18), operated children with strabismus (n=24) and visually normal children (n=21). This instrument is composed of three components. The Child PedEyeQ component has two versions (for ages 5-11 or 12-17) and is completed by the children. The Proxy and Parent PedEyeQ components have three versions (ages 0-4, 5-11 or 12-17) and are answered by the parent or caregiver.

All PedEyeQ domain scores were significantly lower in children with strabismus compared with visually normal children, except the functional vision domain in the child version. Despite previous evidence of a positive effect

*(Continued on p. 11)*

Photo: Jasleen Jhaji, OD



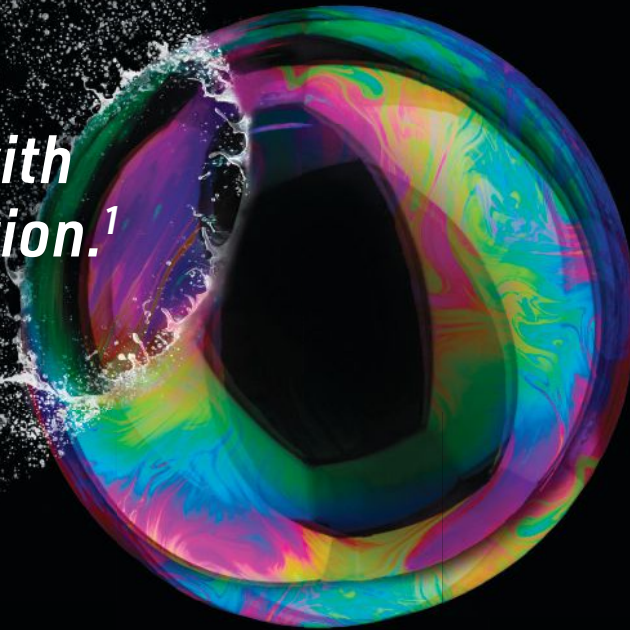
**Young patients with strabismus may have decreased quality of life even after corrective surgery, study shows.**



**tyrvaya™**  
(varenicline solution)  
nasal spray 0.03 mg

# NOW APPROVED

*Dry eye starts with  
tear film disruption.<sup>1</sup>*



*Treat by activating  
tear film production.<sup>2</sup>*

## INTRODUCING A WHOLE NEW WAY TO TREAT DRY EYE DISEASE.<sup>2</sup>

Tyrvaya™, the first and only nasal spray approved to treat the signs and symptoms of dry eye, is believed to activate the trigeminal parasympathetic pathway via the nose, resulting in increased tear film production.<sup>2</sup> The exact mechanism of action is unknown at this time.

Watch Tyrvaya in action at [Tyrvaya-pro.com](http://Tyrvaya-pro.com).



### INDICATION

Tyrvaya™ (varenicline solution) Nasal Spray is indicated for the treatment of the signs and symptoms of dry eye disease.

**Please see Brief Summary of Prescribing Information on the adjacent page and the full Prescribing Information at [Tyrvaya-pro.com](http://Tyrvaya-pro.com).**

### IMPORTANT SAFETY INFORMATION

#### Adverse Reactions

The most common adverse reaction reported in 82% of patients was sneezing. Events that were reported in 5-16% of patients were cough, throat irritation, and instillation-site (nose) irritation.

**References:** 1. Craig JP, Nelson JD, Azar DT, et al. *Ocul Surf.* 2017;15(4):802-812. 2. Tyrvaya. Prescribing Information. Oyster Point Pharma; 2021.

© 2021 Oyster Point Pharma, Inc. Oyster Point™, the Oyster Point logo, Tyrvaya™ and the Tyrvaya logo are trademarks of Oyster Point Pharma, Inc. All rights reserved. OP-TYR-000867 10/21



**BRIEF SUMMARY:** Consult the full Prescribing Information for complete product information available at [www.tyrvaya-pro.com](http://www.tyrvaya-pro.com).

### INDICATIONS AND USAGE

TYRVAYA™ (varenicline solution) nasal spray is a cholinergic agonist indicated for the treatment of the signs and symptoms of dry eye disease.

### ADVERSE REACTIONS

**Clinical Trials Experience:** Because clinical trials are conducted under widely varying conditions, adverse reaction rates observed in the clinical trials of a drug cannot be directly compared to rates in the clinical trials of another drug and may not reflect the rates observed in practice.

In three clinical trials of dry eye disease conducted with varenicline solution nasal spray, 349 patients received at least 1 dose of TYRVAYA. The majority of patients had 31 days of treatment exposure, with a maximum exposure of 105 days.

The most common adverse reactions reported in 82% of TYRVAYA treated patients was sneezing. Other common adverse reactions that were reported in >5% of patients include cough (16%), throat irritation (13%), and instillation-site (nose) irritation (8%).

### USE IN SPECIFIC POPULATIONS

**Pregnancy: Risk Summary:** There are no available data on TYRVAYA use in pregnant women to inform any drug associated risks. In animal reproduction studies, varenicline did not produce malformations at clinically relevant doses.

All pregnancies have a risk of birth defect, loss, or other adverse outcomes. In the US general population, the estimated background risk of major birth

defects and miscarriage in clinically recognized pregnancies is 2% to 4% and 15% to 20%, respectively.

**Data: Animal Data:** Pregnant rats and rabbits received varenicline succinate during organogenesis at oral doses up to 15 and 30 mg/kg/day, respectively. While no fetal structural abnormalities occurred in either species, maternal toxicity, characterized by reduced body weight gain, and reduced fetal weights occurred in rabbits at the highest dose (4864 times the MRHD on a mg/m<sup>2</sup> basis).

In a pre- and postnatal development study, pregnant rats received up to 15 mg/kg/day of oral varenicline succinate from organogenesis through lactation. Maternal toxicity, characterized by a decrease in body weight gain, was observed at 15 mg/kg/day (1216 times the MRHD on a mg/m<sup>2</sup> basis). Decreased fertility and increased auditory startle response occurred in offspring at the highest maternal dose of 15 mg/kg/day.

**Lactation: Risk summary:** There are no data on the presence of varenicline in human milk, the effects on the breastfed infant, or the effects on milk production. In animal studies varenicline was present in milk of lactating rats. However, due to species-specific differences in lactation physiology, animal data may not reliably predict drug levels in human milk.

The lack of clinical data during lactation precludes a clear determination of the risk of TYRVAYA to an infant during lactation; however, the developmental and health benefits of breastfeeding should be considered along with the mother's clinical need for TYRVAYA and any potential adverse effects on the breastfed child from TYRVAYA.

**Pediatric Use:** Safety and efficacy of TYRVAYA in pediatric patients have not been established.

**Geriatric Use:** No overall differences in safety or effectiveness have been observed between elderly and younger adult patients.

## IN BRIEF

### Retinal Thickness Fluctuations During Anti-VEGF Associated With Poor Outcomes.

Researchers recently found that fluctuations in retinal thickening may be associated with ranibizumab treatment response in patients with neovascular age-related macular degeneration (nAMD). A total of 1,097 patients with nAMD received monthly or as-needed (PRN) ranibizumab (0.5mg or 2.0mg) for 24 months. Fluctuation scores were grouped into four categories and used to assess central foveal thickness variability, with a change of <50µm considered insignificant.

**Patients with lower fluctuations scores had the greatest vision gains at month 24**, with changes from baseline of 9.0 to 10.8 and 8.7 to 10.6 letters in the monthly and PRN arms, respectively. Corresponding changes for high fluctuation patients were 6.7 and 6.5 letters, respectively. There were no differences between groups for association between fluctuations in subretinal fluid height and BCVA gains. There were inverse correlations between magnitude of fluctuations in neurosensory and inner retina thickness and BCVA gains for the high fluctuation group vs. the others. **Patients with more anatomical stability showed rapid, robust BCVA gains, while those with variability had worse responses.**

"Fluctuations in retinal thickness during anti-VEGF treatment may be associated with treatment response," the study authors concluded. **"Patients with the greatest fluctuation scores may still be able to attain vision gains, although less than those among patients with the lowest fluctuation scores.** Monitoring fluctuations in retinal thickness during treatment may help prognosticate the response."

Antunes Sheth V, D'Rozario M, Gune S, Blotner S. Fluctuations in central foveal thickness and association with vision outcomes with anti-VEGF therapy for nAMD: HARBOR post hoc analysis. *BMJ Open Ophthalmol.* March 9, 2022. [Epub ahead of print].

### Diabetes Patients More Likely to Have Accommodative, Binocular Disorders.

It's been shown that diabetes mellitus (DM) may impair ocular accommodation and binocular vision performance. To investigate, researchers studied 30 patients with DM (hemoglobin A1c above 6.5%) and 30 controls (ages 18-40).

The study showed that **aspects of accommodative and binocular vision performance are strongly affected by diabetes** and there's a correlation between accommodative/binocular disorders and severity of disease. **A significant percentage of young individuals with DM have severe vision-related symptoms—26.6% compared with the control group at 6.6%.**

The near point of convergence was more remote in the diabetic group. Mean accommodation amplitude and vergence facility and the median monocular accommodative facility were significantly lower in the diabetic group.

The authors suggested **exams of young diabetic patients should not just focus on pathological anterior or posterior segment changes but also on accommodative and binocular functions.**

Jeon HS, Byun SJ, Hyon JY, et al. Risk of stroke or acute myocardial infarction in subconjunctival hemorrhage: a nationwide cohort study. *Ophthalmic Epidemiol.* November 18, 2021. [Epub ahead of print].



Manufactured for: Oyster Point Pharma, Inc, 202 Carnegie Center, Suite 109, Princeton, NJ 08540  
For more information visit [www.tyrvaya-pro.com](http://www.tyrvaya-pro.com).  
To report an adverse event, contact 1-877-EYE-0123.  
TYRVAYA™, the Tyrvaya logo, Oyster Point™ and the Oyster Point logo are trademarks of Oyster Point Pharma Inc.  
©2021 Oyster Point Pharma, Inc. All Rights Reserved.  
Issued: Oct 2021

OP-TYR-000867 10/21



# Mental Illness and Eye Disease in Children, Teens

*Anxiety, schizophrenia, bipolar and depression were potential considerations.*

Multiple studies have found depression and anxiety to be associated with eye disease, but few have focused on other mental illnesses such as anxiety, schizophrenia, bipolar disorder and depression. In a recent study, researchers sought to evaluate the association between five eye diseases—glaucoma, cataract, congenital optic nerve disease, congenital retinal

disease and blindness/low vision—and mental illness in children and teens.

Nearly 12 million children 19 years and younger at the time of eye diagnosis were included. Of the patients with at least one of the five eye diseases, 30.5% had glaucoma, 9.5% had cataract, 21.4% had congenital optic nerve disease, 26.9% had congenital retinal disease and 25.9% had blindness or low vision.

These diseases were associated with anxiety, schizophrenia, bipolar disorder and depression. The chance of having these psychiatric diagnoses was higher among children with at least one of the five eye diseases than among children without eye disease, with odds ratios ranging from 1.26 to 1.54.

Inverse associations were found with substance use, with the exception of non-significant associations between glaucoma and bipolar and between cataracts and substance use.

“It is possible that since our study grouped substance use disorder together, we were not able to distinguish which substances were involved; for example, it is possible that eye disease can increase the risk of certain substances but not others,” they explained in their report.

“It is also possible that eye disease can increase the use of substances but not necessarily increase the risk of substance use disorder, as there is a threshold of substance use that is deemed pathologic.”

The authors noted that these studies reinforce the need to investigate the role eye disease plays in mental illness in children and teens; however, they have been limited in their definitions of mental illness beyond depression and anxiety, and in the type of eye diseases they studied.

“While case reports have demonstrated association between Leber hereditary optic neuropathy and schizophrenia, this study suggests that there may also be an increased prevalence of schizophrenia and bipolar disorder in children and teens with eye disease, not just depression and anxiety,” the authors concluded. “While schizophrenia may present with visual symptoms, it is unlikely that this feature of disease underlies the association with serious eye disease observed here.”

Meer EA, Lee YH, Repka MX, et al. Association of mood disorders, substance abuse and anxiety disorders in children and teens with serious structural eye diseases. *Am J Ophthalmol.* March 6, 2022. [Epub ahead of print].

Photo: Zlka Radovanovic on Unsplash



**Children with eye disease are more likely to have one of several mental health conditions, including anxiety, depression and/or schizophrenia.**

## Strabismus Increases Mental Illness, Lowers QOL

*(Continued from p. 8)*

of strabismus surgery, kids with successful outcomes had worse PedEyeQ scores in many domains compared with visually normal children.

In the child component, the frustration/worry domain score was significantly lower in kids with strabismus. In the proxy component, frustration/worry and eyecare domain scores were both significantly lower than functional vision, bothered by eyes/vision and social domain scores. In the parent component, worry about child's eye condition

domain score was significantly lower than all other parents' scores, while the impact on parent and family domain score was significantly higher than all others.

The researchers said they believe educational programs and psychosocial rehabilitation interventions that aim to improve the quality of life, participation in society and psychosocial functioning should be implemented in children with strabismus and their families.

“It is at least as important to address the functional and psychosocial effects of strabismus during childhood, while the social competencies and personality are developing,” the researchers noted in their paper, published in *Clinical Ophthalmology*.

1. Lee YH, Repka MX, Borlik MF, et al. Association of strabismus with mood disorders, schizophrenia and anxiety disorders among children. *JAMA Ophthalmol.* March 10, 2022. [Epub ahead of print].

2. Silva N, Castro C, Caiado F, et al. Evaluation of functional vision and eye-related quality of life in children with strabismus. *Clin Ophthalmol.* 2022;16:803-13.

# Age, High IOP, Shallow Ant. Chamber Up PACD Risk

*This study also found that cataract removal may be a protective factor.*

More than 77% of patients with primary angle-closure glaucoma (PACG) are Asian. The visual outcomes of this form of glaucoma can be devastating, and compared with open-angle glaucoma, the condition is associated with a three-fold increased risk of severe bilateral vision impairment. Its prevalence is also increasing globally, and particularly in Asia, it is emerging as a serious public health concern. Less is known about the incidence and progression of primary angle-closure disease (PACD), which precedes PACG.

To gain a better understanding of the incidence and risk factors of PACD in a multi-ethnic Asian population, researchers analyzed data over six years from the Singapore Epidemiology of Eye Diseases study, a population-based cohort study that included participants aged 40 or older living in Singapore. All completed ophthalmic examinations at baseline and six-year follow-up visits. Of 6,762 participants with valid data from both examinations, those included in the analysis were the 5,298 determined to be at risk for PACG and the 5,060 at risk for PACD.

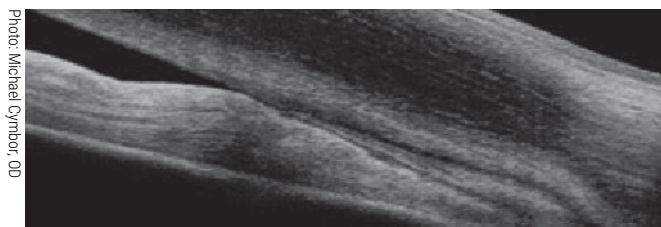


Photo: Michael Gymbor, MD

**Risk factors for PACD—which may lead to angle-closure glaucoma—include older age, higher IOP and more shallow anterior chamber depth.**

The six-year age-adjusted PACD incidence in the cohort was 3.5%. For PACG, primary angle-closure and primary angle-closure suspect, it was 0.29%, 0.46% and 2.54%, respectively. In addition, the team found that 9.38% of primary angle-closure suspects progressed to primary angle-closure or PACG over the six-year period.

Several baseline parameters were identified as risk factors for PACD development, including increasing age per decade (odds ratio: 1.35), higher intraocular pressure (odds ratio: 1.04) and shallower anterior chamber depth (odds ratio: 1.11). On the other hand, late posterior subcapsular cataract was associated with a decreased likelihood of developing PACD (odds ratio: 0.60).

Another important finding: as the rate of cataract surgeries increased, the number of patients who devel-

oped PACD decreased. “Studies have shown that cataract removal is associated with a deeper anterior chamber depth and wider anterior chamber angles, which subsequently reduces the risk of PACD,” the researchers wrote. As an example, they pointed to the former Liwan Eye study,

where “the highest PACD incidence observed could be largely explained by the much lower rate of cataract surgery reported in the study.”

Although age was shown to be a significant risk factor for PACD in this study, it, along with gender, didn’t have a significant effect on progression across disease stages.

The researchers concluded, “These findings may aid clinicians in deciding the frequency of monitoring or urgency of treatment and patient counseling.” In addition, they suggested the data could help “policy administrators ensure adequate resources are allocated to screening and intervention initiatives to address angle-closure glaucoma-related vision impairment.”

Teo ZL, Da Soh Z, Tham YC, et al. Six-year incidence and risk factors for primary angle closure disease: the Singapore Epidemiology of Eye Diseases study. *Ophthalmology*. March 9, 2022. [Epub ahead of print].

## IN BRIEF

**3D Retinal Imaging Edges Out RNFL Scans for Glaucoma Diagnosis.** A study recently found that the 3D structural configuration of the central retinal vessel trunk could be used as a biomarker for glaucoma diagnosis. Its diagnostic power was found to outperform the gold-standard diagnosis parameter: RNFL thickness.

Researchers trained a deep learning network to automatically segment the central retinal vessel trunk and its branches from the B-scans of the OCT volume of the optic nerve head. A total of 4,108 participants (1,639

glaucoma and 2,469 non-glaucoma) were recruited.

The study used two different approaches for diagnosis. In the first, only 3D convolutional neural networks (CNNs) and the 3D structure of the central retinal vessel trunk and its branches provided the diagnosis. For the second, the team projected the 3D structure of the central retinal vessel trunk and its branches orthographically onto sagittal, frontal and transverse planes to obtain three 2D images, and then a 2D CNN was used for diagnosis. The diagnostic performance of the central retinal vessel trunk and its branches analysis was also compared with that of RNFL thickness.

**The 3D and 2D diagnostic networks were able to differentiate glaucoma from non-glaucoma subjects with accuracies of 82.7% and 83.3%, respectively.** The corresponding area-under-the-curve (AUC) scores for the central retinal vessel trunk and its branches were 0.89 and 0.90, respectively, higher than those obtained with RNFL thickness alone (reported AUCs range from 0.74 to 0.80).

“We used the complete OCT volume and the 3D structure of the central retinal vessel trunk and its branches to demonstrate its diagnostic capabilities,” the researchers noted. “We did not restrict the network to only track the

location of central retinal vessel trunk or changes in the blood vessels, but allowed it to discover novel structural configurations by analyzing the 3D structure of the glaucomatous and non-glaucomatous central retinal vessel trunk and its branches.”

They concluded, “The paradigm introduced in this study has many potential clinical applications and may help increase diagnostic accuracy, predict future patterns and possibly impact prognosis of patients.”

Panda SK, Cheong H, Tun TA, et al. The three-dimensional structural configuration of the central retinal vessel trunk and branches as a glaucoma biomarker. *Am J Ophthalmol*. March 2, 2022. [Epub ahead of print].

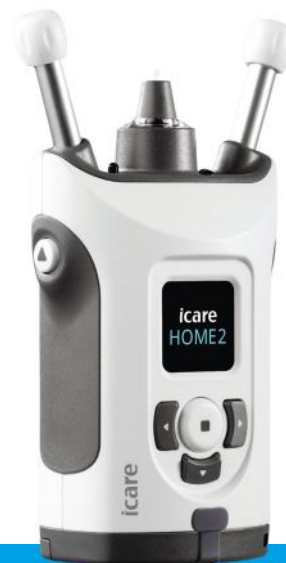# 24-hour at home tonometry

JUST LAUNCHED

## iCareHOME2

Glaucoma management based  
on real-world IOP data

- + **NEW!** IOP measurements taken in supine, reclined or sitting positions
- + **NEW!** New smart light guide for easy positioning
- + **NEW!** Interactive display screen
- + **NEW!** Comprehensive IOP reports



For more information, scan,  
call 888.422.7313, or email  
[infoUSA@icare-world.com](mailto:infoUSA@icare-world.com)  
[www.icare-world.com/USA](http://www.icare-world.com/USA)

For better perception **icare**



# Low Vitamin A May Cause Childhood Chalazion

*By contrast, vitamin D had no correlation with the condition.*

**E**vidence shows that vitamin deficiency is a key risk factor for children with chalazion. In a recent case-control study, researchers demonstrated that low serum vitamin A was significantly associated with this condition, suggesting vitamin A deficiency is a possible cause of chalazion among these patients.

The study authors enrolled 180 participants—90 chalazion patients and 90 healthy controls. Serum from collected blood samples was used to test levels of vitamins A and D (for the latter, 25(OH)D specifically was measured). Serum level of <math><0.7\mu\text{mol/L}</math> and <math><50\text{nmol/L}</math> were defined as a deficiency of vitamin A and D, respectively.

Baseline characteristics, including age and BMI, were similar between the two groups. The study authors reported that the average serum vitamin A levels in chalazion patients were significantly lower than in the control group. They observed no significant difference in the serum D levels of the chalazion and healthy cohorts.

The association between serum level of vitamin A and chalazion occurrence was also analyzed. Data showed that the percentage of

deficiency among chalazion patients (52.2%) was considerably higher than their healthy counterparts (28.6%), which researchers note suggests a negative relationship between serum vitamin A level and chalazion instance.

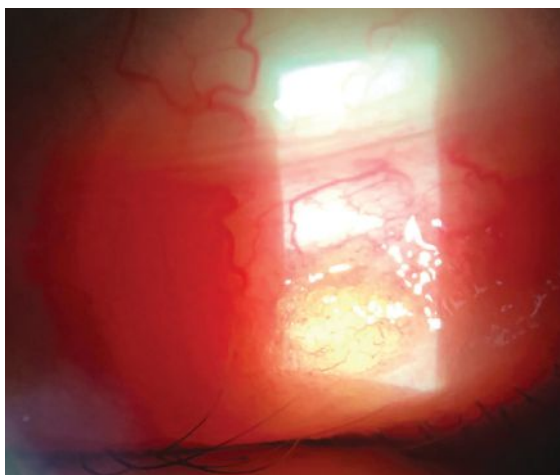


Photo: Farman Asaashan, OD

**Children who don't get enough vitamin A may be at an increased risk of developing chalazion, this study shows.**

"Due to lower storage of vitamin A in liver, children face a bigger risk of vitamin A deficiency than adults," the researchers wrote. "Vitamin A deficiency may cause Bitot's spots, conjunctival and corneal desiccation, multiple yellow-white peripheral focal retinal pigment epithelium defects and finally lead to serious

clinical manifestations such as dry eye disease, and night blindness."

They added, "Vitamin A plays a crucial role on inflammatory response. Lower levels of serum vitamin A lead to inflammation-related diseases including chalazion."

No significant difference in vitamin D deficiency was observed between the chalazion and control groups (58.9% vs 56.7%).

"We found that serum vitamin A levels were significantly lower in patients with chalazion than in control subjects, while the serum levels of 25(OH)D were not significantly different between the two groups," the study authors concluded. "Furthermore, we found a negative relationship between the serum vitamin A level and the morbidity of chalazion in children. These data demonstrate that vitamin A deficiency is a potential risk factor for chalazion in children."

While the link between chalazion and vitamin A deficiency in children has been established, the researchers noted a need for further investigation of the molecular mechanisms. ◀

Cheng H, Lv X, Yao J, et al. Clinical report: correlation of serum vitamins and chalazion. *Optom Vis Sci*. February 23, 2022. [Epub ahead of print].

## IN BRIEF

■ **Case Report: Severe Dietary Restriction Leads to Fungal Keratitis.** Though rare in advantaged countries, vitamin A deficiency may still occur as a result of malnutrition or extreme dieting, as was the issue in a recent case report published in the *British Medical Journal*. **An Australian woman in her 60s presented with bilateral corneal perforations and decreased visual acuity.** Culturing revealed a yeast colony comprised of *Candida albicans* in her left cornea.

Her diagnosis was corneal perforations secondary to bilateral fungal keratitis and hypovitaminosis A. **The researchers wrote in their paper that her vitamin deficiency was likely due to a diet of nothing but bananas and yogurt.** She underwent tectonic corneal grafts for the perforations and received retinyl palmitate as well as oral and topical voriconazole. She declined epithelial defect management, despite being informed of the risk of recurrent microbial keratitis, and did not change her diet. Her final vision was hand movement OS and 6/30 OD.

The ocular sequelae of vitamin A deficiency include nyctalopia, corneal ulcer and scarring. **Ocular features may include Bitot's spots (elevated, "foamy" conjunctival plaques) and conjunctival and corneal xerosis;** however, the authors noted in their paper that, like this case, those classically described features may not be seen on examination. Nevertheless, they wrote, "their absence shouldn't preclude clinical suspicion of vitamin A deficiency." "Early and specific questioning to explore the causative condition is imperative in routine clinical prac-

tice to avoid omitting the history of hypovitaminosis A," they continued. "This case highlights the importance of considering a multifactorial cause in corneal perforations" and diligently obtaining a thorough case history. **"Consider vitamin A deficiency in cases of corneal perforation or impending perforations, especially in the context of an unusual or nutrient-deficient diet,"** the report concluded.

Chung I, Tavassoli S, Wong N, et al. Vitamin A deficiency presenting with fungal keratitis and bilateral corneal perforations. *BMJ Case Rep*. 2022;15(3):e247853.

## BRIEF SUMMARY OF PRESCRIBING INFORMATION

This Brief Summary does not include all the information needed to use VYZULTA safely and effectively. See full Prescribing Information for VYZULTA.

**VYZULTA® (latanoprostene bunod ophthalmic solution), 0.024%, for topical ophthalmic use.**

Initial U.S. Approval: 2017

### 1 INDICATIONS AND USAGE

VYZULTA® (latanoprostene bunod ophthalmic solution) 0.024% is indicated for the reduction of intraocular pressure (IOP) in patients with open-angle glaucoma or ocular hypertension.

### 4 CONTRAINDICATIONS

None

### 5 WARNINGS AND PRECAUTIONS

#### 5.1 Pigmentation

VYZULTA® (latanoprostene bunod ophthalmic solution), 0.024% may cause changes to pigmented tissues. The most frequently reported changes with prostaglandin analogs have been increased pigmentation of the iris and periorbital tissue (eyelid).

Pigmentation is expected to increase as long as latanoprostene bunod ophthalmic solution is administered. The pigmentation change is due to increased melanin content in the melanocytes rather than to an increase in the number of melanocytes. After discontinuation of VYZULTA, pigmentation of the iris is likely to be permanent, while pigmentation of the periorbital tissue and eyelash changes are likely to be reversible in most patients. Patients who receive prostaglandin analogs, including VYZULTA, should be informed of the possibility of increased pigmentation, including permanent changes. The long-term effects of increased pigmentation are not known.

Iris color change may not be noticeable for several months to years. Typically, the brown pigmentation around the pupil spreads concentrically towards the periphery of the iris and the entire iris or parts of the iris become more brownish. Neither nevi nor freckles of the iris appear to be affected by treatment. While treatment with VYZULTA® (latanoprostene bunod ophthalmic solution), 0.024% can be continued in patients who develop noticeably increased iris pigmentation, these patients should be examined regularly [see Patient Counseling Information (17) in full Prescribing Information].

#### 5.2 Eyelash Changes

VYZULTA may gradually change eyelashes and vellus hair in the treated eye. These changes include increased length, thickness, and the number of lashes or hairs. Eyelash changes are usually reversible upon discontinuation of treatment.

#### 5.3 Intraocular Inflammation

VYZULTA should be used with caution in patients with a history of intraocular inflammation (iritis/uveitis) and should generally not be used in patients with active intraocular inflammation as it may exacerbate this condition.

#### 5.4 Macular Edema

Macular edema, including cystoid macular edema, has been reported during treatment with prostaglandin analogs. VYZULTA should be used with caution in aphakic patients, in pseudophakic patients with a torn posterior lens capsule, or in patients with known risk factors for macular edema.

#### 5.5 Bacterial Keratitis

There have been reports of bacterial keratitis associated with the use of multiple-dose containers of topical ophthalmic products. These containers had been inadvertently contaminated by patients who, in most cases, had a concurrent corneal disease or a disruption of the ocular epithelial surface.

#### 5.6 Use with Contact Lens

Contact lenses should be removed prior to the administration of VYZULTA because this product contains benzalkonium chloride. Lenses may be reinserted 15 minutes after administration.

### 6 ADVERSE REACTIONS

The following adverse reactions are described in the Warnings and Precautions section: pigmentation (5.1), eyelash changes (5.2), intraocular inflammation (5.3), macular edema (5.4), bacterial keratitis (5.5), use with contact lens (5.6).

#### 6.1 Clinical Trials Experience

Because clinical trials are conducted under widely varying conditions, adverse reaction rates observed in the clinical trials of a drug cannot be directly compared to rates in the clinical trials of another drug and may not reflect the rates observed in practice.

VYZULTA was evaluated in 811 patients in 2 controlled clinical trials of up to 12 months duration. The most common ocular adverse reactions observed in patients treated with latanoprostene bunod were: conjunctival hyperemia (6%), eye irritation (4%), eye pain (3%), and instillation site pain (2%). Approximately 0.6% of patients discontinued therapy due to ocular adverse reactions including ocular hyperemia, conjunctival irritation, eye irritation, eye pain, conjunctival edema, vision blurred, punctate keratitis and foreign body sensation.

### 8 USE IN SPECIFIC POPULATIONS

#### 8.1 Pregnancy

##### Risk Summary

There are no available human data for the use of VYZULTA during pregnancy to inform any drug associated risks.

Latanoprostene bunod has caused miscarriages, abortion, and fetal harm in rabbits. Latanoprostene bunod was shown to be abortifacient and teratogenic when administered intravenously (IV) to pregnant rabbits at exposures  $\geq 0.28$  times the clinical dose. Doses  $\geq 20$   $\mu\text{g}/\text{kg}/\text{day}$  (23 times the clinical dose) produced 100% embryofetal lethality. Structural abnormalities observed in rabbit fetuses included anomalies of the great vessels and aortic arch vessels, domed head, sternebral and vertebral skeletal anomalies, limb hyperextension

and malrotation, abdominal distension and edema. Latanoprostene bunod was not teratogenic in the rat when administered IV at 150 mcg/kg/day (87 times the clinical dose) [see Data].

The background risk of major birth defects and miscarriage for the indicated population is unknown. However, the background risk in the U.S. general population of major birth defects is 2 to 4%, and of miscarriage is 15 to 20%, of clinically recognized pregnancies.

##### Data

##### Animal Data

Embryofetal studies were conducted in pregnant rabbits administered latanoprostene bunod daily by intravenous injection on gestation days 7 through 19, to target the period of organogenesis. The doses administered ranged from 0.24 to 80 mcg/kg/day. Abortion occurred at doses  $\geq 0.24$  mcg/kg/day latanoprostene bunod (0.28 times the clinical dose, on a body surface area basis, assuming 100% absorption). Embryofetal lethality (resorption) was increased in latanoprostene bunod treatment groups, as evidenced by increases in early resorptions at doses  $\geq 0.24$  mcg/kg/day and late resorptions at doses  $\geq 6$  mcg/kg/day (approximately 7 times the clinical dose). No fetuses survived in any rabbit pregnancy at doses of 20 mcg/kg/day (23 times the clinical dose) or greater. Latanoprostene bunod produced structural abnormalities at doses  $\geq 0.24$  mcg/kg/day (0.28 times the clinical dose). Malformations included anomalies of sternum, coarctation of the aorta with pulmonary trunk dilation, retroesophageal subclavian artery with absent brachiocephalic artery, domed head, forepaw hyperextension and hindlimb malrotation, abdominal distention/edema, and missing/fused caudal vertebrae.

An embryofetal study was conducted in pregnant rats administered latanoprostene bunod daily by intravenous injection on gestation days 7 through 17, to target the period of organogenesis. The doses administered ranged from 150 to 1500 mcg/kg/day. Maternal toxicity was produced at 1500 mcg/kg/day (870 times the clinical dose, on a body surface area basis, assuming 100% absorption), as evidenced by reduced maternal weight gain. Embryofetal lethality (resorption and fetal death) and structural anomalies were produced at doses  $\geq 300$  mcg/kg/day (174 times the clinical dose). Malformations included anomalies of the sternum, domed head, forepaw hyperextension and hindlimb malrotation, vertebral anomalies and delayed ossification of distal limb bones. A no observed adverse effect level (NOAEL) was established at 150 mcg/kg/day (87 times the clinical dose) in this study.

#### 8.2 Lactation

##### Risk Summary

There are no data on the presence of VYZULTA in human milk, the effects on the breastfed infant, or the effects on milk production. The developmental and health benefits of breastfeeding should be considered, along with the mother's clinical need for VYZULTA, and any potential adverse effects on the breastfed infant from VYZULTA.

#### 8.4 Pediatric Use

Use in pediatric patients aged 16 years and younger is not recommended because of potential safety concerns related to increased pigmentation following long-term chronic use.

#### 8.5 Geriatric Use

No overall clinical differences in safety or effectiveness have been observed between elderly and other adult patients.

### 13 NONCLINICAL TOXICOLOGY

#### 13.1 Carcinogenesis, Mutagenesis, Impairment of Fertility

Latanoprostene bunod was not mutagenic in bacteria and did not induce micronuclei formation in the *in vivo* rat bone marrow micronucleus assay. Chromosomal aberrations were observed *in vitro* with human lymphocytes in the absence of metabolic activation.

Latanoprostene bunod has not been tested for carcinogenic activity in long-term animal studies. Latanoprost acid is a main metabolite of latanoprostene bunod. Exposure of rats and mice to latanoprost acid, resulting from oral dosing with latanoprost in lifetime rodent bioassays, was not carcinogenic.

Fertility studies have not been conducted with latanoprostene bunod. The potential to impact fertility can be partially characterized by exposure to latanoprost acid, a common metabolite of both latanoprostene bunod and latanoprost. Latanoprost acid has not been found to have any effect on male or female fertility in animal studies.

#### 13.2 Animal Toxicology and/or Pharmacology

A 9-month toxicology study administered topical ocular doses of latanoprostene bunod to one eye of cynomolgus monkeys: control (vehicle only), one drop of 0.024% bid, one drop of 0.04% bid and two drops of 0.04% per dose, bid. The systemic exposures are equivalent to 4.2-fold, 7.9-fold, and 13.5-fold the clinical dose, respectively, on a body surface area basis (assuming 100% absorption). Microscopic evaluation of the lungs after 9 months observed pleural/subpleural chronic fibrosis/inflammation in the 0.04% dose male groups, with increasing incidence and severity compared to controls. Lung toxicity was not observed at the 0.024% dose.

U.S. Patent Numbers: 7,273,946; 7,629,345; 7,910,767; 8,058,467.

VYZULTA is a trademark of Bausch & Lomb Incorporated or its affiliates.

© 2020 Bausch & Lomb Incorporated or its affiliates.

##### Distributed by:

Bausch + Lomb, a division of

Bausch Health US, LLC

Bridgewater, NJ 08807 USA

Based on 9612403 (Folded), 9612303 (Flat) 5/2019

VYZ.0109.USA.20 Issued: 5/2020



**VYZULTA**

(latanoprostene  
bunod ophthalmic  
solution), 0.024%

# THE HORSEPOWER YOU NEED TO LOWER IOP

**Powerful IOP reduction with excellent tolerability<sup>1,2</sup>**

VYZULTA delivered **up to 9.1 mmHg mean IOP reduction** from baseline in pivotal trials.<sup>1,2\*</sup>

**TAKE A TEST RIDE AT [VYZULTAHCP.COM](http://VYZULTAHCP.COM)**

\*Pivotal study designs: Two Phase 3, randomized, multicenter, parallel-group studies, APOLLO and LUNAR, evaluating noninferiority of once-daily VYZULTA vs twice-daily timolol maleate 0.5% in patients with open-angle glaucoma or ocular hypertension. Primary endpoint was IOP measured at 9 assessment time points in study eye. APOLLO (VYZULTA, n=284; timolol, n=133) and LUNAR (VYZULTA, n=278; timolol, n=136).<sup>2,3</sup>

## INDICATION

VYZULTA® (latanoprostene bunod ophthalmic solution), 0.024% is indicated for the reduction of intraocular pressure (IOP) in patients with open-angle glaucoma or ocular hypertension.

## IMPORTANT SAFETY INFORMATION

- Increased pigmentation of the iris and periorbital tissue (eyelid) can occur. Iris pigmentation is likely to be permanent
- Gradual changes to eyelashes, including increased length, increased thickness, and number of eyelashes, may occur. These changes are usually reversible upon treatment discontinuation
- Use with caution in patients with a history of intraocular inflammation (iritis/uveitis). VYZULTA should generally not be used in patients with active intraocular inflammation
- Macular edema, including cystoid macular edema, has been reported during treatment with prostaglandin analogs. Use with caution in aphakic patients, in pseudophakic patients with a torn posterior lens capsule, or in patients with known risk factors for macular edema
- There have been reports of bacterial keratitis associated with the use of multiple-dose containers of topical ophthalmic products that were inadvertently contaminated by patients
- Contact lenses should be removed prior to the administration of VYZULTA and may be reinserted 15 minutes after administration
- Most common ocular adverse reactions with incidence  $\geq 2\%$  are conjunctival hyperemia (6%), eye irritation (4%), eye pain (3%), and instillation site pain (2%)

For more information, please see Brief Summary of full Prescribing Information on adjacent page.

**References:** **1.** VYZULTA Prescribing Information. Bausch & Lomb Incorporated. **2.** Weinreb RN, Scassellati Sforzolini B, Vittitow J, Liebmann J. Latanoprostene bunod 0.024% versus timolol maleate 0.5% in subjects with open-angle glaucoma or ocular hypertension: the APOLLO study. *Ophthalmology*. 2016;123(5):965-973. **3.** Medeiros FA, Martin KR, Peace J, Scassellati Sforzolini B, Vittitow JL, Weinreb RN. Comparison of latanoprostene bunod 0.024% and timolol maleate 0.5% in open-angle glaucoma or ocular hypertension: the LUNAR study. *Am J Ophthalmol*. 2016;168:250-259.

VYZULTA and the V design are trademarks of Bausch & Lomb Incorporated or its affiliates. Any other product/brand names and/or logos are trademarks of the respective owners. ©2021 Bausch & Lomb Incorporated or its affiliates. All rights reserved. VYZ.0258.USA.20

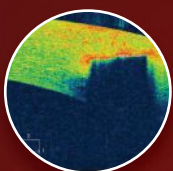
**BAUSCH + LOMB**



# FEATURES

REVIEW OF OPTOMETRY • Vol. 159, No. 4 • APRIL 15, 2022

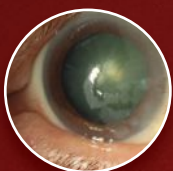
## 9th ANNUAL CORNEAL DISEASE REPORT



### 32 Clinical Pearls in Corneal Foreign Body Removal

How to properly identify, treat and manage patients with this ocular trauma.

By Bridget Hendricks, OD



### 42 Fine-Tune Your Corneal Disease Diagnostic Skills

Take these quizzes to see where your knowledge of these conditions ranks.

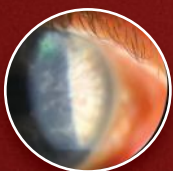By Paul Hammond, OD



### 50 Improving the Gold Standard For CXL

Here's a look at what's currently available, what's in the works and what's on the horizon.

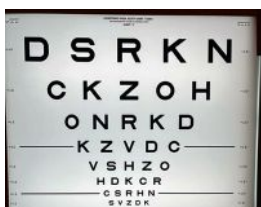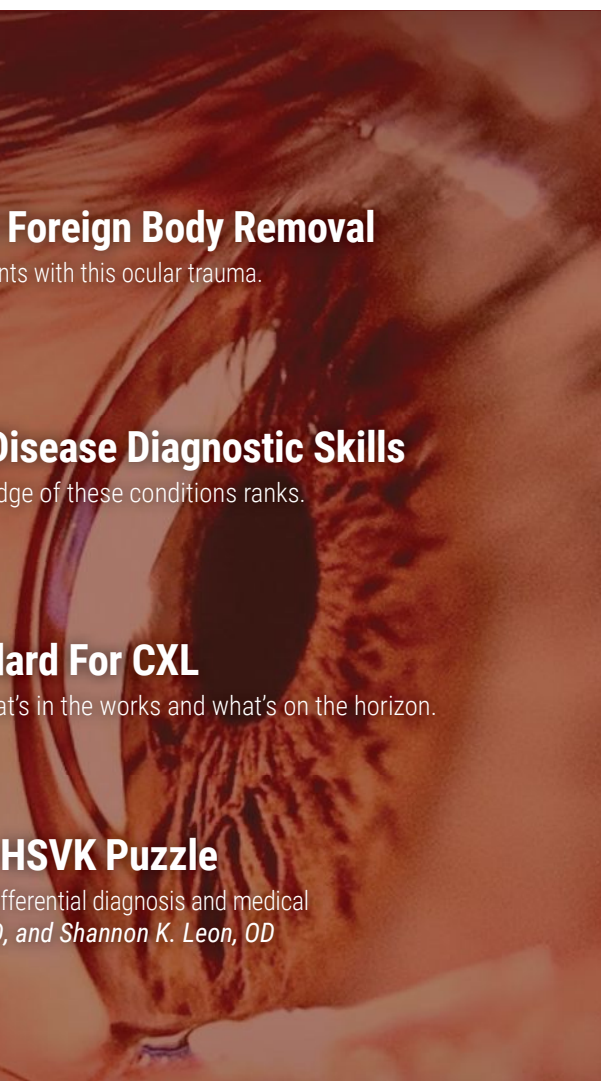
By Lily Arendt, OD



### 56 CE: Piecing Together the HSVK Puzzle

Given the seriousness of this condition, proper differential diagnosis and medical management is key. By Alexander Martinez, OD, and Shannon K. Leon, OD

EARN 2 CE CREDITS



### 66 Brush Up on Your Low Vision Skills

You can make rehabilitation a priority in your practice with fewer hassles than you may think.

By Joshua L. Robinson, OD



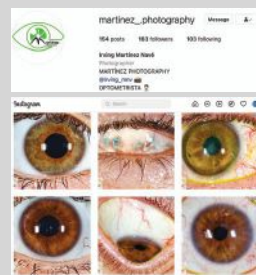### 74 To Cut or Not to Cut? Weighing Strabismus Surgery Referral

Determine when this intervention is truly better than vision therapy—and how to set expectations.

By Brenda Montecalvo, OD

#### Instagram Spotlight

This month's cover photo was taken by optometrist Irving Martínez Navé, a reader from León, Guanajuato, Mexico. You can follow him on Instagram at [@martinez\\_photography](https://www.instagram.com/martinez_photography) for more great clinical images from his patient base.



Do you want to have your clinical photos showcased in *Review of Optometry*? Write to us at [editor@reviewofoptometry.com](mailto:editor@reviewofoptometry.com).

# DEPARTMENTS

REVIEW OF OPTOMETRY • APRIL 15, 2022



VISIT US ON SOCIAL MEDIA

Facebook: revoptom

Twitter: revoptom

Instagram: revoptom

LinkedIn: company/review-of-optometry

4

## NEWS REVIEW

Clinical, legislative and practice development updates.

20

## LETTERS TO THE EDITOR

Feedback and ideas from the optometric community.

24

## OUTLOOK

### Upstairs, Downstairs

The medical/optical dichotomy of optometry was on display once again at Vision Expo East.

**Jack Persico, Editor-in-Chief**

26

## THROUGH MY EYES

### Cornea Cornerstone

How to properly manage this important part of optometric care.

**Paul M. Karpecki, OD**

28

## CHAIRSIDE

### Can You Handle the Truth?

Recognize what's real—and what's not.

**Montgomery Vickers, OD**

30

## CLINICAL QUANDARIES

### Assuming the Worst

Careful observation and history taking is paramount when evaluating a swollen eyelid.

**Paul C. Ajamian, OD**

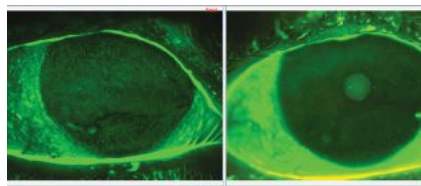
80

## CORNEA AND CONTACT LENS Q+A

### Out for Blood

This dry eye treatment may not be first on your list, but it's worth taking into consideration.

**Joseph P. Shovlin, OD**



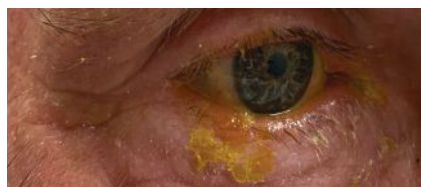82

## THERAPEUTIC REVIEW

### Herpes Hurts

Temporal pain often portends this condition, so learn how to best manage it.

**Joseph W. Sowka, OD**




86

## GLAUCOMA GRAND ROUNDS

### A Tale of Two Patients

One had more structural damage, the other more progression. Here's how to proceed in both cases.

**James L. Fanelli, OD**



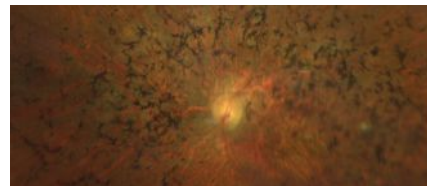
90

## RETINA QUIZ

### Visually Handicapped

This patient's medical history and genetics played a key role in finding the correct diagnosis.

**Mark Dunbar, OD**



92

## SURGICAL MINUTE

### Ring Me Up

The IC-8 IOL creates a permanent pinhole effect, improving the prospects for a monovision approach.

**Derek N. Cunningham, OD,  
and Walter O. Whitley, OD, MBA**

95

## FOCUS ON REFRACTION

### Three Sides to Every Survey

This patient history tool is simple to implement yet significant for outcomes.

**Marc B. Taub, OD, MS, and Pamela H. Schnell, OD**

98

## DIAGNOSTIC QUIZ

### What's Your Angle?

A patient comes in with IOP of 65mm Hg and 20/400 vision. How do you arrive at a diagnosis and address her urgent needs?

**Andrew S. Gurwood, OD**

REVIEW OF OPTOMETRY (ISSN 0147-7633) IS PUBLISHED MONTHLY, 12 TIMES A YEAR BY JOBSON MEDICAL INFORMATION LLC, 395 HUDSON STREET, 3RD FLOOR FLOOR, NEW YORK, NY 10014. PERIODICALS POSTAGE PAID AT NEW YORK, NY AND ADDITIONAL MAILING OFFICES. POSTMASTER: SEND ADDRESS CHANGES TO REVIEW OF OPTOMETRY, PO BOX 81, CONGERS, NY 10920-0081. SUBSCRIPTION PRICES: US: ONE YEAR \$56; TWO YEARS \$97, CANADA: ONE YEAR \$88, TWO YEARS \$160, INT'L: ONE YEAR \$209, TWO YEARS \$299. FOR SUBSCRIPTION INFORMATION CALL TOLL-FREE (877) 529-1746 (USA); OUTSIDE USA, CALL (845) 267-3065. OR EMAIL US AT REVOPOTOMETRY@CAMBEYWEST.COM. PUBLICATIONS MAIL AGREEMENT NO: 40612608. CANADA RETURNS TO BE SENT TO BLEUCHIP INTERNATIONAL, P.O. BOX 25542, LONDON, ON N6C 6B2.



# Optometry's Role in the Patient Journey



**Gloria Chiu, OD, FAAO, FSLC**

Associate Professor of Clinical Ophthalmology  
USC Roski Eye Institute,  
USC Keck School of Medicine  
Los Angeles

## KEY TAKEAWAYS

- Cross-linking with the only FDA-approved iLink™ System can stop or slow progressive keratoconus.
- Early diagnosis and treatment are essential to preserve as much vision as possible.
- Optometrists are uniquely positioned to change lives and protect vision by identifying at-risk patients in the mild stages of the disease.

**K**eratoconus (KC) is a degenerative condition with onset in early adolescence. It is characterized by gradual thinning of the corneal stroma, causing a cone-shaped protrusion and worsening vision. As doctors of optometry, our top priority with these patients should be to manage their disease—and only secondarily to correct their vision.

A referral for corneal collagen cross-linking, which has been shown to halt progression in 92%-100% of cases<sup>1</sup>, may be able to preserve vision. As

it becomes a debilitating disease that affects every aspect of their lives. Worsening KC severity is associated with significant declines in reading, mobility, and emotional well-being quality of life (QoL) scores.<sup>3</sup> The impact on QoL can be even greater than that of retinal diseases and can be felt even when one eye still has good vision<sup>4</sup> so it is important that patients get help as early as possible.

In the U.S., when cross-linking is performed with the iLink™ platform (Glaukos), the only FDA-approved cross-linking system, it is generally covered by insurance for 96% of those with commercial insurance. In a recent simulation model, treatment with iLink™ was found to be highly cost effective, resulting in a 26% reduction in PKPs and patients spending 28 fewer years in the advanced stages of KC.<sup>5</sup> Young patients who can be treated

early while their vision is still good have the most to gain.

That's where optometrists' role becomes so critical. Our awareness of early progressive KC signs and risk factors can be nothing short of life changing for that young myope in our chair. There is no need to wait until a patient has lost vision or has slit lamp signs (e.g., thinning or striae) to refer for a more in-depth KC evaluation. It is standard of care to intervene with cross-linking upon detection of progression.<sup>6</sup>

Advanced tomography/topography provides the most sensitive and accurate diagnostic information. However, there are a number of signs and symptoms that should heighten suspicion of KC and prompt further testing, either in the practice or by referral. These include myopic shift, rapidly changing astigmatism, vision that won't correct to 20/20 (with no other known reason), distorted mires on manual keratometry, and scissoring or an irregular retinoscopy reflex. Patients with a history of eye rubbing, connective tissue disease, Down syndrome, or a family history of KC are also at higher risk.

By promptly referring these patients for further testing and, if warranted, iLink™ cross-linking treatment, optometrists are uniquely positioned to protect and preserve patients' vision over their entire lifetime. ■

## REFERENCES:

1. Koller T et al. J Cataract Refract Surg 2009;35:1358.
2. Davidson AE et al. Eye (Lond) 2014;28:189.
3. Tan JCK, et al. Cornea 2019;38:600.
4. Kandel H, et al. Clin Exp Ophthalmol 2022;Epub ahead of print.
5. Lindstrom RL et al. J Med Econ 2021;24:410.
6. American Academy of Ophthalmology Preferred Practice Pattern, Corneal Ectasia, 2018

## INDICATIONS

Photrexa Viscous (riboflavin 5'-phosphate in 20% dextran ophthalmic solution) and Photrexa (riboflavin 5'-phosphate ophthalmic solution) are indicated for use with the iLink System in corneal collagen cross-linking for the treatment of progressive keratoconus and corneal ectasia following refractive surgery.

## IMPORTANT SAFETY INFORMATION

Corneal collagen cross-linking should not be performed on pregnant women.

Ulcerative keratitis can occur. Patients should be monitored for resolution of epithelial defects. The most common ocular adverse reaction was corneal opacity (haze). Other ocular side effects include punctate keratitis, corneal striae, dry eye, corneal epithelium defect, eye pain, light sensitivity, reduced visual acuity, and blurred vision.

These are not all of the side effects of the corneal collagen cross-linking treatment. For more information, go to [www.livingwithkeratoconus.com](http://www.livingwithkeratoconus.com) to obtain the FDA-approved product labeling.

You are encouraged to report all side effects to the FDA.

Visit [www.fda.gov/medwatch](http://www.fda.gov/medwatch), or call 1-800-FDA-1088.

## With Cross-Linking<sup>5</sup>

**26%** fewer PKPs | **28** fewer years in late-stage KC

with any surgical procedure, there is the potential for complications and cross-linking may not be right for everyone. After treatment, patients will still need regular optometric care. Follow-up care is similar to that required for PRK. However, there is no global period, so each follow-up visit is charged as a regular exam.

Without cross-linking treatment, progressive KC typically continues to worsen until around age 40 (and sometimes longer), with 10%-20% of cases requiring a penetrating keratoplasty (PKP).<sup>2</sup> When patients reach the advanced stages of keratoconus,

**SCAN WITH PHONE**

Learn more about iLink corneal cross-linking here





# LETTERS TO THE EDITOR

Feedback and ideas from the optometric community.

## Debating the Value of Genetic Testing

*Early accounts of AvaGen's role in clinical practice stimulate discussion and highlight the need for greater dialog.*

**Editor's note:** The January/February edition of *Review of Cornea & Contact Lenses* included a feature on genetic testing in keratoconus that included anecdotal impressions from several optometrists, as well as commentary from representatives of Avellino, makers of the AvaGen test. In one section of the discussion, Brian Chou, OD, reported receiving differing results on repeat testing of the same patient.

Here, representatives of Avellino offer elaboration and Dr. Chou responds to the new information.


### Genetic Testing for Keratoconus Will Continue to Evolve, but Patients Can Benefit Now

By Mile Brujic, OD, and Sarvari Panchumarthi, PhD

We want to thank the editorial team for their article, "KCN Genetic Testing: Where Does It Fit In?"

One area optometrists should be devoting an increasing amount of attention and interest to is genetic testing. As with many new technological advancements in eye care, an increasing understanding of how these tests work and how to integrate them in the practice of optometry will be of the utmost importance today and in the next several years.

AvaGen by Avellino helps detect the genetic risk for keratoconus and the presence of corneal dystrophies. A rather new type of test to enter the field, there are three main aspects to it



**KCN GENETIC TESTING: WHERE DOES IT FIT IN?**

This new technology holds the potential to help identify some patients early, but experts caution it's just one piece of the diagnostic puzzle.

By Jane Cole, Contributing Editor

**A** clear-cut diagnosis of keratoconus (KCN) can be difficult for a clinician to make. It may require corneal cross-linking (CXL) or risk-reducing procedures that may cause post-op issues in patients with corneal dystrophies and astigmatism. However, not every diagnosis is obvious—there is often a gray area in which the individual doesn't exhibit clinical signs of the disease but may still harbor latent KCN.

These gray areas can sometimes place doctors in tricky situations, as early detection of ocular conditions is always the best approach to stop before vision loss.

Enter AvaGen (Avellino), the first commercially available test of its kind to help identify patients at risk for developing KCN and certain other corneal dystrophies. The DNA test generates a polygenic KCN risk score based on the analysis of 75 KCN-related genes and more than 2,000 gene variants, according to the company. "Since some ethnicities show a higher prevalence of this eye condition, the AvaGen test also factors this information into its results," the company says. The test is also purported to measure susceptibility of several corneal dystrophies, including epithelial basement membrane, granular, lattice, Reis-Bückler, Schneider and Theiler-Belke, Avellino states.

"Genetic testing to KCN provides one more data point for determining risk of disease development," says Aaron Broemer, OD, of Boise, ID. "Unlike previous ways of screening for the disease, genetic testing provides a look not only at current risk status but also future risk. This can be both helpful and confusing as clinical decisions are made."

**KCN CLUES**

On the screening front, KCN diagnoses have expanded and become even more refined in recent years. For example, corneal tomography allows clinicians to evaluate the anterior and posterior cornea along with global pachymetry, says Melissa Barrett, OD, of UC Davis. Anterior segment optical coherence tomography (AS-OCT) can evaluate corneal epithelial thickness and wavefront aberrometry can be used to evaluate specific aberrations such as the third-, fourth- and fifth-order aberrations, especially vertical coma and trefoil. Also, corneal biomechanics can supply useful information to predict early KCN, she suggests.

"AS-OCT has certainly evolved to provide as much more information about the cornea in those at high risk or who actually have KCN, but their condition missed by traditional technologies," adds Mile Brujic, OD, of Bowling Green, OH. "Currently the diagnosis of keratoconus at a mild stage—"the sweet spot" for doing something about it—requires sophisticated imaging. Dr. Broemer says.

Beyond the traditional and enhanced diagnostic tools available, numerous studies have supported the premise that genetics play a role into whether an individual may develop KCN.

One recent investigation included genetic screening in a large cohort of Chinese and Czech patients with KCN, and its researchers suggested variants in the VSM1 and TCF14 genes might be responsible for the condition through autosomal-dominant inheritance patterns with variable expressivity. The authors concluded that genetic screening is of great value in establishing a disease classification system of subclinical and early-stage KCN and for the preoperative screening of refractive surgery individuals to prevent postoperative corneal ectasia."

that are critical to help understand its clinical utility.

First is understanding the polygenic risk score (PRS) for keratoconus. The AvaGen PRS scale ranges from 0 to 100 and is divided into low-, medium- and high-risk segments. The risk score for a patient broadly falls into one of those three segments/categories. As an example, a polygenic risk score of 9 and a score of 22 are both in the low genetic risk category.

The PRS is based on the number and types of multitudes of genetic variants found in each tested individual. As long as the PRS remains in the same risk category, the minor differences in the score number are not indicative of significant differences in disease risk. Via next-generation sequencing (the

technology used in the AvaGen genetic test), the analytical sensitivity and specificity of the test is 100%.

With respect to Dr. Chou's testing of AvaGen using the same sample patient's DNA with three different names, dates of birth and ethnicities, we would like to point out that the difference between a PRS of 9 and 22 (found in the first and second samplings of the patient) is not clinically meaningful. Both scores place the patient's genetic risk in the same category: low-risk. The genes identified in the risk of keratoconus are always detected, and if a specific variant used in the PRS calculation is 'dropped out' due to low quality of read depth, the PRS value would be expected to differ slightly.

Avellino does quality control by running each patient's sample in triplicates in its test process for each run. In the third testing of the same patient, which was received in mid-October 2021, the PRS yielded a higher value (61), as the company released an improved version of the PRS analysis in this same month.

Second, understanding how a polygenic risk score is developed for complex genetic diseases is key.

Complex genetic diseases occur due to the cumulative effect of several single-nucleotide variants (SNVs) of very small effect size. Unlike monogenic diseases (where the presence of a single pathogenic variant yields a more definitive predisposition for the disease), polygenic diseases are more complex in nature. There is always an interplay of genes and environment in the manifestation of a polygenic disease. This makes the prediction of disease risk in polygenic diseases more elusive.

As genomics knowledge improves for a certain disease, the polygenic risk score's predictive value can be refined and improved over time. For AvaGen,

To treat ocular inflammation and pain following ophthalmic surgery or ocular itching associated with allergic conjunctivitis.

## DEXTENZA KEEPS PATIENTS

# COMPLIANT

AND SATISFIED<sup>1-3\*</sup>

### A hands-free advancement in ophthalmic steroid treatment.<sup>1,4</sup>

Easy-to-insert<sup>†</sup> and preservative-free intracanalicular DEXTENZA offers patients a satisfying post-op experience—providing up to 30 days of sustained steroid coverage.<sup>1-5</sup>

#### INDICATIONS

DEXTENZA is a corticosteroid indicated for:

- The treatment of ocular inflammation and pain following ophthalmic surgery.
- The treatment of ocular itching associated with allergic conjunctivitis.

#### IMPORTANT SAFETY INFORMATION

##### CONTRAINDICATIONS

DEXTENZA is contraindicated in patients with active corneal, conjunctival or canalicular infections, including epithelial herpes simplex keratitis (dendritic keratitis), vaccinia, varicella; mycobacterial infections; fungal diseases of the eye, and dacryocystitis.

##### WARNINGS AND PRECAUTIONS

**Intraocular Pressure Increase** - Prolonged use of corticosteroids may result in glaucoma with damage to the optic nerve, defects in visual acuity and fields of vision. Steroids should be used with caution in the presence of glaucoma. Intraocular pressure should be monitored during treatment.

**Bacterial Infections** - Corticosteroids may suppress the host response and thus increase the hazard for secondary ocular infections. In acute purulent conditions, steroids may mask infection and enhance existing infection.

**Viral Infections** - Use of ocular steroids may prolong the course and may exacerbate the severity of many viral infections of the eye (including herpes simplex).

**Fungal Infections** - Fungus invasion must be considered in any persistent corneal ulceration where a steroid has been used or is in use. Fungal culture should be taken when appropriate.

**Delayed Healing** - Use of steroids after cataract surgery may delay healing and increase the incidence of bleb formation.

**Other Potential Corticosteroid Complications** - The initial prescription and renewal of the medication order of DEXTENZA should be made by a physician only after examination of the patient with the aid of magnification, such as slit lamp biomicroscopy, and, where appropriate, fluorescein staining. If signs and symptoms fail to improve after 2 days, the patient should be re-evaluated.

##### ADVERSE REACTIONS

###### Ocular Inflammation and Pain Following Ophthalmic Surgery

The most common ocular adverse reactions that occurred in patients treated with DEXTENZA were: anterior chamber inflammation including iritis and iridocyclitis (10%), intraocular pressure increased (6%), visual acuity reduced (2%), cystoid macular edema (1%), corneal edema (1%), eye pain (1%), and conjunctival hyperemia (1%). The most common non-ocular adverse reaction was headache (1%).

###### Itching Associated with Allergic Conjunctivitis

The most common ocular adverse reactions that occurred in patients treated with DEXTENZA were: intraocular pressure increased (3%), lacrimation increased (1%), eye discharge (1%), and visual acuity reduced (1%). The most common non-ocular adverse reaction was headache (1%).

Please see adjacent Brief Summary of full Prescribing Information.

\*93% (187/201) DEXTENZA patients were satisfied with the insert in the Phase 3 Study for the treatment of ocular inflammation and pain following ophthalmic surgery.<sup>3</sup>

<sup>†</sup>73.6% of physicians in Study 1, 76.4% in Study 2, and 79.6% in Study 3, for the treatment of ocular inflammation and pain following ophthalmic surgery, rated DEXTENZA as easy to insert.<sup>2,5</sup>

**References:** **1.** DEXTENZA [package insert]. Bedford, MA: Ocular Therapeutix, Inc; 2021. **2.** Tyson SL, et al. *J Cataract Refract Surg.* 2019;45(2):204-212 [erratum in: 2019;45(6):895]. **3.** Data on File 00837. Ocular Therapeutix, Inc. **4.** Sawhney AS, Inventors, et al. Incept, LLC, Assignee. Drug Delivery Through Hydrogel Plugs. US Patent 8,409,606 B2. April 2, 2013. **5.** Walters T, et al. *J Clin Exp Ophthalmol.* 2016;7(4):1-11.

**Dextenza**<sup>®</sup>  
(dexamethasone ophthalmic insert) 0.4mg  
for intracanalicular use

# Dextenza®

(dexamethasone ophthalmic insert) 0.4 mg  
for intracanalicular use

**BRIEF SUMMARY:** Please see the DEXTENZA Package Insert for full Prescribing Information (10/2021)

## 1 INDICATIONS AND USAGE

### 1.1 Ocular Inflammation and Pain Following Ophthalmic Surgery

DEXTENZA® (dexamethasone ophthalmic insert) is a corticosteroid indicated for the treatment of ocular inflammation and pain following ophthalmic surgery (1.1).

### 1.2 Itching Associated with Allergic Conjunctivitis

DEXTENZA® (dexamethasone ophthalmic insert) is a corticosteroid indicated for the treatment of ocular itching associated with allergic conjunctivitis (1.2).

## 4 CONTRAINDICATIONS

DEXTENZA is contraindicated in patients with active corneal, conjunctival or canalicular infections, including epithelial herpes simplex keratitis (dendritic keratitis), vaccinia, varicella; mycobacterial infections; fungal diseases of the eye, and dacryocystitis.

## 5 WARNINGS AND PRECAUTIONS

### 5.1 Intraocular Pressure Increase

Prolonged use of corticosteroids may result in glaucoma with damage to the optic nerve, defects in visual acuity and fields of vision. Steroids should be used with caution in the presence of glaucoma. Intraocular pressure should be monitored during the course of the treatment.

### 5.2 Bacterial Infection

Corticosteroids may suppress the host response and thus increase the hazard for secondary ocular infections. In acute purulent conditions, steroids may mask infection and enhance existing infection [see Contraindications (4)].

### 5.3 Viral Infections

Use of ocular steroids may prolong the course and may exacerbate the severity of many viral infections of the eye (including herpes simplex) [see Contraindications (4)].

### 5.4 Fungal Infections

Fungus invasion must be considered in any persistent corneal ulceration where a steroid has been used or is in use. Fungal culture should be taken when appropriate [see Contraindications (4)].

### 5.5 Delayed Healing

The use of steroids after cataract surgery may delay healing and increase the incidence of bleb formation.

### 5.6 Other Potential Corticosteroid Complications

The initial prescription and renewal of the medication order of DEXTENZA should be made by a physician only after examination of the patient with the aid of magnification, such as slit lamp biomicroscopy, and, where appropriate, fluorescein staining. If signs and symptoms fail to improve after 2 days, the patient should be re-evaluated.

## 6 ADVERSE REACTIONS

The following serious adverse reactions are described elsewhere in the labeling:

- Intraocular Pressure Increase [see Warnings and Precautions (5.1)]
- Bacterial Infection [see Warnings and Precautions (5.2)]
- Viral Infection [see Warnings and Precautions (5.3)]
- Fungal Infection [see Warnings and Precautions (5.4)]
- Delayed Healing [see Warnings and Precautions (5.5)]

### 6.1 Clinical Trials Experience

Because clinical trials are conducted under widely varying conditions, adverse reaction rates observed in the clinical trials of a drug cannot be directly compared to rates in the clinical trials of another drug and may not reflect the rates observed in practice. Adverse reactions associated with ophthalmic steroids include elevated intraocular pressure, which may be associated with optic nerve damage, visual acuity and field defects, posterior subcapsular cataract formation; delayed wound healing; secondary ocular infection from pathogens including herpes simplex, and perforation of the globe where there is thinning of the cornea or sclera [see Warnings and Precautions (5)].

### 6.2 Ocular Inflammation and Pain Following Ophthalmic Surgery

DEXTENZA safety was studied in four randomized, vehicle-controlled studies (n = 567). The mean age of the population was 68 years (range 35 to 87 years), 59% were female, and 83% were white. Forty-seven percent had brown iris color and 30% had blue iris color. The most common ocular adverse reactions that occurred in patients treated with DEXTENZA were: anterior chamber inflammation including iritis and iridocyclitis (10%); intraocular pressure increased (6%); visual acuity reduced (2%); cystoid macular edema (1%); corneal edema (1%); eye pain (1%) and conjunctival hyperemia (1%).

The most common non-ocular adverse reaction that occurred in patients treated with DEXTENZA was headache (1%).

### 6.3 Itching Associated with Allergic Conjunctivitis

DEXTENZA safety was studied in four randomized, vehicle-controlled studies (n = 154). The mean age of the population was 41 years (range 19 to 69 years), 55% were female and 61% were white. Fifty seven percent had brown iris color and 20% had blue iris color. The most common ocular adverse reactions that occurred in patients treated with DEXTENZA were: intraocular pressure increased (3%); lacrimation increased (1%); eye discharge (1%), and visual acuity reduced (1%). The most common non-ocular adverse reaction that occurred in patients treated with DEXTENZA was headache (1%).

## 8 USE IN SPECIFIC POPULATIONS

### 8.1 Pregnancy

#### Risk Summary

There are no adequate or well-controlled studies with DEXTENZA in pregnant women to inform a drug-associated risk for major birth defects and miscarriage. In animal reproduction studies, administration of topical ocular dexamethasone to pregnant mice and rabbits during organogenesis produced embryofetal lethality, cleft palate and multiple visceral malformations [see Animal Data].

#### Data

##### Animal Data

Topical ocular administration of 0.15% dexamethasone (0.75 mg/kg/day) on gestational days 10 to 13 produced embryofetal lethality and a high incidence of cleft palate in a mouse study. A daily dose of 0.75 mg/kg/day in the mouse is approximately 5 times the entire dose of dexamethasone in the DEXTENZA product, on a mg/m<sup>2</sup> basis. In a rabbit study, topical ocular administration of 0.1% dexamethasone throughout organogenesis (0.36 mg/day, on gestational day 6 followed by 0.24 mg/day on gestational days 7-18) produced intestinal anomalies, intestinal aplasia, gastroschisis and hypoplastic kidneys. A daily dose of 0.24 mg/day is approximately 6 times the entire dose of dexamethasone in the DEXTENZA product, on a mg/m<sup>2</sup> basis.

### 8.2 Lactation

Systemically administered corticosteroids appear in human milk and could suppress growth and interfere with endogenous corticosteroid production; however the systemic concentration of dexamethasone following administration of DEXTENZA is low [see Clinical Pharmacology (12.3)]. There is no information regarding the presence of DEXTENZA in human milk, the effects of the drug on the breastfed infant or the effects of the drug on milk production to inform risk of DEXTENZA to an infant during lactation. The developmental and health benefits of breastfeeding should be considered along with the mother's clinical need for DEXTENZA and any potential adverse effects on the breastfed child from DEXTENZA.

### 8.4 Pediatric Use

Safety and effectiveness in pediatric patients have not been established.

### 8.5 Geriatric Use

No overall differences in safety or effectiveness have been observed between elderly and younger patients.

## 17 PATIENT COUNSELING INFORMATION

Advise patients to consult their eye care professional if pain, redness, or itching develops.

**Ocular**  
Therapeutix™

Ocular Therapeutix, Inc.  
Bedford, MA 01730 USA  
PP-US-DX-0360



**Support the Education  
of Future Healthcare &  
Eyecare Professionals**

# THE RICK BAY FOUNDATION

*for Excellence in Eyecare Education*

Scholarships are awarded to advance the education of students in both **Optometry** and **Ophthalmology**, and are chosen by their school based on qualities that embody Rick's commitment to the profession, including integrity, compassion, partnership and dedication to the greater good.

## INTERESTED IN BEING A PARTNER WITH US?

[www.rickbayfoundation.org](http://www.rickbayfoundation.org)

*(Contributions are tax-deductible in accordance with section 170 of the Internal Revenue Code.)*

## ABOUT RICK

Rick Bay served as the publisher of *The Review Group* for more than 20 years.

To those who worked for him, he was a leader whose essence was based in a fierce and boundless loyalty. To those in the industry and the professions he served, he will be remembered for his unique array of skills and for his dedication to exceeding the expectations of his customers, making many of them fast friends.



THE RICK BAY FOUNDATION  
*for Excellence in Eyecare Education*

*(The Rick Bay Foundation for Excellence in Eyecare Education is a nonprofit, tax-exempt organization under section 501(c)(3) of the Internal Revenue Code.)*



## SHARE YOUR THOUGHTS

Letters are welcome. Write to:  
[editor@reviewofoptometry.com](mailto:editor@reviewofoptometry.com).

*Submissions may be edited for length, content or clarity.*

the PRS was updated in October 2021 with refinements in its calculation due to identification of a fewer number of more prevalent variants (common variants), making the test more refined in the information it generates. Ethnicity differences were also accounted for in variant selection in the new version; therefore, ethnicity details are no longer required to estimate individual polygenic risk score, as they were in the calculation.

Last, with complex genetic diseases, correlation is not causation. A high PRS for a given disease may never see the disease manifest and vice-versa. This is due to the interplay between genetic risk factors and environment/lifestyle. Likewise, someone with a low PRS may experience a given disease, as their lifestyle and other environmental factors may trigger the disease due to non-genetic causes.

This is where using our current clinical skill set to detect conditions such as keratoconus—including refractive error analysis, slit lamp examination, keratometry, topography, tomography, as well as the knowledge and skill of the eyecare practitioner (ECP)—play a crucial role in patient care. A genetic test should never be used in isolation or as the stand-alone diagnostic method for monogenic or polygenic diseases.

A resource for ECPs is the availability of genetic counselors, who can further help interpret results of a patient's genetic test, including PRS, and provide additional guidance, such as helping determine if it is appropriate to test family members. Avellino provides this service for both ECPs and patients.

Genetic testing is a valuable data source for the medical community, with the eyecare field being no exception. While we may be in the early stages of this journey, patients can benefit now from our collective expertise and knowledge of the human genome.

*Mile Brujic, OD, is a practicing doctor at Premier Vision Group in Bowling Green, OH. He provides consulting services to Avellino.*

*Sarvari Panchumarthi, PhD, is a molecular geneticist with more than 20 years of research experience in various subdisciplines of genetics, in particular the genetics concerning cancer, cardiovascular, neurological and ophthalmological disorders.*

## Progress Toward Answers is Welcome—But Questions Remain

By Brian Chou, OD

Offer my thanks to Drs. Brujic and Panchumarthi for their interest in my report. Their explanation about the unusual AvaGen results I received provides insight and also raises new questions.

Still left unanswered: what is the explanation for the same keratoconus subject's identified risk genes getting reported as different each of the three times AvaGen was run? The revised polygenic scoring implemented in October 2021 may explain the subject's higher polygenic risk score of 61 vs. the prior PRS values of 9 and 22. However, the KCN-associated gene profiles themselves changed from test to test. Was this also a function of the update to the PRS algorithm? In other words, were the same genetic variants detected in all three tests but reported differently to reflect updates to the PRS algorithm?

I wonder, too, if other clinicians using AvaGen were notified of the scoring change. I learned of this by reading the companion sidebar Q&A to my own report. Due to the potentially high stakes of medical testing, future modifications to the PRS algorithm should include contemporaneous proactive notice to ECPs, not notice after the fact.

I agree that the test-retest PRS change from 9 to 22 would not have

altered clinical decision-making, as both values were within AvaGen's "low risk" category; even so, how would a clinician interpret a test-retest PRS change of the same increment, if for instance the PRS shifted from 22 to 35, thereby moving into the "moderate" risk category?

Although high analytical validity is requisite and expected for CLIA certification, it does not inform the ECP, nor patient, about the more important clinical validity and utility.

I look forward to Avellino and others elucidating these areas. A pure genetic test for keratoconus that is clinically valid and useful is welcome, even if epigenetics plays a notable role.

*Dr. Chou practices at ReVision Optometry, a referral clinic for keratoconus and scleral lenses in San Diego. He is a past recipient of the National Keratoconus Foundation's Top Doctor award.*

## Is the Joy in Cataract Surgery Fading?

By Don Stover, OD

Cataract surgery 40 years ago meant two months post-op of branded Pred Forte 1% QID, no NSAID and a week of antibiotics. There were limited cases of cystoid macular edema (CME) because it was an all-surgical procedure with no phacoemulsification. High astigmatism (above three diopters) was common, but patients—typically with 20/20+ corrected acuity—did not complain and strangely did not wear their glasses as much as would be predicted. Their color vision was exceptional for the rest of their lives.

Then phaco started and best-corrected vision was reduced to 20/25 or 20/30—explained wrongly as corneal edema, but it really was macular damage. Color vision was commonly the same before surgery as afterwards.

Even though the resultant refractive error was almost devoid of astigmatism, patients were wearing their glasses more, not less. Simultaneously, there were improvements in phaco and pharmaceuticals, such as the addition of NSAIDs, stronger steroids and better injectable drugs for dilation during surgery. Meds that worked just as well once a day became available. Good acuity and improved color vision were now possible again.

But then the economics of cataract surgery changed. Reimbursement was cut from \$1800 to the present-day rate of roughly \$550. The post-op treatment course went from two months to no more than three weeks. For 30 years, attempts were made to use intracameral injectable medication to eliminate or at least minimize drop use after surgery. Recently reintroduced, this no-drop cataract surgery still poses some problems, such as visual or anatomic concerns at the one-year follow-up visit, which suggest an insufficient post-op regimen.

An article was published stating that post-op cataract surgery meds could be taken five minutes apart and still would work as well, despite known differences between generic and branded products, such as lower dosages and different corneal penetration rates. Unfortunately, most patients are told now to take post-op drops five minutes apart.

Also, recent changes in the availability of steroid medications have taken place. Inveltys, a higher concentration, better-penetrating form of loteprednol, seems to have overtaken use of high-potency Durezol or generic prednisolone as a popular treatment for the shortened three-week post-op period. There should be less elevated pressure from steroid responders. This isn't quite true, because loteprednol still causes IOP spikes, as does prednisolone, at three to four weeks in some patients. Durezol almost never has those high pressure spikes in the first two days after surgery if used in BID dosage. I continue to recommend Durezol BID for six weeks and QD for two weeks for cataract surgery patients, and I don't see CME.

More commonly, what we have now with post-op cataract care is a soft steroid used for three weeks, the NSAID Prolensa perhaps used QD and some kind of antibiotic for a week to 10 days.

The one-year visit tells the story. The patients with fewer post-op meds want glasses, even though the refractive error is minimal, because they are having trouble seeing. Their color vision did not improve much after surgery; it should have. Those patients that used longer and stronger steroids and BID dosing for Prolensa don't want glasses at the one-year visit, stating that their color vision is significantly better even if they had pre-existing dry AMD.

“ I miss what cataract surgery was just a few years ago. The patients from those days still come in and can't believe how good their vision is. ”

Another factor comes into play for optometry practices in rural America. Many of our patients have to travel out of town to get surgery. If they are seen by the surgeon for the one day post-op, that means the patient travels on a bumpy highway for a couple of hours, counting the day of surgery and the one-day follow-up back and forth. We've had patients stay overnight in the town where they had surgery and their acuity is always a couple of lines better in the first few days after surgery.

Also, use of 1% cyclogyl right after surgery resulted in a dilated but 20/20-acuity at the one day post-op. Failure to use cyclogyl for the drive home yielded vision of 20/25 or 20/30 almost always at the one-day post-op. If a surgeon counts seconds of phaco time, they should also count how many miles that patient has to drive in to get surgery and follow-up.

In 2020, the cataract surgeon I used for 14 years retired; it was a sad day. In my small optometry practice, sometimes two patients a day were referred there for cataract surgery.

I think “optometry-referred” cataract surgery patients are different. They

often have to travel, and thus need the extra cyclogyl drop and should not travel far again the day after surgery. This is the reason for letting the optometrist see patients the next day instead of the surgeon, but this is hard for most surgeons to appreciate. These patients are most likely more prone to subclinical chronic CME and thus stronger and longer post-op medications in my opinion are recommended.

There is a financial component to “optometry-referred” patients for the patient, the surgeon and the OD. Branded drugs are very costly to the patient. Thirty years ago, the pharmaceutical companies gave branded post-op meds to patients if their brand of intraocular implant was used. Now, there are no gift bags anymore and samples are hard to come by. Branded meds can cost over \$600 and the surgeon may be out of pocket for some injections used during surgery because Medicare won't allow a supply fee. Certain generic NSAIDs, when relied upon at the expense of better anti-inflammatories, may even cause CME.

Then there is the cost of seeing cataract patients for two months. I generally see them for three visits if I see the patient on the first day post-op. I generally don't make money on post-op visits. Wouldn't it be nice if cataract surgery was one fee and the post-op care was another fee? This might support better post-op care.

I must say cataract surgery is quite remarkable. Most surgeons do a very good job; if anything, there continue to be improvements in the surgery itself.

All I know is that I miss what cataract surgery was just a few years ago. The patients from those days still come in and can't believe how good their vision is and what a miracle cataract surgery is. They don't want glasses and color vision is excellent. The more recent cataract surgery patients now want to buy glasses. I should be happy, but I'm really not. I want to be part of the miracle that cataract surgery was again.

*Dr. Stover, a 1981 graduate of University California Berkeley Optometry School, practices in Porterville, CA.*

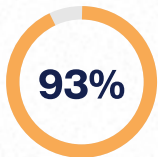
MacuHealth has Micro-Micelle™ Technology,\* offering the **highest bioavailability** of any eye supplement

Sight backed by **science.**

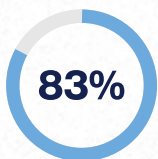
The numbers behind MacuHealth's patented Triple Carotenoid Formula speak for themselves:



**Response rate** at both serum and target tissue in independent studies<sup>1</sup>



Of participants experienced **improved vision** in low-light conditions<sup>2</sup>

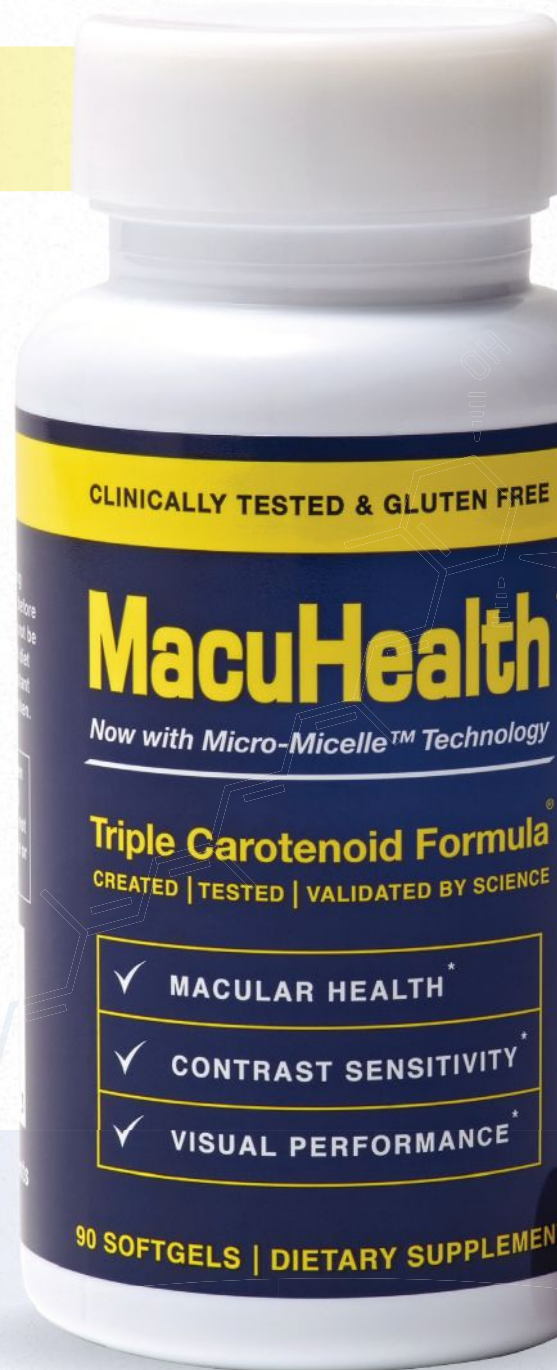

Of those with **early AMD symptoms** experienced increased contrast sensitivity after 24 months<sup>3</sup>

## RECOMMENDED BY OPTOMETRISTS

MacuHealth's patented Triple Carotenoid Formula features Lutein, Meso-Zeaxanthin and Zeaxanthin, essential to reducing the progression of AMD and protecting eyes from oxidative stress.

ACTUAL SIZE



\*Micro-Micelle™ Technology delivers the highest bioavailability studied to date. Compared to standard macular carotenoid supplements, MacuHealth's formula produced an average 6x higher serum response and 1.5x retinal response over a six-month supplementation period.<sup>1</sup>

References: 1. Green-Gomez et al. 2020. 2. Akuffo et al. 2017. 3. Nolan et al. 2016. © 2022 MacuHealth. All rights reserved.



Meet the complete family of products at [MacuHealth.com](https://MacuHealth.com)

**MacuHealth**®



Founded 1891  
Founding Editor, Frederick Boger

EDITOR-IN-CHIEF  
**JACK PERSICO**  
(610) 492-1006 • jpersico@jobson.com

SENIOR EDITOR  
**JULIE SHANNON**  
(610) 492-1005 • jshannon@jobson.com

SENIOR ASSOCIATE EDITOR  
**CATHERINE MANTHORP**  
(610) 492-1043 • cmanthorp@jobson.com

SENIOR ASSOCIATE EDITOR  
**MARK DE LEON**  
(610) 492-1021 • mdeleon@jobson.com

ASSOCIATE EDITOR  
**LEANNE SPIEGLE**  
(610) 492-1026 • lspiegle@jobson.com

SPECIAL PROJECTS MANAGER  
**JILL GALLAGHER**  
(610) 492-1037 • jgallagher@jobson.com

SENIOR ART DIRECTOR  
**JARED ARAUJO**  
(610) 492-1032 • jaraujo@jobson.com

DIRECTOR OF CE ADMINISTRATION  
**REGINA COMBS**  
(212) 274-7160 • rcombs@jobson.com

#### Clinical Editors

Chief Clinical Editor • Paul M. Karpecki, OD

Associate Clinical Editors  
Joseph P. Shovlin, OD, Christine W. Sindt, OD

Clinical & Education Conference Advisor  
Paul M. Karpecki, OD

Case Reports Coordinator • Andrew S. Gurwood, OD

#### Columnists

*Chairside* – Montgomery Vickers, OD

*Clinical Quandaries* – Paul C. Ajamian, OD

*Cornea and Contact Lens Q+A* – Joseph P. Shovlin, OD

*Diagnostic Quiz* – Andrew S. Gurwood, OD

*The Essentials* – Bisant A. Labib, OD

*Focus on Refraction* – Marc Taub, OD, Pamela Schnell, OD

*Glaucoma Grand Rounds* – James L. Fanelli, OD

*Ocular Surface Review* – Paul M. Karpecki, OD

*Retina Quiz* – Mark T. Dunbar, OD

*Surgical Minute* – Derek Cunningham, OD, Walter Whitley, OD

*Therapeutic Review* – Joseph W. Sowka, OD

*Through My Eyes* – Paul M. Karpecki, OD

*Urgent Care* – Alison Bozung, OD

#### Editorial Offices

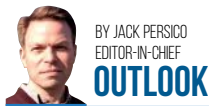19 Campus Blvd., Suite 101 • Newtown Square, PA 19073



Jobson Medical Information/WebMD  
395 Hudson Street, 3rd Floor, New York, NY 10014

Subscription inquiries: (877) 529-1746  
Continuing Education inquiries: (800) 825-4696

Printed in USA



BY JACK PERSICO  
EDITOR-IN-CHIEF

## OUTLOOK

# Upstairs, Downstairs

*The medical/optical dichotomy of optometry was on display once again at Vision Expo East.*

In New York earlier this month for Vision Expo East, one morning I shared a cab over to the Javits Center with a coworker from the division of our company that produces *20/20* and *Vision Monday*, both fixtures of the retailing world of eye care.

The cabbie asked us what was happening at the Javits. “It’s an optical show,” my colleague said, not incorrectly. But his framing (no pun intended, I swear) of the conference around eyewear products surprised me. Had I been riding solo that day, I likely would have said, “It’s a meeting for eye doctors.”

And there in a nutshell lies the somewhat schizophrenic identity of optometry.

We all bring our own priorities to our day-to-day experiences, and I’ll be the first to admit that mine are on the medical aspects of eye care. But of course optical products are a huge driver of practice success and, furthermore, probably still the one aspect of eye care the public mostly associates with optometry. Still, it can be odd to see these elements sometimes manifest not merely as two halves of one whole but as entirely different events.

Walking the show floor with a newer editorial colleague on the *Review* team, in town for her first Vision Expo East, I wryly pointed out that, as usual, the stuff we came to see was “in the basement.” For as long as I can remember (my first VEE was in 1992), the layout of the conference puts retail exhibitors in the spacious upstairs showroom and the med/pharma events in the windowless bottom hall. A fan of British costume dramas, I notice this *Upstairs, Downstairs* feel of the place every year.

That show, like the more recent *Downton Abbey*, chronicled the lives of a wealthy family and their staff, each with their own living quarters. Now, don’t get me wrong: I’m *not* saying the medically minded attendees are treated like lesser participants. But VEE does often feel like two separate lives being lived in the same house. That’s likely inevitable, given the high attendance by dispensary staff there.

Opticians and dispensing professionals comprise a huge contingent of the attendees, as it should be. They’ll always want and need to know all about the latest trends in frames and lenses. Vision Expo, like its precursor OptiFair, has always been one of the premier outlets for the retail and dispensing side of eye care. A meeting with deep roots in the multibillion-dollar optical industry owes nothing to the medical side of optometry; if they wanted to hold a purely retail event, it would be justifiable and probably highly successful. But it wouldn’t wholly reflect what optometry is today.

The organizers are to be commended for investing in the optometric CE side in recent years. The addition of education co-chairs Mark Dunbar and Ben Gaddie several years ago made medical topics a much bigger priority, and these two exceptional ODs once again put together an outstanding program this year. We shared dozens of excellent clinical insights from the optometric program through live coverage in our Twitter feed and other social media outlets during the meeting.

I learned a lot at VEE this year and it’ll be put to good use in these pages. Next year, I’d like to spend a little more time upstairs. ■

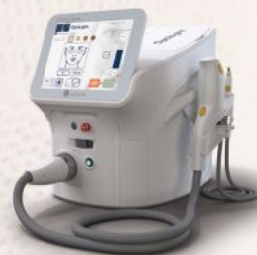Doctors,  
grow your  
practice with  
OptiLight  
for dry eyes.

Mandy Moore

## OptiLight | A Bright Solution for Dry Eyes

Introducing OptiLight by Lumenis, the first and only light therapy for dry eye disease management. OptiLight with patented OPT™ technology is a quick, in-office treatment that can elevate and scale your practice while significantly improving your patient's signs of dry eyes.

**Visit our website to learn more.**



[information.lumenis.com/optilight](https://information.lumenis.com/optilight)

Copyright © 2021-2022 Lumenis Be Ltd. All Rights Reserved  
PB-00043050 Rev A

Visit our website  
to learn more







BY PAUL M. KARPECKI, OD  
CHIEF CLINICAL EDITOR

## THROUGH MY EYES

# Cornea Cornerstone

*How to properly manage this important part of optometric care.*

**W**hile we manage all aspects of primary eye care, what sets us apart as a profession is managing cornea and external disease. Fortunately, the cornea requires little extra equipment beyond our slit lamp to visualize pathology effectively. Consider the opportunities ranging from dry eye disease, epithelial basement membrane dystrophy/recurrent corneal erosion and Fuchs' dystrophy to keratoconus, abrasions, foreign bodies and numerous forms of keratitis—just to name a few!

## Dry Eye Disease

It's essential to differentiate the type of dry eye first; otherwise, your treatment strategy isn't likely to work. Expression of the meibomian glands can be done in two to five seconds with an expression paddle. Abnormal expression will indicate an evaporative dry eye. In contrast, normal meibomian gland expression with significant corneal staining (using NaFI dye) and a thin meniscus will indicate an aqueous-deficient dry eye. Keep in mind that the location of the stain is critical—inferior stain will indicate incomplete overnight lid closure or potentially lagophthalmos.

NaFI dye will also aid in the visualization of a foreign body, papillae, conjunctival staining, conjunctivochalasis, limbal stem cell deficiency, persistent epithelial corneal defects, abrasions and corneal ulcers.

## Corneal Foreign Body Removal

When managing corneal foreign bodies, begin with visual acuity testing followed by a slit lamp examination

and determine the location, depth and possible material you are dealing with. Rule out an infiltrative process in the cornea indicative of a secondary infection. Observe the anterior chamber for cell and flare. Next, place NaFI dye in the eye to help find the foreign body and always evert the upper eyelid.

“  
While we manage all aspects of primary eye care, what sets us apart as a profession is managing cornea and external disease.  
”

Determining the depth is critical and using a slit beam will help you see how far into the cornea it has penetrated. If there is no risk of intraocular foreign bodies, intraocular pressure assessment will confirm and you can begin working on removal. Consider using a 30-gauge needle—which is beveled—and keep the bevel toward the cornea to lift the foreign bodies (sterile jeweler's forceps can also be used). This is especially helpful for a metallic foreign body. Be sure to remove significant residual rust in the cornea with an Alger brush. An antibiotic drop should be instilled and prescribed until the epithelium is healed. Corticosteroids may need to be considered after re-epithelialization if significant inflammation and/or an anterior chamber reaction is noted.

## The Evolution of Crosslinking

There are two potential future treatments. The first involves a scleral lens

with a built-in transducer that emits UV light. The scleral lens bowl is filled with riboflavin solution and placed on the cornea, and the patient wears the lens, which is hooked up to a machine that administers the light treatments.

The second, soon to enter Phase III FDA clinical studies, involves lysyl oxidase, a substance that is deficient in patients with keratoconus. Phase IIb trials with drops containing this ingredient show a decrease of 1.8D in K values, which is technically a greater response than currently approved corneal crosslinking options.

## Herpes Zoster Ophthalmics (HZO)

Optometry is seeing more of these cases and we have to be prepared to manage these patients. Although the cornea is heavily involved, with signs ranging from pseudodendrites to eventual neurotrophic keratitis and lipid keratopathy, the most common sign of HZO is iritis. Since this is a systemic disease with ocular manifestations, the primary therapy is oral antivirals. I prefer valacyclovir 1000mg three times a day for 10 to 14 days.

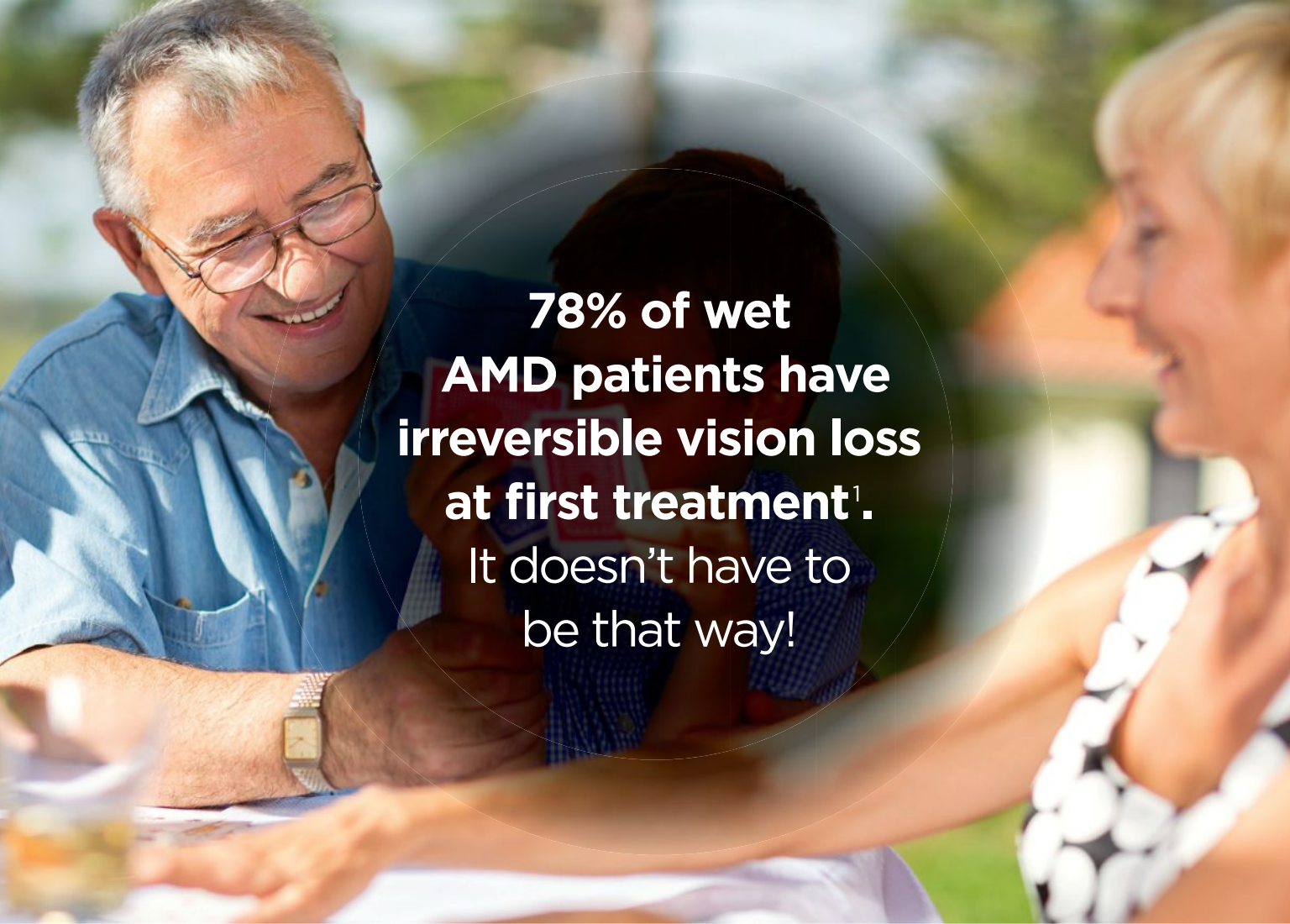
Additionally, treat the ocular inflammation early with potent topical steroids to prevent corneal scarring and quiet the uveitis. Tapering can occur over six weeks and you may need to maintain a prophylactic dose of oral valacyclovir of 1000mg once a day. Also consider ophthalmic gel Zirgan (Bausch + Lomb) five times per day for a week followed by three times a day for a week when the cornea is involved. This aggressive management will help spare vision loss.

The cornea is a comfortable place for optometry. Keep your skills up and gain confidence as you work on a structure that is readily visible and will make a difference for you and your patients in this cornerstone of optometric care. ■

About  
Dr. Karpecki

Dr. Karpecki is the director of Cornea and External Disease for Kentucky Eye Institute, associate professor at KYCO and medical director for Keplr Vision and the Dry Eye Institutes of Kentucky and Indiana. He is also chair of the New Technologies & Treatments conferences. He consults for a wide array of ophthalmic clients, including ones discussed in this article. Dr. Karpecki's full disclosure list can be found in the online version of this article at [www.reviewofoptometry.com](http://www.reviewofoptometry.com).



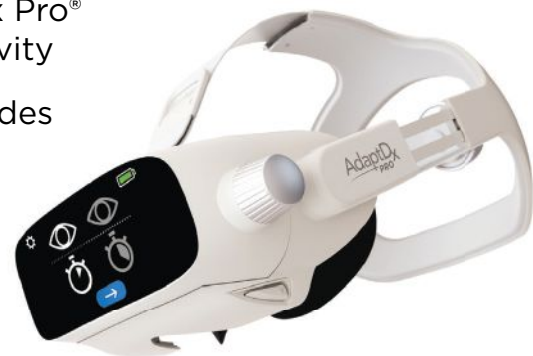

**78% of wet  
AMD patients have  
irreversible vision loss  
at first treatment<sup>1</sup>.**  
It doesn't have to  
be that way!

## Diagnose and Manage AMD with Confidence

- Dark Adaptation testing with the AdaptDx Pro<sup>®</sup> helps you diagnose AMD with 90% sensitivity
- A single number, the Rod Intercept<sup>®</sup>, provides a functional assessment of retinal health
- Monitor disease progression to make a timely referral to a retina specialist
- Reimbursable CPT code 92284

**AdaptDx<sup>®</sup>**  
**PRO<sup>™</sup>**  
*Guided by Theia<sup>™</sup>*



**We're on a mission to eliminate blindness caused by AMD and invite you to join us!**

<sup>1</sup>Olsen TW, Feng X, Kasper TJ, Rath PP, Steuer ER. Fluorescein angiographic lesion type frequency in neovascular age-related macular degeneration. *Ophthalmology*. 2004;111(2):250-255. doi:10.1016/j.ophtha.2003.05.030.



# Can You Handle the Truth?

*Recognize what's real—and what's not.*

Is there such a thing as truth? I was brought up by Betty and Earl to believe there is. Oh, yes, my parents, coincidentally also named Betty and Earl, thought so too, but I'm talking about Betty and Earl down at the drive-in. Betty and Earl knew that if someone came to the drive-in, they would probably want a couple of hot dogs and some popcorn, and you could hang your hat on that, my friends.

So, having been taught that there is truth to certain things, I am concerned that optometry and optometrists might be living in a haze rather than clearly seeing the truths in our profession that we can count on no matter what. Here are some truths in optometry:

**1. People want to have good vision.**

You cannot hurt somebody if you help them see better. I know we can all give examples of folks who come in at 20/50 and say, "I'm just here for a checkup. My eyes are fine." What about them, you may ask? I think we can make them see 20/20, but we cannot make them improve upon their 20/200 brain. Still, they do actually want to see.

**2. Each exam has an endpoint.**

Of course, sometimes the endpoint is that we just cannot help the patient. Not everyone can choose which is better, number one or number two. For some folks, the endpoint is the wilderness, not the mountaintop. Let them continue to wander visually until they decide where to make camp. Personally, I love when a patient comes in with a bag of glasses from 10 different eye doctors, none of whom are any good at optometry. My goal shifts to not being the dumbest doctor in the bag. If you

make the patient be the boss of their own eyeballs, they will never rank you lower than the fifth dumbest eye doctor in the bag. Now *there's* an endpoint for you.

**3. Consulting online reviews is no way to run a practice.** Patients who gripe online are not your best practice consultants. People who harass you online also harass everybody they ever meet online. Do your best to help them receive the care they need from the ophthalmologist who disrespects optometry the most. Karma.

**4. People care about your appearance.** I am living proof that you don't have to be pretty to be successful in optometry, but wearing a clean shirt is not a bad move. Don't leave home without it. Oh, and bathe. You know who you are. Yes, I am talking about you.

**5. It's okay to drive a cool car.**

I know doctors who own a tricked-out, luxurious car but have an old beater they drive to work because they are afraid the patient will think they are just there to make money. (1) There is nothing wrong with making money. Your patients make money too, right? (2) If somebody is messing with my eye, I want them to drive a nice vehicle. That means they see lots of patients. And, taking it even further, if somebody is doing my heart bypass, I want them to

be driving a gold-plated Bentley with a personalized license plate that reads, "BSTHRTDR."

**6. You cannot save your staff from their choices.** I spent my early years trying to make my staffers better and happier. This did not work. But when I changed my approach to make them better employees, they automatically became better and happier or they hit the road, which also, I think, helped them be better and happier while simultaneously making me better and happier. If you want your staffers to make the right choices on the weekend, spend time teaching them to make the right choices in your office.

**7. You must accept you aren't perfect.** If you do, then you are actually perfect after all. Yes, you will blunder through more often than you will ever know. Welcome to humankind. Wanna be perfect? Ask your spouse how to do it.

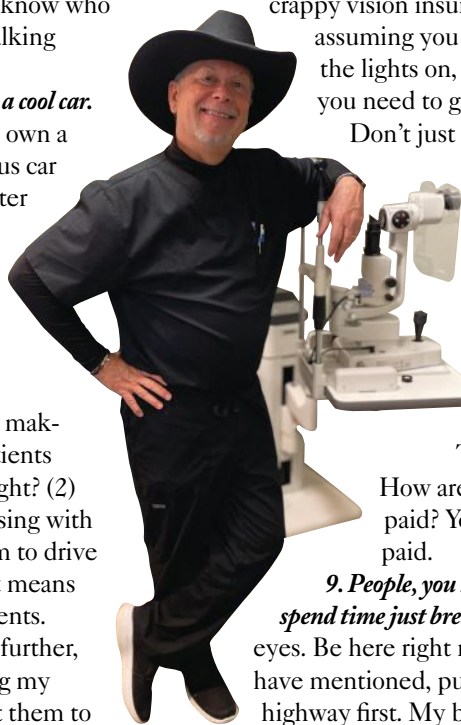
**8. You need to get paid.** I know, 50% of your townspeople are covered by a crappy vision insurance plan. Still, assuming you would like to keep the lights on, then, obviously, you need to get paid. It's okay.

Don't just blindly accept a plan that puts you deeper in the hole with every patient. My goal has always been to charge a million dollars per exam and see one patient a year.

Think. Reconsider.

How are you going to get paid? You need to get paid.

**9. People, you have to stop and spend time just breathing.** Close your eyes. Be here right now. Oh, I should have mentioned, pull your car off the highway first. My bad. ■



**About Dr. Vickers**

Dr. Vickers received his optometry degree from the Pennsylvania College of Optometry in 1979 and was clinical director at Vision Associates in St. Albans, WV, for 36 years. He is now in private practice in Dallas, where he continues to practice full-scope optometry. He has no financial interests to disclose.

# You're Invited

## OTC for Dry Eye: An Implementation Workshop

### What to expect:

- **Discover over the counter (OTC)** solutions for dry eye, how they work, why they work, how practices are implementing them.
- **Explore a new way to implement** OTC for dry eye relief with the Physician Guided Solutions Model.
- **Choose the method of delivery** to your patients from in-practice methods to remote methods with auto-delivery options for your patients' convenience.
- **Learn about MY OASIS™ platform** for a Dry Eye Resource Center: Solution Fulfillment, Education, Compliance

### Who Would Benefit from Attending:

- Optometrist
- Ophthalmologist
- Key Practice Coordinators/Planner
- Office Manager
- Front office team member
- Dry eye team

**Commitment:** 1.5 hour workshop



Also Available on MY OASIS™ Platform.

Call To Order: (844) 820-8940  
Also Available on MY OASIS™ Platform.



[www.oasismedical.com](http://www.oasismedical.com)  
[customerservice@oasismedical.com](mailto:customerservice@oasismedical.com)

Scan to Schedule  
a Workshop







EDITED BY PAUL C. AJAMIAN, OD

## CLINICAL QUANDARIES

# Assuming the Worst

Careful observation and history taking is paramount when evaluating a swollen eyelid.

**Q** A patient presents to me with a significantly swollen left upper lid. What are the next steps?

**A** While there are plenty of possible causes of swollen eyelids, the first that comes to mind is preseptal cellulitis. “While this is the most probable, we must always keep the differential with the highest chance of morbidity or mortality in mind,” says Mark Miriello, OD, of The Eye Institute in Philadelphia. “With swollen eyelids, that is orbital cellulitis.”

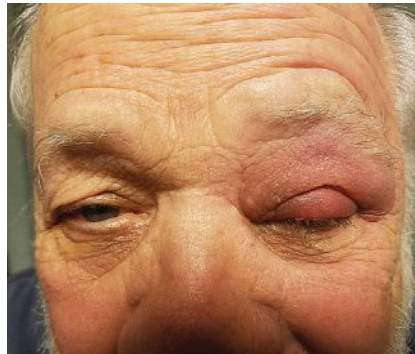Other differentials to consider involve severe anterior segment inflammation such as viral conjunctivitis, corneal abrasion and even uveitis. Taking a careful symptom inventory and thorough slit lamp examination can help rule these differentials out.

### Trace the Source

The orbital septum is a shield of fibrous tissue that acts as a barrier between the eyelids and the orbit itself. Preseptal cellulitis, then, is a bacterial infection of the skin—effectively isolated to the eyelids.<sup>1,2</sup>

Patients present with swollen, red lids that may be tender to the touch and febrile. Since the inflammation is confined to the eyelid, they present with unaffected vision, ocular motility and pupils and without proptosis.<sup>1,3</sup>

The source of the infection is often a result of other infectious eyelid lesions. Sinusitis, particularly of the ethmoid sinus, is a common culprit. Other routes of infection include superficial facial traumas and surgeries, foreign bodies and insect bites.<sup>1</sup>



A patient with preseptal cellulitis who responded well to oral antibiotics.

When taking history, determine if the patient is at risk for any of these etiologies. “Ask about precipitating styes, traumas and sinus infections,” Dr. Miriello says. “If the patient can localize the part of the lids where their symptoms first presented, pay special attention there during slit lamp examination.”

Preseptal cellulitis treatment involves oral antimicrobial therapy. With gram-positive cocci, such as *Staphylococcus* and *Streptococcus* species, being the most common causative organisms, select antibiotics accordingly.<sup>1</sup> Keflex (cephalexin, Advancis Pharmaceutical) is a great choice and is commonly dosed 500mg PO BID for adults.<sup>3</sup> This dosage is well tolerated and can be safely taken up to QID.<sup>4</sup>

Dr. Miriello prefers the more frequent dosing so he never has to wonder if a persistent case would have responded better. The treatment course can range from seven to 10 days, depending on the severity of the initial presentation.<sup>1</sup>

### Check Motility

Orbital cellulitis occurs when these infections gain access to the orbit itself. While these patients may look preseptal, there are several symptoms and signs that readily set this more serious orbital infection apart. Look for some degree of ophthalmoplegia and pain with eye movement due to inflammatory infiltration of the extraocular muscles, Dr. Miriello says. Exophthalmometry is also recommended, since ipsilateral proptosis signals likely orbital involvement.<sup>1,3,5</sup>

As the disease progresses and the retrobulbar optic nerve becomes involved, visual acuity, color vision and pupillary reactions can become affected. Untreated orbital cellulitis may also result in orbital abscesses, cavernous sinus thrombosis or even intracranial extension of the infection, which can be deadly.<sup>1,3,5</sup>

Orbital cases may stem from preseptal ones if timely treatment is not initiated. Sinusitis is overwhelmingly the most common cause. Others include the spread of dental and middle ear infections, infected adnexal injection sites and traumas or surgeries that allow access to the orbit.<sup>1,5</sup>

“These patients require intravenous antibiotics and hospitalization, so prompt referral is crucial when you suspect orbital involvement,” Dr. Miriello says. Multidisciplinary management can greatly improve outcomes.<sup>1,3,5</sup> ■

1. Lee S, Yen MT. Management of preseptal and orbital cellulitis. *Saudi J Ophthalmol*. 2011;25(1):21-9.

2. Rimon A, Hoffer V, Prais D, et al. Peri-orbital cellulitis in the era of *Haemophilus influenzae* type B vaccine: predisposing factors and etiologic agents in hospitalized children. *J Pediatr Ophthalmol Strabismus*. 2008; 45(5):300-4.

3. Lim LT, Miller D, Ah-Kee EY, Ferguson A. Preseptal cellulitis or orbital cellulitis? *West Indian Med J*. 2015; 65(2):304-7.

4. Rodríguez-Uña I, Bañeros-Rojas P, Jiménez C, Díaz-Valle D, Gegúndez-Fernández J, Benítez-del-Castillo J. Systemic antibiotics with ophthalmic clinical usefulness. In: Benítez-del-Castillo J, Díaz-Valle D, Gegúndez-Fernández J, eds. *Ocular Pharmacotherapy*. Jaypee Brothers Medical Publishers; 2017:93-110.

5. Danishyar A, Sergent SR. Orbital Cellulitis. *StatPearls [Internet]*. Treasure Island, FL: StatPearls Publishing; 2021.

About Dr. Ajajian

Dr. Ajajian is the center director of Omni Eye Services of Atlanta. He currently serves as general chairman of the education committee for SECO International and is vice president of the Georgia State Board of Optometry. He has no financial interests to disclose.

BEFORE

AFTER

  
**LASTACRAFT**

**SAME Rx STRENGTH  
AVAILABLE OTC THIS SPRING**

FOR PATIENTS WITH ITCHING DUE TO ALLERGIC CONJUNCTIVITIS



**FAST-ACTING:** Effective at 3 Minutes

**LONG-LASTING:** One Drop Lasts All Day\*

- Works against common allergens: pet dander, pollen, grass, and ragweed
- For ages 2+
- 2x the amount per bottle than the leading brand†

\*Lasts 16 hours

†Compared to the leading Once Daily Eye Allergy Itch Relief brand

IT'S **LASTACRAFT**® SEASON  
[lastacraft.com/doc](http://lastacraft.com/doc)

© 2022 AbbVie. All rights reserved. All trademarks are the property of their respective owners.  
US-LAS-220057 02/22

 **Allergan**  
an AbbVie company

# CLINICAL PEARLS IN CORNEAL FOREIGN BODY REMOVAL

How to properly identify, treat and manage patients with this ocular trauma.



BY BRIDGET HENDRICKS, OD  
WORCHESTER, MA

It's a typical afternoon in your practice and a 35-year-old male presents with the following complaint: "I was installing shelves in my home a few days ago and I think I got something in my eye." He mentions that he could see something dark gray on his eye when he looked in the mirror. He tried to rinse it out, but it wouldn't budge—now the eye is red and painful.

Ocular foreign bodies are a common form of ocular trauma, accounting for approximately 40% of all such traumas and leading to about 2% of all emergency room visits.<sup>1</sup> Patients' symptoms can vary widely depending on the nature and timing of the foreign body injury.

Regardless of your practice mode, most of us have encountered situations similar to this. But what is the best way to proceed? In

this article, we will review how to evaluate, treat and manage patients with an ocular foreign body, as well as provide helpful clinical pearls for successful removal.

## #1: TAKE A THOROUGH PATIENT HISTORY

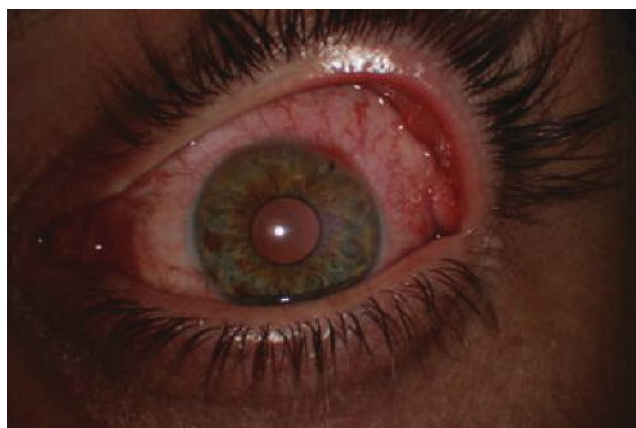A proper detailed history of the patient will help guide your examination, determine the type of prophylactic care needed as well as provide documentation for any workers' compensation or other legal issues that may be associated with the

incident. The case history should be problem-focused with an emphasis on what, when, where and how.

- Ask *what* the foreign body is. Knowing the kind of material involved can help give you an idea of the risk for infection and guide your decision-making on the type of postoperative treatment that may be indicated. Organic or vegetative materials are associated with a higher rate of infection. Metallic materials are likely to result in a rust ring. Inert materials (*i.e.*, glass, ceramic or

high-grade plastic) tend to be non-reactive and carry less risk of an inflammatory response.<sup>3,4</sup>

- Ask *when* the injury occurred. The longer the foreign body has been in place, the higher the risk for infection, inflammation and rust formation (with metallic ferrous material). Salt present in the tears can react with the iron in metallic foreign bodies to create a corneal rust ring around the foreign body. This reaction




**Fig. 1. Preoperative slit lamp biomicroscopy of the patient's left eye shows the embedded corneal foreign body.**

### About the author

**Dr. Hendricks** is an associate professor of optometry at Massachusetts College of Pharmacy and Health Sciences (MCPHS) University School of Optometry, chief of services for the Glaucoma Clinic (The Eye and Vision Center at MCPHS) and practices at the Eye and Vision Center at MCPHS and Edward M. Kennedy Community Health Center. She completed her residency in ocular disease in the VA Boston Healthcare System and served as faculty at the New England College of Optometry before joining MCPHS University in 2017. She has no financial disclosures.





**Fig. 2. Preoperative imaging of the patient's left eye. AS-OCT shows hyper-reflectivity and shadowing due to the corneal foreign body (left). The corneal foreign body did not completely penetrate the cornea (right).**

typically begins within a few hours of the injury occurrence and can result in a complete rust ring within eight to 12 hours.<sup>5</sup>

- Ask *where* the patient was when the injury occurred. Were they at home or at work? Also ask if they were wearing safety eyewear. Proper documentation of this is important, as it could be pivotal information in workers' compensation, insurance and liability cases.

- Ask *how* the injury happened. The mechanism of ocular injury helps determine the force with which the foreign body may have entered the cornea. High-risk mechanisms include grinding, hammering, metal shaving, machine yard work and exposure to explosives.<sup>2</sup> These scenarios should raise your suspicion for possible penetrating injury and help you decide whether imaging scans are necessary.

It is also important to know the patient's previous best-corrected visual acuity (BCVA) and any other relevant ocular history. Underlying pathology, previous corneal injuries and previous surgeries can impact prognosis. Other relevant information to gather during the case history includes documentation of events or interventions since the time of the injury, date of the patient's last tetanus shot and, in the cases of suspected penetrating injury, when the patient last ate or drank should be noted to determine if intraocular surgery is indicated.

## #2: DON'T CUT CORNERS OR RUSH EXAMS

Attention to detail during foreign body removal can make the difference between successful outcomes and sight-threatening complications.

Immediately following the case history, be sure to obtain and document BCVAs before performing any procedures or instilling drops. This will determine the level of suspicion for penetrating injuries, as these injuries are associated with more significantly decreased vision. Baseline visual acuities are also important for medicolegal reasons.

For example, if the patient has amblyopia or another pre-existing condition causing reduced acuity, it is important to have documentation that the acuity was reduced prior to the procedure that you performed. This could protect you from allegations that your procedure is responsible for the patient's reduced acuity. An exception to this rule is if the patient is experiencing intense pain with blepharospasm, rendering them unable to open their eyes. In this case, a drop of topical anesthetic such as proparacaine or tetracaine may be instilled prior to visual acuity measurement.

Other entrance tests such as pupil and extraocular motility testing should be performed, as abnormalities in pupil shape (*e.g.*, a peaked iris) and limited mobility of the eye can be a sign of penetrating injury.

A thorough slit lamp exam should be performed, first without fluo-

rescein dye. Examine all structures of both eyes looking for injection, chemosis, anterior chamber cells and flare and presence of foreign bodies. Be sure to check the conjunctiva for any signs of perforation—this will appear as an area of injection and chemosis surrounding an entrance point. Always perform lid eversion to check for foreign bodies

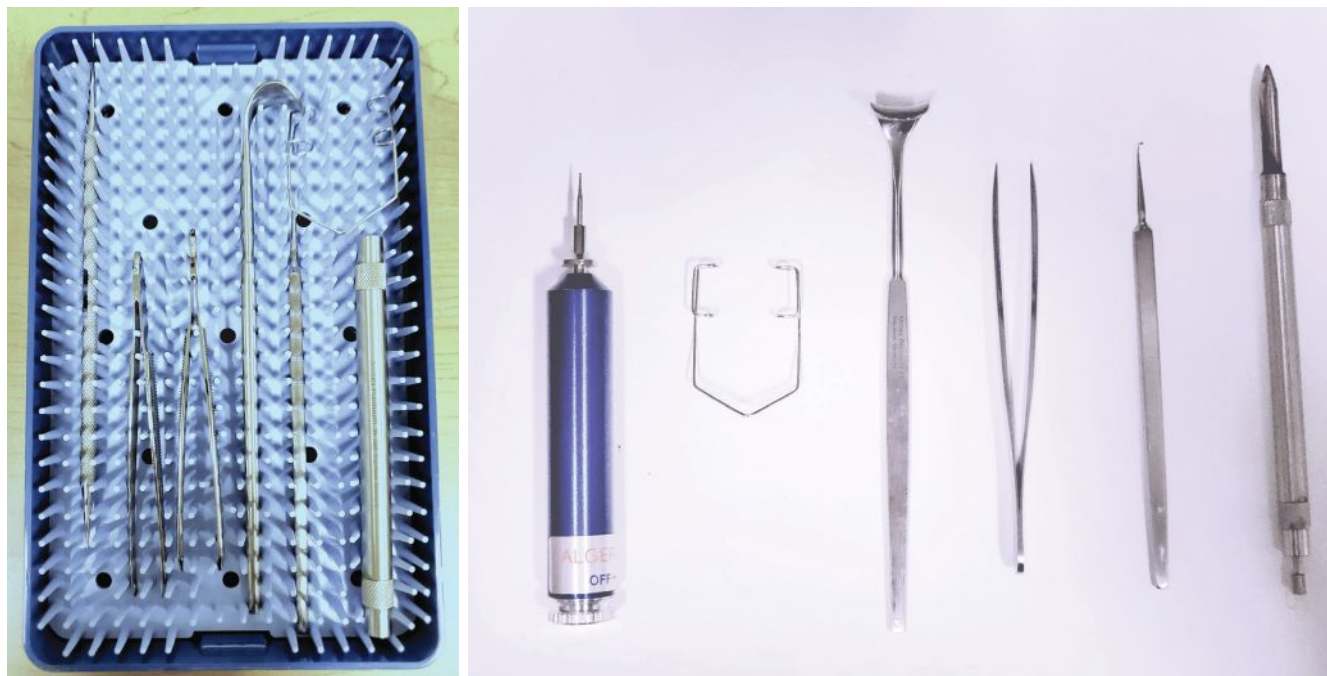
trapped under the eyelid.

After your initial scan of the ocular structures, add fluorescein dye and examine the eye using a Cobalt blue filter. Look for signs of epithelial defects, corneal abrasions or lacerations. Keep in mind that the presence of vertically oriented linear abrasions could result from foreign bodies embedded under the eyelid.

Always perform the Seidel test to help rule out globe perforation. A positive test will appear as a "dark waterfall" of aqueous leakage within the fluorescein, indicating that ocular penetration has occurred. Other signs consistent with a penetrating injury include shallow anterior chamber, hyphema, defects of the iris or pupil, a break in Descemet's membrane and lens opacities.<sup>5</sup>

As a word of caution, small foreign bodies characterized by high heat or high velocity can penetrate the globe and result in a self-sealing entry point. Such wounds may not result in a positive Seidel sign or shallow anterior chamber, but a tunnel through the cornea may be visible. In addition, there may be associated anterior uveitis. If there are any signs or suspicion of penetrating injury, apply a rigid shield (*e.g.*, Fox shield or inverted Styrofoam cup) and refer the patient immediately to the emergency department or ophthalmic surgeon for specialty evaluation and management.

Once the eye is stabilized, further investigation for retained foreign



**Fig. 3.** Foreign body removal kit (left). Instruments from left to right: Algerbrush, speculum, eyelid retractor, jewelers forceps, golf club spud and magnetic probe (right).

bodies is indicated with tests such as dilated fundus examination, gonioscopy and imaging studies. Potential imaging methods include computed tomography scans, B-Scan ultrasonography, ultrasound biomicroscopy, plain film x-rays and magnetic resonance imaging. The latter is contraindicated if suspected foreign body is metallic because it can cause migration of the object, further damaging the ocular tissues.

After you've ruled out penetrating injury and located the foreign body, determine its exact location, size and depth. Keep in mind there can be more than one foreign body present, or one in the fellow eye that the patient is unaware of. An optic section should be used to determine the depth; however, in some cases—especially if there is corneal edema—it is difficult to visualize.

Anterior segment OCT (AS-OCT) can help determine the depth in unclear cases; it will typically show a hyper-reflective lesion representing the foreign body material. The foreign body will also cause shadowing of the corneal layers corresponding to

its location.<sup>6</sup> Thus, the high resolution of AS-OCT provides detailed information that can be used to determine the most appropriate removal technique (*Figures 1 and 2*).

Understanding exact depth and location is also helpful in predicting prognosis. Objects that have penetrated the stroma will produce a scar, which can result in decreased vision if the object is within or near the visual axis. In addition to detailed characteristics of the foreign body, AS-OCT can provide information on the status of the surrounding tissue, the integrity of Descemet's membrane (*i.e.*, risk for impending perforation) and even identify any missed lesions that were not previously visible on slit lamp examination.<sup>6</sup>

Next comes determining whether or not the foreign body actually needs to be removed. If it is not penetrating the globe, it's best to go ahead and remove it. Inert objects such as sand and glass are well-tolerated in the cornea without resulting in a tissue reaction. If an inert object cannot be removed without significant risk and is not in the visual axis, it can be

left in place with close monitoring of the patient.<sup>7</sup> In contrast, organic substances (vegetative materials) and metals are poorly tolerated by the cornea, resulting in edema, scarring, inflammation, neovascularization and stromal necrosis. These substances must be promptly removed.<sup>6</sup>

### #3: CHOOSE THE BEST TOOL FOR THE JOB

If the foreign body is superficial, it can sometimes be rinsed away via ocular irrigation with sterile saline or wiped away with a moist cotton-tipped applicator. If the foreign body is embedded, more invasive tools are necessary: golf spud, jewelers forceps, magnetic probe and small-gauge needles (*Figure 3*). Rust rings may be removed with either a small-gauge needle or an ophthalmic burr/Algerbrush.

Here are some rules of thumb to take into consideration when selecting which instrument to use:

- Make sure instruments are sterile.
- Use the least invasive technique that will allow for safe and effective removal.
- Attempt to remove superficial objects with a moistened sterile



# The most studied eye vitamin brand.<sup>†</sup>

## PreserVision<sup>®</sup>



PreserVision AREDS2 is backed by **20 years of clinical studies** and contains the **EXACT nutrient formula** recommended by the National Eye Institute to help reduce the risk of moderate to advanced AMD progression.\*<sup>2,3</sup>

For samples, call **855-54BL-OTC** (855-542-5682)

**Recommend PreserVision for your patients today**

**BAUSCH + LOMB**

\*These statements have not been evaluated by the Food and Drug Administration. These products are not intended to diagnose, treat, cure, or prevent any disease.

Packaging may vary. AREDS=Age-Related Eye Disease Study.  
†Based on the AREDS and AREDS2 clinical studies.  
‡Data on file for #1 Dr. Recommended Brand, Bausch + Lomb. †National Eye Institute. National Institutes of Health; September 2015. Accessed November 4, 2020. [https://www.nei.nih.gov/sites/default/files/health-pdfs/WYSK\\_AMD\\_English\\_Sept2015\\_PRINT.pdf](https://www.nei.nih.gov/sites/default/files/health-pdfs/WYSK_AMD_English_Sept2015_PRINT.pdf) ‡Age-Related Eye Disease Study 2 Research group. *JAMA*. 2013;309(19): 2005-15. doi:10.1001/jama.2013.4997

PreserVision is a trademark of Bausch & Lomb Incorporated or its affiliates. AREDS and AREDS2 are registered trademarks of the United States Department of Health and Human Services (HHS).

© 2022 Bausch & Lomb Incorporated or its affiliates. PN10273 PVN.0011.USA.22



cotton-tipped applicator. This is best for objects like eyelashes or hairs that are resting on the conjunctiva. Avoid using a cotton-tipped applicator on the cornea. Due to the size of the cotton tip, it could embed the foreign body further into the cornea or cause a large area of epithelial disruption.

- Consider using a magnetic spud for superficial metallic foreign bodies. This will allow you to easily lift superficial metallic objects without causing significant damage to the surrounding tissues. This is also helpful for retrieval and cleanup of any loose flakes of metal that may have been dislodged onto the ocular surface during removal.

- Foreign body spuds (also referred to as golf club spuds due to their characteristic shape) are useful for removing embedded foreign bodies that require excavating, scraping or flicking to dislodge. Due to the blunt edge of the spud, there is minimal risk of perforation.

- Jewelers forceps are helpful in grasping vegetative material that protrudes outward from the ocular surface or lifting off material that is loosely adhered to the surface.

- When used properly, a small-gauge disposable needle, such as the 25-gauge 5/8" is a good all-around tool that results in minimal damage.

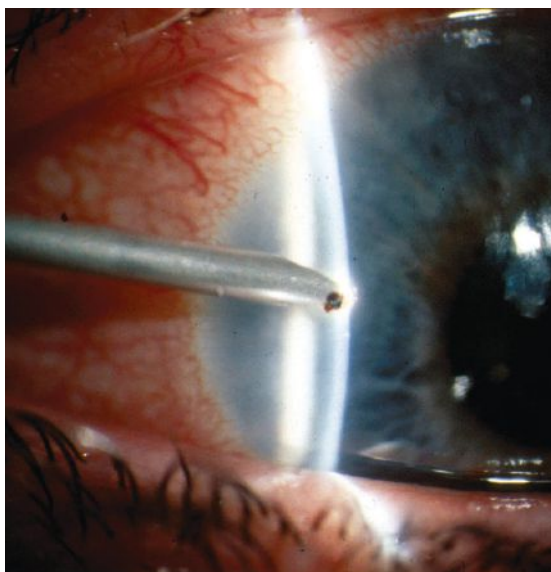


Fig. 4. Spud removal of a metallic foreign body.

#### #4: ENSURE PATIENT CONSENT

Prior to foreign body removal, explain the procedure, risks, benefits and alternatives to the patient and obtain written consent (or document verbal consent in your chart).

Ensure patient comfort and cooperation by properly anesthetizing the ocular surface with topical anesthetic drops such as proparacaine 0.5% or tetracaine 0.5%. Instill one or two drops of anesthetic into the lower cul-de-sac of the eye and wait at least 30 seconds before starting the procedure. Instillation of topical anesthetic into the fellow eye will aid in reducing blink reflex and increasing patient cooperation.

For best stabilization and visualization, a slit lamp should be used with the patient's forehead securely placed against the forehead rest. Identify a fixation target that will ensure proper and steady alignment of the eye and reduce risk of eye movement during the procedure. Instruct the patient to fixate on the target using the opposite eye. Occasionally, the use of an eyelid speculum is required for patients who are less cooperative or have a strong blink reflex.

#### #5: OPTIMIZE STABILITY DURING REMOVAL

Stability is key when performing foreign body removal. Stabilize your arm using the slit lamp table or an arm rest. Hold the instrument like a pencil between your thumb and forefinger. Rest your fourth and fifth fingers holding the instrument on the patient's cheek, bridge of nose or upright bar of the slit lamp. Align your instrument by sighting outside of the slit lamp, positioning it in front of the foreign body at an angle tangential to the ocular surface. It's imperative that you always approach the eye tangentially in order to prevent perforating the eye or further embedding

the foreign body into the eye. Once properly aligned, look through the oculars as you perform the remainder of the procedure. Secure the upper eyelid with your free hand and use the instrument to remove the foreign body.

When using a cotton-tipped applicator, foreign bodies can be removed by gently tapping the moistened tip to the object and lifting it off of the tissue. If the foreign body is conjunctival, you can use a gentle swiping motion if necessary. Avoid any swiping motions on the cornea as this could cause an abrasion.

When using forceps, gently clasp the object and lift it off of the tissue, and avoid pinching the surface of the eye.

When using a needle, position it with the bevel facing outward, toward you. With small strokes, use it to loosen the edges of the foreign body. Then, with the tip of the needle positioned just under the edge of the foreign body, use a subtle flicking motion to release it from the corneal surface. Make sure to maintain a tangential angle to the globe throughout this procedure.

When using a spud, the instrument should be handled in a similar manner as the needle, using the tip of the spud to tease out the edges of the foreign body and then using a flicking motion to release it from the surface of the cornea (*Figure 4*).

#### #6: DOUBLE CHECK, IRRIGATE AND DOCUMENT

Once you have successfully removed the foreign body, irrigate the eye with sterile saline solution and re-examine with the slit lamp. Document the size, location and depth of the resultant epithelial defect.

#### #7: REMOVE ANY RUST AT INITIAL VISIT

Metallic (ferrous) ocular foreign bodies begin to oxidize, forming rust at the injury site within just a few hours of becoming embedded in the cornea. The resulting rust usually forms a ring around the metallic foreign

# Screen Burned Eyes?

# TRY REGENER-EYES

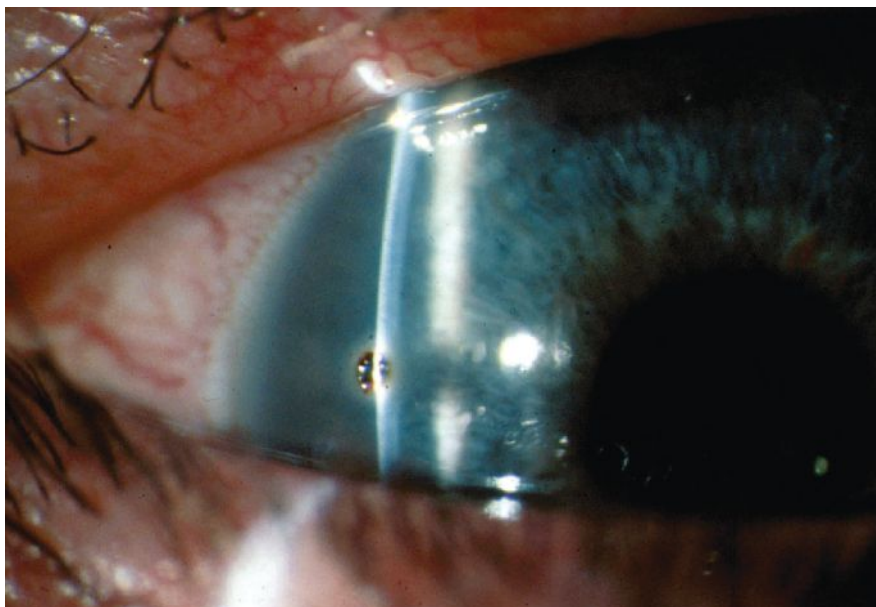
THE **POWER** OF A BIOLOGIC IN THE **EASE** OF AN EYEDROP



[regenereyes.com](http://regenereyes.com) | 877-206-0706

© 2021 Regener-Eyes®, All rights reserved





**Fig. 5. Metallic foreign body with rust ring.**

body (Figure 5). If left there, this rust ring can cause an immune response, resulting in extended healing time, inflammation, tissue damage and stromal necrosis.<sup>8-9</sup> Therefore, it is best to remove as much of the rust as possible, as soon as possible.

An Algerbrush—a small, low-speed, battery-operated drill that is fitted with a tiny dental burr—is commonly used for removal. To alleviate patient apprehension during this technique, mention that the Algerbrush makes a soft whirring noise. The device has a built-in clutch mechanism that will stop the instrument when a certain degree of resistance is encountered. Therefore, when an Algerbrush contacts Bowman's membrane, it will automatically shut off. This safety measure assumes proper use of the instrument, using a tangential approach, and that the foreign body itself is not penetrating Bowman's membrane. In cases where the foreign body is penetrating Bowman's, there is no longer enough resistance to initiate the stop.<sup>9</sup>

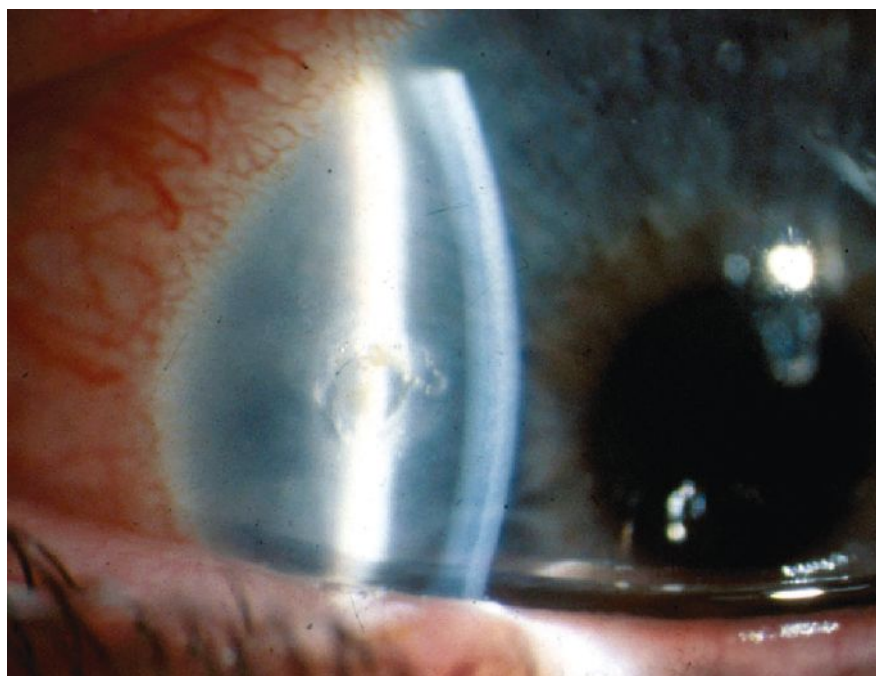
When using the Algerbrush, approach the cornea tangentially and apply it to the rust ring with very little pressure; allow the spinning motion of the burr on the cornea to do the work for you. Lightly contact the

rotating burr with all areas of the rust ring. There should be minimal hand movement, with the exception of moving the instrument to a different part of the rust ring. Occasionally, it is necessary to switch the Algerbrush to your opposite hand in order to take advantage of the now reversed rotation of the burr to remove any resistant rust.

Alternatively, you may use a spud or needle to remove the rust ring, always keeping the instrument tangential to the cornea. Use small motions to scrape away the epithelium that contains the rust.

Ideally, you should remove as much rust as possible during the initial visit in avoid an inflammatory response (Figure 6). However, very deep stromal rust may be left in place if you feel it would be unsafe to attempt to remove it at that visit. Keep in mind: aggressive and widespread use of the burr within the stroma can lead to increased scarring.<sup>9</sup> Thus, in cases of deep stromal rust, it is best to remove only the superficial rust and leave the rest for removal at a follow-up visit.

As the cornea heals, the residual rust will move more anteriorly, allowing for easier removal with less risk of long-term scarring. In some cases, it takes several visits to remove all of the rust. At the conclusion of the procedure, rinse the eye with sterile saline, re-examine the eye with the slit lamp and document the extent of the corneal defect. You may instill a drop of broad-spectrum topical antibiotic for prophylactic coverage.



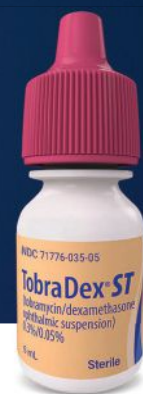**Fig. 6. Corneal epithelial defect immediately following foreign body removal with an Algerbrush.**



When Blepharitis/MGD Strikes,

# STOP FLARES FAST

- >50% reduction in symptoms of blepharitis/blepharoconjunctivitis in 1 week of dosing. No IOP spikes reported during first week of treatment<sup>1,a</sup>
- Greater bactericidal activity—more effective at killing MRSA\* than TobraDex\* (>99.9% kill rate vs 0%)<sup>2</sup>
- Delivers 12.5× higher tobramycin concentration in ocular tissue compared to TobraDex<sup>2</sup>



**RESCUE YOUR PATIENTS FAST.**  
Prescribe the **TOBRADEX® ST** difference.

#### Indications and Usage

For steroid responsive inflammatory ocular conditions of the palpebral and bulbar conjunctiva, cornea, and anterior segment of the globe and chronic anterior uveitis, corneal injury from chemical, radiation or thermal burns, or penetration of foreign bodies for which a corticosteroid is indicated and where the risk of superficial bacterial ocular infection is high or where there is an expectation that potentially dangerous numbers of bacteria will be present in the eye.

#### Important Safety Information

##### CONTRAINDICATIONS:

Most viral disease of the cornea and conjunctiva including epithelial herpes simplex keratitis (dendritic keratitis), vaccinia, and varicella, and also in mycobacterial infection of the eye and fungal disease of ocular structures. Hypersensitivity to any components of the medication.

##### WARNINGS & PRECAUTIONS:

- **IOP increase** – Prolonged use may result in glaucoma with damage to the optic nerve, defects in visual acuity and fields of vision. IOP should be monitored.
- **Aminoglycoside sensitivity** – Sensitivity to topically applied aminoglycosides may occur.
- **Cataracts** – Posterior subcapsular cataract formation may occur.
- **Delayed healing** – May delay healing and increase the incidence of bleb formation. Perforations of the cornea or sclera have occurred. Slit lamp biomicroscopy, and fluorescein staining should be conducted.
- **Bacterial infections** – May suppress host response and increase secondary ocular infections. In acute purulent conditions, steroids may mask infection or enhance existing infection. If signs and symptoms fail to improve after 2 days, the patient should be re-evaluated.

- **Viral infections** – Use with history of herpes simplex requires great caution. The course and severity of many viral infections of the eye (including herpes simplex) may be exacerbated.
- **Fungal infections** – Fungal infections of the cornea may occur and should be considered in any persistent corneal ulceration.
- **Use with systemic aminoglycosides** – Total serum concentration of tobramycin should be monitored.

##### ADVERSE REACTIONS:

The most frequent adverse reactions (<4%) to topical ocular tobramycin are hypersensitivity and localized ocular toxicity, including eye pain, eyelid pruritus, eyelid edema, and conjunctival hyperemia. The reactions due to the steroid component are increased intraocular pressure with possible development of glaucoma, and infrequent optic nerve disorder; subcap-sular cataract; and impaired healing.

The development of secondary infection has occurred. Fungal infections of the cornea may occur. Secondary bacterial ocular infection following suppression of host responses also occurs.

Non-ocular adverse events (0.5% to 1%) included headache and increased blood pressure.

**Please see Brief Summary of full Prescribing Information on the adjacent page.**

<sup>a</sup>Randomized, investigator-masked, active-controlled, parallel-group trial conducted at 7 private practice clinical sites in the United States with 122 adult patients who had moderate to severe blepharitis/blepharoconjunctivitis.<sup>1</sup>

**References:** 1. Torkildsen GL, Cockrum P, Meier E, et al. *Curr Med Res Opin.* 2011;27(1):171-178. 2. Scoper SV, Kabat AG, Owen GR, et al. *Adv Ther.* 2008;25(2):77-88.



© 2022 Eyeavance Pharmaceuticals LLC., a Santen company. All rights reserved.  
TOBRADEX® ST and XanGen® are registered trademarks of Eyeavance Pharmaceuticals LLC.  
\*All other trademarks are the property of their respective owners.  
TST-US-220017 03/22

**TobraDex® ST**  
(tobramycin/dexamethasone  
ophthalmic suspension)  
0.3%/0.05%  
FORMULATED WITH **XanGen®**

## TOBRADEX® ST (tobramycin/dexamethasone ophthalmic suspension) 0.3%/0.05%

### Brief Summary

This Brief Summary does not include all the information needed to use TOBRADEX ST safely and effectively. Please see Full Prescribing Information for TOBRADEX ST at MyTobraDexST.com.

### INDICATIONS AND USAGE

TOBRADEX ST is a topical antibiotic and corticosteroid combination for steroid-responsive inflammatory ocular conditions for which a corticosteroid is indicated and where superficial bacterial ocular infection or a risk of bacterial ocular infection exists.

Ocular steroids are indicated in inflammatory conditions of the palpebral and bulbar conjunctiva, cornea and anterior segment of the globe where the inherent risk of steroid use in certain infective conjunctivitis is accepted to obtain a diminution in edema and inflammation. They are also indicated in chronic anterior uveitis and corneal injury from chemical, radiation or thermal burns, or penetration of foreign bodies.

The use of a combination drug with an anti-infective component is indicated where the risk of superficial ocular infection is high or where there is an expectation that potentially dangerous numbers of bacteria will be present in the eye.

### DOSAGE AND ADMINISTRATION

**Recommended Dosing:** Instill one drop into the conjunctival sac(s) every four to six hours. During the initial 24 to 48 hours, dosage may be increased to one drop every 2 hours. Frequency should be decreased gradually as warranted by improvement in clinical signs. Care should be taken not to discontinue therapy prematurely.

### CONTRAINDICATIONS

**Nonbacterial Etiology:** TOBRADEX ST is contraindicated in most viral diseases of the cornea and conjunctiva including epithelial herpes simplex keratitis (dendritic keratitis), vaccinia, and varicella, and also in mycobacterial infection of the eye and fungal diseases of ocular structures.

**Hypersensitivity:** Hypersensitivity to any component of the medication.

### WARNINGS AND PRECAUTIONS

**IOP increase:** Prolonged use of corticosteroids may result in glaucoma with damage to the optic nerve, defects in visual acuity and fields of vision. IOP should be monitored.

**Aminoglycoside sensitivity:** Sensitivity to topically applied aminoglycosides may occur.

**Cataracts:** May result in posterior subcapsular cataract formation.

**Delayed healing:** May delay healing and increase the incidence of bleb formation after cataract surgery. In those diseases causing thinning of the cornea or sclera, perforations have been known to occur with the use of topical steroids.

**Bacterial infections:** May suppress the host response and thus increase the hazard of secondary ocular infections. In acute purulent conditions, steroids may mask infection or enhance existing infection. If signs and symptoms fail to improve after 2 days, the patient should be re-evaluated.

**Viral infections:** Treatment in patients with a history of herpes simplex requires great caution. Use of ocular steroids may prolong the course and may exacerbate the severity of many viral infections of the eye (including herpes simplex).

**Fungal infections:** Fungal infections of the cornea are particularly prone to develop with long-term use. Fungal invasion must be considered in any persistent corneal ulceration.

**Use with systemic aminoglycosides:** Use with systemic aminoglycoside antibiotics requires monitoring for total serum concentration of tobramycin.

### ADVERSE REACTIONS

The most frequent adverse reactions to topical ocular tobramycin (TOBREX®) are hypersensitivity and localized ocular toxicity, including eye pain, eyelids pruritis, eyelid edema, and conjunctival hyperemia. These reactions occur in less than 4% of patients. Similar reactions may occur with the topical use of other aminoglycoside antibiotics.

Non-ocular adverse events occurring at an incidence of 0.5% to 1% included headache and increased blood pressure.

The reactions due to the steroid component are: increased intraocular pressure (IOP) with possible development of glaucoma, and infrequent optic nerve disorder; subcapsular cataract; and impaired healing.

**Secondary Infection:** The development of secondary infection has occurred. Fungal infections of the cornea are particularly prone to develop with long-term use. Fungal invasion must be considered in any persistent corneal ulceration. Secondary bacterial ocular infection following suppression of host responses also occurs.

### USE IN SPECIFIC POPULATIONS

#### Pregnancy and Nursing Mothers

There are no adequate and well controlled studies in pregnant women. TOBRADEX® ST ophthalmic suspension should be used during pregnancy only if the potential benefit justifies the potential risk to the fetus. Caution should be exercised when TOBRADEX® ST is administered to a nursing woman.

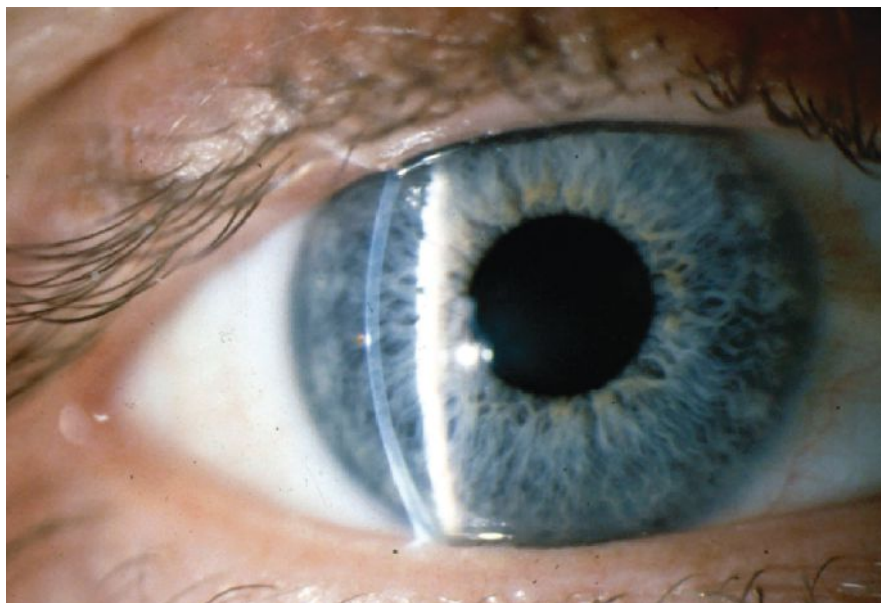
**Pediatric Use:** Safety and effectiveness in pediatric patients below the age of 2 years have not been established.

**Geriatric Use:** No overall differences in safety or effectiveness have been observed between elderly and younger patients.

### Rx Only

**Distributed by:** Santen Pharmaceutical Co., Ltd.  
Fort Worth, TX 76102





**Fig. 7. Healed epithelial defect with trace remaining rust seen at foreign body removal follow-up.**

#### #8: TREAT WITH ANTIBIOTICS

Postoperative care involves prevention of infection, control of pain and inflammation and monitoring for complications. As a rule of thumb, the patient should be treated with a broad-spectrum antibiotic, such as a fluoroquinolone, four times per day for one week or until the defect has re-epithelialized.<sup>10</sup> In cases of large corneal defects or conjunctival defects, antibiotic ointment may be preferred due to longer coverage as well as cushioning for comfort. A cycloplegic, such as cyclopentolate or homatropine, can be prescribed twice per day if there is significant pain or inflammation.

Topical ophthalmic NSAIDs can also be considered for treatment of pain in foreign body patients; however, these medications are not ideal in such cases, as they can lead to compromised corneal healing. Over-the-counter oral analgesics such as acetaminophen and ibuprofen are rarely indicated but can be considered if there is considerable pain.

In cases of excessive inflammation, topical corticosteroids can be used but only after re-epithelialization of the defect.<sup>8-10</sup> Steroids should also be considered if the foreign body is

deep/stromal and central to help reduce the amount of scarring. However, steroids should not be used with vegetative/organic/soil-based foreign bodies due to increased risk of fungal infection. Amniotic membranes are another treatment option for deep central foreign bodies.<sup>10</sup>

For larger corneal defects, treatment with a bandage contact lens is particularly effective for reducing pain and minimizing tissue disruption that is associated with the movement of the eyelid over the defect. However, this would be contraindicated in cases in which the foreign body was organic or vegetative due to risk of fungal keratitis.<sup>10</sup> If a bandage contact lens is used, it is important to see the patient in 24 hours.

At the follow-up visit, the contact lens should be removed and the cornea examined. Continue bandage contact lens treatment until the epithelial defect has healed. Monitor closely, as bandage contact lenses can create an environment more susceptible to infection.

If the foreign body material is organic or vegetative and the patient is at high risk for fungal keratitis, treatment with topical and/or oral anti-fungal medication can be considered.

#### #9: MONITOR OUTCOMES

Patients should be seen for follow-up in 24 hours. Typically, there is significant healing and reduction in pain within the first 24 to 72 hours (Figure 7). Monitor for complications such as non-healing infection, edema, iritis, recurrent corneal erosions and visually significant scarring. If any complications are found, treat appropriately and refer to a specialist when indicated.

#### #10: PREVENT FUTURE INJURIES

One of the most important aspects of postoperative care is providing patient education on the importance of wearing well-fitted safety goggles while performing high-risk activities. Make sure your patient has appropriate safety eyewear, and if not, help them obtain it, as well as explain and demonstrate proper use.

Ocular foreign body removal is a rewarding and skilled service that you can provide to your surrounding community. By following these clinical pearls, you can remove them with confidence, ease and without undue complications, giving your patients much-needed relief. ■

1. Bowes Hamill M. Mechanical Injury. In: Krachmer JH, Mannis MJ, Holland EJ. eds. *Cornea*. 2nd ed. St. Louis: Mosby. 2004;749-76.
2. Parke DW II, Flynn HW Jr, Fisher YL. Management of intraocular foreign bodies: a clinical flight plan. *Can J Ophthalmol*. 2013;48:8-12.
3. Fraenkel A, Lee LR, Lee GA. Managing corneal foreign bodies in office-based general practice. *Aust Fam Physician*. 2017;46(3):89-93.
4. Bowling B, Kanski JJ. *Kanski's Clinical Ophthalmology: A Systematic Approach*. 8th ed. Edinburgh: Elsevier. 2016;878-81.
5. Loporchio D, Mukkamala L, Gorukanti K, et al. Intraocular foreign bodies: a review. *Surv Ophthalmol*. 2016;61(5):582-96.
6. Celebi AR, Kilavuzoglu AE, Altiparmak UE, et al. The role of anterior segment optical coherence tomography in the management of an intra-corneal foreign body. *Springerplus*. 2016;5(1):1559.
7. Arora T, Arora S, Sinha R. Management of intrastromal glass foreign body based on anterior segment optical coherence tomography and Pentacam analysis. *Int Ophthalmol*. 2015;35:1.
8. Koetting C. Foreign body removal start to finish. *Rev Optom*. 2020;157(4):30.
9. Bronner A. No insult to injury: managing foreign body removal: here's what you need to know about this common corneal trauma to yield the best outcomes for your patients. *Rev Optom*. 2017;154(1):47-54.
10. Jayamanne DG, Bell RWN. Non-penetrating corneal foreign body injuries: factors affecting delay in rehabilitation of patients. *Emergency Medicine Journal*. 1994;11:195-7.



# FINE-TUNE YOUR CORNEAL DISEASE DIAGNOSTIC SKILLS

Take these quizzes to see where your knowledge of these conditions ranks.



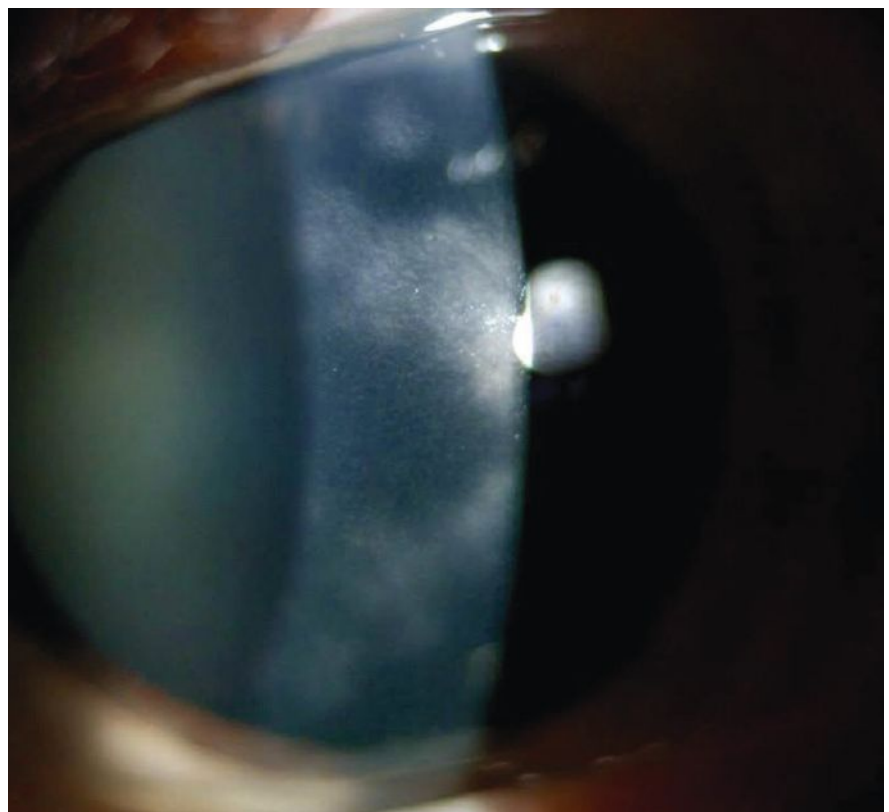
BY PAUL HAMMOND, OD  
MINNEAPOLIS, MN

For a structure only half a millimeter thick, there are a wide variety of problems that can arise in the cornea. Most of these pathologies can be grouped into one of six categories: injury, inflammation, infection, dysplasia, degeneration or deposition.

KMK Optometry has helped 98% of optometry students nationwide prepare for their board exams since 2010, and this month we're going to fine-tune your cornea differential diagnosis skills in particular. Below are some of our favorite cases with photos from our Instagram page that represent a few of the pathology groups mentioned above for you to test your knowledge. Have fun and good luck! Answers to all questions appear at the conclusion of this article on page 49.

## CASE ONE

A 55-year-old woman was referred from the emergency room with gradually worsening vision over



**Case 1. This patient's cornea showed diffuse patches of intrastromal haze.**

the previous week in her left eye with increasing light sensitivity and a headache. Her history included

cataracts, LASIK surgery in 2006 and herpes zoster ophthalmicus in 2019. She noted she had experienced

**About the author**

**Dr. Hammond** specializes in glaucoma and corneal disease at Twin Cities Eye Consultants in Minneapolis, MN. He is also the co-editor of KMKOptometryPro on Instagram. He is a consultant for Allergan.

recent stress due to being furloughed. Her vision was 20/50 in the left eye. Her exam findings were notable for 1+ anterior chamber cell and the corneal findings seen in the photo.

### Corneal Findings

1. What is your tentative diagnosis?

- Corneal hydrops from post-LASIK ectasia.
- Recurrent zoster keratitis.
- Salzmann's nodular degeneration.
- Diffuse lamellar keratitis.

2. Which treatment is most appropriate?

- Corneal crosslinking.
- Superficial keratectomy.
- Oral valacyclovir and topical prednisolone.
- Flap lift with irrigation.
- Topical gancyclovir.

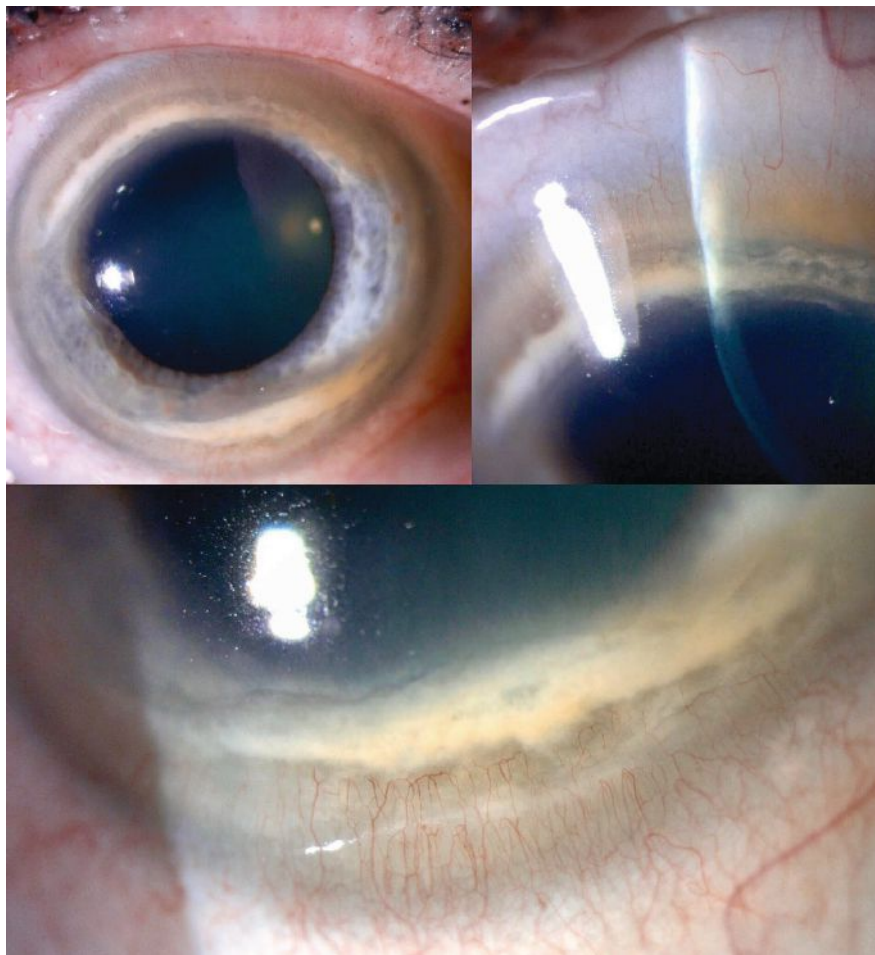### Discussion

Interstitial keratitis is an infectious condition that affects the stromal layer of the cornea and most commonly arises from the herpes simplex virus or the varicella zoster virus, sometimes triggered by stress or fatigue. The treatment is similar for both viruses, involving oral antivirals to inhibit viral replication and topical steroid eye drops to reduce the inflammatory response to the viral antigens. Recurrence can be common as seen with this patient, as well as visually debilitating; herpetic keratitis is one of the leading causes of corneal scarring.

Fortunately, this patient improved from 20/50 to 20/20 vision on oral Valtrex (valacyclovir, GlaxoSmithKline) 1g TID and prednisolone acetate six times a day followed by a six-month taper, and continues to take a QD prophylactic dose of each ongoing.

### CASE TWO

Referred from a local optometrist for "corneal thinning," this patient thought her eyes were perfectly healthy other than having a higher than average amount of astigmatism. She had no pain, redness or tearing, and best-corrected visual acuity (BCVA) was 20/20 OD and 20/25 OS



**Case 2. Slit lamp exam showed paralimbal corneal thinning with neovascularization and lipid deposits bilaterally.**

with against-the-rule 1.5D of cylinder OD and 3.5D of cylinder OS. On slit lamp exam, there was paralimbal corneal thinning with neovascularization and lipid deposits bilaterally, most prominent superiorly and inferiorly, and the epithelium was intact.

### Corneal Findings

3. What is your tentative diagnosis?

- Pellucid marginal degeneration.
- Peripheral ulcerative keratitis.
- Terrien's marginal degeneration.
- Furrow degeneration.

4. Which treatment is most appropriate?

- Corneal crosslinking.
- Bandage contact lens, topical moxifloxacin and oral vitamin C.
- Culture.
- Observation.
- Amniotic membrane graft.

### Discussion

Given the lack of inflammation in this case, the presence of peripheral thinning greatest superiorly and inferiorly accompanied by lipid and neovascularization, the diagnosis of Terrien's marginal degeneration was made. This condition is slowly progressive, causing high levels of against-the-rule astigmatism—usually bilaterally—resulting in normal to mildly reduced visual acuity depending. Vision is usually well-corrected with glasses or scleral contact lenses, and serious complications like spontaneous perforation are quite rare, usually associated with ocular trauma.

This patient was content with her glasses, deferred a scleral lens consult and was referred back to her OD for yearly monitoring.

# Make a Difference for Your Patients and Practice With the ALCON MULTIFOCAL CONTACT

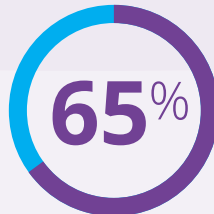
## Millions of People Want and Need Multifocal Contact Lenses and the Number Is Growing



**2,700**

**multifocal contact lens candidates for each optometrist<sup>1,2,\*</sup>**

\*Presbyopia generally occurs around age 40. The emerging presbyopic population was calculated using patients 35-44, and the established presbyopic population was calculated using patients 45-64.

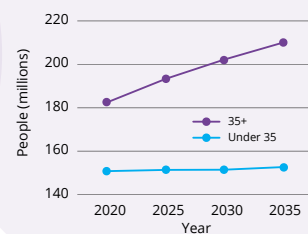


**65%**  
**of presbyopes want to wear contact lenses again<sup>3,\*</sup>**

\*Based on a survey of presbyopes who stopped wearing contact lenses after symptoms of presbyopia emerged.

**Prepare for the "Silver Tsunami"<sup>1,4</sup>**

**US Population Projections**

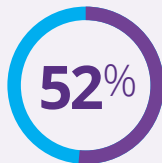

**Older population equals more presbyopes**

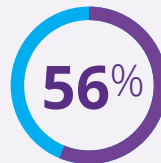### Today's presbyopes think multifocal contact lenses...



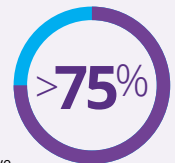Make them look younger<sup>5</sup>



Would increase confidence<sup>6</sup>



Are better for playing sports or for working out<sup>7,\*</sup>



\*Compared with progressive lenses in a study of 20 patients over 2-4 weeks

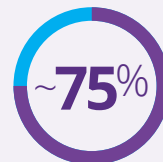## Alcon's Multifocal Contact Lenses: Intentionally Designed for Success

### Meet the Needs of the MAJORITY of Your Patients

Precision Profile™ Design offers predictable seamless vision and can be successfully fit in patients with low levels of astigmatism ( $\leq 0.75D$  cyl)



Of potential contact lens wearers, only approximately one-third require astigmatic correction<sup>8</sup>



of patients with astigmatism have  $\leq 0.75D$  cyl<sup>8,†</sup>

† In at least 1 eye

1. US Census Bureau, Population Division. 2017 National Population Projections Tables: Detailed age and sex composition of the population, 2017-2060. Available at: <https://www.census.gov/data/tables/2017/demo/popproj/2017-summary-tables.html>. Accessed October 28, 2021. 2. American Optometric Association. The state of the optometric profession: 2013. Available at: <https://www.reviewob.com/the-state-of-the-optometric-profession-2013-2/>. Accessed October 28, 2021. 3. Alcon data on file, 2013. 4. US Census Bureau, Population Division. 2017 National Population Projections Tables: Table 3. Detailed age and sex composition of the population, 2017-2060. Available at: <https://www2.census.gov/programs-surveys/popproj/tables/2017/2017-summary-tables/np2017-t3.xlsx>. Accessed October 27, 2021. 5. Merchea M et al. Patient and ECP Satisfaction in the United States with a Novel Water Gradient Daily Disposable Multifocal Contact Lens. Poster presented at: Annual Meeting of the American Optometric Association; June 21-25, 2017; Washington, DC. 6. c\_space Multifocal PR Report: Positioning DAILIES TOTAL1 Multifocal Contact Lenses. Nov, 2018. 7. Fogt JS, Weisenberger K, Fogt N. Visual performance with multifocal contact lenses and progressive addition spectacles. *Cont Lens Anterior Eye*. 2021;101472. 8. Young G, Sulley A, Hunt C. Prevalence of astigmatism in relation to soft contact lens fitting. *Eye & Contact Lens*. 2011;37:20-25. 9. Alcon Multifocal Contact Lenses: Fitting Guidelines. 2017. 10. Merchea M, Evans D, Kannarr S, et al. Assessing a modified fitting approach for improved multifocal contact lens fitting success. Presented at: Annual Meeting of the



# LENS FAMILY

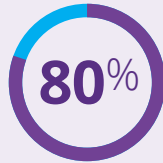

## Benefits of Multifocal Contact Lenses for Your Practice

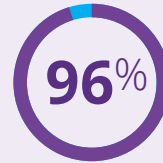### Minimal Chair Time with a Fit Process Optimized by Extensive Research

#### Simple Two-Step

initial fitting process with high rate of fit success<sup>9,†</sup>



first lens fit success<sup>10,†</sup>



fit success with 2 or fewer lenses<sup>10,11,†</sup>

† When following the Alcon Multifocal Fit Guide

### Meet the Needs of Your Patients and Practice with the Alcon Multifocal 3:2:1 Advantage

**3** Lenses for any lifestyle

Near

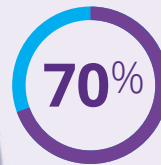
**2** Replacement schedules—

Intermediate

Daily and monthly schedules increase lens replacement compliance

Distance

**1** Innovative optical design— Precision Profile™ Design



### Patients Want to be in Multifocal Contact Lenses

of patients who tried DAILIES TOTAL1® Multifocal contact lenses preferred them over progressive addition spectacles for overall use<sup>7,8</sup>

<sup>8</sup> Based on a study of 20 patients over 2–4 weeks

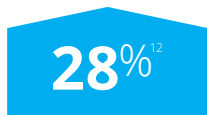
## Alcon Is Your Partner for Patient and Practice Success



Scan the QR code to unlock educational resources from the Alcon Experience Academy!<sup>15</sup>

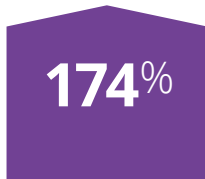
Ask your Alcon Representative for more multifocal training opportunities

More exams per year for your practice



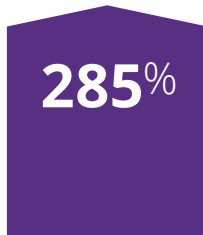Compliant lens wearers return for exams 3 months sooner than noncompliant patients<sup>9</sup>—an opportunity to provide comprehensive eyecare sooner

Increase in annual per-patient revenue



Multifocal contact lenses vs glasses-only wearers<sup>11</sup>

<sup>11</sup> Including contact lens sales and fitting fees

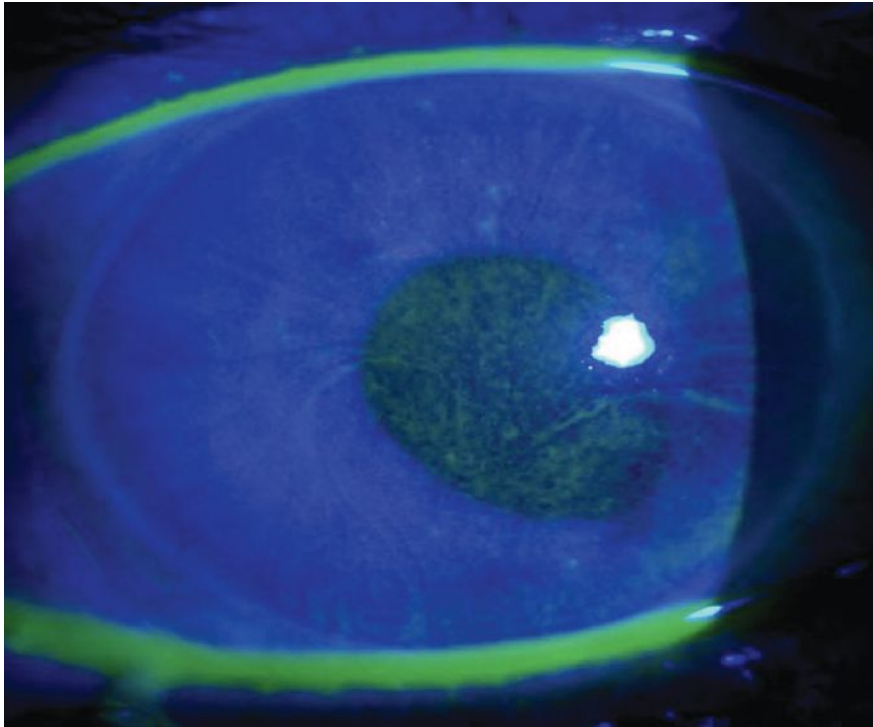


With daily disposable multifocal contact lenses<sup>11</sup>

American Optometric Association; June 20-24, 2018; Denver, CO. **11.** Bauman E, Lemp J, Kern J. Material effect on multifocal contact lens fitting of lenses of the same optical design with the same fitting guide. Presented at: British Contact Lens Association Clinical Conference & Exhibition; June 9-11, 2017; Liverpool, UK. **12.** MBA Best Practices of Contact Lens Management, March 2010. **13.** Dumbleton K et al. Compliance with lens replacement and the interval between eye examinations. *Optom Vis Sci.* 2013;90:351-358. **14.** Alcon data on file, 2018. **15.** Alcon Experience Academy website. [www.alconexperienceacademy.com](http://www.alconexperienceacademy.com).

**Important information for AIR OPTIX® plus HydraGlyde® Multifocal (Iotrafalcon B) contact lenses:** For daily wear or extended wear up to 6 nights for near/far-sightedness and/or presbyopia. Risk of serious eye problems (i.e., corneal ulcer) is greater for extended wear. In rare cases, loss of vision may result. Side effects like discomfort, mild burning, or stinging may occur.

See product instructions for complete wear, care, and safety information. only



**Case 3.** This patient had uncontrolled IOP and a swirling pattern of NaFl staining.

### CASE THREE

This female patient had a history of severe trauma 20 years prior, necessitating vitrectomy, scleral buckle, scleral-fixated IOL and a trabeculectomy, which had scarred down. She was currently taking four different glaucoma drops and had no pain, but vision had gradually declining over the last year along with slight progression of her arcuate (non-central) visual field defects. BCVA was 20/100 with an IOP of 25. There was a diffuse whorling keratitis that picked up NaFl stain, no stromal edema and no inflammation in the anterior chamber.

### Corneal Findings

5. *What is your tentative diagnosis?*

- a. Microcystic corneal edema.
- b. Rhopressa-associated verticillata.
- c. Anterior basement membrane dystrophy.
- d. Limbal stem cell deficiency.

6. *Which treatment is most appropriate?*

- a. Tube shunt and discontinue Rhopressa (netarsudil, Aerie).
- b. Phototherapeutic keratectomy with Prokera (Bio-Tissue).

- c. Descemet's membrane endothelial keratoplasty (DMEK) and Xen implant (Allergan).
- d. Micropulse cyclophotocoagulation and platelet-rich plasma eye drops.

### Discussion

This patient is in a difficult predicament, with uncontrolled IOP on maximal medical therapy and limbal stem cell deficiency (LSCD) from glaucoma drop toxicity. The swirling pattern is reminiscent of verticillata, but that does not stain with NaFl and rarely affects visual acuity. This LSCD pattern arises from the centrifugal nature of epithelial replication from the palisades of Vogt at the limbus as the cells migrate centrally.

For IOP reduction, it was decided to perform micropulse cyclophotocoagulation to avoid incisional surgery that may further damage the cornea. She was also switched to preservative-free Tim-Brim-Dorz Qam and Tim-Brim-Dorz-Lat eye drops Qhs (Imprimis). Platelet-rich plasma eye drops were formulated at 40% for maximum efficacy and used six times a day.

Fortunately, vision recovered to 20/50 after two months of treatment and IOP improved to the upper teens.

### CASE FOUR

This 61-year-old male had not had an eye exam in over 10 years and reported that his vision was not as good as it used to be. His eyes were occasionally dry, but otherwise comfortable. He worked as a roofer and reported smoking a pack of cigarettes per day. He had no history of any ocular surgery or injury. His exam was remarkable for 2+ nuclear cataracts on exam and visual acuity was 20/30. The left cornea had an irregular swath of hazy epithelium without vascularization or ulceration, as documented in the photo.

### Corneal Findings

7. *What is your tentative diagnosis?*

- a. Ocular surface squamous neoplasia (OSSN).
- b. Atypical pterygium.
- c. Salzmann's nodular degeneration.
- d. Limbal dermoid.

8. *Which treatment is most appropriate?*

- a. Topical chemotherapy eye drops.
- b. Surgical resection with amniotic membrane graft and mitomycin-C.
- c. Superficial keratectomy with amniotic membrane graft.
- d. Diamond burr polishing plus bandage contact lens.

### Discussion

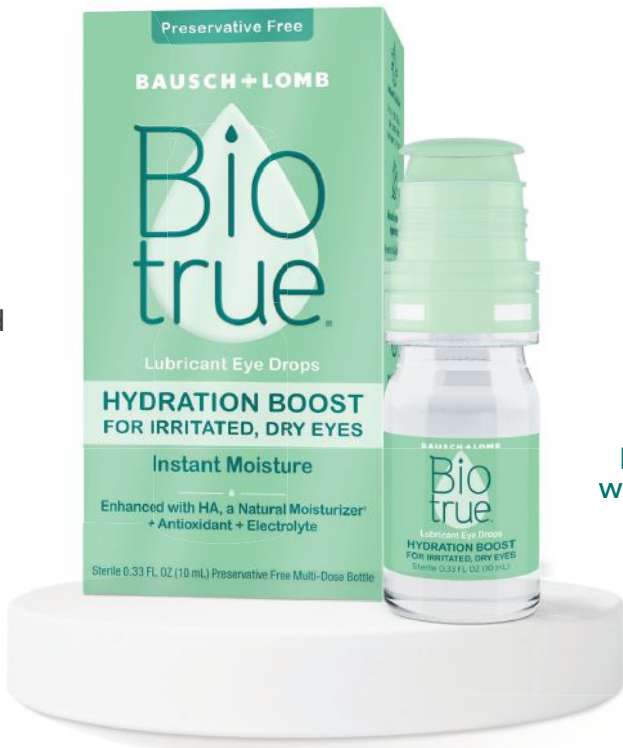Sun exposure is a strong risk factor for developing OSSN and this patient was no different. The photograph shows hazy epithelium in an irregular pattern unlike a pterygium or Salzmann's degeneration. In recent years, topical chemotherapeutic agents such as interferon alpha-2b, mitomycin-C and 5-fluorouracil have gained popularity in their ability to clear OSSN from the conjunctiva and cornea without surgery, and they show superiority in clearing microscopic disease that can be missed with traditional excisional biopsy.

FROM THE  
MAKERS OF  
BIOTRUE®



# Dry eye symptom relief inspired by the biology of the eye

- Helps maintain ocular surface homeostasis
- Soothes eye dryness caused by screen and environmental stressors



Contact lens compatible\*

98%

patient satisfaction with Biotrue® Hydration Boost Eye Drops†



Free from preservatives that can cause irritation



Potassium helps maintain ocular surface homeostasis



Antioxidant protects hyaluronan (HA) against free radicals



HA, a moisturizer found naturally in tears‡

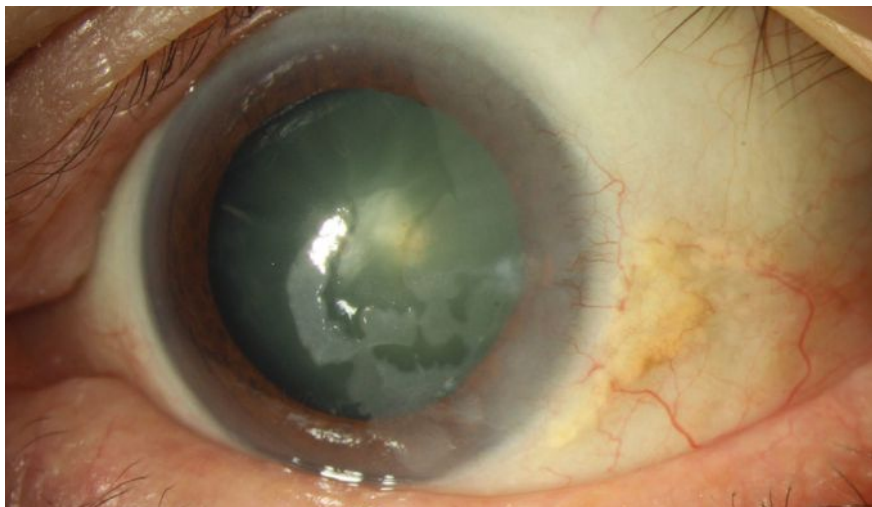

pH balanced

\*Based on standardized testing of soft contact lenses. Not meant to lubricate or rewet lenses.  
†In-Home Use Study: N=728 dry eye sufferers; April 2021. ‡Hyaluronan (HA) is sourced from a large-scale natural fermentation process.

LEARN MORE AT  
[biotrue.com/professional](https://biotrue.com/professional)





**Case 4.** This patient had an irregular swath of hazy epithelium without vascularization or ulceration in his left cornea.

Fortunately, this patient regained a perfectly clear cornea after several rounds of topical interferon drops and is now doing well without signs of recurrence.

### CASE FIVE

A 49-year-old female reported a history of recurrent redness in her left eye the last three years, as well as light sensitivity and mild blur as of this spring. She had a history of chalazion removal two years prior, did not wear contact lenses and was already taking ciprofloxacin eye drops from her PCP, which were not helping.

Slit lamp exam showed significant telangiectatic blepharitis, a corneal infiltrate with a leash of superficial neovascularization from the nasal limbus and a smaller-sized epithelial defect overlying the infiltrate. She denied recent travel out of the country and new sexual partners.

### Corneal Findings

9. What is your tentative diagnosis?

- a. Interstitial keratitis.
- b. Phlyctenular keratoconjunctivitis.
- c. Vernal keratoconjunctivitis.
- d. Recurrent corneal erosion.

10. Which treatment is most appropriate?

- a. Laboratory workup and penicillin.

- b. Oral cetirizine, topical olopatadine and loteprednol.
- c. Debridement, diamond burr polish and bandage contact lens.
- d. Oral doxycycline and tobramycin-dexamethasone eye drops.

### Discussion

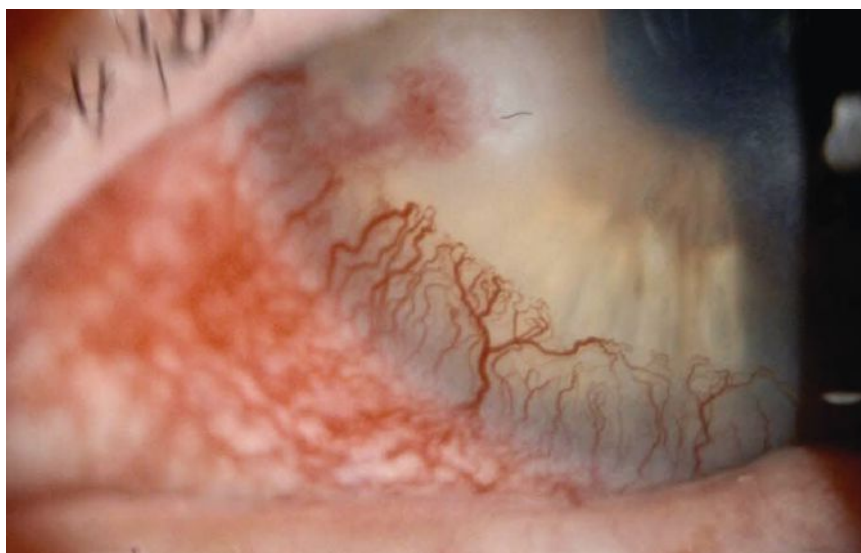
The recurrent nature of the condition, concurrent rosacea blepharitis and classic corneal appearance led to a diagnosis of phlyctenular keratoconjunctivitis. The ciprofloxacin from the PCP was not helpful, as this condition is primarily due to a

hypersensitivity reaction, which is inflammatory in nature. Staphylococcal and tuberculosis antigens are the most common causes, and there is often concomitant ocular rosacea noted as well. The recurrent inflammation creates a nodule that can progress centrally across the cornea as what is termed a “marching phlyctenule,” trailed by a leash of superficial neovascularization.

Fortunately, this patient responded very well to treatment with 50% improvement in symptoms in 48 hours and is currently quiescent on prophylactic therapy of cyclosporine 0.05% eye drops and hypochlorous acid 0.02% lid spray.

### CASE SIX

A 59-year-old female came to our clinic reporting recurrent sharp eye pain in the morning in the right eye over the past month. She had penetrating keratoplasty (PKP) in the left eye that was doing well and had not seen an eye doctor for quite some time. Her vision was 20/50 in the right eye and 20/25 in the left eye. She mentioned decreased vision along with worsening glare at night over the last six months in the right eye. There was no inflammation in either cornea, no arcus, no sutures re-



**Case 5.** Slit lamp exam in this patient showed significant telangiectatic blepharitis, a corneal infiltrate with a leash of superficial neovascularization from the nasal limbus and a smaller-sized epithelial defect overlying the infiltrate.

maining in the transplant and the slit lamp exam revealed the findings in the photograph in the right eye only.

## Corneal Findings

11. What is your tentative diagnosis?
- Schnyder's dystrophy with recurrent corneal erosions.
  - Infectious crystalline keratopathy.
  - Anterior basement membrane dystrophy.
  - Lattice dystrophy with recurrent corneal erosions.
12. Which treatment is most appropriate?
- Superficial keratectomy and amniotic membrane.
  - Descemet's membrane endothelial keratoplasty.
  - Phototherapeutic keratectomy (PTK).
  - Culture and fortified antibiotics.

## Discussion

Corneal dystrophies can be difficult to differentiate, but this appearance of glass-like branching lines in the anterior stroma is classic for lattice corneal dystrophy, the most common of the stromal dystrophies. These patients suffer from recurrent corneal erosions, which can be managed medically to start, but often end up

undergoing PTK to reduce symptoms and improve vision. The opacities tend to coalesce with age and can impact visual acuity as the central cornea becomes more involved.

Historically, PKP was the surgery of choice to restore vision, but now deep anterior lamellar keratoplasty and PTK are excellent options as well and have gained popularity, given their lower risk profiles. The amyloid deposits can recur both after PTK and in corneal grafts after five to 10 years.

This patient opted for PTK and was educated on the likelihood of family members being affected with an autosomal-dominant inheritance pattern.

## THANKS FOR PLAYING!

We hope you not only fine-tuned your corneal diagnostic skills but had fun learning about these cases, which we believe can help you assess patients with similar conditions that may make their way to your office.

Check out our Instagram page, @kmkoptometrypro, to see more interesting cases and continue testing your knowledge, and let us know your thoughts! ■

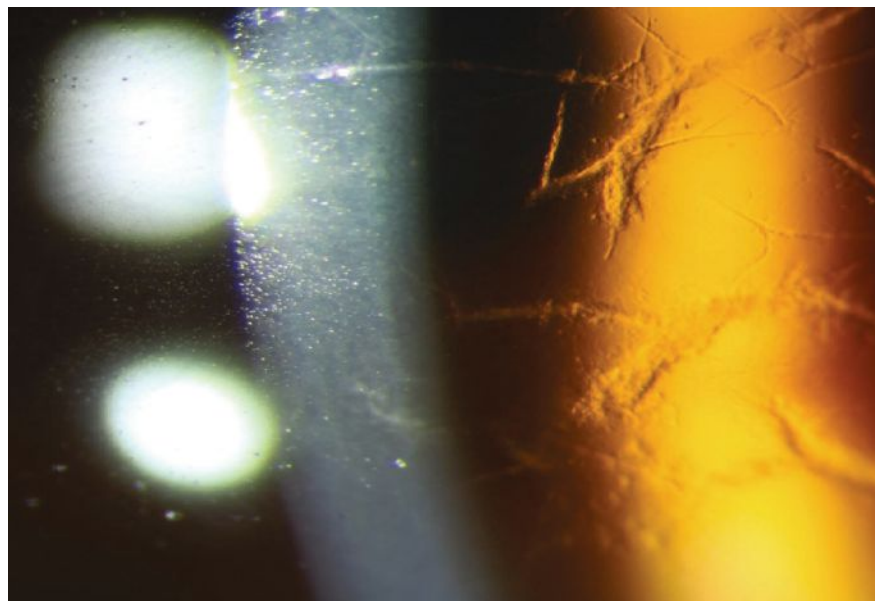
### Answers

- b
- c
- c
- d
- d
- d
- a
- a
- b
- d
- d
- c



# A NEW WAY TO EXPERIENCE REVIEW OF OPTOMETRY

Follow us on Instagram at @revoptom for striking clinical images, daily news headlines, issue previews and great content from the magazine—all formatted for mobile



Case 6. Notice the glass-like branching lines in the anterior stroma in this patient.

# IMPROVING THE GOLD STANDARD FOR CXL

Here's a look at what's currently available, what's in the works and what's on the horizon.



BY LILY ARENDT, OD  
SAN ANTONIO, TX

In 2016, we gained the ability to treat our keratoconus patients suffering from progressive vision loss through the FDA approval of epi-off corneal crosslinking. Historically, keratoconus patients were given glasses or contact lenses to help optimize their vision in the hopes that they would not progress. Thankfully, we can now slow and even halt keratoconus progression, reducing the number of patients who need corneal transplants.

As we continue to perform conventional epi-off corneal crosslinking, outside the United States crosslinking protocols are evolving and researchers are proposing new protocols that aim to offer a faster, more comfortable and effective way to help our patients. This article will look at various crosslinking methods, including accelerated, pulsed light, transepithelial and others that seek to improve on the gold standard, and discuss what these advancements and innovations could mean for us and our patients in 2022 and in the future.

## Conventional Epi-off Crosslinking

The current gold standard for corneal crosslinking in patients with progressive keratoconus and other corneal ectasia is the epi-off Dresden protocol created in 2003.<sup>1</sup> This process involves the removal of 8mm to 9mm of epithelium from the central cornea, followed by the application of a riboflavin solution every two minutes for 30 minutes. After the cornea is saturated, it is irradiated using 370nm UVA at an intensity of 3mW/cm<sup>2</sup> while riboflavin is applied every two minutes for another 30 minutes. A minimum corneal thickness of 400µm is required before UV irradiation or intraoperatively. This is the only FDA-approved crosslinking protocol in the United States, and it has proven to be effective at strengthening the cornea and halting progression in patients with keratoconus.

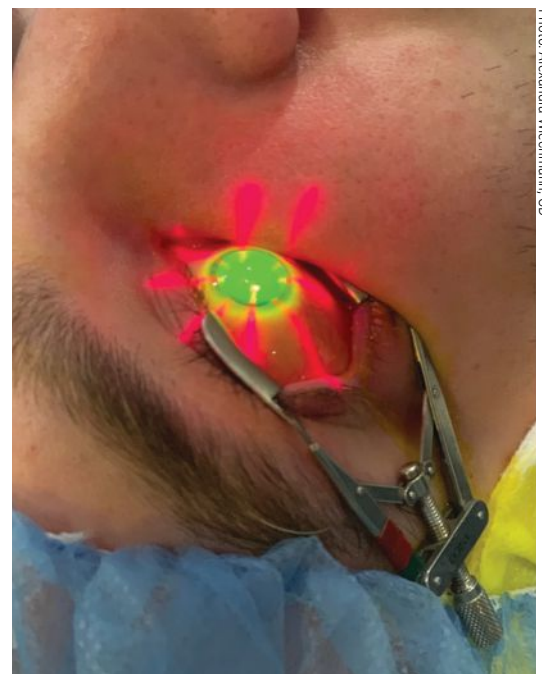


Photo: Alexandra Wiechmann, OD

**Epi-off corneal crosslinking in a patient with progressive keratoconus.**

While effective, the Dresden protocol has its disadvantages. Removal of the epithelium has a higher risk of pain and increased discomfort. It is greatest in the first three days postoperatively and often requires the use

### About the author

**Dr. Arendt** is an ocular disease and refractive surgery resident at Parkhurst Nuvision in San Antonio, TX. She is a member of the Refractive Surgery Alliance, American Optometric Association and Texas Optometric Association. She has no financial interests to disclose.



of topical or oral pain medications.<sup>2</sup> There is a chance that the patient will develop reduced visual acuity, but per the data submitted to the FDA, only 1% to 2% of patients had corneal opacity or scarring at the 12-month follow-up.<sup>3</sup>

Typical postoperative protocol includes application of a bandage contact lens immediately after treatment and frequent use of topical antibiotics during the first three to five days as the epithelium heals. Upon removal of the bandage contact lens, the patient is often switched to topical steroids to decrease inflammation and reduce the risk of persistent corneal haze. This is different than the postoperative haze typically seen after crosslinking between months one through six, which is not visually significant and does not require steroids for resolution.<sup>4</sup> Adding topical steroids before the corneal epithelium has fully healed has been linked to an increased risk of microbial keratitis.<sup>5</sup>

### Epi-off Accelerated Crosslinking

Conventional crosslinking lasts a minimum of one hour and is one of the longest procedures performed in ophthalmology clinics today. To make the process more efficient and less time-consuming, researchers and clinicians have been trying out new accelerated protocols with higher UVA irradiation employed for a shorter amount of time. This is based on the Busen-Roscoe law of reciprocity: “a response is determined by the product of the intensity and the duration of the stimulus.”<sup>6</sup> This means that for an accelerated protocol to achieve similar results as the Dresden protocol, it would need to maintain the same or have a cumulative energy of 5.4J/cm<sup>2</sup>.

In a 2021 study, the seven-year data comparing epi-off accelerated crosslinking and conventional epi-off crosslinking in progressive keratoconus was shared.<sup>7</sup> The accelerated protocol used UVA irradiation of 9mW/cm<sup>2</sup> for a duration of 10 minutes instead of the typical 30 minutes.<sup>7</sup> There was no significant difference between protocols.<sup>7</sup>

Conversely, another study included multiple accelerated protocols, including three minutes at 30mW/cm<sup>2</sup>, five minutes at 18mW/cm<sup>2</sup> and 10 minutes at 9mW/cm<sup>2</sup>, and found that each accelerated protocol was less effective at flattening the cornea when compared with conventional crosslinking.<sup>8</sup> While there is some promise of achieving successful crosslinking in shorter duration, more research is needed to find the ideal energy and duration.

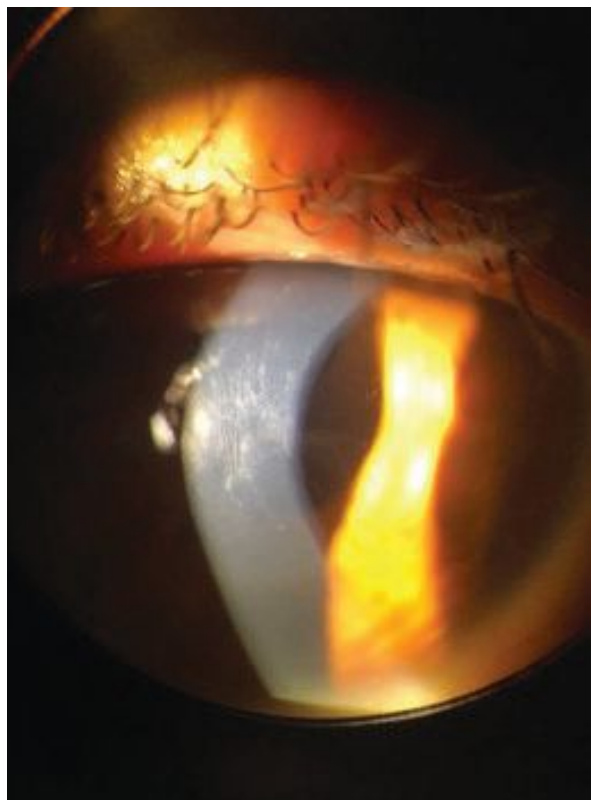
### The Importance of Oxygen

Not only is the energy and duration important but we now know that oxygen is also key in the crosslinking process.

For corneal crosslinking to occur, UVA must interact with both riboflavin and oxygen in the stroma to create oxygen free-radicals that kick-start the formation of covalent bonds between collagen molecules.

To illustrate the importance of oxygen in crosslinking, *ex vivo* epi-off crosslinking was performed on porcine corneas in both a regular oxygen environment (21%) and a low-oxygen environment (<0.1%).<sup>9</sup> The corneas that were crosslinked in the normal oxygen environment showed improved biomechanical stability, while the corneas in the low-oxygen environment had results similar to the non-treated controls.<sup>9</sup> This ultimately raised concerns over the effectiveness of transepithelial crosslinking (epi-on) where the corneal epithelium limits the amount of oxygen diffusion into the stroma.<sup>7</sup>

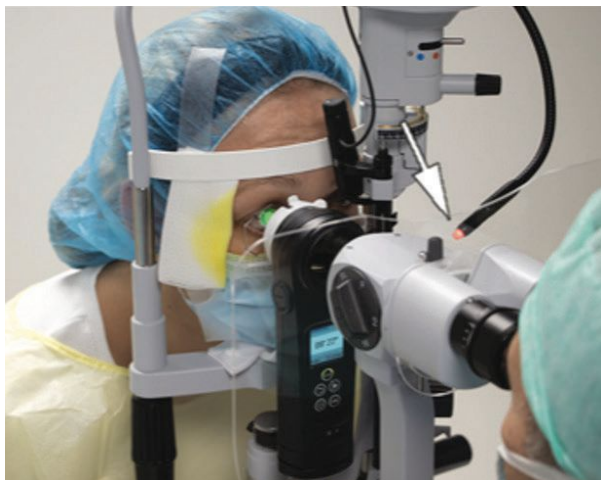In an effort to make epi-off crosslinking even more effective, it was determined that the level of oxygen in the stroma depletes within seconds



**Vogt's striae in a patient with advanced keratoconus before crosslinking.**

after exposure to UVA irradiation and takes three to four minutes to replenish to normal levels.<sup>10</sup> From this came a crosslinking method called pulsed light accelerated crosslinking, in which UVA irradiation is applied on and off repeatedly to allow for oxygen to diffuse back into the stroma. When compared with conventional crosslinking, this method alone was not as effective because it did not penetrate as far down into the cornea as conventional crosslinking but may prove to be a key component in future crosslinking protocols.<sup>11</sup>

To determine how much of the cornea is crosslinked, researchers measure what is called the stromal demarcation line, which represents a transition zone between crosslinked and non-crosslinked stromal tissue. It has been found to occur in histopathological studies as early as 24 hours and has been seen as early as two weeks on slit lamp biomicroscopy.<sup>12</sup> The presence and depth of a stromal demarcation line has been considered



The C-Eye by Emagine AG performs crosslinking on the patient at the slit lamp.<sup>25</sup>

an indirect measurement of treatment effectiveness. When comparing epi-off and transepithelial protocols, the demarcation line was significantly deeper with the former ( $275.05 \pm 41.80 \mu\text{m}$  vs.  $132.60 \pm 22.14 \mu\text{m}$ ).<sup>15</sup> The absence or shallow location of the demarcation line with transepithelial crosslinking is likely secondary to the shielding effect of the intact epithelium to riboflavin and UVA irradiation.

### Crosslinking Thin Corneas

As the epithelium can interfere with successful crosslinking, so too can the corneal thickness. Within the Dresden protocol, patients with thin pachymetry measurements can still undergo crosslinking if their corneas can be swelled to  $400 \mu\text{m}$  with a hypo-osmolar riboflavin solution. Unfortunately, there are many patients with moderate to advanced cases of keratoconus whose corneas will never swell to  $400 \mu\text{m}$  safely but who, arguably, have a greater need for crosslinking to avoid penetrating keratoplasty. To fill this need, there have been multiple attempts to successfully crosslink thinner corneas.

One technique called contact lens-assisted crosslinking involves placing a riboflavin-soaked daily disposable contact lens onto the cornea after removing the epithelium. The eye is then irradiated with UVA as performed in conventional crosslinking.

This technique was performed in a study that produced unsuccessful results, showing no change in corrected distance visual acuity or Kmax postoperatively.<sup>14</sup> This was attributed to the fact that contact lenses act as a barrier by preventing most UVA from reaching the stroma and interfering with oxygen diffusion.<sup>15</sup>

A new protocol was developed in 2021 to crosslink ultrathin

corneas. Referred to as the sub400 protocol, it uses a previously published algorithm to perform customized crosslinking based on each eye's corneal thickness after epithelial removal.<sup>16,17</sup> Each eye receives the same UVA irradiation ( $3\text{mW}/\text{cm}^2$ ), but the duration varies in order to crosslink without harming the endothelium.<sup>17</sup> Study results showed successful crosslinking in corneas ranging in thickness from  $214 \mu\text{m}$  to  $398 \mu\text{m}$  with keratoconus progression halted in 90% of eyes.<sup>17</sup>

While many researchers have been trying to effectively crosslink patients with thinner corneas, others are focused on creating a quicker, safer and more comfortable procedure for patients all while leaving the epithelium in place. This new wave in crosslinking is called transepithelial crosslinking, or epi-on crosslinking.

### Epi-On Crosslinking

Transepithelial crosslinking leaves the epithelium intact and has significantly less postoperative pain, offers a quicker visual recovery (with vision often returning to preoperative levels within two or three days) and allows patients to resume contact lens wear in one week.<sup>18</sup> There is also a decreased risk of postoperative infection and persistent corneal haze infrequently seen with conventional crosslinking. With the quick postoperative recov-

ery associated with transepithelial crosslinking, it raises the possibility of performing bilateral crosslinking on the same day.<sup>18</sup>

While the benefits may seem to speak for themselves, an intact epithelium is quite literally a barrier to a successful crosslinking procedure. Riboflavin is a hydrophilic, high molecular weight molecule that cannot penetrate through an intact epithelium on its own.<sup>19</sup> In a study evaluating the difference in biomechanical effect for both epi-on and epi-off crosslinking in rabbits, it was concluded that epi-on crosslinking produced only one fifth of the biomechanical rigidity in the cornea found after conventional crosslinking.<sup>20</sup> When this is translated to human corneas, it would likely equate to a 64% increase in rigidity with transepithelial vs. a 320% increase with conventional crosslinking.<sup>20</sup> The authors attributed this disparity to insufficient riboflavin diffusion through an intact epithelium.<sup>20</sup>

Certain chemicals can be used to enhance riboflavin permeability and often include benzalkonium chloride, gentamicin and ethylenediamine tetraacetic acid (EDTA).<sup>21,22</sup> Transepithelial crosslinking was performed on 26 eyes of patients between the ages of 11 and 26 with a riboflavin solution containing two permeability enhancers, trometamol and EDTA.<sup>23</sup> Results showed that both uncorrected and corrected distance acuity improved in the first three to six months before gradually returning to baseline over 24 months.<sup>23</sup> A similar trend was found with Kmax values.<sup>23</sup> Due to the ineffectiveness of treatment at the 12-month follow-up, the team ultimately retreated 50% of the patients younger than 18 with epi-off crosslinking.<sup>23</sup> It was concluded that transepithelial crosslinking was likely not a good option for halting progression in patients younger than 26 who have more aggressive forms of keratoconus.<sup>23</sup>

### Iontophoresis

Another way that researchers have tried improving riboflavin permeabil-

When it comes to ocular surface inflammation associated with dry eye disease,

# FLAREX® IS A PROVEN WINNER.



The power of Pred Forte\* [prednisolone acetate ophthalmic suspension, USP] 1%  
with the safety of FML\*<sup>1</sup> [fluorometholone ophthalmic suspension, USP] 0.1%

**97%** of ocular surface inflammation was resolved or improved with FLAREX vs 89% with Pred Forte.<sup>1</sup>

### Head-to-head with FML:



FLAREX was significantly more effective in the resolution of external non-infectious inflammatory conditions of the eye ( $P=0.03$ )<sup>1</sup>

### Head-to-head with Pred Forte:



FLAREX had comparable, non-inferiority efficacy in the treatment of external non-infectious inflammatory conditions of the eye<sup>1</sup>

### In the FDA pivotal clinical evaluation:



No reported adverse events in any treatment group when evaluated versus Pred Forte and FML<sup>1</sup>

**DISPENSE AS WRITTEN.  
THERE IS NO GENERIC EQUIVALENT OF FLAREX.  
BE SURE TO PRESCRIBE IT BY NAME.**

#### INDICATIONS AND USAGE

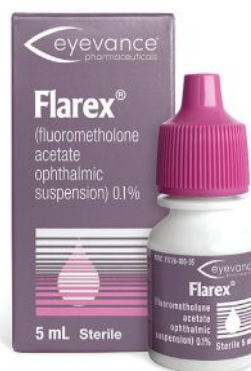FLAREX® (fluorometholone acetate ophthalmic suspension) is indicated for use in the treatment of steroid-responsive inflammatory conditions of the palpebral and bulbar conjunctiva, cornea, and anterior segment of the eye.

#### IMPORTANT SAFETY INFORMATION

**ADVERSE REACTIONS:** Glaucoma with optic nerve damage, visual acuity and field defects, cataract formation, secondary ocular infection following suppression of host response, and perforation of the globe may occur.

Please see the Full Prescribing Information on the next page.

Reference: 1. Leibowitz HM, Hyndiuk RA, Lindsey C, et al. Fluorometholone acetate: clinical evaluation in the treatment of external ocular inflammation. *Ann Ophthalmol.* 1984;16(12):1110-1115.



**Flarex®**  
(fluorometholone acetate ophthalmic suspension) 0.1%

LEARN MORE AT  
**MYFLAREX.COM**

**FLAREX NDC NUMBER: 71776-100-05**



© 2022 Eyeavance Pharmaceuticals LLC., a Santen company. All rights reserved.  
FLAREX® is a registered trademark of Eyeavance Pharmaceuticals LLC.  
\*All other trademarks are the property of their respective owners. FLA-20-AD-74-02 01/22



## **FLAREX® (fluorometholone acetate ophthalmic suspension) 0.1% Brief Summary**

### **INDICATIONS AND USAGE**

FLAREX (fluorometholone acetate ophthalmic suspension) is indicated for use in the treatment of steroid-responsive inflammatory conditions of the palpebral and bulbar conjunctiva, cornea, and anterior segment of the eye.

### **DOSAGE AND ADMINISTRATION**

**Shake Well Before Using.** One to two drops instilled into the conjunctival sac(s) four times daily. During the initial 24 to 48 hours, the dosage may be safely increased to two drops every two hours. If no improvement after two weeks, consult physician. Care should be taken not to discontinue therapy prematurely.

### **CONTRAINDICATIONS**

Contraindicated in acute superficial herpes simplex keratitis, vaccinia, varicella, and most other viral diseases of the cornea and conjunctiva; mycobacterial infection of the eye; fungal diseases; acute purulent untreated infections, which like other diseases caused by microorganisms, may be masked or enhanced by the presence of the steroid; and in those persons who have known hypersensitivity to any component of this preparation.

### **WARNINGS AND PRECAUTIONS**

#### **Topical Ophthalmic Use Only**

For topical ophthalmic use only. Not for injection.

#### **Intraocular Pressure Increase**

Prolonged use may result in glaucoma, damage to the optic nerve, and defects in visual acuity and visual field. It is advisable that the intraocular pressure be checked frequently.

#### **Cataracts**

Use of corticosteroids may result in cataract formation.

#### **Delayed Healing**

Topical ophthalmic corticosteroids may slow corneal wound healing. In those diseases causing thinning of the cornea or sclera, perforation has been known to occur with chronic use of topical steroids.

#### **Viral Infections**

Use in the treatment of herpes simplex infection requires great caution.

#### **Bacterial Infections**

Use of corticosteroids may suppress the host response and thus aid in the establishment of secondary ocular infections. Acute purulent infections of the eye may be masked or exacerbated by the presence of steroid medication.

#### **Fungal Infections**

Fungal infections of the cornea are particularly prone to develop coincidentally with long-term local steroid application. Fungus invasion must be considered in any persistent corneal ulceration where a steroid has been used or is in use.

#### **Contamination**

Do not touch dropper tip to any surface, as this may contaminate the suspension.

#### **Contact Lens Wear**

Contact lenses should be removed during instillation of FLAREX but may be reinserted after 15 minutes.

#### **Temporarily Blurred Vision**

Vision may be temporarily blurred following dosing with FLAREX. Care should be exercised in operating machinery or driving a motor vehicle.

## **ADVERSE REACTIONS**

### **Clinical Trials Experience**

Glaucoma with optic nerve damage, visual acuity and field defects, cataract formation, secondary ocular infection following suppression of host response, and perforation of the globe may occur.

### **Postmarketing Experience**

The following reaction has been identified during postmarketing use of FLAREX in clinical practice. Because reactions are reported voluntarily from a population of unknown size, estimates of frequency cannot be made. The reaction, which has been chosen for inclusion due to either its seriousness, frequency of reporting, possible causal connection to FLAREX, or a combination of these factors, includes dysgeusia.

## **USE IN SPECIFIC POPULATIONS**

### **Pregnancy**

Fluorometholone has been shown to be embryocidal and teratogenic in rabbits when administered at low multiples of the human ocular dose. Fluorometholone was applied ocularly to rabbits daily on days 6-18 of gestation, and dose-related fetal loss and fetal abnormalities including cleft palate, deformed rib cage, anomalous limbs, and neural abnormalities, such as encephalocele, craniorachischisis, and spina bifida, were observed. There are no adequate and well-controlled studies of fluorometholone in pregnant women, and it is not known whether fluorometholone can cause fetal harm when administered to a pregnant woman. Fluorometholone should be used during pregnancy only if the potential benefit justifies the potential risk to the fetus.

### **Lactation**

Systemically administered corticosteroids appear in human milk and could suppress growth, interfere with endogenous corticosteroid production, or cause other untoward effects. It is not known whether topical administration of corticosteroids could result in sufficient systemic absorption to produce detectable quantities in human milk. Because many drugs are excreted in human milk, caution should be exercised when FLAREX is administered to a nursing woman.

### **Pediatric Use**

Safety and effectiveness in pediatric patients have not been established.

### **Geriatric Use**

No overall differences in safety or effectiveness have been observed between elderly and younger patients.

## **NONCLINICAL TOXICOLOGY**

### **Carcinogenesis, Mutagenesis, Impairment of Fertility**

No studies have been conducted in animals or in humans to evaluate the possibility of these effects with fluorometholone.

## **PATIENT COUNSELING INFORMATION**

### **Risk of Contamination**

Do not touch dropper tip to any surface, as this may contaminate the suspension.

### **Use with Contact Lenses**

The preservative in FLAREX, benzalkonium chloride, may be absorbed by soft contact lenses. Contact lenses should be removed during instillation of FLAREX but may be reinserted 15 minutes after instillation.

### **Temporarily Blurred Vision**

Patients should be advised that their vision may be temporarily blurred following dosing with FLAREX. Care should be exercised in operating machinery or driving a motor vehicle.

### **Rx Only**

**Distributed by:** Santen Pharmaceutical Co., Ltd.  
Fort Worth, TX 76102



© 2022 Eyeavance Pharmaceuticals LLC., a Santen company. All rights reserved.  
FLAREX® is a registered trademark of Eyeavance Pharmaceuticals LLC.  
FLA-003-02 01/22

ity with transepithelial crosslinking is with iontophoresis, which is the use of an electrical current to enhance molecule penetration into a tissue. In one study, a 1mA electrical current was used to improve riboflavin absorption through an intact epithelium.<sup>24</sup> At the two-year follow-up, there was a 20% failure rate in the iontophoresis crosslinking group compared with a 7.5% failure rate with conventional crosslinking.<sup>24</sup> The same study also evaluated for the presence of a corneal demarcation line at the two-year follow-up and determined that it was only visible in the iontophoresis corneas 35% of the time compared with 95% in conventional crosslinking cases.<sup>24</sup> While an effective way to improve riboflavin penetration through the epithelium, iontophoresis alone does not appear to be the trick to successful epi-on crosslinking.

With the continuous effort and the multitude of modifications in crosslinking protocols, researchers are bound to achieve a successful transepithelial crosslinking result that rivals conventional epi-off crosslinking. Throughout the literature, the consensus appears to be that we need clinical trials that show effective crosslinking with longer follow-ups and larger sample sizes. Until then, I believe we should focus on increasing access to care for patients who need crosslinking. One research team out of Zurich, led by Farhad Hafazi, MD, PhD, has created a device that aims to do just that.

### Crosslinking at the Slit Lamp

The C-Eye by Emagine AG, a UVA illumination device, was designed to be mounted onto the slit lamp, allowing patients to receive crosslinking while seated in an exam room.<sup>25</sup> For epi-off crosslinking, the epithelium is removed at the slit lamp using an ethanol-based technique.<sup>25</sup> After, the patient is relocated to a reclining chair where corneal thickness is measured while riboflavin is instilled.<sup>25</sup> They are then moved back to the slit lamp for UVA irradiation treatment lasting for

10 minutes.<sup>25</sup> The creator of this device says that it will “increase accessibility to treatment globally and reduce overall costs related to the procedure” by moving it from the operating room to the exam room.<sup>25</sup> Technology like this may be the next step toward optometrists performing crosslinking. At the start of 2022, there are currently three states whose scope of practice allows ODs to perform the procedure: Virginia, Louisiana and Oklahoma.

### What's Next?

Glaukos, the creator of the first-generation iLink therapy currently FDA-approved for epi-off corneal crosslinking, is currently vying for FDA approval of an epi-on crosslinking protocol. In February 2021, Glaukos shared positive results from its pivotal Phase III trial for iLink epi-on therapy.<sup>26</sup> The study included 279 eyes randomized in a 2:1 ratio to receive transepithelial therapy or placebo-controlled treatment.<sup>26</sup> The study demonstrated a statistically significant improvement in Kmax at six months from baseline (-1.00D), meeting the primary efficacy endpoint.<sup>26</sup> The company also shared that the treatment was well-tolerated, with no patients leaving the study due to adverse events.<sup>26</sup> The next step for Glaukos includes submitting an NDA this year, and the company is aiming for FDA approval in 2023.<sup>26</sup>

### Takeaways

There are many protocols that have been created to try and improve on the gold standard of crosslinking, the epi-off Dresden protocol, which is currently the only FDA-approved crosslinking method in the United States. Researchers from all over the world are looking for ways to make the procedure faster, more effective, more comfortable and even more accessible to patients. Until we find a better option, we can rest assured knowing that we do currently have a way to halt progression in our patients with progressive keratoconus and improve the quality of their lives in invaluable ways. ■

- Wollensak G, Spörl E, Seiler T. Treatment of keratoconus by collagen cross linking. *Ophthalmologie*. 2003;100(1):44-9.
- Ghanem V, Ghanem R, De Oliveira R. Postoperative pain after corneal collagen cross-linking. *Cornea*. 2013;32(1):20-4.
- Food and Drug Administration. Photrex. [www.accessdata.fda.gov/drugsatfda\\_docs/label/2016/203324s000lbl.pdf](http://www.accessdata.fda.gov/drugsatfda_docs/label/2016/203324s000lbl.pdf). Accessed March 15, 2022.
- Greenstein SA, Fry KL, Bhatt J, Hersh PS. Natural history of corneal haze after collagen crosslinking for keratoconus and corneal ectasia: Scheimpflug and biomicroscopic analysis. *J Cataract Refract Surg*. 2010;36(12):2105-14.
- Tzamalís A, Romano V, Cheeseman R, et al. Bandage contact lens and topical steroids are risk factors for the development of microbial keratitis after epithelium-off CXL. *BMJ Open Ophthalmol*. 2019;4(1):e000231.
- Elsevier's Dictionary of Psychological Theories.
- Nicula C, Rednik A, Nicula A, et al. Comparative results between "epi-off" accelerated and "epi-off" standard corneal collagen crosslinking-UVA in progressive keratoconus - 7 years of follow-up. *Ther Clin Risk Manag*. 2021;17:975-88.
- Mirafteb M, Hashemi H, Abdollahi M, et al. The efficacy of standard versus accelerated epi-off corneal cross-linking protocols: a systematic review and sub-group analysis. *Int Ophthalmol*. 2019;39(11):2675-83.
- Richoz O, Hammer A, Tabibian D, et al. The biomechanical effect of corneal collagen cross-linking (CXL) with riboflavin and UV-A is oxygen dependent. *Transl Vis Sci Technol*. 2013;2(7):6.
- Kamaev P, Friedman M, Sherr E, Muller D. Photochemical kinetics of corneal cross-linking with riboflavin. *Invest Ophthalmol Vis Sci*. 2012;53(4):2360-7.
- Jiang L, Jiang W, Qiu S. Conventional vs. pulsed-light accelerated corneal collagen cross-linking for the treatment of progressive keratoconus: 12-month results from a prospective study. *Exp Ther Med*. 2017;14(5):4238-44.
- Seiler T, Hafezi F. Corneal cross-linking-induced stromal demarcation line. *Cornea*. 2006;25(9):1057-9.
- Spadea L, Di Genova L, Tonti E. Corneal stromal demarcation line after 4 protocols of corneal crosslinking in keratoconus determined with anterior segment optical coherence tomography. *J Cataract Refract Surg*. 2018;44(5):596-602.
- Jacob S, Kumar D, Agarwal A, et al. Contact lens-assisted collagen cross-linking (CACXL): a new technique for cross-linking thin corneas. *J Refract Surg*. 2014;30(6):366-72.
- Chen X, Stojanovic A, Eidel J, Ulheim T. Corneal collagen cross-linking (CXL) in thin corneas. *Eye Vis (London)*. 2015;2(1):15.
- Kling S, Hafezi F. An algorithm to predict the biomechanical stiffening effect in corneal cross-linking. *J Refract Surg*. 2017;33(2):128-36.
- Hafezi F, Kling S, Gilardoni F, et al. Individualized corneal cross-linking with riboflavin and UV-A in ultrathin corneas: the sub400 protocol. *Am J Ophthalmol*. 2021;224:133-42.
- Stulting RD, Trattler WB, Wolfson JM, et al. Corneal crosslinking without epithelial removal. *J Cataract Refract Surg*. 2018;44(11):1363-70.
- Baiocchi S, Mazzotta C, Cerretani D, et al. Corneal crosslinking: Riboflavin concentration in corneal stroma exposed with and without epithelium. *J Cataract Refract Surg*. 2009;35(5):893-9.
- Wollensak G, Iomdina E. Biomechanical and histological changes after corneal crosslinking with and without epithelial debridement. *J Cataract Refract Surg*. 2009;35(3):540-6.
- Chang S, Chi R, Wu C, Su M. Benzalkonium chloride and gentamicin cause a leak in corneal epithelial cell membrane. *Exp Eye Res*. 2000;71(1):3-10.
- Majumdar S, Hippalgaonkar K, Repka M. Effect of chitosan, benzalkonium chloride and ethylenediaminetetraacetic acid on permeation of acyclovir across isolated rabbit cornea. *Int J Pharm*. 2008;348(1):175-8.
- Caporossi A, Mazzotta C, Paradiso AL, et al. Transepithelial corneal collagen crosslinking for progressive keratoconus: 24-month clinical results. *J Cataract Refract Surg*. 2013;39(8):1157-63.
- Jouve L, Borderie V, Sandali O, et al. Conventional and iontophoresis corneal cross-linking for keratoconus: efficacy and assessment by optical coherence tomography and confocal microscopy. *Cornea*. 2017;36(2):153-62.
- Hafezi F, Richoz O, Torres-Netto E, et al. Corneal cross-linking at the slit lamp. *J Refract Surg*. 2021;37(2):78-82.
- Glaukos announces positive phase 3 trial results for iLink epi-on investigational therapy. *Eyewire*. February 25, 2021. <https://www.eyewire.com/news/articles/glaukos-announces-positive-phase-3-trial-results-for-ilink-epi-on-investigational-therapy/>. Accessed March 15, 2022.

Earn 2 CE Credits  
(COPE APPROVED)

# PIECING TOGETHER THE HSVK PUZZLE

Given the seriousness of this condition, proper differential diagnosis and medical management is key.



BY ALEXANDER MARTINEZ, OD,  
AND SHANNON K. LEON, OD  
SAN ANTONIO, TX

Throughout our careers as eye-care professionals, we encounter many concerning conditions with the potential for devastating visual outcomes. One in particular is the often-frustrating herpes simplex virus keratitis (HSVK). Due to its varied presentation and recurrence rate, delays in proper diagnosis and treatment often lead to corneal scarring and poor visual outcomes. Thus, it has become increasingly important to recognize the signs and symptoms of this condition and promptly initiate appropriate management. By increasing our understanding of HSVK, we can improve our patients' overall comfort and their visual prognosis.

## Understanding the Virus

To truly recognize why HSVK can be so visually devastating, we must first understand the pathophysiology that makes this pathogen so prevalent.



Epithelial disease presents with dendritic lesions that are characteristic of the condition.

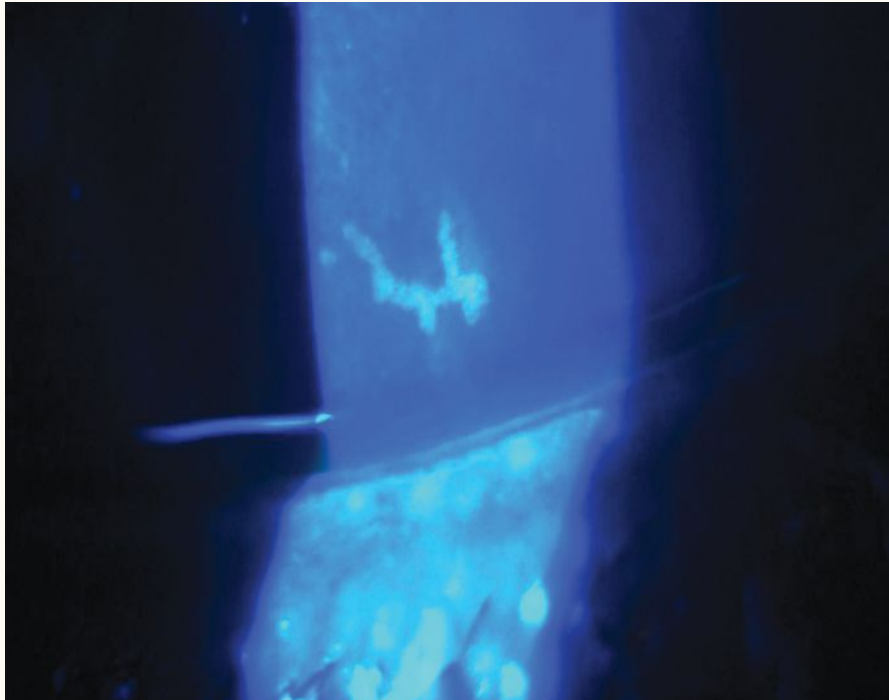
The herpes simplex virus (HSV) is a linear, double-stranded DNA virus that belongs to the *Herpesviridae* family.<sup>1</sup> There are over 100 known herpes viruses within this family, including HSV-1, HSV-2, varicella-zoster virus, cytomegalovirus and the Epstein-Barr virus.<sup>2</sup>

HSV is unique in its ability to reproduce quickly in a variety of tissues and establish latency, which can be reactivated at a later time.<sup>3</sup> This has resulted in HSVK becoming the leading cause of infectious corneal blindness among developed nations.<sup>3</sup> In fact, over 10 million people worldwide may

About the  
authors

Drs. Martinez and Leon practice at the South Texas Eye Institute in San Antonio, TX. They are graduates of the Rosenberg School of Optometry, where they completed their optometry degrees and residencies in primary care. They have no financial interests to disclose.





**Use of vital dye staining is extremely helpful in distinguishing dendrites and making an accurate diagnosis.**

have herpetic eye disease, with the seroprevalence being over 50% in the United States alone.<sup>3</sup>

HSV-1 is the most common serotype associated with ocular infections. Ocular involvement rarely stems from HSV-2, a disease typically sexually transmitted through the transferral of infected secretions.<sup>3</sup> There are two main stages of infection in the pathophysiology of HSV-1: primary infection and reactivation (or recur-

rence).<sup>3</sup> Primary infection occurs through direct contact with mucous membranes of the face, lips or eyes due to trigeminal nerve innervation of all three structures. These primary infections commonly cause contagious cold sores or fever blisters in and around the mouth. They rarely involve the cornea.<sup>3,4</sup> Signs and symptoms of corneal manifestations associated with this phase of the infection are often subclinical and mild.<sup>3</sup>

Once a primary infection occurs in the mucous membrane of the eye, the virus then travels down to the trigeminal ganglion, where it becomes latent.<sup>3</sup> Any event that stresses the immune system, whether it be physiological (e.g., fever) or otherwise (e.g., environmental stressors), can then result in reactivation of the latent virus.<sup>3</sup> After the virus is reactivated it travels along the ophthalmic branch of the trigeminal ganglion to the cornea, resulting in either superficial epithelial replication, which presents as dendritic keratitis, or in an immune-mediated response (stromal or endothelial keratitis).<sup>3</sup>

### Making the Correct Diagnosis

HSVK can have various clinical manifestations, making it challenging for the clinician to determine a proper diagnosis. It is essential to first obtain a thorough case history to gather any relevant information that can assist in the diagnosis. Important questions to ask include recent use of topical or oral corticosteroids, ocular trauma, ocular surgeries, psychological stress, history of HSVK, recent illnesses, fever, extraordinary ultraviolet light exposure, immunosuppression, history of sexually transmitted diseases and hormonal changes.<sup>5-7</sup> Physical stimuli, emotional triggers and corticosteroid use can weaken the immune system, allowing the virus to reactivate and causing ocular HSV.

**Release Date:** April 15, 2022

**Expiration Date:** April 15, 2025

**Estimated Time to Complete Activity:** two hours

Jointly provided by the Postgraduate Institute for Medicine (PIM) and Review Education Group

**Educational Objectives:** After completing this activity, the participant should be better able to:

- Understand the presentations of herpes simplex virus keratitis.
- Distinguish between HSVK and differential diagnoses.
- Diagnose patients with herpes simplex virus keratitis.
- Medically manage herpes simplex virus keratitis cases.

**Target Audience:** This activity is intended for optometrists engaged in managing herpes simplex virus keratitis patients.

**Accreditation Statement:** In support of improving patient care, this activity has been planned and implemented by PIM and the Review Education Group. PIM is jointly accredited by the Accreditation Council for Continuing Medical Education, the



Accreditation Council for Pharmacy Education and the American Nurses Credentialing Center to provide CE for the healthcare team. PIM is accredited by COPE to provide CE to optometrists.

**Reviewed by:** Salus University, Elkins Park, PA  **Faculty/Editorial Board:** Alexander Martinez, OD, and Shannon K. Leon, OD

**Credit Statement:** This course is COPE-approved for two hours of CE credit. Activity #123706 and course ID 77910-TD. Check with your local state licensing board to see if this counts toward your CE requirement for relicensure.

**Disclosure Statements:** PIM requires faculty, planners and others in control of educational content to disclose all their financial relationships with ineligible companies. All identified conflicts of interest are thoroughly vetted and mitigated according to PIM policy. PIM is committed to providing its learners with high-quality, accredited CE activities and related materials that promote improvements or quality in healthcare and not a specific proprietary business interest of an ineligible company.

Those involved reported the following relevant financial relationships with ineligible entities related to the educational content of this CE activity: *Authors:* Drs. Martinez and Leon have no financial interests to disclose. *Managers and Editorial Staff:* The PIM planners and managers have nothing to disclose. The Review Education Group planners, managers and editorial staff have nothing to disclose.

**Table 1. Topical Antiviral Therapy Dosing<sup>13</sup>**

Antiviral	Dosage
Trifluridine ophthalmic solution 1% (Viroptic)	One drop nine times a day for seven days, reduced to five times a day if the ulcer healed after day seven ( $\leq 21$ days)
Ganciclovir gel 0.15% (Zirgan)	One drop five times a day until the ulcer resolves, reduced to TID for seven days
Acyclovir ointment 3% (Avaclryl)	Not available in the United States

Next, a gross examination of the facial adnexa can reveal vesicles on the forehead, eyelids or nose that may respect the vertical midline, which would narrow down the diagnosis to herpes zoster ophthalmicus, not HSVK. The latter typically presents with an acute onset of symptoms of unilateral ocular pain, redness, photophobia, tearing, itching, foreign body sensation, irritation and blurred vision.<sup>1</sup>

HSVK can usually be diagnosed with a slit lamp biomicroscopy exam alone and without any laboratory testing. Corneal sensitivity evaluation is also important and is easily performed using a cotton wisp by first testing the unaffected cornea to determine any differences in corneal sensation compared with the non-affected eye. Decreased corneal sensation is a hallmark for herpetic keratitis, unlike other microbial infections where there is an increase in sensation.<sup>8</sup>

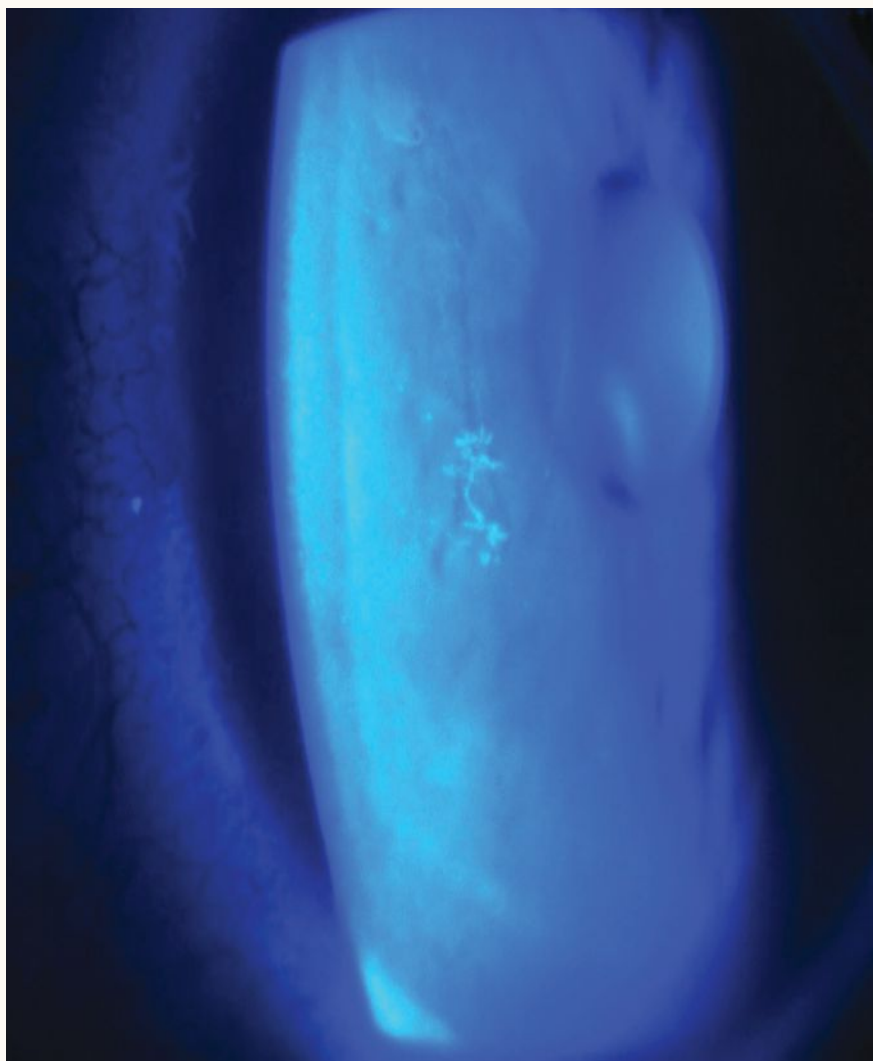
Corneal sensory loss is a common sequela from both herpes simplex keratitis and herpes zoster ophthalmicus, with more severity in the latter.<sup>9</sup> The degree of corneal sensory loss is directly proportional to the number of recurrences.<sup>9</sup> During the slit lamp examination, dyes such as fluorescein, rose bengal and lissamine green are essential in assisting the clinical diagnosis of HSVK. Corneal dendrites are easily seen with fluorescein dye, since the body of the dendrite will illuminate as there is epithelial breakdown and decaying cells present. On the other hand, rose bengal and lissamine green will stain the dendrite's viral infected cells at the margins of the swollen terminal bulbs.<sup>6,7,10</sup>

These dyes also assist the clinician in correctly distinguishing a corneal dendrite from a pseudodendrite caused by herpes zoster ophthalmicus. Pseudodendrites have raised centers filled with swollen cells without terminal bulbs, ulceration or

branching.<sup>11,12</sup> These epithelial cells are not adherent, typically seen in the periphery and appear to be stuck.<sup>11,12</sup> They also stain poorly with vital dyes, producing a negative staining with fluorescein and rose bengal.<sup>6,12</sup>

A slit lamp examination is typically sufficient in diagnosing HSVK; however, laboratory and diagnostic tests are available for atypical cases where a diagnosis of HSVK cannot easily be made. The main diagnostic tests for HSVK include culturing, direct fluorescent antibody (DFA) and polymerase chain reaction (PCR). Other, less commonly used diagnostic tests include cytology, enzyme-linked immunosorbent assay and serology.<sup>13</sup>

Culturing HSV-1 is considered the



**Even patients who only demonstrate small dendrites such as this one can present with significant pain and discomfort.**

**Table 2. Oral Antiviral Therapy Dosing<sup>8,13</sup>**

Antiviral	Dosage
<b>HSV Epithelial Keratitis: Dendrite (seven to 10 days)</b>	
Acyclovir	400mg five times daily
Valacyclovir	500mg two times daily
Famciclovir	250mg two times daily
<b>HSV Epithelial Keratitis: Geographic Ulcer (14 to 21 days)</b>	
Acyclovir	800mg five times daily
Valacyclovir	1g three times daily
Famciclovir	500mg two times daily
<b>HSV Stromal Keratitis Without Ulceration* (≥10 weeks)</b>	
Acyclovir	400mg two times daily
Valacyclovir	500mg one time daily
Famciclovir	250mg two times daily
<b>HSV Stromal Keratitis With Ulceration** (seven to 10 days)</b>	
Acyclovir	800mg three to five times daily
Valacyclovir	1g three times daily
Famciclovir	500mg two times daily
<b>HSV Endothelial Keratitis*** (variable timeframe)</b>	
Acyclovir	400mg three to five times daily
Valacyclovir	500mg two times daily
Famciclovir	250mg two times daily
<b>Prophylaxis of Recurrent HSVK (≥one year)</b>	
Acyclovir	400mg two times daily
Valacyclovir	500mg one time daily
Famciclovir	250mg two times daily
<p>* Prophylactic dose of oral antiviral with a therapeutic dose of topical corticosteroid.</p> <p>** Therapeutic dose of oral antiviral with a limited dose of topical corticosteroid. Oral antiviral is reduced to prophylactic dose after seven to 10 days and maintained as long as topical corticosteroids are used.</p> <p>*** Therapeutic dose of antiviral with a therapeutic dose of topical corticosteroid. Oral antiviral is reduced to prophylactic dose after seven to 10 days and maintained as long as topical corticosteroids are used.</p>	

gold standard. Culturing a virus is a misnomer as a virus cannot grow on a culture plate of agar but can infect other cells on the plate, thus proliferating the virus. Only cases of HSV epithelial keratitis can be cultured, since a virus cannot be cultured from the stroma or endothelium.<sup>6,13</sup> Culturing tends to have high specificity and low sensitivity and typically takes up to 10 days to obtain the results.<sup>13</sup>

DFA and PCR have proven to be reliable alternatives in determining the presence of HSV-1. DFA detects

any HSV-1 antigens and provides rapid results with lower specificity than PCR, which detects viral DNA and is shown to be as sensitive and specific as a cell culture.<sup>13</sup> A limitation of PCR is its inability to differentiate between pathological levels of HSV and normal shedding of HSV in the tear film.<sup>13</sup> Serology is not commonly used, since a majority of people have already had prior exposure to HSV; thus, it has low specificity.<sup>8,13</sup> Serology is more useful in younger patients where primary infections are more common.<sup>13</sup>

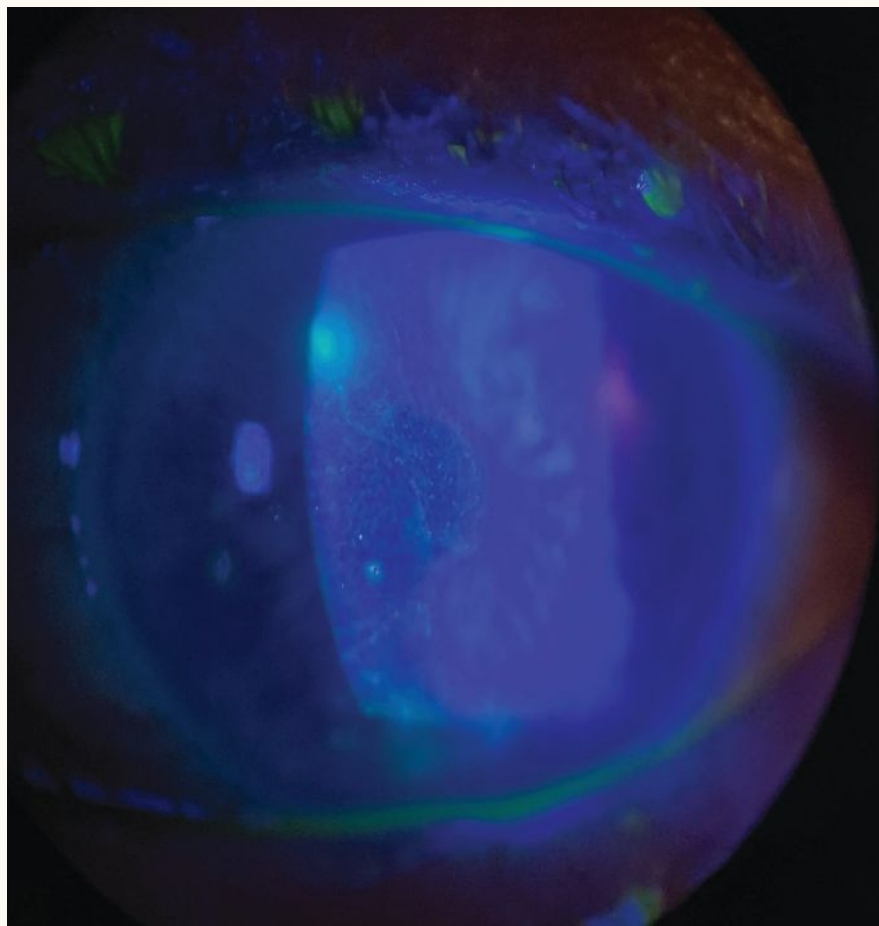
## Clinical Presentations

HSVK can present with different corneal manifestations depending on what layer of the cornea the virus raids: the epithelium, stroma and/or endothelium.<sup>1</sup> Herpes simplex epithelial keratitis is the most common subtype of HSVK and is responsible for 50% to 80% of all ocular herpes infections.<sup>14</sup> Within 12 to 24 hours, infected epithelial cells form punctate vesicles. These vesicles, the beginning stages of dendrites, are formed by the swollen cell nuclei filled with replicating DNA viral load.<sup>5,15</sup> As epithelial cells swell, apoptose and shed the virus, adjacent cells become infiltrated, ultimately causing a corneal dendrite.

These dendritic lesions present with granular epithelium, branching linear pattern, terminal bulbs and raised gray edges.<sup>5,16</sup> The body of the dendrite stains with fluorescein dye while the borders of the terminal bulbs stain with rose bengal or lissamine green. The dendritic lesion may progress and form a geographic ulcer in 25% of cases.<sup>5</sup> HSV epithelial keratitis is classically the most painful type of HSVK as epithelial cells are invaded by the herpes virus, causing epithelial cell death. Common symptoms include pain, tearing, photophobia, foreign body sensation, conjunctival injection and decreased vision.<sup>15</sup> HSV stromal keratitis has two subtypes: HSV stromal keratitis with epithelial ulceration (necrotizing) and HSV stromal keratitis without epithelial ulceration (non-necrotizing). Meanwhile, HSV endothelial keratitis can be described as diffuse, linear or disciform.<sup>5,16</sup>

Herpes simplex stromal keratitis is considered an immune-mediated inflammatory response caused by viral antigens in the stroma. HSV stromal keratitis can present with or without epithelial ulceration. Herpes simplex stromal keratitis with ulceration is a rare form of HSV keratitis likely caused by live virus proliferation in the stroma.<sup>10</sup> It presents as a gray-white opaque stromal edema with necrosis and ulceration of the overlying corneal epithelium.<sup>5</sup> HSV stromal keratitis





**A resolving central dendrite with multifocal stromal keratitis with ulceration in a patient with an aggressive form of ocular HSVK who is recovering from COVID-19.**

with ulceration is commonly misdiagnosed as bacterial keratitis due to its clinical presentation of an epithelial defect with a stromal infiltrate. Corneal neovascularization can originate from the periphery and encroach toward the inflammatory site of the stroma. If left untreated, HSV stromal keratitis can develop corneal thinning, ulceration and conclusive perforation.<sup>17</sup> Other complications include the formation of a corneal abscess, keratic precipitates, anterior uveitis and elevated intraocular pressure (IOP).<sup>5</sup>

Common symptoms for both HSV stromal keratitis with or without ulceration include photophobia, blurred vision, redness, photophobia and tearing.<sup>17</sup> HSV stromal keratitis without ulceration is the most common form of HSV stromal keratitis. This subtype is sometimes referred to as “immune-mediated” or “non-necrotizing” and

can be recurrent. It is caused by an inflammatory response against retained HSV antigens from a previous HSVK episode inducing an antibody-complement cascade in the stroma.<sup>5,10</sup> This stromal inflammatory response can occur in the latent or active stages of the infection.<sup>6</sup> Herpes simplex stromal keratitis without epithelial ulceration presents as a stromal infiltrate without any epithelial disruption. The stromal inflammation may be focal, multifocal, diffuse and/or associated with anterior uveitis. If chronic, it can cause neovascularization, corneal scarring and corneal thinning.<sup>5</sup>

HSV endothelial keratitis is another form of an immune-mediated response where the herpes virus spreads to the endothelium, causing endothelial cell dysfunction.<sup>14</sup> Unlike HSV stromal keratitis, about half of these cases have no prior history of HSV epithelial

keratitis and can occur independently from other forms of HSVK. HSV endothelial keratitis is commonly referred to as disciform keratitis; contrastingly, *disciform* is not completely accurate as HSV endothelial keratitis can also be considered linear or diffuse. The orientation of the associated keratic precipitates built up on the posterior wall of the endothelium and the extent of the stromal edema determines its classification.<sup>14</sup> Disciform keratitis is the most common presentation of HSV endothelial keratitis, with disc-shaped stromal edema with underlying semi-circle-shaped keratic precipitates.<sup>5,16</sup>

Like the names suggest, linear endothelial HSVK has a vertical lined pattern of keratic precipitates and diffuse endothelial HSVK has keratic precipitates diffusely scattered across the entirety of the cornea. Clinical features of HSV endothelial keratitis include stromal edema caused by stromal deturgescence, overlying epithelial edema, inflammation of the endothelium with underlying keratic precipitates without significant anterior uveitis and elevated IOP.<sup>13</sup>

Common symptoms are pain, redness, tearing, blurred vision and photophobia. Recurrent endothelial keratitis can cause endothelial cell loss, chronic corneal edema, scarring, corneal structural damage and irregular astigmatism.<sup>1</sup>

### Differential Diagnosis

One of the most difficult aspects of diagnosing and managing patients with HSVK is its wide variety of clinical manifestations. Due to its prevalence, consider HSVK as a possible diagnosis in any patient who presents with a unilateral red eye, especially with staining on the cornea. Familiarizing yourself with the differentials that may exhibit similar characteristics to HSVK will help to prevent delay in diagnosis and initiation of treatment.

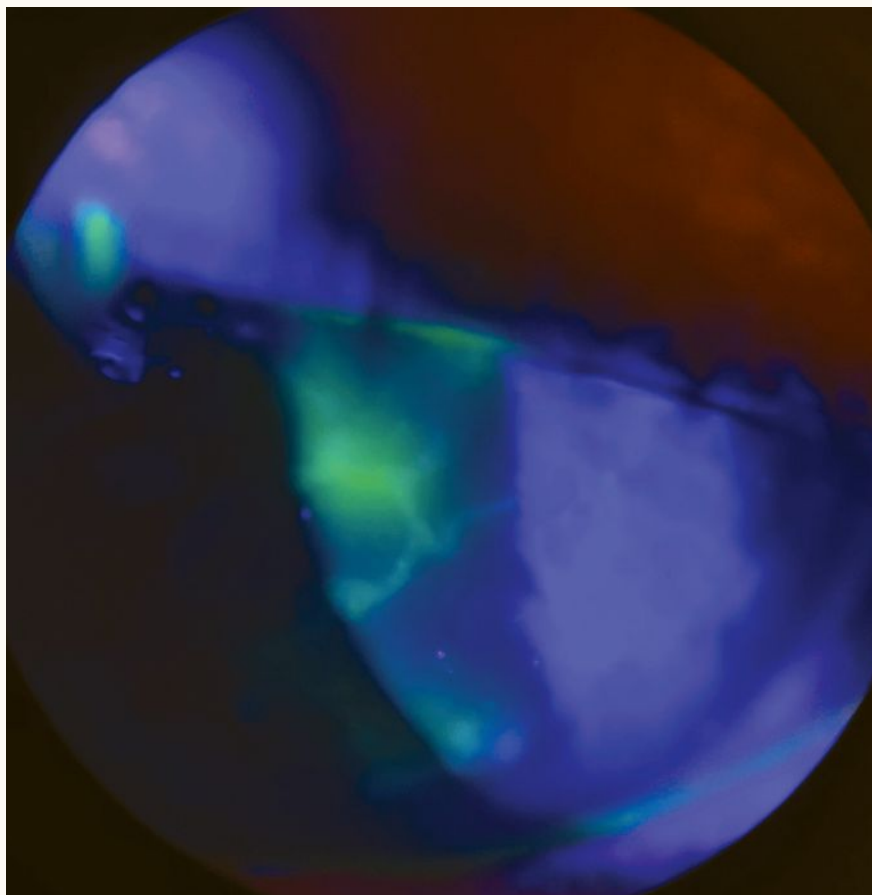
Due to the fact that HSVK can impact multiple layers of the cornea, the differentials may vary based on which layer of tissue is impacted. For example, dendritic epithelial keratitis may have different differentials than

those of stromal or endothelial keratitis, although in some cases these may overlap. HSV epithelial keratitis differentials should include other types of infectious and noninfectious keratitis that may cause dendrite-like or geographic-like lesions on the cornea. This list may be extensive and should include varicella zoster viral keratitis, *Acanthamoeba* keratitis, microbial keratitis without stromal involvement (*i.e.*, bacterial/fungal), *Chlamydial* epithelial keratitis, Epstein-Barr epithelial keratitis, recurrent corneal erosions, exposure keratopathy, Thygeson's superficial punctate keratitis and epithelial basement membrane dystrophy (EBMD).<sup>13</sup>

Many of these conditions, such as *Acanthamoeba* keratitis and microbial keratitis, may be difficult to distinguish due to dendrite-like corneal presentations. Many times, these conditions can be differentiated based on a thorough clinical history. *Acanthamoeba* and bacterial keratitis are commonly associated with contact lens wear and water exposure. Fungal keratitis is likely associated with corneal insult or injury due to vegetation. HSVK can occur without contact lens use, water exposure or vegetative trauma. Other conditions such as Thygeson's and EBMD differ from HSVK in that they most commonly present bilaterally, whereas bilateral HSVK is very rare.

Apart from HSV epithelial keratitis, HSV stromal and endothelial keratitis have their own list of differentials to consider. These separate conditions can also present with interstitial keratitis and keratouveitis that mimic the presentation of HSV stromal and endothelial disease.<sup>13</sup> These differentials may include microbial keratitis with stromal involvement (any type), syphilis, Cogan's syndrome, measles keratitis, mumps keratitis, Lyme disease, Posner-Schlossman syndrome, cytomegalovirus endothelial keratitis and corneal graft rejection.<sup>13</sup>

In many cases of HSVK differentials, possible diagnoses may be eliminated based on a thorough case history and clinical discussion with



**A corneal dendrite can be large and cause severe pain and discomfort.**

the patient. However, in cases where the puzzle cannot be solved based on verbal communication alone, use of corneal staining or, in some cases, laboratory testing may be needed to diagnose HSVK with confidence.

### Treatment and Management

Complicating the proper diagnosis and treatment of HSV are the multiple corneal layers affected. The indicated medications and their dosages vary depending on the subtype of HSVK present. Treatment for HSVK includes oral antivirals, topical antivirals and topical corticosteroids; however, not all available treatment options are appropriate for each HSVK subtype. Thus, it is important to correctly diagnose the subtype of HSVK to formulate an appropriate treatment plan.

There are three topical antivirals approved by the FDA as treatment for HSVK: trifluridine ophthalmic solution 1%, ganciclovir gel 0.15%

and acyclovir ointment 3% (*Table 1*).<sup>13</sup> Acyclovir ointment 3% is currently not available to be prescribed as it is still on the discontinued drug product list for reasons other than safety and effectiveness.<sup>18</sup> Trifluridine ophthalmic solution 1% is known to be more toxic to the ocular surface than ganciclovir gel 0.15% since it is nonselective against DNA synthesis of both normal and viral-infected cells.<sup>5</sup> The cellular and ocular surface toxicity caused by trifluridine ophthalmic solution 1% can result in epithelial keratitis and delayed reepithelization. In contrast, ganciclovir gel 0.15% does not target the DNA of healthy cells, thus causing less ocular surface toxicity.

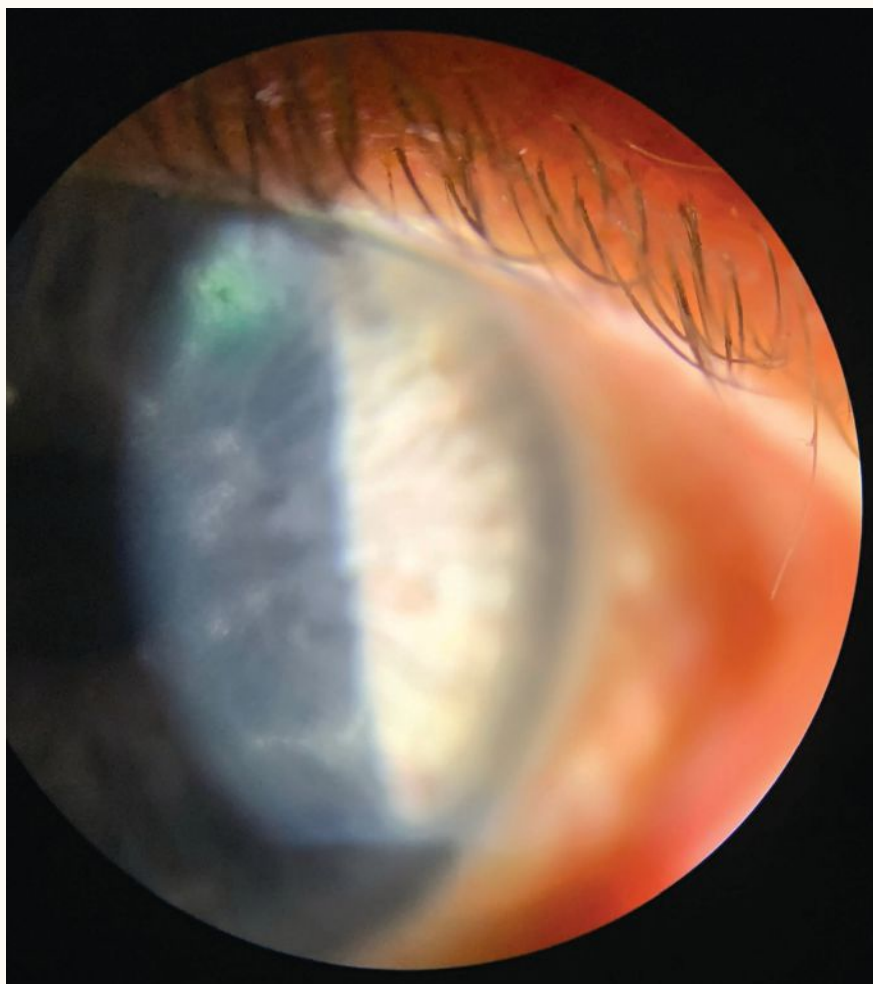
Oral antiviral agents are considered off-label for the treatment of HSVK. Currently, the available oral antivirals are acyclovir, valacyclovir and famciclovir (*Table 2*).<sup>8,13</sup> These oral antiviral agents have excellent corneal and anterior chamber penetration making

them effective treatment options for HSVK. However, due to the possibility of renal injury caused by oral antiviral agents, there needs to be special consideration when prescribing them for patients with kidney disease as there can be issues with the metabolism and excretion of the medication.<sup>8</sup>

**HSV epithelial keratitis.** Oral antiviral agents are commonly used as treatment for HSVK epithelial keratitis without the use of topical corticosteroids, which are contraindicated as they can prolong epithelialization and cause the dendrite to progress into a geographic ulcer.<sup>16</sup> The benefits of treating with oral antivirals instead of topical antivirals are that they are more affordable, have reduced dosing schedules and are not toxic to the cornea. Both topical and oral antivirals have independently been shown to be equally effective in treating HSV epithelial keratitis; however, there has not been sufficient evidence that treating HSV keratitis with both oral and topical antivirals hastens the healing process.<sup>5,16</sup>

The HEDS study showed no added benefit in concurrently treating HSVK with topical and oral antivirals.<sup>13</sup> For HSV epithelial keratitis, oral acyclovir is dosed 400mg five times a day for seven to 10 days, valacyclovir is dosed 500mg two times a day for seven to 10 days and famciclovir is dosed 250mg two times a day for seven to 10 days.<sup>6,13</sup> If treating with topical antivirals, trifluridine ophthalmic solution 1% is dosed one drop nine times a day for seven days and then reduced to five times a day if the ulcer has healed after day seven. Treatment with trifluridine ophthalmic solution 1% should not exceed 21 days due to the associated risk of ocular toxicity. Ganciclovir gel 0.15% is dosed one drop five times a day until the ulcer resolves and then reduced to three times a day for seven days.<sup>13</sup> For geographic ulcers, the dosages for oral antivirals are doubled for a treatment period of 15 to 21 days.

**HSV stromal keratitis without ulceration.** HSV stromal keratitis is considered an immune-mediated response to viral antigens in the stroma. Thus,



**HSV stromal keratitis with or without ulceration can be focal, multifocal or diffuse. This patient has HSV stromal keratitis with epithelial involvement.**

a therapeutic dose of topical corticosteroids is needed to quell the inflammatory response alongside a dose of oral antivirals. It is important that oral antivirals are used while the patient is being treated with topical corticosteroids. In HSV stromal keratitis without ulceration, oral acyclovir is dosed 400mg twice daily, valacyclovir is dosed 500mg once daily and famciclovir is dosed 250mg twice daily. Topical corticosteroids can be dosed six to eight times daily and should be used for at least 10 weeks and tapered slowly as the cornea improves. Developing a treatment plan for HSVK is more of an art than a science, as the treatment is based on the patient's medical and ocular history, clinical presentation and rate of healing. Also, considering HSV stromal and endothelial keratitis are

unpredictable in nature with the risk of permanent vision loss, refer these patients to a board-certified corneal specialist to help with comanagement.

**HSV stromal keratitis with ulceration.** When ulceration is present, the treatment plan needs to change. A limited dose of topical corticosteroids can be used along with a therapeutic dose of an oral antiviral. Oral acyclovir is dosed 800mg three to five times a day for seven to 10 days, valacyclovir is dosed 1g three times a day for seven to 10 days and famciclovir is dosed 500mg two times a day for seven to 10 days. The oral antiviral should then be reduced to a prophylactic dose and maintained throughout the duration of treatment with the topical corticosteroid. There is a lack of data that supports any specific recommended length of treatment for



this subtype of HSVK; therefore, clinical experience and presentation greatly aid in developing the treatment plan.<sup>13</sup> Again, patients with HSV stromal keratitis should be further managed by a board-certified corneal specialist. Oral antivirals are preferred in treating any form of HSV stromal keratitis or endothelial keratitis since trifluridine ophthalmic solution 1% and ganciclovir gel 0.15% do not have adequate corneal stroma penetration.<sup>13</sup>

**HSV endothelial keratitis.** This is relatively uncommon, and there are only a few studies that provide recommended treatment plans. Treatment with topical corticosteroids is needed, since it is an inflammatory-mediated response to the virus in the corneal endothelium. HSV endothelial keratitis responds extremely well to topical corticosteroids and, in comparison to HSV stromal keratitis, HSV endothelial keratitis heals at a remarkably faster rate.<sup>8,13</sup> Therapeutic doses of both topical corticosteroids and oral antiviral agents are needed for this subtype of HSVK. Topical corticosteroids can be dosed one drop six to eight times a day and tapered slowly. Oral acyclovir is dosed 400mg three to five times daily, valacyclovir is dosed 500mg two times daily and famciclovir is dosed 250mg two times daily. The therapeutic dose of oral antiviral should be reduced to seven to 10 days and maintained throughout the entire course of the topical corticosteroid taper schedule. Ganciclovir gel 0.15% and trifluridine ophthalmic solution 1% are not recommended in treating HSV endothelial keratitis due to their poor corneal penetration.<sup>13</sup> Given the challenging nature of this condition, comanagement with a specialist can be useful for both the optometrist and their patient.

## Life After HSVK

A previous history of HSV stromal keratitis and recurrent HSVK increases the risk of future HSVK recurrence.<sup>13</sup> An oral antiviral maintenance dose can be introduced for patients who are at a higher risk to prevent recurrence of HSVK. The HEDS II study found a

45% reduction in recurrent episodes of ocular HSVK when on prophylactic treatment.<sup>19</sup> The maintenance dose for acyclovir 400mg is two times daily for one year, valacyclovir 500mg is one time daily for one year and famciclovir is two times daily for one year.

This long-term maintenance dose can be extended past one year for special cases that present a higher risk of recurrence, such as in immunocompromised patients. As for prophylaxis, a patient with a history of HSVK may also be on a short-term maintenance dose if they plan to undergo any ocular surgeries such as cataract surgery. Lastly, an oral antiviral maintenance dose is needed if a patient were to be prescribed a corticosteroid at any time.

HSV stromal keratitis and endothelial keratitis, whether initial or recurrent episodes, are the greatest threat to permanent corneal structural damage and vision loss. These inflammatory reactions can cause corneal scarring, neovascularization, corneal thinning, decreased corneal sensation and fibrosis. Recurrent episodes place the patient at a higher risk of developing permanent corneal structural abnormalities. Approximately one million people worldwide are affected by permanent visual impairment due to ocular HSV.<sup>13</sup> There are also a reported 1,000 penetrating keratoplasties annually in the United States due to visually significant corneal scarring from ocular HSV.<sup>13</sup>

It is imperative to be vigilant in recognizing early clinical signs and symptoms of HSVK to help prevent severe cases from causing visually significant corneal damage. It is also important to educate patients and discuss possible visual outcomes and options. Comanaging with a corneal specialist is crucial in reducing your liability as a provider.

Depending on the course of the condition, the patient may benefit from an amniotic membrane for improved epithelial healing or a specialty contact lens for improved vision. A patient with significant corneal scarring and decreased vision may experience an improvement in vision from specialty lenses such as scleral lenses.

HSVK is a common and often visually devastating condition. Doctors of optometry can better manage these patients through a detailed understanding of the clinical presentation, differentials and treatments. This not only increases confidence in managing the condition but also improves outcomes and overall visual prognosis. ■

1. Azher TN, Yin XT, Tajfirouz D, et al. Herpes simplex keratitis: challenges in diagnosis and clinical management. *Clin Ophthalmol.* 2017;11:185-91.
2. Whitley RJ. Herpesviruses. In: Baron S, editor. *Medical Microbiology*. 4th edition. Galveston (TX): University of Texas Medical Branch at Galveston; 1996. Chapter 68. Available from: <https://www.ncbi.nlm.nih.gov/books/NBK8157/>.
3. Ahmad B, Patel BC. Herpes Simplex Keratitis. [Updated 2021 Nov 2]. In: StatPearls [Internet]. Treasure Island (FL): StatPearls Publishing; 2022 Jan-. Available from: <https://www.ncbi.nlm.nih.gov/books/NBK545278/>.
4. Sibley D, Larkin DFP. Update on Herpes simplex keratitis management. *Eye (Lond).* 2020;34(12):2219-26.
5. Tsatsos M, MacGregor C, Athanasiadis I, et al. Herpes simplex virus keratitis: an update of the pathogenesis and current treatment with oral and topical antiviral agents. *Clin Exp Ophthalmol.* 2016;44(9):824-37.
6. Leon S. Herpes Simplex Keratitis: Managing the Masquerader. *Review of Cornea and Contact Lenses.* 2020.
7. Chan RVP (Ed.). *Herpes simplex keratitis - Europe*. American Academy of Ophthalmology. 2013. <https://www.aao.org/topic-detail/herpes-simplex-keratitis-europe>.
8. Leon S. Be a Hero to Your HSVK Patients. *Review of Optometry.* 2017. <https://www.reviewofoptometry.com/article/ro0717-be-a-hero-to-your-hsvk-patients2>.
9. Chodosh J, Ung L. Adoption of Innovation in Herpes Simplex Virus Keratitis. *Cornea.* 2020;39(1):S7-S18.
10. Welder JD, Wagoner MD, Kitzmann AS. Herpes Simplex Keratitis. *EyeRounds.org.* 2012. <https://eyerounds.org/cases/160-HSV.htm>.
11. American Academy of Ophthalmology. Herpes Zoster Ophthalmicus. <https://www.aao.org/focalpointssnipdetail.aspx?id=8367b620-245c-4ebf-89e7-eca0c8d35aa3>.
12. Bronner A. Get to Know HZO. *Review of Optometry Continued Education.* 2021. <https://www.reviewofoptometry.com/ce/get-to-know-hzo>.
13. White ML, Chodosh J. Herpes simplex virus keratitis: a treatment guideline. *The American Academy of Ophthalmology Clinical Guidelines.* June 2014. <https://www.aao.org/clinical-statement/herpes-simplex-virus-keratitis-treatment-guideline>.
14. Zhu L, Zhu H. Ocular herpes: The pathophysiology, management and treatment of Herpetic Eye Diseases. *Virology.* 2014;29(6):327-42.
15. Roozbahani M, Hammersmith KM. Management of Herpes Simplex Virus Epithelial Keratitis. *Curr Opin Ophthalmol.* 2018;29(4):360-4.
16. Chodosh J, Ung L. Adoption of Innovation in Herpes Simplex Virus Keratitis. *Cornea.* 2020;39(1):S7-S18.
17. Wang L, Wang R, Xu C, et al. (2020). Pathogenesis of Herpes Stromal keratitis: Immune Inflammatory Response Mediated by Inflammatory Regulators. *Front Immunol.* 2020;11:766.
18. Roth L. Determination That AVACLYR (Acyclovir Ophthalmic Ointment), 3 Percent, Was Not Withdrawn From Sale for Reasons of Safety or Effectiveness. *Federal Register.* 2021. <https://www.federalregister.gov/documents/2021/05/20/2021-10593/determination-that-avaclyr-acyclovir-ophthalmic-ointment-3-percent-was-not-withdrawn-from-sale-for>.
19. Austin A, Lietman T, Rose-Nussbaumer J. Update on the Management of Infectious Keratitis. *Ophthalmology.* 2017;124(11):1678-89.

OPTOMETRIC STUDY CENTER QUIZ

To obtain CE credit through the Optometric Study Center, complete the test form on the following page and return it with the \$35 fee to: Jobson Healthcare Information, LLC, Attn.: CE Processing, 395 Hudson Street, 3rd Floor New York, New York 10014. To be eligible, please return the card within three years of publication. You can also access the test form and submit your answers and payment via credit card online at [revieweducationgroup.com](http://revieweducationgroup.com). You must achieve a score of 70 or higher to receive credit. Allow four weeks for processing. For each Optometric Study Center course you pass, you earn two hours of credit. Please check with your state licensing board to see if this approval counts toward your CE requirement for relicensure.

1. HSV-1 is which classification of virus?
  - a. Linear, single-stranded DNA virus.
  - b. Linear, double-stranded DNA virus.
  - c. Linear, triple-stranded DNA virus.
  - d. None of the above.
2. Which is a member of the *Herpesviridae* family?
  - a. HSV-2.
  - b. Epstein-Barr virus.
  - c. Cytomegalovirus.
  - d. All of the above.
3. HSV-1 reactivation occurs along which branch of the trigeminal ganglion resulting in corneal involvement?
  - a. Mandibular.
  - b. Maxillary.
  - c. Ophthalmic.
  - d. None of the above.
4. Which type of HSVK is thought to be due to an immune-mediated response?
  - a. Epithelial keratitis.
  - b. Stromal keratitis.
  - c. Endothelial keratitis.
  - d. Both b and c.
5. Which is considered to be a differential diagnosis of HSV epithelial keratitis?
  - a. *Acanthamoeba* keratitis.
  - b. Cogan's syndrome.
  - c. Rubeosis irides.
  - d. Arcus senilis.
6. Which is considered to be a differential diagnosis of HSV stromal keratitis?
  - a. Cogan's syndrome.
  - b. Syphilis.
  - c. Lyme disease.
  - d. All of the above.
7. Which is not one of the three main diagnostic tests for HSVK?
  - a. Culture.
  - b. Serology.
  - c. DFA.
  - d. PCR.
8. Which is the most common subtype of HSVK?
  - a. HSV endothelial keratitis.
  - b. HSV stromal keratitis with ulceration.
  - c. HSV epithelial keratitis.
  - d. Disciform keratitis.
9. Which can trigger a recurrence of HSVK?
  - a. Immunosuppression.
  - b. Psychological stress.
  - c. Ocular surgeries.
  - d. All of the above.
10. Which is a form of HSV endothelial keratitis?
  - a. Disciform.
  - b. Diffuse.
  - c. Linear.
  - d. All of the above.
11. Which is commonly misdiagnosed as a bacterial infection?
  - a. HSV epithelial keratitis.
  - b. Disciform keratitis.
  - c. HSV stromal keratitis without ulceration.
  - d. HSV stromal keratitis with ulceration.
12. Which subtype of HSVK can manifest independently from other forms of HSVK?
  - a. HSV stromal keratitis with ulceration.
  - b. HSV endothelial keratitis.
  - c. Necrotizing stromal keratitis.
  - d. HSV stromal keratitis without ulceration.
13. Which vital dye stains the body of a dendrite?
  - a. Lissamine green.
  - b. Rose bengal.
  - c. Fluorescein.
  - d. Giemsa stain.
14. Which is not an FDA-approved topical antiviral medication?
  - a. Trifluridine solution 1%.
  - b. Vidarabine ointment 3%.
  - c. Ganciclovir gel 0.15%.
  - d. Acyclovir ointment 3%.
15. Which topical antiviral is dosed one drop nine times a day for seven days and then reduced to five times a day after seven days if the ulcer is healed?
  - a. Trifluridine ophthalmic solution 1%.
  - b. Vidarabine ointment 3%.
  - c. Ganciclovir gel 0.15%.
  - d. Acyclovir ointment 3%.
16. What is the maximum number of days a patient can be on trifluridine ophthalmic solution 1% treatment?
  - a. 15 days.
  - b. 21 days.
  - c. 30 days.
  - d. 10 days.
17. Topical antiviral medications are not recommended for which subtype of HSVK?
  - a. HSV stromal keratitis.
  - b. HSV epithelial keratitis.
  - c. HSV endothelial keratitis.
  - d. Both a and c.
18. Which is the correct initial dose for an oral antiviral agent in treating HSVK stromal keratitis with ulceration?
  - a. Acyclovir 800mg three to five times daily.
  - b. Valacyclovir 1g three times daily.
  - c. Famciclovir 500mg two times daily.
  - d. All of the above.
19. Which is the recommended initial treatment for HSVK stromal keratitis without ulceration?
  - a. Prophylactic dose of an oral antiviral agent.
  - b. Therapeutic dose of topical corticosteroid.
  - c. Limited dose of topical corticosteroid.
  - d. Both a and b.
20. Which reacts extremely well to topical corticosteroids and heals at a faster rate compared with other subtypes of HSVK?
  - a. HSV epithelial keratitis.
  - b. HSV endothelial keratitis.
  - c. HSV stromal keratitis without ulceration.
  - d. HSV stromal keratitis with ulceration.

# Examination Answer Sheet

## Piecing Together the HSVK Puzzle

Valid for credit through April 15, 2025

**Online:** This exam can be taken online at [revieweducationgroup.com](http://revieweducationgroup.com). Upon passing the exam, you can view your results immediately and download a real-time CE certificate. You can also view your test history at any time from the website.

**Directions:** Select one answer for each question in the exam and completely darken the appropriate circle. A minimum score of 70% is required to earn credit.

**Mail to:** Jobson Healthcare Information, LLC, Attn.: CE Processing, 395 Hudson Street, 3rd Floor New York, New York 10014.

**Payment:** Remit \$35 with this exam. Make check payable to Jobson Healthcare Information, LLC.

**Credit:** This course is COPE-approved for two hours of CE credit. Course ID 77910-TD.

**Processing:** There is a four-week processing time for this exam.

Jointly provided by PIM and the Review Education Group.  
Salus University has sponsored the review and approval of this activity.

### Answers to CE exam:

1.  A  B  C  D
2.  A  B  C  D
3.  A  B  C  D
4.  A  B  C  D
5.  A  B  C  D
6.  A  B  C  D
7.  A  B  C  D
8.  A  B  C  D
9.  A  B  C  D
10.  A  B  C  D
11.  A  B  C  D
12.  A  B  C  D
13.  A  B  C  D
14.  A  B  C  D
15.  A  B  C  D
16.  A  B  C  D
17.  A  B  C  D
18.  A  B  C  D
19.  A  B  C  D
20.  A  B  C  D

### Post-activity evaluation questions:

Rate how well the activity supported your achievement of these learning objectives. 1=Poor, 2=Fair, 3=Neutral, 4=Good, 5=Excellent

21. Understand the presentations of herpes simplex virus keratitis. ① ② ③ ④ ⑤
22. Distinguish between HSVK and differential diagnoses. ① ② ③ ④ ⑤
23. Diagnose patients with herpes simplex virus keratitis. ① ② ③ ④ ⑤
24. Medically manage herpes simplex virus keratitis cases. ① ② ③ ④ ⑤
25. Based upon your participation in this activity, do you intend to change your practice behavior? (Choose only one of the following options.)  
 A I do plan to implement changes in my practice based on the information presented.  
 B My current practice has been reinforced by the information presented.  
 C I need more information before I will change my practice.
26. Thinking about how your participation in this activity will influence your patient care, how many of your patients are likely to benefit? (please use a number):
27. If you plan to change your practice behavior, what type of changes do you plan to implement? (Check all that apply.)  
 A Apply latest guidelines  D Change in current practice for referral  G More active monitoring and counseling  
 B Change in diagnostic methods  E Change in vision correction offerings  H Other, please specify: \_\_\_\_\_  
 C Choice of management approach  F Change in differential diagnosis
28. How confident are you that you will be able to make your intended changes?  
 A Very confident  B Somewhat confident  C Unsure  D Not confident
29. Which of the following do you anticipate will be the primary barrier to implementing these changes?  
 A Formulary restrictions  D Insurance/financial issues  G Patient adherence/compliance  
 B Time constraints  E Lack of interprofessional team support  H Other, please specify: \_\_\_\_\_  
 C System constraints  F Treatment related adverse events
30. Additional comments on this course: \_\_\_\_\_

Please retain a copy for your records. Please print clearly.

First Name

Last Name

E-Mail

The following is your:  Home Address  Business Address

Business Name

Address

City  State

ZIP

Telephone #  -  -

Fax #  -  -

OE Tracker Number

### Rate the quality of the material provided:

1=Strongly disagree, 2=Somewhat disagree, 3=Neutral, 4=Somewhat agree, 5=Strongly agree

31. The content was evidence-based. ① ② ③ ④ ⑤
32. The content was balanced and free of bias. ① ② ③ ④ ⑤
33. The presentation was clear and effective. ① ② ③ ④ ⑤

By submitting this answer sheet, I certify that I have read the lesson in its entirety and completed the self-assessment exam personally based on the material presented. I have not obtained the answers to this exam by any fraudulent or improper means.

Signature \_\_\_\_\_ Date \_\_\_\_\_ Lesson 122632 RO-OSC-0422



# BRUSH UP ON YOUR LOW VISION SKILLS

You can make rehabilitation a priority in your practice with fewer hassles than you may think.



BY JOSHUA L. ROBINSON, OD  
NASHVILLE

The term “low vision” refers to vision loss that is uncorrectable with current medical and surgical interventions or using traditional spectacle and contact lenses.<sup>1,2</sup> While the Centers for Medicare and Medicaid Services recognize distinct categories of low vision based primarily on best-corrected visual acuity (VA), a much broader range of patients may also be defined as having “low vision” based on compromised visual fields, impaired contrast sensitivity, or other deficits in visual function.<sup>3</sup>

The practice modality known as vision rehabilitation involves development of an individual rehabilitation plan (IRP) to help care for the patient with low vision. According to the American Optometric Association, an IRP may include “prescription glasses or contact lenses, optical and electronic magnification devices, assistive technology, glare control with therapeutic filters, contrast enhancement, eccentric viewing, visual field enhancement, non-optical options

and referral for additional services with other professionals.”<sup>2</sup>

A 2017 analysis estimated that 7.08 million people in the United States were living with uncorrectable VA loss.<sup>4</sup> The same study indicated that 1.08 million of these individuals demonstrated VA loss that qualified them to meet the federal definition of “legal blindness.”<sup>4,5</sup> When considering the other deficits in visual function that could convey “low vision” or “legal blindness” status, these numbers grow larger yet. Projections estimate the number of legally blind individuals will double by the year 2050, due in large part to the prevalence of age-related eye disease and the general aging of the US population.<sup>6</sup>

Our optometric training and scope of practice makes us the ideal providers of vision rehabilitation care. We are well-equipped to combine our understanding of optics with our knowledge of ophthalmic diseases and their functional implications to effectively serve the visually impaired patients in our practices. However, for those of us outside of academic and not-for-profit practice settings, it may be difficult to tackle

IRP development and provide comprehensive vision rehabilitation care. For this reason, it is important to discuss the ways in which all practicing optometrists can readily incorporate some foundational vision rehabilitation components into their practice to better serve this growing patient population.

## Levels of Vision Rehabilitation

In 2010, the Association of Schools and Colleges of Optometry (ASCO) convened a working group of optometric vision rehabilitation educators from across the country to define and delineate tiered competencies for vision rehabilitation care among graduates from schools and colleges of optometry.

The result of this group’s work is summarized in *Table 1*, which clearly lays out 20 entry level competencies for vision rehabilitation care that can be expected of any practicing optometrist regardless of their practice setting.<sup>7</sup> It is valuable to review each of the points laid out in *Table 1* and elaborate on the ways in which these can be applied in most optometric practices.

### About the author

**Dr. Robinson** is an assistant professor in the department of ophthalmology and visual sciences and director of Low Vision Rehabilitation at the Vanderbilt Eye Institute. He is a Fellow of the American Academy of Optometry and a Clinical Diplomate in the Academy’s Low Vision Section. He has no financial disclosures.

## Patient History Competencies

The first of the 20 ASCO competencies shown in *Table 1* has to do with the foundational knowledge of epidemiology and vision impairment we all obtain through our strong optometric education and ongoing continuing education efforts.<sup>7</sup> Our understanding of, and ability to communicate, these basic principles are rightfully at the top of the ASCO list of entry level competencies.

Competency number two requires that the optometrist obtain a thorough case history. A comprehensive understanding of a visually impaired patient's rehabilitative needs requires a case history that goes beyond that of a routine eye exam and dives into specific functional difficulties caused by one's vision loss, goals and expectations for the vision rehabilitation process.

While the exact set of intake questions used may vary from clinic to clinic, the National Eye Institute's Visual Functioning Questionnaire-25 (VFQ-25) provides a solid bank of foundational questions from which to adapt an intake questionnaire for visually impaired patients.<sup>8</sup> Listening when patients voice functional concerns relative to their vision loss, along with asking the appropriate questions to elicit functional concerns when needed, are foundational to the development of an effective IRP.

The next four ASCO competencies describe the ability to recognize various patient-specific factors that may influence the vision rehabilitation process. These include familial, psychological and social factors as well as physical and neurologic comorbidities that may impact an IRP. Recognition of these factors may take place during the case history discussion or at any time throughout the vision rehabilitation evaluation.

If appreciation for any of these factors seems to fall outside of what we all took from our optometric education, *Faye's Clinical Low Vision (2nd Ed.)* remains a proven and useful resource.<sup>9</sup>

**TABLE 1. ASCO ENTRY LEVEL LOW VISION REHABILITATION COMPETENCIES<sup>7</sup>**

1. Be able to apply epidemiologic aspects of visual impairment, appropriate terminology and classifications of visual impairment in order to communicate with patients, the public and other health care providers.
2. In addition to performing a standard case history, be able to ask basic questions about symptoms, functional difficulties and rehabilitation goals to anticipate the level of care that patients with visual impairment may require.
3. Be able to recognize functional implications, hereditary factors and prognoses of common causes of visual impairment and explain them in language understandable to patients, families and other care providers.
4. Be able to recognize psychological factors (e.g., depression, grief, motivation) that may affect adjustment to vision loss and the potential for rehabilitation.
5. Be able to recognize pertinent social factors (e.g., social support system, education level vocation, physical environment) and how they may influence the rehabilitation plan and process.
6. Be able to recognize significant physical and neurological comorbidities (e.g., Parkinson's disease, stroke dementia) that influence low vision rehabilitation and modify evaluation strategies and rehabilitation.
7. Be able to perform visual acuity testing at both distance and near on patients with visual impairment using appropriate charts with proper documentation (e.g., working distance eccentric viewing illumination).
8. Be able to perform trial lens refraction and modify refractive techniques for the patient with visual impairment (e.g., bracketing handheld Jackson cross cylinder).
9. Be able to recognize common symptoms of contrast sensitivity loss, screen for loss, recommend basic modifications (e.g., filter, lens lighting and environmental options) and refer for comprehensive low vision rehabilitation when indicated.
10. Be able to detect scotomas of the central visual field, understand their impact on visual acuity and visual function and educate patients about their implications for activities of daily living.
11. Understand basic optical principles of low vision rehabilitation devices and be able to predict magnification levels needed to achieve patient goals.
12. Be able to prescribe basic optical and non-optical low vision rehabilitation devices, provide training in their use and refer for comprehensive low vision rehabilitation when indicated.
13. Be able to recognize availability of and indications for use of adaptive technology (e.g., video magnification, software) and refer for comprehensive low vision rehabilitation when indicated.
14. Be cognizant of rehabilitation strategies for visual field deficits (e.g., sighted guide technique, orientation and mobility, visual field enhancement devices and equipment, scanning training) and refer for comprehensive low vision rehabilitation when indicated.
15. Develop an understanding of the special considerations for examining children, the elderly and the multiply handicapped and educate about referral options and potential for rehabilitation.
16. Understand relevant vision standards for driving, provide necessary assessment and documentation and refer for comprehensive low vision rehabilitation, driver education/training and medical evaluation when indicated.
17. Be aware of the criteria for legal blindness determination and be able to educate patients on the basic social and legal ramifications of legal blindness certification.
18. Understand that the needs of patients with visual impairment may require professional collaboration and be able to coordinate care with available rehabilitative, educational and social service resources.
19. Identify governmental, private and consumer organizations that offer support and information to individuals with visual impairment (e.g., NEI, Veterans Administration, state rehabilitation agencies, foundations for the blind, consumer advocacy groups and support groups).
20. Be familiar with third-party reimbursement for low vision rehabilitation services and materials.

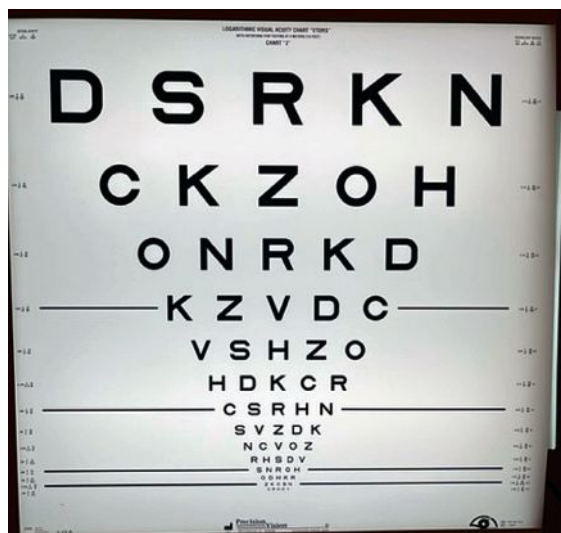
### Assessment Competencies

Competency number seven begins the actual vision examination process, detailing a thorough measurement of VA at distance and near. Depending on the practice setting and some patient-specific factors, various VA charts may be used. For distance VA measurement, a stand-based Early Treatment Diabetic Retinopathy Study (ETDRS; Precision Vision) chart remains the gold standard (*Figure 1*).<sup>10</sup>

This chart is mobile and conveniently allows for adjustment of the patient-to-target distance in cases when a patient is unable to read the largest optotypes from the standard 4m viewing distance. The backlit version also eliminates the need to provide proper illumination of the surface of the chart. A useful alternative distance VA chart is the William Feinbloom Distance Test Chart for the Partially Sighted (*Designs for Vision; Figure 2*). In employing this option, it is important to use and document appropriate illumination of the target.

For measuring near VA, various options exist that use single letters/numbers, words or continuous text. One of the more commonly used continuous text options is the MNRead Reading Test ((Lighthouse Low Vision Products; *Figure 3*).<sup>11</sup> Regardless of the chart being used, documenting distance and near VA is completed in standard form of “testing distance/optotype size” in a common (metric or imperial) measurement, always noting eccentric view (if employed) and lighting used (where pertinent).

A careful trial frame refraction, described in competency number eight, dictates everything that comes thereafter in a vision rehabilitation evaluation. This type of refraction is not all that different from the expert phoropter refractions being performed on our patients on a daily basis. The main difference lies in the use of a



**Fig. 1. The ETDRS logMAR chart can measure VA at distance.**

trial frame, loose lenses and a handheld Jackson cross cylinder (JCC) lens, which simplify the refraction of a patient who uses an eccentric view or atypical head posture to reach a null point and dampen nystagmus.

Further, the trial frame and loose lenses allow for larger and more efficient jumps in lens power when a patient’s acuity dictates a larger “just noticeable difference” in lens power be demonstrated. Otherwise, the trial frame refraction uses the same order of spherocylindrical lens power refinement steps and bracketing technique as a refraction in the phoropter. The goal of the trial frame refraction is the same as any other refraction we perform: to optimize a patient’s visual clarity through correction of ametropia.

Competency number nine pertains to contrast sensitivity (CS), a measure of visual function that is often reduced in the visually impaired patient and is likely not a primary focus in most routine eye care settings. Formal clinical testing of contrast sensitivity is simple and may be completed with any number of validated clinical tests. The Pelli-Robson CS Chart and Mars Letter Contrast Sensitivity Test are two common options for efficiently testing CS. The practicing optometrist should

be comfortable recognizing and screening for contrast sensitivity limitations, potentially using one of the aforementioned tests, and should also be able to recommend simple modifications (filters and environmental lighting) to aid in these patients’ function. If not, they should be prepared to make a referral to a comprehensive vision rehabilitation program.

Another important visual function consideration is the recognition of, and modifications to account for, scotomas. Many patients needing vision rehabilitation care have central visual deficits from commonly encountered conditions such

as age-related macular degeneration, various inherited macular dystrophies, retinal vascular occlusions and some optic nerve disorders. Presence of scotomas may be detected through knowledge of a patient’s diagnosis, responses during the intake interview, or formal tests such as microperimetry or the California Central Field Test.

Competency number 10 states that the optometrist should be able to detect scotomas and educate the patient on their presence and strategies, such as eccentric viewing, for working around them. Again, if they are unable to do so, referral to a comprehensive vision rehabilitation program should be initiated.

### Treatment Competencies

A comprehensive understanding of optics is foundational to our optometric education and to competency number 11. Being able to predict magnification needs based on a patient’s visual function and goals and understanding the angular magnification properties of various devices used in vision rehabilitation are considered entry-level competencies.

For example, using a ratio of the target print size to the currently legible print size helps to determine the dioptric power needed to reach the target print size. This can



# ARC

Atypical Refractive Correction

A revolutionary soft lens design utilizing unique transition and edge curves for a fit that centers on the cornea providing comfort and acuity.

With no need to worry about peripheral curves or any other parameter that may complicate the fit, the ARC is easy to fit, thus reducing valuable chair time.

## A SOFT LENS OPTION indicated for **KERATOCONUS** and any irregular cornea

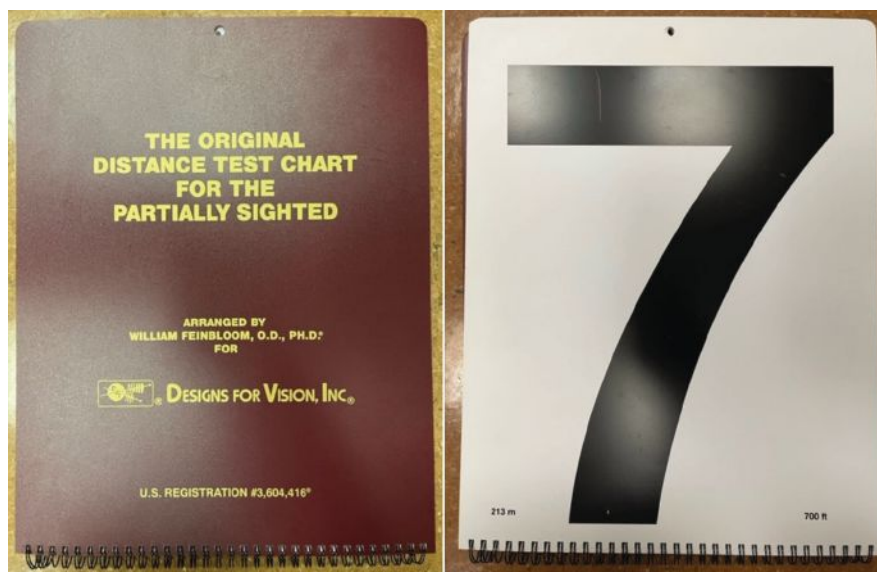For more information on ARC and other irregular cornea options

800.241.9312 | [xcelspecialtycontacts.com](http://xcelspecialtycontacts.com)

Recommended in  
**DEFINITIVE**<sup>™</sup>



  
**X-CEL**  
SPECIALTY CONTACTS



**Fig. 2. The Feinbloom Distance Test Chart for the Partially Sighted.**

predict the appropriate handheld or spectacle-based tools for a given patient and guide the optometrist's handling of the device demonstration, prescription and training process.

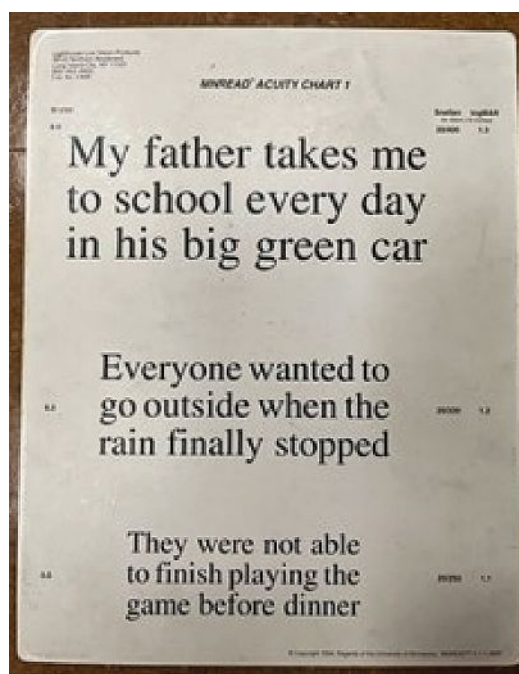In general, one should be comfortable prescribing near reading add powers up to around six diopters and accounting for the corresponding convergence demand through the appropriate amount of base in prism. Otherwise, referral for comprehensive vision rehabilitation is indicated.

Basic vision rehabilitation device prescription and training are the focus of point number 12. The optometrist should be equipped to demonstrate low-powered optical magnification devices and non-optical devices such as lighting options and filters. If they choose not to perform these demonstrations, referral to a comprehensive vision rehabilitation program is the standard.

Recognition of pertinent assistive technology options for a given patient is an important part of developing an IRP. Standalone desktop and portable video-based magnifiers, as well as the mobile phone and tablet devices already owned by many of our patients, are examples of helpful assistive

technology options that can benefit our visually impaired patients. Competency number 13 notes that it is adequate to recognize the need for, and refer to, appropriate assistive technology training programs when indicated.

When a patient's visual impairment entails visual field compromise, the optometrist should be comfortable recognizing its impact on patient



**Fig. 3. The MNRead Continuous Text Acuity Chart can help measure VA at near.**

function and addressing this appropriately. As outlined in competency number 14, this may include prescription of devices that enhance visual field awareness (e.g., prisms, reverse telescopes) or referral for appropriate training such as sighted guide and formal orientation and mobility programs.

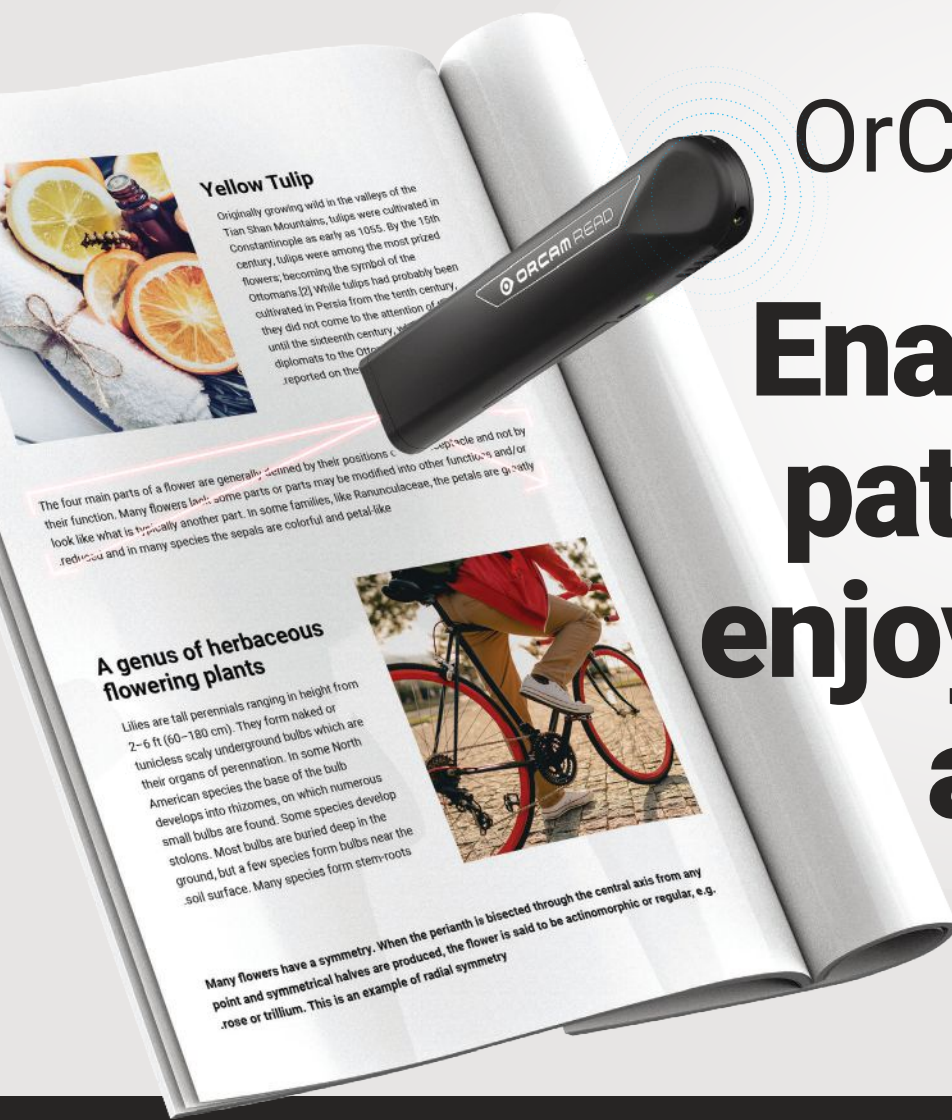Just as in primary optometric care, the practitioner is likely to encounter children and people with multiple disabilities among their visually impaired patient base. Competency number 15 notes that the optometrist should be comfortable employing specialized examination techniques and making appropriate referral for services and training in these cases, when indicated.

Competencies number 16 and 17 stress the importance of knowing legal blindness and licensure laws to better serve visually impaired patients and to provide documentation or referral for additional training or services as needed. A refresher on legal blindness criteria can be found on the Social Security Administration's website, while state-by-state vision testing standards for licensure are kept up to date by Prevent Blindness on their website.<sup>5,12</sup>

Competency points 18 and 19 pertain to the multidisciplinary nature of comprehensive vision rehabilitation care. The optometrist should know when to include referral to other rehabilitation professionals and social or psychological support services in a patient's IRP. Further, connecting a patient with the appropriate governmental or community support networks can be an important part in helping to meet that patient's individual needs.

The American Printing House for the Blind, the National Federation of the Blind and the American Foundation for the Blind all maintain helpful online directories of available vision rehabilitation resources in one's state or region.<sup>13-15</sup>





# OrCam Read

## Enable your patients to enjoy reading again



### Full Page Capture

Unlike all other devices which require word-by-word scanning.



### Smart Reading

Ask the device to read only the text that interests you.



### Easy to Use

An intuitive device - simply point and click to start reading.

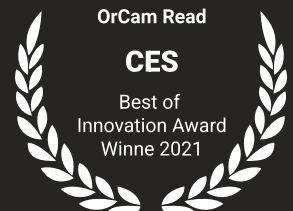
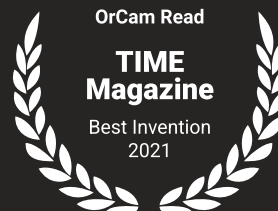
### No Connectivity Required

Offline operation - for use anywhere.



Contact for more information or a demonstration:  
[eyedoc@orcaml.com](mailto:eyedoc@orcaml.com)





Finally, competency point number 20 pertains to one’s understanding of vision rehabilitation billing, coding and reimbursement structures. These factors likely play a role in limiting the number of private practice optometrists providing entry level vision rehabilitation services, but it doesn’t have to be that way. The practicing optometrist should understand that vision rehabilitation billing is typically based on time spent and uses the Evaluation & Management (E&M, 99xxx) codes.

The time spent includes any face-to-face time with the patient, as well as time spent on the same day preparing for the case and documenting findings or communicating with other professionals regarding the case. It does not include the refraction or other diagnostic testing that are being billed as separate services.

Table 2 lays out time requirements for billing each E&M code for both new and established outpatients. Any additional time spent beyond the Level 5 allotment in each column can be billed in additional 15-minute increments using code 99417. The ability to bill visits based on time can help to offset the inherent reduction in patient volumes when providing vision rehabilitation care in a private practice setting.

As for the prescription of vision rehabilitation devices, it should be

noted that most are not covered as durable medical equipment by Medicare and other medical insurance carriers. While we are hopeful that this will change in the coming years, it is important for the vision rehabilitation practitioner to be able to tap into other coverage options for these devices. Options may include state blind or vocational rehabilitation services, private grant opportunities, flexible spending accounts or other local funding resources.

### Clinical Takeaways

Caring for visually impaired patients falls squarely in optometry’s wheelhouse. Our comprehensive understanding of both ophthalmic disease and optics puts us all in a position to help our visually impaired patients to maximize their quality of life.

As the prevalence of vision impairment continues to grow, provision of vision rehabilitation services will fall to optometrists in all practice settings.<sup>6</sup> While not all of us are equipped to provide comprehensive vision rehabilitation services, the core competencies defined by the ASCO provide a road map to starting the vision rehabilitation process for patients who need it.<sup>7</sup>

As was noted in the preceding discussion of all 20 ASCO competencies, there will come a point in many vision rehabilitation cases where referral for more comprehensive services is in-

dicated. This may be dictated by the need for near add powers above a certain threshold, prescription a bioptic telescope, eccentric viewing training, or referral for vocational rehabilitation, among many other factors.

When the needs of the patient are simpler, private practice optometrists can use the ASCO competencies to enhance their care for this growing, and grateful, patient population.

In summary, it’s important to view vision rehab as a spectrum of interventions—many of which are accessible to primary care optometrists—rather than a binary choice that forces ODs to be “all-in” or “all-out.” ■

1. Turbet D, Gudgel D. What is low vision? American Academy of Ophthalmology. [www.aao.org/eye-health/diseases/low-vision](http://www.aao.org/eye-health/diseases/low-vision). September 23, 2021. Accessed March 2, 2022.
2. Low vision and vision rehabilitation. American Optometric Association. [www.aao.org/healthy-eyes/caring-for-your-eyes/low-vision-and-vision-rehab?ss=y](http://www.aao.org/healthy-eyes/caring-for-your-eyes/low-vision-and-vision-rehab?ss=y). Accessed March 2, 2022.
3. ICD-10-CM/PCS MS-DRG v37.0 Definitions Manual. Centers for Medicare & Medicaid Services. [www.cms.gov/icd10m/version37-fullcode-cms/fullcode\\_cms/P0427.html](http://www.cms.gov/icd10m/version37-fullcode-cms/fullcode_cms/P0427.html). Accessed March 2, 2022.
4. Flaxman AD, Wittenborn JS, Robalik T, et al. Prevalence of visual acuity loss or blindness in the US: a Bayesian meta-analysis. *JAMA Ophthalmol*. 2021;139(7):717-23.
5. Disability evaluation under social security. Social Security Administration. [www.ssa.gov/disability/professionals/bluebook/2.00-SpecialSensesandSpeech-Adult.htm](http://www.ssa.gov/disability/professionals/bluebook/2.00-SpecialSensesandSpeech-Adult.htm). Accessed March 2, 2022.
6. Varma R, Vajaranant TS, Burkemper B, et al. Visual impairment and blindness in adults in the United States: demographic and geographic variations from 2015 to 2050. *JAMA Ophthalmol*. 2016;134(7):802-9.
7. Kammer RL et al. The development of entry level low vision rehabilitation competencies in optometric education. *Optom Ed*. 2010;35(3):98-107.
8. Visual Function Questionnaire 25. National Eye Institute. [www.nei.nih.gov/learn-about-eye-health/resources-for-health-educators/outreach-materials/visual-function-questionnaire-25](http://www.nei.nih.gov/learn-about-eye-health/resources-for-health-educators/outreach-materials/visual-function-questionnaire-25). Accessed March 2, 2022.
9. Faye EE. *Clinical Low Vision* (2nd Ed). Boston: Little, Brown and Company; 1984.
10. Shamir RR, Friedman Y, Joskowicz L, et al. Comparison of Snellen and Early Treatment Diabetic Retinopathy Study charts using a computer simulation. *Int J Ophthalmol*. 2016;9(1):119-23.
11. Brussee T, van Nispen RM, van Rens GH. Measurement properties of continuous text reading performance tests. *Ophthal Physiol Opt*. 2014;34(6):636-57.
12. Prevent Blindness. State vision screening and standards for license to drive. [www.vision.preventblindness.org/2003/06/06/state-vision-screening-and-standards-for-license-to-drive/#top](http://www.vision.preventblindness.org/2003/06/06/state-vision-screening-and-standards-for-license-to-drive/#top). Updated April 2020. Accessed March 2, 2022.
13. Low vision services: APH directory of services listings. Vision Aware. [visionaware.org/directory/results/?CategoryID=66](http://visionaware.org/directory/results/?CategoryID=66). Accessed March 2, 2022.
14. National Federation of the Blind. [nfb.org](http://nfb.org). Accessed March 2, 2022.
15. American Foundation for the Blind. [afb.org](http://afb.org). Accessed March 2, 2022.

**TABLE 2. OUTPATIENT TIME-BASED E&M CODING LEVELS FOR NEW AND ESTABLISHED PATIENTS**

	New	Established
Level 1	99201 (10 minutes)	99211 (N/A)
Level 2	99202 (15 minutes)	99212 (10 minutes)
Level 3	99203 (30 minutes)	99213 (20 minutes)
Level 4	99204 (45 minutes)	99212 (30 minutes)
Level 5	99205 (60 minutes)	99215 (40 minutes)



# Scleral Lens News

## **NEW!** SynergEyes VS™ 3 Innovations:

1

### Multifocal

Front Surface  
Progressive Center Distance  
Design

2

### Aberration Control

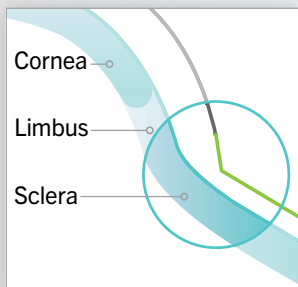
Helps address lens-induced  
aberrations for consistent power  
throughout optical zone

3

### Limbal Clearance Factor


Broadens the area of  
limbal clearance;  
beneficial for larger HVIDs

SynergEyes VS™ is an innovative scleral lens with a distinctive bi-tangential periphery and linear landing zones that fits the true shape of the sclera. Designed to accommodate a wide variety of corneal conditions, each parameter may be adjusted independently, without affecting other parameters.



Linear landing zones follow the straight anatomy of the para-limbal sclera

**Linear Scleral  
Landing Zone:  
Standard**



**Toric  
Periphery:  
Standard**

**100%  
TORIC  
PERIPHERY**

Standard toric peripheral system aligns with the toricity of the sclera

## SynergEyes VS™ All Inclusive Pricing

- Linear Landing Zones • Toric Peripheries • Aberration Control<sup>1</sup> • Limbal Clearance Factor
- 90-day Guaranteed Fit • Unlimited Exchanges Provided and Shipped Free of Charge<sup>2</sup>
- No Need to Return Opened Lenses for Credit

[SynergEyes.com/Professional](http://SynergEyes.com/Professional)  
877.733.2012 option 5

1. Aberration Control is standard on Multifocal and an option on Single Vision; price is all inclusive.  
2. Unlimited free exchanges and associated shipping during 90-day fitting period.  
SynergEyes VS™ available in US only.



# TO CUT OR NOT TO CUT?

## Weighing Strabismus Surgery Referral

Determine when this intervention is truly better than vision therapy—and how to set expectations.



BY **BRENDA MONTECALVO, OD**  
BEAVERCREEK, OH

**T**here is no rush to immediately recommend surgery for strabismus. Collaborative efforts between the surgeon and optometrist allow for better outcomes. Developing all visual skills benefits the patient with strabismus, providing sensory fusion. The critical stage for sensory fusion is less limiting with new approaches used in vision therapy (VT). When amblyopia exists, VT should be the first-line approach in order to gain the best possible outcome for misalignment.

### The Consequences of Strabismus

Patients living with constant strabismus face a lifetime of difficulties. They are more likely to be diagnosed with psychological disorders, often have low self-esteem, are less likely to find a partner, marry or have a family.<sup>1</sup> They even have more difficulty being a competitive job applicant, compared with those without strabismus. Patients in their third decade of life with uncorrected strabismus are more likely

to face long-term psychological disorders. One study showed that individuals with constant exotropia were three-times more likely to be diagnosed with a psychological disorder than controls. Patients with uncorrected strabismus also had higher rates of homicidal and suicidal ideation.<sup>1</sup>

Strabismus puts people at a considerable disadvantage due to the noticeable nature of having a turned eye, resulting in negative social stigma. In addition, there are many professions that depend on stereopsis.<sup>2</sup> Achieving the best possible outcomes for these patients is critical for them to avoid negative psychological, socioeconomic and employment consequences. New evidence shines light on understanding outcomes of surgical intervention.

As optometrists, we meet patients going through life with these challenges because of their strabismus. We are obligated to at least make all possible treatments known and available to those interested in pursuing better vision.

Creating the very best possible outcome involves a collaborative ef-

fort between the optometrist and the strabismic surgeon. Good communication and respect for each other's skills allows for comprehensive care. First, take time to visit each other's practices. Second, educate the staff on how each profession contributes to successful outcomes. Third, schedule regular meetings between the two teams to discuss specific cases.

Understanding when to refer for surgery and combining the skills of a good optometric vision therapist will give your patient the best opportunity for cosmetically straight eyes with some level of stereopsis. To facilitate this for the strabismus patient, follow these steps:

1. Measure best-correlated visual acuity (VA) of each eye.
2. Evaluate binocularity to determine deviation and if any immediate spectacle compensation will improve the binocular stasis.
3. Evaluate the ocular motor and accommodative systems.
4. Determine if there is any appreciation of diplopia under any condition.
5. Identify level of suppression and fusion.

#### About the author

**Dr. Montecalvo** practices at Nova Vision Care in Beavercreek, OH. She is a Fellow of the College of Optometrists in Vision Development, the American Academy of Optometry and the College of Syntonic Optometry. She is vice president of the College of Syntonic Optometry, a member of the AOA InfantSee Committee, board member of the Vision Leads Foundation, dean of the Vision Aces Academy and CEO of the Cedarville Vision Therapy Seminars. She is on the NeuroLens Advisory Board and a compensated speaker for the company.



6. If there is some level of visual motor function that can be improved by VT, eight sessions should be completed. Then re-evaluate the system for possible improvements, such as less suppression, better cosmetic alignment, improved oculomotor function and better accommodative flexibility.

7. If improvements are identified, continue with eight more sessions and re-evaluate.

8. If there is a plateau in improvement and the deviation is still obvious, referral for surgery should be suggested.

9. After surgery, re-evaluation of visual motor skills should be conducted and post-VT activities should be instituted to maintain gains made through surgery.

### Procedure Risks

Short- and long-term complications from surgical intervention reinforce why collaboration is important. Post-op complications of strabismus surgery include conjunctivitis, scleritis, sub-Tenon's abscess, orbital cellulitis, endophthalmitis, hypopyon, vitreous haze and scleral perforation.<sup>3</sup>

Intraoperative surgical site complications can include scleral perforation, lost muscle, slipped muscle and oculocardiac reflex, while post-op surgical site complications can include postoperative infection, allergic reaction, foreign body granuloma, conjunctival inclusion cyst, conjunctival scarring, fat adherence, dellen, anterior segment ischemia, eyelid retraction, ptosis and possible change in refraction.<sup>4</sup> Post-op strabismus complications can involve diplopia, hyperphoria, anti-elevation syndrome and iatrogenic Brown syndrome.<sup>4</sup>

There are several risk factors to be aware of regarding strabismus surgery. Unsatisfactory eye alignment is more likely after surgery in patients with poor fusion potential or with more complicated types of strabismus. Patients with dense amblyopia or structural problems in one or both eyes have limited potential for binocular vision and do not employ fusional mechanisms

to improve or maintain eye alignment.

Similarly, patients with neuro-developmental anomalies have been shown to have higher rates of undercorrection and overcorrection after strabismus surgery. Also, patients with more unusual and severe forms of strabismus, such as cranial nerve III palsies, are more difficult to align satisfactorily with surgery.<sup>5</sup>

### Surgical Timing Without Amblyopia

The outcomes of infantile strabismus surgery are based on two main factors: ocular alignment and stereopsis. Stereopsis is measured several different ways. The optimal standard is full random dot stereopsis. However, there are lesser degrees of stereo that do qualify as successful.

We are often misled into believing that strabismus surgical outcomes are high. We should note that they are considerably lower than one would hope for. Pediatric strabismus surgery has low success rates and high reoperation rates because of difficult alignment measurements and the nature of different strabismus types.

This is true when you have an inexperienced surgeon such as a first-year resident. Multiple surgeries per case are also common. The more surgeries one has, the greater chance for exotropia, vertical deviations, no stereopsis, constant diplopia or constant uncorrectable strabismus.

A successful outcome can be based on a variety of measurements. If cosmetic alignment is the criteria, the success rate is higher. Full stereopsis criteria have a much lower success rate. Socio-psychological effects are negative for those with poor eye align-



**Prescribe performance lenses to help with functional vision. These lenses can help with symptoms of poor eye teaming, tracking and focusing.**

ment, so all efforts should be made for the optometrist and ophthalmologist to collaborate in order to achieve the best outcome possible.


The definition of success in strabismus surgery varies among different studies. Most studies set their success criteria as 8pd to 10pd deviations from orthophoria at either the three-month, six-month or last follow-up.<sup>6</sup>

Recently, an evidence-based study concluded that performing surgery later in life in patients with infantile esotropia increased the motor success rate of surgery. In addition, orthophoria is achieved with fewer surgical operations.<sup>7</sup> Another study showed that more favorable long-term outcomes and less vertical deviations occurred when fewer surgeries were performed.<sup>8</sup> The Cochrane study also concluded that there is no clear consensus on the optimal timing of surgery.<sup>9</sup>

Clinically, a sandwich approach—VT before and after surgery—has demonstrated that the highest outcomes are possible for these patients. This might consist of vision therapy prior to strabismus surgery to optimize sensory readiness for motor fusion and/or post-surgical therapy to stabilize or safeguard binocular vision.<sup>10</sup>

### VT Skills

Oculomotor, localization and accommodative skills build a foundation prior to



**Examples of some of the many tools VT practitioners use to help improve stereopsis.**

sensory fusion. Management of these foundational skills prior to working on sensory fusion allows the optometrist providing pre- and post-VT to gain better outcomes. Clinically, my patients often gain cosmetic alignment simply by developing these skills, especially opposite to the direction of deviation. For example, with esotropia, working pursuits, saccades, localization and accommodative flexibility in temporal secondary gaze improves the ability to begin to appreciate fusion in primary gaze. For exotropia, these skills are emphasized in nasal secondary gaze. Poor eye movements reduce the success of gaining sensory fusion.

An overall limiting factor for patient outcomes is misaligned oculocentric localization. The patient's awareness of where objects are judged to be located can be displaced in the direction of deviation. This needs to be addressed for both surgery and VT cases. Oculocentric localization should match the visual axis of each eye.

After the above skills are developed, in esotropia, depending on the type, VT is used to improve sensory fusion (the patient should have good second-

degree fusion prior to surgery if possible) and relative motor fusion ranges if possible. In exotropia with some sensory fusion, VT is used to improve motor fusion recoveries and ranges as much as possible prior to surgery.

Much care is needed when working with anomalous correspondence. The safest approach is to overemphasize the skills of oculomotor, localization and accommodation. Use caution when attempting to gain normal correspondence with VT prior to surgery. Attempts to break suppression should only be done for short periods (five minutes or less).

VT post-op depends on the patient's alignment and fusional status after surgery. Generally, VT focuses on improving all visual skills including eye movements, localization, accommodation, sensory and motor fusion, again around the new angle. The ability to recover fusion is more beneficial than simply building ranges.

One study on resolution without surgery showed that esotropia with onset in early infancy frequently resolves in patients first examined at less than 20 weeks of age when the deviation is less

than 40pd and is intermittent or variable. Cases with a constant deviation of greater than or equal to 40pd presenting after 10 weeks of age have a low likelihood of spontaneous resolution.<sup>10</sup> Child development of fusion occurs at about three months; thus, misalignment is normal prior to this age.

A large percentage of patients with either esotropia or exotropia gain sensory fusion with a visual motor-based VT program. The few that do not are then referred for surgical intervention. This gives the patient the best possible outcome.

### **Surgical Timing with Amblyopia**

There is conflicting evidence whether or not to treat the strabismic amblyope before or after treating the eye deviation. One study suggested the patient obtain the best VA possible prior to surgery. Recent studies suggest that correcting eye alignment earlier will give the amblyopic eye the opportunity to develop better VA and binocular vision.<sup>11</sup> Surgery is generally reserved for children with anisometropic amblyopia who do not respond to standard treatment, or children with serious vision impairment who are unable to wear glasses for developmental, sensory or other reasons. As a result, only a small percentage of children are suitable candidates for this surgery.<sup>12</sup>

The Cochrane study stated that the optimum timing of when to perform strabismus surgery in children with amblyopia is unknown.<sup>9</sup> It noted that treatment for amblyopia involves methods of exercising the amblyopic eye by encouraging its increased use.

The researchers referenced several methods used to reduce the vision of the non-amblyopic eye temporarily, including penalization with cycloplegic or dilating eye drops, optical blurring of vision with high-plus lenses or physical occlusion of the normal eye. They acknowledged the newer binocular training approaches for amblyopia treatment available.<sup>9</sup> These usually involve using a digital device that deprives the non-amblyopic eye in a bi-ocular viewing task.



# Smart System® | VR Headset



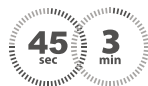Vision Source  
Exchange  
Washington, DC  
Booth #841

## The Only VR Headset with Time-Tested Software

**M&S takes vision testing to new heights.** The programmable VR Headset with Surface Pro 7 Controller is powered by our trusted M&S Smart System® software for fast, accurate and convenient vision testing. Complete with audible cues for both patient and technician, this portable device allows testing to take place anywhere, including in the patient's home.



Active Eye Tracking  
Function



Visual Field

QuickScreen  
45 sec

Full Threshold  
3 min per eye



Intuitive  
Interface

Schedule a demo at: [MSTech-Eyes.com/vr-headset](https://MSTech-Eyes.com/vr-headset)



**M&S**  
TECHNOLOGIES



847-763-0500  
[mstech-eyes.com](https://mstech-eyes.com)

The First Choice in Vision Testing Systems

A HILCO VISION COMPANY



©2022 M&S and Smart System are registered trademarks of the Hilsinger Company Parent LLC. All rights reserved. The Hilsinger Company Parent LLC holds US Patents 7,354,155; 7,926,948; 8,425,040; 8,167,429; 8,419,184; 8,550,631; 8,992,022; 9,433,347; 9,820,644; 10,244,938 and 10,182,713. Other Patents Pending.





**Today, innovative technology, such as this virtual reality headset, allows us to treat amblyopia, strabismus, convergence disorders and other binocular vision problems.**

To date, very few studies been conducted that represent VT. Treatment often involves a multitude of activities other than simply sitting and playing video games. These would include bi-ocular pursuits, saccades, accommodative tasks, visual spatial activities, anti-suppression decision-making procedures and visually guided movement activities. It is likely that when assessing all VT tools, successful outcomes would be much higher than those in controlled studies.

Binocular training should aim to treat amblyopia by restoring the underlying issue of reduced or absent binocularity.<sup>13</sup>

### **New Approaches to Amblyopia Treatment**

Based on new research, the very best intervention for patients with amblyopia is to first develop a visual system in the amblyopic eye that can fixate, pursue and saccade with equal accuracy as compared with the nonamblyopic eye. The second step is to create binocularity for long term maintenance of acuity gains. Recent research has shown that by develop-



**Recent research has shown that, by developing better performance for various visual systems (e.g., eye movements, accommodation, binocularity), the amblyopic patient improves without patching.**

ing better visual systems, such as eye movements, accommodation and binocularity, the amblyopic eye improves without patching.<sup>13-15</sup> This new concept has positive implications for patients, especially children who would prefer not to look different from their peers. This is a more positive psychological approach for these patients. Also, the lasting effect of VA gains is much greater using these methods than by full-time patching.

Classic teaching dictates that amblyopia must be corrected to the maximum extent possible before realignment surgery is undertaken.<sup>11</sup>

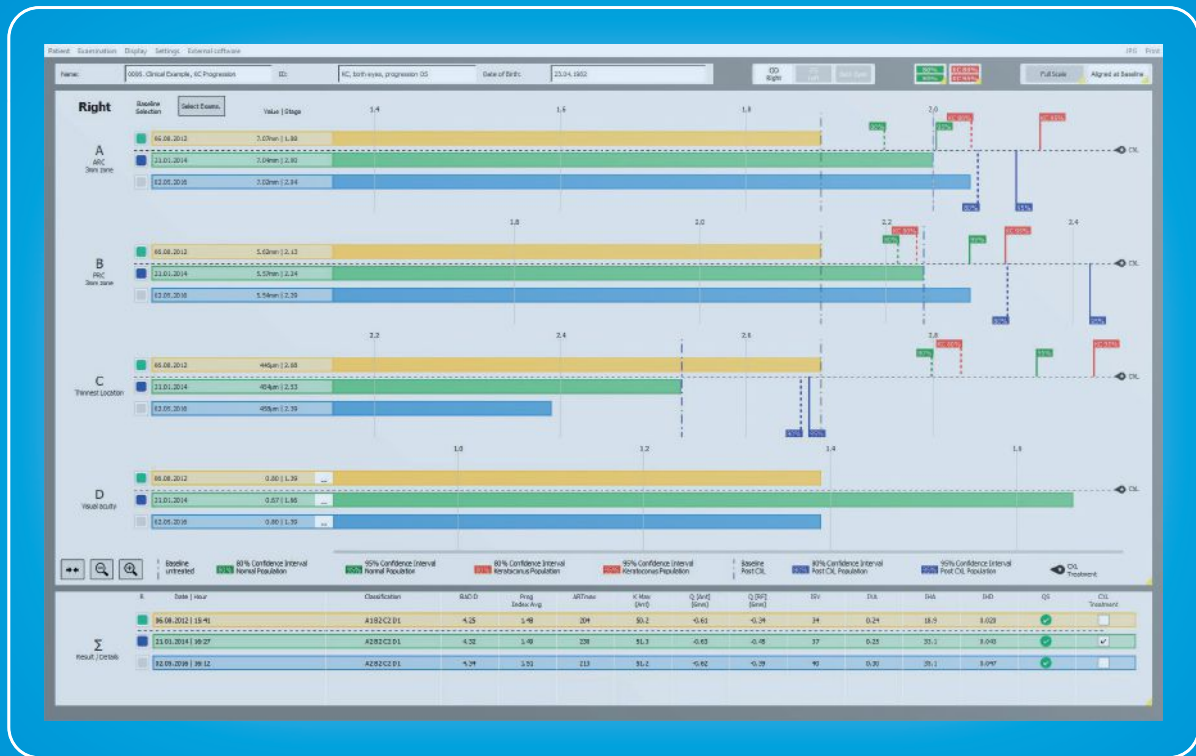
Based on my clinical experience, VT is extremely effective for amblyopia when it involves changing how the brain processes information for the amblyopic eye. This style of vision therapy uses a wide variety of eye movements and accommodative flexibility activities prior to attempting anti-suppression and fusion activities. The amblyopic eye also has opportunities to participate in a variety of perceptual activities. Typically, you will begin to see improved VA within about six to eight weeks.

After the eye movements and accommodative abilities are as equal as possible between the two eyes, incorporate the anti-suppression, fusion and convergence and divergence activities. A patient with amblyopia who develops good binocularity more readily maintains gains made in VA improvement. This is accomplished without having to continue with blur patch or deprivation activities.

Bottom line: there is no rush to jump into the deep end and recommend surgery as a first-line treatment for strabismus, and more specifically for exotropia. Wait until you have exhausted all the tools and techniques we have at our disposal. ■

1. Mohny BG, McKenzie JA, Capo JA, et al. mental illness in young adults who had strabismus as children. *Pediatrics*. 2008;122(5):103-8.
2. Al-Saud LM, Mushtaq F, Mirghani I, et al. Drilling into the functional significance of stereopsis: the impact of stereoscopic information on surgical performance. *Ophthalmic Physiol Opt*. 2017; 37(4): 498-506.
3. Ing M. 7 Complications of Strabismus Surgery. *Ento Key*. [entokey.com/7-complications-of-strabismus-surgery](http://entokey.com/7-complications-of-strabismus-surgery). February 21, 2021. Accessed March 22, 2022.
4. Clark RA, Lee AR. Strabismus surgery complications. EyeWiki. [eyewiki.aao.org/strabismus\\_surgery\\_complications](http://eyewiki.aao.org/strabismus_surgery_complications). Updated March 10, 2022. Accessed March 24, 2022.
5. Coats DK, Olitsky SE, eds., Unexpected postoperative alignment, in: *Strabismus Surgery and Its Complications*. Berlin, Heidelberg: Springer; 2007; 291–294.
6. Fu JJ, Hsieh MW, Lee LC, et al. A novel method ensuring an immediate target angle after horizontal strabismus surgery in children. *Front Med*. February 24, 2022. [Epub ahead of print].
7. Muz OE, Sanac AS. Effects of surgical timing on surgical success and long-term motor and sensory outcomes of infantile esotropia. *J Pediatr Ophthalmol Strabismus*. 2020;57(5):319-25.
8. Lee D, Kim WJ, Kim MM., Surgical outcomes and occurrence of associated vertical strabismus during a 10-year follow-up in patients with infantile esotropia. *Indian J Ophthalmol*. 2021;69(1):130-4.
9. Korah S, Philip SS, Jasper S, et al. Strabismus surgery before vs. after completion of amblyopia therapy in children. *Cochrane Database Syst Rev*. 2014;10(10):CD009272.
10. Press LJ. The sandwich approach to vision therapy and strabismus. *The Visionhelp Blog*. [visionhelp.wordpress.com/2019/11/14/the-sandwich-approach-to-vision-therapy-and-strabismus](http://visionhelp.wordpress.com/2019/11/14/the-sandwich-approach-to-vision-therapy-and-strabismus). November 14, 2019. Accessed February 15, 2022.
11. Von Noorden GK. *Esodeviations. Binocular vision and ocular motility: theory and management of strabismus*. 5th Edition. St. Louis: Mosby, 2002.
12. Bedinghaus T. Amblyopia surgery: everything you need to know. *VeryWellHealth*. [www.verywellhealth.com/amblyopia-lazy-eye-overview-4175206](http://www.verywellhealth.com/amblyopia-lazy-eye-overview-4175206). Updated October 15, 2020. Accessed March 22, 2022.
13. Hess RF, Mansouri B, Thompson B. Restoration of binocular vision in amblyopia. *Strabismus*. 2011;19(3):110-8.
14. Hess RF, Thompson B. New insights into amblyopia: binocular therapy and noninvasive brain stimulation. *J AAPOS*. 2013;17(1):89-93.
15. Li SL, Jost RM, Morale SE, et al. Binocular iPad treatment of amblyopia for lasting improvement of visual acuity. *JAMA Ophthalmol*. 2015;133(4):479-80.

# Keratoconus Progression at a Glance!



Retrospective use



Free update



User-friendly



## The Belin ABCD Progression Display now includes post-CXL data

The newly integrated post-CXL function and database allow for evaluation of the cornea after crosslinking, based on the full complement of parameters including posterior corneal surface and corneal thickness at its thinnest spot.

Monitor your keratoconus treatment with ease and improve your surgery outcomes!



EDITED BY JOSEPH P. SHOVLIN, OD

# Out for Blood

*This dry eye treatment may not be first on your list, but it's worth taking into consideration.*

**Q** List the blood product options for dry eye patients. What are their advantages and disadvantages? What contraindications and risks do they carry?

**A** “Dry eye disease is an increasingly common ophthalmic condition that negatively impacts the quality of life of millions worldwide,” says Andrew Fischer, OD, of Professional Eyecare Associates in Indiana. As our understanding of this disease continues to expand, so does the availability of our treatment options, he adds.

Blood-based dry eye treatments have increased in popularity and aided many dry eye patients for whom “traditional” treatment methods may have been unable to provide adequate relief. Blood-based products can be drawn from the patient themselves (autologous) or from a donor (allogeneic) and can be prepared in various treatment forms, including serum eye drops and platelet-derived eye drops. Blood-based drops are indicated for moderate to severe dry eye, persistent epithelial defects, graft-vs.-host disease, recurrent corneal erosions, neurotrophic keratitis and limbal stem cell deficiency, to name a few.

In short, blood-derived dry eye treatments help accelerate corneal

epithelial cell healing by increasing the growth factor available to the ocular surface. While there is an abundance of clinical research supporting the use of blood-based eye drops for dry eye, this treatment is not FDA-approved; therefore, there is not a universally accepted standardized protocol preparation.

## Serum Drops

This is perhaps the most common blood-based product used in dry eye therapy, says Dr. Fischer. To prepare serum eye drops, a sample of blood is obtained, allowed to clot at room temperature and centrifuged to separate the blood cell components from the serum. The serum is then collected and diluted with a balanced salt solution to prespecified concentrations, most commonly 20% and 50% serum by volume, but higher concentrations can be prepared.

These drops have potential limitations, as blood serum can contain pro-inflammatory cytokines, especially in patients with autoimmune diseases such as Sjögren’s syndrome or graft-vs.-host disease. For these patients, autologous serum may be counterproductive and lead to further degradation of the ocular surface.<sup>1</sup>

## Platelet-derived Drops

Options in this category include platelet-rich plasma (PRP), platelet-rich growth factor (PRGF) and platelet lysate (PL). Unlike serum eye drops, these prepara-

tions contain blood platelets, which inherently have high levels of growth hormones, promoting wound healing and corneal epithelial regeneration.<sup>2</sup>

To produce platelet-based drops, an anticoagulant is added to a blood sample, which is then centrifuged and separated into platelet-poor plasma, PRP and red and white blood cells. The PRP is extracted and transferred into dropper bottles for use. Unlike serum eye drops, PRP drops aren’t diluted. PRGF can be produced from PRP by adding calcium chloride, which significantly increases growth factor concentration. PL is derived from PRP, diluted to 30% by volume and frozen then thawed to increase growth factor concentration due to platelet thermolysis.

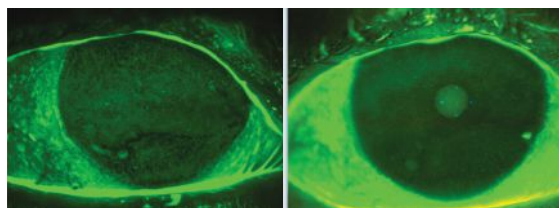
## Takeaways

Contraindications to autologous blood products are largely relative, as the product is ultimately derived from the patient’s own body; however, blood infections, anemia and clotting disorders can be considered contraindications. In these cases, allogenic samples are an option.

Blood-derived dry eye treatments are especially useful in patients who are sensitive to preservatives or request a more holistic approach to dry eye treatment. While the TFOS DEWS II considers blood-based therapy a third-line treatment, it may be worth taking into consideration earlier in the process, especially in patients who could benefit from the robust healing properties of natural growth factors. ■

1. Ma IH, Chen LW, Tu WH, et al. Serum components and clinical efficacies of autologous serum eye drops in dry eye patients with active and inactive Sjogren syndrome. *Taiwan J Ophthalmol.* 2017;7(4):213-20.

2. Alio JL, Rodriguez AE, Ferreira-Oliveira R, et al. Treatment of dry eye disease with autologous platelet-rich plasma: a prospective, interventional, non-randomized study. *Ophthalmol Ther.* 2017;6(2):285-93.

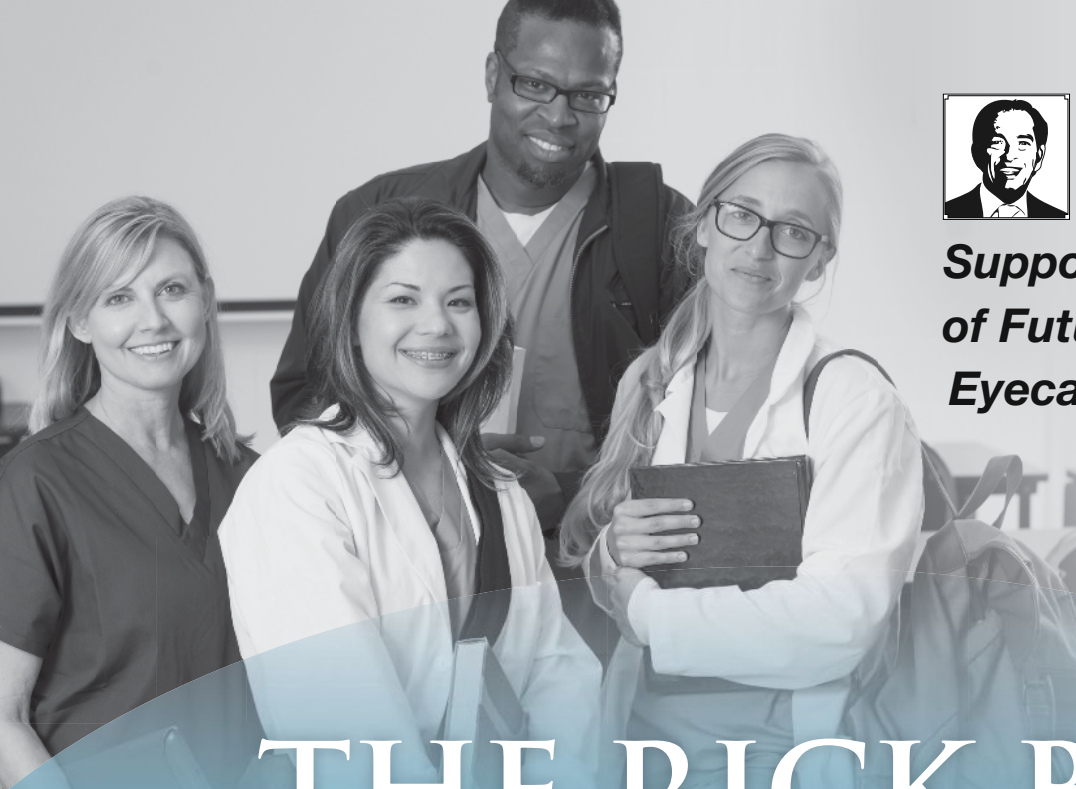


**This dry eye patient experienced significant relief after approximately 12 weeks of blood-based treatment.**

About Dr. Shovlin

Dr. Shovlin, a senior optometrist at Northeastern Eye Institute in Scranton, PA, is a fellow and past president of the American Academy of Optometry and a clinical editor of *Review of Optometry* and *Review of Cornea & Contact Lenses*. He consults for Kala, Aerie, AbbVie, Novartis, Hubble and Bausch + Lomb and is on the medical advisory panel for Lentechs.





THE RICK BAY FOUNDATION  
*for Excellence in Eyecare Education*

**Support the Education  
of Future Healthcare &  
Eyecare Professionals**

# THE RICK BAY FOUNDATION

*for Excellence in Eyecare Education*

Scholarships are awarded to advance the education of students in both **Optometry** and **Ophthalmology**, and are chosen by their school based on qualities that embody Rick's commitment to the profession, including integrity, compassion, partnership and dedication to the greater good.

## INTERESTED IN BEING A PARTNER WITH US?

[www.rickbayfoundation.org](http://www.rickbayfoundation.org)

*(Contributions are tax-deductible in accordance  
with section 170 of the Internal Revenue Code.)*

### **ABOUT RICK**

Rick Bay served as the publisher of *The Review Group* for more than 20 years. To those who worked for him, he was a leader whose essence was based in a fierce and boundless loyalty. To those in the industry and the professions he served, he will be remembered for his unique array of skills and for his dedication to exceeding the expectations of his customers, making many of them fast friends.



*(The Rick Bay Foundation for Excellence in Eyecare Education is a nonprofit, tax-exempt organization under section 501(c)(3) of the Internal Revenue Code.)*



BY JOSEPH W. SOWKA, OD

## THERAPEUTIC REVIEW

# Herpes Hurts

*Temporal pain often portends this condition, so learn how to best manage it.*

**A** 79-year-old man presented with a three-day history of headache and pain and tenderness on the right side of his head. He also had mild ocular discomfort OD and related that it felt similar to when he develops styes; he used artificial tears to no improvement. He denied weight loss, appetite loss and jaw claudication. He was otherwise feeling well.

### Beware a Vesicular Rash

His uncorrected visual acuity was 20/40 OD and 20/30 OS, commensurate with his cataracts. Intraocular pressure (IOP) was 13mm Hg OD and 10mm Hg OS. The remainder of his exam was normal. The only abnormality was a small, isolated vesicular lesion on his right lower eyelid. He did also have diffuse redness to his right forehead scalp, and he reported pain when his right temporal head was palpated.

Due to the head and scalp pain, two alternate diagnoses were considered; namely, herpes zoster dermatitis as the primary consideration and temporal arteritis as a secondary possibility. He was referred to obtain an erythrocyte sedimentation rate, C-reactive protein, platelet count and hemoglobin level, as well as prescribed valacyclovir 1,000mg TID PO.

He returned emergently the next day with rapidly worsening vesicular eruptions across the right side of his face and increased ocular discomfort. His acuity and IOP were unchanged,

but he now had a blistering rash on his forehead extending to his scalp, upper and lower eyelid edema, several subepithelial infiltrates and keratic precipitates on his right cornea and a mild degree of flare in the anterior chamber.

His tests for temporal arteritis were normal. His diagnosis now clearly was herpes zoster dermatitis and ophthalmicus. He was maintained on valacyclovir and prescribed prednisolone acetate 1% QID OS. He was immediately referred to his primary care physician who then added a Medrol Dosepak (oral methylprednisone, Pfizer) and gabapentin 300mg TID PO to the regimen.

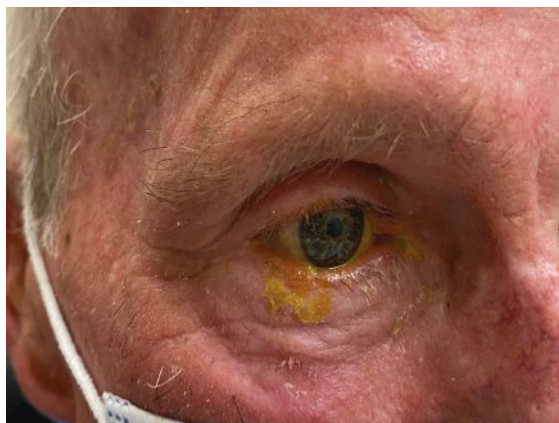### Burning Red

Herpes zoster rash can affect any dermatome on the body, but it most commonly resides in the facial and midthoracic-to-upper lumbar dermatomes.<sup>1,2</sup> The rash appears as erythematous macules and papules, progress-

ing into vesicles in approximately 12 to 24 hours. The rash then progresses into pustules at days three and four, with crusting at seven to 10 days. This rash is often accompanied by a regional lymphadenopathy.<sup>1-8</sup> There is often a prodrome of fever, malaise, headache and dysesthesia over one to four days prior to developing of any visible cutaneous involvement.<sup>1</sup>

In fact, it may take 48 to 72 hours after the onset of pain for any sign of rash to emerge. At this stage, the diagnosis may be elusive and, in some instances, can be mistaken for giant cell arteritis. Burning pain classically precedes dermatologic involvement and can persist for several months after the rash resolves.<sup>1-12</sup> Following resolution of the crusting pustules, about 9% of all patients suffer from extreme pain known as postherpetic neuralgia.<sup>1-8</sup> Severe and possibly debilitating pain remains, despite the absence of active, visible skin lesions.<sup>1-12</sup>

The presentation of herpes zoster ophthalmicus (HZO) may vary from dermatologic involvement alone to ocular manifestations such as lid retraction, keratitis, scleritis, uveitis, glaucoma, retinitis (acute retinal necrosis and progressive outer retinal necrosis), optic neuritis and panophthalmitis. When ocular manifestations arise, the condition is termed HZO; it occurs in 7% of all zoster patients.<sup>2,4</sup> Anecdotally, cases involving the eye have been observed to produce adnexal pain over months, without iritis, uveitis or vesicular breakout, making the chief complaint a mystery until the skin manifestations appear. The lesions of herpes zoster generally completely resolve within one to three weeks.<sup>6,7</sup>

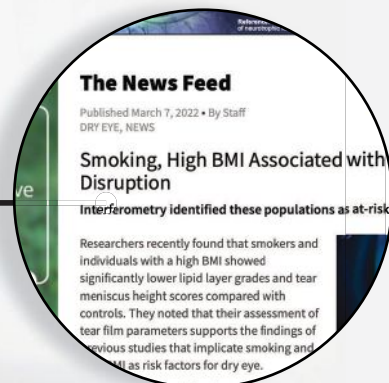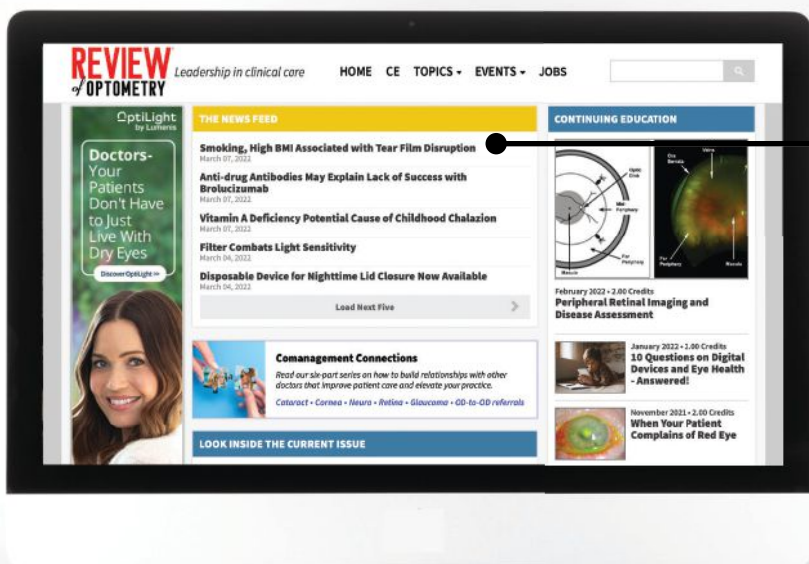


**Initial presentation with mild eyelid involvement only.**

**About Dr. Sowka**

**Dr. Sowka** is an attending optometric physician at Center for Sight in Sarasota, FL, where he focuses on glaucoma management and neuro-ophthalmic disease. He is a consultant and advisory board member for Carl Zeiss Meditec and Bausch Health.

Find out first from



## THE NEWS FEED

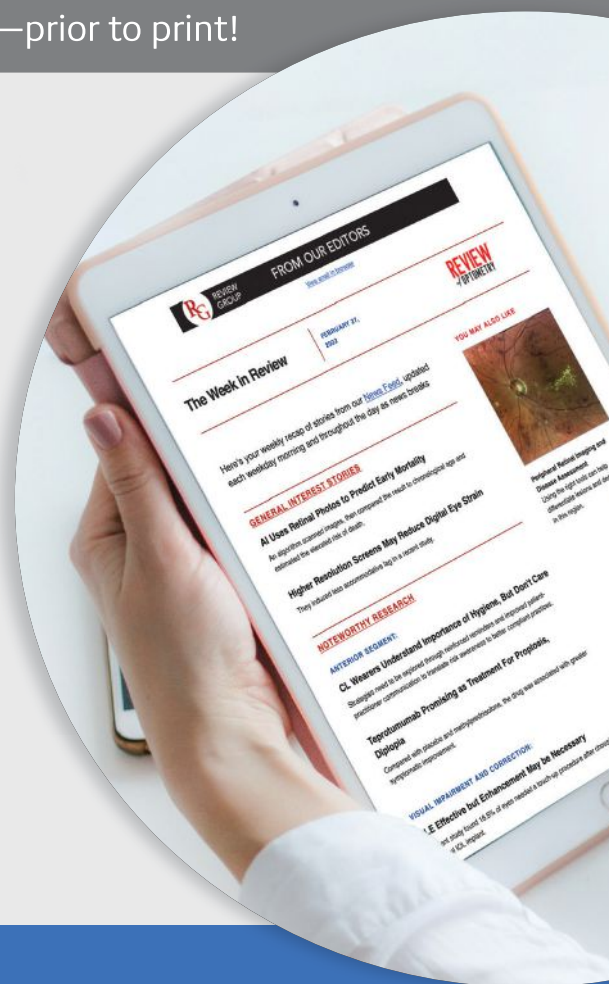
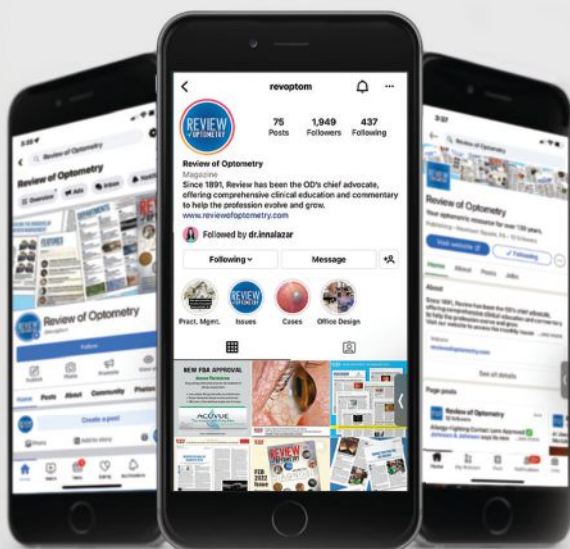Updated every weekday

[www.reviewofoptometry.com/news](http://www.reviewofoptometry.com/news)

OVER 60 NEWS STORIES PUBLISHED EVERY MONTH  
Read the latest news as it happens—prior to print!

### Three ways to keep up with current events:

- 1 on the website
- 2 through social media
- 3 in your inbox



FACEBOOK: /revoptom  
INSTAGRAM: @revoptom

TWITTER: @revoptom  
LINKEDIN: review-of-optometry



Varicella zoster virus (VZV) causes chickenpox and herpes zoster represents a separate clinical condition caused by the same virus.<sup>1-12</sup> The VZV is a member of the herpesvirus family. Varicella is spread by direct contact with active skin lesions or airborne via droplets and is highly contagious. The virus has an affinity for the upper respiratory tract and typically enters the human system through the conjunctiva and/or nasal or oral mucosa, producing the characteristic pox appearance.<sup>1-10</sup> When the host's immunity fails, the dormant virus leaves the confines of the dorsal root ganglion, where it lies dormant to produce chickenpox upon first infection or shingles (the zoster presentation) upon recurrence.<sup>1-12</sup>

Ninety percent of the population develops serological infection by adolescence, with nearly 100% of the population having some evidence of antibodies to the disease by age 60.<sup>1</sup> Only 20% of patients suffer reactivation after initial infection.<sup>2</sup> Any condition that decreases immune status, such as human immunodeficiency virus infection, chemotherapy, malignancy and long-term oral corticosteroid or other immunosuppressant use, increases the risk of herpes zoster activation. A second reactivation is even more rare and occurs mostly in immunosuppressed patients such as organ transplant recipients or those who suffer from AIDS or neoplasm.<sup>1</sup>

### Treatment

Herpes zoster is managed using orally administered antiviral medications such as acyclovir (800mg PO five times a day), famciclovir (500mg PO TID) and valacyclovir (500mg to 1,000mg BID-TID for one week).<sup>1,10,12,13</sup> The antiviral medications are most effective when initiated within 72 hours of the onset of the rash, especially for reducing the degree of post-herpetic neuralgia.<sup>12</sup>

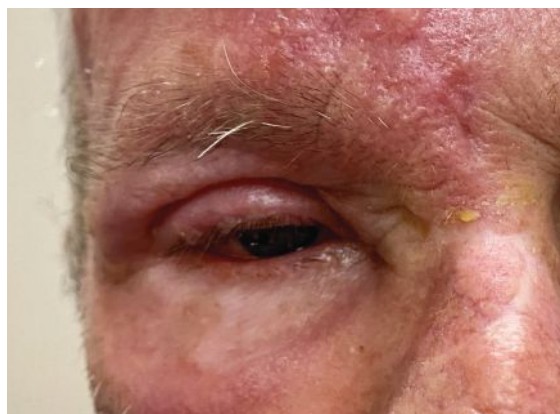Orally administered corticosteroids can reduce pain and potentially the onset of postherpetic neuralgia.<sup>10,12</sup> Since the disease is self-limiting, most

care is palliative, including the use of astringents, such as calamine lotion or aluminum acetate solution to minimize weeping and soothe the affected area, and topical antibiotic creams and ointments to prevent secondary infection. Patients with postherpetic neuralgia may require narcotics for pain control.<sup>12</sup> Tricyclic antidepressants and anticonvulsants in low dosages are potential options for unremitting pain.<sup>12</sup> Capsaicin cream (based on the chemical in chili peppers that makes them hot), lidocaine patches and injectable nerve blocks can be used in the worst cases.<sup>12</sup>

Antiviral agents can play role in preventing varicella zoster disease in immunocompetent and immunosuppressed patients.<sup>10</sup> As with herpes zoster, acyclovir has been documented as effective in preventing disease reactivation, but the proper dose, duration and circumstance of its uses are controversial.<sup>10</sup>

Since VZV-specific cell-mediated immunity and cell-mediated immunity in general declines with age, it should be expected that the incidence of herpes zoster virus (HZV) increases with age. This may explain the increased incidence of HZV in immunocompromised individuals or those who are undergoing immunosuppressive therapy.<sup>7,8</sup> Therefore, any patient younger than 50 who presents with signs of an acute zoster infection must be referred to rule out an immunocompromised state.

It is now well-accepted that herpes zoster should be combated prophylactically through vaccination. Shingrix (GlaxoSmithKline), a recombinant zoster vaccine, reduces the incidence of herpes zoster by more than 90% and is preferred to the live, attenuated herpes zoster vaccine used previously. Shingrix is approved for adults 50 years and older. The Centers for Disease Control and Prevention's Advisory Committee on Immunization Practices recom-



**Profound vesicular eruption the next day despite being on oral antiviral medication.**

mends this vaccine for adults 60 years and older, except for certain immunosuppressed patients.<sup>14,15</sup>

For the patient reported here, upon his last follow-up eight weeks after his initial presentation, his ocular inflammation resolved on topical steroids and had been discontinued, as had the valacyclovir. He reported a great improvement in all findings, though he was still on gabapentin for postherpetic neuralgia. ■

1. Gurwood AS, Savochka J, Sirgany BJ. Herpes zoster ophthalmicus. *Optometry*. 2002;73(5):295-302.
2. McCrary ML, Severson J, Tyring SK. Varicella zoster virus. *J Am Acad Dermatol*. 1999;41(1):1-14.
3. Ragozzino MW, Melton LJ III, Kurland LT, et al. Population-based study of herpes zoster and its sequelae. *Medicine (Baltimore)*. 1982; 61:310-6.
4. Karbassi M, Raizman MB, Schuman JS. Herpes zoster ophthalmicus. *Surv Ophthalmol*. 1992;36(6):395-10.
5. Cobo M, Foulks GN, Liesegang TJ, et al. Observations on the natural history of herpes zoster ophthalmicus. *Curr Eye Res*. 1987;6(1):195-9.
6. Burgoon CF, Burgoon JS, Baldrige GD. The natural history of herpes zoster. *J Am Med Assoc*. 1957;164(3):265-9.
7. Arvin AM. Investigations of the pathogenesis of Varicella zoster virus infection in the SCIDhu mouse model. *Herpes*. 2006;13(3):75-80.
8. Carreño A, López-Herce J, Verdú A, et al. Varicella encephalopathy in immunocompetent children. *J Paediatr Child Health*. 2007;43(3):193-5.
9. Heininger U, Seward JF. Varicella. *Lancet*. 2006;368(9544):1365-76.
10. Boeckh M. Prevention of VZV infection in immunosuppressed patients using antiviral agents. *Herpes*. 2006;13(3):60-5.
11. No author listed. Chickenpox, pregnancy, and the newborn. *Drug Ther Bull*. 2005;43(9):69-72.
12. Stankus SJ, Dlugopolski M, Packer D. Management of herpes zoster (shingles) and postherpetic neuralgia. *Am Fam Physician*. 2000;61(8):2437-48.
13. Martin JB. Viral encephalitis and prion diseases. In: Fauci AS, Braunwald E, Isselbacher KJ, et al. eds. *Harrison's Principles of Internal Medicine*, (14th ed.), New York: McGraw-Hill, 1998;1023-31.
14. Schmader K. Herpes Zoster. *Ann Intern Med*. 2018;169(3):ITC19-31.
15. Saguil A, Kane S, Mercado M, Lauters R. Herpes zoster and postherpetic neuralgia: prevention and management. *Am Fam Physician*. 2017;96(10):656-63.



# EAST COAST OPTOMETRIC GLAUCOMA SYMPOSIUM

MAY 6–7, 2022

GRAND HYATT  
1000 H STREET NW, WASHINGTON, DC



IN-PERSON EVENT

## OVERVIEW

The East Coast Optometric Glaucoma Symposium (ECOGS) meeting will be held as an in-person event. This two-day biannual symposium is designed to provide optometrists with exposure to current thinking on evolving standards of care, state-of-the-art technology and breaking research that will guide current and future glaucoma care in the optometric setting. Incorporating cases, clinical pearls, and discussion sessions, the program will maximize the opportunity for participant/ faculty engagement.

The OGS conferences are long-running and trusted programs for optometrists managing patients with glaucoma. Each East Coast symposium focuses on glaucoma diagnosis and management, with the West Coast symposium focusing on therapies and innovations for comprehensive glaucoma coverage.

## PROGRAM CO-CHAIRS



**Murray Fingeret, OD, FAAO**  
Clinical Professor  
State University of New York  
College of Optometry  
Founding Member  
Optometric Glaucoma Society  
President, Optometric Glaucoma  
Foundation Hewlett, New York



**Robert N. Weinreb, MD**  
Chair & Distinguished Professor  
of Ophthalmology  
UC San Diego  
Director, Shiley Eye Institute  
Director  
Hamilton Glaucoma Center  
Morris Gleich MD  
Chair in Glaucoma  
San Diego, California

## FACULTY



**Michael Chaglasian, OD, FAAO**  
Associate Professor  
Illinois College of Optometry  
Chief of Staff  
Illinois Eye Institute  
Executive Vice President  
Optometric Glaucoma Society  
Chicago, Illinois



**Jonathan S. Myers, MD**  
Chief of Wills Eye Glaucoma  
Service Associate Professor  
of Ophthalmology Thomas  
Jefferson University's  
Sidney Kimmel Medical College  
Philadelphia, Pennsylvania



**Anthony Realini, MD, MPH**  
Professor of Ophthalmology  
Director of Glaucoma Fellowship  
Vice Chair for Clinical Research  
West Virginia University  
Morgantown, West Virginia

Earn up to 12 LIVE COPE credits\*

For more information and to register, visit:

[www.reviewedu.com/ogseast](http://www.reviewedu.com/ogseast)



\*Approval pending



BY JAMES L. FANELLI, OD

## GLAUCOMA GRAND ROUNDS

# A Tale of Two Patients

*One had more structural damage, the other had more progression. Here's how to proceed in both cases of glaucoma.*

**T**wo Caucasian females, both in their late 70s, presented as new patients in order to establish care. Both had similar histories insofar as having been diagnosed with glaucoma for several years and managed with medications and surgery. One patient had SLTs performed bilaterally, whereas the other had bilateral SLTs and a trabeculectomy in one eye. Upon presentation, both were clearly in the advanced stage of their glaucoma. And then their stories diverged somewhat.

They were initially seen by me approximately 12 months apart, with the latter having been a patient of mine now for only nine months or so. Where I practice has a very large influx of patients who are moving to the area for retirement. Inheriting someone else's patient is part and parcel of having a glaucoma practice, but at the end of the day, successfully

managing these patients is a win-win for everyone: the patient, myself and the practice.

### Management Challenges

While the majority (about 75%) of glaucoma patients fall into the mild to moderate category, some will certainly fall into the advanced category (about 15%), and the remaining will fall into the refractory category (about 10%), meaning that despite appropriate therapy, they continue to progress or have difficulty maintaining stability. Optometry is well positioned to manage the 75% of glaucoma cases that fall into the mild to moderate stage and often can do so without the assistance of our non-optometric ophthalmic colleagues. Even the 15% of patients who have advanced disease can be managed by optometry and surgical intervention. But oftentimes, in cases of advanced disease, there are some refractory patients who need further care by fellowship-trained glaucoma surgeons.

Our challenge in managing patients with advanced disease lies in making sure they remain stable. In essence, this is our goal for all glaucoma patients. Certainly, in mild to moderate disease states, there is a bit of room for some progression throughout the patient's lifetime without significant effects on quality of life, but in patients with advanced disease, there is little room for progression. Once progression is even subtly determined, a

change in therapy is warranted, often involving a surgical strategy.

Determining progression in glaucoma involves both structural and functional testing. Studies seem to indicate that patients with minimal to no visual field loss are best identified as having progressed by changes seen in their OCT findings, whereas individuals with more advanced disease seem to demonstrate progression more readily with visual field changes.<sup>1</sup> This is certainly partly attributable to the floor effect seen when there is significant loss of retinal ganglion cells, but these rules are not steadfast in all cases. At the end of the day, both structural and functional testing is required for all glaucoma patients, independent of disease staging.

One of the inherent difficulties in visual field studies is the subjectivity of the testing, not to mention the simple truth that many patients do not enjoy sitting for a visual field test. Reliability indices can clearly give an indication as to the usefulness of the visual field in determining whether or not there is progression. Perhaps newer visual field platforms, such as virtual reality headset-based field testing, may make the testing experience more enjoyable for the patient and more reliable as well. We've introduced virtual reality visual field testing in my office, and to my surprise, the large majority of patients who have used the device have actually commented that they enjoy that modality.

### Case Details

Both patients' BMO-MRW printouts showed significant erosion of the neuroretinal rims in just about all sectors of the optic nerves, especially temporally. One of the places to look for structural progression of glaucoma (in addition to the circumpapillary



**Olleyes virtual reality visual field unit. Full glaucoma threshold visual field capability is available on the device.**

**About Dr. Fanelli**

**Dr. Fanelli** is the founder and director of the Cape Fear Eye Institute in Wilmington, NC. He is chairman of the EyeSki Optometric Conference and the CE in Italy/Europe Conference. He is an adjunct faculty member of PCO, Western U. and UAB School of Optometry. He is on advisory boards for Heidelberg Engineering and Glaukos.





# YOU WON'T WANT TO MISS THIS!

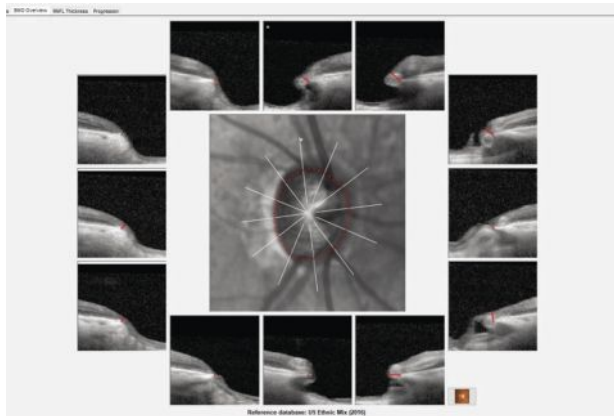
The Academy is pleased to recognize the many achievements and innovations of our profession and honor those who have guided us through our first century.

RSVP when Academy 2022 San Diego registration opens in May.\*

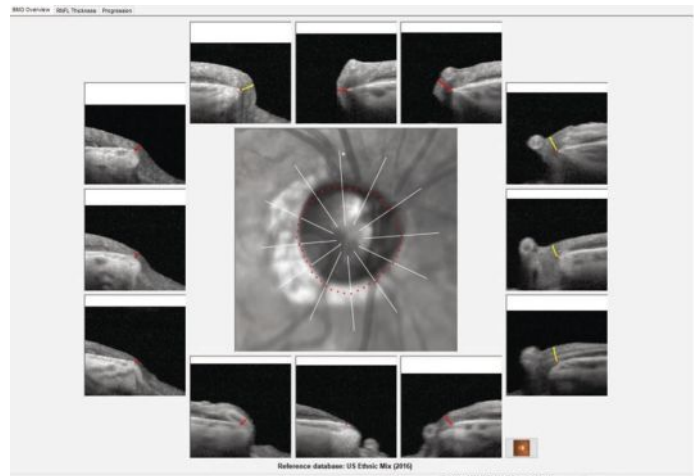
CENTENNIAL  
*Celebration*  
October 28, 2022

*\*Included in registration.*





**Radial optic nerve scans obtained at the 12 o'clock position with significant thinning of the neuroretinal rim from six o'clock through 12 o'clock in the right eye of the patient with more advanced structural damage.**



**Erosion of the temporal neuroretinal rim in the right eye of the other patient.**

RNFL) is the neuroretinal rim. OCT of these patients should include scans of the RNFL, BMO and macular ganglion cell layer, all the while looking for subtle signs of progression.

Interestingly, the patient with slightly more advanced structural damage, the most recent of the two, has remained stable throughout the time I have seen her, but the other has progressed, which is especially evident in the ganglion cell layer analysis.

She has been a challenge from the first visit, presenting with an extensive history of red irritated eyes, sensitivity to several glaucoma medications, a failed trabeculectomy in one eye and IOPs in the mid-teens OU. She was on a steroid drop TID to control for inflammation and three separate glaucoma medications. Frankly, her eyes were not quite as advanced as the other patient, she is the one who has been

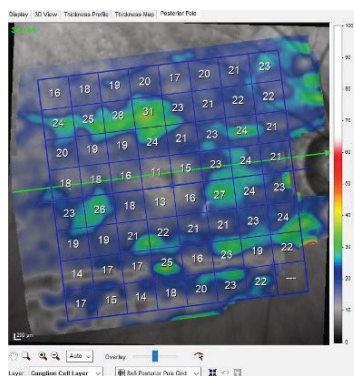
My initial goal of her treatment was threefold: (1) to decrease her medication burden, (2) to reduce her chronic inflammation and (3) to obtain better IOP control. After reviewing her previous records and adjusting a variety of her medications, slowly but surely, and with very close monitoring, we were able to achieve a reasonably good outcome of all three goals. This took, however, the better part of six months to accomplish. All the while, her fields and OCT findings remained stable.

Unfortunately, her OCTs began to show subtle change recently, and without any realistic medical options left, she was referred to the most appropriate glaucoma surgeon for further intervention. While her disease was not quite as advanced as the other patient, she is the one who has been

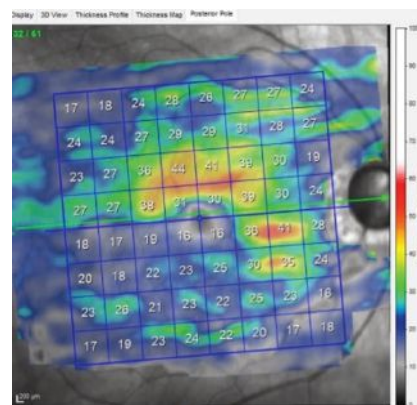
experiencing consistent progression while in my care.

Will this patient be seeing the glaucoma surgeon exclusively from here on out? No, the glaucoma surgeon will render what surgical intervention they believe would best suit the patient, but she will ultimately return to my care for continued management. It's important to find the right glaucoma surgeon, one who provides the best care for the patient and has mutual respect for all members of their care team. Great glaucoma surgeons do great things in the operating room and recognize that great optometrists do great things in the office. And sometimes, that great glaucoma surgeon is not in your home town. ■

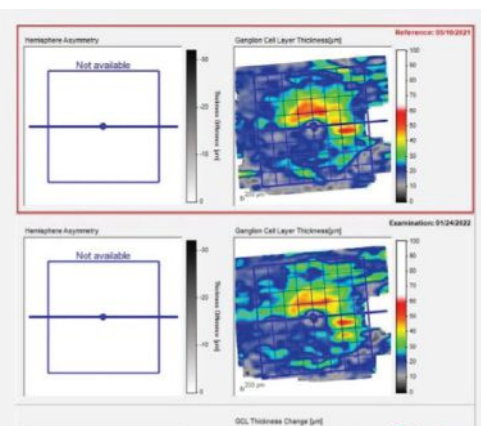
1. Abe RY, Diniz-Filho A, Zangwill LM, et al. The relative odds of progressing by structural and functional tests in glaucoma. *Invest Ophthalmol Vis Sci.* 2016;57(9):421-8.



**An exceedingly thinned ganglion cell layer in the macula of the patient with more advanced structural damage.**



**Subtle progression in ganglion cell layer loss in the other patient.**





PRESENTS

# Innovations and Implementations in Practice

JUNE 10–11, 2022

RENAISSANCE NEWPORT BEACH HOTEL  
4500 MACARTHUR BLVD, NEWPORT BEACH, CALIFORNIA



IN-PERSON EVENT

## OVERVIEW

The Intrepid Eye Society, in tandem with Review Education Group and MedscapeLIVE!, look forward to bringing you “Intrepid Presents” in an in-person format in June 2022.

The Intrepid Eye Society is a group of emerging thought-leaders in optometry looking to promote excellence and growth in our field through innovation and implementation. We’ll discuss future medical therapeutics, diagnostics, practice development, research and development, and collaborative care.

## CO-CHAIRS



**Nate Lighthizer, OD, FAAO**

Chief of Specialty Care and Dry Eye Clinics  
Director of Continuing Education  
Associate Professor  
Associate Dean  
NSU Oklahoma College of Optometry  
Intrepid Eye Society - President



**John D. Gelles, OD, FIAO, FCLSA, FSLs, FBCLA**

Director, Specialty Contact Lens Division  
Cornea and Laser Eye Institute  
CLEI Center for Keratoconus  
Clinical Assistant Professor  
Department of Ophthalmology  
Rutgers New Jersey Medical School  
Intrepid Eye Society - Education Chair

Earn up to 14 LIVE COPE credits\*

For more information and to register, visit:  
[www.reviewedu.com/ies](http://www.reviewedu.com/ies)



\*Approval pending







# Visually Handicapped

*This patient's medical history and genetics played a key role in finding the correct diagnosis.*

**A** 35-year-old mentally handicapped Hispanic male presented with his mother for a second opinion on possible treatment options to help him see better. He reported a gradual painless, progressive loss of vision in both eyes that started at about nine years old. His mother reported that his vision was so poor by age 14 that he was only able to detect light.

His medical history is significant for mental delay. He also has hearing loss and polycystic kidney disease. As a child, he had strabismus surgery on the right eye to improve alignment and also had surgery to remove extra toes.

On examination, he had only light perception vision in each eye. Though his extraocular alignment appeared normal, he did have roving eye movements. His pupils were equal, round

and reactive to light; there was no afferent pupillary defect. Tensions by applanation tonometry measured 12mm Hg in each eye. The anterior segment was unremarkable.

Dilated fundus exam was significant for vitreous syneresis and a posterior vitreous detachment in each eye. Other changes can be seen in *Figures 1, 2, 3 and 4*.

## Take the Retina Quiz

*1. What is the likely diagnosis for this patient?*

- a. Fundus albipunctatus.
- b. Retinitis pigmentosa.
- c. Stargardt's macular disease.
- d. Gyrate atrophy.

*2. What is the likely etiology?*

- a. Bardet-Biedl syndrome.
- b. Defect in ABC4 gene.

- c. Usher's syndrome.
- d. Non-specific hereditary retinal degeneration.

*3. What other systemic findings would you expect to see in this patient?*

- a. Tall, thin stature.
- b. Cardiac abnormalities.
- c. Testicular hypogonadism.
- d. Normal development.

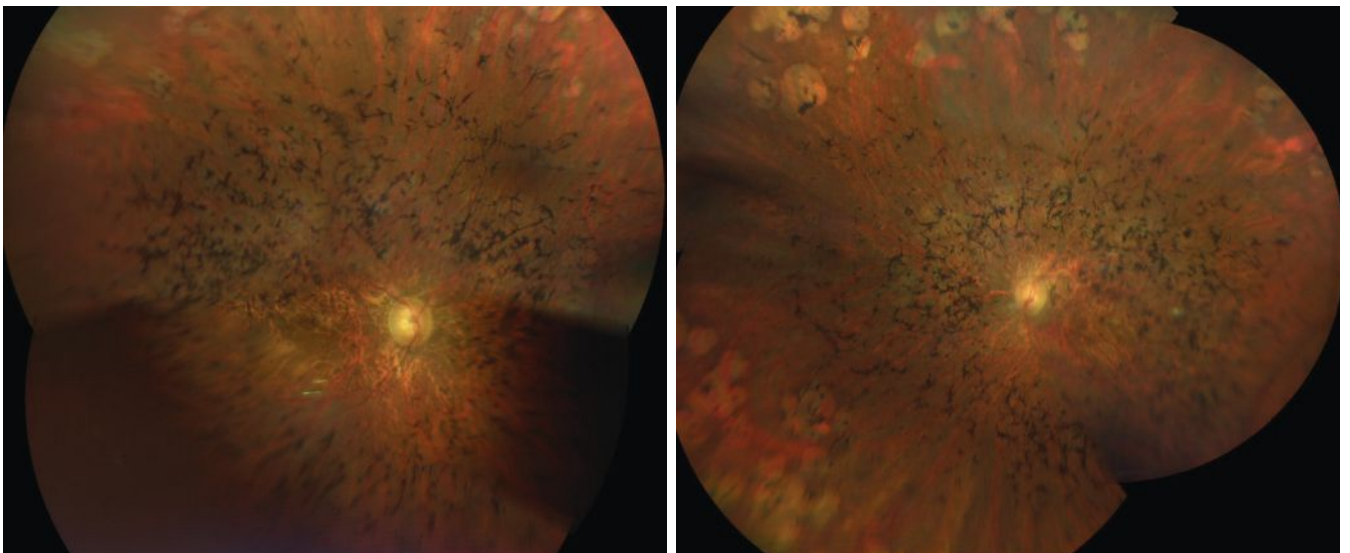
*4. What treatment options should be considered for this patient?*

- a. Stem cell implantation.
- b. Genetic therapy.
- c. Argus retinal implant.
- d. All of the above.

*For answers, see page 98.*

## Diagnosis

Sadly, our patient has advanced retinitis pigmentosa (RP). There is extensive bone pigment spicules throughout the arcades and extending into the posterior pole. The vessels are severely attenuated and there is some pallor of the optic nerve, but not as much as you would expect considering how advanced his disease is.

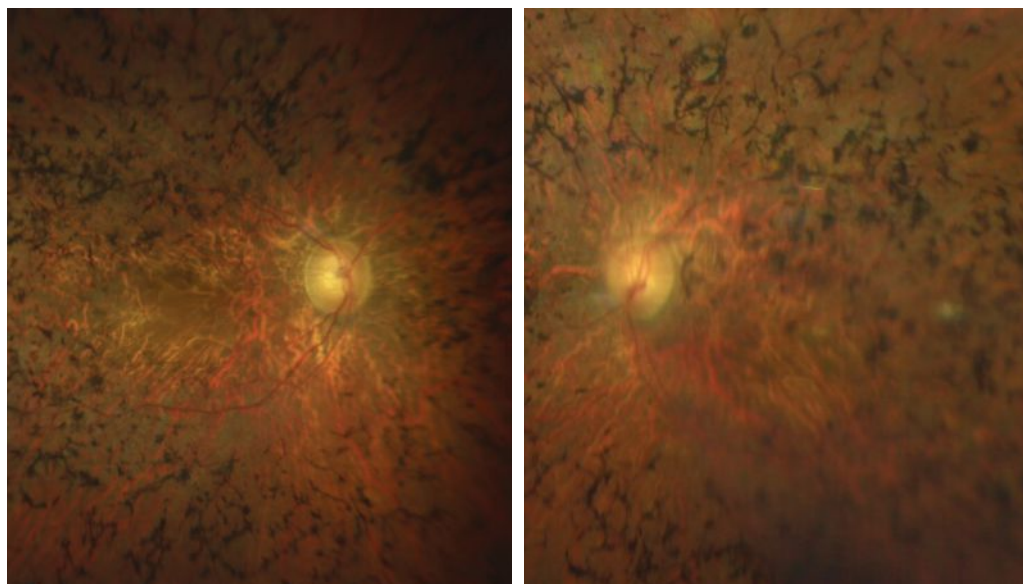


**Figs. 1 & 2. Here is a widefield view of the right and left eye of our patient. How do you explain the clinical findings?**

**About Dr. Dunbar**

**Dr. Dunbar** is the director of optometric services and optometry residency supervisor at the Bascom Palmer Eye Institute at the University of Miami. He is a founding member of the Optometric Glaucoma Society and the Optometric Retina Society. Dr. Dunbar is a consultant for Carl Zeiss Meditec, Allergan, Regeneron and Genentech.

RP is a genetically heterogeneous group of disorders with varying modes of inheritance from autosomal dominant to x-linked recessive. Patients will develop bilateral, progressive vision loss, typically between the ages of nine and 19 with no sex or race predilection.<sup>1</sup> Symptoms include night blindness (most common), loss of peripheral vision, reduced color vision and blurred vision.<sup>2-3</sup> Signs include the triad of perivascular bone-spicule pigmentation in the mid-periphery, waxy pallor of the optic disc and vessel attenuation. Other



**Figs. 3 & 4. Here is a closer view of the macula and posterior pole of our patient. How would you characterize the optic nerves?**

findings commonly seen in RP include cystoid macular edema, diffuse RPE atrophy, optic disc drusen (10%), epiretinal membrane, vitreous condensation, keratoconus and posterior subcapsular cataracts (35% to 51% of cases).<sup>2</sup>

## Discussion

An estimated 100,000 people in the United States have RP and more than 80 mutated genes are known to cause this condition.<sup>4,6</sup> In fact, RP may represent many different genetic disorders leading to a final common pathway that is clinically recognized as RP. The vast majority of cases affect only the eyes; however, there are several systemic conditions that are associated with RP, including Usher's syndrome and Bardet-Biedl syndrome (BBS), among others. It is evident based on our patient's medical history and clinical findings that he has BBS.

BBS is a genetic condition that impacts multiple body systems. It is classically defined by six features: obesity (specifically, fat deposition along the abdomen), intellectual impairments, kidney problems, genital and hormonal problems (hypogonadism), extra toes and digits (polydactylism) and visual impairment in the form of a rod-cone dystrophy, which occurs in 90% of patients with BBS.<sup>7</sup> This condition

develops as the result of mutations in more than 21 different genes and is usually autosomal recessive. Of the 21 genes, the most common are BBS1 (28% of cases), BBS10 (10% of cases), BBS2, BBS12 and ARL.<sup>6,7</sup>

Interestingly, there is no clear link between the different mutations identified and disease severity, but some trends have emerged. Patients with mutations in the BBS1 gene seem to have milder ophthalmologic involvement, whereas patients with mutations in the BBS2, BBS3 and BBS4 genes experience classic deterioration in their vision. Our patient had all the classic features of BBS including, unfortunately, severe RP.<sup>8</sup>

There is no specific cure for RP. For blind individuals with this condition, the Argus II Retinal Prosthesis System is considered with the hopes of providing useful vision to those that are severely impacted. The device combines a miniature eye implant with a patient-worn camera and a processor; it stimulates the visual cortex to sense shimmering, light or dark patterns or spots. The patient must learn how to interpret these signals as shapes and objects. The vision generated by Argus II is very different from traditional sight and the patient learns to interpret the new "language" of sight.<sup>9</sup>

Unfortunately, our patient was not a candidate for the Argus II because of his roving eye movements and mental delay. In these types of situations, we make sure visually handicapped patients are referred to the Miami Lighthouse for the Blind, but our patient was already well-connected. In fact, he had been using a mobile cane for close to 20 years. He travels by himself to places such as the Lighthouse, the gym and the mall while using public transportation, and he is fluent in Braille. ■

1. Fahim AT, Daiger SP, Weleber, RG. Nonsyndromic retinitis pigmentosa overview. *Gene Reviews*. January 19, 2017.
2. Hamel C. Retinitis pigmentosa. *Orphanet J Rare Dis*. 2006;1:40.
3. Iannaccone A, Berdia, J. Retinitis Pigmentosa. National Organization for Rare Disorders (NORD) [www.rarediseases.org/rare-diseases/retinitis-pigmentosa](http://www.rarediseases.org/rare-diseases/retinitis-pigmentosa). July 5, 2016. Accessed March 17, 2022.
4. Birtel J, Gliem M, Mangold E, et al. Next-generation sequencing identifies unexpected genotype-phenotype correlations in patients with retinitis pigmentosa. *PLoS One*. 2018;13(12):e0207958.
5. Ge Z, Bowles K, Goetz K, et al. NGS-based molecular diagnosis of 105 eyeGENE probands with retinitis pigmentosa. *Sci Rep*. 2015;5:18287.
6. Haer-Wigman L, van Zelst-Stams WA, Pfundt R, et al. Diagnostic exome sequencing in 266 Dutch patients with visual impairment. *Eur J Hum Genet*. 2017;25(5):591-9.
7. Bardet-Biedl Syndrome (BBS): for patients. *Gene Vision*. [www.gene.vision/knowledge-base/bardet-biedl-syndrome-bbs-for-patients/#cite\\_note-1](http://www.gene.vision/knowledge-base/bardet-biedl-syndrome-bbs-for-patients/#cite_note-1). November 30, 2020. Accessed March 17, 2022.
8. Bardet Biedl Syndrome. National Organization of Rare Disease Database (NORD). [www.rarediseases.org/rare-diseases/bardet-biedl-syndrome](http://www.rarediseases.org/rare-diseases/bardet-biedl-syndrome). Accessed March 17, 2022.
9. Discover Argus II. Second Sight. [www.secondsight.com/discover-argus](http://www.secondsight.com/discover-argus). 2019. Accessed March 17, 2022.



EDITED BY DEREK N. CUNNINGHAM, OD,  
AND WALTER O. WHITLEY, OD, MBA

## SURGICAL MINUTE

# Ring Me Up

*The IC-8 IOL creates a permanent pinhole effect, improving the prospects for a monovision approach.*

BY JAKE WYSIADLOWSKI, OD  
AUSTIN, TX

As surgical technology evolves, the number of options we have to improve post-cataract vision continues to grow. FDA approval seems imminent for the IC-8 intraocular lens (IOL) from Acufocus, which stands out among the rest by combining small-aperture optics with a monofocal lens. This lens adds a small mini-ring in its center that extends depth of focus. The lens is designed to mitigate the visual effects of unfocused peripheral light.

## Range of Benefits

The 1.36mm aperture of the ring only allows focused rays of light onto the retina, while the peripheral, defocused rays are blocked by the 3.23mm mask, a descendant of the now-discontinued Kamra corneal inlay. It is a one-piece hydrophobic, acrylic IOL with a 6mm optic zone, 12.5mm length and powers that range from +10D to +30D in 0.50D steps.

A toric design has not been released; however, the IOL can work for up to 1.50D of astigmatism due to the pinhole effect. The lens has been reported to provide up to 3D of extended depth of focus with a monovision offset, reduce effects of lower and higher-order aberrations and allows plus or minus 1D of deviation from target refraction.

For a video of the procedure, read this article online at [www.reviewofoptometry.com](http://www.reviewofoptometry.com).

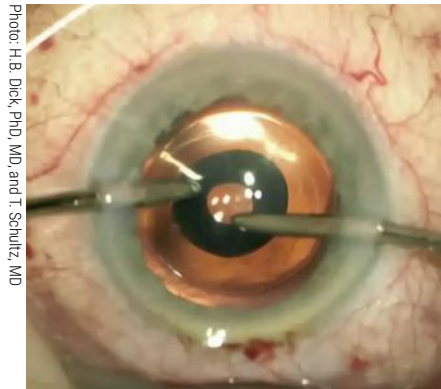


Photo: H.B. Dick, PhD, MD, and T. Schultz, MD

**The mini-ring in the center of the IC-8 IOL extends a patient's depth of focus.**

## Implanting the Lens

In most cases, the IC-8 lens is used in combination with a low amount of monovision, typically -0.75D to -1D. The lens is implanted in the non-dominant eye and a monofocal IOL with an aim of plano is placed in the dominant eye. Assuring the lens is well-centered with the visual axis to allow the optics to work properly is important.

Also, refracting these patients can yield interesting results due to the extended depth of focus. For this reason, a midpoint refraction or a red/green balance refraction is recommended. For the midpoint refraction, begin with a manifest refraction, then determine the maximum plus and maximum minus lenses to blur, and then determine the midpoint. For the red/green balance refraction, you want the patient to report the letters on the green and red side being equal in clarity.

Surgeons have reported good near and intermediate vision with better

distance vision compared to traditional monovision. There is also less ametropia due a lower amount of offset for the IC-8 IOL eye.

## Who Can Benefit from IC-8?

Patients with irregular corneas from keratoconus or previous refractive surgeries such as radial keratotomy could benefit from this lens because only central light rays reach the retina. However, due to the reduced amount of light entering the light with this modality, it is important to be cautious if considering implanting bilaterally. The lens may also be beneficial in those reporting light sensitivity or problems with glare.

Patients with central corneal scarring, large pupils, macular pathology, severe glaucoma, AMD, vitreous opacities or even those with high need for near vision should not be considered candidates for this IOL. Patients with pupils larger than the mask can notice dysphotopsias. Reduced contrast sensitivity can occur, as well as a minor reduction in visual field. Patients may report difficulties in low-light conditions due to the IOL design.

Postoperative management is fairly similar to other IOLs with a few extra considerations, including thorough patient education on this type of lens modality, which will provide a smoother postoperative period.

From patients desiring presbyopia correction to those looking for greater functional range of vision, this unique IOL should provide solutions for appropriately selected and properly educated patients. ■

## ABOUT THE AUTHOR



**Dr. Wysiadlowski** is an ocular disease resident at Dell Laser Consultants in Austin, TX.

About Drs.  
Cunningham and Whitley

**Dr. Cunningham** is the director of optometry at Dell Laser Consultants in Austin, TX. He has no financial interests to disclose. **Dr. Whitley** is the director of professional relations and residency program supervisor at Virginia Eye Consultants in Norfolk, VA. He is a consultant for Alcon.



# New Technologies & Treatments in Eye Care



**REGISTER NOW**

**SEPTEMBER 9–11, 2022**

SAN ANTONIO, TEXAS

**NOVEMBER 11–13, 2022**

ORLANDO, FLORIDA

## LETTER FROM THE CHAIR

Dear Colleagues,

I am thrilled to welcome you to our New Technologies & Treatments in Eye Care conference series - in person for 2022!

NT&T continues to serve as a forum to gain clinical pearls and insights that we know you're going to face in clinical practice routinely and regularly, but even some of the rarer forms of cases and presentations so that the next time you see it, you'll have a new sense of understanding and ability to manage it effectively.

We strive to continually offer educational sessions that will strengthen the practical and clinical skills you need to improve the overall quality, efficacy and patient care in your clinic.

Join our renowned faculty live as they share their expertise on glaucoma, retinal disease, ocular surface disease and much more.

I look forward to seeing you in person for this engaging and innovative experience!

Sincerely,



**Paul M. Karpecki, OD, FFAO**

Director of Cornea, Kentucky Eye Institute  
Chief Clinical Editor, Review of Optometry  
Director, CJO Optometric Dry Eye Guidelines for EyeCare

Earn up to 19 LIVE COPE credits\*

[www.reviewedu.com/ntt2022](http://www.reviewedu.com/ntt2022)



Practice For Sale



Practice Sales • Appraisals • Consulting  
[www.PracticeConsultants.com](http://www.PracticeConsultants.com)

**PRACTICES FOR SALE  
NATIONWIDE**

Visit us on the Web or call us to learn more about our company and the practices we have available.

[info@PracticeConsultants.com](mailto:info@PracticeConsultants.com)

**925-820-6758**

[www.PracticeConsultants.com](http://www.PracticeConsultants.com)

**Charleston SC  
Practice For Sale**

Gross over \$500K on 3.5 days  
Seller owns 1000 sq/ft suite  
EMR and medical model

Call 843 906-9694

Email [3Dmira@gmail.com](mailto:3Dmira@gmail.com)

**Practice for Sale**

Well established rural optometry practice including building and land in Lake Isabella, Ca.

Contact

[llwagwag@yahoo.com](mailto:llwagwag@yahoo.com)

**Practice Opportunity**

**Work in the South Pacific!**

High-tech US clinic hiring US-licensed medical OD

Full/part-time or locum

Contact [davidkhorram@gmail.com](mailto:davidkhorram@gmail.com)

**REVIEW  
of OPTOMETRY**

Do you have Products and Services for sale?

**CLASSIFIED  
ADVERTISING WORKS**

- JOB OPENINGS
- CME PROGRAMS
- PRODUCTS
- AND MORE...

Contact us today for classified advertising:  
Toll free: **888-498-1460**  
E-mail: [sales@kerhgroup.com](mailto:sales@kerhgroup.com)



**REVIEW  
of OPTOMETRY**

Targeting Optometrists?

**CLASSIFIED ADVERTISING WORKS**

- JOB OPENINGS
- CME PROGRAMS
- PRODUCTS & SERVICES
- AND MORE...

Contact us today for classified advertising:

Toll free: **888-498-1460**

E-mail: [sales@kerhgroup.com](mailto:sales@kerhgroup.com)





BY MARC B. TAUB, OD, MS, AND PAMELA H. SCHNELL, OD

## FOCUS ON REFRACTION

# Three Sides to Every Survey

*This patient history tool is simple to implement yet significant for outcomes.*

(Dr. Taub) was interviewing for a job early in my career, and I was asked a question that I occasionally now use in my resident and faculty interviews. The answer I gave was instantaneous and, perhaps in hindsight, a little smug, but ultimately, I got the job. The question from the interviewer was, “If you were stranded on a deserted island and could have one piece of equipment to help you give an eye exam, what would it be?” Of course, you might be thinking of things like a slit lamp, phoropter or retinoscope. Those are all answers I have heard as the questioner. My answer: “Me!” Keep in mind that this was 20 years ago when I was a snot-nosed punk, but even today, I would still give the same answer.

My reasoning was, and remains, that through a good history with proper questioning and sleuthing, almost every condition can be diagnosed without picking up a single piece of equipment. This is not just hubris; according to Nobel Peace Prize laureate Bernard Lown, medical history provides enough information in about 75% of patient encounters to make the diagnosis even before the physical examination and additional testing is completed.<sup>1</sup> One study revealed that the initial (upon reading the referral letter and taking the history) and final diagnoses matched in 83% of

new patients.<sup>2</sup> Another found a success rate of 76%.<sup>3</sup> Confidence in the correct diagnosis in this investigation

increased from 7.1 on a scale of one to 10 after the patient history to 8.2 after the physical examination and 9.3 after the laboratory testing.<sup>3</sup>

### The Trio

History-taking, for most optometrists, starts when the examination begins and hopefully lasts throughout the entire process. However, it can also start before the patient even steps into the room through symptom surveys. These assist by guiding the exam and helping patients make connections

**19 Item COVID-QOL Checklist Questionnaire**

Check the column which best represents the occurrence of each symptom

Name \_\_\_\_\_ Date \_\_\_\_\_

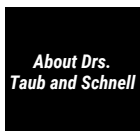
		Never 0	Seldom 1	Occasional 2	Frequently 3	Always 4
1. Headaches with near work	A					
2. Words run together reading	B					
3. Burn, itch, watery eyes	B					
4. Skips/repeats lines reading	OM					
5. Head tilt/close one eye when reading	B					
6. Difficulty copying from chalkboard	A					
7. Avoids near work/reading	A					
8. Omits small words when reading	OM					
9. Writes up/down hill	O					
10. Misaligns digits/columns of numbers	OM					
11. Reading comprehension down	P					
12. Holds reading too close	A					
13. Trouble keeping attention on reading	P					
14. Difficulty completing assignments on time	*					
15. Always says "I can't" before trying	P					
16. Clumsy, knocks things over	O					
17. Doesn't use his/her time well	P					
18. Loses belongings/things	P					
19. Forgetful/poor memory	P					

A=Accommodation; B=Binocularity; O=Orientation; OM=Ocularmotor; P=Perception; \*=All

Other Comments: \_\_\_\_\_

Completed By: \_\_\_\_\_

**This checklist focuses on quality-of-life for those suffering from vision impairment. To download a full-sized copy, please visit [www.reviewofoptometry.com](http://www.reviewofoptometry.com).**



**Dr. Taub** is a professor, chief of the Vision Therapy and Rehabilitation service and co-supervisor of the Vision Therapy and Pediatrics residency at Southern College of Optometry (SCO) in Memphis. He specializes in vision therapy, pediatrics and brain injury. **Dr. Schnell** is an associate professor at SCO and teaches courses on ocular motility and vision therapy. She works in the pediatric and vision therapy clinics and is co-supervisor of the Vision Therapy and Pediatrics residency. Her clinical interests include infant and toddler eye care, vision therapy, visual development and the treatment and management of special populations. They have no financial interests to disclose.



between their symptoms and their vision. There are quality-of-life surveys for dry eye, computer vision syndrome and almost every other visual condition in the book. Since this column concentrates on prescribing and binocular vision topics, we will narrow our focus a bit and introduce you to several surveys that you might consider adding to your paperwork when you see a pediatric patient on your schedule.

When the landmark Convergence Insufficiency Treatment Trial found that in-office vision therapy is the superior treatment for convergence insufficiency compared with home therapy and pencil push-ups, the primary measure used to show improvement was the Convergence Insufficiency

Symptom Survey (CISS).<sup>4,5</sup> A 15-question Likert-scale survey, the CISS was designed to quantify the severity of symptoms associated with convergence insufficiency, showing good validity and reliability.<sup>6,7</sup>

Questions include, “Do you have double vision when reading or doing close work?” and, “Do you have headaches when reading or doing close work?” Each question is rated on a scale of zero to four based on severity, with zero indicating “never” and four indicating “always.” A score of 16 or higher was found to differentiate children with convergence insufficiency from those with normal binocular vision. Even though one study found that children with oculomotor dys-

function, but not those with accommodative insufficiency, had higher CISS scores than those with normal binocular function, the survey remains invaluable in identifying children who suffer from all types of binocular vision issues.<sup>8</sup>

The Quality-of-Life checklist developed by the College of Optometrists in Vision Development (COVD-QOL) was originally a 30-question Likert scale questionnaire but was later shortened to 19 questions. It documents improvement when treating patients with vision therapy, correlates with academic performance and has good test-retest reliability.<sup>9-11</sup> We use this checklist as part of all exams that we perform for children older than six. A parent fills it out if the child is younger, but older children can complete it independently. Like the CISS, it uses a zero to four scale, with a four indicating that the symptom “always” occurs. The COVD-QOL overlaps many questions on the CISS but also includes questions relating to forgetfulness, poor memory and saying “I can’t” before even trying a task. A score of 20 or higher indicates the need for a complete binocular vision evaluation.

The largest area of growth that we have seen in our practice involves patients suffering from a brain injury. These injuries can take place shortly before the exam, or they may have happened years to decades earlier. The patient may not realize that their symptoms are linked to the injury, so the Brain Injury Vision Symptom Survey (BIVSS) aims to help make that connection and allow the doctor to grade the severity of the visual symptoms. The 28-question, four-point Likert scale survey assesses eight areas of vision, including visual clarity, double vision and photosensitivity. It has been shown to have good validity and test-retest reliability.<sup>12,13</sup> A score of 31 is a red flag and an indication that further evaluation must be considered.

Even though the BIVSS was designed for traumatic brain injuries, we use it for all acquired injuries, as well

**CONVERGENCE INSUFFICIENCY SYMPTOM SURVEY (CISS)**

Name \_\_\_\_\_ DATE \_\_\_\_\_

**Clinician instructions:** Read the following subject instructions and then each item exactly as written. If subject responds with “yes” - please qualify with frequency choices. **Do not give examples.** **Subject instructions:** Please answer the following questions about how your eyes feel when reading or doing close work.

	Never	Infrequently	Sometimes	Fairly often	Always
1. Do your eyes feel tired when reading or doing close work?	0	1	2	3	4
2. Do your eyes feel uncomfortable when reading or doing close work?	0	1	2	3	4
3. Do you have headaches when reading or doing close work?	0	1	2	3	4
4. Do you feel sleepy when reading or doing close work?	0	1	2	3	4
5. Do you lose concentration when reading or doing close work?	0	1	2	3	4
6. Do you have trouble remembering what you have read?	0	1	2	3	4
7. Do you have double vision when reading or doing close work?	0	1	2	3	4
8. Do you see the words move, jump, swim or appear to float on the page when reading or doing close work?	0	1	2	3	4
9. Do you feel like you read slowly?	0	1	2	3	4
10. Do your eyes ever hurt when reading or doing close work?	0	1	2	3	4
11. Do your eyes ever feel sore when reading or doing close work?	0	1	2	3	4
12. Do you feel a "pulling" feeling around your eyes when reading or doing close work?	0	1	2	3	4
13. Do you notice the words blurring or coming in and out of focus when reading or doing close work?	0	1	2	3	4
14. Do you lose your place while reading or doing close work?	0	1	2	3	4
15. Do you have to re-read the same line of words when reading?	0	1	2	3	4
To obtain score, total the number of "X"s in each column Multiply by the column value	x0	x1	x2	x3	x4
Sum					

SCORE: \_\_\_\_\_

This form helps pinpoint convergency insufficiency impact. To download, please visit [www.reviewofoptometry.com](http://www.reviewofoptometry.com) and look for this article's page.

as for patients suffering from neurological conditions like MS and ALS. We also use it to determine potential treatment benefits from vision therapy, tints and occlusion.

## Takeaways

There is no one data point on which an entire diagnosis can be based. The same can be said for symptom surveys. They are yet another tool at your disposal to enhance and create a complete patient history that can, in turn, be used to guide your exam and the testing choices that you make, allowing for more effective and efficient diagnosis and treatment.

Since these surveys represent only one data point, there are times when the results match the objective data and times when they do not. If the survey score is high but the objective data is normal or relatively normal, look closely at who filled out the survey. We have seen circumstances in which the parent fills out the survey quite differently than their child does,

and vice-versa. As there are three sides to every story, perhaps there are also three sides to every survey. Take the time to consider each to help paint a fuller picture.

If the survey score is low but the objective data indicates a problem, that doesn't necessarily mean that the survey is wrong; keep in mind that the patient may not be symptomatic yet or ever. The absence of symptoms may in fact be a symptom. The entirety of the examination must be considered altogether in the decision-making process.

The amount of output needed to start using surveys is minimal, but the impact on your clinical exams and patient outcomes can be enormous. Incorporating these tools into your care process in the clinic should be a no-brainer. ■

1. Lown B. *The Lost Art of Healing: Practicing Compassion in Medicine*. New York: Ballantine Books, 1999.

2. Hampton JR, Harrison MJG, Mitchell JRA, et al. Relative contributions of history-taking, physical examination, and laboratory investigation to diagnosis and management of medical outpatients. *BMJ Open Ophthalmol*. 1975;2:486-9.

3. Peterson MC, Holbrook JH, Von Hales D, et al. Contributions of the history, physical examination, and laboratory investigation in making medical diagnoses. *West J Med*. 1992;156:163-5.

4. Convergence Insufficiency Treatment Trial Study Group. The convergence insufficiency treatment trial: Design, methods, and baseline data. *Ophthalmic Epidemiol*. 2008;15(1):24-36.

5. Convergence Insufficiency Treatment Trial Study Group. Randomized clinical trial of treatments for symptomatic convergence insufficiency in children. *Arch Ophthalmol*. 2008;126(10):1336-49.

6. Borsting EJ, Rouse MW, Mitchell GL, et al. Validity and reliability of the revised convergence insufficiency symptom survey in children aged 9 to 18 years. *Optom Vis Sci*. 2003;80:832-8.

7. Rouse MW, Borsting EJ, Mitchell GL, et al. Validity and reliability of the revised convergence insufficiency symptom survey in adults. *Ophthalmic Physiol Opt*. 2004;24:384-90.

8. Pang Y, Tan QQ, Gabriel H, et al. Application of the convergence insufficiency symptom survey in oculomotor dysfunction and accommodative insufficiency. *Optom Vis Sci*. 2021;98(8):976-82.

9. Harris P, Gormley L. Changes in scores on the COVD quality of life assessment before & after vision therapy: a multi-office study. *J Behav Optom*. 2007;18(2):43-7.

10. Vaughn W, Maples WC, Hoenes R. The association between vision quality of life and academics as measured by the college of optometrists in vision development quality of life questionnaire. *Optometry*. 2006;77(3):116-23.

11. Gerchak D, Maples WC, Hoenes R. Test retest reliability of the COVD-QOL short form on elementary school children. *J Behav Optom*. 2006;17(3):65-70.

12. Laukkanen H, Scheiman M, Hayes JR. Brain Injury Vision Symptom Survey (BIVSS) Questionnaire. *Optom Vis Sci*. 2017;9(1):43-50.

13. Weimer A, Jensen C, Hannu Laukkanen H, et al. Test-retest reliability of the Brain Injury Vision Symptom Survey. *Vis Devel Rehab*. 2018;4(4):177-85.

## ADVERTISER INDEX

*This index is published as a convenience and not as part of the advertising contract. Every care will be taken to index correctly. No allowance will be made for errors due to spelling, incorrect page number, or failure to insert.*

Akorn .....	7
.....	<a href="http://www.acellfx.com">www.acellfx.com</a>
Alcon .....	44 & 45
.....	<a href="http://www.alconexperienceacademy.com">www.alconexperienceacademy.com</a>
Alcon Laboratories.....	100
.....	<a href="http://www.patadaypro.com">www.patadaypro.com</a>
Alcon Laboratories.....	CoverTip
.....	<a href="http://www.alcon.com">www.alcon.com</a>
Allergan, Inc. ....	31
.....	<a href="http://www.lastacraft.com/doc">www.lastacraft.com/doc</a>
Bausch + Lomb .....	2 & 3
.....	<a href="http://www.vyzultahcp.com">www.vyzultahcp.com</a>
Bausch + Lomb .....	15 & 16
.....	<a href="http://www.vyzultahcp.com">www.vyzultahcp.com</a>
Bausch + Lomb .....	35
.....	(855)542-5682
.....	<a href="http://www.bausch.com">www.bausch.com</a>

Bausch + Lomb .....	47
.....	<a href="http://www.biotrue.com/professional">www.biotrue.com/professional</a>
Bausch + Lomb .....	99
.....	<a href="http://www.BauschInfuse.com">www.BauschInfuse.com</a>
Glaukos .....	19
.....	<a href="http://www.glaukos.com">www.glaukos.com</a>
Icare USA .....	13
.....	(888) 422-7313
.....	<a href="mailto:infoUSA@icare-world.com">infoUSA@icare-world.com</a>
.....	<a href="http://www.icare-world.com/USA">www.icare-world.com/USA</a>
Lumenis .....	25
.....	<a href="http://www.information.lumenis.com/optilight">www.information.lumenis.com/optilight</a>
MGS Technologies.....	77
.....	(847) 763-0500
.....	<a href="http://www.mstech-eyes.com">www.mstech-eyes.com</a>
MacuHealth .....	23
.....	<a href="http://www.macuhealth.com">www.macuhealth.com</a>
MacuLogix .....	27
.....	<a href="http://www.maculogix.com">www.maculogix.com</a>
Oasis .....	29
.....	(844) 820-8940
.....	<a href="mailto:customerservice@oasismedical.com">customerservice@oasismedical.com</a>
.....	<a href="http://www.oasismedical.com">www.oasismedical.com</a>

Oculus, Inc.....	79
.....	(888) 519-5375
.....	<a href="mailto:ads@oculususa.com">ads@oculususa.com</a>
.....	<a href="http://www.pentacam.com">www.pentacam.com</a>
Orcam.....	71
.....	<a href="http://www.orcam.com">www.orcam.com</a>
Oyster Point.....	9 & 10
.....	<a href="http://www.oysterpointrx.com">www.oysterpointrx.com</a>
RegenerEyes.....	37
.....	(877) 206-0706
.....	<a href="http://www.regenereyes.com">www.regenereyes.com</a>
Santen Inc. USA.....	39 & 40
.....	<a href="http://www.santeninc.com">www.santeninc.com</a>
Santen Inc. USA.....	53 & 54
.....	<a href="http://www.myflarex.com">www.myflarex.com</a>
SynergEyes.....	73
.....	(877) 733-2012
.....	<a href="http://www.SynergEyes.com/Professional">www.SynergEyes.com/Professional</a>
Thea Pharma .....	5
.....	<a href="http://ivizia.com/ecp">ivizia.com/ecp</a>
Xcel Specialty.....	69
.....	(800) 241-9312
.....	<a href="mailto:xcelinfo@xcelspecialtycontacts.com">xcelinfo@xcelspecialtycontacts.com</a>
.....	<a href="http://www.xcelspecialtycontacts.com">www.xcelspecialtycontacts.com</a>



# What's Your Angle?

*A patient comes in with IOP of 65mm Hg and 20/400 vision. How do you arrive at a diagnosis and address her urgent needs?*

**A** 75-year-old African-American female presented to the office acutely with a chief complaint of ocular pain and redness OS of four days' duration. Her ocular history was remarkable for uneventful phacoemulsification surgery in that eye, completed two weeks prior. Systemic history was positive for hypertension, for which she was properly medicated and compliant. The patient denied allergies of any kind.

## Clinical Findings

Her best-corrected entering visual acuities were 20/20 OD and 20/400 OS, with no improvement using pin-hole at distance or near. Her external examination was normal. There was excessive lacrimation with conjunctival injection OS. There was no evidence of afferent pupillary defect. The pertinent biomicroscopic examination of the anterior segment OS is demonstrated in the photographs. Goldmann

applanation tonometry measured 15mm Hg OD and 65mm Hg OS.

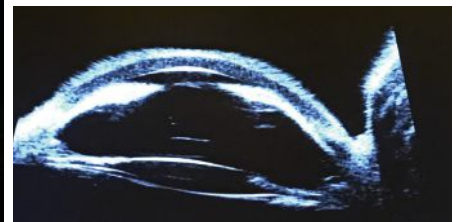
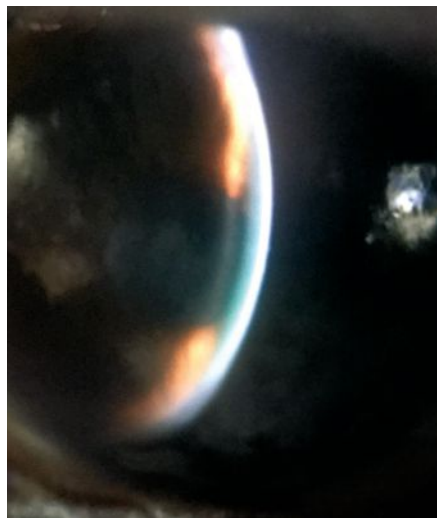## For More Information

Additional studies might have included gonioscopy, B-scan ultrasonography, anterior segment and angle optical coherence tomography and ultrasound biomicroscopy (obtained in this case and shown below).

Additionally, history questions should be asked regarding inadvertent trauma, which may have produced accidental hypotony with or without a cyclodialysis cleft. More questions might include use of any medication from the sulfonamide group (*e.g.*, oral acetazolamide, topiramate), which may cause an idiosyncratic uveal effusion with forward movement of both the choroid and ciliary body.

## Your Diagnosis

What would be your diagnosis in this case? What is the patient's likely prognosis? To find out, please read the online version of this article at [www.reviewofoptometry.com](http://www.reviewofoptometry.com). ■



**Biomicroscopy and ultrasound biomicroscopy yielded the above findings. What do they—and the case history—point toward?**

### About Dr. Gurwood

Dr. Gurwood is a professor of clinical sciences at The Eye Institute of the Pennsylvania College of Optometry at Salus University. He is a co-chief of Primary Care Suite 3. He is attending medical staff in the department of ophthalmology at Albert Einstein Medical Center, Philadelphia. He has no financial interests to disclose.

## Retina Quiz Answers (from page 90)—Q1: b, Q2: a, Q3: c, Q4: c

### NEXT MONTH IN THE MAG

In May, we present our annual dry eye report. Articles will include:

- How to Ease into Next-Level Dry Eye Care
- Understanding Patient Lifestyle Influences on Dry Eye
- How to Get Patients Pumped Up for Dry Eye Therapy

- How Dry Eye Screening Questionnaires Can Build Your Practice

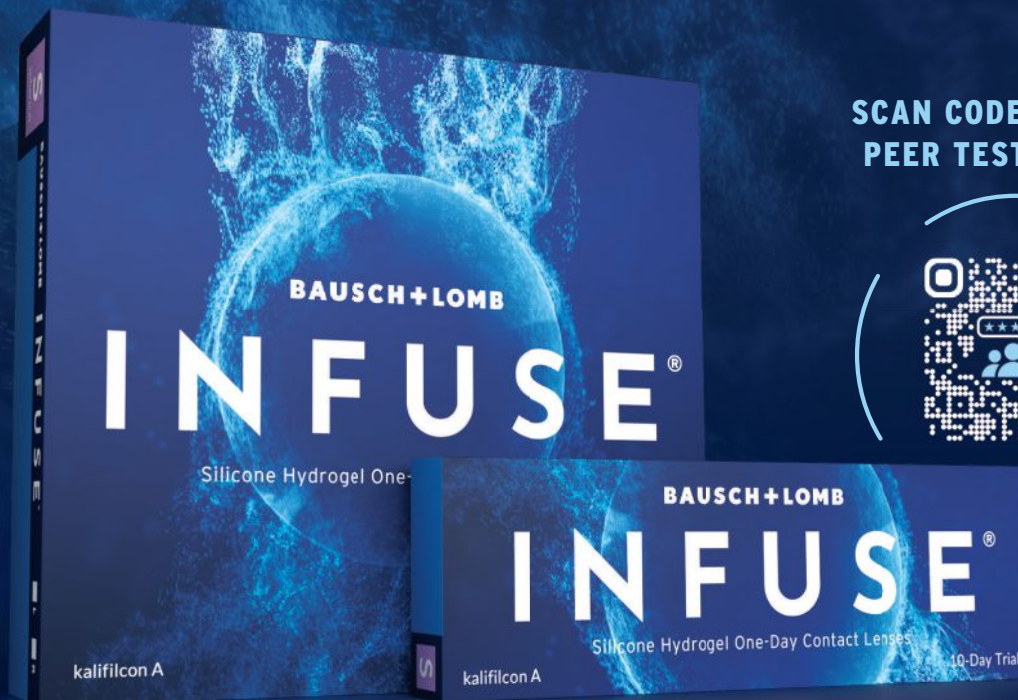*Also in this issue:*

- How to Work up Charles Bonnet Syndrome and Similar Conditions
- Scope Expansion: How to Add Incisions and Injections to Your Practice



# OFFER PATIENTS AN **EXCEPTIONAL** LENS EXPERIENCE

Eye Care Professionals across the nation are sharing their success with Bausch + Lomb INFUSE®. See the impact it can have on your practice and patients, too.



**SCAN CODE TO WATCH  
PEER TESTIMONIALS**

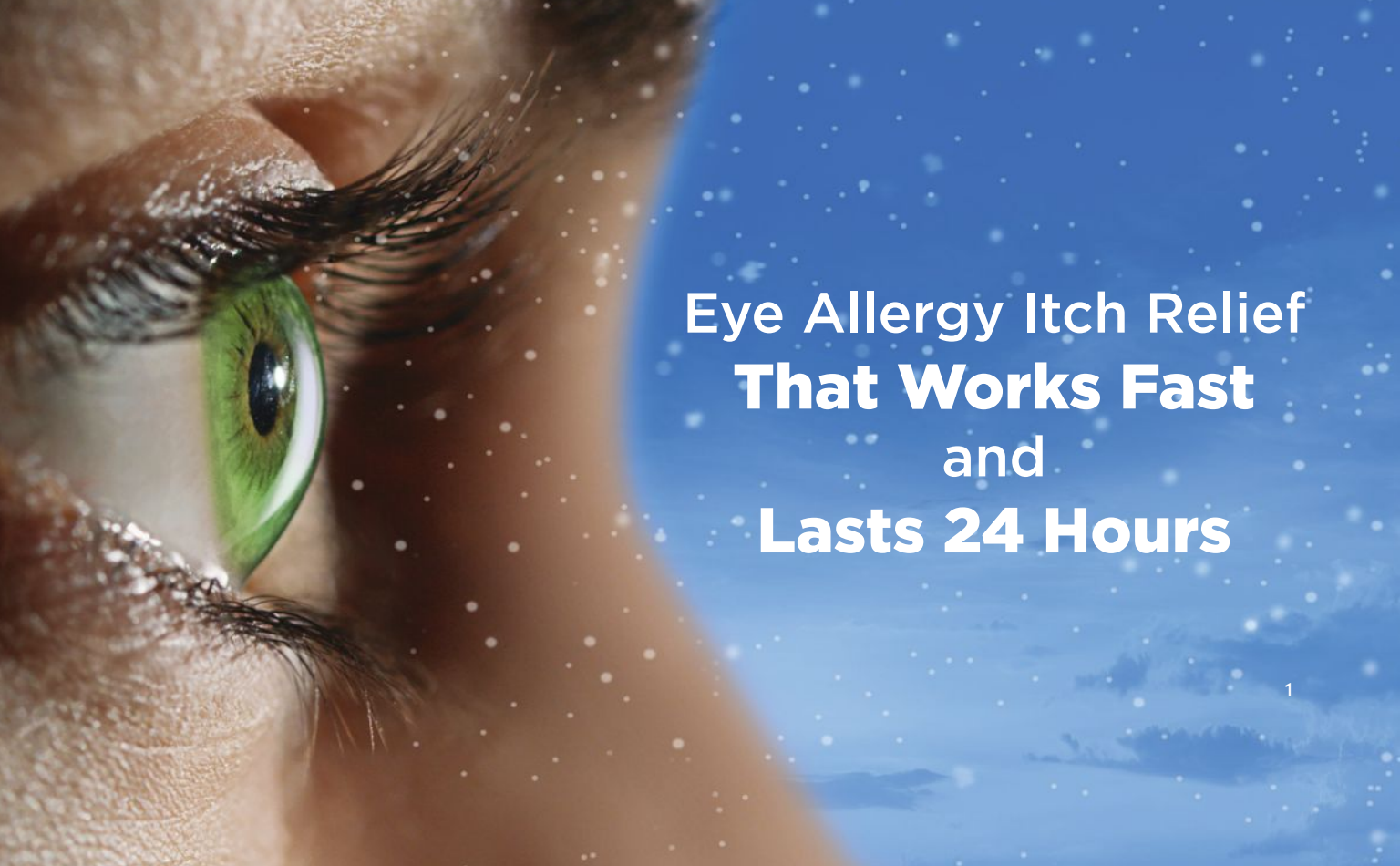

## **HERE'S A SNEAK PEEK AT WHAT YOUR PEERS ARE SAYING:**

"INFUSE® helps address symptoms of contact lens dryness."  
- Dr Kevin Nehaul

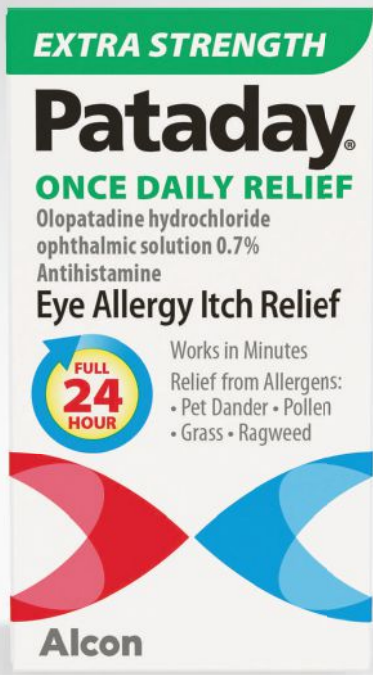"The lens speaks for itself."  
- Dr Scott Moscow

"INFUSE® has great comfort, vision, and oxygen transmissibility."  
- Dr Michelle Mumford

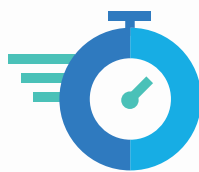


# Eye Allergy Itch Relief That Works Fast and Lasts 24 Hours

1



Recommend to your patients  
the first over-the-counter eye  
drop that provides 24-hours  
of eye allergy itch relief



Works in Minutes<sup>1</sup>



One Drop  
Once a Day  
for 24-Hour Relief<sup>1,2</sup>



Full Prescription  
Strength  
Formerly known as Pazeo

1. PAZEO [package insert] Fort Worth, TX: Alcon Inc.; 2016.  
2. McLaurin E, Narvekar A, Gomes P, Adevale A, Torkildsen G. Phase 3 randomized double-masked study of efficacy and safety of once-daily 0.7% olopatadine hydrochloride ophthalmic solution in subjects with allergic conjunctivitis using conjunctival allergen challenge model. Cornea. 2015;34(10):1245-1251.