

REVIEW[®] *of* OPTOMETRY

July 15, 2022 • reviewofoptometry.com

VITAL DYES
FOR DRY EYES

*How to read staining
patterns better.*

PAGE 32

28th Annual **GLAUCOMA REPORT**

TAKING THE LEAD ON GLAUCOMA

TOTAL30[®]

THE FIRST AND ONLY
WATER GRADIENT
MONTHLY REPLACEMENT
CONTACT LENS



FEELS LIKE NOTHING, EVEN AT DAY 30¹

Like DAILIES TOTAL1[®], TOTAL30[®] approaches 100% water at the surface, so that nothing touches the eye but a gentle cushion of moisture. And it is adapted with CELLIGENT[®] Technology for exceptional comfort even through day 30.¹



SEE HOW TOTAL30[®] CAN TRANSFORM YOUR PRACTICE.
SCAN THE QR CODE TO FIND OUT MORE.

Reference: 1. In a clinical study wherein patients (n=66) used CLEAR CARE[®] solution for nightly cleaning, disinfecting, and storing; Alcon data on file, 2021.

See product instructions for complete wear, care, and safety information. Rx only

© 2021 Alcon Inc. US-T30-2100284

Alcon

Pilocarpine: New and Improved?, p. 28 • HSVK Reoccurrence, p. 73 • New Dry Eye Meds, p. 80

REVIEW[®] of OPTOMETRY

July 15, 2022 • reviewofoptometry.com

**VITAL DYES
FOR DRY EYES**

*How to read staining
patterns better.*

PAGE 32

28th Annual **GLAUCOMA REPORT**

TAKING THE LEAD ON GLAUCOMA

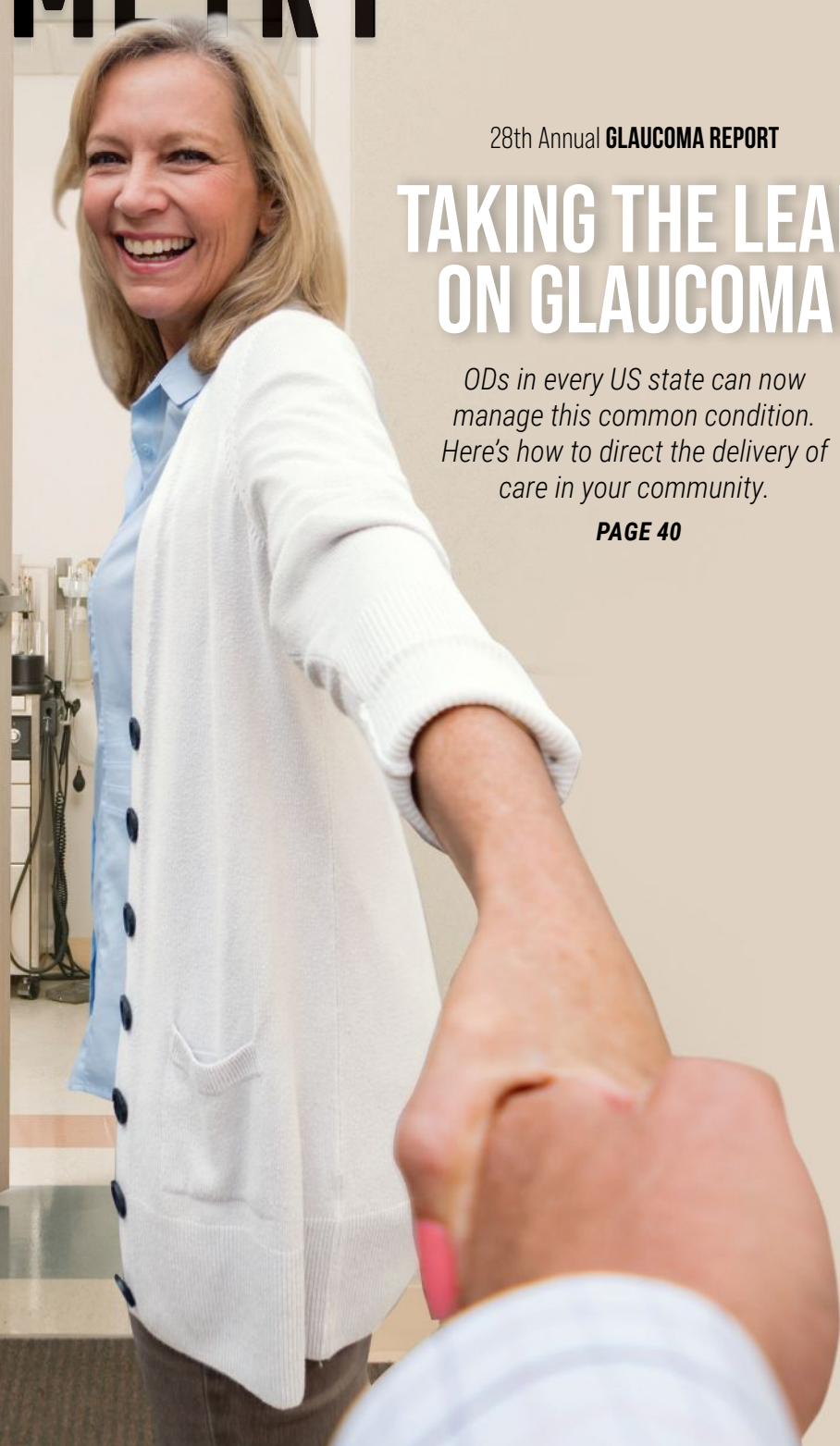
*ODs in every US state can now
manage this common condition.
Here's how to direct the delivery of
care in your community.*

PAGE 40

Prepping for the
Glaucoma Grind, p. 50

On the Threshold:
New VF Testing Tech, p. 56

MIGS on the Move, p. 64
—EARN 2 CE CREDITS



An Updated Approach to Identifying and Treating Acquired Ptosis

Kelly Nichols, OD, MPH, PhD

University of Alabama at Birmingham
School of Optometry
Birmingham, Alabama

Kelly Malloy, OD, FFAO

The Eye Institute of the
Pennsylvania College of Optometry
Salus University
Philadelphia, Pennsylvania

Jason Bacharach, MD

North Bay Eye Associates
Petaluma, California

Eye care continues to evolve toward a greater emphasis on more active identification and treatment, as well as the use of novel, minimally invasive treatments. This approach is particularly important when it comes to conditions that are common in the population. Clinical experience tells us that ptosis is one of the most prevalent conditions of the upper eyelid. It is also clear that despite the effects of ptosis on appearance, vision, and quality of life,¹⁻⁴ it is very likely underdiagnosed. This is at least in part because its presentation can be relatively mild or moderate, meaning that it might escape detection during a routine exam. Similarly, patients might not feel compelled to report ptosis, particularly if it is of the more slowly progressive, age-related variety. Additionally, until recently, the only effective

treatment option available was surgery, which may not be suitable for all patients, especially those with mild or moderate ptosis. Thus, the prevailing approach, unless the patient is particularly motivated to undergo surgery, has often been simply ‘watch-and-wait.’

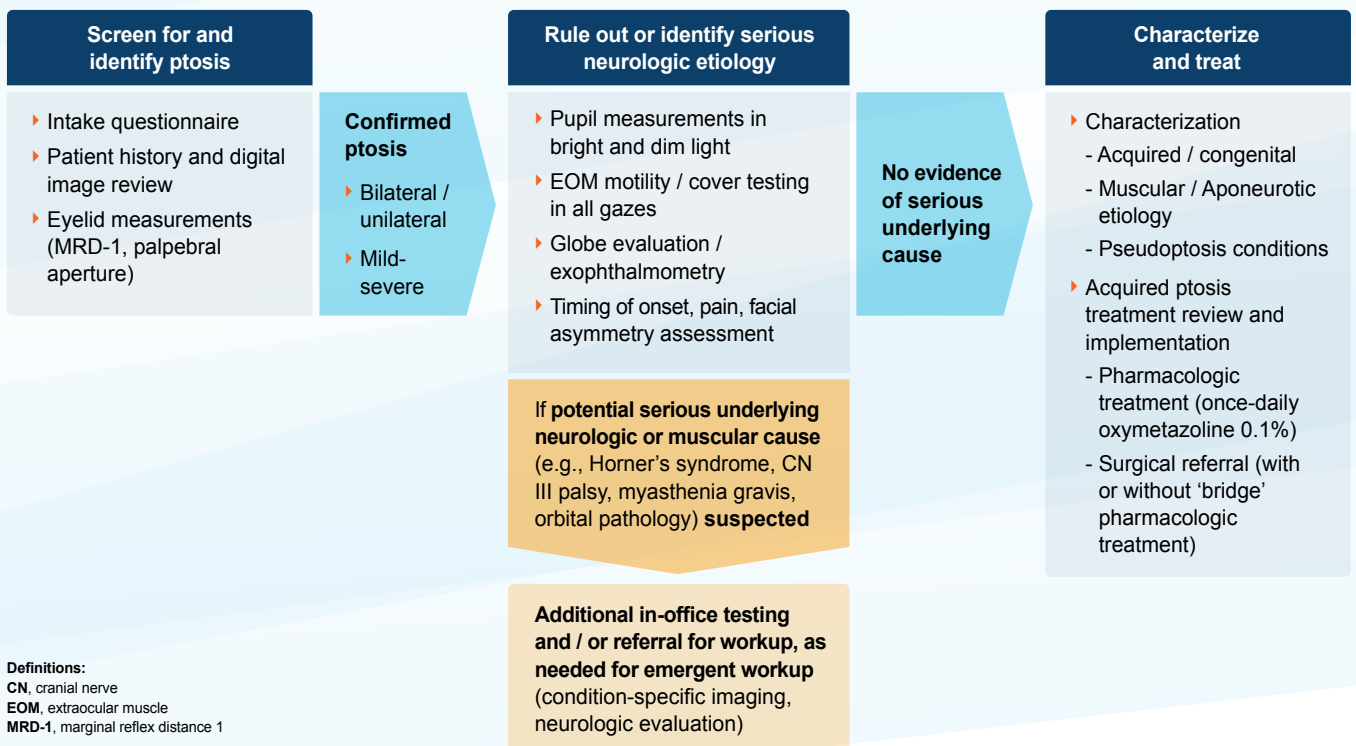
As part of a joint optometry and ophthalmology working group, we recently reviewed current evidence and clinical experience to propose an updated, practical algorithm for acquired ptosis identification, diagnosis, workup, and treatment.⁵ One of the prompts for this work was the introduction of the first pharmacologic agent approved for acquired ptosis — a topical solution of the selective alpha-adrenergic agonist oxymetazoline 0.1% (Upneeq®, RVL Pharmaceuticals, Inc., Bridgewater, NJ, USA) — and the need to

explore how this non-invasive therapeutic might help evolve clinical practice. Broadly, as a once-daily eye drop, oxymetazoline 0.1% presents the potential to treat more acquired ptosis patients and, at the same time, allow primary eye care providers to take on an expanded role in ptosis management.

Accurate and timely ptosis identification can be easy and efficient

In order to make informed treatment decisions, acquired ptosis needs to be accurately diagnosed, meaning that an active approach to identification is essential. The good news is that identifying ptosis is straightforward and can be easily incorporated

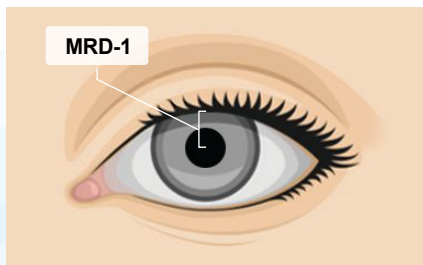
Figure 1 | Clinical recommendations for the diagnosis and treatment of acquired ptosis. Adapted from Nichols et al.⁵



Definitions:
CN, cranial nerve
EOM, extraocular muscle
MRD-1, marginal reflex distance 1

into your current workflow, starting at patient check-in and the pre-exam workup (Figure 1).

Simple questions added to your intake questionnaires can help identify patients who have noticed drooping or other changes in their eyelids. During the work-up, technical staff can review patient history and collect digital images of the eyes, as well as perform simple eyelid position measurements to record the presence of ptosis, as well as its severity and laterality. Easy and reliable measures of the eyelids include the marginal reflex distance 1 (MRD-1; distance between the central pupillary light reflex and center of the upper eyelid margin) or palpebral aperture (distance between the central margins of the



upper and lower eyelids). The important thing to remember is that practices already have the tools (penlight, mm ruler) and expertise to efficiently collect this information, and that observation of the eyelids can be woven into staff and doctor workflow relatively seamlessly. As identifying ptosis becomes a more routine part of your comprehensive exam, the easier it becomes to spot by visually assessing upper eyelid position, even when relatively mild. At that point, MRD-1 or other related measurements may be less necessary for ptosis identification, though they can still support accurate tracking and assessment of interval change.

Taking a few minutes for differential diagnosis and ptosis characterization supports good treatment decisions

Once eyelid ptosis is confirmed based on eyelid measurement and doctor review, it is important to examine for any signs of potentially serious underlying neurologic

causes of the ptosis (Figure 1), following the same approach to differential diagnosis that you would for any patient under your care. In the case of acquired ptosis, this includes assessment for concerning features like sudden onset, fatigability, associated ocular or facial pain, asymmetric exophthalmometry measurements, presence of a mass or lesion weighing down the eyelid, pathologic anisocoria, or reduced functional ability of the extraocular muscles. Presence of any of these factors needs to prompt additional in-office testing and / or immediate referral to neuro-ophthalmology or the emergency department for initiation of neuro-imaging and other testing as necessary. Some potential underlying causes for ptosis are noted in Figure 1. For more detailed information regarding the workup for underlying causes of ptosis, see Nichols et al.⁵

Once it is confirmed that no signs of serious underlying conditions are present, ptosis should be characterized using straightforward tests of upper eyelid retractor muscle and aponeurosis function. The patient should also be examined for potential mechanical factors and the presence of “pseudoptosis” conditions that may masquerade as ptosis. Dermatochalasis is one of the more common conditions that can give the appearance of ptosis, but it can also be present in parallel with ptosis. In either case, performing simple tests to define the relative contributions of ptosis and dermatochalasis is important in guiding treatment. Basic exophthalmometry to assess the axial position of the eyes can help identify forward protrusion, globe dystopias, or asymmetries that might also give the appearance of ptosis.⁶

An active approach to treatment will benefit more of your patients

Given its non-invasive nature and familiar route of administration, oxymetazoline 0.1% should be considered as a first option for the majority of patients with non-pathologic acquired ptosis. This includes cases of persistent and progressive acquired ptosis, as

well as more transient forms due, for example, to periocular neurotoxin injection or following ocular surgery. Clinical oxymetazoline 0.1% application significantly raises the upper eyelid and improves superior visual field deficits. Particularly notably, oxymetazoline 0.1% has rapid effects on upper eyelid position, with significant improvements in position observed 5 minutes after administration and significant effects lasting through at least 6 hours post-dosing.^{7,8} Further, oxymetazoline 0.1% has a favorable safety profile, with reported adverse event rates and types comparable to those in patients using placebo and minimal effects on pupil size, intraocular pressure, or visual acuity.⁹

Surgery provides a more permanent correction of ptosis and is effective, with a wide range of technical approaches available based on etiology and severity. Surgical referrals should be provided in cases of acquired ptosis that are particularly severe, unlikely to benefit from pharmacologic intervention based on underlying etiology, or when the patient desires permanent surgical correction.

Identifying and treating ptosis is a simple way to provide better comprehensive care

There is broad availability of clinical tools for accurate diagnosis, as well as expanding therapeutic options for ptosis. Therefore, eyelid evaluation should be a part of the comprehensive eye exam, particularly for patients with known identifiable risk factors for acquired ptosis, such as advanced age, long-term contact lens wear, or history of ocular surgery.¹⁰⁻¹⁶ Paying more attention to the eyelids in daily practice can identify not only candidates for pharmacologic treatment, but also more candidates who can benefit from surgical correction. The proposed stepwise approach to identifying, characterizing, and treating acquired ptosis can be easily and efficiently integrated into your clinical practice, and reflects the type of comprehensive care that we aim to provide to all of our patients.

References: 1. Alniemi ST, Pang NK, Woog JJ, Bradley EA. Comparison of automated and manual perimetry in patients with blepharoptosis. *Ophthalm Plast Reconstr Surg*. 2013;29:361-363. 2. Ho SF, Morawski A, Sampath R, Burns J. Modified visual field test for ptosis surgery (Leicester Peripheral Field Test). *Eye (Lond)*. 2011;25:365-369. 3. McKean-Cowdin R, Varma R, Wu J, Hays RD, Azen SP, Los Angeles Latino Eye Study Group. Severity of visual field loss and health-related quality of life. *Am J Ophthalmol*. 2007;143:1013-1023. 4. Richards HS, Jenkinson E, Rumsey N, et al. The psychological well-being and appearance concerns of patients presenting with ptosis. *Eye (Lond)*. 2014;28:296-302. 5. Nichols KK, Malloy KA, Karpecki PM, et al. Topical review: an update of diagnostic and management algorithms for acquired ptosis. *Optom Vis Sci*. 2022;99:230-240. 6. Bacharach J, Lee WW, Harrison AR, Freddo TF. A review of acquired blepharoptosis: prevalence, diagnosis, and current treatment options. *Eye (Lond)*. 2021;35:2468-2481. 7. Slonim CB, Foster S, Jaros M, et al. Association of oxymetazoline hydrochloride, 0.1%, solution administration with visual field in acquired ptosis: a pooled analysis of 2 randomized clinical trials. *JAMA Ophthalmol*. 2020;138:1168-1175. 8. Bacharach J, Wirta DL, Smyth-Medina R, et al. Rapid and sustained eyelid elevation in acquired blepharoptosis with oxymetazoline 0.1%: randomized phase 3 trial results. *Clin Ophthalmol*. 2021;15:2743-2751. 9. Wirta DL, Korenfeld MS, Foster S, et al. Safety of once-daily oxymetazoline HCl ophthalmic solution, 0.1% in patients with acquired blepharoptosis: results from four randomized, double-masked clinical trials. *Clin Ophthalmol*. 2021;15:4035-4048. 10. Forman WM, Leatherbarrow B, Sridharan GV, Tallis RC. A community survey of ptosis of the eyelid and pupil size of elderly people. *Age Ageing*. 1995;24:21-24. 11. Hashemi H, Khabazkhoob M, Emamian MH, et al. The prevalence of ptosis in an Iranian adult population. *J Curr Ophthalmol*. 2016;28:142-145. 12. Kim MH, Cho J, Zhao D, et al. Prevalence and associated factors of blepharoptosis in Korean adult population: the Korea National Health and Nutrition Examination Survey. *Eye (Lond)*. 2017;31:940-946. 13. Bleyen I, Hiemstra CA, Devogelaere T, van den Bosch WA, Wubbels RJ, Paridaens DA. Not only hard contact lens wear but also soft contact lens wear may be associated with blepharoptosis. *Can J Ophthalmol*. 2011;46:333-336. 14. Godfrey KJ, Korn BS, Kikkawa DO. Blepharoptosis following ocular surgery: identifying risk factors. *Curr Opin Ophthalmol*. 2016;27:31-37. 15. Hwang K, Kim JH. The risk of blepharoptosis in contact lens wearers. *J Craniofac Surg*. 2015;26:e373-e374. 16. Wang Y, Lou L, Liu Z, Ye J. Incidence and risk of ptosis following ocular surgery: a systematic review and meta-analysis. *Graefes Arch Clin Exp Ophthalmol*. 2019;257:397-404.



Colorado Becomes 10th State Allowing ODs to Use Lasers

“As-taught” law brings many new procedures into the fold, better reflecting the capabilities of ODs there, advocates say. In California, a similar bill cleared a legislative hurdle.

Optometrists in Colorado received good news in June when Governor Jared Polis signed HB 22-1233 into law, permitting ODs there to take advantage of several new rights. The optometric scope of practice in Colorado is now expanded to include advanced procedures such as lesion removal, injections and corneal crosslinking, as well as three laser procedures: YAG capsulotomy, peripheral iridotomy and selective laser trabeculoplasty. The news comes just months after a successful Virginia effort added many such procedures to ODs’ rights in that state.

Every 10 or 11 years, Colorado law requires that optometry go through a sunset process to reassess and amend the definition and regulations of the profession. The new sunset bill, effective until 2033, will allow ODs in Colorado to practice according to their training and qualifications, as set forth by the state’s Board of Optometry and national exams. Guidelines on the certification required to perform each new procedure will be determined in the coming months by the Board.

“Everyone is excited about the expanded scope of practice, especially newer ODs who have already been trained in many of these procedures, but prior to the passing of this bill, were not able to take advantage of their training or education,” says Deanna Alexander, OD, Colorado Optometric Association (COA) legislative co-chair. “ODs are excited to see the profession moving forward.”

The scope expansion will also improve access to care for state residents. For the majority of Colorado counties, optometrists are the primary eyecare providers, which is one reason why the COA fought so hard to have the bill passed—but not without a good fight by the opposition.

Karen Moldovan, government relations director at the COA, offers a few words of advice for optometrists and advocates in other states trying to push for scope expansion laws.

“Throughout the legal process, legislators were interested in the safety precedents set nationally and by other states with expanded scope laws,” Mrs. Moldovan notes. “We were confidently able to present data from states like Oklahoma, Kentucky, Louisiana and others that have already passed these laws and showed that there were no patient safety concerns by any means. The more states that produce this com-

PELLING data, the stronger the national precedent will be.”

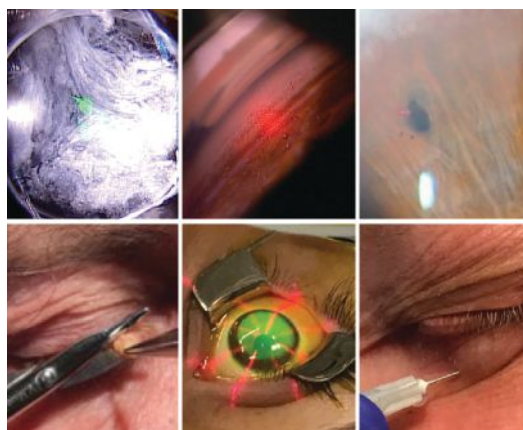Mrs. Moldovan also emphasizes the importance of educating legislators on the various procedures and how they are performed, and explaining that, unlike many other forms of surgery, most patients can drive themselves home after an in-office ocular procedure.

“We’ve had legislators hear from optometrists in Colorado who are licensed in other states and have performed many of these procedures before,” she says. “These doctors were able to share their first-hand experiences and perspective on things like what the procedure looks like in the office.”

Additionally, Mrs. Moldovan noted that it was helpful to offer a live demo for legislators to walk them through a laser procedure and show them the technology. “What is really important is helping legislators understand what the procedures are and what they are not.”

Lastly, Dr. Alexander also credits the win to ongoing relationships between ODs and the state. “Get engaged at the state level and connect with your legislative team,” she advises. “In Colorado, and throughout the nation, it’s the relationships we build with the state that help us push these things forward and keep optometry strong.”

These strategies will surely be at play next month in California, where optometric leaders are pursuing similar legislation. On June 29, the state Senate moved a bill proposing laser and other minor surgical procedures out of committee. Another hearing is set for Aug. 1. ◀



Colorado’s new law adds these services to its optometric scope: (clockwise from upper left) capsulotomy, SLT, peripheral iridotomy, intralesional injection, collagen crosslinking and lesion incision/excision.

Outdoor Time, Tanning May Lower Cataract Surgery Risk

Those who spent longer in the sun and tanned more easily may have better outcomes.

It's long been known that prolonged outdoor time increases ultraviolet light exposure and thus the incidence of cataract development. But an unusual new study links outdoor time with a *lower* incidence of cataract surgery in a large Australian cohort. The key difference seems to be the individual's propensity for tanning and the role of melanin.

This population-based prospective cohort study included 137,133 participants 45 to 65 years old without prior history of cataract surgery. Time spent outside and tanning from repeated sun exposure were assessed via questionnaire. Whether a patient proceeded to need and receive cataract surgery was then determined.

During a mean follow-up of nine years, 10% of participants received cataract surgery. More time outdoors and tanning from repeated sun ex-

posure were significantly associated with a lower risk of cataract surgery. Participants who spent over 10 hours outside had a 9% decreased risk compared with those who spent fewer than two hours outside. Compared with participants who easily tanned from repeated sun exposure, those less likely to tan had a 5% to 7% increased risk.

"We found reduced risk of cataract surgery among participants who reported more outdoor time," the study authors noted in their paper. They added that, "subjects who tan easily had lower risk, suggesting a potential role between melanin and cataract." A suntan is a sign that the skin is releasing melanin, a natural protector against the sun's UV rays.

The team speculated that one explanation could be that "those who tan easily have higher melanin



Photo: Mathews Fade on Unsplash

Individuals more prone to tanning from UV exposure may have greater protective mechanisms against cataract development.

levels and better antioxidant capability and thus a lower risk of cataract." Meanwhile, older study participants who tanned less were found to have increased cataract risk, which could be due to reduced melanin levels due to older age. ◀

Han X, Zhang J, Wang W, et al. Associations among outdoor time, skin tanning, and the risk of surgically treated cataract for Australians 45 to 65 years of age. *Transl Vis Sci Technol.* June 2, 2022. [Epub ahead of print].

New Retinal Finding Found in Severely Myopic Eyes

Distinguishing it from macular hole retinal detachment is key, due to differing treatment strategies.

Researchers identified a new clinical entity in myopic eyes that they termed "extreme macular schisis simulating retinal detachment" (EMSSRD). They observed this finding on high-resolution OCT after evaluating patients who initially appeared to have macular hole retinal detachments.

"EMSSRDs resemble a macular hole retinal detachment, but they differ by having thin remnants of the retina on the retinal pigment epithelium," the researchers explained in their paper for the journal *Retina*.

They analyzed data of 617 highly myopic eyes with myopic tractional maculopathy. They diagnosed EMSSRD on OCT based on high retinal elevation (>500µm), less obvious columnar structures and presence of thin

remnants of outer retinal tissues above the retinal pigment epithelium.

Of the total eyes, 4% had EMSSRD. All of these eyes had macular atrophy caused by myopic macular neovascularization. The team noted that less than 1% of eyes progressed to macular hole retinal detachment, and these detachments all began away from rather than within the macular atrophy.

"This suggested that although the tissue adhesion was strong in the area of the macular neovascularization-related macular atrophy, the retinal detachment can spread to the area of macular atrophy with a strong adhesion because of continued tractional forces," the researchers wrote. "When the tractional force exceeded adhesion, it resulted in a macular hole retinal detachment."

Almost 2% of eyes in the study required vitreoretinal surgery, but the researchers found no significant difference between pre- and postoperative best-corrected visual acuity (BCVA) in eyes operated on due to worsening EMSSRD or progression to macular hole retinal detachment. They also explained that they found no difference in BCVA improvement between the two types.

"The differentiation between EMSSRD and macular hole retinal detachment is important because the treatment strategies including urgent vitrectomy for macular hole retinal detachment are different from that of EMSSRD," they concluded. ◀

Uramoto K, Azuma T, Watanabe T, et al. Extreme macular schisis simulating retinal detachment in eyes with pathologic myopia. *Retina.* May 27, 2022. [Epub ahead of print].

Specific Nutrients May Lower AMD Progression Risk

Recent systematic review confirmed the benefits of carotenoids, antioxidants and a Mediterranean diet.

A number of studies have explored the connection between nutrition and supplements and the development or progression of age-related macular degeneration (AMD). To better understand where the current literature stands, researchers recently conducted a systematic review that found that a high intake of specific nutrients as well as antioxidant supplementation and a Mediterranean diet decrease the risk of progression of early to late AMD.

The study authors included studies published between January 2015 and May 2021 that were identified through a multi-database search. They assessed the certainty of evidence according to the GRADE methodology. The main outcome measures included development, progression and side effects of AMD.

Seven systematic reviews, seven randomized controlled trials and 13 nonrandomized studies were included. The researchers reported a high certainty of evidence for the association between high consumption of specific nutrients, such as beta-carotene, lutein, zeaxanthin, copper, folate, magnesium, vitamin A, niacin, vitamin B6, vitamin C, docosahexaenoic acid and



Photo: Nadine Pirmeau on Unsplash

Research suggests that a Mediterranean diet may be the most protective against AMD.

eicosapentaenoic acid, and a lower risk of progression of early to late AMD.

There was a moderate certainty of evidence that the use of antioxidant supplements and adherence to a Mediterranean diet was correlated with a decreased risk of progression of early to late AMD. Additionally, there was a moderate certainty of evidence that high alcohol consumption was linked to a higher risk of AMD development.

The study authors also found that supplementary vitamin C, vitamin E and -carotene were not associated with the development of AMD. Supplementary omega-3 fatty acids were not associated with progression to late AMD. Both had a high certainty of evidence, according to the researchers.

Based on this systematic review, the study authors recommend low alcohol consumption to decrease the risk of AMD progression. Patients with early AMD who do not smoke should take the AREDS 1 formula, which includes vitamin C, vitamin E, beta-carotene, zinc as zinc oxide and copper as cupric oxide.

“In addition, the preventive effect of lutein (10mg/day) and zeaxanthin (2mg/day) as supplements is plausible, making them a good alternative for beta-carotene,” they noted in their paper

on the study. “Secondly, for persons with early AMD, we would recommend a Mediterranean diet, characterized by a high intake of vegetables, fruit, legumes, grains and nuts, a moderate consumption of fish, poultry, dairy and red wine, the use of olive oil instead of butter and a limited consumption of red meat.”

Future research should focus on personalized therapeutic and preventive approaches, according to the study authors, such as the connection between nutrition and immunological parameters. ◀

Pameijer EM, Heus P, Damen JA, et al. What did we learn in 35 years of research on nutrition and supplements for age-related macular degeneration: a systematic review. *Acta Ophthalmol.* June 13, 2022. [Epub ahead of print].

IN BRIEF

■ **Reticular Pseudodrusen Identified as Risk Factor for AMD Progression.** A post-hoc analysis of two clinical trial cohorts—Age-Related Eye Disease Study (AREDS) and AREDS2—recently found that reticular pseudodrusen serves as a risk factor for progression to late-stage AMD.

This study included eyes with no late AMD at baseline in AREDS (n=6,959 eyes) and AREDS2 (n=3,355 eyes).

The researchers graded color fundus photographs from annual study visits for soft drusen, pigmentary abnormalities and late AMD. In AREDS, the study authors reported a **correlation between the presence of reticular pseudodrusen and a higher risk of progression to late-stage disease.** However, they observed significant differences in the associated risk at simplified severity scale levels. The nine-step scale also showed a higher risk of progression when reticular pseudodrusen is present.

In both cohorts, the study authors found that **the presence of reticular pseudodrusen carried a higher risk for geographic atrophy than neovascular AMD.**

“Reticular pseudodrusen represents an important anatomical risk factor for progression to late AMD, particularly geographic atrophy. However, **the added risk associated with reticular pseudodrusen varies markedly by severity level,**” the study authors noted in *Ophthalmology*. “**It carries highly increased risk at lower/moderate**

levels and less increased risk at higher levels.”

For an accurate understanding of progression risk and subtype predictions, they concluded that **reticular pseudodrusen status should be considered in combination with traditional features.** Moving forward, it should also be included in updated AMD classification systems and risk calculators as well as clinical trials.

Agrón E, Domalpally A, Cukras CA, et al. Reticular pseudodrusen: the third macular risk feature for progression to late AMD. *Ophthalmol.* May 31, 2022. [Epub ahead of print].



DON'T WAIT FOR TOO LATE

When pressure builds, surgery isn't usually the first step in treating patients with mild to moderate glaucoma. But **minimally invasive glaucoma surgery (MIGS)** might be the best option for both your cataract and post-cataract surgery glaucoma patients.

Often more effective than drops and less invasive than traditional surgery, MIGS may be a treatment option worth considering sooner.

Keep Glaucoma In The Deep
ConsiderMIGSEarly.com

Smoking Intensity Tied to VF Loss Rate in Glaucoma

Patients who previously or currently smoked over 20 packs a year progressed the fastest.

Smoking is known to worsen the outcomes and be a modifiable risk factor for numerous ocular diseases, including glaucoma. A new study found that among glaucoma patients, heavy smokers especially were more likely to have visual field loss in affected eyes. They concluded that smoking levels may act as a significant predictor of disease progression.

The retrospective study involved 511 eyes of 354 patients with primary open-angle glaucoma who had at least three years of follow-up and five visual field tests. The median baseline age was 64.8 years. Approximately 60% of patients reported a history of alcohol consumption, 42% reported a history of smoking and 11% were heavy smokers at baseline.

They found that higher smoking intensity was associated with faster visual field loss by $-0.05\mu\text{m}/\text{year}$ per 10 pack-years, while alcohol showed no association. Other factors associated with faster rates of visual field worsening over time were history of smoking, lower BMI and older age.

“A total of 38.5% of eyes progressed among patients with ≥ 20 pack-years smoking, while 26% of eyes progressed among never smokers,” the researchers noted in their study. In heavy smokers, median visual field mean deviation worsened to -14.5dB from -3.7dB at baseline, while in glaucoma patients who never smoked, the final visual field mean deviation was -10dB from a baseline of -3.2dB .

The researchers pointed out that even heavy smokers who have since

quit the habit may still run into lasting consequences from the high level of chemical inhalation and nicotine absorption. “The effect of smoking intensity with ≥ 20 pack-years on vascular and neural tissue may be extended in smokers and attribute to faster glaucoma progression later in life,” they explained.

These findings highlight yet another reason not to smoke: to slow the progression of glaucomatous disease and improve visual outcomes. The study also cautions that close monitoring is necessary for patients who smoke or used to smoke more than 20 packs a year. ◀

Mahmoudinezhad G, Nishida T, Weinreb RN, et al. Impact of smoking on visual field progression in a long-term clinical follow-up. *Ophthalmology*. June 16, 2022. [Epub ahead of print].



DON'T WAIT FOR TOO LATE

When pressure builds, surgery isn't usually the first step in treating patients with mild to moderate glaucoma. But **minimally invasive glaucoma surgery (MIGS)** might be the best option for both your cataract and post-cataract surgery glaucoma patients.

Often more effective than drops and less invasive than traditional surgery, MIGS may be a treatment option worth considering sooner.

**Keep Glaucoma In The Deep
ConsiderMIGSEarly.com**

©2022 Sight Sciences, Inc. 3/22 OM-2244-US.v1

Omega-3 Supplementation Does Not Prevent Dry Eye

These findings add to the skepticism about such an intervention that followed the DREAM study's failure to find a treatment effect.

While several small randomized studies have suggested that marine omega-3 fatty acid supplementation may aid the treatment of dry eye disease (DED)—and one prominent trial, the DREAM study, found no evidence—questions also remain regarding whether these supplements can prevent the condition. Looking to answer this, a recent study found no connection between omega-3 fatty acid supplementation and the incidence of DED.

The researchers conducted an ancillary analysis of data from the Vitamin D and Omega-3 Trial (VITAL), which aims to assess the effects of those two agents in preventing cancer and cardiovascular disease. This analysis (called VITAL Dry Eye) included 23,523 US adults—men age 50 and older and women 55 and older—who did not have a previous diagnosis of DED or any severe dry eye symptoms at the time of study entry. The median age was 67 years, and 24% were women.

During a median of 5.3 years of treatment and follow-up, the researchers reported that 2% of the participants were diagnosed with DED, which was confirmed with medical records. There was no difference in diagnosed DED between participants in the omega-3 fatty acid or placebo groups. Additionally, the researchers observed no dif-

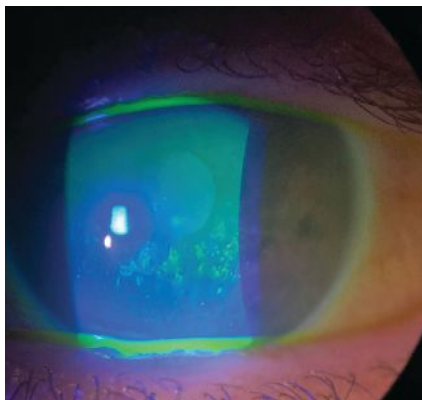


Photo: Pan Theriot, MD

This study found no difference in dry eye severity between those who supplemented with OFA and those who didn't.

ference between cohorts for diagnosed DED plus incidence of severe DED symptoms.¹

These findings, which demonstrated that 1g per day of marine omega-3 fatty acid had no effect on the incidence of diagnosed DED or reported severe DED symptoms, appear consistent with conclusions from the DREAM study. The current study also found no benefit with supplementation in newly reported severe DED symptoms, a component of the secondary endpoint that, according to the study authors, is more closely related to the endpoints explored in DREAM.

“When considered together, neither DREAM, which examined the effect

of omega-3 supplementation as an adjuvant in DED management, nor our study, which assessed the individual effect of omega-3 supplementation in DED prevention, provides support for long-term use of omega-3 supplements in reducing risks of DED,” they concluded in their report.

In a commentary on the VITAL Dry Eye study, Penny Asbell, MD, the principal investigator of the DREAM study, noted, “Unfortunately, the hope that omega-3 fatty acid supplementation would provide benefit for a wide array of diseases has eroded as the results of large-scale clinical trials have accumulated.”² She pointed out that the medical benefits of omega-3 supplementation are limited to “lowering triglycerides, secondary prevention of coronary heart disease and a few others.”

Given the longstanding habit within eye care of recommending omega fatty acids, however, Dr. Asbell did conclude, “Likely the debate on the role of omega-3 supplements for DED will continue.” ◀

1. Christen WG, Cook NR, Manson JE, et al. Efficacy of marine omega-3 fatty acid supplementation vs placebo in reducing incidence of dry eye disease in healthy US adults: a randomized clinical trial. *JAMA Ophthalmol.* June 9, 2022 [Epub ahead of print].

2. Asbell PA, Maguire MG. Another disappointment for omega-3 fatty acid and dry eye disease. *JAMA Ophthalmol.* June 9, 2022. [Epub ahead of print].

IN BRIEF

■ **Eyelid Rubbing, Squeezing Temporarily Increases IOP.** It's known that IOP levels can vary throughout the day, but they can also change from one minute to the next. A recent study discovered that one factor that causes short-term IOP variation in glaucoma patients is eyelid movement. In fact, the team found that **eyelid squeezing and rubbing can temporarily increase IOP by over 40mm Hg, voluntary blinks by 12mm Hg and eyelid closure by 4mm Hg.**

A relatively new alternative to in-office tonometry, the implantable IOP sensor is a clinical tool that makes it possible to observe these temporary changes in IOP. Using a small cohort of 11 primary open-angle glaucoma patients who had this sensor previously implanted, a research team investigated the extent of which specific eyelid muscle actions impact a patient's IOP.

The team evaluated various eyelid movements and corresponding pressure level changes by instructing patients to do the following: six

cycles of blinking with 10-second intervals in between and five cycles of eyelid closure, squeezing and rubbing with 15-second intervals in between. IOP levels were recorded from the sensor using an external antenna placed around the eye under examination.

The average peak in IOP increase following eyelid rubbing was 59.1mm Hg from baseline. For eyelid squeezing, the peak IOP increase was 42.2mm Hg; for eyelid closure, 3.8mm Hg; and for voluntary blinking, 11.6mm Hg.

The research team concluded that although their study observed brief, substantial increases during eyelid squeezing and rubbing, **“It is currently unknown whether these IOP changes are clinically relevant.”** More research is warranted to determine whether these brief IOP fluctuations during eyelid muscle movement contribute to glaucomatous damage.

van den Bosch JJON, Pennisi V, Mansouri K, et al. Effect of eyelid muscle action and rubbing on telemetrically obtained intraocular pressure in patients with glaucoma with an IOP sensor implant. *Br J Ophthalmol.* June 14, 2022. [Epub ahead of print].

Earlier Puberty Onset in Girls Linked to Myopia

A significant proportion of the sex disparity in the condition may be explained by female patients reaching this stage of life earlier.

Adolescent myopia has been positively associated with the onset of puberty, and Chinese researchers believe this association may help explain the higher myopia prevalence in females. They noted that this could be explained by the differences in physiological and behavioral changes during puberty between genders.

In a nationwide cross-sectional study, data came from five national surveys in China, including 338,896 boys aged 11 to 18 and 439,481 girls aged nine to 18. Myopia was defined according to unaided distance visual acuity and subjective refraction, and puberty status was defined dichotomously as menarche or spermarche, the milestones of sexual maturity.

The researchers found that menarche was associated with a 7% higher risk of myopia among girls but that the association between spermarche and myopia in boys was smaller and nonsignificant. The sex disparity in

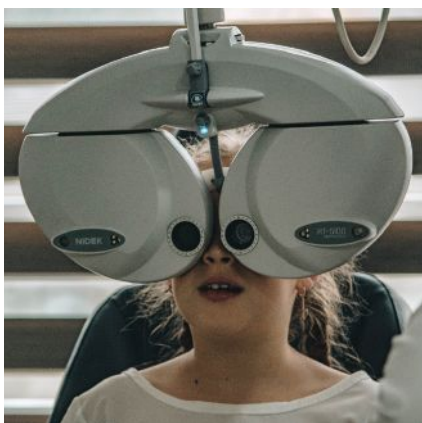

Photo: rrd on Unsplash

Early interventions to mitigate myopia might be more important in girls, researchers suggest.

myopia was consistent across seven- to 18-year-olds in all five surveys. Post-menarche girls and post-spermarche boys showed a 29% to 41% and 8% to 19% higher risk of myopia than pre-menarche girls and pre-spermarche boys, respectively.

Over 16% of the sex disparity in myopia could be explained by earlier

onset of puberty in girls, compared with almost 11% explained by several other behavioral factors together.

The study authors noted that going through puberty at a younger age puts females at an increased risk of developing higher-grade myopia earlier and therefore increase their risk of developing secondary ocular pathology. “For these reasons, early interventions for preventing myopia onset might be more important in girls,” they wrote. “Because our study did not analyze refraction and axial length data, it remains unclear whether earlier puberty could lead to a higher degree of myopia in girls.”

They believe that detailing the public health implications of this finding requires further longitudinal studies with more accurate measures of myopia and puberty status. ◀

Xu R, Zhong P, Jan C, et al. Sex disparity in myopia explained by puberty among Chinese adolescents from 1995 to 2014: a nationwide cross-sectional study. *Front Public Health*. May 30, 2022. [Epub ahead of print].

IN BRIEF

■ **Hyperreflective Lesions Found in Retinal Layers of COVID-19 Patients.** A recent study evaluating retinal and choroidal changes in the macular region of patients with COVID-19 demonstrated no significant change in retinal thickness in the different retinal layers of these patients; however, **qualitative changes, such as hyperreflective lesions in different retinal layers, were observed.**

Study participants had recovered from a mild to moderate degree of COVID-19 infection. The researchers performed macular SD-OCT at least two weeks and up to one month after disease recovery.

The study included both eyes of 30 patients and 60 controls. **The researchers reported that 28.3% of eyes in the patient group showed at least one abnormal finding**

indicated by macular SD-OCT. This included hyperreflective lesions in different retinal layers. **Dilated choroidal vessels and retinal pigment epitheliopathy were observed in 68.3% and 6.7% of eyes in the patient group, respectively.**

The data revealed no significant differences in retinal layers or retinal volume between COVID-19-recovered patients and healthy controls. Additionally, the researchers determined that **subfoveal choroidal thickness was significantly thicker among patients vs. controls.**

“The results of this study showed that patients with COVID-19 developed non-statistically significant thickening in retinal layers, which can demonstrate choroidal changes similar to those in patients with the pachychoroid spectrum,” the study authors concluded. **“Also, in COVID-19 patients, hyperreflective lesions are present in all retinal**

layers, and the findings of the current study indicate that the retina and choroid could be involved in COVID-19 patients, highlighting the necessity of examination.”

Abrishami M, Daneshvar R, Emamveridian Z, et al. Spectral-domain optical coherence tomography assessment of retinal and choroidal changes in patients with coronavirus disease 2019: a case-control study. *J Ophthalmol Inflamm Infect*. June 18, 2022. [Epub ahead of print].

■ **New DR Risk Factor Identified in Patients with Diabetic Kidney Disease.** Despite strict control of hyperglycemia, hypertension and hyperlipidemia, patients with type 2 diabetes remain at high risk for diabetic kidney disease, suggesting that **damage may have occurred before controlling these factors.**

This prospective study included 83 patients with type 2 diabetes, categorized into groups with no DR, non-proliferative DR (NPDR) and

proliferative DR (PDR). The researchers found that **homocysteine was negatively correlated with high-density lipoprotein-cholesterol and positively correlated with total cholesterol-high-density lipoprotein cholesterol, low-density lipoprotein cholesterol and urine microalbumin.**

The researchers also identified the following independent risk factors for diabetes mellitus and DR: traditional risk factors, homocysteine, arteriosclerosis-associated plasma indices and urine microalbumin.

“Some nontraditional risk factors such as homocysteine and lipoprotein (a) should also be considered in the prevention and treatment of DR,” the researchers concluded.

Chen X, Zhang X, Nie Y, et al. Circulating level of homocysteine contributes to diabetic retinopathy associated with dysregulated lipid profile and impaired kidney function in patients with type 2 diabetes mellitus. *Eye (Lond)*. June 23, 2022. [Epub ahead of print].

Temporary Prism Therapy Effective in AACE

Stepwise power reduction over time eliminated the condition within a year in 40% of patients.

Characterized by a sudden onset of concomitant esotropia with diplopia, the condition known as acute acquired concomitant esotropia is increasing in prevalence in children and adults due to excessive smartphone and screen use. Fresnel prism is a common and effective treatment for reducing prismatic strength in strabismus and various other visual disorders. A recent study found a technique for prismatic treatment that seemed to optimize and speed up outcomes for some patients: treating in a step-by-step manner.

The researchers included 36 patients with acute acquired concomitant esotropia of 25 prism diopters or less. They all underwent one year of prismatic correction using a step-by-step approach to prescribe press-on base-out Fresnel prisms between two and 10 prism diopters. At the conclusion of the study period, the cohort was divided into the following two groups: the treatment-success group, which consist-

ed of patients who had their esotropia eliminated and were weaned off the prisms within a year, and the treatment-continuing group, which comprised patients who needed to continue wearing a Fresnel prism beyond one year.

Slightly less than 40% of the patients were weaned off the prism and regained orthophoria and binocular single vision within a year after treatment began. Those patients had better cooperation, a smaller angle of esotropia and a shorter duration from onset to treatment. Notably, 100% of patients in the treatment-success group had good cooperation throughout treatment, while this was only true for 36% of the treatment-continuing group.

In their paper, the researchers explained the methodology behind a step-by-step treatment plan: “This approach not only uses the optical principle of the prism but also increases the abduction fusion force of patients to reduce and further eliminate esotropia,” they wrote. Additionally, they noted the

following reason for choosing to treat patients with base-out Fresnel press-on prisms instead of ground-in prisms: “Given gradual prismatic reduction and the higher cost of treatment, ground-in prisms were not recommended even for patients with esotropia less than 14 prism diopters.”

It’s important to consider that only patients with acute acquired concomitant esotropia of 25 prism diopters or less were included in this study. The data supports the conclusion that “prismatic correction in a step-by-step manner to reduce prismatic strength allows these patients to achieve successful motor outcomes, avoiding surgical correction and botulinum toxin injection and preventing them from experiencing the trauma and complications caused by surgery and botulinum toxin injection,” the researchers concluded. ◀

Wu Y, Feng X, Li J, et al. Prismatic treatment of acute acquired concomitant esotropia of 25 prism diopters or less. *BMC Ophthalmol.* June 24, 2022. [Epub ahead of print].

RNFL Thickness Helps Predict Adult Cognitive Decline

Thinner structures were more likely to lead to Alzheimer’s in this older population.

Retinal layer thickness is hypothesized to be related to cognitive function in patients with mild cognitive impairment and Alzheimer’s disease. However, longitudinal cohort studies of older healthy populations are scarce. Looking to close this gap, researchers recently found that macular retinal nerve fiber layer (RNFL) thickness can be a prognostic biomarker of long-term cognitive decline in adults 60 and older.

A total of 430 randomly sampled people participated in the baseline assessment, 215 of whom completed a mean of 5.4 years of follow-up. Using

spectral-domain OCT, the team assessed the thickness of six retinal layers in the macular region, peripapillary RNFL and the subfoveal choroid.

Baseline macular RNFL thickness was associated with baseline Consortium to Establish a Registry for Alzheimer’s Disease score and Mini-Mental State Examination score. A thinner baseline total macular RNFL thickness (lowest quartile <231µm) was associated with a larger decline in the two test scores during the follow-up period. Furthermore, participants with baseline total macular RNFL thickness below the lowest quartile cutoff value

presented a greater decline in cognitive scores and a higher prevalence of cognitive impairment and Alzheimer’s disease than those with RNFL thickness above the lowest cutoff value.

“Overall, macular RNFL thickness may be considered a noninvasive ocular biomarker for assessing changes in cognitive function in patients,” the study authors concluded in *JAMA Ophthalmology*. “However, to confirm these results, further large-scale population-based studies should be performed.” ◀

Kim HM, Han JW, Park YJ, et al. Association between retinal layer thickness and cognitive decline in older adults. *JAMA Ophthalmol.* May 26, 2022. [Epub ahead of print].

CLINICAL EDITORS

CHIEF CLINICAL EDITOR ~ PAUL M. KARPECKI, OD

ASSOCIATE CLINICAL EDITORS ~ JOSEPH P. SHOVLIN, OD, CHRISTINE SINDT, OD

CONTRIBUTING EDITORS

PAUL C. AJAMIAN, OD, ATLANTA

ALISON BOZUNG, OD, MIAMI

DEREK N. CUNNINGHAM, OD, AUSTIN, TEX.

MARK T. DUNBAR, OD, MIAMI

JAMES L. FANELLI, OD, WILMINGTON, NC

ANDREW S. GURWOOD, OD, PHILADELPHIA

PAUL M. KARPECKI, OD, LEXINGTON, KY.

BISANT LABIB, OD, ELKINS PARK, PA

PAMELA H. SCHNELL, OD, MEMPHIS, TENN.

JOSEPH P. SHOVLIN, OD, SCRANTON, PA

JOSEPH W. SOWKA, OD, FORT LAUDERDALE, FLA.

MARC TAUB, OD, MEMPHIS, TENN.

MONTGOMERY VICKERS, OD, DALLAS

WALTER O. WHITLEY, OD, MBA, VIRGINIA BEACH, VA.

EDITORIAL ADVISORY BOARD

JEFFREY R. ANSHEL, OD, ENCINITAS, CALIF.

JILL AUTRY, OD, RPH, HOUSTON

SHERRY J. BASS, OD, NEW YORK

EDWARD S. BENNETT, OD, ST. LOUIS

MARC R. BLOOMENSTEIN, OD, SCOTTSDALE, ARIZ.

ALISON BOZUNG, OD, MIAMI

AARON BRONNER, OD, KENNEWICK, WASH.

MILE BRUJIC, OD, BOWLING GREEN, OHIO

CHRIS J. CAKANAC, OD, MURRYSVILLE, PA

JERRY CAVALLERANO, OD, PhD, BOSTON

BRIAN CHOU, OD, SAN DIEGO

MICHAEL CHAGLASIAN, OD, CHICAGO

A. PAUL CHOUS, MA, OD, TACOMA, WASH.

GLENN S. CORBIN, OD, WYOMISSING, PA

MICHAEL DELGIODICE, OD, CLIFTON, NJ

S. BARRY EIDEN, OD, DEERFIELD, ILL.

ARTHUR B. EPSTEIN, OD, PHOENIX

STEVEN FERRUCCI, OD, SEPULVEDA, CALIF.

MURRAY FINGERET, OD, HEWLETT, NY

IAN BEN GADDIE, OD, LOUISVILLE, KY

GARY S. GERBER, OD, HAWTHORNE, NJ

JESSICA HAYNES, OD, MEMPHIS, TENN.

MILTON HOM, OD, AZUSA, CALIF.

DAVID KADING, OD, SEATTLE

JEROME A. LEGERTON, OD, MBA, SAN DIEGO

THOMAS L. LEWIS, OD, PhD, PHILADELPHIA

BLAIR B. LONSBERRY, MS, OD, MED, PORTLAND, OR

KELLY A. MALLOY, OD, PHILADELPHIA

DANICA MARRELLI, OD, HOUSTON, TEX.

RON MELTON, OD, CHARLOTTE, NC

PAMELA J. MILLER, OD, JD, HIGHLAND, CALIF.

MARC MYERS, OD, COATESVILLE, PA

CARLO J. PELINO, OD, JENKINTOWN, PA

JOSEPH PIZZIMENTI, OD, FORT LAUDERDALE, FLA.

CHRISTOPHER J. QUINN, OD, ISELIN, NJ

MOHAMMAD RAFIEETARY, OD, MEMPHIS, TENN.

JOHN L. SCHACHET, OD, ENGLEWOOD, COLO.

JACK SCHAEFFER, OD, BIRMINGHAM, ALA.

PAMELA H. SCHNELL, OD, MEMPHIS, TENN.

LEO P. SEMES, OD, BIRMINGHAM, ALA.

DIANA L. SHECHTMAN, OD, FORT LAUDERDALE, FLA.

JEROME SHERMAN, OD, NEW YORK, NY

LEONID SKORIN, JR., OD, DO, ROCHESTER, MINN.

JOSEPH W. SOWKA, OD, FORT LAUDERDALE, FLA.

JESSICA STEEN, OD, DAVIE, FLA.

BRAD M. SUTTON, OD, INDIANAPOLIS

LORETTA B. SZCZOTKA, OD, PhD, CLEVELAND

MARC TAUB, OD, MEMPHIS, TENN.

TAMMY P. THAN, MS, OD, BIRMINGHAM, ALA.

RANDALL THOMAS, OD, CONCORD, NC

SARA WEIDMAYER, OD, ANN ARBOR, MICH.

KAREN YEUNG, OD, LOS ANGELES



Business Offices

19 Campus Boulevard, Suite 101
Newtown Square, PA 19073
Subscription inquiries (877) 529-1746 (USA only)
outside USA, call (847) 763-9630

PUBLISHER

MICHAEL HOSTER

(610) 492-1028

mhoster@jobson.com

SENIOR MANAGER, STRATEGIC ACCOUNTS

MICHELE BARRETT

(610) 492-1014

mbarrett@jobson.com

REGIONAL SALES MANAGER

JONATHAN DARDINE

(610) 492-1030

jdardine@jobson.com

PRODUCTION MANAGER

FARRAH APONTE

(212) 274-7057

faponte@jobson.com

PRODUCTION MANAGER

KAREN LALLONE

(610) 492-1010

klallone@jobson.com

DIGITAL MARKETING MANAGER

MATT EGGER

(610) 492-1029

megger@jobson.com

CLASSIFIED ADVERTISING

(888) 498-1460

SUBSCRIPTIONS

\$63 PER YEAR, \$99 (US) IN CANADA,
\$158 (US) IN ALL OTHER COUNTRIES
revoptometry@cambeywest.com

CIRCULATION

PO BOX 71, CONGERS, NY 10920-0071

(877) 529-1746

OUTSIDE USA: (845) 267-3065

SENIOR CIRCULATION MANAGER

HAMILTON MAHER

(212) 219-7870

hmaher@jhihealth.com

CEO, INFORMATION GROUP SERVICES

MARC FERRARA

SENIOR VICE PRESIDENT, OPERATIONS

JEFF LEVITZ

VICE PRESIDENT, HUMAN RESOURCES

TAMMY GARCIA

VICE PRESIDENT, CREATIVE SERVICES & PRODUCTION

MONICA TETTAMANZI

CORPORATE PRODUCTION DIRECTOR

JOHN ANTHONY CAGGIANO

VICE PRESIDENT, CIRCULATION

JARED SONNERS

Jobson Health Information/WebMD

395 Hudson Street, 3rd Floor, New York, NY 10014

BRIEF SUMMARY OF PRESCRIBING INFORMATION

This Brief Summary does not include all the information needed to use VYZULTA safely and effectively. See full Prescribing Information for VYZULTA.

VYZULTA® (latanoprostene bunod ophthalmic solution), 0.024%, for topical ophthalmic use.

Initial U.S. Approval: 2017

1 INDICATIONS AND USAGE

VYZULTA® (latanoprostene bunod ophthalmic solution) 0.024% is indicated for the reduction of intraocular pressure (IOP) in patients with open-angle glaucoma or ocular hypertension.

4 CONTRAINDICATIONS

None

5 WARNINGS AND PRECAUTIONS

5.1 Pigmentation

VYZULTA® (latanoprostene bunod ophthalmic solution), 0.024% may cause changes to pigmented tissues. The most frequently reported changes with prostaglandin analogs have been increased pigmentation of the iris and periorbital tissue (eyelid).

Pigmentation is expected to increase as long as latanoprostene bunod ophthalmic solution is administered. The pigmentation change is due to increased melanin content in the melanocytes rather than to an increase in the number of melanocytes. After discontinuation of VYZULTA, pigmentation of the iris is likely to be permanent, while pigmentation of the periorbital tissue and eyelash changes are likely to be reversible in most patients. Patients who receive prostaglandin analogs, including VYZULTA, should be informed of the possibility of increased pigmentation, including permanent changes. The long-term effects of increased pigmentation are not known.

Iris color change may not be noticeable for several months to years. Typically, the brown pigmentation around the pupil spreads concentrically towards the periphery of the iris and the entire iris or parts of the iris become more brownish. Neither nevi nor freckles of the iris appear to be affected by treatment. While treatment with VYZULTA® (latanoprostene bunod ophthalmic solution), 0.024% can be continued in patients who develop noticeably increased iris pigmentation, these patients should be examined regularly [see Patient Counseling Information (17) in full Prescribing Information].

5.2 Eyelash Changes

VYZULTA may gradually change eyelashes and vellus hair in the treated eye. These changes include increased length, thickness, and the number of lashes or hairs. Eyelash changes are usually reversible upon discontinuation of treatment.

5.3 Intraocular Inflammation

VYZULTA should be used with caution in patients with a history of intraocular inflammation (iritis/uveitis) and should generally not be used in patients with active intraocular inflammation as it may exacerbate this condition.

5.4 Macular Edema

Macular edema, including cystoid macular edema, has been reported during treatment with prostaglandin analogs. VYZULTA should be used with caution in aphakic patients, in pseudophakic patients with a torn posterior lens capsule, or in patients with known risk factors for macular edema.

5.5 Bacterial Keratitis

There have been reports of bacterial keratitis associated with the use of multiple-dose containers of topical ophthalmic products. These containers had been inadvertently contaminated by patients who, in most cases, had a concurrent corneal disease or a disruption of the ocular epithelial surface.

5.6 Use with Contact Lens

Contact lenses should be removed prior to the administration of VYZULTA because this product contains benzalkonium chloride. Lenses may be reinserted 15 minutes after administration.

6 ADVERSE REACTIONS

The following adverse reactions are described in the Warnings and Precautions section: pigmentation (5.1), eyelash changes (5.2), intraocular inflammation (5.3), macular edema (5.4), bacterial keratitis (5.5), use with contact lens (5.6).

6.1 Clinical Trials Experience

Because clinical trials are conducted under widely varying conditions, adverse reaction rates observed in the clinical trials of a drug cannot be directly compared to rates in the clinical trials of another drug and may not reflect the rates observed in practice.

VYZULTA was evaluated in 811 patients in 2 controlled clinical trials of up to 12 months duration. The most common ocular adverse reactions observed in patients treated with latanoprostene bunod were: conjunctival hyperemia (6%), eye irritation (4%), eye pain (3%), and instillation site pain (2%). Approximately 0.6% of patients discontinued therapy due to ocular adverse reactions including ocular hyperemia, conjunctival irritation, eye irritation, eye pain, conjunctival edema, vision blurred, punctate keratitis and foreign body sensation.

8 USE IN SPECIFIC POPULATIONS

8.1 Pregnancy

Risk Summary

There are no available human data for the use of VYZULTA during pregnancy to inform any drug associated risks.

Latanoprostene bunod has caused miscarriages, abortion, and fetal harm in rabbits. Latanoprostene bunod was shown to be abortifacient and teratogenic when administered intravenously (IV) to pregnant rabbits at exposures \geq 0.28 times the clinical dose. Doses \geq 20 μ g/kg/day (23 times the clinical dose) produced 100% embryofetal lethality. Structural abnormalities observed in rabbit fetuses included anomalies of the great vessels and aortic arch vessels, domed head, sternebral and vertebral skeletal anomalies, limb hyperextension

and malrotation, abdominal distension and edema. Latanoprostene bunod was not teratogenic in the rat when administered IV at 150 mcg/kg/day (87 times the clinical dose) [see Data].

The background risk of major birth defects and miscarriage for the indicated population is unknown. However, the background risk in the U.S. general population of major birth defects is 2 to 4%, and of miscarriage is 15 to 20%, of clinically recognized pregnancies.

Data

Animal Data

Embryofetal studies were conducted in pregnant rabbits administered latanoprostene bunod daily by intravenous injection on gestation days 7 through 19, to target the period of organogenesis. The doses administered ranged from 0.24 to 80 mcg/kg/day. Abortion occurred at doses \geq 0.24 mcg/kg/day latanoprostene bunod (0.28 times the clinical dose, on a body surface area basis, assuming 100% absorption). Embryofetal lethality (resorption) was increased in latanoprostene bunod treatment groups, as evidenced by increases in early resorptions at doses \geq 0.24 mcg/kg/day and late resorptions at doses \geq 6 mcg/kg/day (approximately 7 times the clinical dose). No fetuses survived in any rabbit pregnancy at doses of 20 mcg/kg/day (23 times the clinical dose) or greater. Latanoprostene bunod produced structural abnormalities at doses \geq 0.24 mcg/kg/day (0.28 times the clinical dose). Malformations included anomalies of sternum, coarctation of the aorta with pulmonary trunk dilation, retroesophageal subclavian artery with absent brachiocephalic artery, domed head, forepaw hyperextension and hindlimb malrotation, abdominal distention/edema, and missing/fused caudal vertebrae.

An embryofetal study was conducted in pregnant rats administered latanoprostene bunod daily by intravenous injection on gestation days 7 through 17, to target the period of organogenesis. The doses administered ranged from 150 to 1500 mcg/kg/day. Maternal toxicity was produced at 1500 mcg/kg/day (870 times the clinical dose, on a body surface area basis, assuming 100% absorption), as evidenced by reduced maternal weight gain. Embryofetal lethality (resorption and fetal death) and structural anomalies were produced at doses \geq 300 mcg/kg/day (174 times the clinical dose). Malformations included anomalies of the sternum, domed head, forepaw hyperextension and hindlimb malrotation, vertebral anomalies and delayed ossification of distal limb bones. A no observed adverse effect level (NOAEL) was established at 150 mcg/kg/day (87 times the clinical dose) in this study.

8.2 Lactation

Risk Summary

There are no data on the presence of VYZULTA in human milk, the effects on the breastfed infant, or the effects on milk production. The developmental and health benefits of breastfeeding should be considered, along with the mother's clinical need for VYZULTA, and any potential adverse effects on the breastfed infant from VYZULTA.

8.4 Pediatric Use

Use in pediatric patients aged 16 years and younger is not recommended because of potential safety concerns related to increased pigmentation following long-term chronic use.

8.5 Geriatric Use

No overall clinical differences in safety or effectiveness have been observed between elderly and other adult patients.

13 NONCLINICAL TOXICOLOGY

13.1 Carcinogenesis, Mutagenesis, Impairment of Fertility

Latanoprostene bunod was not mutagenic in bacteria and did not induce micronuclei formation in the *in vivo* rat bone marrow micronucleus assay. Chromosomal aberrations were observed *in vitro* with human lymphocytes in the absence of metabolic activation.

Latanoprostene bunod has not been tested for carcinogenic activity in long-term animal studies. Latanoprost acid is a main metabolite of latanoprostene bunod. Exposure of rats and mice to latanoprost acid, resulting from oral dosing with latanoprost in lifetime rodent bioassays, was not carcinogenic.

Fertility studies have not been conducted with latanoprostene bunod. The potential to impact fertility can be partially characterized by exposure to latanoprost acid, a common metabolite of both latanoprostene bunod and latanoprost. Latanoprost acid has not been found to have any effect on male or female fertility in animal studies.

13.2 Animal Toxicology and/or Pharmacology

A 9-month toxicology study administered topical ocular doses of latanoprostene bunod to one eye of cynomolgus monkeys: control (vehicle only), one drop of 0.024% bid, one drop of 0.04% bid and two drops of 0.04% per dose, bid. The systemic exposures are equivalent to 4.2-fold, 7.9-fold, and 13.5-fold the clinical dose, respectively, on a body surface area basis (assuming 100% absorption). Microscopic evaluation of the lungs after 9 months observed pleural/subpleural chronic fibrosis/inflammation in the 0.04% dose male groups, with increasing incidence and severity compared to controls. Lung toxicity was not observed at the 0.024% dose.

U.S. Patent Numbers: 7,273,946; 7,629,345; 7,910,767; 8,058,467.

VYZULTA is a trademark of Bausch & Lomb Incorporated or its affiliates.

© 2020 Bausch & Lomb Incorporated or its affiliates.

Distributed by:

Bausch + Lomb, a division of

Bausch Health US, LLC

Bridgewater, NJ 08807 USA

Based on 9612403 (Folded), 9612303 (Flat) 5/2019

VYZ.0109.USA.20 Issued: 5/2020



VYZULTA

(latanoprostene
bunod ophthalmic
solution), 0.024%

THE HORSEPOWER YOU NEED TO LOWER IOP

Powerful IOP reduction with excellent tolerability^{1,2}

VYZULTA delivered **up to 9.1 mmHg mean IOP reduction** from baseline in pivotal trials.^{1,2*}

TAKE A TEST RIDE AT VYZULTAHCP.COM

*Pivotal study designs: Two Phase 3, randomized, multicenter, parallel-group studies, APOLLO and LUNAR, evaluating noninferiority of once-daily VYZULTA vs twice-daily timolol maleate 0.5% in patients with open-angle glaucoma or ocular hypertension. Primary endpoint was IOP measured at 9 assessment time points in study eye. APOLLO (VYZULTA, n=284; timolol, n=133) and LUNAR (VYZULTA, n=278; timolol, n=136).^{2,3}

INDICATION

VYZULTA® (latanoprostene bunod ophthalmic solution), 0.024% is indicated for the reduction of intraocular pressure (IOP) in patients with open-angle glaucoma or ocular hypertension.

IMPORTANT SAFETY INFORMATION

- Increased pigmentation of the iris and periorbital tissue (eyelid) can occur. Iris pigmentation is likely to be permanent
- Gradual changes to eyelashes, including increased length, increased thickness, and number of eyelashes, may occur. These changes are usually reversible upon treatment discontinuation
- Use with caution in patients with a history of intraocular inflammation (iritis/uveitis). VYZULTA should generally not be used in patients with active intraocular inflammation
- Macular edema, including cystoid macular edema, has been reported during treatment with prostaglandin analogs. Use with caution in aphakic patients, in pseudophakic patients with a torn posterior lens capsule, or in patients with known risk factors for macular edema
- There have been reports of bacterial keratitis associated with the use of multiple-dose containers of topical ophthalmic products that were inadvertently contaminated by patients
- Contact lenses should be removed prior to the administration of VYZULTA and may be reinserted 15 minutes after administration
- Most common ocular adverse reactions with incidence $\geq 2\%$ are conjunctival hyperemia (6%), eye irritation (4%), eye pain (3%), and instillation site pain (2%)

For more information, please see Brief Summary of full Prescribing Information on adjacent page.

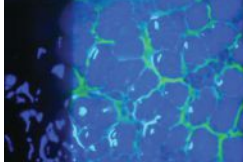
References: **1.** VYZULTA Prescribing Information. Bausch & Lomb Incorporated. **2.** Weinreb RN, Scassellati Sforzolini B, Vittitow J, Liebmann J. Latanoprostene bunod 0.024% versus timolol maleate 0.5% in subjects with open-angle glaucoma or ocular hypertension: the APOLLO study. *Ophthalmology*. 2016;123(5):965-973. **3.** Medeiros FA, Martin KR, Peace J, Scassellati Sforzolini B, Vittitow JL, Weinreb RN. Comparison of latanoprostene bunod 0.024% and timolol maleate 0.5% in open-angle glaucoma or ocular hypertension: the LUNAR study. *Am J Ophthalmol*. 2016;168:250-259.

VYZULTA and the V design are trademarks of Bausch & Lomb Incorporated or its affiliates. Any other product/brand names and/or logos are trademarks of the respective owners. ©2021 Bausch & Lomb Incorporated or its affiliates. All rights reserved. VYZ.0258.USA.20

BAUSCH + LOMB

FEATURES

REVIEW OF OPTOMETRY • Vol. 159, No. 7 • JULY 15, 2022




32 Vital Dyes for Dry Eyes

We break down the several staining patterns associated with various ocular conditions and how to interpret each one.

By Rebecca Rojas, OD

28th Annual GLAUCOMA REPORT


SCOPE EXPANSION SERIES



40 Taking the Lead on Glaucoma Care

ODs in every US state can now manage this common condition. Here's how to direct the delivery of care in your community.

By Catlin Nalley, Contributing Editor



50 Prepping for the Glaucoma Grind

Once in your care, people with this disease become lifelong patients. Learn how to best accommodate the ongoing needs of those in the advanced stage.

By Judy Hu, OD

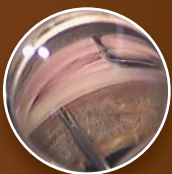


56 On the Threshold: New VF Testing Tech

This exciting development has numerous potential possibilities for improving optometric care.

By Melanie Anspaugh, OD

EARN 2 CE CREDITS



64 MIGS on the Move

A decade after their debut, these procedures now dominate the surgical sphere. Which options are most popular today, and where do ODs fit into the clinical picture?

By Jessica Steen, OD

DEPARTMENTS

REVIEW OF OPTOMETRY • JULY 15, 2022



VISIT US ON SOCIAL MEDIA

Facebook: revoptom

Twitter: revoptom

Instagram: revoptom

LinkedIn: company/review-of-optometry

4

NEWS REVIEW

Clinical, legislative and practice development updates.

18

OUTLOOK

Leveling Up in Glaucoma

ODs everywhere can treat it medically. More should master the basics now as the profession readies a jump to the next plateau.

Jack Persico, Editor-in-Chief

20

THROUGH MY EYES

VF Meets VR

The newest consumer technology stands ready to reinvent one of our oldest clinical tests.

Paul M. Karpecki, OD

22

CHAIRSIDE

Post-Vacation High

Takeaways from my recent trip to Italy.

Montgomery Vickers, OD

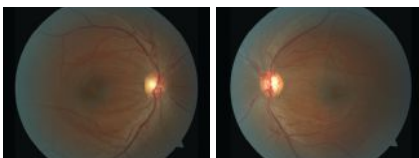
24

CLINICAL QUANDARIES

Two-for-one Deal

With bilateral macular lesions, think about retinal dystrophies, but keep other conditions in mind.

Paul C. Ajamian, OD



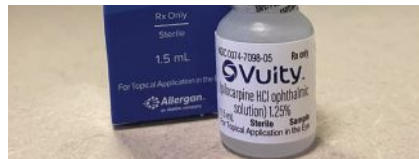28

THE ESSENTIALS

Pilocarpine: New and Improved?

The drug recently re-emerged as an option for presbyopia.

Bisant A. Labib, OD



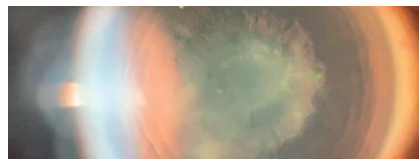73

CORNEA AND CONTACT LENS Q + A

HSVK Reoccurrence and Risk of Resistance

The more episodes a patient has, the less likely they may be to respond to antivirals due to prolonged treatment.

Joseph P. Shovlin, OD



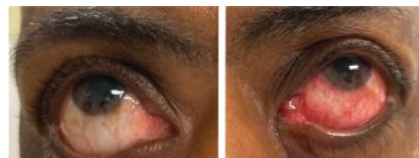74

URGENT CARE

Answers in the Angiography

These case findings could signal more than just a retinal condition.

Alison Bozung, OD



80

OCULAR SURFACE REVIEW

Power Trio

Three promising new therapeutic look to dramatically change dry eye disease management.

Paul M. Karpecki, OD




82

RETINA QUIZ

In Need of a Fill-up

This patient's older age and scattered blot hemorrhages led to the diagnosis.

Mark Dunbar, OD



86

PRODUCT REVIEW

New items to improve clinical care and strengthen your practice.

90

DIAGNOSTIC QUIZ

Born This Way

When a patient describes a longstanding and gradually worsening issue, what type of disease should you consider?

Andrew S. Gurwood, OD

IVERIC
BIO

TRANSFORMATIVE
THERAPIES
FOR RETINAL DISEASES

We are focused on developing treatments for patients suffering from retinal diseases with significant unmet medical needs.

Geographic Atrophy | Stargardt Disease | Inherited Retinal Diseases

Learn more at IvericBio.com

Founded 1891
Founding Editor, Frederick Boger

EDITOR-IN-CHIEF
JACK PERSICO
(610) 492-1006 • jpersico@jobson.com

SENIOR EDITOR
JULIE SHANNON
(610) 492-1005 • jshannon@jobson.com

SENIOR ASSOCIATE EDITOR
CATHERINE MANTHORP
(610) 492-1043 • cmanthorp@jobson.com

SENIOR ASSOCIATE EDITOR
MARK DE LEON
(610) 492-1021 • mdeleon@jobson.com

ASSOCIATE EDITOR
LEANNE SPIEGLE
(610) 492-1026 • lspiegle@jobson.com

SPECIAL PROJECTS MANAGER
JILL GALLAGHER
(610) 492-1037 • jgallagher@jobson.com

SENIOR ART DIRECTOR
JARED ARAUJO
jaraujo@jobson.com

GRAPHIC DESIGNER
LYNNE O'CONNOR
lyoconnor@webmd.net

DIRECTOR OF CE ADMINISTRATION
REGINA COMBS
(212) 274-7160 • rcombs@jobson.com

Clinical Editors

Chief Clinical Editor • Paul M. Karpecki, OD
Associate Clinical Editors
Joseph P. Shovlin, OD, Christine W. Sindt, OD
Clinical & Education Conference Advisor
Paul M. Karpecki, OD
Case Reports Coordinator • Andrew S. Gurwood, OD

Columnists

Chairside – Montgomery Vickers, OD
Clinical Quandaries – Paul C. Ajamian, OD
Cornea and Contact Lens Q+A – Joseph P. Shovlin, OD
Diagnostic Quiz – Andrew S. Gurwood, OD
The Essentials – Bisant A. Labib, OD
Focus on Refraction – Marc Taub, OD, Pamela Schnell, OD
Glaucoma Grand Rounds – James L. Fanelli, OD
Ocular Surface Review – Paul M. Karpecki, OD
Retina Quiz – Mark T. Dunbar, OD
Surgical Minute – Derek Cunningham, OD, Walter Whitley, OD
Therapeutic Review – Joseph W. Sowka, OD
Through My Eyes – Paul M. Karpecki, OD
Urgent Care – Alison Bozung, OD

Editorial Offices

19 Campus Blvd., Suite 101 • Newtown Square, PA 19073

Jobson Medical Information/WebMD
395 Hudson Street, 3rd Floor, New York, NY 10014

Subscription inquiries: (877) 529-1746
Continuing Education inquiries: (800) 825-4696

Printed in USA



BY JACK PERSICO
EDITOR-IN-CHIEF
OUTLOOK

Leveling Up in Glaucoma

ODs everywhere can treat it medically. More should master the basics now as the profession readies a jump to the next plateau.

It sure took long enough. The push for optometric prescribing rights in glaucoma spanned 45 years, from West Virginia's ground-breaking 1976 law to Massachusetts's better-late-than-never authorization in 2021. But that isn't the only reason optometry's uptake of glaucoma responsibilities has been so unevenly distributed throughout the profession compared to other prescribing rights.

The cost of the necessary equipment and difficulties in billing medical insurance plans are the top two setbacks to fully embracing glaucoma care, optometrists told us in a 2020 reader survey. When you combine those logistical impediments with the time-consuming nature of glaucoma services and a generalized anxiety about making the wrong clinical call on a vision-threatening disease, it's easy to see why a sizable number of optometrists decide to concentrate on other aspects of eye care.

Trouble is, optometry is already moving on to the next level of glaucoma management: performing laser procedures like SLT and, to a lesser extent, LPI. The routine, day-to-day work of glaucoma care—performing tonometry, optic nerve evaluation, OCT and visual fields, then managing the patient medically—was once aspirational for many optometrists. Now, those are the table stakes.

The rising stature of SLT as a first-line therapy in glaucoma management dovetails nicely with the legislative gains that are now making it available to optometrists. The profession has an opportunity to transform itself, and the care glaucoma patients receive, in one fell swoop.

All the experts who teach SLT to ODs stress that it's well within your skill set. Laser trabeculoplasty can delay the need for filtering surgery or other advanced aspects of care. If optometry embraces this new tool, patients can remain in their care for longer before comanagement or referral to ophthalmology is needed.

And the opportunity is poised to explode. Colorado's recent success in passing a laser law brings the number of states with such privileges to 10. These laws currently give more than 5,000 US optometrists the right to perform laser procedures, or a bit over 10% of the country's OD workforce.

But it won't stay that way for long. California alone has just about the same number of practicing optometrists as the 10 current laser states combined—and it's in play for a laser law too. In late June, a bill authorizing California ODs to perform laser and other minor surgical procedures cleared a key legislative hurdle.

If California gets a laser law this year, well, that's the ballgame. Laser procedures would instantly vault into mainstream optometry and other states would have an even stronger case to make in their own scope expansion efforts. This would, of course, be welcome. But especially in glaucoma, not everyone's ready to level up yet.

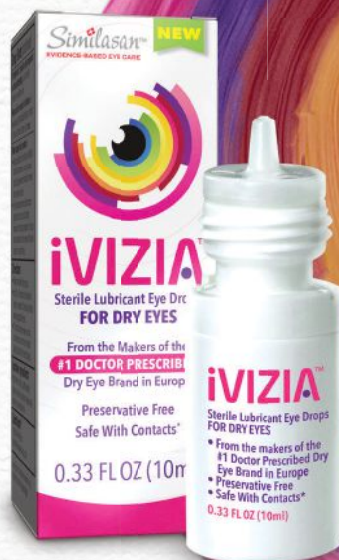I encourage anyone who wishes they could do more to read this month's cover story, "Taking the Lead on Glaucoma," for advice from optometric experts in the disease. Whether you need to master the core components or are ready to make the jump to lasers, these pros can show you the path forward. Good luck! ■

New from the makers of the #1-prescribed dry eye brand in Europe*

Covering the spectrum of Dry Eye Relief

Introducing preservative-free iVIZIA™ lubricant eye drops for the comprehensive combination of lasting relief and ocular surface protection.¹⁻⁶

- Trehalose provides bioprotection, osmoprotection, and rehydration¹⁻⁴
- Hyaluronic acid (HA) and povidone deliver lubrication with long-lasting relief⁵⁻⁶
- Increased tear film thickness for up to 240 minutes⁷
- Preservative free
- Proprietary multi-dose bottle design for calibrated dosing and contamination protection
- Suitable for all dry eye sufferers, including contact lens wearers†



Help patients see dry eye relief differently. Recommend iVIZIA OTC.

Request samples and learn more by scanning the QR code or visiting [iVIZIA.com/ECP](https://www.iVIZIA.com/ECP).



*Prescription market data, Sept. 2021 – S01K without cyclosporine.

†To limit blurriness when using contact lenses, remove contacts, apply drops, then insert contacts.

References: **1.** Chen W, Zhang X, Liu M, et al. Trehalose protects against ocular surface disorders in experimental murine dry eye through suppression of apoptosis. *Exp Eye Res.* 2009;89(3):311-318. **2.** Aragona P, Colosi P, Rania L, et al. Protective effects of trehalose on the corneal epithelial cells. *ScientificWorldJournal.* 2014;2014:717835. **3.** Chiambaretta F, Doan S, Labetoulle M, et al. A randomized, controlled study of the efficacy and safety of a new eyedrop formulation for moderate to severe dry eye syndrome. *Eur J Ophthalmol.* 2017;27(1):1-9. **4.** Liu Z, Chen D, Chen X, et al. Trehalose induces autophagy against inflammation by activating TFEB signaling pathway in human corneal epithelial cells exposed to hyperosmotic stress. *Invest Ophthalmol Vis Sci.* 2020;61(10):26. **5.** US FDA Department of Health and Human Services. Ophthalmic drug products for over-the-counter human use. Updated October 21, 2021. Accessed January 19, 2022. <https://www.accessdata.fda.gov/scripts/cdrh/cfdocs/cfcfr/CFRSearch.cfm?CFRPart=349>. **6.** Jones L, Downie LE, Korb D, et al. TFOS DEWS II management and therapy report. *Ocul Surf.* 2017;15(3):575-628. **7.** Schmidl D, Schmetterer L, Witkowska KJ, et al. Tear film thickness after treatment with artificial tears in patients with moderate dry eye disease. *Cornea.* 2015;34(4):421-426.



BY PAUL M. KARPECKI, OD
CHIEF CLINICAL EDITOR

THROUGH MY EYES

VR Meets VF

The newest consumer technology stands ready to reinvent one of our oldest clinical tests.

While the entertainment world has numerous virtual reality (VR) headsets for gaming and exploring, optometry has similar and exciting opportunities for use of this tech in visual field (VF), macular degeneration and objective testing.

COVID-19 has made us revisit many of our diagnostic technologies. Few patients today want to stick their heads in a dome that hasn't been disinfected, which isn't a simple task and could damage the device. Existing dome VF technologies require their own dark room, aren't comfortable to sit for a significant amount of time and use monocular testing, which increases time and anxiety. These factors contribute to patient fatigue and can lead to a decreased sensitivity and reliability, resulting in multiple tests.^{1,2}

VR Headset Technology

Head-mounted devices make VF testing more user-friendly. Devices such as HTC (Vive), Oculus (Oculus), Heru's VR headset and the Smart System VR Headset (M&S Technologies) are placed over the eyes and secured behind the head. The patient simply looks at a central target and the requested VF (10-2, 24-2 or 30-2) is measured in about three minutes per eye. There is also a screening VF that takes about 45 seconds. Some systems test binocularly since the patient can't truly tell which eye is being tested in a VR headset, and most can also import data directly into an EHR system.

Some attributes I've found helpful include binocular vision testing to

increase efficiency and active tracking. It's important to have systems that don't simply have a fixation target, but rather active pausing of the test when fixation is lost. For example, the Smart System VR headset target goes from red to gray when the internal cameras sense the patient's eyes are not looking at the target, and testing automatically stops. Once the patient resumes fixation, the target turns red again and the test resumes. Also look for systems that include verbal cues through the headset to assist with testing and fixation.

“**24-2C, SITA Fast, SITA Faster and now VR technologies, as well as the new objective field testing, will change how we measure VFs.**”

Patients don't typically lose a single point of vision in glaucoma, but rather a cluster or area that eventually leads to a nasal step defect or arcuate pattern. The Smart System VR headset provides an intriguing aspect called neighborhood cluster testing, which has been shown to increase efficiency and accuracy. The test detects larger clusters and each cluster is explored more closely, and the information from neighboring positions help define the shape and pattern of impairment.

Other Applications for VR

Many of these same systems not only perform VF testing but can measure visual acuity, color vision testing and

contrast sensitivity. AdaptDx Pro (Maculogix), for example, can help diagnose AMD. Dark adaptation is a 5.5 minute test that, like VF testing, is typically reimbursed by insurance unless you use it as a screening device. Off-fovea light comes through the VR headset and the patient monitors light input to determine when adaptation occurs. Patients without AMD will typically adapt well before 5.5 minutes, which is a normal rod intercept. The system is sensitive enough to determine AMD three years before signs such as drusen are evident and can also be used to track disease progress. The manufacturer recently went out of business but the technology will survive in some fashion.

ObjectiveField

This VF device is another fascinating advancement that involves a short simultaneous bilateral exam (about three and a half minutes per eye) with automatic asymmetric reporting. The technology, from Konan Medical, is based on neurological (pupillary) response to stimuli and provides accurate results in faster time that reduce the need for retesting, and is simple to sanitize compared with bowl-shaped subjective VF devices.

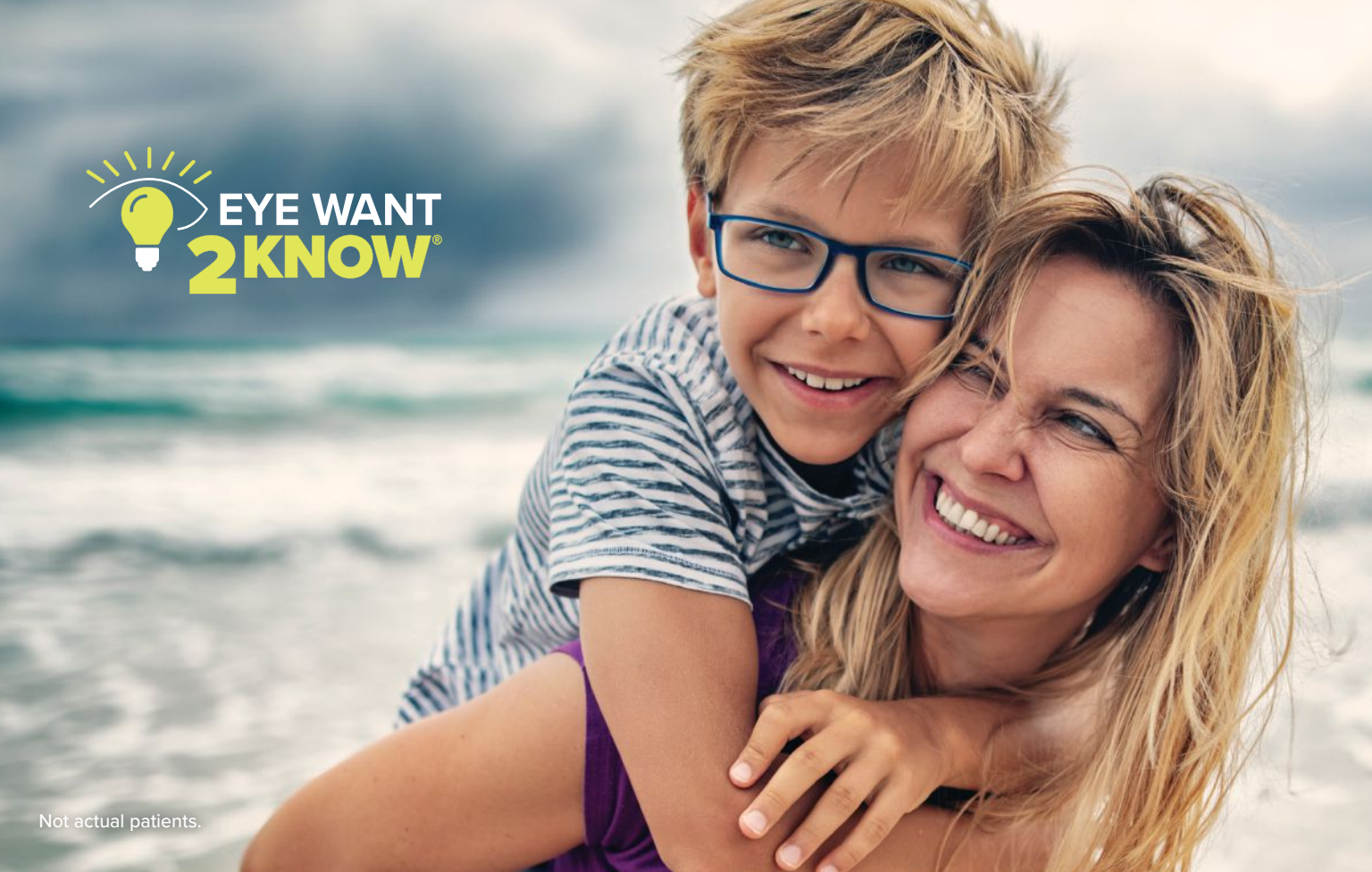24-2C, SITA Fast, SITA Faster and now VR technologies, as well as the new objective field testing, will change how we measure VFs. These systems already translate the data into clinically meaningful printouts we're familiar with. There are variances among the technologies worth exploring, but VF—one of the tests least preferred by patients—is ripe for reinvention. ■

1. Hudson C, Wild JM, O'Neill EC. Fatigue effects during a single session of automated static threshold perimetry. *Invest Ophthalmol Vis Sci.* 1994;35:268-80.

2. Barkana Y, Gerber Y, Mora R, et al. Effect of eye testing order on automated perimetry results using the Swedish Interactive Threshold Algorithm Standard 24-2. *Arch Ophthalmol.* 2006;124(6):781-784.

About
Dr. Karpecki

Dr. Karpecki is the director of Cornea and External Disease for Kentucky Eye Institute, associate professor at KYCO and medical director for Keplr Vision and the Dry Eye Institutes of Kentucky and Indiana. He is also chair of the New Technologies & Treatments conferences. He consults for a wide array of ophthalmic clients, including ones discussed in this article. Dr. Karpecki's full disclosure list can be found in the online version of this article at www.reviewofoptometry.com.



Not actual patients.

Genetic testing could change how you view their inherited retinal disease (IRD)

You may have the chance to end the diagnostic odyssey for your patients living with IRDs. Access free^a genetic testing options for eligible patients.



THE TIME TO TEST IS NOW

Visit HCP.EW2K.com/RevOpt
or scan the QR code to learn more.

^aThis initiative is open to US residents only, subject to the Terms and Conditions of the program.

Spark, Spark Therapeutics and its design, Eye Want 2 Know and its design are trademarks or registered marks of Spark Therapeutics in the United States.

© 2022 Spark Therapeutics, Inc. All rights reserved. N-EW2K-US-680006 Printed in the USA. May 2022





Post-Vacation High

Here's what you can take away from my recent trip to Italy.

Don't hate me for what I'm about to say. You've been warned. I recently returned from 13 days in Italy. I guess I'd say this spectacular trip was related to optometry since it's the reason we could afford it. But there is also a deeper message that can be taken from this trip that is pertinent to all of our practices. Do you agree that one sign I have been practicing optometry too long is that everything reminds me of something optometric? Kinda pathetic, right?

What I have learned about optometry from Italy:

1. You should never say goodbye to old stuff. I loved the churches. Some were over a thousand years old! Sometimes a direct ophthalmoscope or a PD ruler is still a good idea. Oh, and it's still okay if you spend some time just helping your patients see better like optometrists did in the good ole days.

2. Optometrists need a sense of humor. A little laugh will not make your patients think you're not serious. Italian artists have a sense of humor. One famous painting at the Uffizi portrayed Mary and Baby Jesus with the grown-up Jesus in the crowd surrounding them! It was like "Where's Waldo."

3. Take a lunch break. Food is really important. Nowadays, in the United States, it can be really expensive to eat fresh, healthy food, but in Italy it is very affordable. And we all know resveratrol is good for you, so go ahead and have that glass of wine. You'll feel better and live longer.

Okay, maybe just with dinner. Not for lunch.

4. You are certainly allowed to make your own decisions, and I would never advise anyone to take my advice on the future of healthcare, but Italians brag about socialized medicine. They say it's awesome and covers everything at no charge, assuming you forget the 70% of their income they pay in taxes. It reminds me of that old line: If you think healthcare is expensive now, just wait until it's free from the government. But they are healthier because they have to walk everywhere since gas is twice as much as it is here. And it's already through the roof here.

5. I've said this before, but look in the mirror, fellow doctors. Italians always look put together. In every little medieval city, even the city maintenance workers look like Versace. Even the town cheesemaker in Oira dresses up like he's meeting the Pope. Love it!

6. Two words: mid-day siestas. In Italy, most shop owners shut down between 1:00 and 2:30 in the afternoon. I have always believed that optometry offices should be open at noon for those dads who run over

during lunch to pick up little Suzy's contact lenses, but closing later on in the day seems okay to me. Gives us a chance to regroup, finish morning notes and, most importantly, binge *Bridgerton*.

7. Put art in your office. I saw where Andy Warhol's picture of Marilyn Monroe sold for like \$200 million. It seems wrong to me that this is about 200 times more than the real Marilyn ever earned, but I still love art. If nothing else, stick a couple of polaroids of your kid patients behind the phoropter on a bulletin board. Ask mom and dad if that's okay and have them sign a release in case Billy's mug shot is worth \$200 million one day.

8. Back to stylin'. Are you still wearing those funky glasses that you got for yourself 10 years ago? Shame on you! Italians choose their glasses as carefully as they choose their tomatoes. Your patients should never see you in the same glasses twice.

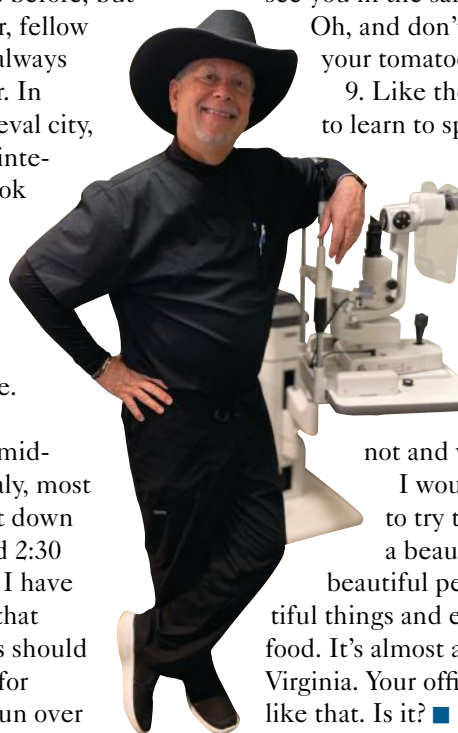
Oh, and don't forget to choose your tomatoes carefully, too.

9. Like the Italians, we need to learn to speak English. Don't

throw out big dumb words to try to impress your patients! This will never prove you are smarter than them, mainly because you are

not and will never be.

I would advise all of you to try to visit Italy. It's a beautiful place full of beautiful people doing beautiful things and eating beautiful food. It's almost as amazing as West Virginia. Your office should also be like that. Is it? ■



**About
Dr. Vickers**

Dr. Vickers received his optometry degree from the Pennsylvania College of Optometry in 1979 and was clinical director at Vision Associates in St. Albans, WV, for 36 years. He is now in private practice in Dallas, where he continues to practice full-scope optometry. He has no financial interests to disclose.

VisuALL ETS

eye tracking system



The future of eye care is comprehensive and simple, with less strain on the practice and the patients.

All diagnostic eye measurements are only a few clicks away.

That future is now.

VISUAL FIELD
+
COLOR VISION
+
VISUAL ACUITY
+
PUILOMETRY
+
EXTRAOCULAR
MOTILITY



350 Springfield Ave, Suite 200 Summit, NJ 07901
sales@olleyes.com / 1-855-OLLEYES (1-855-655-3937)
www.olleyes.com





EDITED BY PAUL C. AJAMIAN, OD

CLINICAL QUANDARIES

Two-for-one Deal

When encountering bilateral macular lesions, think about retinal dystrophies, but keep other conditions in mind.

Q I have a 51-year-old African American male who presents with symmetrical bilateral macular lesions and 20/20 acuity. What could be causing them?

A “When we see bilateral macular lesions, our first thought is congenital dystrophy or age-related macular degeneration (AMD),” says Anney Joseph, OD, of Westchester Medical Group in Rye, NY. “However, we must also rule out infection and drug toxicity.”

Differentials

Pattern dystrophies are a group of dominantly inherited macular changes at the retinal pigment epithelium (RPE) level characterized by differing patterns of pigment deposits. These dystrophies occur due to various mutations in the human retinal degeneration slow/peripherin gene.¹

Adult vitelliform macular dystrophy is an autosomal dominant disease that results in bilateral “egg-like” lesions in the macula. These lesions are made up of lipofuscin deposits in the RPE layer and usually manifest between 30 and 50 years of age. Visual potential is typically good and treatment is only warranted if choroidal neovascular membrane forms.² Fluorescein angiography (FA) shows hypofluorescence in the area of the vitelliform lesion with a ring of hyperfluorescence that intensifies

in the late phases. OCT reveals the hyperreflective accumulation below the sensory retina at the fovea and above the RPE as well as thinning of the overlying outer retinal layers.³ In late stage with progression (collapse of the vitelliform or the “scrambled egg” stage), disruption of the inner/outer segment junction layer interface and external limiting membrane will lead to visual impairment.

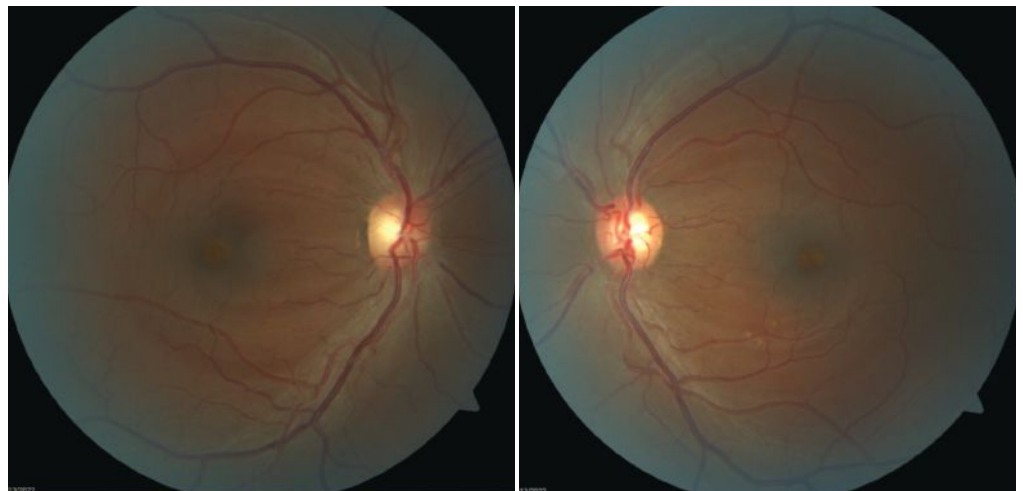
Butterfly-shaped pattern dystrophy is a rare, bilateral condition characterized by a buildup of yellow, orange or gray pigmented material in a butterfly-shaped pattern within the RPE of the macula. The butterfly shape may also be described as linear, stellate, branching or shaped like a letter. FA will help differentiate this condition from others, Dr. Joseph says.

On FA, a large hypofluorescent, butterfly-shaped macular lesion will appear. OCT will show hyper-

reflective material at the RPE level. The yellow or pigmented material is usually present in the second or third decade of life and patients are typically asymptomatic. However, the disease can progress with age, causing decreased visual acuity in a patient’s fifties and beyond.⁴

Multifocal pattern dystrophy simulating Stargardt’s disease or fundus flavimaculatus is characterized by irregular yellow-white flecks scattered throughout the posterior pole. The flecks are usually seen around the retinal vascular arcades as well as the macular area. Onset of this dystrophy is typically in the fifth decade and visual acuity is relatively good and stable. On FA, the flecks are hyperfluorescent in the early and late phase. To distinguish this from Stargardt’s, one would note the absence of the dark choroid on FA. OCT will show highly reflective focal thickening of the hyper-reflective outer red line.⁵

Fundus pulverulentus is the rarest of all the pattern dystrophies. It is characterized by coarse pigment mottling of the RPE layer in the macula. This dystrophy is commonly confused with AMD.



Bilateral macular lesions can arise from myriad conditions that an OD must rule out.

About Dr. Ajamian

Dr. Ajamian is the center director of Omni Eye Services of Atlanta. He currently serves as general chairman of the education committee for SECO International and is vice president of the Georgia State Board of Optometry. He has no financial interests to disclose.

For Chronic Eye Conditions



Think Simple

Preservative-Free Formulations*

- No Preservatives
- No Prior Authorizations
- No Coupons or Copays

Now with Simple Pricing

Any **SINGLE** Drug:

NOW only **\$19/mo**[†]

Any **COMBO** Drug:

NOW only **\$39/mo**[†]

Various options consisting of:

Brimonidine, Dorzolamide, Latanoprost, Timolol

Scan QR Code or visit:
www.SimpleDrops.com



Important: Patients may need to take more than one eye drop product pursuant to multiple dosing regimens, as directed by his or her prescriber in order for the active ingredients to remain effective throughout the day.

[†] Months supply can vary based on the dosing regimen prescribed by the doctor

*For professional use only. ImprimisRx specializes in customizing medications to meet unique patient and practitioner needs. ImprimisRx dispenses these formulations only to individually identified patients with valid prescriptions. No compounded medication is reviewed by the FDA for safety or efficacy. ImprimisRx does not compound essential copies of commercially available products. References available upon request.

Simple Drops and ImprimisRx are registered trademarks of Harrow Health Inc.
©2021 ImprimisRx. All Rights Reserved. IMPO0543 06/21

imprimis **Rx**[®]

On FA, the pigment mottling shows as hypofluorescent areas. This condition's typical onset is in the fourth to fifth decade of life and visual acuity is relatively good and stable unless choroidal neovascularization forms.⁶

Consider Degeneration

AMD typically occurs in older adults when drusen accumulate in the RPE layer. These deposits can be viewed on OCT in between the RPE and Bruch's membrane. It can be unilateral or bilateral and typically vision loss occurs in later stages (intermediate and exudative/wet).

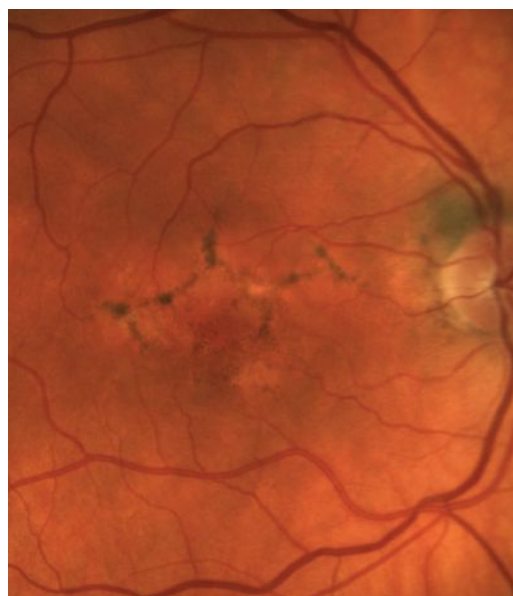
"Prophylactic treatment, including vitamins, diet and UV protection, is indicated in early and intermediate stages," Dr. Joseph says. "When choroidal neovascular membranes form, invasive treatment with intravitreal injection and/or laser is indicated." OCT has become irreplaceable in early detection of choroidal neovascular membrane and subretinal fluid in exudative, or wet, AMD. OCT can also track patients' response to treatment.

In younger patients with pigmented macular lesions, Dr. Joseph suggests considering TORCH syndrome, which refers to infection of a developing fetus or newborn by any of a group of infectious agents: toxoplasmosis, other agents (syphilis, parvovirus, varicella-zoster), rubella, cytomegalovirus or herpes virus.

"Given the patient's HIV status, cytomegalovirus is a possibility, Dr. Joseph says. "However, CD4 count is not as low as we would see with cytomegalovirus retinitis."

Beware of Medications

Dr. Joseph also takes note of the drugs the patient is currently taking. Of the listed medications, ritonavir has been reported to cause retinal toxicity. Ritonavir, an antiretroviral protease inhibitor used in the therapy and prevention of HIV and AIDS, can cause lesions in the macula,



Butterfly-shaped pattern dystrophy is characterized by a buildup of yellow, orange or gray pigmented material within the RPE of the macula.

including retinal pigment epitheliopathy, macular telangiectasis and intraretinal crystal deposits, which cause vision loss as well as visual field defects.⁷ OCT will reveal thickened and irregular RPE layer with overlying loss of inner/outer segment junction layer. Visual acuity, function and retinal layers will improve after discontinuation of the medication.⁸

When thinking of medications that can cause bilateral retinal toxicity, Dr. Joseph believes one would be remiss not to mention hydroxychloroquine and the drugs known to contribute to talc retinopathy. Hydroxychloroquine toxicity's early signs are macular edema and/or bilateral granular depigmentation of the RPE layer in the macula. With continued use, progression to an atrophic bull's-eye maculopathy with concentric rings of hypo- and hyperpigmentation surrounding the fovea is observed clinically.

With further continued medication usage, widespread atrophy, as well as retinal arteriolar attenuation and optic disc pallor, may be noted. Risk of toxicity is dependent on the daily dose and duration of use. Screening recommendations include baseline fundus exam for pre-existing maculopathy and annual screening (includ-

ing automated visual field and OCT) after five years for patients without major risk factors (high dose, long duration, concomitant renal disease or tamoxifen use).⁹

Talc is an insoluble filler material in oral medications such as methylphenidate but also seen in narcotics like heroin and cocaine. Talc retinopathy consists of refractile, irregularly shaped yellow deposits/crystals found inside small retinal vessels and within retinal layers. This retinopathy is seen in chronic intravenous drug users. OCT will show numerous highly reflective focal areas in the inner retina. Clinical findings can range from asymptomatic crystalline retinopathy to capillary nonperfusion and neovascularization.^{10,11}

When you see a bilateral symmetrical macular pattern, be aware of all of these conditions. "Many can be simply watched, but when in doubt or if you suspect progression, get a friendly second opinion," Dr. Joseph says. ■

1. Kohl S, Christ-Adler M, Apfelstedt-Sylla E, et al. RDS/peripherin gene mutations are frequent causes of central retinal dystrophies. *J Med Genet.* 1997;34(8):620-6.

2. Doan A, Stone EM. Best vitelliform macular dystrophy: 30-year-old female referred for bilateral macular lesions. *EyeRounds.* February 21, 2005. www.eyerounds.org/cases/case1.htm. Accessed May 31, 2022.

3. Benhamou N, Souied EH, Zolf R, et al. Adult-onset foveomacular vitelliform dystrophy: a study by optical coherence tomography. *Am J Ophthalmol.* 2003;135(3):362-7.

4. Deutman AF, van Blommestein JD, Henkes HE, et al. Butterfly-shaped pigment dystrophy of the fovea. *Arch Ophthalmol.* 1970;83(5):558-69.

5. Boon CJ, van Schooneveld MJ, den Hollander AI, et al. Mutations in the peripherin/RDS gene are an important cause of multifocal pattern dystrophy simulating STGD1/fundus flavimaculatus. *Br J Ophthalmol.* 2007;91(11):1504-11.

6. Parodi MB. Choroidal neovascularization in fundus pulverulentus. *Acta Ophthalmol Scand.* 2002;80(5):559-60.

7. Roe RH, Jumper JM, Gualino V, et al. Retinal pigment epitheliopathy, macular telangiectasis, and intraretinal crystal deposits in HIV-positive patients receiving ritonavir. *Retina.* 2011;31(3):559-65.

8. Tu Y, Poblete RJ, Freilich BD, et al. Retinal toxicity with Ritonavir. *Int J Ophthalmol.* 2016;9(4):640-2.

9. Marmor MF, Kellner U, Lai TY, et al.; American Academy of Ophthalmology. Recommendations on screening for chloroquine and hydroxychloroquine retinopathy. *Ophthalmology.* 2016;123(6):1386-94.

10. Shah VA, Cassell M, Poulouse A, et al. Talc retinopathy. *Ophthalmology.* 2008;115(4):755-55.e2.

11. Soliman MK, Sarwar S, Hanout M, et al. High-resolution adaptive optics findings in talc retinopathy. *Int J Retina Vitreous.* 2015;1:10.

Photo: Mohammad Rafeeqy, OD

Love at first fit 😍

Start your new wearers in a lens that can help keep up with today's digital demands^{*1-4}

Young new wearers average **9 hours** per day in front of a screen⁵⁻⁷



During that time, they **blink 60% less**^{8,9}



You know what that can mean: **more dryness**^{8,9} and more **eye fatigue**¹⁰



Start with ACUVUE® OASYS 1-Day for **superior comfort**¹¹ while using digital screens.



*The presence of PVP within the lens and on its surface results in a design with low pervaporation, which helps to enable comfort during digital device use.

References:

1. JJV Data on File 2021. ACUVUE® Brand Contact Lenses: PVP [poly(N-vinyl pyrrolidone)] and its Similarity to Mucin. 2. JJV Data on File 2018. Material Properties: ACUVUE® OASYS Brand Contact Lenses with HYDRACLEAR® PLUS, ACUVUE® OASYS with Transitions™ Light Intelligent Technology™, and Other Reusable Contact Lenses. 3. JJV Data on File 2021. Material Properties: 1-DAY ACUVUE® MOIST, 1-DAY ACUVUE® TruEye®, and ACUVUE® OASYS 1-Day with HydraLuxe® Technology Brand Contact Lenses. 4. JJV Data on File 2015. Minimal Frictional Energy/Sliding Work with ACUVUE® OASYS 1-Day with HydraLuxe® Technology Brand Contact Lenses. 5. Forbes. Americans spent on average more than 1,300 hours on social media last year [webpage], <https://www.forbes.com/sites/petersuci/2021/06/24/americans-spent-more-than-1300-hours-on-social-media/?sh=5b6fd6c72547>. Accessed November 12, 2021. 6. Forbes. Online marketing as we know it is changing with the Rise of Generation Z [webpage], <https://www.forbes.com/sites/jawertz/2018/09/30/online-marketing-as-we-know-it-is-changing-with-the-rise-of-generation-z/?sh=7ee4a14f65ab>. Accessed November 12, 2021. 7. U switch. How much of your time is screen time? [webpage], <https://www.uswitch.com/mobiles/screentime-report/>. Accessed November 12, 2021. 8. Tsubota K, Nakamori K. Dry eyes and video display terminals. N Engl J Med. 1993;328(8):584. doi: 10.1056/NEJM199302253280817. 9. Patel S, Henderson R, Bradley L, et al. Effect of visual display unit use on blink rate and tear stability. Optom Vis Sci 1991;68(11):888-892. doi:10.1097/00006324-199111000-00010. 10. JJV Data on File, 2021. ACUVUE® OASYS Brand Family Digital Device Claims (ACUVUE® OASYS 1-Day and ACUVUE® OASYS with TRANSITIONS™). 11. JJV Data on File 2021. ACUVUE OASYS Family Digital Device Claims.

Important Safety Information:

ACUVUE® Contact Lenses are indicated for vision correction. As with any contact lens, eye problems, including corneal ulcers, can develop. Some wearers may experience mild irritation, itching or discomfort. Lenses should not be prescribed if patients have any eye infection, or experience eye discomfort, excessive tearing, vision changes, redness or other eye problems. Consult the package insert for complete information. Complete information is also available from Johnson & Johnson Vision Care, Inc. by calling 1-800-843-2020, or by visiting www.jnjvisionpro.com. All third-party trademarks herein are the intellectual property of their respective owners.

©Johnson & Johnson Vision Care, Inc. 2022
Johnson & Johnson Vision Care, Inc.
7500 Centurion Pkwy N, Jacksonville, FL 32256

PP2022AO1D4099



BY BISANT A. LABIB, OD

THE ESSENTIALS

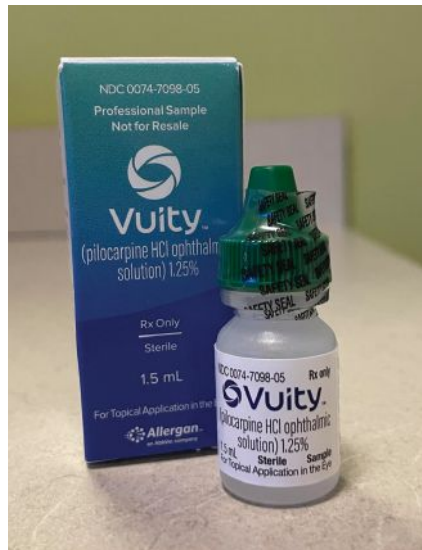Pilocarpine: New and Improved?

The drug recently re-emerged as an option for presbyopia.

A once-commonly used topical ophthalmic medication, pilocarpine has recently re-emerged and gained popularity as a novel treatment for presbyopia.^{1,2} Although this drug has been around for several decades chiefly as a glaucoma therapy, it has not been routinely prescribed in recent years. With its newly approved use, it is time to re-explore this topical agent and its many (sometimes overlooked) ophthalmic uses as well as potential adverse side effects to be on the lookout for.

Mechanism of Action

Pilocarpine is a muscarinic acetylcholine agonist. It can be administered topically or orally. In order to understand its effects, it is important to first be aware of the muscarinic receptors in the body and their mechanisms of action. There are five different types of muscarinic acetylcholine receptors: M1 through M5. The expression and actions of each vary, and pilocarpine works primarily on the M1 through M3 subtypes, eliciting parasympathetic effects. Specifically, its action on the M3 receptor is most pertinent to its ocular uses. This receptor is expressed in salivary glands and smooth muscle cells, in addition to other areas throughout the body. The parasympathetic effects it has on these areas stimulate salivary gland function, increasing salivation and smooth muscle contraction.¹



Contraction of the ciliary muscle enables Vuity's improvement of near vision acuity in patients responsive to such action.

Clinical Uses

Pilocarpine is not readily used in the clinical setting. Diagnostically, it can help with the diagnosis of Adie's tonic pupil, which is characterized by the loss of the direct and indirect pupillary light response. Additionally, there are accommodative paresis and slit lamp findings such as segmental iris palsy. Because the underlying pathophysiologic mechanism is a result of damage to the postganglionic parasympathetic nerve of the iris sphincter, which is made up of smooth muscle, pilocarpine testing can help elicit the diagnosis.

Administration of either 0.125% or 0.062% pilocarpine in the affected

eye, in dim lighting, can help assess cholinergic supersensitivity.³ This action substantiates the amount of acetylcholine, resulting in constriction of the pupil by stimulating the sphincter. It also affects accommodation due to its action on the ciliary muscle.⁴

Other Considerations

Although it is no longer first-line, pilocarpine has long been used in the management of elevated intraocular pressure (IOP) in glaucoma. Its action on the smooth muscle stimulates the iris sphincter and results in the iris pulling away from the trabecular meshwork and aqueous outflow, increasing the eye's ability to lower IOP.^{5,6} As such, pilocarpine is a known treatment for glaucoma secondary to acute angle closure from mydriasis or pupil block.

A necessary consequence of this mechanism of action is pupillary miosis.⁵ While pilocarpine treatment normally increases the width of the angle due to reduced iris thickness, it can cause acute angle closure in rare cases. For example, a patient with spherophakia who has a highly convex lens and weak zonules will have anterior displacement of the iris-lens diaphragm into the anterior chamber. Other risks include patients with pseudoexfoliation syndrome, phacomorphic glaucoma and malignant glaucoma.^{5,6}

Studies also indicate that oral administration of a pilocarpine 20mg daily dose can serve as treatment for Sjögren's-related dry eye. Because of its parasympathetic activity, it can increase lacrimation and has been shown to improve both dry eye symptoms and tear film quality. One study showed improvement in Schirmer's testing, ocular surface disease index

About
Dr. Labib

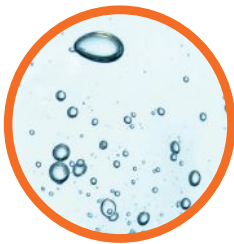
Dr. Labib graduated from Pennsylvania College of Optometry, where she now works as an associate professor. She completed her residency in primary care/ocular disease and is a fellow of the American Academy of Optometry and a diplomate in the Comprehensive Eye Care section. She has no financial interests to disclose.

NEW



HELP YOUR PATIENTS GO FROM
DRY EYES
TO EXTRA LONG-LASTING
HYDRATION¹⁻⁸

Introducing blink® triple care — the first and only over-the-counter eye drop with both hyaluronate and a nano-emulsion lipid within the unique formula.⁹⁻¹⁰ Here's how our **DUAL ACTION MOISTURE SEAL TECHNOLOGY**⁵⁻⁸ works:



HYALURONIC ACID
binds moisture and helps
boost hydration³⁻⁵



LIPID NANO EMULSION
helps protect against tear
evaporation¹¹ to lock in moisture⁵⁻⁸

The result is **3-in-1 Extended Relief**¹⁻⁸ for both Aqueous-Deficient and Evaporative Dry Eyes¹²:



Instantly Soothes¹⁻⁸



Extra Long-Lasting Hydration¹⁻⁸



Locks in Moisture⁵⁻⁸

References: 1. Wasmanski AD and Kislán T. Cross-Over Evaluation of Polyethylene Glycol 400 (PEG-400) 0.4% and 0.25% Artificial Tears in Mild Dry Eye Patients. Invest. Ophthalmol. Vis. Sci. 2010;51(13):6263. 2. Montani G. Intrasubject Tear Osmolarity Changes with Two Different Types of Eye Drops. Optom. Vis. Sci. 2013;90(4): 372-377. doi: 10.1097/OPX.0b013e318288bbde 3. Laurent TC. Structure of Hyaluronic Acid. In: EA Balazs (Ed.), Chemistry and Molecular Biology of Intracellular Matrix. Academic Press, London. 1970:703-732. 4. Aragona P, Papa V, Micali A, et al. Long Term Treatment with Sodium Hyaluronate-Containing Artificial Tears Reduces Ocular Surface Damage in Patients with Dry Eye. Br. J. Ophthalmol. 2002;86(2):181-184. doi: 10.1136/bjo.86.2.181. 5. Prabhasawat P, Tesavibul N, Kasetsuwan K. Performance Profile of Sodium Hyaluronate in Patients with Lipid Tear Deficiency: Randomised, Double-Blind, Controlled, Exploratory Study. Br. J. Ophthalmol. 2007;91(1):47-50. doi: 10.1136/bjo.2006.097691. 6. Zheng X, Goto T, Shiraishi A, et al. In vitro efficacy of ocular surface lubricants against dehydration. Invest. Ophthalmol. Vis. Sci. 2013;32(9):1260-1264. doi: 10.1097/j.ico.0b013e31829cfd44. 7. Maissa C, Guillon M, Simmons P, et al. Effect of castor oil emulsion eyedrops on tear film composition and stability. Contact Lens Anterior Eye. 2010;33(2):76-82. doi: 10.1016/j.clae.2009.10.005. 8. Craig JP, Nichols KK, Akpek EK, et al. TFOS DEWS II Definition and Classification Report. The Ocular Surface. 2017;15(3):276-283. 9. US Dry Eye OTC Product Comparison. 10. IRI US 2020 Dry Eye Share Competitive Report. 11. JJV Data on File 2020. Blink Triple Care Lubricating Eye Drops - Consolidated, Approved Claims List. 12. 2012. Lemp, Miachael A. Distribution of Aqueous-Deficient and Evaporative Dry Eye in a Clinic-Based Patient Cohort: A Retrospective Study

Important Safety Information: Blink® Tears, Blink GelTears® and Blink® Triple Care drops are for the temporary relief of burning, irritation and discomfort due to dryness of the eye or exposure to wind or sun, and may be used as a protectant against further irritation. Patients should stop use and contact their eye care practitioner if they experience eye pain, changes in vision, continued redness or irritation of the eye, or if the condition worsens or persists for more than 72 hours.

© Johnson & Johnson Surgical Vision, Inc. 2022. PP2022CN4045

Table 1. Pilocarpine Mechanisms and Ocular Effects

Mechanism	Action	Uses/Adverse Effects
Increased parasympathetic or cholinergic activity	Constriction of the dilated eye	Adie's tonic pupil diagnosis
Contraction of smooth iris muscle	Miosis	Intraocular surgery prep, acute angle-closure glaucoma treatment/anterior chamber flare
Contraction of smooth muscle of the ciliary body	Increased accommodation	Presbyopia treatment
Anterior displacement of iris-lens diaphragm	Decreased space in the anterior chamber	Angle-closure glaucoma in susceptible patients
Action on meibomian gland epithelial cells (topical)	Changes in morphology and survival of cells	Meibomian gland dysfunction and dry eye disease treatment/exacerbation
Increased parasympathetic activity (systemic/oral)	Lacrimation and salivation	Xerostomia and Sjögren's syndrome treatment

and tear breakup time. It was also shown to be well-tolerated, with the most common side effects being sweating and increased salivation.⁷ Due to pilocarpine's effect on salivation, it is also approved orally for the treatment of xerostomia (dry mouth) resulting from radiation exposure.¹

On the other hand, topical administration of pilocarpine has been shown to affect the morphology and survival of meibomian gland epithelial cells. Meibomian glands are imperative in tear film stability and prevention of tear film evaporation. Topical pilocarpine has been speculated to act on the meibomian gland receptors and deter their function, exacerbating dry eye and having the opposite effect of what is seen with oral treatment.⁸

Emergent Treatment

Vuity (pilocarpine 1.25%, Allergan) was approved in late 2021 as a treatment for adults with presbyopia. It is the first of its kind and gives patients an option for a non-surgical management strategy for visual correction.⁹ Treatment outcomes can be explained by pilocarpine's parasympathetic activity on the ciliary muscle. By causing contraction of this muscle, the lens increases in thickness and depth of focus, allowing for clear near vision in affected patients with

presbyopia. Since the lens does not readily change its shape, one study suggested the addition of topical nonsteroidal anti-inflammatory drugs to decrease the intensity of the pupil and ciliary muscle contraction. This allows the lens to more easily change its shape and position, allowing for clear vision at distance as well.²

Side Effects

In addition to the aforementioned effects, pilocarpine also has a unique side effect when administered topically: it induces the presence of flare in the anterior chamber. Flare is characterized by an increase in protein content and can affect vision due to light scattering. This phenomenon is commonly documented and termed "miotic iridocyclitis." The precise mechanism is not fully understood but presumed to arise from a breakdown in the blood-aqueous barrier. Furthermore, studies have concluded that there is a reservoir of plasma-derived proteins in the iris stroma that originate from the fenestrated blood vessels of the ciliary body. As such, it is speculated that thinning of the iris in miosis causes these proteins to permeate through the anterior chamber and appear as flare.¹⁰

Additional side effects, particularly with oral administration of pilocar-

pine, include those that pertain to an increase in parasympathetic activity. Since pilocarpine acts on muscarinic receptors, which are located throughout the body, systemic side effects are not uncommon. These include vasodilation, sweating, diaphoresis, increased salivation, vomiting, bradycardia, bronchospasm and increased urination and diarrhea. As such, contraindications for treatment are chronic obstructive pulmonary disease, peptic ulcer disease, arrhythmia, coronary vascular disease, hyperthyroidism and urinary obstruction, to name a few.¹

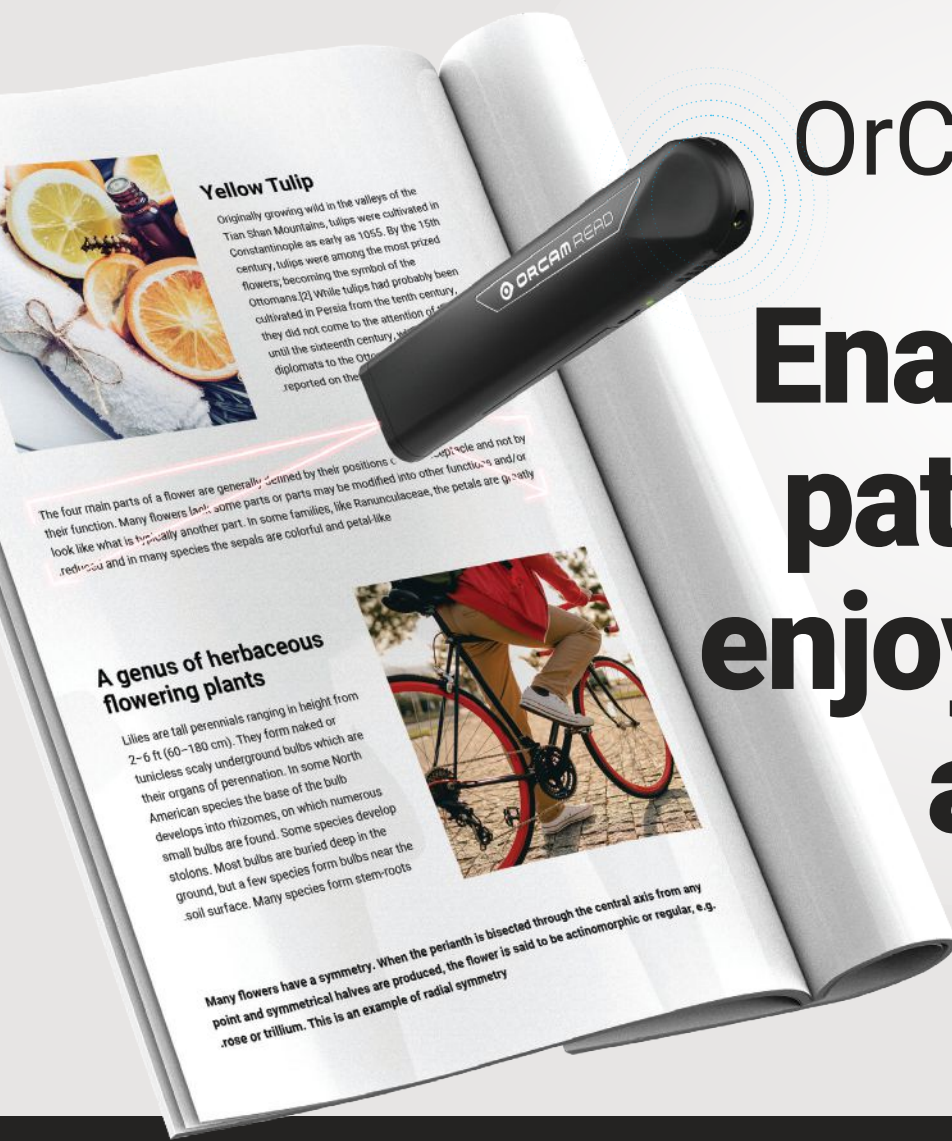Takeaways

Although pilocarpine has been around for a very long time, it previously had limited ocular uses. However, the drug's recent re-emergence has earned increasing attention for its treatment of adults with presbyopia. Given this new use, it is important to revisit and understand the mechanisms and many effects of the drug. ■

- Panarese V, Moshirfar M. Pilocarpine. In: StatPearls [Internet]. Treasure Island (FL): StatPearls Publishing; 2022.
- Benozzi G, Perez C, Leiro J, et al. Presbyopia treatment with eye drops: an eight year retrospective study. *Transl Vis Sci Technol.* 2020;9(7):25.
- Yoo YJ, Hwang JM, Yang HK. Dilute pilocarpine test for diagnosis of Adie's tonic pupil. *Sci Rep.* 2021;11(1):10089.
- Senthilkumar S, Balamurugan N, Menezes RG, Thirumalaikolundusubramanian P. Bedside test for anisocoria: not a small matter. *Indian J Crit Care Med.* 2014;18(7):480-1.
- Yang MC, Lin KY. Drug-induced acute angle-closure glaucoma: a review. *J Curr Glaucoma Pract.* 2019;13(3):104-9.
- Day AC, Nolan W, Malik AN, et al. Pilocarpine induced acute angle closure. *BMJ Case Rep.* 2012;2012:bcr0120125694.
- Felberg S, Dantas PEC, Sato EH. Oral pilocarpine for the treatment of dry eye in patients with Sjögren's syndrome. *Arq Bras Oftalmol.* 2021:S0004-27492021005009201.
- Zhang Y, Kam WR, Liu Y, et al. Influence of pilocarpine and timolol on human meibomian gland epithelial cells. *Cornea.* 2017;36(6):719-24.
- Jackson MA, Giyanani J, Shabaik Y, et al. In vitro and in-eye comparison of commercial pilocarpine ophthalmic solution and an optimized, reformulated pilocarpine for presbyopia treatment. *Ophthalmol Ther.* 2022;11(2):869-79.
- Freddo TF, Neville N, Gong H. Pilocarpine-induced flare is physiological rather than pathological. *Exp Eye Res.* 2013;107:37-43.

OrCam Read

Enable your patients to enjoy reading again



Full Page Capture

Unlike all other devices which require word-by-word scanning.



Smart Reading

Ask the device to read only the text that interests you.



Easy to Use

An intuitive device - simply point and click to start reading.

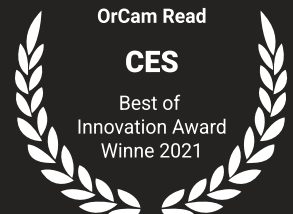
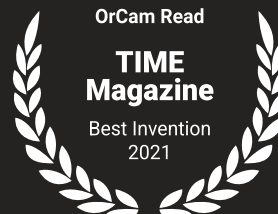
No Connectivity Required

Offline operation - for use anywhere.



Contact for more information or a demonstration:
eyedoc@orcaml.com



VITAL DYES FOR DRY EYES

We break down the several staining patterns associated with various ocular conditions and how to interpret each one.

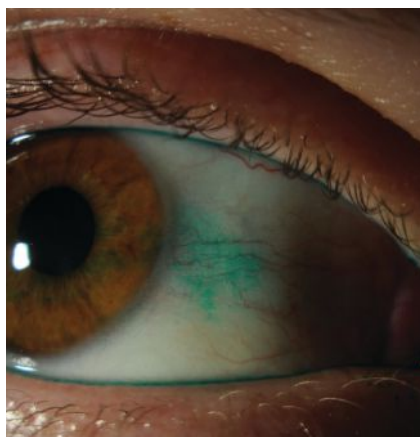

BY REBECCA ROJAS, OD
NEW YORK, NY

Corneal vital dyes have existed in eye care since the 1880s and their use has provided us with essential information on the health of the ocular surface to help aid diagnosis and treatment. Furthermore, new drug approvals from the FDA rely on changes in ocular surface noted by corneal staining to determine side effects and endpoints of clinical trials.¹

Vital dyes penetrate living cells or tissues without damaging them, making them diagnostically very useful. The three dyes typically used in eye care are sodium (NaFl) fluorescein, lissamine green and rose bengal, with fluorescein being the most common.²

Sodium fluorescein is an orange, water-soluble dye that penetrates damaged corneal epithelial cells. It was first used by Pflüger in 1882 when he detected positive staining on the cornea signifying breaks in the epi-



Slit lamp photo depicting lissamine green staining on conjunctiva from dry eye.

thelium.^{3,4} It was then used to monitor abrasions and give insight into how the cornea heals.^{5,6} Since then, the use of sodium fluorescein has expanded and is now implemented as a standard in ophthalmic practice. It is used to detect and diagnose ocular conditions associated with epithelial defects, Seidel sign, Jones Dye Test nasolacrimal duct obstruction and others. It's also used when performing applan-

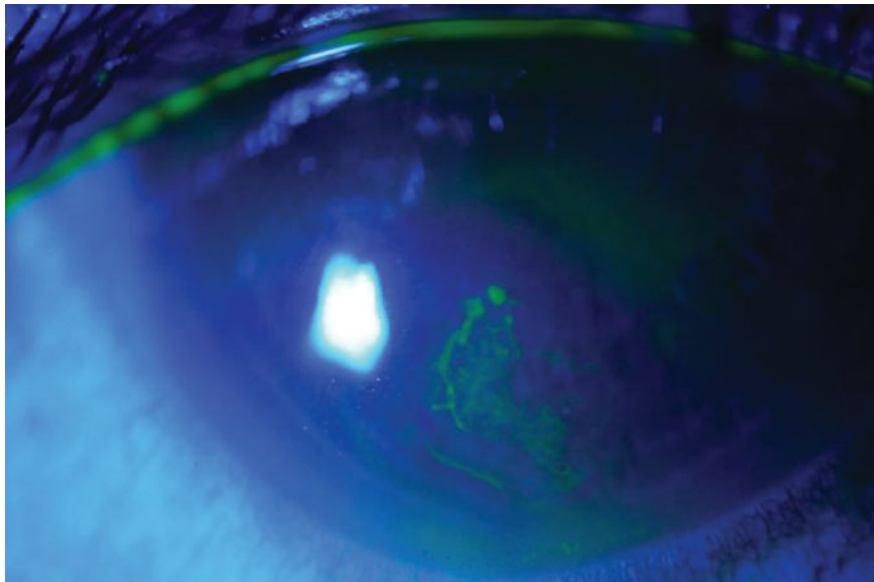
tion tonometry, evaluating tear meniscus height and fitting contact lenses fits. An intravenous form is administered when performing fluorescein angiography. A Wratten filter should be used to highlight staining when using the cobalt blue excitation filters, as it eliminates the reflected blue light.

Lissamine green is a water-soluble dye and an ideal stain for the bulbar conjunctiva, since it provides better contrast than NaFl. It stains degenerative cells where there is a disruption or damage of mucin coating.¹ Since the dye diffuses into cells that are already dead and degenerative, it is not as toxic to the cornea as rose bengal and produces less irritation upon instillation.

Rose bengal is used less in practice due to its stinging and toxic effect; like lissamine green, it stains dead and devitalized cells.^{7,8} It has been argued that rose bengal is not actually a vital dye as it also stains healthy cells and affects their viability.⁹ Therefore, if herpes simplex virus (HSV) is suspected, make sure to culture

About the author

Dr. Rojas is an instructor in optometric science (in Ophthalmology) at Columbia University Medical Center. She received her undergraduate degree from the University of Central Florida and graduated from Nova Southeastern College of Optometry. She completed her optometric residency in ocular disease at SUNY College of Optometry. She specializes in medically necessary contact lens fittings and dry eye, and comanages refractive, corneal and ocular disease. She has no financial disclosures.



A patient with recurrent corneal erosion.

prior to staining with rose bengal, as it kills the virus.¹⁰ Both lissamine green and rose bengal are better choices for assessing conjunctival staining than NaFl because it provides better contrast against the palpebral and bulbar conjunctiva.¹¹

There have been studies where a mixture of dyes was formulated to simultaneously evaluate the cornea and conjunctiva with one drop, but no formulations are pre-mixed for purchase in general practice. The optimal concentration and mixture was either 2% or 1% fluorescein and 1% lissamine, which provided sufficient staining with the least discomfort and irritation to patients.^{12,13}

Any of the three dyes discussed can be used in practice to determine the integrity of the health of the eye, but to understand the pathophysiology of the staining patterns, it is important to review the anatomy of the cornea and conjunctiva.

Cornea and Conjunctiva

The corneal epithelium is made up of non-keratinized stratified squamous epithelium, which spans across a smooth surface of five to seven layers and is about 50µm thick.¹⁴ The epithelial layers are composed of three types of cells: superficial, wing and basal cells.¹⁵ These cells are held

together by desmosomes, which form tight junctions, and hemidesmosomes, which anchor the basal cells to the basement membrane. The epithelium is covered by the tear film, which is comprised of lipid, aqueous and mucin.¹⁶ The mucin layer is responsible for surface wetting, prevention of debris adhering to ocular surface and tear spreading.¹⁷

A disturbance to any area of the epithelial layers or tear layers will result in staining patterns to be evaluated and help aid in diagnosis.

The conjunctiva covers the “non-cornea” portion of the external globe and is made up of non-keratinized stratified squamous and columnar cells, which are arranged in three-to-five cell layers.¹⁸ Goblet cells interspersed in between the cells produce

mucin to form part of the tear film. The conjunctiva is divided into the palpebral and bulbar regions and the fornices; it provides protection by acting as a physical barrier from foreign objects and microorganisms along with maintaining a stable tear film. Just like in the cornea, any uptake of vital staining is due to damage to the conjunctival epithelium. In healthy tissue, it is common to see the dyes accumulate in the conjunctival folds and this should be differentiated from punctate bulbar staining and mucin flecks.¹⁹

Staining Patterns

These can be present in various forms. The most common type is superficial punctate staining, which manifests as patterns of small dots or flecks that stain brightly with fluorescein in either a diffuse pattern or segregated patches on certain areas.²⁰ These flecks and small stains are termed *punctate epithelial erosions* when focal defects are noted, or *superficial punctate keratitis* when focal areas of inflammation are involved. The depth, location and intensity of staining patterns are also noted to determine proper diagnosis.

There have been several studies and scales produced to grade density and severity of staining, as assessment can vary per clinician and differ based on amount of dye used and timing of observation.¹ Diffuse patterns of punctate staining are mostly associated with medicamentosa or viral conjunctivitis, while specific areas such as the

Table 1. Common Staining Patterns

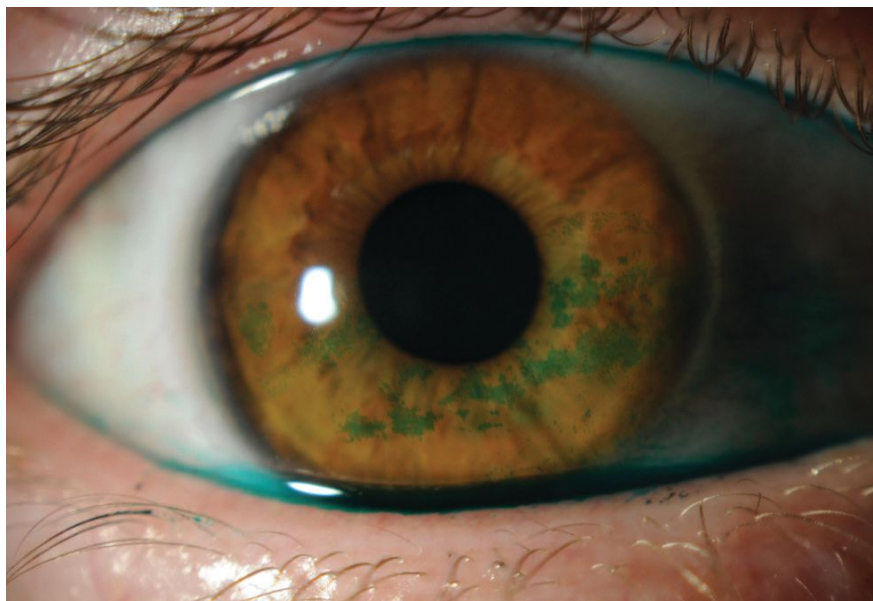
Superior	Interpalpebral	Inferior	Diffuse
<ul style="list-style-type: none"> - Superior limbal keratoconjunctivitis - Foreign body under upper lid - Atopic and vernal keratoconjunctivitis - Floppy eyelid - Conjunctival concretions - Superior entropion - Trichiasis 	<ul style="list-style-type: none"> - Exposure keratopathy - UV keratopathy - Aqueous-deficient dry eye - Medicamentosa (diffuse) 	<ul style="list-style-type: none"> - Blepharitis - MGD - Lagophthalmos - Ectropion - Inferior entropion - Mucus fishing syndrome - Conjunctivochalasis 	<ul style="list-style-type: none"> - Medicamentosa - Toxicity - Viral conjunctivitis - Bacterial

classic “three and nine o’clock” pattern are related to contact lens wear, causing desiccation of the peripheral cornea in areas where lids are not in direct contact with the epithelium because of the lens edge.

Not only is the location of the staining important, but so is the type of staining pattern—pooling of dye or negative staining. Negative staining represents non-stained areas where the stain has run off elevated areas of cornea, which is prominent in cases of Salzmann’s nodular degeneration and epithelial basement dystrophy.

Positive staining occurs when fluorescein penetrates disruptions in the intercellular junctions of the corneal epithelial cells, causing areas of defined hyperfluoresced dots (punctate staining) that may coalesce from micro-punctate to macro-punctate or patchy patterns.²¹ Positive stains on the cornea are also associated with dendritic lesions as the HSV virus begins to spread to epithelial cells, causing disruption and cell lysis. In active HSV infections, the bed of the ulcerative lesion stains with fluorescein while the edges of the ulcer stain with rose bengal, so a combination of drops is useful. Positive NaFl staining is also noted in areas with complete full-thickness epithelial defects, such as ulcers or abrasions, as evidenced by diffusion of the dye into the stroma.

Pooling of dye is seen secondary to areas of corneal thinning or indentations on cornea. Some examples include pterygia, dellen and blebs. This “spillover” effect is different from actual staining and more like the effect of negative staining but over a larger area. Remember that sodium fluorescein does not penetrate where cells are intact and healthy, so the stain is filling the depressed area. Another example is called “dimple veiling,” which can be found in rigid gas permeable lens wearers with steep central clearance and a flatter peripheral curve profile, allowing small bubbles to enter and become trapped during lens wear, causing indentions and divots in the epithelium.



Slit lamp photo depicting lissamine green staining on cornea.

Cornea and Conjunctival Staining

Here are some instances of frequent patterns of corneal and conjunctival staining encountered in routine practice. Superficial superior corneal staining can range from anything that is contact lens-related to superior limbic keratopathy.²² It is typically not associated with dry eye, as the upper lid protects the superior ocular surface.

- **Superior limbic keratoconjunctivitis (SLK)** presents with staining and localized conjunctivochalasis produced by mechanical friction from the upper palpebral conjunctiva and superior cornea. Its presence can be associated with thyroid eye disease or possibly caused by contact lens wear.²²

In thyroid eye disease, there is an association with lid retraction, known as Dalrymple’s sign, which in turn produces pressure from the upper lid, causing defective blinking and mechanical disruption to the bulbar conjunctiva. As mechanical disruption occurs, it causes tiny breaks in the cornea epithelium, resulting in small abrasions that uptake the stain.²² Therefore, on clinical examination, you may find injection on the superior bulbar conjunctiva and fine punctate staining along the superior limbus with associated filaments and neovascularization.

Corneal filaments are not only associated with SLK but also with other ocular conditions ranging from dry eye to neurotrophic keratopathy and can stain with any of the three vital dyes mentioned. They are composed of a mucin plaque covered with sloughed-off degenerative epithelial cells, lipids and protein material coalescing to create an elevated plaque.²³ These can vary in size and presentation depending on the etiology. Plaques can be thin and hair-like, as seen in filamentary keratitis, or uniquely shaped as dendriform plaques, as found in herpes zoster. The base of the plaques can either be attached to the corneal epithelium or conjunctival fornix.

- **Floppy eyelid syndrome** is another cause of superiorly located mechanical trauma due to the laxity of the lid. The laxity is caused by loss of rigidity of the tarsal plate due to depleted levels of elastin. It is more common on the side the patient sleeps on and can include trichiasis in severe cases. This presents superficial punctate staining along with conjunctival irritation as the chronic everted eyelid or misdirected lashes rub along the cornea.²⁴ This is a common finding in patients with keratoconus, conjunctivitis, blepharitis and obstructive sleep apnea.

THE LATEST CUSTOM SOFT LENS FAMILY FROM **BAUSCH+LOMB**



Let your custom soft potential
FLOURISH

with REVIVE™—a custom soft lens family
designed to help you meet the needs of more patients.

SPHERE

Powers:
+/-30.00D in 0.25D steps

TORIC

Cylinder: -0.50D to
-10.00D in 0.25D steps

AXIS: 1° to 180°
in 1° steps

MULTIFOCAL

ADD powers
up to +3.00D

**MULTIFOCAL
TORIC**

**Customizable
Central Near-Zone**
Size: 2.4 mm standard

SCAN TO UNCOVER THE POSSIBILITIES OF REVIVE™

Visit bauschsvp.com for Important Safety Information.

Revive is a trademark of Bausch & Lomb Incorporated or its affiliates.
©2022 Bausch & Lomb Incorporated or its affiliates. MTB.0086.USA.22



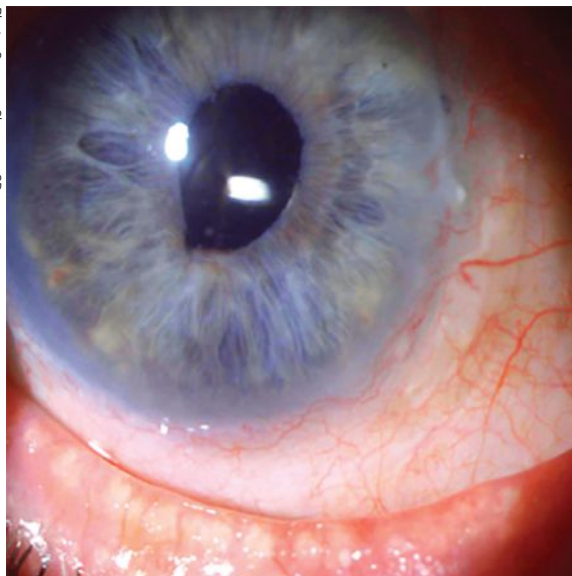
- A **foreign body** under the superior lid produces linear scratches or irritation on the cornea or conjunctiva indicating breakdown of any of the three layers of the corneal epithelium and produces repeated abrasions with each blink. When any positive staining is present in a linear or curvilinear pattern, the upper lid should be everted and evaluated for any foreign bodies or misdirected lashes.

- **Limbal stem cell deficiency (LSCD)** results from damage or dysfunction to the limbal stem cells, whose main function is to maintain the transparency and health of the cornea.²⁵ When there is disruption to the limbal stem cells, the conjunctival epithelium encroaches on the cornea, resulting in conjunctivalization.^{26,27} Fluorescein staining presents a stippled, opaque, whorl-like pattern with some cases portraying a demarcation line between the conjunctival and corneal cells.²⁶ In the initial stages, the limbus and periphery will stain more and then progress to a more diffuse, central pattern as the severity of the disease progresses.^{28,29} Associations with LSCD can range from genetic conditions causing limbal stem cell dysfunction to external factors such as chronic inflammation, trauma secondary to chemical burns or surgeries or poorly fitted contact lenses.^{30,31}

- **Aqueous-deficient dry eye** is most associated with interpalpebral staining and typically starts with conjunctival staining on the nasal and temporal areas, which is seen more prominently with lissamine green.³¹ In aqueous-deficient dry eye, there is an increase in mucin production by the goblet cells, which combines with epithelial and other debris to form filamentary plaques that will stain with rose bengal or lissamine green.

- **Exposure keratopathy** can occur for a variety of reasons and presents with both interpalpebral punctate staining or inferior staining, depending on the cause. Interpalpebral staining is encountered with aqueous deficiency,

Photo: Suzanne Sherman, OD



A patient with limbal stem cell deficiency.

exposure and neurotrophic keratopathy, as there is less protection from the lids. Most interpalpebral presentations are associated with UV or chemical exposure from smoke, fumes or sunlamps from the lack of lid protection.³²

Exposure keratopathy secondary to lid abnormalities or incomplete lid closure can be associated with Bell's palsy, thyroid eye disease—which includes both Stellwag's sign (incomplete or infrequent blinking) and Dalrymple's sign (widened palpebral fissure)—or floppy eyelid syndrome.³³ When the tear film is disrupted, the epithelial cells are more prone to damage and suffer erosions, which will stain with sodium fluorescein in the exposed areas.

- **Neurotrophic keratopathy** occurs because of damage to the trigeminal nerve, causing loss of corneal sensitivity. The patient will not have complaints of irritation to match the degree of the corneal erosions noted.

The most common etiologies associated with neurotrophic keratopathy are varicella-zoster virus or HSV but the condition can also follow ocular surgery or trauma, diabetic neuropathy, topical medication use (*e.g.*, NSAIDs, anesthetic abuse), chronic contact lens use and extensive photocoagulation. The cornea is highly innervated from the long posterior ciliary nerves

and most fibers emerge from the ophthalmic branch of the trigeminal nerve. Nerves release neuromediators that protect the cornea by providing reflex blinking and nutrition. The denervation of the cornea causes dysfunction and damage in the epithelial layer because of decreased metabolism and proliferation of epithelial cells.³⁴

- **Thygeson's superficial punctate keratitis** produces small, elevated clusters of superficial and intra-epithelial corneal lesions. Lesions are centrally located and have a duller, less organized appearance than staining associated with dry eye. Lesions have an ovoid, gray-white appearance

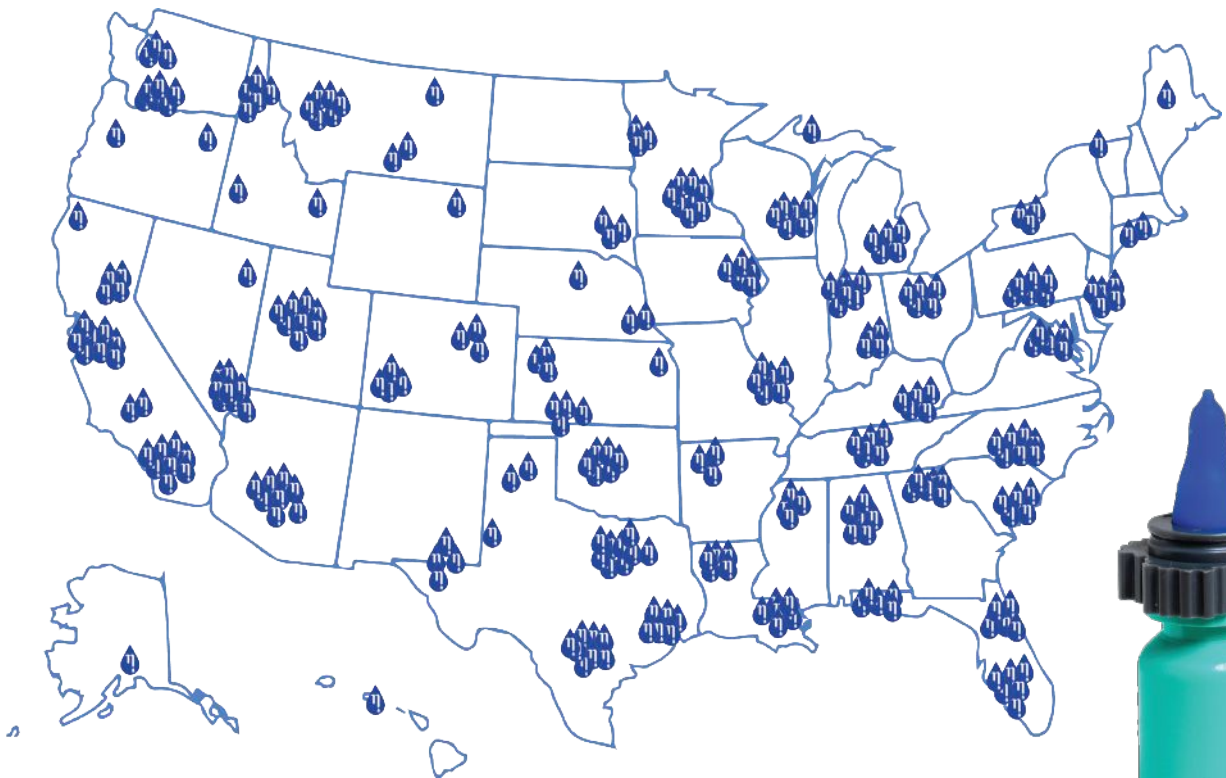and can produce areas of negative staining with minimal to no conjunctival staining. The pathophysiology is still unknown but it is hypothesized to have a viral or immunologic mechanism without inflammatory correlations. Patients may be asymptomatic or have similar complaints to that of dry eye, including foreign body sensation, tearing or photophobia.

Inferior staining patterns are most associated with blepharitis, meibomian gland dysfunction, lid abnormalities and mechanical causes.²² Inferior staining should prompt you to evaluate the lid margin for blepharitis and meibomian gland dysfunction. A linear pattern of conjunctival and corneal staining is usually associated with blepharitis, as there is staphylococcal bacteria floating in the stagnant tear lake in the inferior conjunctival margin and irritating the cornea.

- **Conjunctivochalasis** is redundant conjunctival folds that are exposed and dry and irritated. The most common cause is age-related and hypothesized to be the degradation of elastic fibers and collagen from age, mechanical factors and inflammation.^{35,36} There will be positive rose bengal staining on the inferior lid margin and inferior conjunctival folds, as the upper eyelids are not completely closing due to the extra conjunctival tissue and inability

NANO DROPPER

Don't let your clinic and patients get left behind.



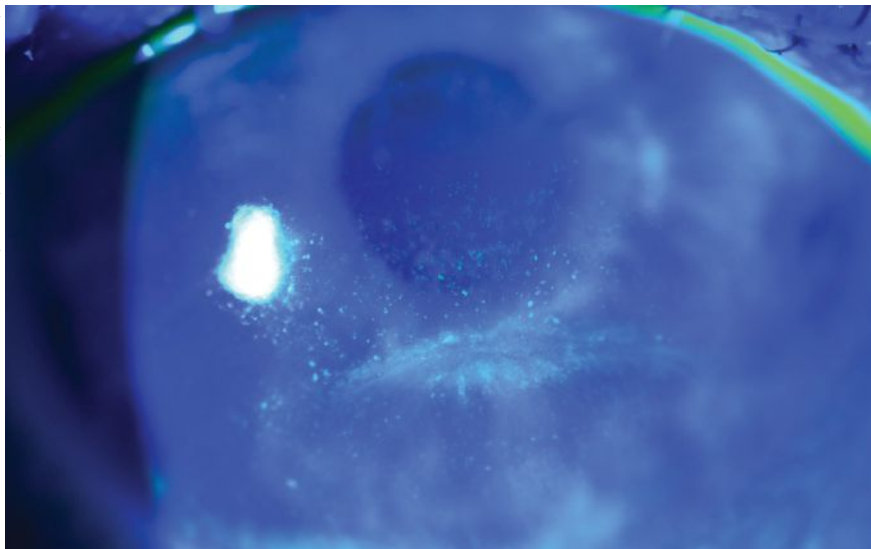
Since our launch in June 2020, amidst a global pandemic, we have incorporated **hundreds of clinics** around the country into our partner clinic network. Each clinic has elevated the standard of care for their patients. **Are you ready to join in?**

**Use discount code
REVIEWOPTO10 for 10% off
your first order!**

The Nanodropper is the only FDA-listed, volume-reducing adaptor for eyedrop bottles designed to deliver precisely the amount of fluid the eye can absorb. Smaller drops reduce the waste and cost of in-clinic and Rx formulations while minimizing local and systemic side effects.

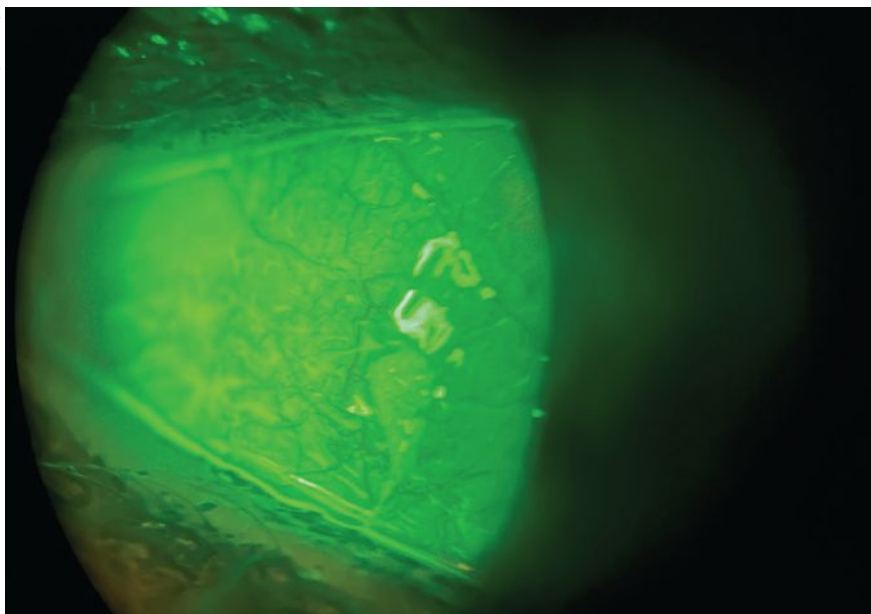
www.nanodropper.com | support@nanodropper.com | (507) 405-5676

Photo: Wrt Blue, ophthalmic photographer



This patient with lagophthalmos from facial nerve paralysis has interpalpebral corneal staining.

Photo: Million Horn, OD



Fluorescein staining seen in dry eye.

to evenly spread tear film.³⁷ The folds can also cause mechanical disruption and block the punctum, leading to stagnant tear film with inflammatory cytokines, which in turn can cause ocular surface inflammation and linear staining on the mucosal area of the lid margin.³⁸ This is seen mostly on the inferior temporal bulbar conjunctiva, with breaks in the tear meniscus with staining as the tear film is destabilized by redundant folds.

Mechanical factors can also be associated with inferior staining patterns,

particularly in cases of mucus fishing syndrome. In such patients, there will be prominent lissamine green uptake in the inferior bulbar conjunctival and nasal fornices due to constant mechanical irritation from the eye. This usually stems from foreign body sensation associated with dry eye, causing eye rubbing and removal of mucus strands formed from epithelial injury. The activity typically continues in an ongoing cycle with more mucin being produced as the patient “fishes out” the mucus strands.

• **Lid wiper epitheliopathy** presents with staining on the superior and inferior lid margins.³⁹ The Marx line is a clear boundary that runs along the inner surfaces of the superior and inferior eyelid margin at the mucocutaneous junction.⁴⁰ This line connects the area where meibomian glands secrete lipids and the aqueous tear fluid.⁴⁰ Positive lissamine staining highlights its positioning and irregularity, which can be an indication of gland dysfunction. The position can shift outside the lid margin area decreasing the friction as the lids become more lax with aging or can be more intense due to added friction on lids from contact lenses.⁴¹

Lid wiper epitheliopathy is caused by damage to the epithelial cells in the Marx line region associated with frictional forces of each blink and tear film instability.⁴² This is an additional area to focus on that will give insight on patients complaining of dry eye symptoms with no other clinical signs prior to seeing corneal staining.

Takeaways

Dry eye is one of the most common diagnoses encountered in routine exams and understanding the pathophysiology of vital dyes and their staining patterns will result in appropriate management and patient education. It’s important to note that staining patterns not only provide insight, but also can be associated with a combination of causes (*e.g.*, atopic keratoconjunctivitis and mucus fishing syndrome).

The health of the ocular surface is vital for clear vision, so when a patient has symptoms and no other obvious cause, reaching for vital dyes and exploring the patterns noted on the conjunctiva and cornea is an important tool to get to the result and find the most suitable treatment plan. ■

1. Begley C, Caffery B, Chalmers R, et al. Review and analysis of grading scales for ocular surface staining. *The Ocular Surface*. 2019;17(2):208-20.
2. Wu Y, Wang C, Wang X, et al. Advances in dry eye disease examination techniques. *Front Med*. 2021;8:826530.
3. Morgan P, Maldonado-Codina C. Corneal staining: Do we really understand what we are seeing? *Cont Lens Anterior Eye*. 2009;32(2):48-54.
4. Eliason JA, Maurice DM. Staining of the conjunctiva and conjunctival tear film. *Brit Jour Ophthal*. 1990;74:519-22.

5. Ward KW. Superficial punctate fluorescein staining of the ocular surface. *Optom Vis Sci.* 2008;85(1):8-16.

6. Romanchuk KG. Fluorescein. Physicochemical factors affecting its fluorescence. *Surv Ophthalmol.* 1982;26:269-83.

7. Kim J, Foulks GN. Evaluation of the effect of lissamine green and rose bengal on human corneal epithelial cells. *Cornea.* 1999;18(3):328-32.

8. Efron N. Putting vital stains in context. *Clinical and Experimental Optometry.* 2012;96(4):400-21.

9. Seitzman GD, Cevallos V, Margolis TP. Rose bengal and lissamine green inhibit detection of herpes simplex virus by PCR. *Am J Ophthalmol.* 2006 Apr;141(4):756-8.

10. Stroop WG, Chen TM, Chodosh J, et al. PCR assessment of HSV-1 corneal infection in animals treated with rose bengal and lissamine green B. *Invest Ophthalmol Vis Sci.* 2000;41(8):2096-102.

11. McDonnell C, Murphy O, Cochrane, A, et al. Lissamine green - where have we been and where are we now? *Optometry in Practice.* 2020;21(2):C-75784.

12. Korb DR, Herman JP, Finnemore VM. An evaluation of the efficacy of fluorescein, rose bengal, lissamine green, and a new dye mixture for ocular surface staining. *Eye Contact Lens.* 2008;34(1):61-4.

13. Yoon KC, Im SK, Kim HG, You IC. Usefulness of double vital staining with 1% fluorescein and 1% lissamine green in patients with dry eye syndrome. *Cornea.* 2011;30(9):972-6.

14. DeMonte DW, Kim T. Anatomy and physiology of the cornea. *Journal of Cataract & Refractive Surgery.* 2011;37(3):588-98.

15. Sridhar MS. Anatomy of cornea and ocular surface. *Indian J Ophthalmol.* 2018; 66(2):190-4.

16. Kanski JJ, Menon J. *Clinical Ophthalmology.* Butterworth-Heinemann. 2003.

17. Willcox MDP, Argüeso P, Georgiev GA, et al. TFOS DEWS II Tear Film Report. *Ocular Surf.* 2017;15(3):366-403. (17)

18. Downie LE, Banditz S, Bergmanson JPG, et al. BCLA Clear - anatomy and physiology of the anterior eye. *Cont Lens Ant Eye.* 2021;44(2):132-56.

19. Bron AJ, Argüeso P, Irkec M, Bright FV. Clinical staining of the ocular surface: mechanisms and interpretations. *Prog Retin Eye Res.* 2015;44:36-61.

20. Bandamwar KL, Papas EB, Garrett Q. Fluorescein staining and physiological state of corneal epithelial cells. *Cont Lens Ant Eye.* 2014;37(3):213-23.

21. Komai S, Yokoi N, Kato H, et al. Clinical implication of patchy pattern corneal staining in dry eye disease. *Diagnostics.* 2021;11(2):232.

22. Fennger BJ, Tong J. Corneal staining characteristics in limited zones compared with whole cornea documentation for the detection of dry eye subtypes. *Invest Ophthalmol Vis Sci.* 2013;54:8013-9.

23. Fraunfelder FT, Wright P, Tripathi RC. Corneal mucus plaques. *Am J Ophthalmol.* 1977;83:191-7.

24. Alshuhaibani A, Mudhaiyan T. Floppy eyelid syndrome. EyeWiki. American Academy of Ophthalmology. October 21, 2021. Accessed June 27, 2022. www.eyewiki.aao.org/Floppy_Eyelid_Syndrome.

25. Le Q, Xu J, Deng SX. The diagnosis of limbal stem cell deficiency. *Ocular Surf.* 2018;16(1):58-69.

26. Dua HS. Stem cells of the ocular surface: scientific principles and clinical applications. *Br J Ophthalmol.* 1995;79:968-9.

27. Tseng SC. Significant impact of limbal epithelial stem cells. *Indian J Ophthalmol* 2000;48:79-81.

28. Dua HS, Saini JS, Azuara-Blanco A, Gupta P. Limbal stem cell deficiency: concept, aetiology, clinical presentation, diagnosis and management. *Indian J Ophthalmol.* 2000;48:83-92.

29. Vora GK, Daluvoy MB. Diagnosis and Management of Limbal Stem Cell Deficiency. *Ophthalmic Pearls.* February 2014. Accessed June 27, 2022. www.aao.org/assets/a87b735e-0790-4801-a864-5ccfb43890b/63555989712770000/february-2014-ophthalmic-pearls.pdf.

30. Deng SX, Borderie V, Chan CC, et al. Global consensus on definition, classification, diagnosis and staging of limbal stem cell deficiency. *Cornea.* 2019;38(3):364-75.

31. Uchiyama E, Aronowicz JD, Butovich IA, McCulley JP. Pattern of vital staining and its correlation with aqueous tear deficiency and meibomian gland dropout. *Eye Contact Lens.* 2007;33(4):177-9.

32. Singh P, Tripathy K. Keratopathy. *StatPearls.* Treasure Island (FL): StatPearls Publishing. February 21, 2022.

33. Fu L, Patel BC. Lagophthalmos. *StatPearls.* Treasure Island (FL): StatPearls Publishing. November 2, 2021.

34. Jabbour S, Ashton K, Bala S, et al. The management of neurotrophic keratitis. *Current Opinion in Ophthalmology.* 2021;32(4):362-8.

35. Meller D, Tseng SC. Conjunctivochalasis: literature review and possible pathophysiology. *Surv Ophthalmol.* 1998;43(3):225-32.

36. Marmalidou A, Khirkhah A, Dana R. Conjunctivochalasis: a systematic review. *Surv Ophthalmol.* 2018;63(4):554-64.

37. Di Pascuale MA, Espana EM, Kawakita T, Tseng SCG. Clinical characteristics of conjunctivochalasis with or without aqueous tear deficiency. *Br J Ophthalmol.* 2004;88(3):388-92.

38. Yvon C, Patel BC, Malhotra R. Conjunctivochalasis. *StatPearls.* Treasure Island (FL): StatPearls Publishing. March 12, 2022.

39. Yamaguchi M, Kutsuna M, Uno T, et al. Marx line: fluorescein staining line on the inner lid as indicator of meibomian gland function. *Am J Ophthalmol.* 2006;141(4):669-75.

40. Efron N, Brennan NA, Morgan PB, Wilson T. Lid wiper epitheliopathy. *Prog Retin Eye Res.* 2016;53:140-74.

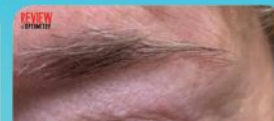
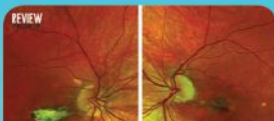
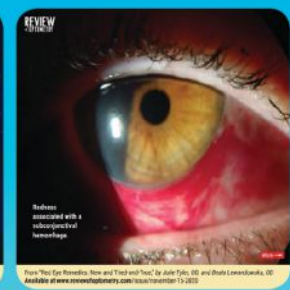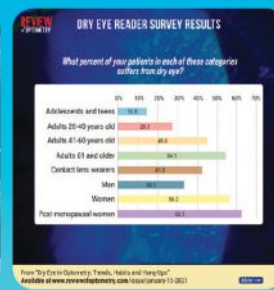
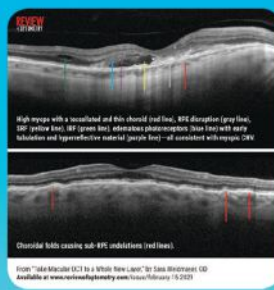
41. Norm M. Meibomian orifices and Marx's line. Studied by triple vital staining. *Acta Ophthalmol (Copenh).* 1985;63(6):698-700.

42. Knop E, Knop N, Zhivov A, et al. The lid wiper and mucocutaneous junction anatomy of the human eyelid margins: an in vivo confocal and histological study. *J Anat.* 2011;218(4):449-61.



A NEW WAY TO EXPERIENCE REVIEW OF OPTOMETRY

Follow us on Instagram at @revoptom for striking clinical images, daily news headlines, issue previews and great content from the magazine—all formatted for mobile



TAKING THE LEAD ON GLAUCOMA

ODs in every US state can now manage this common condition. Here's how to direct the delivery of care in your community.

BY CATLIN NALLEY
CONTRIBUTING EDITOR

As a lifelong, vision-threatening disease requiring frequent monitoring and treatment, glaucoma is one of the most common conditions optometrists handle on a daily basis. Most of the United States relies on ODs as their primary eye care providers; thankfully, recent legislation has made it possible for every OD across the country to offer glaucoma patients care close to home from a clinician they trust. In addition, one in five states can now perform selective laser trabeculoplasty (SLT), which is moving towards becoming a first-line treatment for glaucoma. Now more than ever, as practice rights for optometrists continue to increase, it's time to take the reins on glaucoma management at your practice.

No matter what level of glaucoma care you currently offer or which services are authorized in your state, it's critical to the health of your patients and your practice to stay informed and be prepared to implement the evolving techniques to manage the condition. Below, we provide ODs with guidance on how to expand on existing glaucoma services while embracing newer opportunities such as SLT to maximize the level of care offered to patients.

This article is the third in our scope expansion series, following one on incisions and injections (May) and another on lasers (June), all with the goal of helping you navigate these exciting new roles and responsibilities for ODs.

The Evolving Role of ODs in Glaucoma

Unlike the other procedures and services previously discussed in this series, the legislative battles regarding glaucoma management have—for the most part—been won. As of 2021, all optometrists in the United States can treat the condition topically, but the net wave is heating up, as 10 states now allow ODs to perform at least one type of laser procedure.

In January 2021, Massachusetts became the last state to give optometrists the authority to treat patients with glaucoma. Under the new legislation, comparable to that in many other states, ODs in Massachusetts can now prescribe topical and oral therapeutics including schedule III, IV, V and VI drugs for the diagnosis, prevention and treatment of glaucoma. They can also prescribe all necessary eye medications including oral anti-infectives.

Fast-forward a few months to June 2022, when legislation in Texas granted optometrists the authority to indepen-

dently manage glaucoma patients—eliminating the previous requirement of comanagement with an ophthalmologist, which is the case in a growing portion of the country. In addition, the Texas scope bill allows optometrists in the state to prescribe any oral medication used to treat eye conditions.

Most recently, Colorado claimed the title of the 10th state to allow optometrists to use lasers when its sunset bill was signed by Governor Jared Polis early last month. The as-taught law means that, in addition to enjoying several other new practice rights that align with current training and education, ODs in Colorado can now offer their glaucoma patients more treatment options aside from the standard eye drop, one example being SLT. *(You can read more about Colorado's recent scope expansion by clicking the link in the online version of this article or by turning to page 4.)*

SLT is becoming accepted as a first-line treatment for patients with open-angle glaucoma and ocular hypertension since the release of data from the LiGHT trial, which reported its effectiveness over topical therapy. The study found that 74% of patients treated with SLT required no drops to maintain their target intraocular pressure three years after the procedure. It also found that patients who received

IOP AND THE OD: ADVICE ON SETTING A TARGET PRESSURE

A key aspect of glaucoma management is IOP. Guidelines suggest that you should set a target IOP that is intended to be the level at which you prospectively hope the patients' disease will be slowed and their vision preserved, explains Dr. Rixon. While there is no consensus on how to set a target IOP, generally speaking, the worse the disease is, the lower the goal IOP should be.

"Setting a target IOP is a part of the overall risk management process, but it is not the ultimate determinant of successful or failed treatment," he says. "It's dynamic and can be intensified or loosened according to how the disease behaves. The ultimate determinant of success or failure is in slowing the rate of disease progression, which is determined most readily by watching for structural and functional progression."

Dr. Rixon urges ODs to always keep in mind that IOP is a highly dynamic parameter. "Our ability to catch the peaks and valleys of eye pressure over 24/7/365 is limited, especially as we typically only capture an extremely small snapshot of IOP when we get a single reading during our visits," he notes. That's why it's important to caution your patients not to fixate on the IOP captured during follow-ups.

Patience is key. Determining trends and understanding the rate of progression doesn't happen overnight. Dr. Rixon suggests labeling follow-ups as glaucoma progression evaluations instead of blanket IOP checks. This reinforces—for both you and your patient—what you're trying to combat.

"You have to take the 30,000-foot view of these patients and consider more than just the snapshot IOP that day. A big issue I see in the various clinics I have worked at is the hair-trigger reaction to not meeting a target pressure," he says. "The target IOP is an educated guess and is not set in stone. The highest level of IOP at which the patient is still susceptible to damage may take time to figure out."

SLT were within their target pressure more often than those treated with eye drops (93% vs. 91%).

With the increasing availability of SLT and research supporting its potential, ODs are in the perfect position to take the lead and manage this progressive, chronic condition and provide a very high level of care to their patients.

Despite these recent significant gains in scope expansion, there remains a need for more OD involvement in glaucoma. The number of patients with

glaucoma—and those with potential risk for blindness due to the disease—is projected to increase from three million in 2020 to 6.3 million by 2050. According to Andrew Rixon, OD, an attending optometrist and the residency coordinator at the Memphis VA Medical Center, "Glaucoma is an optometry problem, and we have a necessity to help combat this disease," he says. "A majority of cases are still underdiagnosed, and as front-line providers we are often the entry point to patient healthcare. It's a

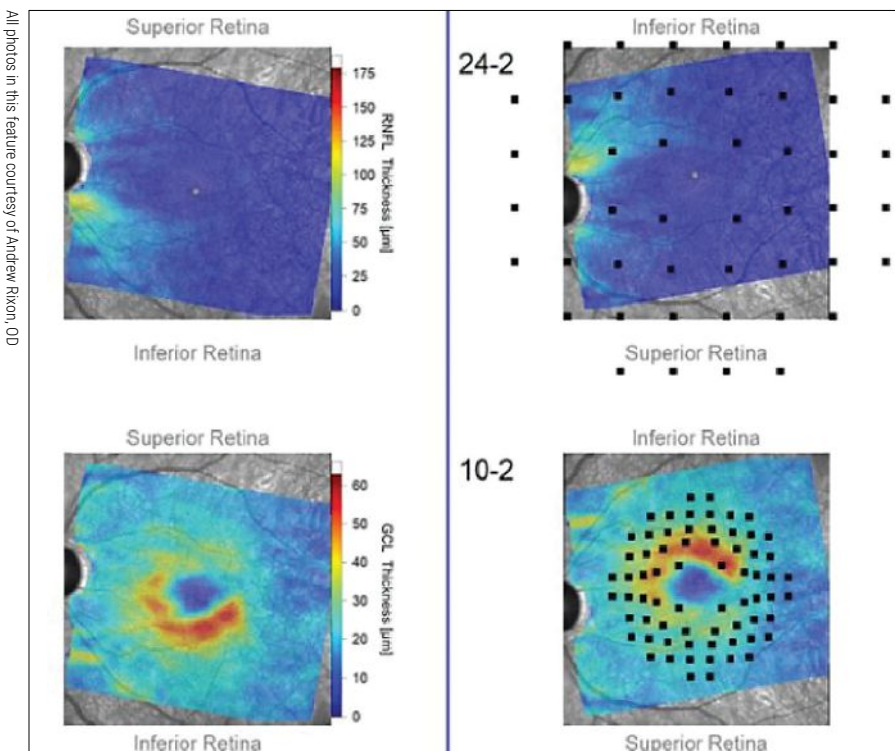
fundamental part of our job as primary eyecare providers. Our job is to maximize vision and a critical component of maximizing vision comes through prevention of vision loss."

Now let's take a closer look at how to integrate glaucoma management into clinical practice and lay the foundation to successfully take on a larger role in caring for this patient population.

Tools You'll Need

When incorporating glaucoma care into practice, optometric education has prepared ODs to manage this multifaceted disease, according to Jackie Burress, OD, who practices in the Eastern Oklahoma VA Healthcare System, who also notes that there are a number of continuing education resources readily available to help optometrists refresh their knowledge on or learn about new tools and medications. As always, you should check with your state board to ensure you are following all the necessary protocols before implementing new services into your practice.

A core component of effective glaucoma management is having the right tools at your disposal. "Practitioners need high-quality instruments to determine the risk of glaucoma, classify the type and stage and identify subtle progression," says Shaleen Ragha, OD, who practices at The Eye Center at the Southern College of Optometry. These instruments include spectral-domain or swept-source OCT with high resolution, accurate and repeatable



Images show macular structural data with superimposed visual field loci taken from a portion of a Hood Report, which is one tool that can aid in glaucoma diagnosis.

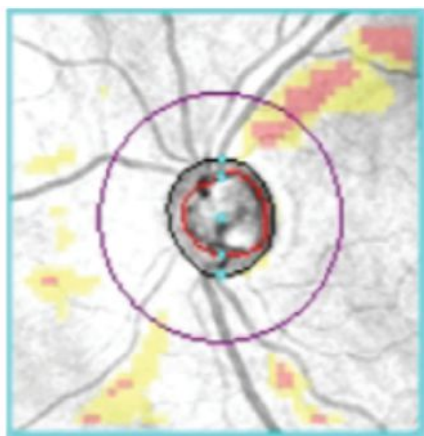
tracking, minimal inter-visit variability and a relevant patient database. “The optic nerve rim, retinal nerve fiber layer (RNFL), circumpapillary RNFL and macular ganglion cell layer thicknesses are key indicators for diagnosis and progression. High-quality imaging is crucial to delineate correct layer segmentation and repeatability,” she says.

When purchasing an OCT, Dr. Ragha urges ODs to take advantage of the company’s customer service team to better understand the device’s acquisition abilities, sources for error and manipulation and extraction of data.

Dr. Burress acknowledges that an OCT is a significant expense; however, she notes that if a practice is able to afford the cost, the device will provide lots of valuable information about the optic nerve and ganglion cells. “With OCT, we are now able to monitor for minor changes that would have been undetectable prior to this technology,” she says.

If an OCT is out of an optometrist’s price range, Dr. Burress recommends seeking creative solutions, such as mobile technology companies that allow you to rent the OCT for a day or partnering with a fellow OD in the area who has an OCT in-house. “Often-times, you can refer for the test, and then they will send your patient back to you for management.”

It is also important not to overlook the importance of gonioscopy, according to Dr. Burress. “A gonio lens is cost-effective and allows you to learn valuable information about your patient,”



Structural changes in the optic nerve rim can signify glaucomatous progression.

she points out. “You can examine the angle to differentiate between open-angle and closed-angle glaucomas and assess for signs of damage from trauma, including angle recession and synechia. Gonioscopy also allows us to determine the best candidates for SLT.”

Once your state’s law allows ODs to perform SLT, that will be another investment to consider. As noted in last month’s article on lasers from this scope expansion series, ODs can choose to purchase a stand-alone or a combination laser from various companies. Most new YAG/SLT combination lasers are cheaper than an OCT with a price tag of \$40,000 or less. Refurbished equipment that comes with a warranty is also a great option for those in search of a more wallet-friendly solution.

Steven G. Zegar, OD, practices in Slidell, LA, which passed its optometric laser bill in 2014. He has since

performed hundreds of ophthalmic procedures (primarily capsulotomies, but some SLT as well) and witnessed the benefits it’s had on his practice and his patients. Dr. Zegar urges optometrists who are hesitant to invest in a laser to consider the various alternatives to be able to offer SLT and other laser services to your patients. “You can ask to use another local optometrist’s laser, as well as ask if you can shadow them during the procedure,” he says. In addition, Dr. Zegar adds, “There are also services in some locations that can rent you a laser. That’s what we do at our practice; someone from the equipment company brings the laser to my office once a month on a Wednesday morning for two hours.” This option allows you to schedule patients’ laser procedures during the time window you choose without having to front a high cost.

With SLT playing an increasingly prominent role in glaucoma care, you may want to consider adding this instrument to your clinic if you have the means. The more treatment options you can offer your patients—especially when it’s something other than a drop—the more satisfied they will be with your care.

Another important tool is an automated visual field that performs threshold testing to evaluate function in correlation to structure, as seen on funduscopy and OCT, Dr. Ragha suggests. She also notes that “a trained technician is helpful to ensure good instruction to the patient and communication of test observations to the doctor. Since it is a subjective test, reliability should be considered in interpretation.”

There are a number of other devices that aid in the diagnosis of and risk assessment of glaucoma. Goldmann applanation tonometry is the current gold standard for measuring intraocular pressure (IOP), according to Dr. Ragha. “The Goldmann tip comes with most slit-lamp instruments and appropriate sterilization is recommended,” she explains. “As for ophthalmic diagnostic pharmaceuticals, Fluress (fluorescein benoxinate) or a topical anesthetic with a fluorescein strip can be used.”

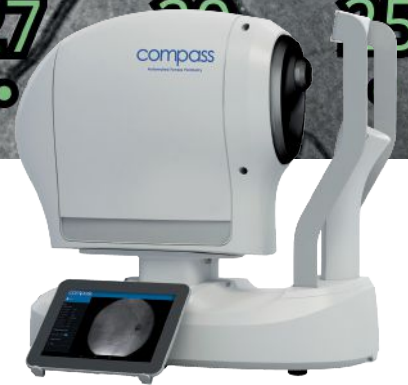HESITANT TO MANAGE GLAUCOMA? HERE’S ADVICE

Integrating a new service into clinical practice is not a simple task, and while it is natural to feel hesitant, your optometric skills will serve you well in this challenge. Adding glaucoma care to your repertoire not only benefits your patients but also enhances own practice and professional growth. Drs. Burress and Rixon offer some advice and inspiration below.

- Accept the challenge and attack the obstacle. Improvement as a person and a doctor doesn’t come by staying comfortable.
- There are a plethora of resources within the professional industry that support ODs.
- Be patient and diligent.
- Seek out a peer mentor who is already providing these services. Remember, you aren’t on an island by yourself.
- Focus more of your continuing education hours on glaucoma.
- Invest in your practice with the purchase of an OCT and retinal camera.
- Continue to learn and grow as a healthcare provider to positively impact your patients.



The next level of iCare



iCare COMPASS

Automated perimeter
with **retinal tracking**

The active Retinal Tracker of iCare COMPASS compensates for eye movements resulting in superior repeatability. Defects are delineated precisely. Retinal function and structure are correlated with the TrueColor retinal image.

- + Unique retinal tracking
- + TrueColor confocal retinal image acquired
- + No trial lenses



JUST LAUNCHED

iCare HOME2

24-hour at home
tonometry

- + **NEW!** Supine, reclined & seated positions
- + **NEW!** New smart light guide for easy positioning
- + **NEW!** Interactive display screen
- + **NEW!** Comprehensive IOP reports



For more information, scan,
call 888.422.7313, or email
infoUSA@icare-world.com
www.icare-world.com/USA

For better perception **icare**

Corneal pachymetry is also helpful to determine the risk of progression and also under- or over-estimation of Goldmann IOP readings, explains Dr. Ragha. She notes that an OCT with anterior segment capability or an ultrasound pachymeter can be used.

To document optic nerve and RNFL appearance at baseline, Dr. Ragha finds fundus photography to be helpful. This can be repeated if any changes are noted. “Color imaging, specifically using blue- or red-free filters, can highlight RNFL defects,” she says.

Preparing Staff

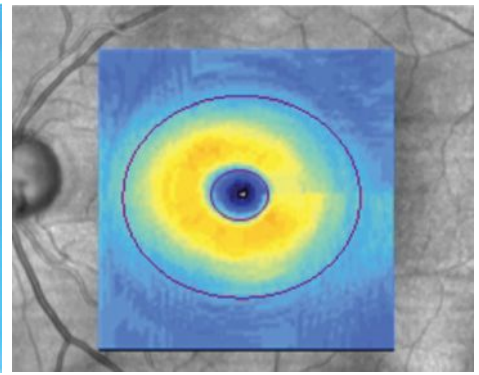
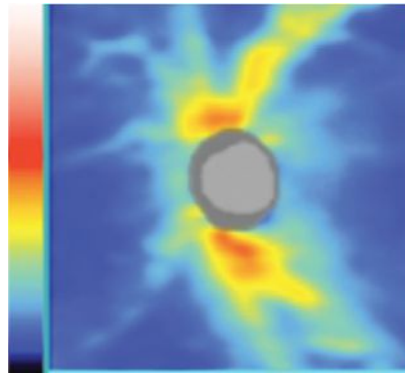
Staff education is also a key component to successfully incorporating glaucoma care into your practice. This is a multi-tiered process, according to Dr. Rixon, and begins with an understanding of the comprehensive care provided by the doctor as well as ongoing education to ensure patients receive the highest quality of care.

“Administrative staff is then able to promote to the patients what services the doctor provides and what skills and time are involved in their respective visits,” he says. “Secondly, clinical staff will need to become proficient in performing the new technologies that are brought into the practice and be able to explain why each technology is being used.” For example, if or when your practice introduces SLT, ensure the entire staff is prepared to answer questions about the newer therapeutic option that most patients will be unfamiliar with.

Oftentimes, he notes, clinical staff will be responsible for educating patients on medication instillation and drop schedules as well as communicating with patients during phone calls and telehealth appointments. Therefore, it is important that they receive the necessary training and education to support coherent glaucoma management within the practice.

Detecting and Diagnosing

As with any condition, enacting a care plan begins with an appropriate diagnosis. “Glaucoma is a chronic, progressive



It's important to analyze all tissue that can be affected by glaucoma, which includes both the optic nerve head and the macula.

optic neuropathy that involves loss of both neural and connective tissue (lamina cribrosa),” Dr. Rixon notes. “Although it is often conflated with glaucoma, elevated IOP is nowhere in any consensus definition of glaucoma; rather, it is a risk factor.”

Therefore, the most important step involved in designating a patient as a glaucoma suspect or as having glaucomatous optic neuropathy is conducting a detailed, stereoscopic evaluation of the optic nerve head.

While there are myriad risk factors associated with the development of glaucoma, ODs have to anchor the work on their optic nerve head evaluation to begin the diagnostic process and build a baseline of structural and functional information to work from, he advises.

“Thinning of superior-temporal or inferior-temporal rim tissue is a sign of glaucomatous damage, whereas a large cup-to-disc ratio may be normal for a large-size disc,” adds Dr. Ragha. “IOP is an important risk factor; however, remember that low-pressure glaucoma can still exist, as well as ocular hypertension, in cases where there are no signs of glaucoma.” She emphasizes that this is why a full workup that includes pachymetry, gonioscopy, OCT and visual fields is necessary.

It is important to note that IOP also has diurnal variation, so OCT and visual field evaluation should have more emphasis when deciding on the course of management, according to Dr. Ragha. Instrumentation errors,

artifacts and concurrent disease should be considered when interpreting OCT and visual fields.

“From my experience in teaching, the most common mistake is evaluating summary reports and skipping review of the actual scans or plots,” Dr. Ragha notes. “For any serial testing, new scans and fields should be compared to the baseline, which may be the last time progression was noted or a treatment change was made.”

Classifying the type of glaucoma you are dealing with is also critically important. Do not assume every case is one of primary open-angle glaucoma, Dr. Rixon warns. Gonioscopy is underused in optometry and ophthalmology; however, he notes, this tool is key to accurate classification.

Starting—and Keeping—Patients on Treatment

Once a glaucoma diagnosis has been made, a patient-centric approach to care with shared decision-making is required, according to Dr. Rixon, who says that this begins with a baseline level of knowledge of the disease. Since each patient has a different level of healthcare literacy, the OD must first try to understand what the patient does and does not know before education begins.

“Personally, I believe setting expectations on the front end about how dynamic the patient’s individualized care can be is critical,” he says. “Patients need to understand that the number of visits they will need

NEW!



More Moisture⁴ for Your Contact Lens Patients Introducing Biotrue[®] Hydration Plus Multi-Purpose Solution

25% MORE Hyaluronan (HA)
means **MORE MOISTURE**
to lenses in the first
12 hours of wear^{1,2}



**Added Ingredients Informed
by TFOS DEWS II**



Essential Electrolyte found
in natural tears

An antioxidant to protect
hyaluronan against
free radicals³

**Exceptional Cleaning
+ Disinfection**



Kills 99.9% of
germs tested⁵

Clinically tested
for patient comfort

Discover our extended line of
Biotrue[®] products at

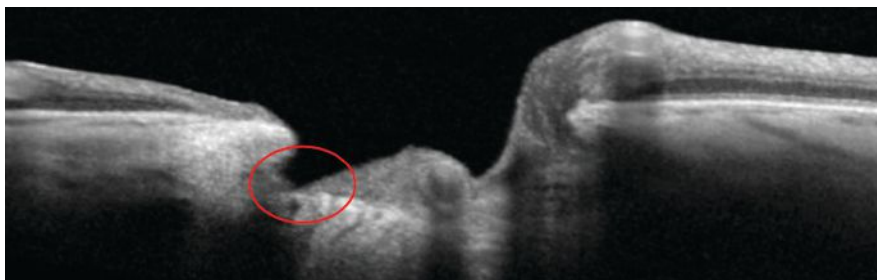[biotrue.com](https://www.biotrue.com)

¹Compared to Biotrue Multi-Purpose Solution.
²Based on a laboratory study.

³Antioxidant protects hyaluronan against free radicals.

⁴For 12 hours compared to Biotrue Multi-Purpose Solution, based on a laboratory study.

⁵Standardized Testing (ISO 14729) against S. aureus, P. aeruginosa, S. marcescens, C. albicans, F. solani.



Loss of prelaminar neural tissue in a patient with myopic glaucoma.

initially and throughout the course of the disease will depend entirely on how their disease behaves and that as a team, we will chart out a custom course together.”

Manner and urgency of treatment depend on multiple factors, including disease stage at diagnosis, quality of life, risk tolerance, life expectancy, ability to administer medications, side effects of treatment and consideration of ocular comorbidities such as surface disease.

For ODs who are able to perform SLT, Dr. Burrell recommends considering this as a first-line treatment. “This procedure is becoming more common in practice. It is also great to recommend in patients who have a history of poor compliance with traditional glaucoma medications.” Using an SLT laser, treatments are generally applied 360 degrees to the trabecular meshwork using adjacent, non-overlapping spots (approximately 100). The goal is to see tiny “champagne bubbles” in the anterior chamber during the procedure.

It’s important to note that SLT isn’t the best choice for every glaucoma patient: it’s contraindicated for neovascular glaucoma, and for those with heavily pigmented trabecular meshwork, energy settings of the laser may need to be decreased. (*Interested in adding SLT to your optometric toolbox? Check out the previous article in this series, “Adding Lasers to Your Practice,” featured in our June issue, for step-by-step advice.*)

When opting to start a patient on topical medications, Dr. Rixon emphasizes the importance of assuming patients are not compliant with drop installation, as that is the more likely scenario. Instructing the individual on

how to properly instill meds and having them demonstrate successful instillation prior to leaving the office will ensure that lack of knowledge on how to administer the medication is one less deterrent to adherence. This task, he notes, can be delegated to clinical staff and reinforced to patients with educational handouts and videos.

“The simpler, the better,” advises Dr. Rixon. “If possible, start with a once-daily medication for ease of instillation and be flexible with when it is instilled. PGAs have been shown to blunt the diurnal/nocturnal IOP curve up to 84 hours post-instillation. Flexibility with the drop schedule isn’t an issue, as long as it doesn’t reduce treatment effectiveness.” One idea to promote adherence is to have patients instill their drops at the same time as they take their other medications, if they are prescribed any.

It is also important to take your patient’s insurance and financial information into consideration, suggests Dr. Burrell. If the drop is too costly, compliance will be affected. Consider

opting for glaucoma drops with a lower copay that provide good IOP management, such as timolol. However, when prescribing this drug, Dr. Burrell says you must “be sure the patient has a resting pulse rate at 60 beats per minute or above so that bradycardia does not occur. Also, check to see if the patient is on a systemic beta-blocker, as this can lower the efficacy of timolol.”

Continuous Monitoring of Disease Progression

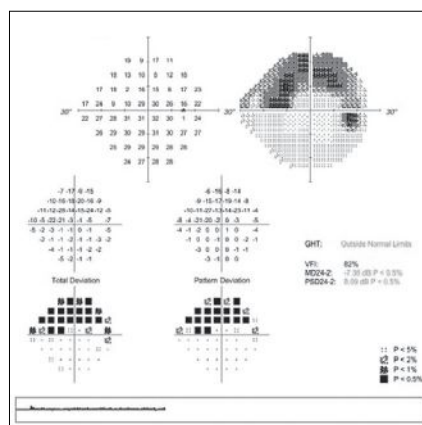
Frequent in-person follow-up is a key component of any chronic condition. After a diagnosis, Dr. Rixon prefers to bring patients back for a six-week evaluation, which is used to assess any side effects of treatment, unforeseen burden of treatment, adherence issues and to answer any questions that the glaucoma patient may have. The goal is to establish sufficient baseline information to detect the rate at which a patient is progressing.

The World Glaucoma Association recommends two reliable baseline visual fields within the first six months of treatment and at least two additional fields within the following 18 months for mild to moderate disease. Six total visual fields are recommended in the first two years in patients at high risk of visual disability.

OCT scans of both the macula and optic nerve are crucial when assessing the structure of the neural and connective tissues affected by glaucoma. Careful assessment of the structure will help guide visual field strategies and provide a more comprehensive understanding of a patient’s disease.

“The most studied and repeatable parameter on OCT to gauge progression is the average or global RNFL. Generally, a baseline OCT and an additional OCT at six and 12 months from diagnosis are beneficial to address machine test-retest variability and rule out your patient being a fast progressor,” Dr. Rixon says, while noting that testing regimens should be customized to the individual.

When considering glaucoma management, Dr. Rixon notes that while early



Superior arcuate defect in a patient with moderate glaucoma.

When it comes to ocular surface inflammation associated with dry eye disease,

FLAREX® IS A PROVEN WINNER.



The power of Pred Forte* (prednisolone acetate ophthalmic suspension, USP) 1%
with the safety of FML*,¹ (fluorometholone ophthalmic suspension, USP) 0.1%

97% of ocular surface inflammation was resolved or improved with FLAREX vs 89% with Pred Forte.¹

**Head-to-head
with FML:**



FLAREX was significantly more effective in the resolution of external non-infectious inflammatory conditions of the eye ($P=0.03$)¹

**Head-to-head
with Pred Forte:**



FLAREX had comparable, non-inferiority efficacy in the treatment of external non-infectious inflammatory conditions of the eye¹

**In the FDA pivotal
clinical evaluation:**



No reported adverse events in any treatment group when evaluated versus Pred Forte and FML¹

**DISPENSE AS WRITTEN.
THERE IS NO GENERIC EQUIVALENT OF FLAREX.
BE SURE TO PRESCRIBE IT BY NAME.**

INDICATIONS AND USAGE

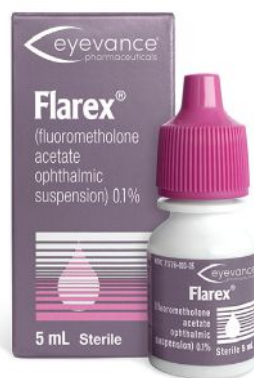FLAREX® (fluorometholone acetate ophthalmic suspension) is indicated for use in the treatment of steroid-responsive inflammatory conditions of the palpebral and bulbar conjunctiva, cornea, and anterior segment of the eye.

IMPORTANT SAFETY INFORMATION

ADVERSE REACTIONS: Glaucoma with optic nerve damage, visual acuity and field defects, cataract formation, secondary ocular infection following suppression of host response, and perforation of the globe may occur.

Please see the Full Prescribing Information on the next page.

Reference: 1. Leibowitz HM, Hyndiuk RA, Lindsey C, et al. Fluorometholone acetate: clinical evaluation in the treatment of external ocular inflammation. *Ann Ophthalmol.* 1984;16(12):1110-1115.



Flarex®
(fluorometholone acetate ophthalmic suspension) 0.1%

LEARN MORE AT
MYFLAREX.COM

FLAREX NDC NUMBER: 71776-100-05



© 2022 Eyeavance Pharmaceuticals LLC., a Santen company. All rights reserved.
FLAREX® is a registered trademark of Eyeavance Pharmaceuticals LLC.
*All other trademarks are the property of their respective owners. FLA-20-AD-74-02 01/22

FLAREX® (fluorometholone acetate ophthalmic suspension) 0.1% Brief Summary

INDICATIONS AND USAGE

FLAREX (fluorometholone acetate ophthalmic suspension) is indicated for use in the treatment of steroid-responsive inflammatory conditions of the palpebral and bulbar conjunctiva, cornea, and anterior segment of the eye.

DOSAGE AND ADMINISTRATION

Shake Well Before Using. One to two drops instilled into the conjunctival sac(s) four times daily. During the initial 24 to 48 hours, the dosage may be safely increased to two drops every two hours. If no improvement after two weeks, consult physician. Care should be taken not to discontinue therapy prematurely.

CONTRAINDICATIONS

Contraindicated in acute superficial herpes simplex keratitis, vaccinia, varicella, and most other viral diseases of the cornea and conjunctiva; mycobacterial infection of the eye; fungal diseases; acute purulent untreated infections, which like other diseases caused by microorganisms, may be masked or enhanced by the presence of the steroid; and in those persons who have known hypersensitivity to any component of this preparation.

WARNINGS AND PRECAUTIONS

Topical Ophthalmic Use Only

For topical ophthalmic use only. Not for injection.

Intraocular Pressure Increase

Prolonged use may result in glaucoma, damage to the optic nerve, and defects in visual acuity and visual field. It is advisable that the intraocular pressure be checked frequently.

Cataracts

Use of corticosteroids may result in cataract formation.

Delayed Healing

Topical ophthalmic corticosteroids may slow corneal wound healing. In those diseases causing thinning of the cornea or sclera, perforation has been known to occur with chronic use of topical steroids.

Viral Infections

Use in the treatment of herpes simplex infection requires great caution.

Bacterial Infections

Use of corticosteroids may suppress the host response and thus aid in the establishment of secondary ocular infections. Acute purulent infections of the eye may be masked or exacerbated by the presence of steroid medication.

Fungal Infections

Fungal infections of the cornea are particularly prone to develop coincidentally with long-term local steroid application. Fungus invasion must be considered in any persistent corneal ulceration where a steroid has been used or is in use.

Contamination

Do not touch dropper tip to any surface, as this may contaminate the suspension.

Contact Lens Wear

Contact lenses should be removed during instillation of FLAREX but may be reinserted after 15 minutes.

Temporarily Blurred Vision

Vision may be temporarily blurred following dosing with FLAREX. Care should be exercised in operating machinery or driving a motor vehicle.

ADVERSE REACTIONS

Clinical Trials Experience

Glaucoma with optic nerve damage, visual acuity and field defects, cataract formation, secondary ocular infection following suppression of host response, and perforation of the globe may occur.

Postmarketing Experience

The following reaction has been identified during postmarketing use of FLAREX in clinical practice. Because reactions are reported voluntarily from a population of unknown size, estimates of frequency cannot be made. The reaction, which has been chosen for inclusion due to either its seriousness, frequency of reporting, possible causal connection to FLAREX, or a combination of these factors, includes dysgeusia.

USE IN SPECIFIC POPULATIONS

Pregnancy

Fluorometholone has been shown to be embryocidal and teratogenic in rabbits when administered at low multiples of the human ocular dose. Fluorometholone was applied ocularly to rabbits daily on days 6-18 of gestation, and dose-related fetal loss and fetal abnormalities including cleft palate, deformed rib cage, anomalous limbs, and neural abnormalities, such as encephalocele, craniorachischisis, and spina bifida, were observed. There are no adequate and well-controlled studies of fluorometholone in pregnant women, and it is not known whether fluorometholone can cause fetal harm when administered to a pregnant woman. Fluorometholone should be used during pregnancy only if the potential benefit justifies the potential risk to the fetus.

Lactation

Systemically administered corticosteroids appear in human milk and could suppress growth, interfere with endogenous corticosteroid production, or cause other untoward effects. It is not known whether topical administration of corticosteroids could result in sufficient systemic absorption to produce detectable quantities in human milk. Because many drugs are excreted in human milk, caution should be exercised when FLAREX is administered to a nursing woman.

Pediatric Use

Safety and effectiveness in pediatric patients have not been established.

Geriatric Use

No overall differences in safety or effectiveness have been observed between elderly and younger patients.

NONCLINICAL TOXICOLOGY

Carcinogenesis, Mutagenesis, Impairment of Fertility

No studies have been conducted in animals or in humans to evaluate the possibility of these effects with fluorometholone.

PATIENT COUNSELING INFORMATION

Risk of Contamination

Do not touch dropper tip to any surface, as this may contaminate the suspension.

Use with Contact Lenses

The preservative in FLAREX, benzalkonium chloride, may be absorbed by soft contact lenses. Contact lenses should be removed during instillation of FLAREX but may be reinserted 15 minutes after instillation.

Temporarily Blurred Vision

Patients should be advised that their vision may be temporarily blurred following dosing with FLAREX. Care should be exercised in operating machinery or driving a motor vehicle.

Rx Only

Distributed by: Santen Pharmaceutical Co., Ltd.
Fort Worth, TX 76102



and aggressive intervention is desirable, it has to be done judiciously. “Immediately reacting to a few in-office post-treatment IOP readings often results in unnecessary escalation and complicates matters for both the patient and practitioners,” he says. “If the total picture shows that the patient is at high risk for progression or is progressing at the current level of treatment, then additional intervention is necessary.” Dr. Rixon emphasizes that providers of glaucoma care need to “manage the disease, not the IOP.”

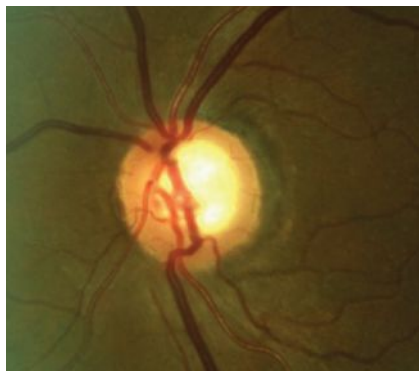
Common Challenges and Pitfalls

While ODs are equipped with the skills and knowledge to effectively manage glaucoma patients, implementing this service into clinical practice does not come without its difficulties. “Don’t assume that there won’t be any bumps in the road,” urges Dr. Rixon. “There is a learning curve to integrating any new service, and it’s important to stay the course no matter how frustrating and humbling the growth process can be.”

Glaucoma management is a long-term commitment, and you can’t assume that “if you build it, they will come,” he says. “You need to constantly avail patients of the services you provide. This goes back to educating your patients and re-emphasizing that you are their primary eyecare provider.”

Integrating new technology is also an ongoing process. As a provider, you are essentially learning a new language in a world that is constantly evolving, explains Dr. Rixon. “It is a time-consuming task to keep up with all the innovation in technology. Although product manuals are great in teaching how to acquire good information, they are not universally good at teaching how to interpret and apply that information,” he points out. “There is a time commitment that may not be expected on the front end.”

Dr. Burrell emphasizes that ODs should avoid thinking that implementing this service will show them down in the clinic. “Since IOP and nerve assessment is something done at every routine exam, you are already screening



Superior temporal rim erosion and corresponding RNFL thinning in a patient with early POAG.

for glaucoma on a daily basis,” she says. She adds that it is important to remember that multiple visits may be necessary to gather the information needed to diagnose glaucoma.

Since no noticeable symptoms are associated with this chronic disease until advanced stages, patients often have a poor understanding of the condition, notes Dr. Ragha, which can be a challenge for the OD. “To further complicate this misconception, treatment at that point will not restore vision loss,” she says. “Spending time explaining the condition and treatment as well as briefly showing test results at each visit can help patients understand their glaucoma.”

Medication adherence is a known issue with glaucoma patients, according to Dr. Rixon, who notes that studies show as few as 10% of patients make it a year without a major gap in treatment.

“Adherence patterns established in the first year are often indicative of future patterns, so early and consistent education about the ‘what’ and ‘why’ of glaucoma care is key,” he says. “Open-ended communication and employing an ask-tell-ask method has been shown to improve detection of medication non-adherence and consequentially improve adherence.”

Providing Comprehensive Care

When embracing glaucoma management, ODs are the clinicians who can and should take the lead, and fortunately, the evolving legal landscape agrees.

“We want to offer the best care for our patients with the greatest outcome possible,” Dr. Ragha says. “Access to care is an issue for many people, especially the elderly. Offering glaucoma care close to home allows them better access to treatment and the patient will be more willing to follow-up.”

Dr. Zegar recommends choosing to partner up with ophthalmologists and other physicians who support the expansion of optometry’s scope of practice. In addition to networking with local specialists such as endocrinologists and dermatologists who often need to refer patients to eye doctors, it’s also beneficial to invite them to your practice and show them which procedures you perform and which equipment you use. “I’m getting anywhere from eight to 12 weekly referrals from internal medicine,” says Dr. Zegar. “It takes work and effort to form and maintain these connections, but it really helps your practice grow, especially once you offer the more advanced procedures.”

And if you’re further along in your career than others, don’t write off glaucoma—including laser procedures—as something for the next generation. Dr. Zegar was 71 years old when Louisiana passed its laser law. Today, at age 79, he still sees patients 4.5 days a week. “I feel any of my peers who do not take advantage of these highly expanded modes of practice are depriving themselves of intellectual challenge and not serving their respective communities to the fullest extent,” he says. “Adding lasers brightened as well as extended my view of optometric practice.”

When optometrists work at the top of their expertise, everyone benefits. “Most of us chose this field because we want to take care of people’s vision and ocular health,” says Dr. Ragha. “Insurance reimbursement and cost of equipment and staff play a role in the hesitancy of managing specific conditions. However, the knowledge you need to manage glaucoma is at your fingertips, and your patients benefit from the wide scope of care.” ■

Next month: Part 4 of this series will delve into the use of oral medications.

PREPPING FOR THE GLAUCOMA GRIND

Once in your care, people with this disease become lifelong patients. Learn how to best accommodate the ongoing needs of those in the advanced stage.





BY JUDY HU, OD
BOWIE, MD

As medical optometry expands in scope, the role of the optometrist in glaucoma care is becoming more comprehensive. It is important for clinicians to be familiar with the diagnostic challenges associated with the disease and the tools that can better help manage these patients. In addition to making the correct diagnosis, ODs must be confident in our ability to effectively treat and manage patients with various stages of glaucoma, especially end-stage.

Stages of Disease

To understand how to manage glaucoma, it is helpful to define the different stages of the disease. The following ICD-10 definitions are widely used and straightforward for clinicians to adapt in practice:¹

- Mild or early.** Optic nerve abnormalities consistent with glaucoma
 - but no glaucomatous visual field (VF) abnormalities on any VF test
 - or abnormalities present only on



SITA SWAP testing helps display early glaucomatous defects.

short wavelength automated perimetry or frequency doubling perimetry.

Moderate. Optic nerve abnormalities consistent with glaucoma

- and glaucomatous VF abnormalities in one hemifield not within 5° of fixation (note: 5° = involvement of spots nearest fixation).

Advanced, late, severe. Optic nerve abnormalities consistent with glaucoma

- and glaucomatous VF abnormalities in both hemifields
- and/or loss within 5° of fixation in at least one hemifield.

At the initial glaucoma evaluation, disease severity must be clearly and

About the author

Dr. Hu graduated from the University of California Berkeley School of Optometry and completed her residency in ocular disease at the Baltimore Veterans Affairs Medical Center. She currently practices at the Glaucoma Center in Bowie, MD, and is a speaker for Aerie Pharmaceuticals.

correctly staged. Based on the clinical exam, diagnostic analysis and associated risk factors (e.g., age, race, central corneal thickness, family history, ocular comorbidities), an appropriate target pressure can then be determined accordingly.

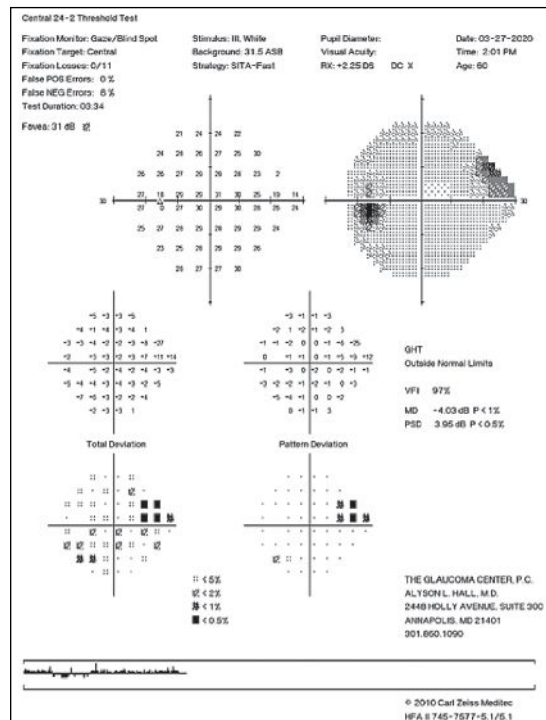
Diagnostic OCT Challenges

In early glaucoma, particularly pre-perimetric glaucoma, OCT of the retinal nerve fiber layer (RNFL) is extremely useful in showing early tissue loss. In advanced glaucoma, the OCT RNFL scan becomes less useful due to what is known as the “floor effect,” which means that loss of the nerve fiber layer may still occur but is no longer detectable on OCT. This is theorized to be caused by residual tissue, such as glial cells or blood vessels, being measured instead.² The RNFL scan will not show progressive thinning greater than 40µm to 45µm, beyond which macular OCT ganglion cell analysis should be considered.³

Since central vision is typically intact until very late-stage disease, macular OCT can be helpful in tracking progression in severe glaucoma. Studies have shown that even with advanced structural damage and in eyes that have reached the floor effect with RNFL measurements, progression can still be detected with the macular OCT ganglion cell analysis algorithm.^{2,4} This is especially useful in patients who are poor VF test-takers or who are unable to complete VF testing due to physical or mental limitations.

Diagnostic VF Challenges

In severe to end-stage glaucoma, the standard 24-2 VF is often completely depressed or with only a small central island remaining. In these cases, it is critical that the clinician switches to 10-2 VF testing to allow for more precise



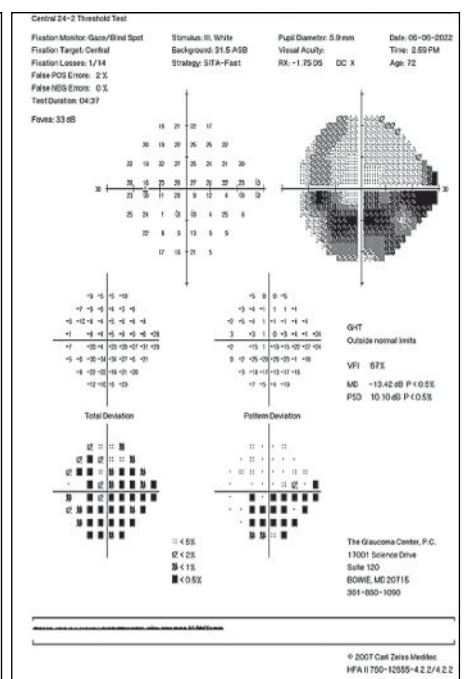

Superior nasal step in a patient with moderate glaucoma.

monitoring of the central island. The 24-2 field tests a total of 54 points that are 6° apart vs. the 68 points the 10-2 field is able to test 2° apart. Of the 54 points in the 24-2 algorithm, only 12 are tested within the central

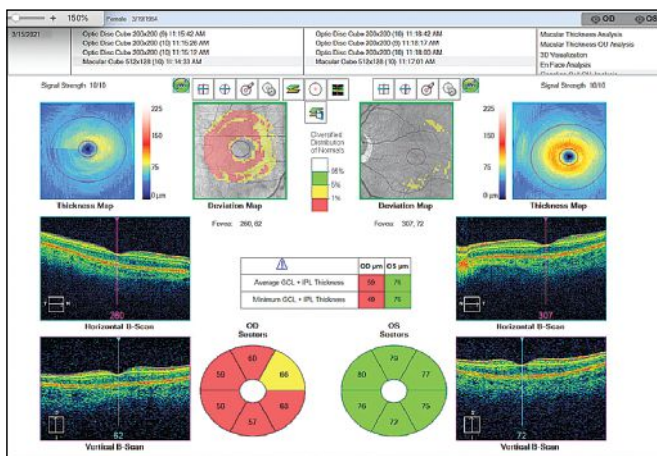
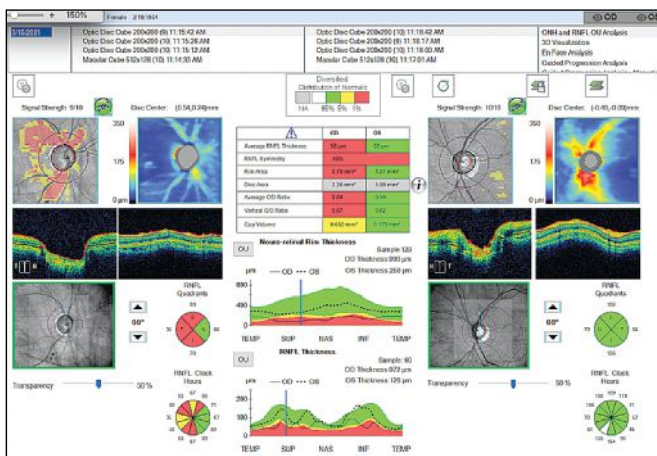
10° of fixation. This is insufficient to allow for adequate monitoring of the central points in advanced disease, which help determine a patient’s ability to complete daily activities such as driving and reading.⁵ An effective alternative is the Humphrey 24-2C VF test, which includes the 24-2 grid but also incorporates 10 additional test points in the central 10° of vision.⁶

In early to moderate glaucoma, the rate of mean deviation (MD) change is comparable between the 24-2 and 10-2 fields. However, in eyes with severe disease, the rate of MD change is significantly higher on the 10-2 compared with the 24-2. The MD value is calculated from a subset of the total points. In the 24-2, the points are mostly central and midperipheral, whereas in the 10-2, the points are all within the central 10°. Therefore, the central VF loss in more severe disease is not able to be followed for progression with the 24-2 test.⁵

In advanced disease, it is necessary to take VF test consideration



Dense superior and inferior arcuate defects in an advanced glaucoma patient (left). Inferior arcuate defect involving fixation and early superior nasal step (right).



Left: Severe glaucomatous optic nerve damage of the right eye with a very thin RNFL, which may not show further thinning past this point. **Right:** Macula ganglion cell complex, which can help provide information about progression in the same individual.

one step further. When VF loss is very severe, the standard size III automated perimetry may no longer be adequate to catch progression. Switching to a Fastpac size V stimulus with 10-2 testing allows for a larger target size so that points that previously did not respond to a size III target will now show a response. This is typically reserved for end-stage glaucoma when there is only a small central island remaining.³

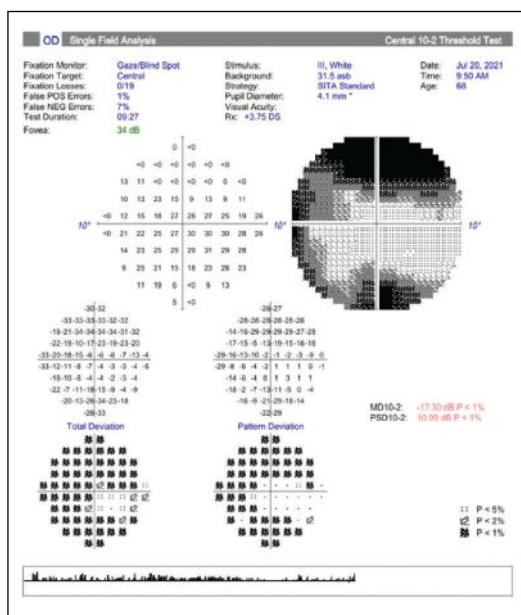

While there is a need for at least three tests the first year of glaucoma diagnosis to pinpoint progression, much of the frequency of testing in advanced disease depends on the stability of the patient. If a severe glaucoma patient has been stable for many years with well-controlled intraocular pressure (IOP), VF testing twice a year may be sufficient. Contrast that with a severe glaucoma patient whose IOP is above ideal, or whose VF shows deterioration, more follow-ups are required to monitor for changes in IOP fluctuation, and more frequent fields are required to confirm progression.

Medical Management

Setting target pressures can sometimes be challenging in advanced disease; however, we can reference major landmark studies such as the Advanced Glaucoma Intervention Study for guidance. While there is no magic number for the perfect target IOP in advanced disease, we know from the study that patients who consistently maintained an IOP of less than 18mm Hg at every visit over six years, with a mean IOP of 12.3mm Hg, had good VF preservation.⁷ As a general rule of thumb, a target IOP in the low teens is a good initial goal

for severe disease. Other factors, of course, contribute to this goal. For example, a young monocular patient with a thin central corneal thickness and strong family history of glaucoma may require a single-digit target IOP. Compare this case to an elderly patient in poor systemic health with a thick central corneal thickness and other ocular comorbidities who may not necessarily require aggressive therapy to lower IOP to the low teens.

It is important to change this target pressure accordingly depending on how the patient progresses. An IOP



Left: Small central island in advanced glaucoma. **Right:** The same patient was assessed with 10-2 testing to allow for more points in the remaining central island to be monitored.

Give More Patients the Comfort They Deserve:¹

DAILIES TOTAL1® CONTACT LENSES

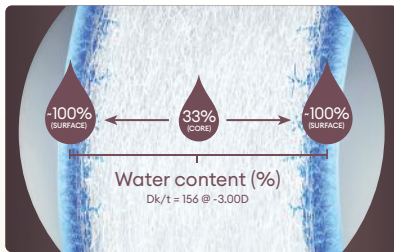
Sphere, Multifocal and for Astigmatism!



DAILIES TOTAL1® One-Day Contact Lenses are the first and only daily disposable lenses to feature Water Gradient Technology, a breakthrough lens technology offering lens wearers an experience so comfortable, they often forget they're wearing lenses!² DAILIES TOTAL1® for Astigmatism now let you offer more patients the comfort and vision they deserve.¹

Unique Technologies Designed for the Ultimate Contact Lens Experience

Water Gradient Technology, a unique permanent water surface chemistry, enables the outstanding wearing experience of the DAILIES TOTAL1® contact lens family. DAILIES TOTAL1® lenses begin with a low-water-content



silicon hydrogel lens core that provides exceptional breathability.* Outside of the core, the lens material gradually increases up to nearly 100% water at the outermost surface.¹ This ensures

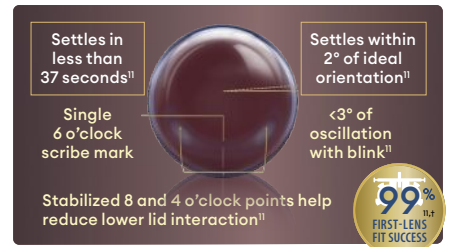
that a gentle cushion of moisture is the only part of the lens interacting with the delicate tissues of the eye.^{3,4}

The DAILIES TOTAL1® family lenses also feature innovative and exclusive SmartTears® Technology, which continuously releases phosphatidylcholine into the tear film during wear. Phosphatidylcholine is an ingredient found naturally in tears which helps to stabilize the lipid layer of the tear film.^{5,6,7}

This combination of advanced technology makes DAILIES TOTAL1® lenses a remarkable choice for first-line use in your contact lens wearers. In a study of symptomatic lens wearers, switching to DAILIES TOTAL1® provided up to 3 additional hours of comfortable wear time vs. their habitual lenses.⁸

Give Astigmats the Experience They Deserve

Astigmatic contact lens wearers can struggle with dryness and end-of-day discomfort.⁹ DAILIES TOTAL1® for Astigmatism offer outstanding overall comfort and exceptionally stable vision by combining advanced lens technologies with Alcon's proven PRECISION BALANCE 8|4® lens design.¹⁰ And because they demonstrate 99% first lens fit success,[†] incorporating DAILIES TOTAL1® for Astigmatism into your practice is easy.¹¹



Outstanding Comfort and Seamless Vision at All Distances for Presbyopes

Today's presbyopes express that multifocal contact lenses help them look younger,¹² and are better for an active lifestyle than progressive lenses.¹³ With DAILIES TOTAL1® Multifocal, patients with presbyopia get that same outstanding experience, as well as predictable, seamless vision at all distances thanks to PRECISION PROFILE® Design.^{12,14} Fitting DAILIES TOTAL1® multifocal lenses is easy, with a 2-step initial fitting process that demonstrates 80% first lens fit success,¹⁵ and 96% success with 2 lenses or fewer per eye.^{15,16}

All contact lens wearers deserve outstanding comfort and vision born from breakthrough technologies. Offer your patients the incredible benefits of Water Gradient and SmartTears® Technologies, as well as remarkable specialty optics, with the DAILIES TOTAL1® family of lenses—available now in a wide range of parameters for your patients needing sphere, multifocal or astigmatic correction!

* Breathability @ -3.00D: DAILIES TOTAL1® and DAILIES TOTAL1® Multifocal, 156 Dk/t; DAILIES TOTAL1® for Astigmatism, 127 Dk/t.

¹ Based on in vitro measurements of unworn lenses.

[†] Based on lens movement, centration and rotation at initial fitting.

1. Alcon data on file, 2021. 2. Alcon data on file, 2014. 3. Angelini TE, Nixon RM, Dunn AC, et al. Viscoelasticity and mesh-size at the surface of hydrogels characterized with microheology. *Invest Ophthalmol Vis Sci.* 2013;54:E-abstract 500. 4. Thekveili S, Qui Y, Kapoor Y, et al. Structure-property relationship of delectifcon A lenses. *Contact Lens Anterior Eye.* 2012;35(Suppl 1):e14. 5. Greiner JV, Glonek T, Korb DR, Leahy C. Phospholipids in meibomian gland secretion. *Ophthalmic Res.* 1996;28:44-49. 6. Pitt WG, Jack DR, Zhao Y, Nelson JL, Pruitt JD. Loading and release of a phospholipid from contact lenses. *Optom Vis Sci.* 2011;88:502-506. 7. Shine WE, McCulley JP. Polar lipids in human meibomian gland secretions. *Curr Eye Res.* 2003;26:89-94. 8. Michaud L, Forcier P. Comparing two different daily disposable lenses for improving discomfort related to contact lens wear. *Cont Lens Anterior Eye.* 2016;39:203-209. 9. Multi Sponsor Surveys Inc. The 2014 Gallup target market report for toric contact lenses. 10. Alcon data on file, 2021. 11. Alcon data on file, 2020. 12. Merchea M, Evans D, Kannarr S, et al. Patient and ECP satisfaction in the United States with a novel Water Gradient daily disposable multifocal contact lens. Presented at the American Optometric Association Annual Meeting, June 20-24, 2018, Denver, CO. 13. Fogt JS, Weisenberger K, Fogt N. Visual performance with multifocal contact lenses and progressive addition spectacles. *Contact Lens Anterior Eye.* 2021;101472. 14. Lemp J, Kern J. Alcon multifocal contact lenses for presbyopia correction. Paper presented at the Canadian Association of Optometrists Congress; June 28-30, 2017; Ottawa, ON. 15. Merchea M, Evans D, Kannarr S, et al. Assessing a modified fitting approach for improved multifocal contact lens fitting success. Presented at: Annual Meeting of the American Optometric Association; June 20-24, 2018; Denver, CO. 16. Bauman E, Lemp J, Kern J. Material effect on multifocal contact lens fitting of lenses of the same optical design with the same fitting guide. Presented at: British Contact Lens Association Clinical Conference & Exhibition; June 9-11, 2017; Liverpool, UK.

Important Safety Information

See product instructions for complete wear, care, and safety information.

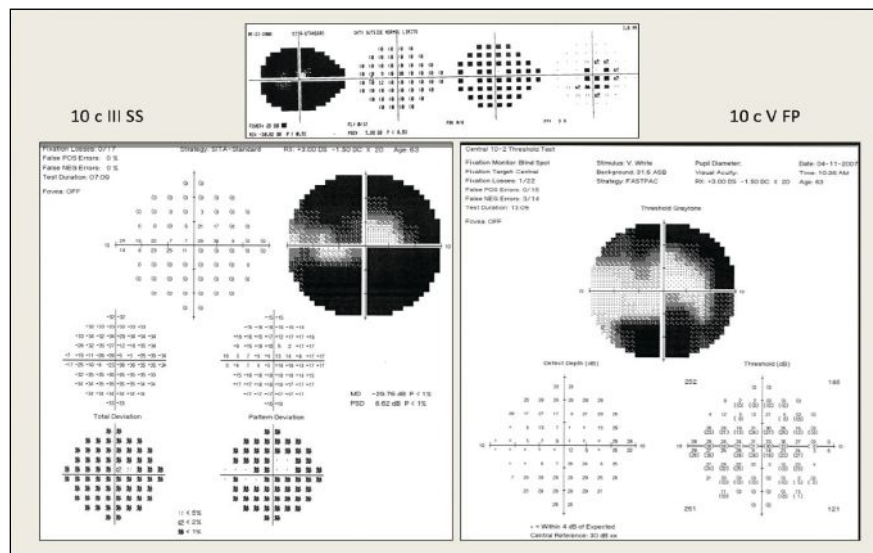
in the low teens may be appropriate at first for a severe glaucoma patient, but if their VF shows consistent progressive defects, a more aggressive treatment goal needs to be implemented.

In addition to setting appropriate treatment goals for each patient, it is also important to comanage any surgical candidates with ophthalmology, a process that should begin as soon as possible to avoid consequential delays. It is beneficial for optometrists treating glaucoma to establish a good relationship and frequent communication with a glaucoma surgeon to encourage more timely and effective intervention as needed. In cases where IOP is inadequately controlled on maximum-tolerated medical therapy and still elevated after laser intervention, prompt referral is necessary for consideration of incisional glaucoma surgery such as a trabeculectomy or tube shunt surgery.

Topical Therapy Considerations

Clinicians must acknowledge the critical role that the patient plays in their own glaucoma treatment success. In early- to moderate-stage glaucoma, it is easier for patients to keep track of their eye medication(s) and be compliant with their therapy, which typically only involves one or two drops. In severe glaucoma, it is more common for patients to be on multiple drops. As we know, compliance becomes more difficult with more complex eye drop regimens.⁸ In these situations, it is wise to consider fixed-dose combination agents to increase adherence. Switching to combination drop therapy when the patient requires more than a single agent to lower IOP will significantly simplify the regimen and decrease the number of trips to the pharmacy to increase the likelihood of better outcomes overall.

It is also important to consider the ocular surface when treating glaucoma. The majority of glaucoma drops contain benzalkonium chloride, which can be damaging to the ocular surface and lead to or exacerbate existing ocular surface disease (OSD).⁹ This outcome



Pictured here is 24-2 testing (top) and 10-2 testing (bottom left). Fastpac size V stimulus testing allows for better monitoring of the central remaining points (bottom right).

is of significant concern in the elderly population, which is already at risk for dry eye disease.⁹ Approximately 40% to 59% of glaucoma patients on topical medications have OSD, which can significantly impact their quality of life.¹⁰ Using a preservative-free formulation can help decrease ocular surface toxicity and irritation and improve patient satisfaction with the recommended therapy.¹¹ By encouraging patient compliance with the prescribed regimen, the likelihood of incisional surgery decreases. As glaucoma surgery carries risks of failure, infection and vision loss, the importance of a well-tolerated topical regimen cannot be understated.

Takeaways

Glaucoma is the second leading cause of blindness worldwide, and about three million Americans currently live with it, a number that will grow as the population ages and lives longer.¹⁰ This is a disease that optometrists encounter regularly and may find rewarding to manage as it establishes a lifelong relationship between the doctor and the patient, whose quality of life may improve with the appropriate treatment regimen.

It is important that optometrists who manage glaucoma understand the full spectrum of the disease and

know how to best implement diagnostic tools to supplement clinical examination, especially in advanced cases when time is even more of the essence. Understanding when it's necessary to refer for laser or surgical intervention is equally as important to treatment success. ■

1. Glaucoma quick reference guide. American Academy of Ophthalmology. www.aao.org/assets/706a6588-8001-4155-a24b-3eddad58c0f7/635672098930070000/glaucoma-icd-10-quick-reference-guide-pdf. Accessed June 3, 2022.
2. Bowd C, Zangwill LM, Weinreb RN, et al. Estimating optical coherence tomography structural measurement floors to improve detection of progression in advanced glaucoma. *Am J Ophthalmol*. 2017;175:37-44.
3. Francis BA, Chopra V. Glaucoma progression detection, part 2. *Ophthalmology Management*. November 1, 2018. [Epub ahead of print].
4. Lavinsky F, Wu M, Schuman JS, et al. Can macula and optic nerve head parameters detect glaucoma progression in eyes with advanced circumpapillary retinal nerve fiber layer damage? *Ophthalmology*. 2018;125(12):1907-12.
5. Rao HL, Begum VU, Khadka D, et al. Comparing glaucoma progression on 24-2 and 10-2 visual field examinations. *PLoS One*. 2015;10(5):e0127233.
6. Phu J, Kalloniatis M. Ability of 24-2C and 24-2 grids to identify central visual field defects and structure-function concordance in glaucoma and suspects. *Am J Ophthalmol*. 2020;219:317-31.
7. The Agis Investigators. The Advanced Glaucoma Intervention Study (AGIS): 7. The relationship between control of intraocular pressure and visual field deterioration. *Am J Ophthalmol*. 2000;130(4):429-40.
8. Newman-Casey PA, Robin AL, Blachley T, et al. The most common barriers to glaucoma medication adherence: a cross-sectional survey. *Ophthalmology*. 2015;122(7):1308-16.
9. Bonniard AA, Yeung JY, Chan CC, Birt CM. Ocular surface toxicity from glaucoma topical medications and associated preservatives such as benzalkonium chloride (BAK). *Expert Opin Drug Metab Toxicol*. 2016;12(11):1279-89.
10. Zhang X, Vadoothker S, Munir WM, Saeedi O. Ocular surface disease and glaucoma medications: a clinical approach. *Eye Contact Lens*. 2019;45(1):1-18.
11. Thygesen J. Glaucoma therapy: preservative-free for all? *Clinical Ophthalmol*. 2018;12:707-17.

Photo: Peter Lalle, OD

The availability of products and features may vary by country.
OCULUS reserves the right to change product specifications and design.

Keep the Light On

with OCULUS Perimeters



OCULUS Easyfield® C: Small and clever
A complete perimeter with no dark room required

The OCULUS Easyfield® C provides quick screening and full threshold exams without the need of a dark room. Its network compatibility and small footprint provide flexibility even in confined spaces.



Scan here or visit
www.oculususa.com

Toll free 888-519-5375
ads@oculususa.com



ON THE THRESHOLD: NEW VF TESTING TECH

This exciting development has numerous potential possibilities for improving optometric care.



BY MELANIE ANSPAUGH, OD
SCOTTSDALE, AZ

Glaucoma is one of the leading causes of blindness in the United States, affects more than three million Americans and accounts for more than 17 million office visits a year.¹ With an aging and increasingly diverse population, optometrists will see more glaucoma in their offices and need to be prepared.

In terms of managing and diagnosing glaucoma, standard automated perimetry (SAP) has been the gold standard for decades. Whether the progressive loss of retinal ganglion cells in our glaucoma patients is from compressive forces, vascular ischemia or a combination of both pathophysiologicals, axonal disruption is quantifiable using diagnostic perimetry and optical coherence tomography (OCT).

Newer technologies such as OCT allow measurement of retinal nerve fiber and ganglion cell layer thicknesses, thus visualizing structural changes from glaucoma that may present prior to functional loss, allowing for earlier detection. However, to evaluate functional change, SAP remains standard

of care, making it a crucial tool for managing glaucoma.

Standard automated perimetry devices such as the Humphrey Field Analyzer (HFA; Zeiss) and Octopus (Haag-Streit) are cornerstones in most optometric offices. However, the instrument takes up office space, must be isolated to a dark room and is dependent on proper instructions and patient positioning. This makes testing difficult and time consuming for staff and patients. In addition, certain patients may be precluded from visual field testing (*i.e.*, those who have limited mobility or are home-bound).

With recent technological advances, alternatives to SAP have become available. The increased presence of headset technology in eyecare could make it easier for healthcare providers to individualize management.² These tools can be adapted to a patient instead of requiring the patients to conform to analog instruments.

Visual information analysis with headset-based visual fields is an exciting technology with numerous possibilities for improving optometric care.³

This device's portability may contribute to increased efficiency in a typical practice; multiple test subjects can be

assessed simultaneously using the same server in a single, well compartmentalized room, by a single technician. Doctor-patient interactions may also change from centralized to more individual settings, providing more options for providers to reach marginalized and underserved communities.

Several portable visual field testing options are described below. As independent data is scarce, bear in mind that much of what's discussed comes from company sources. We also review independent research when possible.

VisuAll (Olleyes)

This device is a portable virtual reality headset with a wireless, Bluetooth-enabled remote to record patient responses. It's available in three models: VisuAll ETS and VisuAll S for office use and VisuAll H for home use.⁴

The test can be performed in any position or lighting condition. No trial lenses are needed as patients can wear their own glasses.⁴ The head-mounted display is split into two halves, one for each eye, eliminating the need for patching. Patient testing instructions are given in an easy-to-follow video.

Gaze tracking and fixation monitoring are built into the application. The

About
the author

Dr. Anspaugh practices medical optometry at Eye Physicians and Surgeons of Arizona, an ophthalmology clinic specializing in glaucoma and cataracts. She is a Fellow of the American Academy of Optometry. She has no financial disclosures.

patient will be prompted to return to central fixation and stimuli presentations are stopped until fixation is corrected.

Results from the VisuAll are displayed through an application that can be downloaded onto a laptop, smartphone or tablet for the doctor's interpretation. The test result layout is similar to the HFA, making interpretation familiar and straightforward.⁵

In addition to visual field testing, VisuAll offers color vision testing, visual acuity testing, contrast sensitivity, extraocular motility and pupillometry. The company says that visual field testing options range from the most common protocols (24-2, 30-2, 10-2) to screening tests. Testing time is about three minutes for threshold and 45 seconds for screenings.⁴

When comparing the 24-2 option of the VisuAll with our standard perimeters (*i.e.*, Humphrey and Octopus), there are a lot of similarities. The background luminance of the VisuAll is 10cd/m², which is the same as both the Humphrey and Octopus. White-on-white stimuli are presented at a duration of 200ms. This matches with the Humphrey but varies from the Octopus at 100ms.

The VisuAll presents 50 test locations, which is slightly less than the Humphrey at 54 and the Octopus at 59. Stimuli are presented in a 6° grid pattern across the horizontal and vertical midlines.² This is identical to the Humphrey but varies from the Octopus, which presents stimuli in an unequal spacing pattern, more dense centrally and more spaced out peripherally.

Research review. As it stands, information from clinical trials regarding the VisuAll's performance is positive in regards to its performance compared with traditional SAP. In a limited study out of the Wills Eye Institute, 25 healthy eyes vs. 26 controlled mild/moderate glaucoma eyes were evaluated with a 24-2 test with both the VisuAll and HFA. Testing time for the VisuAll was on average three minutes longer for both healthy and glaucomatous eyes than the HFA. VisuAll runs a full

threshold, which takes more time than a SITA standard. The mean sensitivity of the whole visual field and the sensitivity of each individual quadrant in the two devices were compared with excellent correlation.^{5,6}

Moreover, another study, done at Glaucoma Associates of Texas, was presented at the American Glaucoma Society (AGS) meeting in March 2022.⁷ It looked at early detection of retinal dysfunction in eyes with pre-perimetric glaucoma using a virtual reality platform. Over 1,700 patients were tested with the VisuAll; 128 were diagnosed with pre-perimetric open-angle glaucoma. The VisuAll was then compared with the HFA and with the corresponding ganglion cell complex areas on OCT to evaluate structure-function relationship of both instruments. Results showed that the VisuAll and HFA were similar in detecting decreased retinal sensitivity of the superior hemifield that correlated to the corresponding inferior ganglion cell complex thickness.⁷ Overall, VisuAll detected a greater number of visual field defects than the HFA in eyes with pre-perimetric glaucoma.⁷

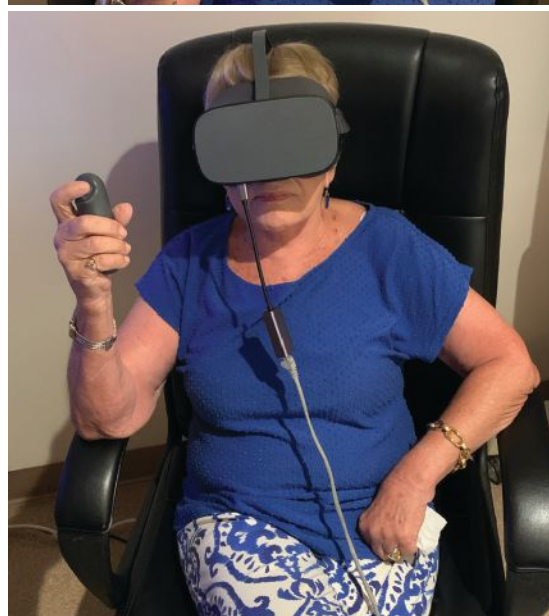re:Vive (Heru)

Heru is a company founded by physicians and researchers at Bascom Palmer Eye Institute. Two versions of this device currently exist: re:Vive 1.0 and the updated 2.0. The unit consists of a lightweight headset and wireless clicker to record patient responses. A software application can be downloaded onto a portable device such as a laptop or tablet for result viewing.⁸

The re:Vive continually tells the patient how to take

the test through a function called Virtual Personality to educate the patient on test-taking instructions. It also has another function called Active Track that corrects for fixation and gaze tracking errors using cameras in the device. A stimulus is only presented if the patient is properly fixating. In addition, if a screening test is being run and the patient is struggling, the re:Vive will automatically convert the test into a full threshold.

No trial lenses are needed. The re:Vive presents the stimuli at optical infinity, thus presbyopic changes are of no consequence.



This VF headset and remote allows patients to not hunch forward, as in a traditional SAP device. They are free to move their head and neck, sit back in a chair and enjoy being more comfortable.

Photos: James L. Fanelli, OD

Current available visual field tests include: 24-2, 10-2, suprathreshold and foveal threshold. Stimuli are bright on a dark background with a luminance of 10cd/m². The testing results layout is similar to the HFA, again making interpretation straightforward.

The re:Vive 2.0 model added additional modes, including color vision testing (screener Ishihara plates, extended Farnsworth D-15) and contrast sensitivity testing. Clinical trials testing this model are still in progress.

Research review. When compared with the HFA, threshold testing time for the re:Vive is 4.3 minutes as opposed to five minutes. One study noted its repeatability and that mean deviation has a strong correlation.⁹

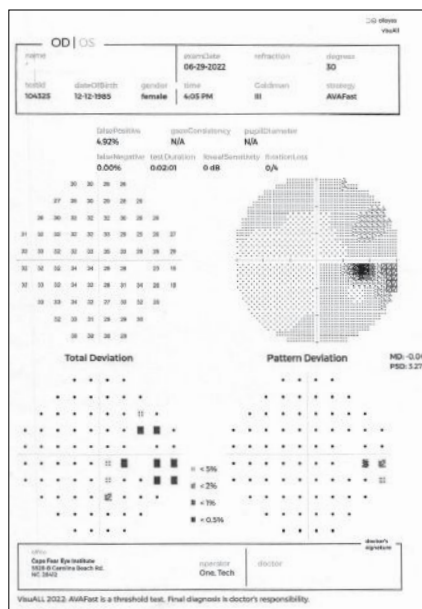
To further confirm the accuracy of the Heru Threshold test strategy, a prospective study comparing the HFA 24-2 with re:Vive by Heru 24-2 was performed. The study included 47 eyes (21 healthy and 26 patients with glaucoma and neuro-ophthalmic diseases) and found strong correlations between the Heru visual field mean deviation (MD) and threshold values and those of HFA in normal eyes and eyes with glaucoma and other pathologies.¹⁰ That study also found excellent reproducibility on normal and pathologic eyes, respectively. The device's re:Imagine Threshold strategy was statistically significantly faster than the HFA SITA Standard (4.3 vs. five minutes respectively).^{9,10}

VF2000 (Micro Medical Devices)

This company launched the first virtual reality visual field headset in 2018—the VF2000 Visual Field Analyzer. MMD now offers three versions: VF2000 Focus, VF2000 G2 and VF2000 NEO. All units are composed of a lightweight headset and wireless patient response remote.¹¹

The VF2000 Focus is equipped with a technology the company calls Focus Wheel that accounts for up to seven diopters of refractive error, reducing the need for trial lenses for a significant amount of patients.¹²

The VF2000 G2 adds 4K resolution and optional vision screening tests.



The printout from the VisuAll unit is laid out exactly the same as an HFA printout to ease the transition to the new platform.

Finally, the VF2000 NEO model offers the previously mentioned features plus eye tracking technology to reduce fixation errors.^{13,14}

Interestingly, the Active Eye Tracking technology in the Neo model pauses the test if patients shut their eyes allowing for a break. Also, there is an option to use a patient's blink to measure stimuli response. This is an advantage over other devices that may allow patients with disabilities or paralysis to complete visual field testing.¹⁴

Similar to other devices, the VF2000 series offers other functionalities, such as visual acuity testing, color vision testing and contrast sensitivity testing.¹¹

Research review. A study out of Stanford University compared the VF2000 to the HFA. A total of 41 patients with known history of reliable visual field testing were selected, 28 of whom were known to have glaucoma and 13 were glaucoma suspects. MD and pattern standard deviation (PSD) were compared between both devices. Results found less than a 0.20dB difference between the VF2000 and HFA across all patients.¹⁵

Another study determined that the Palm Scan VF2000 was 100% sensitive and specific in detecting glaucoma.

However, about 28% of moderate glaucoma cases were misclassified as mild and 17% were misclassified as severe by the visual field analyzer. Furthermore, 20% of severe cases were misclassified as moderate by this instrument.¹⁶

Advanced Vision Analyzer (AVA; Elisar Vision Technologies)

This organization, based in India, has presented a device that consists of a battery operated head-mounted device with a cable-attached patient response button. The results of the test can be displayed on a laptop or tablet.¹⁷

The AVA offers foveal threshold testing, 24-2, 30-2 as well as screening tests. A fixation monitoring, eye-tracking system is included. A cloud-based software allows doctors to wirelessly print or email reports.¹⁷

Research review. Little independent information is known about this device. One study demonstrated functional equivalence between the AVA and the HFA. However, its authors noted that further studies with larger numbers of patients and detailed clinical evaluation for the actual diagnostic accuracy of the AVA were required to allow for definite conclusions.¹⁸

Melbourne Rapid Fields (MRF; M&S Technologies)

M&S recently launched a virtual reality headset with similar features as the previously mentioned devices. But in addition to the VR headset, M&S offers two versions of their MRF that can be clinic-based or home-based.¹⁹ These options allow for more frequent progression analyses as well as patient convenience.

The clinic-based MRF is a portable, space saving design consisting of a tablet with responder and surround shroud. The shroud blocks reflections, ambient lighting and maintains 33cm distance.²⁰

Tests offered include: 10-2, 24-2, 30-2 and screening. Testing time is three to four minutes per eye for a threshold 30-2. Patient instructions are given through an interactive system throughout the test. Upon completion, the results can

Photo: James L. Fanelli, OD

VF2000 FROM MICRO MEDICAL DEVICES

THE NEW STANDARD IN VISUAL FIELD TESTING

- ✓ 3 Available Models
- ✓ 4 CPT Codes
- ✓ 20+ Testing Protocols



THE PATENTED VR VISUAL FIELD DEVICE

Micro Medical Devices was the first to bring portable, wearable visual field testing equipment to the eye care industry and has continued to innovate on this proprietary technology ever since. Today, we offer three models that provide unique features to fit every set of clinical requirements and continue to be among the most reliable devices on the market.



PORTABILITY

Can be used anywhere in your practice or in the field, with or without a network connection.




ACCESSIBILITY

Comfortable to use for *any* patient and eligible for a 50% ADA Tax Credit.



PRACTICE EFFICIENCY

See more patients in less time with a versatile array of testing protocols and self-guided operation.



Results “in perfect agreement” with results from the HFA in clinical comparisons.

WHAT YOUR COLLEAGUES ARE SAYING ABOUT VF2000 TECHNOLOGY



ON EFFICIENCY:

"The instrument takes up very little space and it's portable, so you can take it into exam rooms rather than patients moving around the clinic."

SARAH MACIVER, OD



ON EASE OF USE:

"It's very quick to get my technicians up to speed. I've had techs that had no experience whatsoever and I'm able to train them in about 20 minutes."

GREG EVANS, OD



ON RELIABILITY OF RESULTS:

"Older screening devices we used before the VF2000 had a lot of false positives. This is much more accurate, reliable, and repeatable. I would never go back to those units."

BABAK KAMKAR, OD

VF2000 FOCUS

- ✓ 20+ VF Patterns
- ✓ Adjustable focus wheel practically eliminates the need for trial lenses



VF2000 G2

- ✓ 20+ VF Patterns
- ✓ Plus optional add-on modules (stereopsis, contrast sensitivity, visual acuity, complex color testing, and D15 color testing)

VF2000 NEO

- ✓ 20+ VF Patterns, all modules available to G2 plus Pupillometry add-on available.
- ✓ Active Eye Tracking to reduce fixation loss for the most reliable results



TRY THE MODEL OF YOUR CHOICE FREE FOR 30 DAYS

Scan here, visit micromedinc.com, or call toll-free: **866-806-3817**



be saved to a HIPAA-compliant cloud-based storage, saved as a PDF, printed or integrated into an EMR.

In a 2016 study, 90 eyes were tested using the MRF vs. SITA standard 24-2 HFA. Each test was run twice to establish repeatability. In the cohort, 12 eyes were healthy and 78 were glaucomatous ranging from mild to moderate stage. Results showed shorter test durations on the MRF vs. HFA (5.7 minutes vs 6.3). The MRF had a high correlation with HFA on MD and PSD. In addition, repeatability of MRF highly corresponded to the HFA. The overall conclusion was that there was a strong correlation between outcomes and repeatability between the two devices.²¹

With the web-based Melbourne Rapid Fields, the software application is emailed through a secure link. The patient opens the link from the comfort of their home on a computer or tablet to complete a visual field test. The patient follows the prompts given to fixate appropriately on the stimuli presented. The results are immediately transmitted to the doctor.²²

In 2021, M&S Technologies announced its new device, the Smart System Virtuality Reality Headset. It will provide accurate 10-2, 24-2 and 30-2 visual field and contour stereo testing. The headset is purported to be adaptable to add many of the Smart System vision testing modules.²³

On the Horizon

The objectiveField Analyzer (OFA) by Konan Medical is not currently commercially available. The company details that the device works by analyzing pupillary responses to multifocal stimuli using infrared cameras. Responses are measured using something the company calls “clustered volley,” a multifocal pupil objective perimetry method.²⁴

Multifocal stimuli are arranged in a dartboard layout consisting of 44 test regions per eye. The OFA presents dichoptic multifocal stimuli to both eyes, measuring direct and consensual responses from each eye concurrently. The company asserts that the patient

pattern deviation) match up pretty well, and this has been validated clinically.¹

From a billing perspective, the VR technology carries the same criteria, and CPT coding as does standard field testing, depending on the strategy used (screening or threshold field studies). Furthermore, available tests include 30-2, 24-2, 10-2, neuro fields and ptosis fields. Those account for all of the strategies used in my clinic. CPT coding is the same as standard field testing, and reimbursement is the same.

The learning curve for my techs to operate the instrument was very short, and the device has verbal instructions in several languages for patients, making patient learning time very short. Conveniently, the instrument also performs other tests, such as visual acuities, pupillometry and color vision, lending itself to a pretesting suite of tests that can be performed in the office before the physician sees the patient. In fact, we just acquired a second unit to begin using it in this regard; the tech sets the patient up with the headset and leaves to begin evaluating a second patient while the first undergoes the series of programmed tests, reducing one-on-one tech/patient time.

I no longer feel that I am beating up patients every time I need another field to follow their glaucoma or neuro-ophthalmology problem. I don't experience their sighs or exasperation with the thought of a subsequent test. They actually enjoy the new format, believe it or not. Just as important, I get reliable data I can use to effectively manage the patient precisely.

Disclosure: Dr. Fanelli has consulted with VisuAll on this visual field unit.

1. Razeghinejad R, Gonzalez-Garcia A, Myers JS, Katz LJ. Preliminary report on a novel virtual reality perimeter compared with standard automated perimetry. *J Glaucoma.* 2021;30(1):17-23.5.



INCORPORATING VR VISUAL FIELDS INTO A BUSY OFFICE

By James L. Fanelli, OD

Director of the Cape Fear Eye Institute, Wilmington, NC.

We are now a bit over six months into using virtual reality (VR) field testing in our office using the VisuAll Olleyes VR field unit. To say this has been a game changer is an understatement.

My practice is heavily glaucoma- and neuro-ophthalmology-based, which in turn generates a very significant number of VF tests each day. Prior to the addition of the Olleyes unit, we were running two separate VF instruments, and those machines were kept pretty busy each day. With the addition of this VR field unit, several metrics have changed, for the better.

From a logistics perspective, the VisuAll is mobile, portable and small. It can be used anywhere in your office and does not require a dedicated VF room. More often than not, the patient undergoes testing in the dilation/hold area in the patient care section of the office. It does not need to be completed in a pretest or exam room. That is very different from traditional field testing space requirements.

From a patient experience perspective, the effect of adopting this technology has been huge, especially in the glaucoma population. These patients are used to having periodic VF tests, and I'd say that very few of them actually look forward to taking the test. While I've known for years many patients' reticence to taking VFs, I always imagined it was because they thought the test was boring or simply difficult to take. To my surprise, the number of patients who've completed the Olleyes testing who have expressed subdued happiness has been huge. Every day, unsolicited positive

responses come from patients having completed the testing. But what I found most interesting is the common theme of patient comfort; they don't need to hunch forward and remain stationary in a traditional field device. The are free to move their head and neck, sit back in a comfortable chair and enjoy not being immobile. It makes perfect sense, and I didn't realize that was the biggest hurdle my patients had with traditional field units. Testing time is also greatly reduced, as full threshold field testing is done binocularly using a novel method, further facilitating patient acceptance.

From a reliability perspective, having a large number of patients in clinic with chronic disease processes and serial fields over many years, of utmost concern to me was the reliability and reproducibility of test results. Of course, when one moves from one VF platform to another, data conversion may not exist. Establishing a new baseline is rather easy with the VisuAll unit; after the field tests, baseline data can be generated. Certainly, the first one or two fields need to be manually compared with the previous field device you were using, but with greater patient acceptance of this technology, getting to that threshold of three tests is relatively painless. Fortunately, I've been very pleased with the reproducibility of field defects seen in both patients with advanced and mild disease, when comparing older technology to the newer tools. While the field printouts look similar to a standard HFA field printout, the devil is in the details. And conveniently, the raw data (e.g., decibel values,

THE NEW NEI STUDY IS IN:

6,351 EYES.

10 YEARS OF DATA.

1 PROVEN FORMULA.



The NEI reconfirms its recommendation of a specific nutrient formulation to help reduce the risk of AMD progression.*†

Now there is 10 years of data from the National Eye Institute's AREDS2 Follow-on Study that supports the AREDS2 formulation.² This exact nutrient formula is contained in PreserVision AREDS 2 eye vitamins. In fact, PreserVision was the brand used in the last 5 years of the NEI's 10-year follow-on study.

Scan and see the data for yourself. Order your samples and patient tools: 1-855-54BL-OTC (1-855-542-5682)



BAUSCH + LOMB

PreserVision is a trademark of Bausch & Lomb Incorporated or its affiliates. AREDS and AREDS2 are registered trademarks of the United States Department of Health and Human Services (HHS). © 2022 Bausch & Lomb Incorporated or its affiliates. PV2.0664.USA.21

2 Chew, E.Y. et al. 2022. The Long-term effects of adding Lutetin-Zeaxanthin and Omega-3 Fatty Acids to the AREDS Supplements on Age-Related Macular Degeneration. [Unpublished Manuscript] The AREDS2 Research Group/National Eye Institute.

*These statements have not been evaluated by the Food and Drug Administration. These products are not intended to diagnose, treat, cure or prevent any disease.

† Based on the AREDS and AREDS2 clinical studies

‡ In patients with moderate-to-advanced Age-related Macular Degeneration (AMD)

1 Data on file for #1 Doctor Recommended Brand, Bausch + Lomb

will find this comfortable and appreciate having the test completed quickly and without need for user input.²⁵

The initial technical specifications state that a macular, 24° and 30° test are available. A 30° test that is equivalent to a 30-2 takes seven minutes to test each eye concurrently. Trial lenses are needed: -3.00D, +3.00D, -6.00D, +6.00D, -9.00D, +9.00D. Background luminance is 10cd/m².

The ObjectiveField Analyzer is not a portable device. Thus, it retains the attendant disadvantages of traditional perimeters in that aspect. However, its clinical applications extend beyond perimetric evaluation.

Researchers in Australia have tested prototypes of this device. One study determined its ability to diagnose and monitor multiple sclerosis in early-stage disease.²⁶ Another study determined that the OFA might be a useful tool for assessing retinal function, detecting altered sensitivity and delay even before detectable structural changes. Peripheral macular regional thickness was more correlated with the device's sensitivity and delay than the central macula. Thus, peripheral macular health may have higher prognostic value than central retina.²⁷

Discussion

Virtual reality visual field devices offer much promise and some genuinely new ideas. The advantages over SAP are tremendous. These portable devices can be used anywhere in the office without staff supervision, freeing up office space and reducing staffing challenges. Moreover, the application's simplicity may increase clinical efficiency, allowing practices to administer more field tests per patient, thus improving accuracy over time. The removal of patching and trial lenses make test administration much easier for the patient, and built-in gaze tracking and fixation monitoring enables better reliability.

In addition, these mobile technologies have the potential to help provide higher quality eye care to limited mobility patients, nursing home and homebound patients, medical mis-

sions and community-based healthcare centers.

As with any new technology, more clinical trials and studies are needed, particularly with larger sample sizes. The early data that is available now shows strong correlation and repeatability with standard automated perimeters. More compelling, however, would be independent studies that document the capabilities of these devices in detecting disease progression—something sorely lacking in the current literature.

Besides limited data, another potential disadvantage of the portable devices is lack of stimulus presentation options. For reduced visual acuity and moderate/severe glaucoma patients, a stimulus V is needed for better accuracy in following glaucoma progression. Stimulus III presentation is the most common option on most of the portable devices.

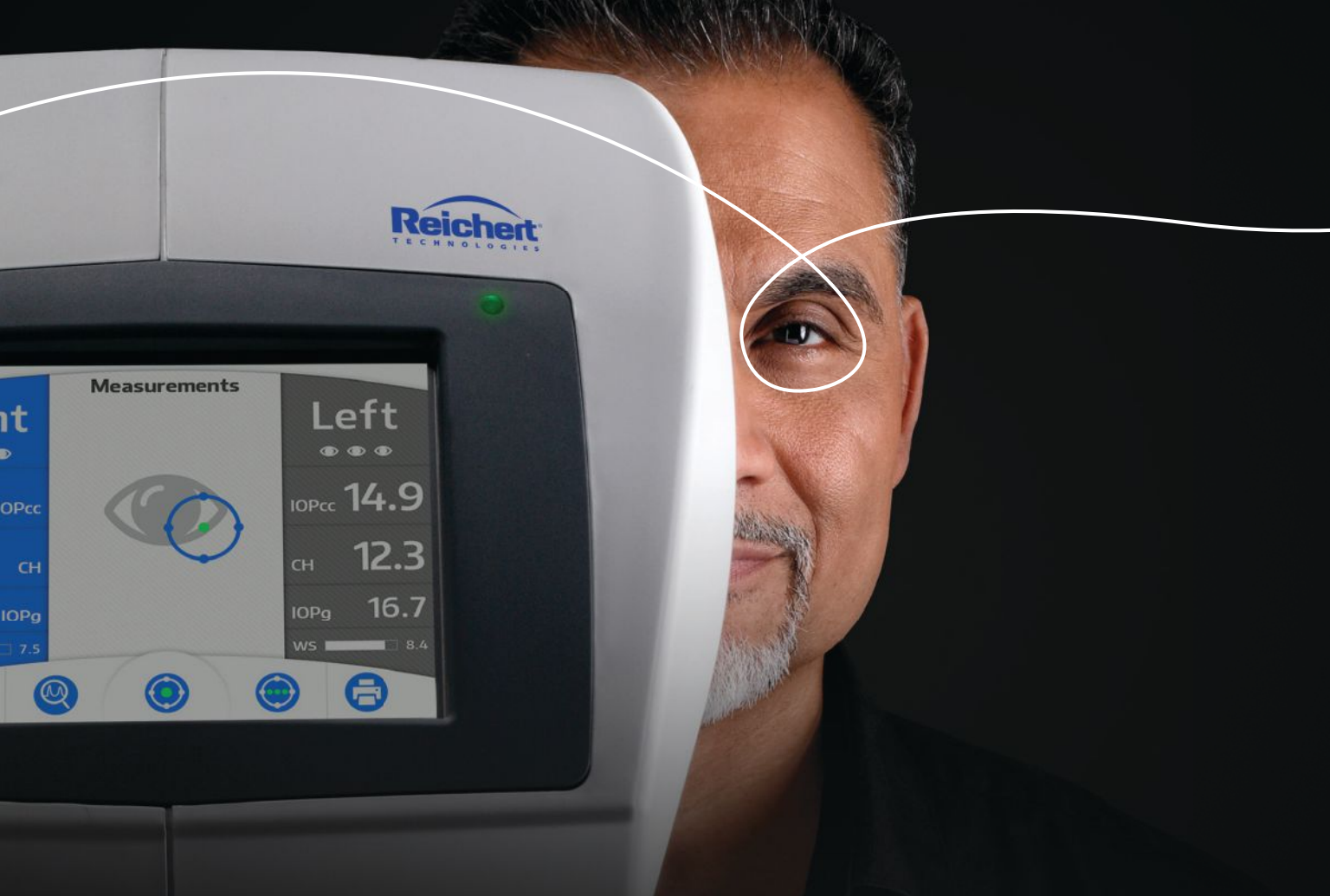In addition, all the portable devices offer numerous other testing capabilities such as contrast sensitivity, color vision and visual acuities. Is it worth having an all-in-one device, but not have its merit verified for a long time? If all pre-existing office equipment were replaced with headset-based testers, what would happen if the device malfunctioned? Of course these are hypotheticals, but something to ponder.

Portable headsets have the potential to upgrade and improve a tedious aspect of eye care. However, at this time, I feel not enough independent data is available to comfortably start debulking our clinics of our standard perimeters.

This exciting technology has the ability to offer more advantages than disadvantages over traditional standard automated perimeters. As more research data emerges, our options for treating and managing glaucoma will continue to grow. ■

1. Centers for Disease Control and Prevention. Don't let glaucoma steal your sight! Vision Health Institute. November 24, 2020. www.cdc.gov/visionhealth/resources/features/glaucoma-awareness.html. Accessed June 1, 2022.
2. Montelongo M, Gonzalez A, Morgenstern F, Donahue SP, Groth SL. A Virtual Reality-Based Automated Perimeter, Device, and Pilot Study. *Transl Vis Sci Technol.* 2021;10(3):20.
3. Soans RS, Renken RJ, John J, et al. Patients Prefer a virtual reality approach over a similarly performing screen-based approach for continuous oculomotor-based screening of glaucomatous and neuro-ophthalmological visual field defects. *Front Neurosci.* 2021;15:745355.

4. Olleyes. Olleyes virtual visual field products. olleyes.com. Accessed June 1, 2022.
5. Razeghinejad R, Shukla AG. In the field. *The Ophthalmologist.* August 25, 2020. theophthalmologist.com/subspecialties/in-the-field. Accessed June 1, 2022.
6. Razeghinejad R, Gonzalez-Garcia A, Myers JS, Katz LJ. Preliminary report on a novel virtual reality perimeter compared with standard automated perimetry. *J Glaucoma.* 2021;30(1):17-23.
7. Grover DS, Tolman A, Ali A, Fellman RL. Early detection of retinal dysfunction in eyes with pre-perimetric glaucoma using a virtual reality platform. Poster presented at American Glaucoma Society Annual Meeting. March 2022. olleyes.com/wp-content/uploads/2022/03/AGS-2022-GAT-poster.pdf. Accessed June 1, 2022.
8. Heru. Rethinking glaucoma management using wearable diagnostics from Heru reVive visual field. www.seeheru.com/rethinking-glaucoma-management-using-wearable-diagnostics-from-heru-revive-visual-field. Accessed June 1, 2022.
9. Goldbach AH, Shousha MA, Duque C, et al. Visual field measurements using Heru Visual Field Multi-platform application downloaded on two different commercially available augmented reality device. ARVO Annual Meeting 2021.
10. Kashem R, Godlbach AH, Elsayy A, et al. Comparison of Heru Visual field as a cloud based artificial intelligence-powered software application downloadable on commercial augmented reality headset with Humphrey Field Analyzer SITA Standard. ARVO Annual Meeting 2021.
11. Micro Medical Devices. A virtual reality visual field headset for the modern practice. micromedinc.com/vr-visual-field-test-headset. Accessed June 1, 2022.
12. Micro Medical Devices. Visual field analyzer -VF2000 Focus. micromedinc.com/vf2000-visual-field-analyzer. Accessed June 1, 2022.
13. Micro Medical Devices. The next evolution of the visual test machine -G2. micromedinc.com/VF2000-g2. Accessed June 1, 2022.
14. Micro Medical Devices. The premium virtual reality visual field device -Neo. micromedinc.com/VF2000-neo. Accessed June 1, 2022.
15. Tran E, Wan L, Yan W, et al. Comparison of virtual reality (PalmScan VF2000) visual fields analyzer with Humphrey visual field in glaucoma patients. *Invest Ophthalmol Vis Sci.* 2020;61:3893.
16. Shetty V, Sankhe P, Haldipurkar SS, et al. Diagnostic performance of the PalmScan VF2000 Virtual Reality Visual Field Analyzer for identification and classification of glaucoma. *J Ophthalmic Vis Res.* 2022;17(1):33-41.
17. Elisar Vision Technology. AVA Advanced Vision Analyzer. www.elisar.com/products. Accessed June 1, 2022.
18. Narang P, Agarwal A, Srinivasan M, Agarwal A. Advanced Vision Analyzer - virtual reality perimeter: device validation, functional correlation and comparison with Humphrey Field Analyzer. *Ophthalmol Sci.* 2021;1(2):100035.
19. M&S Technologies. Melbourne Rapid Fields (MRF). www.mstech-eyes.com/products/category/melbourne-rapid-fields. Accessed June 1, 2022.
20. M&S Technologies. In-clinic visual field testing. www.mstech-eyes.com/products/detail/melbourne-rapid-fields. Accessed June 1, 2022.
21. Kong YX, He M, Crowston JG, Vingrys AJ. A comparison of perimetric results from a tablet perimeter and Humphrey Field Analyzer in glaucoma patients. *Transl Vis Sci Technol.* 2016;5(6):2.
22. M&S Technologies. Web-based visual field testing. www.mstech-eyes.com/products/detail/mrfi-web-based. Accessed June 1, 2022.
23. M&S Technologies. M&S Technologies launches the Smart System virtual reality headset including Critical Eye Tracking. www.mstech-eyes.com/news/story/ms-technologies-launches-the-smart-system-virtual-reality-headset-including. August 2, 2021. Accessed June 6, 2022.
24. Konan Medical. ObjectiveField frequently asked questions & specifications. www.konanmedical.com/ofa-specs-faq. Accessed June 6, 2022.
25. Konan Medical. ObjectiveField objective field analyzer (OFA). www.konanmedical.com/objectivefield. Accessed June 6, 2022.
26. Carle C, Maddess T, Baird-Gunning J, et al. Diagnostic power of rapid objective visual testing of multiple sclerosis patients. *Invest. Ophthalmol Vis Sci.* 2021;62(8):2420.
27. Rai BB, Maddess T, Carle CF, et al. Comparing Objective perimetry, matrix perimetry and regional retinal thickness in mild diabetic macular edema. *Transl Vis Sci Technol.* 2021;10(13):32.



MEASURE BEYOND PRESSURE WITH CORNEAL HYSTERESIS.

Only **Ocular Response Analyzer® G3** measures **Corneal Hysteresis (CH)** and **Corneal Compensated IOP (IOPcc)** using patented technology to assess the unique corneal biomechanical properties of your patient. Corneal Hysteresis has shown to be an independent risk factor and more predictive of glaucoma development and progression than CCT or IOP¹⁻³. Using biomechanics, IOPcc is less influenced by corneal properties than Goldmann applanation tonometry⁴.

LEARN MORE



WATCH THE VIDEOS AT
[REICHERT.COM/ORA](https://www.reichert.com/ora)

Reichert
AMETEK

passionate about eye care

<p>Earn 2 CE Credits (COPE APPROVED)</p>
--

MIGS ON THE MOVE

A decade after their debut, these procedures now dominate the surgical sphere. Which options are most popular today, and where do ODs fit into the clinical picture?



BY JESSICA STEEN, OD
DAVIE, FL

The traditional stepwise approach in the management of patients with open-angle glaucoma—moving from medication to laser-based procedures to surgical options, requiring failure at each step prior to moving to a successive level—has been disrupted through the development and improved understanding of efficacy and risk of available options.¹⁻³ Glaucoma is the leading cause of global irreversible blindness, and despite continued research in disease pathogenesis, all available treatment options act to reduce intraocular pressure (IOP), the key treatable risk factor for disease development and progression.^{2,4}

The number of glaucoma surgical procedures in the United States has rapidly grown over time, displaying a shift toward minimally invasive glaucoma surgery (MIGS) since regulatory approval of the first device in 2012 and a general reduction in traditional filtering procedures.^{3,4-7} While traditional incisional glaucoma

procedures (*i.e.*, trabeculectomy and aqueous shunt surgery), which create subconjunctival filtration blebs, can lower IOP substantially, they are subject to a significant recovery period and carry the risk of a wide variety of vision-threatening side effects.¹⁻³

MIGS procedures act to bridge the gap between first-line options of medications and selective laser trabeculoplasty (SLT) and incisional or traditional glaucoma filtration procedures by lowering IOP while carrying a risk profile comparable to cataract surgery.^{1,2,8} While cataract surgery alone lowers IOP for a period of approximately two years, it is not recommended as a sole treatment for IOP reduction in individuals with primary open-angle glaucoma.^{1,8}

In general, most MIGS devices and procedures are on-label for the treatment of mild to moderate open-angle glaucoma and ocular hypertension for patients undergoing cataract surgery.^{1,2} At this time, while not designed to be a replacement for the aggressive IOP reduction offered by traditional filtration procedures that may be required for advanced or refractory disease, MIGS can offer

significant benefits in a widening spectrum of patients with open-angle glaucoma, including eliminating the need for IOP-lowering medication in patients with mild disease to reducing the number of medications required to delaying the need for incisional surgery in patients with more severe disease.^{1,2,6,9-11}

MIGS devices and procedures vary in their location of impact and mechanism of IOP lowering but are generally characterized by these features: they are performed using an *ab interno* approach where no conjunctival incision is made, cause minimal trauma, are efficacious in lowering IOP with a high safety profile and are characterized by rapid recovery.⁹

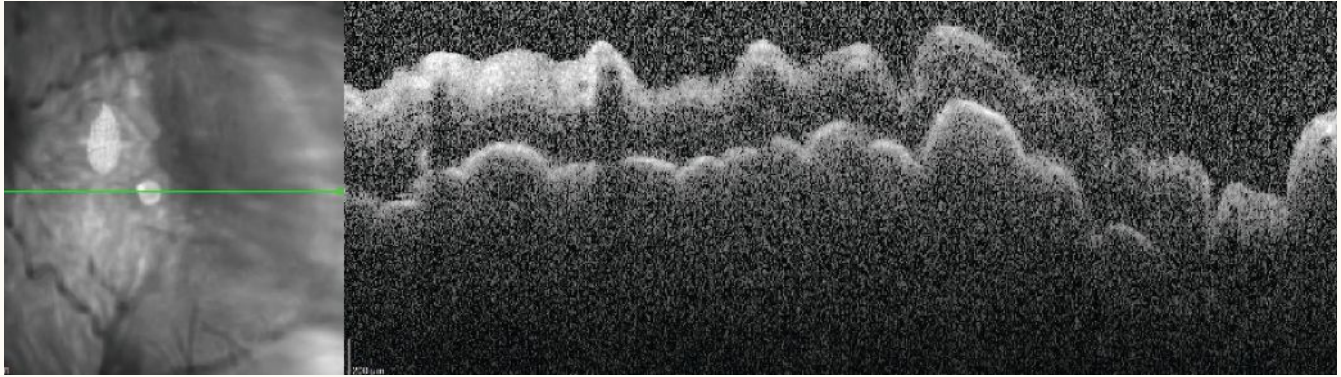Here, we discuss where MIGS stand today with a focus on understanding the physiological basis for MIGS utility, indications, efficacy and potential complications in order to optimize perioperative management.

The MIGS Menu

These device options can be challenging to digest, but, in general, most surgeries act to reduce resistance to aqueous outflow through

About the author

Dr. Steen is an attending optometrist and assistant professor at Nova Southeastern University College of Optometry. She has no financial interests to disclose.



Hypotony maculopathy on spectral-domain OCT.

procedures which may or may not form a bleb.^{2,10,11} The surgical approach to bleb-forming MIGS may be *ab interno* or *ab externo* (outside of the eye); however, *ab externo* procedures do not fit the original criteria for MIGS and will not be included in this discussion.^{2,9-11}

MIGS may enhance aqueous egress from the eye by increasing trabecular outflow through stripping, stenting or dilating tissue, enhancing uveoscleral outflow (via suprachoroidal pathways), creating a subconjunctival drainage pathway from the anterior chamber or reducing aqueous production.^{2,10,11} The latter (decreasing aqueous volume) can be accomplished through direct ablation of the ciliary process or application of energy to the ciliary body.^{2,10,11}

• Among the many MIGS options, the first device to gain regulatory

approval in the United States, the *iStent* trabecular microbypass stent, and its second-generation counterpart, the *iStent inject*, which has a modified design and consists of two stents, have accumulated the most diverse, long-term safety and efficacy data available. The *iStent* has been the most widely used device in the United States, accounting for 44% of glaucoma procedures in 2017.^{5,7}

Recently released five-year data of the *iStent inject* shows sustained IOP-lowering in eyes as a standalone procedure and in eyes undergoing cataract surgery by an average of 42% and 39%, respectively, with 46% of patients medication-free and all eyes able to maintain or reduce their medication regimen over the study period, as well as an overall reduction in the need for IOP-lower-

ing medication.¹² Five eyes required additional surgical procedures for management of IOP.¹²

Postoperative findings of mild hyphema and mild corneal edema resolved within the first week.¹³ Two eyes of one standalone *iStent inject* patient developed cataract progression by postoperative month three, and an isolated eye from the standalone group developed anterior uveitis at month 24, which resolved with topical treatment.¹² Over a five-year period, there were no stent-related complications, episodes of chronic inflammation, hypotony, endophthalmitis, Descemet's membrane compromise, obstruction, myopic shift or choroidal detachment.¹²

• The *Hydrus Microstent* has a unique design that scaffolds Schlemm's canal for approximately 90 degrees.^{14,15} Comparing the Hydrus

Release Date: July 15, 2022

Expiration Date: July 15, 2025

Estimated Time to Complete Activity: two hours

Jointly provided by the Postgraduate Institute for Medicine (PIM) and Review Education Group

Educational Objectives: After completing this activity, the participant should be better able to:

- Take the lead in the management of MIGS patients.
- Recognize MIGS utility, device indications and efficacy.
- Address and manage MIGS-related complications.
- Comanage MIGS patients effectively.

Target Audience: This activity is intended for optometrists engaged in managing glaucoma patients with MIGS.

Accreditation Statement: In support of improving patient care, this activity has been planned and implemented by PIM and the Review Education Group. PIM is jointly accredited by the Accreditation Council for Continuing Medical Education, the



Accreditation Council for Pharmacy Education and the American Nurses Credentialing Center to provide CE for the healthcare team. PIM is accredited by COPE to provide CE to optometrists.

Reviewed by: Salus University, Elkins Park, PA



Faculty/Editorial Board: Jessica Steen, OD

Credit Statement: This course is COPE-approved for two hours of CE credit. Activity #124283 and course ID 79160-GL. Check with your local state licensing board to see if this counts toward your CE requirement for relicensure.

Disclosure Statements: PIM requires faculty, planners and others in control of educational content to disclose all their financial relationships with ineligible companies. All identified conflicts of interest are thoroughly vetted and mitigated according to PIM policy. PIM is committed to providing its learners with high-quality, accredited CE activities and related materials that promote improvements or quality in healthcare and not a specific proprietary business interest of an ineligible company.

Those involved reported the following relevant financial relationships with ineligible entities related to the educational content of this CE activity: *Author:* Dr. Steen has no relevant financial interests to disclose. *Managers and Editorial Staff:* The PIM planners and managers have nothing to disclose. The Review Education Group planners, managers and editorial staff have nothing to disclose.

Microstent implanted at the time of cataract surgery with cataract surgery alone, the Hydrus group had a higher proportion of eyes with IOP less than or equal to 18mm Hg without medication use, a lower average number of glaucoma medications, a greater percentage of eyes that were medication-free through five years and fewer eyes that required additional IOP-lowering procedures.¹⁵ There were no observations of late inflammation, corneal edema or need for device removal; however, focal peripheral anterior synechiae were identified near the trabecular entry point in 15% of the Hydrus Microstent group, which was not shown to have an impact on IOP during the study period.¹⁵

While no corneal edema or decompensation was identified through five years, reduction in corneal endothelial cell loss was identified in both the microstent plus cataract surgery group and the cataract surgery group alone at a similar rate with 21% of individuals exhibiting endothelial cell loss greater than or equal to 30%

of baseline, a threshold considered as a significant change through five years with a stable rate of change noted over the study period.¹⁵ Endothelial cell loss following MIGS is of particular interest due to identified accelerated progressive endothelial cell loss previously noted following implantation of a supraciliary microstent, called *CyPass*, which resulted in voluntary market withdrawal.^{1,10,11}

• No-device trabecular bypass, or *excimer laser trabeculostomy*, uses a 308nm xenon chloride excimer laser to create 10µm to 200µm trabeculostomy openings across 90° of the angle through the trabecular meshwork and inner wall of Schlemm's canal.¹⁶ Properties of the excimer laser that make it attractive for intraocular

use include the photoablative effect with minimal thermal damage and tissue penetration.¹⁶ While approved in the European Union, a clinical trial in the United States is currently recruiting patients to evaluate safety and efficacy of the procedure.¹⁷

• Dilation of Schlemm's canal, or *ab interno canaloplasty*, resulting in breaking herniations in distal channels may be performed by flushing the canal with viscoelastic, threading a microcatheter or suture through the canal or a combination of the two procedures depending on the proprietary device used.^{18,19} Following threading of the microcatheter or suture through the canal, it may be pulled toward the center of the pupil to cleave the trabecular meshwork resulting in trabeculotomy.²⁰

While published data exists to support IOP lowering, safety and mechanism of action based on physiological understanding of outflow pathways, long-term data and randomized controlled clinical trials are lacking.¹¹ Mild postoperative hyphema is the most common complication encountered due to the necessary goniotomy needed to enter the canal, and risk of hyphema increases when trabeculotomy is performed.^{10,11,21}

• Stripping procedures using devices such as the *Trabectome* and the *Kabook Dual Blade* remove a portion of the trabecular meshwork and inner wall of Schlemm's canal to facilitate increased trabecular outflow.^{10,11,21,22} In a meta-analysis of



Two iStent inject devices.

Image: Glaukos

Aqueous Humor Dynamics for the Clinician

MIGS procedures take a more physiological approach to IOP lowering in comparison to incisional procedures or to aqueous suppressants.²⁹ To best understand where and how specific MIGS options act to lower IOP and why post-op complications may arise, let's briefly revisit aqueous humor dynamics with a specific focus on glaucoma pathology.

Once aqueous humor is produced by the epithelia at the tips of the ciliary process and flows into the anterior chamber, it leaves the eye through the trabecular (conventional) and uveoscleral (alternate) pathways.¹³ In the conventional pathway, which accounts for as much as 90% of outflow, aqueous humor crosses the superficial portions of the trabecular meshwork, moves through the corneoscleral meshwork into the juxtacanalicular tissue and passes through the inner wall of Schlemm's canal, where it encounters the greatest resistance.¹³

Once aqueous crosses into Schlemm's canal, it enters one of approximately 30 external collector channels, which are distributed unevenly—with the greatest number of collector channels found in the inferior nasal quadrant of the eye—and flows into the deep scleral plexus and the episcleral venous system.¹³

When IOP increases, such as in the majority of eyes with open-angle glaucoma, the juxtacanalicular tissue and inner wall of Schlemm's canal herniate into the ostia of collector channels, reducing their outflow capacity and further driving outflow resistance and elevating IOP.¹³ These occluded ostia seem to be of specific relevance to glaucoma treatment as glaucomatous eyes have a higher number of occluded collector channel ostia in comparison to nonglaucomatous eyes.¹³

While currently available MIGS procedures use a number of strategies for lowering IOP, including increasing trabecular and uveoscleral outflow and reducing aqueous production, the most commonly encountered procedures are aimed at the trabecular meshwork and Schlemm's canal to allow the surgeon to directly treat the areas of the eye where outflow resistance is greatest in order to restore the conventional pathway's outflow capacity.^{23,7,10,11}



Hydrus microstent placed within Schlemm's canal.

5,091 individuals who underwent Trabectome as a standalone procedure or combined phaco-Trabectome, the average IOP reduction was approximately 31% with final IOP near 15mm Hg and a reduction of IOP-lowering medication by less than one drop on average.²¹

The overall vision-threatening complication rate was less than 1%, with the most common complication identified as hyphema, which occurred up to 31 months following the procedure and was associated with transient IOP elevation.²¹ Peripheral anterior synechiae was reported in as many as 14% of cases.²¹ Less common reported complications included cyclodialysis cleft, which was identified in six instances, with one requiring surgical closure, transient hypotony (no cases persisted beyond three months) and aqueous misdirection syndrome.²¹ In patients undergoing Kahook Dual Blade, which may be performed as a standalone procedure or in combination with cataract surgery, reduction in IOP and postoperative medications is expected with a similar risk profile and complications in comparison to Trabectome.^{11,22}

- In the case of refractory open-angle glaucoma, where previously surgical treatment has failed or where further IOP lowering is required beyond maximally-tolerated medical therapy, the *Xen gel stent* implant may be considered.^{1,11,23} Xen is sometimes compared with trabeculectomy as both are filtration bleb-dependent procedures, use mitomycin C intraoperatively, have similar post-procedure follow-up care and treatment and carry a similar IOP-lowering effect, albeit Xen carries an improved safety profile.^{24,25}

Conversely to trabeculectomy, the Xen gel stent does not involve incision of the sclera and conjunctiva with on-label *ab interno* placement and does not require iridectomy or sutures.²⁵ Xen differs from the majority of MIGS procedures in its indication due to its mechanism of IOP lowering by passing the physiological outflow pathways, potential for IOP lowering by an increased risk of complication and need for close postoperative observation by the operating surgeon due to the likelihood of post-procedure intervention.²³⁻²⁵

Comparison of success rates

between MIGS presents challenges due to differences in patient characteristics, glaucoma subtype, follow-up duration, medication use, previous failed surgeries and definition of “success.” However, following Xen implantation, up to 89% of eyes had IOP less than or equal to 21mm Hg or 20% lower than baseline without requiring additional medical therapy at one year and 71% at two years, with a significant reduction in the number of post-procedure IOP-lowering medications.²⁴ Overall, IOP was reduced by 35% to a final average near 15mm Hg with a greater IOP-lowering effect identified in eyes with higher baseline IOP in the included studies which ranged in duration from 12 to 36 months.²⁴

Postoperative management of patients undergoing Xen implantation is more complex than other MIGS procedures due to the risk of complications and need for additional intervention. To limit the risk of subconjunctival fibrosis, bleb needling is considered to be a routine part of postoperative care, with most eyes undergoing needling within one month following surgery and some requiring subconjunctival 5-fluorouracil treatment.^{24,25}

Hypotony, or IOP less than 6mm Hg, may occur in up to 10% of eyes and is typically described to be transient with improvement within one month.²⁴ Hypotony-related complications include maculopathy and choroidal effusion.²³⁻²⁵ Hyphema was generally mild (less than one-third of the anterior chamber) and is reported to occur in 6% of eyes which may result in transient IOP spikes.^{24,25} Other complications following Xen implantation related to the device include occlusion, exposure, migration and bleb-related complications such as bleb leakage, blebitis and endophthalmitis.²³⁻²⁵

- Reduction in aqueous humor production using *micropulse trans-scleral laser* therapy carries a lesser risk of hypotony, pupillary mydriasis, chronic inflammation and vision loss

in comparison to standard cyclode-structive thermal procedures such as endocyclophotocoagulation and transscleral cyclophotocoagulation.²⁶

Micropulse transscleral laser therapy delivers energy to the pars plana (rather than to the pars plicata) in a series of repetitive, short pulses with incorporated rest periods to prevent reaching a cyclodestructive threshold.²⁶ It is presumed to reduce IOP through biological stimulation resulting in increased trabecular and uveoscleral outflow in addition to aqueous suppression.²⁶ Micropulse transscleral laser therapy reduces IOP gradually, with maximum IOP lowering of 31% achieved at 12 months.²⁶

Collaborative Pre-, Post-op Care

Based on the variety of procedures available and an understanding of the indications, general success rate and potential complications of MIGS, effective communication with the consultative surgeon is central to maximizing outcomes.

At the time of referral, providing the surgeon with the patient's glaucoma and ocular history—including glaucoma diagnosis (which requires careful gonioscopic evaluation), disease severity, treatment history, the general roadmap of IOP (peak, untreated pressure if available and target pressure)—and patient goals will help the surgeon in determining the optimal procedure.

If cataract is present, evaluation to determine the presence of ocular findings that may increase the complexity of surgery (*e.g.*, peripheral anterior synechiae, conjunctival scarring, zonular instability) is necessary.² While all procedures carry risks, MIGS vary in their potential IOP-lowering effect, safety profile and indications, all of which are carefully considered as part of the complex decision-making process in determining a procedure of choice.^{2,27,28}

When asked which IOP-lowering procedure American Glaucoma

Society members would choose for themselves as the patient—following need for further IOP lowering after SLT and maximizing all commercially available topical glaucoma medications—the most frequent responses, in order, were *ab interno* trabeculotomy, Xen gel stent and iStent inject, followed by trabeculectomy.²⁹ With traditional trabeculectomy being preferred by participants older than 61, in the youngest cohort of participants (between 30 and 40 years of age), the top four ranked procedures were all forms of MIGS, with trabeculectomy being ranked lower.²⁹

The procedures that surgeons may choose as a primary procedure for themselves and those they are most likely to offer a hypothetical patient in a similar setting differed.^{3,29} When analyzing surgical practice preference, 59% of individuals would offer a hypothetical patient traditional trabeculectomy with mitomycin C in 2016, where only 18% would prefer to have the same procedure performed on themselves in 2018.^{3,29} The short time period between the two studies and varying results further adds support to reflect the rapid paradigm shift in consideration of MIGS that has occurred in the United States.

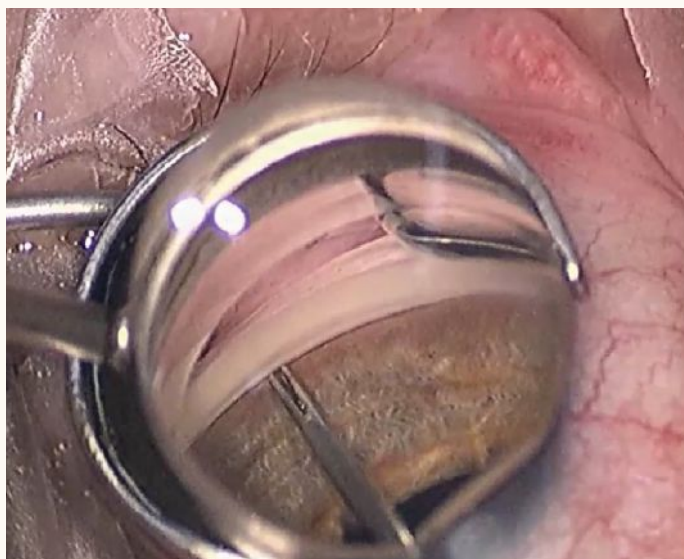Due to the relatively recent development and use of MIGS, the long-term outcomes, generally beyond five years, are not known.^{1,2} Successful postoperative care requires a collaborative relationship with direct communication between the comanaging optometrist and

surgeon. Postoperatively, patients can be expected to use the typical regimen of topical ocular medications, including prophylactic antibiotic, nonsteroidal anti-inflammatory and steroid taper, over a four-week period.^{27,28}

For individuals with mild to moderate disease undergoing MIGS strategies that target Schlemm's canal and the trabecular meshwork, IOP-lowering medications may not be stopped prior to surgery. A reduction in IOP-lowering therapy can be considered as early as one week post-op if target pressure is achieved.

Due to the risk of hypotony in the immediate postoperative period, patients undergoing bleb-forming MIGS should have IOP-lowering medications discontinued on the day of the procedure.^{24,25} The most common expected postoperative course includes mild inflammation and hyphema appearing as an anterior chamber reaction resulting in blurred vision, which is typically mild and self-limiting within the first postoperative week.²⁸

Fluctuations in IOP postoperatively can be a sign of increased inflammation, hyphema, device malposition or obstruction, wound leak and cyclodialysis cleft.^{27,28} Careful clinical examination to determine the cause



Placement of iStent inject perpendicular to the trabecular meshwork.

Photo: Justin Schweitzer, OD

followed by conservative treatment with topical steroids, cycloplegics or IOP-lowering medications may be needed. In the case of device malposition, obstruction, significant or recurrent hyphema or sustained IOP elevation, the patient should be promptly evaluated by the surgeon.³⁰

Hypotony following a canal-based procedure in the absence of wound leakage should be suspicious for cyclodialysis cleft, as these procedures do not bypass the conventional pathway. Therefore, aqueous must still overcome episcleral venous pressure to leave the eye, preventing IOP from dropping below episcleral venous pressure. Iatrogenic cyclodialysis cleft, or separation of the longitudinal fibers from the scleral spur during surgery, results in an unintentionally produced drainage pathway of aqueous from the anterior chamber directly into the suprachoroidal space.³¹

The mainstay of medical treatment for hypotony due to cyclodialysis cleft is cycloplegia to allow the ciliary muscle to relax and detached fibers to reattach to the scleral spur with consideration of increase in topical ocular steroid dosage.³¹ If conservative treatment does not close the cleft, surgical or laser therapy may be employed.³¹

While MIGS are characterized by their rapid recovery and high safety profile, patients do experience postoperative complications. While generally mild, transient and self-limiting, depending on the procedure, they may occur at a similar or higher rate than cataract surgery alone.²⁸ If a complication is identified during the post-op course, the comanaging physician should have a low threshold for intervention, and when resolution does not occur with conservative treatment, they should have the patient return to the surgeon.

The Bottom Line

Developments in the MIGS space focus primarily on enhancement of

natural physiology to reduce IOP. While not a replacement for incisional glaucoma surgeries, such as trabeculectomy or aqueous shunts, a variety of MIGS have established their safety and efficacy as a bridge between first-line therapies (*i.e.*, medications and SLT) and traditional filtering procedures. MIGS continue to expand their reach with available and developing devices, challenging the IOP-lowering potential of filtration procedures with the goal of an improved safety profile.

Comanaging providers should be familiar with available procedures and devices as well as expected results, including complications, and take a collaborative approach to pre- and post-op care. Randomized controlled clinical trials evaluating MIGS in a standardized way and evaluation of long-term durability are ongoing as the MIGS experience continues to develop. ■

1. Weinreb RN, Garway-Heath DF, Leung C, et al. Glaucoma Surgery: WGA consensus series – 11. 2019. Amsterdam, The Netherlands: Kugler Publications.

2. Fellman RL, Mattoc C, Singh K, et al. American Glaucoma Society Position Paper: Microinvasive Glaucoma Surgery. *Ophthalmol Glaucoma*. 2020;3:1-6.

3. Vinod K, Gedde SJ, Feuer WJ, et al. Practice Preferences for Glaucoma Surgery: A Survey of the American Glaucoma Society. *J Glaucoma*. 2017;26:687-93.

4. Tham YC, Li X, Wong TY, et al. Global prevalence of glaucoma and projections of glaucoma burden through 2040: a systematic review and meta-analysis. *Ophthalmology*. 2014;121:2081e90.

5. Lee JH, Ma AK, Warren JL, et al. Impact of iStent Micro-Bypass Shunt on Medicare Part B Glaucoma Surgical Expenditure. *Ophthalmol Glaucoma*. 2021;4:131-8.

6. Boland MV, Corcoran KJ, Lee AY. Changes in Performance of Glaucoma Surgeries 1994 through 2017 Based on Claims and Payment Data for United States Medicare Beneficiaries. *Ophthalmol Glaucoma*. 2021;S2589-4196:00032-6.

7. Yang SA, Mitchell W, Hall N, et al; IRIS® Registry Data Analytics Consortium. Trends and Usage Patterns of Minimally Invasive Glaucoma Surgery in the United States: IRIS® Registry Analysis 2013-2018. *Ophthalmol Glaucoma*. 2021;4:558-68.

8. Mansberger SL, Gordon MO, Jampel H, et al. Reduction in intraocular pressure after cataract extraction: the ocular hypertension treatment study. *Ophthalmology*. 2012;119:1826-31.

9. Saheb H, Ahmed II. Micro-invasive glaucoma surgery: current perspectives and future directions. *Curr Opin Ophthalmol*. 2012;23:96-104.

10. Lavia C, Dallorto L, Maule M, et al. Minimally-invasive glaucoma series (MIGS) for open angle glaucoma: a systematic review and meta-analysis. *PLoS One*. 2017;12:e0183142.

11. Nichani P, Popovic MM, Schlenker MB, et al. Micro-invasive glaucoma surgery: A review of 3476 eyes. *Surv Ophthalmol*. 2021;66:714-42.

12. Hengerer FH, Auffarth GU, Conrad-Hengerer I. iStent inject Trabecular Micro-Bypass with or Without Cataract Surgery Yields Sustained 5-Year Glaucoma Control. *Adv Ther*. 2022;39(3):1417-31.

13. Freddo T, Civan M, Gong H, et al. Aqueous humor and the dynamics of its flow: mechanisms and routes of aqueous humor drainage. *Albert and Jakobiec's Principles and Practices of Ophthalmology*. 4th edition. Springer.

14. Samet S, Ong JA, Ahmed II. Hydrus microstent implantation for surgical management of glaucoma: a review of design, efficacy and safety. *Eye Vis (Lond)* 2019; 6:32.

15. Ahmed IIK, De Francesco T, Rhee D, et al. HORIZON Investigators. Long term outcomes from the HORIZON randomized trial for a Schlemm's canal microstent in combination cataract and glaucoma surgery. *Ophthalmology*. 2022;S0161-6420(22)00160-9.

16. Durr GM, Töteberg-Harms M, Lewis R, et al. Current review of Excimer laser Trabeculotomy. *Eye Vis (Lond)*. 2020;7:24.

17. Elios Vision, Inc. Excimer laser trabeculotomy glaucoma treatment study (ELTGTs). <https://clinicaltrials.gov/ct2/show/NCT04899063>. Retrieved April 2, 2022.

18. New World Medical announces launch details for the STREAMLINE Surgical System. 2022. <https://www.new-worldmedical.com/new-world-medical-announces-launch-details-for-the-streamline-surgical-system/>.

19. Gallardo MJ. 36-Month Effectiveness of Ab-Interno Canaloplasty Standalone versus Combined with Cataract Surgery for the Treatment of Open-Angle Glaucoma. *Ophthalmol Glaucoma*. 2022;S2589-4196(22)00025-4.

20. Grover DS, Smith O, Fellman RL, et al. Gonioscopy-assisted transluminal trabeculotomy: an ab interno circumferential trabeculotomy: 24 months follow-up. *J Glaucoma* 2018;27:393-401.

21. Kaplowitz K, Bussell II, Honkanen R, et al. Review and meta-analysis of ab-interno trabeculectomy outcomes. *Br J Ophthalmol*. 2016;100(5):594-600.

22. Iwasaki K, Kakimoto H, Orii Y, et al. Long-Term Outcomes of a Kahook Dual Blade Procedure Combined with Phacoemulsification in Japanese Patients with Open-Angle Glaucoma. *J Clin Med*. 2022;11(5):1354.

23. Allergan, Inc. XEN Gel Stent (Instructions for Use), Irvine, CA: Allergan, Inc.; 2017. https://allergan-web-cdn-prod.azureedge.net/actavis/actavis/media/allergan-pdf-documents/labeling/xen/dfu_xen_glaucoma_treatment_system_us_feb2017.pdf.

24. Chen XZ, Liang ZQ, Yang KY, et al. The Outcomes of XEN Gel Stent Implantation: A Systematic Review and Meta-Analysis. *Front Med (Lausanne)*. 2022;9:804847.

25. Lewczuk K, Konopińska J, Jabłońska J, et al. XEN Glaucoma Implant for the Management of Operated Uncontrolled Glaucoma: Results and Complications during a Long-Term Follow-Up. *J Ophthalmol*. 2021;2021:2321922.

26. Bernardi E, Töteberg-Harms M. MicroPulse Transscleral Laser Therapy Demonstrates Similar Efficacy with a Superior and More Favorable Safety Profile Compared to Continuous-Wave Transscleral Cyclophotocoagulation. *J Ophthalmol*. 2022;2022:8566044.

27. Aptel F, Colin C, Kaderli S, et al. Management of postoperative inflammation after cataract and complex ocular surgeries: a systematic review and Delphi survey. *Br J Ophthalmol*. 2017;101:1-10.

28. Yook E, Vinod K, Panarelli JF. Complications of microinvasive glaucoma surgery. *Curr Opin Ophthalmol*. 2018;29:147-54.

29. Chang TC, Vanner EA, Parrish RK 2nd. Glaucoma surgery preferences when the surgeon adopts the role of the patient. *Eye (Lond)*. 2019 Oct;33:1577-83.

30. Siedlecki A, Kinariwala B, Sieminski S. Uveitis-Glaucoma-Hyphema Syndrome Following iStent Implantation. *Case Rep Ophthalmol*. 2022;13(1):82-8.

31. Ioannidis AS, Barton K. Cyclodialysis cleft: causes and repair. *Curr Opin Ophthalmol*. 2010;21(2):150-4.

OPTOMETRIC STUDY CENTER QUIZ

To obtain CE credit through the Optometric Study Center, complete the test form on the following page and return it with the \$35 fee to: Jobson Healthcare Information, LLC, Attn.: CE Processing, 395 Hudson Street, 3rd Floor New York, New York 10014. To be eligible, please return the card within three years of publication. You can also access the test form and submit your answers and payment via credit card online at revieweducationgroup.com. You must achieve a score of 70 or higher to receive credit. Allow four weeks for processing. For each Optometric Study Center course you pass, you earn two hours of credit. Please check with your state licensing board to see if this approval counts toward your CE requirement for relicensure.

1. The term "MIGS" is typically described by which of the following?
 - a. Minimally invasive glaucoma surgery.
 - b. Minor intracapsular glaucoma surgery.
 - c. Macro invasive glaucoma surgery.
 - d. Micro implant glaucoma surgery.
2. The majority of currently available MIGS devices and procedures are primarily indicated for use in patients with _____.
 - a. Chronic angle-closure glaucoma.
 - b. Mild to moderate open-angle glaucoma.
 - c. Severe open-angle glaucoma.
 - d. Neovascular glaucoma.
3. Which of these is an example of a non-bleb-forming MIGS procedure?
 - a. iStent inject.
 - b. Xen gel implant.
 - c. Kahook Dual Blade.
 - d. Endoscopic cyclophotocoagulation.
4. Which feature is part of the characterization of MIGS?
 - a. Prolonged postoperative recovery.
 - b. *Ab interno* approach.
 - c. Conjunctival incision.
 - d. Minimal effect on IOP.
5. Where is resistance to aqueous outflow greatest in the conventional outflow pathway?
 - a. In the deep scleral plexus.
 - b. In the collector channels.
 - c. In the aqueous veins.
 - d. In the inner wall of Schlemm's canal.
6. In which region is the highest concentration of collector channels found?
 - a. Inferior nasal.
 - b. Inferior temporal.
 - c. Superior nasal.
 - d. Superior temporal.
7. Hypotony following a canal-based stenting procedure in the absence of wound leak should be suspicious for _____.
 - a. Retained viscoelastic.
 - b. Steroid response.
 - c. Cyclodialysis cleft.
 - d. Hypotony is an expected finding following canal-based stenting procedures.
8. Which statement describes the expected course of mild postoperative hyphema following combined cataract surgery and canal-based MIGS?
 - a. Resolution within 30 minutes postoperatively.
 - b. Resolution within one week postoperatively.
 - c. Resolution between one and two months postoperatively.
 - d. Any amount of postoperative hyphema requires anterior chamber washout.
9. Which device or procedure results in aqueous humor bypassing the conventional outflow pathway?
 - a. Xen gel implant.
 - b. Hydrus microstent.
 - c. iStent inject.
 - d. *Ab interno* canaloplasty.
10. What is the long-term 20-year IOP-lowering effect of the Xen gel implant?
 - a. 10% reduction.
 - b. 25% reduction.
 - c. 45% reduction.
 - d. No data exists to answer this question.
11. Which procedure is an appropriate first-line therapy for the management of open-angle glaucoma?
 - a. Cataract surgery.
 - b. SLT.
 - c. Trabeculectomy.
 - d. Xen gel implant.
12. Traditional incisional glaucoma surgeries include which of these?
 - a. Cataract surgery.
 - b. *Ab interno* canaloplasty.
 - c. *Ab interno* goniotomy.
 - d. Trabeculectomy.
13. Which pressure must be overcome for aqueous humor to leave the eye via the conventional pathway?
 - a. Episcleral venous pressure.
 - b. Systolic blood pressure.
 - c. Ocular perfusion pressure.
 - d. Cerebrospinal fluid pressure.
14. Which trend accurately describes MIGS?
 - a. Prevalence of MIGS in the United States is decreasing.
 - b. Prevalence of MIGS in the United States is increasing.
 - c. Prevalence of MIGS in the United States is unchanged.
 - d. No data exists to answer this question.
15. Which feature is a key modifiable risk factor in open-angle glaucoma development and progression?
 - a. Age.
 - b. Axial length.
 - c. Stereoacuity.
 - d. IOP.
16. Which procedure is necessary for the diagnosis of primary open-angle glaucoma?
 - a. B-scan ultrasonography.
 - b. Corneal hysteresis.
 - c. Gonioscopy.
 - d. Refractive error measurement.
17. Uveoscleral outflow may be enhanced surgically by using which pathway?
 - a. The suprachoroidal pathway.
 - b. The conventional pathway.
 - c. The visual pathway.
 - d. The subconjunctival pathway.
18. Which complication has been described in five-year results of trabecular microstent insertion when performed as a standalone procedure?
 - a. Cataract development.
 - b. Hypotony.
 - c. Chronic inflammation.
 - d. Corneal decompensation.
19. Which procedure describes using a laser to create multiple openings in the trabecular meshwork and inner wall of Schlemm's canal to increase aqueous outflow without implantation of a device?
 - a. Excimer laser trabeculotomy.
 - b. *Ab interno* canaloplasty.
 - c. *Ab externo* goniotomy.
 - d. Endocyclophotocoagulation.
20. How many microstents are visible in the angle following on-label iStent inject placement?
 - a. One.
 - b. Two.
 - c. Three.
 - d. Four.

Examination Answer Sheet

MIGS on the Move

Valid for credit through July 15, 2025

Online: This exam can be taken online at revieweducationgroup.com. Upon passing the exam, you can view your results immediately and download a real-time CE certificate. You can also view your test history at any time from the website.

Directions: Select one answer for each question in the exam and completely darken the appropriate circle. A minimum score of 70% is required to earn credit.

Mail to: Jobson Healthcare Information, LLC, Attn.: CE Processing, 395 Hudson Street, 3rd Floor New York, New York 10014.

Payment: Remit \$35 with this exam. Make check payable to Jobson Healthcare Information, LLC.

Credit: This course is COPE-approved for two hours of CE credit. Course ID 79160-GL.

Processing: There is a four-week processing time for this exam.

Jointly provided by PIM and the Review Education Group.

Salus University has sponsored the review and approval of this activity.

Answers to CE exam:

1. A B C D
2. A B C D
3. A B C D
4. A B C D
5. A B C D
6. A B C D
7. A B C D
8. A B C D
9. A B C D
10. A B C D
11. A B C D
12. A B C D
13. A B C D
14. A B C D
15. A B C D
16. A B C D
17. A B C D
18. A B C D
19. A B C D
20. A B C D

Post-activity evaluation questions:

Rate how well the activity supported your achievement of these learning objectives. 1=Poor, 2=Fair, 3=Neutral, 4=Good, 5=Excellent

21. Take the lead in the management of MIGS patients. ① ② ③ ④ ⑤
22. Recognize MIGS utility, device indications and efficacy. ① ② ③ ④ ⑤
23. Address and manage MIGS-related complications. ① ② ③ ④ ⑤
24. Comanage MIGS patients effectively. ① ② ③ ④ ⑤
25. Based upon your participation in this activity, do you intend to change your practice behavior? (Choose only one of the following options.)
 - A I do plan to implement changes in my practice based on the information presented.
 - B My current practice has been reinforced by the information presented.
 - C I need more information before I will change my practice.
26. Thinking about how your participation in this activity will influence your patient care, how many of your patients are likely to benefit? (please use a number):
27. If you plan to change your practice behavior, what type of changes do you plan to implement? (Check all that apply.)

<input type="checkbox"/> A Apply latest guidelines	<input type="checkbox"/> D Change in current practice for referral	<input type="checkbox"/> G More active monitoring and counseling
<input type="checkbox"/> B Change in diagnostic methods	<input type="checkbox"/> E Change in vision correction offerings	<input type="checkbox"/> H Other, please specify: _____
<input type="checkbox"/> C Choice of management approach	<input type="checkbox"/> F Change in differential diagnosis	_____
28. How confident are you that you will be able to make your intended changes?
 - A Very confident
 - B Somewhat confident
 - C Unsure
 - D Not confident
29. Which of the following do you anticipate will be the primary barrier to implementing these changes?

<input type="radio"/> A Formulary restrictions	<input type="radio"/> D Insurance/financial issues	<input type="radio"/> G Patient adherence/compliance
<input type="radio"/> B Time constraints	<input type="radio"/> E Lack of interprofessional team support	<input type="radio"/> H Other, please specify: _____
<input type="radio"/> C System constraints	<input type="radio"/> F Treatment related adverse events	_____
30. Additional comments on this course: _____

Please retain a copy for your records. Please print clearly.

First Name

Last Name

E-Mail

The following is your: Home Address Business Address

Business Name

Address

City State

ZIP

Telephone # - -

Fax # - -

OE Tracker Number

Rate the quality of the material provided:

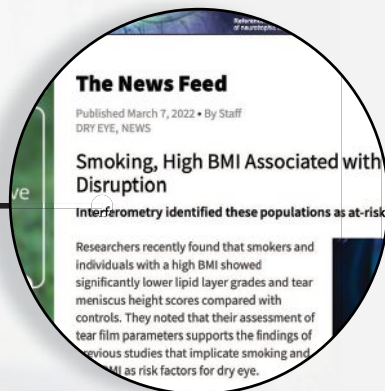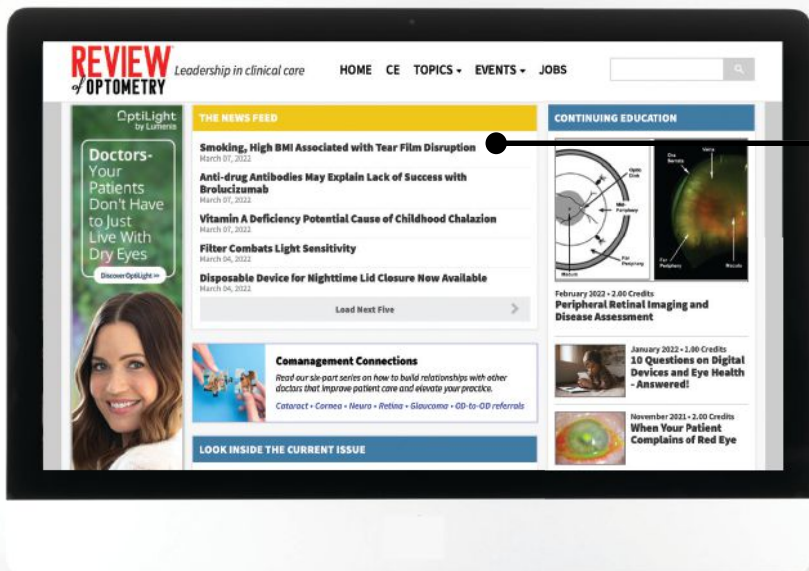
1=Strongly disagree, 2=Somewhat disagree, 3=Neutral, 4=Somewhat agree, 5=Strongly agree

31. The content was evidence-based. ① ② ③ ④ ⑤
32. The content was balanced and free of bias. ① ② ③ ④ ⑤
33. The presentation was clear and effective. ① ② ③ ④ ⑤

By submitting this answer sheet, I certify that I have read the lesson in its entirety and completed the self-assessment exam personally based on the material presented. I have not obtained the answers to this exam by any fraudulent or improper means.

Signature _____ Date _____ Lesson 122955 RO-OSC-0722

Find out first from



THE NEWS FEED

Updated every weekday

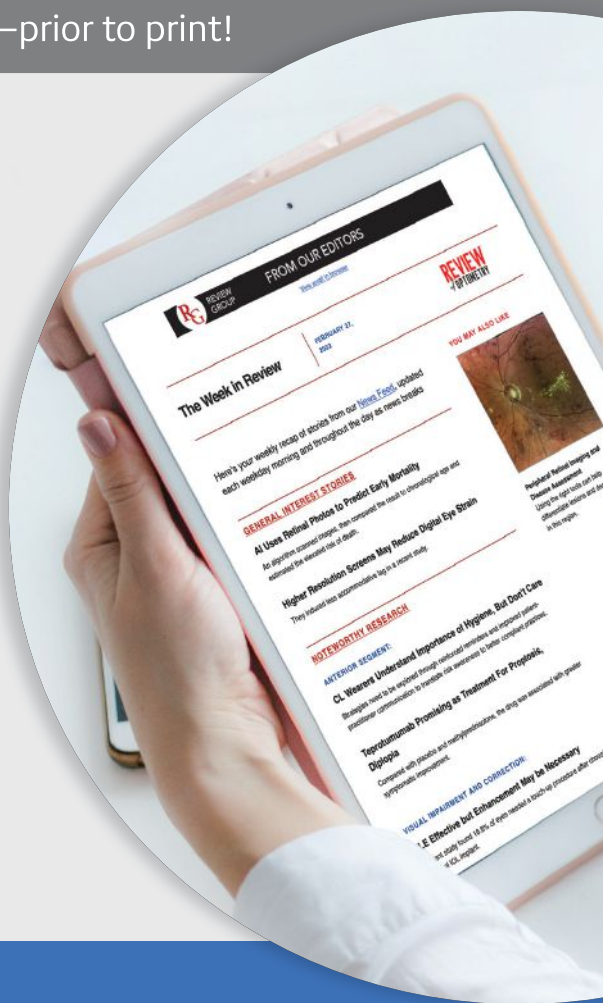
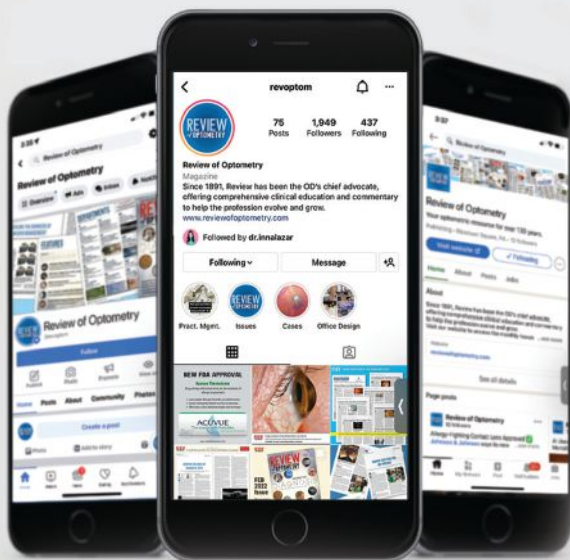www.reviewofoptometry.com/news

OVER 60 NEWS STORIES PUBLISHED EVERY MONTH

Read the latest news as it happens—prior to print!

Three ways to keep up with current events:

- 1 on the website
- 2 through social media
- 3 in your inbox



FACEBOOK: /revoptom
INSTAGRAM: @revoptom

TWITTER: @revoptom
LINKEDIN: review-of-optometry



EDITED BY JOSEPH P. SHOVLIN, OD

HSVK Reoccurrence and Risk of Resistance

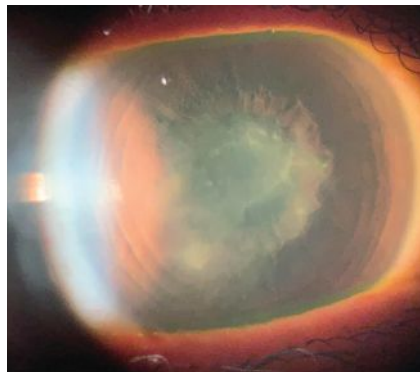
The more episodes a patient has, the less likely they may be to respond to antivirals due to prolonged treatment.

Q I have a patient who requires oral antiviral prophylaxis for recurrent herpes simplex viral keratitis (HSVK). Are there any significant risks for viral resistance with chronic use like we experience with prolonged use of antibiotics?

A HSVK is a fairly common corneal complication, says Cecelia Koetting, OD, who practices in Denver. The rate of incidence within the United States is estimated at 8.4 new cases per 100,000 and 20.7 total episodes per 100,000 each year.¹ In patients affected by recurrent HSVK, Dr. Koetting notes there is concern for possible resultant scarring and loss of vision or other permanent damage to the eye such as reduced corneal sensation. There is an increased risk with each occurrence of HSVK. Reoccurrence after the initial episode has been estimated to be 10% at one year, 23% at two, 36% at five and >60% at 20 years.¹ Oftentimes, these patients require antiviral prophylaxis to help decrease the risk, says Dr. Koetting.

Thoughts

The HEDS study found the reoccurrence rate of HSVK to be 34% after a single episode in the 346 included patients.² Use of prophylactic acyclovir 400mg PO QD was shown in the same study to decrease the incidence of HSVK reoccurrence by 45% over an 18-month treatment period.² Another study found that one-year HSVK sup-



A corneal scar from HSVK with a persistent epithelial defect after a corneal erosion.

pression therapy with oral valaciclovir 500mg PO QD was as effective as acyclovir 400mg PO BID in reducing HSVK disease reoccurrence, but that any benefit ceased when the antiviral was stopped.³

There is some concern that affected patients may develop resistance to these prophylactic antivirals, notes Dr. Koetting. Several case reports and studies have documented resistance to acyclovir and other antivirals and discussed potential mechanisms of action. HSVK is a DNA virus, and replication of the virus requires the protein thymidine kinase (TK).⁴⁻⁶ This is the target of antiviral drugs acyclovir, valaciclovir and famciclovir that are commonly used as treatment. The theory is that resistance results from mutations that affect the production or specificity of TK.⁴⁻⁶

When suspected or previously known drug resistance exists in HSVK

patients, switch to another antiviral. Resistance rates with acyclovir are approximately 0.1% to 0.98% in immunocompetent patients and approximately 3.92% to 14.3% in immunosuppressed patients.⁸ Alternative antivirals, such as foscarnet and cidofovir, are available and have the same mechanism of action involving TK but prevent viral DNA synthesis by inhibiting DNA polymerase.⁶⁻⁸ Studies have also indicated that approximately 5% of patients who are acyclovir-resistant are also resistant to other antivirals, including foscarnet and cidofovir.⁷

Clinical Takeaways

There is always the possibility that patients on prophylactic antivirals eventually develop resistance. This does not mean we should stop administering this treatment for HSVK, but it does mean that we must monitor affected patients even more closely to make sure the prescribed therapy is having the intended effect and not causing adverse events such as renal failure. The same goes for patients with persistent HSVK that is responding poorly to standard therapy. ■

1. Young RC, Hodge DO, Liesegang TJ, Baratz KH. The incidence, recurrence and outcomes of herpes simplex virus eye disease in Olmsted County, Minnesota, 1976 through 2007: the impact of oral antiviral prophylaxis. *Arch Ophthalmol.* 2010;128(9):1178-83.
2. Herpetic Eye Disease Study Group. Acyclovir for the prevention of recurrent herpes simplex virus eye disease. *N Engl J Med.* 1998;339(5):300-6.
3. Miserocchi E, Modorati G, Galli L, Rama P. Efficacy of valaciclovir vs acyclovir for the prevention of recurrent herpes simplex virus eye disease: a pilot study. *Am J Ophthalmol.* 2007;144(4):547-51.
4. Piret J, Boivin G. Antiviral resistance in herpes simplex virus and varicella-zoster virus infections: diagnosis and management. *Curr Opin Infect Dis.* 2016;29(6):654-62.
5. Pan D, Kaye SB, Hopkins M, et al. Common and new acyclovir resistant herpes simplex virus-1 mutants causing bilateral recurrent herpetic keratitis in an immunocompetent patient. *J Infect Dis.* 2014;209(3):345-9.
6. Choong K, Walker NJ, Apel AJ, Whitby M. Aciclovir-resistant herpes keratitis. *Clin Exp Ophthalmol.* 2010;38(3):309-13.
7. Gilbert C, Bestman-Smith J, Boivin G. Resistance of herpesviruses to antiviral drugs: clinical impacts and molecular mechanisms. *Drug Resist Updat.* 2002;5(2):88-114.

About Dr. Shovlin

Dr. Shovlin, a senior optometrist at Northeastern Eye Institute in Scranton, PA, is a fellow and past president of the American Academy of Optometry and a clinical editor of *Review of Optometry* and *Review of Cornea & Contact Lenses*. He consults for Kala, Aerie, AbbVie, Novartis, Hubble and Bausch + Lomb and is on the medical advisory panel for Lentechs.



Answers in the Angiography

These case findings could signal more than just a retinal condition.

A 62-year-old Black male presented to the emergency department with complaints of redness and soreness of the left eye for one week with associated subjective ipsilateral vision loss. The patient's entering visual acuity was 20/25 with pinhole in both eyes. His intraocular pressures (IOPs) were 17mm Hg OD and 16mm Hg OS. The right pupil was normal, but the left was slightly dilated, sluggish and minimally reactive to light. There was no afferent pupillary defect appreciable by reverse.

Slit lamp examination of the right eye was largely unremarkable, but the conjunctiva of the left eye exhibited diffuse injection (*Figure 1*). The left eye did not have any neovascularization of the iris, and the globe was not tender to palpation. Both eyes had clear corneas and quiet anterior chambers. There was bilateral optic nerve cupping consistent with a

known diagnosis of bilateral primary open-angle glaucoma. The right fundus had bear tracking pigmentation. The left fundus, however, was abnormal with diffuse retinal blot hemorrhages throughout the arcades and peripherally. The retinal arteries in the left eye were attenuated and the veins were engorged, with slight tortuosity (*Figure 2*).

The patient had a history of cataracts and glaucoma, for which he was using netarsudil/latanoprost, brimonidine/timolol and dorzolamide in both eyes with reported compliance. At his most recent exam two months prior, his IOPs were 18mm Hg OD and 33mm Hg OS on the same medications, revealing a peculiar IOP reduction in the left eye. At that same visit, the fundus exam was reportedly normal without hemorrhages. He had been referred to a glaucoma surgeon due to uncontrolled glaucoma on

maximum medical therapy in the left eye. His systemic medical history was significant for medically managed diabetes, hypertension, hyperlipidemia and human immunodeficiency virus.

Fundus Findings

Retinal hemorrhages can present due to several conditions including, but not limited to, diabetes, hypertension, sickle cell disease and hematologic malignancy. Hemorrhaging is bilateral and relatively symmetric in these conditions. Unilateral retinal hemorrhages, however, are most commonly seen in retinal vein occlusion, which may involve the central retinal vein (CRVO) or any branch tributary.¹

In the acute phase, a fundus exam typically reveals optic nerve edema, diffuse flame and blot hemorrhages in all four quadrants and dilated, tortuous veins along the affected distribution. It is common to also see concurrent cotton wool spots and cystoid macular edema (CME).

While the clinical appearance of our patient's fundus did have some features seen in CRVO, the distribution and appearance of the retinal hemorrhages was somewhat atypical. Specifically, there were no flame hemorrhages, and the hemorrhages were mostly located outside the posterior pole. We could have considered a resolving CRVO, in which case the optic nerve edema and retinal hemorrhages could have already cleared, but the patient had seen his ophthalmologist for a dilated eye exam two months prior, and no retinal hemorrhages were noted at that time. It was therefore less likely that this was an old CRVO. Furthermore, was the conjunctival injection and ocular pain simply a red herring?

Patients can have multiple ocular conditions simultaneously, so first

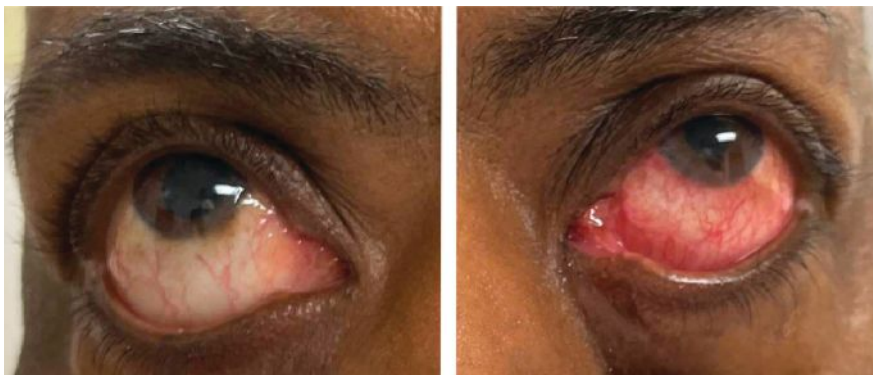

Fig. 1. Note the asymmetry in conjunctival injection between the right and left eyes. Images were taken after the instillation of tropicamide and phenylephrine drops.

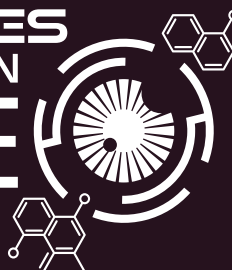**About
Dr. Bozung**

Dr. Bozung works in the Ophthalmic Emergency Department of the Bascom Palmer Eye Institute (BPEI) in Miami and serves as the clinical site director of the Optometric Student Externship Program as well as the associate director of the Optometric Residence Program at BPEI. She has no financial interests to disclose.

REGISTER NOW

 IN-PERSON EVENTS

NEW TECHNOLOGIES & TREATMENTS IN EYE CARE



SEPTEMBER 9–11, 2022

OMNI LA MANSION DEL RIO | SAN ANTONIO, TEXAS

Early bird registration: **\$395**

Deadline to register with special rate: July 23, 2022

Earn up to **19 LIVE COPE credits***

See event website for additional information.



NOVEMBER 11–13, 2022

HILTON ORLANDO LAKE BUENA VISTA | ORLANDO, FLORIDA

Early bird registration: **\$395**

Deadline to register with special rate: September 11, 2022

Earn up to **19 LIVE COPE credits***

See event website for additional information.

PROGRAM CHAIR



Paul M. Karpecki, OD, FAAO

Kentucky Eye Institute

Lexington, Kentucky

Chief Clinical Editor

Review of Optometry

www.reviewedu.com/ntt2022

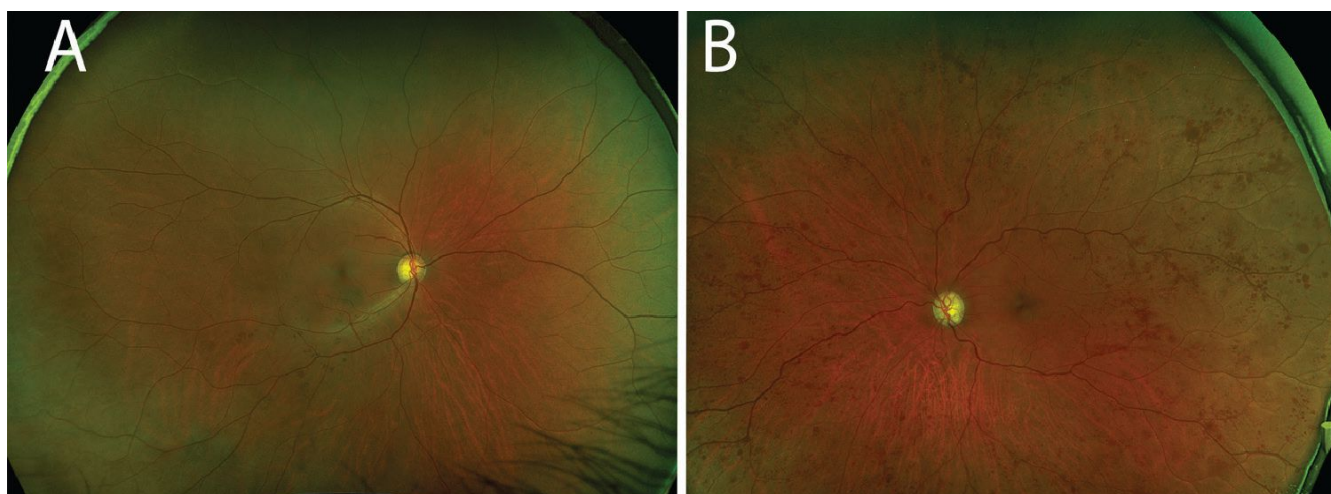

Fig. 2. (A) The right fundus was largely unremarkable. (B) In the left fundus, one can appreciate the extensive blot hemorrhages in the midperiphery and periphery. Note the attenuated arteries and dilated veins.

simplify the situation by considering a unifying condition that could produce all the ophthalmic findings in question. Ocular ischemic syndrome (OIS) is a rare condition that presents at a rate of about 7.5 cases per million individuals every year.² It often appears as a painful red eye, minimally reactive pupil, anterior chamber inflammation and iris neovascularization with low IOP. Furthermore, the dilated fundus exam reveals midperipheral blot hemorrhages, dilated veins and attenuated arteries. Optic disc edema and macular edema are uncommon.

Can We Break the Tie?

Though our patient did not have anterior chamber inflammation or neovascularization at his initial visit, his exam was still concerning for OIS. Given the overlap in clinical presentation of CRVO and OIS, consider the imaging modalities available to distinguish between the two conditions. First, recall that CME is much more common in CRVO than OIS, presenting in the majority of CRVO and only 15% to 17% of OIS cases.^{2,3} OCT—helpful in evaluating the macular status—revealed an absence of CME (*Figure 3*).

Another tool that can aid in distinguishing these two conditions is intravenous fluorescein angiography (FA). In OIS, this method often reveals delayed choroidal flush, delayed arm-to-retina time, prolonged retinal

circulation time and late staining of the arteries.²

Our patient’s FA was ordered with the left eye as “transit,” meaning that photos of the left fundus were taken as soon as fluorescein dye was pushed into the circulation through the antecubital vein. Choroidal flush is the first angiographic sign seen in FA. Normal choroidal flush occurs at about 10 to 15 seconds.^{4,5} Our patient’s imaging revealed a delayed choroidal filling, with choroidal flush first appearing beyond the normal threshold at 26 seconds (*Figure 4a*). Arterial circulation was also delayed and only first appreciable at 35 seconds, nine seconds after the choroidal flush (normal: one to two seconds after).

Later images revealed incomplete filling of the arterial branches signifying retinal arterial stasis (*Figure 4b*). Additionally, late-phase imaging at five minutes revealed staining of the retinal arteries without venous staining or leakage, which was felt to be more consistent with an arterial process.

Putting it All Together

Once a diagnosis of OIS is on the table, the clinician’s job is not complete. It is important to discuss the condition fully with the patient and communicate findings with the patient’s other health-care providers. OIS is most commonly seen in cases of severe carotid artery occlusion or stenosis. It has also been attributed to vasculitis (such as giant cell arteritis and Takayasu arteritis), aortic arch syndrome, carotid artery dissection and hyperhomocysteinemia.^{2,6,7}

The recommended lab studies for an OIS workup include erythrocyte sedimentation rate, C-reactive protein and

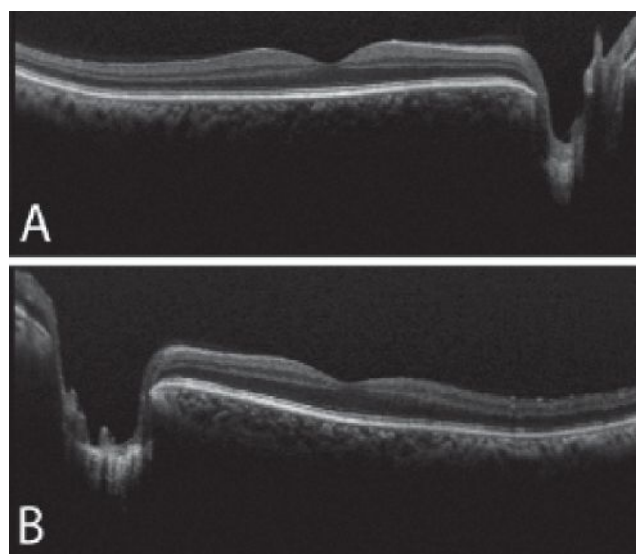


Fig. 3. OCT of the right (A) and left (B) eyes reveals no macular edema or retinal thickening. There is deep cupping in the left eye greater than the right eye, which corroborates with the fundus exam.

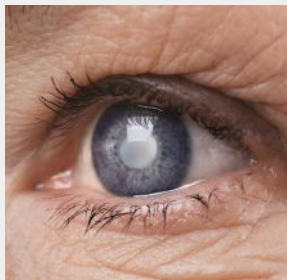REGISTER NOW

**IN-PERSON EVENTS**

Join Review Education Group and MedscapeLIVE! this December for the West Coast Optometric Glaucoma Symposium (WCOGS) and Retina Update 2022. The conferences will be co-located at the Hilton La Jolla Torrey Pines in La Jolla, California. Attendees are encouraged to participate in both symposia to greatly enhance their learning experience.

Early bird special pricing: \$149 single conference | \$250 bundled

Deadline to register with special rate: October 21, 2022



WEST COAST OPTOMETRIC GLAUCOMA SYMPOSIUM

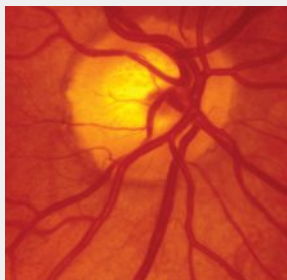
DECEMBER 9–10, 2022

LA JOLLA, CALIFORNIA

Program Co-Chairs: Murray Fingeret, OD, FAAO; Robert N. Weinreb, MD

EARN UP TO 12 LIVE CE CREDITS*

WCOGS is a 2-day biannual symposium designed to provide optometrists with exposure to current thinking on evolving standards of care, state-of-the-art technology and breaking research that will guide current and future glaucoma care in the optometric setting. Incorporating cases, clinical pearls, and discussion sessions, the program will maximize the opportunity for participant/faculty engagement.



THE OPTOMETRIC RETINA SOCIETY AND REVIEW EDUCATION GROUP PRESENT

RETINAUPDATE2022

DECEMBER 10–11, 2022

LA JOLLA, CALIFORNIA

Program Co-Chairs: Mohammad Rafieetary, OD, FAAO; Steven Ferrucci, OD, FAAO

EARN UP TO 11 CE CREDITS*

Retina Update 2022 will help ensure that primary practitioners consider all relevant research so they can practice in an effective and appropriate manner. The program will offer specific direction and practical advice on how to detect and manage a broad range of retinal disease and promote improved retinal health.

Earn up to 23 LIVE COPE credits*

For more information and to register

www.reviewedu.com/winteroptometry

complete blood count. Imaging studies of the carotid arteries and heart—such as a carotid duplex and ultrasound, angiography of the head and neck and an echocardiogram—should also be obtained. Multispecialty management is always indicated in these cases, and patients should be promptly referred to a primary care physician, cardiologist and/or neurologist for a complete workup. They may be advised to seek treatment with a vascular surgeon or interventional radiologist in the case of significant carotid stenosis. Treatment will ultimately depend on the underlying condition and its severity as well as the patient’s comorbidities.

Patients with OIS are at risk of developing severe ocular complications such as neovascularization and neovascular glaucoma. They should be monitored regularly with gonioscopy and dilated fundus examination to evaluate for any signs of neovascular changes. If present, treatments such as panretinal photocoagulation and intravitreal anti-VEGF injection should be considered, though the overall visual prognosis remains poor in cases of OIS.⁸

Management and Status

The patient was under the care of a cardiologist and was urgently advised to seek further workup. Unfortunately, as of the most recent follow-up, he was still awaiting carotid and cardiac studies to confirm or rule out the suspected diagnosis. He continued to have persis-

Table 1. Comparison of OIS and CRVO^{2,9} (Our patient’s findings are highlighted in red.)

	OIS	CRVO
<i>Symptoms and Anterior Segment Findings</i>		
Pain	Dull ache, soreness	Absent
Decreased vision	Common	Common
Conjunctival injection	Diffusely injected	Absent
Pupil	Mid-dilated, poorly reactive	Normal reactivity
Anterior chamber	Cell/flare common, iris neovascularization common	Cell/flare absent, iris neovascularization common
<i>Fundus Exam</i>		
Veins	Dilated	Dilated, tortuous
Arteries	Attenuated	Normal
Optic nerve	Normal	Usually edematous, collateral vessels present when chronic
Hemorrhage type/location	Deep, blot hemorrhages in midperiphery	Superficial flame and deep blot hemorrhages in all four quadrants including posterior pole
Macular edema	Usually absent	Usually present
<i>Fluorescein Angiography</i>		
Choroidal filling time	Delayed	Normal
Arterial filling time	Delayed	Normal
Arteriovenous transit time	Delayed (due to low arterial perfusion)	Delayed (due to decreased venous outflow)
Late retinal vessel staining	Arteries > veins	Veins > arteries

tent ocular redness and pain and developed iris neovascularization. The IOP and retinal findings remained stable. Due to the appearance of neovascular changes, he received an intravitreal anti-VEGF injection and panretinal photocoagulation in the left eye. ■

1. Rehak M, Wiedemann P. Retinal vein thrombosis: pathogenesis and management. *J Thromb Haemost.* 2010;8(9):1886-94.
2. Terelak-Borys B, Skonieczna K, Grabska-Liberek I. Ocular ischemic syndrome – a systematic review. *Med Sci Monit.* 2012;18(8):RA138-44.
3. Laouri M, Chen E, Looman M, Gallagher M. The burden of disease of retinal vein occlusion: review of the literature. *Eye (Lond).* 2011;25(8):981-8.
4. 2020-2021 Basic and Clinical Science Course, Section 12: Retina and Vitreous. American Academy of Ophthalmology, 2020:33-37.
5. Ruia S, Tripathy K. Fluorescein Angiography. In: StatPearls [Internet]. Treasure Island (FL): StatPearls Publishing; 2022.
6. Larrazabal RB, Chiu HHC, Magbitang-Santiago AT. Takayasu arteritis presenting as bilateral ocular ischemic syndrome. *Vasc Specialist Int.* 2020;36(3):163-9.
7. Luo J, Yan Z, Jia Y, Luo R. Clinical analysis of 42 cases of ocular ischemic syndrome. *J Ophthalmol.* 2018;2018:2606147.
8. Hazin R, Daoud YJ, Khan F. Ocular ischemic syndrome: recent trends in medical management. *Curr Opin Ophthalmol.* 2009;20(6):430-3.
9. Mendrinós E, Machinis TG, Pournaras CJ. Ocular ischemic syndrome. *Surv Ophthalmol.* 2010;55(1):2-34.

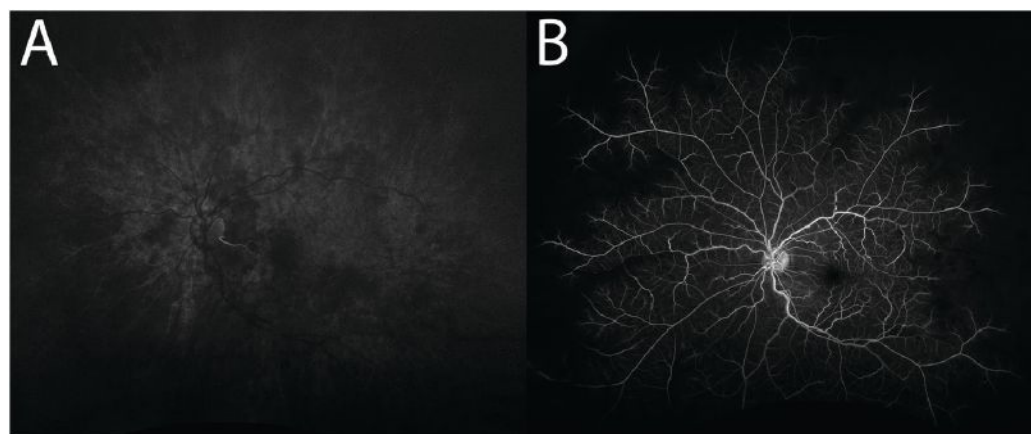
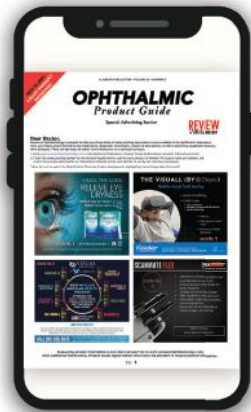

Fig. 4. (A) Delayed first appearance of choroidal flush, captured at 26 seconds. Note the filling of a small cilioretinal artery, which is supplied by the choroid. (B) Delayed and incomplete filling of the retinal arteries, captured at 69 seconds. There are also a few microaneurysms present.

OPHTHALMIC Product Guide



Hold your mobile device over the code to view reviewofoptometry.com/publications/archive.

Innovative products to enhance your practice

Experience Review's Product Guide in print or digital. Simply select the products, devices or services you'd like to be contacted about for more information.

www.reviewofoptometry.com/publications/archive

E-BLAST PRODUCT SHOWCASE!

FROM OUR PARTNERS

DIGITAL SHOWCASE

OPHTHALMIC Product Guide

Click on a product to sign up to receive more information from the manufacturer.

Featuring Products by:

INTRODUCING PICTOR Prestige

Image Anytime. Anywhere.

CALL 202 705 3673

FROM OUR PARTNERS

DIGITAL SHOWCASE

OPHTHALMIC Product Guide

Click on a product to sign up to receive more information from the manufacturer.

Featuring Products by:

AREOS 2

BEST-IN-CLASS MACULAR HEALTH

CALL 202 705 3673

In addition to mailing the print edition and hosting the digital versions of the Product Guide on our website, we will be blasting each company's listings to our OD email database! Each company will have a designated product showcase deployment day following distribution of the print editions, providing an additional opportunity to receive more information on all the items you want!



BY PAUL M. KARPECKI, OD
CHIEF CLINICAL EDITOR

OCULAR SURFACE REVIEW

Power Trio

Three promising new therapeutics look to dramatically change dry eye disease management.

Over the past few months, three companies announced their second pivotal Phase III FDA trial results for novel ocular surface disease agents, and the results aren't just promising—they are exciting, for clinicians and patients alike. All trials met their pre-specified primary endpoints, meaning they could get approved within the next year. It's valuable for us to know about these potential pharmaceuticals so we can begin identifying patients with certain ocular diseases and give them hope that new agents may come available in the near future to treat their condition.

Perfluorohexyloctane: NOV03

This may be the first drug approved for the signs and symptoms of dry eye disease (DED) associated with meibomian gland dysfunction (MGD).

Studies have shown that MGD is present in 86% of all DED cases.¹ Most if not all current eye drops are 30 μ L to 50 μ L doses, but NOV03 is only 12 μ L—and that small amount goes a long way. It appears to practically replace a dysfunctional lipid layer and has been shown to last over four hours after a single administration. To put that in perspective, most therapeutic drops are measurable on the eye for about three to five minutes.

The second Phase III clinical trial results matched the previous study and revealed that NOV03 easily met both primary efficacy endpoints: statistical improvement in total corneal fluorescein staining and eye dryness score (using a visual analog scale), compared with hypotonic saline at day 57. Hypotonic saline is often a base for artificial tears. More impressive is the fact that these two endpoints were met as soon as two weeks. The drop is very comfortable and the only adverse event that occurred in more than 1% of patients was mild blepharitis. Even though the agent remains on the eye for four to six hours, patients did not report blurred vision. The drop is preservative-free and the study was dosed at QID.

Managing meibomian gland dysfunction in the most common form of DED, affecting upwards of 30 million

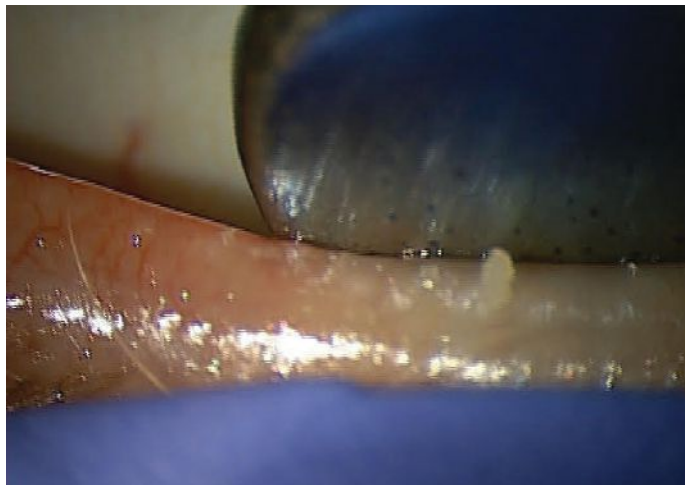
patients, is an incredible need as current therapeutics are only addressing the inflammation that is a result of the MGD (or blepharitis), but do not treat the cause. This is a drug I am confident will give great hope to patients struggling with evaporative DED.

Lotilaner: TP-03

We've all seen our fair share of *Demodex* blepharitis, a condition estimated to affect about 25 million patients in the United States alone.² Even that sizable number may be an underestimation. If doctors begin routinely looking more closely for collarettes—by having the patient look down while at the slit lamp and examining the base of the upper lid margin—an even greater number of patients will be identified.

Demodex is a common cause of itching, grittiness and eye dryness that leads to lash thinning, lash loss, evaporative dry eye, hordeola, chalazion, meibomian gland atrophy and rosacea.

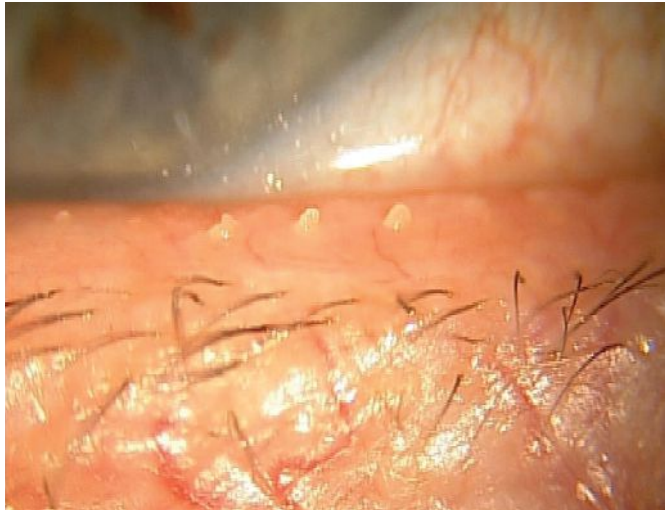
Lotilaner (Tarsus Pharmaceuticals) is an anti-parasitic that works by paralyzing the mite's nervous system through parasite-specific GABA inhibition. Tarsus's results of their second Phase III pivotal trial are consistent with their previous Phase III trial for the treatment of *Demodex* blepharitis. TP-03 met the primary endpoints of collarette cure rate and mite eradication as well as all secondary endpoints, with high statistical significance. The study found that 89% of patients achieved a clinically meaningful collarette cure rate (<10 collarettes per eye), which is impres-



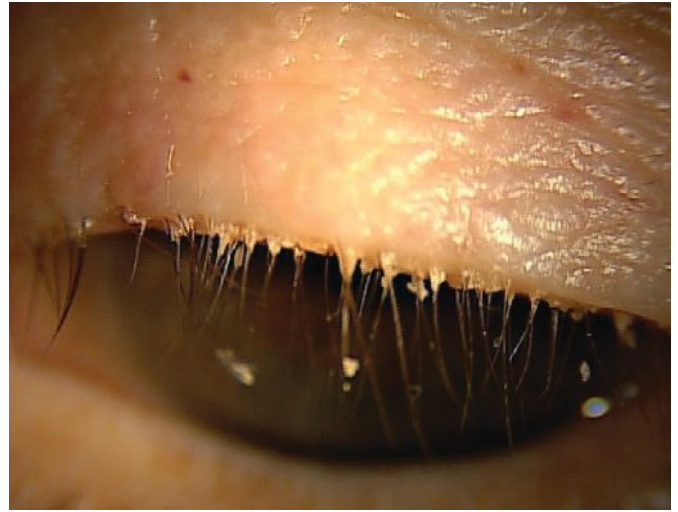
A patient with DED associated with MGD showing poor MG expression.

About
Dr. Karpecki

Dr. Karpecki is Director of Cornea/External Disease for Kentucky Eye Institute and the Medical Director for Keplr Vision. He is the Chief Clinical Editor for *Review of Optometry* and chair of the New Technologies & Treatments conferences. A fixture in optometric clinical education, he consults for a wide array of ophthalmic clients, including ones discussed in this article. Dr. Karpecki's full disclosure list can be found in the online version of this article at www.reviewofoptometry.com.



Another MGD patient that likely suffers from chronic tear instability resulting from inadequate lipid release to the ocular surface.



Having a patient look slightly down identifies collarettes in *Demodex* blepharitis.

sive considering there are few effective treatments for *Demodex* blepharitis, and no patients were permitted to scrub their eyelid margins. Further, 56% of patients showed a complete collarette cure rate and 31% showed a complete resolution of erythema.

Considering this is not a steroid or anti-inflammatory agent, the improvement in erythema is notable. The most common adverse event, which occurred in less than 10% of patients, was burning upon instillation. The drug was dosed at BID for six weeks and long-lasting effects are expected following this treatment duration.

Demodex is currently the most difficult form of blepharitis to manage, making it the most common blepharitis. A fast-acting, effective agent dosed for only six weeks is what this extremely large patient base is in desperate need of.

Reproxalap

Inflammation is central to the development and perpetuation of dry eye. A pro-inflammatory mediator called reactive aldehyde species may play a key role in clinical manifestations of DED, and a new drug targets such activity.

Reproxalap (Aldeyra Therapeutics) is a small-molecule reactive aldehyde species (RASP) inhibitor. RASP has been shown to be greatly elevated in ocular (DED and allergic conjunctivitis) and systemic inflammatory diseases.³ Its mechanism of action works at a very high level in the inflammatory cascade, possibly positioning this drug at or above the level of where corticosteroids work, but without the potential of intraocular pressure elevation or other complications.⁴

I believe we are in great need of a fast acting, potent but safe, multimodal anti-inflammatory agent that targets the direct pathway to cytokine production as inhibition of RASP in DED and potentially other ocular surface diseases, especially to patients who can't take corticosteroids. The overlap between DED and allergic eye diseases may affect over 30 million people, let alone those with DED in isolation.

In the second Phase III FDA trial, data reached statistically significant improvements over vehicle for its pre-specified primary endpoints of Schirmer test scores and >10mm Schirmer responders. Both are FDA-approvable endpoints for DED.

These data points were achieved after a single day of dosing, although data submitted will include trial results over five studies involving over 1,700 patients, including 12-week dosing studies. Those clinical trials also achieved statistically significant positive results for ocular dryness symptom score and ocular redness.

Exciting Times Ahead

These three drug candidates couldn't be more desperately needed by patients, as they are far different from anything currently available. While we wait for them to be approved, we can begin identifying patients, educating them about what's to come and provide hope and excitement for the next potential wave of OSD therapeutics. ■

1. Lemp MA, Crews LA, Bron AJ, et al. Distribution of aqueous-deficient and evaporative dry eye in a clinic-based patient cohort: a retrospective study. *Cornea*. 2012;31(5):472-8.

2. Zhap YE, Wu LP, Hu L, Xu JR. Association of blepharitis with *Demodex*: a met-analysis. *Ophthalmic Epidemiol*. 2012;19(2):95-102.

3. Clark D, Karpecki P, Salapatek AM, et al. Reproxalap improves signs and symptoms of allergic conjunctivitis in an allergen chamber: a real-world model of allergen exposure. *Clin Ophthalmol*. 2022;16:15-23.

4. Higdon A., Diers AR, Oh JY. et al. Cell signalling by reactive lipid species: new concepts and molecular mechanisms. *Biochem J*. 2012;442(Pt 3):453-64.



In Need of a Fill-up

This patient's older age and scattered blot hemorrhages led to the diagnosis.

An 85-year-old white male presented for an annual follow-up of cortical cataracts in both eyes. He did not feel his vision was appreciably worse than the year before. He had a history of asymmetric intraocular pressure (IOP) with the right eye always being slightly higher than the left. At his last eye exam one year earlier, IOP measured 21mm Hg OD and 18mm Hg OS. His medical history was significant for hypertension and hypercholesterolemia, for which he was taking diltiazem and rosuvastatin.

Upon examination, his best-corrected visual acuity measured 20/40 OD

and 20/20 OS. Confrontation visual fields were full to careful finger counting OU. Motility testing was normal, and the pupils were equal, round and reactive to light; there was no afferent pupillary defect. The anterior segment exam was significant for nuclear sclerotic cataract and cortical cataract in both eyes, with the right eye worse than the left, and consistent with his visual acuity. Tensions by applanation measured 21mm Hg OD and 13mm Hg OS.

On dilated fundus exam, the cup-to-disc ratio measured 0.5 in each eye with temporal sloping. There was mild retinal pigmented epithelium mottling

in the macula of each eye without subretinal fluid or choroidal neovascularization. The periphery of the right eye was normal, and there were scattered blot hemorrhages in the left eye (*Figure 1*). An OCT of the macula and retinal nerve fiber layer was normal, and an image of the fluorescein angiography (FA) at 25 seconds is available for review (*Figure 2*).

Take the Retina Quiz

1. How would you interpret the FA?

- Essentially normal.
- Peripheral capillary nonperfusion.
- Delayed arterial filling.
- Occlusion of the central retinal vein.

2. What is the most likely diagnosis?

- Early central retinal vein occlusion.
- Venous stasis retinopathy.
- Asymmetric nonproliferative diabetic retinopathy.
- Ocular ischemic syndrome (OIS).

3. What additional testing is recommended?

- Visual field.
- OCT angiography.
- Carotid artery studies.
- MRI of the brain.

4. What additional findings would you expect to see with this condition?

- Anterior segment neovascularization.
- Macular edema.
- Retinal neovascularization.
- Posterior subcapsular cataract.

5. How should this patient be managed?

- Careful observation.
- Anti-VEGF injection.
- Refer for consideration of endarterectomy.
- All of the above.

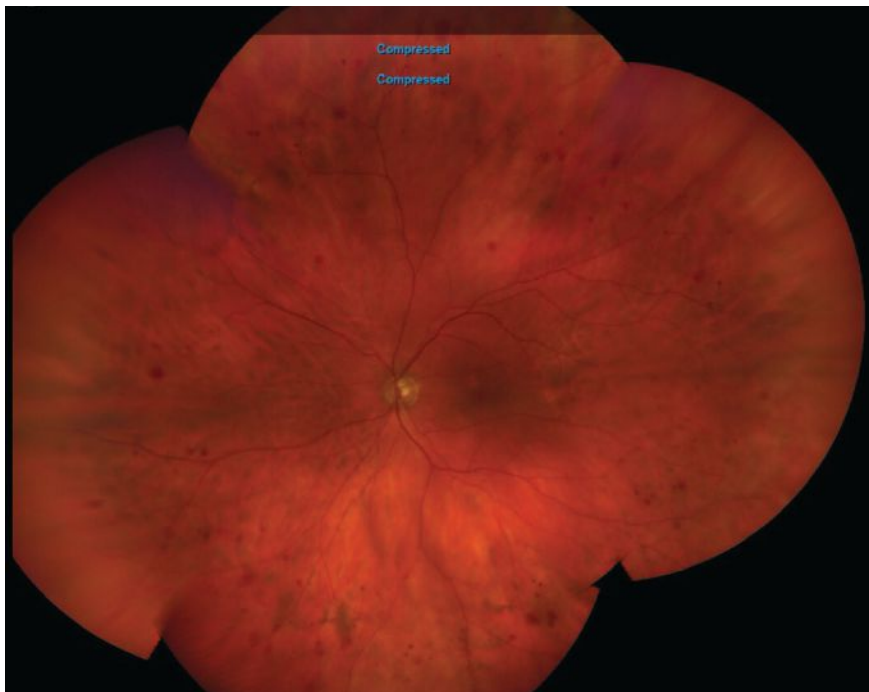

Fig. 1. Here is a widefield view of the left eye of our patient. Note the peripheral retinal hemorrhages. What is the etiology?

For answers, see page 90.

About Dr. Dunbar

Dr. Dunbar is the director of optometric services and optometry residency supervisor at the Bascom Palmer Eye Institute at the University of Miami. He is a founding member of the Optometric Glaucoma Society and the Optometric Retina Society. Dr. Dunbar is a consultant for Carl Zeiss Meditec, Allergan, Regeneron and Genentech.



“ I didn't realize
STARS
were little dots that twinkled ”

—Misty L, *RPE65* gene therapy recipient

**WE'RE SEEING
AMAZING RESULTS.
AND SO ARE THEY.**

At the Foundation Fighting Blindness our mission is everybody's vision. Our work shines a light on the darkness of inherited retinal diseases (IRDs).

We're the world's leading organization searching for treatments and cures. We need your help to fuel the discovery of innovations that will illuminate the future for so many. We have robust disease information, a national network of local chapters and support groups, local educational events, and our My Retina Tracker® Registry to help keep your patients connected with clinical and research advancements.

Help accelerate our mission
by donating at ECPs4Cures.org.

**FOUNDATION
FIGHTING
BLINDNESS**

FightingBlindness.org

Diagnosis

The presence of peripheral blot hemorrhages in the left eye was concerning, especially since they were not noted on his prior exam. The initial thought was that this is likely from an early or mild retinal vein occlusion, but, given his age, we also considered that the hemorrhages could be from ocular ischemic syndrome.

OIS is a rare condition caused by ocular hypoperfusion to the eye and orbit as a result of stenosis or occlusion of the common or internal carotid arteries, most commonly due to atherosclerosis.^{1,2} In most cases, a stenosis of 90% or more of the common or internal carotid artery on the ipsilateral side of the eye is usually seen. In 50% of the cases, the carotid artery is completely obstructed.

An FA was performed to determine if there was any delay in filling of the fluorescein dye, which we would expect to see if this were from OIS. Indeed, there was a delay; we didn't see the choroidal filling until about 18 seconds (normal is 11 seconds) and we didn't see the dye enter the central retinal artery until about 28 seconds. The normal arteriovenous transit time is also approximately 11 seconds.

Based on the clinical and FA findings, it was recommended that our patient have a complete work-up by his cardiologist, including carotid artery studies. We also tried to elicit any history of transient ischemic attack-like symptoms or other indications of a stroke. He denied any symptoms of transient visual loss or other stroke-like symptoms. In fact, he said he was pretty healthy and felt fine.

The patient was seen by his cardiologist and had carotid duplex scanning done. The results showed that there was a near occlusive atherosclerotic plaque at the left common carotid artery bifurcation and proximal bulb with severe high-grade stenosis of at least 70% to 95%. There was also extensive atherosclerotic plaque in

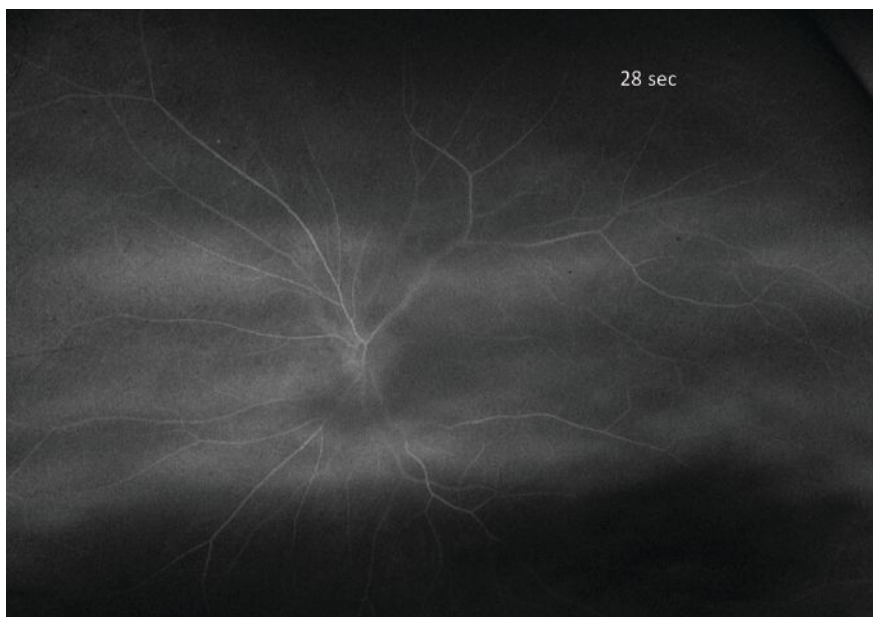


Fig. 2. Here is a frame of the FA at 28 seconds. Is this normal?

the right common carotid bifurcation and bulb with 50% to 69% stenosis proximal right internal carotid artery. The report concluded that there was high-grade stenosis of both external carotid arteries with reversal of flow in the left external carotid artery and high velocity stenosis at the origin of the left vertebral artery. Given these results, we were able to establish a definitive diagnosis of OIS.

Discussion

The exact incidence of OIS is unknown. The mean age of patients is 65 years, and men are affected twice as often as women.^{1,2} This is likely attributed to the higher incidence of cardiovascular disease in males. In 20% of cases, the involvement is bilateral. Vision loss is seen in up to 90% of patients due to retinal ischemia and/or secondary glaucoma.¹ Fortunately, our patient had excellent visual function.

He did not have glaucoma but, interestingly, patients with OIS can have either elevated IOP from anterior segment neovascularization or low IOP as a result of ciliary body shutdown from the ischemia. In fact, iris or angle neovascularization can be seen in up to 66% of eyes with OIS and may be the only presenting sign of the condition.¹ Luckily, our patient

did not have any anterior segment neovascularization.

Other findings commonly seen with OIS—in addition to retinal hemorrhages and anterior segment neovascularization (ASNV)—include orbital pain or a dull ache in about 40% of patients, likely from orbital hypoxia, and anterior chamber flare when ASNV is present.¹ Other posterior segment findings may include narrowed arteries and dilated veins, which was not obvious in our patient.

All of this was explained to our patient, and the cardiologist even discussed the option of surgical intervention with endarterectomy. In the end, our patient declined to have any treatment beyond routine follow-up on a regular basis. He was seen one year later and was still functioning well. The acuity in the left eye had dropped to 20/25 and the retinal hemorrhages were still present. He still had asymmetric IOP of 22mm Hg OD and 14mm Hg OS. He reported that he is doing well and living a productive life, including playing golf on a regular basis. ■

1. Terelak-Borys B, Skonieczna K, Grabska-Liberek I. Ocular ischemic syndrome—a systematic review. *Med Sci Monit.* 2012;18(8):RA138-44.

2. Brown GC, Magargal LE. The ocular ischemic syndrome. Clinical, fluorescein angiographic and carotid angiographic features. *Int Ophthalmol.* 1988;11(4):239-51.

For more on ocular ischemic syndrome, read this month's Urgent Care column on page 74.



I was only seeing light flashes early on, but light

FLASHES

when you've not seen anything for
so many years—it was wonderful

—Keith H, retinal prosthesis recipient

**WE'RE SEEING
AMAZING RESULTS.
AND SO ARE THEY.**

At the Foundation Fighting Blindness our mission is everybody's vision. Our work shines a light on the darkness of inherited retinal diseases (IRDs).

We're the world's leading organization searching for treatments and cures. We need your help to fuel the discovery of innovations that will illuminate the future for so many. We have robust disease information, a national network of local chapters and support groups, local educational events, and our My Retina Tracker® Registry to help keep your patients connected with clinical and research advancements.

Help accelerate our mission
by donating at ECPs4Cures.org.

**FOUNDATION
FIGHTING
BLINDNESS**

FightingBlindness.org

PRODUCT REVIEW



ONLINE FIRST:
GET THE LATEST
PRODUCT NEWS AT
www.reviewofoptometry.com

New items to improve clinical care and strengthen your practice.

► CONTACT LENSES AND SOLUTIONS

New Acuvue Lens Aims for Maximum Comfort

Contact lens discomfort—the number one reason for patient drop-out—is exacerbated by heavy digital device use, which reduces blink rates and contributes to dry eye symptoms. A new addition to the Acuvue product line called Oasys Max 1-Day was designed to help, says Johnson & Johnson Vision. The company announced the product's FDA approval last month and said the lens will be available this fall.



Like the existing Oasys 1-Day, the new “Max” version is a 38% water content silicone hydrogel (senofilcon A) lens with polyvinylpyrrolidone as a wetting agent. The company says the Oasys Max also uses new, as-yet-unspecified technologies that work to optimize comfort, even for lens wearers who use digital devices for extended periods each day. J&J says that overall screen time has increased by 40% in recent years, causing patients to blink up to 60% less, and that 71% of eyecare professionals reported seeing patients who are experiencing eye discomfort as a result.

The following power ranges and base curves will be available for Oasys Max 1-Day:

- *Single vision:* -12.00D to +8.00D in 0.25D steps (0.50D steps above $\pm 6.00D$), base curves: 8.5mm and 9.0mm.
- *Multifocal:* -9.00D to +6.00D (0.25D steps) with adds of low (+0.75D to +1.25D), mid (+1.50D to +1.75D) and high (+2.00D to +2.50D), base curve: 8.4mm.

B+L Launches Revive Custom Soft Contact Lenses

Soft contact lenses now come in so many stock offerings that doctors can have an off-the-shelf option at the ready for most patients—but not all. Lens wearers have unique prescription needs, vision goals and expectations, eye shape and other ocular parameters. To provide a more individualized vision-correcting solution for a broad range of patients, Bausch + Lomb launched a new family of customizable soft contact lenses called Revive. The product line includes spherical, toric, multifocal and multifocal toric options.

Revive lenses are made of a non-ionic material that



helps resist protein deposits, B+L says, allowing for up to three months of daily

wear; the replacement schedule is at the discretion of the doctor. The company explains that the customizable parameters include lens diameter, base curve and power, all of which can be adjusted as needed until the optimal fit is achieved. A table of lens parameter options can be found on our website at www.reviewofoptometry.com/products.

Toric lens versions include what B+L calls “dual elliptical stabilization,” a process for ballasting that adds material with more forethought toward achieving the optimal shape and position than traditional “slab-off” designs, company literature explains. B+L says this aids in orientation and rotational stability. For multifocal fits, the near zone diameter is customizable from 1.8mm to 3.0mm to account for small-pupil patients or other circumstances where a non-standard design is desired.

Whether a patient has a high prescription or a physical characteristic such as unusual pupil size that traditionally makes it challenging to find a successful fit, B+L says that the Revive customizable lens family will help to meet a larger number of patients' needs.

BioTrue Hydration Plus Offers 12-hour Moisture

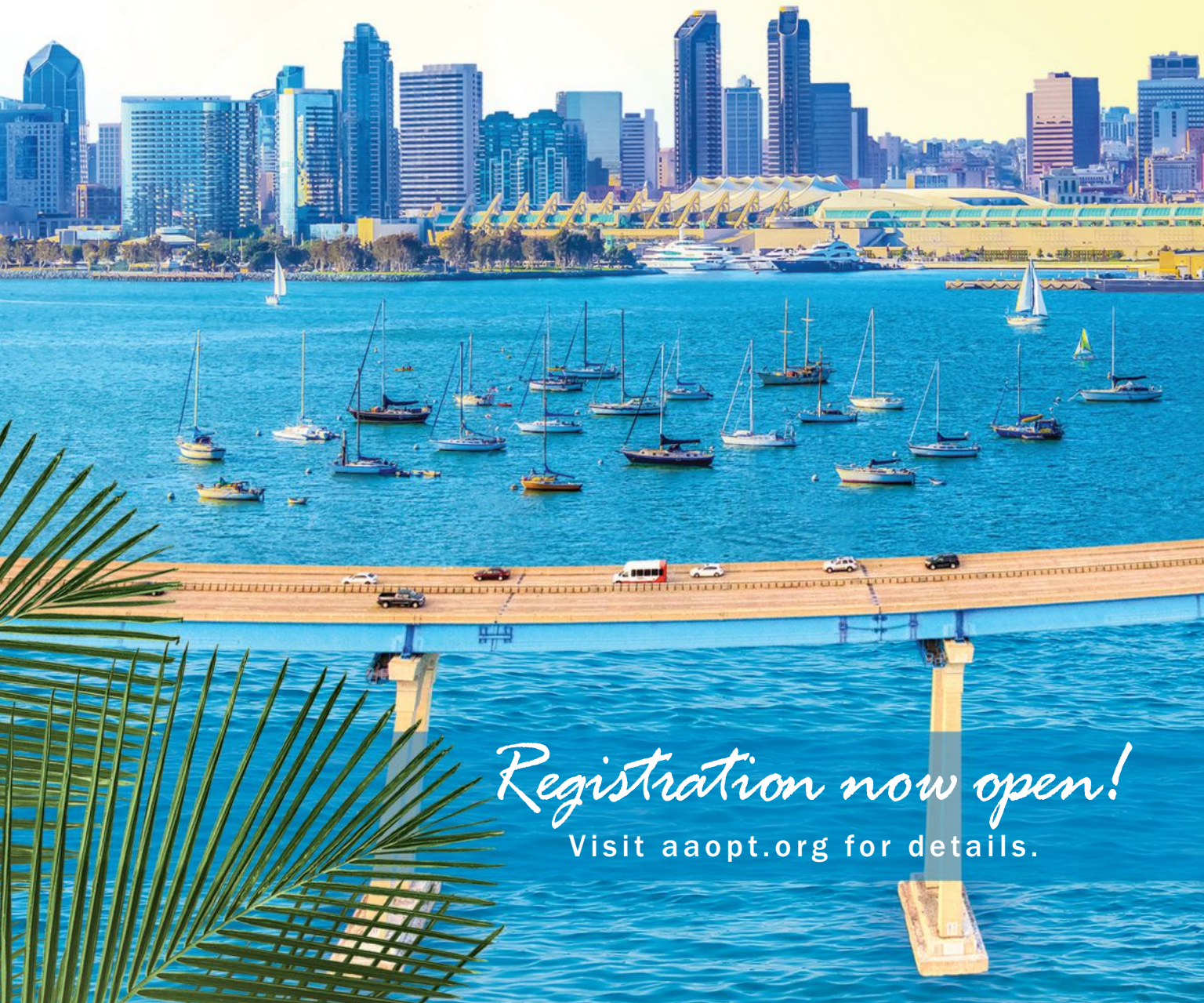A growing number of people today are opting to use natural products to manage their well-being for reasons such as ingredient transparency and the potential for reduced side effects. Several eyecare companies offer contact lenses and solutions that cater to lens wearers in search of a more natural and preservative-free option, one example being Bausch + Lomb's BioTrue line. The company recently launched a new addition to BioTrue's product portfolio called Hydration Plus Multi-Purpose Solution, which B+L says matches the pH of healthy tears and keeps lenses moist for 12 hours.

Compared with the standard BioTrue MPS product, the formula in Hydration Plus contains 25% more hyaluronan, a moisturizer found naturally in tears that helps the lenses maintain moisture, the company explains in a press release. It's also made up of a unique combination of other ingredients, including potassium, an electrolyte and erythritol, an antioxidant that protects hyaluronan against free radicals, all of which help to maintain ocular surface homeostasis, says B+L. The solution is now available in a multi-dose, eco-friendly bottle. ■



Centennial Celebration
ACADEMY **20**
san diego **22**
OCTOBER 26-29, 2022

Presented by AMERICAN ACADEMY of OPTOMETRY



Registration now open!
Visit aaopt.org for details.

Practice For Sale



Practice Sales • Appraisals • Consulting
www.PracticeConsultants.com

**PRACTICES FOR SALE
NATIONWIDE**

Visit us on the Web or call us to learn more about our company and the practices we have available.
info@PracticeConsultants.com
925-820-6758

www.PracticeConsultants.com

Business For Sale

EVOLUTION ADVISORS
Optimizing the Outcome of Your Business Exit

**For Sale:
High-End
Eyewear Business**

Sacramento California

\$495,000

Revenue \$660,308
Cash Flow \$227,396
33 years in business

Contact: Randy Hendershot
randy@evobizsales.com
916 993 5433

**REVIEW
of OPTOMETRY**

Do you have
Products and
Services for sale?

**CLASSIFIED
ADVERTISING WORKS**

- JOB OPENINGS
- CME PROGRAMS
- PRODUCTS
- AND MORE...

Contact us today for
classified advertising:
Toll free: **888-498-1460**
E-mail: sales@kerhgroup.com

KERHGROUP

Targeting Optometrists?

CLASSIFIED ADVERTISING WORKS

- JOB OPENINGS
- CME PROGRAMS
- PRODUCTS & SERVICES
- AND MORE...

Contact us today for classified advertising:
Toll free: **888-498-1460**
E-mail: sales@kerhgroup.com

**Do you have Products
and Services for sale?**

**CONTACT US TODAY
FOR CLASSIFIED ADVERTISING**
Toll free: **888-498-1460**
E-mail: sales@kerhgroup.com

Faculty

UMSL Optometry Assistant Clinical Professor (Non-tenure-track)

The College of Optometry at the University of Missouri-St. Louis invites applications for full-time non-tenure track positions with an opportunity to join a dynamic and progressive academic community. Successful applicants will receive a nine-month appointment. Initial rank for the full-time clinical appointment will be commensurate with prior experience, qualifications and individual interests. There is the possibility for a summer research or instructional assignment if mutually agreeable.



Applications are encouraged from a variety of areas including:

- Low vision, Vision rehabilitation
- Pediatric Optometry, Binocular Vision, Acquired Brain Injury
- Ocular Surface Disease, Dry Eye
- Ocular and Systemic Disease including diagnostic and therapeutic procedures
- Primary Eye Care

Responsibilities: Successful candidates for clinical ranks are expected to provide instruction and service in the professional program and maintain a clinical practice for UMSL Eye Care and affiliated clinic partners. They may also serve as a mentor for student research. The primary area of emphasis depends upon prior accomplishments, qualifications and candidate interests.

Qualifications Required:

- Ability to contribute to the development, evaluation, and enhancement of optometric education
- Ability to contribute to the mission and strategic priorities of the College of Optometry
- Open to development and use of innovative instructional strategies and technology
 - Knowledge in area of emphasis and contemporary issues in optometry and healthcare
 - Commitment to effective dissemination of evidence based practice and translating research into clinical care and education
- Commitment to foster inclusive college community for all students, patients, staff, and faculty

The position requires a Doctor of Optometry (OD) degree, eligible for or active license to practice optometry in Missouri, and alternative teaching styles such as learner-centered and case-based approaches. A license to practice in Illinois is desirable. Candidates with a Masters or Doctoral Degree with a record of scholarship or who have completed an ACOE-accredited residency are preferred.

The University of Missouri-St. Louis is a public, metropolitan land-grant institution committed to basic and applied research, teaching and service with 17,000

students and 1,325 full and part-time faculty members UMSL is the largest university in the St. Louis region and the 3rd largest in Missouri with 131 degree and associate programs. See additional information about UMSL.edu

The College of Optometry includes a 4-year professional degree (O.D.) program and post-professional residency programs. See additional information about Optometry.umsl.edu.

Those who wish to be considered a candidate for a position must provide an application that includes a letter of interest, curriculum vitae and a list of four professional references. Formal submissions via the University website: www.umsl.jobs. Applications will be accepted and reviewed immediately. The position will remain open until filled.

Questions may be directed to:
Julie DeKinder, OD
Director, Academic and Residency Programs
dekinderj@umsl.edu

The University of Missouri-Saint Louis is an equal opportunity/affirmative action employer committed to excellence through diversity.



Born This Way

When a patient describes a longstanding and gradually worsening issue, what type of disease should you consider?

A 74-year-old man presented to the office with a chief complaint of poor vision, OS>OD “for years.” He said the issue gradually became worse, making his left eye substantially weaker than the right. He did not report any pain. He denied trauma, systemic disease and allergies of any kind. He reported no medication use.

Clinical Findings

His best-corrected entering visual acuities were 20/40 OD and 20/60

OS. His external examination was unremarkable, with no evidence of an afferent pupillary defect. Confrontation fields were normal. Goldmann applanation tonometry measured 17mm Hg OU.

The pertinent anterior segment findings are demonstrated in the photographs below.

For More Information

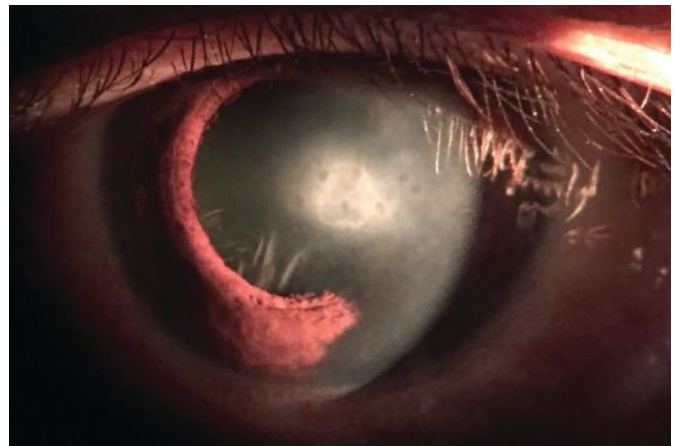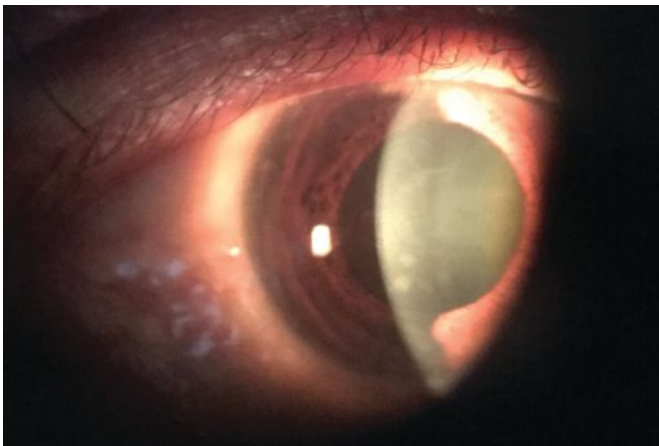
Additional studies included refraction to determine if an updated spectacle prescription might improve

his function. Laser interferometry could be completed to assess retinal function to ensure that if a surgical approach (cataract or corneal) were undertaken, no retinal contraindications would prevent a good outcome. Corneal staining with sodium fluorescein and rose bengal would permit understanding of the cornea’s overall health status.

Your Diagnosis

What would be your diagnosis in this case? Is there anything in the reported history that might point toward the etiology? What is the patient’s likely prognosis?

To find out the diagnosis and management course, please read the online version of this article at www.reviewofoptometry.com. ■



The anterior segment findings in our patient, OD (left) and OS (right). Do these presentations lead to any possible diagnoses to consider?

About Dr. Gurwood

Dr. Gurwood is a professor of clinical sciences at The Eye Institute of the Pennsylvania College of Optometry at Salus University. He is a co-chief of Primary Care Suite 3. He is attending medical staff in the department of ophthalmology at Albert Einstein Medical Center, Philadelphia. He has no financial interests to disclose.

Retina Quiz Answers (from page 82)—Q1: c, Q2: d, Q3: c, Q4: a, Q5: c

NEXT MONTH IN THE MAG

In August, we present our 46th annual contact lens report. Articles will include:

- Which Factors Matter Most in Contact Lens Selection?
- Six Tips for Succeeding with Multifocals

- The Newest Lenses on the Market: What Makes Them Different?

- Using Contact Lens Surface Treatments to Reduce Complaints

Also in this issue:

- Scope Expansion Series: Making the Most of Oral Meds
- How to Work Up Vertigo, Nystagmus and Other Neuro Concerns

INNOVATION RUNS IN THE FAMILY

The widest range of lenses for immediate in-office fittings,*
built with innovative technologies for success



MoistureSeal® Technology
for all-day comfort



OpticAlign® Design
for stability



3-Zone Progressive™ Design
for seamless vision



SCAN to discover more about the
Bausch + Lomb ULTRA® family

*Based on a fit set comparison of leading brands: Biofinity, Air Optix, Acuvue Oasys, and Acuvue Vita.

Bausch + Lomb ULTRA, MoistureSeal, the MoistureSeal drop design, OpticAlign, and 3-Zone Progressive are trademarks of Bausch & Lomb Incorporated or its affiliates.

Any other products/brand names and/or logos are trademarks of the respective owners.

©2022 Bausch & Lomb Incorporated or its affiliates. ZUS.0009.USA.22.

BAUSCH + LOMB



**RECOMMEND
OPTI-FREE®
PUREMOIST®, SO
YOUR PATIENTS
ARE FREE TO
GET THE
MOST OUT OF
THEIR DAY**

**THAT'S OPTI-FREE®
FREEDOM**



Free your patients with OPTI-FREE® Puremoist®, Alcon's #1 doctor recommended, multi-purpose solution.¹ Its dual-disinfecting formula cleans while the HydraGlyde® Moisture Matrix moisturizes, for comfort that lasts from morning 'til night.²⁻⁴



Opti-Free.MyAlcon.com

References: **1.** Alcon data on file, 2019. **2.** Kern JR, Kappell G, Trinh H, et al. Antimicrobial properties of a novel contact lens disinfecting solution, OPTI-FREE® EverMoist®. *Cont Lens Anterior Eye*. 2011;34(suppl 1):S30. **3.** Alcon data on file, 2010. **4.** Alcon data on file, 2011.

© 2019 Alcon Inc. 5/19 US-OPM-19-E-1125

Alcon