

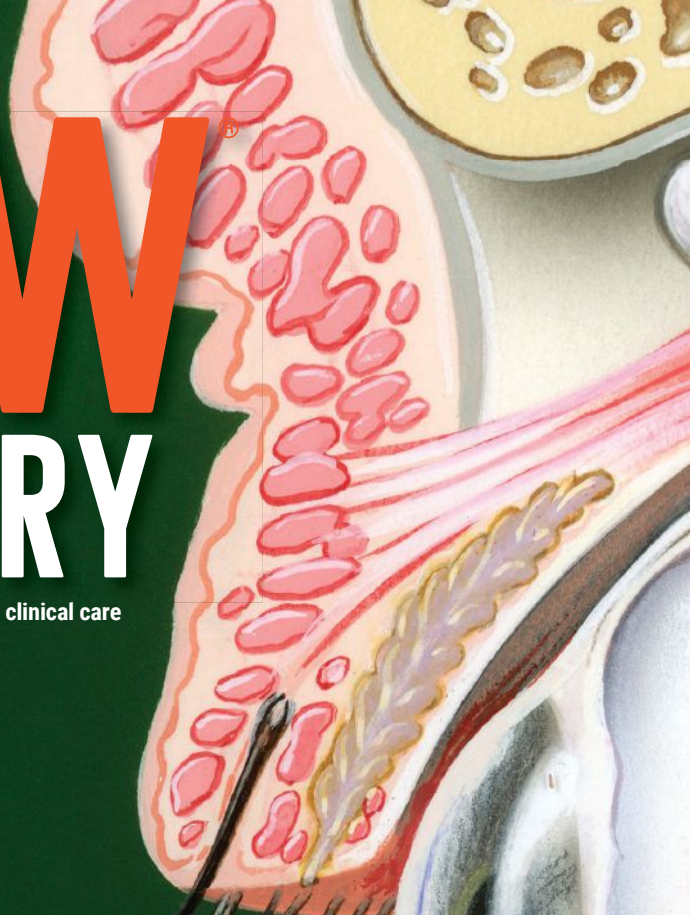
Survey: Optometrists Ready to Step Up to Subspecialization, P. 40

REVIEW of OPTOMETRY

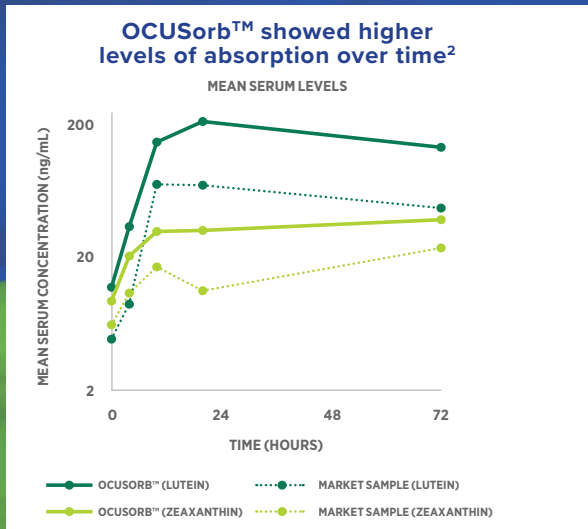
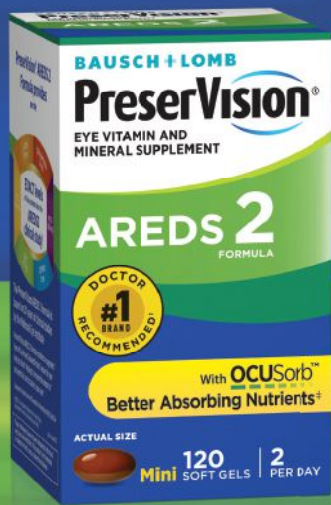
October 15, 2023 • reviewofoptometry.com

Leadership in clinical care

Restoring & Maintaining Eyelid Health



SAME PROVEN FORMULA BETTER ABSORPTION[†]



Contains the exact AREDS 2 formula recommended by the NEI - with more bioavailable ingredients!

Only PreserVision AREDS 2 Formula Eye Vitamins contain OCUSorb™, a proprietary formulation of micronized lutein and zeaxanthin that has been clinically shown to offer superior absorption.[†]

For patient samples and tools: 1-855-54BL-OTC (1-855-542-5682)

NEI = National Eye Institute

¹Data on file for #1 Doctor Recommended Brand, Bausch + Lomb

²Compared to the market sample, Kotagiri SR, Morde A, Rai D, et al. Ophthalmol Ther. 2022;11(4):1463-1477

³Compared to original lutein and zeaxanthin in PreserVision AREDS 2 Soft Gels

AREDS and AREDS2 are registered trademarks of the United States Department of Health and Human Services (HHS).

OCUSorb is a trademark of OmniActive Health Technologies Ltd. used under license. © 2023 Bausch + Lomb. PN10654 PVN.0065.USA.23

*This statement has not been evaluated by the Food and Drug Administration. This product is not intended to diagnose, treat, cure or prevent any disease.



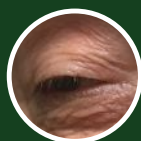Survey: Optometrists Ready to Step Up to Subspecialization, P. 40

REVIEW *of* OPTOMETRY

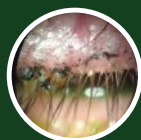October 15, 2023 • reviewofoptometry.com

Leadership in clinical care

Restoring & Maintaining *Eyelid Health*



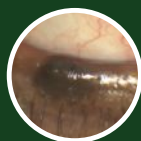Follow This Practical Workup
for Acquired Ptosis, P. 48



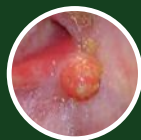Five Questions About
Medical Therapy for *Demodex*, P. 60



Tackle MGD With These
Hands-on Interventions, P. 66

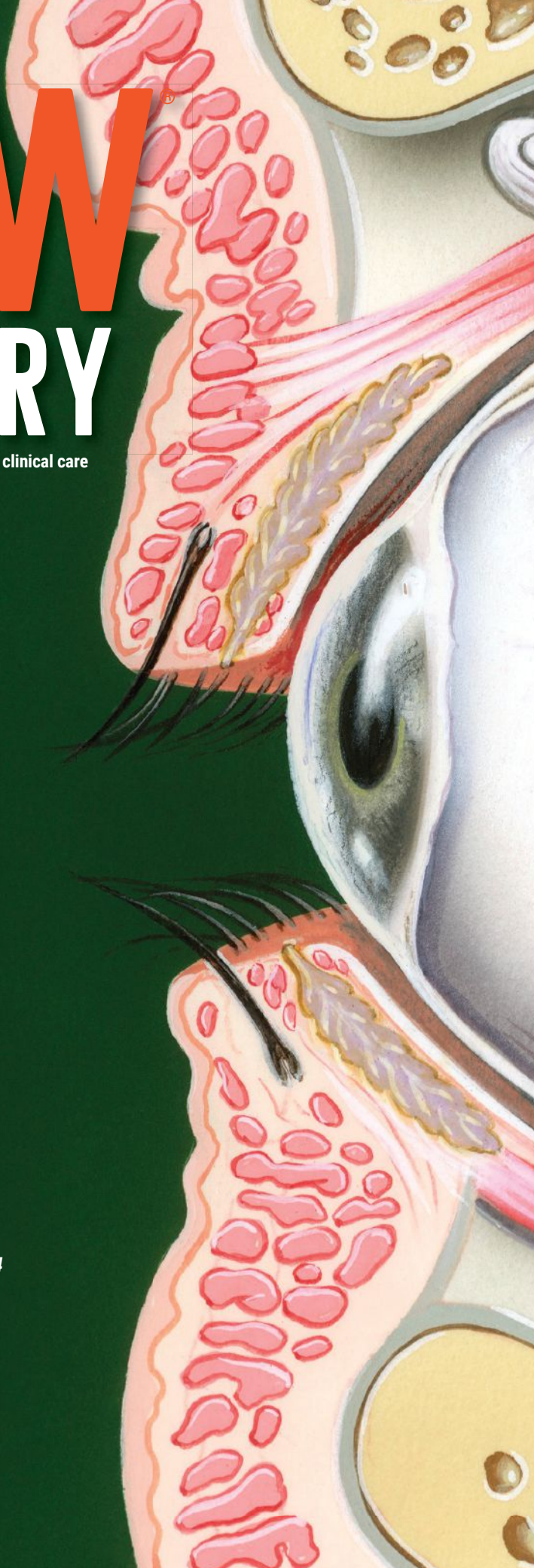


Recognize Benign vs. Malignant
Eyelid Tumors and Lesions, P. 74



A Game Plan for Managing Eyelid
Lesions and Related Conditions, P. 84

—EARN 2 CE CREDITS



When Selecting a Prescription
Dry Eye Treatment

DON'T

**MAKE
HER
WAIT.**



Not an actual patient.

Indication

Xiidra® (lifitegrast ophthalmic solution) 5% is indicated for the treatment of signs and symptoms of dry eye disease (DED).

Important Safety Information

- Xiidra is contraindicated in patients with known hypersensitivity to lifitegrast or to any of the other ingredients.
- In clinical trials, the most common adverse reactions reported in 5-25% of patients were instillation site irritation, dysgeusia and reduced visual acuity. Other adverse reactions reported in 1% to 5% of the patients were blurred vision, conjunctival hyperemia, eye irritation, headache, increased lacrimation, eye discharge, eye discomfort, eye pruritus and sinusitis.
- To avoid the potential for eye injury or contamination of the solution, patients should not touch the tip of the single-use container to their eye or to any surface.



Novartis Pharmaceuticals Corporation
East Hanover, New Jersey 07936-1080



CHOOSE XIIDRA
Because lasting symptom
relief can start as early as
2 WEEKS^{1*}



Access to Xiidra is
better than ever²

*Xiidra reduced symptoms of eye dryness at 2 weeks (based on Eye Dryness Score compared to vehicle) in 2 out of 4 studies, with improvements observed at 6 and 12 weeks in all 4 studies.^{1†}

Important Safety Information (cont)

- Contact lenses should be removed prior to the administration of Xiidra and may be reinserted 15 minutes following administration.
- Safety and efficacy in pediatric patients below the age of 17 years have not been established.

Please see Brief Summary of Important Product Information on adjacent page.

[†]Pivotal trial data

The safety and efficacy of Xiidra were assessed in four 12-week, randomized, multicenter, double-masked, vehicle-controlled studies (N=2133). Patients were dosed twice daily. **Use of artificial tears was not allowed during the studies.** The study end points included assessment of signs (based on Inferior fluorescein Corneal Staining Score [ICSS] on a scale of 0-4) and symptoms (based on patient-reported Eye Dryness Score [EDS] on a visual analogue scale of 0-100).¹

Effects on symptoms of dry eye disease: A larger reduction in EDS favoring Xiidra was observed in all studies at day 42 and day 84. Xiidra reduced symptoms of eye dryness at 2 weeks (based on EDS) compared to vehicle in 2 out of 4 clinical trials.¹

Effects on signs of dry eye disease: At day 84, a larger reduction in ICSS favoring Xiidra was observed in 3 of the 4 studies.¹

References: **1.** Xiidra [package insert]. East Hanover, NJ: Novartis Pharmaceuticals Corp. **2.** Data on file. DRF Fingertip Formulary[®] Novartis Pharmaceuticals Corp; July 2022.

XIIDRA, the XIIDRA logo and ii are registered trademarks of Novartis AG.

Xiidra® (lifitegrast ophthalmic solution), for topical ophthalmic use

Initial U.S. Approval: 2016

BRIEF SUMMARY: Please see package insert for full prescribing information.

1 INDICATIONS AND USAGE

Xiidra® (lifitegrast ophthalmic solution) 5% is indicated for the treatment of the signs and symptoms of dry eye disease (DED).

4 CONTRAINDICATIONS

Xiidra is contraindicated in patients with known hypersensitivity to lifitegrast or to any of the other ingredients in the formulation [see *Adverse Reactions (6.2)*].

6 ADVERSE REACTIONS

The following serious adverse reactions are described elsewhere in the labeling:

- Hypersensitivity [see *Contraindications (4)*]

6.1 Clinical Trials Experience

Because clinical trials are conducted under widely varying conditions, adverse reaction rates observed in clinical trials of a drug cannot be directly compared to rates in the clinical trials of another drug and may not reflect the rates observed in practice.

In five clinical trials of DED conducted with lifitegrast ophthalmic solution, 1401 patients received at least one dose of lifitegrast (1287 of which received lifitegrast 5%). The majority of patients (84%) had less than or equal to 3 months of treatment exposure. One hundred-seventy patients were exposed to lifitegrast for approximately 12 months. The majority of the treated patients were female (77%). The most common adverse reactions reported in 5%-25% of patients were instillation-site irritation, dysgeusia, and reduced visual acuity.

Other adverse reactions reported in 1%-5% of the patients were blurred vision, conjunctival hyperemia, eye irritation, headache, increased lacrimation, eye discharge, eye discomfort, eye pruritus, and sinusitis.

6.2 Postmarketing Experience

The following adverse reactions have been identified during post-approval use of Xiidra. Because these reactions are reported voluntarily from a population of uncertain size, it is not always possible to reliably estimate their frequency or establish a causal relationship to drug exposure.

Rare serious cases of hypersensitivity, including anaphylactic reaction, bronchospasm, respiratory distress, pharyngeal edema, swollen tongue, urticaria, allergic conjunctivitis, dyspnea, angioedema, and allergic dermatitis have been reported. Eye swelling and rash have also been reported [see *Contraindications (4)*].

8 USE IN SPECIFIC POPULATIONS

8.1 Pregnancy

Risk Summary

There are no available data on Xiidra use in pregnant women to inform any drug-associated risks. Intravenous (IV) administration of lifitegrast to pregnant rats, from pre-mating through gestation day 17, did not produce

teratogenicity at clinically relevant systemic exposures. Intravenous administration of lifitegrast to pregnant rabbits during organogenesis produced an increased incidence of omphalocele at the lowest dose tested, 3 mg/kg/day (400-fold the human plasma exposure at the recommended human ophthalmic dose [RHOD], based on the area under the curve [AUC] level). Since human systemic exposure to lifitegrast following ocular administration of Xiidra at the RHOD is low, the applicability of animal findings to the risk of Xiidra use in humans during pregnancy is unclear [see *Clinical Pharmacology (12.3) in the full prescribing information*].

Data

Animal Data

Lifitegrast administered daily by IV injection to rats, from pre-mating through gestation day 17, caused an increase in mean pre-implantation loss and an increased incidence of several minor skeletal anomalies at 30 mg/kg/day, representing 5,400-fold the human plasma exposure at the RHOD of Xiidra, based on AUC. No teratogenicity was observed in the rat at 10 mg/kg/day (460-fold the human plasma exposure at the RHOD, based on AUC). In the rabbit, an increased incidence of omphalocele was observed at the lowest dose tested, 3 mg/kg/day (400-fold the human plasma exposure at the RHOD, based on AUC), when administered by IV injection daily from gestation days 7 through 19. A fetal no observed adverse effect level (NOAEL) was not identified in the rabbit.

8.2 Lactation

Risk Summary

There are no data on the presence of lifitegrast in human milk, the effects on the breastfed infant, or the effects on milk production. However, systemic exposure to lifitegrast from ocular administration is low [see *Clinical Pharmacology (12.3) in the full prescribing information*]. The developmental and health benefits of breastfeeding should be considered, along with the mother's clinical need for Xiidra and any potential adverse effects on the breastfed child from Xiidra.

8.4 Pediatric Use

Safety and efficacy in pediatric patients below the age of 17 years have not been established.

8.5 Geriatric Use

No overall differences in safety or effectiveness have been observed between elderly and younger adult patients.

Distributed by:
Novartis Pharmaceuticals Corporation
One Health Plaza
East Hanover, NJ 07936
T2020-87



Study Finds Increased Risk of Stroke, Heart Attack, Death After RVO

Researchers suggest doctors should be aware of elevated likelihood of these vascular events.

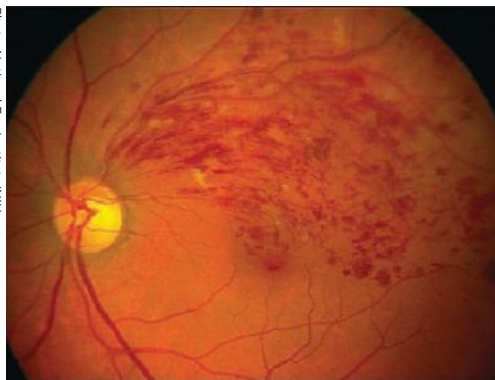
Retinal vein occlusion (RVO) is associated with cardiovascular risk factors, and it's possible that such incidents may also carry predictive value for a subsequent vascular event or mortality risk. In a new study, researchers examined rates of stroke, myocardial infarction, deep vein thrombosis, pulmonary embolism and death in patients after RVO and found patients an increased risk of many of these vascular events.

A total of 45,303 patients with a diagnosis of RVO and a control group of patients with cataract were included. Patients were excluded if they had history of stroke, myocardial infarction, deep vein thrombosis or pulmonary embolism within two years of diagnosis of RVO or cataract. The average age of RVO diagnosis was 68.1 years. Regarding systemic comorbidities, half of the cohort had a diagnosis of hypertension (51.6%) and about a third had diabetes (28.2%) and/or hyperlipidemia (31.3%).

With a closely matched control population to assure parity in age, gender, ethnicity, race and the systemic comorbidities noted above, this study found increased risks of death and subsequent vascular events, including stroke and myocardial infarction, after RVO.

“Overall, our study shows increased risk of subsequent vascular events such as death, stroke and myocardial infarction after RVO compared to a control population at follow-ups of one, five

Photo: National Eye Institute/NIH



Retinal vein occlusion may be a bellwether of future systemic cardiovascular events.

RELATIVE RISKS FOLLOWING RVO

Cardiovascular Event	1 Year RR	5 Year RR	10 Year RR
Death	1.30	1.22	1.08
Stroke	1.61	1.31	1.18
MI	1.26	1.13	1.06
DVT	1.65	0.94	1.05
PE	0.98	0.95	0.85

and 10 years,” the authors wrote in their paper for *American Journal of Ophthalmology*.

“There was minimal risk of subsequent deep vein thrombosis or pulmonary embolism in RVO patients, except for a mildly elevated risk of deep vein thrombosis at one year compared to the control population, though this trend was not seen at five or 10 years of follow-up.”

Examining central vein occlusion and branch RVO separately may be

needed to explore the underlying mechanism, as both showed elevated risk of death when comparing these patients. “We performed subgroup analyses and found a matched analysis of patients with central RVO compared to branch RVO showed higher risk of death for patients who experienced central RVO at one year, five years and 10 years,” the study authors noted.

They did point out several study limitations in their paper, including that ischemic and nonischemic retinal vein occlusion were not distinguished between one another. “Whether the degree of ischemic insult to the retina portends to a worse systemic prognosis could be a consideration for future investigations,” they wrote.

Overall, optometrists and ophthalmologists “should be aware of elevated risk of death and vascular events including myocardial

infarction or stroke in patients presents with RVO,” the researchers concluded from their findings. “Long-term systemic evaluation for cardiovascular risk factors in conjunction with primary care providers for patients who present with branch RVOs and central RVOs is imperative to minimize subsequent vascular events.” ◀

Wai KM, Ludwig CA, Koo E, et al. Risk of stroke, myocardial infarction, deep vein thrombosis, pulmonary embolism and death after retinal vein occlusion. *Amer J Ophthalmol*. August 23, 2023. [Epub ahead of print].

Academy of Ophthalmology Gives Qualified Support to Thermal Pulsation for MGD, Dry Eye

Nine of 11 studies in a new literature review reported that the treatment's clinical benefit was superior to conventional methods, but industry involvement should give pause.

Researchers report, in a new Ophthalmic Technology Assessment by the American Academy of Ophthalmology, on a literature review to evaluate the safety and efficacy of an increasingly popular treatment for meibomian gland dysfunction (MGD)—thermal pulsation—alongside conventional therapies, such as warm compresses and eyelid hygiene. The team found that the intervention can improve subjective and objective parameters of MGD and dry eye after a single session, though treatment durability and long-term benefits remain unclear.

In each of the 11 studies included in the review, participants underwent single, 12-minute sessions using the LipiFlow thermal pulsation system (Johnson & Johnson). Controls were treated with lid hygiene or warm compress therapy.

Throughout the first 12 months after thermal pulsation treatment, patients showed improvement in both subjective and objective metrics of MGD and dry eye compared with controls. Nine of 11 studies reported greater efficacy with thermal pulsation than with standard warm compress therapy and eyelid hygiene, although it's important to note that four of these studies had relevant industry conflicts of interest.

"Patients from predominately white or Asian populations experienced both subjective benefits (as measured by validated questionnaires) and objective improvement in the health of the eyelids and ocular surface compared with nontreatment for several months after a single thermal pulsation session," the researchers reported in their study, published in *Ophthalmology*.

Regarding safety, the procedure passed with flying colors in all 11 studies, none of which reported serious adverse events.

While this literature review only evaluated patients with up to one year

of follow-up, further research will be needed to assess the durability of thermal pulsation in patients with MGD or dry eye, the authors suggest. "Independent, unbiased studies of different thermal pulsation treatment frequencies and controlled studies of other thermal pulsation platforms in diverse populations are warranted," they wrote, adding that devices other than LipiFlow should also be assessed.

The team concluded that, based on the current evidence, "thermal pulsation seems to be safe and may add to the therapeutic armamentarium for MGD and dry eye, and it may fill a void if regi-

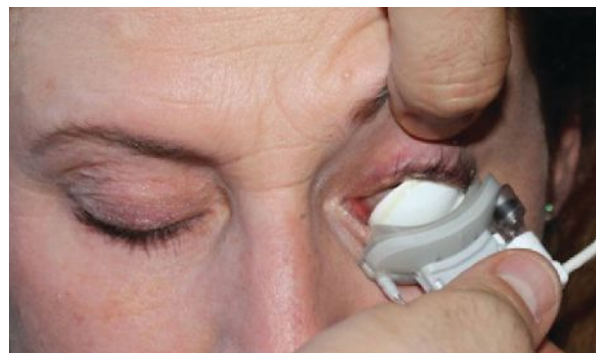

Photo: Katherine Sanford, OD

While research validates the safety and efficacy of thermal pulsation for the treatment of MGD and dry eye, the durability and long-term effects warrant further investigation.

mented lid hygiene and warm compresses are not possible or not desirable." ◀

Tao JP, Shen JF, Aakalu VK, et al. Thermal pulsation in the management of meibomian gland dysfunction and dry eye: a report by the American Academy of Ophthalmology. *Ophthalmology*. August 27, 2023. [Epub ahead of print].

AAOphth Report Supports First-line SLT

Another recent Ophthalmic Technology Assessment performed by the American Academy of Ophthalmology reviewed the safety and efficacy of selective laser trabeculoplasty (SLT), which confirmed the procedure's clinical safety and identified areas for further research.

Thirty articles—including the LiGHT Trial—were included in the study. Of these, 19 studies were assigned a level 1 rating and 11 were assigned a level 2 rating.

The data from level 1 studies show that SLT has long-term effectiveness as a primary or supplemental treatment to medical therapy in open-angle glaucoma. First-line SLT and medications showed equivalent IOP control for open-angle glaucoma and ocular hypertension and may also be more cost-effective and provide better long-term disease control than medications. Interestingly, SLT didn't result in measurable quality-of-life improvement.

In level 1 studies, SLT and argon laser trabeculoplasty were found to be equivalent in safety and long-term efficacy in several studies, with repeat SLT possibly more effective than repeat ALT in the long-term. Level 1 studies also showed that SLT's IOP lowering was equivalent to several other modalities, including micropulse laser trabeculoplasty, pattern-scanning laser trabeculoplasty and titanium-sapphire laser trabeculoplasty. Level 2 data showed equivalence with excimer laser trabeculoplasty.

Additionally, most studies indicated that perioperative corticosteroid and NSAID drops didn't hinder the treatment's IOP-lowering effects.

The review also identified several areas for further study, including a need for more randomized clinical trials with diverse patient populations and more randomized studies on treatment settings and repeatability.

Takusagawa HL, Hogue A, Sit AJ, et al. Selective laser trabeculoplasty for the treatment of glaucoma: a report by the American Academy of Ophthalmology. *Ophthalmology* 2023;1-11.

Optometry Defends Proposed VA National Practice Standards

In a recent House of Representatives hearing, AOA and AFOS members were able to refute many spurious claims of inadequate training and safety concerns voiced by ophthalmology and organized medicine.

The Department of Veterans Affairs is the country's largest integrated healthcare network, with nearly 1,300 facilities extending from coast to coast, most of which offer eyecare services. VA optometrists account for roughly 75% of the network's total eyecare visits each year.

While 10 states and counting now recognize more advanced procedures, including laser eye surgery, as part of optometry's scope of practice, doctors in the VA must abide by Department regulations regardless of individual laws in their practicing state. Aiming to rectify this, the VA has been developing new national practice standards for optometry and more than 50 other health specialties through what's known as the Federal Supremacy Project. The Department is proposing to allow its ODs to practice to the full extent of their training and ability—that is, based on the scope of practice of each provider's state of licensure. VA doctors with the proper certification would be allowed to perform laser and other types of eye surgeries, certain injections and lesion removal.

Unsurprisingly, ophthalmology and organized medicine are pushing back against the initiative, as was evident by testimonies presented in a congressional hearing on Sept 19. Several members of the American Medical Association and American Academy of Ophthalmology (AAOphth) took the stand to argue against the proposed national standards, citing spurious claims about the training and abilities of today's optometrists.

Present to defend the proposed national practice standards was a member of the American Optometric Association (AOA) Board of Trustees, Paul Barney, OD, joined by 20 optometrists in the room from the AOA and Armed Forces Optometric Society (AFOS), who showed up to express their support.

Dr. Barney opened his remarks by pointing out that “roughly 40% of counties or county equivalents in the US have access to a doctor of optometry but not an ophthalmologist, and that number is expected to grow. American doctors of optometry are stepping up to fill that gap,” he said. “Optometry's training and abilities have continued to advance alongside the evolution of technology, and today's rigorous four-year optometry school curriculum focuses exclusively on the study of ocular health and vision care, laser and surgical education,” he explained.

In his opening statement for the opposition, AAOphth CEO, Stephen McLeod, MD, argued that the reverse was true. “As medical doctors with extensive surgical training, indeed many thousands of hours devoted specifically to eye surgery, only ophthalmologists possess the expertise and the experience required to perform a surgery and to address the potential complications that might arise.” He went on to allege that “optometrists are not trained to safely perform surgical procedures; optometry training primarily focuses on the correction of refractive error, glasses and contact lenses, and on primary eye care.”

Refuting this claim, Dr. Barney noted that “contrary to what detractors say, laser and surgical care has been and continues to be taught at each and every school and college of optometry in the country.”

Flawed “Evidence” of OD Risk

Nate Lighthizer, OD, associate dean at NSU Oklahoma College of Optometry, adds that today's optometrists are trained to provide and manage a much broader range of care than Dr. McLeod had contended. “An optometrist's four-year training covers every aspect of the eye-



Stephen McLeod, MD, portrayed optometric training in advanced procedures as inherently flawed. ODs countered with evidence to the contrary.

ball—glasses, contact lenses, low vision, ocular disease, glaucoma, macular degeneration, dry eye and the list goes on and on,” says Dr. Lighthizer. “Our students here in Oklahoma are trained at every level, from didactically in the classroom to hands-on laboratory training with lasers and simulated model eyes made and invented by ophthalmology. The students are then tested on both of those in the lab and in the classroom. They're also doing procedures on live patients.”

In response to Dr. McLeod's argument on the stand that many optometrists will be “performing a laser procedure for the first time on a human eye,” Dr. Lighthizer makes the point that this is the case for every doctor—optometrists and ophthalmologists alike.

“When new procedures come out, ophthalmologists don't have to go back to medical school or ophthalmology residency,” he says. “They build upon their training and education and they add a new procedure to their armamentarium, which ophthalmologists who previously graduated will also perform for the first time on a human eye. Optometry is doing the exact same thing, and now every optometry school trains students on laser procedures.”

(See VA SCOPE on p. 14)

Real-world Results of Gene Therapy Show Its Merits in Hereditary Vision Loss

Subretinal injection of voretigene neparvovec achieved stable median BCVA and mean retinal thickness, and improvements in low-level luminance VA up to 32 months, but new chorioretinal atrophy appeared in 50% of treated eyes.

Inherited retinal degeneration (IRD) resulting from associated biallelic mutations of the RPE65 gene typically ends in blindness by the third or fourth decade of life. The mutation can manifest in a spectrum of retinal phenotypes, including Leber's congenital amaurosis, early-onset severe retinal dystrophy and juvenile retinitis pigmentosa.

Three years ago, the FDA approval of subretinal voretigene neparvovec (Luxturna, Spark Therapeutics) received worldwide acclaim as the first commercialized gene therapy, one that counteracts progress of RPE65-IRD.

New research appearing in *Ophthalmology* covers the impact that voretigene neparvovec treatment has on outcomes in a series of patients treated since approval. Patients with RPE65-IRD were treated by one surgeon at a single center with the injection and oral immunosuppression as was

recommended by manufacturer recommendation. A total of 30 eyes from 19 patients was analyzed—including 10 pediatric patients less than 20 years of age—and ages spanning from eight to 40 years old.

After comparing data from baseline to 24 months post-treatment, the study researchers found the fovea was completely or partially detached in 16 eyes, attached in 12 and not assessable in two upon intraoperative imaging. Median best-corrected visual acuity (BCVA) was better in the pediatric group at baseline and did not change significantly. Meaningful BCVA loss occurred in four out of 18 adult eyes, while meaningful gain was observed in two out of 18 adult eyes and two out of eight pediatric ones.

Low-luminance visual acuity and scotopic two-color threshold perimetry improved in pediatric cases, while scotopic blue full-field stimulus threshold

testing improved in all ages, but especially with children. New chorioretinal atrophy was observed in 13 out of 26 (50%) eyes at the site of the bleb and/or peripheral of vascular arcades. Mean retinal thickness also remained relatively stable, with an average thickness of 166.7 μ m at baseline and 157.7 μ m at month 12.

In their paper, the researchers elaborate on their findings, making sure to point out that significant loss of BCVA did not correlate with developing new or accentuated chorioretinal atrophy, an observation that aligns with other research. Median sum of total degrees at baseline was four times greater in the pediatric group than in adults, displaying the progressive nature of underlying degenerative processes. Five pediatric patients saw considerable improvement of up to 50% (190 sum degrees) at month 12, which corresponds to a gain of five years' Goldmann visual fields. Consequently, this treatment effect would be relevant for better patient mobility and would favor protocols prioritizing younger patient treatment.

However, the authors do report "severe vision loss in individual patients that appear to be treatment related in patients whom we treated only unilaterally." With some hands-on experience, the team now suggests "to prolong the treatment interval of the second eye to at least three months, since half of the unilaterally treated patients were unhappy because of loss of BCVA that did not appear predictable from the baseline data." ◀

Lorenz B, Künzel SH, Preising MN, et al. Real-world experience with Voretigene Neparvovec gene augmentation therapy in RPE65-mutation associated inherited retinal degeneration. *Ophthalmology*. September 11, 2023. [Epub ahead of print].

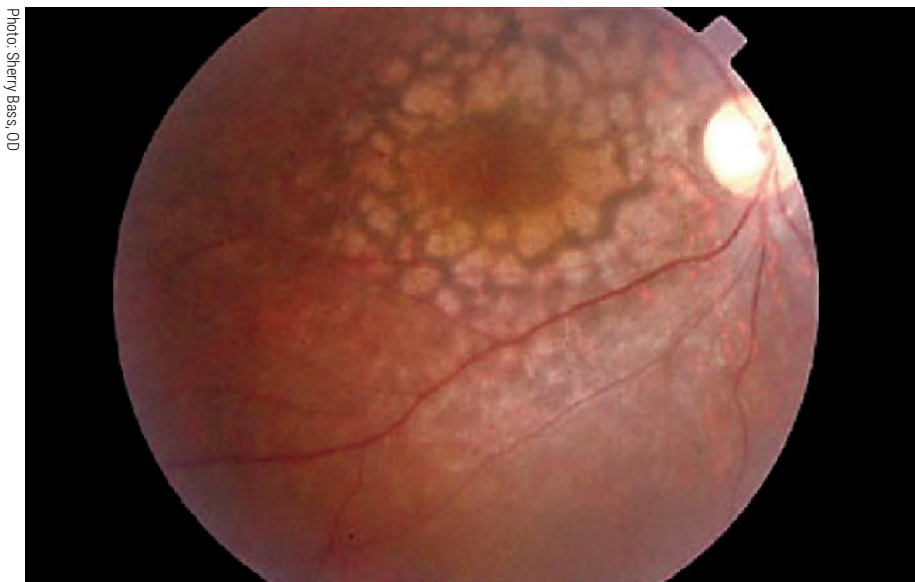
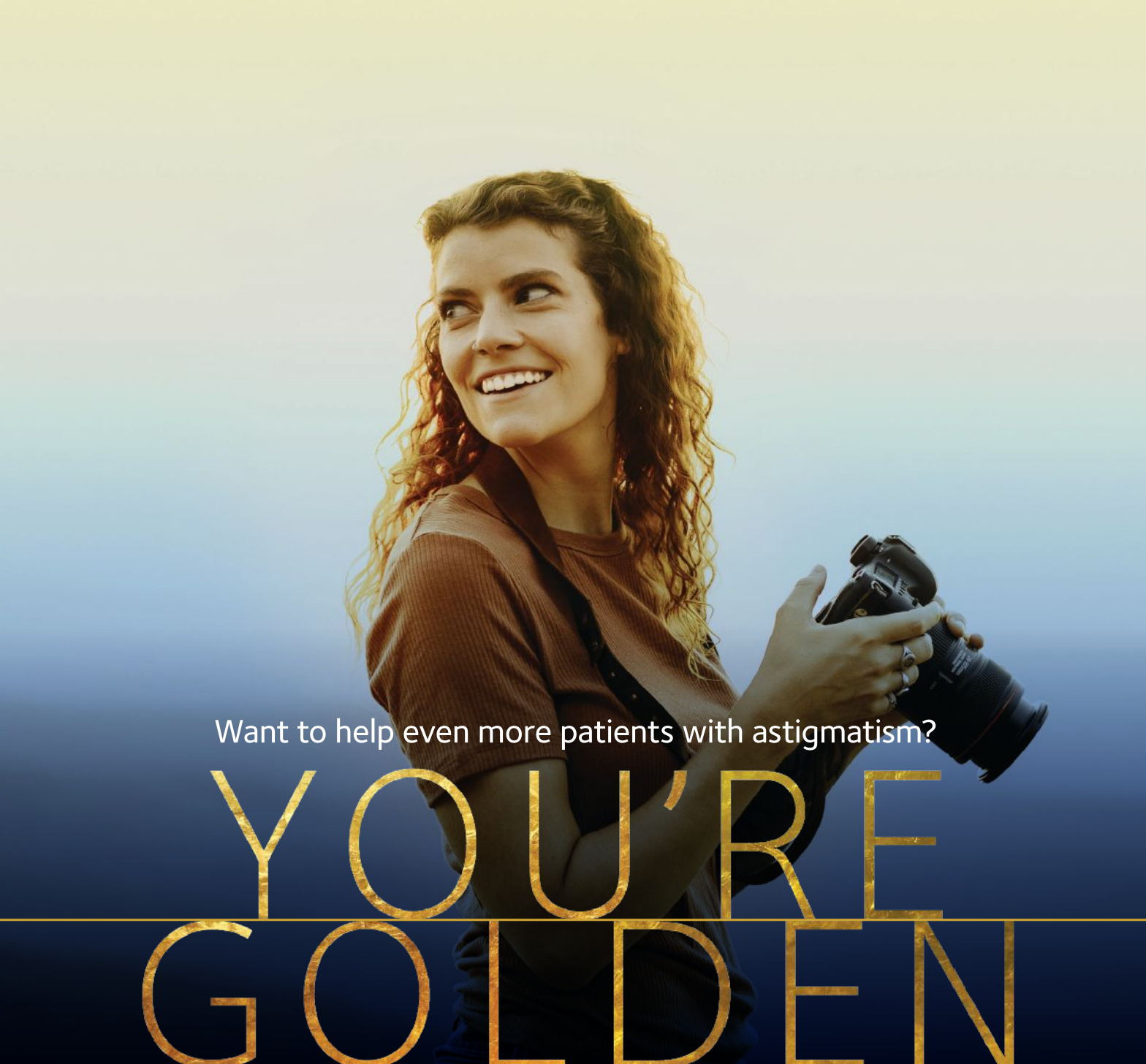


Photo: Sherry Bass, OD

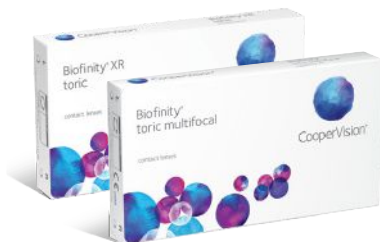Leber's congenital amaurosis (pictured) and related RPE65 conditions were generally responsive to gene therapy, particularly in the pediatric population of participants.



Want to help even more patients with astigmatism?

YOU'RE GOLDEN

Patients with astigmatism rave about Biofinity® toric lenses¹. It's also the **the most prescribed toric lens on the market**². With Aquaform® Technology and an extraordinary range³, more patients can experience premium comfort and visual clarity. With Biofinity®, you're golden.



Biofinity® |
toric | XR toric



EXPLORE
MORE TORIC



1. The results of an online survey involving patients who wear Biofinity toric contact lenses. January 2018 Biofinity toric wearer online survey. Data on file.
2. CVI data on file, 2021. US industry reports and internal estimates.
3. CooperVision data on file 2021. Rx coverage database; 14 to 70 years.
©2023 CooperVision 15193 ROO 9/23

Ophthalmology Workforce Expected to Decline 12% by 2035

The already understaffed profession would become the second lowest in terms of capacity relative to demand among 38 surgical specialties.

Since the 1990s, the number of ophthalmologists practicing in the US has been trending downwards, while the demand for eyecare is simultaneously increasing due to the country's aging population. In other words, as the number of patients climbs, the number of ophthalmologists drops, which could have major implications on the accessibility and availability of care.

A group of researchers recently evaluated ophthalmology workforce supply and demand projections between the years 2020 and 2035 to assess the potential trouble that lies ahead. Not unexpectedly, their data—obtained from the Health Resources and Services Administration website—forecasted a sizeable shortage of ophthalmology supply relative to demand by the year 2035.

Across the 15-year time span, the total ophthalmology supply is projected to decrease by 2,650 full-time OMDs, equating to a 12% decline. Meanwhile, the total demand is projected to increase by 24%, or 5,150 full-time ophthalmologists, representing a supply and demand mismatch of 30% workforce inadequacy. If initiatives to improve access to eyecare are successful by 2035, this projected shortage could expand to 36%.

More densely populated areas such as major cities will be disproportionately impacted by the growing shortage of ophthalmologists—by 2035, metro

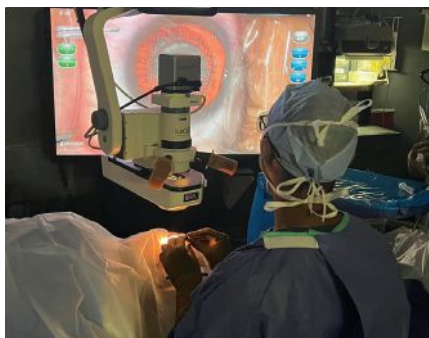

Photo: Lawrence Woodard, MD

While the number of ophthalmologists will decrease by 2,650, the demand for these doctors will increase to 5,150, representing a supply and demand mismatch of 30%. Popular surgeries like cataract removal will be among the sectors hardest hit.

geographies will face 77% workforce inadequacy vs. 29% in non-metro areas.

To hammer home the concerning reality of these numbers, the study authors pointed out in their *Ophthalmology* paper that by the year 2035 “ophthalmology is projected to have the second lowest rate of workforce adequacy (70%) out of 38 medical and surgical specialties studied.” Additionally, current projections suggest both optician and optometric workforces will also be inadequate by 2035, the paper states.

While the correlation between county-level ophthalmologist and optometrist availability requires further investigation, the researchers point out several potential consequences of projected shortages.

“There are known associations between ophthalmologist supply and eye health, which have been better demonstrated in specific geographies or for specific eye diseases,” they noted in their paper. “For example, access and utilization of diabetic eye care have been correlated with ophthalmologist supply. The prevalence of visual impairment was found to be inversely correlated with density of eyecare clinicians in California.”

Technological advancement could be one helpful solution to minimize workforce inadequacy in eyecare by enabling the use of telehealth and improving durability of ophthalmologic interventions, the researchers proposed. In addition to this, they go on to list numerous other factors that must be considered when forecasting eyecare supply and demand, including scope of practice, geographic trends, interconnectedness of allied professionals and the aging population and workforce.

In conclusion, the study authors urge that “further dedicated workforce supply and demand research for ophthalmology and other professionals is needed to help inform policy decisions and strategy to overcome projected workforce inadequacy.”

Berkowitz ST, Finn AP, Parikh R, Kuriyan AE, Patel S. Ophthalmology workforce projections in the United States, 2020-2035. *Ophthalmology*. September 13, 2023. [Epub ahead of print].

IN BRIEF

■ **Vitreous Detachment Can Be CRVO Prognostic Biomarker.** The vitreomacular interface is known to have important implications for retinal disease processes, including vein occlusion. Prior studies have suggested complete posterior vitreous detachment (PVD) may be protective against neovascularization in eyes with ischemic CRVO. A recent study in *Retina* found **cases of CRVO with complete PVD had significantly lower rates of cystoid macular**

edema (CME), lower central subfield thickness (CST) and lower anti-VEGF injection burden at one year.

The retrospective study assessed patients with acute, treatment-naïve CRVO who had at least one year of follow-up. Clinical characteristics, treatment patterns and outcomes were analyzed between eyes stratified based on presence or absence of a complete PVD on OCT.

Of the 102 acute, treatment-naïve CRVOs identified, 51% had complete PVD at presentation and 49% did not. **CST was significantly lower**

in those with complete PVD (12 months: 284.9µm vs. 426.8µm; last follow-up: 278µm vs. 372.8µm). One-year intravitreal injection burden was significantly less for those with a complete PVD than those without (5.1 vs. 6.7 injections). At 12 months, those with complete PVD at presentation had significantly less CME than those with incomplete PVD at presentation (32% vs. 65%).

“Vitreous may serve as a reservoir and microenvironment for pro-inflammatory cytokines and molecules present in eyes with RVO,”

the researchers wrote in their paper. “The presence of a complete PVD in eyes with CRVO contributes to reduced levels of locally circulating pro-inflammatory molecules at the vitreomacular interface.”

They concluded, **“Assessment of the vitreomacular relationship on OCT at presentation in CRVO eyes may serve as a prognostic imaging biomarker.”**

Zheng Y, Woodward R, Feng HL, et al. Implications of complete posterior vitreous detachment in eyes with central retinal vein occlusion. *Retina*. September 5, 2023. [Epub ahead of print].



TARSUS

Join us this October for An Experience to Remember

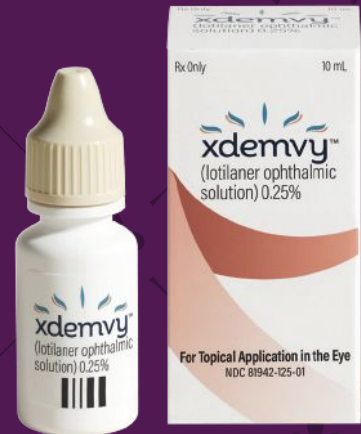Friday, October 13, 2023

6:00 PM – 8:00 PM CT

The Sugar Mill

1021 Convention Center Blvd., New Orleans, LA 70130

Enjoy a New Orleans-style reception and dinner while hearing about real-world patient and physician experiences with newly approved XDEMZY™ (lotilaner ophthalmic solution) 0.25%.



FACULTY



Paul M. Karpecki, OD
Moderator

Director of Cornea
Kentucky Eye Institute
Lexington, KY



Ben Gaddie, OD
Presenter

Owner and Director
Gaddie Eye Centers
Louisville, KY



Joshua Davidson, OD
Guest Speaker

Williamson Eye
Baton Rouge, LA



Selina McGee, OD
Guest Speaker

Owner
CEO BeSpoke Vision
Edmond, OK



REGISTER NOW

www.reviewofoptometry.com/tarsus-nola

This is an approved affiliate event in conjunction with the American Academy of Optometry. We encourage all participants to register for Academy 2023 New Orleans by visiting www.aaopt.org. US—2300348 8/23

Sponsored by



Brought to you by



Are One-week Cataract Post-op Visits Still Necessary?

Study says yes: omitting it would result in missed complications in 4.5% to 16% of cases.

As the most common ophthalmic procedure, cataract surgery accounts for 60% of Medicare eyecare costs. While these patients are typically evaluated postoperatively at one day, one week and one month, evidence is lacking on the necessity of this traditional schedule for uncomplicated cases. Given cataract's increasing incidence worldwide and the ever-safer techniques in use by surgeons, it's necessary to periodically revisit these care recommendations with an eye toward reducing the burden on practices and patients.

To investigate whether the week-one visit could be safely omitted, a team of doctors recently conducted a retrospective record review and published their findings in *Optometry & Vision Science*. Though they found the complication rate at one-week post-op was not low enough to justify omitting this visit, they noted that future research may help determine if telemedicine could be a viable alternative.

The study analyzed the records of a primarily Black and African-American population in an urban setting (n=72 eyes). Only subjects with no complications at one-day post-op were included in the review.

At one-week post-op, complications were detected in 15.3% of patients,

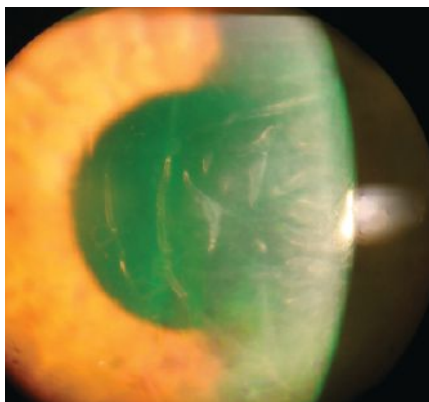

Photo: Derek Cunningham, OD

Though the safely profile of cataract surgery continues to improve, post-op corneal edema remains the most common complication, according to this study.

5.6% of whom required a treatment change. The most common complication observed was central corneal stromal edema (eight patients; 11%), followed by central microcystic corneal edema, increased intraocular pressure and hypotony, which each occurred in one patient (1.4% each).

The researchers determined from these findings that, "Omitting the one-week postoperative examination would result in missed complications in 4.48% to 15.97% of patients and failure to make unexpected management changes in 1.78% to 13.84% of patients," the team wrote in their journal article.

There have been mixed results in other studies that evaluated the outcome of omitting the postoperative week-one exam. For example, the authors cite one study involving 1,000 patients that found a similar 4.1% complication rate. However, another (n=1,510) found that only 0.9% of patients required an unexpected management change at one-week post-op.

One possible way to identify patients who may be able to safely skip the one-week visit is through phone surveys. The researchers cite several studies that reported high levels of patient satisfaction with telephone follow-ups for uncomplicated cases. Additionally, these surveys were also found to accurately predict the need for unexpected management changes.

Considering the small sample size in this study, the researchers advise that "clinicians should consider whether it is safe to omit the postoperative week-one examination and risk failure to identify and treat complications." Future research will also be able to determine whether telemedicine has a place in postoperative care for cataract patients. ◀

McLaughlin M, Salazar P, Piser D, Bands T, Shpountova K. Is it safe to omit the one-week postoperative examination after uncomplicated phacoemulsification? *Optom Vis Sci*. September 6, 2023. [Epub ahead of print].

IN BRIEF

■ **Optic Neuritis May Follow Fibromyalgia Diagnosis.**

Fibromyalgia is fairly prevalent but poorly understood, its ocular involvement even less so. In a recent study, researchers divided subjects aged 20 to 79 into those diagnosed with fibromyalgia and those with pain but no diagnosis. Both groups contained 479,892 participants (median age 45).

New incident optic neuritis cases were seen in 663 patients with fibromyalgia and 311 patients without fibromyalgia. Optic neuritis developed at a mean age of 54 and 52 years in the fibromyalgia

and non-fibromyalgia groups, respectively.

Overall, **the fibromyalgia group had an optic neuritis incidence rate of 35.65 per 100,000 person-years, compared with 16.75 per 100,000 person-years in the non-fibromyalgia group.** Those with fibromyalgia also had a significantly higher hazard ratio than the non-fibromyalgia group. Mean time to incident optic neuritis from fibromyalgia onset was 2.4 years.

Additionally, the researchers reported that **optic neuritis risk significantly increased in men between 60 and 79 years of age, and in women between 20 and 39 years of age.** They attributed these

differences to the effects of sex hormones and immune reactions, explaining that men have increased overall inflammation in old age due to declining levels of testosterone, while women with fibromyalgia often have growth hormone deficiencies, leading to a decrease in estrogen production in early adulthood that would otherwise protect against neuroinflammation until menopause-related declines.

"Since the autoantibody in fibromyalgia has not yet been fully elucidated and is still being studied, it is assumed that various immune mechanisms exist between fibromyalgia and the optic nerve, which consequently contribute to

the neuroinflammation of the optic nerve," the researchers wrote in their paper.

"Based on our results, **older men and younger women diagnosed with fibromyalgia should be followed up for the development of optic neuritis,**" the researchers concluded. "From a prevention perspective, regular ophthalmic examination and active control of any inflammatory reactions may be helpful in preventing or detecting this complication in its early stages in fibromyalgia patients."

Cho H, Lee G, Lee J. Increased risk of optic neuritis in patients with fibromyalgia: nationwide population-based cohort study in South Korea. *Am J Ophthalmol* 2023. [Epub ahead of print].

Dopaminergic Therapy Ineffective Aid to Amblyopia

Due to the shortened window in which amblyopia treatment yields likelihood of success, the need for effective therapy is palpable. Standard of care includes optical correction of refractive error and (somewhat controversially) occlusive path therapy, which may be effective up until 10 years of age. After this, the brain's plasticity is not as well maintained in neural pathways, and kids have even been shown to plateau in visual improvement at an even younger age, around seven to eight years.

Since older children may have not received or may have failed occlusive therapy, researchers seek alternative therapies. As outlined in a new literature review in *Ophthalmology*, one possible way to augment amblyopia treatment is with levodopa and/or carbidopa.

Of 55 articles, 12 were considered appropriate and included in final assessment. Each was assigned a level of

evidence by panel rating. Nine were rated level 1, three were rated level 2 and none were rated level 3 (lowest). Reviewing said articles, the researchers found treatment with these agents ranged in duration from three to 16 weeks, due to concerns of long-term adverse effects like tardive dyskinesia; no studies reported this complication in any participants.

Levodopa dosing ranged from 1.5mg to 8.3mg/kg/day, usually divided into three doses daily. Any carbidopa used in these studies was about 25% of the levodopa dosage in all treatments. Although the authors did find evidence supporting oral administration of both agents as an effective augmentation, the improved vision effect was small and only significant when compared with patching alone in two of the 12 studies. Unfortunately, vision regression was also reported in a majority of the young patients in nine out of 12 studies.

As such, the authors concluded that given the potential for significant side effects such as tardive dyskinesia long-term, "levodopa/carbidopa does not appear to be a viable option for amblyopia therapy." While short-term side effects were not consistently reported, most were mild, including headache and nausea.

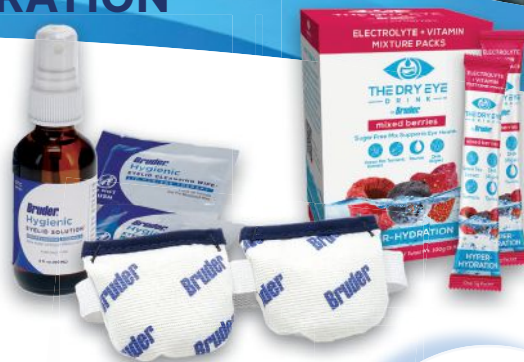Though improvement with levodopa/carbidopa was minimal and transient, the authors do note that studies demonstrated statistical significance when treatment possessed two characteristics: small patient numbers and younger patients.

Moving forward, the authors suggest that "future research may focus on changing the dosage of these medications, studying newer agents to increase dopaminergic or other neurotransmitter functions and minimizing side effects." ◀

Morrison DG, Heidary G, Chang MY, et al. Levodopa/carbidopa to augment the treatment of amblyopia: a report by the American Academy of Ophthalmology. *Ophthalmology*. August 29, 2023. [Epub ahead of print].



Open your eyes to Bruder.™ You know us for our #1 doctor-recommended moist heat mask. But did you know we also offer a comprehensive line of science-based products for lid hygiene and hydration? Your patients' healthy eyes start here, with Hygiene and the Bruder Hygienic Eyelid Solution and Cleansing Wipes (with or without tea tree oil). And don't forget to Hydrate with The Dry Eye Drink™ by Bruder, specially formulated to help improve the ocular surface.



Learn how to make Bruder part of your dry eye treatment protocol.



Join us at AAO 2023 Booth #1239 or contact us at eye@bruder.com or 888-827-8337 | bruder.com/pro

OD Advocates Come Out Swinging in VA Scope Fight

(Continued from p. 7)

To further challenge the safety of optometry-performed procedures, Dr. McLeod cited evidence from a 2016 study published in *JAMA Ophthalmology*, which found that the likelihood of repeat SLT was nearly tripled when performed by an optometrist rather than an ophthalmologist. However, Marc Myers, OD, of Coatesville VAMC, along with Dr. Lighthizer, say these findings must be taken with a grain of salt, if they're worth anything at all.

"The data in this study was obtained from 2008 to 2013, so it's a decade old, which is ancient in the world of health-care," Dr. Myers points out. He adds that because SLT is a repeatable procedure, a second treatment does not mean the first attempt was unsuccessful or flawed; rather, the treatment may have been repeated because it would benefit the patient.

Dr. Lighthizer also points out that the study didn't look at any outcomes (e.g., IOP reduction, effectiveness rate) or rate of complications; it only looked at when the code was billed. He echoes Dr. Myers, noting, "We have no idea if the procedures were being repeated more often by ODs because they were ineffective the first time, or if doctors were doing 180 degrees in one setting and then doing another 180 degrees weeks to months later."

A more recent study published this past August observed the actual outcomes of optometry- vs. ophthalmol-



Paul Barney, OD, set the record straight, explaining that educational curricula include laser and other surgical techniques at all colleges of optometry.

ogy-performed laser surgery, this time assessing patients who received YAG capsulotomy rather than trabeculectomy. No adverse reactions occurred in any of the patients who underwent the procedure by an OD and close to all patients reported subjective (99%) and objective (95%) improvements in vision.

At last month's hearing, Dr. Barney presented additional evidence on the safety of optometrist-performed laser surgery. He noted that in Oklahoma, where ODs have been using lasers for nearly 30 years, "state officials report little or no patient complaints have resulted from this increase in scope of care. Further," he continued, "malpractice rates for doctors of optometry in states with the authority to provide laser eye care and other contemporary procedures are roughly identical to rates and states with-

out that authority, which highlights the safety and efficacy of this care provided by optometrists."

The AOA expresses its gratitude to its members and ODs across the country who are advocating for these new national standards. "AFOS and AOA doctors and staff came together in a remarkable showing of what it means to fight for optometry and what is best for those who serve our country, with little notice," says Lindsay Wright, OD, executive director of AFOS. "Following the hearing, we didn't stop but instead spent the next day advocating with key legislators and leadership in DC, working to help them understand the significance of the national practice standards and Senate Bill 10 (CAREERS Act) for VA optometry." Dr. Wright adds, "This is a long game and this incredible group of doctors demonstrated the value of perseverance and standing up for what is right."

While advocacy efforts are in full swing, the process of securing these new regulations is far from over. The VA has yet to finalize the practice standards for optometry and many of the other health specialties in its system. Once completed, they will first need to pass the House of Representatives, where the bill currently resides, before heading to the Senate.

The AOA urges optometrists to contact their US Senators and House members to help communicate the importance of expanding access for America's veterans. ◀

IN BRIEF

■ Antihypertensive Drug May Increase Glaucoma Risk.

Hypertension and glaucoma often go hand in hand, but what if the treatment for one increased the risk for the other? That may be the case with antihypertensive calcium channel blockers (CCBs), according to a new study.

CCBs decrease blood pressure by relaxing venous smooth muscle. This has been thought to increase and stabilize blood flow to the optic nerve head. However, there's

inconclusive evidence, with studies showing different classes of CCBs have different and varying effects.

The cross-sectional, population-based study included 427,480 participants (median age 58), of which 7.8% were CCB users. The researchers found **use of CCBs—but not other antihypertensives—was associated with 39% increased odds of glaucoma.**

Additionally, CCB use was associated with thinner macular ganglion cell inner plexiform layer and macular retinal nerve fiber layer thickness, but not with intraocular

pressure (IOP). "The implication that CCBs are directly detrimental to retinal tissue is contrary to the general view of these agents being neuroprotective," they wrote.

The researchers proposed one explanation for this discrepancy: "In vitro studies do not account for the blood pressure-lowering ability of CCBs, and the CCBs investigated in the visual field studies did not appreciably affect blood pressure in glaucoma cases. It may be that the detrimental consequences of CCBs only manifest when coupled with the hypotensive and/or vasodilatory

properties of certain CCBs, such as amlodipine."

They concluded **there appears to be an "adverse association between CCB use and glaucoma, despite no apparent association with IOP."** Though a causal relationship wasn't established, they advised "CCB replacement or withdrawal may be considered should glaucoma progress despite optimal care."

Blazaki S, Blavakis E, Chlouverakis G, et al. Evolution of macular atrophy in eyes with neovascular age-related macular degeneration compared to fellow non-neovascular eyes. *Graefes Arch Clin Exp Ophthalmol*. August 11, 2023. [Epub ahead of print].

A Straightforward Approach to Managing and Supporting Patients with Diabetes



Paul Chous, MA, OD, FAAO
Chous Eyecare Associates



Nathan Lighthizer, OD, FAAO
NSU Oklahoma College of Optometry



Paul Karpecki, OD, FAAO
Kentucky Eye Institute

What can you tell us about the new *Modern Fundamentals of Diabetic Retinopathy Management in Optometry* report?

Dr. Chous: In 2022, I met with several colleagues who share my interest and passion for elevating diabetic eye care in optometry. We all agreed that there was a significant unmet need for concrete strategies to improve optometric management of diabetic eye disease. We formed a task force with a goal of creating actionable, practical guidelines to help address this significant public health issue.

Dr. Lighthizer: After many months of collaboration, we concluded that optometrists can do better for their patients without placing unreasonable burdens on our practices. To that end, the report contains five practical guidelines as well as several proposed strategies for implementation — all of which represent the consensus of the full panel.

Dr. Karpecki: The approach includes five pillars. In short, optometrists need to 1) detect, 2) grade, 3) assess risk, 4) manage and 5) support. (See *Five Pillars of DR Management*)

Your task force agreed that both structure and function are needed when caring for patients with, or at risk for, DR. But what, specifically, do you recommend optometrists use as a functional measure?

Dr. Karpecki: One of the reasons we rely so heavily on advanced structural tools like OCT and OCT-A is because they often show damage before you detect it using conventional examination techniques like fundus biomicroscopy and fundus photography,

and certainly visual acuity, which is preserved until late in DR progression. One of the reasons we rely so heavily on OCT is because it provides objective structural measurements, whereas grading DR severity is somewhat subjective. We need better, objective measurements of retinal function to complement structural assessment.

Dr. Lighthizer: Just as we want to see an objective measure of structure, we need an objective measure of function. This is what we get with ERG. With an objective ERG test, functional signs of loss can predict progression.^{1,2} Better still, it's faster than refraction. With the handheld RETeval[®], you can run a DR protocol test in minutes and have confidence in your management.

Learn More About the Guidelines

The task force recently released expanded details on each of the five pillars in the *Modern Fundamentals of Diabetic Retinopathy Management*. Free full text access to the complete report is available by using the QR code.



Once you've established a baseline using ERG, how do you manage and support patients with diabetes in your practice?

Dr. Lighthizer: DR is a puzzle that you put together over time, using all the tools at your disposal to keep your patient safe. ERG is one such tool. It can be used as a baseline throughout the patient's disease journey in optometric practice. The RETeval DR Score can guide the patient's follow-up schedule as well as referral decisions. A score of 23.4 or higher indicates an 11-fold risk of requiring medical intervention within 3 years.²

Dr. Chous: The time between retinal examinations depends on risk assessment, but no matter how severe or early the disease is, I strongly believe that multidisciplinary resources are required to best manage all DR patients. Good nutrition is essential and is something we should emphasize with our patients, as well as the importance of preventing hypoglycemia in patients with early DR, an emerging and vastly under-appreciated risk factor for worsening DR.

Dr. Karpecki: Regarding support, it's important to emphasize the asymptomatic nature of DR at its earlier, most treatable levels of severity and encourage patients to achieve individually optimized metabolic control in concert with their diabetes physicians.

¹Al-Otaibi H, Al-Otaibi MD, Khandekar R, et al. *Transl Vis Sci Technol.* 2017;6(3):3. doi:10.1167/tvst.6.3.3

²Brigell MG, Chiang B, Maa AY, Davis CQ. *Transl Vis Sci Technol.* 2020;9(9):40. doi:10.1167/tvst.9.9.40

Five Pillars of DR Management

- 1. DETECT:** Approach diabetic retinopathy as a chronic progressive disease. Being a chronic progressive disease implies that you can detect it before it becomes advanced disease. This can be achieved using both structural and functional testing.
- 2. GRADE:** Grade diabetic retinopathy at the time of diagnosis and at each subsequent visit. Chart structural retinal damage and quantify retinal cell function.
- 3. ASSESS RISK:** To assess risk of progression, monitor diabetic retinopathy patients over time using both structural and objective functional measures.
- 4. MANAGE:** Utilize multidisciplinary resources to manage all diabetic retinopathy patients, regardless of disease severity.
- 5. SUPPORT:** Provide comprehensive patient education and strategies to help prevent disease progression.

FEATURES

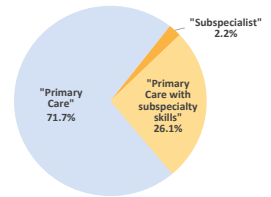
REVIEW OF OPTOMETRY • Vol. 160, No. 10 • OCTOBER 15, 2023

40 Optometrists Ready to Step Up to Subspecialization

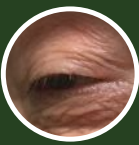New survey finds enthusiasm for recognizing ODs who wish to concentrate on particular aspects of care within the broader swath of the profession's services.

By Jack Persico, Editor-in-Chief

What type of optometrist are you?



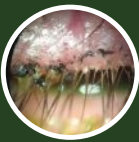RESTORING EYELID HEALTH



48 Follow This Practical Workup for Acquired Ptosis

The condition can arise for a multitude of reasons. Learn how to differentiate, diagnose and treat them.

By Elizabeth Marunde, OD



60 Five Questions About Medical Therapy for Demodex

The first targeted drug for this widespread condition is now available, offering a new treatment avenue for eyecare clinicians and their patients.

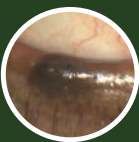By Catlin Nalley, Contributing Editor



66 Tackle MGD with These Hands-on Interventions

Adding gland expression, along with blepharoxoliation and IPL, unlocks new levels of control over patient outcomes. We show you the proper way to go about it.

By Mila Ioussifova, OD, and Hardeep Kataria, OD

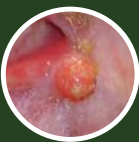

74 Recognize Benign vs. Malignant Eyelid Tumors and Lesions

Learn how to handle these abnormalities as well as the steps needed to diagnose them.

By Rodney Bendure, OD, and Frank Mai, OD

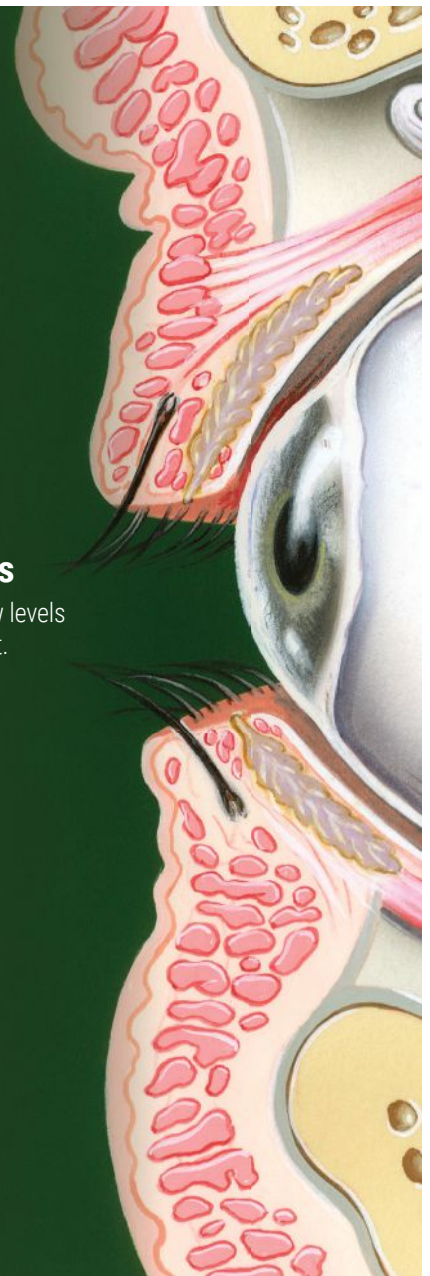
EARN 2 CE CREDITS



84 A Game Plan for Managing Eyelid Lesions and Related Conditions

Optometrists play a critical role in the identification and treatment of these issues.

By Vera Howe, OD





KERATOCONUS and CROSS-LINKING

The Paradigm Shift in Keratoconus Treatment



**Daniel G. Fuller,
OD, FAODipl, FSLs**
Memphis, TN

KEY TAKEAWAYS

- Only iLink® cross-linking can slow or halt the progression of keratoconus.
- Referring progressing patients to a cornea specialist prior to vision loss is ideal.
- Slowing or halting keratoconus progression may allow patients to continue to tolerate contact lenses.

Ten years ago, there was little reason to refer a patient with keratoconus to a cornea specialist early in the course of their disease. All we could do was manage patients' vision as long as possible, hoping they didn't progress to needing a corneal transplant.

The approval of iLink® cross-linking marked a major paradigm shift in keratoconus management. Professional societies have adjusted treatment guidelines to reflect the ability of cross-link-

referring progressing patients for cross-linking before they lose vision, just as we refer glaucoma patients for treatment as soon as the disease is detected. For patients who are still in their peak earning and learning years, early treatment could mean 50+ years of functional vision.

Cost-effective and FDA approved

A discrete-event simulation model showed that, compared to conventional treatment, iLink cross-linking would reduce the rate of penetrat-

Vision correction post cross-linking

Slowing or halting keratoconus progression may allow patients to continue to tolerate contact lenses.^{3,4} Typically, patients can resume contact lens wear within one to three months of the cross-linking procedure, although I find that corneal remodeling may continue for up to 12 months post-treatment. During this time, lens parameters may need to be adjusted. About one-third of eyes are able to continue in habitual contact lenses after cross-linking, while two-thirds require a new contact lens fit.⁵

With iLink cross-linking and modern specialty contact lenses, we have the best keratoconus management options now that I've ever seen. This represents not just a business opportunity, but the chance to have a life-changing impact on our patients. ■

Contact Lens Fitting Post Cross-Linking⁵

100% ACCEPTABLE FIT

65% IMPROVED SUBJECTIVE COMFORT

20% INCREASE IN NEAR-IDEAL FIT

ing treatment to slow or halt progression of the underlying disease. The American Academy of Ophthalmology, for example, now states in its Preferred Practice Pattern (PPP) that referral prior to vision loss is ideal, and that when keratoconus is suspected, more frequent follow-up to look for progression is warranted.¹ Any signs of progression or onset of keratoconus at a young age should lead to a prompt referral.¹

Optometry is very good at helping patients with keratoconus see better with gas permeable (GP), hybrid, and scleral lenses. But as rewarding as it is to help the vision-impaired, we can have an even greater impact by catching this disease early and

ing keratoplasty by 26%, and result in patients spending 28 fewer years in the advanced stages of keratoconus—all while saving money for patients, insurers, and society.²

The iLink procedure is an epithelium-off treatment that has undergone the scrutiny of randomized controlled clinical trials as part of the FDA approval process, demonstrating proven efficacy and safety. It is important to refer patients to doctors who use iLink, the only cross-linking procedure approved by the FDA. I believe that good science promotes good patient care and, in the case of iLink, also allows patients to use their insurance.

REFERENCES:

1. Garcia-Ferrer FJ, Akpek EK, Amescua G, et al. for the AAO PPP Corneal/External Disease Committee. Corneal ectasia PPP 2018.
2. Lindstrom RL, Berdahl JP, Donnerfeld ED, et al. Corneal cross-linking versus conventional management for keratoconus: a lifetime economic model. *J Med Econ* 2021;24(1):410-20.
3. Singh K, Bhattacharyya M, Arora R, et al. Alterations in contact lens fitting parameters following cross-linking in keratoconus patients of Indian ethnicity. *Int Ophthalmol*. 2018;38(4):1521-30.
4. Isik P, Harbiyeli II, Erdem E, Yagmur M. Improved contact lens fitting after corneal cross-linking in eyes with progressive keratoconus. *Cont Lens Anterior Eye*. 2021;3:101488.
5. Mandathara PS, Kalaiselvan P, Rathni VM, et al. Contact lens fitting after corneal collagen cross-linking. *Oman J Ophthalmol*. 2019;12(3):177-80.

INDICATIONS

Photrex® Viscous (riboflavin 5'-phosphate in 20% dextran ophthalmic solution) and Photrex® (riboflavin 5'-phosphate ophthalmic solution) are indicated for use with the KXL System in corneal collagen cross-linking for the treatment of progressive keratoconus and corneal ectasia following refractive surgery.

IMPORTANT SAFETY INFORMATION

Corneal collagen cross-linking should not be performed on pregnant women. Ulcerative keratitis can occur. Patients should be monitored for resolution of epithelial defects. The most common ocular adverse reaction was corneal opacity (haze). Other ocular side effects include punctate keratitis, corneal striae, dry eye, corneal epithelium defect, eye pain, light sensitivity, reduced visual acuity, and blurred vision. These are not all of the side effects of the corneal collagen cross-linking treatment. For more information, go to www.livingwithkeratoconus.com to obtain the FDA-approved product labeling. You are encouraged to report all side effects to the FDA. Visit www.fda.gov/medwatch, or call 1-800-FDA-1088.

SCAN WITH PHONE
Learn more about iLink
corneal cross-linking here



DEPARTMENTS

REVIEW OF OPTOMETRY • OCTOBER 15, 2023

VISIT US ON SOCIAL MEDIA

Facebook: revoptom

Twitter: revoptom

Instagram: revoptom

Threads: revoptom

LinkedIn: company/review-of-optometry

5

NEWS REVIEW

Clinical, legislative and practice updates for ODs.

22

OUTLOOK

Playing the Percentages

Ophthalmology's ranks are declining, patient demand is rising and ODs say they're open to a bold idea that might help with both.

Jack Persico, Editor-in-Chief

24

THROUGH MY EYES

The Big Picture

What legacy do you want to leave behind?

Paul M. Karpecki, OD

27

LETTERS TO THE EDITOR

Feedback and ideas from the OD community.

28

CHAIRSIDE

Use Your Turn Signals

Don't make assumptions with your patients.

Montgomery Vickers, OD

30

CLINICAL QUANDARIES

Fishin' for Trouble

Managing traumatic hyphema requires vigilance.

Paul C. Ajamian, OD



32

FOCUS ON REFRACTION

The Forgotten Tool for Binocular Vision

Contact lenses can be great for certain issues.

Marc Taub, OD, MS, Edd, and Pamela Schnell, OD

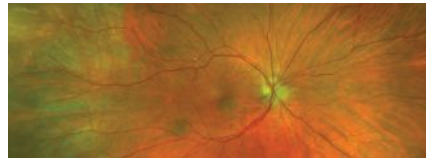
36

YOU BE THE JUDGE

ER Referral Goes Awry

Can your correct diagnosis be ignored and result in blindness?

Jerome Sherman, OD, and Sherry Bass, OD



94

CORNEA AND CONTACT LENS Q + A

Pregnant Pause

In expectant mothers, the possibility of temporary ocular changes can complicate prescribing and diagnosis.

Joseph P. Shovlin, OD

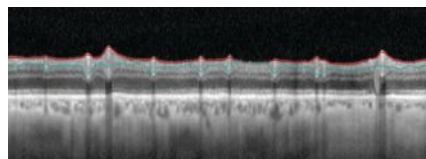
96

GLAUCOMA GRAND ROUNDS

Responsibility is a Two-Way Street

Once you've given patients every opportunity to benefit from your care, the rest is up to them.

James L. Fanelli, OD



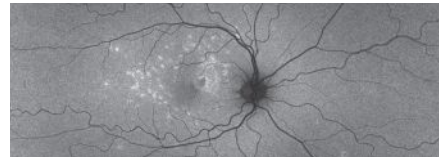100

RETINA QUIZ

Punc'd

Not all white dots are created equal.

Rami Aboumourad, OD



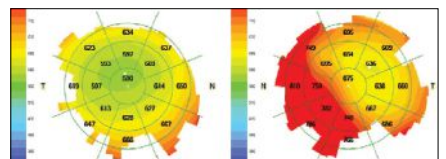
107

THERAPEUTIC REVIEW

Keep Count

Endothelial cell loss is a common source of worry in patients with both glaucoma and corneal disease.

Jessica Steen, OD



110

SURGICAL MINUTE

The Evolution of IPL

From units to bottles, there's been a big change in how this alternative treatment has been used and designed.

Derek N. Cunningham, OD, and Walter O. Whitley, OD, MBA

114

DIAGNOSTIC QUIZ

Pain from Above

A young patient experiences difficulty with upgaze movements. How serious might it be?

Andrew S. Gurwood, OD

REVIEW OF OPTOMETRY (ISSN 0147-7633) IS PUBLISHED MONTHLY, 12 TIMES A YEAR BY JOBSON MEDICAL INFORMATION LLC/WEBMD, 283-299 MARKET STREET, 2 GATEWAY CENTER, 4TH FLOOR, NEWARK, NJ 07102. PERIODICALS POSTAGE PAID AT NEWARK, NJ AND ADDITIONAL MAILING OFFICES. POSTMASTER: SEND ADDRESS CHANGES TO REVIEW OF OPTOMETRY, PO BOX 81, CONGERS, NY 10920-0081. SUBSCRIPTION PRICES: US: ONE YEAR \$56, TWO YEARS \$97, CANADA: ONE YEAR \$88, TWO YEARS \$160, INT'L: ONE YEAR \$209, TWO YEARS \$299. FOR SUBSCRIPTION INFORMATION CALL TOLL-FREE (877) 529-1746 (USA); OUTSIDE USA, CALL (845) 267-3065. OR EMAIL US AT REVOPATOMERY@CAMBEYWEST.COM. PUBLICATIONS MAIL AGREEMENT NO: 40612608. CANADA RETURNS TO BE SENT TO BLEUCHIP INTERNATIONAL, P.O. BOX 25542, LONDON, ON N6C 6B2.

For the treatment of all stages
of neurotrophic keratitis (NK)



NOT JUST ANY SOLUTION A RESOLUTION

Complete and long-lasting resolution of NK for most patients*¹⁻⁴

- Up to 72% of patients achieved complete corneal healing in clinical trials**¹⁻³
- 80% of these patients remained healed at 1 year (REPARO trial)*⁴

* Resolution was evaluated in clinical trials as complete corneal healing, defined as the absence of staining in the lesion area and no persistent staining in the rest of the cornea after 8 weeks of treatment and as <0.5-mm lesion staining at 48-week follow-up.^{1,3}

† Key study findings were after 8 weeks of treatment, 6 times daily. REPARO (Study NGF0212): 52 European patients with neurotrophic keratitis (NK) in 1 eye per group; 72% of patients completely healed; vehicle response rate 33.3%.

Study NGF0214: 24 US patients with NK in 1 or both eyes per group; 65.2% completely healed; vehicle response rate 16.7%.^{2,3}

Important Safety Information WARNINGS AND PRECAUTIONS

Use with Contact Lens

Contact lenses should be removed before applying OXERVATE because the presence of a contact lens (either therapeutic or corrective) could theoretically limit the distribution of cenergermin-bkbj onto the area of the corneal lesion. Lenses may be reinserted 15 minutes after administration.

Eye Discomfort

OXERVATE may cause mild to moderate eye discomfort such as eye pain during treatment. The patient should be advised to contact their doctor if a more serious eye reaction occurs.

ADVERSE REACTIONS

In clinical trials, the most common adverse reaction was eye pain following instillation which was reported in approximately 16% of patients. Other adverse reactions occurring in 1% to 10% of OXERVATE patients and more frequently than in the vehicle-treated patients included corneal deposits, foreign body sensation, ocular hyperemia, ocular inflammation and tearing.

USE IN SPECIFIC POPULATIONS

Pregnancy

There are no data from the use of OXERVATE in pregnant women to inform any drug associated risks.

Lactation

The developmental and health benefits of breastfeeding should be considered, along with the mother's clinical need for OXERVATE, and any potential adverse effects on the breastfed infant from OXERVATE.

Pediatric Use

The safety and effectiveness of OXERVATE have been established in the pediatric population. Use of OXERVATE in pediatric patients 2 years of age and older is supported by evidence from adequate and well-controlled trials of OXERVATE in adults with additional safety data in children.

INDICATION

OXERVATE® (cenergermin-bkbj) ophthalmic solution 0.002% (20 mcg/mL) is indicated for the treatment of neurotrophic keratitis.

DOSAGE AND ADMINISTRATION

Instill one drop of OXERVATE in the affected eye(s), 6 times a day at 2-hour intervals for eight weeks.

To report ADVERSE REACTIONS, contact Dompé U.S. Inc. at 1-833-366-7387 or FDA at 1-800-FDA-1088 or www.fda.gov/medwatch.

Please see the Brief Summary of full Prescribing Information for OXERVATE on the following page.

References: 1. OXERVATE® (cenergermin-bkbj) ophthalmic solution 0.002% (20 mcg/mL) [US package insert], Boston, MA; Dompé U.S. Inc.; 2019. 2. Bonini S, et al. *Ophthalmology*. 2018;125:1332-1343. 3. Pflugfelder SC, et al. *Ophthalmology*. 2020;127:14-26. 4. Data on File. Clinical Study Report (NGF0212). Dompé U.S. Inc., 2016.

oxervate® 
(cenergermin-bkbj ophthalmic
solution) 0.002% (20 mcg/mL)



Brief Summary of full Prescribing Information

Consult the full Prescribing Information for complete product information, available at www.oxervate.com/prescribing-information.

INDICATIONS AND USAGE

OXERVATE® (cenegermin-bkbj) ophthalmic solution 0.002% is indicated for the treatment of neurotrophic keratitis.

DOSAGE AND ADMINISTRATION

General Dosing Information

Contact lenses should be removed before applying OXERVATE and may be reinserted 15 minutes after administration.

If a dose is missed, treatment should be continued as normal, at the next scheduled administration.

If more than one topical ophthalmic product is being used, administer the eye drops at least 15 minutes apart to avoid diluting products. Administer OXERVATE 15 minutes prior to using any eye ointment, gel or other viscous eye drops.

Recommended Dosage and Dose Administration

Instill one drop of OXERVATE in the affected eye(s), 6 times a day at 2-hour intervals for eight weeks.

WARNINGS AND PRECAUTIONS

Use with Contact Lens

Contact lenses should be removed before applying OXERVATE because the presence of a contact lens (either therapeutic or corrective) could theoretically limit the distribution of cenegermin-bkbj onto the area of the corneal lesion. Lenses may be reinserted 15 minutes after administration.

Eye Discomfort

OXERVATE may cause mild to moderate eye discomfort such as eye pain during treatment. The patient should be advised to contact their doctor if a more serious eye reaction occurs.

ADVERSE REACTIONS

Clinical Studies Experience

Because clinical studies are conducted under widely varying conditions, adverse reaction rates observed in the clinical studies of a drug cannot be directly compared to rates in the clinical studies of another drug and may not reflect the rates observed in practice.

In two clinical trials of patients with neurotrophic keratitis, a total of 101 patients received cenegermin-bkbj eye drops at 20 mcg/mL at a frequency of 6 times daily in the affected eye(s) for a duration of 8 weeks. The mean age of the population was 61 to 65 years of age (18 to 95). The majority of the treated patients were female (61%). The most common adverse reaction was eye pain following instillation which was reported in approximately 16% of patients. Other adverse reactions occurring in 1-10% of OXERVATE patients and more frequently than in the vehicle-treated patients included corneal deposits, foreign body sensation, ocular hyperemia, ocular inflammation and tearing.

USE IN SPECIFIC POPULATIONS

Pregnancy

Risk Summary

There are no data from the use of OXERVATE in pregnant women to inform any drug associated risks.

Administration of cenegermin-bkbj to pregnant rats or rabbits during the period of organogenesis did not produce adverse fetal effects at clinically relevant doses. In a pre- and postnatal development study, administration of cenegermin-bkbj to pregnant rats throughout gestation and lactation did not produce adverse effects in offspring at clinically relevant doses.

Lactation

Risk Summary

There are no data on the presence of OXERVATE in human milk, the effects on breastfed infant, or the effects on milk production. The developmental and health benefits of breastfeeding should be considered, along with the mother's clinical need for OXERVATE, and any potential adverse effects on the breastfed infant from OXERVATE.

Pediatric Use

The safety and effectiveness of OXERVATE have been established in the pediatric population. Use of OXERVATE in this population is supported by evidence from adequate and well-controlled trials of OXERVATE in adults with additional safety data in pediatric patients from 2 years of age and older.

Geriatric Use

Of the total number of subjects in clinical studies of OXERVATE, 43.5 % were 65 years old and over. No overall differences in safety or effectiveness were observed between elderly and younger adult patients.

NONCLINICAL TOXICOLOGY

Carcinogenesis, Mutagenesis, Impairment of Fertility

Carcinogenesis and Mutagenesis

Animal studies have not been conducted to determine the carcinogenic and mutagenic potential of cenegermin-bkbj.

Impairment of fertility

Daily subcutaneous administration of cenegermin-bkbj to male and female rats for at least 14 days prior to mating, and at least 18 days post-coitum had no effect on fertility parameters in male or female rats at doses up to 267 mcg/kg/day (1709 times the MRHOD).

In general toxicology studies, subcutaneous and ocular administration of cenegermin-bkbj in females was associated with ovarian findings including persistent estrus, ovarian follicular cysts, atrophy/reduction of corpora lutea, and changes in ovarian weight at doses greater than or equal to 19 mcg/kg/day (119 times the MRHOD).



CLINICAL EDITORS

CHIEF CLINICAL EDITOR ~ PAUL M. KARPECKI, OD

ASSOCIATE CLINICAL EDITORS ~ JOSEPH P. SHOVLIN, OD, CHRISTINE SINDT, OD

CONTRIBUTING EDITORS

RAMI ABOUMOURAD, OD, MIAMI

PAUL C. AJAMIAN, OD, ATLANTA

SHERRY J. BASS, OD, NEW YORK

ALISON BOZUNG, OD, MIAMI

DEREK N. CUNNINGHAM, OD, AUSTIN, TX

JAMES L. FANELLI, OD, WILMINGTON, NC

ANDREW S. GURWOOD, OD, PHILADELPHIA

PAUL M. KARPECKI, OD, LEXINGTON, KY

BISANT LABIB, OD, ELKINS PARK, PA

NATE LIGHTHIZER, OD, TAHLEQUAH, OK

PAMELA H. SCHNELL, OD, MEMPHIS

JOSEPH P. SHOVLIN, OD, SCRANTON, PA

JEROME SHERMAN, OD, NEW YORK

MARC TAUB, OD, MEMPHIS

MONTGOMERY VICKERS, OD, DALLAS

WALTER O. WHITLEY, OD, MBA, VIRGINIA BEACH, VA

EDITORIAL ADVISORY BOARD

JEFFREY R. ANSHEL, OD, KAUAI, HAWAII

JILL AUTRY, OD, RPH, HOUSTON

SHERRY J. BASS, OD, NEW YORK

EDWARD S. BENNETT, OD, ST. LOUIS

MARC R. BLOOMENSTEIN, OD, SCOTTSDALE, AZ

ALISON BOZUNG, OD, MIAMI

MILE BRUJIC, OD, BOWLING GREEN, OH

CHRIS J. CAKANAC, OD, MURRYSVILLE, PA

JERRY CAVALLERANO, OD, PhD, BOSTON

BRIAN CHOU, OD, SAN DIEGO

MICHAEL CHAGLASIAN, OD, CHICAGO

A. PAUL CHOUS, MA, OD, TACOMA, WA

GLENN S. CORBIN, OD, WYOMISSING, PA

MARK T. DUNBAR, OD, MIAMI

S. BARRY EIDEN, OD, DEERFIELD, IL

STEVEN FERRUCCI, OD, SEPULVEDA, CA

MURRAY FINGERET, OD, HEWLETT, NY

IAN BEN GADDIE, OD, LOUISVILLE, KY

GARY S. GERBER, OD, HAWTHORNE, NJ

JESSICA HAYNES, OD, MEMPHIS

MILTON HOM, OD, AZUSA, CA

DAVID KADING, OD, SEATTLE

JEROME A. LEGERTON, OD, MBA, SAN DIEGO

THOMAS L. LEWIS, OD, PhD, PHILADELPHIA

BLAIR B. LONSBERRY, MS, OD, MED, PORTLAND, OR

KELLY A. MALLOY, OD, PHILADELPHIA

DANICA MARRELLI, OD, HOUSTON

RON MELTON, OD, CHARLOTTE, NC

PAMELA J. MILLER, OD, JD, HIGHLAND, CA

MARC MYERS, OD, COATESVILLE, PA

CARLO J. PELINO, OD, JENKINTOWN, PA

JOSEPH PIZZIMENTI, OD, FORT LAUDERDALE, FL

CHRISTOPHER J. QUINN, OD, ISELIN, NJ

MOHAMMAD RAFIEETARY, OD, MEMPHIS

JOHN L. SCHACHET, OD, ENGLEWOOD, CO

JACK SCHAEFFER, OD, BIRMINGHAM, AL

PAMELA H. SCHNELL, OD, MEMPHIS

LEO P. SEMES, OD, JACKSONVILLE, FL

DIANA L. SHECHTMAN, OD, FORT LAUDERDALE, FL

JEROME SHERMAN, OD, NEW YORK

LEONID SKORIN, JR., OD, DO, ROCHESTER, MN

JOSEPH W. SOWKA, OD, SARASOTA, FL

JESSICA STEEN, OD, DAVIE, FL

BRAD M. SUTTON, OD, INDIANAPOLIS

LORETTA B. SZCZOTKA, OD, PhD, CLEVELAND

MARC TAUB, OD, MEMPHIS

TAMMY P. THAN, MS, OD, SUN CITY, AZ

RANDALL THOMAS, OD, MPH, CONCORD, NC

SARA WEIDMAYER, OD, ANN ARBOR, MI

KAREN YEUNG, OD, LOS ANGELES



Business Offices

19 Campus Boulevard, Suite 101
Newtown Square, PA 19073
Subscription inquiries (877) 529-1746 (USA only)
outside USA, call (847) 763-9630

PUBLISHER

MICHAEL HOSTER

(610) 492-1028

mhoster@jobson.com

SENIOR MANAGER, STRATEGIC ACCOUNTS

MICHELE BARRETT

(610) 492-1014

mbarrett@jobson.com

REGIONAL SALES MANAGER

JONATHAN DARDINE

(610) 492-1030

jdardine@jobson.com

PRODUCTION MANAGER

KAREN LALLONE

(610) 492-1010

klallone@jobson.com

DIGITAL MARKETING MANAGER

MATT EGGER

(610) 492-1029

megger@jobson.com

CLASSIFIED ADVERTISING

(888) 498-1460

SUBSCRIPTIONS

\$63 PER YEAR, \$99 (US) IN CANADA,
\$158 (US) IN ALL OTHER COUNTRIES
revoptometry@cambeywest.com

CIRCULATION

PO BOX 71, CONGERS, NY 10920-0071
(877) 529-1746
OUTSIDE USA: (845) 267-3065

SENIOR CIRCULATION MANAGER

HAMILTON MAHER

(212) 219-7870

hmaher@jhihealth.com

CEO, INFORMATION GROUP SERVICES

BILL SCOTT

SENIOR VICE PRESIDENT, OPERATIONS

JEFF LEVITZ

VICE PRESIDENT, HUMAN RESOURCES

TAMMY GARCIA

VICE PRESIDENT, CREATIVE SERVICES & PRODUCTION

MONICA TETTAMANZI

CORPORATE PRODUCTION DIRECTOR

JOHN ANTHONY CAGGIANO

VICE PRESIDENT, CIRCULATION

JARED SONNERS

Jobson Health Information/WebMD
395 Hudson Street, 3rd Floor, New York, NY 10014

EDITOR-IN-CHIEF

JACK PERSICO

(610) 492-1006 • jpersico@jobson.com

SENIOR EDITOR

JULIE SHANNON

(610) 492-1005 • jshannon@jobson.com

SENIOR ASSOCIATE EDITOR

MARK DE LEON

(610) 492-1021 • mdeleon@jobson.com

ASSOCIATE EDITOR

LEANNE SPIEGLE

(610) 492-1026 • lspiegle@jobson.com

ASSOCIATE EDITOR

RACHEL RITA

(610) 492-1000 • rrita@jobson.com

SENIOR SPECIAL PROJECTS MANAGER

JILL GALLAGHER

(610) 492-1037 • jgallagher@jobson.com

SENIOR ART DIRECTOR

JARED ARAUJO

jaraujo@jobson.com

GRAPHIC DESIGNER

LYNNE O'CONNOR

lyoconnor@jobson.com

DIRECTOR OF CE ADMINISTRATION

REGINA COMBS

(212) 274-7160 • rcombs@jobson.com

Clinical Editors

Chief Clinical Editor • Paul M. Karpecki, OD

Associate Clinical Editors

Joseph P. Shovlin, OD, Christine W. Sindt, OD

Clinical & Education Conference Advisor

Paul M. Karpecki, OD

Case Reports Coordinator • Andrew S. Gurwood, OD

Columnists*Advanced Procedures* – Nate Lighthizer, OD*Chairside* – Montgomery Vickers, OD*Clinical Quandaries* – Paul C. Ajamian, OD*Cornea and Contact Lens Q+A* – Joseph P. Shovlin, OD*Diagnostic Quiz* – Andrew S. Gurwood, OD*The Essentials* – Bisant A. Labib, OD*Focus on Refraction* – Marc Taub, OD, Pamela Schnell, OD*Glaucoma Grand Rounds* – James L. Fanelli, OD*Ocular Surface Review* – Paul M. Karpecki, OD*Retina Quiz* – Rami Aboumourad, OD*Surgical Minute* – Derek Cunningham, OD, Walter Whitley, OD*Therapeutic Review* – Jessica Steen, OD*Through My Eyes* – Paul M. Karpecki, OD*Urgent Care* – Alison Bozung, OD*You Be The Judge* – Jerome Sherman, OD, Sherry Bass, OD**Editorial Offices**

19 Campus Blvd., Suite 101 • Newtown Square, PA 19073

Jobson Medical Information/WebMD

283-299 Market Street, 2 Gateway Center, 4th Floor
Newark, NJ 07102

Subscription inquiries: (877) 529-1746

Continuing Education inquiries: (800) 825-4696

Printed in USA

BY JACK PERSICO
EDITOR-IN-CHIEF**OUTLOOK**

Playing the Percentages

Ophthalmology's ranks are declining, patient demand is rising—and ODs say they're open to a bold idea that might help with both.

The numbers tell the story this month. “Ophthalmology Workforce Expected to Decline 12% by 2035,” declares one of our news articles, which details a study that pairs a drop in the number of practitioners with an increase in need for eye care and concludes that ophthalmology will fall short by 30% relative to patient demand just 12 years from now. That’s based on status quo patterns of access to eye care. If future policy changes succeed in reducing barriers to healthcare access, the gap between supply and demand in ophthalmology widens to 36%.

The same report projects a future shortage of optometrists of 11% under the reduced-barriers scenario (none in the status quo), though it doesn’t detail how it arrives at that or explain whether the MD shortage in any way causes the OD one in their projections. Either way, we all know where the spillover from unmet ophthalmology demand shows up: in your chair. When they get there, more and more patients will need a level of care that goes beyond the routine. An aging population and a shrinking ophthalmology profession all but guarantees it. How, then, to both train optometrists for advanced expertise and communicate to patients as well as other doctors who’s capable of what?

Also this month, we share highlights from a new survey conducted by Jobson Optical Research on opinions about creating a process of subspecialization within optometry. It’s a contentious topic in some circles, but the survey found widespread openness to the idea. According to the data, 70% of practicing optometrists—and a whopping 92% of students—said they would value the opportunity to earn a subspecialty

credential of some kind. The point is all the more intriguing when you consider that just 28.3% of respondents identify as “primary care providers with subspecialty skills” (26.1%) or as bona fide subspecialists (2.2%).

Crucially, 82.4% of respondents would be more inclined to refer to another OD if that doctor had a subspecialty credential. Intraprofessional referral is an untapped area where optometrists can collectively pick up the slack in eyecare delivery. With ophthalmologists up to their eyeballs in, well, eyeballs, ODs can cut down on the overwhelming demand and get patients seen more quickly by building a much more robust OD-to-OD network than what exists now. “I think it would more greatly set optometrists apart from each other so that employers, other healthcare specialists, politicians and the public know who to trust and turn to in certain situations or with specific issues,” wrote a student at Ohio State College of Optometry in their survey response.

Subspecialization seems inevitable, and it sounds desirable, but there are obviously plenty of hurdles to overcome. How should subspecialties be defined, and by whom? What would a credentialing process be like? Do established ODs need to undergo formal training or can “time in the field” qualify them? Would it foster discontent and rivalry within the profession? Optometrists have excelled as generalists of the eye. The trick is to maintain that while adding another layer of skill—and, importantly, transparency—for anyone inclined to pursue it. Subspecialties would make optometry less of a black box, a critical evolutionary step as its numbers grow and ophthalmology’s drop. ■

GO AHEAD. MAKE MYDAY.[®]

You're at the top of your game, which is why you prescribe lenses with top of the line performance.

ADVANTAGE 01 Unsurpassed Comfort¹

ADVANTAGE 02 Optimized Design

ADVANTAGE 03 Unparalleled Range^{2,3,4}

ADVANTAGE 04 Net Plastic Neutral⁵

ADVANTAGE 05 Simply Satisfied Guarantee[™]



When you prescribe the MyDay[®] family of lenses, you'll make their day.



CooperVision[®]



plasticbank

Simply Satisfied[™]
GUARANTEE



Christi Locke, OD, MS, FAAO

Thomas Eye Group | Atlanta, GA

1. CVI data on file, 2013, 2015 & 2017. MyDay[®] clinical studies 1-week DW compared to 1-DAY ACUVUE[®] MOIST, DAILIES TOTAL1[®] and ACUVUE[®] OASYS 1-Day. 2. CooperVision data on file 2020. Rx coverage database n=120,406 eyes for Rx with <0.75DC; 14 to 70 years. 3. CVI data on file, 2021. Based on number of prescription options available in the USA across all soft 1-day toric lenses as reported by the 4 main manufacturers. 4. CVI data on file, 2021. Based on prescription option combinations (sph and add) available across all daily disposable multifocal soft lenses from CVI, JUV, B+L and Alcon in USA May 2021. 5. MyDay[®] daily disposable orders includes MyDay[®] daily disposable, MyDay[®] daily disposable toric, MyDay[®] daily disposable multifocal product sold and distributed by CooperVision in the US. Net plastic neutrality is established by purchasing credits from Plastic Bank. A credit represents the collection and conversion of one kilogram of plastic that may reach or be destined for waterways. CooperVision purchases credits equal to the weight of plastic in MyDay[®] daily disposable orders in a specified time period. MyDay[®] daily disposable plastic is determined by the weight of plastic in the blister, the lens, and the secondary package, including laminates, adhesives, and auxiliary inputs (e.g. ink). CVI Data on file, 2022. ©2023 CooperVision 14678A-ROO 9/23



BY PAUL M. KARPECKI, OD
CHIEF CLINICAL EDITOR

THROUGH MY EYES

The Big Picture

What legacy do you want to leave behind?

During *Review's* New Technologies & Treatments in Eye Care conference in Savannah, GA in August, I had the honor of providing a big-picture talk to the Intrepid Eye Society, which co-chaired the program. Although I usually speak or write about clinical subjects, vision for the profession, key opportunities and insights, I like to step back periodically and focus on a subject that may affect the lives of many in my cherished profession.

There comes a time that we should look at the big picture for our lives. While I've made many mistakes and trusted the wrong people, those hard falls taught me more than I could have imagined. I've learned that we have the ability to create the life we want, so why not make it the best one possible?

Values Make Decisions Easier

Start by being clear about your values. If you know what you stand for, you have a filter in place for any decision. If humility is one of your core values, it's easy to give credit to your staff and others when accomplishments are achieved. If dedication to family is a core value, electing not to add another clinic day or even an extra evening becomes an easier decision.

Begin With the End in Mind

The famous time management author Stephen Covey stated the above principle. If you take this quote to the ultimate level, it would mean to think of your obituary and what you'd like it to state. That can be difficult because we don't want to think about the end of life

on earth, and it's so far away we can't fathom the thought, but it's truly about thinking of the legacy you want to leave. Do you want to be known for helping your community, faith, charity, being a dedicated parent, moving the profession forward, to name but a few?

“**Picture your ideal future—make it emotionally charged, detailed and as vivid as possible.**”

Once that's clear, then the specific optometric career choice—including where you want to practice—becomes easier. If your career is a priority at this stage, moving anywhere in the country for the best opportunity is ideal, but if it's to raise children where you or your spouse grew up so grandparents and family are close, then the decision is very different.

SWOT Analysis

Strengths, weaknesses, opportunities and threats—many companies evaluate these, but each of us should do something similar for one primary reason. Usually, what feels most natural (sometimes it takes practice to get there) but most liberating, effortless and enjoyable is often what we were meant to do. Next, look at the strengths you have and where you may need to hire or get help. Then, translate that into specific and unique opportunities, while always asking yourself, “What's the worst thing that can happen if it fails?” That is, what is my safety net should an unexpected

situation arise? If contingency plans are in place, it's much easier to take the risk.

Along those lines, in his book *Good to Great*, Jim Collins describes the “hedgehog concept”—list all of your activities and determine which ones fit into all three of the following ‘buckets’: something you are passionate about, something that could eventually generate sustainable income and something that you can be better at than most. If you can find specific work that fits all three, you are where you are supposed to be career- or business-wise. If not, it may be time to take your career in a slightly different direction. I've seen many colleagues successfully do this in the corporate world and as medical science liaisons and researchers.

Set Goals and a Vision

My residents who set written goals and plans have been the more successful in their careers and lives. Make your goals specific, measurable, set a time frame, write them as if you've already achieved them and review them periodically. As core values change, you may have to adjust, and that's perfectly fine. Picture your ideal future—make it emotionally charged, detailed and as vivid as possible.

Make Life Fulfilling

In the movie *Back to the Future*, Doc leaves by saying, “Your future is whatever you make it. So make it a good one!” It's a great reminder that things aren't so complex and you can make your life what you want. Sure, there will be bumps along the way and mistakes will be made, but bounce back and learn from them. If we think of the legacy we want to leave before our time comes, vividly picture the ideal future and set goals and plans based on the values we hold dear, our decisions, and thus lives, can truly be fulfilling. ■

About
Dr. Karpecki

Dr. Karpecki is the director of Cornea and External Disease for Kentucky Eye Institute and an associate professor at KYCO. He is the Chief Clinical Editor for *Review of Optometry* and chair of the New Technologies & Treatments conferences. A fixture in optometric clinical education, he consults for a wide array of ophthalmic clients, including ones discussed in this article. Dr. Karpecki's full disclosure list can be found in the online version of this article at www.reviewofoptometry.com.

iyuzehTM
(latanoprost ophthalmic solution) 0.005%

Transform how you lower IOP.
**POWER
WITHOUT
PRESERVATIVES.**



We owe it to our patients with elevated intraocular pressure, with open-angle glaucoma or ocular hypertension to provide a new evidence-based approach. It is an extremely exciting time to prescribe IYUZEHTM for my patients.

Monique M. Barbour, MD, MHA, FAO



INDICATIONS AND USAGE

IYUZEHTM is a prostaglandin analogue indicated for the reduction of elevated intraocular pressure in patients with open-angle glaucoma or ocular hypertension.

IMPORTANT SAFETY INFORMATION

CONTRAINDICATIONS

Known hypersensitivity to latanoprost or any other ingredients in this product.

WARNINGS AND PRECAUTIONS

Pigmentation: Topical latanoprost ophthalmic products, including IYUZEHTM have been reported to cause changes to pigmented tissues. The most frequently reported changes have been increased pigmentation of the iris, periorbital tissue (eyelid), and eyelashes. Pigmentation is expected to increase as long as latanoprost is administered.

The pigmentation change is due to increased melanin content in the melanocytes rather than to an increase in the number of melanocytes. After discontinuation of latanoprost, pigmentation of the iris is likely to be permanent, while pigmentation of the periorbital tissue and eyelash changes have been reported to be reversible in some patients. Patients who receive treatment should be informed of the possibility of increased pigmentation. The long-term effects of increased pigmentation are not known.

Iris color change may not be noticeable for several months to years. Typically, the brown pigmentation around the pupil spreads concentrically towards the periphery of the iris and the entire iris or parts of the iris become more brownish. Neither nevi nor freckles of the iris appear to be affected by treatment. While treatment with IYUZEHTM can be continued in patients who develop noticeably increased iris pigmentation, these patients should be examined regularly.

Eyelash Changes: Latanoprost ophthalmic products, including IYUZEHTM may gradually change eyelashes and vellus hair in the treated eye; these changes include increased length, thickness, pigmentation, the number of lashes or hairs, and misdirected growth of eyelashes. Eyelash changes are usually reversible upon discontinuation of treatment.

Intraocular Inflammation: IYUZEHTM should be used with caution in patients with a history of intraocular inflammation (iritis/uveitis) and should generally not be used in patients with active intraocular inflammation because inflammation may be exacerbated.

Macular Edema: Macular edema, including cystoid macular edema, has been reported during treatment with latanoprost ophthalmic products, including IYUZEHTM. IYUZEHTM should be used with caution in aphakic patients, in pseudophakic patients with a torn posterior lens capsule, or in patients with known risk factors for macular edema.

Herpetic Keratitis: Reactivation of herpes simplex keratitis has been reported during treatment with latanoprost. IYUZEHTM should be used with caution in patients with a history of herpetic keratitis. IYUZEHTM should be avoided in cases of active herpes simplex keratitis because inflammation may be exacerbated.

Contact Lens Use: Contact lenses should be removed prior to the administration of IYUZEHTM and may be reinserted 15 minutes after administration.

ADVERSE REACTIONS


The following adverse reactions have been reported with the use of topical latanoprost products: iris pigmentation changes, eyelid skin darkening, eyelash changes (increased length, thickness, pigmentation, and number of lashes), intraocular inflammation (iritis/uveitis), and macular edema, including cystoid macular edema.

DRUG INTERACTIONS

The combined use of two or more prostaglandins, or prostaglandin analogs including IYUZEHTM is not recommended. It has been shown that administration of these prostaglandin drug products more than once daily may decrease the IOP lowering effect or cause paradoxical elevations in IOP.

Please see full Prescribing Information at www.iyuzeh.com and Brief Summary on the next page.

Explore the power of preservative-free latanoprost at iyuzeh.com



Théa
let's open our eyes

IYUZEH is a trademark of Laboratoires Théa.
Copyright ©2023 Théa Pharma Inc. | All Rights Reserved. | PRC-IYZ-1410-v2 08.2023

iyuzeh™

(latanoprost ophthalmic solution) 0.005%

HIGHLIGHTS OF PRESCRIBING INFORMATION

This brief summary does not include all the information needed to use IYUZEH safely and effectively. See full prescribing information for IYUZEH.

Initial U.S. Approval: 2022

INDICATIONS AND USAGE

IYUZEH is a prostaglandin F_{2α} analogue indicated for the reduction of elevated intraocular pressure in patients with open-angle glaucoma or ocular hypertension.

CONTRAINDICATIONS

Known hypersensitivity to latanoprost or any other ingredients in this product.

WARNINGS AND PRECAUTIONS

Pigmentation: Topical latanoprost ophthalmic products, including IYUZEH have been reported to cause changes to pigmented tissues. The most frequently reported changes have been increased pigmentation of the iris, periorbital tissue (eyelid), and eyelashes. Pigmentation is expected to increase as long as latanoprost is administered.

The pigmentation change is due to increased melanin content in the melanocytes rather than to an increase in the number of melanocytes. After discontinuation of latanoprost, pigmentation around the pupil spreads concentrically towards the periphery of the iris and the entire iris or parts of the iris become more brownish. Neither nevi nor freckles of the iris appear to be affected by treatment. While treatment with IYUZEH can be continued in patients who develop noticeably increased iris pigmentation, these patients should be examined regularly.

Iris color change may not be noticeable for several months to years. Typically, the brown pigmentation around the pupil spreads concentrically towards the periphery of the iris and the entire iris or parts of the iris become more brownish. Neither nevi nor freckles of the iris appear to be affected by treatment. While treatment with IYUZEH can be continued in patients who develop noticeably increased iris pigmentation, these patients should be examined regularly.

Eyelash Changes: Latanoprost ophthalmic products, including IYUZEH may gradually change eyelashes and vellus hair in the treated eye; these changes include increased length, thickness, pigmentation, the number of lashes or hairs, and misdirected growth of eyelashes. Eyelash changes are usually reversible upon discontinuation of treatment.

Intraocular Inflammation: IYUZEH should be used with caution in patients with a history of intraocular inflammation (iritis/uveitis) and should generally not be used in patients with active intraocular inflammation because inflammation may be exacerbated.

Macular Edema: Macular edema, including cystoid macular edema, has been reported during treatment with latanoprost ophthalmic products, including IYUZEH. IYUZEH should be used with caution in aphakic patients, pseudophakic patients with a torn posterior lens capsule, or in patients with known risk factors for macular edema.

Herpetic Keratitis: Reactivation of herpes simplex keratitis has been reported during treatment with latanoprost. IYUZEH should be used with caution in patients with a history of herpetic keratitis and should be avoided in cases of active herpes simplex keratitis because inflammation may be exacerbated.

Contact Lens Use: Contact lenses should be removed prior to the administration of IYUZEH and may be reinserted 15 minutes after administration.

ADVERSE REACTIONS

The following adverse reactions have been reported with the use of topical latanoprost products and are discussed in greater detail in the prescribing information:

- Iris pigmentation changes
- Eyelid skin darkening
- Eyelash changes (increased length, thickness, pigmentation, and number of lashes)
- Intraocular inflammation (iritis/uveitis)
- Macular edema, including cystoid macular edema

Because clinical trials are conducted under widely varying conditions, adverse reaction rates observed in the clinical trials of a drug cannot be directly compared to rates in the clinical trials of another drug and may not reflect the rates observed in practice.

In the two clinical trials conducted with IYUZEH (latanoprost ophthalmic solution) 0.005% comparing it to XALATAN the preserved 0.005% latanoprost reference product, the most frequently reported ocular adverse reactions were conjunctival hyperemia and eye irritation (Table 1).

Table 1. Adverse Reactions

Symptom/Finding	Adverse Reactions [n (%)]	
	IYUZEH (n=378)	XALATAN (n=358)
Conjunctival hyperemia	129 (34)	133 (37)
Eye irritation	72 (19)	112 (31)
Eye pruritus	57 (15)	58 (16)
Abnormal sensation in eyes	51 (14)	52 (15)
Foreign body sensation in eyes	44 (12)	36 (10)
Vision blurred	28 (7)	30 (8)
Lacrimation increased	19 (5)	14 (4)
Photophobia	13 (3)	17 (5)

POSTMARKETING EXPERIENCE

The following adverse reactions have been identified during post-approval use of topical latanoprost products. Because these reactions are reported voluntarily from a population of uncertain size, it is not always possible to reliably estimate their frequency or establish a causal relationship to drug exposure. The reactions, which have been chosen for inclusion due to either their seriousness, frequency of reporting, possible causal connection to ophthalmic latanoprost products, or a combination of these factors, include:

- Nervous System Disorders: Dizziness; headache; toxic epidermal necrolysis
- Eye Disorders: Eyelash and vellus hair changes of the eyelid (increased length, thickness, pigmentation, and number of eyelashes); keratitis; corneal edema and erosions; intraocular inflammation (iritis/uveitis); macular edema, including cystoid macular edema; trichiasis; periorbital and lid changes resulting in deepening of the eyelid sulcus; iris cyst; eyelid skin darkening; localized skin reaction on the eyelids; conjunctivitis; pseudophemphigoid of the ocular conjunctiva.
- Respiratory, Thoracic and Mediastinal Disorders: Asthma and exacerbation of asthma; dyspnea
- Skin and Subcutaneous Tissue Disorders: Pruritus
- Infections and Infestations: Herpes keratitis
- Cardiac Disorders: Angina; palpitations; angina unstable
- General Disorders and Administration Site Conditions: Chest pain

DRUG INTERACTIONS

The combined use of two or more prostaglandins, or prostaglandin analogs including IYUZEH is not recommended, and administration of these prostaglandin drug products more than once daily may decrease the IOP lowering effect or cause paradoxical IOP elevations.

USE IN SPECIFIC POPULATIONS

Pregnancy: There are no adequate and well-controlled studies of IYUZEH administration in pregnant women to inform drug-associated risks.

Lactation: It is not known whether this drug or its metabolites are excreted in human milk. Because many drugs are excreted in human milk, caution should be exercised when IYUZEH is administered to a nursing woman. The developmental and health benefits of breastfeeding should be considered along with the mother's clinical need for IYUZEH and any potential adverse effects on the breastfed child from IYUZEH.

Pediatric Use: The safety and effectiveness of IYUZEH have not been established in pediatric patients.

Geriatric Use: No overall differences in the safety or effectiveness of IYUZEH have been observed between elderly and younger adult patients.

OVERDOSAGE

Intravenous infusion of up to 3 mcg/kg of latanoprost in healthy volunteers produced mean plasma concentrations 200 times higher than during clinical treatment with latanoprost ophthalmic solution and no adverse reactions were observed. IV dosages of 5.5 to 10 mcg/kg caused abdominal pain, dizziness, fatigue, hot flushes, nausea, and sweating.

HANDLING THE CONTAINER

IYUZEH is a sterile solution that does not contain a preservative supplied in a single-dose container. The solution from one individual container is to be used immediately after opening for administration to one or both eyes. Since sterility cannot be maintained after the individual container is opened, the remaining contents should be discarded immediately after administration. Open a new single-dose container every time you use IYUZEH.

Manufactured for: Théa Pharma Inc. Waltham, MA.

All rights reserved.

U.S. Patent N^o. 8,637,054.

Revised: 04/2023

©2021 Laboratoires Théa. All Rights Reserved. IYUZEH™ is a trademark of Laboratoires Théa.

LETTERS TO THE EDITOR

Feedback and ideas from the optometric community.

SHARE YOUR THOUGHTS

Letters are welcome. Write to:
editor@reviewofoptometry.com.

Submissions may be edited for length,
content or clarity.

Playing in the Sandbox

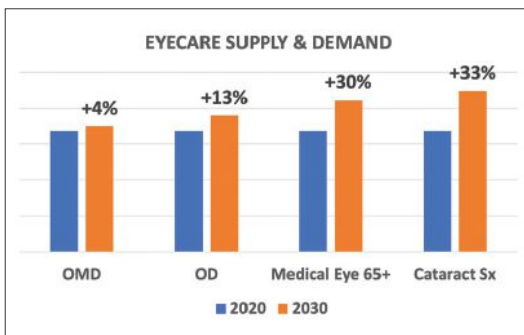
Unavoidable shortages of ophthalmologists compel better OD-MD relations to meet the urgent need for eye care.

It is mission-critical that the professions of ophthalmology and optometry learn to play nicer in the eyecare sandbox. Significant disruptions in both the supply of eyecare providers and the demand for medical and surgical eyecare will require that eyecare providers (ECPs) work in a more collaborative manner now and well into the future. Let's take a look at the numbers driving these disruptions.

Supply of Eyecare Providers

The Association of University Professor of Ophthalmology (AUPO) tracks and reports the number of residency positions each year. From this, one can project out a minimum of three years the number of new residency trained ophthalmologists (OMDs) entering the workforce. Additionally, approximately 2.5% of the workforce (this is true for both ophthalmology and optometry and equates to a 40-year professional career) exit each year due to death, disability or simply retirement. Over the past decade, the average number of new OMDs was 460 per year. This decade the average is 492 per year.

I track both the number of ophthalmologists and optometrists (ODs) entering and exiting each year. The reported number of total OMDs in the US varies anywhere from 16,500 to 18,500. My tracking shows 17,000 for 2023. Based on the AUPO data and 2.5% exit estimate, we will have 495 new OMDs entering and 425 exiting, for a net increase of 70 ophthalmologists for the entire country.



Some estimate the exiting rate is as high as 500 per year. The US Health Resources and Services Administration projects a shortage of OMDs in 2025 of 6,180.

There are approximately 48,000 ODs in the US with 1,777 completing their programs this year and 1,250 exiting, for a net increase of 527.

Based on the difference between entering and exiting ECPs from 2020 to 2030, the supply of ophthalmologists will increase just 4.0% and optometrists 12.9%. These increases are NOT per year but over the entire 10-year period. Additionally, I have not factored in the impact of work-life balance trends that may reduce the number of hours worked by ECPs.

Demand for Eyecare Services

The need for medical and surgical eyecare is growing at a rapid pace. I track demand and then project future needs based upon US Census data. Medicare reports utilization and payment data for all billed and paid services in the Medicare fee-for-service program each year. With this data, one can then estimate the services delivered in the

Medicare Advantage program as well as make conservative estimate for the commercial market. My data indicates that ECPs provided 56.9 million medical eye exams in 2019 (2020 was the COVID anomaly). Applying Census projections, we can expect the demand for medical eye exams to increase to 71.5 million in 2030, for a 25.7% increase. The rate of increased demand for the age 65 and older population is 30.5%. This does not include the increased demand for diagnostic testing, surgical procedures or intravitreal injections.

It is estimated that 4.2 million cataract procedures were performed in the US in 2020 (ignoring COVID for just a moment). Estimates for 2030 run around 5.6 million procedures. The average number of procedures each year per surgeon is around 400. The increase of 1.4 million procedures will require an additional 3,500 surgeons, yet we will only have at most 700, many of whom will subspecialize in retina, glaucoma or pediatric ophthalmology. This massive imbalance will require surgeons to spend more and more time in the surgical facility and less time in the office-based clinic.

Ophthalmology and optometry must collaborate to manage this potential public health crisis. The US Bureau of Labor Statistics estimates that 17% of optometrists work in a vertically integrated eyecare practice. That is a solid start but needs to increase over the next decade or two. Simply looking at the 10-year projections for supply and demand should be a wake-up call for both ophthalmology and optometry to collaboratively play nicer in the eyecare sandbox.

—Richard C. Edlow, OD
The Eyeconomist

To comment on these discussions, or start your own, write to editor@reviewofoptometry.com.



Use Your Turn Signals

Don't make assumptions and cut to the chase with your patients, even when they don't properly use theirs.

There are a lot of issues in this world that can drive you to the dark side. One of these asks the same question that good, fair-minded folks have asked since Percy Douglas-Hamilton patented the first automobile turn signal in 1909: "Why don't people use their turn signals when driving?"

I mean, what is up with that anyway? My dear father never explained the birds and the bees to me, but feeling this topic was much more important, he spent hours instructing me about the proper use of automobile turn signals; when to use them, how far from the turn to use them and how to make sure they don't stay on while your car goes straight ahead for 10 miles driving every vehicle behind you totally looney tunes.

I now agree this was way more important than that birds and bees stuff. In optometry, we often make assumptions about a patient, either because he doesn't exactly use his turn signals properly or maybe he forgets to flip it off once he has made his turn.

For example, you recheck a patient's spectacle prescription over and over because he's not satisfied, making small but possibly significant Rx adjustments over a two-month period. You raise the seg. You lower the seg. You add plus. You subtract plus. You change the base curve. You change it back. On and on it goes.

Then he says, "My wife doesn't like metal frames." Ooohhh. OooKay. He decided to finally use his turn signal. It's like those dumb bunnies who flip on

the turn signal when they are already three quarters into their turn after you've been patiently waiting for your chance to merge into traffic because you assumed they were not turning at all.

My advice? No lens remakes until you say, "I love that frame on you. It looks great, don't you agree?" That's right. Cut to the chase and once you know it's not the frame, then you can raise and lower segs to your heart's content.

Sometimes a patient does indeed use their optometric turn signal properly. I recall one who came in for his exam and the first thing he said was he needed prescription sunglasses for his upcoming cruise. During the exam, I noticed he was flushed and short of breath, so I immediately called his PCP and we both agreed he should come over (the office was next door) right away. Turned out, he was in the process of growing a clot. 911 was called and he was taken to the hospital where thankfully he survived and has thrived.

I felt pretty good about myself... maybe I saved his life after all... and was happy to take

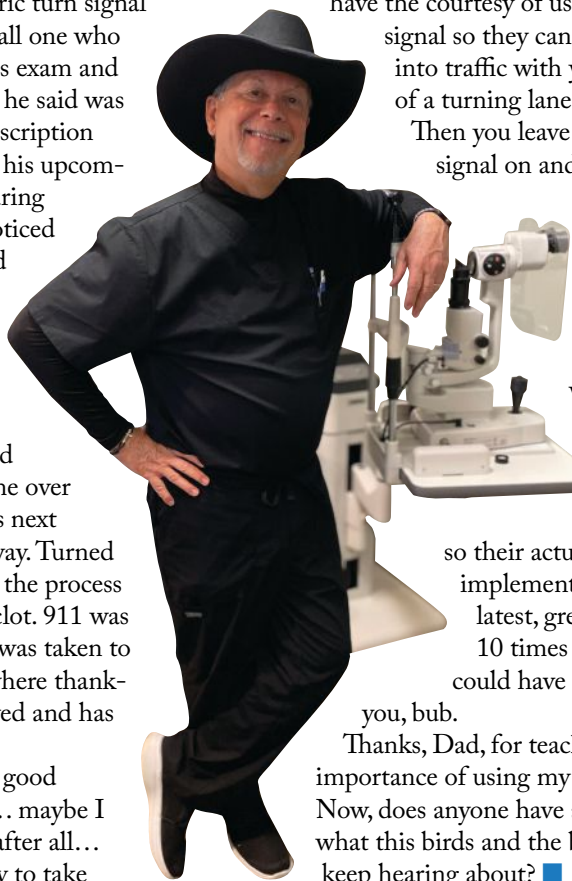
his phone call a week later. Surely, he was calling to express his gratitude. I already had my, "Nah, it was nothing, just doing my job" speech ready to go. No. He was ticked off because he never got his sunglasses in time for the cruise. For many reasons, including—you will agree—some very, very reasonable ones, I ignored his turn signal. Duh. Ignore a patient's turn signal at your own peril, doc, not the patient's!

You also do not often use your turn signal properly, right? Ever show up Monday morning with your latest, greatest theory about changing every moment of every staffer's workload starting this second? What? They're not smiling? Huh? They are about to show you what road rage means... starting this second. Come on, doc! At least have the courtesy of using your turn signal so they can safely merge into traffic with you! Ever heard of a turning lane?

Then you leave your turn signal on and on and on as they suffer through the implementation of your latest, greatest theory while you still mindlessly plod away by doing things the old way

so their actual physical implementation of your latest, greatest theory is 10 times harder than it could have been. That's on you, bub.

Thanks, Dad, for teaching me the importance of using my turn signals. Now, does anyone have any idea on what this birds and the bees thing is I keep hearing about? ■



About Dr. Vickers

Dr. Vickers received his optometry degree from the Pennsylvania College of Optometry in 1979 and was clinical director at Vision Associates in St. Albans, WV, for 36 years. He is now in private practice in Dallas, where he continues to practice full-scope optometry. He has no financial interests to disclose.

From the makers of the #1-prescribed dry eye brand in Europe*

Covering the spectrum of

Dry Eye Relief

Over-the-counter iVIZIA® lubricant eye drops deliver a unique combination of immediate and long-lasting relief and ocular surface protection in a preservative-free formulation.

- Advanced formulation offers a combination of povidone (active), hyaluronic acid (HA), and trehalose
- HA and trehalose increased tear film thickness for up to 240 minutes
- Proprietary, multi-dose bottle

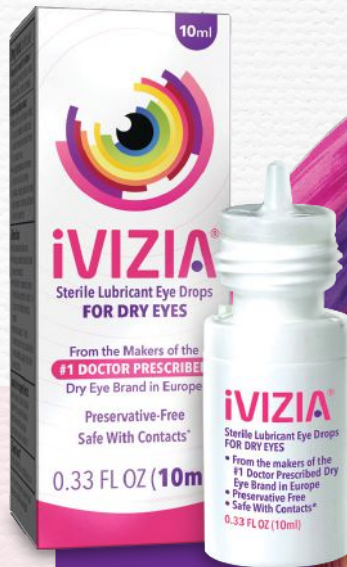Chronic Dry Eye Patient Usage Study†:

Up to
8 hours
of relief

as well as improved comfort during computer work, reading, and driving¹

84%

of users reported iVIZIA worked better than their previous eye drops¹



Safe for use with contact lenses‡



Scan here.

Recommend iVIZIA and request samples by visiting [iVIZIA.com/ECP](https://www.ivizia.com/ECP).

*Prescription market data, Dec. 2022 – S01K without cyclosporine.

†In a chronic dry eye patient usage study, participants from a variety of socioeconomic backgrounds answered questions about iVIZIA. There were 203 chronic dry eye patients, ranging from ages 28-80, who used their current eye drops before switching to iVIZIA for 30 days.¹

‡To limit blurriness when using contact lenses, remove contacts, apply drops, then insert contacts.

Reference: 1. Data on file.

Copyright ©2023 Thea Pharma Inc. | Similasan | All Rights Reserved. | PRC-IED-1030-v2 04.2023

Made by
Thea
let's open our eyes

Distributed by
Similasan
EVIDENCE-BASED EYE CARE



EDITED BY PAUL C. AJAMIAN, OD

CLINICAL QUANDARIES

Fishin' for Trouble

Managing traumatic hyphema requires vigilance during and after treatment.

Q An eight-year-old girl presents as a weekend emergency after a fishing line with weights on the end sprung into her eye. What's the appropriate management of this patient?

A "First, obtain a good case history," says Jessica Schiffbauer, OD, of The Eye Centers of Racine and Kenosha, WI. Ask the child and her family questions that include time of injury, time the vision loss occurred, any systemic medications with anticoagulants (aspirin, NSAIDs, warfarin or clopidogrel), personal or family history of sickle cell disease and history of any nose bleeds, bleeding gums or easy bruising.

Examine Closely

Check the patient's vision and pinhole acuity. "For patients with recent injury or trauma, advise staff to avoid touching the eye until further instructed, which includes deferring fluorescein instillation and IOP measurement until the doctor sees the patient," Dr. Schiffbauer says.

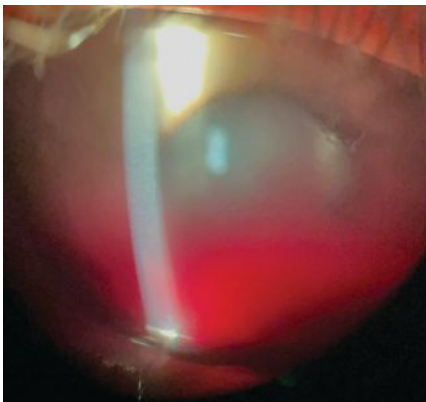


Fig. 1. Slit lamp image of hyphema.

To rule out a ruptured globe or penetrating ocular injury, perform a slit lamp examination prior to the insertion of drops. This is often difficult due to pain and photophobia. "Anesthetic will probably be required, so I put in a drop or two of proparacaine to perform the slit lamp exam and then use a fluorescein strip to check Seidel," Dr. Schiffbauer notes.

Once a laceration or penetrating injury has been ruled out, assess the anterior chamber for circulating red blood cells and/or inflammatory cell and flare, each graded separately. Dr. Schiffbauer measures the height of the hyphema and notes the location of any clot or blood. If possible, she will try to document the hyphema with a slit lamp photo, as she did here on initial presentation (*Figure 1*). Capturing these pictures is great so you will have them on file as you follow these patients through the healing process.

Now it's time to check the IOP, and using iCare for a child this age is probably a good choice. Dilated fundus exam is mandatory. "Unfortunately, in this case, the view of the posterior segment was limited due to the hyphema," Dr. Schiffbauer observes. "If ultrasound is available, I would perform a B-scan with light pressure to assess the status of the retina."

The Five-Day Period

The greatest risk for new bleeding or rebleeding occurs within the first five days. Advise the patient—and their parents—to keep their head continuously elevated, sleep with the head

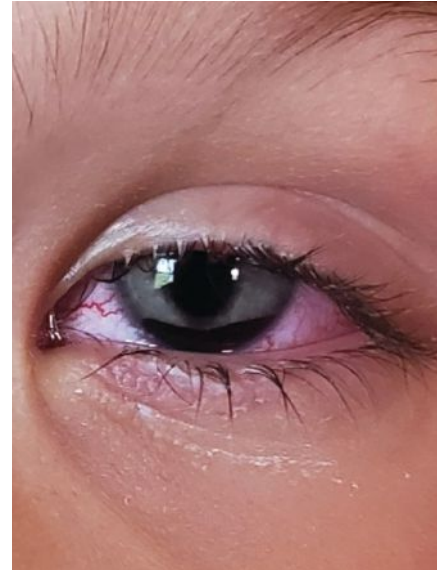

Fig. 2. Significant improvement at 28-hour follow-up.

propped up at a 45° angle, avoid physical activity, bending or lifting, and also wear an eye shield while sleeping. It may be best for the child to stay home from school to avoid further injury to the eye and reduce the risk of a rebleed.

Start the patient on a topical cycloplegic such as Cyclogyl (cyclopentolate 1%, Alcon) or atropine TID OD and a topical steroid such as prednisolone every two hours.

"If the IOP is in the upper twenties or higher, start a combination ocular hypotensive medication such as brimonidine-timolol, dorzolamide-timolol or brinzolamide-brimonidine BID," Dr. Schiffbauer advises. "Avoid prostaglandins and miotics to avoid more inflammation and confirm that the child has no asthma or breathing issues prior to starting a beta-blocker."

Depending on the response from topical treatment, oral treatment for IOP may be indicated. If this patient does have sickle cell disease or trait, avoid carbonic anhydrase inhibitors, alpha agonists and prostaglandins. Monitor this patient daily to check

About
Dr. Ajamian

Dr. Ajamian is board certified by the American Board of Optometry and serves as Center Director of Omni Eye Services of Atlanta. He is vice president of the Georgia State Board of Optometry and general CE chairman of SECO International. He has no financial interests to disclose.

NEW
TECHNOLOGIES
& TREATMENTS IN
EYE CARE



NOVEMBER 10–12, 2023
GRAND HYATT NASHVILLE
NASHVILLE, TENNESSEE

CONFERENCE CHAIR



Paul M. Karpecki, OD, FFAO

Director of Cornea Services
Kentucky Eye Institute
Medical Director
Keplr Vision
Lexington, Kentucky

FACULTY



Marc Bloomenstein, OD, FFAO

Director of Optometric Services
Schwartz Laser Eye Center
Scottsdale, Arizona



Doug Devries, OD

Co-Founder
Eye Care Associates of Nevada
Associate Clinical Professor of Optometry
Sparks, Nevada



Mark Dunbar, OD, FFAO

Director of Optometry
University of Miami
Adjunct Faculty
Nova Southeastern University
New England College of Optometry
Miami, Florida



For more information and to register,
scan the QR code or visit:

www.reviewedu.com/nttnashville

Earn up to 22 COPE credits*

visual acuity, IOP and slit lamp for improvement.

At the 28-hour follow-up, our patient's condition improved significantly (*Figure 2*). The blood had settled, and the vision was clearing dramatically. This was encouraging, but Dr. Schiffbauer would still be worried about the risk of a rebleed, given the patient's age.



For patients with recent injury or trauma, advise staff to avoid touching the eye until further instructed.

—Jessica Schiffbauer, OD



“Continue with the drops and slowly taper off the cycloplegic and anti-inflammatory as the blood, fibrin and white blood cells start to resolve,” she suggests. “At this visit, I would also attempt to evaluate the posterior segment.”

Once the patient has made it past the critical period, Dr. Schiffbauer would perform gonioscopy to check for signs of peripheral anterior synechiae or angle recession.

“If continual improvement is noted, start spacing out the visits and tapering off the drops,” she says. “Due to the patient's age, I would recommend keeping all the restrictions in place until the hyphema has resolved.”

Educate this child's parents about the risk of complications following a traumatic injury, such as cataracts, elevated IOP and glaucoma. If no complications arise, examine this patient annually with gonioscopy. Also, stress the need for eyewear protection for future fishing trips.

“This case and ones like it are easily managed by the doctor of optometry. Consider a second opinion if there is corneal blood staining, no significant improvement (<50%) of the hyphema after one week, or extremely elevated pressure that does not respond to topical therapy,” Dr. Schiffbauer recommends. ■



*COPE Accreditation Pending



Postgraduate Institute
for Medicine

REVIEW
Education GROUP



The Forgotten Tool for Binocular Vision

Contact lenses can be great for certain issues of this sort.

Binocular vision and accommodative issues are prevalent in most patient populations. In a population of optometry students, one study found that the prevalence of non-strabismic accommodative dysfunction was 55%, vergence dysfunction was 73% and oculomotor dysfunction was 15%.¹ Another study investigated university students' vision and found that 32.3% showed general binocular dysfunction.² In a population of Australian children from a remote village, one study found that 15% had binocular vision or accommodative disorders.³

While all of these issues can benefit from treatment that includes vision therapy, several of them may also benefit from the addition of plus lenses. These can potentially help with accommodative

insufficiency, convergence excess and basic esophoria.


While it is lovely when numbers line up perfectly to diagnose these conditions, another way to decide whether plus at near will be valuable to the patient is to look at the examination data. The following findings indicate that plus at near may be an effective addition to treatment: high AC/A, esophoria at near, low positive relative accommodation (PRA), high monocular estimation method (MEM) or fused cross-cylinder test (lag of accommodation), low amplitude of accommodation and failing minus on accommodative facility. Plus at near can be given either for near vision only, or as a bifocal if the patient has a distance prescription or is unwilling to take their glasses off for near viewing.

Believe it or not, some patients, especially teens and young adults, do not like wearing reading glasses or bifocals. Even though there are visual advantages, the emotional and psychosocial aspects of wearing glasses with a line, or what may be deemed “granny glasses,” sometimes outweigh those benefits for patients. In such cases, we have progressive addition lenses, but another option to consider is contact lenses. There are several bifocal contact lens designs to weigh, of which some will be described in two case reports below.

Case 1

An 18-year-old female college student presented with complaints of headaches and eye strain with extended reading and computer work that started upon entering college several months prior. She was a graphic design major, which required her to spend extended time on the computer. She wore contact lenses (-3.00D OU, Bausch + Lomb Ultra sphere) and had worn glasses since age 12. Her acuity with contacts was 20/20 OD, OS, OU at distance and 20/25 OD, OS, OU at near. Her cover test was ortho at distance and three esophoria at near. Stereopsis was 40 seconds of arc and negative relative accommodation (NRA) and PRA was unbalanced at +2.50/-0.50. The base-out vergence at near showed normal blur and break but poor recovery. Near point of convergence was “to the nose” x 3.

The patient was trial framed at near with +1.00D over her habitual contact lenses. Her visual acuity sharpened to 20/20 OU at near, the cover test at near was measured at three exophoria and stereopsis was 25 seconds of arc; she was diagnosed with convergence excess. She was presented with two treatment options, including plus readers over her contact lenses or bifocal contact lenses—she chose the latter.



The Ultra multifocal is designed to fit different add powers as well as levels of astigmatism.

About Dr. Taub and Schnell

Dr. Taub is a professor and co-supervisor of the Vision Therapy and Pediatrics residency at Southern College of Optometry (SCO) in Memphis. He specializes in vision therapy, pediatrics and brain injury. **Dr. Schnell** is an associate professor at SCO and teaches courses on ocular motility and vision therapy. She works in the pediatric and vision therapy clinics and is co-supervisor of the Vision Therapy and Pediatrics residency. Her clinical interests include infant and toddler eye care, vision therapy, visual development and the treatment and management of special populations. They have no financial interests to disclose.

Look for choroidal hypertransmission, a marker of Geographic Atrophy (GA) on OCT^{1*}

- While BCVA is poorly correlated to lesion size, visual function continues to decline as lesions grow^{2,3}
- It is critical to recognize GA and refer patients in a timely manner, as disease progression is relentless and irreversible^{1,3-7}

Learn more about identifying GA
at [RecognizeAndReferGA.com](https://www.recognizeandreferga.com)



**RECOGNIZE
AND REFER**

*GA is defined by atrophic lesions, resulting from loss of photoreceptors, RPE, and underlying choriocapillaris. This results in a choroidal hypertransmission defect on OCT.^{1,8,9}
BCVA=best-corrected visual acuity; OCT=optical coherence tomography; RPE=retinal pigment epithelium.

References: 1. Fleckenstein M, Mitchell P, Freund KB, et al. The progression of geographic atrophy secondary to age-related macular degeneration. *Ophthalmology*. 2018;125(3):369-390. doi:10.1016/j.ophtha.2017.08.038. 2. Heier JS, Pieramici D, Chakravarthy U, et al. Visual function decline resulting from geographic atrophy: results from the chroma and spectri phase 3 trials. *Ophthalmol Retina*. 2020;4(7):673-688. doi:10.1016/j.oret.2020.01.019. 3. Sunness JS, Margalit E, Srikumaran D, et al. The long-term natural history of geographic atrophy from age-related macular degeneration: enlargement of atrophy and implications for interventional clinical trials. *Ophthalmology*. 2007;114(2):271-277. 4. Boyer DS, Schmidt-Erfurth U, van Lookeren Campagne M, Henry EC, Brittain C. The pathophysiology of geographic atrophy secondary to age-related macular degeneration and the complement pathway as a therapeutic target. *Retina*. 2017;37(5):819-835. doi:10.1097/iae.0000000000001392. 5. American Optometric Association. AOA Comprehensive adult eye and vision examination. *Quick Reference Guide: Evidence-Based Clinical Practice Guideline*. 1st ed. Accessed July 13, 2023. https://www.aoa.org/documents/EBO/Comprehensive_Adult_Eye_and_Vision_20QRG.pdf. 6. Holz FG, Strauss EC, Schmitz-Valckenberg S, van Lookeren Campagne M. Geographic atrophy: clinical features and potential therapeutic approaches. *Ophthalmology*. 2014;121(5):1079-1091. doi:10.1016/j.ophtha.2013.11.023. 7. Lindblad AS, Lloyd PC, Clemons TE, et al; Age-Related Eye Disease Study Research Group. Change in area of geographic atrophy in the age-related eye disease study: AREDS report number 26. *Arch Ophthalmol*. 2009;127(9):1168-1174. doi:10.1001/archophthalmol.2009.198. 8. van Lookeren Campagne M, LeCouter J, Yaspan BL, Ye W. Mechanisms of age-related macular degeneration and therapeutic opportunities. *J Pathol*. 2014;232(2):151-164. doi:10.1002/path.4266. 9. Chakravarthy U, Bailey CC, Scanlon PH, et al. Progression from early/intermediate to advanced forms of age-related macular degeneration in a large UK cohort: rates and risk factors. *Ophthalmol Retina*. 2020;4(7):662-672.

Apellis

The APELLIS® name and logo is a registered trademark of Apellis Pharmaceuticals, Inc.
©2023 Apellis Pharmaceuticals, Inc. 8/23 US-GA-2300089 v1.0

A Powerful Approach to Myopia Management

New Tools Can Help Clinicians Stay Ahead of the Curve



Thomas Aller, OD, FBCLA

As the incidence of myopia increases worldwide, with a predicted prevalence of around 50% of the world's population by 2050,¹ eyecare professionals likely will see an uptick in visits from younger patients in need of diagnosis, prognosis, and treatment. While some clinicians may have sidestepped the myopia arena until now, they have a unique opportunity to begin screening for and managing this growing population of patients. Actively searching for patients at risk for developing myopia and utilizing the available spectacles, contact lenses, orthokeratology and low dose atropine to effectively manage myopia is now

the standard of care, as noted by a number of professional organizations.^{2,3}

Providing care for myopic and at-risk patients will not only offer the eyecare practice another touchpoint with patients and their family members, but it affords the possibility of detecting myopia and high myopia early. This is especially important since high myopia brings with it heightened risk of vision impairment associated with retinal damage, cataracts, and glaucoma.¹ As persuasively argued in a recent article, "there is no safe level of myopia"⁴ and "each diopter matters."⁵

Lenstar Myopia from Haag-Streit, is an all-inclusive, turn-key system which includes the device, software with viewer licenses, computer, monitor, power table, and printer.



Lenstar Myopia Device

A Comprehensive Tool to Track Myopia

To optimally address myopia in the practice, comprehensive diagnostic, monitoring, and management are needed along with the right tools. While several biometers approved in the US have been found to effectively measure axial length, it's helpful to understand the unique needs of a practice to find the right solution.

Lenstar Myopia, launched in 2020, combines the established Lenstar 900 optical biometer with EyeSuite Myopia

Sponsored by



An Advanced Approach to Track Progression

In his research to create the Age-Matched Myopia Control (AMMC[®]) framework, Prof. Dr. Hayan Kaymak and his team found, to assess myopia progression, evaluating the speed of axial length change is preferable to refractive change when determining therapy and measuring its effectiveness.^{1,2} They concluded that the primary goal of myopia therapy in children should be reducing abnormally fast axial length growth. The team uncovered, through epidemiologically collected growth curves, that eyes with an axial length associated with adult emmetropia experience their highest growth rates in childhood,^{3,4,5} and that physiologically required axial length growth underlies the excessive axial length growth of pediatric myopic eyes.


Based on these findings,⁶ the team extracted new epidemiological growth curves describing so-called “physiological” axial length growth as a function of age. Dr. Kaymak’s work demonstrates that targeting such a growth rate—which varies slightly by gender and age^{3,4,5}—should be a goal for myopia therapy. They developed the AMMC[®] framework with that strategy in mind.

1. Kaymak H, Graff B, Neller K, et al. (2022, September 4-7) Myopia therapy – keep it simple: physiological axial length growth as the treatment goal. Poster presented at the International Myopia Conference. Rotterdam, Netherlands.
2. Cho P, Cheung SW, Boost MV. Categorisation of myopia progression by change in refractive error and axial elongation and their impact on benefit of myopia control using orthokeratology. PLoS One. 2020 Dec 29;15(12):e0243416.
3. Tideman JW, Polling JR, Vingerling JR, et al. Axial length growth and the risk of developing myopia in European children. Acta Ophthalmol. 2018 May;96(3):301-9.
4. Trukenbrod C, Meigen C, Brandt M, et al. Longitudinal analysis of axial length growth in a German cohort of healthy children and adolescents. Ophthalmic Physiol Opt. 2021 May;41(3):532-540.3-5.
5. Sanz Diez P, Yang LH, Lu MX, et al. Growth curves of myopia-related parameters to clinically monitor the refractive development in Chinese schoolchildren. Graefes Arch Clin Exp Ophthalmol. 2019 May;257(5):1045-53.
6. Kaymak H, Neller K, Graff B, et al. Optometrische Schulreihenuntersuchungen : Erste epidemiologische Daten von Kindern und Jugendlichen der 5. bis 7. Klasse [Optometric eye screening in schools : First epidemiological data for children and adolescents in grades 5-7]. Ophthalmologie. 2022 Jan;119(Suppl 1):33-40.

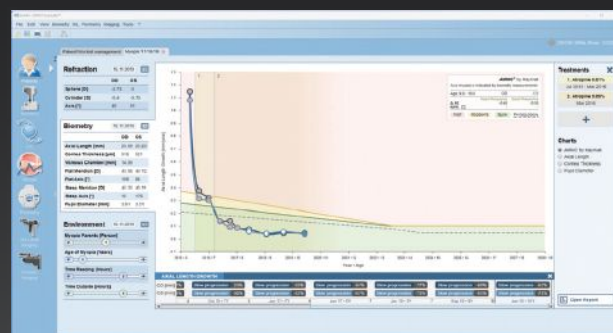software, developed according to the latest clinical findings and collaboration with international myopia experts. It offers three simple, yet pivotal, analytic models for myopia diagnostics and management based on refraction, axial length measurement, and the influences of environmental factors.

Refraction. The software’s refractive analysis, which I helped develop in collaboration with Pascal Blaser of myopicare.com, presents refractive progression trends based on predicted outcomes of different treatment methods, and compares them to the untreated course of myopia. The patient’s refractive status is shown with calculations based on literature-based average control rates that can be adapted according to the practitioner’s experience or as new control rates become available in the published literature.

Axial Length Measurement. Visualization of axial length or biometry data supports myopia progression analysis by overlaying axial length growth curves of peer-reviewed population-based studies. Additional measurements such

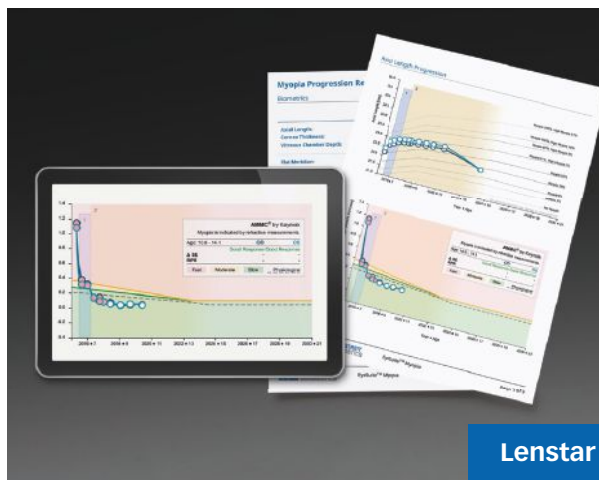


Lenstar Myopia’s Refraction display visualizes a patient’s current refraction with progression curves indicating different treatments with their reported efficacies.



Lenstar Myopia’s Age-Matched Myopia Control uses a traffic light system to clearly indicate when a patient’s axial length growth rate is abnormally fast compared with emmetropic patients of the same age and gender.

as pupillometry, vitreous chamber depth, central corneal thickness, and keratometry add additional insights to better facilitate accurate predictions about the onset and progression of myopia, as well as provide information required for treatments such as corrective lenses. Three distinct progression visualizations are available based on data from the Tideman myopia study,⁶ a meta-analysis which distinguishes between Asian and Caucasian myopia development risks, and the recently released AMMC[®] framework.



The Lenstar Myopia parental report is a customizable, printable report of each patient's status and includes their individualized treatment plans.

Lenstar Myopia Parental Report

The Age-Matched Myopia Control (AMMC[®]) framework

developed by Prof. Dr. Hakan Kaymak tracks axial growth based on extensive research analysis and clinical findings. While axial length growth is normal at a young age, distinguishing pathological axial length growth from emmetropic growth is necessary to ascertain patient myopia status. AMMC[®] compares axial length growth speed to a broad demographic database to rapidly uncover pathologically fast-growing eyes and classify axial length growth as "low/tolerable," "moderate," or "high." Eyecare professionals receive a clear indication for the need for therapeutic action based on the age and status of the patient. Importantly, excessive axial length growth can be detected before it becomes visible in refraction so treatment can be administered in pre-myopic children to keep axial length growth in a desirable physiological range.

Environment. The third module is an interactive tool. It displays the impact of environmental factors such as myopic parents, age of onset, time spent outside, time spent reading or doing near eye work, and their potential effects on myopia progression. With the device's easy customization capabilities, doctors can even add the capability to track mobile and tablet usage for parents.

Having had the somewhat unique experience of being able to use optical biometry for over 20 years and having had the opportunity to be involved with the Lenstar Myopia's early development, I can confidently assert that the level of precision offered by this tool allows for optimized myopia management for each individual patient. Subjective

refractions are notoriously inaccurate, even with cycloplegia in clinical trials, with differences of 0.50D or more necessary to have confidence that there really is a difference between two measurements. With a reported standard deviation of 0.015mm and repeatability of 0.04mm,⁷ Lenstar Myopia offers the possibility of increased accuracy and rapid assessment of treatment effectiveness.

Simple & Accurate Measurements & Reports

At the heart of myopia management is the ability to correctly measure children's eyes. Being able to easily and rapidly capture measurements with the click of a joystick can increase doctor and patient comfort. This is especially important because children can be impatient and have difficulty cooperating with the measurement process.

Lenstar 900's Automated Positioning System (APS) offers such ease of measurement while yielding essential data such as axial length, pupillometry, vitreous chamber depth, central corneal thickness, and keratometry to improve predictive accuracy about the onset and progression of myopia.

Yet, the right information is not valuable if it can't be communicated in a clear, understandable way to parents. Lenstar Myopia's customizable report, based on «myopia.care™», provides parents with digestible information to encourage them to actively participate in their child's myopia management.

Sponsored by



Helping to Catch Myopia Early

Since myopia treatments, on average, can only slow progression, to achieve the lowest possible level of myopia and risk of myopia-related pathologies, it is advisable for clinicians to identify future myopes in the pre-myopia stage and to start treatment when convinced the child is likely to be a future myope.¹ Pre-myopia has been defined as having a level of hyperopia that is insufficient for the age,² so failing to slow hyperopia or acceleration of axial elongation are likely signs of future myopia. With the fastest axial growth reportedly occurring up to two years prior to the official onset of myopia,³ it can be very helpful to identify these patients prior to myopia onset and begin treatment.

Lenstar Myopia is quite valuable for such a strategy, as it precisely measures axial length and provides percentile curves and predictions of future myopia based on age and axial length. The new AMMC[®] analysis also provides rapid comparison of observed growth rates with age- and gender-matched emmetropic growth rates for fast determination of the risk of future myopia. While early treatment of future myopia helps to deliver the best final outcome, it is always challenging to suggest a treatment for a condition that is not yet present. However, the availability of precision measurements and normative data summarized and illustrated in thorough reports offered by Lenstar Myopia helps the practitioner make the case for early treatment.

1. Aller TA. Clinical management of progressive myopia. *Eye (Lond)*. Feb 2014;28(2):147-53.

2. Flitcroft DI, He M, Jonas JB, et al. IMI - Defining and Classifying Myopia: A Proposed Set of Standards for Clinical and Epidemiologic Studies. *Invest Ophthalmol Vis Sci*. 02 2019;60(3):M20-M30.

3. Mutti DO, Hayes JR, Mitchell GL, et al. Refractive error, axial length, and relative peripheral refractive error before and after the onset of myopia. *Invest Ophthalmol Vis Sci*. Jun 2007;48(6):2510-9.

Lenstar Myopia is fast, accurate and non-invasive. With its Automated Positioning System (APS), capturing measurements is quick and easy.



Moving Forward With Myopia Care

While it is not the standard of care for every eye care practitioner to become a myopia management specialist, it is the standard of care to identify those patients at risk of developing myopia. Every doctor can and should be prescribing treatments that slow myopia in order to reduce the likelihood of future visual impairment in the vast majority of children at risk of developing myopia. That said, some doctors may wish to detect and refer myopia patients, some may wish to limit their treatments to simple but effective therapies such as novel myopia-controlling spectacles or low dose atropine, and other doctors may want to specialize at the highest level of myopia management. In all cases, Lenstar Myopia, with its demonstrated precision, ease of use, and beneficial predictive and tracking capabilities, is an incredibly helpful tool for comprehensive myopia management.

1. The Impact Of Myopia And High Myopia. Report of the Joint World Health Organization–Brien Holden Vision Institute Global Scientific Meeting on Myopia. Available at: https://myopiainstitute.org/wp-content/uploads/2020/10/Myopia_report_020517.pdf (last accessed July 27, 2023).

2. WCO. Resolution: The Standard of Care for Myopia Management by Optometrists. <https://worldcouncilofoptometry.info/resolution-the-standard-of-care-for-myopia-management-by-optometrists/> (last accessed September 18, 2023).

3. Modjtahedi BS, Abbott RL, Fong DS, et al. Reducing the global burden of myopia by delaying the onset of myopia and reducing myopic progression in children: The Academy's Task Force on Myopia. *Ophthalmology*. Jun 2021;128(6):816-26.

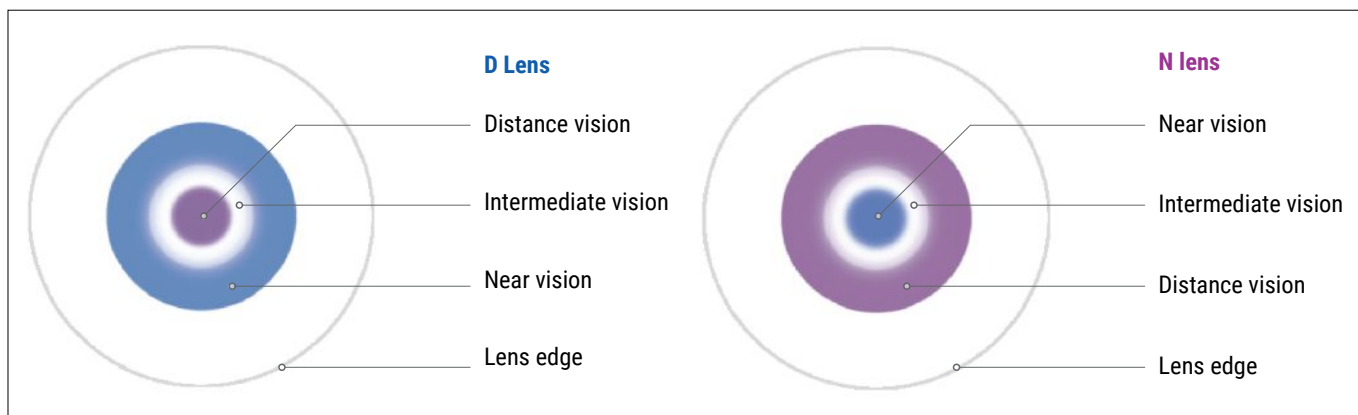
4. Flitcroft DI. The complex interactions of retinal, optical and environmental factors in myopia aetiology. *Prog Retin Eye Res*. Nov 2012;31(6):622-60.

5. Bullimore MA, Brennan NA. Myopia control: why each diopter matters. *Optom Vis Sci*. 06 2019;96(6):463-5.

6. Tideman JWL, Polling JR, Vingerling JR, et al. Axial length growth and the risk of developing myopia in European children. *Acta Ophthalmol*. 2018 May;96(3):301-9.

7. Kaymak H, Graff B, Neller K, et al. (2022, September 4-7) Myopia therapy – keep it simple: physiological axial length growth as the treatment goal. Poster presented at the International Myopia Conference. Rotterdam, Netherlands.

Thomas Aller, OD, FBCLA, has been researching myopia control methods for over 30 years. In 2016, he launched Myappia, a myopia progression app, and he has collaborated with myopiare.com and Haag-Streit on Lenstar Myopia. Dr. Aller is a UC Berkeley Visiting Scholar and has served as an Adjunct Professor at the UH College of Optometry. He also serves as a consultant and advisor to several companies working on myopia control contacts, spectacles, pharmaceuticals, and medical devices.



The Biofinity multifocal comes in two different lens designs, center-distance (left) or center-near (right)

Fortunately, the Ultra family of contact lenses from Bausch + Lomb (B+L) includes a multifocal option with a variety of features, including low vs. high add powers and astigmatism up to $-2.75DC$. The low add ranges from $+0.75D$ to $+1.50D$ and the high add from $+1.75D$ to $+2.50D$. With the Ultra sphere and multifocal both having the same base curve ($8.5mm$) and diameter ($14.2mm$), it was an easy switch to the multifocal version with a low add OU for this patient. The final contact lens prescription was B+L Ultra multifocal $-3.00DS/+1.00$ add OU. This refinement provided the clear distance and comfortable near vision that the patient required for her schoolwork. Upon follow-up, she reported that her symptoms had abated and she could function symptom-free throughout the day.

Case 2

A 12-year-old girl presented with complaints of words moving on the page or screen and blurry vision when looking too long at near. She wore glasses since the age six, with a current Rx of $-3.00-3.25 \times 180$ OD and $-2.50-4.00 \times 180$ OS. Her corrected visual acuity was 20/25 OD, OS, OU at distance and 20/30 OD, OS, OU at near. Her cover test was ortho at distance and three exophoria at near; stereopsis was 60 seconds of arc. A subjective refraction found a small increase in myopia ($-3.25-3.25 \times 180$ OD and $-2.75-4.00 \times 180$ OS). NRA and PRA was unbalanced at $+2.00/-0.25$. Accommodative amplitudes were 8.00D OD, OS and the MEM was $+1.25D$ OD, OS.

The patient was trial framed at near with $+0.75D$ over her new prescription. Her visual acuity sharpened to 20/20 OU, the MEM was $+0.75D$ and stereopsis was 20 seconds of arc. She was consequently diagnosed with accommodative insufficiency and given two treatment options: a bifocal in her glasses, either as a flat top or progressive addition lens, or a bifocal contact lens. She exuberantly chose the latter.

Although this patient's high cylinder and need for a multifocal contact lens could have certainly been intimidating, only one non-customizable, stock option exists on the market that corrects cylinder greater than $-2.75DC$. Fortunately, it is a great one! The Biofinity family from CooperVision includes a multifocal option with a variety of features, including four add powers ($+1.00, +1.50, +2.00, +2.50$), inclusion of astigmatism up to $-5.75DC$ and specification of a center-distance (CD) vs. center-near design. After vertexing, the appropriate trial lenses to order were $-3.25-2.75 \times 180/+1.00$ add/CD OD and $-2.75-3.75 \times 180/+1.00$ add/CD OS.

At the fitting, the lenses were sitting appropriately and did not rotate. Her vision was 20/20 OD, OS, OU at distance and at near. The MEM was measured at $+0.50$ and the accommodative amplitudes were 12D OD, OS. The patient was subsequently scheduled for a follow-up appointment in three months. This would determine whether near visual symptoms improved and exam data continued to be stable. If they are, the add power may be increased to $+1.50$

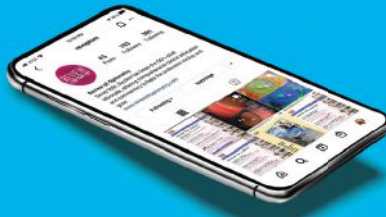OU in order to provide a minor amount of myopia control to reduce myopic progression.

Discussion

Multifocal contacts are a wonderful option for patients who need plus at near to treat accommodative and vergence issues. With the advancement of contact lens technology and production, it is becoming safer and more comfortable for young patients with accommodative insufficiency, convergence excess and basic esophoria to be fit into them. Although the lenses can be intimidating to fit initially, there are only a handful of multifocal options on the market—and only two with astigmatism correction. The only pieces of data that the practitioner needs are an accurate binocular balance prescription and a determination of the desired add power to get started. Patients will be thrilled—socially and emotionally—for this treatment option, while having their symptoms addressed at the same time. This is a win-win scenario for all parties. ■

We would like to thank Charwan Rasheed, OD, assistant professor of optometry at Southern College of Optometry, for assisting with the contact lens aspects of this column.

1. Dahal M, Khatri B. Prevalence of non-strabismic binocular vision dysfunction among optometry students in Bangalore, India. *Optom Vis Perform.* 2019;7(1):23-7.
2. Read SA, Hopkins S, Black AA, et al. Prevalence of vision conditions in children in a very remote Australian community. 2022;106(2):195-201.
3. Porcar E, Martinez-Palomera A. Prevalence of general binocular dysfunctions in a population of university students. *Optom Vis Sci.* 1997;74(2):111-3.



A NEW WAY TO EXPERIENCE REVIEW OF OPTOMETRY

Follow us on Instagram at @revoptom for striking clinical images, daily news headlines, issue previews and great content from the magazine—all formatted for mobile



REVIEW OF OPTOMETRY
NEWS FEED - THE NEWS FEED - THE NEWS FEED - THE NEWS FEED - THE NEWS FEED - THE NEWS FEED

Stories for 3-26-21

Missed Neuro Diagnosis Common, Can Lead to Patient Harm
Study looks back at all retinal vein occlusions and one in four of those experienced some kind of adverse impact on health.

CDC Aims to Break Down Telemed Barriers in Glaucoma
Three researchers are studying for a five-year investigation into the logistics and clinical value of remote monitoring.

Thyroid Eye Disease Increases Risk of Optic Nerve Damage
Affected eyes experience thinning of the RPE, and ocular cell death, increasing the likelihood of progression to advanced optic neuropathy.

Read today at www.reviewofoptometry.com

REVIEW OF OPTOMETRY

High myopia with a maculopathy and this choroid fold (red line), RPE disruption (gray line), and (white line) RPE tear (green line) retinal photoreceptors (blue line) with early subretinal and hyperreflective material (purple line)—all associated with myopic OI.

Choroidal folds causing sub-RPE undulations (red lines)

From "Late Macular OI in a White Eye Laser" by Lisa Weidner, MD
Available at www.reviewofoptometry.com (Issue February 15 2021)

REVIEW OF OPTOMETRY

DRY EYE READER SURVEY RESULTS

What percent of your patients fit each of these categories suffering from dry eye?

Age Group	0%	5%	10%	15%	20%	25%	30%	35%	40%	45%	50%
Adults 20-40 years old	0	0	0	0	0	0	0	0	0	0	0
Adults 41-60 years old	0	0	0	0	0	0	0	0	0	0	0
Adults 61 and older	0	0	0	0	0	0	0	0	0	0	0
Contact lens wearers	0	0	0	0	0	0	0	0	0	0	0
Men	0	0	0	0	0	0	0	0	0	0	0
Women	0	0	0	0	0	0	0	0	0	0	0
Postmenopausal women	0	0	0	0	0	0	0	0	0	0	0

From "Dry Eye Prevalence, Risk and Treatable Risk" by Anne Yen, MD and David Weidner, MD
Available at www.reviewofoptometry.com (Issue February 15 2021)

REVIEW OF OPTOMETRY

Retina associated with a subconjunctival hemorrhage.

From "The Eye Prevalence, Risk and Treatable Risk" by Anne Yen, MD and David Weidner, MD
Available at www.reviewofoptometry.com (Issue February 15 2021)

REVIEW OF OPTOMETRY

CLINICAL FEATURES OF COMMON SECONDARY CONDITIONS ASSOCIATED WITH GLAUCOMA

Condition	Key Features	Associated Findings
Normal-tension glaucoma	Asymptomatic or subtle visual field defects	Asymptomatic or subtle visual field defects
Open-angle glaucoma	Asymptomatic or subtle visual field defects	Asymptomatic or subtle visual field defects
Angle-closure glaucoma	Asymptomatic or subtle visual field defects	Asymptomatic or subtle visual field defects
Neovascular glaucoma	Asymptomatic or subtle visual field defects	Asymptomatic or subtle visual field defects
Exfoliative glaucoma	Asymptomatic or subtle visual field defects	Asymptomatic or subtle visual field defects
Pigmentary glaucoma	Asymptomatic or subtle visual field defects	Asymptomatic or subtle visual field defects
Secondary glaucoma	Asymptomatic or subtle visual field defects	Asymptomatic or subtle visual field defects

From "70 Questions About OI: Get Up to Speed on Ocular OI" by Ann Yu, MD, PhD and Ronald Wang, MD, PhD
Available at www.reviewofoptometry.com (Issue March 15 2021)

REVIEW OF OPTOMETRY

RETN 2021: A 21-year-old white female high myope presented with blurred vision, OD-OS, for over six months, and she felt like there was a "dead spot" in her central vision. Medical history was significant for Crohn's disease since age 14, which had a recent flare-up. BCVA measured 20/400 OD with moderate myopia and 20/70 OS. A fundus photograph showed a central coloboma in both eyes but was negative OD. There was also thinning of both optic nerves. She had a micro-epilepsy history, and other significant changes noted above. (Image left for OCT scans.)

From "Retinal OI: A Case Report" by Paul Howard, MD
Available at www.reviewofoptometry.com (Issue March 15 2021)

REVIEW OF OPTOMETRY

MAR 2021
Dry Eye Issue

Available March 15 2021
www.reviewofoptometry.com

REVIEW OF OPTOMETRY

CLINICAL QUESTION: A 67-year-old female presented with a red eye, a painful eye of the lower lid and eyelashes. What do you think is happening and how would you treat it? (Image left for OCT scans, and the response and management.)

From "The Eye Prevalence, Risk and Treatable Risk" by Anne Yen, MD and David Weidner, MD
Available at www.reviewofoptometry.com (Issue February 15 2021)

REVIEW OF OPTOMETRY

Mean Retinal Thickness (Meanar Data 10/10/20)

The patient calls on the macular OCT indicating edema. She has had a macular OCT scan with the classic pattern of inner retinal edema and the outer retina appearing more acute outer retinal edema. The patient was diagnosed with a choroidal artery occlusion (CAO).

From "The Eye Prevalence, Risk and Treatable Risk" by Anne Yen, MD and David Weidner, MD
Available at www.reviewofoptometry.com (Issue February 15 2021)

REVIEW OF OPTOMETRY

Additional studies that might yield diagnostically pertinent data:

- 30 to 40 look for peripheral retinal lesions
- 45 to 55 look for peripheral retinal lesions
- 60 to 70 look for peripheral retinal lesions
- 85 to 90 look for peripheral retinal lesions
- 100 to 110 look for peripheral retinal lesions
- 120 to 130 look for peripheral retinal lesions
- 140 to 150 look for peripheral retinal lesions
- 160 to 170 look for peripheral retinal lesions
- 180 to 190 look for peripheral retinal lesions
- 200 to 210 look for peripheral retinal lesions
- 220 to 230 look for peripheral retinal lesions
- 240 to 250 look for peripheral retinal lesions
- 260 to 270 look for peripheral retinal lesions
- 280 to 290 look for peripheral retinal lesions
- 300 to 310 look for peripheral retinal lesions
- 320 to 330 look for peripheral retinal lesions
- 340 to 350 look for peripheral retinal lesions
- 360 to 370 look for peripheral retinal lesions
- 380 to 390 look for peripheral retinal lesions
- 400 to 410 look for peripheral retinal lesions
- 420 to 430 look for peripheral retinal lesions
- 440 to 450 look for peripheral retinal lesions
- 460 to 470 look for peripheral retinal lesions
- 480 to 490 look for peripheral retinal lesions
- 500 to 510 look for peripheral retinal lesions
- 520 to 530 look for peripheral retinal lesions
- 540 to 550 look for peripheral retinal lesions
- 560 to 570 look for peripheral retinal lesions
- 580 to 590 look for peripheral retinal lesions
- 600 to 610 look for peripheral retinal lesions
- 620 to 630 look for peripheral retinal lesions
- 640 to 650 look for peripheral retinal lesions
- 660 to 670 look for peripheral retinal lesions
- 680 to 690 look for peripheral retinal lesions
- 700 to 710 look for peripheral retinal lesions
- 720 to 730 look for peripheral retinal lesions
- 740 to 750 look for peripheral retinal lesions
- 760 to 770 look for peripheral retinal lesions
- 780 to 790 look for peripheral retinal lesions
- 800 to 810 look for peripheral retinal lesions
- 820 to 830 look for peripheral retinal lesions
- 840 to 850 look for peripheral retinal lesions
- 860 to 870 look for peripheral retinal lesions
- 880 to 890 look for peripheral retinal lesions
- 900 to 910 look for peripheral retinal lesions
- 920 to 930 look for peripheral retinal lesions
- 940 to 950 look for peripheral retinal lesions
- 960 to 970 look for peripheral retinal lesions
- 980 to 990 look for peripheral retinal lesions
- 1000 to 1010 look for peripheral retinal lesions
- 1020 to 1030 look for peripheral retinal lesions
- 1040 to 1050 look for peripheral retinal lesions
- 1060 to 1070 look for peripheral retinal lesions
- 1080 to 1090 look for peripheral retinal lesions
- 1100 to 1110 look for peripheral retinal lesions
- 1120 to 1130 look for peripheral retinal lesions
- 1140 to 1150 look for peripheral retinal lesions
- 1160 to 1170 look for peripheral retinal lesions
- 1180 to 1190 look for peripheral retinal lesions
- 1200 to 1210 look for peripheral retinal lesions
- 1220 to 1230 look for peripheral retinal lesions
- 1240 to 1250 look for peripheral retinal lesions
- 1260 to 1270 look for peripheral retinal lesions
- 1280 to 1290 look for peripheral retinal lesions
- 1300 to 1310 look for peripheral retinal lesions
- 1320 to 1330 look for peripheral retinal lesions
- 1340 to 1350 look for peripheral retinal lesions
- 1360 to 1370 look for peripheral retinal lesions
- 1380 to 1390 look for peripheral retinal lesions
- 1400 to 1410 look for peripheral retinal lesions
- 1420 to 1430 look for peripheral retinal lesions
- 1440 to 1450 look for peripheral retinal lesions
- 1460 to 1470 look for peripheral retinal lesions
- 1480 to 1490 look for peripheral retinal lesions
- 1500 to 1510 look for peripheral retinal lesions
- 1520 to 1530 look for peripheral retinal lesions
- 1540 to 1550 look for peripheral retinal lesions
- 1560 to 1570 look for peripheral retinal lesions
- 1580 to 1590 look for peripheral retinal lesions
- 1600 to 1610 look for peripheral retinal lesions
- 1620 to 1630 look for peripheral retinal lesions
- 1640 to 1650 look for peripheral retinal lesions
- 1660 to 1670 look for peripheral retinal lesions
- 1680 to 1690 look for peripheral retinal lesions
- 1700 to 1710 look for peripheral retinal lesions
- 1720 to 1730 look for peripheral retinal lesions
- 1740 to 1750 look for peripheral retinal lesions
- 1760 to 1770 look for peripheral retinal lesions
- 1780 to 1790 look for peripheral retinal lesions
- 1800 to 1810 look for peripheral retinal lesions
- 1820 to 1830 look for peripheral retinal lesions
- 1840 to 1850 look for peripheral retinal lesions
- 1860 to 1870 look for peripheral retinal lesions
- 1880 to 1890 look for peripheral retinal lesions
- 1900 to 1910 look for peripheral retinal lesions
- 1920 to 1930 look for peripheral retinal lesions
- 1940 to 1950 look for peripheral retinal lesions
- 1960 to 1970 look for peripheral retinal lesions
- 1980 to 1990 look for peripheral retinal lesions
- 2000 to 2010 look for peripheral retinal lesions
- 2020 to 2030 look for peripheral retinal lesions
- 2040 to 2050 look for peripheral retinal lesions
- 2060 to 2070 look for peripheral retinal lesions
- 2080 to 2090 look for peripheral retinal lesions
- 2100 to 2110 look for peripheral retinal lesions
- 2120 to 2130 look for peripheral retinal lesions
- 2140 to 2150 look for peripheral retinal lesions
- 2160 to 2170 look for peripheral retinal lesions
- 2180 to 2190 look for peripheral retinal lesions
- 2200 to 2210 look for peripheral retinal lesions
- 2220 to 2230 look for peripheral retinal lesions
- 2240 to 2250 look for peripheral retinal lesions
- 2260 to 2270 look for peripheral retinal lesions
- 2280 to 2290 look for peripheral retinal lesions
- 2300 to 2310 look for peripheral retinal lesions
- 2320 to 2330 look for peripheral retinal lesions
- 2340 to 2350 look for peripheral retinal lesions
- 2360 to 2370 look for peripheral retinal lesions
- 2380 to 2390 look for peripheral retinal lesions
- 2400 to 2410 look for peripheral retinal lesions
- 2420 to 2430 look for peripheral retinal lesions
- 2440 to 2450 look for peripheral retinal lesions
- 2460 to 2470 look for peripheral retinal lesions
- 2480 to 2490 look for peripheral retinal lesions
- 2500 to 2510 look for peripheral retinal lesions
- 2520 to 2530 look for peripheral retinal lesions
- 2540 to 2550 look for peripheral retinal lesions
- 2560 to 2570 look for peripheral retinal lesions
- 2580 to 2590 look for peripheral retinal lesions
- 2600 to 2610 look for peripheral retinal lesions
- 2620 to 2630 look for peripheral retinal lesions
- 2640 to 2650 look for peripheral retinal lesions
- 2660 to 2670 look for peripheral retinal lesions
- 2680 to 2690 look for peripheral retinal lesions
- 2700 to 2710 look for peripheral retinal lesions
- 2720 to 2730 look for peripheral retinal lesions
- 2740 to 2750 look for peripheral retinal lesions
- 2760 to 2770 look for peripheral retinal lesions
- 2780 to 2790 look for peripheral retinal lesions
- 2800 to 2810 look for peripheral retinal lesions
- 2820 to 2830 look for peripheral retinal lesions
- 2840 to 2850 look for peripheral retinal lesions
- 2860 to 2870 look for peripheral retinal lesions
- 2880 to 2890 look for peripheral retinal lesions
- 2900 to 2910 look for peripheral retinal lesions
- 2920 to 2930 look for peripheral retinal lesions
- 2940 to 2950 look for peripheral retinal lesions
- 2960 to 2970 look for peripheral retinal lesions
- 2980 to 2990 look for peripheral retinal lesions
- 3000 to 3010 look for peripheral retinal lesions
- 3020 to 3030 look for peripheral retinal lesions
- 3040 to 3050 look for peripheral retinal lesions
- 3060 to 3070 look for peripheral retinal lesions
- 3080 to 3090 look for peripheral retinal lesions
- 3100 to 3110 look for peripheral retinal lesions
- 3120 to 3130 look for peripheral retinal lesions
- 3140 to 3150 look for peripheral retinal lesions
- 3160 to 3170 look for peripheral retinal lesions
- 3180 to 3190 look for peripheral retinal lesions
- 3200 to 3210 look for peripheral retinal lesions
- 3220 to 3230 look for peripheral retinal lesions
- 3240 to 3250 look for peripheral retinal lesions
- 3260 to 3270 look for peripheral retinal lesions
- 3280 to 3290 look for peripheral retinal lesions
- 3300 to 3310 look for peripheral retinal lesions
- 3320 to 3330 look for peripheral retinal lesions
- 3340 to 3350 look for peripheral retinal lesions
- 3360 to 3370 look for peripheral retinal lesions
- 3380 to 3390 look for peripheral retinal lesions
- 3400 to 3410 look for peripheral retinal lesions
- 3420 to 3430 look for peripheral retinal lesions
- 3440 to 3450 look for peripheral retinal lesions
- 3460 to 3470 look for peripheral retinal lesions
- 3480 to 3490 look for peripheral retinal lesions
- 3500 to 3510 look for peripheral retinal lesions
- 3520 to 3530 look for peripheral retinal lesions
- 3540 to 3550 look for peripheral retinal lesions
- 3560 to 3570 look for peripheral retinal lesions
- 3580 to 3590 look for peripheral retinal lesions
- 3600 to 3610 look for peripheral retinal lesions
- 3620 to 3630 look for peripheral retinal lesions
- 3640 to 3650 look for peripheral retinal lesions
- 3660 to 3670 look for peripheral retinal lesions
- 3680 to 3690 look for peripheral retinal lesions
- 3700 to 3710 look for peripheral retinal lesions
- 3720 to 3730 look for peripheral retinal lesions
- 3740 to 3750 look for peripheral retinal lesions
- 3760 to 3770 look for peripheral retinal lesions
- 3780 to 3790 look for peripheral retinal lesions
- 3800 to 3810 look for peripheral retinal lesions
- 3820 to 3830 look for peripheral retinal lesions
- 3840 to 3850 look for peripheral retinal lesions
- 3860 to 3870 look for peripheral retinal lesions
- 3880 to 3890 look for peripheral retinal lesions
- 3900 to 3910 look for peripheral retinal lesions
- 3920 to 3930 look for peripheral retinal lesions
- 3940 to 3950 look for peripheral retinal lesions
- 3960 to 3970 look for peripheral retinal lesions
- 3980 to 3990 look for peripheral retinal lesions
- 4000 to 4010 look for peripheral retinal lesions
- 4020 to 4030 look for peripheral retinal lesions
- 4040 to 4050 look for peripheral retinal lesions
- 4060 to 4070 look for peripheral retinal lesions
- 4080 to 4090 look for peripheral retinal lesions
- 4100 to 4110 look for peripheral retinal lesions
- 4120 to 4130 look for peripheral retinal lesions
- 4140 to 4150 look for peripheral retinal lesions
- 4160 to 4170 look for peripheral retinal lesions
- 4180 to 4190 look for peripheral retinal lesions
- 4200 to 4210 look for peripheral retinal lesions
- 4220 to 4230 look for peripheral retinal lesions
- 4240 to 4250 look for peripheral retinal lesions
- 4260 to 4270 look for peripheral retinal lesions
- 4280 to 4290 look for peripheral retinal lesions
- 4300 to 4310 look for peripheral retinal lesions
- 4320 to 4330 look for peripheral retinal lesions
- 4340 to 4350 look for peripheral retinal lesions
- 4360 to 4370 look for peripheral retinal lesions
- 4380 to 4390 look for peripheral retinal lesions
- 4400 to 4410 look for peripheral retinal lesions
- 4420 to 4430 look for peripheral retinal lesions
- 4440 to 4450 look for peripheral retinal lesions
- 4460 to 4470 look for peripheral retinal lesions
- 4480 to 4490 look for peripheral retinal lesions
- 4500 to 4510 look for peripheral retinal lesions
- 4520 to 4530 look for peripheral retinal lesions
- 4540 to 4550 look for peripheral retinal lesions
- 4560 to 4570 look for peripheral retinal lesions
- 4580 to 4590 look for peripheral retinal lesions
- 4600 to 4610 look for peripheral retinal lesions
- 4620 to 4630 look for peripheral retinal lesions
- 4640 to 4650 look for peripheral retinal lesions
- 4660 to 4670 look for peripheral retinal lesions
- 4680 to 4690 look for peripheral retinal lesions
- 4700 to 4710 look for peripheral retinal lesions
- 4720 to 4730 look for peripheral retinal lesions
- 4740 to 4750 look for peripheral retinal lesions
- 4760 to 4770 look for peripheral retinal lesions
- 4780 to 4790 look for peripheral retinal lesions
- 4800 to 4810 look for peripheral retinal lesions
- 4820 to 4830 look for peripheral retinal lesions
- 4840 to 4850 look for peripheral retinal lesions
- 4860 to 4870 look for peripheral retinal lesions
- 4880 to 4890 look for peripheral retinal lesions
- 4900 to 4910 look for peripheral retinal lesions
- 4920 to 4930 look for peripheral retinal lesions
- 4940 to 4950 look for peripheral retinal lesions
- 4960 to 4970 look for peripheral retinal lesions
- 4980 to 4990 look for peripheral retinal lesions
- 5000 to 5010 look for peripheral retinal lesions
- 5020 to 5030 look for peripheral retinal lesions
- 5040 to 5050 look for peripheral retinal lesions
- 5060 to 5070 look for peripheral retinal lesions
- 5080 to 5090 look for peripheral retinal lesions
- 5100 to 5110 look for peripheral retinal lesions
- 5120 to 5130 look for peripheral retinal lesions
- 5140 to 5150 look for peripheral retinal lesions
- 5160 to 5170 look for peripheral retinal lesions
- 5180 to 5190 look for peripheral retinal lesions
- 5200 to 5210 look for peripheral retinal lesions
- 5220 to 5230 look for peripheral retinal lesions
- 5240 to 5250 look for peripheral retinal lesions
- 5260 to 5270 look for peripheral retinal lesions
- 5280 to 5290 look for peripheral retinal lesions
- 5300 to 5310 look for peripheral retinal lesions
- 5320 to 5330 look for peripheral retinal lesions
- 5340 to 5350 look for peripheral retinal lesions
- 5360 to 5370 look for peripheral retinal lesions
- 5380 to 5390 look for peripheral retinal lesions
- 5400 to 5410 look for peripheral retinal lesions
- 5420 to 5430 look for peripheral retinal lesions
- 5440 to 5450 look for peripheral retinal lesions
- 5460 to 5470 look for peripheral retinal lesions
- 5480 to 5490 look for peripheral retinal lesions
- 5500 to 5510 look for peripheral retinal lesions
- 5520 to 5530 look for peripheral retinal lesions
- 5540 to 5550 look for peripheral retinal lesions
- 5560 to 5570 look for peripheral retinal lesions
- 5580 to 5590 look for peripheral retinal lesions
- 5600 to 5610 look for peripheral retinal lesions
- 5620 to 5630 look for peripheral retinal lesions
- 5640 to 5650 look for peripheral retinal lesions
- 5660 to 5670 look for peripheral retinal lesions
- 5680 to 5690 look for peripheral retinal lesions
- 5700 to 5710 look for peripheral retinal lesions
- 5720 to 5730 look for peripheral retinal lesions
- 5740 to 5750 look for peripheral retinal lesions
- 5760 to 5770 look for peripheral retinal lesions
- 5780 to 5790 look for peripheral retinal lesions
- 5800 to 5810 look for peripheral retinal lesions
- 5820 to 5830 look for peripheral retinal lesions
- 5840 to 5850 look for peripheral retinal lesions
- 5860 to 5870 look for peripheral retinal lesions
- 5880 to 5890 look for peripheral retinal lesions
- 5900 to 5910 look for peripheral retinal lesions
- 5920 to 5930 look for peripheral retinal lesions
- 5940 to 5950 look for peripheral retinal lesions
- 5960 to 5970 look for peripheral retinal lesions
- 5980 to 5990 look for peripheral retinal lesions
- 6000 to 6010 look for peripheral retinal lesions
- 6020 to 6030 look for peripheral retinal lesions
- 6040 to 6050 look for peripheral retinal lesions
- 6060 to 6070 look for peripheral retinal lesions
- 6080 to 6090 look for peripheral retinal lesions
- 6100 to 6110 look for peripheral retinal lesions
- 6120 to 6130 look for peripheral retinal lesions
- 6140 to 6150 look for peripheral retinal lesions
- 6160 to 6170 look for peripheral retinal lesions
- 6180 to 6190 look for peripheral retinal lesions
- 6200 to 6210 look for peripheral retinal lesions
- 6220 to 6230 look for peripheral retinal lesions
- 6240 to 6250 look for peripheral retinal lesions
- 6260 to 6270 look for peripheral retinal lesions
- 6280 to 6290 look for peripheral retinal lesions
- 6300 to 6310 look for peripheral retinal lesions
- 6320 to 6330 look for peripheral retinal lesions
- 6340 to 6350 look for peripheral retinal lesions
- 6360 to 6370 look for peripheral retinal lesions
- 6380 to 6390 look for peripheral retinal lesions
- 6400 to 6410 look for peripheral retinal lesions
- 6420 to 6430 look for peripheral retinal lesions
- 6440 to 6450 look for peripheral retinal lesions
- 6460 to 6470 look for peripheral retinal lesions
- 6480 to 6490 look for peripheral retinal lesions
- 6500 to 6510 look for peripheral retinal lesions
- 6520 to 6530 look for peripheral retinal lesions
- 6540 to 6550 look for peripheral retinal lesions
- 6560 to 6570 look for peripheral retinal lesions
- 6580 to 6590 look for peripheral retinal lesions
- 6600 to 6610 look for peripheral retinal lesions
- 6620 to 6630 look for peripheral retinal lesions
- 6640 to 6650 look for peripheral retinal lesions
- 6660 to 6670 look for peripheral retinal lesions
- 6680 to 6690 look for peripheral retinal lesions
- 6700 to 6710 look for peripheral retinal lesions
- 6720 to 6730 look for peripheral retinal lesions
- 6740 to 6750 look for peripheral retinal lesions
- 6760 to 6770 look for peripheral retinal lesions
- 6780 to 6790 look for peripheral retinal lesions
- 6800 to 6810 look for peripheral retinal lesions
- 6820 to 6830 look for peripheral retinal lesions
- 6840 to 6850 look for peripheral retinal lesions
- 6860 to 6870 look for peripheral retinal lesions
- 6880 to 6890 look for peripheral retinal lesions
- 6900 to 6910 look for peripheral retinal lesions
- 6920 to 6930 look for peripheral retinal lesions
- 6940 to 6950 look for peripheral retinal lesions
- 6960 to 6970 look for peripheral retinal lesions
- 6980 to 6990 look for peripheral retinal lesions
- 7000 to 7010 look for peripheral retinal lesions
- 7020 to 7030 look for peripheral retinal lesions
- 7040 to 7050 look for peripheral retinal lesions
- 7060 to 7070 look for peripheral retinal lesions
- 7080 to 7090 look for peripheral retinal lesions
- 7100 to 7110 look for peripheral retinal lesions
- 7120 to 7130 look for peripheral retinal lesions
- 7140 to 7150 look for peripheral retinal lesions
- 7160 to 7170 look for peripheral retinal lesions
- 7180 to 7190 look for peripheral retinal lesions
- 7200 to 7210 look for peripheral retinal lesions
- 7220 to 7230 look for peripheral retinal lesions
- 7240 to 7250 look for peripheral retinal lesions
- 7260 to 7270 look for peripheral retinal lesions
- 7280 to 7290 look for peripheral retinal lesions
- 7300 to 7310 look for peripheral retinal lesions
- 7320 to 7330 look for peripheral retinal lesions
- 7340 to 7350 look for peripheral retinal lesions
- 7360 to 7370 look for peripheral retinal lesions
- 7380 to 7390 look for peripheral retinal lesions
- 7400 to 7410 look for peripheral retinal lesions
- 7420 to 7430 look for peripheral retinal lesions
- 7440 to 7450 look for peripheral retinal lesions
- 7460 to 7470 look for peripheral retinal lesions
- 7480 to 7490 look for peripheral retinal lesions
- 7500 to 7510 look for peripheral retinal lesions
- 7520 to 7530 look for peripheral retinal lesions
- 7540 to 7550 look for peripheral retinal lesions
- 7560 to 7570 look for peripheral retinal lesions
- 7580 to 7590 look for peripheral retinal lesions
- 7600 to 7610 look for peripheral retinal lesions
- 7620 to 7630 look for peripheral retinal lesions
- 7640 to 7650 look for peripheral retinal lesions
- 7660 to 7670 look for peripheral retinal lesions
- 7680 to 7690 look for peripheral retinal lesions
- 7700 to 7710 look for peripheral retinal lesions</



BY JEROME SHERMAN, OD, AND SHERRY BASS, OD

YOU BE THE JUDGE

ER Referral Goes Awry

Can your correct diagnosis be ignored and result in blindness?

Ophthalmic clinicians should always be on the lookout for conditions that can quickly result in permanent loss of vision or even blindness. Early detection, diagnosis and appropriate treatment may prevent permanent vision loss or blindness in select cases.

On occasion, the ophthalmic clinician arrives at the correct diagnosis in a case, informs the patient about the urgency of the situation, writes a note (with the presumed diagnosis, tests required and suggested treatment plan) that the patient takes to the ER or ED. Shortly afterwards, the referring doctor speaks via phone with one or more of the ER doctors several times and answers all their questions. But somehow, the ER MD and the hospital consultants might arrive at an incorrect diagnosis. In such cases, it is not unusual for malpractice allegations to be instituted against all the doctors and consultants associated with the hospital and even the clinician who made the initial and correct diagnosis and referral.

Case

A 70-year-old woman presented to her optometrist, where she reported a history of an abscess of two teeth on the right side of her mouth that her dentist treated with antibiotics several days earlier. Coincidentally, she also had a history of temporal mandibular joint (TMJ) problems on the right side of her mouth. The patient believed that the dental issues were responsible for blurred vision in her

right eye and jaw pain. She described her vision in her right eye as “filmy.”

Her primary reason for the visit to the optometrist was to update her contact lens prescription and obtain new lenses. VA with a slightly modified prescription was measured at 20/20-OD and 20/20- OS. The external exam included pupillary testing that was normal as well as the absence of afferent pupil defect (APD). The slit lamp exam revealed mild cataracts OU with the right cataract slightly more progressed than the left. IOPs were recorded as 15mm Hg OU.

A dilated fundus examination was performed. The cup-to-disc ratio was noted as 0.35 in each eye. Mild vessel crossing changes were observed and attributed to high blood pressure that was being treated. Images of the fundus were also obtained with the Optomap. A zone nasal to the disc in the right eye was believed to be a congenital lesion. New contact lenses were prescribed, and the patient was told to report any changes in her vision.

Two days later, the patient saw her dentist for jaw pain, but the dentist was more concerned about a complaint of worsening vision as well. They called the optometrist, and a second vision exam was performed several hours later within this two-day period.

Now, the VA in the OD was not 20/20- but 20/200. Pupillary testing revealed that the right pupil was now fixed. IOPs were again 15mm Hg OU. Perimetry screening revealed a very

abnormal field OD. OCT revealed an elevated optic nerve head in the right eye only. Fundus images with the Optomap now revealed an abnormal optic nerve head with 360° swelling around the disc.

The optometrist concluded that the patient needed immediate treatment, told the patient about the seriousness of the condition and concluded that she must be seen and treated ASAP. The optometrist wrote the following note that the patient immediately took to the ER of a nearby major medical center:

... Sudden loss of vision OD, temple not sore to touch, OD pupil fixed, OD optic nerve head (ONH) swollen (edema) ... Please r/o (rule out) giant cell arteritis (GCA) ... Sed rate, C-reactive protein (CRP), consider imaging... please send report...

Making the Wrong Call

Shortly afterwards, the optometrist was on the phone with the ER MDs who asked several questions, such as, “Was a retinal detachment definitively ruled out?” The optometrist said yes and offered to make the fundus images available. The ER MD said that they would take their own photos.

The work-up following the patient’s presentation included ESR and CRP, both of which were borderline high. An ER MD and one of the ophthalmologists who consulted labeled the jaw pain as non-specific. Ophthalmologists and neuro-ophthalmologists were consulted, but in-person evaluations were not performed until the next morning. The diagnosis arrived upon was non-arteritic anterior ischemic optic neuropathy (NAION) and steroids were not prescribed, even though the optometrist’s note stated, “Please rule out GCA.”

About Drs.
Sherman
and Bass

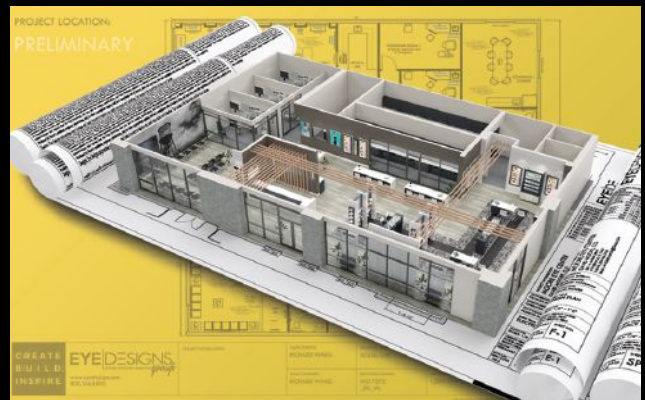Dr. Sherman is a Distinguished Teaching Professor at the SUNY State College of Optometry and editor-in-chief of *Retina Revealed* at www.retinarevealed.com. During his 53 years at SUNY, Dr. Sherman has published about 750 various manuscripts. He has also served as an expert witness in 400 malpractice cases, approximately equally split between plaintiff and defendant. Dr. Sherman has received support for *Retina Revealed* from Carl Zeiss Meditec, MacuHealth and Konan. **Dr. Bass** is a Distinguished Teaching Professor at the SUNY College of Optometry and is an attending in the Retina Clinic of the University Eye Center. She has served as an expert witness in a significant number of malpractice cases, the majority in support of the defendant. She serves as a consultant for ProQR Therapeutics.

Your Complete Resource.

MERCHANDISING · SPACE PLANNING · DESIGN · DESIGN



DRY EYE + MED SPA



ARCHITECTURE · SPACE PLANNING · FRAME DISPLAYS · DISPENSING FURNITURE



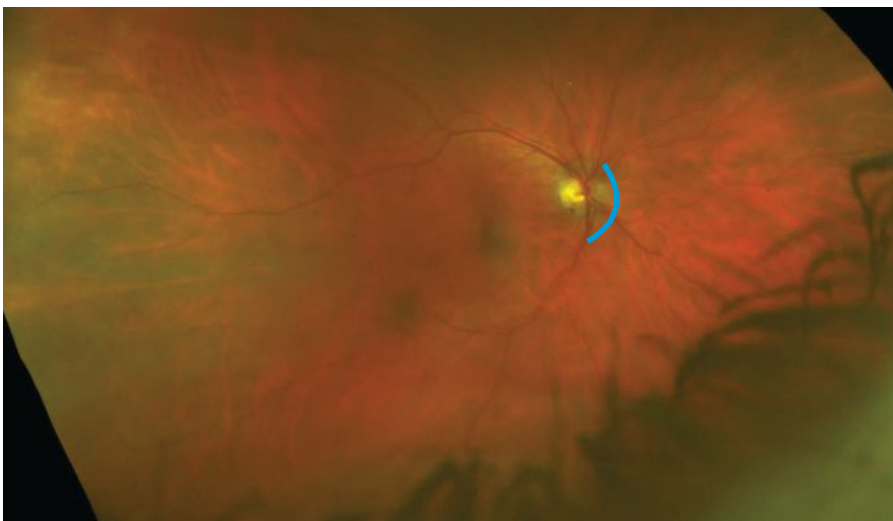
DESIGN STARTS HERE!

AAO BOOTH 6354

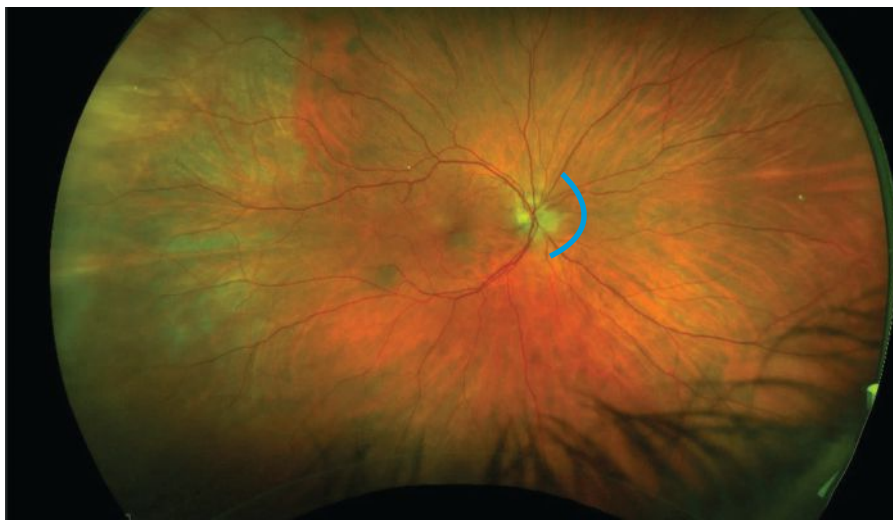EYEDESIGNS[®]
CUSTOM INTERIORS + FURNITURE *group*

800-346-8890 · www.eyedesigns.com

EXAM LANES · LIGHTING · SEATING · OPTICAL ART · & MORE



Ultra-widefield image OD taken about five years prior to recent episode. The parapapillary disc zone from about one to six o'clock appears blurred. Subtle medullated nerve fibers?



Ultra-widefield image OD taken two days prior to referral to ER and with a different ultra-widefield device than the previous image. The entire image has far greater clarity and detail than the image taken five years earlier. Note the difference in blood vessels. The disc zone from about two to six o'clock is blurred. Is this just a better image of the same abnormality imaged five years earlier, or is it an early indication of optic neuropathy?

Several days later, the patient was evaluated at another major hospital after further loss of vision. This exam resulted in IV steroids to be immediately initiated, and then a temporal artery biopsy was performed that proved to be positive. The diagnosis arrived upon was GCA, an inflammatory disorder that often responds to steroids if administered in a timely fashion. When not treated in a timely manner, loss of vision in the fellow eye is quite common. The patient progressed shortly to no light perception OU, and she remains totally blind.

Not surprisingly, the hospital and all the clinicians involved with any aspect of the care were sued.

You Be the Judge

- Should everyone be held culpable of malpractice in this case of total blindness?
- Did the patient have GCA at the time of the first visit to the OD?
- Based upon symptoms and clinical findings, should the OD have made the urgent referral to the ER two days earlier?

- If the referring doctor were an ophthalmologist and not an optometrist, would the ER MDs have diagnosed GCA and initiated IV steroids immediately?
- Is the standard of care in such a case to begin steroids even before the results of the temporal artery biopsy are available?
- If the insurance carrier for the hospital and the MDs settled the case for several million dollars well prior to trial, would the case against the OD then be dropped?

Comments and Our Opinion

I (JS) was requested to review all the records and about a dozen depositions of all the doctors involved. My conclusion was that the OD met the existing standard of care and even went beyond the minimally acceptable standard of care on the second visit when the OD composed a comprehensive note that should have resulted in a near immediate correct diagnosis and timely IV steroids by the ER MDs. The OD was also available via telephone to answer questions posed by the ER MDs.

Two other OD experts reached a different conclusion and stated in several lengthy written reports that the OD should have diagnosed GCA and immediately refer the patient on the first visit because of the chief complaints and the abnormal fundus as documented with the Optos images.

I responded that the ER MDs and consultants got it wrong even with a detailed note from the optometrist documenting the drop in VA to 20/200 OD from 20/20, and a fixed pupil OD that was normal two days earlier. Would

NOTE: This article is one of a series based on actual lawsuits in which the author served as an expert witness or rendered an expert opinion. These cases are factual, but some details have been altered to preserve confidentiality. The article represents the authors' opinion of acceptable standards of care and do not give legal or medical advice. Laws, standards and the outcome of cases can vary from place to place. Others' opinions may differ; we welcome yours.

they have arrived at the correct diagnosis two days earlier? Quite unlikely!

We will never know with absolute certainty whether or not GCA was present two days earlier. The jaw pain on the first visit to the OD was believed by the patient and the optometrist to be due to the recent tooth abscess and perhaps also to the long-standing TMJ. (The ER doctors noted two days later that the jaw pain was “not specific.”) The 20/20-VA OD on the first visit and the absence of an APD and a normal disc appearance (as interpreted by the optometrist) certainly did not support a diagnosis of GCA.

The nasal disc zone was interpreted by the optometrist as a congenital lesion, perhaps a form of medullated nerve fibers. Images taken several years earlier were far inferior but also appeared to document a similar abnormal zone. This nasal disc finding years earlier could not be a papillitis due to GCA.

Outcome

The case against the hospital and its many personnel and consultants was quite strong, and the insurance companies involved settled quickly for a total amount of several million dollars rather than risk going to trial. Surprisingly, the case against the OD continued for about another year. The two key defense attorneys and I believed the case could have been won at trial. The representatives of the insurance company for the OD decided to settle rather than risk a culpable verdict and a very large jury award at trial. A jury is generally quite sympathetic to a blind patient. This settlement approached a million dollars.

It is generally agreed that most patients with suspected GCA should be started on oral prednisone 40mg/day to 60mg/day until the results of a temporal artery biopsy become available.¹ We feel the frustration for the OD who did the right thing and for the patient who must now adapt to being totally blind for the rest of her life. ■

1. Seetharaman M, Albertini JG, Paget SA, et al. Giant cell arteritis (temporal arteritis) treatment & management. Medscape. [emedicine.medscape.com/article/332483-treatment?form=fpf#d1](https://www.medscape.com/article/332483-treatment?form=fpf#d1). Last updated July 7, 2022. Accessed August 21, 2023.

Medscape **LIVE!**

LIVE COPE*

EARLY BIRD & COMBINED REGISTRATION SPECIALS!
See websites for details

REGISTRATION OPEN!

DECEMBER 8–10, 2023
CARLSBAD, CALIFORNIA

OMNI LA COSTA, 2100 COSTA DEL MAR ROAD

West Coast Optometric Glaucoma Symposium and Retina Update 2023 are co-located this year.

We encourage you to participate in both symposia!



WEST COAST OPTOMETRIC GLAUCOMA SYMPOSIUM



DECEMBER 8–9, 2023

Program Co-chairs:
Murray Fingeret, OD, FAAO
Robert N. Weinreb, MD

Earn up to **12 LIVE COPE credits***

To register, scan the QR code or visit:
www.reviewedu.com/wcogs

THE OPTOMETRIC RETINA SOCIETY AND REVIEW EDUCATION GROUP PRESENT

RETINAUPDATE2023



DECEMBER 9–10, 2023

Program Co-chairs:
Mohammad Rafieetary, OD, FAAO
Steven Ferrucci, OD, FAAO

Earn up to **11 LIVE COPE credits***

To register, scan the QR code or visit:
www.reviewedu.com/orsretupdate

Earn up to **23 COPE credits***



Postgraduate Institute
for Medicine

*COPE Accreditation Pending

Retina Update 2023 is partially supported by independent educational grants from Regeneron.

REVIEW
Education GROUP

OPTOMETRISTS READY TO STEP UP TO SUBSPECIALIZATION

New survey finds enthusiasm for recognizing ODs who wish to concentrate on particular aspects of care within the broader swath of the profession's services.

BY JACK PERSICO
EDITOR-IN-CHIEF

A majority of optometrists are content to describe themselves as primary eyecare providers, but over one quarter feel they also possess “subspecialty skills” in one or more specific niches—and they would like such capabilities to be recognized by others, too. Doing so would bolster referrals to ODs and could allow greater integration of optometry into the wider healthcare infrastructure. Enthusiasm for subspecialization is strongest among the younger members of the profession, but even most senior ODs see it as valuable, while still expressing some wariness over an as-yet-undefined credentialing process. Still, ODs seem ready to hash out the details.

Those are some of the key findings from a new survey on optometric sentiment toward optometric subspecialization. Conducted by Jobson Optical Research in August 2023, this survey received input from 506 practicing ODs and 95 optometry students.

The research is being released during this year's Academy of Optometry annual meeting in hopes of stimulating discussion among various stakeholders. The full report will be available for download from Jobson Optical

What type of optometrist are you?

Respondents: ODs only

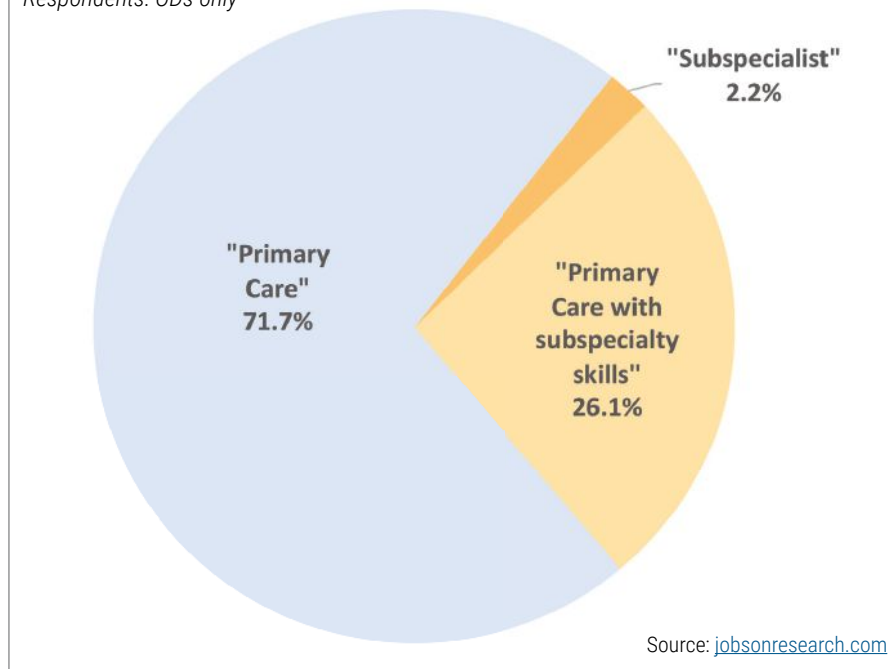


Fig. 1. Primary eyecare remains the chief responsibility of optometrists, but over one-quarter say they possess an additional layer of skills in one or more specific disciplines.

Research. Below, we share highlights of some of the major trends and discuss how they might inform a profession-wide discussion about efforts to formally credential ODs in various subspecialties.

“It would reassure patients that they are seeing a provider who understands

their individual condition thoroughly,” wrote an optometrist from Cincinnati in response to the survey. “It would also serve as a way for eyecare providers to refer patients to each other in a meaningful and more purposeful way if we knew each other’s clinical interests.”

Subspecialties Taking Shape

Among ODs who responded to the survey (*i.e.*, excluding students), 41.5% have been practicing for over 20 years and 62.7% are in private practice settings. As *Figure 1* shows, primary eye care is the domain of virtually all respondents but, importantly, 26.1% say they also have additional expertise above and beyond that level and 2.2% call themselves subspecialists outright.

In the survey, 86% of those who lay claim to subspecialty skills point toward the clinical experience they developed over the span of their careers (*Figure 2*). Peer-to-peer training via continuing education was called out by 69.9% and optometric residency training came in at a healthy 36.4% of respondents.

Still, formalized processes to define, train and credential subspecialists are needed for any such effort to take off.

“Subspecialization permeates the entire healthcare system,” says David Heath, OD, president of SUNY College of Optometry and a longtime proponent of subspecialization within optometry. “Pretty much every doctoral-level health profession has subspecialties and there are guidelines, rules and paradigms that are applied. As subspecialties emerge in the optometric profession, we should be in compliance with reasonable and standard structures within the healthcare delivery system.”

Lack of consistent nomenclature is one problem. “What defines a pediatric optometrist, for instance?” asks Dr. Heath. “Is that centered on developmental issues or more medical ones?”

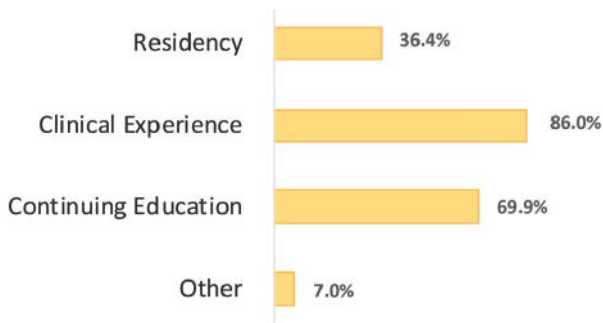
Survey respondents cited a wide range of areas they see as their strengths (*Figure 2*). Some map onto ophthalmology subspecialization categories like glaucoma and retina, others comprise uniquely optometric services (*e.g.*, contact lenses, vision therapy, low vision) and at least one—“ocular disease”—seems an artifact of a previous generation’s effort to evolve optometric care. Educational curricula and advanced training or experience

Interested in obtaining the full report?
Check jobsonresearch.com for details.

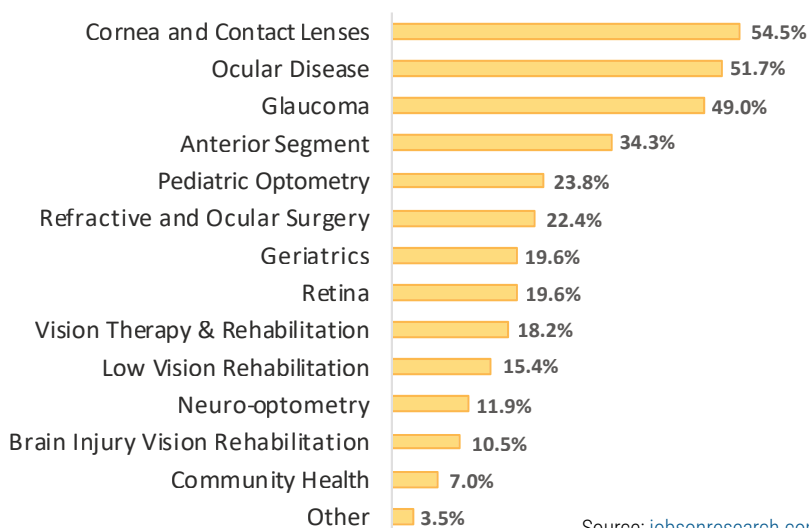
If “Subspecialist” or “Primary Care with subspecialty skills”:

Respondents: ODs only

How did you acquire your specialized skills? (Check all that apply)



Which subspecialty areas? (Check all that apply)



Source: jobsonresearch.com

Fig. 2. Through a combination of residency training, CE and ample clinical experience, optometrists feel they have developed specialized skills, chiefly in optometric strongholds.

in a focused medical environment that emphasized ocular disease broadened optometry’s mandate beyond refraction and corrective lenses years ago. That may be a point of pride for many ODs—51.7% point to their skills in ocular disease management, second only to contact lenses—but its clinical footprint is too broad to claim as a subspecialty.

“Having a common understanding of what a subspecialty is—which we don’t currently have—can only make referrals and collaboration among optometrists all that much stronger and better,” says Dr. Heath, “and it’s something that ODs themselves are saying they would embrace.”

That’s borne out by the survey data. Even though only 28.3% of survey respondents consider their own skills to include elements of specialized care, a healthy majority do believe there should be subspecialties within optometry and that, moreover, there already are. *Figure 3* shows the sentiment on these questions by age bracket. Current students and those ODs who have practiced five years or less are most bullish on both matters: 82.4% say there should be optometric subspecialties while 85.6% say these already exist.

“I believe a formal credential would allow you to state your specialty with defined support from somewhere,” wrote

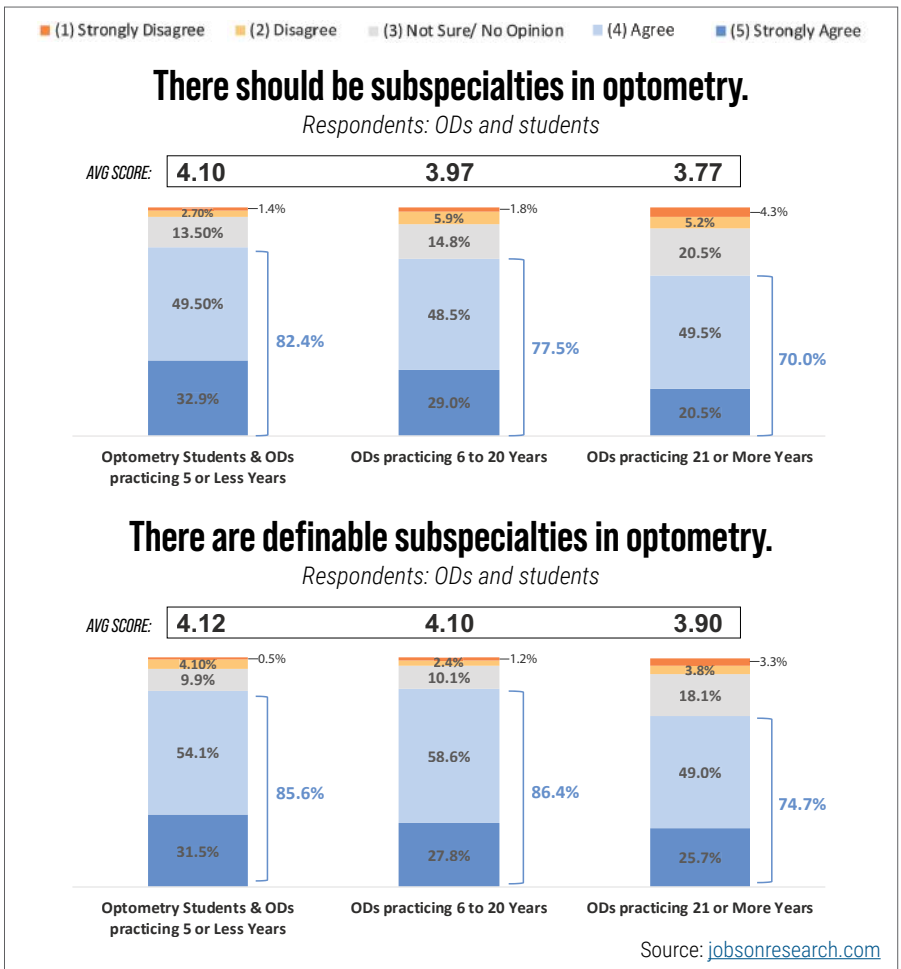


Fig. 3. Respondents endorsed the idea of optometric subspecialties with healthy majorities.

a student at Pacific University College of Optometry. “It’s not just saying, ‘I’m really good at this’—it proves that you

have met a level of standard. It would feel better and easier to promote yourself and your specialty.”

Optometrists practicing 21 or more years were a bit more measured in their support but still endorsed both ideas, with 70.0% and 74.7% expressing agreement, respectively. “It would increase patient access for those who are having long waits for ophthalmology specialists,” an OD from Chicago suggested. “At the same time, optometrists would have closer partnerships with PCPs.”

OD-to-OD Networks

The topic of intraprofessional referrals is another area where formal subspecialization would be advantageous. Although the survey found that 70.8% of optometrists already refer to other ODs in some fashion (Figure 4), many cited a desire for greater clarity about who’s on the other end of that relationship.

“I think formal credentialing coupled with a directory of said specialty would make it much easier to refer to colleagues for these specialties,” another survey respondent pointed out. “As it stands, everything seems to be by word of mouth.”

Indeed, 82.4% of respondents said they would be more inclined to refer to another optometrist if that individual had formal training validated by a community of their peers (Figure 5).

Some areas are quite far along in the process. “Low vision has already defined itself,” explains Dr. Heath. “That community has a set of approximately 20

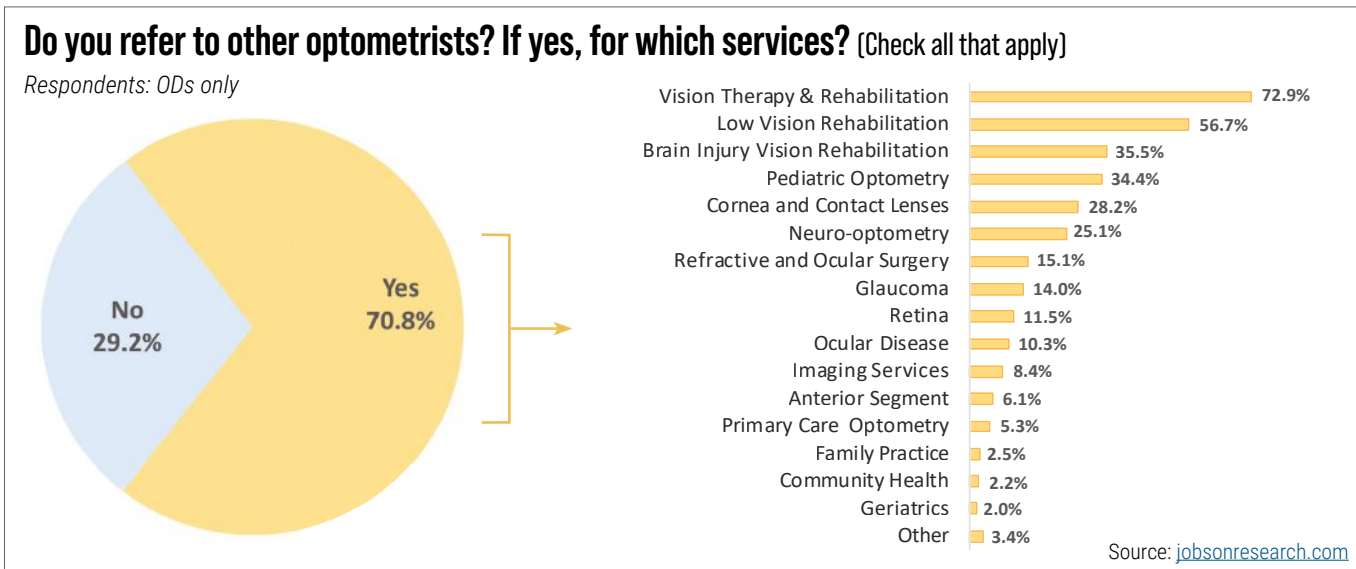
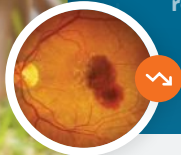

Fig. 4. OD-to-OD referral is surprisingly robust among survey respondents and heavily concentrated on traditional areas of optometric expertise.

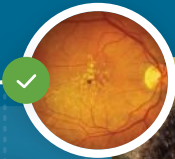Prevent AMD Vision Loss with Digital Healthcare



IRIS REGISTRY

20/83 VA

Average at wet AMD diagnosis according to IRIS Registry real-world data¹



ALOFT STUDY

≥20/40 VA

Average at wet AMD diagnosis with ForeseeHome²



ForeseeHOME™
AMD Monitoring Program

Early Detection Helps Preserve Vision

ForeseeHome is a **remote monitoring** program for at-risk dry AMD patients that helps **detect wet AMD earlier** and alerts you of changes.


Remote patient monitoring leads to better outcomes and stronger optometric practices

- ✓ FDA Cleared
- ✓ Medicare Covered

- Plug and play digital health solution for your patients
- Solidify long-term relationships with your patients
- No cost to your practice
- Strengthen your referral relationships with qualified wet AMD referrals

The Key to Successful Home Monitoring

NOTAL VISION MONITORING CENTER



Engagement & Education

Benefits Verification & Authorization

Continuous Monitoring



Practice Workflow Implementation

Remote Patient Management

Vision Alert Management



ForeseeHome is a registered trademark, and the ForeseeHome AMD Monitoring Program and logo and the Notal Vision logo are trademarks of Notal Vision. © 2023 Notal Vision, Inc. All rights reserved.

References: 1. Rao P et al. *Ophthalmology*. 2018;125(4):522-528. 2. Mathai M, Reddy S, Elman MJ, Garfinkel RA, Ladd B, Wagner A, Sanborn GE, Jacobs J, Busquets M, Chew EY; ALOFT study group. Analysis of the Long-term visual Outcomes of ForeseeHome Remote Telemonitoring - The ALOFT study. *Ophthalmology Retina*. 2022;6:922-929.

See website for FDA Indication for Use.

SM-169.3



GET STARTED TODAY

1-855-600-3112

Mon-Fri, 8 AM to 6 PM EST

notalvision.info/revopt

advanced competency statements that really identify the knowledge and skills required. Other areas we may consider discrete disciplines within optometry still need to undergo a process of establishing broad-based community agreement on what comprises their core competencies," Dr. Heath notes.

A Group Effort

Dr. Heath believes the momentum, and most of the heavy lifting, will happen at the level of the societies. "In every health profession, the formalization of subspecialties occurred through grassroots activities," explains Dr. Heath. "You really need the community that views themselves as either subspecialists or primary care docs with

subspecialty skills to be developing the advanced competencies that define the area. They can't be developed from above. It has to come from the bottom up."

Professional organizations ranging from ASCO and the Academy down to the many area-specific societies that help foster subspecialty expertise can

play a role in moving the conversation forward, he suggests. Some may be looking at ways to credential their members, he says, while many others may simply want to get together to talk about their shared interests and expertise. "But any credentialing process has to be built atop the cumulative knowledge of those

practitioners operating at the ground level," Dr. Heath emphasizes.

Membership in professional societies that prioritize advanced training provides a chance for mentoring and greater access to expertise. Nearly one quarter of respondents (24.4%) with such an affiliation say they belong to a Special Interest Group or Section of the Academy of Optometry (Figure 6). Among single-discipline organizations, the most populous in the survey seem to be the College of Optometrists in Vision Development (COVD) at 23.3% and the Scleral Lens Education Society, which garnered a 22.1% response. However, it's worth noting that specialty organization membership

as a whole only represented 17% of the entire sample studied.

Devil's in the Details

If there's one area where optometrists—established ones in particular—may express some trepidation, it's in the prospects for credentialing.

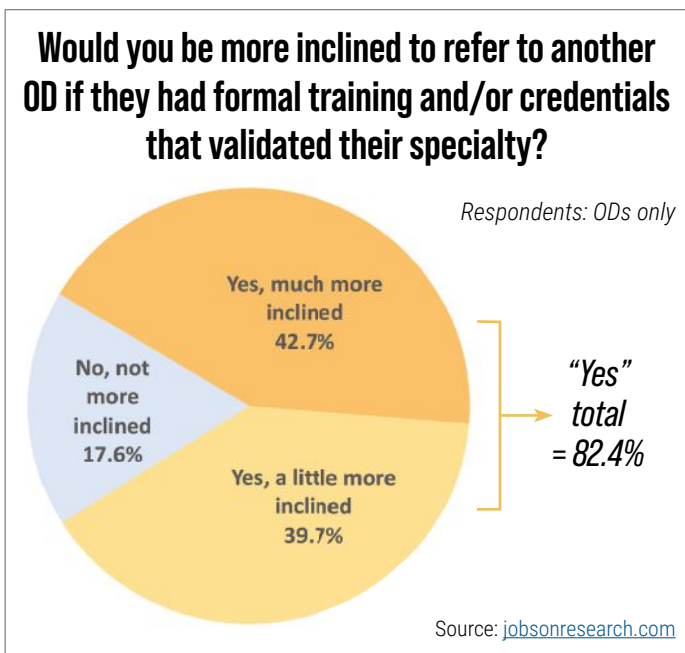


Fig. 5. "There should be less stigma about OD-to-OD referrals," wrote an OD from Minnesota. "Subspecialization would allow a practitioner to become phenomenal in one area and provide the absolute best care possible to each patient."

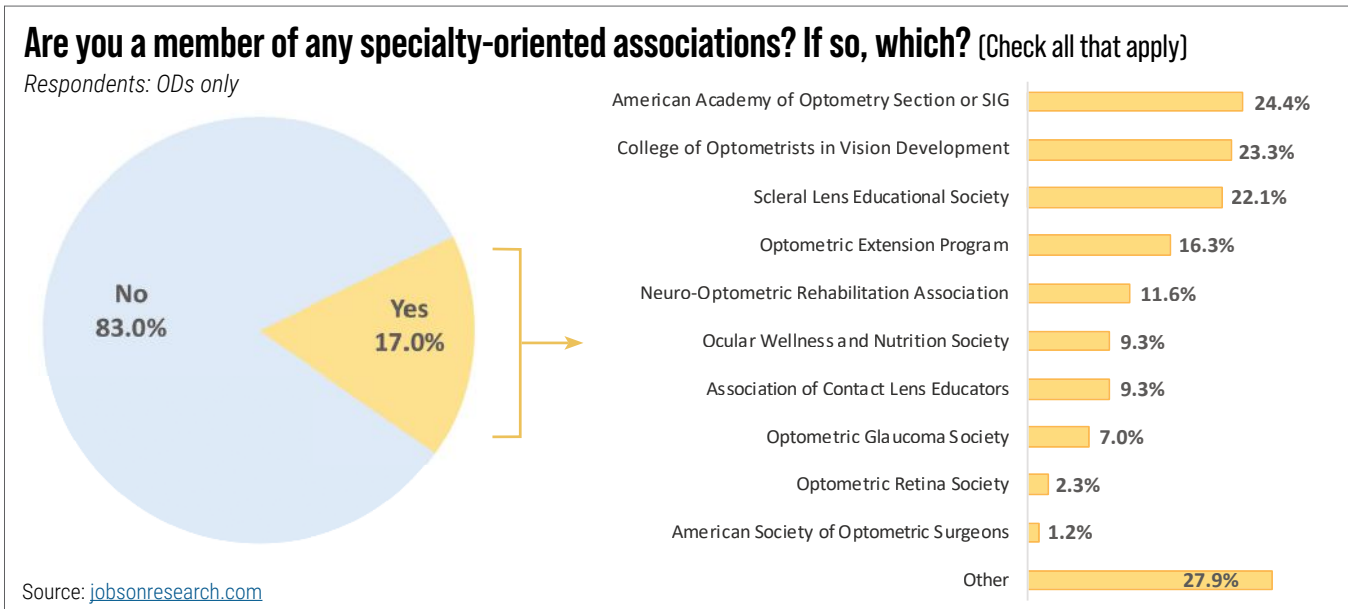
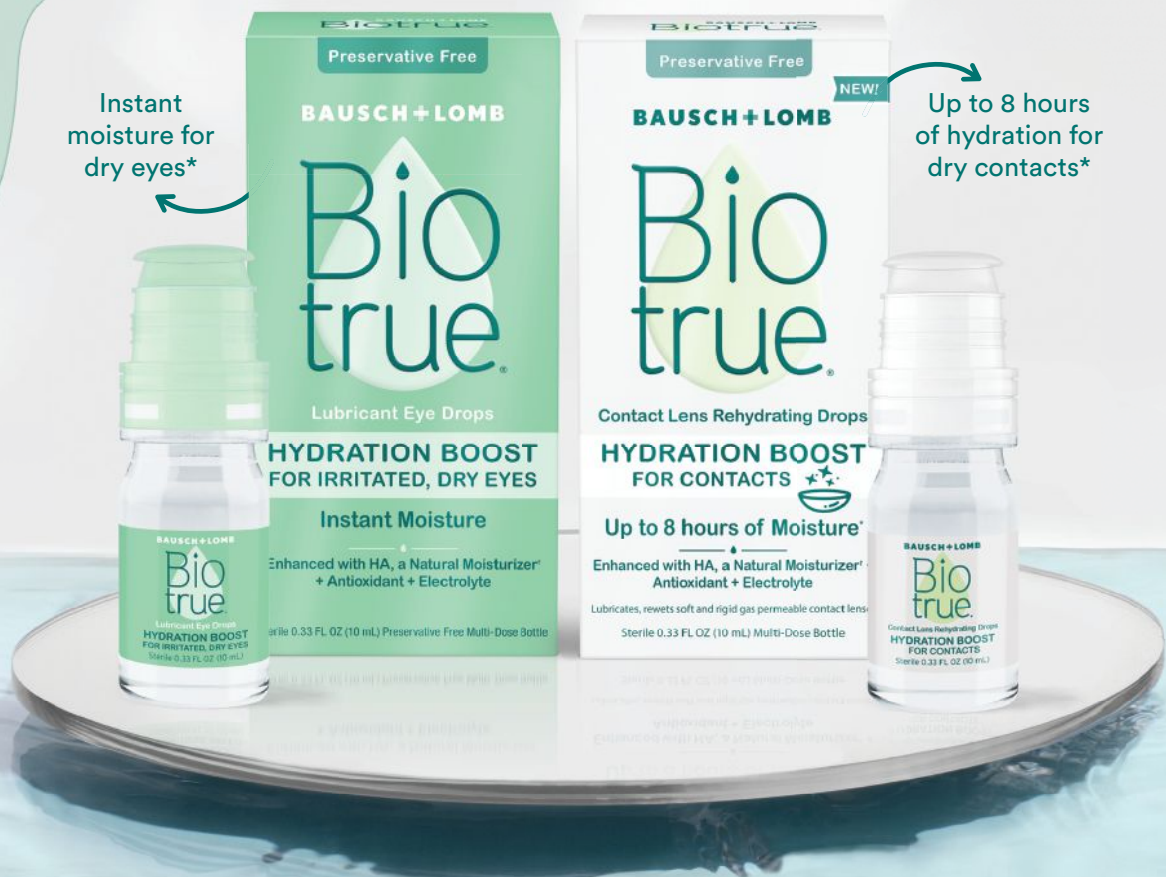

Fig. 6. A relatively easy way to begin developing specialized expertise is through the mentorship to be found in professional societies. Only about one-sixth of survey respondents reported having taken such a step, however.

Bio-inspired hydration for dry eyes and contacts



Preservative free



pH balanced to match healthy tears



Hyaluronan (HA), a natural moisturizer†



Enhanced with an antioxidant and an electrolyte‡

Recommend Bio true® Drops to your patients today

*Based on a laboratory study.

†Sourced from a large scale natural fermentation process.

‡Antioxidant protects HA from free radicals.

©2023 Bausch + Lomb. BDB.0071.USA.23

BAUSCH + LOMB

Figure 7 shows that a slim majority of 51.9% of ODs with 21 years or more under their belts agree there should be a definable process for recognizing optometric subspecialists. Younger optometric students and students were a bit more open to the idea, however (61.7% agreed).

“When we ask whether there should be a formal process of credentialing,” says Dr. Heath, “there’s a tendency to quickly jump to concerns about undergoing more exams and possibly more exclusionary behaviors that could ensue.” Older ODs who remember the acrimony over board certification are in no mood for a repeat performance.

“I’m an evolutionist—let’s take small steps,” offers Dr. Heath. “There’s no reason to jump to a model another profession may have developed over a span of decades. Allowing the organic development of subspecialties is really critical.”

Again, it’s already well underway, notes Dr. Heath. “COVID has a board certification credential for their fellows, and the diplomate processes of the Academy are relatively sophisticated and involve multiple kinds of assessment. Optometry residency education, much like in all other health professions, requires a demonstration of advanced competencies.” As well, VA optometrists use the Advanced Competence in Medical Optometry exam as a way to achieve formal recognition, and the American Board

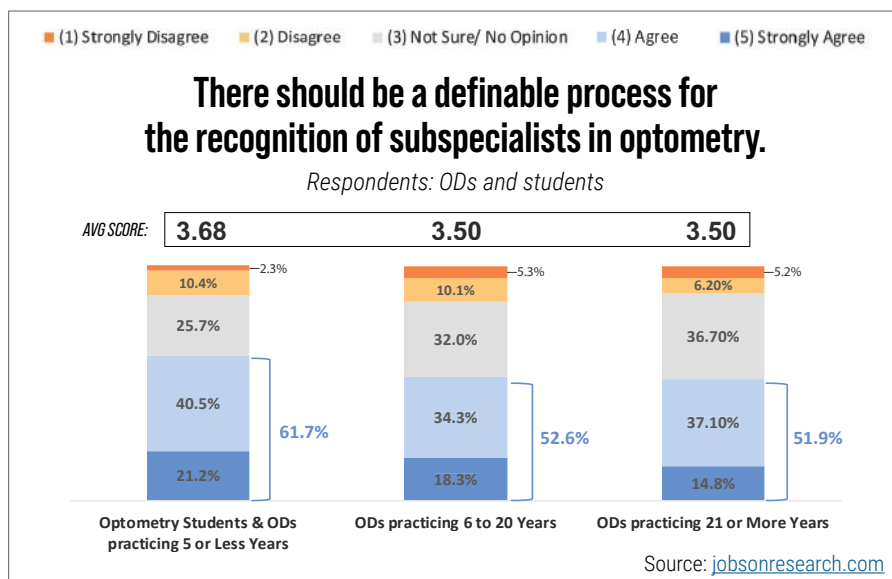


Fig. 7. Optometrists with an established patient base, reputation and referral network may worry about as-yet-unknown mechanisms to codify optometric subspecialties.

of Optometry is piloting a Certificate of Added Qualification over and above one’s status as board certified.

“What we can do as a profession is highlight the principles and guidelines that underpin subspecialties and ensure that development is in concert with health care as a whole,” says Dr. Heath.

Value Added

Encouragingly, 70% of ODs and 92% of students said they would welcome the chance to earn a subspecialty credential (Figure 8). This is a surprisingly can-do

attitude when you recall that just 28.3% said they consider themselves to be currently skilled in something that might be called a subspecialty.

As always, students will be the agents of change. “It would add value to one’s expertise on the topic as well as inspire patient confidence in your skills and education,” summed up a current Nova Southeastern student. At the same time, noted a Canadian optometrist in the survey, “optometry is a profession of generality, and that really should not be lost.” ■

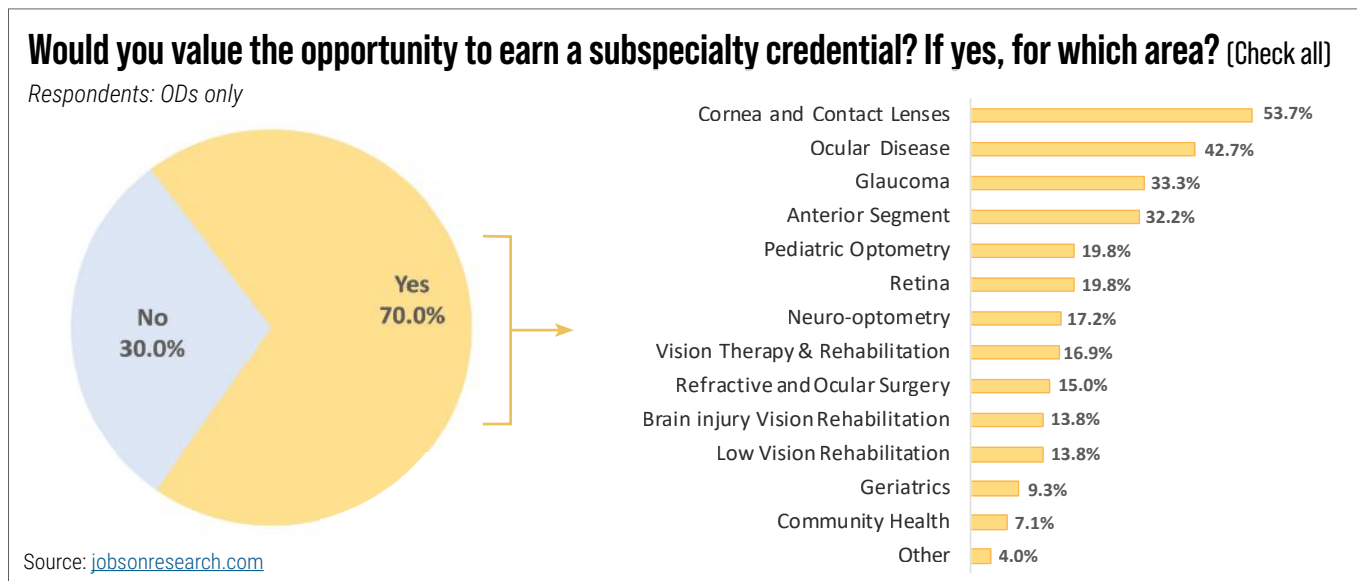


Fig. 8. A robust 70% of ODs say they appreciate the opportunity to pursue a credential of some sort, especially in specialty contact lenses.



Changing SIGHT Overnight.

Overnight Orthokeratology

1.

NCLE certified consultation experts to guide you through the entire fitting process

2.

Highly adjustable parameters with an online lens design calculator

3.

Dynamic Edge Profile™ delivers remarkable comfort

4.

Diameter & optic zone options for myopia management patients, along with standard Orthokeratology patients

Scan to learn more about REMLens®.



X-CEL
SPECIALTY CONTACTS

800.241.9312
xcelspecialtycontacts.com/remlens

Vision Shaping
Treatment VST®

MADE EXCLUSIVELY WITH
BOSTON® EQUALENS® II
LENS MATERIALS

FOLLOW THIS PRACTICAL WORKUP FOR ACQUIRED PTOSIS

The condition can arise for a multitude of reasons. Learn how to differentiate, diagnose and treat them.



ELIZABETH MARUNDE, OD
ELKINS PARK, PA

Ptosis typically refers only to drooping of the upper eyelid, with drooping of the lower eyelid termed reverse ptosis. There are two muscles that assist in the elevation of the eyelid: the levator palpebrae superioris (LPS) and the superior tarsal muscle, also known as Muller’s muscle (MM). When these muscles are not functioning properly, it can result in a droopy, or ptotic eyelid. The primary muscle responsible for elevation is the LPS, which when damage occurs, results in a more prominent ptosis. In contrast, when the MM is damaged, it results in a more subtle ptosis. There are four categories of ptosis: aponeurotic, myogenic, neurogenic and mechanical. Through a thorough case history and examination, eyecare providers can differentiate between these categories and etiologies of the condition.

History Questions

Case history is an important tool for eyecare providers to differentiate

TABLE 1. CASE HISTORY QUESTIONS AND THEIR CORRELATION WITH SPECIFIC DIAGNOSES

History Question	Top Differential Diagnosis
How long has the ptosis been present? Ask to see old photos.	Since birth: likely congenital Acquired: keep digging
Is the ptosis constant, intermittent or variable?	Variable or intermittent: myasthenia gravis Constant: nonspecific
Any family history of ptosis?	Yes: chronic progressive external ophthalmoplegia (CPEO)
Any associated diplopia?	Yes: myasthenia gravis, CPEO, cranial nerve III palsy
Any associated pupil abnormality?	Yes: cranial nerve III palsy, Horner’s syndrome
Any recent trauma and/or surgery?	Yes: mechanical or traumatic ptosis
Any autoimmune diseases?	Yes: myasthenia gravis
Any difficulty breathing or swallowing?	Yes: myasthenia gravis
Any history of vasculopathic diseases, including diabetes, hypertension or hyperlipidemia?	Yes: cranial nerve III palsy
Any recent botulinum toxin type A injections of the forehead?	Yes with positive correlation: myogenic ptosis secondary to botulinum toxin
Headaches?	Yes: Horner’s syndrome, cranial nerve III palsy

between various types and etiologies of ptosis (*Table 1*). First, ask the patient if they have noticed any change in the appearance of their eyelids, and if so, when it was first noted. If they cannot give a specific timeline, old photos can be used to determine the longevity of the ptosis. Ask the patient if

there is any family history of ptosis or other eye conditions and inquire if any specific event that may have resulted in ptosis has occurred, such as any ocular trauma, surgery, contact lens use or botulinum toxin type A injections in and around the forehead/ocular region.^{1,2} The next step is to investigate

About the author

Dr. Marunde completed her doctorate of optometry at University of the Incarnate Word Rosenberg School of Optometry in San Antonio, Texas. She completed a two-year residency in neuro-ophthalmic disease at Salus University, Pennsylvania College of Optometry, where she is currently an instructor.

TABLE 2. NORMATIVE VALUES FOR EYELID MEASUREMENTS^{4,12,38-40}

Examination Technique	Normative Values
Palpebral aperture	~10mm
Lid crease	Men: 7mm to 8mm Women: 8mm to 10mm
Levator function	Poor: 0mm to 4mm Fair: 5mm to 9mm Good: 9mm to 11mm Excellent: >12mm
Exophthalmometry	Caucasian: 12mm to 21mm African American: 12mm to 24mm Difference \geq 2mm is significant
Margin-reflex distance ¹	4mm to 5mm
Fatigue/ice-pack testing	A difference \geq 2mm is considered positive

the variability of the ptosis. Ask if there is a time of day when the ptosis is more noticeable or if worse when tired.

There are several diagnoses where ptosis is a main clinical finding. Conditions such as myasthenia gravis (MG), cranial nerve III (CN III) palsies, chronic progressive external ophthalmoplegia (CPEO) and Horner's syndrome (HS) all may present with ptosis. Given the possible etiologies, clinicians should inquire about other ocular complaints, including diplopia and anisocoria. Difficulty breathing or swallowing, headaches and neck pain should also be investigated. Due to possible systemically associated conditions, ask about history of autoimmune diseases, vasculopathic diseases (diabe-

tes, hypertension, hyperlipidemia) and other medical conditions.¹

Examination Elements

A thorough eye exam in conjunction with a detailed case history can help pinpoint a working diagnosis. While asking case history questions, take note of the patient's appearance. Observe any asymmetry of their eyelids or facial structure. Patients may not recognize a subtle eyelid droop; eyecare providers may be the first to notice the ptosis. It is necessary to determine if the abnormal presentation is the result of an enlarged vs. a reduced palpebral aperture. Assess for scars, abnormal blinking, gross lid lesions and eyelid edema, which may point to clues regarding eyelid symmetry.

Additional examination elements can also be quite helpful when assessing for eyelid asymmetry. Exophthalmometry should be conducted to evaluate for pseudoptosis, which is a test measuring how the globe is sitting in the orbit. Both proptosis and enophthalmos may present with asymmetric palpebral apertures and facial appearance.³ Careful extraocular muscle (EOM) motilities should be performed with thorough cover testing in multiple positions of gaze. Variability may be uncovered with multiple cover tests and EOM motility evaluations. Measuring pupil sizes in bright and dim illumination is also helpful in differentiating between the common causes of ptosis.

Patients with true ptosis rather than pseudoptosis may engage their frontalis muscles and tilt their head back to compensate for eyelid droop.³ Eyelid measurements are most accurately obtained when the elevator muscles are isolated. Isolation is achieved by placing a hand on the forehead, neutralizing the frontalis muscle. Palpebral apertures, lid crease, margin-reflex distance and levator function measurements should be performed on every patient with ptosis (Figure 1).

Margin-reflex distance 1 is performed with the patient looking at a transilluminator while the doctor measures the distance between the upper lid margin and corneal reflex.⁴ Additional eyelid evaluations can be performed, such as fatigue/ice-pack testing, orbicularis oculi strength and assessing for a curtain sign

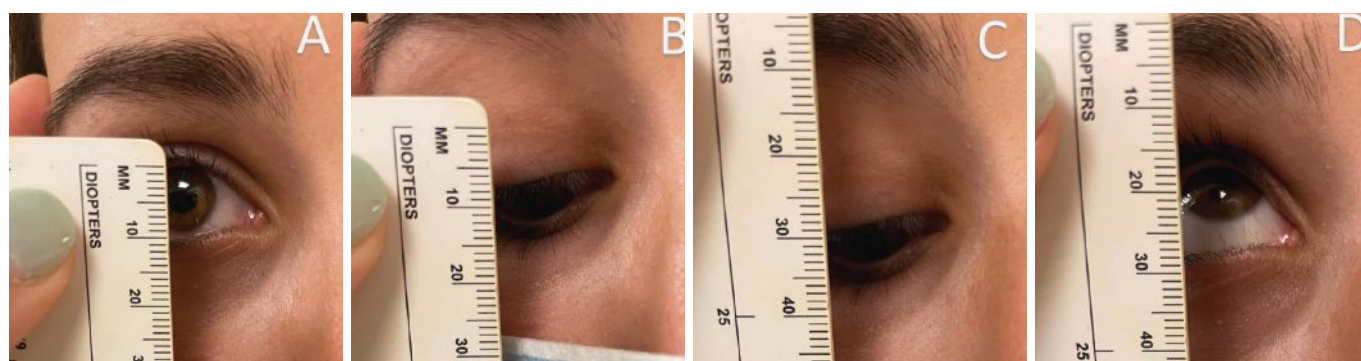


Fig. 1. Image A represents measuring palpebral aperture. In this instance, the palpebral aperture is 10mm. Image B represents measuring lid crease; there may be more than one lid crease present and all should be measured. The lid crease here is 7mm. Images C and D represent measuring levator function. Levator function is measured by the difference between down and up gazes. Here, the levator function is 14mm.

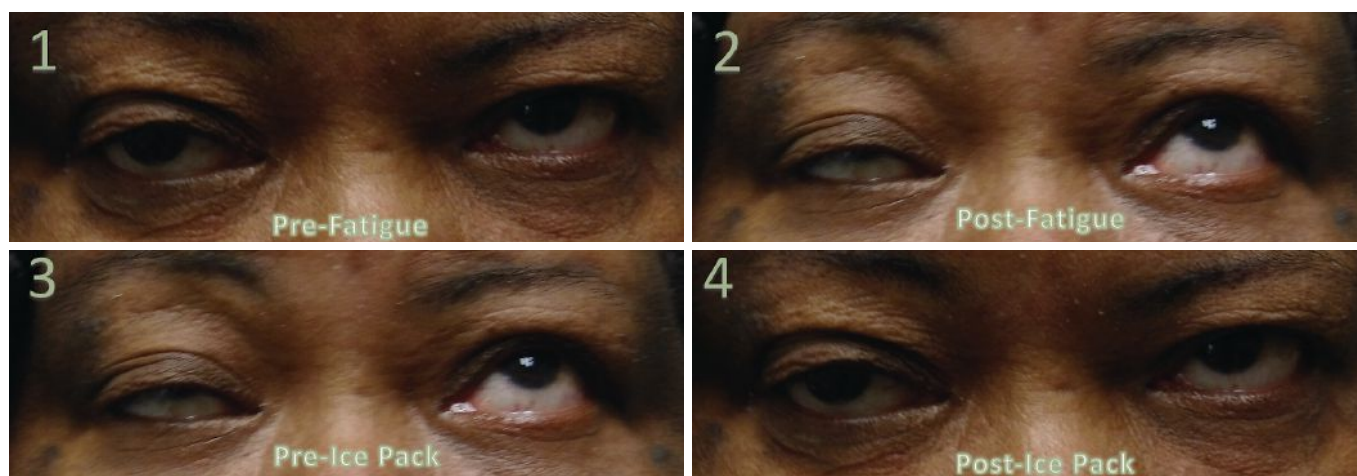


Fig. 2. These images represent a positive fatigue and ice pack test. Image 1 was taken prior to the fatigue testing. Image 2 was taken after two minutes of sustained up gaze. There was >2mm difference in the right palpebral aperture, indicating a positive test. Note the positive test occurred while up gaze was sustained. Image 3 depicts after fatigue testing, but prior to ice pack testing. Image 4 is after ice pack testing and is a positive result, as there is >2mm difference in the right palpebral aperture.

(Table 2). A positive curtain is evidenced by additional drooping of the fellow eyelid when manually lifting the more ptotic eyelid.⁴ After testing the function of eyelids, a careful ocular health examination should also be performed on them.

Isolated Ptosis

There are many different reasons why ptosis manifests in a patient. The types may require distinct subsequent follow-up care or management, thus it is important to differentiate between the classifications.

Aponeurotic ptosis. This type typically presents in the fifth to sixth decade of life and is the most common type seen in adults.³ Aponeurotic type ptosis is secondary to dehiscence or disinsertion of the levator aponeurosis and is commonly associated with aging. Patients may notice a subtle change in their eyelid appearance over time. While this condition is typically bilateral, it can present asymmetrically. When assessing eyelid measurements, a normal levator function and a high lid crease are common. These patients are not likely to present with abnormal extraocular motilities or pupillary abnormalities.³

Traumatic ptosis. Broadly spanned, traumatic ptosis may be categorized as aponeurotic, myogenic, neurogenic or mechanical, depending on the mecha-

TABLE 3. WORKUP ASSOCIATED WITH HORNER'S, CN III PALSY AND MYASTHENIA GRAVIS

Condition	Additional Testing
Horner's syndrome	Neuroimaging head and neck extending to the apex of the lung
CN III palsy	Neuroimaging of the brain and orbits Angiography of the brain Bloodwork: CBC with platelets, ESR, CRP, FTA-ABS, RPR, Lyme, ACE, ANA
Myasthenia gravis	Acetylcholine receptor binding, blocking and modulating Anti-MuSK antibody Anti-striated muscle antibody LRP4 antibody Single fiber electromyography Chest x-ray to look for thymoma

nism of injury. This type is the second most common etiology and can happen when there is damage to the belly of the LPS or the MM or from disinsertion of the levator aponeurosis of the tarsal plate.⁵ Like aponeurotic ptosis, these patients may present with a high lid crease, and there is typically a cause-and-effect relationship for this etiology. Therefore, case history is vital for diagnosis. Inquiring about any recent trauma to the head or orbital region can help identify this etiology. This type can also be a post-surgical finding related to ocular speculum use in cataract surgery.⁶

Mechanical ptosis. This can occur secondary to external etiologies that prevent the eyelid from elevating or cause

an asymmetric appearance. Some causes include blepharochalasis, chalazion, orbital fat prolapse, eyelid tumors, blood product due to trauma and cicatricial changes of the palpebral conjunctiva. Therefore, a careful external ocular examination of the adnexa, eyelids and conjunctiva is recommended.³

Ptosis secondary to botulinum toxin A injections. Ptosis can occur after a botulinum toxin A injection of the glabellar complex. The glabellar complex includes the frontalis, procerus, corrugator supercilii, depressor supercilii and orbicularis oculi muscles. Glabellar complex injections are used for cosmetic purposes and in the treatment of chronic migraines.⁷ Post-botulinum toxin A ptosis can occur

Re-defining the frontiers of Vision Testing technology.



The future of Visual Testing is here.

Experience the new era of eyecare tech with the VisuALL VRP at your fingertips.



Dynamic Matrix

Our proprietary eye tracking algorithm can reduce fixation loss to zero.



AI Assistant

Annie can increase office efficiency, monitor patients, speak over 35+ languages and so much more.

**One product.
One complete
diagnostic
universe.**



Extraocular Motility



Visual Acuity



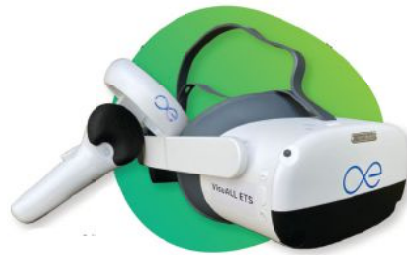Visual Field



Color Vision



Pupillometry



Contrast Sensitivity



**Experience the future.
Visit us at AAOpt, Booth 1413**

Scan code to know more or visit www.olleyes.com

Exclusive Distrubters



anywhere between two days and 10 days later, with the ptosis lasting anywhere from two to four weeks after injection.⁸

Ptosis with Diplopia

Conditions such as autoimmune or mitochondrial diseases can result in ptosis with related double vision, two of which are described below.

Myasthenia gravis. This neuromuscular disease is an antibody-mediated autoimmune condition with improper communication in the neuromuscular junction (NMJ).⁹ Through a T-cell-dependent process, antibodies are created to attack the acetylcholine receptors in the NMJ resulting in decreased density of the receptors and abnormal morphology of the NMJ. MG affects voluntary muscles with ocular MG affecting the LPS, MM and EOMs. Pupillary muscle fibers are not affected, as they are not voluntary. However, EOMs are particularly susceptible to the effects of MG because the muscle fibers have a high frequency of synaptic firing when sustaining a fixated gaze. EOMs also have a lower density of acetylcholine receptors, resulting in faster onset weakness than in other skeletal muscles. In 50% of cases, ocular manifestations are the initial sign of MG.¹⁰

While diplopia and ptosis are the most common ocular manifestations of MG, they can occur independently of each other. When formulating history questions, keep in mind that the symptoms of diplopia and ptosis improve with rest. This results in variable ptosis or diplopia that can worsen by the end of the day.¹¹ MG can be a systemic condition that becomes life-threatening if vital muscles are affected. The muscles of the esophagus may be affected, causing difficulty swallowing and increased risk of choking. If the diaphragm is affected, it can result in difficulty breathing and possible respiratory failure. Patients who present with difficulty breathing or swallowing should be sent to a hospital emergency department for treatment.^{3,11}

EOMs affected by MG are variable and cover testing can mimic patterns consistent with cranial nerve palsies, gaze palsies and internuclear ophthalmop-

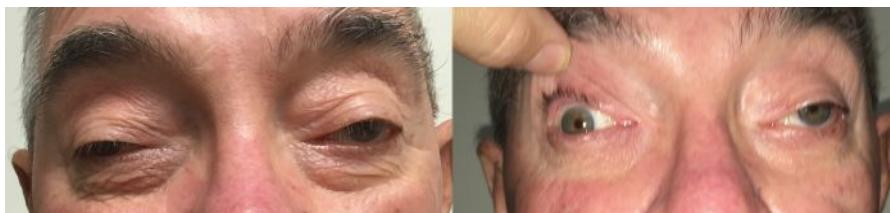

Fig. 3. This photo represents a patient with chronic progressive external ophthalmoplegia. At left, he is looking in primary gaze without his lids held. At right, he is in primary gaze with lids held.

moplegia; there may also be a nonspecific pattern. MG should be considered in patients with a presentation of both diplopia and ptosis. The cover test results and eyelid measurements may worsen with fatigue and improve with ice pack testing, since cooling increases the amount of acetylcholine in the NMJ by inhibiting acetylcholinesterase activity.¹²

Before fatigue and ice pack testing, baseline ocular alignment, EOMs and eyelid measurements should be obtained. Fatigue and ice pack tests should be performed for two minutes each, with the fatigue test performed first. A 2mm or greater difference in pre- and post-palpebral aperture measurements is considered a positive result for both tests.^{11,13} Positive results are indicative of MG (*Figure 2*). Other tests suggestive of MG include orbicularis oculi weakness and a positive curtain test. These, however, are nonspecific for MG.^{11,13}

Blood tests are the most common way to test for MG. Acetylcholine receptor antibody titers have the highest positivity rate at 85% when suspecting MG, followed by anti-muscle specific kinase (MuSK) antibody, lipoprotein receptor-related antibody 4 (LRP4) and anti-striated muscle antibody. A stepwise approach is expected when ordering these blood tests, starting with acetylcholine receptor antibody (binding, blocking, modulating). If these tests are negative, anti-MuSK antibody, LRP4 antibody and anti-striated muscle antibody can be ordered if suspicion for MG is high; however, less than 10% of patients with MG will be seronegative for any of these antibodies.¹⁴ If this is the case, single fiber electromyography can be performed to confirm the MG diagnosis (*Table 3*).¹⁵

Chronic progressive external ophthalmoplegia. This genetic condition results in slowly developing ptosis and ophthalmoplegia. CPEO has been classified as a mitochondrial encephalomyopathy and can be confirmed with genetic testing. Since mitochondria are found in nearly every tissue, these patients may also present with other affected organ systems.¹⁶ Ocular presentation is typically asymmetric and becomes more symmetric as the disease progresses (*Figure 3*). CPEO affects all external ocular muscles, limiting all directions of gaze. Given the genetic correlation, eyecare providers should inquire about a family history of ptosis or ophthalmoplegia.^{17,18}

Each case of CPEO is unique. Therefore, the cover test pattern can be nonspecific and may mimic other conditions. However, these patients will not have variability of ocular misalignment or ptosis, as is seen with MG. Patients with mitochondrial syndromes may present with other ocular and systemic findings as well; fundus examination may reveal optic disc atrophy or retinopathy with disruption of the retinal pigment epithelium. Comanagement with other specialties is necessary due to potential systemic involvement of mitochondrial syndromes.¹⁸

Ptosis with Miosis

Another class of ptosis, accompanied by pupil constriction, is mainly indicative of the neurological condition of Horner's syndrome (HS).

This syndrome is caused by damage to the oculosympathetic pathway. Initiating in the hypothalamus, this pathway has a long ipsilateral course and consists of three neurons. Associated symptoms can assist in localization of the lesion within this pathway. The first neuron starts

To treat ocular inflammation and pain following ophthalmic surgery or ocular itching associated with allergic conjunctivitis.

DEXTENZA KEEPS PATIENTS

COMPLIANT

AND SATISFIED^{1-3*}

A hands-free advancement in ophthalmic steroid treatment.^{1,4}

Easy-to-insert[†] and preservative-free intracanalicular DEXTENZA offers patients a satisfying post-op experience—providing up to 30 days of sustained steroid coverage.¹⁻⁵

INDICATIONS

DEXTENZA is a corticosteroid indicated for:

- The treatment of ocular inflammation and pain following ophthalmic surgery.
- The treatment of ocular itching associated with allergic conjunctivitis.

IMPORTANT SAFETY INFORMATION

CONTRAINDICATIONS

DEXTENZA is contraindicated in patients with active corneal, conjunctival or canalicular infections, including epithelial herpes simplex keratitis (dendritic keratitis), vaccinia, varicella; mycobacterial infections; fungal diseases of the eye, and dacryocystitis.

WARNINGS AND PRECAUTIONS

Intraocular Pressure Increase - Prolonged use of corticosteroids may result in glaucoma with damage to the optic nerve, defects in visual acuity and fields of vision. Steroids should be used with caution in the presence of glaucoma. Intraocular pressure should be monitored during treatment.

Bacterial Infections - Corticosteroids may suppress the host response and thus increase the hazard for secondary ocular infections. In acute purulent conditions, steroids may mask infection and enhance existing infection.

Viral Infections - Use of ocular steroids may prolong the course and may exacerbate the severity of many viral infections of the eye (including herpes simplex).

Fungal Infections - Fungus invasion must be considered in any persistent corneal ulceration where a steroid has been used or is in use. Fungal culture should be taken when appropriate.

Delayed Healing - Use of steroids after cataract surgery may delay healing and increase the incidence of bleb formation.

Other Potential Corticosteroid Complications - The initial prescription and renewal of the medication order of DEXTENZA should be made by a physician only after examination of the patient with the aid of magnification, such as slit lamp biomicroscopy, and, where appropriate, fluorescein staining. If signs and symptoms fail to improve after 2 days, the patient should be re-evaluated.

ADVERSE REACTIONS

Ocular Inflammation and Pain Following Ophthalmic Surgery

The most common ocular adverse reactions that occurred in patients treated with DEXTENZA were: anterior chamber inflammation including iritis and iridocyclitis (10%), intraocular pressure increased (6%), visual acuity reduced (2%), cystoid macular edema (1%), corneal edema (1%), eye pain (1%), and conjunctival hyperemia (1%). The most common non-ocular adverse reaction was headache (1%).

Itching Associated with Allergic Conjunctivitis

The most common ocular adverse reactions that occurred in patients treated with DEXTENZA were: intraocular pressure increased (3%), lacrimation increased (1%), eye discharge (1%), and visual acuity reduced (1%). The most common non-ocular adverse reaction was headache (1%).

Please see adjacent Brief Summary of full Prescribing Information.

*93% (187/201) DEXTENZA patients were satisfied with the insert in the Phase 3 Study for the treatment of ocular inflammation and pain following ophthalmic surgery.³

[†]73.6% of physicians in Study 1, 76.4% in Study 2, and 79.6% in Study 3, for the treatment of ocular inflammation and pain following ophthalmic surgery, rated DEXTENZA as easy to insert.^{2,5}

References: **1.** DEXTENZA [package insert]. Bedford, MA: Ocular Therapeutix, Inc; 2021. **2.** Tyson SL, et al. *J Cataract Refract Surg.* 2019;45(2):204-212 [erratum in: 2019;45(6):895]. **3.** Data on File 00837. Ocular Therapeutix, Inc. **4.** Sawhney AS, Inventors, et al. Incept, LLC, Assignee. Drug Delivery Through Hydrogel Plugs. US Patent 8,409,606 B2. April 2, 2013. **5.** Walters T, et al. *J Clin Exp Ophthalmol.* 2016;7(4):1-11.

© 2021 Ocular Therapeutix, Inc. All Rights Reserved.
DEXTENZA is a registered trademark of Ocular Therapeutix, Inc. PP-US-DX-0346

Dextenza[®]
(dexamethasone ophthalmic insert) 0.4 mg
for intracanalicular use

Dextenza®

(dexamethasone ophthalmic insert) 0.4 mg
for intracanalicular use

BRIEF SUMMARY: Please see the DEXTENZA Package Insert for full Prescribing Information (10/2021)

1 INDICATIONS AND USAGE

1.1 Ocular Inflammation and Pain Following Ophthalmic Surgery

DEXTENZA® (dexamethasone ophthalmic insert) is a corticosteroid indicated for the treatment of ocular inflammation and pain following ophthalmic surgery (1.1).

1.2 Itching Associated with Allergic Conjunctivitis

DEXTENZA® (dexamethasone ophthalmic insert) is a corticosteroid indicated for the treatment of ocular itching associated with allergic conjunctivitis (1.2).

4 CONTRAINDICATIONS

DEXTENZA is contraindicated in patients with active corneal, conjunctival or canalicular infections, including epithelial herpes simplex keratitis (dendritic keratitis), vaccinia, varicella; mycobacterial infections; fungal diseases of the eye, and dacryocystitis.

5 WARNINGS AND PRECAUTIONS

5.1 Intraocular Pressure Increase

Prolonged use of corticosteroids may result in glaucoma with damage to the optic nerve, defects in visual acuity and fields of vision. Steroids should be used with caution in the presence of glaucoma. Intraocular pressure should be monitored during the course of the treatment.

5.2 Bacterial Infection

Corticosteroids may suppress the host response and thus increase the hazard for secondary ocular infections. In acute purulent conditions, steroids may mask infection and enhance existing infection [see Contraindications (4)].

5.3 Viral Infections

Use of ocular steroids may prolong the course and may exacerbate the severity of many viral infections of the eye (including herpes simplex) [see Contraindications (4)].

5.4 Fungal Infections

Fungus invasion must be considered in any persistent corneal ulceration where a steroid has been used or is in use. Fungal culture should be taken when appropriate [see Contraindications (4)].

5.5 Delayed Healing

The use of steroids after cataract surgery may delay healing and increase the incidence of bleb formation.

5.6 Other Potential Corticosteroid Complications

The initial prescription and renewal of the medication order of DEXTENZA should be made by a physician only after examination of the patient with the aid of magnification, such as slit lamp biomicroscopy, and, where appropriate, fluorescein staining. If signs and symptoms fail to improve after 2 days, the patient should be re-evaluated.

6 ADVERSE REACTIONS

The following serious adverse reactions are described elsewhere in the labeling:

- Intraocular Pressure Increase [see Warnings and Precautions (5.1)]
- Bacterial Infection [see Warnings and Precautions (5.2)]
- Viral Infection [see Warnings and Precautions (5.3)]
- Fungal Infection [see Warnings and Precautions (5.4)]
- Delayed Healing [see Warnings and Precautions (5.5)]

6.1 Clinical Trials Experience

Because clinical trials are conducted under widely varying conditions, adverse reaction rates observed in the clinical trials of a drug cannot be directly compared to rates in the clinical trials of another drug and may not reflect the rates observed in practice. Adverse reactions associated with ophthalmic steroids include elevated intraocular pressure, which may be associated with optic nerve damage, visual acuity and field defects, posterior subcapsular cataract formation; delayed wound healing; secondary ocular infection from pathogens including herpes simplex, and perforation of the globe where there is thinning of the cornea or sclera [see Warnings and Precautions (5)].

6.2 Ocular Inflammation and Pain Following Ophthalmic Surgery

DEXTENZA safety was studied in four randomized, vehicle-controlled studies (n = 567). The mean age of the population was 68 years (range 35 to 87 years), 59% were female, and 83% were white. Forty-seven percent had brown iris color and 30% had blue iris color. The most common ocular adverse reactions that occurred in patients treated with DEXTENZA were: anterior chamber inflammation including iritis and iridocyclitis (10%); intraocular pressure increased (6%); visual acuity reduced (2%); cystoid macular edema (1%); corneal edema (1%); eye pain (1%) and conjunctival hyperemia (1%).

The most common non-ocular adverse reaction that occurred in patients treated with DEXTENZA was headache (1%).

6.3 Itching Associated with Allergic Conjunctivitis

DEXTENZA safety was studied in four randomized, vehicle-controlled studies (n = 154). The mean age of the population was 41 years (range 19 to 69 years), 55% were female and 61% were white. Fifty seven percent had brown iris color and 20% had blue iris color. The most common ocular adverse reactions that occurred in patients treated with DEXTENZA were: intraocular pressure increased (3%), lacrimation increased (1%), eye discharge (1%), and visual acuity reduced (1%). The most common non-ocular adverse reaction that occurred in patients treated with DEXTENZA was headache (1%).

8 USE IN SPECIFIC POPULATIONS

8.1 Pregnancy

Risk Summary

There are no adequate or well-controlled studies with DEXTENZA in pregnant women to inform a drug-associated risk for major birth defects and miscarriage. In animal reproduction studies, administration of topical ocular dexamethasone to pregnant mice and rabbits during organogenesis produced embryofetal lethality, cleft palate and multiple visceral malformations [see Animal Data].

Data

Animal Data

Topical ocular administration of 0.15% dexamethasone (0.75 mg/kg/day) on gestational days 10 to 13 produced embryofetal lethality and a high incidence of cleft palate in a mouse study. A daily dose of 0.75 mg/kg/day in the mouse is approximately 5 times the entire dose of dexamethasone in the DEXTENZA product, on a mg/m² basis. In a rabbit study, topical ocular administration of 0.1% dexamethasone throughout organogenesis (0.36 mg/day, on gestational day 6 followed by 0.24 mg/day on gestational days 7-18) produced intestinal anomalies, intestinal aplasia, gastroschisis and hypoplastic kidneys. A daily dose of 0.24 mg/day is approximately 6 times the entire dose of dexamethasone in the DEXTENZA product, on a mg/m² basis.

8.2 Lactation

Systemically administered corticosteroids appear in human milk and could suppress growth and interfere with endogenous corticosteroid production; however the systemic concentration of dexamethasone following administration of DEXTENZA is low [see Clinical Pharmacology (7.2.3)]. There is no information regarding the presence of DEXTENZA in human milk, the effects of the drug on the breastfed infant or the effects of the drug on milk production to inform risk of DEXTENZA to an infant during lactation. The developmental and health benefits of breastfeeding should be considered along with any potential adverse effects on the breastfed child from DEXTENZA.

8.4 Pediatric Use

Safety and effectiveness in pediatric patients have not been established.

8.5 Geriatric Use

No overall differences in safety or effectiveness have been observed between elderly and younger patients.

17 PATIENT COUNSELING INFORMATION

Advise patients to consult their eye care professional if pain, redness, or itching develops.

Ocular
Therapeutix™

Ocular Therapeutix, Inc.
Bedford, MA 01730 USA
PP-US-DX-0360

Feature PTOSIS

in the hypothalamus and travels down the dorsal portion of the brainstem and spinal cord to the level of T1, where it synapses in the ciliospinal center of Budge and exits the central nervous system.^{19,20} The second neuron ascends the cervical sympathetic chain, travels over the apex of the lung and synapses at the level of C3 to C4 in the superior cervical ganglion, between the internal carotid artery and internal jugular vein. The final neuron travels with the internal carotid artery into the skull base, through the cavernous sinus, then joins the ophthalmic division of the trigeminal nerve to enter the orbit through the superior orbital fissure. The oculosympathetic nerve ultimately innervates the MM and the iris dilator muscle.¹⁹⁻²¹

HS classically presents with ptosis, miosis and anhidrosis, but anhidrosis is not a common symptom reported by patients. MM assists in the elevation of the eyelid, but the primary muscle is the LPS. Therefore, ptosis associated with Horner's is typically smaller than when involving the LPS, only about 2mm to 3mm. Reverse ptosis may also be present due to damage of the sympathetic innervation of the lower eyelid MM.¹⁹ Anisocoria is expected in HS patients and is typically greater in dim illumination. Pictures taken with an infrared camera can help observe anisocoria when measuring in dim conditions. Coexistent EOM abnormalities can help localize HS to the brainstem or cavernous sinus.²⁰ For example, a patient with a cranial nerve IV palsy and an ipsilateral HS could localize to the cavernous sinus. In contrast, a patient with a cranial nerve IV palsy and a contralateral HS can localize to the midbrain. Inquiries about headaches and neck pain are vital because painful HS is a medical emergency because of concern for a carotid artery dissection.²²

Horner's syndrome should be considered in all patients with ipsilateral miosis and ptosis. To confirm HS, a diagnostic test can be performed on an untouched cornea; no ocular drops should be instilled before this testing. Cocaine 2% to 10% is highly effective at confirming HS and is considered positive when anisocoria becomes greater within 45 minutes. The unaffected pupil will dilate while the pupil with HS will fail to do so in response to cocaine.²² Because it is a controlled substance, though, cocaine is difficult to obtain.

Apraclonidine 0.5%, an alpha-2 adrenergic agonist, is more easily accessible and more commonly used to confirm Horner's. A positive result can present up to an hour after drop instillation, occurring when the eye with the HS dilates in response, causing a reversal of anisocoria (Figure 4).²³ Alpha-2 adrenergic agonists are contraindicated in children under six years old, as administration can result in bradycardia, hypotension, lethargy and somnolence. Therefore, cocaine is the preferred method for diagnostic testing in children with suspected HS.²⁴

Hydroxyamphetamine and phenylephrine are agents that can be used to localize HS. However, these tests also need to be performed on an untouched cornea. Therefore, this testing must be completed at least 72 hours after initial confirmatory testing.^{25,26} After HS confirmation without known etiol-

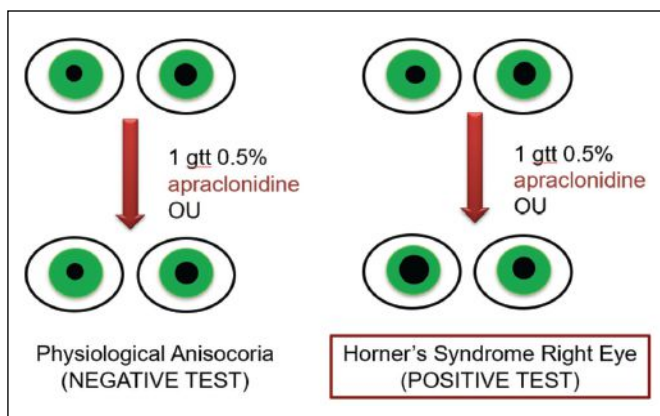


Fig. 4. A negative and positive response to 0.5% apraclonidine as related to the diagnosis of Horner's syndrome. In a positive result, anisocoria are expected to reverse with 0.5% apraclonidine, while in a negative result, there will be no reversal of anisocoria.

ogy, neuroimaging should be ordered. A magnetic resonance imaging (MRI) or computerized tomography scan (CT) of the head and neck with and without contrast should be performed. If possible, these images should extend to the apex of the lung to assess for any lesions along the oculosympathetic pathway (Table 3). When ordering neuroimaging for HS, consultation with radiology can help to ensure the most appropriate combination of studies are ordered.

Ptosis with Mydriasis and Diplopia

A ptosis presentation with both double vision and dilated pupils is often indicative of a cranial nerve III palsy.

The third cranial nerve originates in the medial portion of the midbrain in the oculomotor complex. As it exits the midbrain, caudal to the mammillary bodies, it passes between the posterior cerebral and superior cerebellar arteries, running adjacent to the posterior communicating artery before traveling through the lateral wall of the cavernous sinus. After exiting the cavernous sinus, CN III splits into the superior and inferior divisions before entering the orbit through the superior orbital fissure.²⁷ The superior division of CN III innervates the superior rectus and LPS. By contrast, the inferior division innervates the inferior rectus, medial rectus and inferior oblique. The inferior division is also accompanied by the parasympathetic postganglionic fibers. These provide pupillary input to the iris sphincter and ciliary muscle.²⁸

If the LPS is affected in either a partial or complete CN III palsy, it can result in any degree of ptosis. Since CN III innervates most EOMs, diplopia is a common complaint. However, patients who present with a more prominent ptosis from a CN III palsy may not complain of diplopia, as the eyelid may be covering the visual axis. It is commonly thought that the eye will be “down and out;” however, this may not be true for subtler palsies. The cover test pattern that should raise concern for a CN III palsy is a reversing hyper-deviation in up and down gazes with increased exodeviation in the gaze, contralateral to the affected eye (Figure 5).

A partial or complete CN III palsy could result from damage anywhere along the pathway of CN III; compressive, ischemic or vasculopathic etiologies are most common.²⁹ A vasculopathic etiology is suspected with conditions of diabetes, hypertension and hyperlipidemia, but is a diagnosis of exclusion and should not be assumed without further investigation.

Neuroimaging is needed to assess for a compressive lesion when evaluating CN III palsies. This will include an MRI or CT scan of the brain and orbits both with and without contrast and magnetic resonance imaging of the arteries (MRA) or computerized tomography of the arteries (CTA). CN III palsies can also be due to infectious and inflammatory etiologies, with a complete blood count including platelets, C-reactive protein and erythrocyte sedimentation rate helping assess for giant cell arteritis, generalized infections and anemia. Specific infectious etiologies, such as syphilis and Lyme disease, should additionally be investigated. Autoimmune conditions and other infectious processes, such as sarcoidosis, should be ruled out (Table 3).^{30,31} If the patient has no known vasculopathic conditions, risk factors for such should be assessed with blood pressure monitoring and lab testing for diabetes and hyperlipidemia.²⁰

Vasculopathic CN III palsy occurs due to compromised vasa nervorum blood supply to the internal aspect of the nerve, sparing the more superficial pupillary fibers. These etiologies tend to improve on their own in about three months.²⁹ Not as forgiving, a compressive CN III palsy can cause ipsilateral mydriasis due to damage of the parasympathetic pupillary fibers running on the outer surface of the nerve. This can result in greater anisocoria in bright illumination. A pupil-involving CN III palsy is particularly concerning for a posterior communicating artery aneurysm.^{29,32} All patients with a new CN III palsy, especially those with pupillary involvement or pain, should be sent to the hospital emergency department to rule out aneurysm with MRA or CTA.³³

Treatment

When treating ptosis, it is essential to first treat any underlying systemic condition. Diseases such as MG and CPEO should be comanaged with other specialties like neurology, cardiology, endocrinology and rheumatology, dependent upon

	Up Gaze Left Hyper	
Right Gaze	Primary Gaze	Left Gaze >Exo
	Down Gaze Right Hyper	

Fig. 5. This represents a pattern of right CN III palsy. There is a left hyper-deviation in up gaze with a right hyper-deviation in down gaze. This is representative of a reversing hyper-deviation. There is also an increasing exodeviation in left gaze. The opposite would be true of a left CN III palsy.

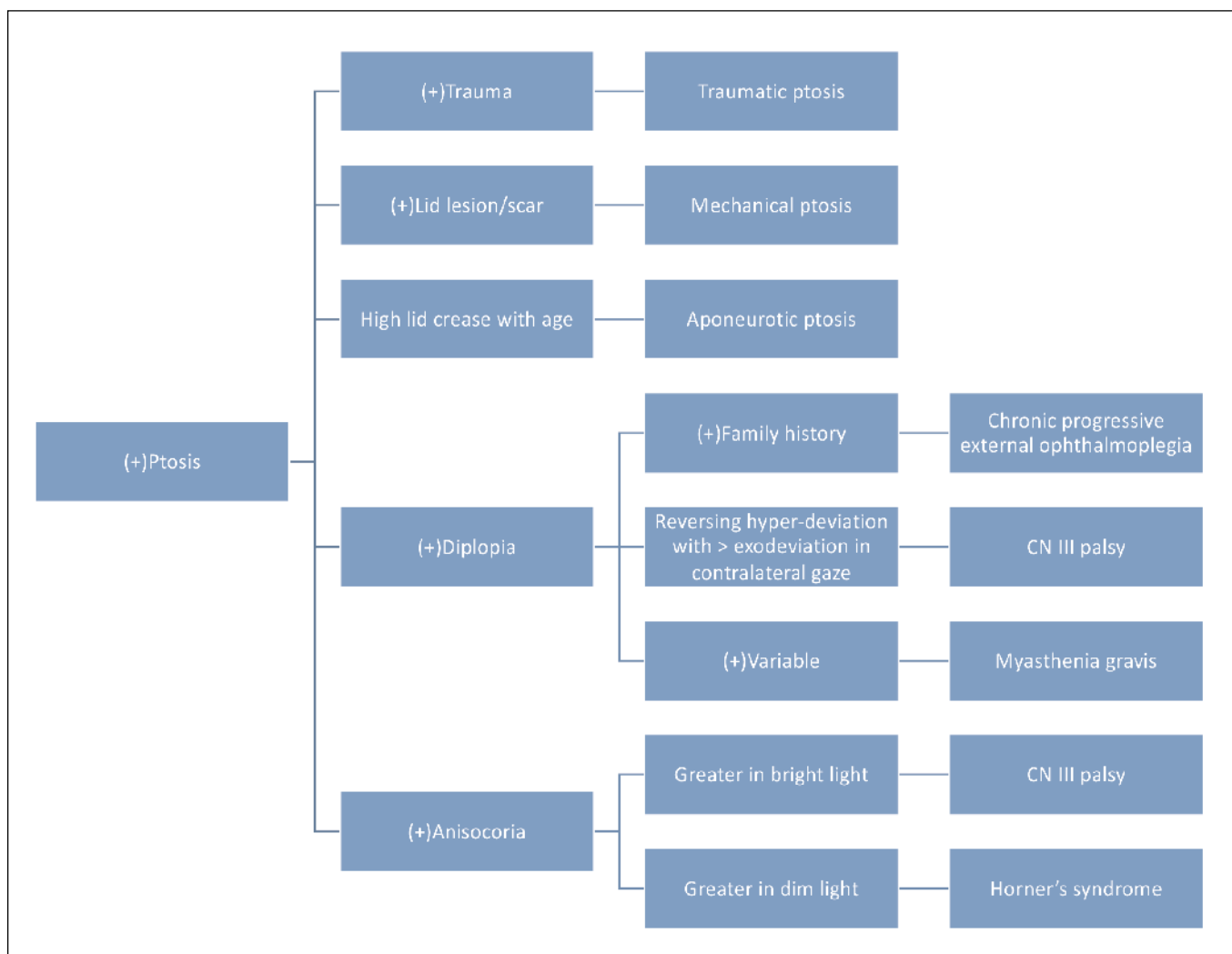


Fig. 6. The flowchart above represents the common differentials of ptosis (not an all-inclusive list).

the patient’s clinical presentation. In patients who complain of the cosmesis of ptosis, there are topical medications and surgical options. Topical ophthalmic medications include oxymetazoline hydrochloride 0.1% and off-label use of apraclonidine 0.5%.

These medications are alpha-adrenergic agonists and are thought to stimulate the sympathetic nervous system, resulting in a contraction of MM and elevation of the upper eyelid by approximately 2mm.^{34,35} Oxymetazoline hydrochloride is used once daily and takes five to fifteen minutes to take effect. This medication can be used on a daily basis, or as needed based on the patient’s desire to improve the cosmetic appearance of their ptosis.³⁶ Oxymetazoline hydrochloride should be avoided in patients with cardiovascular disease and narrow angles. Side effects include ocular surface dryness and irritation after drop instillation.³⁶ For patients with long-standing prominent ptosis, surgical intervention may be indicated, except in patients with variable or progressive ptosis. Referral to an oculoplastic specialist can be needed for surgical intervention.³⁷

Takeaways

It is common for initial ptosis evaluations to be performed by optometrists, although outside care may be necessary, depending on evaluation results. Not all patients will be aware of their ptosis; optometrists may be the first to take note of the finding, especially in subtler cases. While there are many etiologies of acquired ptosis, optometrists can incorporate case history, examination techniques and additional testing to differentiate and diagnose associated conditions. Comanagement with other specialties should be considered in conditions with potential systemic involvement. ■

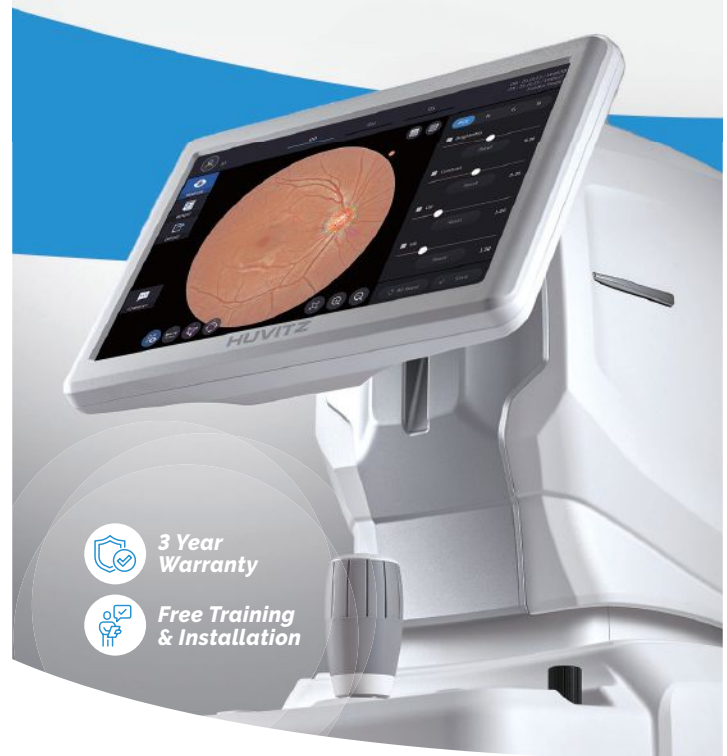1. Shahzad B, Siccardi MA. Ptosis. In: StatPearls. Treasure Island (FL): StatPearls Publishing. Updated February 19, 2023.
2. Alotaibi GF, Alsukait SF, Alsalman HH, Turkmani MG. Eyelid ptosis following botulinum toxin injection treated with brimonidine 0.33% topical gel. JAAD Case Rep. 2022;22:96-8.
3. Finsterer J. Ptosis: causes, presentation, and management. Aesthetic Plast Surg. 2003;27(3):193-204.
4. Koka K, Patel BC. Ptosis correction. In: StatPearls. Treasure Island (FL): StatPearls Publishing. Updated July 10, 2023.
5. Lim JM, Hou JH, Singa RM, Aakalu VK, Setabutr P. Relative incidence of blepharoptosis subtypes in an oculoplastics practice at a tertiary care center. Orbit. 2013;32(4):231-4.

6. Jacobs SM, Tying AJ, Amadi AJ. Traumatic ptosis: evaluation of etiology, management, and prognosis. *J Ophthalmic Vis Res.* 2018;13(4):447-52.
7. FDA approved medication guide: BOTOX (onabotulinumtoxinA). FDA. Published 2011. [accessdata.fda.gov/drugsatfda_docs/label/2011/103000s5232lbl.pdf](https://www.accessdata.fda.gov/drugsatfda_docs/label/2011/103000s5232lbl.pdf). Accessed July 11, 2023.
8. Klein AW. Complications, adverse reactions and insights with the use of botulinum toxin. *Dermatol Surg.* 2003;29(5):549-56.
9. Dresser L, Wlodarski R, Rezania K, Soliven B. Myasthenia gravis: epidemiology, pathophysiology and clinical manifestations. *J Clin Med.* 2021;10(11):2235.
10. Grob D, Arsula EL, Brunner NG, Namba T. The course of myasthenia gravis and therapies affecting outcome. *Ann N Y Acad Sci.* 1987;505:472-99.
11. Nair AG, Patil-Chhablani P, Venkatramani DV, Gandhi RA. Ocular myasthenia gravis: a review. *Indian J Ophthalmol.* 2014;62(10):985-91.
12. Sethi KD, Rivner MH, Swift TR. Ice pack test for myasthenia gravis. *Neurology.* 1987;37(8):1383-5.
13. Keane JR. Vertical diplopia. *Semin Neurol.* 1986;6(2):147-54.
14. Lazaridis K, Tzartos SJ. Autoantibody specificities in myasthenia gravis; implications for improved diagnostics and therapeutics. *Front Immunol.* 2020;11:212.
15. Rivero A, Crovetto L, Lopez L, et al. Single fiber electromyography of extraocular muscles: a sensitive method for the diagnosis of ocular myasthenia gravis. *Muscle Nerve.* 1995;18(9):943-7.
16. Deschauer M, Müller T, Dreha S, Zierz S. [Familial mitochondrial chronic progressive external ophthalmoplegia. Five families with differing genetics]. *Nervenarzt.* 2001;72(2):122-9.
17. Caballero PEJ, Candela MS, Alvarez CIC, Tejerina AA. Chronic progressive external ophthalmoplegia: a report of six cases and a review of the literature. *Neurologist.* 2007;13(1):33-6.
18. Bau V, Zierz S. Update on chronic progressive external ophthalmoplegia. *Strabismus.* 2005;13(3):133-42.
19. Walton KA, Buono LM. Horner syndrome. *Curr Opin Ophthalmol.* 2003;14(6):357-63.
20. Sanders M. Walsh and Hoyt's clinical neuro-ophthalmology. 4th ed., volume 5. *J Neurol Neurosurg Psychiatry.* 1996;61(2):236-7.
21. Reede DL, Garcon E, Smoker WRK, Kardon R. Horner's syndrome: clinical and radiographic evaluation. *Neuroimaging Clin N Am.* 2008;18(2):369-85.
22. Kardon RH, Denison CE, Brown CK, Thompson HS. Critical evaluation of the cocaine test in the diagnosis of Horner's syndrome. *Arch Ophthalmol.* 1990;108(3):384-7.
23. Bremner F. Apraclonidine is better than cocaine for detection of Horner syndrome. *Front Neurol.* 2019;10:55.
24. Al-Shahwan S, Al-Torbak AA, Turkmani S, et al. Side-effect profile of brimonidine tartrate in children. *Ophthalmology.* 2005;112(12):2143.
25. Danesh-Meyer HV, Savino P, Sergott R. The correlation of phenylephrine 1% with hydroxyamphetamine 1% in Horner's syndrome. *Br J Ophthalmol.* 2004;88(4):592-3.
26. Wilhelm H, Wilhelm B, Kriegbaum C. Interaction of the indirectly acting topical sympathomimetics cocaine and pholegrine. *Ger J Ophthalmol.* 1996;5:168-70.
27. Flanders M, Hasan J, Al-Mujaini A. Partial third cranial nerve palsy: clinical characteristics and surgical management. *Can J Ophthalmol.* 2012;47(3):321-5.
28. Joyce C, Le PH, Peterson DC. Neuroanatomy, cranial nerve 3 (oculomotor). In: StatPearls. Treasure Island (FL): StatPearls Publishing. Updated March 27, 2023.
29. Keane JR. Third nerve palsy: analysis of 1400 personally-examined inpatients. *Can J Neurol Sci.* 2010;37(5):662-70.
30. Appenzeller S, Veilleux M, Clarke A. Third cranial nerve palsy or pseudo third nerve palsy of myasthenia gravis? A challenging diagnosis in systemic lupus erythematosus. *Lupus.* 2009;18(9):836-40.
31. Kaiser PK, Friedman NJ, Pineda R. Third cranial nerve palsy. *The Massachusetts eye and ear infirmary illustrated manual of ophthalmology.* 4th ed. Saunders Elsevier, 2014:83-87.
32. Capó H, Warren F, Kupersmith MJ. Evolution of oculomotor nerve palsies. *J Clin Neuroophthalmol.* 1992;12(1):21-5.
33. Motoyama Y, Nonaka J, Hironaka Y, Park YS, Nakase H. Pupil-sparing oculomotor nerve palsy caused by upward compression of a large posterior communicating artery aneurysm. Case report. *Neurol Med Chir (Tokyo).* 2012;52(4):202-5.
34. Morales J, Brown SM, Abdul-Rahim AS, Crosson CE. Ocular effects of apraclonidine in Horner syndrome. *Arch Ophthalmol.* 2000;118(7):951-4.
35. Bacharach J, Wirta DL, Smyth-Medina R, et al. Rapid and sustained eyelid elevation in acquired blepharoptosis with oxymetazoline 0.1%: randomized Phase 3 trial results. *Clin Ophthalmol.* 2021;15:2743-51.
36. Upneeq [package insert]. Bridgewater, NJ: RVL Pharmaceuticals, INC.; 2020.
37. McCord CD, Tanenbaum M, Nunery WR. Oculoplastic surgery. New York: Lippincott, Williams and Wilkins, 1995.
38. Patil SB, Kale SM, Math M, Khare N, Sumeet J. Anthropometry of the eyelid and palpebral fissure in an Indian population. *Aesthet Surg J.* 2011;31(3):290-4.
39. Rana K, Beecher MB, Caltabiano C, et al. Normal periocular anthropometric measurements in an Australian population. *Int Ophthalmol.* 2023;43:2695-2701.
40. Migliori ME, Gladstone GJ. Determination of the normal range of exophthalmometric values for black and white adults. *Am J Ophthalmol.* 1984;98(4):438-42.

High quality, automatic digital retinal imaging.

Experience the HFC-1 Non-Mydriatic Fundus Camera.

- Quick and stable auto tracking and auto shooting
- Adjust fixation target position
- Enhanced Visualization Technology captures fine pathological variation
- Full color digital image acquisition



 **3 Year Warranty**

 **Free Training & Installation**

COBURN TECHNOLOGIES 

1-800-COBURN-1
See our full line of products at [coburntechnologies.com](https://www.coburntechnologies.com)

tyrvaya[®]
(varenicline solution)
nasal spray 0.03 mg

FOR THE SIGNS
& SYMPTOMS OF
DRY EYE DISEASE

SHE'S LOOKING TO YOU FOR A
DIFFERENT APPROACH WHEN
ARTIFICIAL TEARS ARE NOT ENOUGH.¹

BEFORE ANOTHER DROP

ACTIVATE REAL TEARS

WITH THE FIRST AND ONLY NASAL
SPRAY FOR DRY EYE²



Tyrvaya[®] is not another drop

It's an **ocular surface-sparing** nasal spray.²



Activates real, basal tears

Tyrvaya[®] is believed to work by activating the trigeminal parasympathetic pathway resulting in **basal tear production**.^{2*}



Real tears, real fast

In 2 clinical trials with **mild, moderate, and severe** dry eye disease patients, Tyrvaya increased tear production from baseline by **≥10 mm in Schirmer's Test Score (STS) in nearly 50% of patients at week 4**, with increased tears seen as early as the first dose and over 12 weeks.^{2-8†}

SEE WHAT
TYRVAYA
CAN DO



*The exact mechanism of action is unknown.

†Tyrvaya was evaluated across 3 randomized, vehicle-controlled, double-masked studies in which adults aged ≥22 years diagnosed with dry eye disease received 1 spray of either active drug or vehicle in each nostril twice daily. Primary endpoint: % of patients with mean change from baseline in STS of ≥10 mm at week 4 in ONSET-1: 52% with Tyrvaya (n=48) vs 14% with vehicle (n=43) and in ONSET-2: 47% with Tyrvaya (n=260) vs 28% with vehicle (n=252). Onset of action: mean change from baseline in STS ~5 minutes after first dose (not a prespecified endpoint) in ONSET-1 was 17.2 mm with Tyrvaya (n=48) vs 4.0 mm with vehicle (n=43) and in ONSET-2 was 16.5 mm with Tyrvaya (n=260) vs 6.9 mm with vehicle (n=251). Observed data. On Day 1 in clinical studies, a baseline anesthetized Schirmer's test was performed. Tyrvaya was then administered concurrently with Schirmer's test. Schirmer's test results were measured at ~5 minutes. Mean change from baseline in STS at week 12 in the MYSTIC study was 10.8 mm with Tyrvaya vs 6.0 mm with vehicle. Limitations: Ex-US, single-center study. All subjects were Hispanic or Latino. Tyrvaya group mean baseline STS 5.5 mm (n=41); vehicle group mean baseline STS 5.3 mm (n=41). All randomized and treated patients were included in the analysis and missing data were imputed using last-available data. ²⁻⁸
See references on next page.

Indication

Tyrvaya[®] (varenicline solution) nasal spray is indicated for the treatment of the signs and symptoms of dry eye disease.

Important Safety Information

The most common adverse reaction reported in 82% of patients was sneezing. Events that were reported in 5-16% of patients were cough, throat irritation, and instillation-site (nose) irritation.

Please see Brief Summary of Prescribing Information on the next page and the full Prescribing Information at Tyrvaya-pro.com.

BRIEF SUMMARY: Consult the full Prescribing Information for complete product information available at www.tyrvaya-pro.com.

INDICATIONS AND USAGE

TYRVAYA[®] (varenicline solution) nasal spray is a cholinergic agonist indicated for the treatment of the signs and symptoms of dry eye disease.

ADVERSE REACTIONS

Clinical Trials Experience: Because clinical trials are conducted under widely varying conditions, adverse reaction rates observed in the clinical trials of a drug cannot be directly compared to rates in the clinical trials of another drug and may not reflect the rates observed in practice.

In three clinical trials of dry eye disease conducted with varenicline solution nasal spray, 349 patients received at least 1 dose of TYRVAYA. The majority of patients had 31 days of treatment exposure, with a maximum exposure of 105 days.

The most common adverse reactions reported in 82% of TYRVAYA treated patients was sneezing. Other common adverse reactions that were reported in >5% of patients include cough (16%), throat irritation (13%), and instillation-site (nose) irritation (8%).

USE IN SPECIFIC POPULATIONS

Pregnancy: Risk Summary: There are no available data on TYRVAYA use in pregnant women to inform any drug associated risks. In animal reproduction studies, varenicline did not produce malformations at clinically relevant doses.

All pregnancies have a risk of birth defect, loss, or other adverse outcomes. In the US general population, the estimated background risk of

major birth defects and miscarriage in clinically recognized pregnancies is 2% to 4% and 15% to 20%, respectively.

Data: Animal Data: Pregnant rats and rabbits received varenicline succinate during organogenesis at oral doses up to 15 and 30 mg/kg/day, respectively. While no fetal structural abnormalities occurred in either species, maternal toxicity, characterized by reduced body weight gain, and reduced fetal weights occurred in rabbits at the highest dose (4864 times the MRHD on a mg/m² basis).

In a pre- and postnatal development study, pregnant rats received up to 15 mg/kg/day of oral varenicline succinate from organogenesis through lactation. Maternal toxicity, characterized by a decrease in body weight gain, was observed at 15 mg/kg/day (1216 times the MRHD on a mg/m² basis). Decreased fertility and increased auditory startle response occurred in offspring at the highest maternal dose of 15 mg/kg/day.

Lactation: Risk summary: There are no data on the presence of varenicline in human milk, the effects on the breastfed infant, or the effects on milk production. In animal studies varenicline was present in milk of lactating rats. However, due to species-specific differences in lactation physiology, animal data may not reliably predict drug levels in human milk.

The lack of clinical data during lactation precludes a clear determination of the risk of TYRVAYA to an infant during lactation; however, the developmental and health benefits of breastfeeding should be considered along with the mother's clinical need for TYRVAYA and any potential adverse effects on the breastfed child from TYRVAYA.

Pediatric Use: Safety and efficacy of TYRVAYA in pediatric patients have not been established.

Geriatric Use: No overall differences in safety or effectiveness have been observed between elderly and younger adult patients.

References: **1.** Jones L, Downie LE, Korb D, et al. *Ocul Surf.* 2017;15(3):575-628. **2.** Tyrvaya. Prescribing Information. Oyster Point Pharma; 2021. **3.** Oyster Point Pharma. Data on file. OPP-002 (ONSET-1) Clinical Study Report. August 4, 2019. **4.** Oyster Point Pharma. Data on file. OPP-101 (ONSET-2) Interim Clinical Study Report. October 13, 2020. **5.** Quiroz-Mercado H, Hernandez-Quintela E, Chiu KH, Henry E, Nau JA. *Ocul Surf.* 2022;24:15-21. **6.** Wirta D, Torkildsen GL, Boehmer B, et al. *Cornea.* 2022;4(10):1207-1216. **7.** Wirta D, Vollmer P, Paauw J, et al. *Ophthalmology.* 2021;0(0):379-387. **8.** Oyster Point Pharma. Data on file. OPP-004 (MYSTIC) Clinical Study Report. March 19, 2020.

Manufactured for Oyster Point Pharma, Inc. 202 Carnegie Center, Suite 106, Princeton NJ 08540. For more information, visit www.tyrvaya-pro.com. To report an adverse event, contact 1-877-EYE-0123.

© 2023 Viatrix Inc. and/or its affiliates. All rights reserved. VIATRIS and the Viatrix Logo are trademarks of Mylan Inc., a Viatrix Company. Oyster Point[®], Tyrvaya[®], and the Tyrvaya logo are trademarks of Oyster Point Pharma, Inc., a Viatrix company, in the United States and certain jurisdictions. OP-TYR-002308 7/23

FIVE QUESTIONS ABOUT MEDICAL THERAPY FOR DEMODEX

The first targeted drug for this widespread condition is now available, offering a new treatment avenue for eyecare clinicians and their patients.

BY CATLIN NALLEY
CONTRIBUTING EDITOR

Demodex blepharitis—a prevalent yet underdiagnosed and undertreated condition—affects at least 25 million Americans and can have a significant impact on an individual's daily life.¹ Characterized by collarettes, which lead to a number of associated symptoms such as red, irritated and itchy eyelids, it accounts for more than two-thirds of all blepharitis cases.^{1,2}

Until recently, management options for *Demodex* blepharitis have been limited. Clinicians have traditionally relied on encouraging patients to practice better lid hygiene to reduce bacterial overgrowth and recommending eyelid cleansers with tea tree oil to help eradicate mites. However, this past July, the long-awaited first targeted therapeutic for the condition finally received FDA approval. Formerly known as TP-03 during its development stage, Xdemvy (lotilaner ophthalmic solution 0.25%, Tarsus Pharmaceuticals) requires a six-week course of treatment and involves one drop of the solution in each eye, administered twice daily approximately 12 hours apart.

The approval of Xdemvy was supported by findings from two random-

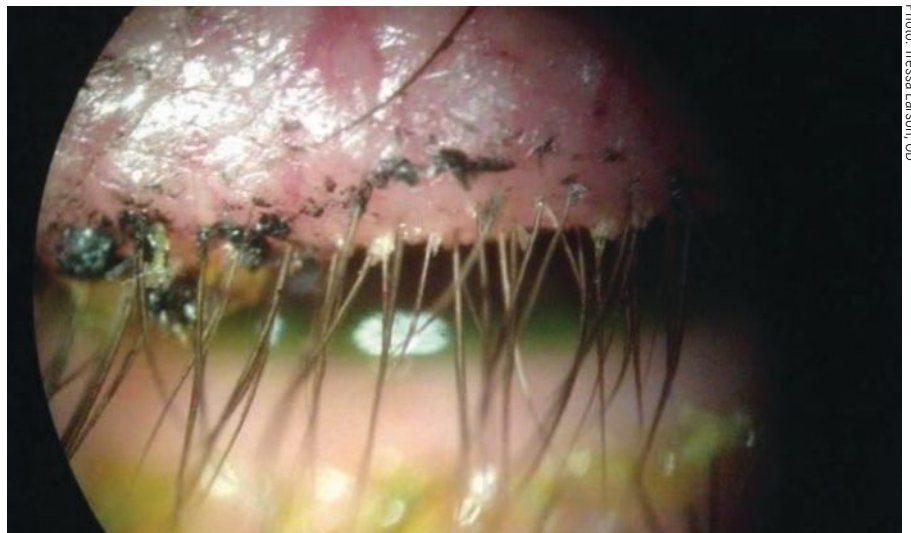

Photo: Tressa Larson, OD

This patient's lid margins display *Demodex* infestation at the base of the lashes.

ized, vehicle-controlled studies—known as Saturn-1 and Saturn-2—involving 833 patients who received either Xdemvy or vehicle. Both trials met the primary endpoint of collarette reduction to no more than two per upper eyelid by day 43 as well as the secondary endpoints of mite eradication (zero per lash) and erythema cure (grade zero). The safety profile of Xdemvy was also favorable in both studies.

In Saturn-1, 81% of patients receiving treatment had a collarette grade of zero or one on day 43 vs. 23% for placebo. In Saturn-2, these percentages

were 89% vs. 33%, respectively. The Saturn-2 study authors additionally reported that treatment led to a clinically meaningful collarette reduction to 10 collarettes or fewer (89.1%), mite eradication (51.8%), erythema cure (31.1%) and composite cure (19.2%).³

In many cases, the treatment also showed effectiveness in as little as two weeks; by day 15 in Saturn-1, 68% of patients achieved complete mite eradication vs. 18% of those on placebo.

As one of the study authors and a clinical investigator for Saturn-1 and Saturn-2, Paul Karpecki, OD, director

of Cornea and External Disease for Kentucky Eye Institute and chief clinical editor of this magazine, has had firsthand experience with Xdemvy and believes its recent FDA approval will have a significant impact on patients and optometric practice.

“About 58% of all patients entering an optometry practice have collarettes, the pathognomonic sign for *Demodex* blepharitis,” he notes. “We have never had a prescription drop for this most common cause of blepharitis until Xdemvy. Given the data on eradication rates, this will be a welcome therapeutic.”

Though Elyse Chaglasian, OD, associate dean for faculty at the Illinois College of Optometry, has not yet had the opportunity to experience this new agent firsthand, she believes Xdemvy could benefit a variety of patients, and she looks forward to incorporating it into clinical practice. “It is gratifying to see years of research come to fruition,” she says. “This new treatment fills a gap in care and has the potential to significantly improve the quality of life for our patients with *Demodex* blepharitis.”

Below, you’ll find answers to five common questions clinicians may be asking about this new therapeutic agent, helping you better understand its clinical role and how to optimize its use in your practice.

1. Where does this new drug fit into clinical practice?

Now that Xdemvy is available, optometrists must determine when it should be prescribed and who the best candidates are for this approach. In Dr. Karpecki’s opinion, any patient with more than two collarettes should consider treatment.

“My experience is that *Demodex* builds over time, eventually leading to scalloped lid margins, meibomian gland dysfunction (MGD), thin or missing lashes, atrophy of the meibomian glands and chronic evaporative dry eye, to name a few consequences,” he notes.

“I would want this ectoparasite eradicated as soon as it’s identified

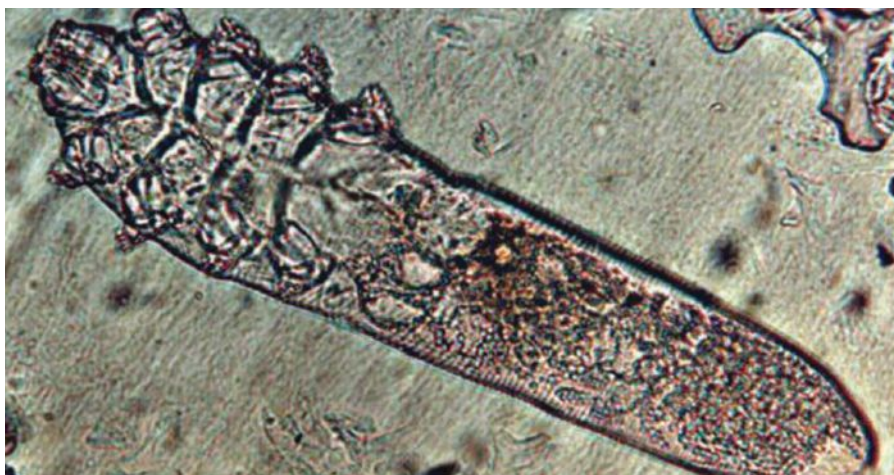


Photo: Joseph Showlin, OD

This image depicts a *Demodex folliculorum* mite under a microscope. While these critters can be found on the skin of most humans, an overpopulation may lead to ocular surface discomfort and require intervention.

as opposed to waiting for significant symptoms such as irritation, itching, recurrent hordeola or chalazia,” he explains. “I would also recommend gently rubbing the base of the lashes with any excess drop after instillation in the eyes BID.”

Diagnosing a patient with *Demodex* blepharitis does not require additional tools or equipment, according to Dr. Karpecki, who advises clinicians to “look for collarettes by having the patient look down while at the slit lamp, scanning the lid margins with slightly higher magnification.”

Dr. Chaglasian is already considering which of her patients might be candidates for Xdemvy. “I treat a woman who is your typical dry eye patient with multiple issues, including MGD and *Demodex*. Her main complaint is red and irritated eyelids,” she says. Dr. Chaglasian adds that while treatments, including low-level light therapy and tea tree and okra-based lid wipes, have helped this patient, they have not resolved the issue completely.

“She is, in my opinion, the perfect candidate. We have exhausted available options and Xdemvy will hopefully provide the relief she needs,” Dr. Chaglasian notes. “This isn’t just another artificial tear or lid wipe. Xdemvy is a class of drug that we have never had before in *Demodex* blepharitis that can treat a condition that is endemic among our patients.”

2. Should other treatments be used simultaneously?

Coupling Xdemvy with other treatments (e.g., meibomian gland expression, warm compresses, lid scrubs, blepharoexfoliation) could prove beneficial in some cases. Depending on the specific needs of your patient, a multifaceted approach may offer the best outcomes.

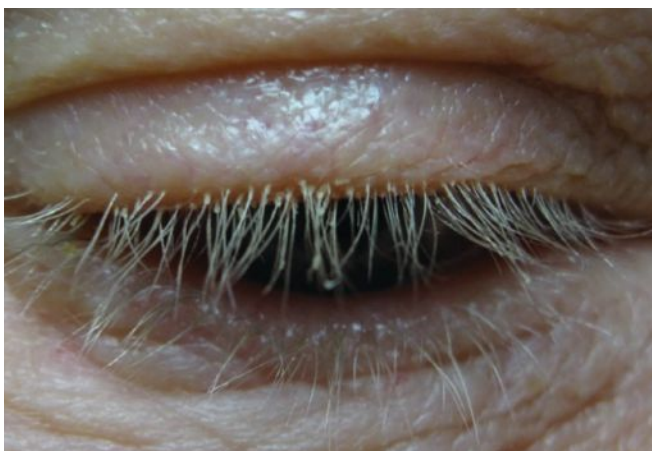“I do believe therapeutics do best when surrounded by other treatment options,” notes Dr. Karpecki. For example, he suggests that a case of moderate to severe *Demodex* blepharitis would benefit from blepharoexfoliation to remove the bulk of pathology and collarettes, combined with Xdemvy for eradication of the mites.

“Another option could be a low-level light therapy blue mask with intense pulsed light (IPL) treatment followed by Xdemvy for six weeks,” he says. “Or, one could simply prescribe Xdemvy BID for six weeks and then begin a manuka extract hygiene product such as MyboClean (Danelli Ocular Creation) once daily long-term to maintain lid hygiene.”

Given the high association between MGD and *Demodex* blepharitis, Dr. Karpecki would recommend warm hydrating compresses for these patients.

When discussing the use of ivermectin, he notes, “since oral ivermectin requires Kg conversion to determine dosage, I am hopeful that Xdemvy, with

Photo: Patrick M. Vollmer, OD



Cylindrical dandruff that presents at the base of the lashes, shown here, is a telltale sign of *Demodex* infestation.

its high eradication rates, will remove the need for this oral medication going forward except for use in extreme cases.”

3. What if patients don't achieve good enough results from Xdemvy alone?

The majority of patients who received Xdemvy in Saturn-1 and Saturn-2 clinical trials benefited from treatment. As previously noted, more than 50% of patients in Saturn-2 achieved complete collarette cure—defined as zero to two collarettes per lid at day 43—and 89% had a significant, clinically meaningful collarette cure.³

Saturn-1 data showed that a greater proportion of patients in the study group achieved a clinically meaningful collarette cure (81.3% vs. 23.0%), complete collarette cure (44.0% vs. 7.4%), mite eradication (67.9% vs. 17.6%), erythema cure (19.1% vs. 6.9%) and composite cure (13.9% vs. 1.0%) when compared with the control group.⁴

While these results are promising and suggest that most patients will benefit from Xdemvy, optometrists must be prepared to care for patients who don't see the full benefit of this agent after the six-week treatment period. So, what is the contingency plan in these cases?

When asked about the best approach for patients who don't respond to treatment, or have a suboptimal outcome, Dr. Karpecki recommends considering IPL in addition to blue-light low-level

light therapy with blepharoexfoliation. However, he notes that based on the positive trial results, “my expectation is that there will be very few patients that don't experience a significant improvement after six weeks of Xdemvy.”

One possibility to consider in more severe or persistent cases of *Demodex*

blepharitis is whether the patient may be experiencing comorbid *Demodex* overgrowth on their facial skin that is preventing the condition's full resolution. See the sidebar on the following page to learn more about how these patients may potentially benefit from pairing targeted lid therapies with dermatologic treatment.

4. How should I address any adverse effects that arise from treatment?

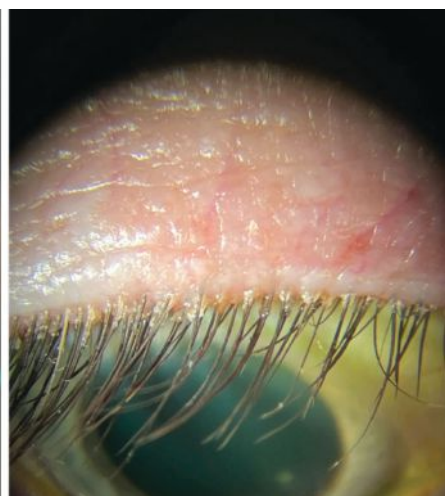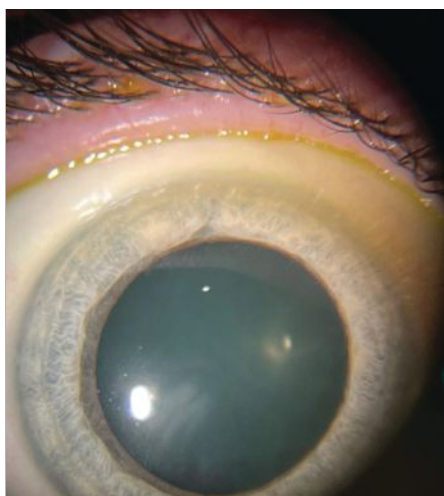
Like any therapeutic agent, Xdemvy is not immune to potential side effects. Therefore, optometrists must be prepared to not only address any adverse events that occur but also educate patients prior to prescribing the drug.

According to the prescribing information, the most common ocular adverse reactions in the clinical trials were instillation site stinging and burning, which was observed in 10% of patients. More severe adverse effects, mainly chalazion/hordeolum and punctate keratitis, were reported in less than 2% of patients treated with Xdemvy.²

In Saturn-1, 19.8% of patients who received Xdemvy had at least one treatment-emergent adverse event compared with 21.5% in the control group. The study authors reported that all treatment-emergent adverse events were mild.⁴

The most common adverse event reported among patients in the Xdemvy cohort in Saturn-1 was instillation site pain (11.8%). Other, less frequent ocular treatment-emergent adverse events observed in the study and control groups included instillation site pruritus (1.4% vs. 3.3%), reduced visual acuity (2.8% vs. 2.9%), eye pain (1.4% vs. 1.4%), eye discharge (1.4% vs. 1.0%) and chalazion (0.5% vs. 1.4%), all of which were reported to be mild.⁴

Safety findings from Saturn-2 were consistent with Saturn-1, further demonstrating the safety and tolerability of Xdemvy among patients with *Demodex* blepharitis. No serious treatment-related adverse events were observed. The study authors reported that in Saturn-2, instillation site pain, burning and/or



These photos show the same patient during a slit lamp exam. Left: Patient looking straight ahead with minimal identifiable blepharitis. Right: Patient looking down with obvious collarettes, indicating a *Demodex* infestation.

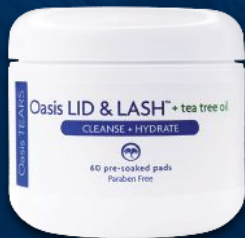Photo: Cecilia Koertling, OD



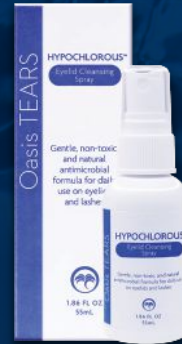TOO MUCH SCREEN TIME

Introduce **Lid Hygiene Regimen** and **Comprehensive Dry Eye Relief** to Your Patients

SCRUB & CLEANSE



OT7300
Oasis TEARS
LID & LASH
+ Tea Tree Oil



OT7400
Oasis TEARS
HYPOCHLOROUS
Spray

ENCOURAGE FLOW



OM8000
Oasis REST & RELIEF
Eye Mask



ON3000
Oasis TEARS
OMEGA 3

QUALITY TEARS



OT6200
Oasis TEARS PLUS
Preservative-Free



ON3010
Oasis TEARS
VISION Supplement

Visit OASIS at the
AAO 2023 Expo
Booth #1754



SCAN HERE TO
Receive a Lid Hygiene Kit and
Schedule a Lid Hygiene Workshop

Call (844) 820-8940
Email customerservice@oasismedical.com
Visit www.oasismedical.com

stinging was experienced by 16 (7.9%) patients, and three patients (1.5%) developed signs or symptoms of dry eye. Additionally, 91% of patients found the drop to be neutral to very comfortable.³

Despite the strong safety profile reported in clinical trials, optometrists must clearly outline any potential side effects to patients and readily offer support to those who experience them.

“It is important to set expectations for patients even if 90% may not develop adverse effects,” advises Dr. Karpecki. “I would let patients know that they may experience burning or stinging upon instillation of the drop and that it’s normal,” he says. “There were very few patients in the clinical trials that discontinued use due to adverse events like instillation site stinging and burning.”

No one wants a surprise adverse reaction, emphasizes Dr. Chaglasian. “It all comes down to patient education,” she notes. “Optometrists need to take the time to not only communicate the benefits but also any possible side effects, no matter how unlikely.”

5. How do I navigate insurance coverage?

Contending with insurance coverage and pricing hurdles, especially when it comes to a newly approved treatment, can be challenging for both optometrists and their patients. Dr. Karpecki urges ODs to use available options recommended by the company (Tarsus Pharmaceuticals, in the case of Xdemvy).

“Insurance providers all wait six months before adding a new therapy to a formulary, so companies have to find alternate ways to make their drug available to patients,” he notes. “Specialty pharmacies, such as BlinkRx, make the drug more easily available and for discounted rates—typically \$50 or less.”

Dr. Karpecki says that he believes this price is reasonable, especially when you consider that the drug is not a long-term therapy like many immunomodulators used in, for example, dry eye disease. Other specialty pharmacy options where you might be able to

More than Meets the Eyelid

When patients present with *Demodex* blepharitis, the goal of treatment is typically to eradicate mites from the eyelids—but what about the rest of the face? According to a recent study in *American Journal of Ophthalmology*, facial *Demodex* overgrowth is not uncommon among those with ocular demodicosis, and its presence may hinder the effectiveness of treatment efforts targeted only at the eyelids. For this reason, researchers suggest that co-treatment with a topical parasiticide applied to the facial skin may be beneficial to achieve a higher mite eradication rate, especially in patients with more severe *Demodex* blepharitis.

In the prospective clinical cohort study, 89 patients with ocular demodicosis were enrolled from a tertiary medical center. High ocular *Demodex* load was defined as \geq eight mites per eye, and facial *Demodex* overgrowth was defined as a density of $>$ five mites/cm² as assessed through direct microscopic examination. All patients underwent three months of ocular treatment including twice-daily cleansing with tea tree oil in addition to topical lubricants and/or anti-allergy eye drops when indicated. Those with prominent facial symptoms or higher facial *Demodex* densities were additionally prescribed a daily course of topical ivermectin cream (Soolantra, Galderma), while those with less severe symptoms or lower facial *Demodex* densities were prescribed topical metronidazole gel (Metrogel, Galderma).

Patients with a high ocular *Demodex* load were noted to have a higher prevalence of facial *Demodex* overgrowth compared to those with a low ocular *Demodex* load (49% vs. 77%, respectively). Topical treatment on facial skin in patients with facial demodicosis resulted in a significantly higher ocular *Demodex* eradication rate (76% vs. 16% for those with facial demodicosis who only received ocular treatment).

The researchers concluded in their paper, “Concurrence of ocular and facial demodicosis is common, especially in cases of severe ocular demodicosis. While ocular treatment alone is effective for patients with ocular demodicosis only, co-treatment with topical ivermectin on the facial skin enhances ocular *Demodex* eradication in patients with comorbid facial *Demodex* overgrowth.” They advise that a combined ophthalmological and dermatological service may be beneficial to maximize resolution in these patients.

Huang WL, Huang CM, Chu CY, Hu FR. Comorbidity of ocular and facial demodicosis. *Am J Ophthalmol*. September 20, 2023. [Epub ahead of print].

order Xdemvy for a lower price include AllianceRx Walgreens Pharmacy, Carepoint Pharmacy and CVS Specialty Pharmacy.

When dealing with insurance coverage for Xdemvy, “be sure to have the correct ICD-10 diagnosis codes, which should include both H01.00 (unspecified blepharitis) and B88.0 (other acariasis),” Dr. Karpecki adds.

Takeaways

The introduction of Xdemvy into clinical practice addresses a huge unmet need for patients with *Demodex* blepharitis, Dr. Chaglasian says. “We have in-office treatments that can be effective for a short time, but at-home treatments, such as lid wipes, offer mixed results at best and don’t take care of the underlying problem,” she explains.

“Xdemvy has the potential to provide long-term relief for our patients,” Dr. Chaglasian reiterates. “For so long, we have been doing the best we can with what we have, but now we have a product that fills this gap. It is a game changer for the treatment of this prevalent condition.” ■

1. Karpecki P. Call the exterminator. *Review of Optometry*. 2023;160(9):84.

2. Tarsus announces positive topline data from Saturn-2 phase 3, the second pivotal trial of TP-03 for the treatment of *Demodex* blepharitis, and expects to file a new drug application this year. Tarsus Pharmaceuticals. Published May 02, 2022. ir.tarsusrx.com/news-releases/news-release-details/tarsus-announces-positive-topline-data-saturn-2-phase-3-second. Accessed September 18, 2023.

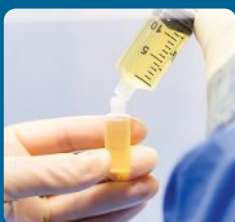3. Gaddie IB, Donnenfeld ED, Karpecki P, et al. Lotilaner ophthalmic solution 0.25% for *Demodex* blepharitis: randomized, vehicle-controlled, multicenter, phase 3 trial (Saturn-2). *Ophthalmology*. June 5, 2023. [Epub ahead of print].

4. Yeu E, Wirta DL, Karpecki P, et al. Lotilaner ophthalmic solution, 0.25%, for the treatment of *Demodex* blepharitis: results of a prospective, randomized, vehicle-controlled, double-masked, pivotal trial (Saturn-1). *Cornea*. 2023;42(4):435-43.

Visit us at **AAO**
booth 805.

Serum Tears Made Simple.

Think serum tears are hard to get?
Learn how **Vital Tears** has simplified the process.



At Vital Tears, our mission is to make serum tears easily available and affordable for your patients. We've done that for patients across the country through our:

- **Rapid serum drop delivery**
- **Convenient blood draw options**
- **Affordable payment options**
- **Superior customer service**

Visit us at **AAO booth 805.**

SCAN THIS CODE TO DOWNLOAD OUR
PHYSICIAN INFORMATION PACKET



OR CALL TOLL-FREE (800) 360-9592

 **Vital Tears™**

TACKLE MGD WITH THESE HANDS-ON INTERVENTIONS

Adding gland expression, along with blepharoexfoliation and IPL, unlocks new levels of control over patient outcomes. We show you the proper way to go about it.



MILA IOUSSIFOVA, OD,¹
AND HARDEEP KATARIA, OD,²
¹PORTLAND, OR; ²PORTER RANCH, CA

Meibomian gland dysfunction (MGD) is a common and chronic condition and contributes to nearly 60% of all dry eye disease (DED).¹ Although the pathophysiology of MGD is poorly understood, it is characterized by the obstructions of the terminal ducts, cystic dilation, acinar cell dropout and gland dropout caused by hyperkeratinized ductal epithelium (*Figures 1 and 2*). This leads to qualitative and quantitative changes in the MG secretion and reduced meibum to coat the aqueous layer of the tear film, resulting in tear film instability and evaporative dry eye. The diagnosis of MGD can be made based on the clinical examination, imaging and patient symptomatology; however, more than half of MGD patients do not present with symptoms.²

Just about all optometrists are able to recognize MGD, but there are nuances to the grading of cases that impact

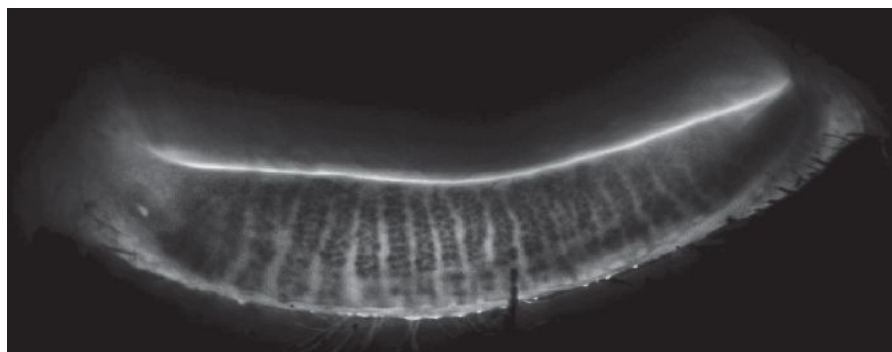


Fig. 1. Normal MG morphology on LipiScan meibography.

management decisions. These finer points may be less familiar and will be discussed below. Management strategies involving in-office interventions are not yet mainstream practice but are increasingly being adopted by optometrists. Thus, the remainder of this feature will detail the procedures and devices in order to help you integrate these into practice should you choose to.

Diagnosis

Traditionally, MGD was identified by assessing the function of the glands by simply pushing on them and ask-

ing patients their symptoms. Recent literature shows the value of assessing the morphology of the glands, thus broadening our diagnosis to looking at structure and function. The structure is assessed with photos of the anterior segment—specifically meibography—an infrared image of the glands (*Figure 2*) or by diffuse/transillumination of the glands with the slit lamp (*Figure 3*).

Upon structural assessment, evidence of dilation, truncation, tortuosity and/or atrophy of the glands suggests a dysfunction in their ability to produce and/or secrete meibum. Functional assessment

About the authors

Dr. Ioussifova graduated from the New England College of Optometry and completed a residency program in community health and ocular disease in Boston. She is a fellow of the American Academy of Optometry, previously served as an adjunct clinical faculty at the Pacific University College of Optometry and was an examiner for the NBEO. Dr. Ioussifova owns South Waterfront Eye Center, a practice with special interests in advanced dry eye treatments, nutritional counseling and aesthetic services. **Dr. Kataria** graduated from the New England College of Optometry, completed her clinical rotations at Bascom Palmer Eye Institute as well as a residency in primary care and ocular disease at the Baltimore VAMC. After practicing medical optometry and advanced ocular surface disease as an associate, she now owns a private practice near Los Angeles called Avant Eyes Optometry & Advanced Dry Eye Center. They have no financial disclosures.

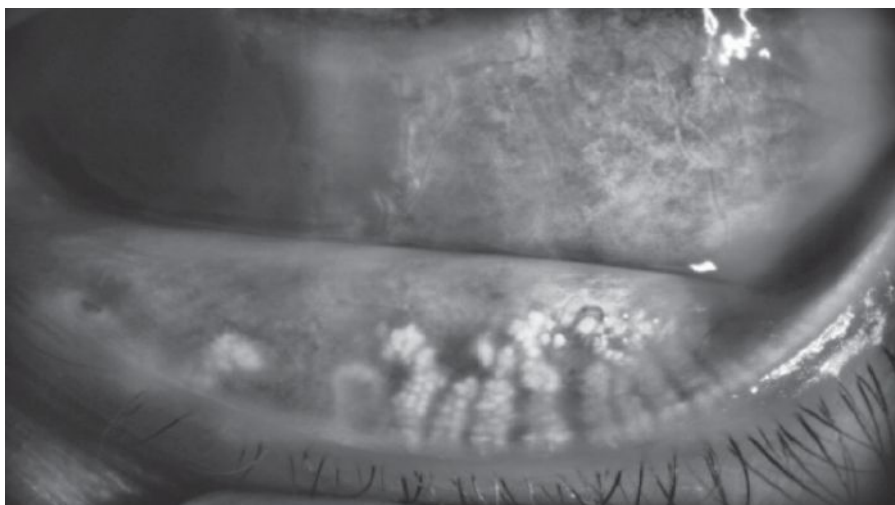

Fig. 2. Abnormal MG morphology with truncation and atrophy of glands.

entails gentle fingertip expression of the glands to look for evidence of thick, pasty and/or waxy meibum with reduced meibum production, which suggests a dysfunction in the quality and quantity of meibum being released.³

Grading MGD

In keeping with this approach that considers both structure and function (a paradigm common in glaucoma and many other ocular disease), let's consider each of these spheres in detail.

Function is assessed by using a clinical grading scale called the Meibomian Glands Yielding Liquid Secretion (MGYLS) score. Gland expressibility is important when assessing the quality and quantity of the secreted meibum. The Meibomian Gland Evaluator (Johnson & Johnson) delivers a standard force of 1.25g/mm² over an area of

40mm² (eight glands) that approximates the force applied to the eyelids and MG during a natural blink. Lipid secretion from each gland is assessed to determine the MGYLS score. Eight glands are assessed at a time. For example, if only two thirds of glands on the lower eyelid are producing liquid secretion, the MGYLS is 16/24.

Meibographic imaging can be helpful in conjunction with expressibility scores to determine if an inactive gland is due to pathological or physiological reasons.³

Three types of MG secretions were first described in one study:⁴

- Clear, oily lipid
- Waxy, cloudy
- Opaque, inspissated

Structure is assessed using the meiboscoring grading scale. It is now a well identified and widely used method of assessing morphology:⁵

- Grade 0 = no loss of meibomian glands
- Grade 1 = less than the one-third loss of the total area
- Grade 2 = less than two-thirds loss of the total area
- Grade 3 = more than two-thirds loss of the total area

Therefore, a careful assessment of the structure and function of the glands is necessary to understand disease severity and help guide treatment.

Appropriate Therapy

As MGD is the leading cause of DED, treating it is critical, but with so many treatment options available, how do we know which one to choose?

Treatments range from age-old (warm compresses and eyelid hygiene) to brand new (Miebo, the perfluorohexyloctane drops just launched by Bausch + Lomb that target evaporation). Miebo, in conjunction with MG evacuation treatments, could be beneficial in controlling signs and symptoms of MGD, as perfluorohexyloctane helps to reduce the evaporation rate and stabilizes the tear film, therefore improving the homeostasis of the ocular surface.

Other pharmaceutical options include topical or oral antibiotics and steroidal or nonsteroidal anti-inflammatories, as well as nutraceuticals. Direct manipulation of the affected area is yet another avenue for treatment, as physical interventions like blepharoexfoliation, thermal evacuation, light-based therapies and intraductal probing all have a potential role to play.

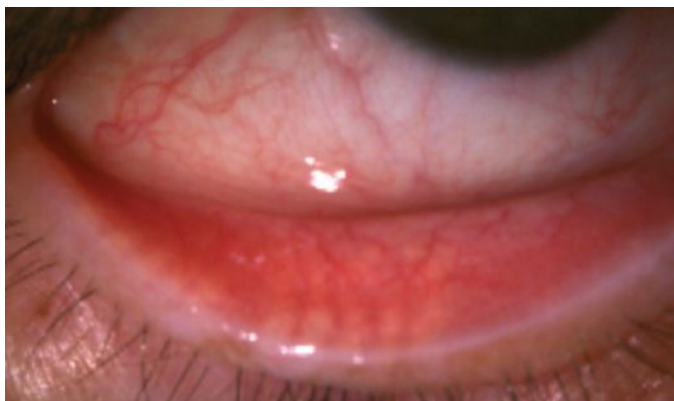

Fig. 3. Diffuse illumination of MG structure.

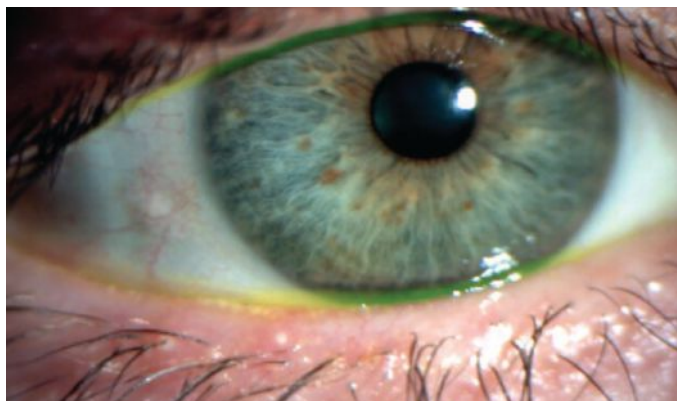

Fig. 4. Hyperkeratinization along the eyelid margin.

It is established that MGD is associated with changes in the composition and structure of meibum, which contributes to the vicious cycle of impaired tear film quality. The physical changes of the meibum are associated with an increase in lipid melting point, starting at 35°C in obstructive MGD compared with 32°C in normal eyes.⁶ In-office treatments aim to raise the temperature in MGs, melt the stagnant meibum and evacuate it by applying pressure. Subsequently, lid margins should be evaluated for telangiectasia, biofilm, eyelid wiper epitheliopathy, blepharitis and hyperkeratinized epithelial cells obstructing the MG secretion (Figure 4).

The meiboscore scale may be used as a guide to treatment with mild-moderate cases that would benefit most from thermal evacuation procedures, as well as more MGD and atrophy that would benefit procedures.⁵

Blepharoexfoliation

Blepharitis is commonly associated with MGD and DED, with over 40% of patients in primary eye care having the condition, of which more than half are due to overpopulation of *Demodex* mites.⁷ Patients often complain of itchy and irritated eyes, especially in the morning, as the mites tend to be more active at night. To diagnose the condition, have the patient look down to examine the top eyelashes to look for crusts, flakes or collarettes. The latter are pathognomonic for *Demodex* (Figure 5).

In-office procedures of blepharoexfoliation may offer a more efficient treatment and faster symptom relief, followed by home eyelid hygiene for maintenance. Blepharoexfoliation should be combined with in-office MG expressions to remove biofilm and hyperkeratinized epithelial cells along the eyelid margin.

There are several options for

in-office blepharoexfoliation:

- Zocular Eyelid System Treatment (ZEST), a manual eyelid cleaning system containing gel with activated okra polysaccharide complex.
- BlephEx (Alcon), a handheld device to mechanically remove debris and exfoliate the eyelid margin.
- NuLids Pro (NuSight Medical), an in-office version of the home eyelid cleaning device NuLids. This is a great tool for patients to use at home as part of their lid hygiene maintenance after

an in-office procedure.

- Lid debridement with tools like a Karpecki debrider or golf spud, which removes biofilm and excess keratin from the lid margins. However, unlike the aforementioned tools, these methods would not address blepharitis.

Once the eyelids are cleared of debris and margins are exfoliated, a thermal or light-based treatment followed by MG expressions can be performed.

Blepharoexfoliation should be repeated as often as needed based on symptom relief and appearance, as well as severity of eyelid hyperkeratinization and blepharitis.

Thermal Treatments

This category of intervention has seen newer entrants in recent years, giving optometrists several systems to choose from.

- *LipiFlow* (Johnson & Johnson Vision). The oldest and most familiar of such systems, this device delivers consistent heat at 42.5°C to the inner eyelids and pulsating pressure of 5.2psi to melt and evacuate stagnant meibum. The unit consists of a desktop console that regulates the heat and pressure delivered to the patient's eyelids via sterile single-use applicators that vault over the cornea.

The advantages of this treatment are that it is hands-free and automated, both eyes are treated at the same time for 12 minutes and the applicator insertion and removal can easily be delegated to a trained technician. The downside is that applicators come in one size and the treatments are not customizable. When selecting patients, those with mild to moderate MGD show the best results with LipiFlow. Although less effective in advanced MGD, a single LipiFlow treatment session has been shown to be effective in improving meibomian gland secretion for up to three years in patients with mild to

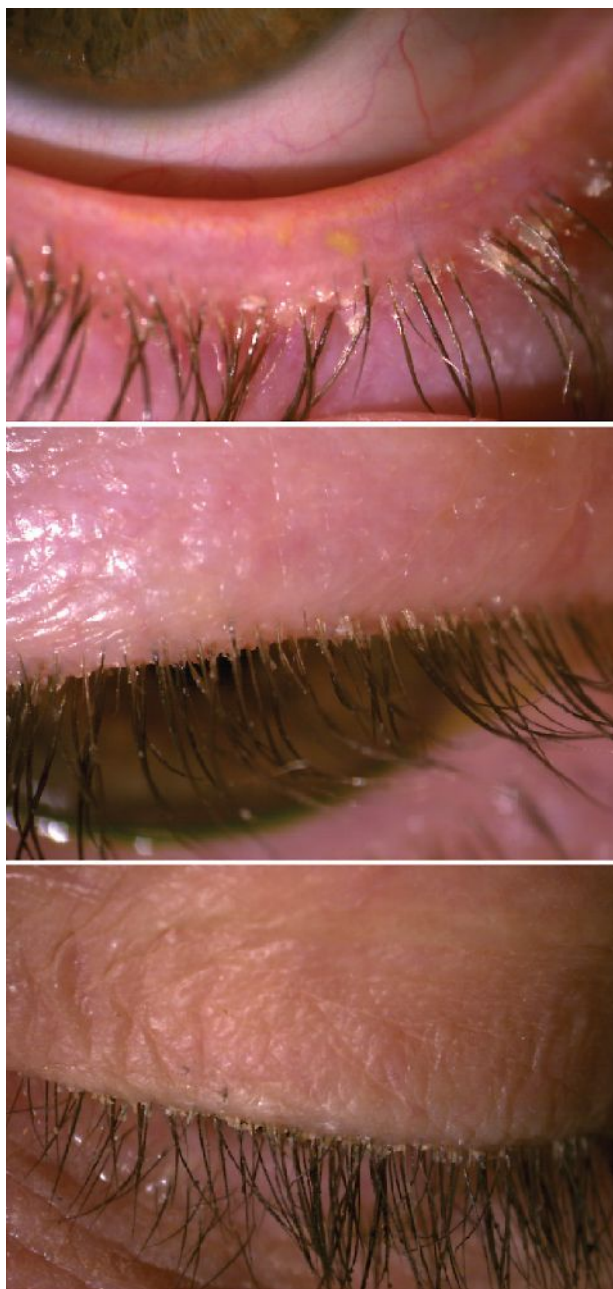

Fig. 5. Collarettes in *Demodex* blepharitis.

moderate MGD.⁸

• **Systane iLux (Alcon).** This handheld device uses single-use sterile tips to deliver LED-based therapeutic heat to the eyelids while applying pressure to evacuate the meibum. The advantages are that the unit is portable and small, and treatments are customizable if more pressure or retreatment is needed because the MG orifices and meibum excretions are visible during the procedure. The downsides are that each eye is treated separately and it can be time consuming for the doctor or practice. A single treatment with iLux has been shown to improve signs and symptoms at two weeks, lasting up to 12 weeks, and its efficacy was shown to be noninferior to LipiFlow.⁹

• **TearCare (Sight Sciences).** This is a blink-assisted thermal delivery device that consists of a small portable hub with temperature and time control and what the company calls Smart Lids, which adhere externally to the top and bottom eyelids. The treatment temperature is 45°C for 15 minutes and both eyes are treated at the same time. Patients can keep their eyes open and are instructed to do blinking exercises during treatments. MG evacuation is performed after thermal treatment using MG expressor forceps. The treatments are customizable, as the temperature and treatment time are adjustable. The effectiveness of a single TearCare treatment has been shown to last up to six months and, with retreatment, up to 12 months.¹⁰

• **MiboFlo (Mibo Medical Group).** This thermal delivery system contains a console that controls temperature and a wand with two reusable tips that can be disinfected. Ultrasound gel is used over the skin, allowing the tips to glide over the lids to distribute the temperature of 42.5°C for 12 minutes, followed by

manual MG expressions. Both time and temperature are adjustable, therefore treatments can be customized. With a new dual handpiece option, the treatments can be performed by a clinician monocularly or binocularly. The efficacy of MiboFlo treatment can last up to six months, although retreatment is often needed.¹¹

• **Radiofrequency (RF) devices.** Ablative RF has been used for decades in numerous surgical procedures, whereas non-ablative RF is used for cosmetic procedures such as skin tightening and wrinkle reduction and prevention. Radio waves at 4MHz are delivered with a single electrode in a monopolar RF, which requires a grounding pad or between two electrodes in bipolar RF. The electric current then generates heat up to 45°C in the tissue, which stimulates collagen and elastin formation. The temperature can be adjusted to safe levels when applied over the lids in a circular motion, which heats the MGs to melt thick and stagnant meibum. Plastic corneal shields can protect the ocular surface and apply backpressure on the lids to help with meibum evacuation during a monopolar RF treatment. Corneal shields are not necessary for bipolar RF.

Additionally, MG expression can be performed with MG expressor forceps after RF treatment. The benefit of this approach is that, while treating MGD, it also offers aesthetic benefits like skin tightening and wrinkle reduction in treated areas. Skin tightening around the eyelids can also result in a more adequate, full blink, assisting in the mitigation of MGD's effects. In one study comparing the effects of RF treatment to LipiFlow, both groups showed improvements in MG expressions, wax plug scoring and SPEED scores.¹²

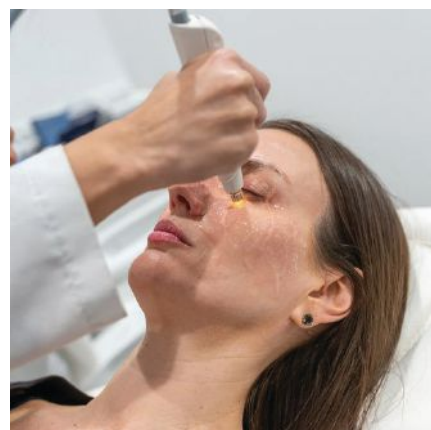


Fig. 6. A patient undergoing OptiLight intense pulsed light therapy.

Light-based Therapies

These procedures have a somewhat steeper learning curve than thermal pulsation but are increasingly embraced within eyecare. Note that ODs may not be permitted to perform these procedures in every state; be sure to check with your board before proceeding.

• **Intense pulsed light (IPL).** In 1995, this technology was cleared by the FDA to treat telangiectasia of the skin; by happenstance, dermatologists noticed that treatments near the eyes led to improvements in dry eye symptoms, and it has been used in eyecare for the past two decades. IPL uses broad wavelength non-coherent light and a series of filters ranging from 515nm to 715nm to target the skin's three main chromophores (hemoglobin, water and melanin). The proposed mechanisms of action are thrombosis of abnormal telangiectatic blood vessels on lid margin and liquefaction of meibum. The increase in skin temperature from IPL may be modest and transient. Treatment effects include reducing *Demodex* infestation, stimulating the mitochondria and thus inducing photobiomodulation, increasing the intracellular activity of the MGs and improving the microstructure and macrostructure of MG acini.¹³⁻¹⁴

Four sessions of IPL followed by MG expressions performed every two weeks are effective in treating patients with ocular rosacea and associated MGD; this protocol has been shown to significantly improve signs and symptoms.¹⁵

A Picture is Worth a Thousand Words

It can be notoriously challenging to explain meibomian glands and their functions to patients. To facilitate patient education, it is crucial to employ some form of imaging, e.g., meibography and/or anterior segment imaging with video capabilities. Patients appreciate the cause of their DED more readily when they can visualize their disease state and monitor for progression.

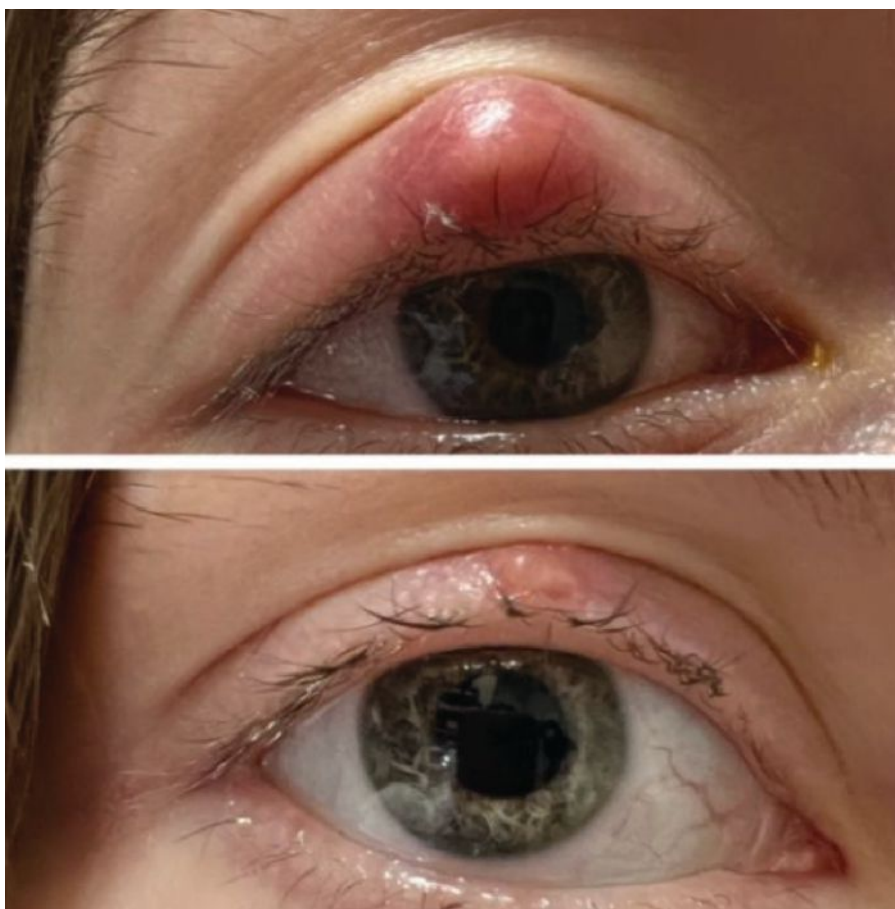


Fig. 7. Before and after chalazion treatment with the M22 IPL (Lumenis).

Treatment protocols vary; some treat the eyelid directly with corneal shields in place (off-label), while the on-label use of the OptiLight (Lumenis) is tragus to tragus white sparing the eyelids (Figure 6).

Typically, patients need at least four treatments, each separated by two to six weeks and may need one to two treatments a year for maintenance. More advanced MGD cases may need a greater number of application and a combination of IPL with thermal treatments mentioned above to effectively evacuate obstructed glands.

Patient selection is important as IPL can cause skin photosensitivity or pigimentary changes; it is contraindicated for patients on certain medications like doxycycline, those with skin conditions like melasma or darker skin types like Fitzpatrick V and VI. However, with the right patient selection, there are many advantages of IPL, as it targets

the root cause of DED by improving MG function and reducing inflammation, and it has been shown to be effective even in the most advanced cases of MGD. In addition, an off-label IPL treatment of chalazion has been shown to have similar resolution rates as excision surgery, while also preventing the recurrence of gland obstruction and improving MG function (Figure 7).¹⁶

• **Low-level-light therapy (LLLT).**

This procedure delivers red or near-infrared light from a low-power LED-based light source to treat MGD through photobiomodulation. LLLT has been used in dermatology as an adjunct to aesthetic procedures to promote wound healing, decrease inflammation and reduce pain. Equinox (Marco) offers a specially designed mask that delivers three light options to the eyelids and upper two thirds of the face: red (633nm), used for photobiomodulation of MGs, wound healing

and collagen and elastin production; blue light (400nm to 450nm), which has a bacteriostatic effect used to treat blepharitis; and yellow light (560nm to 580nm), which is used to stimulate cells' metabolism and relieve swelling.

Non-ophthalmic units adopted from aesthetic companies like Celluma are an affordable alternative used by clinicians as a standalone treatment or add-on to IPL. We find that LLLT is a great option for the pediatric population with blepharitis, chalazion and MGD, or for those who may not be a good candidate or tolerate IPL. Two treatments a week for three weeks have been shown to reduce signs and symptoms of MGD.¹⁷

Putting It All Together

Many unique challenges exist in diagnosing and managing MGD, from navigating insurance benefits to choosing appropriate treatments and perfecting your techniques in gland expressions. Let's put it all together in a sample patient encounter:

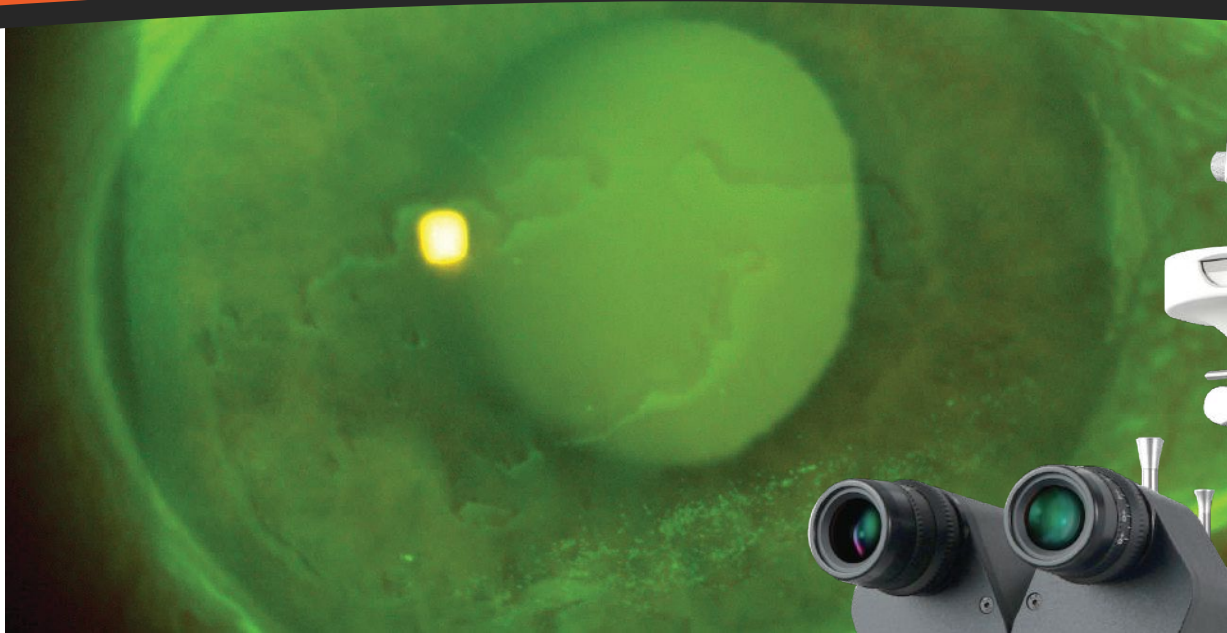
1. Consider implementing MG imaging when establishing your dry eye clinic.

Many slit lamps now offer imaging and video capabilities. There are portable meibography devices and combination units of imaging and topography available. Meibography is an invaluable tool for achieving patient "buy-in" to in-office procedures and allows them to have a tangible result in following the efficacy of their treatment plan and disease progression.

2. Address MGD at a medical visit that is billed to the patient's medical insurance carrier.

The diagnosis can be discussed briefly during a routine exam, but any related testing cannot be billed to a vision insurance plan. Anterior segment imaging or meibography is either billed for reimbursement or patients pay out-of-pocket. Offices that do not bill medical insurance carriers may opt to set an out-of-pocket fee for a DED evaluation that includes a set of imaging, such as meibography and/or corneal topography if the patient is pre-surgical. The provider may choose to include a follow-up in this fee or charge separately for each visit.

The Anterior Segment Virtuoso



Nothing performs better in the anterior chamber than the Firefly® Imaging System. Using wavelengths similar to natural light, it delineates eye anatomy with an optical resolution of 200 lp/mm.

The standard Firefly comes fully loaded with video capture, automatic exposure, artificial intelligence, meibography, and a Wratten yellow filter. Optional Dry Eye Diagnostic module.

See Firefly's online image gallery, and we're sure you'll applaud the performance. Visit eyefficient.com



FIREFLY'S ONLINE GALLERY



EYEFFICIENTSM

© 2023 EYEFFICIENT, ALL RIGHTS RESERVED

Tips for Purchasing Equipment

Consider these factors when evaluating in-office treatments:

- Cost of purchasing the equipment and any consumables.
- Reimbursement or charge to the patient.
- FDA approval (if applicable).
- State laws (applicable to IPL and RF).
- Is there a dual function? (e.g., both MGD treatment and aesthetic benefits)
- Efficacy and repeatability.
- Technician support—limited support may require more automated techniques.
- Geographic footprint—do you have enough space?

3. Patients should receive a validated dry eye questionnaire at every visit, such as SPEED, DEQ-5 or OSDI; this includes their baseline visit. A quantifiable assessment of the patient's symptoms is important for the provider to summarize a baseline of symptom severity and a tangible and standardized method of following improvements with treatments. Patients should also commit to one symptom that bothers them the most; the progress of this symptom should be assessed at every visit.

4. Assess structure and function. Perform meibography and/or anterior segment imaging of the glands and anterior segment with vital dyes. Assessment of MG function is very important and should be documented at the initial visit; i.e., inspissated, waxy or clear lipid secretions.

5. Implement a treatment plan and follow the patient closely, within three to four weeks. Assess compliance and disease state progression at each visit.

6. Upon follow-up, perform anterior segment imaging with vital dyes and MG expressibility scores. Questionnaires are performed at each visit.

Honing Manual MG Expression

We always recommend heating the MGs to the appropriate therapeutic melting temperature for a sustained period of time prior to expressing glands in-office. As previously reported, a warm compress will not achieve the therapeutic melting temperature of the meibum; rather, in-office heating should

occur with a standardized device such as the LipiFlow, TearCare, iLux or RF.⁵ Expressions are then performed within minutes of heating the glands.

MG expressor forceps, such as the Mastrota Meibomian Paddle, can be used to gently express the glands on each of the four lids. This is typically performed in the slit lamp after anesthetizing the eye. Sometimes it's easier to reach the top lids by reclining the patient at a 45° angle in the chair. All four lids should be expressed. Cotton tip applicators can certainly be used for expressions, but a dedicated paddle will allow for an easier experience for the patient and provider. When holding the paddle, we recommend a vertical/45° angle to the lid margin to access the distal portion of the glands. Circular and rectangular shapes of paddles are available.

With an especially inspissated gland, providers should sustain pressure for a few seconds longer than easily expressed glands. More force is not necessary; rather, sustained pressure and passing the gland multiple times is more effective. Debridement of the eyelid margin can provide great relief to symptomatic patients before and after manual expressions in-office.

Takeaways

MGD treatment is not only rewards patients and providers but also is an excellent practice builder. Start by understanding the literature on the pathophysiology of MGD and educate your patients on the disease state. Then, consider offering

one blepharoxfoliation and thermal/light treatment. Augment your in-office offerings with at-home products for sale and focus on improving patient symptoms with your treatment regimen. As your dry eye clinic grows, you can add more devices and expand your services. ■

1. TCY Chan, SSW Chow, KHN Wan, HKL Yuen. Update on the association between dry eye disease and meibomian gland dysfunction. *Hong Kong Medical Journal*. 2019;25(1):38-47.
2. Arita R, Fukuoka S, Kawashima, M. Proposed algorithm for management of meibomian gland dysfunction based on noninvasive meibography. *J Clin Med*. 2021;10(1):65.
3. Tomlinson A, Bron AJ, Korb DR, et al. The international workshop on meibomian gland dysfunction: report of the diagnosis subcommittee. *Invest Ophthalmol Vis Sci*. 2011;30;52(4):2006-49.
4. Bron AJ, Benjamin L, Snibson GR. Meibomian gland disease. Classification and grading of lid changes. *Eye (Lond)*. 1991;5(Pt 4):395-411.
5. Arita R, Itoh K, Iinoue K, Amano S. Noncontact infrared meibography to document age-related changes of the meibomian glands in a normal population. *Ophthalmology*. 2008;115(5):911-5.
6. Geerling G, Tauber J, Baudouin C, et al. The international workshop on meibomian gland dysfunction: report of the subcommittee on management and treatment of meibomian gland dysfunction. *Invest Ophthalmol Vis Sci*. 2011;52(4):2050-64.
7. Trattler W, Karpecki P, Rapoport Y, et al. The prevalence of Demodex blepharitis in US eye care clinic patients as determined by collarettes: a pathognomonic sign. *Clin Ophthalmol*. 2022;16:1153-64.
8. Greiner JV. Long-term (three-year) effects of a single thermal pulsation system treatment on meibomian gland function and dry eye symptoms. *Eye Contact Lens*. 2016;42(2):99-107.
9. Wesley G, Bickle K, Downing J, et al. Systane iLux thermal pulsation system in the treatment of meibomian gland dysfunction: a post-hoc analysis of a 12-month, randomized, multicenter study. *Clin Ophthalmol*. 2022;16:3631-40.
10. Gupta PK, Holland EJ, Hovanesian J, et al. TearCare for the treatment of meibomian gland dysfunction in adult patients with dry eye disease: a masked randomized controlled trial. *Cornea*. 2022;41(4):417-26.
11. Gomez ML, Afshari NA, Gonzalez DD, Cheng L. Effect of thermoelectric warming therapy for the treatment of meibomian gland dysfunction. *Am J Ophthalmol*. 2022;242:181-8.
12. Jaccoma EH, Litherland C, Jaccoma A, Ahmed AH. Pellevé vs. LipiFlow MGD-related dry eye treatment study: the TheraLid procedure. A pilot study comparing the efficacy of the Pellevé System to LipiFlow for the treatment of dry eye due to meibomian gland dysfunction. *J Dry Eye Ocu Surf Dis*. 2018;1(1):e11-21.
13. Craig JP, Chen YH, Trunbull PR. Cumulative effect of intense pulsed light therapy for meibomian gland dysfunction confirmed in prospective, double-masked, placebo controlled trial. *Invest Ophthalmol Vis Sci*. 2015;56(7):6194.
14. Cote S, Zhang AC, Ahmadzai V, et al. Intense pulsed light therapy for the treatment of meibomian gland dysfunction. *Cochrane Database Syst Rev*. 2020;3(3), CD013559.
15. Toyos R, Desai NR, Toyos M, Dell SJ. Intense pulsed light improves signs and symptoms of dry eye disease due to meibomian gland dysfunction: a randomized controlled study. *PLoS One*. 2022;17(6):e0270268.
16. Zhu Y, Zhao H, Huang X, et al. Novel treatment of chalazion using light-guided-tip intense pulsed light. *Sci Rep*. 2023;13(1):12393.
17. Park Y, Kim H, Kim S, Cho KJ. Effect of low-level light therapy in patients with dry eye: a prospective, randomized, observer-masked trial. *Sci Rep*. 2022;12(1):3575.



Unique never felt so good.

Unique pH™ is a highly effective multipurpose solution for gas permeable contact lenses that cleans, conditions, and disinfects in one bottle.

Unique pH™ conditions lenses by adjusting to the eye's natural tear pH to enhance the wettability and comfort of gas permeable contact lenses on insertion. The formula is designed to provide a soothing effect during lens wear.

Complimentary starter kits available!

ORDER ONLINE

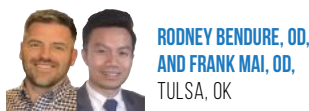

www.meniconwebstore.com



RECOGNIZE BENIGN VS. MALIGNANT EYELID TUMORS AND LESIONS

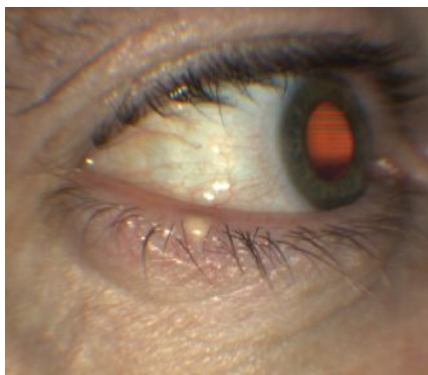
Learn how to handle these abnormalities as well as the steps needed to diagnose them.



The profession is evolving, and more optometric physicians are becoming confident with minor surgical procedures, including the management of eyelid lumps and bumps. Beginning with Oklahoma in 1998, about 17 states now privilege optometrists to perform minor surgical procedures.¹ Incorporating these procedures into practice once a state grants surgical procedures is up to the individual doctor. However, we should all have the foundational knowledge to appropriately diagnose and manage, whether that means in-house removal or referral.

Know Your Way Around

A good grasp of eyelid and adnexa anatomy is essential in the management of eyelid lesions. Though eyelid skin is the thinnest anywhere on the human body, it contains an array of structures including epithelium, muscle, fat, tarsus, conjunctiva as well as dermal adnexal structures such as eyelash hair follicles,



A sebaceous cyst of Zeis.

sweat and sebaceous glands, nerve fibers and associated blood and lymphatic vessels.² Eyelid neoplasms can derive from any of these structures.³⁻⁵

Most eyelid lesions encountered in clinical practice are benign. However, there is some variability in their clinical presentations. This can lead to overlap of characteristics even between benign and malignant lesions.⁶ Think keratoacanthoma vs. basal cell carcinoma. Interestingly, it has been reported that 2% to 4.6% of lesions diagnosed as benign clinically were found to be malignant on histological examination.^{7,8} Bearing this in mind, we try to not be too cavalier

even when we are confident making a tentative clinical diagnosis. In our office, we send a sample of all excised masses to the pathology department for confirmation.

Histologic terms such as *hyperkeratosis*, *acanthosis* and *dyskeratosis* are useful to pathologists. However, we find it more clinically advantageous to describe neoplasms on the basis of physical characteristics such as size, attachment (sessile vs. pedunculated), ulceration, variation in color, borders, changes to surrounding adnexal structures and whether loosely or firmly attached to underlying tissue.

In a world where our profession is driven to see more and more patients with ever more complex health conditions, it can be tempting to cut corners. It is, however, incumbent upon the clinician to take a few moments to grossly observe the patient prior to moving on with the eye exam. Much can be gleaned by looking at basic symmetry or the condition of exposed skin of other parts of the body during a face-to-face history.

If you find a lesion of interest, take a pertinent history. Onset, evolution

About the authors

Dr. Bendure is a staff optometrist and externship coordinator at Ernest Childers VA Outpatient Clinic in Tulsa, OK. He is a fellow of the American Academy of Optometry. **Dr. Mai** is a staff optometrist and residency supervisor at Ernest Childers VA Outpatient Clinic in Tulsa, OK. He completed his ocular disease residency at Jack C. Montgomery VA Medical Center in Muskogee, OK, and is a fellow of the American Academy of Optometry. They serve as adjunct faculty at Northeastern State University Oklahoma College of Optometry, Arizona College of Optometry and Chicago College of Optometry. They have no financial disclosures.

LESION TERMINOLOGY²

Bulla. A large (more than 0.5cm) serous fluid-filled lesion.

Crust. Solidified serous or purulent exudate.

Cyst. A nodule consisting of an epithelial-lined cavity filled with fluid or semisolid material.

Macule. Localized area of color change without infiltration, depression or elevation, less than 1cm in diameter.

Neoplasia. Abnormal tissue growth, either benign (localized, non-invasive and non-spreading) or malignant (progressive growth with the potential for distant spread).

Nodule. A palpable solid area measuring more than 1cm.

Papilloma. A benign neoplastic tag or wart-like projection of the skin or mucous membrane.

Papule. A solid elevation less than 1cm in diameter.

Plaque. A solid elevation of the skin, greater than 1cm in diameter.

Pustule. A pus-filled elevation less than 1cm in diameter.

Scale. Readily detached fragments of shed keratin layer.

Tumor strictly refers only to a swelling, though is commonly used to denote a neoplasm.

Ulcer. A circumscribed area of epithelial loss. In skin an ulcer extends through the epidermis into the dermis.

Vesicle. Circumscribed lesion containing serous fluid (less than 0.5cm across).

THE ABCs OF CUTANEOUS NEOPLASMS

A: Asymmetry. Draw a line through the lesion. Are both sides symmetric?

B: Regular borders suggest benign lesions, whereas malignant lesions tend to have irregular borders.

C: Uniform color is associated with benign lesions. Color variations in a neoplasm suggest malignancy.

D: Lesions larger than 6mm in diameter should raise suspicion of malignancy.

E: Evolution. Changes such as rapid growth, bleeding, crusting and local tissue changes such as loss of lashes warrant biopsy.

Size and depth are the two most important prognostic indicators for malignancy.¹⁰

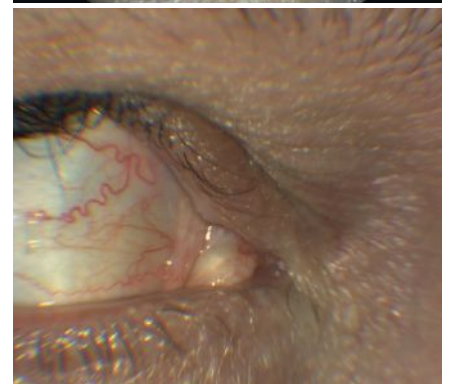
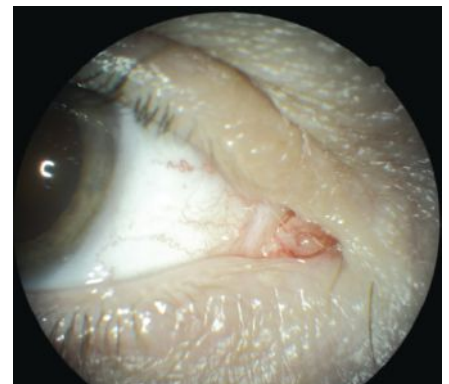with associated lymphadenopathy. Gauge symmetry to the corresponding node on the opposite side of the head. Photo-documentation is invaluable for monitoring progression.

Benign Epithelial Neoplasms

These kinds of eyelid lesions are six- to eight-times more common than malignant.¹¹ Due to the variety of tissue types contained within the eyelids, there are a multitude of possibilities. For the sake of brevity, we will discuss only some of the most common types seen in clinical practice.

Squamous papillomas, commonly referred to as “skin tags,” are flesh-colored growths consisting of squamous hyperplasia within the epithelium. They may be sessile (broad-based attachment) or pedunculated (on a stalk). Removal by simple excision may be performed for cosmesis or effects on vision.^{2,5}

Seborrheic keratosis (SK) typically affects older individuals. These appear



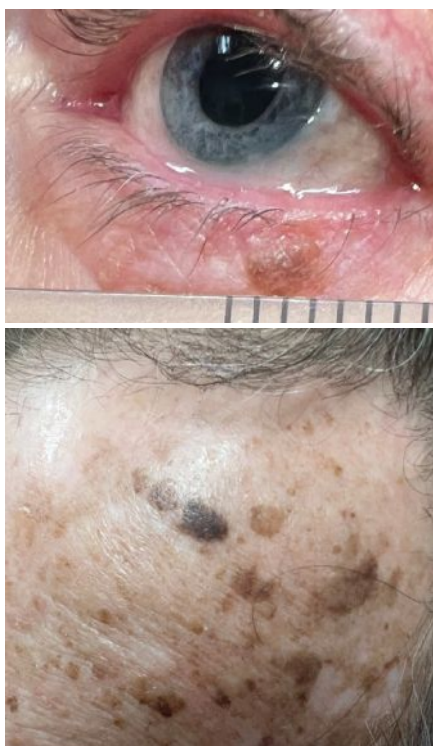
At top, mass in the caruncle right eye. Lesion was biopsied with histologic report of squamous papilloma. At bottom, 18 months post-op. Note the scar tissue.

(changes to the lesion over time such as rapid growth, bleeding, crusting, loss of lashes) and changes or variations in color should be assessed. Bear in mind

fair complexion, history of excessive sun exposure, prior radiation treatment and especially a personal history of skin cancer would increase suspicion of malignancy.³

A closer look with a slit lamp biomicroscope can enhance your ability to evaluate lesion characteristics. Pay close attention to the overall appearance as well as the surrounding skin and adnexal structures. Normal eyelid structure loss such as madarosis (loss of lashes), poliosis (absence of pigment within the lashes), tylosis (thickened eyelid margins) or deformation of lid position should raise suspicion of malignancy.⁹ Palpate the lesion and area immediately surrounding to determine whether the lesion is moveable or attached firmly to underlying tissue, and also assess regional lymph nodes for possible involvement. This step is often overlooked, but some malignancies such as squamous cell carcinoma can metastasize to nearby organs via lymph nodes

as elevated, pigmented, crusty, greasy, stuck-on plaques. While benign, a sudden increase in number or size could indicate a systemic malignancy. They develop from intradermal proliferation of basal cells within the epidermis. Treatment is complete excision.^{2,5}



This lesion could be mistaken for a junctional nevus, demonstrating overlap in clinical characteristics. However, it was confirmed histologically to be an SK. At the bottom is an image of numerous SKs on the forehead of the same patient.

Epidermal inclusion cysts are slowly enlarging keratin filled cysts. They can be removed by excision and curettage.³

Verruca vulgaris, also known as viral wart, is an epidermal growth caused by the human papilloma virus. There are two forms of verruca: ones that project in a finger-like nature from their base called filiform or digitate, and plana, which are flat in appearance. Beginning as small papules slightly lighter than the surrounding skin, they tend to darken and become hyperkeratotic with time. While benign, eyelid margin warts can cause punctate keratitis or even corneal pannus. Observation is often adequate, as these lesions tend to eventually outgrow their blood

supply and spontaneously involute. Otherwise, they may be removed by excision, cryotherapy or chemical cautery if eye irritation ensues or for cosmetic reasons.¹²

A *chalazion*, which is typically secondary to an internal hordeolum, is a sterile, chronic eyelid lipogranuloma that forms after an infected meibomian gland ruptures and releases sebum into the surrounding tarsal tissue. They are associated with chronic blepharitis, meibomian gland dysfunction, seborrhea, acne rosacea and *Demodex* infestation of the sebaceous gland.¹³

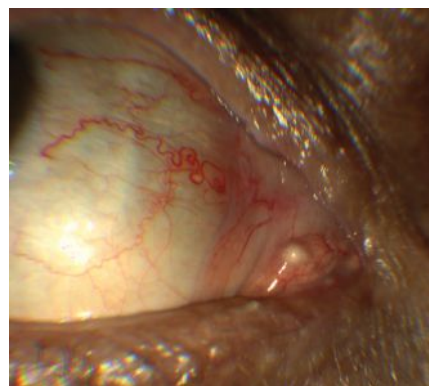Molluscum contagiosum, associated with the DNA poxvirus, is characterized by small, typically 1mm to 2mm, flesh-colored papules often with an umbilicated center. More common in the very young and in immunocompromised patients, these marginal eyelid lesions can cause follicular conjunctivitis and are spread by skin-to-skin contact. Normally they eventually regress spontaneously, except in the immunocompromised, where they can develop into disfiguring lesions. In healthy individuals, the prognosis is good, and the risk of transmission is low.¹³

Pyogenic granuloma presents in the form of a pinkish or red, vascularized mass that protrudes from the conjunctiva. These rapidly growing, delicate lesions are typically a response to local trauma and are composed of blood vessels and fibroblasts and readily bleed with minor insult.⁶

Ephelides, more commonly known as freckles, are small 1mm to 3mm tan or brown macules present in sun-exposed areas of the skin. They tend to occur more frequently in individuals with light skin pigmentation and worsen with sun exposure. No treatment is necessary, but if there is a cosmetic concern, sun protection can minimize their appearance.⁶

Sebaceous or pilar cysts are caused by blocked pilosebaceous follicles containing sebum. They may arise from glands of Zeis within the eyelashes, from meibomian glands or from sebaceous glands associated with hair follicles.²

Eccrine hidrocystomas/sudoriferous cysts are small, smooth and translucent nodules on the lid skin, not involving the margin. Associated with sweat glands, these cysts



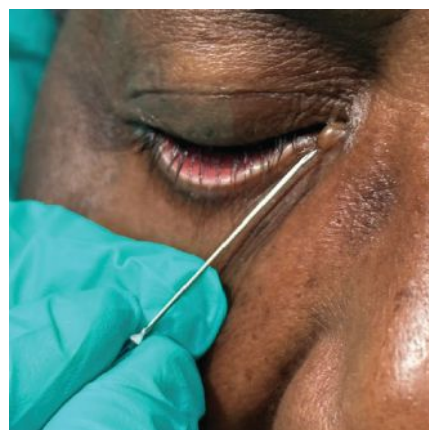
A case of a sebaceous cyst on the right caruncle of this 67-year-old Caucasian male. Although rare, they may occasionally occur on the inner canthus including the caruncle and within thin (vellus) eyebrow hairs over the periocular skin.²

often increase in size during hot and humid weather. They can be lanced and drained, but often recur unless they are excised. A similar lesion, apocrine hidrocystoma, is a translucent, milky cyst on the eyelid margin. These do not typically enlarge during hot, humid weather.²

Premalignant Epithelial Neoplasms

These are precancerous lesions according to histologic findings.

Actinic keratosis (AK), also known as solar keratosis, is a pink or red, scaly lesion common on sun-exposed areas



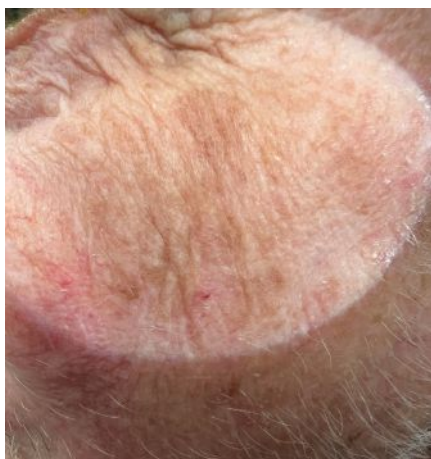Eccrine cyst drainage. Definitive treatment is complete excision. However, we have found simple incision and drainage more tolerable for patients and also note that, though they can, they don't often recur. If they do, a repeat drainage seems to reduce recurrence, presumably from development of scar tissue within the sac.

of the skin such as the face, scalp, and hands. It can sometimes occur on the eyelid.³ Some 25% of cases develop into squamous cell carcinoma.⁹

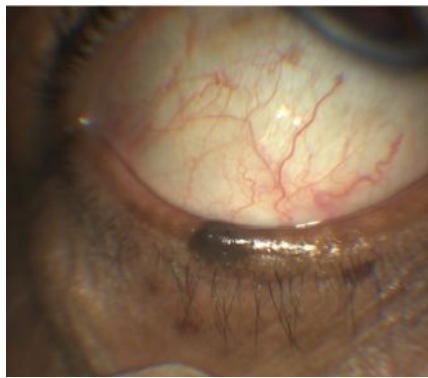
Keratoacanthomas appear as rapidly growing papules with a central keratin-filled core in elderly or immunocompromised individuals. They can resolve over several months. Complete excision is recommended due to an approximately 12% risk of conversion to squamous cell carcinoma.³

Lentigos are caused by a proliferation of melanocytes (as opposed to ephelides, which are caused by an increase in melanin production by a stable number of melanocytes). Lentigo maligna, a precancerous lesion, should be differentiated from solar lentigo, in that the former has more irregular borders, variations of color and notching. Excisional biopsy of lesions suspicious for maligna should be performed by an oculoplastics specialist and include 5mm wide margins as frozen sections, as 10% of melanomas of the eyelids originate from maligna.^{3,6}

Melanocytic nevi arises in childhood from a proliferation of nevocytes within the epidermis at the junction of the epidermal-dermal border (junctional nevus). Interestingly, nevocytes are capable of producing melanin, like melanocytes. Over time, these cells migrate partially into the dermis (compound nevus) and



Solar lentigos and areas of actinic keratoses. These evenly hyperpigmented macules should be differentiated from the precancerous maligna, which has variable pigmentation and even more irregular borders.⁶



This pigmented lesion was reportedly unchanged since childhood. Note the functioning meibomian glands, normal lashes and general lack of dysplasia. We opted to photograph and monitor this and the associated small ephelides on this patient's lower eyelid.

finally reside fully within the dermis (intradermal nevus).⁶

Malignant Epithelial Lesions

Although benign lesions of the lids are six- to eight-times more common than malignant ones, some 5% to 10% of all skin malignancies occur on the eyelids. This may be because the eyelid is quite thin and also one of the most sun-exposed areas of the body.¹⁵

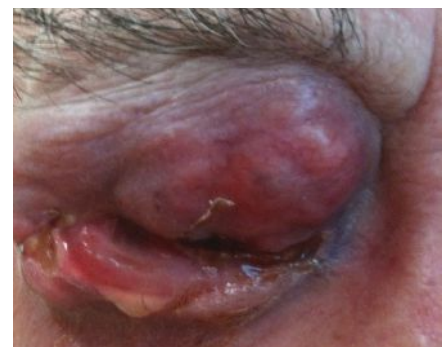The most common type of eyelid skin cancer—about 90% of malignancies—is basal cell carcinoma (BCC). These originate in the basal layer of the epidermis and usually affect older, fair-skinned individuals with a history of chronic sun exposure. BCC demonstrates an affinity for the lower eyelid (50% to 60%) and medial canthus (25% to 30%) and manifests a low likelihood of systemic spread (less than 1% incidence of metastasis). However, local invasion can occur, and those located near the medial canthus can spread via anatomic fissures into the orbit and sinuses, making management more difficult.

Forms include nodular, nodulo-ulcerative and sclerosing. Despite these varying appearances, BCC typically presents in its classic form as a firm, pearl papule with superficial telangiectasia at the early stage. In later stages, it may present with central ulceration and necrosis. Complete excision is

recommended, with clear sections, in order to prevent recurrence, which is often aggressive.^{2,9}

Squamous cell carcinoma (SCC) is less common, accounting for 5% to 10% of malignant eyelid neoplasms. However, it tends to be more aggressive, with spread to local lymph nodes in approximately 20% of cases. SCC can also spread along nerves into the orbit and even intracranially. It is a malignancy of the stratum spinosum layer of the epidermis and rarely contains superficial telangiectasia. Like BCC, SCC occurs in older individuals with a history of chronic sun exposure. Types include nodular, ulcerating and cutaneous horn. SCC classically presents as a rough, scaly and/or ulcerated erythematous plaque. It may be flat or elevated and is most commonly located on the lower eyelid margin.^{2,9}

Sebaceous gland carcinoma (SGC) is a rare and slow-growing tumor with a predilection for the upper eyelid. It typically affects elderly females, and may also be associated with previous radiation therapy. Originating from meibomian glands or glands of Zeis, the classic presentation is a yellow, firm mass in the upper eyelid, often with associated madarosis and tylosis. These tumors can be mistaken for internal hordeola in their early stages, thus



This patient presented for an eye infection. Reportedly the mass had been growing for over a year, but he and his family had not addressed it due to his poor health. The patient was commencing hospice for a terminal condition (not cancer related) and the patient, wife and their daughter refused any services specific to the tumor, requesting only antibiotics for the associated blepharoconjunctivitis.



Example of a radiofrequency device in our office.

recalcitrant or recurrent cases should arouse suspicion. As mentioned previously, SGC are associated with poor prognosis with an overall mortality rate of 5% to 10%, but lesions greater than 2cm are associated with a 60% mortality rate. Symptomatic lesions present for longer than six months are associated with a 38% mortality rate.^{2,9}

Melanomas are rare, accounting for only 1% of eyelid malignancies, yet are highly aggressive and potentially lethal. Despite their relative paucity, cutaneous melanoma accounts for two-thirds of all skin cancer-related deaths.⁶ They develop secondary to dysplasia of melanocytes in the epidermis.⁹ Though an image of a pigmented lesion comes to mind when thinking of these lesions, about 50% are initially non-pigmented. By the time the patient presents to clinic, they usually have irregular borders, uneven pigmentation and a history of rapid growth. Wide-margin excision, with inclusion of regional lymph nodes, is effective in localized forms. For those

with significant metastasis, survival rates are poor.²

Excisional Biopsy Protocols

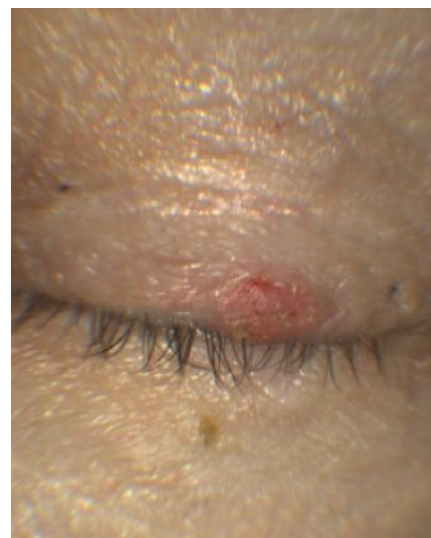Lesions with a high degree of symmetry, regular borders, even pigmentation, no disruption in normal lid anatomy and lack of ulceration, are more likely benign and can be considered for in-office excision. We recommend that a representative sample of all lesions excised be sent to the lab for pathological confirmation.

Before performing any surgical procedure, be sure to review drug allergies, discuss the risks, benefits and alternatives with the patient, and obtain informed consent with appropriate signature(s). If infiltrative anesthesia is required, inform the patient of a brief pinching sensation followed by mild burning associated with the injection. For appropriate infection control, wear sterile latex or nitrile gloves and proper eye protection. Position the patient comfortably for the procedure. You may need to recline the patient to a secure supine position to allow for easy access to the lesion. In a case such as this, where the procedure is not performed behind the slit lamp, magnifying loops can be helpful.

Consideration of the lesion base with underlying skin will determine the type of excisional technique you should use. Pedunculated lesions with smaller diameter stalks (usually 1mm to 2mm) or slightly larger can simply be removed by simple excision, often without the use

of anesthetic. Larger diameter or flat-based lesions tend to require anesthesia for pain control. First, prep the area with ophthalmic Betadine. Next, inject 1% to 2% lidocaine with epinephrine 1:100,000 subcutaneously using a 27- or 30-gauge, 1/2- to 5/8-inch needle attached to a 3mL syringe. Remember to check blood pressure and pulse prior to injecting any preparation containing epinephrine. We tend to use a “bevel-down” technique for eyelid anesthesia to avoid penetrating too deeply. To ensure you’ve adequately infiltrated the tissue, you may need to retract the needle partially while still within the lesion, then orient in a different direction to inject additional anesthetic, noting slight elevation of the tissue all around the base of the lesion. Always remember when performing injections that you should pull back on the plunger before pushing it down to ensure you don’t get a flash of blood, suggestive that you’ve entered a blood vessel.

Check that the area is numb by pinching the base of the mass with your toothed forceps. Pull the lesion slightly upward away from the base placing tension on the base of the lesion and underlying skin. Position the curved-tipped scissors parallel to the



The above lesion remained after antibiotic treatment for blepharitis. The report from an oculoplastics ophthalmologist describes an inflamed SK and treated by kenalog injection.

TREATMENT FOR EYELID LESIONS

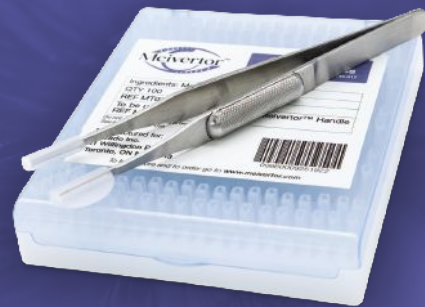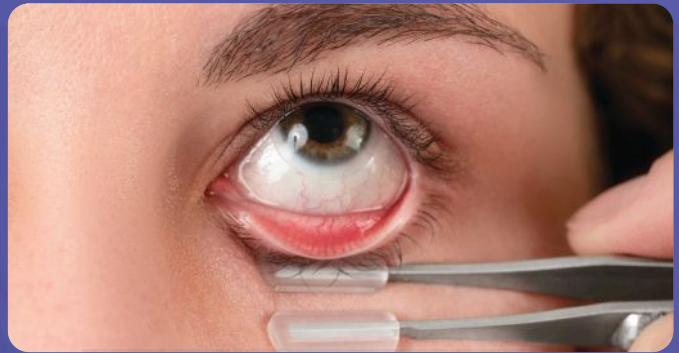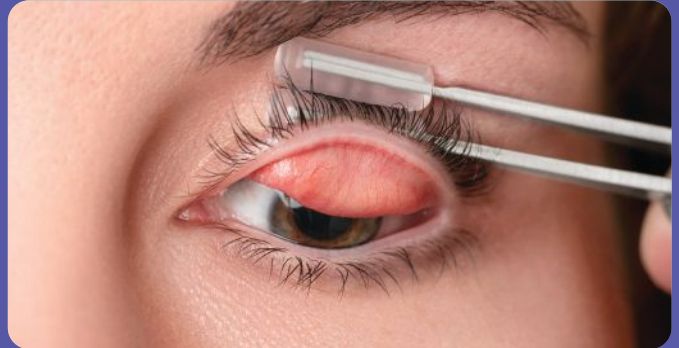- Incisional biopsy involves removal of a portion of a lesion for histopathology.
- Excisional biopsy is performed on small tumors and fulfills both diagnostic and treatment objectives.
- Marsupialization involves the removal of the top of a cyst allowing drainage of its contents and subsequent epithelialization.
- Hyfrecation uses a low powered electrosurgery device to destroy tissue.
- Ablation by laser or cryotherapy.
- Radiofrequency devices such as those provided by Ellman and Sonique are capable of cutting, coagulating and fulgurating (destruction) of lesions.



US Patent 11,446,017

The ONLY SINGLE-HANDED UPPER and lower eyelid EVERSION TOOL

- Optimize the functionality of your meibographer
- Empower your technician to take the images you need – flipping a lid has never been easier
- Whenever you evert an upper eyelid – AND need a free hand – use your Meivertor



“Amazingly well designed, incredible balance to the instrument, and ease of use. I would recommend every technician who does meibography have one.”

-Dr. Paul Karpecki, OD, FAAO

“Love the Meivertor. First true game changer in the meibography game in my opinion.”

-Dr. Bradley Barnett, MD

“The Meivertor is a terrific product that has become one of my staff’s favourite in a very short time!”

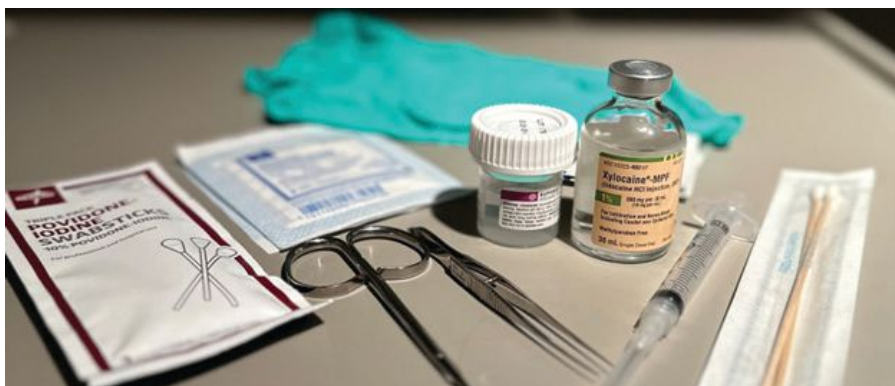-Dr. Kimberly K. Friedman, OD, FAAO

“Anyone struggle with lid eversion for meibomian gland imaging? Try using the Meivertor. Teaching techs has been a breeze and we can image both the upper and lower lids with ease!”

-Dr. Preeya Gupta, MD



For more information and to purchase go to meivertor.com



Some examples of surgical equipment useful for in-office lesion removals.

skin surface, tips away from the patient, straddle the base of the stalk and snip the lesion at the junction of the base and skin surface. If minor bleeding occurs, apply firm and direct pressure with a sterile gauze pad or cotton-tipped applicator.

For significant or persistent bleeding, consider using thermal cautery. Place the excised lesion in the formalin container suitable for transport to the laboratory for histologic evaluation. Prior to releasing the patient, apply a broad-spectrum ophthalmic antibiotic ointment to the epithelial defect. Advise the patient to keep the area clean and dry and instruct the patient to apply the ointment three times daily for a few days post-procedure. We recommend non-aspirin oral analgesics for patients with any residual discomfort or irritation.

We prefer to refer lesions with malignant characteristics or those involving the lid margin to an oculoplastics ophthalmologist for evaluation, biopsy and reconstruction if needed. Alternatives to excision include epidermal curettage, chemical removal with dichloroacetic acid, chemotherapy, radiation or photodynamic therapy, as well as cryogenic therapy such as Mohs micrographic surgery.¹²

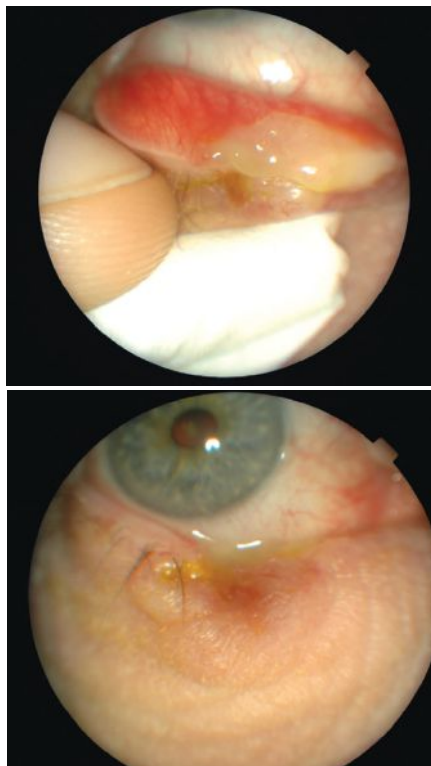
Case #1

A 67-year-old Caucasian male farmer was referred for a recurrent sty of the right eye. He had received a prescription from his primary care physician for a topical antibiotic cream twice in the past two years for the same lesion, which he reported as a scab which eventually fell

off and left a “raw” spot on his eyelid that never resolved.

We noted a lesion with raised borders, central ulceration and telangiectatic vessels. When we everted the lower lid, there was apparent dysplasia of the palpebral conjunctiva. Notably, he had a personal history of two skin cancer removals and carcinoma *in situ* of the anus. The patient was tentatively diagnosed with malignant neoplasm of the right lower lid and referred to a local oculoplastics ophthalmologist for biopsy.

The patient underwent excisional biopsy with Mohs procedure and was



Case 1, recurrent hordeolum removal.

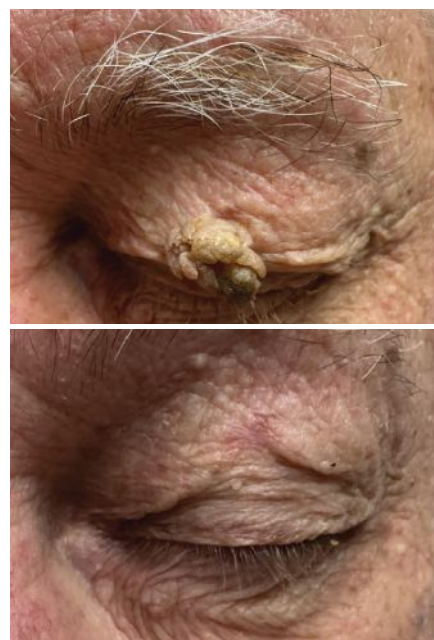
diagnosed with infiltrative basal cell carcinoma, which involved much of the lower right eyelid and punctum. He underwent reconstruction using a rotational flap from the upper right lid and reconstruction of his lower punctum and canaliculus using a silicone tube. At follow-up, the patient verbalized that he was quite pleased with the outcome. We continued to follow the patient until his death in 2021, with no evidence of recurrence.

Case #2

A 70-year-old healthy white male presented with a recurrent mass on his left upper eyelid, which he had removed himself using toenail clippers over a decade prior. The lesion had since slowly regrown, absent bleeding, pain, or change in color. After obtaining informed consent, the base of the lesion was anesthetized, and the lesion was removed by simple excision. The histologic pathology report diagnosed verruca vulgaris. Four-week follow-up reveals healing scar tissue at the site of the lesion.

Case #3

A 76-year-old Caucasian male presented with a complaint of a cyst of the lower left eyelid, reporting it had been



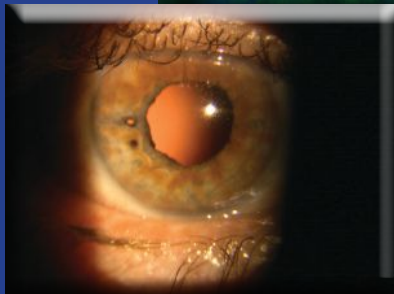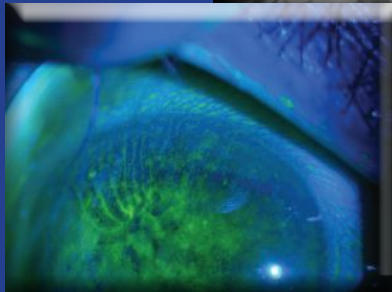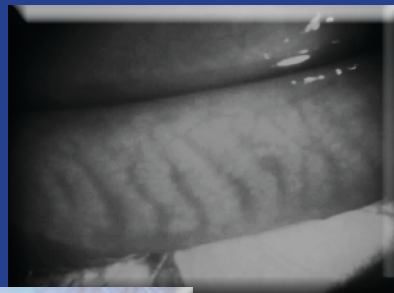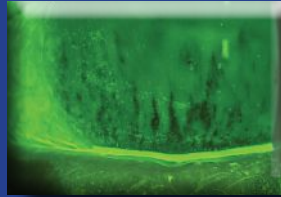

Case 2, recurrent verruca.

EyeRes™

Digital Imaging Systems

by **TelScreen**

Slit Lamps • Digital Imaging Systems for Lasers and Slit Lamps • Functional Meibography



Gold

Platinum

Diamond



@telscreen



@telscreen



Find the imaging system that fits your budget at TelScreen.

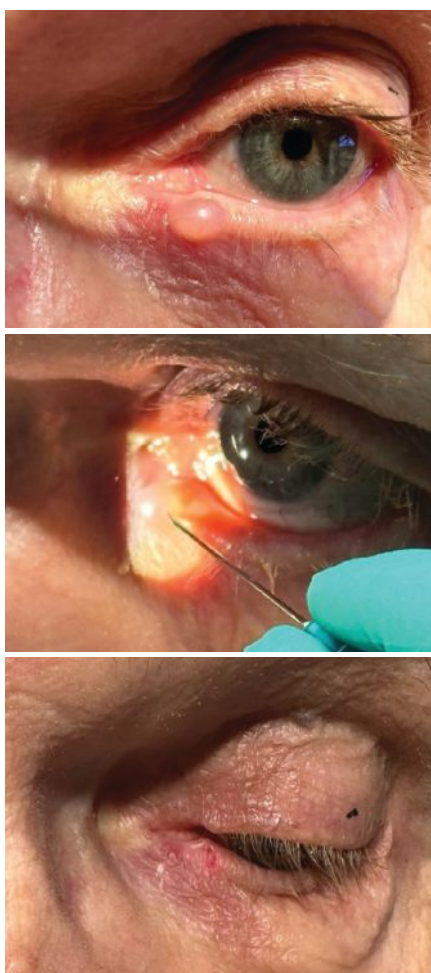info@TelScreen.com

stable for several years. This eccrine cyst was drained in-office with a sterile 32-gauge needle and cotton-tip applicator behind the slit lamp.

Case #4

A 78-year-old Caucasian male presented for a general exam with a secondary complaint of a small “bump” under his left eye. It had been stable for one to two years, no rapid growth, bleeding, changes in color or pain. Inspection in the slit lamp revealed a small lesion with mildly elevated rim tissue and an umbilicated center. The veteran requested to have it removed.

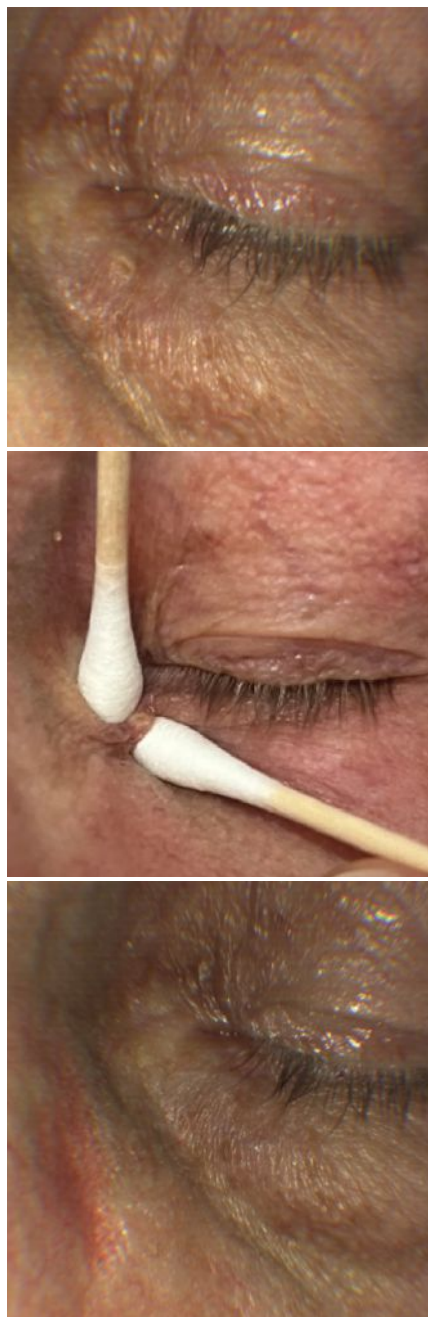We were able to efficiently express the entire contents. In this case, we did not send the expressed material to the lab for confirmation, but for a recurrent case, we would. We ensured complete resolution had occurred at a follow-up two weeks later.



Case 3, eccrine cyst drainage.

What about when you just aren't sure? We've all been there: a patient presents with lackluster history skills and a lesion about which you are on the fence. Is it infectious, inflammatory, benign or malignant?

In cases such as this, when the patient can't give a clear answer as to onset, associated symptoms, duration or evolution, we often opt to photograph, treat with the appropriate antibiotic and have the patient back in a number



Case 4, mildly elevated lesion.

of weeks to determine if any changes have taken place. Note, it is best to use a ruler to document size.

Takeaways

On any given day, the optometrist will encounter a variety of eyelid lumps and bumps. While most of these are benign and carry only a cosmetic concern, some will present with malignant characteristics. Whether you intend to include surgical procedures in your repertoire, mastering the diagnosis and management of eyelid lesions is one way to achieve the superior level of care our patients expect and deserve. ■

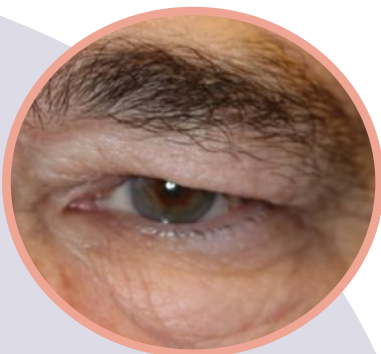
- Schneider J, Scheibling C. Optometry's essential and expanding role in health care: assured quality and greater access for healthier communities. Avalon Health Economics. www.aoa.org/AOA/Documents/Advocacy/state/Optomtery%27s%20Essential%20and%20Expanding%20Role%20in%20Health%20Care-Final%20Report%20%28002%29.pdf. June 12, 2019. Accessed July 23, 2023.
- Salmon JF. Kanski's Clinical Ophthalmology: A Systematic Approach. 9th ed. Edinburgh: Elsevier; 2020.
- Onofrey BE, Skorn L, Holdeman NR. Ocular Therapeutics Handbook a clinical manual. Wolters Kluwer; 2020.
- Remington LA. Clinical Anatomy and Physiology of the Visual System. St. Louis, Missouri Butterworth-Heinemann; 2012.
- Gawkrödger DJ, Ardern-Jones MR. Dermatology: An Illustrated Color Text. 7th ed. Elsevier; 2021.
- Yanoff M, Duker JS. Ophthalmology. 6th ed. Elsevier; 2022.
- Kersten RC, Ewing-Chow D, Kulwin DR, Gallon M. Accuracy of clinical diagnosis of cutaneous eyelid lesions. Ophthalmology. 1997;104(3):479-84.
- Margo CE. Eyelid tumors: accuracy of clinical diagnosis. Am J Ophthalmol. 1999;128(5):635-6.
- Friedman NJ, Kaiser PK, Pineda R. The Massachusetts Eye and Ear Infirmary. 4th ed. Elsevier; 2014.
- Fitzpatrick TB, Johnson R, Wolff K, Suurmond R. Color Atlas and Synopsis of Clinical Dermatology. 4th ed. McGraw-Hill, St. Louis, 2001.
- Deprez M, Uffer S. Clinicopathological features of eyelid skin tumors: a retrospective study of 5,504 cases and review of literature. Am J Dermatopathol. 2009;31(3):256-62.
- Casser L, Fingeret M, Woodcome H, et al. Atlas of Primary Eyecare Procedures. 2nd ed. Appleton & Lange; 1997.
- Penne R. Oculoplastics. 2nd ed. Wolters Kluwer Health/Lippincott Williams & Wilkins Health; 2012.
- Bolognia JL, Shaffer JV, Duncan KO, Ko CJ. Dermatology Essentials. Elsevier, 2022.
- Cook BE Jr, Bartley GB. Epidemiologic characteristics and clinical course of patients with malignant eyelid tumors in an incidence cohort in Olmsted County, Minnesota. Ophthalmology. 1999;106(4):746-50.
- Landow, SM, Oh DH, Weinstock MA. Teledermatology within the Veterans Health Administration, 2002-2014. Telemed J E Health. 2015;21(10):769-73.

BEYOND AESTHETIC CONCERNS:

THE IMPORTANCE OF RECOGNIZING AND MANAGING BLEPHAROPTOSIS

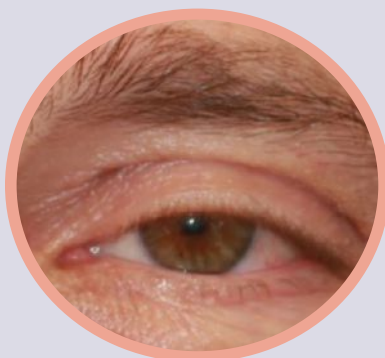
▶ **DERMATOCHALASIS**

Dermatochalasis of the upper eyelid refers to redundant skin.



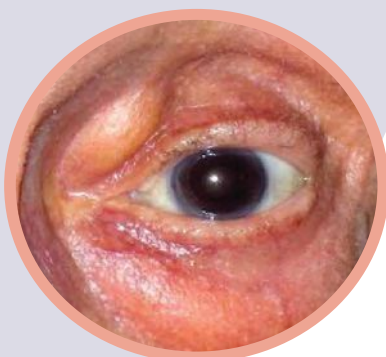
▶ **PTOSIS**

Ptosis indicates a low upper eyelid position.



▶ **STEATOBLEPHARON**

Steatoblepharon is anterior herniation of the orbital fat.



The eyes serve as a crucial focal point during social interactions. The skin surrounding the eyes is the thinnest on the body and often exhibits the initial signs of aging and fatigue. As individuals age, fine lines and deeper creases (rhytids) develop on the face due to sun damage and collagen remodeling, transforming lines of facial expression into permanent static creases. The eyelid skin loses its elasticity, leading to redundant upper lid skin that may overhang the eyelashes (dermatochalasis). The brows lose volume and descend, particularly laterally, contributing to “lateral hooding.” Progressive attenuation of the orbital septum permits orbital fat to herniate into the eyelids (steatoblepharon), causing the eyelids to appear puffier, especially medially, where the nasal fat pads may become quite prominent. Eyelid laxity develops, predisposing individuals to lower

SPONSORED BY

RVL
PHARMACEUTICALS

This educational material was developed with Mednetrin, LLC, “Educating and empowering patients and providers”.

Sponsored supplement published in the October 2023 issue of Review of Optometry

Table of Contents

3. Evaluating Ptosis in the Clinic

5. Ptosis Classification

8. Eyelid Metrics

10. Addressing An Often-Overlooked Condition

11. Ptosis Visual Field Loss Can Be Additive to Visual Field Loss from Other Conditions

11. Ptosis and Visual Field Loss

eyelid malposition (e.g., retraction, ectropion, or entropion). Thinning or stretching of the levator aponeurosis or separation from the tarsal plate results in ptosis (aponeurotic ptosis). Consequently, many individuals seek eyelid plastic surgeons to enhance their appearance and improve their vision by addressing issues such as overhanging skin (dermatochalasis) and low-lying upper eyelids (ptosis).¹

‘Blepharoptosis, or “ptosis,” is a prevalent eyelid disorder characterized by the abnormal drooping of the upper eyelid in primary gaze. Ptosis typically arises when the levator muscle detaches from its eyelid insertion and can manifest as unilateral or bilateral, congenital or acquired.¹ With a reported prevalence ranging from 4.7% to 13.5% in adults, its incidence increases with age.¹ Although acquired ptosis is frequently observed in clinical settings, it is crucial to conduct a differential diagnosis during patient evaluation to rule out severe neurologic or orbital diseases. If left unaddressed, ptosis can result in appearance-related anxiety, depression, and deficits in the superior visual field.^{2,3}

Assessments of the superior visual field using static perimetry testing, such as the Humphrey visual field test, demonstrate that even mild ptosis can lead to significant impairment, which exacerbates with moderate ptosis.⁴ This impairment can heighten the func-

tional burden for patients with glaucoma or geographic atrophy and potentially confound visual field findings. Additionally, ptosis patients experiencing visual field impairment may face a decline in health-related quality of life due to reduced independence and increased difficulty in driving and performing everyday tasks.²

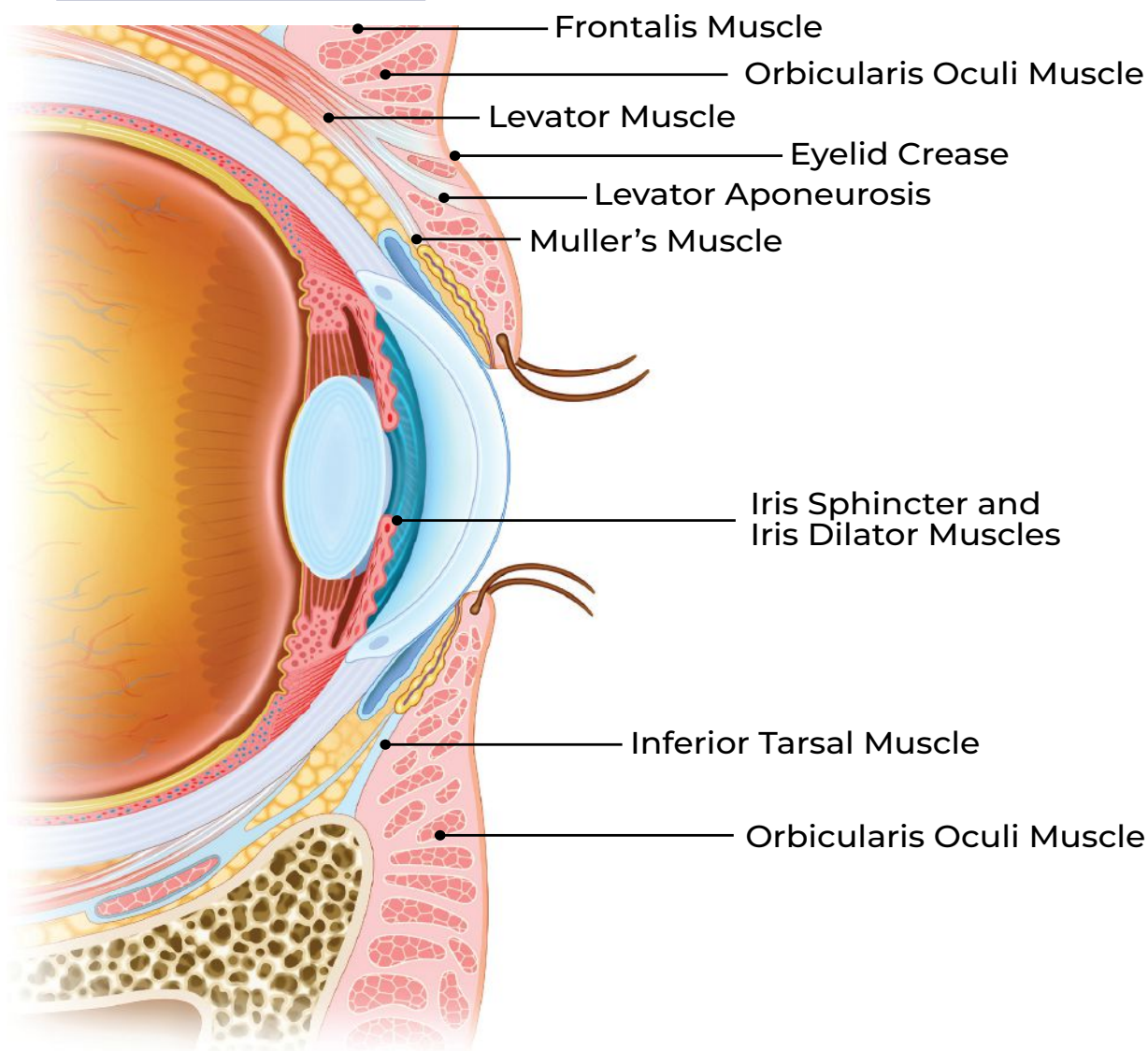
As individuals age, fine lines and deeper creases (rhytids) develop on the face due to sun damage and collagen remodeling, transforming lines of facial expression into permanent static creases.

Fortunately, eye care professionals can easily recognize and evaluate ptosis by understanding basic anatomy and employing simple evaluation strategies.¹ This knowledge equips clinicians to more effectively explain the condition to patients and identify those who may benefit from medical therapy or referral to an oculoplastic surgeon. This monograph focuses on the clinical assessment of the eye zone, with an emphasis on adult ptosis. The images and tables provided present multiple complementary perspectives on periocular anatomy. Designed for efficient review, it is intended to serve as a valuable future reference.

EVALUATING PTOSIS IN THE CLINIC

To effectively evaluate and manage ptosis, it is crucial to possess a comprehensive understanding of the regional eyelid anatomy, not only the protractors (elevators) of the eyelid. The primary protractor of the eyelid is the orbicularis oculi muscle, which is divided into orbital and palpebral components. The orbital component assists in voluntary forced lid closure, while the palpebral component aids in involuntary lid closure.

► EYELID ANATOMY



The following table serves as a useful reference to identify the periocular muscles.

EYELID ANATOMY						
Periocular Muscle	Innervation	Receptors	Type of Muscle	Action	Disorders Involving This Muscle	Comments
Levator Muscle	3rd cranial (oculomotor) nerve—superior division	Nicotinic cholinergic and beta 1 adrenergic	Striated	Elevates and retracts upper eyelid	3rd nerve palsy, aponeurotic ptosis, botulinum toxin injection, myasthenia gravis, various myopathies	Primary lid elevator, under volitional control
Müller's (Superior Tarsal) Muscle	Sympathetic nervous system	Alpha 1D > beta 1 > alpha 2C > beta 2 adrenergic	Smooth	Elevates and retracts the upper eyelid	Horner syndrome	Secondary lid elevator, autonomically innervated, typically only contributes 1-2mm to upper lid elevation.
Inferior Tarsal Muscle	Sympathetic nervous system	Alpha 2 and beta 1 adrenergic receptors	Smooth	Retracts the lower eyelid	Horner syndrome	
Frontalis Muscle	7th cranial (facial) nerve—frontal (temporal) branch	Nicotinic cholinergic receptors	Striated	Elevates the eyebrows	Facial nerve palsy, myasthenia gravis, botulinum toxin injection, myopathies	This muscle is often involuntarily activated to compensate for upper lid ptosis or dermatochalasis.
Orbicularis Oculi Muscle	7th cranial (facial) nerve	Nicotinic cholinergic receptors	Striated	Closes the eyes	Facial nerve palsy, myasthenia gravis, botulinum toxin injection, myopathies	Orbicularis oculi weakness may result in lagophthalmos or a deficient blink reflex.
Rectus and Oblique Muscles	3rd, 4th, and 6th cranial nerves	Nicotinic cholinergic receptors	Striated	Moves the eyes in all directions	Cranial nerve palsy, myasthenia gravis, orbital myositis, CPEO, etc.	4 rectus and 2 oblique muscles, each paired (yoked) with another in the opposite orbit. EOM dysfunction generally leads to incomitant strabismus with binocular diplopia.
Iris Sphincter Muscle	Parasympathetic nervous system (nerve fibers travel with inferior division of CN3 in the orbit)	Muscarinic cholinergic receptors (M3 > M2 subtype)	Smooth	Constricts the pupil	Pupil-involving 3rd nerve palsy, Adie's tonic pupil	Segmental pupillary paralysis with vermiform (worm-like) constriction is highly suggestive of an Adie tonic pupil.
Iris Dilator Muscle	Sympathetic nervous system (nerve fibers enter orbit with V1 (first division of CN5))	Alpha 1A > alpha 1B > alpha 1D adrenergic	Smooth	Dilates the pupil	Horner syndrome	
Conjunctival and Episcleral Vessel Wall	Sympathetic and parasympathetic nervous system	Alpha adrenergic and muscarinic cholinergic	Smooth	Constricts blood vessels	Horner syndrome	

PTOSIS HISTORY

A comprehensive patient history is crucial, as it can offer numerous clues about whether a patient presents with isolated ptosis or a more concerning condition.¹ The most common type of ptosis, involutional ptosis, is typically bilateral (although it can be asymmetric) and has a gradual onset, progressing over months to years. It is essential to assess the entire face and obtain an overall gestalt before focusing on the periocular region, as this can prevent overlooking important nearby pathology that warrants attention or may impact ptosis management, such as brow droop or facial weakness.

When providing the best care for patients, it is critical to first rule out any serious conditions. The most common serious neurological or muscular conditions encountered in clinical practice include Horner syndrome, 3rd cranial (oculomotor) nerve palsy, myasthenia gravis, and chronic progressive external ophthalmoplegia (CPEO).¹ A thorough review of a patient's history can help determine the timing of ptosis onset, as a sudden onset may signal serious underlying pathology.¹

Patient Presentation

The following questions can assist clinicians in gathering relevant information that may further clarify a patient's presentation of ptosis:

- Does the patient have diabetes or hypertension?
- Is the ptosis new onset or longstanding?
- Do functional changes occur during the day (e.g., complete closure)?
- Does the patient experience double vision?
- Are the extraocular muscle movements (EOMs) equal and full?
- When assessing levator function while holding the eyebrows, what is the excursion of the upper eyelid from downgaze to upgaze? (It should be equal to and more than 12mm).
- Are pupil sizes equal in both light and dark conditions?

PTOSIS CLASSIFICATION

Acquired ptosis, the most common form of ptosis, can be categorized by etiology, including aponeurotic, myogenic, neurogenic, mechanical, or traumatic origins. The following table serves as a useful reference to better understand these classifications. (See pages 6-7.)

PTOSIS CLASSIFICATION

Mechanism of Ptosis	Related Diagnoses (green = common diagnosis) (red = more serious diagnosis)	Etiology	Typical Clinical Features	
Aponeurotic	Involuntional	Levator dehiscence or disinsertion	Bilateral ptosis (not uncommonly asymmetric) with good to excellent LF, high upper lid crease	
Mechanical	Lid edema; lid or orbital mass; fibrosis	Increased upper lid weight or restriction of lid movement	Visible or palpable pathology	
Myogenic	Chronic progressive external ophthalmoplegia (CPEO)	Mitochondrial or nuclear DNA mutation	Bilateral, symmetric, slowly progressive ptosis with reduced LF and generalized ophthalmoparesis; often features orbicularis oculi weakness	
	Oculopharyngeal muscular dystrophy (OPMD)	Mutation of the PABPN1 (polyadenylate-binding protein nuclear 1) gene on chromosome 14	Gradually progressive ptosis with reduced LF; +/-generalized ophthalmoparesis with reduced saccadic velocity; often features orbicularis oculi muscle weakness	
	Myotonic dystrophy	Nuclear DNA mutation; type 1 (abnormal repeats in DMPK gene on chromosome 19); more often displays facial and ocular features	Progressive muscle wasting and weakness; bilateral ptosis with reduced levator function, generalized ophthalmoparesis, possible orbicularis oculi and facial weakness; prolonged muscle contraction with inability to relax (myotonia), e.g., hand grip; cataracts; cardiac conduction abnormalities	
	Myasthenia gravis	Autoantibodies interfering with neuromuscular transmission at the neuromuscular junction	Any of the following: ptosis (unilateral or bilateral), diplopia strabismus, or ocular motility impairment; facial or orbicularis oculi muscle weakness; bulbar, limb, or respiratory muscle weakness if generalized condition; variability and fatigability; no pupil involvement	
	Chemodenervation	Diffusion of botulinum toxin injected nearby	Transient ptosis with reduced levator function	
Neurogenic	Third nerve palsy	Various causes of CN3 dysfunction (aneurysm, tumor, infarct, diabetes, trauma, etc.)	Ptosis; anisocoria with larger, sluggish pupil ipsilateral to ptosis (if pupil involvement); impaired supraduction, adduction, and infraduction, unless superior or inferior divisional CN3 palsy	
	Horner syndrome	Various causes of a sympathetic pathway lesion (e.g., carotid dissection, neck trauma or surgery, Pancoast tumor (apical lung cancer))	Ptosis; anisocoria with ipsilateral miosis; dilation lag with anisocoria greater in dim lighting; possible anhidrosis, possible pain	
Traumatic	Blunt or penetrating injury	Levator muscle or aponeurosis injury	Ptosis; possible visible wound site	
Pseudoptosis	Non-Levator / Mullers-induced ptosis	Globe, eyelid, or brow malposition; or strabismus, mimicking ptosis	Breadth of entities: dermatochalasis, brow ptosis , lash ptosis, enophthalmos, contralateral upper eyelid retraction, orbicularis spasm (blepharospasm, hemifacial spasm, or synkinetic spasm due to aberrant facial nerve regeneration)	
Congenital	Levator muscle dysgenesis ("simple congenital ptosis")	Maldevelopment of levator muscle	Unilateral or bilateral ptosis with reduced levator function; lid lag, possible poor lid crease; increased risk of amblyopia, strabismus, and refractive error	
	Marcus Gunn jaw winking syndrome (congenital synkinetic ptosis)(2-13% of cases of congenital ptosis)	Abnormal innervation of the levator by a motor branch of CN5, with external pterygoid-levator muscle synkinesis	Unilateral ptosis; upper eyelid elevation with various movements of the mouth and jaw	
	Blepharophimosis syndrome	Mutation in FOXL2 gene or cytogenetic rearrangements involving chromosome 3	Bilateral ptosis with poor levator function, epicanthus inversus, blepharophimosis (horizontal narrowing of palpebral fissure), and telecanthus; possible amblyopia, refractive error, and strabismus; possible ovarian dysfunction in women	
	Double elevator palsy	Ptosis or pseudoptosis with impaired supraduction due to inferior rectus restriction, superior rectus paresis, or supranuclear palsy (3 types)(sporadic)	Unilateral ptosis and impaired supraduction	

Making the Diagnosis	Comments
Typical clinical features, gradual onset and progression, possible history of CL wear	Most common form of ptosis, along with mechanical. May be exacerbated by contact lens wear or eye surgery using a lid speculum.
Exam findings (e.g., lid swelling, hematoma, mass, symblepharon, etc.); history (e.g., prior eye trauma or surgery, etc.)	Treatment depends on the underlying condition, e.g., observation for resolution of lid swelling or resection of an eyelid or orbital mass.
Typical clinical features; muscle biopsy showing "ragged red fibers"; genetic testing	Surgery should be conservative due to risk of corneal exposure secondary to lagophthalmos (orbicularis muscle weakness) and deficient Bell's phenomenon.
Typical clinical features; usually strong family history; ancestry: French Canadian, New Mexican Hispanics, Bukharan Jews in central Asia; genetic testing	Dysphagia may need to be addressed, e.g., cricopharyngeal myotomy or botulinum toxin injection, to prevent malnutrition and aspiration pneumonia.
Typical clinical features, strong family history, EMG, genetic testing	Surgery should be conservative due to risk of corneal exposure secondary to lagophthalmos (orbicularis muscle weakness) and deficient Bell's phenomenon.
Positive ice test, decremental response on RNS, jitter on SFEMG, positive acetylcholine receptor or MuSK antibodies	Treatment with pyridostigmine (acetylcholinesterase inhibitor) and often systemic immunomodulatory therapy. Neurology consult to assess whether the condition is ocular or generalized. CT or MRI of chest to rule out thymic disorders, e.g., thymoma.
History of botulinum toxin injections in or near the eyelids within the past 3 months	May treat pharmacologically (oxymetazoline or apraclonidine) or observe until it spontaneously resolves.
Typical clinical features	Urgent neuroimaging with contrast (MRI or CT) and cerebral angiography (MRA, CTA, or conventional) to rule out cerebral aneurysm, if pupil is involved. Treatment is directed toward the underlying etiology.
Typical clinical features, positive apraclonidine test (replaced the cocaine test)	Imaging (CT or MRI) of the head/neck/upper chest, cerebral angiography (usually CTA or MRA). Urgent imaging to rule out carotid dissection if acute onset Horner syndrome, especially if there's neck, facial, or head pain.
Onset of ptosis following orbital trauma	Ptosis may spontaneously improve, so typically ptosis repair is delayed at least 3-4 months for observation, unless levator is transected.
Eye exam	Treatment depends on the underlying condition, e.g., upper blepharoplasty for dermatochalasis or botulinum toxin injections for orbicularis spasm.
Isolated congenital ptosis (unilateral or bilateral) with decreased levator function; possible congenital ptosis	Represents ~75% of congenital ptosis cases.
Typical clinical features; no findings of aberrant regeneration of CN7 (facial nerve synkinesis)	Synkinesis refers to co-contraction of unrelated muscles due to nerve "miswiring"; this is a congenital cranial dysinnervation syndrome.
Typical clinical features; +FH, genetic testing, and chromosome analysis	May have other associated anomalies
Typical clinical features; no other findings to suggest a CN3 palsy	May be difficult to distinguish from congenital CN3 palsy. Strabismus surgery may be required for hypotropia.

EYELID METRICS

After ruling out any serious conditions and determining that the patient has acquired ptosis, it is crucial to employ evaluation strategies to assess the degree and severity of the condition.⁵ Accurate documentation of normal upper eyelid position plays a significant role in evaluating blepharoptosis and eyelid retraction.⁵ Although palpebral fissure measurements were once considered the primary index for eyelid position, recent recommendations caution against relying solely on these measurements, as they depend on both upper and lower eyelid positions.⁵ Instead, upper and lower eyelid positions should be recorded individually.⁵

The following table offers a review of eyelid measurements. Note that these measurements vary by race, age, and ethnicity.

Eyelid Metrics	Details	Normal Range (mm)	Comments
Primary Measurements			
Palpebral fissure height (PF_v)	Vertical dimension	11-12	MRD1 + MRD2 = PFh; Malposition of the upper and lower eyelid may impact PFh, so this is not an optimal measure of upper lid height for ptosis.
Margin-reflex distance 1 (MRD1)	Corneal light reflex to upper lid margin	4-5	Measurement of upper lid margin position relative to the central corneal apex visualized with a penlight or flash. Alternatively, it's possible to qualitatively assess upper lid position relative to superior limbus using clock hours, i.e., where the upper lid intersects the limbus nasally and temporally.
Levator function (LF)	Maximal vertical excursion of upper lid margin from downgaze to upgaze	13-17	Tests strength and functionality of the levator muscle. Hold the brow in place to neutralize any frontalis muscle contribution. >15mm (supranormal) is seen in some involutional cases due to greater descent of upper lid in downgaze. This metric helps determine nature of the ptosis and the type of corrective surgery.
Lid crease height (LC_v)	Distance from lash line to upper lid crease	6-8 (men) 8-10 (women)	Lid crease is site of attachment of levator aponeurosis to skin. It is best measured in downgaze. Lid crease height is measured in the plane of pretarsal platform, and is typically higher with involutional ptosis and lower in Asians.
Pre-tarsal platform (PTP)	Distance from upper lid fold to upper lid margin	1-8	Typically redundant skin hinges at the upper lid crease, termed the upper lid fold (ULF), which descends toward the upper lid margin. The visible portion of pre-tarsal skin (PTP) is a potential cause of upper eyelid asymmetry.
Margin-reflex distance 2 (MRD2)	Corneal light reflex to lower lid margin	5-6	Measurement of lower lid margin position to quantify lower lid retraction or reverse ptosis (elevation of the lower lid). The lower lid margin normally rests at or just above the inferior limbus.
Scleral show (SS)	Scleral show	< 0	In the setting of lid retraction (widening), this is a measure of the exposed "white" (sclera) above or below the 12 (upper) or 6 (lower) clock-hour positions.
Brow	Brow position and shape often assessed relative to the superior orbital rim	Peak above lateral limbus	According to the classic aesthetic ideal, the brows (in men) are horizontal and positioned along the superior orbital rim, while the brows (in women) are more arched, with the apex over the lateral limbus and lateral brow 1cm over the superior orbital rim.
Secondary Measurements			
Effective margin-reflex distance (eMRD1)	Light reflex to inferior edge of overhanging skin or ptotic lashes	4-5	Method of documenting visual impact of dermatochalasis or lash ptosis when skin or lashes are lower than the upper lid margin. Thus, when applicable, eMRD1 will always be less than MRD1.
Palpebral fissure width (PF_w)	Horizontal dimension	29-31	Lateral canthal dehiscence results in shortening of palpebral fissure width, rounding of the lateral canthal angle (LCA), and increasing the distance from the LCA to the lateral orbital rim (normal ~2-3mm).
Canthal tilt	Angle between a line through the medial and lateral canthal angles and an imaginary horizontal line	+5-8 degrees (lateral canthal angle ~1-2mm above medial)	May also measure vertical discrepancy between lateral to the medial canthal angle. Positive canthal tilt, with the lateral canthal angle a bit higher than the medial, is often considered more attractive. Negative canthal tilt (lateral canthal dystopia) may contribute to lower eyelid retraction and less favorable lacrimal drainage mechanics.
Tarsal height	Measurement of vertical dimension of the tarsal plate	upper lid 8-10mm, lower lid 4mm	Reduced superior tarsal height may result from prior surgery in which superior tarsectomy was performed, e.g., prior Hughes tarsoconjunctival flap or Fasanella Servat ptosis repair, which can make subsequent ptosis surgery more challenging.

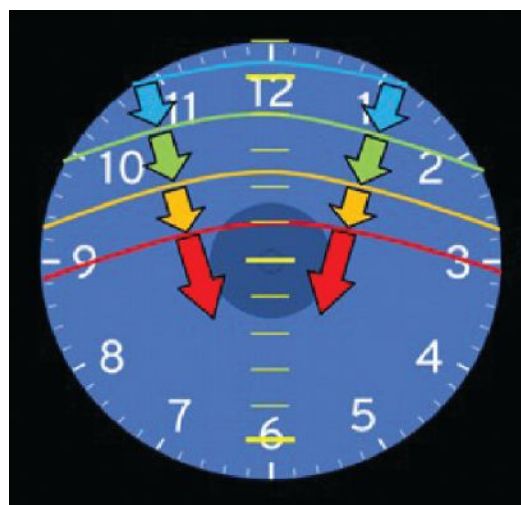
PRACTICAL EVALUATION STRATEGIES

During the evaluation of patients with ptosis, envisioning the iris as a clock face can serve as a useful mental guide for clinicians when applying different eyelid measurements to assess the surface anatomy.

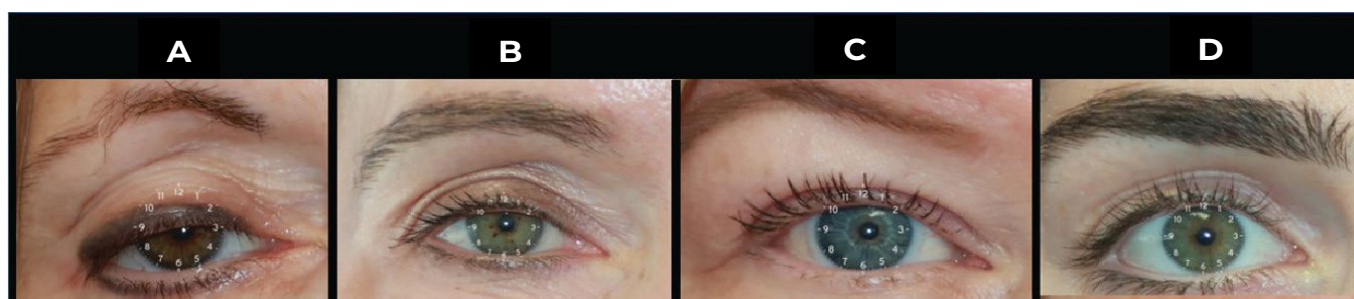	Degree of Ptosis	MRD1 Range
	Severe	<1mm
	Moderate	1.0-2.5mm
	Mild	2.5-4.0mm
	Normal	4.0-5.5mm

Table (above): MRD1 ranges (mm) of ptosis by severity.

Figure (right): Depicts clockface positions of degrees of ptosis with color codings depicted in above Table. Yellow dashes centrally represent mm increments. Central circle represents 3mm pupil.



Using this method to visually assess the degree of ptosis in these clinical images, the below ratings can be assigned:



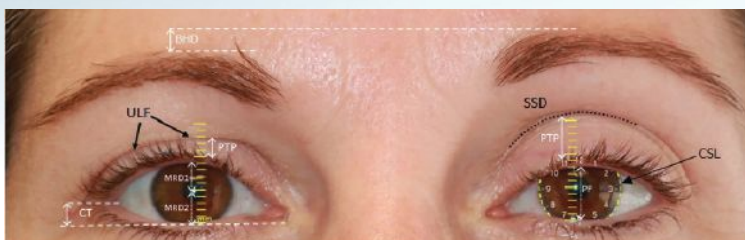A. Severe Ptosis

B. Moderate Ptosis

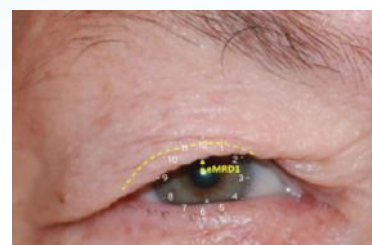C. Mild Ptosis

D. Normal Eyelid

In the below left photo (see page 10), note the mild ptosis in the left upper lid accompanied by a compensatory deep superior sulcus. PF refers to the palpebral fissure height, with a graded yellow millimeter ruler shown for measurement. MRD1 represents Marginal Reflex Distance 1, and MRD2 stands for Marginal Reflex Distance 2. To accurately measure the MRD, an excellent light reflex on the corneal apex is necessary. Alternatively, a more qualitative assessment of eyelid position can be made by observing the intersection of the lid margin with the CSL (Corneal-Scleral Limbus), as seen in the left eye (~9.6 to 2.1 clock hours). PTP denotes the Pre-Tarsal Platform, ULF refers to the Upper Lid Fold, SSD signifies the Superior Sulcus Depression or Defect, BHD represents the Brow Height Difference, and CT stands for Canthal Tilt.

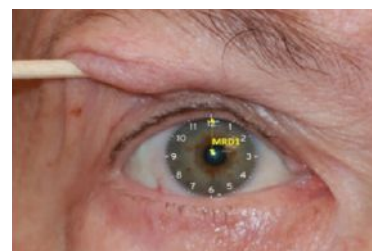


Distinguishing between dermatochalasis and blepharoptosis can be challenging, as both



eMRD

conditions present with drooping eyelids and may appear similar, making precise diagnosis crucial for appropriate treatment. The effective margin-reflex distance (eMRD) aids in differentiating these conditions by evaluating functional eyelid obstruction. To assess eMRD, measure the standard margin-reflex distance (MRD1) in primary gaze, then manually lift the overhanging skin and measure again. A notable discrepancy between MRD1 and eMRD implies dermatochalasis, where the visual axis clears as the overhanging skin is lifted, while a minimal difference suggests true blepharoptosis.



MRD1

ADDRESSING AN OFTEN-OVERLOOKED CONDITION

The term “ptosis,” which originates from the Greek word meaning “falling” or “sinking,” intriguingly illustrates the drooping appearance of the affected body part. Blepharoptosis, or low-lying eyelids, is a widespread issue, primarily caused by age-related changes, but occasionally it may signal a more severe underlying concern. A comprehensive patient history and systematic examination are essential for determining the nature of ptosis, informing the need for ancillary testing and guiding the development of treatment plans.

It is important for clinicians to assess the entire face and consider the overall context before focusing on the periorbital region. This approach helps prevent overlooking related pathologies, such as brow droop or facial weakness, which may impact ptosis management. In some cases, ptosis can lead to a significant impact on a patient’s field of vision, making it vital for clinicians to address the issue to improve visual function and overall quality of life.

By gaining a thorough understanding of acquired ptosis and its potential treatments, clinicians can address this often-overlooked condition more effectively and expand their eye care services. This knowledge empowers them to guide patients with ptosis through the eye care continuum, providing tailored care to meet their unique needs.

References:

1. Bacharach J, Lee WW, Harrison AR, et al. A review of acquired blepharoptosis: prevalence, diagnosis, and current treatment options. *Eye (Lond)*. 2021; Apr 29. [Epub ahead of print].
2. McKean-Cowdin R, Varma R, Wu J, Hays RD, Azen SP, Los Angeles Latino Eye Study Group. Severity of visual field loss and health-related quality of life. *Am J Ophthalmol*. 2007;143: 1013-23.
3. Richards HS, Jenkinson E, Rumsey N, et al. The psychological well-being and appearance concerns of patients presenting with ptosis. *Eye*. 2014;28:296-302.
4. Meyer DR, Stern JH, Jarvis JM, Lininger LL. Evaluating the visual field effects of blepharoptosis using automated static perimetry. *Ophthalmology*. 1993;100:651-8.
5. Small RC, Meyer DR. Eyelid metrics. *Ophthalmic Plast Reconstr Surg*. 2004 Jul;20(4):266-7.

PTOSIS VISUAL FIELD LOSS CAN BE ADDITIVE TO VISUAL FIELD LOSS FROM OTHER CONDITIONS

Ptosis-related visual field loss can worsen the overall impact on a patient's vision when combined with visual field loss from other conditions, such as glaucoma or retinal disorders. Assessing upper eyelid position before performing visual field testing is crucial to avoid misleading results that may affect treatment decisions. In cases of significant ptosis (e.g., MRDI < 3), taping the upper eyelid up during testing is recommended. Although ptosis alone may cause considerable visual field impairment, the combined visual field loss from ptosis and another coexisting disorder could lead to even greater visual disability. Treating ptosis in patients with concurrent disorders affecting the visual field can substantially enhance their quality of life.

PTOSIS AND VISUAL FIELD LOSS

A 73-year-old woman was referred for glaucoma surgery due to worsening visual fields attributed to low tension glaucoma in both eyes, despite well-controlled eye pressures and stable optic nerve cupping.

Surprisingly, her most recent visual field showed significant progression of superior visual field loss (*Figure 1*). The patient reported frequently bumping her head on overhead cabinets, particularly on the left side.

External examination revealed upper eyelid ptosis, worse in the left eye, with an MRDI of 2.5mm in the right eye and 1mm in the left eye (*Figure 2*). Intraocular pressures were 11 mmHg in the right eye and 10 mmHg in the left eye. Fundus exam showed enlarged optic nerve cupping in both eyes, similar to optic disc photos from a year prior, except for a new small optic disc hemorrhage in the left eye (*Figure 3*), and OCT appeared unchanged.

Repeat automated perimetry with the left upper eyelid taped revealed a significant improvement in superior visual field loss, now displaying a discrete superior arcuate visual field defect close to fixation (*Figure 4*), similar to previous visual fields. This finding confirmed that glaucoma was stable, and glaucoma surgery was unnecessary.

The patient and referring clinician were advised that the superior visual loss OS could be improved by treatment of the ptosis.

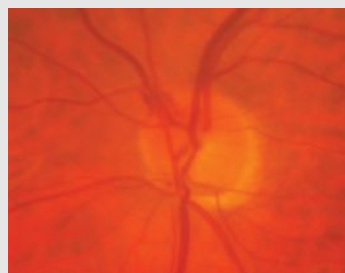

Figure 3. Increased left optic nerve cupping with loss of the inferior neural rim. Despite the small superonasal disc hemorrhage, there was no discernible change in the optic nerve cupping.

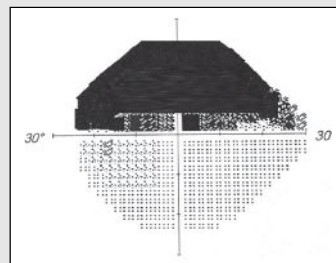


Figure 1. Threshold perimetry of left eye displaying severe diffuse superior visual field loss.

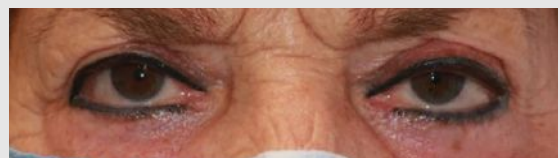

Figure 2. Bilateral upper eyelid ptosis, greater on the left.

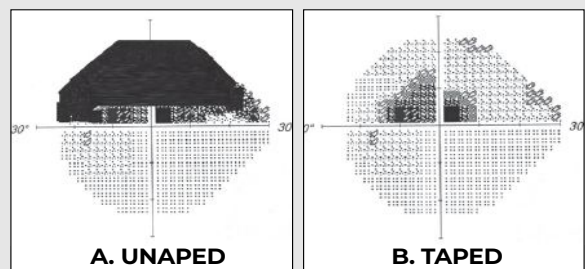


Figure 4. Threshold perimetry, left eye. A. Previous untaped visual field. B. Repeat visual field with the upper eyelid taped showed a discrete superior arcuate visual field defect close to fixation, with elimination of the ptosis contribution to the severe superior visual field impairment.

SPONSORED BY

RVL
PHARMACEUTICALS

Review Tops the Charts Again!

REVIEW of OPTOMETRY

The OD's FIRST CHOICE

Practitioners rely on *Review of Optometry* more than any other eye care publication

**Ranked #1
Eye Care Publication
In FIVE Critical
Readership Categories:**



Total Readers



Most Read Publication/
Website Within the
Last Six Months



Average Page
Exposures



Websites Visited within
the Last Six Months



Quality Clinical Content
I Use in My Practice

Source: Kantar Media Eyecare 2023 Study

Review also is number one in readership across the following categories:

- Total Optometrists
- ODs in High-Volume Practices (76pts/wk)
- Solo Practitioners
- Annual Practice Revenue (\$500k+)
- ODs who Purchase Examination Equipment
- Write Prescriptions (11+ per week)
- Perform Refractions (51+ per week)
- Contact Lens Prescribers
- Years in Practice (1-15 and 15+)
- Among Key Opinion Leaders



To our readers: Thank you for your loyalty, time and trust.
We'll keep working hard to earn your support.

Earn 2 CE Credits
(COPE APPROVED)

A GAME PLAN FOR MANAGING EYELID LESIONS AND RELATED CONDITIONS

Optometrists play a critical role in the identification and treatment of these issues.



BY VERA HOWE, OD
IOWA CITY, IA

The eyelids are the first structure examined under the slit lamp microscope and are often cursorily evaluated. The eyelids function to protect the front surface of the globes from injury, and the skin is exposed to sunlight and ultraviolet rays. In addition, the eyelids help regulate the amount of light that reaches the eye. The eyelids' structure is instrumental in tear film maintenance by distributing the tear film over the ocular surface during blinking as well as their action on the conjunctival sac and lacrimal sac in tear flow. Attention to the lids involves examining the dermal surface, the eyelid margins and palpebral conjunctiva as well as the dynamics of lid movement and position as it pertains

to the ocular surface and the lacrimal system.

As such, the eyelids are common locations for both benign and malignant lesions to appear and, due to the thin skin and constant use, are prone to age-related changes. Below, the most common lesions and lid malpositions will be reviewed, as well as nonsurgical and pre- and postoperative management.

Eyelid Anatomy

Before you can correctly identify and effectively manage eyelid lesions and conditions, a clear understanding of its anatomy is necessary. The eyelid skin is the thinnest in the body and has no subcutaneous fat. The palpebral conjunctiva is the innermost layer of tissue that lies adjacent to the globe. Anterior to the palpebral conjunctiva is the tarsal plate, the connective tissue structure within the eyelid that provides its rigidity and shape.

Between the tarsal plate and outermost layer of skin is muscle tissue composed of the orbicularis oculi and levator palpebrae superioris. The tarsal plate surrounds and protects the meibomian glands. These glands secrete lipid through openings along the eyelid margin that contributes to the tear film stability. The eyelashes on the eyelid margin are anterior to the meibomian glands and are surrounded by the glands of Moll (apocrine glands) and the glands of Zeis (sebaceous glands).¹

Common Eyelid Lesions

The ability to recognize and distinguish between various eyelid lesions is critical for effective patient care. Conditions optometrists will likely encounter in clinical practice include hordeolum, chalazion and pyogenic granulomas, to name a few.

Hordeolum. This is an acute infection associated with an obstructed

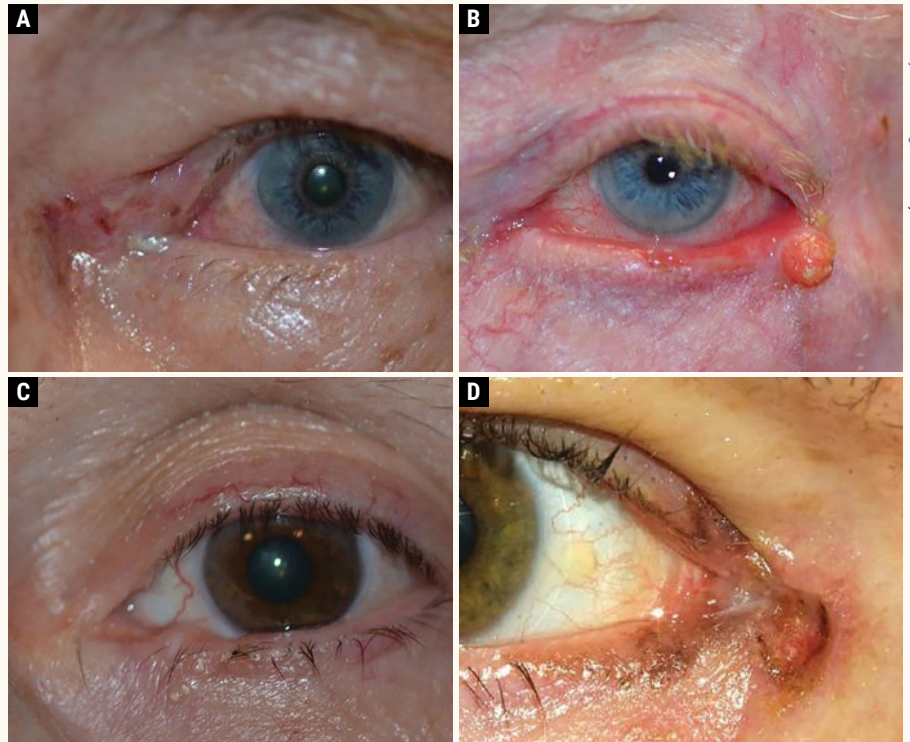
About the authors

Dr. Howe is a clinical assistant professor at the University of Iowa Hospitals and Clinics Department of Ophthalmology and Visual Sciences in Iowa City, IA, where she serves as the director of Optometric Services. She graduated from the Illinois College of Optometry and completed her contact lens and cornea residency at the Illinois Eye Institute. She is a fellow of the American Academy of Optometry. She has no financial interests to disclose.

sebaceous gland, most commonly due to staphylococcus bacteria.¹ It appears as a tender, erythematous nodule and can be associated with eyelid edema, superficial skin flaking or crusting or cellulitis or abscess formation. External hordeola are localized infections in the ciliary glands (Zeis or Moll) found at the eyelid margin and appear as a pustule near an eyelash follicle. Internal hordeola occur within the tarsus in the meibomian glands and present with more diffuse tenderness and eyelid erythema.

Hordeola tend to resolve spontaneously, but primary treatment consists of warm compresses multiple times a day. Additional treatment options for hordeola include topical antibiotic ointment, combination antibiotic/steroid ointment and in cases with cellulitis, abscess, or significant inflammation, systemic antibiotics that cover staphylococcal infections (amoxicillin/clavulanate, cephalosporins, fluoroquinolones) may be indicated.^{2,3} Surgical intervention is not necessary but may be helpful to accelerate resolution.

Chalazion. This focal nodule on the eyelid arises from an obstructed sebaceous gland (meibomian or Zeis). This condition, which affects all age groups,



This series shows the range of potential eyelid carcinomas: (A) basal cell carcinoma, (B) nodular squamous cell carcinoma, (C) sebaceous cell carcinoma and (D) melanoma.

is caused by lipogranulomatous inflammation and may be associated with inflammatory disorders of the eyelid such as rosacea and blepharitis. Chalazia can be treated in the acute phase with warm compresses used for 10 to 15 minutes

two to four times daily. Spontaneous resolution can occur about 25% of the time with conservative treatment.^{4,5}

In complex or recurrent cases, oral doxycycline or azithromycin may be considered because of their ability to

A Game Plan for Managing Eyelid Lesions and Related Conditions

Jointly provided by Postgraduate Institute for Medicine (PIM) and Review Education Group

Release Date: October 15, 2023

Expiration Date: October 15, 2026

Estimated Time to Complete Activity: two hours

Target Audience: This activity is intended for optometrists engaged in optic nerve disorder management.

Educational Objectives: After completing this activity, participants should be better able to:

- Correctly identify various eyelid lesions and conditions in clinical practice.
- Effectively manage patients with eyelid lesions.
- Recognize when a patient should be referred to a specialist.
- Determine when an eyelid lesion may be malignant and requires biopsy.

Faculty: Vera Howe, OD

Disclosure of Conflicts of Interest: PIM requires faculty, planners and others in control of educational content to disclose all their financial relationships with ineligible companies. All identified conflicts of interest are thoroughly vetted and mitigated according to PIM policy. PIM is committed to providing its learners with high-quality, accredited CE activities and related materials that promote improvements or quality in health care and not a specific proprietary business interest of an ineligible company.

Those involved reported the following relevant financial relationships with ineligible entities related to the educational content of this CE activity: *Faculty* – Dr. Howe has

nothing to disclose. *Planners and Editorial Staff* – PIM has nothing to disclose. The Review Education Group has nothing to disclose.

Accreditation Statement: In support of improving patient care, this activity has been planned and implemented by PIM and the Review Education Group. PIM is jointly accredited by the Accreditation Council for Continuing Medical Education, the Accreditation Council for Pharmacy Education and the American Nurses Credentialing Center to provide CE for the healthcare team. PIM is accredited by COPE to provide CE to optometrists.

Credit Statement: This course is COPE-approved for two hours of CE credit. Activity #126905 and course ID 87274-TD. Check with your local state licensing board to see if this counts toward your CE requirement for relicensure.

Disclosure of Unlabeled Use: This educational activity may contain discussion of published and/or investigational uses of agents that are not indicated by the FDA. The planners of this activity do not recommend the use of any agent outside of the labeled indications. The opinions expressed in the educational activity are those of the faculty and do not necessarily represent the views of the planners. Refer to the official prescribing information for each product for discussion of approved indications, contraindications and warnings.

Disclaimer: Participants have an implied responsibility to use the newly acquired information to enhance patient outcomes and their own professional development. The information presented in this activity is not meant to serve as a guideline for patient management. Any procedures, medications or other courses of diagnosis or treatment discussed or suggested in this activity should not be used by clinicians without evaluation of their patient's condition(s) and possible contraindications and/or dangers in use, review of any applicable manufacturer's product information and comparison with recommendations of other authorities.



downregulate the inflammatory cascade, inhibiting bacterial lipase production and improving the tear film balance.⁶ Surgery or intralesional injection may be indicated in the event of failed conservative management. Intralesional injection is a non-surgical option for recalcitrant chalazia and results in an approximately 80% reduction of the lesion in about two weeks after the first or second injection.^{5,7} While effective and minimally invasive, appropriate patient selection is imperative as intralesional steroid injections carry the risk of skin depigmentation, dermal and fat atrophy, and intra-arterial embolism, which is a risk with triamcinolone injection.^{1,5} In the event of chronic or recurrent chalazia, pathologic examination should be performed to rule out masquerade conditions, such as sebaceous cell carcinoma. Intense pulsed light treatment is relatively new in eye care but shows promise as an effective treatment for chalazia.⁸

Pyogenic granulomas. These nontender, red, fleshy vascular lesions are often found on skin and mucosa as well as on the palpebral conjunctiva of the eye. They are typically dome-shaped, vary from 1mm to 10mm in diameter and can be pedunculated or sessile. Pyogenic granulomas are vascular lesions that often arise rapidly from an area of insult, such as a hordeolum, chalazion, punctal plug, trauma or surgical site. Most pyogenic granulomas are asymptomatic, but they can bleed easily and cause discomfort.

Removal of the irritant that is responsible for the pyogenic granuloma formation is the first treatment in management; however, pyogenic granulomas rarely resolve spontaneously and require treatment only if they are symptomatic. There is evidence that they respond well to topical therapies, such as corticosteroids or beta blockers.^{9,10} Topical steroids should be used four times a day for one to two weeks or topical beta blockers, such as timolol maleate 0.5% twice daily for at least three weeks. Beta blockers can be remarkably effective and do not carry the risk of steroid-induced intraocular

pressure response.¹¹ In cases where there is not effective resolution of the lesion, surgical excision remains an option.

Malignant Eyelid Lesions

The most common malignant eyelid lesions are basal cell carcinoma, squamous cell carcinoma and sebaceous cell carcinoma.¹² Less commonly, melanoma can be identified. Eyelid malignancies have common characteristics of ulceration, a chronic, nonhealing lesion, intermittent bleeding, asymmetric appearance, madarosis and destruction of the normal eyelid anatomy. Any lesion that is suspicious should be biopsied and sent for histologic evaluation.

Basal cell carcinoma (BCC). The most common eyelid malignancy, basal cell carcinoma accounts for approximately 90% to 95% of malignant eye tumors in the United States.² They are found most often on sun exposed eyelid skin, most commonly the lower eyelid and medial canthus. Nodular BCC is the most common form, and these lesions have a pearly border with telangiectasias and tend to ulcerate. Morpheiform BCC is less common but more aggressive than nodular BCC. The morpheiform BCC lesion tends to be firm and slightly elevated and have indeterminate margins. Patients at highest risk for basal cell carcinoma are fair-skinned, blue-eyed, blonde, or red-haired, middle aged or older, and with British or Scandinavian ancestry.^{2,13} Treatment depends on size and location and can include surgical excision, topical immunotherapy, radiotherapy and oral treatment. Surgical excision is considered the gold standard of treatment, which includes Mohs microangiographic surgery and frozen section evaluation. For individuals in which surgery alone is not possible, these other treatments have had varying levels of success.¹³

Squamous cell carcinoma (SCC). This condition accounts for 5% to 10% of eyelid malignancies and is more aggressive than BCCs. SCCs is often found on lower and upper eyelids and the medial canthus but may be pres-

ent on more than one periocular area and appear as elevated, nonhealing, erythematous lesions.¹⁴ They tend to have a flaky appearance, caused by the production of keratin as they arise from keratinocyte proliferation. The lesion may arise spontaneously or from areas of solar injury or actinic keratosis. SCC may invade into orbit or intracranially. Risk factors include male gender, fair complexion, history of ultraviolet exposure, a high fat diet, chemical exposure, smoking and immunosuppression.¹² Individuals who are immunocompromised are more prone to aggressive SCCs. Treatment is complete excision with histological confirmation of clear margins, although for individuals who are not good surgical candidates, targeted epidermal growth factor receptor (EGFR) has shown promise.¹² In the event of orbital invasion, exenteration may be required.

Sebaceous cell carcinoma (SebCCa). This highly malignant and potentially lethal tumor arises from the oil glands of the eyelid, namely meibomian and Zeis glands or the sebaceous glands of the caruncle, eyebrow or facial skin. It occurs evenly in men and women and occurs twice as frequently in the upper lid as it does in the lower lid due to a greater number of sebaceous glands in the upper lids.^{2,15} SebCCa is the most common eyelid malignancy in the Asian-Indian population, and the third most common in the Caucasian population.^{12,16} SebCCa occurs primarily in those over the age of 50, with the greatest incidence among those in their 70s and 80s. It is known as the “great masquerader” as it may present as chronic unilateral blepharconjunctivitis or chronic or non-healing chalazion. A hallmark feature of SebCCa is pagetoid spread and skip lesions, so wide excision of the primary lesion and map biopsies (this includes the palpebral conjunctiva in the superior and inferior lids as well multiple sections of the bulbar conjunctiva) must be performed.¹⁷ Surgical excision is the primary treatment method for SebCCa. A fresh tissue histology is necessary to establish clear

margins due to the malignant nature of sebaceous cell carcinoma.^{12,17}

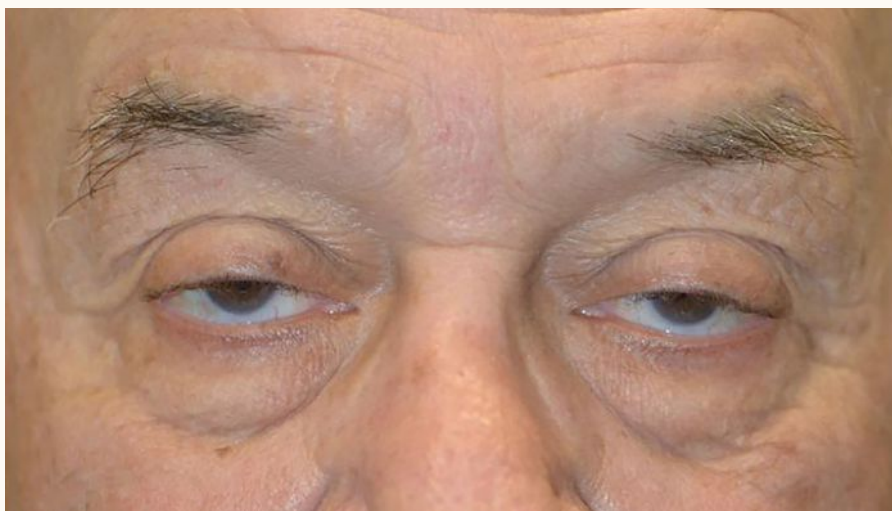Primary melanoma of the eyelid skin. While this is a rare entity (<0.1% of eyelid malignancies), the incidence of melanoma in the United States has steadily increased over the last 30 years. Melanomas typically have variable pigmentation and irregular borders and may ulcerate and bleed. Melanoma risk factors include sun exposure, tanning bed use, genetic predisposition and environmental mutagens.² Melanoma should be suspected in any patient over the age of 20 with an acquired pigmented lesion. Primary treatment of a melanoma skin lesion on the eyelid includes wide excision with histologic confirmation of complete tumor removal.^{2,18}

Eyelid Malpositions

Patients with eyelid malpositions require careful evaluation with a focus on general medical history and eyelid condition history. Careful attention should be paid to visual acuity, pupil function, extraocular muscles, ocular surface and tear layer. External photography and visual field examination are also helpful. Malpositions of the eyelids can affect the upper and lower eyelids. The most common eyelid malpositions are upper eyelid ptosis and dermatochalasis as well as lower eyelid ectropion and entropion.

Ptosis. Upper eyelid ptosis can be due to ptosis (the actual eyelid margin being low) or due to dermatochalasis (redundant upper eyelid skin). Both ptosis and dermatochalasis can limit a patient's visual field or activities of daily living.

Ptosis is classified as either congenital or acquired, and further described as myogenic, involutional, mechanical or neurogenic. Congenital ptosis in a small child can result in amblyopia. The most common cause for acquired ptosis is involutional (age-related) and is due to the stretching of the aponeurosis of the levator muscle. This can also be caused by repetitive traction on the eyelid, such as with eye rubbing or



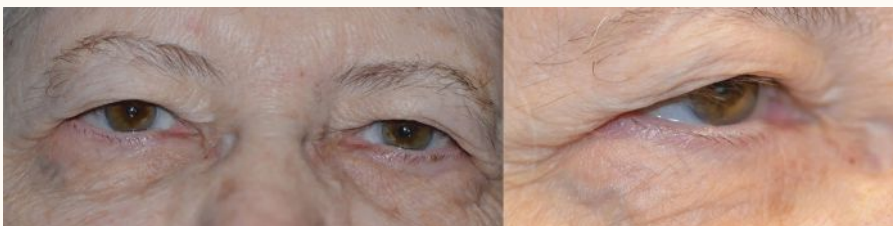Bilateral lid ptosis. The margin reflex distance (MRD) 1 is -1mm.

prolonged use of contact lenses, or by previous eyelid surgery or intraocular surgery. In this condition, the strength of the levator muscle remains normal. Clinical findings will often include ptosis that is worse on downgaze and elevation of the eyelid crease, and the patient will often complain of ptosis that makes reading more difficult.¹⁹

Clinical evaluation of ptosis includes a detailed history, which can provide details regarding variability and time frame. Photographs are helpful in establishing a timeline regarding onset of ptosis, while family history can bring attention to inherited conditions. Examination of the ptosis patient can include the following clinical measurements: margin reflex distance (MRD) 1 and 2, palpebral fissure height, upper eyelid crease position, levator function and presence of lagophthalmos or punctate epithelial erosions. To determine how the ptosis affects function, head position, chin elevation, brow position and brow action in attempted up gaze needs to be evaluated. Pupil examination is also necessary, particularly in unilateral cases, to rule out associated conditions such as Horner's syndrome (miosis in dim illuminations) and cranial nerve III palsy (which may have mydriasis and exotropia). Additionally, a visual field will quantify the level of functional visual field loss and can be used to demonstrate to insurance companies the improve-

ment in visual field with the upper lid taped. Full face photography is often included.

Management of ptosis is as varied as its causes. Care must be taken to determine whether repair will be functional or cosmetic. Functional repairs would be those that could cause amblyopia, have significant superior visual field loss or cause difficulty with reading. Non-surgical options include temporary ptosis correction with a variety of medications. Botulinum toxin can be injected to weaken the upper lid orbicularis and provides improvement lasting about three months. Apraclonidine can be used up to three times daily to provide some improvement as an alpha 2 agonist. Tetrahydrozoline is a non-selective alpha agonist and can provide mild lid elevation, but frequent use should be cautioned against due to ocular surface side effects. Recently, the US FDA approved 0.1% oxymetazoline hydrochloride ophthalmic solution for temporary ptosis improvement, which can maintain 1mm to 2 mm of lid elevation for six to 14 hours. Ptosis eyelid crutches mounted on eyeglass frames can be used for those with severe ptosis in individuals that cannot undergo surgical repair. The type of surgical repair for ptosis is dependent on the function of the levator muscle. In the presence of good levator function, an external approach with levator advancement or internal repair with



Bilateral upper lid dermatochalasis. The upper lids are resting on the eyelashes, causing downward misdirection.

conjunctival muellerectomy are indicated. An internal approach (frontalis sling) may be indicated for individuals with poor levator function.²⁰

The most common complication of surgical ptosis repair is under correction. In the early postoperative period, it is important to differentiate this from eyelid edema causing mechanical ptosis. Other complications include overcorrection, wound healing complications, uneven eyelid height, unacceptable eyelid contour, conjunctival prolapse, tarsal eversion, contralateral ptosis or lagophthalmos with exposure keratopathy.²

Dermatochalasis. This is redundancy of eyelid skin, often associated with fat pad prolapse (steatoblepharon) and may accompany ptosis. While more common in the elderly, it can be found in middle-aged individuals with a family history.¹⁹ Individuals with upper eyelid dermatochalasis may complain of a heavy feeling around their eyes, brow ache, perceiving their upper eyelashes in their field of vision and reduction in their visual field, particularly superiorly. Patients often complain that their upper eyelid skin rubs their eyelashes, and report difficulty wearing mascara due to smearing. The effects of dermatochalasis may be made worse when accompanied by brow ptosis. Lower eyelid dermatochalasis is considered cosmetic by most third-party payers.

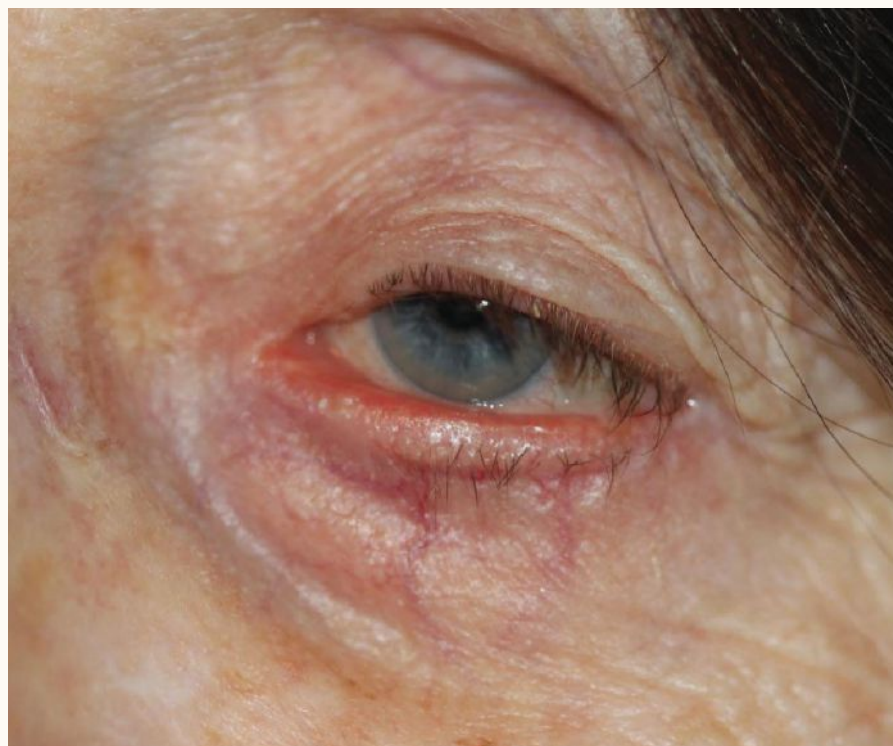
Upper eyelid blepharoplasty was the second most performed procedure in the US in 2020.²¹ This procedure is commonly sought after to improve function by removing excess skin, muscle and/or fat which can obstruct the superior visual field. Upper eyelid blepharoplasty can also be performed to improve appearance. Lower lid

blepharoplasty is performed for cosmetic indications. Aggressive resection of lower eyelid skin and fat may lead to eyelid retraction, ectropion or a sunken periorbital appearance.²

The evaluation for blepharoplasty includes a complete examination of the ocular structures and visual acuity, a history with attention to previous periorbital surgeries, careful documentation of the amount and areas of redundant eyelid tissue and prolapsed fat in both the upper and lower eyelids, presence of lagophthalmos and tear film evaluation and external photography. Prior to surgical referral, dry eye therapy should be maximized, with frequent use of artificial tears, thicker nighttime lubricants and potentially punctal plug

placement, as postoperative dryness is quite common. Additionally, upper blepharoplasty evaluation includes visual field testing, evaluation of forehead and brow height and contour to assess the presence of brow ptosis and the assessment of the upper eyelid crease. Evaluation may include photographs of the brow and eyelids. Lower lid blepharoplasty includes assessment of lower lid elasticity and notation of the orbital rims to avoid postoperative scleral show.

In the immediate postoperative period, management is aimed at improving comfort. Icing the lids helps reduce edema and bruising, but it is normal to expect dry eye symptoms in the first two weeks after a blepharoplasty, as there is reduction in orbicularis function from both edema and anesthetic. Immediately after surgery, the patient will be directed to use ointment, but in subsequent weeks, dryness from post-surgical blink dynamic is common. Serious complications in the post-operative period include orbital hemorrhage, diplopia, excess removal of skin and very rarely, loss of vision.²



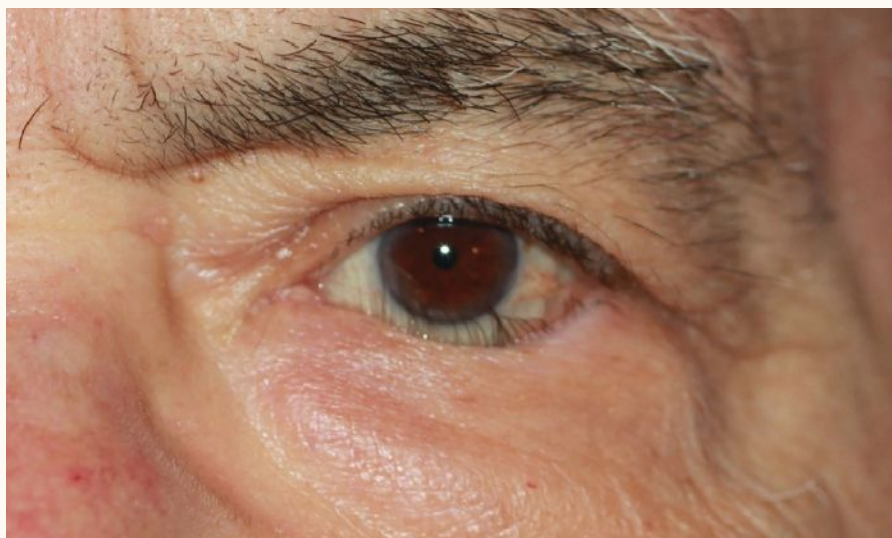This patient presents with epiphora due to involuntional ectropion and loss of punctal apposition to the globe.

The patient should be monitored for significant pain, marked asymmetric swelling or new proptosis. Dimming of vision or asymmetric blurred vision should be evaluated immediately for orbital hemorrhage. Individuals with hypertension, blood dyscrasias and those on anticoagulants are most at risk for hemorrhage. Diplopia can arise due to injury to the trochlea of the superior oblique muscle in upper lid blepharoplasty or to the inferior oblique or inferior rectus in lower lid blepharoplasty. Excess removal of skin can result in lagophthalmos of the upper eyelid as well as eyelid retraction or cicatricial ectropion.²

Lateral canthal tendon disinsertion (LCTD). This condition results in a change from the normal eyelid fissure symmetry, blink dynamics and lacrimal pump function.²² LCTD is often the cause of persistent discharge, ocular irritation and epiphora. The clinical examination demonstrates medial and inferior movement of the lateral commissure with attempts at eyelid closure, lack of apposition of the eyelid margin with associated corneal exposure and a vertically displaced lateral canthal angle.

Additionally, narrowing of the horizontal palpebral fissure, temporal overlap of the eyelids on attempted closure and pseudo upper or lower eyelid retraction is often observed. Clinical exam can confirm the diagnosis by using a cotton-tipped swab to physically reposition the lateral canthal angle temporally and toward the orbit, confirming the diagnosis of LCTD. Surgical repair options include lateral canthopexy, lateral canthoplasty or lateral tarsorrhaphy.²²

Floppy eyelid syndrome. This condition is characterized by ocular irritation, conjunctival injection, eyelash ptosis and mild mucus discharge that is worse on awakening.²³ Patients will often have chronic papillary conjunctivitis and a superior tarsal plate that is rubbery and easily everted. During the exam, the lax upper eyelid may evert spontaneously, especially when pulled up toward the forehead. Often



This patient suffers from corneal irritation resulting from trichiasis caused by lower lid entropion.

these patients are stomach sleepers, with the pillow causing mechanical upper lid eversion and irritation of the superior conjunctiva by the bedding. Floppy eyelid syndrome is associated with obesity, obstructive sleep apnea, keratoconus, eyelid rubbing and hyperglycemia.²³ Treatment begins with conservative medical management, viscous lubrication with lid taping or a shield use at night. If the patient has sleep apnea, use of CPAP may reduce face down sleep positioning. Surgical correction in the form of wedge resection is indicated if refractory to other treatments.

Ectropion. This condition may be classified as congenital, involutional, cicatricial, paralytic or mechanical. Most cases of ectropion are involutional, arising from horizontal eyelid laxity in the medial or lateral canthal tendons or both. This results in loss of apposition of the eyelid to the globe and the eyelid margin is everted. The conjunctival surface can become chronically inflamed and keratinized due to mechanical irritation and drying of the surface of the conjunctiva. Most cases of involutional inferior ectropion occur due to the effects of gravity on a lax lower lid. Cicatricial ectropion occurs due to a deficiency of skin, which may be due to thermal or chemical burns, mechanical injury, aggressive lid

surgery or chronic actinic skin damage. Numerous conditions that result in chronic skin inflammation such as rosacea, atopic dermatitis, eczematoid dermatitis or scarring from herpes zoster can cause cicatricial ectropion. Paralytic ectropion is usually due to CN VII paralysis or palsy. Mechanical causes of ectropion include large eyelid masses, fluid accumulation, or herniated orbital fat. Congenital ectropion is rarely an isolated finding and is often associated with chromosomal abnormalities.²

When evaluating the lower lid, attention must be paid to the punctal position and assessing lid laxity. The distraction test and snapback test are used to assess this. The distraction test is performed by grasping the lower lid and pulling it away from the globe. If the eyelid can be pulled more than 10mm from the globe, it is considered to have significant lid laxity. Additionally, the snapback test is performed by pulling the lower lid down and away from the globe. The lid is held in position for several seconds, and then released.²⁴ The amount of time it takes the lid to return to its original location and is graded on a scale from 0 (immediately returns to original position) to IV (never returns). If a blink is required to return the lid to its original position, it is grade III.

Treatment for ectropion depends on the underlying cause. Medical management of ectropion is targeted at protecting the ocular surface and includes lubrication with both drops and ointments, taping the lower lid temporarily or even moisture chamber goggles. Surgical repair depends on the degree of ectropion and corneal surface health indicated for involutional ectropion. Cicatricial ectropion includes medical management of the underlying cause, protection of the corneal and conjunctival surfaces, and often surgical intervention. Mechanical ectropion is treated by addressing the underlying cause.

Entropion. This can occur in the upper or lower eyelids, is found unilaterally or bilaterally and is classified as congenital, involutional, acute spastic and cicatricial. Most patients will have complaints of tearing, foreign body sensation, irritation and chronic red eye. The most common cause of lower lid entropion is involutional, which is the result of horizontal eyelid laxity, attenuation or disinsertion of eyelid retractors and overaction of the preseptal orbicularis oculi muscle. Horizontal eyelid laxity is a consequence of aging, characterized by the stretching of the tendons of the eyelid and canthus. Attenuation of the eyelid retractors combined with preseptal orbicularis overaction results in inward rotation of the lid margin. Cicatricial entropion is due to contracture of the palpebral conjunctiva, which cause the eyelid to rotate inward. Several conditions can lead to scarring, including autoimmune, inflammatory, infectious, surgically-induced and traumatic conditions.

Additionally, long term use of topical glaucoma medications, especially miotics and prostaglandins can cause chronic conjunctivitis with conjunctival shortening and secondary cicatricial entropion. On clinical examination, if it is possible to manually place the eyelid in its normal anatomic position, the cause is involutional rather than cicatricial. Acute spastic entropion can be a result of chronic ocular irritation or inflammation that results in contrac-

tion of the orbicularis oculi muscle that causes inward rotation of the eyelid margin. The chronic corneal irritation from the entropion perpetuates the cycle of orbicularis spasm.²

Treatment of involutional entropion is first achieved with lubrication, appropriate eyelid taping and bandage contact lens. If this treatment is inadequate, surgical repair is necessary. Acute spastic entropion will often resolve when the underlying cause is effectively treated. Temporary relief can often be obtained with taping of the eyelid to evert the lid margin, cautery or rotational suture placement. In some cases, botulinum toxin can be used to paralyze the preseptal orbicularis muscle.

Management of cicatricial entropion depends on the underlying cause. Surgery is often required, but lubrication, bandage contact lenses and removal of trichiatric lashes can be helpful. Surgery is not indicated during periods of exacerbation of autoimmune disease or until stabilization of an acute inflammatory illness. Congenital entropion tends not to resolve spontaneously and may require surgical correction.²⁵

Takeaways

As primary eyecare providers, the role of optometrists play in the identification, treatment and management of eyelid lesions and conditions is enormous. Optometrists can identify and treat many eyelid lesions and are instrumental in referring malignancies to our surgical colleagues when needed. Accurate assessments of common eyelid conditions and appropriate medical management can improve the quality of life of our patients and may delay or eliminate the need for surgery. Proper presurgical assessments can ensure that surgical candidate selection is optimized, resulting in ideal postoperative results. ■

1. Skorin L, Goemann L. Eyelid inflammation: approach to hordeolum, chalazion and pyogenic granuloma. *Consultant*. 2017;57(5):282-5.
2. Korn BS. 07. Oculofacial plastic and orbital surgery [online course]. American Academy of Ophthalmology 2022-2023 Basic and Clinical Science Course. Accessed August 15, 2023.

3. Alsoudi AF, Ton L, Ashraf DC, et al. Efficacy of care and antibiotic use for chalazia and hordeola. *Eye Contact Lens*. 2022;48(4):162-8.
4. Wu AY, Gervasio KA, Gergoudis KN, et al. Conservative therapy for chalazia: is it really effective? *Acta Ophthalmol*. 2018;96(4):e503-9.
5. Perry HD, Serniuk RA. Conservative treatment of chalazia. *Ophthalmology*. 1980;87(3):218-21.
6. Wladis EJ, Bradley EA, Bilyk JR, et al. Oral antibiotics for meibomian gland-related ocular surface disease: a report by the American Academy of Ophthalmology. *Ophthalmology*. 2016;123(3):492-6.
7. Mohan K, Dhir SP, Munjal VP, et al. The use of intralesional steroids in the treatment of chalazion. *Ann Ophthalmol*. 1986;18(4):158-60.
8. Caravaca A, Alio Del Barrio JL, Martinez Hergueta MC, Amesty MA. Intense pulsed light combined with meibomian gland expression for chalazion management. *Arch Soc Esp Oftalmol (Engl Ed)*. 2022;97(9):490-6.
9. Oke I, Alkharashi M, Petersen RA, et al. Treatment of ocular pyogenic granuloma with topical timolol. *JAMA Ophthalmol*. 2017;135(4):383-5.
10. Ferry AP. Pyogenic granulomas of the eye and ocular adnexa: a study of 100 cases. *Trans Am Ophthalmol Soc*. 1989;87:327-43; discussion 343-7.
11. DeMaria LN, Silverman NK, Shinder R. Ophthalmic pyogenic granulomas treated with topical timolol-clinical features of 17 cases. *Ophthalmic Plast Reconstr Surg*. 2018;34(6):579-82.
12. Yin VT, Merritt HA, Sniegowski M, et al. Eyelid and ocular surface carcinoma: diagnosis and management. *Clin Dermatol*. 2015;33(2):159-69.
13. Shi Y, Jia R, Fan X. Ocular basal cell carcinoma: a brief literature review of clinical diagnosis and treatment. *Oncol Targets Ther*. 2017;10:2483-9.
14. Faustina M, Diba R, Ahmadi MA, et al. Patterns of regional and distant metastasis in patients with eyelid and periorbicular squamous cell carcinoma. *Ophthalmology*. 2004;111(10):1930-2.
15. Dasgupta T, Wilson LD, Yu JB. A retrospective review of 1349 cases of sebaceous carcinoma. *Cancer*. 2009;115(1):158-65.
16. Patel BCK. Epidemiology of eyelid malignancies in indian asians: the importance of being earnest. *Ocul Oncol Pathol*. 2019;5(3):205-9.
17. Song A, Carter KD, Syed NA, et al. Sebaceous cell carcinoma of the ocular adnexa: clinical presentations, histopathology, and outcomes. *Ophthalmic Plast Reconstr Surg*. 2008;24(3):194-200.
18. Chan FM, O'Donnell BA, Whitehead K, et al. Treatment and outcomes of malignant melanoma of the eyelid: a review of 29 cases in Australia. *Ophthalmology*. 2007;114(1):187-92.
19. Allen RC, Harper RA. Basic ophthalmology: essentials for medical students, 10th edition. American Academy of Ophthalmology. 2016.
20. Cahill KV, Bradley EA, Meyer DR, et al. Functional indications for upper eyelid ptosis and blepharoplasty surgery: a report by the American Academy of Ophthalmology. *Ophthalmology*. 2011;118(12):2510-7.
21. Surgeons ASOP. Plastic Surgery Statistics Report. ASPS. www.plasticsurgery.org/documents/News/Statistics/2020/plastic-surgery-statistics-full-report-2020.pdf. Accessed 15 August 2023.
22. Shriver EM, Erickson BP, Kossler AL, et al. Lateral canthal tendon disinsertion: clinical characteristics and anatomical correlates. *Ophthalmic Plast Reconstr Surg*. 2016;32(5):378-85.
23. Skorin L, Jr., Knutson R. Ophthalmic Diseases in Patients With Obstructive Sleep Apnea. *J Am Osteopath Assoc*. 2016;116(8):522-9.
24. Skorin L, Jr., Lange R. Ectropion: classification, diagnosis and management. *Consultant*. 2108;58(6):e180.
25. Skorin L, Jr. A review of entropion and its management. *Cont Lens Anterior Eye*. 2003;26(2):95-100.

OPTOMETRIC STUDY CENTER QUIZ

To obtain CE credit through the Optometric Study Center, complete the test form on the following page and return it with the \$35 fee to: Jobson Healthcare Information, Attn.: CE Processing, Jobson Healthcare Information, LLC/WebMD, 283-299 Market Street, 2 Gateway Center, 4th Floor, Newark, NJ 07102. To be eligible, please return the card within three years of publication. You can also access the test form and submit your answers and payment via credit card online at revieweducationgroup.com. You must achieve a score of 70 or higher to receive credit. Allow four weeks for processing. For each Optometric Study Center course you pass, you earn two hours of credit. Please check with your state licensing board to see if this approval counts toward your CE requirement for relicensure.

- The eyelid is composed of all but what tissue?**
 - Conjunctiva.
 - Subcutaneous fat.
 - Muscle.
 - Connective tissue.
- Which statement regarding the function of the eyelid is FALSE?**
 - Eyelids serve to protect the globe from trauma.
 - Eyelids do not protect the globe from UV light.
 - The eyelids are responsible for distributing the tear film over the ocular surface.
 - The eyelids are responsible for the pumping mechanism of the lacrimal sac and the palpebral sac.
- Hordeola are local infections due to which of the following bacteria?**
 - Enterobacter.
 - Klebsiella.
 - Staphylococcus.
 - Proteus.
- Chalazia are a result of which of the following?**
 - Bacterial infection.
 - Lipogranulomatous inflammation.
 - Trichiasis.
 - Poor hygiene.
- Risks of intralesional chalazia injection includes which of the following?**
 - Dermal and fat atrophy.
 - Local skin depigmentation.
 - Intra-arterial embolism.
 - All the above.
- Pyogenic granuloma treatment can include all but which of the following?**
 - Topical steroid.
 - Topical beta blocker.
 - Surgical excision.
 - Oral antibiotics.
- What type of malignant eyelid lesion is most common in the US?**
 - Basal cell carcinoma.
 - Squamous cell carcinoma.
 - Sebaceous cell carcinoma.
 - Melanoma.
- Malignant eyelid lesions are characterized by all of the following EXCEPT:**
 - Chronic, unhealing lesions.
 - Destruction of the normal eye lid anatomy.
 - Madarosis.
 - Symmetrical appearance.
- Treatments for basal cell carcinoma include which of the following?**
 - Surgical excision.
 - Topical immunotherapy.
 - Radiotherapy.
 - All the above.
- Squamous cell carcinoma is characterized by all the following EXCEPT:**
 - Flaky, keratinized appearance.
 - Pearly, vascularized appearance.
 - Appear as elevated, nonhealing lesions.
 - Occur more frequently in immunocompromised individuals.
- This malignant lesion is highly malignant and is known as the "great masquerader."**
 - Melanoma.
 - Squamous cell carcinoma.
 - Basal cell carcinoma.
 - Sebaceous cell carcinoma.
- This condition of the eyelid is associated with obstructive sleep apnea, obesity, eyelid rubbing and hyperglycemia.**
 - Pyogenic granuloma.
 - Floppy eyelid syndrome.
 - Ptosis.
 - Ectropion.
- The most common cause of acquired ptosis is which of the following?**
 - Myogenic.
 - Involuntary.
 - Mechanical.
 - Neurogenic.
- Prior to ptosis repair surgery, which of the following conditions should be aggressively treated?**
 - Rosacea.
 - Meibomian gland dysfunction.
 - Dry eye.
 - Blepharitis.
- Persistent discharge, ocular irritation and epiphora can be a result of horizontal lid laxity due to which of the following?**
 - Ptosis.
 - Dermatochalasis.
 - Lateral canthal tendon disinsertion.
 - Floppy eyelid syndrome.
- The most common cause of lower eyelid ectropion is which of the following?**
 - Mechanical.
 - Paralytic.
 - Cicatricial.
 - Involuntary.
- What test is most helpful in ectropion evaluation?**
 - Margin reflex distance 1 and 2.
 - Palpebral fissure height.
 - Distraction test.
 - Levator function.
- When performing the snapback test, if a blink is required to return the lid to its original position, it is graded as which of the following?**
 - Grade 0.
 - Grade I.
 - Grade III.
 - Grade VI.
- Cicatricial entropion can be caused by which of the following?**
 - Glaucoma medication use.
 - Trichiasis.
 - Aging.
 - Cranial nerve VII paralysis.
- Initial treatment of involutory entropion includes all of the following EXCEPT:**
 - Lubrication.
 - Steroid injection.
 - Eyelid taping.
 - Contact lenses.

Examination Answer Sheet

A Game Plan for Managing Eyelid Lesions and Related Conditions

Valid for credit through October 15, 2026

Online: This exam can be taken online at revieweducationgroup.com. Upon passing the exam, you can view your results immediately and download a real-time CE certificate. You can also view your test history at any time from the website.

Directions: Select one answer for each question in the exam and completely darken the appropriate circle. A minimum score of 70% is required to earn credit.

Mail to: Jobson Healthcare Information, LLC/WebMD, 283-299 Market Street, 2 Gateway Center, 4th Floor, Newark, NJ 07102.

Payment: Remit \$35 with this exam. Make check payable to Jobson Healthcare Information, LLC.

Credit: This course is COPE-approved for two hours of CE credit. Course ID 87274-TD.

Processing: There is a four-week processing time for this exam.

Jointly provided by PIM and the Review Education Group.

Answers to CE exam:

Post-activity evaluation questions:

1. (A) (B) (C) (D)
2. (A) (B) (C) (D)
3. (A) (B) (C) (D)
4. (A) (B) (C) (D)
5. (A) (B) (C) (D)
6. (A) (B) (C) (D)
7. (A) (B) (C) (D)
8. (A) (B) (C) (D)
9. (A) (B) (C) (D)
10. (A) (B) (C) (D)
11. (A) (B) (C) (D)
12. (A) (B) (C) (D)
13. (A) (B) (C) (D)
14. (A) (B) (C) (D)
15. (A) (B) (C) (D)
16. (A) (B) (C) (D)
17. (A) (B) (C) (D)
18. (A) (B) (C) (D)
19. (A) (B) (C) (D)
20. (A) (B) (C) (D)

Rate how well the activity supported your achievement of these learning objectives. 1=Poor, 2=Fair, 3=Neutral, 4=Good, 5=Excellent

21. Correctly identify various eyelid lesions and conditions in clinical practice. (1) (2) (3) (4) (5)
22. Effectively manage patients with eyelid lesions. (1) (2) (3) (4) (5)
23. Recognize when a patient should be referred to a specialist. (1) (2) (3) (4) (5)
24. Determine when an eyelid lesion may be malignant and requires biopsy. (1) (2) (3) (4) (5)
25. Based upon your participation in this activity, do you intend to change your practice behavior? (Choose only one of the following options.)
 - (A) I do plan to implement changes in my practice based on the information presented.
 - (B) My current practice has been reinforced by the information presented.
 - (C) I need more information before I will change my practice.
26. Thinking about how your participation in this activity will influence your patient care, how many of your patients are likely to benefit? (please use a number):
27. If you plan to change your practice behavior, what type of changes do you plan to implement? (Check all that apply.)

(A) Apply latest guidelines	(D) Change in current practice for referral	(G) More active monitoring and counseling
(B) Change in diagnostic methods	(E) Change in vision correction offerings	(H) Other, please specify: _____
(C) Choice of management approach	(F) Change in differential diagnosis	
28. How confident are you that you will be able to make your intended changes?
 - (A) Very confident
 - (B) Somewhat confident
 - (C) Unsure
 - (D) Not confident
29. Which of the following do you anticipate will be the primary barrier to implementing these changes?

(A) Formulary restrictions	(D) Insurance/financial issues	(G) Patient adherence/compliance
(B) Time constraints	(E) Lack of interprofessional team support	(H) Other, please specify: _____
(C) System constraints	(F) Treatment related adverse events	
30. Additional comments on this course: _____

Please retain a copy for your records. Please print clearly.

First Name

Last Name

E-Mail

The following is your: Home Address Business Address

Business Name

Address

City State

ZIP

Telephone # - -

Fax # - -

OE Tracker Number

Rate the quality of the material provided:
 1=Strongly disagree, 2=Somewhat disagree,
 3=Neutral, 4=Somewhat agree, 5=Strongly agree

31. The content was evidence-based. (1) (2) (3) (4) (5)

32. The content was balanced and free of bias. (1) (2) (3) (4) (5)

33. The presentation was clear and effective. (1) (2) (3) (4) (5)

By submitting this answer sheet, I certify that I have read the lesson in its entirety and completed the self-assessment exam personally based on the material presented. I have not obtained the answers to this exam by any fraudulent or improper means.

Signature _____ Date _____ Lesson 124234 RO-OSC-1023

SECO2024

THE EDUCATION DESTINATION™

FEBRUARY 28 – MARCH 3, 2024
ATLANTA, GEORGIA

SAVE THE DATE

REGISTRATION OPENS NOVEMBER 1ST



ADVANCING EYE CARE WORLDWIDE

SECO International is dedicated to providing world-class educational opportunities to eye care professionals, helping them enhance their skills, expand their networks, and grow their practices. Experience the future of eye care at our flagship event - where groundbreaking technology meets leading-edge education.



EMPOWERING EYE CARE PROFESSIONALS

SECO International is passionate about empowering eye care professionals through top-tier educational content and networking opportunities. Our flagship event, SECO 2024, will bring together the global optometry community, fostering collaboration, knowledge sharing, and the advancement of eye care.



YOUR PARTNER IN EYE CARE EXCELLENCE

SECO International is committed to promoting excellence in eye care through cutting-edge educational offerings, robust networking platforms, and strategic partnerships. At our premier event, SECO 2024, you'll gain access to a global community of optometry professionals and industry leaders, ready to inspire and be inspired.

SCAN HERE TO BE NOTIFIED ABOUT
SECO 2024 REGISTRATION



LEARN MORE AT
attendseco.com



EDITED BY JOSEPH P. SHOVLIN, OD

Pregnant Pause

In expectant mothers, the possibility of temporary ocular changes can complicate prescribing and diagnosis.

Q **Pregnancy can affect the corneal thickness and intraocular pressure (IOP) of women, impeding proper LASIK screening and complicating glaucoma diagnosis and treatment. What management protocol exists for women who may be experiencing transient corneal effects during pregnancy?**

A “A recent paper published in *BMC Ophthalmology* has reopened the conversation about the effects of female sex hormones on the cornea throughout a woman’s life cycle,” notes Suzanne W. Sherman, OD, an associate professor at University of South Florida. Specifically with corneal changes that occur during pregnancy, the question

has been brought up of what standards to follow.¹

The article confirmed that increases in corneal curvature and thickness are due to corneal edema in pregnancy, which can be a factor in transient visual symptoms. These changes are thought to be caused by fluid retention, progesterone and estrogen receptors in the stroma and increased collagenolytic activity. A separate study by Weinreb et al. also reported an increase in corneal thickness, corneal volume and decreased keratometry values.^{2,3}

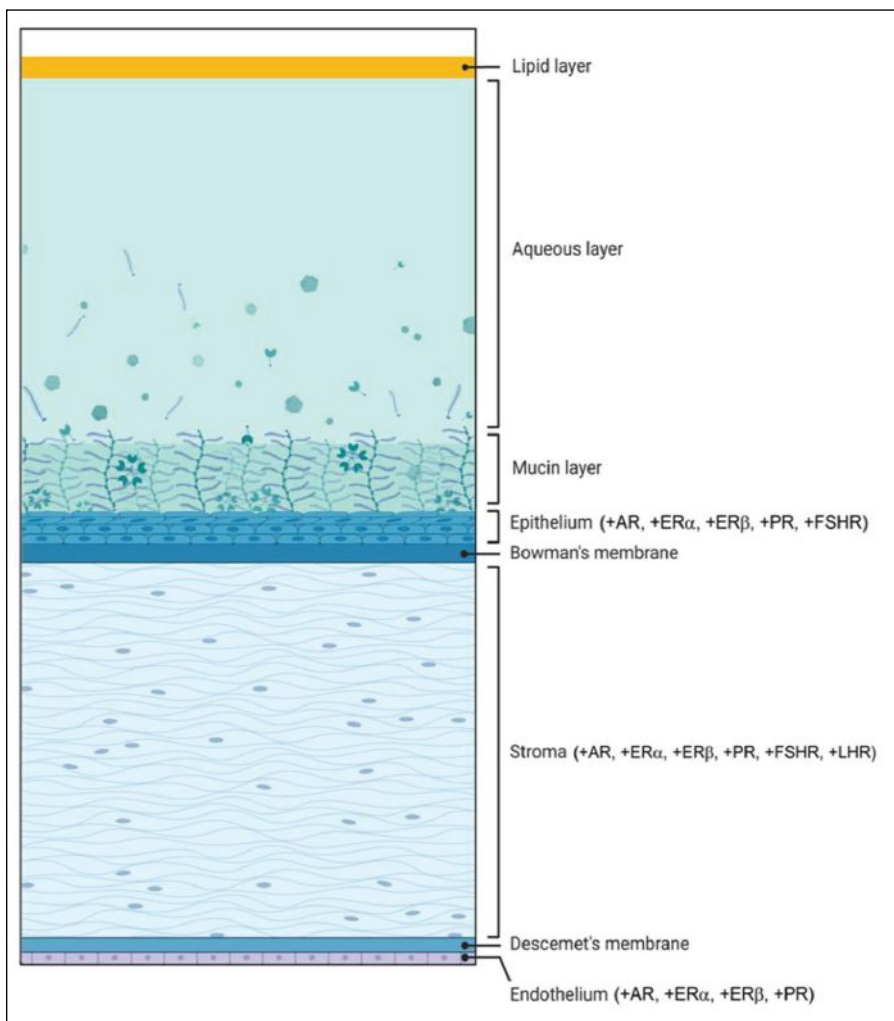
Unintended Changes

“These corneal changes primarily affect refractive error and can contribute to IOP and keratoconus alterations,” Dr. Sherman explains. However, refractive error changes that were caused by corneal thickness and volume alterations were not found statistically significant by Weinreb et al. As such, there is varying opinion on whether to prescribe glasses or contact lenses for pregnant patients with fluctuating visual symptoms. A review by Morya et al. stated that glasses prescribed while pregnant may become irrelevant postpartum due to a myopic shift.⁴ In contradiction, Weinreb et al. state pregnancy is not a contraindication for prescribing corrective lenses.^{2,4}

Thus, no established protocol has been set, but if the patient is symptomatic and a change in manifest refraction is

At left, diagram illustrating the cornea’s hormonal receptors. AR: androgen receptor; ER: estrogen receptor; PR: progesterone receptor; LHR: luteinizing hormone receptor; FSHR: follicle-stimulating hormone receptor. A plus sign (+) indicates evidence of receptor or enzyme mRNA expression in that respective layer.

Reproduced under Creative Commons 4.0 license from Kelly DS, Sabharwal S, Ramsey DJ, Morkin MI. The effects of female sex hormones on the human cornea across a woman’s life cycle. *BMC Ophthalmol.* 2023;23:358.



About Dr. Shovlin

Dr. Shovlin, a senior optometrist at Northeastern Eye Institute in Scranton, PA, is a fellow and past president of the American Academy of Optometry. He consults for Kala, Aerie, AbbVie, Novartis, Hubble and Bausch + Lomb and is on the medical advisory panel for Lentechs.

found, educating the patient on the possibility of a refractive shift postpartum is important, Dr. Sherman establishes.⁵

Another reason a patient may report new-onset visual symptoms during pregnancy is due to an underlying diagnosis of keratoconus, she adds. One study found a decrease in Goldmann and corneal-compensated IOP measurements in pregnant women with keratoconus that lasted until six months post-partum.⁶ This further suggests the importance of screening and discussing corneal crosslinking with keratoconus patients before conception, as well as continuous screening during pregnancy and postpartum.

When looking at pregnant patients, many studies have established that IOP changes in the second trimester, with pregnant women experiencing lower IOP than non-pregnant patients. This is due to an increase in outflow facility via increased uveoscleral outflow, decreased episcleral venous pressure and scleral rigidity, acidosis during pregnancy and the accompanying increase in corneal

thickness, elucidates Dr. Sherman. A decrease in IOP around 10% (2mm Hg to 3mm Hg) is seen in the second half of pregnancy.^{2,5}

The World Glaucoma Association has set guidelines that recommend targets for providers to use based on their patient's glaucoma severity, as this factor determines the aggressiveness of treatment. It recommends the following IOP limits to providers to decide whether to modify treatment: 35mm Hg for mild glaucoma, 30mm Hg for moderate and 25mm Hg for advanced. After 20 weeks, these targets change to 30mm Hg for mild, 25mm Hg for moderate and 20mm Hg for advanced glaucoma. Despite IOP dropping during pregnancy, it has been suggested that glaucoma during pregnancy can result in progressive field loss with up to 17.9% of patients experiencing loss.^{5,7,8} Depending on the severity, these patients should be followed every one to three months.

Currently, a specific protocol for prescription changes due to transient corneal effects during pregnancy does not

exist, Dr. Sherman states. "It is up to the provider to educate the patient and collaboratively conclude if a new prescription is necessary. In terms of transient corneal effects that can alter the course of patients' glaucoma or keratoconus, increased screening is recommended, and the frequency of this assessment will depend on the severity of the patient's condition," she concludes. ■

1. Kelly DS, Sabharwal S, Ramsey DJ, Morkin MI. The effects of female sex hormones on the human cornea across a woman's life cycle. *BMC Ophthalmol.* 2023;23:358.

2. Weinreb RN, Lu A, Beeson C. Maternal corneal thickness during pregnancy. *Am J Ophthalmol.* 1988;105(3):258-60.

3. Millodot M. The influence of pregnancy on the sensitivity of the cornea. *Br J Ophthalmol.* 1977;61(10):646-9.

4. Morya AK, Gogia S, Gupta A, et al. Motherhood: what every ophthalmologist needs to know. *Indian J Ophthalmol.* 2020;68(8):1526-32.

5. Sherman SW. Pregnancy and postpartum ophthalmic changes can present a challenge. *Optometry Times.* 2022;14(2).

6. Naderan M, Jahanrad A. Topographic, tomographic and biomechanical corneal changes during pregnancy in patients with keratoconus: a cohort study. *Acta Ophthalmol.* 2017;95(4):e291-6.

7. Khong EWC, Chan HHL, Watson SL, Lim LL. Pregnancy and the eye. *Curr Opin Ophthalmol.* 2021;32(6):527-35.

8. Weinreb R, Grajewski A, Papadopoulos M, et al. Medical treatment of glaucoma: the 7th Consensus Report of the World Glaucoma Association. Fort Lauderdale, Florida: Kugler Publications. 2010.

OPEN YOUR EYES[™] to Bruder
a Hilco Vision Company

HYGIENE | HEAT | HYDRATION

Open your eyes to Bruder.[™] You know us for our #1 doctor-recommended moist heat mask. But did you know we also offer a comprehensive line of science-based products for lid hygiene and hydration? Like the new Dry Eye Drink[™] by Bruder, a hyper-hydrating drink mix with a unique blend of anti-inflammatory ingredients and vitamins to help improve the ocular surface, along with electrolytes to help with absorption.



Available in orange, mixed berries, and strawberry lemon flavors. Also available in a PM version to aid in sleep.

Learn more about the beneficial ingredients.



Join us at AAO 2023 Booth #1239 or contact us at eye@bruder.com or 888-827-8337 | bruder.com/pro



BY JAMES L. FANELLI, OD

GLAUCOMA GRAND ROUNDS

Responsibility is a Two-Way Street

Once you've given patients every opportunity to benefit from your care, the rest is up to them.

In early August this year, a 90-year-old Caucasian male presented for a health examination complaining of acute vision loss in the right eye of four weeks' duration. He reported he had gotten some hand lotion in both eyes; subsequently, the vision in one of his eyes had remained blurred. He reported that both eyes felt irritated for several days, which eventually cleared, while the blurred vision remained unchanged. He was already a patient of mine; I previously saw him in early 2019, when he was then found to have optic nerve characteristics associated with glaucoma, especially in the right eye. Unfortunately, he did not return that year for follow-up care as scheduled.

Recently, I wrote a column describing a patient who did not comply with my previous plan and proffered some suggestions on how to get the patient to 'buy into' your renewed management. This case was a bit different; in this situation, the patient was accompanied by his son, with whom the father was living. His son is a longstanding patient I have been monitoring for several years as a glaucoma suspect. The son reported he had tried coaxing his father to seek care shortly after vision of the right eye

was affected, but the father declined until this day.

Case

The father only reported use of guaifenesin (Mucinex) 40mg twice daily and 81mg aspirin once daily, with no other medications taken and no allergies to medications. Entering visual acuities were 20/40 OD and OS with his habitual prescription; best-corrected acuities were 20/40 OD and 20/25-2 OS. Pupils were ERRLA with no afferent pupillary defect noted. Confrontation visual fields OD were slightly constricted superiorly, but there also was mild bilateral dermatochalasis noted.

The slit lamp examinations of the anterior segments were essentially unremarkable, with deep quiet chambers

and no corneal abnormalities. Pachymetry readings from his 2019 visit were 634 μ m OD and 595 μ m OS. Applanation tensions at the current visit were 26mm Hg OD and 21mm Hg OS. These intraocular pressure readings were 4mm and 3mm Hg higher than in 2019—essentially unchanged.

Through dilated pupils, the patient was pseudophakic OU with clear, centered intraocular lenses and bilateral opened capsules. His cup-to-disc ratio was estimated to be 0.75x0.95 OD and 0.45x0.60 OS. The neuroretinal rim OD was eroded temporally from six o'clock to 11 o'clock with no rim tissue appreciated inferotemporally (*Figure 1*); that of the OS was thinned, but what remained was mildly pink and decently perfused. The retinal vasculature was characterized by moderate arteriosclerotic retinopathy OU. Both maculae were reasonably healthy, with mild retinal pigment epithelium granulation and scattered drusen, with an epiretinal membrane observed OS (*Figure 2*). Posterior vitreous detachments existed bilaterally and the peripheral retinal evaluations were normal.

When reviewing the patient's vision loss history, he recounted first noticing decreased vision when rubbing his eyes after the hand lotion incident and not before. The decrease was more noticeable when rubbing his left eye, a common phenomenon that eyecare practitioners regularly hear. My assumption was the vision loss he noticed had most likely been present for a while due to uncontrolled glaucoma and was only recently noticed upon covering the fellow eye. This reasoning was due to his lack of a pupillary defect, no fundusoscopic appearance of

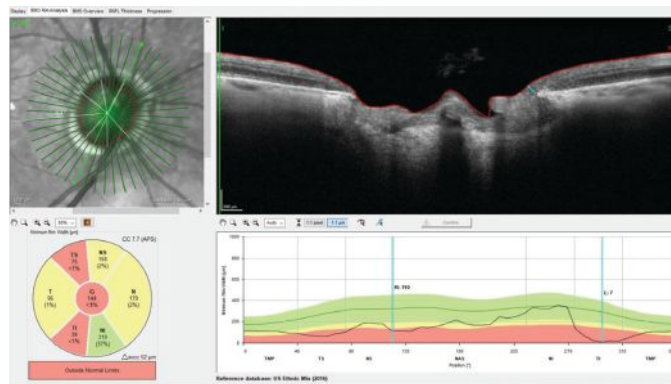


Fig. 1. A Bruch's membrane opening-minimum rim width (BMO-MRW) scan of the right optic nerve. Note in the section provided, erosion of the inferotemporal neuroretinal rim at the seven o'clock position to a paltry 7 μ m of remaining axons.

About Dr. Fanelli

Dr. Fanelli is the founder and director of the Cape Fear Eye Institute in Wilmington, NC. He is chairman of the EyeSki Optometric Conference and the CE in Italy/Europe Conference. He is an adjunct faculty member of PCO, Western U. and UAB School of Optometry. He is on advisory boards for Heidelberg Engineering and Glaukos.

ADVANCED TESTING. DYNAMIC TECHNOLOGY.

VISUAL FIELD testing without the constraints or discomfort of traditional Standard Automated Perimetry



Our Virtual Eye device can help you increase practice efficiency with:

- ✓ Test modalities, reporting accuracy, and repeatability comparable to SAP tests^{1,2}
- ✓ Audio instructions that replace the need for monitoring
- ✓ Portable, comfortable testing in any location

1. Munshi H, Da Silva K, Savatovsky E, Bitrian E, Grajewski AL. Preliminary Retrospective Validation of a Novel Virtual Reality Visual Field Standard Testing Algorithm, as Compared to Standard Automated Perimetry. Ophthalmology. - Submitted.

2. Patel A, Lee W, Munshi H, Chang TCP, Grajewski A, Tse D, Tse B. Comparison of Virtual Reality Device vs. Standard Automated Perimetry in the Assessment of Superior Visual Field Prior to Functional Upper Eyelid Surgery. ARVO Annual Meeting, Denver, CO. May 1st - 4th, 2022.

**Visit our website
to learn more:**



© Virtual Vision Health 2023. All rights reserved.
3109 Grand Ave #554 | Miami, FL 33133
Phone: 800-475-6010
Email: sales@virtualvision.health
www.virtualvision.health

 **VIRTUALVISION**

acute non-glaucomatous optic neuropathy and a previous history of suspected untreated glaucoma. Furthermore, erosion of his right temporal neuroretinal rim was consistent with glaucomatous damage. As such, I was not completely convinced of an acute neuro-ophthalmic cause of unilateral vision loss, though the possibility certainly existed.

However, upon looking at his previous records and comparing the state of his optic nerves then vs. now, his pachymetry readings and seeing no frank evidence of a neuro-ophthalmic origin, pressure-independent glaucoma moved to the top of the list. This was coupled with the awareness that many cases of normal-pressure glaucoma present with a vascular component to the disease process. The possibility of a concurrent vascular issue is highlighted in the diffuse retinal nerve fiber layer (RNFL) loss seen in *Figure 3*.

Discussion

At this point, I enlisted the help of the patient’s son to stress the importance of appropriate follow-up care, given that the son and I had a good doctor-patient relationship and he was a compliant patient himself. While it appeared as though the decreased vision in the right eye was caused by pressure-independent advanced glaucoma, I was not 100% certain that was the only underlying pathology, which in and of itself warranted further investigation. I made my case to the patient and his son; the son made his case to his father, and the father apparently bought into the management plan of a follow-up visit. After a lengthy discussion with the father regarding the need for this follow-up care to assess visual fields for both neuro-ophthalmic field defects and glaucomatous defects, I was able to work the patient into my schedule the following morning.

That next morning, the patient did not show up. Just before his scheduled appoint-

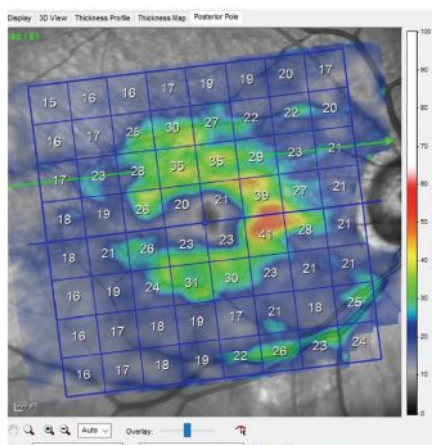


Fig. 2. Ganglion cell layer scan of the patient’s right macula, showing significant loss of ganglion cells in the inferior right portion, which is consistent with inferotemporal neuroretinal rim thinning.

ment, the son called and stated that his father simply refused to go to and that he would “live with it.” The son was honest that his father had simply dug in his heels and wanted nothing to do with being seen again.

This unfortunate scenario plays out occasionally in each of our offices. Despite my best efforts back in 2019 and again this August to impart upon the patient the importance of further evaluation to mitigate continued vision loss, some patients simply do not want to nor will follow through. I don’t completely understand that thought process, but it does exist.

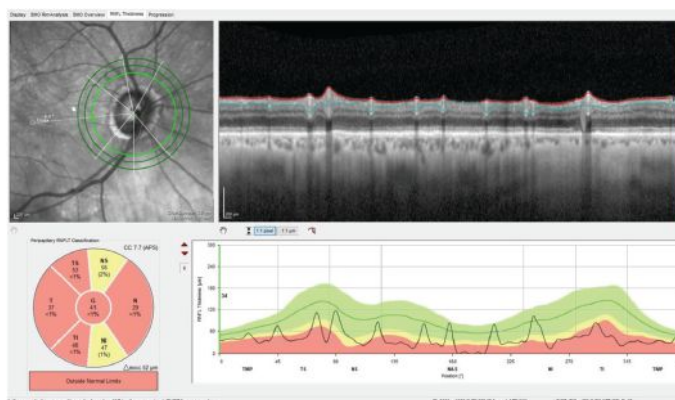


Fig. 3. Note the generalized loss of perioptic RNFL tissue in the 3.5mm diameter RNFL circle scan of the right eye; this is consistent with advanced glaucomatous disease. However, taken with the BMO-MRW scan seen in Figure 1, this does call into question the possibility of a concurrent vascular etiology of the observed damage.

Interestingly, a recent study conducted at Duke University looked at the incidence and reasoning for loss to follow-up care of glaucoma patients.¹ I was expecting to read that many patients bail out of due to medication noncompliance, but two unrelated findings were fascinating. Establishing the first, the retrospective study was done at a tertiary care facility which receives referred patients from both in- and out-of-state. The researchers found most patients lost to follow-up were actually in-state; individuals closer to the facility were more likely to be lost to follow-up than those further away. I found this interesting but somewhat expected the reverse to be true. Of course, there are several reasons why this may be the case, but it was intriguing nonetheless.

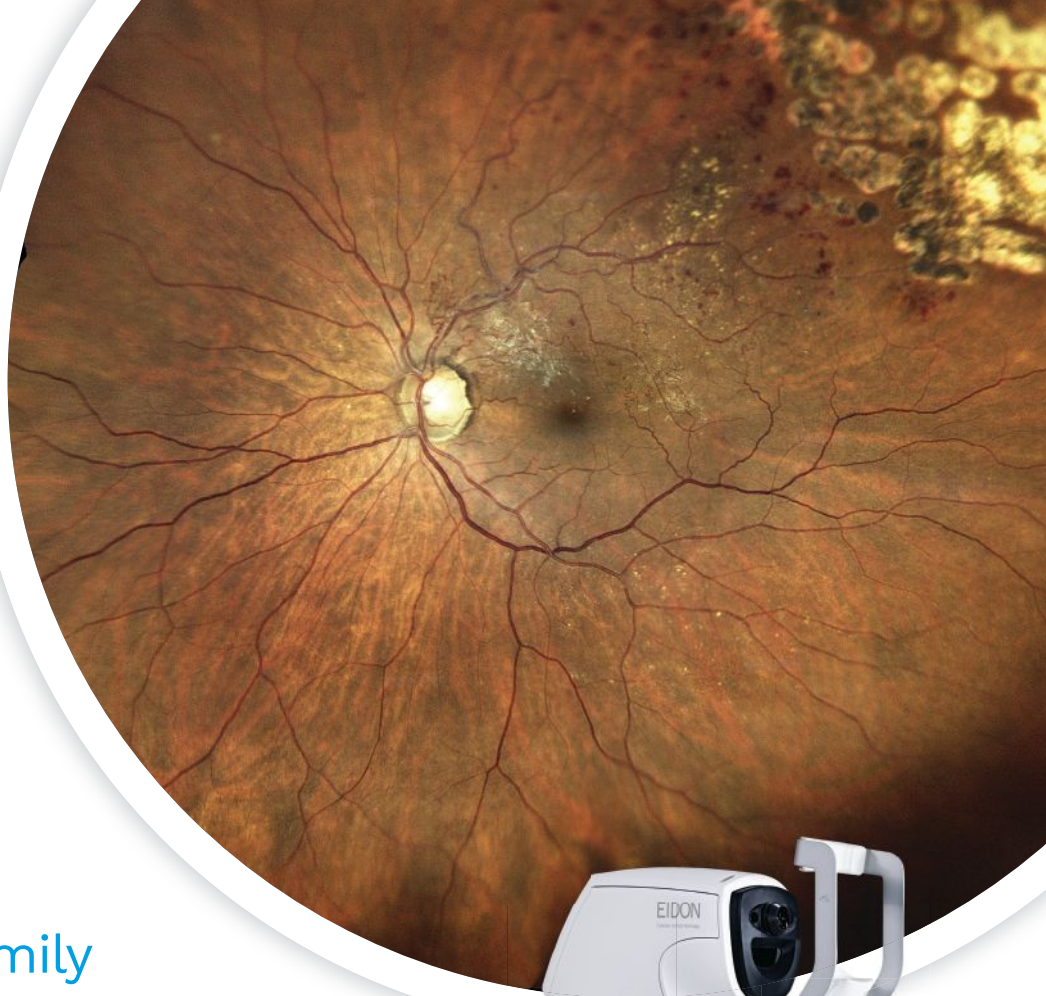The most riveting finding, in my opinion, is that patients with a more advanced disease stage were more likely to be lost to follow-up than patients with milder forms. Again, I would have expected just the opposite. Perhaps patients with more advanced disease feel as if there is no or little hope in management or improvement? I can only conjecture. But as the authors of this study concluded, further investigation as to why this happens is warranted.

So, what do you and I do? How can we help reduce loss to follow-up care for our patients? The simple answer is to do your best. Do your best to offer the highest level of care you can, to stay at the forefront of glaucoma care, to educate your patients as to the importance of disease management and to present material in a way that resonates with them. The simple truth of the matter is that you can lead a horse to water but you cannot make it drink, as the old saying goes. Patients must assume a certain amount of responsibility for their own care. ■

1. Williams AM, Schempf T, Liu PJ, Rosdahl JA. Loss to follow up among glaucoma patients at a tertiary eye center over 10 years: incidence, risk factors, and clinical outcomes. *Ophthalmic Epidemiol.* 2023;30(4):383-91.

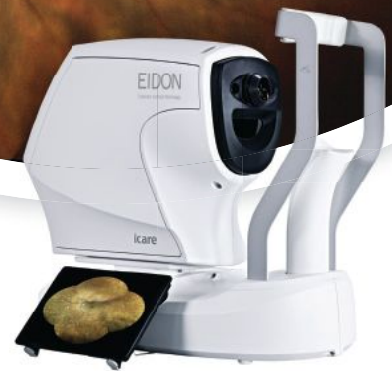

YEARS OF INNOVATION



iCare **EIDON Family**

High-resolution imaging covering 200°



Using white LED light provides TrueColor detail rich retinal images from the macula to the periphery



Confocal Technology allows scanning through media opacities and pupils as small as 2.5 mm resulting in high resolution images



Fully automated easy-to-use family of products with advanced features and multiple imaging modalities



Discover the next level of eye care with our full line of devices.

Scan or visit www.icare-world.com/USA

icare





Punc'd

Not all white dots are created equal.

A 21-year-old Caucasian myopic female presented with a two-week history of acute onset painless central vision loss in her right eye. She denied flashing lights, floaters, redness, pain and photophobia. Her past medical, ocular and family histories were all unremarkable. She was a college student studying pre-law and endorsed significant stress levels in preparing for final exams. A thorough review of systems only elicited outbreak of cold sores within two weeks of symptom onset. Posterior segment imaging can be found below.

Visual acuity (VA) was 20/100 with pinhole improvement to 20/70 OD and 20/20 OS. IOP was 15mm Hg OD and 13mm Hg OS. Confrontation visual fields were full to finger counting and there was no relative afferent pupillary defect. Anterior segment examination was normal and notably negative for anterior chamber or vitreous cell.

Take the Retina Quiz

1. Which of the following regarding interpretation of the multimodal imaging is false?

- There are multifocal gray-white lesions in the right macula by fundus photos.
- There is multifocal hyperautofluorescence in the right macula by fundus autofluorescence.
- There is multifocal hyperfluorescence in the right macula by fluorescein angiography.
- There is subretinal fluid in the right macula on OCT.

2. What is the most likely diagnosis?

- Multifocal choroiditis with panuveitis.
- Multiple evanescent white dot syndrome.

- Punctate inner choroidopathy.
- Presumed ocular histoplasmosis syndrome.

3. Which of the following is NOT typical of the demographic for this disease entity?

- Asian descent.
- Female gender.
- Myopic refractive error.
- All of the above are typical.

4. What is the average visual prognosis for this condition?

- 20/20 or better.
- 20/40 or better.
- 20/200 or worse.
- Hand motions or worse.

5. Which of the following is a reasonable treatment option for this patient?

- Intravitreal anti-vascular endothelial growth factor (VEGF) agent.
- Observation.
- Systemic corticosteroid.
- All of the above.

For answers to the quiz, see page 114.

Diagnosis

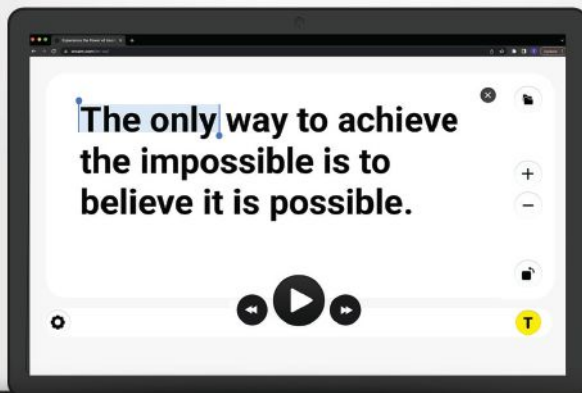
Fundus exam revealed a parafoveal hyperpigmented macular lesion with faint punctate white spots throughout the macula (Figure 1). The parafoveal hyperpigmented lesion demonstrated gross hypo-autofluorescence (AF) with a faint ring of hyper-AF, while the macular white spots all demonstrated hyper-AF on fundus AF (Figure 2). OCT demonstrated multifocal photoreceptor loss involving the fovea and a parafoveal hyperreflective subretinal lesion without

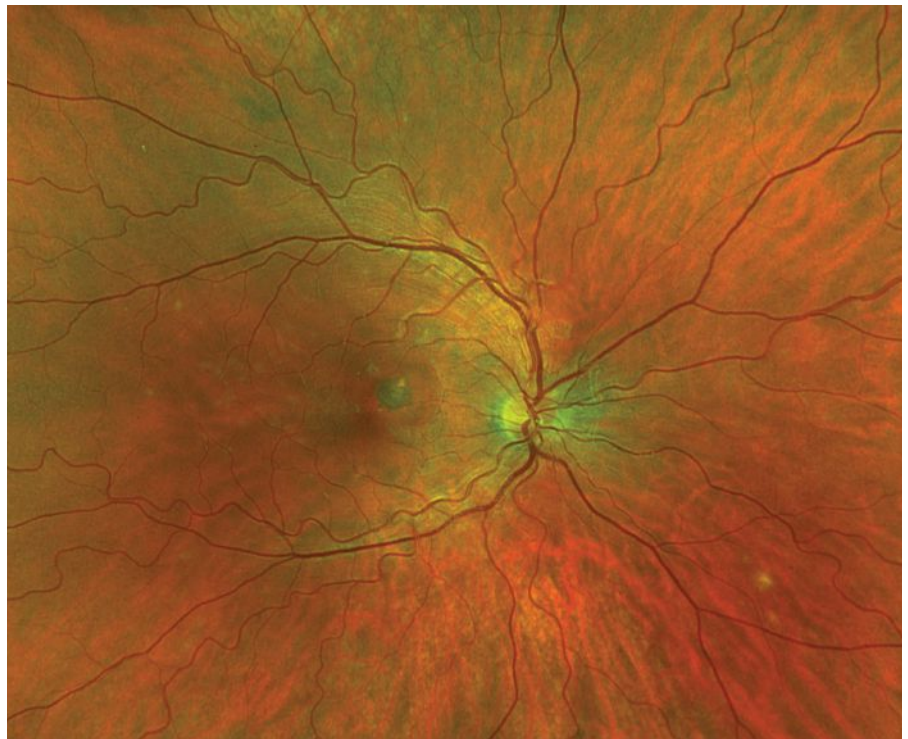

Fig. 1. Optos ultra-widefield fundus photograph of the right eye.

Enable your patients to read independently with the new **OrCam Read 3**

An all-in-one low vision solution that supports evolving vision needs



Read any text,
printed or
digital



Capture
full pages



Smart Reading
and voice
commands



Instant
summarization
of any text*



Easy to use



Zoom in & out



Customize contrast



Copy, paste & save

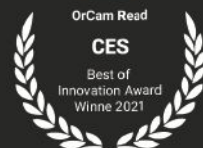

Read aloud any text



Read Handwriting

To offer OrCam to your patients or for a free device demonstration, contact us: usorcam@orcaml.com



 **ORCAM**

* Choose from 20 languages

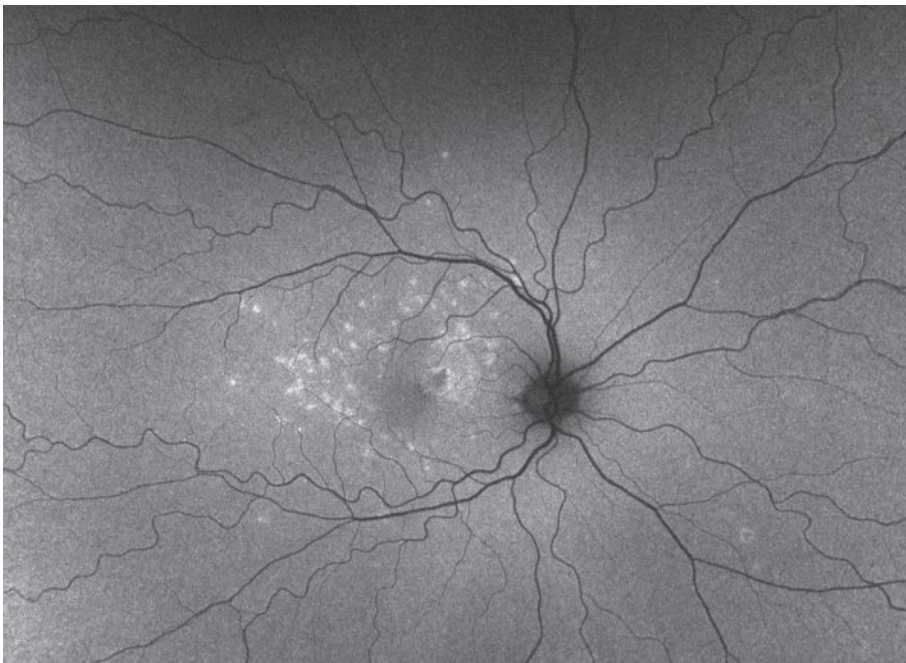


Fig. 2. Optos ultra-widefield fundus autofluorescence of the right eye.

evidence of exudation (*Figure 3*). Fluorescein angiography showed staining of the parafoveal lesion as well as the white macular dots seen clinically; there was notably no leakage seen (*Figure 4*). Indocyanine green angiography demonstrated hypocyancescence of some of the macular lesions in the early and late frames. Serologies for syphilis, tuberculosis, sarcoidosis and general blood chemistries were negative. A clinical diagnosis of punctate inner choroidopathy (PIC) was made.

Discussion

First described in 1984, PIC is a rare inflammatory condition typically affecting young, white (97%), myopic (85%) women (90%).^{1,2} Presentation is often within the second through fifth decades of life with a mean age at diagnosis in the 30s (median 30 years old) and mean refractive error of -4.5D (median -7D), with only 1% of patients being hyperopic.^{1,3} Typical symptoms includes scotomas, photopsias, metamorphopsias and blurred vision.^{1,4} Pathophysiology is thought to be autoimmune, and the presence or family history of autoimmune disease may be a predisposing risk factor; furthermore, a direct familial association of PIC has been demonstrated.⁵

It is believed that PIC, multifocal choroiditis (MFC) and multifocal choroiditis with panuveitis (MCP) all lie on the same spectrum of disease, or at least share a similar pathogenesis.^{3,4} While distinction between PIC and MFC can be challenging, clinical presentation of PIC generally includes multiple round, gray/yellow/white lesions (100µm to 300µm in diameter) of the inner choroid and retinal pigment epithelium (RPE) that are distributed through-

out the posterior pole, and often evolves to bilateral involvement.^{1,2,4} Lesions in MFC tend to be larger in size and extramacular in location, and MCP shows a similar fundus appearance to MFC in the setting of panuveitis, which is notably absent in PIC.^{3,4} Once quiescent, acute inflammatory lesions either produce foci of chorioretinal atrophy with or without pigmentation or resolve entirely without atrophic changes.³ The resultant fundus appearance may be indistinguishable between PIC, MFC and MCP, and also presumed ocular histoplasmosis syndrome. Of note, the absence of vitritis does not necessarily exclude MCP; conversely, the presence of vitritis does not exclude presumed ocular histoplasmosis.⁴ Sequelae of chronic inflammation include macular neovascular membranes and subretinal fibrosis which can impact final VA.³

Multimodal Imaging

This is important when evaluating uveitic entities to best characterize the structures involved and extent of disease dissemination. Fundus AF will show hyper-AF of acute lesions and hypo-AF corresponding with subsequent atrophic changes.⁵ Spectral domain OCT is limited in its ability to image the choroid, but may show acute hyperreflective opacities in the sub-RPE and choroidal space, multifocal outer-retinal and RPE atrophy, choroidal thickening due to cellular infiltration, subretinal fibrosis, macular neovascular membranes formation and subretinal fluid.^{3,5} Fluorescein angiography classically shows early hyperfluorescence with late staining and indocyanine green angiography shows early and late hypocyancescence with sporadic hypercyancescence of blood vessel walls, suggestive of a vasculitic component in some patients.^{1-3,5}

Treatment

Systemic, local and periocular corticosteroids have been used for acute inflammatory lesions and regression of acute macular neovascular membranes, and immunomodulatory therapy has been used in small sample sizes to successfully mitigate disease recurrence.⁴ Macular neovascular membrane management has

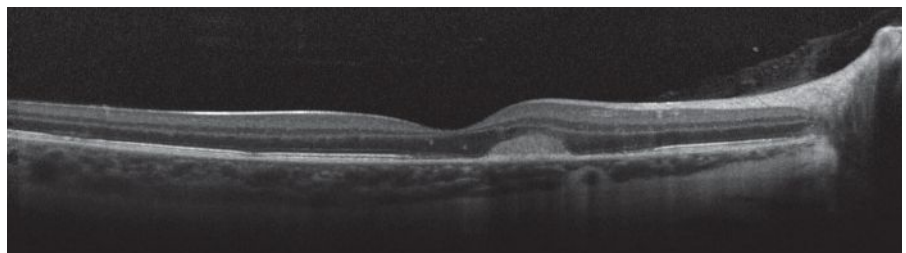


Fig. 3. Spectralis Heidelberg OCT of the right eye.

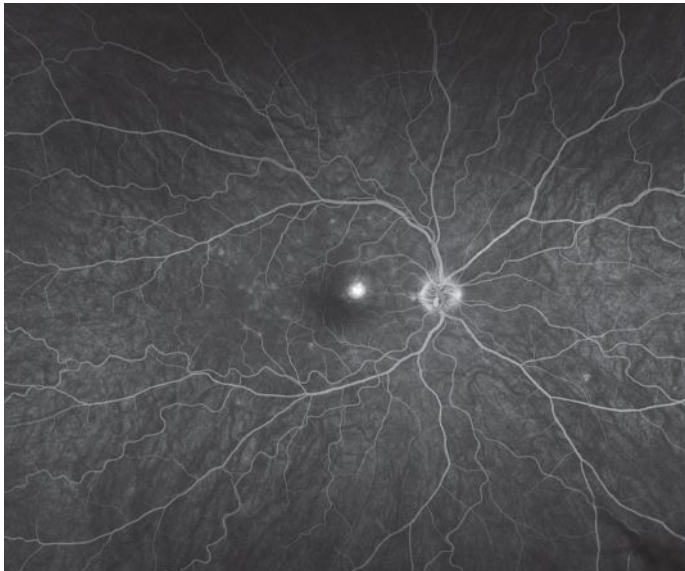

Fig. 4. Optos ultra-widefield fluorescein angiography late phase of the right eye.

evolved from photodynamic therapy to intravitreal anti-VEGF drugs with successful regression of macular neovascular membranes.^{3,4} All therapies carry their own risk/reward profile that should be considered and reviewed in the collaborative decision-making between physician and patient.

Prognosis

Final visual acuity and prognosis in PIC are generally favorable in the absence of macular neovascular membranes, though 40% to 83% of patients either present with or develop macular neovascular membrane lesions at some point in their disease course.^{1,3-6} VA outcomes range from 20/40 or better in as many as 66% to 77% of patients, to 20/200 or worse in 15% to 20% (largely due to fovea-involving macular neovascular membrane and subretinal fibrosis).^{1,3,6}

We felt that our patient presented more subacutely given the presence of a moderately pigmented subretinal macular neovascular membrane adjacent to the fovea. All treatment options were discussed and the collective decision was made to observe closely. The macular dots slowly regressed clinically and on fundus AF in the absence of treatment and the macular neovascular membranes remained stable on OCT with no evidence of exudation at follow-up four months later. She will continue to be monitored for recurrence or evolution to bilaterality. ■

- Amer R, Lois N. Punctate inner choroidopathy. *Surv Ophthalmol.* 2011;56(1):36-53.
- Watzke RC, Packer AJ, Folk JC, et al. Punctate inner choroidopathy. *Am J Ophthalmol.* 1984;98(5):572-84.
- Campos J, Campos A, Mendes S, et al. Punctate inner choroidopathy: a systematic review. *Med Hypothesis Discov Innov Ophthalmol.* 2014;3(3):76-82.
- Agarwal A, Gass JDM. *Gass' Atlas of Macular Diseases*, 5th ed. London: Elsevier-Health Sciences Division. 2011.
- Cicinelli MV, Ramtohol P, Marchese A, et al. Latest advances in white spot syndromes: new findings and interpretations. *Prog Retin Eye Res.* 2023;97:101207.
- Essex RW, Wong J, Fraser-Bell S, et al. Punctate inner choroidopathy: clinical features and outcomes. *Arch Ophthalmol.* 2010;128(8):982-7.

UNITED STATES POSTAL SERVICE® **Statement of Ownership, Management, and Circulation (Requester Publications Only)**

1. Publication Title: **Review of Optometry** 2. Publication Number: **0 8 7 - 3 5 0** 3. Filing Date: **09/11/23**

4. Issue Frequency: **Monthly** 5. Number of Issues Published Annually: **12** 6. Annual Subscription Price (if any): **\$56.00**

7. Complete Mailing Address of Known Office of Publication (Not printer) (Street, city, county, state, and ZIP+4®): **Jobson Medical Information LLC, 283-299 Market St, 2 Gateway Building, 4th Floor, Newark, NJ 07102** Contact Person: **Jared Sonners** Telephone (include area code): **973-206-8091**

8. Complete Mailing Address of Headquarters or General Business Office of Publisher (Not printer): **Jobson Medical Information LLC, 283-299 Market St, 2 Gateway Building, 4th Floor, Newark, NJ 07102**

9. Full Names and Complete Mailing Addresses of Publisher, Editor, and Managing Editor (Do not leave blank)

Publisher (Name and complete mailing address): **Michael Hoster Publisher, Reviews Group
Jobson Medical Information LLC, 19 Campus Drive, Suite 101, Newtown Square, PA 19073**

Editor (Name and complete mailing address): **Jack Persico, Editor-in-Chief
Jobson Medical Information LLC, 19 Campus Drive, Suite 101, Newtown Square, PA 19073**

Managing Editor (Name and complete mailing address): **N/A**

10. Owner (Do not leave blank. If the publication is owned by a corporation, give the name and address of the corporation immediately followed by the names and addresses of all stockholders owning or holding 1 percent or more of the total amount of stock. If not owned by a corporation, give the names and addresses of the individual owners. If owned by a partnership or other unincorporated firm, give its name and address as well as those of each individual owner. If the publication is published by a nonprofit organization, give its name and address.)

Full Name: **WebMD Health Corp** Complete Mailing Address: **283-299 Market Street, 2 Gateway Building, 4th Floor
Newark, NJ 07102**

11. Known Bondholders, Mortgagees, and Other Security Holders Owning or Holding 1 Percent or More of Total Amount of Bonds, Mortgages, or Other Securities. If none, check box. None

Full Name: Complete Mailing Address:

12. Tax Status (For completion by nonprofit organizations authorized to mail at nonprofit rates) (Check one)
 Has Not Changed During Preceding 12 Months (Publisher must submit explanation of change with this statement.)
 Has Changed During Preceding 12 Months (Publisher must submit explanation of change with this statement.)

PS Form 3526-R, July 2014 (Page 1 of 4) (See instructions page 4) PSN: 7530-09-000-8855 PRIVACY NOTICE: See our privacy policy on www.usps.com

3. Publication Title		14. Issue Date for Circulation Data Below	
Review of Optometry		August 15, 2023	
5. Extent and Nature of Circulation		Average No. Copies Each Issue During Preceding 12 Months	No. Copies of Single Issue Published Nearest to Filing Date
Monthly			
a. Total Number of Copies (Net press run)		42,498	42,336
b. Legitimate Paid and/or Requested Distribution (By mail and outside the mail)	(1) Outside County Paid/Requested Mail Subscriptions stated on PS Form 3541. (Include direct written request from recipient, telemarketing, and internet requests from recipient, paid subscriptions including nominal rate subscriptions, employer requests, advertiser's proof copies, and exchange copies.)	40,590	39,935
	(2) In-County Paid/Requested Mail Subscriptions stated on PS Form 3541. (Include direct written request from recipient, telemarketing, and internet requests from recipient, paid subscriptions including nominal rate subscriptions, employer requests, advertiser's proof copies, and exchange copies.)	0	0
	(3) Sales Through Dealers and Carriers, Street Vendors, Counter Sales, and Other Paid or Requested Distribution Outside USPS®	173	159
	(4) Requested Copies Distributed by Other Mail Classes Through the USPS (e.g., First-Class Mail®)	0	0
c. Total Paid and/or Requested Circulation (Sum of 15b (1), (2), (3), and (4))		40,763	40,094
d. Non-requested Distribution (By mail and outside the mail)	(1) Outside County Nonrequested Copies Stated on PS Form 3541 (include sample copies, requests over 3 years old, requests induced by a premium, bulk sales and requests including association requests, names obtained from business directories, lists, and other sources)	1,443	2,011
	(2) In-County Nonrequested Copies Stated on PS Form 3541 (include sample copies, requests over 3 years old, requests induced by a premium, bulk sales and requests including association requests, names obtained from business directories, lists, and other sources)	0	0
	(3) Nonrequested Copies Distributed Through the USPS by Other Classes of Mail (e.g., First-Class Mail, nonrequestor copies mailed in excess of 10% limit mailed at Standard Mail® or Package Services rates)	0	0
	(4) Nonrequested Copies Distributed Outside the Mail (include pickup stands, trade shows, showrooms, and other sources)	96	50
e. Total Nonrequested Distribution (Sum of 15d (1), (2), (3) and (4))		1,539	2,061
f. Total Distribution (Sum of 15c and e)		42,302	42,155
g. Copies not Distributed (See Instructions to Publishers #4, (page #3))		197	181
h. Total (Sum of 15f and g)		42,499	42,336
i. Percent Paid and/or Requested Circulation (15c divided by 15f times 100)		96.36%	95.11%

If you are claiming electronic copies, go to line 16 on page 3. If you are not claiming electronic copies, skip to line 17 on page 3.

UNITED STATES POSTAL SERVICE® **Statement of Ownership, Management, and Circulation (Requester Publications Only)**

6. Electronic Copy Circulation

	Average No. Copies Each Issue During Preceding 12 Months	No. Copies of Single Issue Published Nearest to Filing Date
a. Requested and Paid Electronic Copies	-	-
b. Total Requested and Paid Print Copies (Line 15c) + Requested/Paid Electronic Copies (Line 16a)	-	-
c. Total Requested Copy Distribution (Line 15f) + Requested/Paid Electronic Copies (Line 16a)	-	-
d. Percent Paid and/or Requested Circulation (Both Print & Electronic Copies) (16b divided by 15c x 100)	-	-

I certify that 50% of all my distributed copies (electronic and print) are legitimate requests or paid copies.

7. Publication of Statement of Ownership for a Requester Publication is required and will be printed in the **October 15, 2023** issue of this publication.

8. Signature and Title of Editor, Publisher, Business Manager, or Owner: **B Scott** Date: **09/19/23**

President Jobson Optical Group

I certify that all information furnished on this form is true and complete. I understand that anyone who furnishes false or misleading information on this form or who omits material or information requested on the form may be subject to criminal sanctions (including fines and imprisonment) and/or civil sanctions (including civil penalties).



izervay[™]
(avacincaptad pegol
intravitreal solution) 2 mg

INDICATION

IZERVAY[™] (avacincaptad pegol intravitreal solution) is indicated for the treatment of geographic atrophy (GA) secondary to age-related macular degeneration (AMD)

IMPORTANT SAFETY INFORMATION

CONTRAINDICATIONS

- IZERVAY is contraindicated in patients with ocular or periocular infections and in patients with active intraocular inflammation.

WARNINGS AND PRECAUTIONS

- Endophthalmitis and Retinal Detachments
 - Intravitreal injections, including those with IZERVAY, may be associated with endophthalmitis and retinal detachments. Proper aseptic injection technique must always be used when administering IZERVAY in order to minimize the risk of endophthalmitis. Patients should be instructed to report any symptoms suggestive of endophthalmitis or retinal detachment without delay and should be managed appropriately.

NOW APPROVED

for the treatment of geographic atrophy (GA) secondary to age-related macular degeneration (AMD).



To learn more and stay up to date,
visit [IZERVAYecp.com](https://www.izervayecp.com)

- Neovascular AMD
 - In clinical trials, use of IZERVAY was associated with increased rates of neovascular (wet) AMD or choroidal neovascularization (7% when administered monthly and 4% in the sham group) by Month 12. Patients receiving IZERVAY should be monitored for signs of neovascular AMD.
- Increase in Intraocular Pressure
 - Transient increases in intraocular pressure (IOP) may occur after any intravitreal injection, including with IZERVAY. Perfusion of the optic nerve head should be monitored following the injection and managed appropriately.

ADVERSE REACTIONS

- Most common adverse reactions (incidence $\geq 5\%$) reported in patients receiving IZERVAY were conjunctival hemorrhage, increased IOP, blurred vision, and neovascular age-related macular degeneration.

Please see Brief Summary of Prescribing Information for IZERVAY on the following page.

IZERVAY™ (avacincaptad pegol intravitreal solution)

Rx only

Brief Summary: This information is not comprehensive. Visit IZERVAYecp.com to obtain the FDA-approved product labeling or call 609-474-6755.

1 INDICATIONS AND USAGE

IZERVAY is indicated for the treatment of geographic atrophy (GA) secondary to age-related macular degeneration (AMD).

2 DOSAGE AND ADMINISTRATION

2.1 General Dosing Information

IZERVAY must be administered by a qualified physician.

2.2 Recommended Dosage

The recommended dose for IZERVAY is 2 mg (0.1 mL of 20 mg/mL solution) administered by intravitreal injection to each affected eye once monthly (approximately every 28 ± 7 days) for up to 12 months.

2.4 Injection Procedure

Only 0.1 mL (2 mg) should be administered to deliver a single dose. Any excess volume should be disposed.

Prior to the intravitreal injection, patients should be monitored for elevated intraocular pressure (IOP) using tonometry. If necessary, ocular hypotensive medication can be given to lower the IOP.

The intravitreal injection procedure must be carried out under controlled aseptic conditions, which includes the use of surgical hand disinfection, sterile gloves, a sterile drape, and a sterile eyelid speculum (or equivalent). Adequate anesthesia and a broad-spectrum topical microbicide should be given prior to the injection.

Inject slowly until the rubber stopper reaches the end of the syringe to deliver the volume of 0.1 mL. Confirm delivery of the full dose by checking that the rubber stopper has reached the end of the syringe barrel.

Immediately following the intravitreal injection, patients should be monitored for elevation in intraocular pressure (IOP). Appropriate monitoring may consist of a check for perfusion of the optic nerve head or tonometry.

Following intravitreal injection, patients should be instructed to report any symptoms suggestive of endophthalmitis (e.g., eye pain, redness of the eye, photophobia, blurring of vision) without delay.

Each vial and syringe should only be used for the treatment of a single eye. If the contralateral eye requires treatment, a new vial and syringe should be used and the sterile field, syringe, gloves, drapes, eyelid speculum, filter needle, and injection needle should be changed before IZERVAY is administered to the other eye. Repeat the same procedure steps as above.

Any unused medicinal product or waste material should be disposed of in accordance with local regulations.

3 DOSAGE FORMS AND STRENGTHS

Intravitreal solution: 20 mg/mL clear to slightly opalescent, colorless to slightly yellow solution in a single-dose vial.

4 CONTRAINDICATIONS

4.1 Ocular or Periocular Infections

IZERVAY is contraindicated in patients with ocular or periocular infections.

4.2 Active Intraocular Inflammation

IZERVAY is contraindicated in patients with active intraocular inflammation.

5 WARNINGS AND PRECAUTIONS

5.1 Endophthalmitis and Retinal Detachments

Intravitreal injections may be associated with endophthalmitis and retinal detachments. Proper aseptic injection techniques must always be used when administering IZERVAY in order to minimize the risk of endophthalmitis. Patients should be instructed to report any symptoms suggestive of endophthalmitis or retinal detachment without delay, to permit prompt and appropriate management.

5.2 Neovascular AMD

In clinical trials, use of IZERVAY was associated with increased rates of neovascular (wet) AMD or choroidal neovascularization (7% when administered monthly and 4% in the sham group) by Month 12. Patients receiving IZERVAY should be monitored for signs of neovascular AMD.

5.3 Increase in Intraocular Pressure

Transient increases in intraocular pressure (IOP) have been observed after an intravitreal injection, including with IZERVAY. Perfusion of the optic nerve head should be monitored following the injection and managed as needed.

6 ADVERSE REACTIONS

The following potentially serious adverse reactions are described elsewhere in the labeling:

- Ocular and periocular infections
- Neovascular AMD
- Active intraocular inflammation
- Increase in intraocular pressure
- Endophthalmitis and retinal detachments

6.1 Clinical Trials Experience

Because clinical trials are conducted under widely varying conditions, adverse reaction rates observed in the clinical trials of a drug cannot be directly compared to rates in the clinical trials of another drug and may not reflect the rates observed in practice.

The safety of avacincaptad pegol was evaluated in 733 patients with AMD in two sham-controlled studies (GATHER1 and GATHER2). Of these patients,

292 were treated with intravitreal IZERVAY 2 mg (0.1 mL of 20 mg/mL solution). Three hundred thirty-two (332) patients were assigned to sham.

Adverse reactions reported in ≥2% of patients who received treatment with IZERVAY pooled across GATHER1 and GATHER2, are listed below in Table 1.

Table 1: Common Ocular Adverse Reactions (≥2%) and greater than Sham in Study Eye

Adverse Drug Reactions	IZERVAY N=292	Sham N=332
Conjunctival hemorrhage	13%	9%
Increased IOP	9%	1%
Choroidal neovascularization	7%	4%
Blurred Vision*	8%	5%
Eye pain	4%	3%
Vitreous floaters	2%	<1%
Blepharitis	2%	<1%

* Blurred vision includes visual impairment, vision blurred, visual acuity reduced, visual acuity reduced transiently.

8 USE IN SPECIFIC POPULATIONS

8.1 Pregnancy

Risk Summary

There are no adequate and well-controlled studies of IZERVAY administration in pregnant women. The use of IZERVAY may be considered following an assessment of the risks and benefits.

Administration of avacincaptad pegol to pregnant rats and rabbits throughout the period of organogenesis resulted in no evidence of adverse effects to the fetus or pregnant female at intravenous (IV) doses 5.1 times and 3.2 times the human exposure (based on AUC) at the maximum recommended human dose (MRHD) of 2 mg once monthly, respectively.

In the U.S. general population, the estimated background risks of major birth defects and miscarriage in clinically recognized pregnancies is 2-4% and 15%-20%, respectively.

Animal Data

An embryo fetal developmental toxicity study was conducted with pregnant rats. Pregnant rats received daily intravenous (IV) injections of avacincaptad pegol from day 6 to day 17 of gestation at 0.1, 0.4, 1.2 mg/kg/day. No maternal or embryofetal adverse effects were observed at any dose evaluated. An increase in the incidence of a non-adverse skeletal variation, described as short thoracolumbar (ossification site without distal cartilage) supernumerary ribs, was observed at all doses evaluated. The clinical relevance of this finding is unknown. Plasma exposures at the high dose were 5.1 times the MRHD, based on Area Under the Curve (AUC).

An embryo fetal developmental toxicity study was conducted with pregnant rabbits. Pregnant rabbits received daily IV injections of avacincaptad pegol from day 7 to day 19 of gestation at 0.12, 0.4, 1.2 mg/kg/day. No maternal or embryofetal adverse effects were observed at any dose evaluated. Plasma exposure in pregnant rabbits at the highest dose of 1.2 mg/kg/day was 3.2 times the human exposure at the MRHD, based on AUC.

8.2 Lactation

There is no information regarding the presence of avacincaptad pegol in human milk, the effects of the drug on the breastfed infant or on milk production.

The developmental and health benefits of breastfeeding should be considered along with the mother's clinical need for IZERVAY and any potential adverse effects on the breastfed infant from IZERVAY.

8.4 Pediatric Use

Safety and effectiveness of IZERVAY in pediatric patients have not been established.

8.5 Geriatric Use

Of the total number of patients who received IZERVAY in the two clinical trials, 90% (263/292) were ≥65 years and 61% (178/292) were ≥75 years of age. No significant differences in efficacy or safety of avacincaptad pegol were seen with increasing age in these studies. No dose adjustment is required in patients 65 years and above.

17 PATIENT COUNSELING INFORMATION

Advise patients that following IZERVAY administration, patients are at risk of developing neovascular AMD, endophthalmitis, elevated intraocular pressure and retinal detachments. If the eye becomes red, sensitive to light, painful, or if a patient develops a change in vision, instruct the patient to seek immediate care from an ophthalmologist.

Patients may experience temporary visual disturbances and blurring after an intravitreal injection with IZERVAY and the associated eye examinations. Advise patients not to drive or use machinery until visual function has recovered sufficiently.

Manufactured by:
IVERIC bio, Inc., An Astellas Company. Parsippany, NJ 07054

©2023 IVERIC bio, Inc., An Astellas Company. IZERVAY is a trademark of IVERIC bio, Inc., An Astellas Company.



BY JESSICA STEEN, OD

THERAPEUTIC REVIEW

Keep Count

Endothelial cell loss is a common source of worry in patients with both glaucoma and corneal disease.

Open-angle glaucoma (OAG) or ocular hypertension management in those with corneal endothelial disease or in those who have undergone full- or partial-thickness keratoplasty, progressive optic nerve damage as well as progression of corneal disease or graft-related complications can lead to further visual decline. It's valuable to review the nuances in managing intraocular pressure (IOP) with the goal of slowing vision loss due to OAG while being mindful of the potential impact of treatment on the cornea.

Two recent cases with an established diagnosis of severe stage OAG and significant concomitant corneal disease have highlighted the awareness needed in treatment considerations and the potential impact of treatment for each respective disease process on the progression of the other.

A 68-year-old man with history of corneal decompensation following phacoemulsification with supraciliary microstent implantation and device trim in the left eye presented for evaluation of OAG. His IOPs were 18mm Hg in each eye with central corneal thickness (CCT) of 582 μ m in the right eye and 633 μ m in the left eye. He had been using timolol 0.5% BID OU, Muro 128 QID OS and prednisolone acetate BID OS and had advanced glaucomatous optic neuropathy with significant functional loss in line with optic disc appearance.

The second case, a 72-year-old pseudophakic woman with history of penetrating keratoplasty (PK) more than 20 years prior for reported treatment of

Salzmann nodular degeneration of the right eye, had IOPs of 32mm Hg OD and 14mm Hg OS with central corneal thickness of 518 μ m in the right eye and 511 μ m in the left eye at her initial visit. Her optic discs were obliquely inserted, consistent with increased axial length and previous high myopia with asymmetric but bilateral inferior neuroretinal rim loss. She reported a history of latanoprost, dorzolamide-timolol and brimonidine use without consistent adherence to any topical therapy and had self-discontinued all treatment about six weeks prior to presentation.

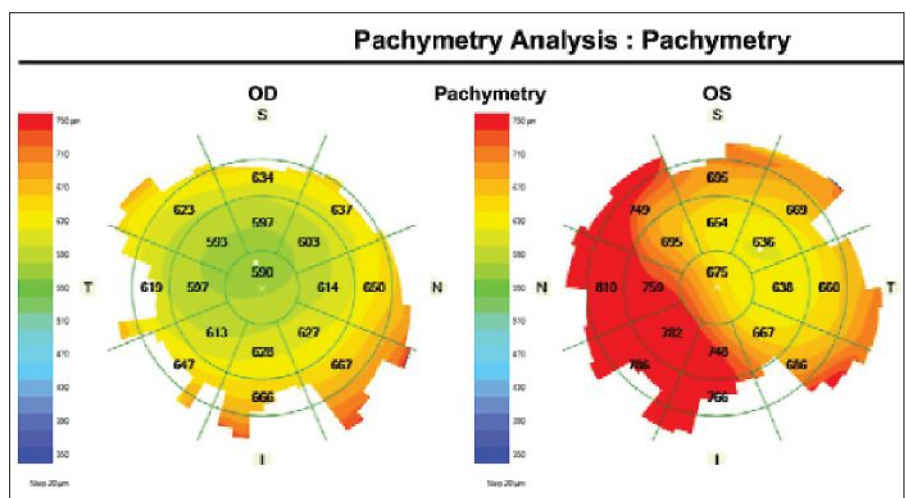
Surgical procedures that lower IOP in individuals with refractory OAG result in endothelial cell loss, which in rare cases may be progressive and necessitate either partial- or full-thickness corneal transplantation, and corneal transplantation is a risk factor for the development

of elevated IOP, as well as the development or progression of glaucoma.

Before and After

Many continue to explore the impact of altering aqueous humor dynamics on ocular structures, including corneal endothelial cells in eyes with OAG through medical and surgical treatment.¹ Endothelial cell count reduction is an expected occurrence after any intraocular procedure, including cataract surgery and vitreoretinal surgery; however, endothelial cell loss months to years after a procedure is an uncommon, but possible, event following glaucoma surgical procedures.²⁻⁴

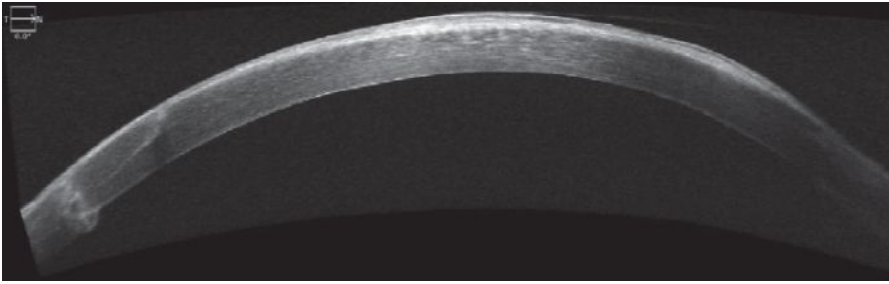
The average incidence of chronic stromal edema five years postoperatively in one study was 11% and 12%, and the progressive endothelial cell density loss identified five years following supraciliary microstent insertion, which ultimately led to voluntary withdrawal followed by FDA Class 1 recall in 2018, supports the long-term need in monitoring corneal health in patients who undergo surgical procedures in the management of glaucoma.¹⁻⁴ If corneal



Increased corneal thickness in the left eye with corneal decompensation.

About Dr. Steen

Dr. Steen is an associate professor at Nova Southeastern University College of Optometry, where she serves as director of the Glaucoma Service, coordinator of the Primary Care with Emphasis in Ocular Disease Residency and teaches courses in glaucoma and ocular pharmacology. Her financial disclosures include Bausch + Lomb, Santen, OcuPhire, Carl Zeiss Meditec, Oyster Point Pharma, Ocuterra, Peripherex, Clearside Biomedical, Allergan, Iveric Bio, Alcon and Thea Pharma.



SD-OCT of the cornea following penetrating keratoplasty.

edema is present and CCT is increased, keep in mind the general overestimation of intraocular pressure by conventional tonometry measures.⁵ Corneal biomechanics are highly complex, and the impact of CCT on IOP is not accurately reflected by existing nomograms or correction factors based on central corneal thickness alone.

History of PK and lamellar keratoplasty are important risk factors for the development of elevated intraocular pressure and glaucoma—both short- and long-term post-op.^{6,7} In a study population of patients with a history of PK or Descemet's stripping endothelial automated keratoplasty, one-third of eyes were determined to require postoperative IOP lowering or escalation of IOP-lowering therapy.⁶ Possible explanations for the OAG or worsening of disease other than elevated IOP due to steroid response include synechial angle closure, increased presence of pro-inflammatory mediators and intraoperative mechanical alteration of the angle that result in reduced trabecular outflow.^{6,7}

History of glaucoma therapy and history of glaucoma surgery in addition to medical therapy are also important risk factors for corneal graft failure.^{6,8}

Medication Considerations

The cytotoxic effects of benzalkonium chloride (BAK) on corneal epithelial cells and conjunctival goblet cells, and its effect of increasing inflammatory markers and tear film destabilization, have been well-described, but its impact on corneal endothelial cells in a clinical environment has not been established.⁹ In a laboratory setting, human corneal endothelial cells were determined to be less viable

following exposure to BAK, which was more pronounced at higher concentrations over longer periods of time.¹⁰ The authors concluded that, due to the effective low-concentration of BAK exposure to corneal endothelial cells in comparison to that of corneal and conjunctival epithelial cells following topical ophthalmic medication instillation, the risk of corneal endothelial cell damage from BAK-preserved IOP-lowering medication was rare.¹⁰ However, considering the host of cytotoxic effects of BAK and the long-term exposure to ocular tissues through chronic therapy in glaucoma management, minimizing BAK load through preservative-free formulations is a reasonable approach to the extent that cost, coverage and access allow.

Of all IOP-lowering medications, dorzolamide and netarsudil are two agents that have been described to have potential impact on the corneal endothelium when topically applied. Dorzolamide reduces aqueous production through selective and temporary inhibition of carbonic anhydrase isozyme II present within the ciliary processes. The enzyme is also present within corneal endothelial cells and its inhibition may impact endothelial cell pump function in moderating stromal hydration.¹¹ While not a contraindication, use topical ophthalmic carbonic anhydrase inhibitors in individuals with low corneal endothelial cell count with caution.¹²

Corneal decompensation has been reported during or following treatment with dorzolamide in nine eyes with previous intraocular surgery and endothelial disease.¹³ Upon further review, each of the nine reported cases had multiple risk factors identified for potential causation of corneal edema and decompensation

through mechanisms other than topical dorzolamide use.¹⁴ In individuals with ocular hypertension or OAG without endothelial abnormality, no significant difference in change in central endothelial cell density or corneal thickness was described in patients treated with dorzolamide in comparison to those treated with timolol or betaxolol.¹¹ In patients with corneal guttata, increased central corneal thickness without decompensation has been measured following three times daily administration of topical dorzolamide for four weeks, supporting the recommendation to monitor patients who use topical dorzolamide in the context of pre-existing corneal endothelial disease.¹⁵

Netarsudil, a commercially available ROCK inhibitor compound, acts to lower IOP through increased trabecular meshwork outflow. In addition to its IOP-lowering effect, netarsudil has also been demonstrated to increase corneal endothelial cell proliferation *in vitro* and has been described as a topically administered adjunct in individuals who undergo Descemet stripping only in the management of Fuchs'.¹⁶ The use of topical netarsudil in patients with Fuchs' endothelial dystrophy continues to be evaluated with a recent Phase II clinical trial identifying decrease in central corneal thickness with once and twice daily dosing with improved visual acuity and symptoms of glare.¹⁷

Takeaways

Considering the advanced optic neuropathy and associated functional vision loss, IOP-lowering therapy was escalated in the 68-year-old man's case. He is currently treated with latanoprost 0.005% QHS OU in addition to dorzolamide-timolol fixed combination BID in the right eye and timolol 0.5% BID in the left eye. The post-PK patient has recently begun latanoprost 0.005% QHS OU with the goal of improved adherence and acceptable tolerability in comparison to previous therapies and is scheduled for follow-up in one month to assess medication efficacy and tolerability.

The common connection of OAG in the context of low endothelial cell

count due to corneal transplant, or low endothelial cell count as a consequence of glaucoma surgery, requires long-term management of both optic nerve and corneal health to maximize visual outcome. ■

- Rosenfeld C, Price MO, Lai X, et al. Distinctive and pervasive alterations in aqueous humor protein composition following different types of glaucoma surgery. *Mol Vis.* 2015;21:911-8.
- Christakis PG, Kalenak JW, Tsai JC, et al. The Ahmed vs. Baerveldt Study: five-year treatment outcomes. *Ophthalmology.* 2016;123(10):2093-102.
- Fang CEH, Mathew RG, Khaw PT, et al. Corneal endothelial cell density loss after glaucoma surgery alone or in combination with cataract surgery: a systematic review and meta-analysis. *Ophthalmology.* 2022;129(8):841-55.
- Lass JH, Benetz BA, He J, et al. Corneal endothelial cell loss and morphometric changes five years after phacoemulsification with or without CyPass micro-stent. *Am J Ophthalmol.* 2019;208:211-8.
- Francis BA, Hsieh A, Lai MY, et al.; Los Angeles Latino Eye Study Group. Effects of corneal thickness, corneal curvature, and intraocular pressure level on Goldmann applanation tonometry and dynamic contour tonometry. *Ophthalmology.* 2007;114(1):20-6.
- Ward MS, Goins KM, Greiner MA, et al. Graft survival vs. glaucoma treatment after penetrating or Descemet stripping automated endothelial keratoplasty. *Cornea.* 2014;33(8):785e9.
- Shree N, Gandhi M, Dave A, et al. Incidence and risk factors for post-penetrating keratoplasty glaucoma. *Indian J Ophthalmol.* 2022;70(4):1239-1245.
- Writing Committee for the Cornea Donor Study Research Group; Sugar A, Gal RL, Kollman C, et al. Factors associated with corneal graft survival in the Cornea Donor Study. *JAMA Ophthalmol.* 2015;133(3):246-54.
- Goldstein MH, Silva FQ, Blender N, et al. Ocular benzalkonium chloride exposure: problems and solutions. *Eye (Lond).* 2022;36(2):361-8.
- Ayaki M, Iwasawa A, Inoue Y. Toxicity of antiglaucoma drugs with and without benzalkonium chloride to cultured human corneal endothelial cells. *Clin Ophthalmol.* 2010;4:1217-22.
- Lass JH, Khosrof SA, Laurence JK, et al. A double-masked, randomized, one-year study comparing the corneal effects of dorzolamide, timolol and betaxolol. Dorzolamide Corneal Effects Study Group. *Arch Ophthalmol.* 1998;116(8):1003-10.
- Merck. Highlights of prescribing information: Trusopt (dorzolamide hydrochloride ophthalmic solution) 2%. www.accessdata.fda.gov/drugsatfda_docs/label/2014/020408s050lbl.pdf. Accessed September 6, 2023.
- Konowal A, Morrison JC, Brown SV, et al. Irreversible corneal decompensation in patients treated with topical dorzolamide. *Am J Ophthalmol.* 1999;127(4):403-6.
- Adamsons I. Irreversible corneal decompensation in patients treated with topical dorzolamide. *Am J Ophthalmol.* 1999;128(6):774-6.
- Wirtitsch MG, Findl O, Heinzl H, et al. Effect of dorzolamide hydrochloride on central corneal thickness in humans with cornea guttata. *Arch Ophthalmol.* 2007;125(10):1345-50.
- Din N, Cohen E, Popovic M, et al. Surgical management of fuchs endothelial corneal dystrophy: a treatment algorithm and individual patient meta-analysis of descemet stripping only. *Cornea.* 2022;41(9):1188-95.
- Lindstrom RL, Lewis AE, Holland EJ, et al. Phase II, randomized, open-label parallel-group study of two dosing regimens of netarsudil for the treatment of corneal edema due to fuchs corneal dystrophy. *J Ocul Pharmacol Ther.* 2022;38(10):657-63.

ADVERTISER INDEX

This index is published as a convenience and not as part of the advertising contract. Every care will be taken to index correctly. No allowance will be made for errors due to spelling, incorrect page number, or failure to insert.

Apellis	33	Menicon	73
.....	www.apellis.com	(800) 636-4266
		www.meniconamerica.com
Bausch + Lomb	COVER TIP	Notal Vision	43
.....	866-246-8245	1-855-600-3112
	www.lumifydrops.com	www.notalvision.com
Bausch + Lomb	45	Novartis Pharmaceuticals	4
.....	866-246-8245	862 778 2100
	www.biortue.com	www.novartis.com
Bruder Healthcare Company	13	Novartis Pharmaceuticals	COVER 2 - 3
.....	(888) 827-8337	862 778 2100
	eyes@bruder.com	www.novartis.com
	www.bruder.com		
Bruder Healthcare Company	95	Oasis Medical	63
.....	(888) 827-8337	(844) 820-8940
	eyes@bruder.com	customerservice@oasismedical.com
	www.bruder.com	www.oasismedical.com
Coburn Technologies	57	Ocular Therapeutix	53, 54
.....	(800) COBURN-1	www.ocutx.com
	www.coburntechnologies.com		
CooperVision	COVER 3	Ocusoft	111
.....	800-341-2020	(800) 233-5469
	www.coopervision.com	www.ocusoft.com
CooperVision	9	Olleyes	51
.....	800-341-2020	(855) 655-3937
	www.coopervision.com	info@olleyes.com
		www.olleyes.com
CooperVision	23	Orcam	101
.....	800-341-2020	eyedoc@orcacom.com
	www.coopervision.com	www.orcam.com
Dompe	19, 20	Oyster Point	58, 59
.....	www.dompe.com/us	www.oysterpointrx.com
Eye Designs	37	RVL Pharmaceuticals, Inc.	Insert
.....	(800) 346-8890	(866) 600-4799
	www.eyedesigns.com	www.rvlpharma.com
Eyefficient	71	Tarsus	114, Cover 4
.....	800-417-8136	www.tarsusrx.com
	www.eyefficient.com		
Glaukos	17	TelScreen	81
.....	(800) 452-8567	502-515-1806
	www.glaukos.com	www.TelScreen.com
Haag-Streit USA	Insert	Thea Pharma	29
.....	(800) 787-5426	781-832-3664
	www.haag-streit.com	www.ivizia.com
Icare USA	99	Thea Pharma	25, 26
.....	(888) 422-7313	781-832-3664
	infoUSA@icare-world.com	www.iyuzeh.com
	www.icare-world.com/USA		
Iveric Bio	104-106	Virtual Vision	97
.....	www.IvericBio.com	www.virtualvision.health
LKC	15	Vital Tears	65
.....	301 840 1992	www.vitaltears.org
	www.lkc.com		
Meivertor	79	X-Cel	47
.....	Meivertor.com	800-241-9312
		www.xcelspecialtycontacts.com



BY DEREK N. CUNNINGHAM, OD, AND
WALTER O. WHITLEY, OD, MBA

SURGICAL MINUTE

The Evolution of IPL

From units to bottles, there's been a big change in how this alternative treatment has been used and designed.

Eight years ago, the initial intense pulsed light (IPL) protocols were developed and an FDA study was done here at Dell Laser Consultants in Austin (Dr. Cunningham's practice). Since then, we have seen several new devices enter this field and many minor alterations in protocols tested. The initial indications for treatment were based on rosacea—more specifically, meibomian gland dysfunction (MGD) from ocular rosacea. Since then, we have seen approval for management of dry eye disease due to MGD.

Although this may seem like a significant indication advancement, the last decade of research in this field has showed us that the majority of general dry eye patients are rosacea-related anyway.

Purpose and Platforms

IPL creates photothermolysis by emitting polychromatic light in millisecond pulse duration using wavelengths of 500nm to 1200nm. Basically, very short pulses of high-energy light are absorbed by photophores (pigment, water, blood vessels) leading to their destruction. By using short pulses of light, we can target these specific cells while causing almost no damage to the surrounding cells.

In MGD, the objective is to deliver energy targeting dermal vascular and pigmented lesions, minimizing vascular leakage of inflammatory mediators and

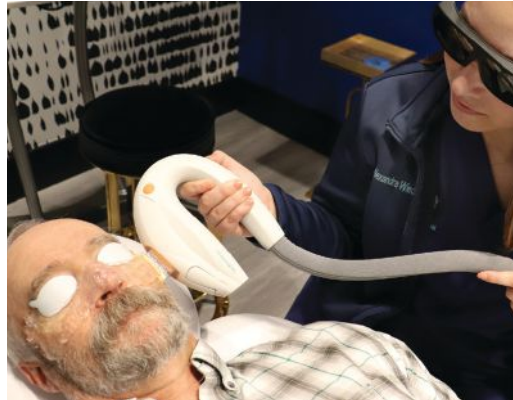

Photo credit: Alexandra Wiechmann, OD

It's important to understand IPL and know the differences between the devices offered.

ablate abnormal vessels.¹ There may also be a photobiomodulation (PBM) effect from the IPL on local tissue and glands. Studies show that PBM can inhibit mast cell degranulation, upregulate antioxidant defenses, reduce reactive oxygen species in oxidative-stressed cells and reduce levels of pro-inflammatory cytokines in activated inflammatory cells.²

Here is a brief breakdown of the similarities between available platforms in the US:

Treatment area. All platforms continue to study treating the upper cheek area from canthus to canthus. Because of the need for eye protection, the actual treatment area is not directly over the meibomian glands. Using current approved protocols and devices, no significant meibomian gland heating has been shown.

Multiple treatments. All current platforms revolve around the initial four treatments separated by two to four weeks.

Differences between platforms include:

Energy. The light that is delivered over a short period of time can be manipulated in many ways. The “flash” of light that you perceive during an IPL is usually multiple pulses at certain energies and certain durations, separated by a specified amount of time to allow for thermal relaxation. For example, a shorter pulse duration will be more painful and absorb more superficially. A longer pulse length will be more gentle and drive energy deeper. The “flash” from the IPL may consist of anywhere from one to eight pulses. The fewer pulses and shorter pulse duration equate to more superficial and uncomfortable treatment. Each of these platforms will have fundamental differences in how they aim to achieve their therapeutic effect.

Cosmetics and pain. There is no doubt that a major driving factor behind the general appeal of IPL was the secondary cosmetic benefit of reducing freckles, age spots, telangiectasia or any irregularity in facial pigment. Although the initial platform for IPL eye treatment (Lumenis M22) was based on a cosmetic-based treatment, more recent IPL platforms have little to no cosmetic benefit. This has been done to decrease discomfort for the patient and may be better targeted at having energy reach the deeper meibomian glands, rather than superficial pigment.

The adoption of IPL in dry eye treatment has been a completely uncharted journey that has much more to be discovered with regards to efficacy and pathophysiology. ■

1. Liu R, Rong B, Tu P, et al. Analysis of cytokine levels in tears and clinical correlations after intense pulsed light treating meibomian gland dysfunction. *Am J Ophthalmol.* 2017;183:81-90.

2. Jiang P, Liu Y, Zhang J, et al. Mast cell stabilization: new mechanism underlying the therapeutic effect of intense pulsed light on rosacea. *Inflamm Res.* 2023;72(1):75-88.

For a video of the procedure, read this article online at www.reviewofoptometry.com.

About Drs. Cunningham and Whitley

Dr. Cunningham is the director of optometry at Dell Laser Consultants in Austin. He has no financial interests to disclose. **Dr. Whitley** is the director of professional relations and residency program supervisor at Virginia Eye Consultants in Norfolk, VA. He is a consultant for Alcon.

Got Mites?

Demodex Mites Live on the Eyelids!

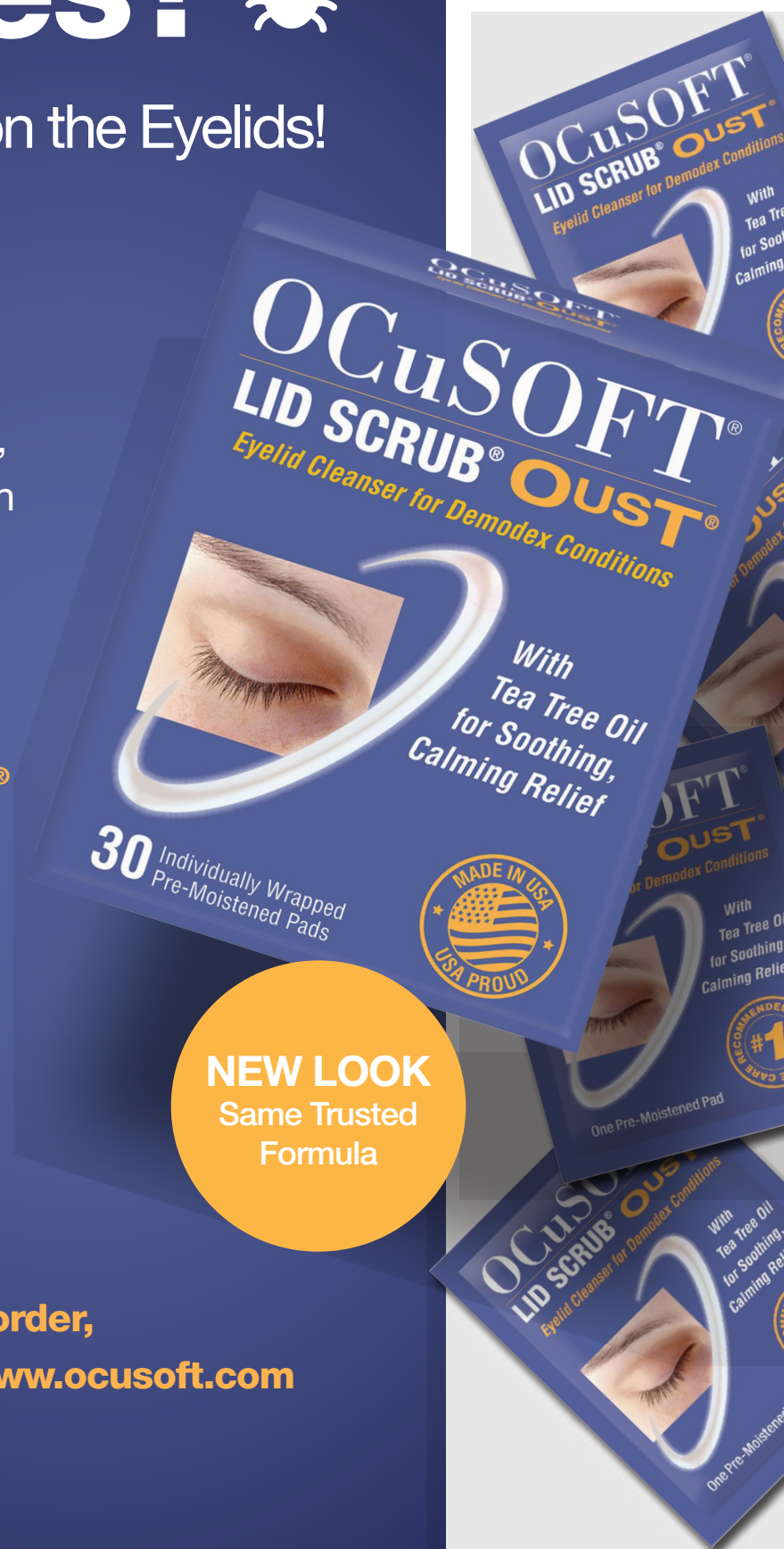Demodex mites are a part of our environment and live on our faces, usually without problems. When an overpopulation occurs, resulting eye/eyelid irritations can arise. OCuSOFT® Lid Scrub® Oust® effectively addresses these problems.

OCuSOFT® Lid Scrub® Oust® Eyelid Cleanser is an extra strength cleanser with tea tree oil that effectively relieves irritation from the eyelashes, eyelids, brow, and face. It also contains a moisturizer to help soothe eyelid discomfort.

For more information and to order, call (800) 233-5469 or visit www.ocusoft.com

OCuSOFT®

©2023 OCuSOFT Inc., Rosenberg, TX 77471



NEW LOOK
Same Trusted
Formula

Merchandise Offered

FRAME DISPLAYS & OPTICAL INTERIORS

FrameDisplays.com is the one-stop-shop for all your optical displays, furniture, and design needs.



Wall Mount



Counter Top



Locking Rods



Trays & Frame Bags



Custom Frame Rods



Optical Cabinets



1-877-274-9300 • www.framedisplays.com



Trusted by more than 40,000 eye care professionals worldwide.

COMPLIMENTARY DESIGN SERVICES



**Complimentary
Zoom Design
Session**



**0% Financing
& Interest for
36 Months***

Practice For Sale



Practice Sales • Appraisals • Consulting
www.PracticeConsultants.com

PRACTICES FOR SALE NATIONWIDE

Visit us on the Web or call us to learn more about our company and the practices we have available.

info@PracticeConsultants.com

925-820-6758

www.PracticeConsultants.com

Targeting Optometrists?

CLASSIFIED ADVERTISING WORKS


- JOB OPENINGS
- CME PROGRAMS
- PRODUCTS & SERVICES
- AND MORE...

Contact us today for classified advertising:
Toll free: **888-498-1460**
E-mail: sales@kerhgroup.com

Contact us today for classified advertising:
Toll free: **888-498-1460**
E-mail: sales@kerhgroup.com

REVIEW[®] of OPTOMETRY

Grow Your Practice



Low Vision Intensive Training 4-day Course

We teach how to:

- create a consistent flow of qualified patients
- conduct the *Shuldiner 12-Step Low Vision Evaluation* in less than an hour
- make low vision in private practice *professionally and financially rewarding*

TURNKEY | Low Financial Risk
20+ Years of Success with 50+ Practices

Learn how to profitably incorporate Low Vision Care into your practice at:
ShuldinerLowVisionTrainingInstitute.org

Or contact

Richard J. Shuldiner, OD, FAAO
Low Vision Diplomat, AAO

Founder, Shuldiner Low Vision Training Institute
(951) 286-2020 | doctor@lowvisioncare.com

Find qualified opticians fast

Finding a qualified optician for your practice can be difficult. That's why private practices and large employers alike trust Eyes On Eyecare® for specialized job posting and recruiting services.

SOURCE TALENT MORE EFFICIENTLY WITH OUR:



Large talent pool of active and passive job seekers



Syndication to major job platforms and cross-promotion to our affiliate network



Dedicated recruiting team with years of eyecare experience sourcing talent for specialized positions



"I had such a wonderful experience using Eyes On Eyecare. It was so easy to post a job and they walk you through the entire process. I recommend them to everyone I know."

- Ashley Wojcik

PROUD PARTNER OF JOBSON OPTICAL GROUP

Learn more at eyesoneyecare.com/hire-now

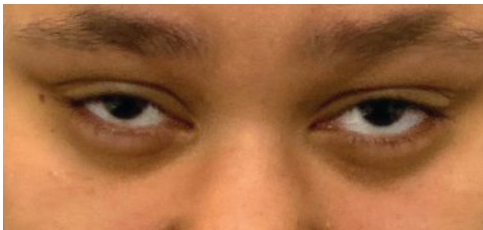


Pain From Above

A young patient experiences difficulty with upgaze movements. How serious might it be?

A 17-year-old woman presented with a chief complaint of headache and pain in upgaze of four months' duration. She explained her vision was good and she realized the issue was getting worse over the last three weeks. Her GP scheduled her to see a neurologist and asked her to see the eye doctor. She denied trauma and took no medications. She denied allergies of any kind.

Best-corrected acuities were 20/20 OD and OS at distance and near. Her external exam found pain upon looking upward in any direction

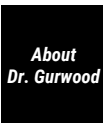

The patient had no restriction of upgaze but reported pain during the experience.

with no limitation of upgaze and no diplopia. There was no afferent pupillary defect. Confrontation fields were full. Anterior segment findings were normal. Goldmann tonometry measured 17mm Hg OU. Dilated fundus exam demonstrated normal-appearing cup disc/ratios measuring 0.3/0.3 round, with sharp and pink discs.

The superior adnexa and orbital rim were palpated, with particular attention paid to the region housing the trochlear fossa, notch and tendon. All other directions of gaze were tested for pain or limitation of motility and diplopia. Exophthalmometry was done to rule out proptosis. The eye was closely inspected for inflammation (iritis, episcleritis). Color and brightness were assessed to ensure there was no evidence of optic neuritis. The fundus was observed for signs of any mass effect (choroidal folds) and papilledema was ruled out by observation of the cup/disc with sharp margins and the identification of a spontaneous venous pulse.

What would be your diagnosis based on the information presented? Read the online version of this article at www.reviewofoptometry.com. ■



Dr. Gurwood is a professor of clinical sciences at The Eye Institute of the Pennsylvania College of Optometry at Salus University. He is a co-chief of Primary Care Suite 3. He is attending medical staff in the department of ophthalmology at Albert Einstein Medical Center, Philadelphia. He has no financial interests to disclose.

Retina Quiz Answers—Q1: d, Q2: c, Q3: a, Q4: b, Q5: d

XDEMY™ (lotilaner ophthalmic solution) 0.25%, for topical ophthalmic use

BRIEF SUMMARY OF PRESCRIBING INFORMATION
Please see the XDEMY™ package insert for full Prescribing Information.

INDICATIONS AND USAGE
XDEMY is indicated for the treatment of Demodex blepharitis.

CONTRAINDICATIONS
None.

WARNINGS AND PRECAUTIONS
Risk of Contamination Do not allow the tip of the dispensing container to contact the eye, surrounding structures, fingers, or any other surface in order to minimize contamination of the solution. Serious damage to the eye and subsequent loss of vision may result from using contaminated solutions.

Use with Contact Lenses Contact lenses should be removed prior to instillation of XDEMY and may be reinserted 15 minutes following its administration.

ADVERSE REACTIONS
Because clinical studies are conducted under widely varying conditions, adverse reaction rates observed in the clinical trials of a drug cannot be directly compared to rates in the clinical trials of another drug and may not reflect the rates observed in practice.

XDEMY was evaluated in 833 patients with Demodex blepharitis in two randomized, double-masked, vehicle-controlled studies (Saturn-1 and Saturn-2) with 42 days of treatment. The most common ocular adverse reaction observed in controlled clinical studies with XDEMY was instillation site stinging and burning which was reported in 10% of patients. Other ocular adverse reactions reported in less than 2% of patients were chalazion/hordeolum and punctate keratitis.

USE IN SPECIFIC POPULATIONS
Pregnancy: Risk Summary There are no available data on XDEMY use in pregnant women to inform any drug associated risk; however, systemic exposure to lotilaner from ocular administration is low. In animal reproduction studies, lotilaner did not produce malformations at clinically relevant doses.

Data Animal Data In an oral embryofetal developmental study in pregnant rats dosed during organogenesis from gestation days 6-19, increased post-implantation loss, reduced fetal pup weight, and incomplete skeletal ossification were observed at 50 mg/kg/day (approximately 1390 times the recommended human ophthalmic dose (RHOD) on a body surface area basis) in the presence of maternal toxicity (i.e., decreased body weight and food consumption). A rare malformation of situs inversus of the thoracic and abdominal viscera occurred in 1 fetus from a pregnant rat receiving 50 mg/kg/day; whether this finding was treatment-related could not be excluded. No maternal or embryofetal toxicity was observed at 18 mg/kg/day (approximately 501 times the RHOD on a body surface area basis). In an oral embryofetal development study in pregnant rabbits dosed during organogenesis from gestation days 7-19, no embryofetal toxicity or teratogenic findings were observed at 20 mg/kg/day (approximately 580-times the RHOD on an AUC basis), even in the presence of maternal toxicity (i.e., decreased food consumption and body weight).

In an oral two-generation reproductive toxicity study, F0 male and female rats were administered lotilaner at doses up to 40 mg/kg/day for 10 weeks before pairing and during the 2-week pairing period (3 weeks for males). Dosing for F0 females continued through lactation day 22. F1 male and female rats were administered lotilaner at 1 and 5 mg/kg/day post-weaning from day 23 for 10 weeks before pairing and during the 2-week pairing period (3 weeks for males). Dosing for F1 parental females continued through lactation day 22. There were no clear adverse effects on the F1 generation, and a slightly lower mean body weight during lactation was noted for F2 pups at 5 mg/kg/day. The observed adverse effect level (NOAEL) was determined to be 5 mg/kg/day

(approximately 139 times the RHOD on a body surface area basis).
Lactation: Risk Summary There are no data on the presence of XDEMY in human milk, the effects on the breastfed infant, or the effects on milk production. However, systemic exposure to lotilaner following 6 weeks of topical ocular administration is low and is >99% plasma protein bound, thus it is not known whether measurable levels of lotilaner would be present in maternal milk following topical ocular administration. The developmental and health benefits of breastfeeding should be considered along with the mother's clinical need for XDEMY and any potential adverse effects on the breast-fed child from XDEMY.

Pediatric Use: Safety and effectiveness in pediatric patients below the age of 18 years have not been established.
Geriatric Use: No overall differences in safety or effectiveness have been observed between elderly and other adult patients.

NONCLINICAL TOXICOLOGY
Carcinogenesis, Mutagenesis, Impairment of Fertility
Carcinogenesis Long-term studies in animals have not been performed to evaluate the carcinogenic potential of lotilaner.
Mutagenesis Lotilaner was not genotoxic in the following assays: Ames assay for bacterial gene mutation, *in vitro* chromosomal aberration assay in cultured human peripheral blood lymphocytes, and *in vivo* rat micronucleus test.

Impairment of fertility In a two-generation study of reproductive performance in rats, F0 male and female rats were administered lotilaner at oral doses of 40 mg/kg/day for 80 days reduced to 20 mg/kg/day for 47-50 supplementary days. Reduced pregnancy rates and decreased implantation rates were observed in F0 females at doses 20 mg/kg/day (approximately 556 times the RHOD on a body surface area basis), which were also associated with maternal toxicity (i.e., decreased body weight and food consumption). No effects on fertility were observed in F0 females at the dose of 5 mg/kg/day (approximately 139 times the MRHOD on a body surface area basis). No effects on fertility were observed in F0 males at the oral dose of 20 mg/kg/day (approximately 556 times the RHOD on a body surface area basis), and no effects on fertility were observed in F1 males and females at the oral dose of 5 mg/kg/day (approximately 139 times the RHOD on a body surface area basis).

PATIENT COUNSELING INFORMATION
Handling the Container Instruct patients to avoid allowing the tip of the dispensing container to contact the eye, surrounding structures, fingers, or any other surface in order to minimize contamination of the solution. Serious damage to the eye and subsequent loss of vision may result from using contaminated solutions.
When to Seek Physician Advice Advise patients that if they develop an intercurrent ocular condition (e.g., trauma or infection), have ocular surgery, or develop any ocular reactions, particularly conjunctivitis and eyelid reactions, they should immediately seek their physician's advice concerning the continued use of XDEMY.

Use with Contact Lenses Advise patients that XDEMY contains potassium sorbate, which may discolor soft contact lenses. Contact lenses should be removed prior to instillation of XDEMY and may be reinserted 15 minutes following its administration.

Use with Other Ophthalmic Drugs Advise patients that if more than one topical ophthalmic drug is being used, the drugs should be administered at least 5 minutes between applications.

Missed Dose Advise patients that if one dose is missed, treatment should continue with the next dose.


RX only
© 2023 Tarsus Pharmaceuticals, Inc. All rights reserved.
XDEMY is a trademark of Tarsus Pharmaceuticals, Inc.
US-2300345 9/23

SPEED. EASE. RANGE.

MyDay® daily disposable multifocal with CooperVision Binocular Progressive System® is a game-changer.¹



Micaela Crowley, O.D.
Lexington, MA



MyDay® multifocal leverages the latest innovation in multifocal contact lens technology with **CooperVision Binocular Progressive System®** to optimize vision for all levels of presbyopia and visual acuity at all distances.² With its speed and ease of fit using OptiExpert™, you can **successfully fit 98% of the time** with two pairs or fewer.^{3,4} Plus, with the **incredible comfort of Aquaform® Technology** that patients' eyes deserve⁵, MyDay® multifocal has changed the game.

If you haven't fit MyDay® multifocal, what are you waiting for? Get in the game.

1. CVI data on file as of May 2023 vs. leading manufacturers. 2. CVI data on file 2020. Prospective, double-masked, bilateral, 1-week dispensing study with MyDay daily disposable multifocal; n=104 habitual MFCL wearers. 3. CVI data on file 2020. Prospective, double-masked, bilateral, one-week dispensing study UK with MyDay® multifocal; n=104 habitual multifocal contact lens wearers. 4. CVI data on file 2021. Prospective, subject-masked, randomized, bilateral, two-week dispensing study at 5 US sites with MyDay® multifocal; n=58 habitual multifocal contact lens wearers. 5. CVI Data on file 2022. Based on global product sales and internal estimates of products using Aquaform® Technology over 12 months in 2022. ©2023 CooperVision 14777ROO 9/23

NOW AVAILABLE
TO PRESCRIBE



Learn more at
XDEMZYHCP.com



xdemzy[™]
(lotilaner ophthalmic
solution) 0.25%

Might over mites

in just 6 weeks

1st &
only

FDA-APPROVED TREATMENT FOR
DEMODEX BLEPHARITIS (DB)

INDICATIONS AND USAGE

XDEMZY (lotilaner ophthalmic solution) 0.25% is indicated for the treatment of *Demodex* blepharitis.

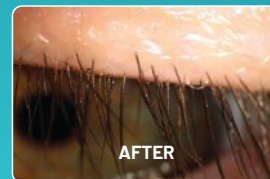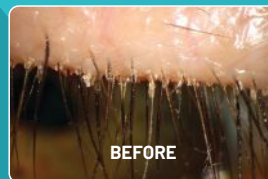
IMPORTANT SAFETY INFORMATION:

WARNINGS AND PRECAUTIONS

Risk of Contamination: Do not allow the tip of the dispensing container to contact the eye, surrounding structures, fingers, or any other surface in order to minimize contamination of the solution. Serious damage to the eye and subsequent loss of vision may result from using contaminated solutions.

Use with Contact Lenses: XDEMZY contains potassium sorbate, which may discolor soft contact lenses. Contact lenses should be removed prior to instillation of XDEMZY and may be reinserted 15 minutes following its administration.

Real results



44% and 55% of patients taking XDEMZY in SATURN-1 (N=209) and SATURN-2 (N=193), respectively, achieved a significant improvement in their eyelids (reduction of collarettes to no more than 2 collarettes per upper lid) at Day 43 vs 7% (N=204) and 12% (N=200) of patients taking vehicle ($P < 0.01$ in each trial).*

All images are of actual patients who participated in clinical trials for Tarsus Pharmaceuticals.

ADVERSE REACTIONS: The most common adverse reaction with XDEMZY was instillation site stinging and burning which was reported in 10% of patients. Other ocular adverse reactions reported in less than 2% of patients were chalazion/hordeolum and punctate keratitis.

Please see next page for a Brief Summary of the full Prescribing Information.

Reference: XDEMZY [prescribing information]. Tarsus Pharmaceuticals, Inc; 2023.

*The safety and efficacy of XDEMZY for the treatment of DB were evaluated in a total of 833 patients (415 of whom received XDEMZY) in two 6-week, randomized, multicenter, double-masked, vehicle-controlled studies (SATURN-1 and SATURN-2). Patients were randomized to either XDEMZY or vehicle at a 1:1 ratio, dosed twice daily in each eye for 6 weeks. All patients enrolled were diagnosed with DB. The primary efficacy endpoint was defined as the proportion of patients with collarette reduction to no more than 2 collarettes per upper eyelid at Day 43 (SATURN-1: XDEMZY N=209, vehicle N=204, $P < 0.01$; SATURN-2: XDEMZY N=193, vehicle N=200, $P < 0.01$).

© 2023 Tarsus Pharmaceuticals, Inc. All rights reserved.
Tarsus, XDEMZY, and the associated logos are trademarks of
Tarsus Pharmaceuticals, Inc. US—2300405 9/23

