

# REVIEW<sup>®</sup> *of* OPTOMETRY

30TH ANNUAL  
SURGERY REPORT

December 15, 2023 • [reviewofoptometry.com](http://reviewofoptometry.com)

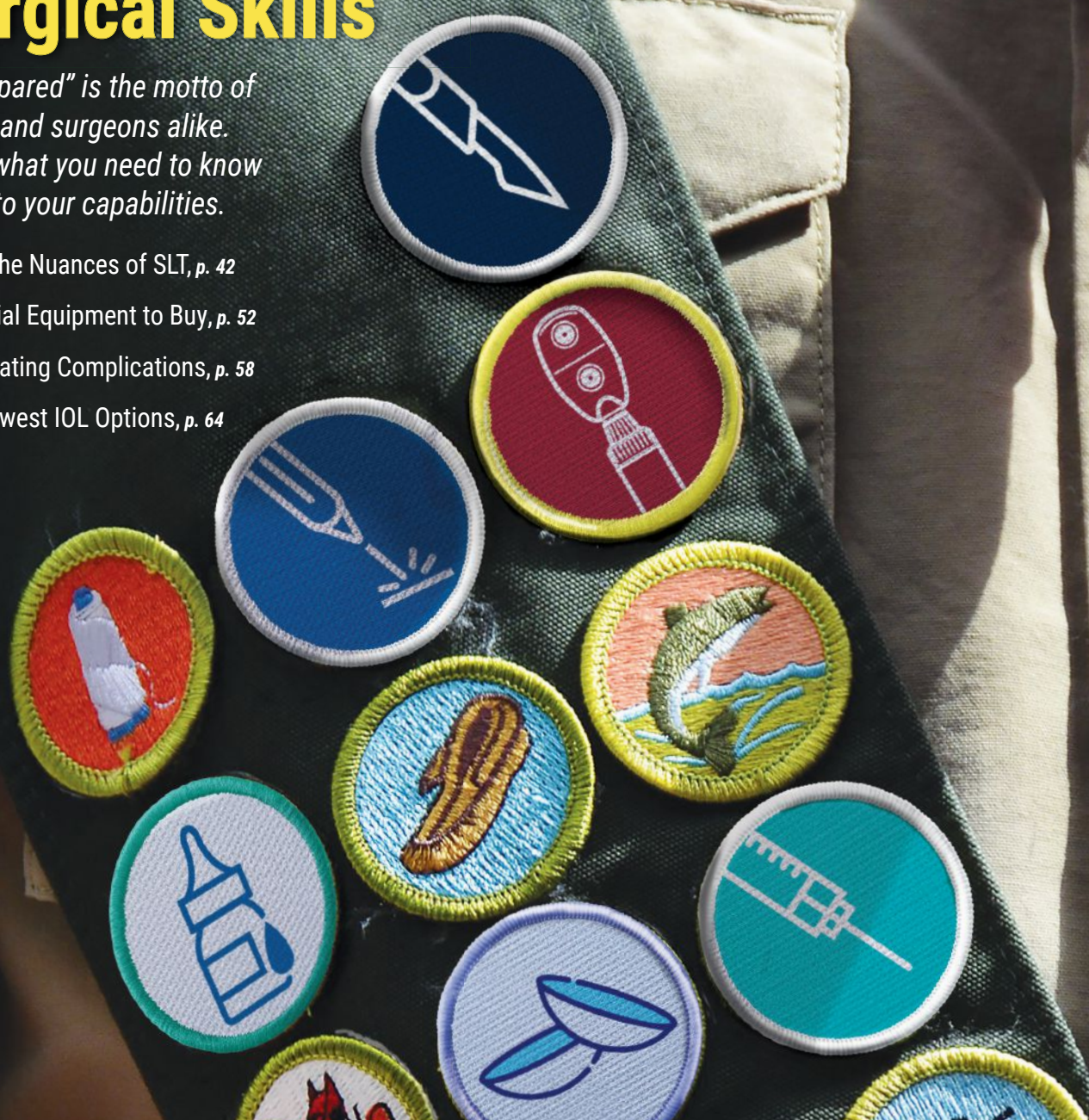Leadership in clinical care

## How to Earn New Surgical Skills

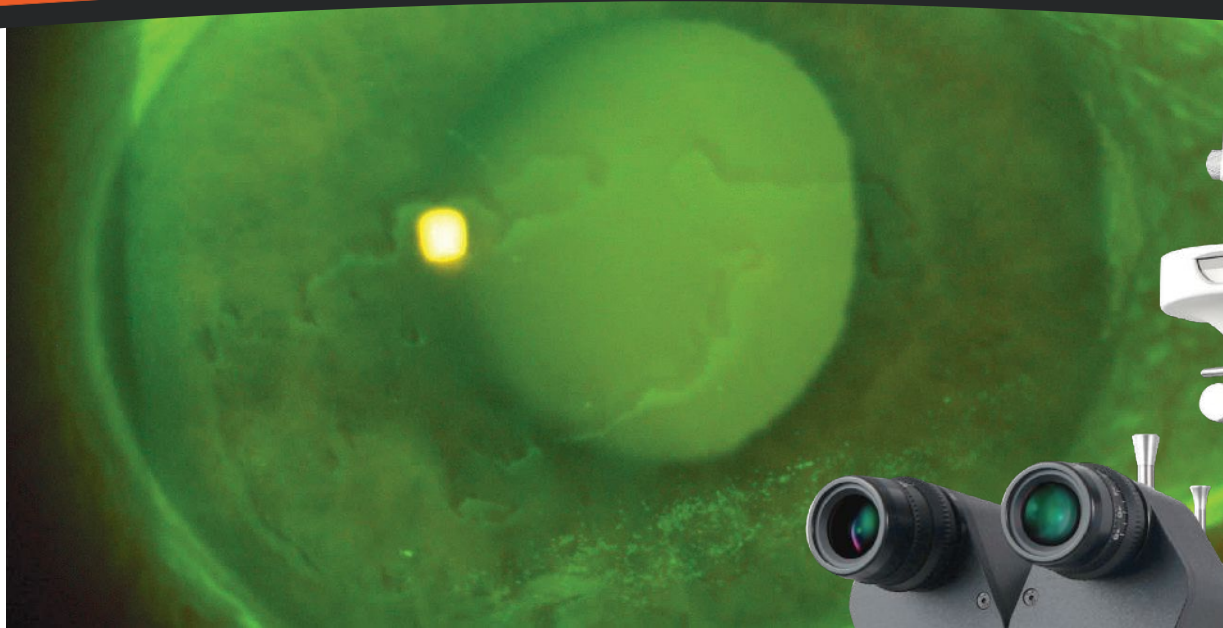
*"Be prepared" is the motto of Scouts and surgeons alike. Here's what you need to know to add to your capabilities.*

- Learn the Nuances of SLT, p. 42
- Essential Equipment to Buy, p. 52
- Anticipating Complications, p. 58
- The Newest IOL Options, p. 64

REVIEW OF OPTOMETRY • VOL. 160, NO. 12 • DECEMBER 15, 2023 • Annual Income Survey • Learn the Nuances of Performing SLT • Equipping the Office for Minor Surgery • Surgical Complications • Cataract Comanagement



# The Anterior Segment Virtuoso



Nothing performs better in the anterior chamber than the Firefly® Imaging System. Using wavelengths similar to natural light, it delineates eye anatomy with an optical resolution of 200 lp/mm.

The standard Firefly comes fully loaded with video capture, automatic exposure, artificial intelligence, meibography, and a Wratten yellow filter. Optional Dry Eye Diagnostic module.

See Firefly's online image gallery, and we're sure you'll applaud the performance. Visit [eyefficient.com](http://eyefficient.com)



FIREFLY'S ONLINE GALLERY



EYEFFICIENT<sup>SM</sup>

© 2023 EYEFFICIENT, ALL RIGHTS RESERVED

## CLINICAL EDITORS

**CHIEF CLINICAL EDITOR** ~ PAUL M. KARPECKI, OD

**ASSOCIATE CLINICAL EDITORS** ~ JOSEPH P. SHOVLIN, OD, CHRISTINE SINDT, OD

## CONTRIBUTING EDITORS

**RAMI ABOUMOURAD, OD, MIAMI**

**PAUL C. AJAMIAN, OD, ATLANTA**

**SHERRY J. BASS, OD, NEW YORK**

**ALISON BOZUNG, OD, MIAMI**

**DEREK N. CUNNINGHAM, OD, AUSTIN, TX**

**JAMES L. FANELLI, OD, WILMINGTON, NC**

**ANDREW S. GURWOOD, OD, PHILADELPHIA**

**PAUL M. KARPECKI, OD, LEXINGTON, KY**

**BISANT LABIB, OD, ELKINS PARK, PA**

**NATE LIGHTHIZER, OD, TAHLEQUAH, OK**

**PAMELA H. SCHNELL, OD, MEMPHIS**

**JOSEPH P. SHOVLIN, OD, SCRANTON, PA**

**JEROME SHERMAN, OD, NEW YORK**

**MARC TAUB, OD, MEMPHIS**

**MONTGOMERY VICKERS, OD, DALLAS**

**WALTER O. WHITLEY, OD, MBA, VIRGINIA BEACH, VA**

## EDITORIAL ADVISORY BOARD

**JEFFREY R. ANSHEL, OD, KAUAI, HAWAII**

**JILL AUTRY, OD, RPH, HOUSTON**

**SHERRY J. BASS, OD, NEW YORK**

**EDWARD S. BENNETT, OD, ST. LOUIS**

**MARC R. BLOOMENSTEIN, OD, SCOTTSDALE, AZ**

**ALISON BOZUNG, OD, MIAMI**

**MILE BRUJIC, OD, BOWLING GREEN, OH**

**CHRIS J. CAKANAC, OD, MURRYSVILLE, PA**

**JERRY CAVALLERANO, OD, PhD, BOSTON**

**BRIAN CHOU, OD, SAN DIEGO**

**MICHAEL CHAGLASIAN, OD, CHICAGO**

**A. PAUL CHOUS, MA, OD, TACOMA, WA**

**GLENN S. CORBIN, OD, WYOMISSING, PA**

**MARK T. DUNBAR, OD, MIAMI**

**S. BARRY EIDEN, OD, DEERFIELD, IL**

**STEVEN FERRUCCI, OD, SEPULVEDA, CA**

**MURRAY FINGERET, OD, HEWLETT, NY**

**IAN BEN GADDIE, OD, LOUISVILLE, KY**

**GARY S. GERBER, OD, HAWTHORNE, NJ**

**JESSICA HAYNES, OD, MEMPHIS**

**MILTON HOM, OD, AZUSA, CA**

**DAVID KADING, OD, SEATTLE**

**JEROME A. LEGERTON, OD, MBA, SAN DIEGO**

**THOMAS L. LEWIS, OD, PhD, PHILADELPHIA**

**BLAIR B. LONSBERRY, MS, OD, MED, PORTLAND, OR**

**KELLY A. MALLOY, OD, PHILADELPHIA**

**DANICA MARRELLI, OD, HOUSTON**

**RON MELTON, OD, CHARLOTTE, NC**

**PAMELA J. MILLER, OD, JD, HIGHLAND, CA**

**MARC MYERS, OD, COATESVILLE, PA**

**CARLO J. PELINO, OD, JENKINTOWN, PA**

**JOSEPH PIZZIMENTI, OD, FORT LAUDERDALE, FL**

**CHRISTOPHER J. QUINN, OD, ISELIN, NJ**

**MOHAMMAD RAFIEETARY, OD, MEMPHIS**

**JOHN L. SCHACHET, OD, ENGLEWOOD, CO**

**JACK SCHAEFFER, OD, BIRMINGHAM, AL**

**PAMELA H. SCHNELL, OD, MEMPHIS**

**LEO P. SEMES, OD, JACKSONVILLE, FL**

**DIANA L. SHECHTMAN, OD, FORT LAUDERDALE, FL**

**JEROME SHERMAN, OD, NEW YORK**

**LEONID SKORIN, JR., OD, DO, ROCHESTER, MN**

**JOSEPH W. SOWKA, OD, SARASOTA, FL**

**JESSICA STEEN, OD, DAVIE, FL**

**BRAD M. SUTTON, OD, INDIANAPOLIS**

**LORETTA B. SZCZOTKA, OD, PhD, CLEVELAND**

**MARC TAUB, OD, MEMPHIS**

**TAMMY P. THAN, MS, OD, SUN CITY, AZ**

**RANDALL THOMAS, OD, MPH, CONCORD, NC**

**SARA WEIDMAYER, OD, ANN ARBOR, MI**

**KAREN YEUNG, OD, LOS ANGELES**



### Business Offices

19 Campus Boulevard, Suite 101

Newtown Square, PA 19073

Subscription inquiries (877) 529-1746 (USA only)

outside USA, call (847) 763-9630

### PUBLISHER

**MICHAEL HOSTER**

(610) 492-1028

mhoster@jobson.com

SENIOR MANAGER, STRATEGIC ACCOUNTS

**MICHELE BARRETT**

(610) 492-1014

mbarrett@jobson.com

REGIONAL SALES MANAGER

**JONATHAN DARDINE**

(610) 492-1030

jdardine@jobson.com

PRODUCTION MANAGER

**KAREN LALLONE**

(610) 492-1010

klallone@jobson.com

DIGITAL MARKETING MANAGER

**MATT EGGER**

(610) 492-1029

megger@jobson.com

### CLASSIFIED ADVERTISING

(888) 498-1460

### SUBSCRIPTIONS

\$63 PER YEAR, \$99 (US) IN CANADA,

\$158 (US) IN ALL OTHER COUNTRIES

revoptometry@cambeystwest.com

### CIRCULATION

PO BOX 71, CONGERS, NY 10920-0071

(877) 529-1746

OUTSIDE USA: (845) 267-3065

SENIOR CIRCULATION MANAGER

**HAMILTON MAHER**

(212) 219-7870

hmaher@jhihealth.com

CEO, INFORMATION GROUP SERVICES

**BILL SCOTT**

SENIOR VICE PRESIDENT, CREATIVE SERVICES & PRODUCTION

**MONICA TETTAMANZI**

DIRECTOR, PRODUCTION /MANUFACTURING

**REBECCA SLEBODNIK**

SENIOR VICE PRESIDENT, HUMAN RESOURCES

**TAMMY GARCIA**

VICE PRESIDENT, CIRCULATION

**JARED SONNERS**

Jobson Health Information/WebMD

299 Market St. 2 Gateway Center - 4th Floor Newark NJ 07102



## Bill Pushes to Add Controlled Substances to Optometry's Scope in Washington D.C.

*After nearly three decades, the jurisdiction may soon join the 47 US states where ODs can currently prescribe and administer these drugs.*

Optometrists in the District of Columbia currently have one of the most restrictive scopes of practice in the United States. The last legal update to the profession's purview in D.C. occurred in April 1998, when licensed ODs in the jurisdiction became authorized to treat and manage glaucoma and administer injections for anaphylaxis. After years of stagnant policy, the mayor of D.C., Muriel Bowser, introduced a bill on October 20 called the Health Occupations Revision General Amendment Act of 2023. The proposal, sponsored by Councilmember Phil Mendelson, outlines several updates to the scope of practice of multiple allied health professionals, including optometrists, podiatrists and pharmacists. In her letter to the Council, Mayor Bowser declared that the changes are intended "for clarity or to reflect current practice trends."

Specifically relating to optometrists, Bill 25-0545 cites that their scope of



**A public hearing took place December 7 at the John A. Wilson Building in Washington, D.C. to discuss a proposal that would, if enacted, give D.C. optometrists the right to prescribe opioids and other controlled substances.**

practice should be expanded "to permit the prescribing and administering of controlled substances as related to the profession." In other words, the pharmaceutical agents used must be "rational to the diagnosis and treatment of diseases of the human eye and its adjacent structures," the bill defines.

Under the current law, ODs in D.C. can only prescribe oral immunosuppressives or medications for glaucoma. This leaves a large gap in care that can possibly delay treatment, as many patients must be referred to other providers to access needed drugs. This isn't because optometrists are not properly trained in this service; in actuality, the clinical use of controlled substances has been taught in US optometry schools for several decades, a fact recognized by the 47 states today that permit ODs to prescribe and administer these drugs to patients. Its near-universal acceptance provides compelling evidence of the regulation's established safety and necessity. Accompanying D.C., the only US states that also still exclude controlled substances from optometry's scope include Hawaii, Maryland and New York.

A public hearing led by the Committee on Health was held earlier this month on Dec. 7 to discuss the bill. ◀

### IN BRIEF

**Ortho-K Safe, With Room for Improvement.** Orthokeratology has long been recognized as a beneficial option to control myopia progression. Researchers in China evaluated the current literature on the modality in reducing myopia development in school-age children to better understand its efficacy and provide evidence for the clinical treatment of myopia. **They found ortho-K to be a safe**

**means to prevent and control myopia—but improving the visual quality of the lens optical area, reducing irritation, improving tear circulation and tear film stability remain important considerations to address.**

A total of 14 studies involving 2,058 children were included in this meta-analysis. The researchers analyzed at least one year of follow-up data of children aged six to 18 with myopia whose spherical refraction was less than -6.00D

and cylindrical lens was less than -1.50D.

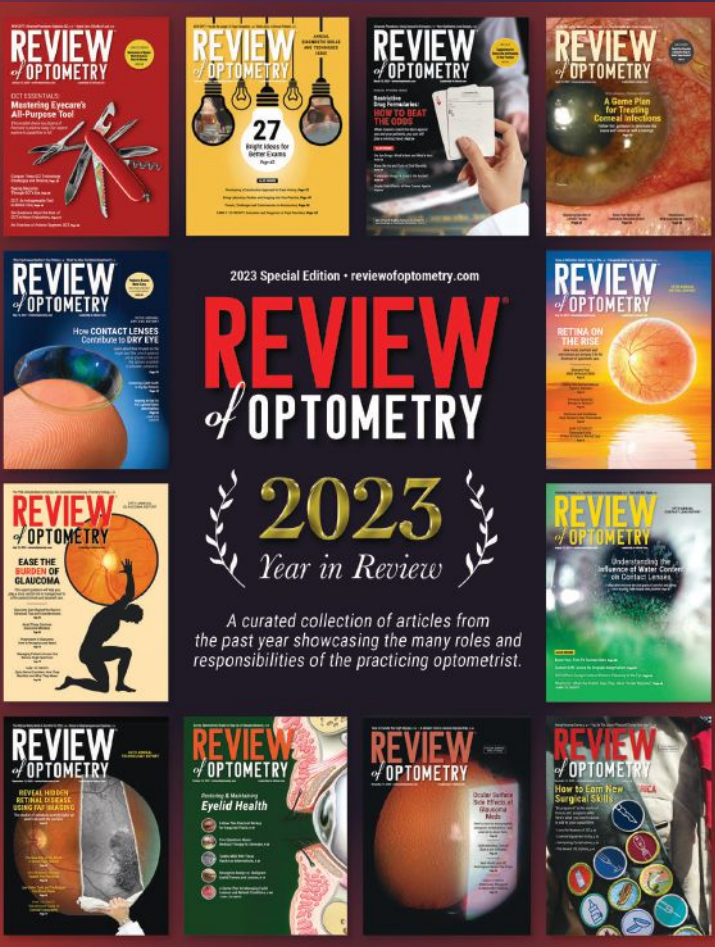
Outcomes indicated that ortho-K improved the uncorrected visual acuity (mean difference; MD=0.40), reduced the diopter change (MD=-3.19) and changed the corneal curvature (MD=-3.21), ocular axis length (MD=-0.66) and amount of ocular axis change (MD=-0.42) after one year of lens wear. Ortho-K lenses also reduced the diopter change (MD=-3.22), length of ocular axis (MD=-1.15) and amount of

ocular axis change after two years of wear (MD=-0.53).

**"These results show that compared with the frame lens, the naked vision, corneal curvature, diopter, axial length and their changes in patients with the corneal plastic lens are statistically different and the myopia control effect are superior,"** the authors of the paper highlighted.

Li X, Xu M, San S, et al. Orthokeratology in controlling myopia of children: a meta-analysis of randomized controlled trials. *BMC Ophthalmol.* 2023;23:441.

# A Year in the Making.




Our 2023 recap delivers:

- “How-to” guidance on dozens of clinical techniques
- Timely insights from the scientific literature
- The year’s biggest legislative news stories
- Commentary from trusted voices in the profession

...all in one place!

Available now at [reviewofoptometry.com](http://reviewofoptometry.com)



## Blue Eyes Save Lives

As the ciliary body is not observed during a routine eye exam, a melanoma is nearly never detected there until it may be too late.

Many eye clinicians go through their eye exams without once seeing the ciliary body. Most ophthalmologists would do so to determine whether a melanoma is present, but it is a rare cancer that is difficult to detect. The ciliary body is a small, oval-shaped structure located in the eye, and it is responsible for producing aqueous humor. It is located behind the iris and in front of the vitreous body. The ciliary body is not visible during a routine eye exam, and it is often overlooked during a comprehensive eye exam. This is because the ciliary body is located behind the iris, and the iris is not fully dilated during a routine eye exam. As a result, the ciliary body is not visible, and any melanoma that may be present is not detected. This is a significant problem because ciliary body melanoma is a rare but aggressive cancer that can lead to blindness if not detected and treated early. The only way to detect a ciliary body melanoma is through a thorough dilated fundus examination, which allows the clinician to see the ciliary body. However, even a dilated fundus examination can miss a ciliary body melanoma if the clinician is not looking for it. This is because the ciliary body is a small, oval-shaped structure that is often overlooked during a dilated fundus examination. The only way to ensure that a ciliary body melanoma is not missed is to perform a thorough dilated fundus examination, including a careful inspection of the ciliary body. This is a challenging task, but it is essential for the early detection and treatment of this rare and aggressive cancer.

## REVEAL HIDDEN RETINAL DISEASE USING FAF IMAGING

This marker of metabolic activity lights up what's beneath the surface.

Retinal Fluorescence Imaging (FAI) is a non-invasive, non-contact imaging technique that allows clinicians to visualize the retinal vasculature and detect early signs of retinal disease. FAF imaging is based on the principle of fluorescence, where a specific wavelength of light is used to excite a fluorescent dye that has been injected into the retinal vasculature. The dye then emits light at a longer wavelength, which is captured by a camera. This process allows clinicians to visualize the retinal vasculature in a way that is not possible with standard fundus photography. FAF imaging is particularly useful for detecting early signs of retinal disease, such as diabetic retinopathy, age-related macular degeneration (AMD), and retinal vein occlusion (RVO). FAF imaging can also be used to monitor the progression of these diseases and to evaluate the effectiveness of treatment. FAF imaging is a valuable tool for clinicians, as it allows them to detect retinal disease at an early stage, before it has caused significant vision loss. This early detection is crucial for the timely initiation of treatment, which can help to preserve vision and improve the quality of life for patients. FAF imaging is a non-invasive, non-contact imaging technique that allows clinicians to visualize the retinal vasculature and detect early signs of retinal disease. FAF imaging is based on the principle of fluorescence, where a specific wavelength of light is used to excite a fluorescent dye that has been injected into the retinal vasculature. The dye then emits light at a longer wavelength, which is captured by a camera. This process allows clinicians to visualize the retinal vasculature in a way that is not possible with standard fundus photography. FAF imaging is particularly useful for detecting early signs of retinal disease, such as diabetic retinopathy, age-related macular degeneration (AMD), and retinal vein occlusion (RVO). FAF imaging can also be used to monitor the progression of these diseases and to evaluate the effectiveness of treatment. FAF imaging is a valuable tool for clinicians, as it allows them to detect retinal disease at an early stage, before it has caused significant vision loss. This early detection is crucial for the timely initiation of treatment, which can help to preserve vision and improve the quality of life for patients.

## PRACTICAL SKILLS REFRESHER: T IDEAS FOR BETTER EXAMS

Practicing to prepare a minor evaluation, we offer suggestions to improve our diagnostic efficiency without fancy equipment.

As an optometrist, you know that a thorough eye exam is essential for the early detection and treatment of eye disease. However, many clinicians find that their eye exams are often incomplete, leading to missed diagnoses and delayed treatment. This is often due to a lack of time or a lack of resources. However, there are several practical tips that can help to improve the efficiency of your eye exams, allowing you to provide a more thorough evaluation in less time. One of the most important tips is to practice. Practicing your eye exam skills regularly can help to improve your efficiency and accuracy. This can be done by using a variety of resources, including textbooks, online courses, and simulation software. Another important tip is to use a checklist. A checklist can help to ensure that you are performing all of the necessary components of an eye exam, and it can also help to identify areas where you may need to improve. Finally, it is important to stay up-to-date on the latest research and techniques in eye care. This can be done by attending conferences, taking continuing education courses, and reading the latest journals and articles. By following these tips, you can improve the efficiency of your eye exams, allowing you to provide a more thorough evaluation in less time. This is essential for the early detection and treatment of eye disease, which can help to preserve vision and improve the quality of life for your patients.

## PRACTICAL WORKUP QUIRED PTOSIS

Consider for a multitude of reasons before diagnosis and treatment.

Ptosis is a condition characterized by the drooping of the upper eyelid. It can be caused by a variety of factors, including aging, muscle weakness, and nerve damage. Ptosis can be a cosmetic concern, but it can also be a sign of a more serious underlying condition. Therefore, it is important to carefully evaluate the patient with ptosis to determine the cause and the appropriate treatment. The evaluation should include a thorough history and physical examination, as well as a detailed eye exam. The history should focus on the onset and progression of the ptosis, as well as any associated symptoms. The physical examination should include a careful inspection of the eyelids and the surrounding structures. The eye exam should include a visual acuity test, a refraction, and a dilated fundus examination. In addition, it is important to perform a ptosis quantification test, which involves measuring the height of the eyelid in millimeters. This test can help to determine the severity of the ptosis and to guide the treatment. There are several treatment options for ptosis, including surgery, botox, and observation. The choice of treatment depends on the cause of the ptosis, the severity of the condition, and the patient's preferences. In some cases, surgery may be the best option, while in other cases, botox or observation may be more appropriate. It is important to discuss the risks and benefits of each treatment option with the patient and to make a decision based on the patient's best interests. Ptosis is a condition that requires a careful and thorough evaluation. By following these steps, you can ensure that you are providing the best possible care for your patients with ptosis.

# Vermont to Introduce Laser Bill Next Month

The state's Office of Professional Regulation has come around to supporting the expansion of optometry's practice scope after opposing it back in 2020.

After several years of laborious efforts to pass legislation that would add in-office procedures—such as injections, lesion removal and certain lasers—to optometry's scope of practice, ODs and advocates in Vermont experienced a devastating setback in 2020. The bill's halt was provoked by a detailed report from its Office of Professional Regulation (OPR), which had been ordered by the General Assembly at the time. At the end of the 40-page document, the OPR stated that it recommended against the scope expansion proposal. It cited that this decision was due to an “inability to confirm that clearly established and appropriately tailored didactic and *in vivo* education and training in specified procedures is universal to accredited educational programs.”

In response to optometry's pushback, in 2021 the OPR was tasked with performing a more comprehensive and fact-based study on the proposed procedures. Fast-forward to this September and the Office has released a new report—a whopping 258 pages—in which its stance on the matter has made a complete 180° from that in 2020. Now, the OPR stands in support of the expansion of optometry's scope to include in-office procedures such as certain injections, removal of benign lid lesions, corneal crosslinking and laser procedures including YAG capsulotomy, SLT and LPI. The report has been submitted as a bill to play out in Vermont's 2024 legislative session, running from January to May.

## 2020: What Went Wrong

The release of the OPR's initial study on optometric advanced procedures in 2020 sparked an immediate negative reaction from the optometry community due to the document's inclusion of certain misconstrued claims and data regarding issues such as ODs' skills and training.

“It recommended against everything,” says Dean Barcelow, OD, who serves as president, executive director and legislative chair of the Vermont Optometric Association (VOA). “There were arguments against almost every point we made. We were really disappointed.” Dr. Barcelow explains that the shortcomings in the report could be attributed to various factors, including understaffing, insufficient evidence collection, ineffective communication with optometry schools and the disruptive effects of a global pandemic in 2020.

The year after the 2020 report was released, Dr. Barcelow and his team at the VOA took their concerns to the Vermont Senate Government Operations Committee. The VOA walked the Committee through each part of the report, pointing out “where the report was factually wrong and where things were misinterpreted,” Dr. Barcelow notes. The decision was then made to return the report to the OPR for another review, the result of which is the document released this past September that has corrected the factual inaccuracies and now favors the proposed scope expansion.

## The Road Ahead

While Vermont ODs and the VOA are thrilled with the OPR's updated recommendation, certain details in the bill may still need fine-tuning to optimize its practical implementation. One area of concern that remains with the report as it's currently written, Dr. Barcelow explains, is the

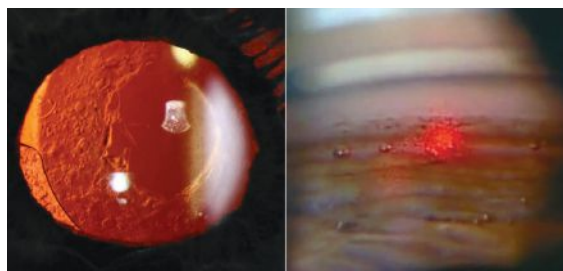
strictness of the certification qualifications for the added procedures.

“The OPR found the most stringent requirements from every single bill passed or introduced and put them into their recommendations,” he says. “If this legislation passes as is, to perform any of these procedures in Vermont we will have to jump through a lot of hoops.” In addition to requiring a 32-hour course and board certification for injection and laser procedures, he notes that the bill would also mandate proctored surgical experience on live, human patients for each of the 43 surgical procedures proposed, a number that no other state with expanded scope requires. The report also specifies that all requirements must be completed post-graduation. Dr. Barcelow says that once the 2024 legislative session kicks off, the VOA plans to engage in conversations with the legislature to discuss the proposed training qualifications.

Logistics aside, another upcoming challenge will be to neutralize the spurious arguments of the opposition. Not surprisingly, ophthalmology and organized medicine are expected to oppose the bill throughout the upcoming legislative session. The most vocal opponent in 2020 was University of Vermont Medical Center Ophthalmology department, Dr. Barcelow recalls, which will more than likely appear in committee hearings again this time around.

While Dr. Barcelow recognizes that “there's going to be a lot of opposition and it's going to be a lot of work,” he's also optimistic that optometry will come out victorious in the end.

Bill hearings will be scheduled with the state House and Senate Government Operations in January. For ODs who wish to show or voice their support for the bill, Dr. Barcelow says that the best way to help is the same as in any other state: “Reach out *in person* to your Vermont legislators and let them know this is an important issue to you.” ◀



The bill specifies that ODs must complete post-graduation proctored training for each proposed procedure.

# Macular and Peripapillary RNFL Shows Evidence of Epilepsy Status

Tracking anatomical changes in these regions may one day help monitor treatment response.

**A**dd another neurological condition to the list of diseases with findings that can manifest in the retina. Clinicians already know the well-established ocular findings in dementia and Parkinson's patients, and new research has linked retinal nerve fiber layer (RNFL) thinning to epilepsy. Recently, OCT has been proposed to help identify thinning of the peripapillary RNFL (p-RNFL) as a promising marker for cerebral neuronal loss in those with the neurological condition.

It's important to note that clinical implications have not yet been identified, but one new study has aimed to systematically characterize the extent of retinal neuroaxonal loss in a wide spectrum of people with epilepsy and to evaluate the main clinical determinants.

**Occurrence and frequency of tonic-clonic seizures and number of anti-seizure medications were both factors associated with the extent of neuroaxonal loss seen.**

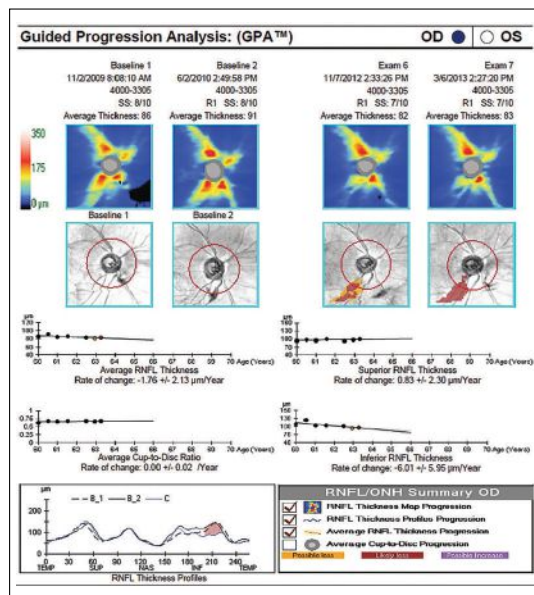
The prospective study had researchers use spectral-domain OCT on 98 people with epilepsy and 85 controls, all ranging in age from 18 to 55. Assessed were structures of all inner retinal layers and the total macula volume. The study authors found those with epilepsy (58% female) displayed significant neuroaxonal loss across all retinal layers (global pRNFL, macular-RNFL, ganglion cell inner plexiform layer and inner nuclear layer) as well as reduced total macula volumes when compared with controls.

Occurrence and frequency of tonic-clonic seizures and number of anti-seizure medications were both factors associated with the extent of neuroaxonal loss seen; this was most pronounced in men.

Elaborating on their findings for an article in the journal *Epilepsia*, the authors pointed to the incidence of tonic-clonic seizures as a relevant determiner of retinal neuroaxonal loss. The retinal measures of those with epilepsy but without tonic-clonic seizures did not differ from the controls, even with comparable disease duration, number of anti-seizure medications taken and were older than those experiencing tonic-clonic seizures. Instead, this group saw retinal measures in between healthy controls and the group experiencing this seizure type, suggesting more subtle retinal changes. Adjacently, the findings suggest significant retinal neuroaxonal loss primarily happens with high disease activity and severity, as evidenced by the relationship with occurrence and frequency of tonic-clonic seizures.

The authors also believe disease activity and severity to be tied to retinal neuroaxonal loss through the association of greater number of anti-seizure medications mapping onto extent of neuroaxonal loss.

Neuroaxonal loss seen in men was more pronounced than in women, independent of age, disease duration, number of anti-seizure medications and seizure frequency. This finding reinforces previous research reporting sex-specific differences in RNFL thick-



**It's hypothesized that neuroaxonal loss in epilepsy is driven by peri-ictal hypoperfusion and hypoxia, leading to increased blood-brain barrier permeability, glial activation, central inflammation and neuronal loss. In time, RNFL serial analysis akin to the above seen in a glaucoma patient may become a clinical tool of disease monitoring in epilepsy care.**

ness in those with epilepsy and another structural MRI study that found greater vulnerability of men to experience seizure-related brain atrophy with temporal lobe epilepsy.

The clinical potential of these results is palpable but not yet fully realized, with the authors stating that “the non-invasive and economic measurement via OCT bears the potential to establish as a practical tool to inform patient management.” This would be helpful to “assess the progression rate of the neuroaxonal loss, which could help to monitor the disease activity and treatment response.”

“This could be of great importance in people who are not able to document their seizures to decide on treatment adjustments,” the authors concluded in their paper. “The retinal thickness could thereby be an objective and more complex parameter than the so far used seizure frequency.”

Delazer L, Bao H, Lauseker M, et al. Association between retinal thickness and disease characteristics in adult epilepsy: a cross-sectional OCT evaluation. *Epilepsia Open*. November 3, 2023. [Epub ahead of print].

# Endophthalmitis Rate 0.045% After Intravitreal Injection

*Study shows younger age and better VA at presentation were associated with favorable visual outcome, while use of steroid was associated with worse visual outcome.*

Post-intravitreal injection (IVI) endophthalmitis is a rare but potentially devastating complication. In a new study, researchers investigated the incidence and clinical and microbiological characteristics, as well as the visual outcome, in IVI-associated endophthalmitis at two medical centers.

In total, 51,536 patients receiving injections were analyzed for post-IVI endophthalmitis. Of those, 23 cases of post-IVI endophthalmitis were diagnosed, yielding an overall incidence of 0.045; this rate was significantly higher in steroidal agents (vs. anti-VEGF) and in bevacizumab or aflibercept (vs. ranibizumab).

Cultures were positive in 56% of cases (100% gram-positive bacteria and 76% coagulase-negative staphylococcus). Higher culture-positive rates were associated with samples taken during vitrectomy, white blood cells on vitreous smear, the number of IVIs in the year prior to presentation and the time interval from last IVI to diagnostic sampling.

At the six- and 12-month follow-up, the median change in VA was -1.10 and -1.02, respectively. Younger age and better BCVA at presentation were associated with better VA outcome, while positive culture result and systemic steroids treatment were each associated with worse visual outcome.

The time interval from IVI to the first procedure was significantly associated with higher culture-positive rates. “This may allow a longer time for bacterial growth and thus a higher bacterial load, resulting in a higher rate of positive culture results,” the authors suggested.

The rate of vision improvement (within one line from the baseline BCVA) compared to presentation was 78% and 74% at six- and 12-month follow-up, respectively, while 35% and 39% of the patients returned to their baseline vision at the six- and 12-month follow-up, respectively. These rates are comparable to other studies, the authors wrote.

Patients who received systemic steroids had worse visual outcomes.

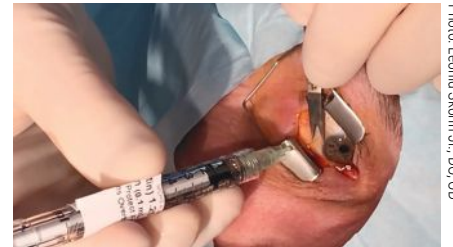

Photo: Leonid Skopin Jr., DO, OD

**Endophthalmitis rate was found to be 0.045% after IVI of anti-VEGF or corticosteroids, which was higher in steroids vs. anti-VEGF, and in bevacizumab or aflibercept vs. ranibizumab.**

“We found a 48% rate of oral steroids treatment, and our analysis revealed no difference in demographics, disease characteristics, presenting signs and symptoms, culture results, primary procedure and measured time intervals between patients treated with systemic steroids and patients who were not,” the researchers wrote in their paper. ◀

Davidov B, Ohayon A, Triviziki O, et al. Postintravitreal injection endophthalmitis: incidence, characteristics, management and outcome. *J Ophthalmol.* November 6, 2023. [Epub ahead of print].

# Six-year Data on Anti-VEGF Impact from IRIS Registry

Real-world scenarios usually don't align perfectly with carefully monitored clinical settings, so the true impact of many treatments often varies. Fortunately, large databases such as the IRIS Registry enable powerful real-world analyses of ocular outcomes. Using this resource, researchers looked into anti-VEGF treatment patterns and the influence of patient demographics on wet AMD outcomes. The findings, published in *Ophthalmology Science*, confirmed that the burdens patients face make it challenging to adhere to treatment.

The retrospective, real-world study included a cohort of 226,767 patients (254,655 eyes; 160,423 with VA data) with a first anti-VEGF and at least two years of follow-up.

The researchers found that patients experienced a mean VA increase of three ETDRS letters at year one, but this was followed by annual decreases, leading to a net loss from baseline of 4.6 letters after six years. They noted that patients with longer follow-up had better baseline and follow-up VA.

The mean number of injections was 7.2 in year one and 5.6 in year two. Injections plateaued in years three to six between 4.2 and 4.6 injections. A total of 38.8% of eyes discontinued treatment and 32.3% switched treatment. Adjusted data showed each additional injection led to a 0.68-letter improvement from baseline to year one, leading the researchers to conclude that multiple injections in a year may be clinically meaningful.

During follow up, 58.5% of patients lost 10 or more letters of vision at least once, and 14.5% had sustained poor vision after a median of 3.4 years.

“Overall, these findings suggest most patients with nAMD may find it difficult to adhere to frequent intravitreal anti-VEGF injections and could therefore be at risk of poor vision outcomes,” the researchers wrote. “New therapies, including those with different modes of action and/or new routes of administration, which safely reduce treatment burden by extending duration between re-treatments while maintaining optimal efficacy, may improve visual outcomes.” ◀

Wykoff CC, Garmo V, Tabano D, et al. Impact of anti-VEGF treatment and patient characteristics on vision outcomes in nAMD: up to 6-year analysis of the AAO IRIS Registry. *Ophthalmology Science.* 2023. [Epub ahead of print].



# Vitamin B1 May Slow AMD Development


This is proposed to be the case through an antioxidative effect.

The link between dietary choices and age-related macular degeneration (AMD) is well established, as carotenoid intake plays a significant role in prevention for certain patients. What of vitamins and nutrients? As one new study outlines, vitamin B1 consumption may be linked to late-stage AMD prevalence.

To look for an association, the study researchers gathered data from the National Health and Nutrition Examination Survey over two cycles, from 2005 to 2008. Included was a total of 5,107 patients aged 40 or older. After accounting for confounding variables, they found vitamin B1 levels to be inversely correlated with late AMD prevalence, suggesting the compound may have some protective effects.

In their paper for *Ophthalmic Research*, the authors go into detail about potential reasons for the correlation. AMD development is well known to be linked with oxidative stress, since the retina requires a high oxygen demand. In the process of converting light into vision, reactive oxygen species (ROS) are produced as metabolic byproducts; when ROS production passes that of the antioxidant systems, oxidative stress occurs.

Increased ROS levels can induce oxidative damage to proteins, lipids and mitochondrial DNA, with mitochondrial injury leading to cell death when releas-



**Vitamin B1 may offer antioxidative protection through thiamin's various beneficial effects.**

ing certain proteins into the cytoplasm. One of these effects is death of retinal pigment epithelium (RPE) cells, and late AMD (specifically geographic atrophy) is identified through RPE cells loss and subsequent photoreceptor malfunction. Oxidative stress is thus quite important in late AMD development.

Thiamin, or vitamin B1, has increasingly been shown to possess antioxidant properties, such as its ability to promote lymphocyte transformation *in vivo* and boosting neutrophil motility *in vivo* and *in vitro*. It can also prevent inactivation of the neutrophil migratory and lymphocyte proliferative responses, thus shielding cells from harmful oxidate products produced by the reaction of peroxidase,  $H_2O_2$  and halide.

Despite this being positive news, it should be taken into account that the results of this study do not reflect similar previous ones, including those of AREDS and Alienor. These differences may be due to differing study models used; this one was cross-sectional, while the other two may signify higher levels of certainty in being a multicenter randomized clinical trial and cohort study, respectively. The current study also

included more factors in adjusted models, like diabetes and hypertension. Both prior studies' patients were at least 70 on average, while those as young as 40 were included here, potentially pivoting B1 to be more beneficial in a younger population as a prophylactic measure.

In summarizing their findings, the researchers noted that "vitamin B1 serves as an antioxidant, while oxidative stress plays an important role in the development of AMD. By inhibiting the oxidative stress, vitamin B1 plays its vital role in slowing down the development of AMD, especially for late AMD." ◀

Zheng Q, Shen T, Xu M, et al. Association between dietary consumption of vitamin B1 and advanced age-related macular degeneration: across-sectional observational study in NHANES 2005-2008. *Ophthalmic Res.* November 3, 2023. [Epub ahead of print].

## IN BRIEF

**Infectious Keratitis Four Times More Common in PK than EK.** A recent retrospective cohort study evaluated the incidence of infectious keratitis—a sight-threatening complication of keratoplasty—after two types of the procedure: penetrating keratoplasty (PK) and endothelial keratoplasty (EK). It found that patients who underwent the former had a fourfold increase in the likelihood of developing infectious keratitis within six months of the procedure.

The researchers identified a total of 115,588 keratoplasties (20% PK and 80% EK) performed on Medicare beneficiaries aged 65 years and older. By six months post-op, infectious keratitis had developed in 3.32% of those who received PK and 0.72% of those who received EK. The researchers reported a median interval between keratoplasty and infectious keratitis diagnosis of 73 days (range 29-114 days) for PK and 74 days (range 38-116 days) for EK. Roughly one in five eyes that developed infectious keratitis underwent repeat keratoplasty

within one year postoperatively (22.9% and 23.8% for PK and EK, respectively).

"The higher rates for infectious keratitis after PK compared with EK are expected because suture-related infections and impaired re-epithelialization are more likely with PK," the study authors explained in their paper for *Cornea*. "Moreover, a larger proportion of indications for PK are higher risk," they elaborated.

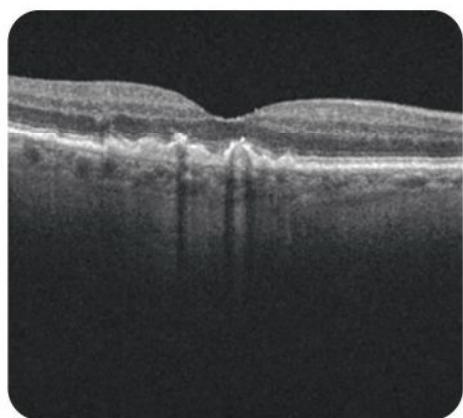
Infectious keratitis post-PK or post-EK was associated with age >85 years. The researchers reasoned in their paper that this

finding "may relate to [the 85+ age group's] overall health and limitations in complying with postoperative instructions."

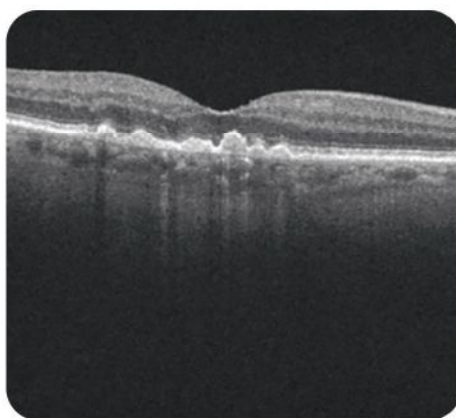
The team concluded their paper by stating that "infectious keratitis was four times more common after PK than EK, and the complication was associated with older age. Our findings may help corneal surgeons in counseling patients at higher risk and guiding their postoperative care."

Muhammad A, Chen D, Kyongjin C, et al. Infectious keratitis after keratoplasty in the United States: analysis of a national Medicare claims data set. *Cornea.* October 30, 2023. [Epub ahead of print].

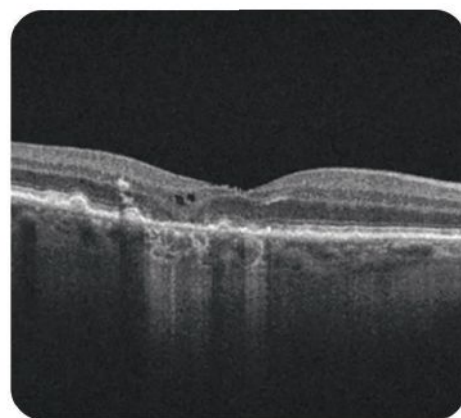
# GEOGRAPHIC ATROPHY (GA) CAN PROGRESS FASTER THAN YOU THINK<sup>1</sup>



**Baseline**



**Month 3**



**Month 6**

1. Boyer D, Schmidt-Erfurth U, van Lookeren Campagne M, et al. The pathophysiology of geographic atrophy secondary to age-related macular degeneration and the complement pathway as a therapeutic target. *Retina*. 2017;37(5);819-835.

## INDICATION

IZERVAY™ (avacincaptad pegol intravitreal solution) is indicated for the treatment of geographic atrophy (GA) secondary to age-related macular degeneration (AMD)

## IMPORTANT SAFETY INFORMATION

### CONTRAINDICATIONS

IZERVAY is contraindicated in patients with ocular or periocular infections and in patients with active intraocular inflammation.

### WARNINGS AND PRECAUTIONS

#### Endophthalmitis and Retinal Detachments

Intravitreal injections, including those with IZERVAY, may be associated with endophthalmitis and retinal detachments. Proper aseptic injection technique must always be used when administering IZERVAY in order to minimize the risk of endophthalmitis. Patients should be instructed to report any symptoms suggestive of endophthalmitis or retinal detachment without delay and should be managed appropriately.

# EVERY MONTH MATTERS WHEN TREATING GA

  
**izervay**<sup>™</sup>  
(avacincaptad pegol  
intravitreal solution) 2 mg



Learn more at  
[IZERVAYecp.com](https://IZERVAYecp.com)

## Neovascular AMD

In clinical trials, use of IZERVAY was associated with increased rates of neovascular (wet) AMD or choroidal neovascularization (7% when administered monthly and 4% in the sham group) by Month 12. Patients receiving IZERVAY should be monitored for signs of neovascular AMD.

## Increase in Intraocular Pressure

Transient increases in intraocular pressure (IOP) may occur after any intravitreal injection, including with IZERVAY. Perfusion of the optic nerve head should be monitored following the injection and managed appropriately.

## ADVERSE REACTIONS

Most common adverse reactions (incidence  $\geq 5\%$ ) reported in patients receiving IZERVAY were conjunctival hemorrhage, increased IOP, blurred vision, and neovascular age-related macular degeneration.

**Please see full Prescribing Information for more information.**

Copyright © 2023 IVERIC bio, Inc. An Astellas Company.  
All rights reserved. US-AP-2300334 10/23

**IVERIC**  
**BIO**  
An Astellas Company

## IZERVY™ (avacincaptad pegol intravitreal solution)

Rx only

**Brief Summary:** This information is not comprehensive. Visit IZERVAYecp.com to obtain the FDA-approved product labeling or call 609-474-6755.

### 1 INDICATIONS AND USAGE

IZERVAY is indicated for the treatment of geographic atrophy (GA) secondary to age-related macular degeneration (AMD).

### 2 DOSAGE AND ADMINISTRATION

#### 2.1 General Dosing Information

IZERVAY must be administered by a qualified physician.

#### 2.2 Recommended Dosage

The recommended dose for IZERVAY is 2 mg (0.1 mL of 20 mg/mL solution) administered by intravitreal injection to each affected eye once monthly (approximately every 28 ± 7 days) for up to 12 months.

#### 2.4 Injection Procedure

Only 0.1 mL (2 mg) should be administered to deliver a single dose. Any excess volume should be disposed.

Prior to the intravitreal injection, patients should be monitored for elevated intraocular pressure (IOP) using tonometry. If necessary, ocular hypotensive medication can be given to lower the IOP.

The intravitreal injection procedure must be carried out under controlled aseptic conditions, which includes the use of surgical hand disinfection, sterile gloves, a sterile drape, and a sterile eyelid speculum (or equivalent). Adequate anesthesia and a broad-spectrum topical microbicide should be given prior to the injection.

Inject slowly until the rubber stopper reaches the end of the syringe to deliver the volume of 0.1 mL. Confirm delivery of the full dose by checking that the rubber stopper has reached the end of the syringe barrel.

Immediately following the intravitreal injection, patients should be monitored for elevation in intraocular pressure (IOP). Appropriate monitoring may consist of a check for perfusion of the optic nerve head or tonometry.

Following intravitreal injection, patients should be instructed to report any symptoms suggestive of endophthalmitis (e.g., eye pain, redness of the eye, photophobia, blurring of vision) without delay.

Each vial and syringe should only be used for the treatment of a single eye. If the contralateral eye requires treatment, a new vial and syringe should be used and the sterile field, syringe, gloves, drapes, eyelid speculum, filter needle, and injection needle should be changed before IZERVAY is administered to the other eye. Repeat the same procedure steps as above.

Any unused medicinal product or waste material should be disposed of in accordance with local regulations.

### 3 DOSAGE FORMS AND STRENGTHS

Intravitreal solution: 20 mg/mL clear to slightly opalescent, colorless to slightly yellow solution in a single-dose vial.

### 4 CONTRAINDICATIONS

#### 4.1 Ocular or Periocular Infections

IZERVAY is contraindicated in patients with ocular or periocular infections.

#### 4.2 Active Intraocular Inflammation

IZERVAY is contraindicated in patients with active intraocular inflammation.

### 5 WARNINGS AND PRECAUTIONS

#### 5.1 Endophthalmitis and Retinal Detachments

Intravitreal injections may be associated with endophthalmitis and retinal detachments. Proper aseptic injection techniques must always be used when administering IZERVAY in order to minimize the risk of endophthalmitis. Patients should be instructed to report any symptoms suggestive of endophthalmitis or retinal detachment without delay, to permit prompt and appropriate management.

#### 5.2 Neovascular AMD

In clinical trials, use of IZERVAY was associated with increased rates of neovascular (wet) AMD or choroidal neovascularization (7% when administered monthly and 4% in the sham group) by Month 12. Patients receiving IZERVAY should be monitored for signs of neovascular AMD.

#### 5.3 Increase in Intraocular Pressure

Transient increases in intraocular pressure (IOP) have been observed after an intravitreal injection, including with IZERVAY. Perfusion of the optic nerve head should be monitored following the injection and managed as needed.

### 6 ADVERSE REACTIONS

The following potentially serious adverse reactions are described elsewhere in the labeling:

- Ocular and periocular infections
- Active intraocular inflammation
- Endophthalmitis and retinal detachments
- Neovascular AMD
- Increase in intraocular pressure

#### 6.1 Clinical Trials Experience

Because clinical trials are conducted under widely varying conditions, adverse reaction rates observed in the clinical trials of a drug cannot be directly compared to rates in the clinical trials of another drug and may not reflect the rates observed in practice.

The safety of avacincaptad pegol was evaluated in 733 patients with AMD in two sham-

controlled studies (GATHER1 and GATHER2). Of these patients, 292 were treated with intravitreal IZERVAY 2 mg (0.1 mL of 20 mg/mL solution). Three hundred thirty-two (332) patients were assigned to sham.

Adverse reactions reported in ≥2% of patients who received treatment with IZERVAY pooled across GATHER1 and GATHER2, are listed below in Table 1.

**Table 1: Common Ocular Adverse Reactions (≥2% and greater than Sham in Study Eye**

Adverse Drug Reactions	IZERVAY N = 292	Sham N = 332
Conjunctival hemorrhage	13%	9%
Increased IOP	9%	1%
Choroidal neovascularization	7%	4%
Blurred vision*	8%	5%
Eye pain	4%	3%
Vitreous floaters	2%	<1%
Blepharitis	2%	<1%

\* Blurred vision includes visual impairment, vision blurred, visual acuity reduced, visual acuity reduced transiently.

### 8 USE IN SPECIFIC POPULATIONS

#### 8.1 Pregnancy

##### Risk Summary

There are no adequate and well-controlled studies of IZERVAY administration in pregnant women. The use of IZERVAY may be considered following an assessment of the risks and benefits.

Administration of avacincaptad pegol to pregnant rats and rabbits throughout the period of organogenesis resulted in no evidence of adverse effects to the fetus or pregnant female at intravenous (IV) doses 5.1 times and 3.2 times the human exposure (based on AUC) at the maximum recommended human dose (MRHD) of 2 mg once monthly, respectively.

In the U.S. general population, the estimated background risks of major birth defects and miscarriage in clinically recognized pregnancies is 2-4% and 15%-20%, respectively.

##### Animal Data

An embryo fetal developmental toxicity study was conducted with pregnant rats. Pregnant rats received daily intravenous (IV) injections of avacincaptad pegol from day 6 to day 17 of gestation at 0.1, 0.4, 1.2 mg/kg/day. No maternal or embryofetal adverse effects were observed at any dose evaluated. An increase in the incidence of a non-adverse skeletal variation, described as short thoracolumbar (ossification site without distal cartilage) supernumerary ribs, was observed at all doses evaluated. The clinical relevance of this finding is unknown. Plasma exposures at the high dose were 5.1 times the MRHD, based on Area Under the Curve (AUC).

An embryo fetal developmental toxicity study was conducted with pregnant rabbits. Pregnant rabbits received daily IV injections of avacincaptad pegol from day 7 to day 19 of gestation at 0.12, 0.4, 1.2 mg/kg/day. No maternal or embryofetal adverse effects were observed at any dose evaluated. Plasma exposure in pregnant rabbits at the highest dose of 1.2 mg/kg/day was 3.2 times the human exposure at the MRHD, based on AUC.

#### 8.2 Lactation

There is no information regarding the presence of avacincaptad pegol in human milk, the effects of the drug on the breastfed infant or on milk production.

The developmental and health benefits of breastfeeding should be considered along with the mother's clinical need for IZERVAY and any potential adverse effects on the breastfed infant from IZERVAY.

#### 8.4 Pediatric Use

Safety and effectiveness of IZERVAY in pediatric patients have not been established.

#### 8.5 Geriatric Use

Of the total number of patients who received IZERVAY in the two clinical trials, 90% (263/292) were ≥65 years and 61% (178/292) were ≥75 years of age. No significant differences in efficacy or safety of avacincaptad pegol were seen with increasing age in these studies. No dose adjustment is required in patients 65 years and above.

### 17 PATIENT COUNSELING INFORMATION

Advise patients that following IZERVAY administration, patients are at risk of developing neovascular AMD, endophthalmitis, elevated intraocular pressure and retinal detachments. If the eye becomes red, sensitive to light, painful, or if a patient develops a change in vision, instruct the patient to seek immediate care from an ophthalmologist.

Patients may experience temporary visual disturbances and blurring after an intravitreal injection with IZERVAY and the associated eye examinations. Advise patients not to drive or use machinery until visual function has recovered sufficiently.

Manufactured by:

IVERIC bio, Inc., An Astellas Company. Parsippany, NJ 07054

©2023 IVERIC bio, Inc., An Astellas Company. IZERVAY is a trademark of IVERIC bio, Inc., An Astellas Company.

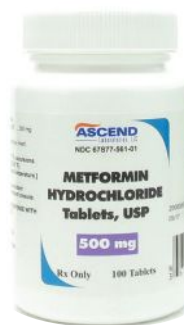## Diabetes Drug Protective Against Wet AMD

A common oral diabetic medication may provide some measure of protection against the pathogenesis of age-related macular degeneration (AMD), according to a study recently published in *Retina*. Metformin has demonstrated anti-angiogenic, anti-inflammatory and antioxidant effects in the retina. Researchers looked at AMD subtypes and investigated the association of metformin use with new-onset neovascular AMD (nAMD). They found that the drug reduced the odds of developing this condition.

The case-control study included 86,930 subjects newly diagnosed with nAMD and 86,918 matched controls, as well as a subgroup analysis of 22,117 subjects with diabetes and 21,616 matched controls. The researchers calculated the risk of various exposures on nAMD development.

Overall, they reported that metformin use was associated with a reduced odds ratio of developing nAMD (0.95) in both cohorts, but especially in those without diabetic retinopathy (DR). In the diabetic cohort without DR, the researchers observed reduced odds of nAMD development at 24-month cumulative doses of 1g to 300g, 301g to 630g and 631g to 1,080g.

They team hypothesized that the dose ceiling effect they saw in subjects without DR may indicate that metformin is more effective in those with greater glycemic control, since these patients didn't require the maximum dose and may have had less baseline pathologic retinal stress. In these patients, they wrote that



**Metformin's effects may be independent of insulin's potential effects.**

it's possible that metformin can reduce retinal stress to levels that prevent nAMD development. For patients who already have DR, the researchers believe that their baseline retinal stress levels may be too severe for metformin to have any effect within the study window.

"As there are only costly therapeutics in the market and limited preventive treatments, further investigation is warranted to validate and

expand on these findings and understand how metformin may be repurposed as an additional therapeutic intervention to prevent this blinding disease," the researchers concluded in their paper. ◀

Khanna S, Shaw L, Hyman MJ, et al. Association of metformin use with risk of newly onset neovascular age-related macular degeneration development. *Retina* 2023. [Epub ahead of print].

## Lacrimal Gland Cancers Need More Attention

Tumors involving the lacrimal gland are fortunately rare, but their scarcity makes them difficult to study. To gain insight into the epidemiology of lacrimal gland tumors in the United States, researchers analyzed data from the North American Association of Central Cancer Registries from 1996 to 2018, hoping to identify trends that might guide care. They found that better diagnostics and treatments are needed urgently.

In total, 3,620 patients were included, of which 56.7% were female; 45% were between the ages of 60 and 79; 83% were Caucasian; and 52% had localized disease. The researchers reported that lymphomas made up almost 60% of lacrimal gland malignancies while 37% were carcinomas.

The cumulative age-adjusted incidence rate per million was 0.53 for all malignancies, and 0.31 and 0.2 for lymphomas and carcinomas, respectively, according to the researchers. Annual crude incidence rates increased steadily,

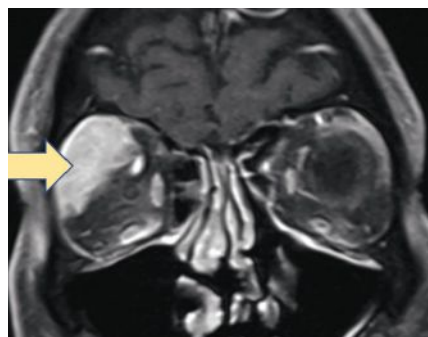


Photo: Ashley Kay Maglione, MD and Kelly Malloy, MD

**Researchers say that the sluggish improvement in survival rates of lacrimal gland malignancies over the years points to an alarming need for improved diagnostics and therapeutics.**

with a significant average annual change of 1.24%, but age-adjusted rates didn't mirror this trend. At five and 10 years, relative survival rates were 88.64 months and 80.26 months, respectively.

The researchers reported that the following were associated with significantly worse outcomes: older age, non-lymphoma tumors and advanced stage at diagnosis. They also found that

relative survival rates didn't change significantly from 1995 to 2018, regardless of gender, race or treatment received.

Overall, lymphomas were the most prevalent type of lacrimal gland malignancies, followed by carcinomas. The researchers concluded in their paper for *Ophthalmic Epidemiology* that "epithelial malignant tumors tended to occur earlier (before the age of 60) than other subtypes. Lymphomas had the best survival outcomes while carcinomas had the worst. Lacrimal gland melanomas were rare and tended to have poor survival outcomes."

They added that the increasing incidence of lacrimal gland cancers "should prompt the prioritization of training programs designed to educate" the next generation of eyecare providers on diagnosing and treating lacrimal gland malignancies. ◀

KhalafAllah MT, Gouda MA, Alfaar AS. In-depth analysis of incidence and survival of lacrimal gland malignancies in the USA 1995 to 2018. *Ophthalmic Epidemiology*. November 27, 2023. [Epub ahead of print].

# ‘Soft’ Steroids Just as Good as Big Guns for Post-Cataract Inflammation Control

For the average patient, study says both groups produce a comparable effect on postoperative IOP as well as visual acuity.

Cataract surgery is known to induce varying levels of postoperative anterior chamber inflammation, which subsides gradually with time and appropriate anti-inflammatory treatment. It is widely assumed that the higher the anti-inflammatory potency of the steroid, the greater its ability to cause additional undesirable ocular adverse effects, of which the main concern is increased IOP. A recent meta-analysis published in *Ophthalmology* assessed the effectiveness and safety of two sub-groups of topical steroid drops, standard (prednisolone acetate 1% or dexamethasone 0.1%) vs. soft (fluorometholone 0.1% or loteprednol etabonate 0.5%), in the post-op management of cataract surgery-induced inflammation. The team of researchers found no significant difference between the groups.

Individual study data was extracted and evaluated in a weighted pooled analysis including grading of total anterior chamber inflammation, anterior chamber cells, anterior chamber flare, postoperative VA, IOP and rate of adverse events. The researchers found 508 studies, of which seven were

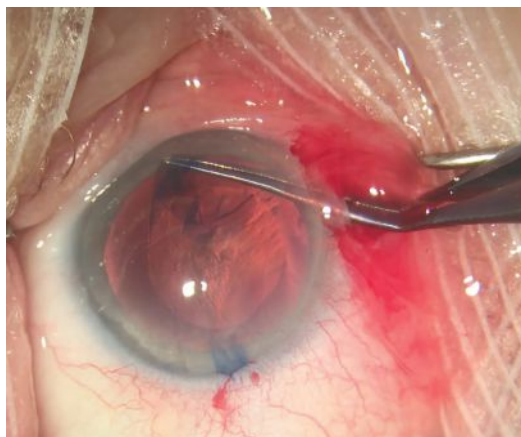


Photo: Christina Tran, BS, and Leonid Skornik Jr., DO, OD

**When evaluating the pooled effect of soft vs. standard steroids on post-cataract surgery IOP, no significant difference was found between the groups.**

eligible for the systematic review, and were ultimately included for analysis, reporting on 593 patients from five countries. The age of included patients, when available, ranged between 3.7 to 73.4 years. Follow-up data was available for analysis at one, seven and 28 days postoperatively.

Except for a significantly lower grade of anterior flare in the standard steroid group at day seven (standardized mean difference, 0.26), inflammatory activity measurements displayed insignificant

differences at every other follow-up (days one and 28 postoperatively). Pooled analysis of IOP at each follow-up demonstrated a higher IOP at the seven-day visit in the standard steroid group, whereas IOP at other time-points was comparable between the groups. Ocular adverse events were also similar between the groups in the qualitative analysis.

“It is important to base the choice of topical postoperative steroidal treatment on high-quality data regarding both risks and benefits of various drugs,” the authors wrote in their paper. “Nevertheless, safety and potency should still be considered for the individual patient with either an increased tendency for postoperative inflammation or a pre-existing glaucomatous damage to the operated eye. In the absence of such characteristics, additional factors may also influence treatment regimen choice, including cost and local availability of the topical steroids,” the team concluded. ◀

Noyman DBE, Chan CC, Mimouni M, Safir M. The efficacy and safety of standard vs. soft topical steroids after cataract surgery—a systematic review and meta-analysis. *Ophthalmology*. November 23, 2023. [Epub ahead of print].

## IN BRIEF

**■ Syphilitic Uveitis on the Rise.** The annual rate of primary syphilis infection has increased 74% since 2017, and with it comes more cases of intraocular inflammation stemming from the sexually transmitted infection. To provide an update, researchers from Vanderbilt University recently reviewed data from 2010 to 2019 on a total of 444,674 inpatient hospital visits and found 1.3% to carry a diagnosis of syphilitic uveitis.

Median age of subjects was 45 years and 78.9% of patients were men. Individuals self-identified

with the following race and ethnicity categories:

- 40.8% Caucasian
- 32.0% African American
- 15.7% Hispanic or Latino
- 6.8% other
- 4.7% unknown

**Incidence per 100,000 population was 0.4 for African Americans**, followed by 0.15 for Hispanic or Latino individuals and 0.11 for white subjects. **The highest percentage of admissions were from the South (42.1%)**, followed by West (25.0%), Northeast (17.4%), and Midwest (15.5%). Most patients (86.9%) presented to urban teaching hospitals and

median length of hospital day was six days.

“Although this study showed an increasing incidence of syphilitic uveitis in both men and women, **the incidence is four times higher in the male population**,” the researchers noted in their paper for *JAMA Ophthalmology*. This is partly attributable to the disproportionate increase in syphilis cases among gay men, they explained. The highest incidence occurring in the South corresponds with higher rates of syphilis in the southern United States.

As these data come from inpatient hospital treatment, they may

underrepresent the true clinical impact at the community level, the authors cautioned. The International Ocular Syphilis Study Group survey found initial misdiagnosis to be one of the most common (63.7%) causes for a poor visual outcome in patients with ocular syphilis, the authors pointed out, emphasizing the need to maintain a high index of suspicion for syphilitic uveitis when evaluating patients with intraocular inflammation.

Mir TA, Kim SJ, Fang W, Harvey J, Hinkle DM. Rising incidence of syphilitic uveitis—related hospitalizations in the US. *JAMA Ophthalmology*. Published online Nov. 22, 2023.



You're driven to improve people's lives through better vision.  
We're driven to help you succeed.

Discover how VSP Vision™ Careers in Eye Care can help you find the job you want so you can pursue your passion as a Doctor of Optometry. Gain a competitive advantage through experienced, dedicated Talent Acquisition Specialists who can help you find your ideal position in private practice, medical, corporate, or retail.

The choice is yours. Get started on the professional opportunity that is right for you. Scan the QR code or visit [vspeyecarecareers.com](https://vspeyecarecareers.com) to find out more.



Private Practice | VSP® Ventures | Visionworks®  
iCare Health Solutions | Onsite Clinics | Optical Outlets

# Race Remains an Imperfect Metric for Glaucoma Patient Assessment

*A more effective profile would encompass social and socioeconomic as well as genetic factors to create a fuller picture of the disease's manifestation and burden, experts argue.*

Numerous studies have shown that the prevalence of glaucoma is disproportionately greater in Black adults vs. non-Hispanic white individuals. However, the practice of using race or ethnicity as a decisive variable in clinical decision-making has been on the decline in recent years, owing to the rise of so-called precision medicine, which takes into account the patient's full genetic make-up and environmental and lifestyle factors. Such an approach is more nuanced than the sometimes arbitrary categorization schemes that sort patients by self-reported ethnicity.

Where, then, does race stand today as a factor in glaucoma, specifically with regard to those traditionally categorized as Black? In a recent assessment for *American Journal of Ophthalmology*, two UCLA researchers aimed to provide updates on the scientific discoveries made and sociological theories that have allowed for a better understanding of this burden and to discuss future directions. They found that there is still deficient data on this group and more research has to be done, including genetic associations, socioenvironmental exposures, downstream effects of racism, genetic ancestry and social determinants of health.

A previous study of Medicaid and commercial insurance found that, irrespective of race, Medicaid recipients received less glaucoma testing compared to counterparts with commercial health insurance. Additionally, disparities in glaucoma testing were observed across all racial and ethnic groups, but were most notable for Black individuals.

Another study analyzing national Medicare data found that, compared to non-Hispanic white beneficiaries, Black and Hispanic patients had lower rates of eye examinations, office visits, consultations and visual field and RNFL testing.

"These racial and ethnic disparities persisted even after stratifying by socioeconomic status, suggesting that other factors, such as systemic or structural racism, may be independently contributing," the authors noted in their paper.

There has been "bad and irresponsible science," they say, regarding the first drug approved by the FDA marketed for a single racial or ethnic group—Black Americans—for the treatment of congestive heart failure. The drug BiDil (isosorbide dinitrate and hydralazine hydrochloride) was formulated and sold not based on scientific evidence showing it was more effective in African Americans, but because it was a way to extend patent protection by 13 years, a study found.

"These examples illustrate the dangers of race-based medicine in obfuscating the line between race and genetic ancestry and perpetuating the false narrative that race is an essential, biological variable while translating it into clinical practice," the authors explained in their article. "It also has the potential to deepen disparities by promoting racial and ethnic stereotyping. Race-based targeting of therapeutics should be rejected, while genomic-based design of drugs and recruitment to trials represents a more promising approach for improved efficiency of drug development."

Advances such as the mapping of the human genome have provided access to an enormous amount of genomic data that estimates how variants affect disease risk. Polygenic risk scores represent a potentially important tool, the authors noted, though these may only be useful and the accuracy may only be valid for European ancestry populations, they added. But they also believe that race will decline in significance as a clinical factor.

"We believe that race will become increasingly less relevant in medicine as

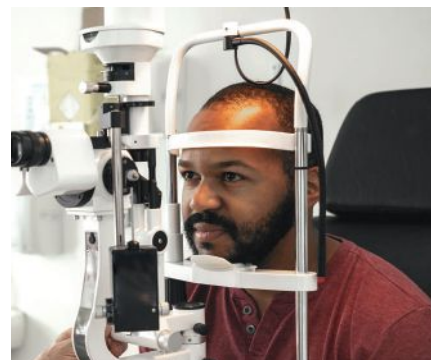

Photo: Getty Images

**Future research aimed at describing the impact of glaucoma on Black individuals should include genetic associations, socioenvironmental exposures, downstream effects of racism, genetic ancestry and social determinants of health.**

the capacity to capture and analyze larger, more comprehensive data sets allow a greater focus on risk at the individual level," the authors explained. Such data sets would incorporate socioeconomic factors as prominently as clinical ones, they noted.

"Though our understanding of the disparities in glaucoma in Black individuals has grown over the past decades, gaps persist, particularly due to deficient data driven by a lack of studies in this disproportionately burdened group," the authors summarized.

The authors concluded by encouraging the eyecare community "to be appropriately hesitant" in using race and ethnicity in their analyses and clinical decision-making, "understanding that it is a unique variable, fraught with complexities and pitfalls and yet also represents our best efforts to imperfectly capture socially driven disparities that have measurable downstream biological impact." ◀

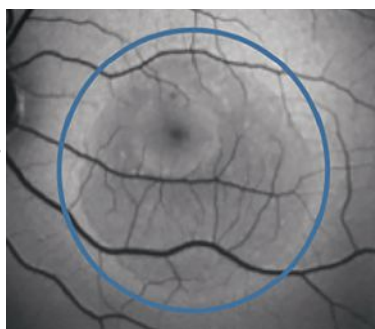
Kitayama K, Wilson RM. Glaucoma in Black individuals: how far have we come and where do we go from here? *Am J Ophthalmol*. October 10, 2023. [Epub ahead of print.]



# Men with CSCR Have Higher Rates of Recurrence, Vision Decline

Some patients with central serous chorioretinopathy (CSCR) develop a chronic form of the disease, which, if untreated, results in a recurrent/persistent course or the patients develop choroidal neovascular membrane that can lead to permanent vision loss. A newly validated multimodal imaging-based CSCR classification allows doctors to categorize the disease based on severity and prognosis. Researchers thought it was pertinent to understand the gender-specific associations using this new system and analyze long-term changes in male and female patients. They found that men tended to have complex CSCR recurrence and progressive decline in

Photo: Mohammed Rafieery, MD



**History of steroid use was associated with a decreased need for treatment and better final VA.**

vision, while women exhibited choroidal neovascularization (CNV) more commonly.

The study included 109 eyes of 58 patients (28 female and 30 male). The term “simple” was used for eyes with RPE alterations of less than/equal to two disc areas, and the term

“complex” was reserved for eyes with more than two disc areas or multifocal RPE alterations.

Simple CSCR was seen in eight (14.8%) eyes and 21 (38.2%) eyes in male and female groups respectively, while complex CSCR was seen in 46 (85.2%) eyes and 34 (61.8%) eyes in male and female groups respectively. Recurrence was more commonly seen in men (34 eyes)

than in women (23 eyes). Male patients (96.7%) were also significantly more likely to have a bilateral presentation (78.6% in women). Conversely, CNV was more commonly seen in female eyes (eight eyes) than male eyes (four eyes).

The researchers did not find any significant effect of gender on the need for treatment and final VA. Factors affecting reduced need for treatment were history of steroid use, good baseline VA and simple CSCR. Those affecting good final VA were history of steroid use, good baseline VA and younger age.

“It is yet to be determined if there is change in these characteristics over the long-term, or if there is any genetic susceptibility justifying this difference, for which larger, more controlled, prospective studies will be required,” the researchers concluded in their paper. ◀

Sahoo NK, Ong J, Selvam A, et al. Gender differences in central serous chorioretinopathy based on the new multimodal imaging classification. *Eye (Lond)*. November 4, 2023. [Epub ahead of print].

## OPEN YOUR EYES to Bruder

a Hilco Vision Company

### HYGIENE | HEAT | HYDRATION

**Open your eyes to Bruder.™** You know us for our #1 doctor-recommended microwave-activated Bruder® mask. Now we've added a new single-use, air-activated Eyedration™ mask, a convenient way for patients to maintain eye health when traveling, or where a microwave is not available. Eyedration begins heating once exposed to the air and maintains therapeutic moist heat on the eyelids for up to 20 minutes. Soft ear loops keep it in place when worn. The mask can also be used in-office to prepare the eye for manual expression or debridement procedures.

Contains 10 individually wrapped masks per pouch.



Read more about the mask



Stock up now on eye care essentials at [order.bruder.com](https://order.bruder.com), [eyes@bruder.com](mailto:eyes@bruder.com) or 888-827-8337. Learn about the science behind Bruder products at [bruder.com/pro](https://bruder.com/pro).

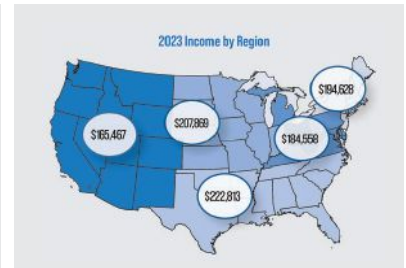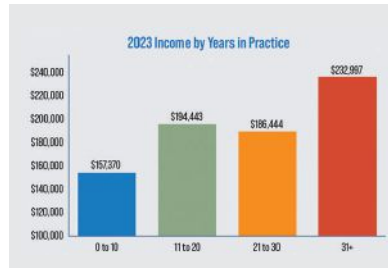
# FEATURES

REVIEW OF OPTOMETRY • Vol. 160, No. 12 • DECEMBER 15, 2023

## 36 2023 Income trends: A Wealth of Experience

Established ODs in private practices put up big numbers this year, lifting overall averages in our survey, while many others—employed docs especially—say their earnings feel stagnant.

By Jack Persico, Editor-in-Chief



30TH ANNUAL  
SURGERY REPORT



### 42 Take SLT to the Next Level: 10 Questions to Ask Yourself

Optometrists who want to be adept at this procedure should have these answers ready.

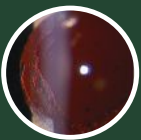
By Nathan Lighthizer, OD, and Komal Patel, OD



### 52 Equipping Your Office for Minor Surgical Procedures

Successful implementation begins by ensuring you have the necessary tools at your disposal.

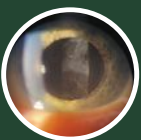By Catlin Nalley, Contributing Editor



### 58 In-office Procedures: Prepare to Handle These Complications

The well-informed optometrist should be able to tackle most of these with relative ease.

By Komal Patel, OD, and Nathan Lighthizer, OD



### 64 Keeping Up with the Newest IOLs

We're in a new era of cataract surgery, one with a plethora of good options. Find out what they are, which is best for each specific individual and how to properly comanage your patients.

By Christian Lopez, OD, Bobby Saenz, OD, and Ricardo Sepulveda, MD

# Could it be KC (KERATOCONUS)?

## KC File #1: The Patient Who Corrects to 20/20



**Mitch "Private Eye" Ibach OD, FAAO**, Vance Thompson Vision

**A** 29-year-old patient came to our office for a LASIK consult because she was unhappy with fluctuating vision in her contact lenses. The patient had ocular allergies but had no other ocular diagnoses.

Her entering glasses prescription was a modest one and we were able to refract her to 20/20. However, the refraction in the right eye was our first clue that something was not quite right.

Not only is  $>2.00$  D of refractive cylinder a warning signal for keratoconus, but the oblique axis is also unusual. About 90% of young corneas have with-the-rule (WTR) astigmatism.<sup>1</sup> The change in myopic spherical equivalent (SE) from baseline (the glasses prescription) was not what we would expect to see in an adult patient, either.

Autokeratometry from her referring optometrist was on the steeper side of normal, and our pachymetry measurements showed that both eyes had borderline thin corneas. Upon further questioning, the patient recalled that her sister had keratoconus. Having a first-degree relative (a parent, sibling, or child) with keratoconus increases the risk of developing the disease by 15- to 67-fold.<sup>2</sup>

At this point, we have some risk factors, but not a clear diagnosis. A closer look at topography, tomography, and anterior segment OCT epithelial mapping provided further information to make a decisive diagnosis of progressive keratoconus in the right eye.

This case illustrates that patients who see 20/20 at the phoropter can still have keratoconus. At 29, our patient was at an age where there is greater risk of progression,<sup>3</sup> and her ocular allergies and family history elevate that risk. She was fortunate to be diagnosed and treated early in the course of her disease, while she was still correctible to 20/20. **Simply by following the KC clues that are hiding in plain sight, you can help patients like this one preserve their vision by referring them to a corneal specialist. If further testing confirms the patient has progressive KC, iLink® cross-linking could slow or halt its progression. Visit [iDetectives.com](http://iDetectives.com) to learn more.** ●

### REFERENCES:

1. Kojima T, et al. *Am J Ophthalmol* 2020;215:127-34. 2. Wang Y, et al. *Am J Med Genet* 2000;93(5):403-9. 3. Ferdi AC, et al. *Ophthalmology* 2019;126(7):935-45.

### #FollowTheClues



**INDICATIONS** Photrexa® Viscous (riboflavin 5'-phosphate in 20% dextran ophthalmic solution) and Photrexa® (riboflavin 5'-phosphate ophthalmic solution) are indicated for use with the iLink System in corneal collagen cross-linking for the treatment of progressive keratoconus and corneal ectasia following refractive surgery.

**IMPORTANT SAFETY INFORMATION** Corneal collagen cross-linking should not be performed on pregnant women. Ulcerative keratitis can occur. Patients should be monitored for resolution of epithelial defects. The most common ocular adverse reaction was corneal opacity (haze). Other ocular side effects include punctate keratitis, corneal striae, dry eye, corneal epithelium defect, eye pain, light sensitivity, reduced visual acuity, and blurred vision. These are not all of the side effects of the corneal collagen cross-linking treatment. For more information, go to [www.livingwithkeratoconus.com](http://www.livingwithkeratoconus.com) to obtain the FDA-approved product labeling. You are encouraged to report all side effects to the FDA. Visit [www.fda.gov/medwatch](http://www.fda.gov/medwatch), or call 1-800-FDA-1088.



SPONSORED AND SUPPLIED BY GLAUKOS



© 2023 Glaukos PM-US-1553 Rev.1

## Refraction and exam findings

	RIGHT EYE	BCVA	LEFT EYE	BCVA
Lensometry	-0.50 -1.50 x31	20/30	-1.50 -0.50 x172	20/20-
Refraction at Phoropter	-0.75 -2.25 x34	20/20	-1.75 -0.75 x160	20/20+
Pachymetry	478 µm		483 µm	
Autokeratometry	45.5 / 47.50 x 112		44.9 / 46.75 x 80	

### KC File #1: THE CLUES

- Large change in refraction from lensometer to phoropter
- High astigmatism (-2.25 D) with an oblique axis
- Borderline thin corneas (478/483 µm)
- Relatively steep auto Ks (47.5)



**iDetective**  
Following the clues  
for early KC detection

# DEPARTMENTS

REVIEW OF OPTOMETRY • DECEMBER 15, 2023

FOLLOW US ON SOCIAL MEDIA

Facebook: revoptom

Twitter: revoptom

Instagram: revoptom

Threads: revoptom

LinkedIn: company/review-of-optometry

6

## NEWS REVIEW

Clinical, legislative and practice updates for optometrists.

22

## OUTLOOK

### Surgery Out of the Shadows

Optometry's embrace of minor procedures is increasingly accepted as part of routine eye care.

**Jack Persico, Editor-in-Chief**

24

## THROUGH MY EYES

### The Optometric Buffet

New meds and new laws give us unprecedented options. Dig in!

**Paul M. Karpecki, OD**

27

## CLINICAL QUANDARIES

### Adjust Your Expectations

A light-modifiable IOL may provide more precise vision post-op.

**Paul C. Ajamian, OD**



28

## CHAIRSIDE

### Unhappy Birthday

More trips around the sun means more chances for your patients to develop the dreaded presbyopia.

**Montgomery Vickers, OD**

30

## FOCUS ON REFRACTION

### Worth Your Time

Use of the Worth 4-dot test warrants some attention—there's so much info it can provide.

**Pamela H. Schnell, OD,  
and Marc B. Taub, OD, MS, EdD**



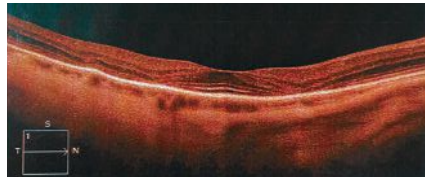
32

## YOU BE THE JUDGE

### Maybe Too Thin?

A fashion model on Plaquenil for rheumatoid arthritis unexpectedly develops toxic maculopathy.

**Jerome Sherman, OD,  
and Sherry Bass, OD**



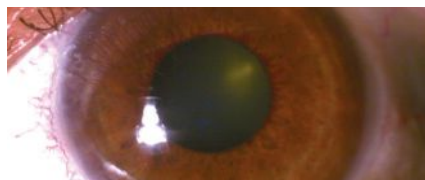
72

## THERAPEUTIC REVIEW

### Ischemic Retinal Ordeal

Neovascular glaucoma requires prompt and aggressive management of IOP and VEGF production.

**Jessica Steen, OD**



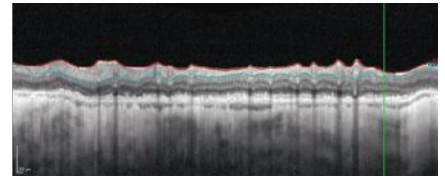
74

## GLAUCOMA GRAND ROUNDS

### AMD Plus Glaucoma: Double Jeopardy

Having both conditions can make it more difficult to determine the causes of changes seen in our testing.

**James L. Fanelli, OD**



76

## SURGICAL MINUTE

### Step into the Vitreous

Get to know this minimally invasive floaters procedure.

**Jeff Banas, OD, and Jessica Schiffbauer, OD**

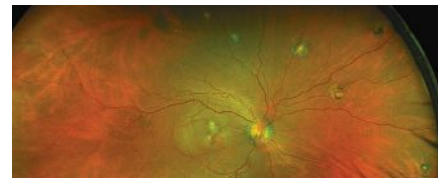
78

## RETINA QUIZ

### Scarred Vision

Inhaling a fungus may have led to this patient's infection.

**Rami Aboumourad, OD**



82

## DIAGNOSTIC QUIZ

### The Ears Have It


A connection with the eyes can happen in many ways.

**Andrew S. Gurwood, OD**

REVIEW OF OPTOMETRY (ISSN 0147-7633) IS PUBLISHED MONTHLY, 12 TIMES A YEAR BY JOBSON MEDICAL INFORMATION LLC/WebMD, 283-299 MARKET STREET, 2 GATEWAY CENTER, 4TH FLOOR, NEWARK, NJ 07102. PERIODICALS POSTAGE PAID AT NEWARK, NJ AND ADDITIONAL MAILING OFFICES. POSTMASTER: SEND ADDRESS CHANGES TO REVIEW OF OPTOMETRY, PO BOX 81, CONGERS, NY 10920-0081. SUBSCRIPTION PRICES: US: ONE YEAR \$56; TWO YEARS \$97, CANADA: ONE YEAR \$88, TWO YEARS \$160, INT'L: ONE YEAR \$209, TWO YEARS \$299. FOR SUBSCRIPTION INFORMATION CALL TOLL-FREE (877) 529-1746 (USA); OUTSIDE USA, CALL (845) 267-3065. OR EMAIL US AT REVOPATOMY@CAMBEYWEST.COM. PUBLICATIONS MAIL AGREEMENT NO: 40612608. CANADA RETURNS TO BE SENT TO BLEUCHIP INTERNATIONAL, P.O. BOX 25542, LONDON, ON N6C 6B2.

# BRIGHTER LOOKING EYES WITH ONE DROP

## The Conversation Eye Care Providers Should Be Having with Patients



**Melissa Toyos, MD**

Practices at Toyos Clinic located in Tennessee, Mississippi, and New York

Aesthetics are an important patient concern that can affect how they feel about themselves and around other people. Patients commonly use products and services that promise aesthetic enhancement, including lash extensions, eyelash growth treatments, colored contact lenses, eye makeup, eye creams, and serums. Increasingly, patients also seek out redness-relieving eye drops to improve the appearance of their eyes.

### Ocular Redness: A Key Patient Concern

Demand is substantial: 4 in 10 sales in the over-the-counter (OTC) eye drop category are for redness relievers.<sup>1</sup> Because ocular redness is often caused by “minor” eye irritations, patients may not recognize it as a valid concern that they can discuss with their eye care provider (ECP) and are, therefore, not always professionally counseled on which redness reliever is best for them. Without their ECP’s input, patients can sometimes lean on potentially unreliable sources, such as the store shelf, their peers, commercials, or the internet. Herein lies an opportunity to educate patients and guide them through the enormous ocular redness market while also addressing the root cause of their symptoms.

### LUMIFY®: A Clinically Proven Approach to Treating Ocular Redness

LUMIFY® (brimonidine tartrate ophthalmic solution) 0.025% drops are indicated for relieving redness of the eye due to minor eye irritations.<sup>2</sup> Most redness relievers are  $\alpha$ 1- or  $\alpha$ 1/ $\alpha$ 2-adrenergic receptor agonists;  $\alpha$ 1-adrenergic receptor agonism constricts corneal arterioles, hindering oxygen delivery to the cornea, which causes rebound redness. Brimonidine tartrate, by contrast, is selective for the  $\alpha$ 2-adrenergic receptor, primarily constricting ocular surface venules, which

do not affect ocular surface oxygen delivery and therefore is not associated with high levels of rebound redness.<sup>3</sup>

In 6 clinical studies with over 600 patients, low-dose brimonidine tartrate demonstrated a 1 minute onset of action, which persisted for up to 8 hours.<sup>4</sup> It had a favorable safety profile and, consistent with its mechanism of action, a low incidence of rebound redness (1.2%).<sup>4,5,6</sup> Adverse event rates did not significantly differ from control, and the most common adverse events in brimonidine-treated eyes were reduced visual acuity (4.0%) and conjunctival redness (2.6%).<sup>5</sup>

### Opportunity for ECPs to Step In

Market research indicates that patients report using of redness relievers an average of 3 days per week.<sup>7</sup> Ocular redness is a key concern for many patients, but the OTC eye care market contains an often overwhelming array of products. Understanding and communicating the benefits and challenges of available products is key to helping patients narrow down which products—out of everything on the shelf—might work best for them.

**LUMIFY® provides safe and effective redness relief for my patients dealing with minor eye irritations**

LUMIFY® is a redness reliever drop differentiated in its mechanism of action, rapid effects, and minimal rebound redness. LUMIFY® provides patients with excellent redness relief. In recommending a product as efficacious and reliable as LUMIFY®, ECPs can establish themselves as trusted professionals who can



### Incorporating ocular aesthetics into the patient conversation

- ✓ Ask patients if they are happy with how their eyes look and feel
- ✓ Ask patients if they use OTC eye care products and if they are satisfied with them
- ✓ Consider that the aesthetic aspect of eye care may be just as important to a patient as the clinical aspect
- ✓ Be ready and willing to provide OTC recommendations

address patients’ needs—both clinical and aesthetic. This can lead not only to improved patient outcomes and satisfaction but could also enhance trust in their relationship with their ECP.

1. IQVIA Sales Data, Latest 52 weeks ending 6/18/2023
2. LUMIFY® [Drug facts]. Bausch & Lomb Incorporated, Bridgewater, NJ.
3. Corboz MR, Rivelli MA, Varty L, et al. Pharmacological characterization of postjunctional  $\alpha$ -adrenoceptors in human nasal mucosa. *Am J Rhinol.* 2005;19(5):495-502.
4. McLaurin E, Cavet ME, Gomes PJ, Ciolino JB. Brimonidine ophthalmic solution 0.025% for reduction of ocular redness: a randomized clinical trial. *Optom Vis Sci.* 2018;95(3):264-271.
5. Ackerman SL, Torkildsen GL, McLaurin E, Vittitow JL. Low-dose brimonidine for relief of ocular redness: integrated analysis of four clinical trials. *Clin Exp Optom.* 2019;102(2):131-139.
6. Torkildsen GL, Sanfilippo CM, DeCory HH, Gomes PJ. Evaluation of efficacy and safety of brimonidine tartrate ophthalmic solution, 0.025% for treatment of ocular redness. *Curr Eye Res.* 2018;43(1):43-51.
7. Data on file. Bausch & Lomb. Rochester, NY

## EDITOR-IN-CHIEF

**JACK PERSICO**  
(610) 492-1006 • jpersico@jobson.com

## SENIOR EDITOR

**JULIE SHANNON**  
(610) 492-1005 • jshannon@jobson.com

## SENIOR ASSOCIATE EDITOR

**MARK DE LEON**  
(610) 492-1021 • mdleon@jobson.com

## ASSOCIATE EDITOR

**LEANNE SPIEGLE**  
(610) 492-1026 • lspiegle@jobson.com

## ASSOCIATE EDITOR

**RACHEL RITA**  
(610) 492-1000 • rrita@jobson.com

## SENIOR SPECIAL PROJECTS MANAGER

**JILL GALLAGHER**  
(610) 492-1037 • jgallagher@jobson.com

## SENIOR ART DIRECTOR

**JARED ARAUJO**  
jaraujo@jobson.com

## GRAPHIC DESIGNER

**LYNNE O'CONNOR**  
lyoconnor@jobson.com

## DIRECTOR OF CE ADMINISTRATION

**REGINA COMBS**  
(212) 274-7160 • rcombs@jobson.com**Clinical Editors**

Chief Clinical Editor • Paul M. Karpecki, OD

Associate Clinical Editors  
Joseph P. Shovlin, OD, Christine W. Sindt, ODClinical & Education Conference Advisor  
Paul M. Karpecki, OD

Case Reports Coordinator • Andrew S. Gurwood, OD

**Columnists***Advanced Procedures* – Nate Lighthizer, OD*Chairside* – Montgomery Vickers, OD*Clinical Quandaries* – Paul C. Ajamian, OD*Cornea and Contact Lens Q+A* – Joseph P. Shovlin, OD*Diagnostic Quiz* – Andrew S. Gurwood, OD*The Essentials* – Bisant A. Labib, OD*Focus on Refraction* – Marc Taub, OD, Pamela Schnell, OD*Glaucoma Grand Rounds* – James L. Fanelli, OD*Ocular Surface Review* – Paul M. Karpecki, OD*Retina Quiz* – Rami Aboumourad, OD*Surgical Minute* – Derek Cunningham, OD, Walter Whitley, OD*Therapeutic Review* – Jessica Steen, OD*Through My Eyes* – Paul M. Karpecki, OD*Urgent Care* – Alison Bozung, OD*You Be The Judge* – Jerome Sherman, OD, Sherry Bass, OD**Editorial Offices**

19 Campus Blvd., Suite 101 • Newtown Square, PA 19073

Jobson Medical Information/WebMD  
283-299 Market Street, 2 Gateway Center, 4th Floor  
Newark, NJ 07102Subscription inquiries: (877) 529-1746  
Continuing Education inquiries: (800) 825-4696

Printed in USA

BY JACK PERSICO  
EDITOR-IN-CHIEF  
**OUTLOOK**

# Surgery Out of the Shadows

*Optometry's embrace of minor procedures is increasingly accepted to be simply one more facet of primary eyecare practice.*

Not that many years ago, instruction for optometrists on minor surgical procedures started gaining prominence in the conference lineups at SECO and elsewhere, showing that these responsibilities were moving out of the realm of niche cases for those practicing in rural areas (the traditional argument for optometric surgery). Naturally, we at *Review* were excited to publicize that. This magazine has always aimed to be both a mirror to the profession's changes and at the same time a catalyst for them, by championing the next wave of optometric evolution.

"The SECO states have always led the way, with West Virginia and North Carolina passing some of the first diagnostic and therapeutic bills," says SECO Education Chair Paul C. Ajamian, OD. "SECO was there to provide education along with the new legislation. Of course we have met with opposition from medicine all along the way, and that will never change. Neither will SECO's commitment to advancing the profession."

Still, worries about what organized medicine might think of this development had the profession a bit skittish about openly flying the flag for optometric surgery up until fairly recently, so we had to take a more subdued approach to the way we presented this new endeavor in our coverage of the bigger meetings like SECO.

Fast forward to today. We're working on our plans for coverage of SECO 2024—and are pleased to see that a new Surgical & Aesthetics Skills Pavilion, will be prominently visible, plain as day, in the exhibit hall next year and that a variety of instructional courses will run throughout the main SECO educational program.

"These courses are delivered by experienced doctors of optometry and medical colleagues who have the same vision for the future," adds Dr. Ajamian, who points to the involvement of Richard Castillo—who's both an OD and DO—in the surgical offerings at SECO 2024.

This feels appropriate for where we are, collectively, as a profession right now. The educational content on laser and incisional techniques is clinically sophisticated and the profession exudes confidence in its skills and its future. I think that comes through clearly in the slate of features that make up this issue's 30th Annual Surgery Report, which, not surprisingly, has come to be dominated by *optometric* surgery in the last few years. Surgical comanagement undoubtedly remains important, but ODs are increasingly happy to drop the *co-* and just go ahead and manage what they can.

"SECO and *Review* have partnered for many years to deliver cutting-edge education that established a new path for the profession," notes Dr. Ajamian. "With 10 states having laser laws and more to come, we've taken the lead in creating learning labs and didactic sessions that allow ODs to become more comfortable with surgical procedures."

To that we say: full speed ahead.

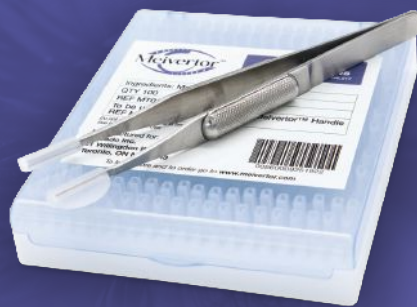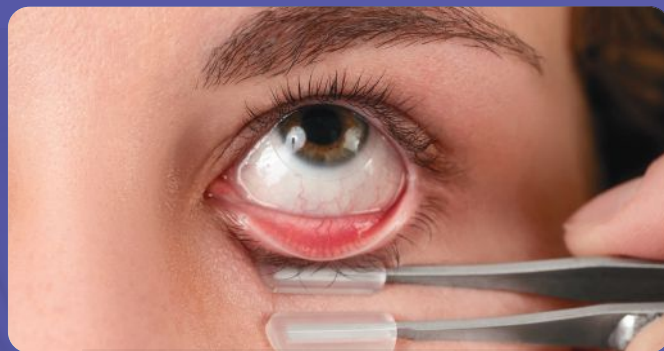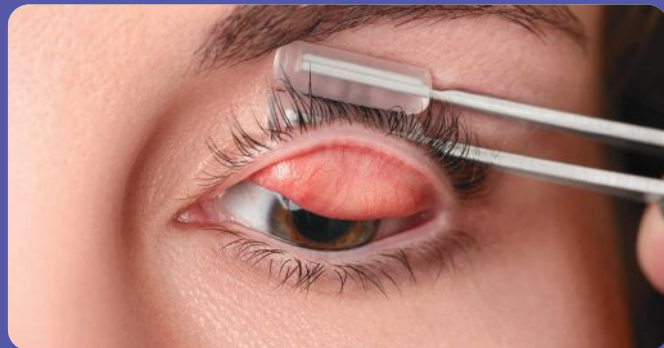Of course, it's critical to remember that an opportunity is not an obligation. Optometric surgery may be the destiny of the profession, but not every individual OD. Pursue what works for you.

So, if you're going to SECO 2024, be sure to swing by the surgical area in the exhibit hall for a demonstration—not just of the procedures, but of a profession that's growing in its capabilities and confidence, even if you don't intend to add those responsibilities yourself. ■



US Patent 11,446,017

# The ONLY SINGLE-HANDED UPPER and lower eyelid EVERSION TOOL



- Optimize the functionality of your meibographer
- Empower your technician to take the images you need – flipping a lid has never been easier
- Whenever you evert an upper eyelid – AND need a free hand – use your Meivertor

“Amazingly well designed, incredible balance to the instrument, and ease of use. I would recommend every technician who does meibography have one.”

-Dr. Paul Karpecki, OD, FAAO

“Love the Meivertor. First true game changer in the meibography game in my opinion.”

-Dr. Bradley Barnett, MD

“The Meivertor is a terrific product that has become one of my staff’s favourite in a very short time!”

-Dr. Kimberly K. Friedman, OD, FAAO

“Anyone struggle with lid eversion for meibomian gland imaging? Try using the Meivertor. Teaching techs has been a breeze and we can image both the upper and lower lids with ease!”

-Dr. Preeya Gupta, MD



For more information and to purchase go to [meivertor.com](http://meivertor.com)



BY PAUL M. KARPECKI, OD  
CHIEF CLINICAL EDITOR

## THROUGH MY EYES

# The Optometric Buffet

*New meds and new laws give us unprecedented options. Dig in!*

Like the term *surgical “privileges,”* as it implies something you’ve earned, received and should maintain with pride and dedication. Fortunately, optometry has some of the highest success rates when it comes to scope surgical privileges and is the dominant prescriber for the most recently approved medications. I’m not surprised, as we take these privileges seriously by maintaining copious hours of education and hands-on training, and know historically what it was like when we were unable to serve these patients, especially in rural areas.

Currently, 11 states have surgical privileges ranging from lasers like SLT and YAG to drug delivery technologies, removal of non-cancerous lumps and bumps and various minor procedures. All 50 states allow for prescribing oral and topical therapeutics related to ocular disease. Those who use full-scope optometry indeed do well and have great experience, but there is a significant percentage that have not provided the care to patients they are entitled to via prescribing topical agents, including recent FDA-approved medications or providing minor ocular surgeries.

Sometimes, the problem is not being able to join medical panels or knowing how to manage vision plans with health insurance, but there are companies like Optometric Medical Solutions that handle all of this, including credentialing, education and billing/coding for optometric practices. Not getting involved in prescribing medications or performing surgery in states that allow it is like having a full buffet available and choosing to eat crackers.

## FDA Approvals

Optometry is responsible for about 70% of the prescriptions for recent drug approvals, and in the last few months, we’ve seen five new medications become available. One of them is Xdemvy (lotilaner ophthalmic, Tarsus Pharmaceuticals) to treat *Demodex* blepharitis, which is instilled in the eye BID for six weeks to eradicate the mites. Based on the Phase III trials, it is expected that over two-thirds of patients will be collarette-free a year later, even with it being a one-time treatment. About 10% of patients mention burning upon instillation.

“Not getting involved in prescribing medications or performing surgery in states that allow it is like having a full buffet available and choosing to eat crackers.”

The fastest uptake of a new ocular drug is Miebo (perfluorohexyloctane ophthalmic, Bausch + Lomb), with over 100,000 prescriptions in less than two months since its launch in September. Part of the success may be its comfort combined with efficacy in preventing evaporation, which is four times better than healthy human meibum. It is dosed up to QID. The most common side effect observed was a slight transient blur upon instillation; make sure to educate patients about this possibility.

As vast as ocular surface disease is, presbyopia dwarfs it. But the first launch of a drug in this class had reasons for not

reaching its potential, including a higher concentration of pilocarpine, which could have lead to side effects like dimming of vision, headache and burning upon instillation.

The latest FDA approval came this past month—Qlosi (“cloh-see”) (pilocarpine hydrochloride ophthalmic, Orasis Pharmaceuticals)—although it won’t launch until 2024. Qlosi has many differentiating factors. First, at 0.4% it is one-third of the concentration of Vuity (pilocarpine 1.25%, Allergan). This alone may help in minimizing side effects and potential complications. It launches at BID dosing, where patients start one drop then add the second two to four hours later, and clinical data shows a consistent eight-hour effect.<sup>1</sup> Other unique aspects of Qlosi include being preservative-free, a near neutral pH—which has been an issue prior for pilocarpine—and it contains unique moisturizers.

Although there are no head-to-head studies, it appears to have longer duration, greater comfort and less adverse events based on the PI data. We’ve also learned a lot from the first pilocarpine medication, such as not treating high myopes and expecting a more accurate six to 10 hours of effect with BID dosing. We can also set expectations more accurately. I believe this new drop can reinvigorate a large population base looking for presbyopia solutions.

The high volume prescribing of optometry combined with an incredible number of new and improved medications makes it an ideal time for all 50 states to treat presbyopia patients, as well as those with ocular surface diseases like *Demodex* blepharitis and dry eye. ■

1. Dunbar M, Koetting C, Karpecki PM. CSF-1 (0.4% pilocarpine HCl ophthalmic solution) for presbyopia: primary and secondary endpoints of the NEAR-1 and NEAR-2 phase 3 clinical trials. *American Academy of Optometry*. October 11, 2023.

### About Dr. Karpecki

Dr. Karpecki is the director of Cornea and External Disease for Kentucky Eye Institute and an associate professor at KYCO. He is the Chief Clinical Editor for Review of Optometry and chair of the New Technologies & Treatments conferences. A fixture in optometric clinical education, he consults for a wide array of ophthalmic clients, including ones discussed in this article. Dr. Karpecki’s full disclosure list can be found in the online version of this article at [www.reviewofoptometry.com](http://www.reviewofoptometry.com).



IYUZEH™ (latanoprost ophthalmic solution) 0.005% is the first and only preservative-free latanoprost for patients with primary open-angle glaucoma (POAG) and ocular hypertension (OHT).

iyuzeh™  
(latanoprost ophthalmic solution) 0.005%



Transform how you lower IOP.

**POWER  
WITHOUT  
PRESERVATIVES.**



*We owe it to our patients with elevated intraocular pressure, with open-angle glaucoma or ocular hypertension to provide a new evidence-based approach. It is an extremely exciting time to prescribe IYUZEH™ for my patients.*

**Monique M. Barbour, MD, MHA, FAAO**

Dr. Barbour is a paid consultant of Thea Pharma Inc.



## INDICATIONS AND USAGE

IYUZEH™ is a prostaglandin analogue indicated for the reduction of elevated intraocular pressure in patients with open-angle glaucoma or ocular hypertension.

## IMPORTANT SAFETY INFORMATION

### CONTRAINDICATIONS

Known hypersensitivity to latanoprost or any other ingredients in this product.

### WARNINGS AND PRECAUTIONS

**Pigmentation:** Topical latanoprost ophthalmic products, including IYUZEH™ have been reported to cause changes to pigmented tissues. The most frequently reported changes have been increased pigmentation of the iris, periorbital tissue (eyelid), and eyelashes. Pigmentation is expected to increase as long as latanoprost is administered.

The pigmentation change is due to increased melanin content in the melanocytes rather than to an increase in the number of melanocytes. After discontinuation of latanoprost, pigmentation of the iris is likely to be permanent, while pigmentation of the periorbital tissue and eyelash changes have been reported to be reversible in some patients. Patients who receive treatment should be informed of the possibility of increased pigmentation. The long-term effects of increased pigmentation are not known.

Iris color change may not be noticeable for several months to years. Typically, the brown pigmentation around the pupil spreads concentrically towards the periphery of the iris and the entire iris or parts of the iris become more brownish. Neither nevi nor freckles of the iris appear to be affected by treatment. While treatment with IYUZEH™ can be continued in patients who develop noticeably increased iris pigmentation, these patients should be examined regularly.

**Eyelash Changes:** Latanoprost ophthalmic products, including IYUZEH™ may gradually change eyelashes and vellus hair in the treated eye; these changes include increased length, thickness, pigmentation, the number of lashes or hairs, and misdirected growth of eyelashes. Eyelash changes are usually reversible upon discontinuation of treatment.

**Intraocular Inflammation:** IYUZEH™ should be used with caution in patients with a history of intraocular inflammation (iritis/uveitis) and should generally not be used in patients with active intraocular inflammation because inflammation may be exacerbated.

**Macular Edema:** Macular edema, including cystoid macular edema, has been reported during treatment with latanoprost ophthalmic products, including IYUZEH™. IYUZEH™ should be used with caution in aphakic patients, in pseudophakic patients with a torn posterior lens capsule, or in patients with known risk factors for macular edema.

**Herpetic Keratitis:** Reactivation of herpes simplex keratitis has been reported during treatment with latanoprost. IYUZEH™ should be used with caution in patients with a history of herpetic keratitis. IYUZEH™ should be avoided in cases of active herpes simplex keratitis because inflammation may be exacerbated.

**Contact Lens Use:** Contact lenses should be removed prior to the administration of IYUZEH™ and may be reinserted 15 minutes after administration.

### ADVERSE REACTIONS


The following adverse reactions have been reported with the use of topical latanoprost products: iris pigmentation changes, eyelid skin darkening, eyelash changes (increased length, thickness, pigmentation, and number of lashes), intraocular inflammation (iritis/uveitis), and macular edema, including cystoid macular edema.

### DRUG INTERACTIONS

The combined use of two or more prostaglandins, or prostaglandin analogs including IYUZEH™ is not recommended. It has been shown that administration of these prostaglandin drug products more than once daily may decrease the IOP lowering effect or cause paradoxical elevations in IOP.

**Please see full Prescribing Information at [www.iyuzeh.com](http://www.iyuzeh.com) and Brief Summary on the next page.**

Explore the power of preservative-free latanoprost at [iyuzeh.com](http://iyuzeh.com)



**Théa**  
let's open our eyes

IYUZEH is a trademark of Laboratoires Théa.  
Copyright ©2023 Thea Pharma Inc. | All Rights Reserved. | PRC-IYZ-1410-v3 09.2023

# iyuzeh™

(latanoprost ophthalmic solution) 0.005%

## HIGHLIGHTS OF PRESCRIBING INFORMATION

This brief summary does not include all the information needed to use IYUZEH safely and effectively. See full prescribing information for IYUZEH.

Initial U.S. Approval: 2022

### INDICATIONS AND USAGE

IYUZEH is a prostaglandin F<sub>2α</sub> analogue indicated for the reduction of elevated intraocular pressure in patients with open-angle glaucoma or ocular hypertension.

### CONTRAINDICATIONS

Known hypersensitivity to latanoprost or any other ingredients in this product.

### WARNINGS AND PRECAUTIONS

**Pigmentation:** Topical latanoprost ophthalmic products, including IYUZEH have been reported to cause changes to pigmented tissues. The most frequently reported changes have been increased pigmentation of the iris, periorbital tissue (eyelid), and eyelashes. Pigmentation is expected to increase as long as latanoprost is administered.

The pigmentation change is due to increased melanin content in the melanocytes rather than to an increase in the number of melanocytes. After discontinuation of latanoprost, pigmentation of the iris is likely to be permanent, while pigmentation of the periorbital tissue and eyelash changes have been reported to be reversible in some patients. Patients who receive treatment should be informed of the possibility of increased pigmentation. The long-term effects of increased pigmentation are not known.

Iris color change may not be noticeable for several months to years. Typically, the brown pigmentation around the pupil spreads concentrically towards the periphery of the iris and the entire iris or parts of the iris become more brownish. Neither nevi nor freckles of the iris appear to be affected by treatment. While treatment with IYUZEH can be continued in patients who develop noticeably increased iris pigmentation, these patients should be examined regularly.

**Eyelash Changes:** Latanoprost ophthalmic products, including IYUZEH may gradually change eyelashes and vellus hair in the treated eye; these changes include increased length, thickness, pigmentation, the number of lashes or hairs, and misdirected growth of eyelashes. Eyelash changes are usually reversible upon discontinuation of treatment.

**Intraocular Inflammation:** IYUZEH should be used with caution in patients with a history of intraocular inflammation (iritis/uveitis) and should generally not be used in patients with active intraocular inflammation because inflammation may be exacerbated.

**Macular Edema:** Macular edema, including cystoid macular edema, has been reported during treatment with latanoprost ophthalmic products, including IYUZEH. IYUZEH should be used with caution in aphakic patients, pseudophakic patients with a torn posterior lens capsule, or in patients with known risk factors for macular edema.

**Herpetic Keratitis:** Reactivation of herpes simplex keratitis has been reported during treatment with latanoprost. IYUZEH should be used with caution in patients with a history of herpetic keratitis and should be avoided in cases of active herpes simplex keratitis because inflammation may be exacerbated.

**Contact Lens Use:** Contact lenses should be removed prior to the administration of IYUZEH and may be reinserted 15 minutes after administration.

### ADVERSE REACTIONS

The following adverse reactions have been reported with the use of topical latanoprost products and are discussed in greater detail in the prescribing information:

- Iris pigmentation changes
- Eyelid skin darkening
- Eyelash changes (increased length, thickness, pigmentation, and number of lashes)
- Intraocular inflammation (iritis/uveitis)
- Macular edema, including cystoid macular edema

Because clinical trials are conducted under widely varying conditions, adverse reaction rates observed in the clinical trials of a drug cannot be directly compared to rates in the clinical trials of another drug and may not reflect the rates observed in practice.

In the two clinical trials conducted with IYUZEH (latanoprost ophthalmic solution) 0.005% comparing it to XALATAN the preserved 0.005% latanoprost reference product, the most frequently reported ocular adverse reactions were conjunctival hyperemia and eye irritation (Table 1).

Table 1. Adverse Reactions

Symptom/Finding	Adverse Reactions [n (%)]	
	IYUZEH (n=378)	XALATAN (n=358)
Conjunctival hyperemia	129 (34)	133 (37)
Eye irritation	72 (19)	112 (31)
Eye pruritus	57 (15)	58 (16)
Abnormal sensation in eyes	51 (14)	52 (15)
Foreign body sensation in eyes	44 (12)	36 (10)
Vision blurred	28 (7)	30 (8)
Lacrimation increased	19 (5)	14 (4)
Photophobia	13 (3)	17 (5)

### POSTMARKETING EXPERIENCE

The following adverse reactions have been identified during post-approval use of topical latanoprost products. Because these reactions are reported voluntarily from a population of uncertain size, it is not always possible to reliably estimate their frequency or establish a causal relationship to drug exposure. The reactions, which have been chosen for inclusion due to either their seriousness, frequency of reporting, possible causal connection to ophthalmic latanoprost products, or a combination of these factors, include:

- Nervous System Disorders: Dizziness; headache; toxic epidermal necrolysis
- Eye Disorders: Eyelash and vellus hair changes of the eyelid (increased length, thickness, pigmentation, and number of eyelashes); keratitis; corneal edema and erosions; intraocular inflammation (iritis/uveitis); macular edema, including cystoid macular edema; trichiasis; periorbital and lid changes resulting in deepening of the eyelid sulcus; iris cyst; eyelid skin darkening; localized skin reaction on the eyelids; conjunctivitis; pseudophemphigoid of the ocular conjunctiva.
- Respiratory, Thoracic and Mediastinal Disorders: Asthma and exacerbation of asthma; dyspnea
- Skin and Subcutaneous Tissue Disorders: Pruritis
- Infections and Infestations: Herpes keratitis
- Cardiac Disorders: Angina; palpitations; angina unstable
- General Disorders and Administration Site Conditions: Chest pain

### DRUG INTERACTIONS

The combined use of two or more prostaglandins, or prostaglandin analogs including IYUZEH is not recommended, and administration of these prostaglandin drug products more than once daily may decrease the IOP lowering effect or cause paradoxical IOP elevations.

### USE IN SPECIFIC POPULATIONS

**Pregnancy:** There are no adequate and well-controlled studies of IYUZEH administration in pregnant women to inform drug-associated risks.

**Lactation:** It is not known whether this drug or its metabolites are excreted in human milk. Because many drugs are excreted in human milk, caution should be exercised when IYUZEH is administered to a nursing woman. The developmental and health benefits of breastfeeding should be considered along with the mother's clinical need for IYUZEH and any potential adverse effects on the breastfed child from IYUZEH.

**Pediatric Use:** The safety and effectiveness of IYUZEH have not been established in pediatric patients.

**Geriatric Use:** No overall differences in the safety or effectiveness of IYUZEH have been observed between elderly and younger adult patients.

### OVERDOSAGE

Intravenous infusion of up to 3 mcg/kg of latanoprost in healthy volunteers produced mean plasma concentrations 200 times higher than during clinical treatment with latanoprost ophthalmic solution and no adverse reactions were observed. IV dosages of 5.5 to 10 mcg/kg caused abdominal pain, dizziness, fatigue, hot flushes, nausea, and sweating.

### HANDLING THE CONTAINER

IYUZEH is a sterile solution that does not contain a preservative supplied in a single-dose container. The solution from one individual container is to be used immediately after opening for administration to one or both eyes. Since sterility cannot be maintained after the individual container is opened, the remaining contents should be discarded immediately after administration. Open a new single-dose container every time you use IYUZEH.

Manufactured for: Thea Pharma Inc. Waltham, MA.

All rights reserved.

U.S. Patent N°. 8,637,054.

Revised: 04/2023

©2021 Laboratoires Théa. All Rights Reserved. IYUZEH™ is a trademark of Laboratoires Théa.



EDITED BY PAUL C. AJAMIAN, OD

CLINICAL QUANDARIES

# Adjust Your Expectations

*A light-modifiable IOL may provide more precise vision post-op.*

**Q** A surgeon I refer to is using a lot of light adjustable lenses (LALs). I am in a quandary as to why the lens is used, the associated cost and the role of the comanaging OD in its postoperative care. Are there other options?

**A** “I have personally found this lens to be very beneficial in post-refractive surgery patients,” says James Lenhart, OD, who has comanaged and completed over 500 LAL post-surgical treatments at Center for Sight in Sarasota, FL. “Most patients are expecting cataract surgery results equal to or greater than what they previously experienced with radial keratotomy or LASIK. However, if the patient has a history of herpes simplex keratitis or is taking systemic medication that may increase sensitivity to UV light, such as tetracycline, doxycycline and hydrochlorothiazide, they should consider another IOL option.”

The LAL is the only FDA-approved IOL that allows refractive adjustments and customizes the patient’s vision after cataract surgery. This is accomplished by the use of a unique silicone formulation that creates a photosensitive IOL material that, with the addition of UV light, can change the lens’s power.

“The LAL option is considered a premium IOL and thus has an out-of-pocket patient cost vs. a standard IOL,” Dr. Lenhart says. “This cost ranges typically from \$3,000 to \$5,000 per eye and is not covered by any insurance. The lens can also correct astigmatism ranging from 0.75D to 2.00D.”

Other options to achieve 20/20 unaided vision, including the standalone toric lenses (range 1.00D to 4.00D), femto-second laser treatment for lower amounts



**Dr. Lenhart locking in final prescription with LAL.**

of astigmatism, and other intraoperative technologies such as the Optiwave Refractive Analysis system (ORA; Alcon) improve outcomes for difficult patients such as post-refractive surgery.

## Post-op Concerns

This lens is going to involve more exams after surgery, including one to three LAL treatments with the light delivery device (LDD). The patient’s refractive status is then finalized with two lock-in LDD treatments. The patient is also encouraged to wear UV blocking glasses to prevent unscripted refractive changes before the lock-in treatments are completed.

According to Dr. Lenhart, the comanaging optometrist can be indispensable in helping the patient. “I view the importance of an accurate refraction in LAL patients as equal to the preoperative refraction in LASIK patients,” he says.

During the post-op period, Dr. Lenhart will see the patient at one day, one week and two weeks out from surgery. During each visit, he does a careful refraction and encourages the patient to use their drops and artificial tears.

As with any cataract surgery and IOL selection, dry eye, posterior capsular opacification and cystoid macular edema can become obvious barriers to achieving the patient’s desired visual/refractive outcome. If needed, Dr. Lenhart will initiate dry eye treatments.

“When early-onset posterior capsular opacification occurs, I will notify the cataract surgeon prior to the first LAL treatment visit,” he says. “If the patient is not seeing clearly at the two-week post-op appointment, we will delay the first LDD treatment that normally occurs three to five weeks out from surgery.”

When the patient has arrived for an LDD treatment, Dr. Lenhart records the patient’s uncorrected vision along with repeating a refraction at distance and near. For him, the starting point for this refraction is the refraction determined at the two-week post-op visit. If clear vision is achieved, the patient is dilated with a goal of achieving 7mm pupils to ensure adequate UV light delivery. Before treatment, the doctor will reestablish the treatment goals based upon the patient’s ocular history and feedback.

Once that is completed, the patient is warned that they might see a slight pink hue for the first 24 hours. The patient is also informed that they might not notice any visual improvement for two to three days. At each subsequent LAL treatment, the patient is asked if they are happy with their visual outcome. Once the visual goals have been achieved, the lock-in LDD treatments are performed.

“The LAL IOL is a novel technology that has a niche with some patients,” Dr. Lenhart says. “This IOL has allowed us to achieve improved refractive outcomes for some of the more unique or visually demanding cataract patients.” ■

1. RxSight P160055: FDA summary of safety and effectiveness data. 2017. [www.accessdata.fda.gov/cdrh\\_docs/pdf/16/P160055B.pdf](https://www.accessdata.fda.gov/cdrh_docs/pdf/16/P160055B.pdf). Accessed November 2, 2023.

About  
Dr. Ajamian

Dr. Ajamian is board certified by the American Board of Optometry and serves as Center Director of Omni Eye Services of Atlanta. He is vice president of the Georgia State Board of Optometry and general CE chairman of SECO International. He has no financial interests to disclose.



# Unhappy Birthday

*More trips around the sun means more chances for your patients to develop the dreaded presbyopia.*

Sometimes I think patients would rather you tell them they have a dreaded eye disease than reference what the problem really is... birthdays.

Everybody wants to live forever, but nobody wants the inevitable side effects of, well, living forever. I recently told a very healthy and active 90-year-old, "You're going to live until you're 110!" He said, "I don't want to live that long," and I said, "I'll check back with you when you're 109."



**Patients who deny, deny, deny and fight their near demands all day often end up goofing up the distance vision they have been bragging about since junior high school just to make the nerdy myopes feel jealous.**

You want to see a patient glaze over? Start explaining PRESBYOPIA. I always start by asking, "Have you ever seen a Presbyterian church?" This is when 50% of the patients consider jumping off a bridge. My father, growing up, was a Methodist. My mother was a Presbyterian. These two churches were across the street from each other in my little hometown of Montgomery, West Virginia (and yes, the town was named after me. I was just born a hundred years after the town was named after me.)

One time I asked my mom, "If dad was a Methodist and you were a Pres-

byterian, why were we all brought up in the Presbyterian church?" Her answer: "We decided it would be easier to cool down a Methodist than to heat up a Presbyterian."

So, as the patient facing his first reading eyewear slowly slips into a coma, I teach him that in old Greek (and Vulgar Latin), the root of the word means "ancient," so the Presbyterian Church is the "Ancient Church" and presbyopia means "ancient eyes." To the patient, who maybe has never had an eye problem in 43 years, I am certain this is just super exciting to learn.

But, that's not all. Now I start talking about how, when I see patients like them, the first thing I think of is a hardware store.

That pretty much pushes the patient into catatonia. But wait, there's more! Now I explain that spectacles are just a tool, like a Phillips head screwdriver or a jackhammer.

Now, they simply hate me.

Yes, folks, eye doctors invented texting and computers just to drum up business. And it has worked beautifully thanks to presbyopia.

By the year 2030, there will be over 40 billion presbyopes in the world. I just made that up by the way, but still, there will be a bunch of them. A few will show up at your office and all of them are hoping you say, "You're fine... just increase the font size." But we are, at heart, interventional by training and, like it or not, their birthdays will mean they need eyewear or something.

My experience clinically is that patients who deny, deny, deny and just fight their near demands all day often end up goofing up the distance vision they have been bragging about since junior high school just to make the nerdy myopes feel jealous. My best presbyopic patient successes often start with them all bent out of shape when I mention the possibility of losing their incredible distance vision, which, by

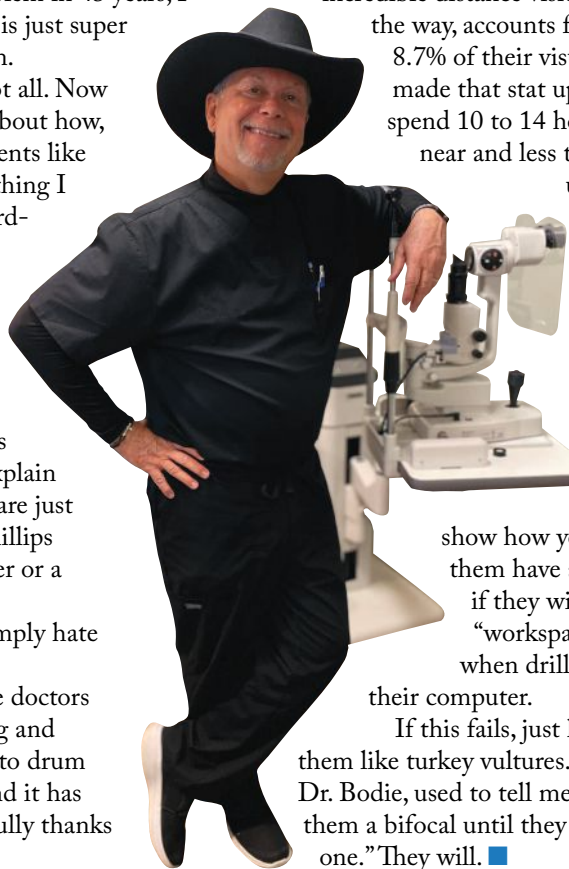
the way, accounts for less than 8.7% of their visual day. I just made that stat up, but they do spend 10 to 14 hours a day at near and less than 30 minutes at 100

yards unless they drive for Uber or Lyft at night or golf.

So, here's my advice. Just be honest and

show how you can make them have a better day if they will only wear "workspace" glasses when drilling down on their computer.

If this fails, just hover above them like turkey vultures. My mentor, Dr. Bodie, used to tell me, "Don't give them a bifocal until they beg you for one." They will. ■



**About Dr. Vickers**

Dr. Vickers received his optometry degree from the Pennsylvania College of Optometry in 1979 and was clinical director at Vision Associates in St. Albans, WV, for 36 years. He is now in private practice in Dallas, where he continues to practice full-scope optometry. He has no financial interests to disclose.

From the makers of the #1-prescribed dry eye brand in Europe\*

## Covering the spectrum of

# Dry Eye Relief

Over-the-counter iVIZIA® lubricant eye drops deliver a unique combination of immediate and long-lasting relief and ocular surface protection in a preservative-free formulation.

- Advanced formulation offers a combination of povidone (active), hyaluronic acid (HA), and trehalose
- HA and trehalose increased tear film thickness for up to 240 minutes
- Proprietary, **multi-dose bottle**

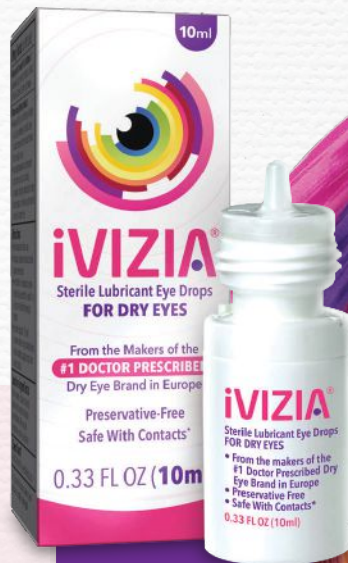### Chronic Dry Eye Patient Usage Study†:

Up to  
**8 hours**  
of relief

as well as improved comfort during computer work, reading, and driving<sup>1</sup>

**84%**

of users reported iVIZIA worked better than their previous eye drops<sup>1</sup>



Safe for use with contact lenses‡



Scan here.

Recommend iVIZIA and request samples by visiting [iVIZIA.com/ECP](https://www.ivizia.com/ECP).

\*Prescription market data, Dec. 2022 – S01K without cyclosporine.

†In a chronic dry eye patient usage study, participants from a variety of socioeconomic backgrounds answered questions about iVIZIA. There were 203 chronic dry eye patients, ranging from ages 28-80, who used their current eye drops before switching to iVIZIA for 30 days.<sup>1</sup>

‡To limit blurriness when using contact lenses, remove contacts, apply drops, then insert contacts.

Reference: 1. Data on file.

Copyright ©2023 Thea Pharma Inc. | Similasan | All Rights Reserved. | PRC-IED-1030-v2 04.2023

Made by  
**Thea**  
let's open our eyes

Distributed by  
**Similasan**  
EVIDENCE-BASED EYE CARE



BY PAMELA H. SCHNELL, OD, AND MARC B. TAUB, OD, MS, EdD

## FOCUS ON REFRACTION

# Worth Your Time

*Use of the Worth 4-dot test warrants some attention—there's so much information it can provide.*

**B**ack in August, we addressed the often-forgotten technique of visuoscopy in this column. As Marc and I began discussing topics for this month, I realized there are a number of tests we all learned in optometry school that we may not use on a daily basis but deserve a fresh look. One of these, which gets used quite frequently if you practice in pediatric or vision therapy areas but may be used less in primary care, is the Worth 4-dot test. As it is one of my favorites, I thought the time was ripe for a review!

## Running the Test

The Worth 4-dot test is so simple to administer that it's easy to forget how much information it can provide. Before diving into the interpretation, let's look at how the test is run. The equipment is minimal—just the Worth 4-dot flashlight (the older version) or transilluminator attachment (newer) and a pair of red/green glasses (*Figure 1*). You may still have these lying around and not realize it, since most of us got them in school!

To administer the test itself, simply have the patient put the red/green glasses on with the red lens over the right eye (over their current Rx if needed) and then show them the illuminated Worth 4-dot target. I like to emphasize to my students putting the red/green glasses on first; one of my more embarrassing mistakes in early residency was accidentally showing a child the target without them—of

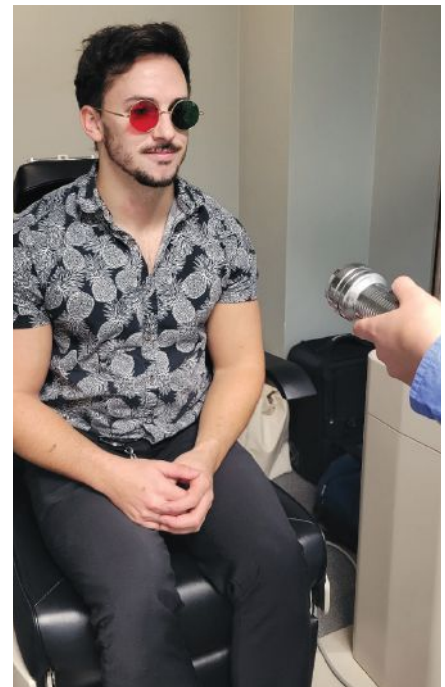
course they saw all four dots (oops)! The target itself should be held so that the white dot is either on the top or the bottom, with the red dot opposite and the two green dots on the sides. This allows easy interpretation of diplopia, should it occur.

Once setup is complete, ask the patient to tell you (or to draw) what they see—how many dots are there? What color(s) are they? The test is administered at a variety of distances, so it is easiest to begin at 40cm and back away from there, asking the patient again to report what they see at about three feet and again at six feet. In addition to testing at multiple distances, the Worth 4-dot can also be administered in both full or dim room illumination; this also becomes important in the interpretation of the results.

## Interpretation

Now that we know how to set up and run the Worth 4-dot test, why are we doing it? What are we looking for? As mentioned, the Worth 4-dot can tell us many things, but most practitioners use it for a gross assessment of fusion. Your patient will respond in one of several ways; looking at the possible responses will make the results easy to understand.

**1. Your patient reports seeing four dots: one red, two green and one yellow.** Great! This is the “normal” response. When the patient is wearing red/green glasses with the red lens over the right eye, the patient will see the red dot



**Fig. 1.** A patient with red/green glasses to administer the test.

with their right eye and the green dots with their left. The white dot will assume whichever color filter the patient looks through; it will appear red to the right eye and green to the left. If both eyes are seeing the white dot simultaneously, the patient will report some version of a blend of red and green, usually described as “yellowish.” This is an example of the phenomenon of luster, which is a type of second-degree fusion.

**2. Your patient reports seeing either two red dots or three green dots.**

In this case, one of the eyes isn't getting the proper input to allow the patient to see four dots. They are suppressing one eye's information, and you can easily determine which by remembering which eye sees which dots. If the patient reports seeing two red dots, they are suppressing their left eye; if they see

### About Dr. Taub and Schnell

**Dr. Taub** is a professor and co-supervisor of the Vision Therapy and Pediatrics residency at Southern College of Optometry (SCO) in Memphis. He specializes in vision therapy, pediatrics and brain injury. **Dr. Schnell** is an associate professor at SCO and teaches courses on ocular motility and vision therapy. She works in the pediatric and vision therapy clinics and is co-supervisor of the Vision Therapy and Pediatrics residency. Her clinical interests include infant and toddler eye care, vision therapy, visual development and the treatment and management of special populations. They have no financial interests to disclose.

three green dots, they are suppressing their right.

**3. Your patient reports seeing five dots: two red and three green.**

In this situation, the patient is experiencing diplopia. Both eyes are getting information but no fusion is happening. Ask the patient to tell you where the red dots lie—are they on the right or the left of the vertical center line? Or are they above or below the horizontal? The location of the dots will tell you whether the patient has an eso, exo or hyper posture. If the red dots appear to the right of vertical center, you have an uncrossed diplopia, representing an eso deviation. If the red dots appear to the left, this is crossed diplopia, or exo. We often already know this from cover testing, but verification is always nice! In addition, fluctuation can be seen easily if the patient reports that the dots move.

So, what about testing with different distances and light levels? These aspects provide key information about the patient's stamina and suppression level (if noted). Let's address each separately.

**Varying the distance.** By moving from your starting point of 40cm to three feet and then six feet, the overall retinal angle that the target subtends

“ In addition to testing at multiple distances, the Worth 4-dot can also be administered in both full or dim illumination; this also becomes important in the interpretation of the results. ”

gets smaller. By showing a progressively smaller target, we can determine roughly how large an area of suppression exists if one is found at all. We can also determine whether a patient is capable of maintaining fusion in a dynamic setting. Although many “official” direction sets say to check at each of the three distances individually, I prefer to move in a more continuous fashion. I hold the target at 40cm, give the instructions and then tell the patient to report any changes as I slowly move away. In this manner, you can pinpoint exactly where in space the patient begins to suppress, picks up fusion, goes double and so on.

**Varying the light levels.** By changing the room lights from full to dim, we can get a sense of how deep a suppression the patient is experiencing.

While there is no need to repeat the test in dim illumination if the results are normal, if the patient suppresses in full room lighting, we need to know whether it is a shallow or a deep suppression, especially if we plan to refer them for vision therapy.

The general rule I give to my students is this: The more unnatural the environment, the deeper the suppression. If the patient suppresses with the lights on but the act of turning them off causes the suppression to break, they have a relatively shallow suppression. That's usually easier to handle in therapy than a deep suppression, which would be indicated if the patient continues to report only two or three dots in dim lighting.

What else can we assess with the Worth 4-dot? Although we don't generally use it for this, I suppose we could get a gross assessment of color vision. For example, if the patient is unable to see a difference in the dots' colors. The other use in the vision therapy world is in determining whether a patient is showing anomalous projection. If that phrase didn't make you cringe, you probably already do vision therapy! If it did, well... we'll save that topic for another day! ■



Fig. 2. The traditional Worth 4-dot (left) and a newer digital version (right).



BY JEROME SHERMAN, OD, AND SHERRY BASS, OD

## YOU BE THE JUDGE

# Maybe Too Thin?

*A fashion model on Plaquenil for rheumatoid arthritis unexpectedly develops toxic maculopathy.*

**P**laquenil (hydroxychloroquine, Sanofi) is considered the drug of choice by rheumatologists for a host of autoimmune disorders. Although it has a relatively safe systemic profile overall and Plaquenil macular toxicity is not common, rheumatologists, internal medicine physicians and especially optometrists and ophthalmologists must remain cognizant of its potential for irreversible visual devastation.

As a general rule, each patient's risk depends on daily dose and duration of treatment. The standard 400mg daily dosage taken continuously results in a calculated cumulative dose at seven years of slightly over 1,000g. Formulas for daily dosage based upon body weight exist but are rarely considered.

The American Academy of Ophthalmology (AAOph) guidelines recommend patients receive a baseline examination within the first year of Plaquenil use and an annual screening after five years of use when the cumulative dose begins to approach 1,000g.

### Case

A tall, quite slender, 25-year-old white female fashion model presented for updating of her contact lenses. Her health history revealed treatment with Plaquenil 400mg/day for approximately 15 months, prescribed by her rheumatologist for both rheumatoid arthritis and Hashimoto's thyroiditis. Her best-corrected visual acuity (VA) with

-1.50 spheres in each eye was recorded as 20/20+. An external exam including Amsler grid in each eye was unremarkable. A dilated fundus exam revealed normal discs with 0.2 cup-to-disc ratios OU, a normal macula with a foveal reflex in each eye and normal peripheral retina in each eye. An SD-OCT of the disc and macula were obtained and was interpreted as normal.

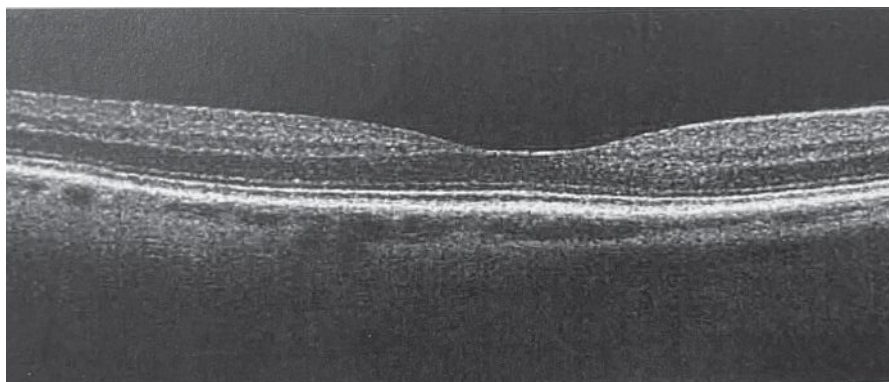
New fashionable glasses were prescribed, as well as daily wear contact lenses. The eye clinician reviewed the possibility of irreversible retinal damage secondary to the drug Plaquenil. The doctor recorded that he discussed daily dosage and cumulative dosage and advised the patient to return yearly for retinal exams.

The patient returned a year later for a follow-up exam as recommended. Because she had since moved, this exam took place in a different office by a dif-

ferent doctor. She reported that she was still being treated for Hashimoto's thyroiditis with Plaquenil 400mg/daily by the same rheumatologist for a total of about two and half years. Best-corrected VA was 20/20- OU, the external exam including confrontation visual fields was normal, Goldmann IOPs were 15mm Hg OU and a dilated fundus exam (DFE) was also normal OU. SD-OCT of the disc and macula was interpreted as normal in both eyes.

About four months later, the patient began having difficulty with her vision, worse in her right eye with both her glasses and contact lenses. As a fashion model, she was very attuned to color and also complained of slightly impaired color vision in both eyes. She returned to the first doctor, who gave her the detailed information about possible retinal problems with Plaquenil, and reported that she was still on Plaquenil 400mg/daily for a total of nearly three years.

Best-corrected VA was now 20/25 OD and 20/20 OS. Amsler grid revealed several small zones of missing lines around the central fixation point in the OD only but loss of contrast of the central lines in both eyes. A DFE



**The first OCT was obtained by the first eye doctor. This horizontal scan of the posterior pole of the right eye was taken with Optovue**

**About Drs. Sherman and Bass**

**Dr. Sherman** is a Distinguished Teaching Professor at the SUNY State College of Optometry and editor-in-chief of *Retina Revealed* at [www.retinarevealed.com](http://www.retinarevealed.com). During his 53 years at SUNY, Dr. Sherman has published about 750 various manuscripts. He has also served as an expert witness in 400 malpractice cases, approximately equally split between plaintiff and defendant. Dr. Sherman has received support for *Retina Revealed* from Carl Zeiss Meditec, MacuHealth and Konan. **Dr. Bass** is a Distinguished Teaching Professor at the SUNY College of Optometry and is an attending in the Retina Clinic of the University Eye Center. She has served as an expert witness in a significant number of malpractice cases, the majority in support of the defendant. She serves as a consultant for ProQR Therapeutics.



# Look for choroidal hypertransmission, a marker of Geographic Atrophy (GA) on OCT<sup>1\*</sup>

- While BCVA is poorly correlated to lesion size, visual function continues to decline as lesions grow<sup>2,3</sup>
- It is critical to recognize GA and refer patients in a timely manner, as disease progression is relentless and irreversible<sup>1,3-7</sup>

Learn more about identifying GA  
at [RecognizeAndReferGA.com](https://www.recognizeandreferga.com)



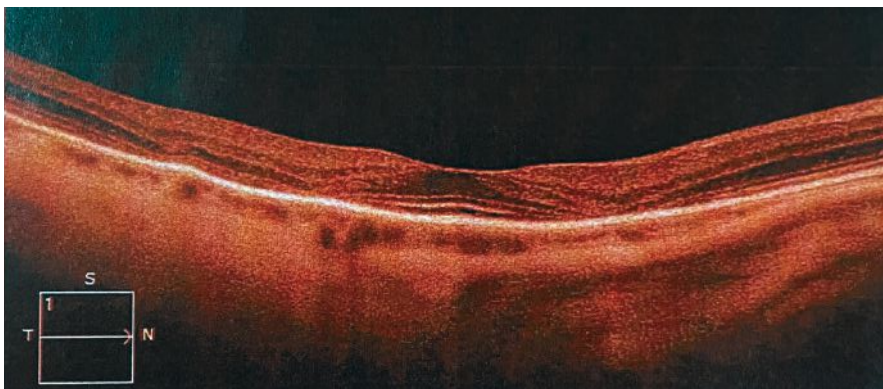
**RECOGNIZE  
AND REFER**

\*GA is defined by atrophic lesions, resulting from loss of photoreceptors, RPE, and underlying choriocapillaris. This results in a choroidal hypertransmission defect on OCT.<sup>1,8,9</sup>  
BCVA=best-corrected visual acuity; OCT=optical coherence tomography; RPE=retinal pigment epithelium.

**References:** 1. Fleckenstein M, Mitchell P, Freund KB, et al. The progression of geographic atrophy secondary to age-related macular degeneration. *Ophthalmology*. 2018;125(3):369-390. doi:10.1016/j.ophtha.2017.08.038. 2. Heier JS, Pieramici D, Chakravarthy U, et al. Visual function decline resulting from geographic atrophy: results from the chroma and spectri phase 3 trials. *Ophthalmol Retina*. 2020;4(7):673-688. doi:10.1016/j.oret.2020.01.019. 3. Sunness JS, Margalit E, Sirkumaran D, et al. The long-term natural history of geographic atrophy from age-related macular degeneration: enlargement of atrophy and implications for interventional clinical trials. *Ophthalmology*. 2007;114(2):271-277. 4. Boyer DS, Schmidt-Erfurth U, van Lookeren Campagne M, Henry EC, Brittain C. The pathophysiology of geographic atrophy secondary to age-related macular degeneration and the complement pathway as a therapeutic target. *Retina*. 2017;37(5):819-835. doi:10.1097/iae.0000000000001392. 5. American Optometric Association. AOA Comprehensive adult eye and vision examination. *Quick Reference Guide: Evidence-Based Clinical Practice Guideline*. 1st ed. Accessed July 13, 2023. [https://www.aoa.org/documents/EBO/Comprehensive\\_Adult\\_Eye\\_and\\_Vision\\_20QRG.pdf](https://www.aoa.org/documents/EBO/Comprehensive_Adult_Eye_and_Vision_20QRG.pdf). 6. Holz FG, Strauss EC, Schmitz-Valckenberg S, van Lookeren Campagne M. Geographic atrophy: clinical features and potential therapeutic approaches. *Ophthalmology*. 2014;121(5):1079-1091. doi:10.1016/j.ophtha.2013.11.023. 7. Lindblad AS, Lloyd PC, Clemons TE, et al; Age-Related Eye Disease Study Research Group. Change in area of geographic atrophy in the age-related eye disease study: AREDS report number 26. *Arch Ophthalmol*. 2009;127(9):1168-1174. doi:10.1001/archophthol.2009.198. 8. van Lookeren Campagne M, LeCouter J, Yaspan BL, Ye W. Mechanisms of age-related macular degeneration and therapeutic opportunities. *J Pathol*. 2014;232(2):151-164. doi:10.1002/path.4266. 9. Chakravarthy U, Bailey CC, Scanlon PH, et al. Progression from early/intermediate to advanced forms of age-related macular degeneration in a large UK cohort: rates and risk factors. *Ophthalmol Retina*. 2020;4(7):662-672.

Apellis

The APPELLIS® name and logo is a registered trademark of Apellis Pharmaceuticals, Inc.  
©2023 Apellis Pharmaceuticals, Inc. 8/23 US-GA-2300089 v1.0



The second OCT was performed a year later by the second eye doctor. This horizontal scan of the posterior pole of the right eye was taken with a Zeiss.

revealed subtle pigmentary changes in both maculae, worse in the right eye.

The doctor immediately arrived at the diagnosis of Plaquenil macular toxicity and called the patient’s rheumatologist, who told the patient to stop the Plaquenil. An appointment with a highly respected retinologist was scheduled. One week later, the retina specialist fully evaluated the patient and agreed with the diagnosis of Plaquenil-induced macula toxicity and advised the patient never to consume Plaquenil again. The retinologist also informed the patient that there was no effective treatment at the present time to reverse the damage already done.

Shortly afterwards, the patient initiated malpractice litigation against the rheumatologist for prescribing too high a dosage of Plaquenil and both eye doctors for failing to perform comprehensive evaluations that could have detected the drug toxicity earlier.

### You Be the Judge

- Was the patient—a successful fashion model who, at 5’ 10”, weighed only 99 lbs.—on too high a dosage of Plaquenil?
- Should the patient’s weight have been a red flag to the rheumatologist and to the two eyes doctors?
- Did the first eye doctor interpret the SD-OCT correctly?
- Did the second one interpret the SD-OCT correctly?
- Is bull’s eye maculopathy, diagnosed with ophthalmoscopy or fundus autofluorescence (FAF), an early sign of toxicity?

- When Plaquenil is discontinued, might the retinopathy still progress?
- If the patient were Asian and not Caucasian, would the recommended exam be modified?

### Our Opinion

One of us (JS) was asked to review the case by the attorneys representing the first eye doctor.

After reviewing all the records and other available information, I opined that the first eye doctor met the existing standard of care. This doc corrected visual acuity to 20/20+ in each eye, performed an Amsler grid, which was normal in each eye, did not find any abnormalities with a dilated fundus exam, obtained an SD-OCT, which was interpreted correctly as normal, and counselled the patient about retinal risks of Plaquenil over time.

Could this doc have gone beyond the standard of care and performed baseline fundus photography, FAF, multifocal electroretinographs (mfERGs), comprehensive color vision and 10-2 visual fields?

It is unclear which test or tests are most sensitive to detect early Plaquenil toxicity, and hence it can be argued that it is in the patient’s interest to perform

several of these tests. There exists literature that demonstrates that mfERGs are most sensitive for detecting early Plaquenil toxicity, but mfERGs are rarely available in ophthalmic practices.

Most surveys reveal that well more than half of ophthalmic clinicians have access to SD-OCT; hence, this easy-to-perform, objective test—which rarely requires dilation—is a component of the existing standard of care in managing patients on Plaquenil.<sup>1</sup> However, the performance of a test alone does not meet the existing standard of care.

In addition to OCT and mfERGs, fundus autofluorescence is the third objective test often recommended. The AAOPh 2016 Revised Screening Guidelines for Plaquenil Toxicity states that one of these three objective tests should be performed. The same Guideline also lists VA, a DFE and a 10-2 SITA standard visual field with a white stimulus but a 24-2 SITA standard or a 30-2 with a white stimulus for Asian patients. It is generally agreed this population develops Plaquenil toxicity initially outside the macula.

Although I (JS) was not asked to render an expert opinion about the second eye doctor, who also performed an SD-OCT, it should be noted that the test was incorrectly interpreted as normal. The thin bright line above the retinal pigment, termed the photoreceptor integrity line (PIL), the ellipsoid zone or the IS/OS junction, should be continuous throughout the entire scan.

In this case, the PIL was present under the fovea but clearly missing to either side of the fovea. This is a finding highly suggestive of early Plaquenil toxicity and is most often encountered prior to bull’s eye maculopathy detection with ophthalmoscopy or fundus photography.

NOTE: This article is one of a series based on actual lawsuits in which the author served as an expert witness or rendered an expert opinion. These cases are factual, but some details have been altered to preserve confidentiality. The article represents the authors’ opinion of acceptable standards of care and do not give legal or medical advice. Laws, standards and the outcome of cases can vary from place to place. Others’ opinions may differ; we welcome yours.

## Additional Comments and Follow-up

Plaquenil-induced macular toxicity is a somewhat uncommon clinical encounter and is very rare in the first several years of treatment, such as in this case. Plaquenil should be discontinued immediately if maculopathy is detected. Note that the maculopathy sometimes continues to progress for several years even after the drug is discontinued due to the slow clearance of the drug from the retina and retinal pigment epithelium. It has even been reported to progress for up to two decades after discontinuation.<sup>2</sup>

“  
**Note that the maculopathy sometimes continues to progress for several years even after the drug is discontinued due to the slow clearance of the drug from the retina and RPE.**  
”

We will never know with any certainty whether this patient's low weight contributed to the early onset, but it is certainly plausible. The case against the rheumatologist was reportedly settled early on for an undisclosed amount. The case against the first eye doc was dropped, primarily because the OCT was performed and interpreted correctly. The case against the second eye doc went forward and was based upon his misinterpretation of the OCT.

One could argue that if he did not perform an OCT, the case against him would not have been pursued. The outcome is unknown at the present time. ■

*Dr. Diana Geraghty and Dr. Sherman are presently composing a manuscript to be submitted for publication tentatively entitled, “Imaging—Friend or Foe in Malpractice Allegations?”*

1. Marmor MF, Kellner U, Lai TY, et al.; American Academy of Ophthalmology. Recommendations on screening for chloroquine and hydroxychloroquine retinopathy (2016 revision). *Ophthalmology*. 2016;123(6):1386-94.

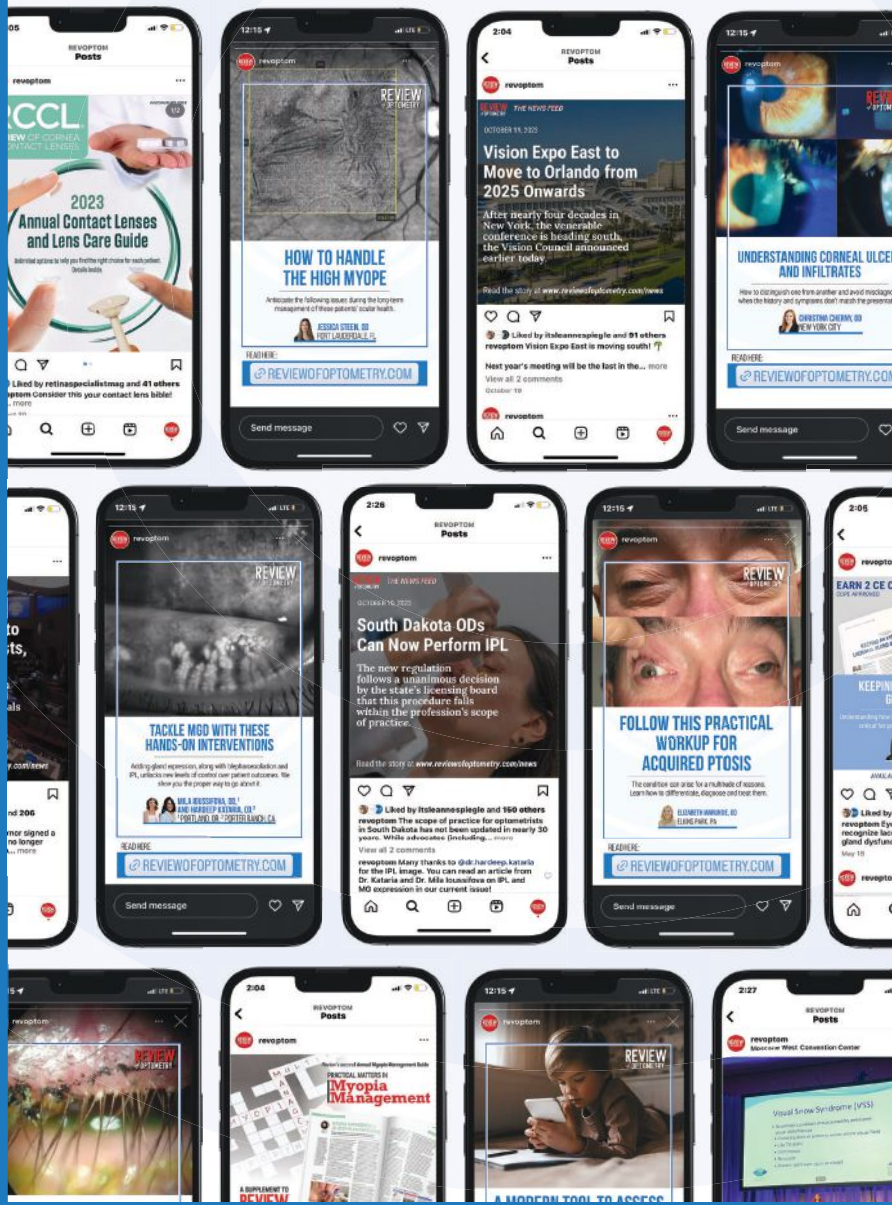
2. Pham BH, Marmor MF. Sequential changes in hydroxychloroquine retinopathy up to 20 years after stopping the drug: implications for mild vs. severe toxicity. *Retina*. 2019;39(3):492-501.

# A NEW WAY TO EXPERIENCE

## REVIEW OF OPTOMETRY

Follow us on Instagram for striking clinical images, news headlines, issue previews and great content from the magazine—all formatted for mobile.

 @REVOPTOM



# 2023 INCOME TRENDS: A WEALTH OF EXPERIENCE

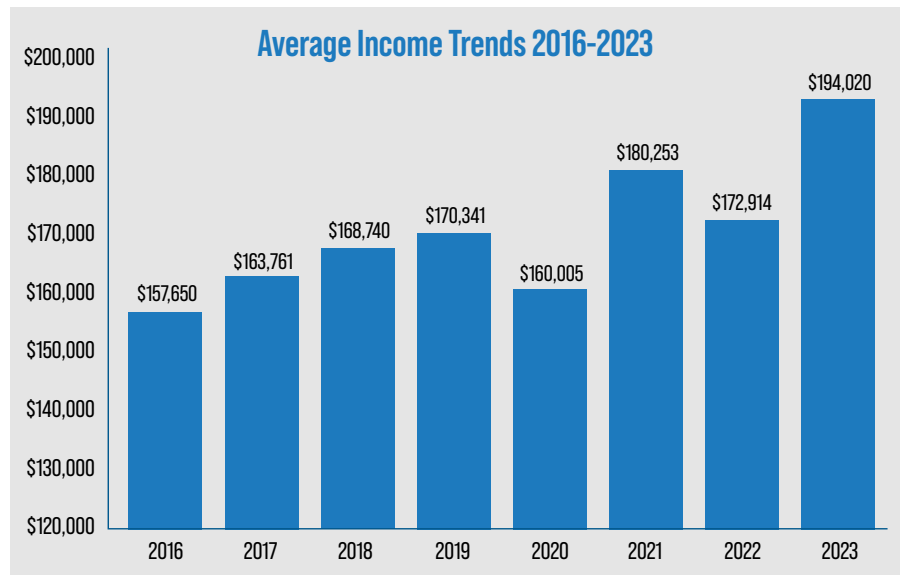
Established ODs in private practices put up big numbers this year, lifting overall averages in our survey, while many others—employed docs especially—say their earnings feel stagnant.

BY JACK PERSICO  
EDITOR-IN-CHIEF

Strange things are happening to the income trends seen in our annual reader survey of late. Pre-COVID, the national average income figures reported by our readers made modest, and likely somewhat disappointing, gains year over year from 2016 to 2019 (see chart). Ever since COVID hit, however, incomes have zig-zagged: an understandable drop during the lockdown year of 2020 followed by an average year-over-year gain of \$20,000 per OD in 2021, then a second income drop in 2022 and *another* big jump this year. In fact, the national average optometric income reported for 2023 stands at \$194,020, representing a gain of 12.2% over 2022's figure of \$172,914.

And yet, plenty of ODs have reason to grumble. "It is a good income but the stress of managed care and government mandates makes the income feel as if it's not enough," wrote Lois Kessen, OD, a Midwestern solo practitioner, in this year's survey.

How did the profession's earnings go from "slow and steady" to "wild and woolly" in recent years? Declining insurance reimbursements and



a nasty jump in operating costs due to inflation are taking their toll on those who reported income declines year over year. But optometrists who notched gains consistently pointed to higher patient volume as the driver, more so than charging higher fees or increasing product sales.

While private practice optometry continues to dwindle as a proportion of the workforce—younger ODs are more often employed, either by choice or necessity—those who are self-employed can rack up some really healthy earnings. For the lucky

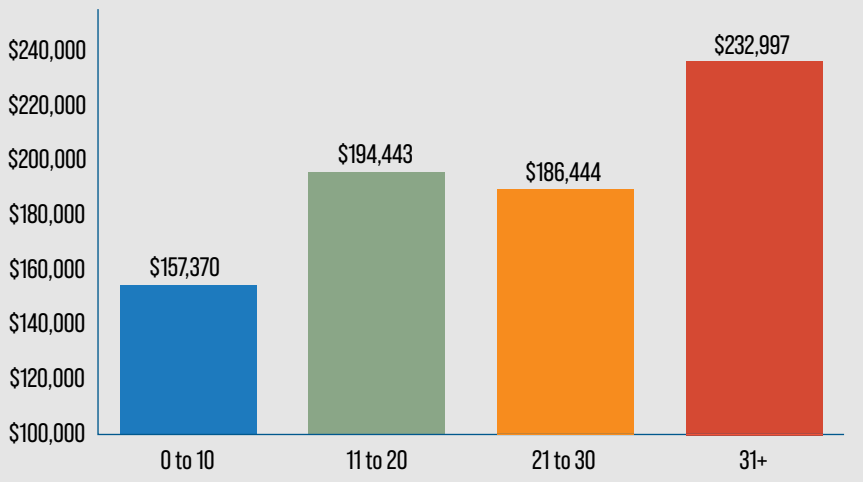
few whose practice growth reaches escape velocity, incomes will soar, especially when their offices are able to juice patient volume.

"Growth of the business has been showing that additional staff is a very good ROI," commented Michael Campbell, OD, a self-employed private practitioner from the South.

"Now that I'm in private practice, I'm finally earning my worth!" enthused Lisa Greene, OD, another Southerner who's her own boss.

These and other success stories are heartening. But plenty of ODs feel

### 2023 Income by Years in Practice



Let's dig into the numbers reported this year, looking in particular at various subsets of the responses to give more color to the overall income numbers.

As always, be mindful that while we ask the same survey questions, the responses we compare from year to year come from different individuals, making trend analysis tricky, especially among a smaller cohort. The results here offer an illuminating look at the profession but aren't considered statistically rigorous, particularly year-over-year comparisons.

### Private Practice Fuels Income

Those who did best in our 2023 income survey demonstrated two clear traits: seniority and self-employment. Optometrists who've been practicing for 31 years or more netted \$232,997 on average this year, while those with zero to 10 years of experience only earned an average of \$157,370, an income differential of over \$75,000 between the cohorts.

An even bigger gap was seen in the category of employment status. While only 42% of respondents identified as self-employed, bosses earned \$100,000 on average more than employees, with a whopping \$255,008 for self-employed ODs this

their income remains about the same even when they give it their all.

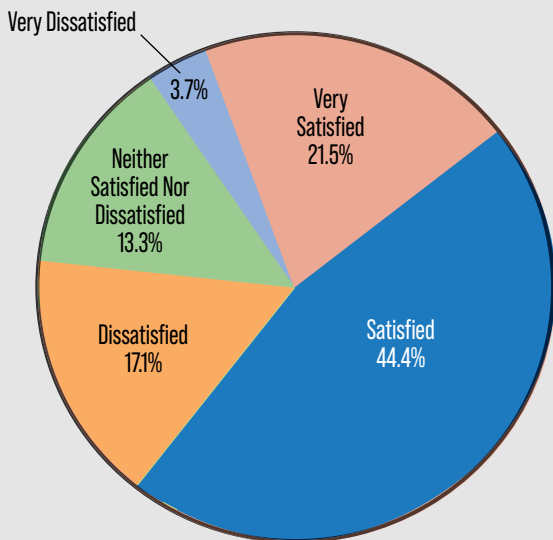
"My patients are coming to me for an exam and then going elsewhere to buy their glasses, either online or at a box store. I'm working harder for less," one Southern optometrist wrote. "Even though my medical model is increasing medical care, it requires me to do more work for less money than when I'm selling nice glasses to people like I did when the economy was stronger."

Those are some of the big-picture trends evident in our 2023 reader survey, in which 337 optometrists shared

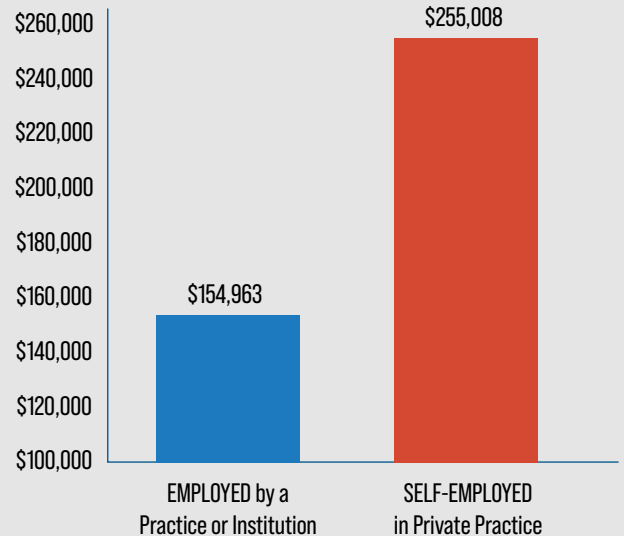
their income data and, often, a piece of their minds.

"I am working more than ever and have had my most productive year when it comes to patient volume, yet the wage inflation combined with decreased insurance reimbursement has resulted in a continued downward trend in net income," wrote one OD who practices in the West. "This is very frustrating given that many other career tracks enjoy year-over-year increased compensation with years of experience and inflation-related wage adjustments. Thank goodness I love what I do!"

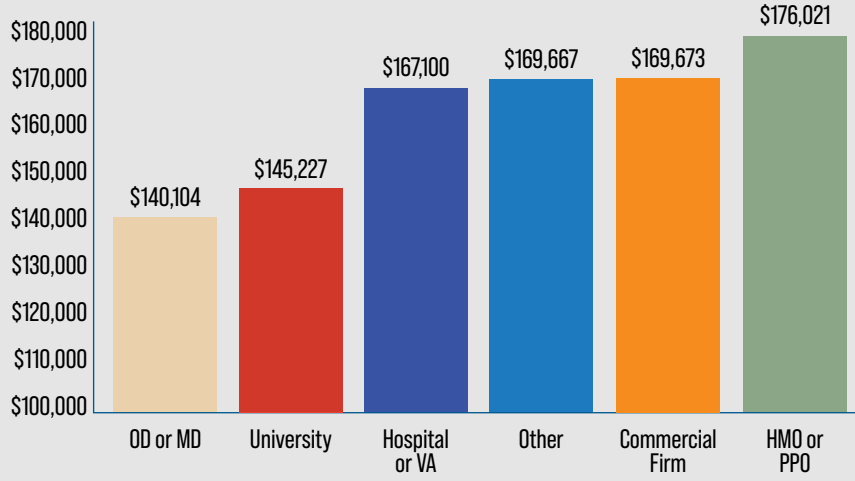
### How Satisfied are You with Your 2023 Income?




### 2023 Income by Employment Status



### 2023 EMPLOYED Income by Practice Setting



### 2023 Income by Gender



year vs. \$154,963 for those who are employed by another.

The cohort with the highest earnings in the 2023 survey was self-employed ODs in partnership or group private practices, who told us they expect to net \$315,159 on average, again making the case for the efficiencies that come with scale.

Those in solo private practice earned the still-impressive average of \$212,251, but the distinction is clear: when thinking about practice size as an income driver, bigger is better. One solo practice OD (again from the South!) articulates this very

path to success from his view in the trenches: “The number of people that I have seen has been going up, and as a result I could benefit from having another doctor in my practice part time to start and hopefully to build up to full-time. Then that would increase my gross revenue and the higher volume would allow me to streamline and increase my net.” Go for it, doc—make that hire!

#### Employed ODs: Lower Earnings, Less Stress

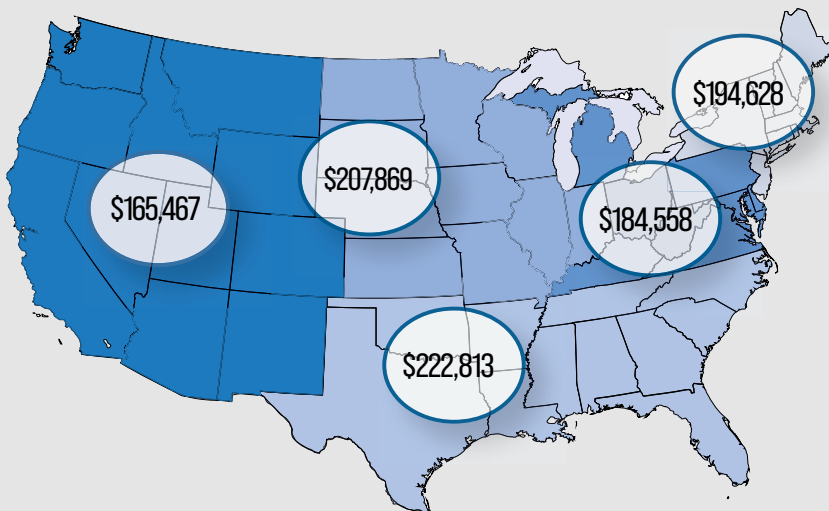
If you take the \$154,963 average income for the group of optometrists

who work for someone, there’s a considerable spread in earnings depending on who’s cutting the checks. The lowest pay comes from private practices, as those employed by an OD or an MD earned just \$140,014 on average. The best payers were HMO/PPO companies, at \$176,021.

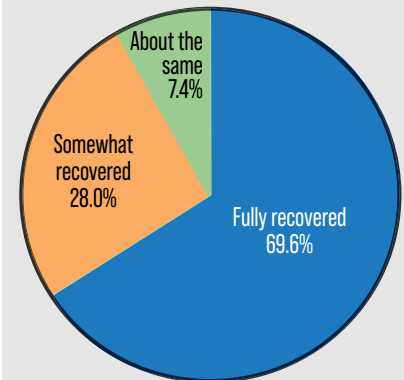
Some of the better paying jobs are also more demanding. “I work way harder than what others do in much less complex care facilities,” wrote Logan Kiekhafer, OD, a Midwestern doc who’s employed by a hospital.

Age is a significant factor in the lower average earnings for employed

### 2023 Income by Region

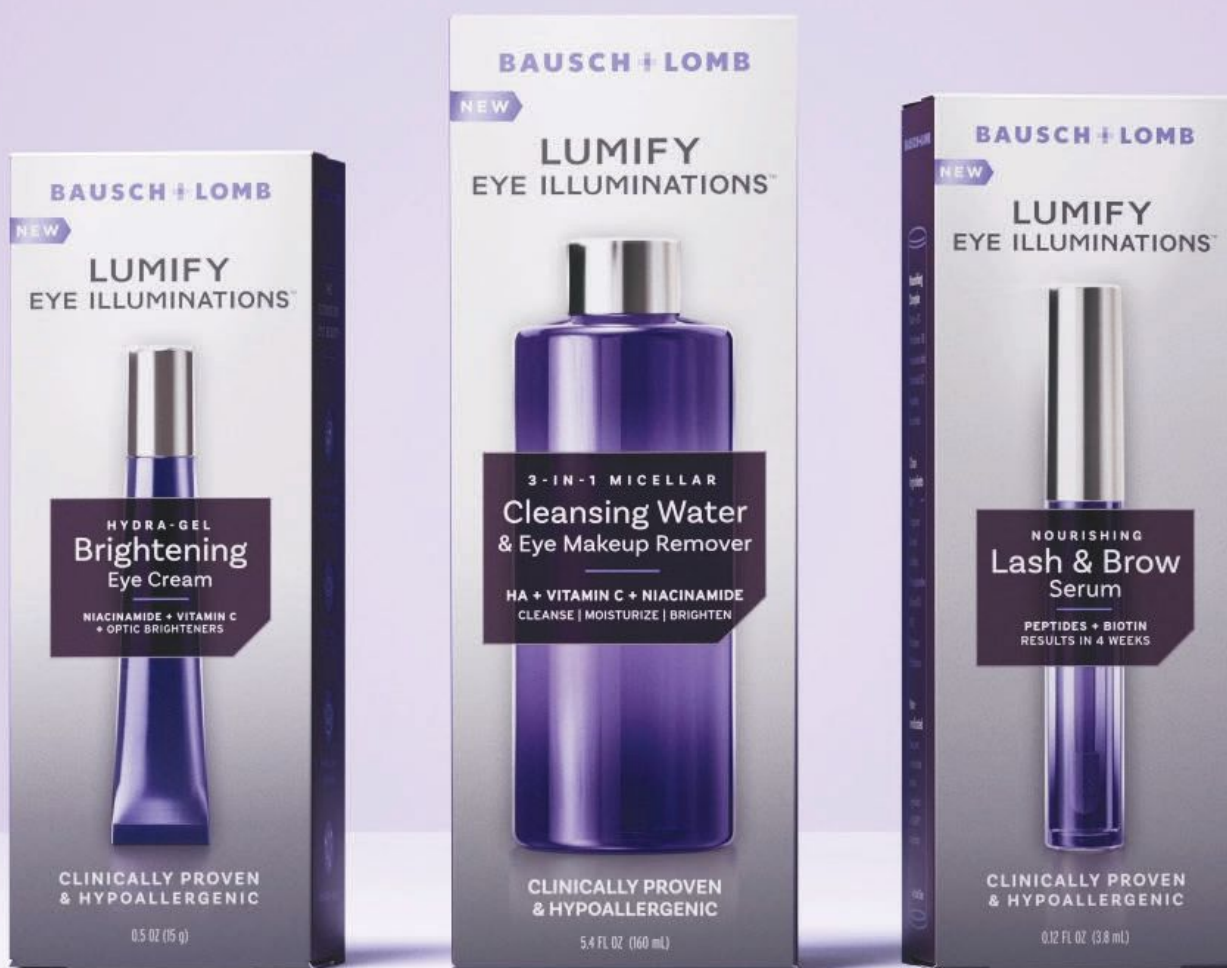

### Has Your Practice Recovered Financially from the Effects of the Pandemic at its Worst?



FROM THE EYE CARE EXPERTS AT **BAUSCH+LOMB**

# LUMIFY EYE ILLUMINATIONS™



Non-irritating formulas

Developed with Eye Doctors  
and Dermatologists

Clinically-proven

A trio of specialty eye care products scientifically formulated for the sensitive eye area.  
Clinically proven with 15,000 product applications up to 12 weeks.

Your patients can find this **in the eye care aisle.**

©2023 Bausch + Lomb LEM.0141.USA.23 [LUMIFYeyes.com](https://www.LUMIFYeyes.com)

ODs, as they tend to be earlier on in their careers (though that’s not always the case). Student loan debt is a notorious albatross around the necks of many, but there’s also a lot of happiness among younger employed ODs. “I’m a relatively newer graduate clearing more than what I’d ever thought I’d make,” one young optometrist from the West wrote.

And another employed optometrist from the West put it simply: “I make enough to support my family doing a job that I love.”

By and large, ODs are happy with their profession and what they earn practicing it. Only about 21% of readers were disenchanted with their incomes: 17.1% said they were dissatisfied and 3.7% were very dissatisfied. By contrast, 44.4% said they were satisfied and another 21.5% called themselves very satisfied, giving two-thirds of the sample overall a positive outlook this year.

Looking at employment status among the satisfied vs. dissatisfied question, we see that, well, money ain’t everything. Of those who said they were satisfied or very satisfied, 56.2% are employed ODs and 43.8% are self-employed. Wrote one senior Midwestern optometrist: “I have no stress as a first-time employee. I was in private practice the past 37 years. I earn less now but have no worries.”

### Geography and Gender

These two categories also can swing the numbers in substantial ways.

As in so many professions, women in this field earn substantially less than men. Female ODs reported an average 2023 income of \$151,271 vs. \$235,162 for male ODs, meaning that women ODs earned 64.3% of what their male counterparts did. This is one more manifestation of structural and cultural factors in America that perpetuate income inequality between the sexes.

Specific to optometry, it’s worth noting that fewer female ODs are self-employed (34.1% for women vs. 48.2% for men) and, as noted above, self-employment is the biggest driver of income growth.

Another factor at work: The women ODs in our survey also skewed younger than the men, and higher earnings accrue later in one’s career. The “years in practice” breakdown by gender was as follows:

	Women	Men
0-10 yrs .....	27.1%	16.1%
11-20 yrs .....	28.9%	23.6%
21-30 yrs .....	27.7%	30.4%
31+ yrs .....	16.3%	29.8%

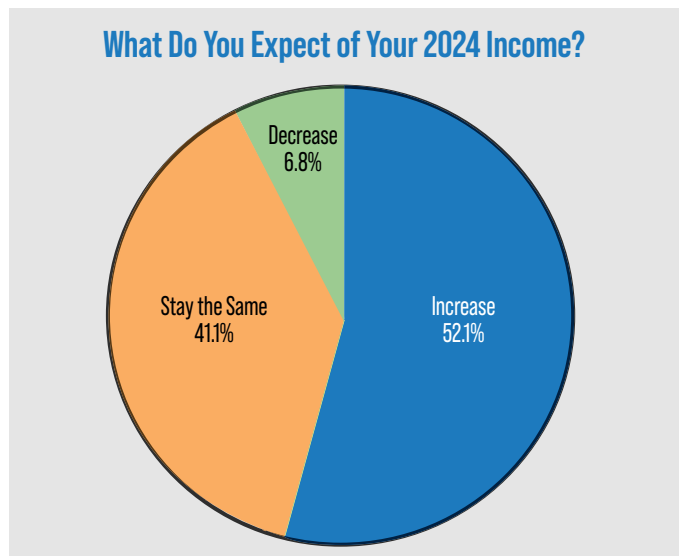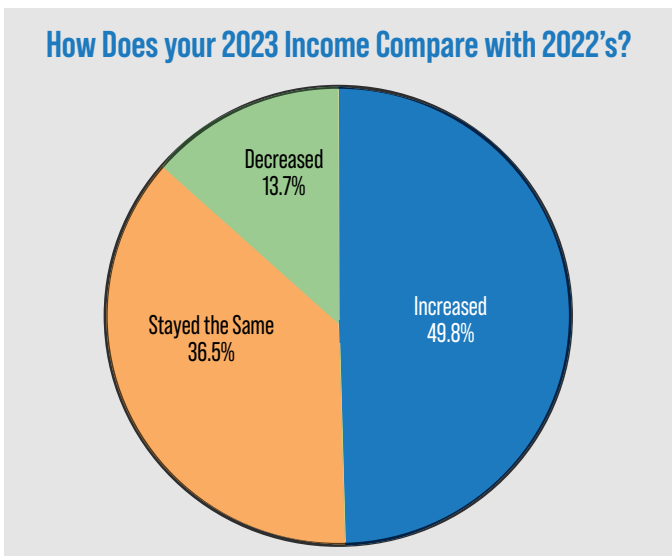
Drilling down into income levels within each of the years in practice cohorts, we find that the gender pay

gap is most pronounced in the 21-30 year bracket, where male optometrists earned \$101,490 more than female ODs on average. The men in this category took home \$234,395 while the women netted \$132,905. The full list of gender pay disparities by years in practice—all favoring men—were as follows:

	Women	Men
0-10 yrs .....	\$132,644	\$190,695
11-20 yrs .....	\$152,454	\$245,616
21-30 yrs .....	\$132,905	\$234,395
31+ yrs .....	\$199,500	\$253,095

Needless to say, we hope to see the gender gap in income shrink in the coming years as more female ODs ascend to positions of seniority in the profession. Of course, headwinds that exist beyond optometry will continue to make such progress challenging.

Looking at regional differences in the United States, practice location also created a notable spread in the income numbers reported. The most striking difference is, frankly, the West vs. everyone else. Western optometrists earned, on average, \$165,467—the lowest of all the regions tracked. The highest earners were found in the South, where average incomes were reported to be \$222,813, a difference of more than \$50,000 per OD based on region of





the country alone. When averaging non-Western US regions as one bloc and comparing that to the West, there's still a \$20,000 penalty for practicing in the West.

"My income has not kept up with inflation," said one optometrist practicing in the West. "I'm not making much more today per patient than I did in 1995 when I graduated."

Another established solo practitioner in the West describes her struggles to maintain profitability of her practice as follows: "I have not had problems with staff turnover the way many of my colleagues have, but increased salaries are really making it difficult. Minimum wage increases have more than doubled my payroll. While I definitely feel that these increases are deserved, I simply don't have the money."

### Winds of Change

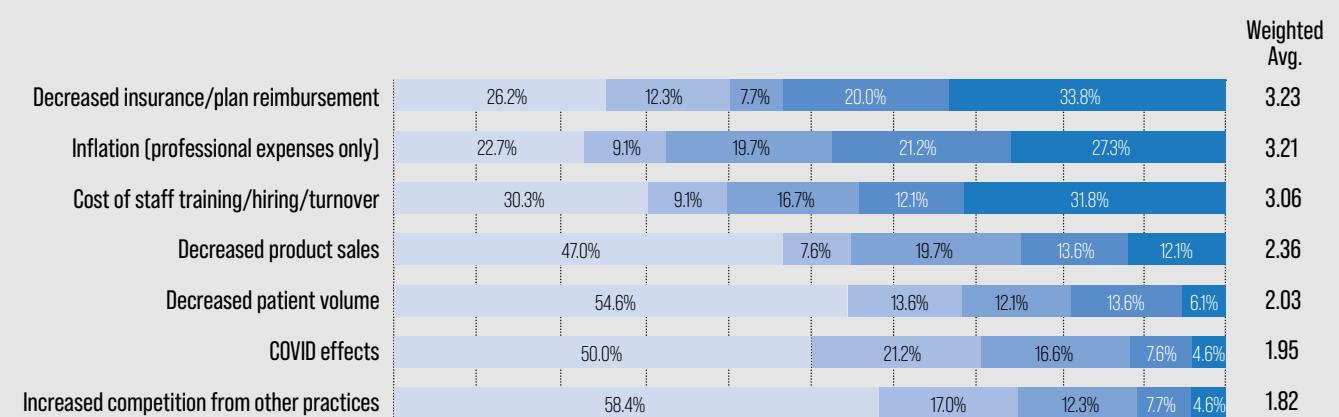
In a year with some notable and concerning income disparities across several metrics, at least one disruptive force seems to have abated: the effects of the COVID pandemic. Only 7.4% of respondents said its impact was the same as ever, while 69.6% declared their practices fully recovered. Instead, those who felt outsized effects on their income this year pointed to one sadly familiar factor—declining insurance reimbursement—and another that's been more of a concern only recently: inflation. "My income has only stayed the same due to increased work hours/efficiency, but reimbursements and patient spending has decreased while cost of good sold has increased," a Midwestern optometrist conveyed in his survey response.

Nevertheless, more than half of respondents anticipate gains in 2024, as 52.1% said they expect their incomes to increase. Only 6.8% are bracing for a decrease, while 41.1% expect to earn pretty much the same as this year.

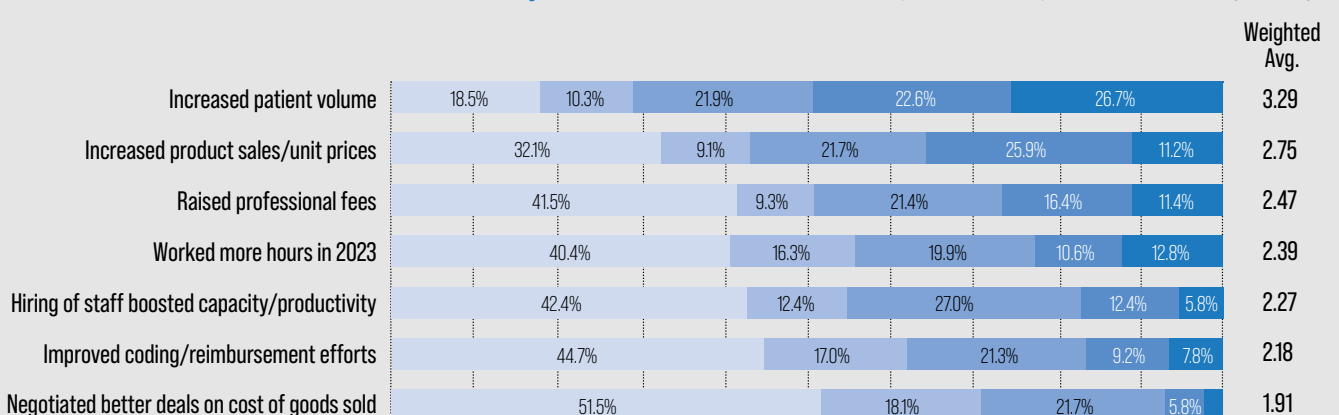
Some of that is strategic, as one solo practitioner from the West explained: "I choose to hold my salary here so that I have more funds available for new equipment, bonuses, etc. It keeps me flexible and able to adapt to new economic challenges."

Others, especially employed optometrists, feel more powerless to effect big increases but often point to the silver lining of work-life balance and a comfortable standard of living. Practicing optometry "supports my family with a nice lifestyle," one wrote. At the end of the day, that's the clearest path to contentment. ■

**If Your 2023 Net Income Decreased, Which Factors Played a Role?** Rated on 1-5 scale (1 = least impact, 5 = most impact)



**If Your 2023 Net Income Increased, Which Factors Played a Role?** Rated on 1-5 scale (1 = least impact, 5 = most impact)



# TAKE SLT TO THE NEXT LEVEL: 10 QUESTIONS TO ASK YOURSELF

Optometrists who want to be adept at this procedure should have these answers ready.



Selective laser trabeculoplasty (SLT) has been a mainstay of the glaucoma treatment armamentarium for almost two decades, initially as a second-line therapy after maximum drop therapy. However, SLT has gained steam as primary therapy in open-angle glaucoma and ocular hypertension cases more recently thanks to the LiGHT trial among other studies. Frankly, the literature encouraging optometrists and ophthalmologists alike to change their current thinking and use SLT earlier in the course of therapy is overwhelming at this point. Optometrists in 10 states are currently authorized to perform SLT. The following set of questions and answers will help guide the early adopter of SLT to take the performance of their SLT procedure in their practice to the next level.

## 1. Does SLT work as primary therapy?

The literature is incredibly strong towards SLT use earlier in the course

of therapy. Generally, the literature indicates that the practitioner can expect 20% to 35% intraocular pressure (IOP) lowering for patients where SLT is used as primary therapy. An initial study demonstrated a mean IOP reduction of 23.8% at 26 weeks after a single treatment.<sup>1</sup> The SLT/Med Study showed the percentage of IOP reduction nine to 12 months after treatment was 26.4% for the SLT group and 27.8% in the medical/prostaglandin arm with the two treatment arms being statistically equivalent.<sup>2</sup>

Overall success depends on how it is defined, with the LiGHT trial showing 74.2% of patients being drop-free three years after primary SLT treatment.<sup>3</sup> The authors wrote that SLT is effective in 80% to 90% of patients with the effect tending to wane with time. SLT has repeatedly been shown to


be equivalent to prostaglandins for first-line therapy, with one study concluding SLT should be offered as a first-line treatment for open-angle glaucoma and ocular hypertension, supporting a change in clinical practice.<sup>2,3</sup> The six-year LiGHT trial data released in early 2023 showed 69.8% of SLT patients remained at or below target IOP after six years (they were drop-free). This does

not necessarily mean one SLT held the IOP below target for that six-year time period. Of those patients that were drop-free, 62.7% needed only one SLT, 30.9% needed two SLTs and 5.9% needed three SLTs to stay below target over the study period. Most significantly, more eyes in the first-line drop arm exhibited disease progression (26.8%) vs. the eyes in the first-line SLT arm that exhibited disease progression (19.6%). Clearly stated, pa-

“**The biggest predictive factor for SLT success is pre-laser IOP (the higher the pre-op IOP, the more likely robust IOP lowering). The second biggest is the number of meds the patient is on.**”

### About the authors

**Dr. Komal Patel** is an assistant professor at the Oklahoma College of Optometry (NSUOCO). She completed a primary care residency at NSUOCO specializing in ocular disease and advanced procedures. Dr. Patel is a diplomate of the American Board of Optometry and a fellow of the American Academy of Optometry. **Dr. Nate Lighthizer** is the associate dean, director of continuing education and chief of specialty care clinics at NSUOCO. He is a founding member and immediate past president of the Intrepid Eye Society. Dr. Lighthizer's full disclosure list can be found in the online version of this article.



**Fig. 1. A 360° SLT is being performed with the Rapid SLT lens. We are in mirror #5 of treatment (top left mirror position).**

tients were more likely to progress over a six-year period on eye drops compared to SLT, with compliance likely being the main driver behind that.<sup>4</sup>

**Bottom line:** *SLT works best as first-line therapy, and eyecare providers are encouraged to use SLT earlier in the course of therapy.*

## 2. Does SLT work as secondary therapy?

SLT has also been investigated as an adjunct treatment for patients on concurrent topical therapy as a means of further IOP reduction. One study reported clinical outcomes of 52 primary open-angle glaucoma (POAG) eyes that received adjunct SLT while on topical medical treatment.<sup>5</sup> Average IOP reduction from baseline was 24.3% at one year, 27.8% at two years, 24.5% at three years and 29.3% at four years.

Similar to medications, the effect of SLT as adjunctive therapy is likely not as robust as primary therapy, with the average IOP reduction being approximately 10% to 25% depending on the

number of medications the patient is on and the baseline IOP prior to the laser.

Ask yourself, “Which glaucoma medication typically lowers IOP the most?” The first eye drop, the second, the third or the fourth? Generally, it is the first eye drop, with clinical experience showing that this first drop lowers IOP approximately 20% to 30%, the second perhaps 15% to 20%, the third eye drop 5% to 15% and the fourth perhaps zero to 10%.

SLT follows those exact same patterns. If a patient is on three glaucoma medications and then SLT is used, the IOP reduction will likely not be 20% to 30% but perhaps closer to 5% to 10% with the added advantage of helping to blunt the diurnal fluctuations of the IOP, which has been proven to be a significant advantage of SLT.

**Bottom line:** *It does work, just temper your expectations on percentage IOP reduction when an SLT is done on a patient who is already on two, three or more glaucoma medications.*

## 3. Which medications does SLT pair best with?

When used as adjunctive therapy, SLT pairs well with most all glaucoma drugs. A retrospective review found no difference between specific classes of glaucoma medications in regard to SLT success.<sup>6</sup> These findings confirm a role for SLT as an adjunct to glaucoma medications, including prostaglandin analogs (PGAs), which have been suggested to possibly impair the effectiveness of SLT by competing for a common pathway to lower IOP.<sup>7</sup> The studies that have suggested that perhaps SLT and PGAs do not pair well together have emphasized the similar mechanisms of lowering IOP for both of them (inflammatory effects via the outflow pathways).

Perhaps it is best for each treatment modality to lower IOP via different mechanisms (*e.g.*, decreased production, increased outflow, lowering episcleral venous pressure). For that reason, at least in theory, SLT could possibly pair best with an aqueous suppressant such as a topical beta-blocker or carbonic anhydrase inhibitor. Clinical experience has shown that SLT pairs well with most topical glaucoma medications.

**Bottom line:** *Clinically speaking, SLT will pair with any glaucoma medication. However, do remember when SLT works best (first-line therapy—see question #1). In theory, SLT pairs best with an aqueous suppressant to maximize the different mechanisms to lower the IOP.*

## 4. When should I not do an SLT?

Knowing when and when not to perform a procedure is critical. SLT is a safe procedure, with few contraindications, though some do exist.

The presence of less than 90° to 180° degrees of visible posterior pigmented trabecular meshwork (TM) on gonioscopy (narrow angles) likely is a contraindication for performing SLT in its current form (see sidebar, “Is There a More ‘Direct’ Approach?”). Numerous secondary glaucomas, including inflammatory, neovascular, angle recession and juvenile, are either



**Fig. 2. SLT being done in a heavily pigmented angle. Care should be taken in these types of angles to decrease the energy, use fewer laser pulses over 180° or less and monitor for any post-op IOP spikes closely.**

absolutely or relatively contraindicated due to the potential for worsening the condition (inflammatory glaucoma), needing other therapy (neovascular glaucoma), or likely non-effectiveness of treatment (angle recession and juvenile glaucoma).

The effect of SLT on the corneal endothelium may be transient, and long-term effects are probably negligible in normal corneas. However, in compromised corneas and corneas with pigment deposits on the endothelium, there may be a risk of corneal endothelial compromise, especially after repeated SLT.<sup>8</sup> Therefore, it may be wise to limit the number of shots and energy when considering SLT in a patient with a compromised corneal endothelium.

While age was a contraindication for the previous version of laser trabeculoplasty (argon; ALT), studies show it is not a contraindication for SLT.<sup>9</sup>

One interesting clarification point: it was once thought that failure of one SLT was a contraindication to perform future SLTs. Some of the leading experts across the world now are providing guidance that just because an SLT failed the first time does not mean it cannot be tried a second or third time.<sup>10</sup> Non-response in the LiGHT

trial had SLT repeated as soon as eight weeks. The authors were willing to give SLT a second try if it did not give a robust IOP lowering the first time. Generally, we will wait approximately three to 12 months before repeating a failed SLT.

*Bottom line: Few contraindications exist for SLT, except for narrow angles, certain secondary glaucomas and possibly corneas with compromised endothelium being the main contraindications.*

## 5. Can I predict which patients are going to be most successful with SLT?

While SLT works well for most, it does not work for all, and selecting patients based on factors that will most likely lead to success of the SLT is critical. Several studies have shown that the strongest predictor of SLT success is higher preoperative IOP.<sup>6,11-12</sup>

Intuitively, the number of medications a patient is on likely affects the percentage of IOP reduction after SLT, with the more preoperative medications likely leading to a lower percentage of IOP reduction, and vice-versa. One study described results after analysis of 111 eyes treated with 360° SLT, finding that the use of three topical IOP-lowering medications was associated with SLT fail-

ure.<sup>13</sup> Conversely, another described the five-year success rates of SLT and found no significant difference in success rate on the basis of the number of preoperative glaucoma eye drops patients were using.<sup>14</sup> There was, however, an increased likelihood of patients requiring a second procedure (SLT or trabeculectomy) during the five-year follow-up period in those who were taking two or more preoperative IOP lowering drops.

Increased angle pigmentation may correlate with SLT efficacy. In one study, patients were subdivided into three groups on the basis of angle pigmentation.<sup>15</sup> Mean IOP decreased by 2.06mm Hg, 2.46mm Hg and 4.75mm Hg in subgroups with low, marked and high angle pigmentation, respectively. Conversely, other studies have shown that angle pigmentation is not predictive of SLT success.<sup>16</sup>

Regarding the mechanism of action of SLT, pigmentation in the angle is an important variable to consider, as SLT selectively targets melanin to achieve the desired biologic/inflammatory effect. However, angles with low pigmentation likely will still show clinically significant IOP-lowering effects provided treatment protocols are adjusted properly (increasing treatment energy).

Multiple other factors have been investigated yet were not found to be significant predictors of success, including age, sex, previous ALT, angle grade, lens status and central corneal thickness.<sup>6</sup>

*Bottom line: The biggest predictive factor for SLT success (defined as robust percent IOP lowering) is pre-laser IOP (the higher the pre-op IOP, the more likely robust IOP lowering). The second biggest predictive factor for success is the number of meds the patient is on (see question #2); however, there are some studies that refute that.*

*For example, in which patient, A or B, is the SLT likely going to lower the IOP more?*

**Patient A:** IOP = 25mm Hg on the day of the procedure. SLT used first-line therapy (zero meds).

**Patient B:** IOP = 18mm Hg on the day of the SLT. Patient is on two glaucoma medications.

*The answer is Patient A.*

## TREAT DRY EYE FLARES FIRST & FAST<sup>1\*</sup>

EYSUVIS<sup>®</sup> IS DESIGNED TO GO DEEP TO DELIVER LOTEPREDNOL NANOPARTICLES TO THE SITE OF INFLAMMATION<sup>2,3</sup>

ACCESS GRANTED

Start with EYSUVIS<sup>®</sup> – the first and only FDA-approved corticosteroid for the short-term treatment of dry eye (up to 2 weeks).<sup>4,5</sup>

EYSUVIS<sup>®</sup>, with proprietary AMPPLIFY Drug Delivery Technology, is designed to deliver loteprednol nanoparticles to the sites of ocular surface inflammation, where dry eye flares start.<sup>2,3</sup>

EYSUVIS<sup>®</sup> goes to work fast and provides rapid improvement of ocular discomfort, with results as early as Day 4 after starting treatment.<sup>1\*</sup>

Go deep to treat dry eye with EYSUVIS<sup>®</sup>.<sup>2,3</sup>



\*The safety and efficacy of EYSUVIS<sup>®</sup> was assessed in 4 multicentered, randomized, double masked, placebo-controlled trials in 2,871 patients with documented Dry Eye Disease. Patients received either EYSUVIS<sup>®</sup> or vehicle 4 times a day for at least 2 weeks. In one Phase 3 study, patients using EYSUVIS<sup>®</sup> showed significant reduction in the symptoms of dry eye (ocular discomfort) as early as Day 4 after starting treatment (vs. vehicle). Symptom improvement continued up to the end of the treatment period (Day 15, primary endpoint). Patients using EYSUVIS<sup>®</sup> also showed significant reduction in signs of dry eye (conjunctival hyperemia) at Day 15 vs. vehicle.

### INDICATION

EYSUVIS is a corticosteroid indicated for the short-term (up to two weeks) treatment of the signs and symptoms of dry eye disease.

### IMPORTANT SAFETY INFORMATION

#### Contraindication:

EYSUVIS, as with other ophthalmic corticosteroids, is contraindicated in most viral diseases of the cornea and conjunctiva including epithelial herpes simplex keratitis (dendritic keratitis), vaccinia, and varicella, and also in mycobacterial infection of the eye and fungal diseases of ocular structures.

#### Warnings and Precautions:

**Delayed Healing and Corneal Perforation:** Topical corticosteroids have been known to delay healing and cause corneal and scleral thinning. Use of topical corticosteroids in the presence of thin corneal or scleral tissue may lead to perforation. The initial prescription and each renewal of the medication order should be made by a physician only after examination of the patient with the aid of magnification, such as slit lamp biomicroscopy, and, where appropriate, fluorescein staining.

**Intraocular Pressure (IOP) Increase:** Prolonged use of corticosteroids may result in glaucoma with damage to the optic nerve, as well as defects in visual acuity and fields of vision. Corticosteroids should be used with caution in the presence of glaucoma. Renewal of the medication order should be made by a physician only after examination of the patient and evaluation of the IOP.

**Cataracts:** Use of corticosteroids may result in posterior subcapsular cataract formation.

**Bacterial Infections:** Use of corticosteroids may suppress the host response and thus increase the hazard of secondary ocular infections. In acute purulent conditions, corticosteroids may mask infection or enhance existing infection.

**Viral Infections:** Use of a corticosteroid medication in the treatment of patients with a history of herpes simplex requires great caution. Use of ocular corticosteroids may prolong the course and may exacerbate the severity of many viral infections of the eye (including herpes simplex).

**Fungal Infections:** Fungal infections of the cornea are particularly prone to develop coincidentally with long-term local corticosteroid application. Fungus invasion must be considered in any persistent corneal ulceration where a corticosteroid has been used or is in use.

#### Adverse Reactions:

The most common adverse drug reaction following the use of EYSUVIS for two weeks was instillation site pain, which was reported in 5% of patients.

Please see Brief Summary of Full Prescribing Information on the following page.

**REFERENCES:** **1.** Holland E, Nichols K, Foulks G, et al. Safety and efficacy of KPI-121 ophthalmic suspension 0.25% for dry eye disease in four randomized controlled trials. Presented at: AAO 2020; November 13-15, 2020; virtual meeting. **2.** Schopf L, Enlow E, Popov A, et al. Ocular pharmacokinetics of a novel loteprednol etabonate 0.4% ophthalmic formulation. *Ophthalmol Ther.* 2014;3(1-2):63-72. **3.** Popov A. Mucus-penetrating particles and the role of ocular mucus as a barrier to micro- and nanosuspensions. *J Ocul Pharmacol Ther.* 2020;36(6): 366-375. **4.** Alcon Data on File, 2022. **5.** Alcon Data on File, 2022.

## BRIEF SUMMARY OF FULL PRESCRIBING INFORMATION

### INDICATIONS AND USAGE

EYSUVIS is a corticosteroid indicated for the short-term (up to two weeks) treatment of the signs and symptoms of dry eye disease.

### CONTRAINDICATIONS

EYSUVIS, as with other ophthalmic corticosteroids, is contraindicated in most viral diseases of the cornea and conjunctiva including epithelial herpes simplex keratitis (dendritic keratitis), vaccinia, and varicella, and also in mycobacterial infection of the eye and fungal diseases of ocular structures.

### WARNINGS AND PRECAUTIONS

**Delayed Healing and Corneal Perforation**—Topical corticosteroids have been known to delay healing and cause corneal and scleral thinning. Use of topical corticosteroids in the presence of thin corneal or scleral tissue may lead to perforation. The initial prescription and each renewal of the medication order should be made by a physician only after examination of the patient with the aid of magnification, such as slit lamp biomicroscopy, and, where appropriate, fluorescein staining. **Intraocular Pressure (IOP) Increase**—Prolonged use of corticosteroids may result in glaucoma with damage to the optic nerve, as well as defects in visual acuity and fields of vision. Corticosteroids should be used with caution in the presence of glaucoma. Renewal of the medication order should be made by a physician only after examination of the patient and evaluation of the IOP. **Cataracts**—Use of corticosteroids may result in posterior subcapsular cataract formation. **Bacterial Infections**—Use of corticosteroids may suppress the host response and thus increase the hazard of secondary ocular infections. In acute purulent conditions of the eye, corticosteroids may mask infection or enhance existing infection. **Viral Infections**—Use of corticosteroid medication in the treatment of patients with a history of herpes simplex requires great caution. Use of ocular corticosteroids may prolong the course and may exacerbate the severity of many viral infections of the eye (including herpes simplex). **Fungal Infections**—Fungal infections of the cornea are particularly prone to develop coincidentally with long-term local corticosteroid application. Fungus invasion must be considered in any persistent corneal ulceration where a corticosteroid has been used or is in use. Fungal cultures should be taken when appropriate. **Risk of Contamination**—Do not to allow the dropper tip to touch any surface, as this may contaminate the suspension. **Contact Lens Wear**—The preservative in EYSUVIS may be absorbed by soft contact lenses. Contact lenses should be removed prior to instillation of EYSUVIS and may be reinserted 15 minutes following administration.

### ADVERSE REACTIONS

Adverse reactions associated with ophthalmic corticosteroids include elevated intraocular pressure, which may be associated with infrequent optic nerve damage, visual acuity and field defects, posterior subcapsular cataract formation, delayed wound healing and secondary ocular infection from pathogens including herpes simplex, and perforation of the globe where there is thinning of the cornea or sclera. **Clinical Trials Experience**—Because clinical trials are conducted under widely varying conditions, adverse reaction rates observed in the clinical trials of a drug cannot be directly compared to rates in the clinical trials of another drug and may not reflect the rates observed in practice. The most common adverse reaction observed in clinical trials with EYSUVIS was instillation site pain, which was reported in 5% of patients.

### USE IN SPECIFIC POPULATIONS

**Pregnancy**—Risk Summary: There are no adequate and well controlled studies with loteprednol etabonate in pregnant women. Loteprednol etabonate produced teratogenicity at clinically relevant doses in the rabbit and rat when administered orally during pregnancy. Loteprednol etabonate produced malformations when administered orally to pregnant rabbits at doses 1.4 times the recommended human ophthalmic dose (RHOD) and to pregnant rats at doses 34 times the RHOD. In pregnant rats receiving oral doses of loteprednol etabonate during the period equivalent to the last trimester of pregnancy through lactation in humans, survival of offspring was reduced at doses 3.4 times the RHOD. Maternal toxicity was observed in rats at doses 347 times the RHOD, and a maternal no observed adverse effect level (NOAEL) was established at 34 times the RHOD. The background risk in the U.S. general population of major birth defects is 2 to 4%, and of miscarriage is 15 to 20%, of clinically recognized pregnancies. Data: Animal Data. Embryofetal studies were conducted in pregnant rabbits administered loteprednol etabonate by oral gavage on gestation days 6 to 18, to target the period of organogenesis.

Loteprednol etabonate produced fetal malformations at 0.1 mg/kg (1.4 times the recommended human ophthalmic dose (RHOD) based on body surface area, assuming 100% absorption). Spina bifida (including meningocele) was observed at 0.1 mg/kg, and exencephaly and craniofacial malformations were observed at 0.4 mg/kg (5.6 times the RHOD). At 3 mg/kg (41 times the RHOD), loteprednol etabonate was associated with increased incidences of abnormal left common carotid artery, limb flexures, umbilical hernia, scoliosis, and delayed ossification. Abortion and embryofetal lethality (resorption) occurred at 6 mg/kg (83 times the RHOD). A NOAEL for developmental toxicity was not established in this study. The NOAEL for maternal toxicity in rabbits was 3 mg/kg/day. Embryofetal studies were conducted in pregnant rats administered loteprednol etabonate by oral gavage on gestation days 6 to 15, to target the period of organogenesis. Loteprednol etabonate produced fetal malformations, including absent innominate artery at 5 mg/kg (34 times the RHOD); and cleft palate, agnathia, cardiovascular defects, umbilical hernia, decreased fetal body weight and decreased skeletal ossification at 50 mg/kg (347 times the RHOD). Embryofetal lethality (resorption) was observed at 100 mg/kg (695 times the RHOD). The NOAEL for developmental toxicity in rats was 0.5 mg/kg (3.4 times the RHOD). Loteprednol etabonate was maternally toxic (reduced body weight gain) at 50 mg/kg/day. The NOAEL for maternal toxicity was 5 mg/kg. A peri-/postnatal study was conducted in rats administered loteprednol etabonate by oral gavage from gestation day 15 (start of fetal period) to postnatal day 21 (the end of lactation period). At 0.5 mg/kg (3.4 times the clinical dose), reduced survival was observed in live-born offspring. Doses  $\geq$  5 mg/kg (34 times the RHOD) caused umbilical hernia/incomplete gastrointestinal tract. Doses  $\geq$  50 mg/kg (347 times the RHOD) produced maternal toxicity (reduced body weight gain, death), decreased number of live-born offspring, decreased birth weight, and delays in postnatal development. A developmental NOAEL was not established in this study. The NOAEL for maternal toxicity was 5 mg/kg. **Lactation**—There are no data on the presence of loteprednol etabonate in human milk, the effects on the breastfed infant, or the effects on milk production. The developmental and health benefits of breastfeeding should be considered, along with the mother's clinical need for EYSUVIS and any potential adverse effects on the breastfed infant from EYSUVIS. **Pediatric Use**—Safety and effectiveness in pediatric patients have not been established. **Geriatric Use**—No overall differences in safety and effectiveness have been observed between elderly and younger adult patients.

### NONCLINICAL TOXICOLOGY

**Carcinogenesis, Mutagenesis, Impairment of Fertility**—Long-term animal studies have not been conducted to evaluate the carcinogenic potential of loteprednol etabonate. Loteprednol etabonate was not genotoxic in vitro in the Ames test, the mouse lymphoma thymidine kinase (tk) assay, in a chromosome aberration test in human lymphocytes, or in vivo in the single dose mouse micronucleus assay. Treatment of male and female rats with 25 mg/kg/day of loteprednol etabonate (174 times the RHOD based on body surface area, assuming 100% absorption) prior to and during mating caused pre-implantation loss and decreased the number of live fetuses/live births. The NOAEL for fertility in rats was 5 mg/kg/day (34 times the RHOD).

For a copy of the Full Prescribing Information, please visit [www.eysuvis-ecp.com/](http://www.eysuvis-ecp.com/)

Manufactured for:  
Kala Pharmaceuticals, Inc.  
Watertown, MA 02472

Marks designated by <sup>™</sup> or <sup>®</sup> are owned by Kala Pharmaceuticals, Inc.  
Patented. [WWW.KALARX.COM/PATENTS](http://WWW.KALARX.COM/PATENTS)

© 2020 Kala Pharmaceuticals, Inc. All rights reserved. US-EYS-2300027

PI Version Date: 10/2020

  
**EYSUVIS**  
(loteprednol etabonate  
ophthalmic suspension) 0.25%

## 6. How long does the effect of SLT last?

SLT treatment efficacy is known to diminish with time. Survival analysis from past studies indicates that the time for 50% of eyes to fail after SLT treatment is approximately two years.<sup>5,17</sup> The LiGHT trial data from 2019 showed 74.2% of patients were drop-free three years after primary SLT treatment.<sup>3</sup> The six-year LiGHT trial data released in September 2022 showed 69.8% of SLT patients remained at or below target IOP after six years (they were drop-free). This does not necessarily mean one SLT held the IOP below target for that time period. Of those patients that were drop-free, 62.7% needed only one SLT, 30.9% needed two SLTs and 5.9% needed three SLTs to stay below target over the six-year period.<sup>4</sup>

If you do the math, there is approximately a 44% chance a single SLT will last six years without the need for further treatment based on the 2022 LiGHT data.<sup>4</sup>

It is recommended that patients be educated that the likely effectiveness of the procedure lasts somewhere between two to six years, with the option available to repeat the SLT when the IOP elevates or progression is shown.

**Bottom line:** *Clinically speaking, SLT has been shown to last between two and six years. Some are longer, some are shorter, depending on number of degrees treated, pre-laser IOP, number of meds the patient is on and general patient idiosyncrasies.*

*In general, length of efficacy can be hard to predict from patient to patient. The LiGHT trial demonstrated that 44% of first-line SLT patients remained below target IOP without any other intervention (drop-free) from a single SLT at the six-year mark.*

## 7. Is SLT repeatable?

Since SLT causes minimal structural damage to the TM, retreatment is a viable option in patients that need further IOP reduction. Although this benefit of SLT was theoretical for many years, the body of evidence now supports the efficacy of repeat SLT.<sup>18</sup> It achieves

a similar absolute level of IOP control with mean percent IOP reduction following repeat SLT perhaps slightly lower than the initial treatment. This is possibly related to the retreatment being done at an overall lower level of IOP.

For example, an initial SLT was done at a baseline IOP of 24mm Hg with a 30% IOP reduction to achieve a post-SLT treatment IOP of 17mm Hg. The IOP elevated in the years following the initial SLT to 22mm Hg. Repeat SLT achieved a 25% IOP reduction, taking the IOP back to 17mm Hg. The repeat SLT achieved the same IOP endpoint with a slightly lower percentage of IOP reduction.

One study demonstrated that repeat SLT can maintain IOP at or below target IOP in medication-naïve POAG and ocular hypertension eyes requiring retreatment with at least an equivalent duration of effect to the initial laser.<sup>19</sup>

Overall, repeat SLT appears to be comparable to initial SLT in regard to efficacy, duration of effect and rate of complications.

**Bottom line:** *SLT is very repeatable, should be repeated and perhaps should be repeated more often. On that note...*

## 8. Should SLT be repeated more often? What about annually?

Considering the mechanism of action of how SLT works, via inflammatory and biologic mechanisms with macrophages and other inflammatory cells “cleaning up” the cellular debris in the TM, it does make sense that SLT done more often could result in enhanced outflow. Why not have the inflammatory cells clean out the drain of the eye (the TM) more often?

With that in mind, researchers from Italy studied the effects of low-energy SLT (half the energy, half the laser pulses, done annually) to observe how that treatment protocol compared to the standard SLT protocol (0.8mJ to 1.0mJ, 80

to 120 laser pulses, repeated as needed often two to six years later) and to traditional ALT.

They found 10-year medication-free rates to be:<sup>20</sup>

- ALT: 22.6%
- Standard SLT: 25.0%
- Low-energy annual SLT: 58.3%

They also found 10-year median times to medication treatment to be:<sup>20</sup>

- ALT: 2.8 years
- Standard SLT: 3.2 years
- Low-energy annual SLT: 6.2 years

The results clearly pointed towards a 10-year benefit for the low-energy, annual SLT arm.

The ongoing Clarifying the Optimal Application of SLT Therapy (COAST) trial will be a major indicator of whether lower energy annual SLT will play a big role in our treatment protocols going forward.<sup>21</sup> Currently, it appears that the published evidence is trending towards low-energy (half the energy, half the shots), annual SLT. The COAST trial, if it has results similar to the Italy study, likely will guide us towards low-energy, annual SLT just the same way that the LiGHT trial guided us towards SLT as a primary treatment option.



**Fig. 3.** Very rare angle bleed seen during an SLT. Look just below the aiming beam to see the blood.

### Is There a More “Direct” Approach?

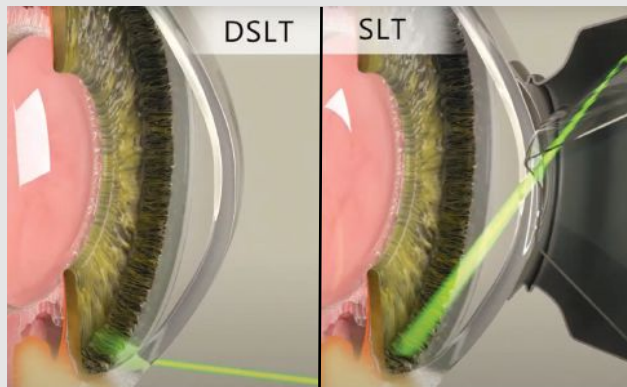
Laser trabeculoplasty done in the angle with a gonioscopy laser lens (Latina or Rapid SLT lens) with laser pulses applied directly to the TM is the traditional and current approach. Clinically, it typically takes two to five minutes to perform a 360° SLT depending on experience level, laser lens used and patient factors. As technology has advanced, other approaches have been invented and are currently being studied. An automated device called direct SLT (DSLST) using a transscleral approach is currently approved in Europe and is being studied in the US. What is this new technology and how does it work?

“Automated” means the laser automatically applies the 120 laser pulses without the doctor having to hit the button that many times. Iris tracking allows the laser to align precisely where it wants to fire the laser pulses, which is right on the limbus. With the current DSLST device approved in Europe and awaiting

FDA 510(K) clearance in the US (the Belkin Eagle DSLST), treatment is an efficient application of laser energy (Figures 4 and 5). Once the button is pressed, the laser automatically fires 120 laser pulses, as long as the auto-alignment and tracking is providing feedback that the laser is aligned on the limbus. If the patient moves their eye during the treatment, the auto-tracking will detect that and the laser will stop firing.

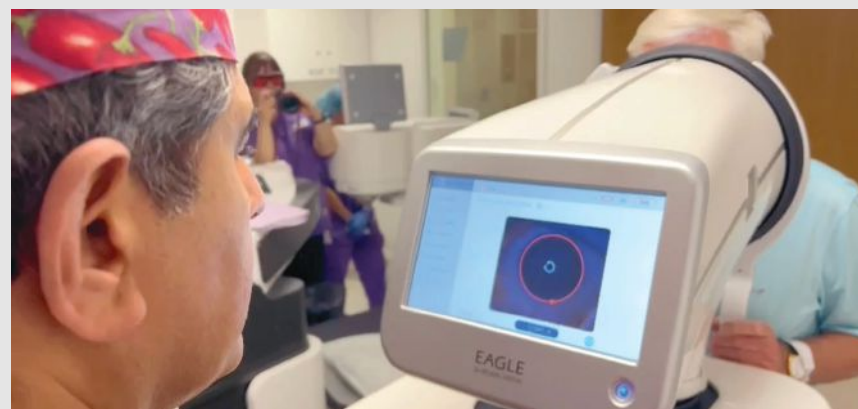The “direct” aspect means that the laser pulses are applied directly to the surface of the eye and not into the angle. No laser lens is required to perform the procedure. The laser pulses are applied directly to the limbal area, which anatomically sits just superficial to the angle and TM of the eye. The theory behind the procedure is that the laser pulses are still applied fairly close to the angle and TM, and therefore the inflammatory/biologic reaction that occurs and cleans up the drain in the TM will still occur because the laser pulses are applied close to the area of the drain.

Current studies are showing a 15% to 30% IOP reduction, depending on energy level used, for the DSLST.<sup>28</sup> Though it hasn't yet reached US shores, it's conceivable that DSLST may revolutionize how SLT therapy is delivered here, as this more automated procedure could encourage greater adoption than the conventional gonio-based technique.



**Fig. 4. DSLST obviates the need for a gonio lens by delivering laser energy directly through the limbal area.**

Photo: Belkin Vision



**Fig. 5. The surgeon uses a screen interface for visualization rather than a gonio lens.**

Photo: Belkin Vision, Sheraz Daya, MD

*Bottom line: The published literature, and early clinical experience, appears to be trending towards doing a lower energy, annual SLT. Half the energy (0.4mJ to 0.5mJ), half the shots (40 to 60 laser pulses), done annually irrespective of IOP, may be the future SLT protocol. While not clinical standard of care at this point, the COAST trial will go a long way towards clarifying that.*

## 9. Is 180° or 360° of treatment recommended?

How many angle degrees to treat depends on clinician preference and the type of glaucoma being managed. The early days of SLT generally recommended 180° of treatment, consistent with prior ALT protocols. Due to the mechanism of action, minimal structural damage in the angle, lower side effect profile and repeatability, it has become generally accepted to perform 360° of SLT treatment for POAG, ocular hypertension and NTG.<sup>3,22-23</sup>

Conversely, some studies indicate that fewer degrees of treatment may be as effective as a full 360° treatment while reducing the incidence and magnitude of postoperative IOP elevation.<sup>24-25</sup> Heavier amounts of pigment in the angle can potentially cause an overproduction of inflammation, leading to higher rates of potential adverse events. Therefore, the general consensus is to perform 180° or less in patients with heavy pigmentation in the TM, pigmentary glaucoma or pseudoexfoliative glaucoma.<sup>11</sup>

*Bottom line: 360° (Figure 1) is largely the standard for POAG, ocular hypertension and low-tension glaucoma. 180° or less is recommended for heavily pigmented angles.*

## 10. What are the potential complications to look out for and how do I manage them?

Complications can arise with any treatment, laser or otherwise, and should be dealt with appropriately. SLT is an extremely safe laser procedure, with IOP spike and inflammation being the two most encountered complications. Inflammation is expected due to the



mechanism of action of how the SLT laser works.

If too much inflammation, redness or ocular soreness is encountered, it can usually be treated with a topical NSAID or topical steroid for two to four days following the procedure. IOP spikes following laser procedures usually start one to five hours following the laser procedure, and often dissipate within 24 to 72 hours even without treatment.

A transient IOP increase of 5mm Hg or more has been reported in 0% to 28% of eyes.<sup>11</sup> More specifically, a study reported transient elevated IOP after SLT of 4.5%, which seems consistent with clinical experience.<sup>26</sup> A systematic review found that prophylactic in-office treatment with IOP-lowering medication reduced the incidence of transient IOP elevation.<sup>27</sup> Heavily pigmented TMs (*Figure 2*) may lead to potentially higher rates of IOP spike, so caution should be taken (less shots, lower energy) when performing an SLT on a heavily pigmented angle.

Blurred vision, redness, peripheral anterior synechiae, bleeding/hyphema (*Figure 3*), ocular soreness, cystoid macular edema, corneal edema and endothelial cell changes have all been rarely reported in the literature and seen clinically.

*Bottom line: Complications can arise yet are rare and very treatable, with the most common being an IOP spike.*<sup>27</sup>

### **Bonus: When can I take the patient off of their glaucoma medications after SLT?**

The answer to this very important question is—like many answers in glaucoma—“It depends!” There are two big, broad reasons why SLT is done:

1. To replace a current topical medication, or
2. To prevent the next topical medication (or first medication).

**Scenario #1.** If a patient is struggling with compliance or adverse effects from glaucoma eye drops such as redness, then the SLT may be done to replace the current medication they are on that is giving them trouble (side effects

or compliance). Remember, it takes approximately six weeks to see the full effect of SLT. Depending on the stage of glaucoma, the troublesome medication could be stopped before the SLT is done (if the glaucoma is relatively mild), or six weeks after the SLT is done and has hopefully kicked in (if the glaucoma is more advanced).

**Scenario #2.** If a patient is progressing (VF or OCT) on one or two medications, or the IOP is not meeting target on one or two meds, then the SLT may be used as an add-on therapy to prevent the patient from going on a second or third drug. In that case, no medication would be stopped, since the SLT is being done to prevent the next med.

*Bottom line: It depends on whether you are doing the SLT to replace a current medication or prevent the next (or first) medication.*

### **Takeaways**

Optometrists are on the front line of glaucoma treatment and placing patients on their initial glaucoma therapy. There are two clear first-line treatment options: SLT and eye drops. More and more ODs are having the option to perform SLT on their patients, either first- or second-line. Having lasers in practice is a great opportunity, and being confident enough to answer the big questions regarding SLT will help demonstrate to patients your knowledge and expertise. ■

1. Latina M, Sibayan S, Shin D, et al. Q-switched 532nm Nd:YAG laser trabeculoplasty (selective laser trabeculoplasty) a multicenter, pilot, clinical study. *Ophthalmology*. 1998;105(11):2082-90.

2. Katz LJ, Steinmann WC, Kabir A, et al; SLT/Med Study Group. Selective laser trabeculoplasty vs. medical therapy as initial treatment of glaucoma: a prospective, randomized trial. *J Glaucoma*. 2012;21(7):460-8.

3. Gazzard G, Konstantakopoulou E, Garway-Heath D, et al. Selective laser trabeculoplasty vs. eye drops for first-line treatment of ocular hypertension and glaucoma (LiGHT): a multicenter randomized controlled trial. *Lancet*. 2019;393(10180):1505-16.

4. Gazzard G, Konstantakopoulou E, Garway-Heath D, et al. Laser in Glaucoma and Ocular Hypertension (LiGHT) Trial: six-year results of primary selective laser trabeculoplasty vs. eye drops for the treatment of glaucoma and ocular hypertension. *Ophthalmology*. 2023;130(2):139-51

5. Weinand FS, Althen F. Long-term clinical results of selective laser trabeculoplasty in the treatment of primary open-angle glaucoma. *Eur J Ophthalmol*. 2006;16(1):100-4.

6. Martow E, Hutnik CM, Mao A. SLT and adjunctive medical therapy: a prediction rule analysis. *J Glaucoma*. 2011;20(4):266-70.

7. Alvarado J, Iguchi R, et al. From the bedside to the bench and back again: predicting and improving the outcomes of SLT glaucoma therapy. *Trans Am Ophthalmol Soc*. 2009;107:167-81.

8. Ong K, Ong L, Franzco L. Corneal endothelial changes after selective laser trabeculoplasty. *Clin Exp Ophthalmol*. 2013;41(6):537-40.

9. Liu D, Chen D, Tan Q, et al. Outcomes of selective laser trabeculoplasty in young patients with primary open angle glaucoma and ocular hypertension. *J Ophthalmol*. 2020;2020:5742832.

10. Garg A, Vickerstaff V, Nathwani N, et al. Efficacy of repeat selective laser trabeculoplasty in medication-naive open-angle glaucoma and ocular hypertension during the LiGHT Trial. *Ophthalmology*. 2020;127(4):467-76.

11. Kennedy J, SooHoo J, Kahook M, Seibold L. Selective laser trabeculoplasty: an update. *Asia Pac J Ophthalmol (Phila)*. 2016;5(1):63-9.

12. Hodge WG, Damji KF, Rock W, et al. Baseline IOP predicts selective laser trabeculoplasty success at one-year post-treatment: results from a randomized clinical trial. *Br J Ophthalmol*. 2005;89(9):1157-60.

13. Lee JW, Liu CC, Chan JC, Lai JSM. Predictors of success in selective laser trabeculoplasty for Chinese open-angle glaucoma. *J Glaucoma*. 2014;23(5):321-5.

14. Woo DM, Healey PR, Graham SL, Goldberg I. Intraocular pressure-lowering medications and long-term outcomes of selective laser trabeculoplasty. *Clin Exp Ophthalmol*. 2015;43(4):320-7.

15. Wasyluk JT, Piekarniak-Wozniak A, Grabska-Liberek I. The hypotensive effect of selective laser trabeculoplasty depending on iridocorneal angle pigmentation in primary open angle glaucoma patients. *Arch Med Sci*. 2014;10(2):306-8.

16. Alon S. Selective laser trabeculoplasty: a clinical review. *J Current Glau Prac*. 2013;7(2):58-65.

17. Bovell AM, Damji KF, Hodge WG, et al. Long term effects on the lowering of intraocular pressure: selective laser or argon laser trabeculoplasty? *Can J Ophthalmol*. 2011;46(5):408-13.

18. Guo Y, Ioannidou A, Jute P. Selective laser trabeculoplasty: a review of repeatability. *Ann Eye Sci*. 2019;4:20.

19. Garg A, Vickerstaff V, Nathwani N, et al. Efficacy of repeat selective laser trabeculoplasty in medication-naive open-angle glaucoma and ocular hypertension during the LiGHT Trial. *Ophthalmology* 2020;127:467-76.

20. Gandolfi S. Low power selective laser trabeculoplasty (SLT) repeated yearly as primary treatment in open angle glaucoma(s): long term comparison with conventional SLT and ALT. ARVO 2018 annual meeting.

21. Realini T, Gazzard G, Latina M, Kass M. Low-energy selective laser trabeculoplasty repeated annually: rationale for the COAST Trial. *J Glaucoma*. 2021;30(7):545-51.

22. Prasad N, Murthy S, Dagianis JJ, Latina MA. A comparison of the intervisit intraocular pressure fluctuation after 180 and 360 degrees of selective laser trabeculoplasty (SLT) as a primary therapy in primary open angle glaucoma and ocular hypertension. *J Glaucoma*. 2009;18(2):157-60.

23. Shibata M, Sugiyama T, Ishida O, et al. Clinical results of selective laser trabeculoplasty in open-angle glaucoma in Japanese eyes: comparison of 180 degree with 360 degree SLT. *J Glaucoma*. 2012;21(1):17-21.

24. Woo DM, Healey PR, Graham SL, Goldberg I. Intraocular pressure-lowering medications and long-term outcomes of selective laser trabeculoplasty. *Clin Experiment Ophthalmol*. 2015;43(4):320-7.

25. McAlinden C. Selective laser trabeculoplasty (SLT) vs. other treatment modalities for glaucoma: systematic review. *Eye (Lond)*. 2014;28(3):249-58.

26. Song J. Complications of selective laser trabeculoplasty: a review. *Clin Ophthalmol*. 2016;10:137-43.

27. Wong MO, Lee JW, Choy BN, et al. Systematic review and meta-analysis on the efficacy of selective laser trabeculoplasty in open-angle glaucoma. *Surv Ophthalmol*. 2015;60(1):36-50.

28. Goldenfeld M, Belkin M, Dobkin-Bekman M, et al. Automated direct selective laser trabeculoplasty: first prospective clinical trial. *Trans Vis Sci Technol*. 2021;10(3):5.

**tyrvaya**<sup>®</sup>  
(varenicline solution)  
nasal spray 0.03 mg

FOR THE SIGNS  
& SYMPTOMS OF  
DRY EYE DISEASE

SHE'S LOOKING TO YOU FOR A  
DIFFERENT APPROACH WHEN  
ARTIFICIAL TEARS ARE NOT ENOUGH.<sup>1</sup>

BEFORE ANOTHER DROP

# ACTIVATE REAL TEARS

WITH THE FIRST AND ONLY NASAL  
SPRAY FOR DRY EYE<sup>2</sup>



## Tyrvaya<sup>®</sup> is not another drop

It's an **ocular surface-sparing** nasal spray.<sup>2</sup>



## Activates real, basal tears

Tyrvaya<sup>®</sup> is believed to work by activating the trigeminal parasympathetic pathway resulting in **basal tear production**.<sup>2\*</sup>



## Real tears, real fast

In 2 clinical trials with **mild, moderate, and severe** dry eye disease patients, Tyrvaya increased tear production from baseline by **≥10 mm in Schirmer's Test Score (STS) in nearly 50% of patients at week 4**, with increased tears seen as early as the first dose and over 12 weeks.<sup>2-8†</sup>

SEE WHAT  
TYRVAYA  
CAN DO



\*The exact mechanism of action is unknown.

†Tyrvaya was evaluated across 3 randomized, vehicle-controlled, double-masked studies in which adults aged ≥22 years diagnosed with dry eye disease received 1 spray of either active drug or vehicle in each nostril twice daily. Primary endpoint: % of patients with mean change from baseline in STS of ≥10 mm at week 4 in ONSET-1: 52% with Tyrvaya (n=48) vs 14% with vehicle (n=43) and in ONSET-2: 47% with Tyrvaya (n=260) vs 28% with vehicle (n=252). Onset of action: mean change from baseline in STS ~5 minutes after first dose (not a prespecified endpoint) in ONSET-1 was 17.2 mm with Tyrvaya (n=48) vs 4.0 mm with vehicle (n=43) and in ONSET-2 was 16.5 mm with Tyrvaya (n=260) vs 6.9 mm with vehicle (n=251). Observed data. On Day 1 in clinical studies, a baseline anesthetized Schirmer's test was performed. Tyrvaya was then administered concurrently with Schirmer's test. Schirmer's test results were measured at ~5 minutes. Mean change from baseline in STS at week 12 in the MYSTIC study was 10.8 mm with Tyrvaya vs 6.0 mm with vehicle. Limitations: Ex-US, single-center study. All subjects were Hispanic or Latino. Tyrvaya group mean baseline STS 5.5 mm (n=41); vehicle group mean baseline STS 5.3 mm (n=41). All randomized and treated patients were included in the analysis and missing data were imputed using last-available data.<sup>2-8</sup>  
**See references on next page.**

## Indication

Tyrvaya<sup>®</sup> (varenicline solution) nasal spray is indicated for the treatment of the signs and symptoms of dry eye disease.

## Important Safety Information

The most common adverse reaction reported in 82% of patients was sneezing. Events that were reported in 5-16% of patients were cough, throat irritation, and instillation-site (nose) irritation.

**Please see Brief Summary of Prescribing Information on the next page and the full Prescribing Information at [Tyrvaya-pro.com](http://Tyrvaya-pro.com).**

**BRIEF SUMMARY:** Consult the full Prescribing Information for complete product information available at [www.tyrvaya-pro.com](http://www.tyrvaya-pro.com).

## **INDICATIONS AND USAGE**

TYRVAYA<sup>®</sup> (varenicline solution) nasal spray is a cholinergic agonist indicated for the treatment of the signs and symptoms of dry eye disease.

## **ADVERSE REACTIONS**

**Clinical Trials Experience:** Because clinical trials are conducted under widely varying conditions, adverse reaction rates observed in the clinical trials of a drug cannot be directly compared to rates in the clinical trials of another drug and may not reflect the rates observed in practice.

In three clinical trials of dry eye disease conducted with varenicline solution nasal spray, 349 patients received at least 1 dose of TYRVAYA. The majority of patients had 31 days of treatment exposure, with a maximum exposure of 105 days.

The most common adverse reactions reported in 82% of TYRVAYA treated patients was sneezing. Other common adverse reactions that were reported in >5% of patients include cough (16%), throat irritation (13%), and instillation-site (nose) irritation (8%).

## **USE IN SPECIFIC POPULATIONS**

**Pregnancy:** Risk Summary: There are no available data on TYRVAYA use in pregnant women to inform any drug associated risks. In animal reproduction studies, varenicline did not produce malformations at clinically relevant doses.

All pregnancies have a risk of birth defect, loss, or other adverse outcomes. In the US general population, the estimated background risk of

major birth defects and miscarriage in clinically recognized pregnancies is 2% to 4% and 15% to 20%, respectively.

Data: *Animal Data:* Pregnant rats and rabbits received varenicline succinate during organogenesis at oral doses up to 15 and 30 mg/kg/day, respectively. While no fetal structural abnormalities occurred in either species, maternal toxicity, characterized by reduced body weight gain, and reduced fetal weights occurred in rabbits at the highest dose (4864 times the MRHD on a mg/m<sup>2</sup> basis).

In a pre- and postnatal development study, pregnant rats received up to 15 mg/kg/day of oral varenicline succinate from organogenesis through lactation. Maternal toxicity, characterized by a decrease in body weight gain, was observed at 15 mg/kg/day (1216 times the MRHD on a mg/m<sup>2</sup> basis). Decreased fertility and increased auditory startle response occurred in offspring at the highest maternal dose of 15 mg/kg/day.

**Lactation:** Risk summary: There are no data on the presence of varenicline in human milk, the effects on the breastfed infant, or the effects on milk production. In animal studies varenicline was present in milk of lactating rats. However, due to species-specific differences in lactation physiology, animal data may not reliably predict drug levels in human milk.

The lack of clinical data during lactation precludes a clear determination of the risk of TYRVAYA to an infant during lactation; however, the developmental and health benefits of breastfeeding should be considered along with the mother's clinical need for TYRVAYA and any potential adverse effects on the breastfed child from TYRVAYA.

**Pediatric Use:** Safety and efficacy of TYRVAYA in pediatric patients have not been established.

**Geriatric Use:** No overall differences in safety or effectiveness have been observed between elderly and younger adult patients.

**References:** **1.** Jones L, Downie LE, Korb D, et al. *Ocul Surf.* 2017;15(3):575-628. **2.** Tyrvaya. Prescribing Information. Oyster Point Pharma; 2021. **3.** Oyster Point Pharma. Data on file. OPP-002 (ONSET-1) Clinical Study Report. August 4, 2019. **4.** Oyster Point Pharma. Data on file. OPP-101 (ONSET-2) Interim Clinical Study Report. October 13, 2020. **5.** Quiroz-Mercado H, Hernandez-Quintela E, Chiu KH, Henry E, Nau JA. *Ocul Surf.* 2022;24:15-21. **6.** Wirta D, Torkildsen GL, Boehmer B, et al. *Cornea.* 2022;4(10):1207-1216. **7.** Wirta D, Vollmer P, Paauw J, et al. *Ophthalmology.* 2021;0(0):379-387. **8.** Oyster Point Pharma. Data on file. OPP-004 (MYSTIC) Clinical Study Report. March 19, 2020.

Manufactured for Oyster Point Pharma, Inc. 202 Carnegie Center, Suite 106, Princeton NJ 08540. For more information, visit [www.tyrvaya-pro.com](http://www.tyrvaya-pro.com). To report an adverse event, contact 1-877-EYE-0123.

© 2023 Viatrix Inc. and/or its affiliates. All rights reserved. VIATRIS and the Viatrix Logo are trademarks of Mylan Inc., a Viatrix Company. Oyster Point<sup>®</sup>, Tyrvaya<sup>®</sup>, and the Tyrvaya logo are trademarks of Oyster Point Pharma, Inc., a Viatrix company, in the United States and certain jurisdictions. OP-TYR-002308 7/23

# EQUIPPING YOUR OFFICE FOR MINOR SURGICAL PROCEDURES

Successful implementation begins by ensuring you have the necessary tools at your disposal.

BY CATLIN NALLEY  
CONTRIBUTING EDITOR

As scope expansion efforts continue across the country, the number of optometrists who can practice to the full extent of their expertise and ability continues to grow. Therefore, ODs must be prepared to incorporate these procedures into clinical practice.

“It is important for every doctor of optometry to consider the thousands of person hours it has taken to move optometry forward,” notes Luke Brog, OD, who practices in Wyoming. “Many are aware because they have been on the front lines. It is in the best interest of your patients and our profession to have as many doctors offering these services in their offices as possible.” Dr. Brog urges ODs, “If your state has already gained these privileges, find a procedure and start offering it. If you don’t have them yet, work with your state board and state legislators to help move the legal efforts forward.”

Once an optometrist has decided they want to perform minor surgical procedures in their practice, they must take the necessary steps to set up themselves—and their patients—for success. That begins by equipping your office with the necessary tools.



Photo: Nathan Lighthizer, OD

**Fig. 1. Example of a radiofrequency unit (Soniquence) that can be used for minor optometric procedures such as benign lesion removal as well as for aesthetic purposes like the reduction of wrinkles and fine lines.**

Below, we will delve into what you need for various procedures—including incisions, injections, selective laser trabeculoplasty (SLT), YAG capsulotomy and laser peripheral iridotomy (LPI)—as well as discuss the considerations behind these purchases. Seasoned ODs share their own experiences and offer insights on specific equipment needs,

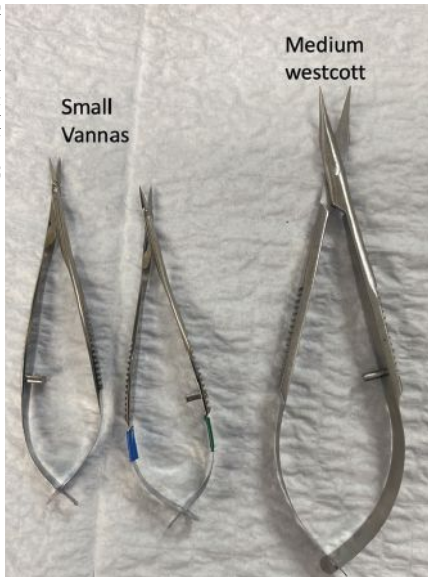
including non-negotiables and often overlooked resources, touch on the pros and cons of various options and discuss navigating big-ticket purchases.

## Incisions and Injections

When performing minor surgical procedures, such as intralesional injections, benign lesion removal and biopsies, there are a variety of tools required for success, some of which are must-haves while others are helpful but not absolute necessities.

“The biggest ticket item is the radiofrequency device (*Figure 1*),” notes Nathan Lighthizer, OD, associate dean at NSU Oklahoma College of Optometry. “However, while a laser is required for laser procedures, a radiofrequency device, like an Ellman or Soniquence unit, even though it is often the preferred device, is not an absolute necessity for lesion removal. There are many different ways to remove lesions, including surgical scissors and scalpels.”

While Dr. Lighthizer has found having a radiofrequency device to be very beneficial and recommends that optometrists consider it, he recognizes that cost is a factor. These devices, he notes, typically run between \$10,000 and \$20,000 and can get much higher in cost if the aesthetics components of the radiofrequency device are added in.



**Fig. 2. Different varieties and sizes of surgical scissors that can be used to perform in-office eyelid procedures.**

There are a number of electrosurgical devices available, according to Dr. Brog, who notes that the level of investment really depends on the doctor's preference. "For all practical purposes, you can purchase a basic unit and it will do everything you need it to in your office," he advises.

Dr. Brog, who opted to purchase a used Ellman unit, says, "If you get them used, make sure that you can get the electrodes for the equipment you purchase. Some companies have discontinued certain models and the electrodes are no longer available." He cautions, "You will also need a smoke evacuator unless you want your entire office to smell from the procedure."

Whether or not they decide to invest in a radiofrequency device, optometrists who want to perform incisions and injections should have the following tools on-hand:

- Surgical scissors (Westcott, Vannas, etc.) in varying sizes (*Figure 2*)
- #11 blade scalpel (either as single-use disposable sterile scalpels that cost about \$0.70 a piece or a stainless steel reusable blade handle for approximately \$10 with disposable #11 surgical blades at \$0.05 a piece)
- #15c blade scalpel

- Featherblade scalpel
- Forceps (both toothed and non-toothed)

Other must-haves include a 2.5mm or 3.0mm trephine blade, 2.0mm-5.0mm punch biopsies, needle drivers and eyelid speculums, according to Dr. Lighthizer. If an optometrist plans to offer chalazion removals, they will need chalazion clamps (small- and medium-sized; *Figure 3*) and chalazion curettes (serrated and non-serrated).

Chris Wroten, OD, who practices in Louisiana, recommends small, curved-tip Vannas scissors. "They are great for cutting the stalks of small lid lesions, trimming lashes and cutting sutures prior to removal," he says. Dr. Wroten

adds that while single-toothed tissue forceps are sometimes overlooked, they can be very useful when performing a lesion removal, as tissue often gets wet and regular forceps will not adequately grasp.

When considering where to get the various instruments needed for in-office incisions and injections, keep in mind that there are surgical sets available that have all the recommended instruments for in-office procedures, including forceps, scissors, scalpels, needle drivers and more (*Figure 4*).

For incisions and injections, Dr. Brog repurposes job trays as surgical trays and prepares them ahead of time. "The trays include povidone-iodine swab

### What You Need to Perform Eyelid Incisions and Injections

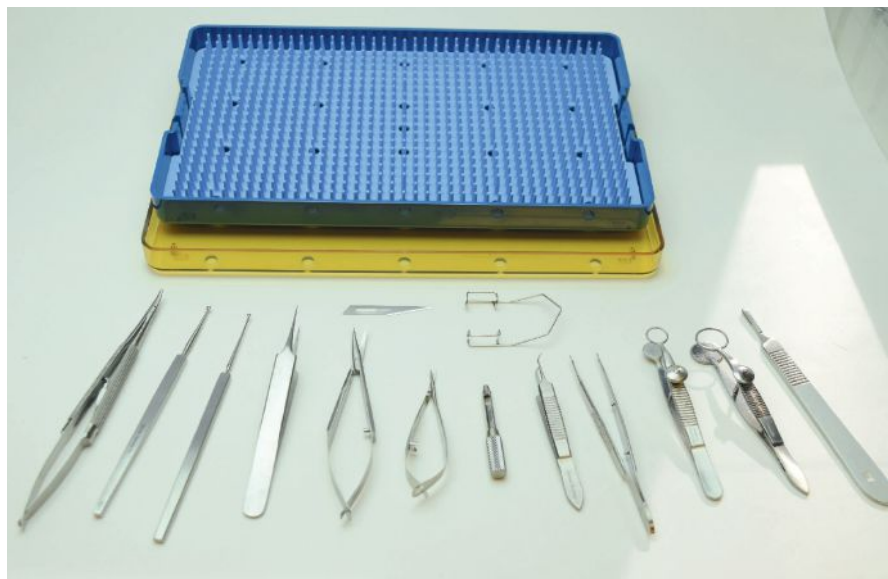- Signed informed consent forms and procedure checklist
- Postoperative instructions for patients
- Blood pressure cuff
- Radiofrequency device, with electrodes (optional)
- Surgical scissors of different sizes, including some with straight and curved tips
- Various scalpels (e.g., #11, #15c and featherblade)
- Forceps (both toothed and non-toothed)
- Chalazion clamps of different sizes, either spring-loaded or swivel-adjustable
- Curettes of different sizes
- Needles and syringes of varying sizes
- Sharps container
- Biohazard specimen bags
- Personal protective equipment (e.g., gloves, masks, shields)
- Magnification tool
- Povidone-iodine swab sticks and/or alcohol swabs
- Topical lidocaine gel (usually 4%)
- Lidocaine and/or lidocaine with epinephrine and sodium bicarbonate (8.4% solution) as a buffering agent to be mixed 9:1 (lidocaine % is usually 0.5%, 1% or 2%)
- Injectable Kenalog-40 if you are going to inject chalazia
- Ophthalmic antibiotic (or steroid-antibiotic) ointment to apply after procedure
- Sterile cotton-tipped applicators for moistening and rubbing tissue during procedures (also used for application of betadine and antibiotic ointment)
- Sterile metal procedure trays to hold tools
- Disposable cautery unit (can help staunch bleeding) (optional)
- Small Band-Aids and/or sterile gauze pads with gauze tape
- Epi-pen (epinephrine, Mylan) in case of anaphylaxis
- Smelling salts in case of syncope (optional)
- Tissue specimen container with formaldehyde to send lesions for pathology report (labs usually supply this free-of-charge upon request) with accompanying forms to fill out
- Camera for taking before and after pictures for your chart notes
- Small steam autoclave or chemical disinfection/sterilization unit

sticks or alcohol swabs for preparing the lesion, cotton swabs, gauze pads to clean off the electrode during procedure, electrodes of various types (loop, diamond, ball and broad needle), triple antibiotic ointment, biohazard specimen bags and small bandages,” he says. “We also have a number of things for infiltration anesthesia, including needles and syringes, prepared on the trays.”

Another important component is personal protective equipment, including gloves and masks. Staff should be trained on how to properly handle needles and biohazard material, says Dr. Brog. “It has been proven that as you remove lesions with electrosurgery, there are particles in the smoke. Some that have been isolated are HPV and HIV. You need to protect yourself and your staff,” he cautions.

Biopsies are another type of procedure optometrists must be equipped to handle. While not every lesion requires a biopsy, if there are concerns around malignancy, ODs must be prepared for when these cases arise. “You should contact your local pathology lab and get the necessary biopsy kits,” says Dr. Lighthizer. “If you are removing eyelid lesions, you have to have the ability to biopsy.”

Other inexpensive—yet important—items are needles and syringes, both which have a wide selection to choose from. In addition to product availability, deciding which to purchase will



**Fig. 4.** Example of an in-office surgical instrument set that has all the recommended tools needed to successfully perform simple procedures (scissors, scalpels, forceps). This may be a wise investment for ODs who are just beginning the process of equipping their practice for these services.

depend on your personal preferences and the specific needs of your patients. The most common needles are 18-, 25- and 30-gauge, according to Dr. Lighthizer, who notes that while some optometrists may opt for different sizes, these three will serve the majority of your needs.

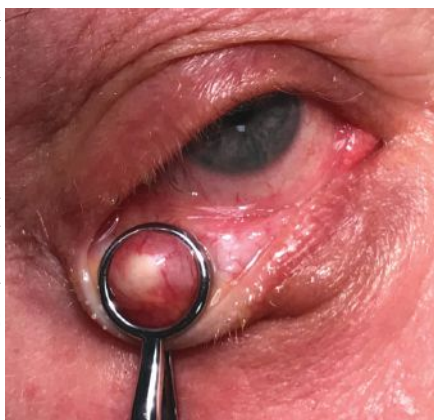“The eyelid tissue is very thin, so it is important to use small-gauge needles,” says Dr. Brog, adding that he would opt for the 30-gauge needle to start. “The length is also important; I prefer one-half inch,” he says. “You could easily use longer ones if you would like.” To ensure the needle is sharp and has an easier time penetrating the tissue, Dr. Brog says he likes “to draw the material up with a 25-gauge needle and then change it before I infiltrate.” He notes that you can certainly use a larger needle than a 25-gauge to draw faster; Dr. Brog’s rationale for choosing this size is that it’s the same as he uses to inject chalazia, so it’s already in his cupboard. Regarding the syringe size, he says that he uses a 1mL because “it is small and easy to use around the eyes.”

Magnification is another equipment consideration to keep in mind. As with most equipment, optometrists have a selection of high-cost and

more economical options, including surgical microscopes, surgical loupes and headset magnifiers. “While not a requirement, magnification tools are very important and they don’t have to come with a high price tag,” says Dr. Lighthizer, pointing out that there are options available for as little as \$30.

There are several other miscellaneous items optometrists should have available when performing incisions and injections at their practice. Some of these include Mayo stands with sterile drapes, a sharps container for used needles and other sharp objects, a camera to take photos pre- and post-procedure, biohazard service, small steam autoclave or chemical disinfection/sterilization unit for reusable surgical instruments, gauze, cotton tip applicators, alcohol wipes, sterile saline, Wek-Cel sponges, antibiotic ointment and a scrub pad to clean electrodes (optional).

Agents to have on-hand include lidocaine with and without epinephrine, betadine, sodium bicarbonate as a buffering agent and Kenalog-40 (triamcinolone acetonide, Bristol-Myers Squibb) for injecting chalazia (see, “*What You Need to Perform Eyelid Incisions and Injections*” for a full list of items required for these procedures).



**Fig. 3.** Clamps are necessary for chalazion/lesion removal to prevent the mass from moving during the procedure.

Photo: Nathan Lighthizer, OD

Photo: Jackie Burress, OD, and Rodney Bendure, OD

## Laser Procedures

The price tag of offering laser procedures in your practice certainly exceeds that of incisions and injections. There are a variety of tools optometrists need to have in their clinical practice to successfully perform laser procedures. This starts with a significant investment: the laser itself. Depending on the type (YAG, SLT or YAG/SLT combination laser) and brand, the price can range from \$20,000 to \$55,000, according to Dr. Lighthizer.

While Dr. Brog acknowledges that lasers are an investment, he believes it is worth the high price tag given the impact for not only patients, but also optometric practice as a whole. “This increased scope of practice has been hard fought for and the more optometrists who are doing these procedures, the better it is for our patients and our profession,” he says.

“Most of the referring ophthalmologists I work with are very busy and it is hard to get patients an appointment with them in a timely manner. By offering these services, my patients can have their eye problems resolved

### What You Need to Perform Laser Procedures (YAG cap, SLT, LPI)

- Signed informed consent forms and procedure checklist
- Postoperative instructions for patients
- Blood pressure cuff
- Laser (i.e., YAG, SLT or YAG/SLT combination)
- SLT laser lens (i.e., Latina, Ocular Instruments; Rapid SLT, Volk)
- YAG laser iridotomy lens (e.g., Abraham, Ocular Instruments)
- YAG laser capsulotomy lens (e.g., Abraham)
- Topical ophthalmic anesthetic (e.g., tetracaine, proparacaine)
- Topical brimonidine for use pre- and post-procedure
- Tropicamide or phenylephrine for dilation during YAG capsulotomy
- Pilocarpine for pupil constriction during LPI
- Cushioning solution for use with laser lenses (e.g., GenTeal Gel Alcon; Celluvisc, Allergan; Goniosol, Novartis; Goniovisc, Hub Pharmaceuticals)
- Tool to measure pre- and post-laser IOP (i.e., iCare, TonoPen [Reichert], Goldmann tonometer [Haag-Streit])
- Safety laser goggles for any assistants in the room
- Alcohol pads to sterilize patient touch surfaces
- Warning sign to put on door when laser surgery is being performed
- Adjustable standalone arm rest

much sooner.” Another plus is that patients may feel more comfortable if they already know and trust the person performing the procedure (you).

There are ways to mitigate the cost, including opting for refurbished/used models or sharing the financial burden with another optometrist. However, Corri Collins, OD, who practices in Lexington, KY, cautions that it is important to look closely at the warranty options, especially when purchasing a used device.

Beyond cost, optometrists should also consider the patient populations they typically treat and which types of procedures they plan to perform. “Making sure you have the volume of patients to pay for this investment is important,” says Dr. Collins, while noting that ODs who plan to offer SLT, YAG capsulotomy and LPI would benefit from a combination laser. “The simple YAG laser will allow you to perform YAG and LPI, but not SLT.”

A combination laser may also be more cost-efficient depending on the needs of the individual practice. It could also be a good option if space is an issue. Dr. Lighthizer opted for a combination device for these reasons as well as its ability

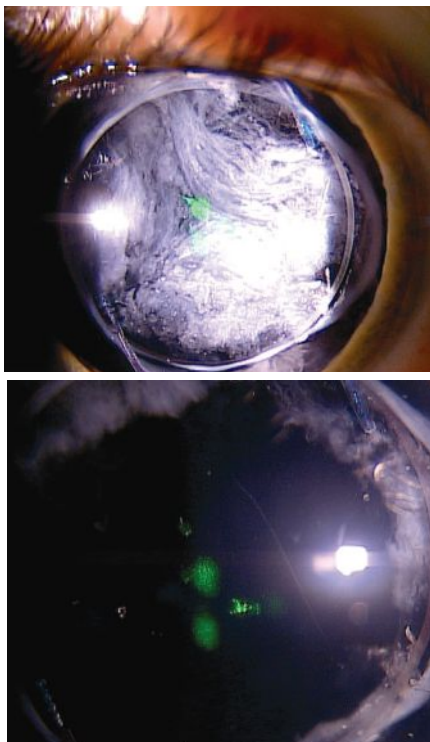
to perform multiple procedures. “Doctors should also remember that when you turn the laser off, it functions like a slit lamp as well,” he notes. “Therefore, when you aren’t using the laser, you can use the room for patient examinations.”

Making this investment can feel daunting, but it should be approached the same way as any other large equipment purchase, recommends Dr. Brog. “You need hands-on experience. Also, it is important to talk to colleagues about what they have and what they like. Equipment representatives can also add insight.”

Shop around, advises Dr. Lighthizer. “Every brand has its own bells and whistles,” he notes. “Explore the interfaces and get a feel for the individual lasers. Ultimately, it comes down to your preference and specific needs. I always say, your favorite laser will likely be the one you have in your office.”

Dr. Wroten recommends getting quotes from the major laser manufacturers to compare prices and features. “Demo their lasers in-office or at a national or regional conference or CE workshop seminar to get a feel for how they work with your arm length, the optics of the slit lamp, what the focusing

Photo: Nathan Lighthizer, OD



**Fig. 5. Patient before (top) and after (bottom) YAG posterior capsulotomy.**

Photo: Nathan Lightizer, OD



**Fig. 6. The Rapid SLT lens from Volk is what Dr. Brog uses (notice the four mirrors). Compared with a one-mirror lens, he has found that this one helps to expedite procedures and is more comfortable for patients since it does not have to be moved around to treat 360° of the eye.**

beams look like, how it's adjusted and so on."

In addition to the laser, optometrists will also need the appropriate laser lenses. Some popular options on the market include the Latina SLT lens or Rapid SLT lens for SLT, the Abraham YAG iridotomy lens for LPI and the Abraham YAG capsulotomy lens for YAG capsulotomy. Like purchasing a laser, Dr. Brog based his choices—Abraham YAG laser capsulotomy lens, the Abraham YAG laser iridectomy lens and Volk's rapid four-mirror SLT lens—on colleague recommendations and hands-on practice.

Some ODs may opt to perform capsulotomies without a lens; however, Dr. Collins finds that, while not always a necessity, the Abraham lens can make the procedure run much smoother with fewer complications. "In some scenarios, doctors will not use a lens during a YAG capsulotomy procedure, but there are certain cases where the lens is crucial," she notes. "If the patient's cornea has certain abnormalities, a lens with a cushioning solution will help to smooth out the appearance of the cornea and make the procedure much easier.

"The lens also helps with the clarity of the posterior capsule as well as minimiz-

ing the possibility of pitting the IOL," Dr. Collins continues. "The Abraham iridectomy lens is also useful in an LPI because it can be used for pressure if there is an iris bleed."

When considering SLT lenses, Dr. Brog initially bought a one-mirror Latina lens, and while he was able to perform the procedure, he reports that it took longer. "The lens has to be turned on the patient's eye many times to treat 360°," he explains. "I found that the patients were more and more uncomfortable as the procedure went on. The rapid four-mirror is much faster and improves patient comfort. The lens only has to be rotated once to treat 360° (Figure 6). You can find these lenses anywhere you buy your 20D, 90D or other lenses you already use in your office."

While the laser and laser lenses are the key pieces needed for these procedures, there are a number of other items required. "Every office should have a blood pressure cuff to check BP before and after the procedure," says Dr. Brog. "You should also have topical proparacaine for pre-procedure anesthesia as well as topical brimonidine for use pre- and post-procedures." Check out the sidebar, "What You Need to Perform Laser Procedures," for other items that you should have on-hand in your clinical practice.

When choosing between different brands, it ultimately comes down to personal preference. For example, there are a variety of cushioning solutions for use with laser lenses (e.g., Genteal Gel, Celluvisc, Goniosol, Goniovisc). Dr. Brog prefers the Genteal Gel since it stays on the lens well as you insert it into the eye, and it is not toxic to the cornea.

On the other hand, Dr. Wroten opts for Celluvisc because he finds it to be gentler on the cornea and has a good viscosity. As discussed above, optometrists must do their own legwork. Test out the different options and get feedback from colleagues who have experience with these items.

There are some tools that, while not necessary, can be helpful additions when performing these procedures. For instance, Dr. Brog recommends having

a strap attached to the laser that goes around the patient's head. He notes that while he has tried different ways to control patient movement during the procedure, including having a staff member or himself hold the patient's head against the rest, a strap has proven most effective.

"Other doctors might prefer other methods and I have seen them used successfully," says Dr. Brog. He adds, "Another thing is to have a good arm rest when performing laser procedures. It helps steady your hand."

While this doesn't necessarily fall under equipment, it is important not to overlook consent forms, urges Dr. Collins. "Make sure you have a good patient consent form that is easy to read and comprehend. It is crucial to have this documentation when performing these procedures."

## Conclusion

Fully equipping your practice to perform these surgical procedures takes time; however, with the right tools and support, optometrists are perfectly positioned to provide these important services to their patients.

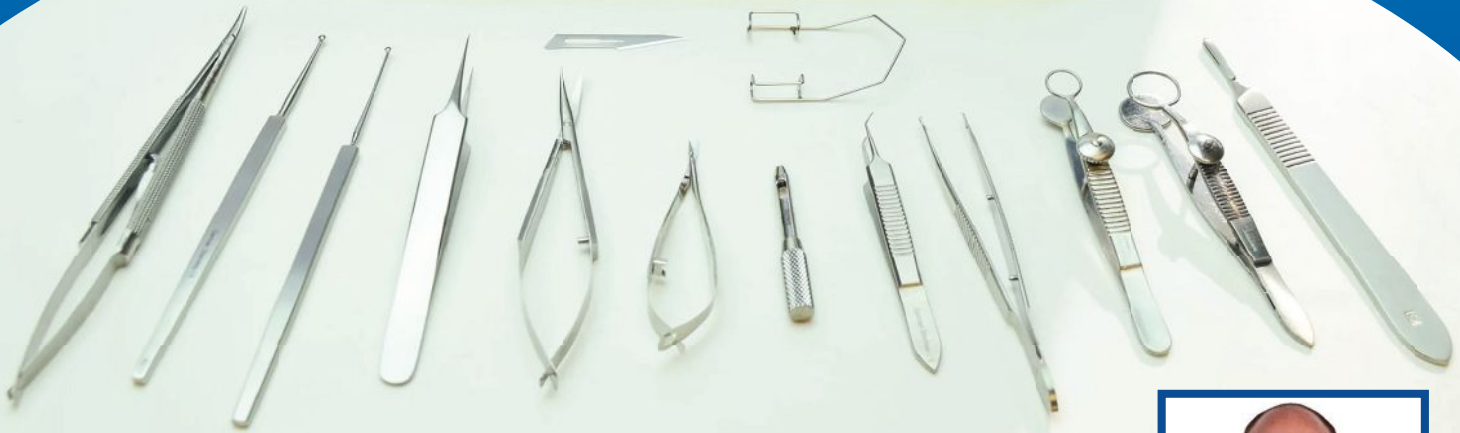
Exactly what you need depends on what level you want to practice, notes Dr. Brog. "You can always start with a few basic procedures and move up from there," he says. When selecting specific tools and equipment, he recommends finding a starting point with trusted information from colleagues.

"As you practice, fine-tune those things with personal preferences. The key is to get started," Dr. Brog says. "It is the same as with your slit lamp, gonio lens, retinoscope or BIO. The more you use them, the more you will determine what works best for you," he explains.

"The most important point in performing these procedures is to do what we always do with any procedure in optometry, and that is to follow the standard of care," he concludes. "Always think about your patients and which tools will best fit their needs. If you do that, you will be successful. It will also make a big difference in the lives of your patients." ■



# LIGHTHIZER OFFICE BASED SURGICAL PROCEDURE SET



"Having the right instruments is essential for much of what we do in life, and especially in medical procedures. Eyecare providers perform procedures in-office ranging from eyelid lesion removals to biopsies, chalazion management, suturing, cyst removal and drainage to many more. The In-Office Surgical Procedures Set contains all of the instruments, toothed forceps, non-toothed forceps, needle drivers, surgical scissors, chalazion tools, among many others, that the eyecare provider will need to get their office procedures clinic rolling. It makes it easy and efficient to have all the essential instruments in one set!"



**Nate Lighthizer,**  
O.D., F.A.A.O

## INDIVIDUAL INSTRUMENTS

- SPK-001 Chalazion Curette, Serrated
- SPK-002 Chalazion Curette, Smooth
- SPK-003 Chalazion Forceps, Small
- SPK-004 Chalazion Forceps, Medium
- SPK-005 Needle Holder
- SPK-006 Stitch Scissors
- SPK-007 Tenotomy Scissors
- SPK-008 Suture Forceps (2 included with set)
- SPK-009 Tying Forceps
- SPK-010 Trephine Blade, 3.0mm
- SPK-011 Eye Speculum, Atraumatic
- SPK-012 Jeweler Forceps #5
- SPK-013 Autoclavable Tray, 6" x 10"
- SPK-014 Scalpel Blades #11, pack of 25 (included with set)
- SPK-017 Surgical Blade Disposal Container\*  
**\*NOT INCLUDED IN SET**
- SPK-018 Scalpel Blade Handle

**DISCOUNT CODE:**  
**NATE10**



**TO ORDER FROM THE DRY EYE DOCTOR, INC. - BY PHONE:** 833-437-9393 or 470-374-5305

**BY E-MAIL:** [sales@thedryeyedoctor.net](mailto:sales@thedryeyedoctor.net)

**PAYMENT TERMS:** Credit Card or Check. We accept VISA, MC, AMEX, Discover

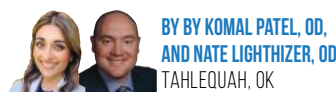**WEBSITE:** [www.thedryeyedoctor.net](http://www.thedryeyedoctor.net)

**ADDRESS:** 5325 Lake Pointe Center Drive #100,  
Cumming, Georgia 30041



# IN-OFFICE PROCEDURES: PREPARE TO HANDLE THESE COMPLICATIONS

The well-informed optometrist should be able to tackle most of these with relative ease.



Injections, laser procedures and surgical interventions are all valuable in-office treatments that optometric physicians can provide for their patients. As with any potential procedure, these categories of treatment are not without their own set of risks and difficulties. Outlined below are both common and uncommon complications for laser procedures, minor surgical methods and injections, all of which are broken down by procedure type.

The key to avoidance and mitigation of most adverse reactions or outcomes consists of proper surgical technique, maintaining asepsis and possessing a thorough understanding of instrumentation and ocular anatomy; however, even with the best of techniques, issues can arise. The eyecare provider stating they have never had a complication with any procedure likely has not performed enough or has performed very few. Be prepared to manage the most common complications and the most severe.

## Laser Procedures

There are three main types of optometric laser treatments that may cause varied effects.

### Nd:YAG Capsulotomy (YAG cap)

Posterior capsular opacification (PCO) is the most common complication after cataract surgery. Proliferation and growth of lens epithelial cells can severely impact patients' daily living activities and lead to visual symptomatology. PCO can develop months to years following extraction.<sup>1</sup> Hydropho-

bic acrylic intraocular lenses (IOLs) have demonstrated a lower incidence of PCO when compared with silicone and hydrophilic acrylic IOLs.<sup>1</sup>

YAG cap is a routine and efficient laser procedure that can be performed in your office to treat PCO; however, any laser procedure will present the possibility of causing complications, due to laser energy that enters the eye. Contraindications to look for before performing a YAG capsulotomy include corneal scars or opacities that limit adequate view of the PCO,

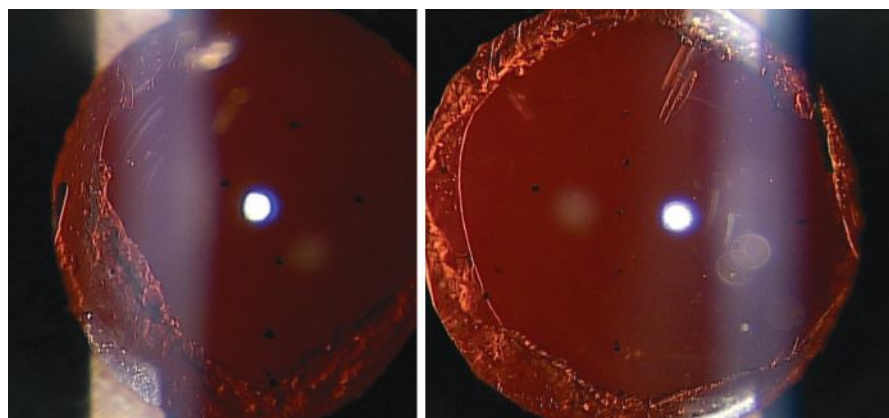
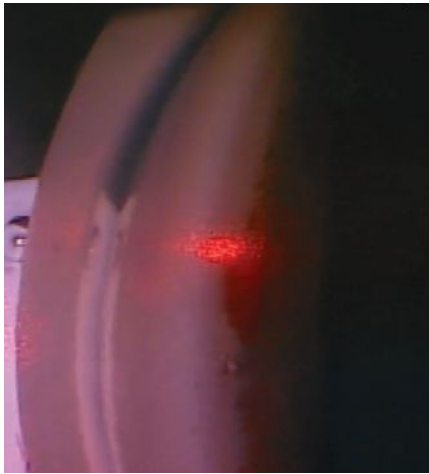


Fig. 1. IOL pits caused by YAG capsulotomy.

#### About the authors

**Dr. Komal Patel** is an assistant professor at the Oklahoma College of Optometry (NSUOCO). She completed a Primary Care residency at NSUOCO specializing in ocular disease and advanced procedures. Dr. Patel is a diplomate of the American Board of Optometry and a fellow of the American Academy of Optometry. **Dr. Nate Lighthizer** is the associate dean, director of continuing education and chief of specialty care clinics at NSUOCO. He is a founding member and immediate past president of the Intrepid Eye Society. Dr. Lighthizer's full disclosure list can be found in the online version of this article.



**Fig. 2. Angle bleed during SLT.**

uveitis, cystoid macular edema (CME), macular pathology, horseshoe tears or high risk of retinal detachment (RD).<sup>2</sup> The presence of these conditions would need to be considered on a case-by-case basis or referred for ophthalmology clearance before performing capsulotomy.

**IOL pitting.** Damage or pitting of the IOL can occur when laser shockwaves move anteriorly and hit the IOL (Figure 1). Factors potentially leading to IOL pits are misalignment of the laser focus, patient movement or IOL material. Silicone IOLs tend to be more susceptible to IOL pits than acrylic ones.<sup>2</sup> Methods to prevent pitting are to increase the posterior offset (200 $\mu$ m to 300 $\mu$ m from the posterior capsule) and starting treatment in the periphery to avoid the visual axis. Thankfully, IOL pits are not visually significant and will rarely affect patients' visual functioning. Various studies have shown the rate of IOL pits ranges from 7.8% to 19.8%.<sup>3,4</sup>

**Inflammation.** Transient anterior iritis is a possible complication after YAG cap, typically resolving in a few days on topical corticosteroid or topical nonsteroidal anti-inflammatory drug (NSAID) therapy. Various studies have shown the rate of uveitis after capsulotomy is between 0.3% to 9.9%.<sup>3</sup>

**Intraocular pressure (IOP) elevation.** Transient increase in IOP is another possible complication with any of the laser procedures discussed in this section. It may occur after capsulotomy

due to debris deposition in the trabecular meshwork or inflammatory swelling of the ciliary body associated with angle closure.<sup>2,4</sup>

One risk factor for IOP elevation is higher total laser energy used during the procedure. Elevated IOP can be prevented by using topical hypotensive medications both pre- and postoperatively, such as alpha-agonists or beta-blockers. Topical hypotensive drops may also be prescribed short-term in patients at risk of prolonged IOP elevation and subsequent damage, including those with advanced glaucoma or steroid responders. Various studies report rates of IOP elevation after capsulotomy ranging between 0.4% to 12.6%.<sup>3</sup>

**Cystoid macular edema.** This condition can occur due to movement of the vitreous or damage to the blood-aqueous barrier, causing the release of inflammatory mediators in the retina.<sup>2,4</sup> Although rare, CME should be treated with topical corticosteroids and NSAID, just like with treating post-cataract surgery CME. Any cases of non-resolving CME should be referred to ophthalmology for treatment. The rate of CME after capsulotomy ranges between 0.1% to 2.9%, as various studies show.<sup>3,4</sup>

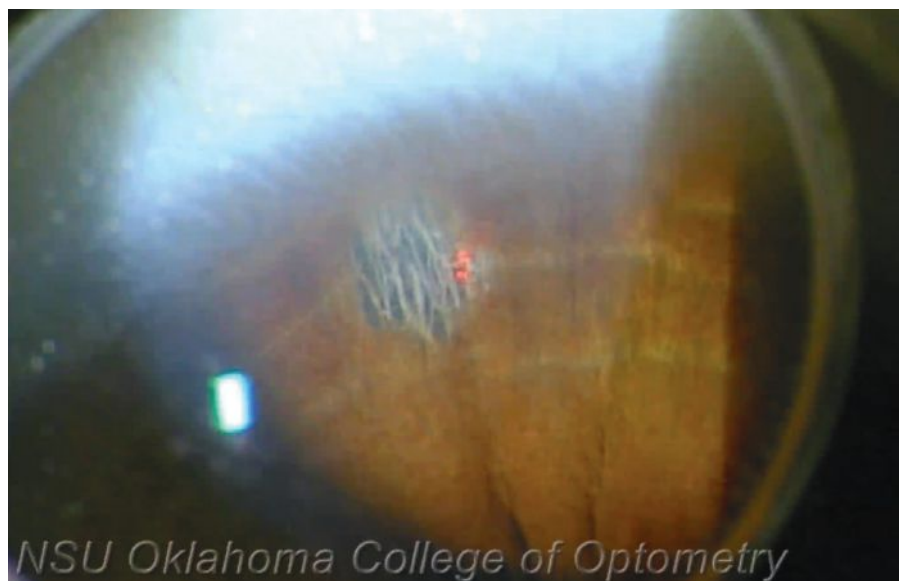**Retinal detachment.** This is one of the most severe, yet rare, complications after YAG cap. The exact mechanism

that leads to an RD or retinal tear is unknown; however, it has been shown that the presence or absence of a posterior vitreous detachment at the time of capsulotomy is not a factor in increasing the risk for RD in the first year after laser treatment.<sup>4</sup> Increased risk of RD is found in patients with a history of RD, lattice degeneration, axial length greater than 24mm and posterior capsule rupture during cataract surgery.<sup>4</sup> Any cases of RD should be urgently referred to ophthalmology for treatment and management. Luckily, the rate of retinal detachment after YAG cap is low, ranging from 0.2% to 2.3%.<sup>3,4</sup>

It has been thoroughly concluded in the literature that complications such as IOL pitting, iritis, IOP elevation, CME and retinal detachment are much more common when total laser energy is higher.<sup>3</sup> One study also concluded that capsulotomy aperture diameter should not exceed 4.0mm in order to decrease the risk of complications.<sup>6</sup> Accordingly, the lowest total laser energy that will complete the procedure successfully should be used to minimize risk of these complications emerging.

### Selective Laser Trabeculoplasty (SLT)

This procedure is increasingly used as first-line therapy for open-angle glaucoma and ocular hypertension. SLT uses laser energy to cause biologic



**Fig. 3. Non-patency of an LPI one week postoperatively.**



Fig. 4. Iris bleed during a YAG LPI.

effects where inflammatory cells clean up the debris in the trabecular meshwork, consequently increasing aqueous outflow. Although the mechanism of action of SLT is not fully understood, it is believed that there is a subclinical SLT-induced inflammatory process, which helps facilitate IOP lowering.<sup>7</sup>

**IOP elevation.** Most IOP elevations are initially seen one hour postoperatively and usually resolve within 24 hours without any long-term complications.<sup>2,8,9</sup> Transient elevation may be more commonly seen in eyes with a heavily pigmented trabecular meshwork.<sup>2,8</sup> This can be prevented through use of topical hypotensive medications pre- and postoperatively.<sup>10</sup> Additionally, clinical experience has shown the incidence of IOP elevation in heavily pigmented angles goes down when treating fewer degrees of the trabecular meshwork (180 $\mu$ m or less instead of 360 $\mu$ m) as well as reducing treatment energy (0.4mJ to 0.6 mJ per pulse instead of the typical 0.8mJ to 1.0 mJ). Rates of IOP elevation after SLT have been reported to be around 0.01% to 27%.<sup>2,8-12</sup>

**Inflammation.** Transient anterior uveitis typically occurs one to three days after SLT and resolves in approximately five days.<sup>8</sup> Risk factors for anterior uveitis include patients with a heavily pigmented trabecular meshwork or history of previous argon laser trabeculoplasty.<sup>8</sup> Transient anterior uveitis after SLT has been reported in up to 83% of patients.<sup>2,8</sup> Topical steroids can be used to treat any iritis. It is

important to note that the mechanism of SLT is inflammatory, thus some degree of inflammatory reaction is expected.

**Hyphema/angle bleed.** After SLT, hyphema is a very rare complication. Only two cases have been reported, both in patients with open-angle glaucoma who developed a hyphema three days after SLT, which self-healed without intervention.<sup>8</sup> If bleeding is seen during SLT (*Figure 2*), hold gentle pressure with the SLT laser lens on the eye to stop the bleed.

**Corneal changes.** SLT may result in some corneal changes, such as corneal edema, corneal haze and endothelial cell count changes, occurring one to

two hours after procedure.<sup>8</sup> These changes are usually not visually or clinically significant and self-resolve. The incidence of corneal edema after SLT is 0.8%.<sup>8</sup> There have been eight reported cases of SLT-induced keratitis causing a hyperopic shift.<sup>8</sup> Keratitis can be treated with frequent use of artificial tears and lubricating ointment, while corneal edema and haze can be treated with sodium chloride hypertonic ophthalmic solution or topical corticosteroid.

### Laser Peripheral Iridotomy (LPI)

This laser type is used as a form of treatment for patients with narrow angles, primary angle closure, primary angle closure glaucoma and occasionally in pigment dispersion syndrome. It eliminates the pupillary block component in primary angle closure and allows the flow of aqueous humor from the posterior to anterior chamber.<sup>13</sup>

**Non-patency of the iridotomy.** An LPI may become non-patent after the procedure (*Figure 3*). Studies show that repeat LPI was required in 1% of patients two weeks after initial LPI and in 20% of cases within six months of initial treatment.<sup>14</sup> The endpoint to watch for during an LPI is a “pigment plume,” which indicates that the

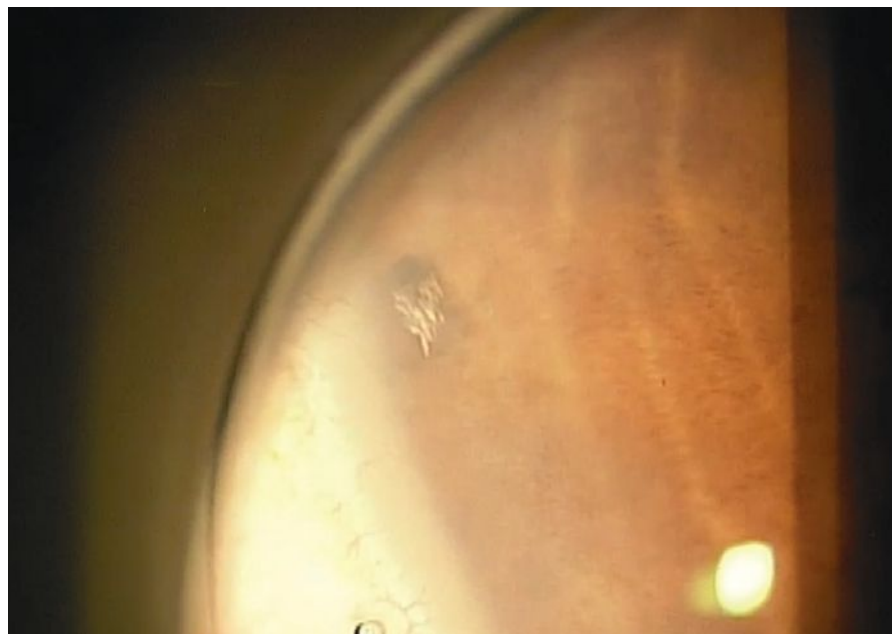
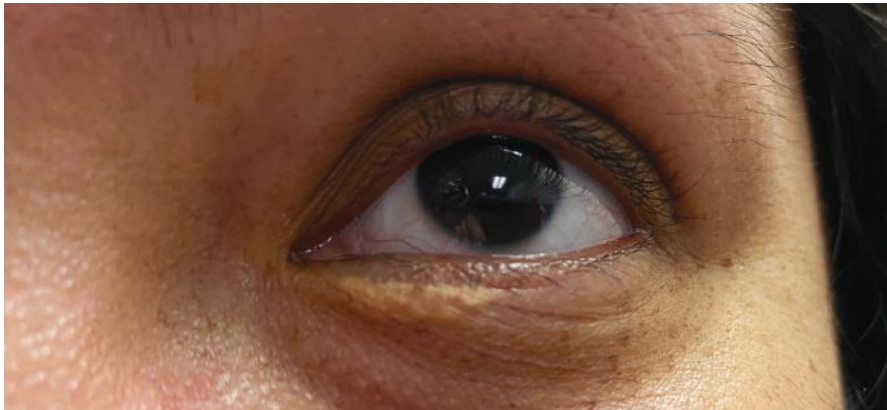


Fig. 5. Endothelial cell hit during YAG LPI.



**Fig. 6. Steroid deposition after intralesional triamcinolone injection for chalazion.**

laser has penetrated through the iris tissue. Ensure that the diameter of the LPI is at least 0.2mm to 0.5mm at the conclusion of the procedure to prevent small iris strands from growing over the iridotomy and causing non-patency. If maximal laser energy has been put into the eye during the initial procedure (100mJ to 150mJ), it may be beneficial to stop treatment and complete the procedure at the one-week follow-up examination. Oftentimes with thicker brown irises, it is common to re-treat the following week. Retroillumination and direct viewing of the PI hole with a gonioscopy lens can be done to examine for PI patency.

**IOP elevation.** Increased pressure may occur more often after an LPI due to the higher amount of total laser energy used or iris pigmentation blocking the trabecular meshwork and decreasing aqueous outflow.<sup>14</sup> IOP elevation after LPI has been seen in 6% to 10% of cases.<sup>14</sup> Use of topical hypotensive medications pre- and postoperatively can minimize elevations. Should they occur, low elevations (<10mm Hg) can be treated with topical medications such as alpha-agonists, beta-blockers or carbonic anhydrase inhibitors. High IOP elevations (>10mm Hg) can instead be treated with oral carbonic anhydrase inhibitors, such as acetazolamide, in addition to topical therapy. Risk factors and side effects of acetazolamide should be considered for each patient.

**Hyphema.** Iris bleeding is seen in 30% to 40% of LPIs.<sup>14</sup> If bleeding does

occur (*Figure 4*), hold gentle pressure with the laser lens on the eye for 30 to 60 seconds. If a hyphema develops after the procedure, it can be treated with topical therapy, including corticosteroids, cycloplegics and hypotensive medications. Do note that there is no increased risk of bleeding in patients on antithrombotic therapy. As such, these medications do not need to be discontinued before an LPI.<sup>14</sup>

***Change in endothelial cell count.***

Endothelial cells may be hit by the laser during an LPI (*Figure 5*), which can lead to decreased endothelial cell counts. One study comparing endothelial cell density in eyes who underwent LPI compared with control eyes showed no statistical difference between the groups.<sup>15</sup> Another study compared eyes treated with LPI vs. phacoemulsification and found the LPI group to have a greater decrease in endothelial cell count than the phaco group.<sup>16</sup> Proper laser beam alignment on the iris can avoid this.

***Cataract development.*** Lenticular injury during an LPI may lead to the development of cataracts. Cataract progression was seen in 23% to 39% of LPI cases up to six years postoperatively.<sup>14</sup> On the contrary, a subset of the ZAP study (Zhongshan Angle Closure Prevention Trial) published in 2022 showed that prophylactic Nd:YAG LPI did not cause significant cataract progression after six years in the 889 patients who received an LPI in one eye.<sup>17</sup> This group concluded that LPI treatment of asymptomatic narrow

**How to Avoid the “Worst Case Scenario”**

As it relates to any laser procedures, injections or surgical procedures, this would entail permanent vision loss. One such scenario for laser procedures consists of retinal or macular burns that developed following a procedure that was accidentally performed with the wrong laser. This most often occurs when a YAG capsulotomy is performed accidentally on SLT mode. There have been rare case reports in the literature regarding YAG capsulotomies done with an SLT laser.<sup>18,19</sup> This will result in the SLT laser beam traveling through the posterior capsule until it hits a pigmented structure, most likely the heavily pigmented retinal pigment epithelium in the macula or foveal region. Laser energy applied directly to the macular or foveal region has a high likelihood of causing irreversible, permanent vision loss.

For this reason, it is highly recommended for all eyecare providers to perform a “time-out” prior to every procedure, but especially for laser procedures. The time-out is your opportunity to take a few seconds and have the treating clinician as well as a second individual (usually a technician) confirm the correct laser is being used with the correct laser settings, laser lens and that the correct eye is being treated. A time-out takes just a matter of seconds and is invaluable to help ensure the worst-case scenario does not happen in your office.

angles does not increase the risk of developing clinically meaningful cataract worsening over time. Nevertheless, if cataract progression were to occur, patients should be referred to ophthalmology for management. Avoid lens damage by proper laser beam alignment on the iris.

**Injections**

The conditions of chalazion and blepharospasm both may be treated with injections (of different kinds) that carry with them potential side effects.

**Intralesional Injection for Chalazion**

Steroid injection for chalazia can be considered if more conservative options fail or if it is patient preference for treatment. It’s typically done with

Kenalog (triamcinolone acetonide, Bristol-Myers Squibb). Intralesional injection is a beneficial option for chalazia near the lacrimal punctum and can resolve a chalazion in a little over two weeks.

**Steroid deposition.** This is a common complication after intralesional steroid injection (Figure 6). One study found an incidence of 92.3%, and these deposits remained for a mean of 18 days.<sup>20</sup> One possibility to decrease steroid deposition risk is to use a lower concentration of triamcinolone. One risk factor for steroid deposition is darker skin, thus caution should be exercised in these patients.

**Depigmentation.** Steroid injections can lead to skin depigmentation or fat atrophy at the injection site, more so with darker skin. These may self-resolve anywhere from seven to 12 months after injection, but it may be permanent.<sup>21,22</sup> One study reported an incidence of 15%, but the patients in this study were pigmented patients.<sup>23</sup> As depigmentation is a risk factor in darker skin tones, caution should be exercised with these patients.

**Vascular occlusion.** In very rare cases, intravascular injections may lead to retrograde infiltration, which could lead to a central retinal artery or vein occlusion. Two case reports have outlined individual patients who had a retinal and choroidal vascular occlusion after periocular injection of corticosteroid.<sup>24,25</sup> Avoid this by injecting with low pressure to minimize retrograde arterial flow of steroid particles or by aspirating the needle and syringe, ensuring it isn't in a blood vessel.

### Botulinum Toxin for Benign Essential Blepharospasm

Botox can be a beneficial treatment option for patients with benign essential blepharospasm, with the effects lasting up to three months.

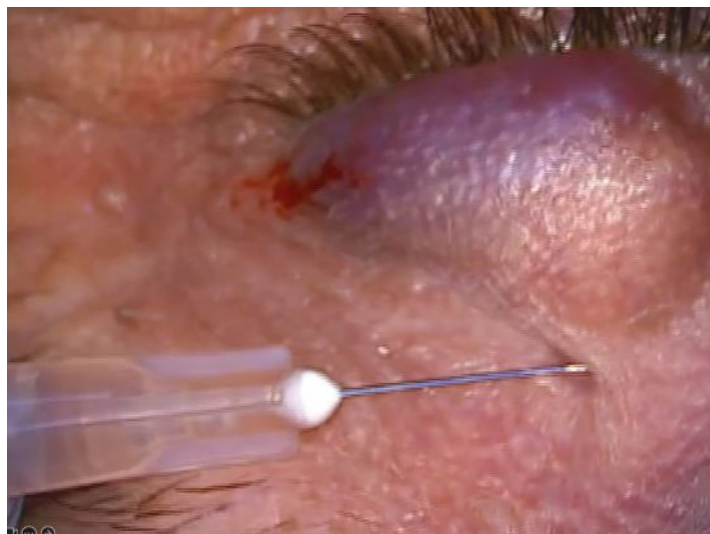

Fig. 7. Ecchymosis after intradermal anesthetic injection before chalazion incision and curettage.

**Eyelid ptosis.** Upper eyelid ptosis, caused by the diffusion of the toxin into the levator palpebrae muscle, is a possible complication from toxin injection.<sup>26</sup> The mechanism of action of botulinum toxin leads to the cessation of levator muscle activity.

Patients at risk for developing postoperative ptosis include those with levator function weakness and those with loose skin or an attenuated orbital septum, allowing easier diffusion of the toxin.<sup>26</sup> Upper eyelid ptosis can occur 48 hours after injection or seven to 10 days after injection, and it usually resolves within two to six weeks.<sup>26</sup> One study reported that ptosis complications occurred in one patient (3.6%) on the fourth day after injection and resolved in two months, while others reported ptosis rates of 9.2% to 10.3% after injection.<sup>27</sup>

If ptosis should occur, optional management may include use of apraclonidine 0.5% to stimulate Müller's muscle and allow for minimal elevation of the upper eyelid.<sup>26,28</sup> Techniques to avoid an upper eyelid ptosis include injecting at least 1cm above the bony supraorbital notch between the inner and outer canthi. Use higher concentration of botulinum toxin to allow for precise minimal volume injections and decreased risk of toxin migration to non-targeted areas.<sup>26</sup>

### Surgical Procedures

Be aware of difficulties that can arise with chalazion incision and eyelid lesion removal.

#### Chalazion Incision and Curettage

When more conservative therapies or steroid injection fail to resolve a chalazion, surgical intervention with the procedure of incision and curettage can be considered. This intervention drains the contents of the chalazion and avoids recurrence, as the entire lesion and capsule are removed.

**Ecchymosis.** Eyelid bruising is common after chalazion incision and curettage (Figure 7). One study reported ecchymosis in 56% of patients with resolution in approximately five days.<sup>20</sup> Monitor eyelid bruising for resolution, typically resolving one to two weeks after surgery.<sup>29</sup> Ecchymosis can be prevented by avoiding anesthetic injection into eyelid blood vessels.

**Meibomian gland damage.** Incision and curettage risks tarsal plate and meibomian gland morphology alterations. If tarsus excision is performed too close to the eyelid margin, eyelid notching may occur. Be careful not to excise closer than 2mm to 3mm from the eyelid margin.<sup>30</sup> Chronic meibomian gland obstruction and atrophy can occur if large horizontal incisions are made across many glands. Avoid this by keeping incisions vertical and parallel to the meibomian gland anatomy.<sup>30</sup> If meibomian gland structure is affected and leads to instability of the tear film, manage it with treatments for evaporative dry eye, including warm compresses, eyelid scrubs, in-office heat therapies and lipid based artificial tears.<sup>29</sup>

**Infection.** This is a possibility with any surgery, but it can be minimized by maintaining aseptic technique throughout the procedure. Antiseptic agents such as povidone-iodine

should be used in the preoperative preparation; prophylactic topical ophthalmic antibiotic ointment can be prescribed postoperatively. Should any postoperative infection occur, treat it with oral antibiotics such as Augmentin (amoxicillin-clavulanic acid, US Antibiotics) or cephalexin. Doxycycline, clindamycin or Bactrim (trimethoprim-sulfamethoxazole, Hoffmann-La Roche) can be used in cases of methicillin-resistant *Staphylococcus aureus* (MRSA).<sup>28,29</sup>

**Suspected malignancy.** Take caution with recurring or non-resolving chalazia, which may raise suspicion for malignancy. A recurrent chalazion should be biopsied to rule out malignancies such as sebaceous gland carcinoma and adenoid cystic carcinoma.<sup>31-33</sup> Sebaceous carcinoma has a mortality rate of 23%, with 50% of these masquerading as benign or inflammatory lesions.<sup>29</sup> They have a 20% risk of recurrence even after removal.<sup>29</sup>

## Eyelid Lesion Removal with RF and Other Surgical Instruments

Radiofrequency removal of eyelid lesions is a quick and effective technique that results in great cosmetic outcomes and minimal to no scarring.

**Infection.** Likelihood of infection is very rare with removal of eyelid lesions via radiofrequency or other means (scalpel or surgical scissors). Maintain aseptic technique throughout the procedure with use of antiseptics such as povidone-iodine in the preoperative preparation; prescribe prophylactic ophthalmic antibiotic ointment postoperatively for one week.<sup>34</sup> Should any postoperative infection occur, it can be treated with oral antibiotics.<sup>34</sup>

**Excessive tissue excised.** Scarring can occur if excision is performed too deeply.<sup>34</sup> This can be avoided by using proper technique and remaining superficial with the radiofrequency device or other surgical instruments. Moist healing is also important in the postoperative period. Thankfully, scarring from radiofrequency is typically less pronounced than other surgical techniques. Use of a topical antibiotic

ointment or other lubricating ointment will ensure the surgical site remains moist to aid healing and reduce scab or scar formation.<sup>34</sup> One study reported a notch-shaped defect in four patients due to an over-resection, although these improved in three months postoperatively with a good cosmetic outcome.<sup>35</sup>

## Takeaways

A doctor cannot truly master an interventional procedure until they are able to anticipate all possible complications and adjust on the fly to mitigate long-term consequences.

Educating patients about possible risks and complications is crucial before performing any laser or surgical procedure, and an informed consent form should be obtained before all. It is vital for optometric physicians to be aware of these possible complications and methods so they may use the proper tools and techniques to avoid them. Should complications occur, be sure to have protocols in place to allow for the best patient outcomes. ■

1. Ursell PG, Dhariwal M, O'Boyle D, Khan J, Venerus A. 5 year incidence of YAG capsulotomy and PCO after cataract surgery with single-piece monofocal intraocular lenses: a real-world evidence study of 20,763 eyes. *Eye (Lond)*. 2020;34(5):960-8.
2. Freisberg LJ, Lighthizer N, Skorin Jr L, Stonecipher K, Zimmerman AB. *The Ophthalmic laser handbook*. Lippincott Williams & Wilkins; 2021.
3. Bhargava R, Kumar P, Phogat H, Chaudhary KP. Neodymium-yttrium aluminium garnet laser capsulotomy energy levels for posterior capsule opacification. *J Ophthalmic Vis Res*. 2015;10(1):37-42.
4. Karahan E, Er D, Kaynak S. An overview of Nd:YAG laser capsulotomy. *Med Hypothesis Discov Innov Ophthalmol*. 2014;3(2):45-50.
5. Halilović EA. Correlation between eye aperture diameter and complications in the posterior eye segment after Nd:YAG capsulotomy. *Bosn J Basic Med Sci*. 2008;8(2):106-9.
6. Moussa G, Kalogeropoulos D, Ch'ng SW, et al. "Comparing outcomes of advanced nurse practitioners to ophthalmologists performing posterior YAG capsulotomy, a six-year study of 6308 eyes". *Eye (Lond)*. 2023;37(3):554-9.
7. Shaarawy TM, Sherwood MB, Hitchings RA, Crowston JG. *Selective laser trabeculoplasty*. Glaucoma. 2nd ed. London: Elsevier/Saunders; 2015.
8. Song J. Complications of selective laser trabeculoplasty: a review. *Clin Ophthalmol*. 2016;10:137-43.
9. Zhou Y, Aref AA. A review of selective laser trabeculoplasty: recent findings and current perspectives. *Ophthalmol Ther*. 2017;6(1):19-32.
10. Shi JM, Jia SB. Selective laser trabeculoplasty. *Int J Ophthalmol*. 2012;5(6):742-9.
11. Hirabayashi MT, Rosenlof TL, An JA. Comparison of successful outcome predictors for MicroPulse® laser trabeculoplasty and selective laser trabeculoplasty at 6 months. *Clin Ophthalmol*. 2019;13:1001-9.

12. Abe RY, Maestrini HA, Guedes GB, et al. Real-world data from selective laser trabeculoplasty in Brazil. *Sci Rep*. 2022;12(1):1923.
13. Shaarawy TM, Sherwood MB, Hitchings RA, Crowston JG. *Peripheral iridotomy for angle-closure glaucoma*. Glaucoma. 2nd ed. London: Elsevier/Saunders; 2015.
14. Radhakrishnan S, Chen PP, Junk AK, Nouri-Mahdavi K, Chen TC. Laser peripheral iridotomy in primary angle closure: a report by the American Academy of Ophthalmology. *Ophthalmology*. 2018;125(7):1110-20.
15. Kumar RS, Baskaran M, Friedman DS, et al. Effect of prophylactic laser iridotomy on corneal endothelial cell density over 3 years in primary angle closure suspects. *Br J Ophthalmol*. 2013;97(3):258-61.
16. Park HYL, Lee NY, Park CK, Kim MS. Long-term changes in endothelial cell counts after early phacoemulsification vs. laser peripheral iridotomy using sequential argon:YAG laser technique in acute primary angle closure. *Graefes Arch Clin Exp Ophthalmol*. 2012;250(11):1673-80.
17. Chang DST, Jiang Y, Kim JA, et al. Cataract progression after Nd:YAG laser iridotomy in primary angle-closure suspect eyes. *Br J Ophthalmol*. 2023;107(9):1264-8.
18. Liyanage SE, Kumaran N, De Alwis D. Macular burns resulting from the accidental use of selective laser trabeculoplasty mode during a laser capsulotomy. *Br J Ophthalmol*. 2014;98(1):141-2.
19. Ledesma-Gil G, Yannuzzi LA, Freund KB, Mainster MA. Dual-mode capsulotomy and selective laser trabeculoplasty lasers continue to cause severe, permanent macular injuries. *Ophthalmology*. 2020;127(12):1766-8.
20. Korn BS, Kikkawa DO. *Video atlas of oculofacial plastic and reconstructive surgery*. 2nd ed. Elsevier; 2017.
21. Park J, Chang M. Eyelid fat atrophy and depigmentation after an intralésional injection of triamcinolone acetonide to treat chalazion. *J Craniofac Surg*. 2017;28(3):e198-e9.
22. Ahmad S, Baig MA, Khan MA, Khan IH, Janjua TA. Intralésional corticosteroid injection vs. surgical treatment of chalazia in pigmented patients. *J Coll Physicians Surg Pak*. 2006;16(1):42-4.
23. Nabie R, Soleimani H, Nikniaz L, et al. A prospective randomized study comparing incision and curettage with injection of triamcinolone acetonide for chronic chalazia. *J Curr Ophthalmol*. 2019;31(3):323-6.
24. Yağci A, Palamar M, Eğriilmez S, Sahbazov C, Ozbek SS. Anterior segment ischemia and retinochoroidal vascular occlusion after intralésional steroid injection. *Ophthalmic Plast Reconstr Surg*. 2008;24(1):55-7.
25. Thomas EL, Laborde RP. Retinal and choroidal vascular occlusion following intralésional corticosteroid injection of a chalazion. *Ophthalmology*. 1986;93(3):405-7.
26. Collier H. Ptoxis explored: a known complication following facial botulinum toxin injections. *J Aesthetic Nurs*. 2013;2(1):8-17.
27. Okumus S, Coskun E, Erbagci I, et al. Botulinum toxin injections for blepharospasm prior to ocular surgeries. *Clin Ophthalmol*. 2012;6:579-83.
28. Onofrey BE, Skorin Jr L, Holdeman NR. *Ocular therapeutics handbook: a clinical manual*. Lippincott Williams & Wilkins; 2020.
29. Zeller JE. Keep an eye on chalazion. *J Nurse Pract*. 2022;18(9):943-6.
30. Dutton JJ. *Atlas of oculoplastic and orbital surgery*. 2nd ed. Lippincott Williams & Wilkins; 2018.
31. Salmon JF. *Kanski's clinical ophthalmology: a systematic approach*. 9th ed. Elsevier; 2020.
32. Nema HV, Nema N. *Ocular tumors*. Springer; 2021.
33. Menon V, Deshmukh R, Mulay K. A rare masquerade of chalazion: adenoid cystic carcinoma. *Indian J Ophthalmol*. 2019;67(8):1371-3.
34. Fowler GC. *Pfenninger & Fowler's procedures for primary care*. Elsevier; 2020.
35. Eshraghi B, Torabi HR, Kasaie A, Rajabi MT. The use of a radiofrequency unit for excisional biopsy of eyelid papillomas. *Ophthalmic Plast Reconstr Surg*. 2010;26(6):448-9.

# KEEPING UP WITH THE NEWEST IOLs

We're in a new era of cataract surgery, one with a plethora of good options. Find out what they are, which is best for each specific individual and how to properly comanage your patients.

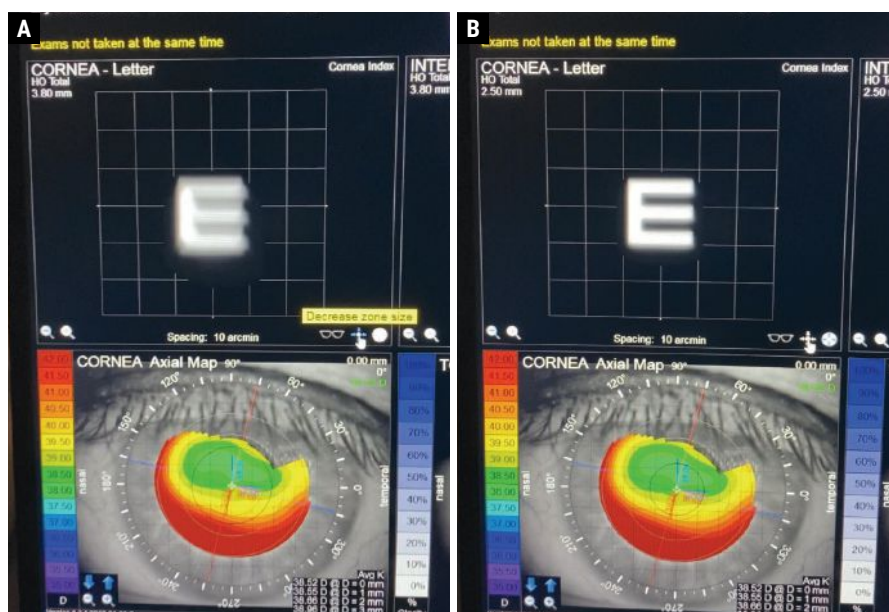


BY BOBBY SAENZ, OD,  
CHRISTIAN LOPEZ, OD, AND  
RICARDO SEPULVEDA, MD  
SAN ANTONIO, TX

As cataract surgery maintains its title as one of the most prevalent surgeries in the United States, technological advancements have resulted in the availability of over 100 intraocular lenses (IOLs) on the market.<sup>1</sup> As optometrists, it is crucial for us to be well-informed about the expected postoperative visual outcomes and potential side effects patients may experience following cataract surgery so that we can provide effective care and guidance during preoperative screening and postoperative follow-up visits. Here, we will delve into the new and improved lens types making waves in the US today.

## Innovative IOLs

The rise of this new technology boom can be attributed to the widespread use of smartphones, tablets and computers in our daily lives. There is now a growing demand on intermediate vision, and some of these new IOLs aim to offer patients the opportunity for not



**A post-refractive myopic LASIK patient presenting for a cataract eval with a decentered ablation. Here, the iTrace is able to show the benefit of a small-aperture IOL. Left is the simulated image of an E with the patient's normal pupil size (A). Right shows the improvement in the simulated image with a small aperture IOL (B).**


only improved vision but also reduced dependence on glasses or contact lenses at intermediate and near tasks.

Historically, there have been two types of lenses used at the time of cataract surgery—monofocal/toric monofocal lenses and multifocal IOLs. Mono-

focals typically aim to provide one focal point of clear vision, such as distance vision when aiming for emmetropia. However, monovision can also be used to create two main areas of clear vision, typically done in patients with a history of monovision, but these patients uncor-

**About the authors** Dr. Saenz is co-founder of LASIK San Antonio and an assistant professor at the University of Incarnate Word Rosenberg School of Optometry. Dr. Lopez is the Director of Optometric Services at Castle Hills Eye Specialists. Dr. Sepulveda is the co-founder of LASIK San Antonio and founder of Castle Hills Eye Specialists. They have no financial disclosures.





**This patient has a Symphony OptiBlue IOL. Figure (A) shows the echellette diffractive design with retroillumination. When viewing the lens directly, you can appreciate the blue hue of the lens (Figure B). The OptiBlue filter blocks the shortest wavelengths of light that produce the most light scatter, helping to mitigate halo, glare and starbursts when driving at night.**

rected can have a lack of intermediate vision. Multifocal IOLs, of course, use multiple foci. Despite the use of this term *multi-* since the early 1990s, many doctors have historically considered these lenses to be more of a bifocal-like correction. Additionally, these initial lenses created glare and halos that were very bothersome to patients.

To achieve a broader range of vision while minimizing side effects, recent developments in lens technology have led to two main categories. One prioritizes distance and intermediate vision while the other encompasses distance, intermediate and near vision, aiming to provide a greater range of functional use. The distance and intermediate vision groups of lenses are called monofocal plus lenses or extended-depth-of-focus (EDOF) lenses, and the distance, intermediate and near vision lenses are called trifocal lenses or trifocal-like multifocal lenses.

### Distance, Intermediate and Near Vision Lenses

Trifocal and trifocal-like multifocal IOLs have gained substantial popularity in recent years due to their ability to provide correction of distance, intermediate and near vision without much need for additional glasses. A recent meta-analysis showed a spectacle independence rate of 91.6% of patients

receiving trifocal IOLs in both eyes.<sup>2</sup>

Despite the extended range of vision that can be achieved, post-op expectations, including side effects, should be discussed with every patient in order to select a lens that best suits the patient's goals. Trifocal IOLs are not perfect and setting and maintaining expectations before surgery is imperative. One of the best ways to determine these could be a patient questionnaire. In a recent study, personality traits such as low conscientiousness, extroversion and high neuroticism significantly influenced the happiness and quality of vision perception at six months after bilateral multifocal lens implantation.<sup>3</sup> In addition to assessing the patient's personality, their ocular surface and overall eye health must be in optimal condition for them to get a trifocal lens.

Next, let's look at several recent products in this category:

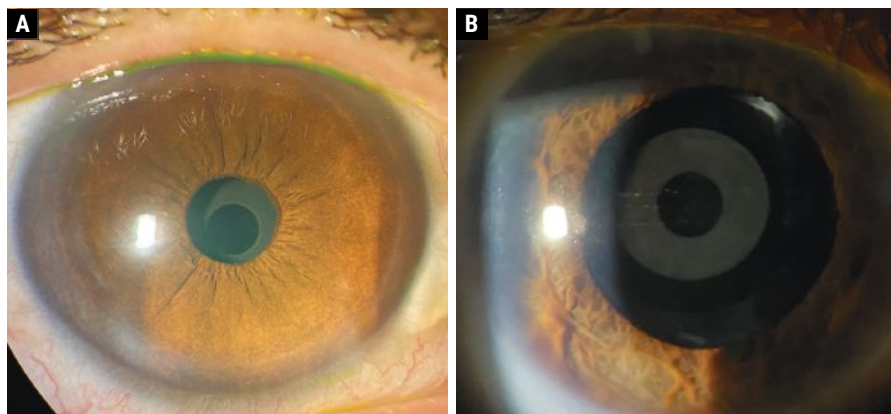
**Clareon PanOptix Trifocal IOL (Alcon).** This is currently the only lens in the US labeled as a trifocal. It is known for its ability to provide vision at multiple distances, including near, intermediate and far. Despite this label, it functions as a quadrifocal, with two of its foci focused at distance.<sup>4</sup> One main advantage of PanOptix includes the excellent range of vision, with an average visual acuity of 20/25 or better from distance to 40cm.<sup>5</sup> Another advantage

of the PanOptix lens and its non-sequential diffractive optics is its capability to achieve clear vision at intermediate distances (around 24 inches) and near distances (around 16 inches), which are commonly used for tasks involving close-up work and reading.

The PanOptix IOL has the ability to correct up to 2.60D of astigmatism. It is a diffractive IOL, so the need for good overhead lighting should be discussed so the patient is aware near vision is dependent on the amount of light directed at the near target. In a study of 65 subjects who underwent bilateral PanOptix implantation, all patients were spectacle independent for distance vision and only two needed over-the-counter readers or near correction.<sup>6</sup>

The greatest limitation to this lens, as in any multifocal, is its optical design, which uses rings for diffraction. These rings will be seen at night by patients and have to be discussed prior to surgery. In most cases, the halos or glare caused by the rings is neuro-adapted by patients over a three to six-month period.<sup>7</sup> The side effect profile of the PanOptix is much better than the initial multifocal lenses of three decades ago, and expectations among practitioners and patients alike need to reflect current performance. A PanOptix IOL OU study of 55 patients showed that at six months there was a 98.2% patient satisfaction rate and only one patient had nocturnal glare that affected their life.<sup>5</sup> The good news is the happiness usually stays. The largest, longest term study so far, of over 1,000 eyes, showed three years of stable visual acuity.<sup>8</sup>

**Tecnis Synergy OptiBlue IOL (Johnson & Johnson Vision).** This lens has a diffractive surface derived from a combination of EDOF (distance & intermediate) and multifocal (distance and near) concepts. It is designed to correct chromatic aberration, spherical aberration and provide a range of vision from distance to near. The Synergy lens is referred to as a continuous range of vision lens by the manufacturer; however, when looking at the optical qualities of the lens using the modulation-transfer-function principle, simulated defocus



The Aphera pinhole IOL in a post-refractive patient undilated (A) and dilated (B).

curves and defocus curves, it behaves similar to a trifocal lens.<sup>9-11</sup> Several studies refer to the Synergy as a trifocal lens, and we believe this term simplifies what this lens is capable of doing to patients, optometry students, optometry residents and doctors.

This trifocal-like lens offers vision at distance, intermediate and near, but its near add power is stronger than what's available in the PanOptix IOL. This allows patients to potentially have better near vision for closer working distances.<sup>11</sup> This can be beneficial for patients with shorter working lengths or for myopes who remove their glasses for near work. Similar to other multifocals, it does require a relatively healthy eye and the need for increased lighting for the best possible vision.

**PanOptix vs. Synergy.** Different surgical groups have their own preferences on which lens is their primary presbyopia-correcting IOL. There are several studies that have put these two lenses head-to-head to see if there is a clear winner. The first is a three-month visual outcomes comparison, which showed that when patients were corrected for distance, the PanOptix and Synergy distance vision was comparable. However, when near vision was evaluated, there was a slight statistical edge for Synergy over PanOptix.<sup>10</sup> A separate study looked at uncorrected distance, intermediate and near vision between Synergy and PanOptix. PanOptix had better distance vision, while the average uncorrected near visual acuity was superior in the Synergy group. There was

no difference in the intermediate vision. When looking at the halo and glare complaints, more patients complained of them at one and three months with the Synergy group, but by six months, glare and halos were the same in both groups. A stat we often tell patients: Only 13% in the study reported halos in both groups at six months.<sup>12</sup> Although not statically significant, the PanOptix patients demonstrated better uncorrected distance visual acuity sooner than the Synergy group.

So, which lens to choose? There is no right answer, as both lenses have advantages and overlap in most categories. Essentially, it comes down to communication with the patient and which area of their vision they prioritize as significant. If that patient prioritizes near vision, Synergy may be the better selection. If they prioritize distance vision, PanOptix may be the better selection.

One interesting fact—when looking at the latest *Market Scope* data, many patients are current selecting PanOptix over Synergy.

### New Kids on the Block

Some really interesting new optical concepts have been introduced in recent years. Here are a few notable ones.

**ClearView3 Multifocal (LensteC).** Previously known as SBL-3, this is a segmented bifocal IOL. Unlike the trifocal IOLs, this lens doesn't use diffractive optics and doesn't have an intermediate focus. Instead, it uses two segmented optical zones, similar to a

traditional lined bifocal or a translating bifocal rigid gas permeable contact lens. The top zone is designed for pure distance and the bottom for near. The Clearview 3 has shown to reduce halos, although patients have reported winged dysphotopsias. Limitations include the lack of lens toricity and intermediate vision. Consider this lens in a patient who wants monofocal-like optics at distance with some near vision.

**EDOFs.** Even though trifocals have significantly improved patient satisfaction and range of vision, there are patients who want to minimize the risk of having halos at night and want more vision than just a monofocal. Thus, EDOFs have come onto the market. Rather than creating different foci, EDOF lenses elongate a single focal point, providing distance and some intermediate vision. These lenses have been gaining traction not only in patients with optimal eye health, but those with a history of refractive surgery and mild pre-existing ocular conditions such as mild epiretinal membranes, primary open-angle glaucoma or age-related macular degeneration.

**Tecnis Symphony IOL (Johnson & Johnson Vision).** This the first IOL to have FDA approval as an EDOF lens. Some think of Symphony more as a low-add multifocal lens due to it being a diffractive lens. Similar to the Vivity lens (discussed below), Symphony provides around 1.53D of add and corrects astigmatism from 1D to 2.6D.<sup>1</sup> The Symphony is currently on its second version—Symphony OptiBlue—which has the same defocus curve as the first version but has shown in optical bench studies to mitigate dysphotopsias and improve contrast.<sup>13</sup>

**Vivity (Alcon).** This EDOF IOL aims to stretch the wavefront to provide a range from distance to intermediate vision. Vivity is able to achieve approximately a +1.5D of add power and can correct corneal astigmatism up to 2.45D.<sup>1</sup> The Vivity IOL was the first EDOF in which we were able to see improved intermediate vision compared to a monofocal IOL, while having less halo symptoms at night compared to

**TABLE 1. FOUR CRITERIA THAT AN EDOF LENS SHOULD MEET TO SATISFY ANSI STANDARDS<sup>19</sup>**

Demonstrate a statistical superiority over a control monofocal group on mean, monocular photopic distance-corrected intermediate visual acuity at 66cm.	Demonstrate at least 0.5D greater monocular photopic negative lens induced distance-corrected depth of focus compared to the monofocal control IOL at 0.2 logMAR visual acuity threshold.	The median, monocular distance-corrected photopic intermediate visual acuity at 66cm is at least 0.2 logMAR.	The mean, monocular photopic best corrected distance acuity for the EDOF IOL is statistically non-inferior to the control using a non-inferiority margin of 0.1 logMAR.
---	---	--	---

a trifocal IOL.<sup>14</sup> For example, a study showed at one month—a point where neuroadaptation was still underway—Vivity had 85% of patients report little to no glare or halos compared with 69% of patients who had PanOptix. In a double-blinded prospective study comparing Symphony to Vivity, 60% of Vivity patients reported no glare compared to 88% of Vivity patients reporting no halo.

**Aphthera IOL (AcuFocus).** Previously known as IC-8, this is a new, small-aperture IOL that uses pinhole optics to provide an EDOF effect. Despite the lens having a small aperture (3.23mm circular mask with 1.36mm aperture), the mask has 3,200 microperforations to aid in minimizing any negative effect on field of vision.<sup>11</sup>

In clinical trials, this lens was implanted in the non-dominant eye (about -0.75D target), while the dominant eye had a traditional monofocal lens implanted.<sup>11</sup> At six months, the binocular average uncorrected distance visual acuity was 20/20, uncorrected intermediate visual acuity was 20/22 and uncorrected near was 20/31.<sup>11</sup> As expected, out of all the lenses Aphthera has the lowest risk of glare and halos. The best patient for this might be one who has an atypical cornea, such as a decentered LASIK ablation. The smaller aperture will decrease the overall aberrations and potentially provide better vision than they had previously achieved.

This lens has been used outside of the US in patients who would benefit from a smaller pupil size to reduce the effect of corneal aberrations. Notably, patients with a history of radial keratotomy, decentered photorefractive keratectomy or LASIK, aniridia or even keratoconus may potentially benefit from this lens.<sup>16</sup> Limitations include dimming of the

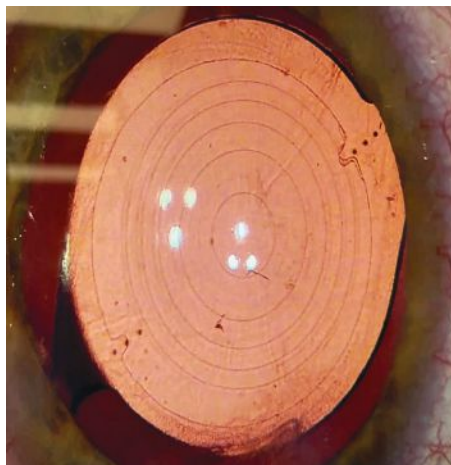
vision on the side where the Aphthera is implanted and the absence from the market of a toric version; however, the pinhole effect can “mask” around 1.5D of astigmatism.<sup>17</sup>

We tell EDOF patients they will still need reading glasses; we don't want to overpromise. There are plenty of surgical groups who will offset these EDOF IOLs; for example, plano target in the dominant eye and -0.75D sph target in the nondominant eye, to reduce the need for reading glasses.

Overall, the biggest benefit of EDOFs compared with traditional multifocals is the reduction in glare symptoms. Thus, if we have a patient who wants to minimize the chance of halos postoperatively, we lean towards an EDOF or an enhanced monofocal lens (more on this shortly).<sup>10</sup>

### Monofocal Plus IOLs

In order for a lens to earn the title of an EDOF, it must meet four of the



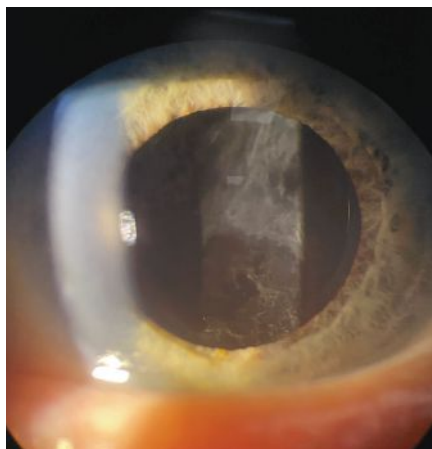
**The Ally femtosecond laser (LensAR) creates markings in the lens capsule to precisely place toric IOLs. Here, a toric trifocal lens was used. If a lens is rotated postoperatively, which usually is suspected with a residual mixed refraction, dilating the patient can help to evaluate the alignment of the toric IOL.**

American National Standard Institute (ANSI) criteria (*Table 1*). There are lenses such as the Tecnis Eyhance IOL (Johnson & Johnson Vision), whose EDOF that provides an add of 1.3D does not currently not meet the ANSI criteria.

The question then becomes, what do we call lenses that create some EDOF effect but are not enough to warrant the term EDOF by ANSI standards? Terms in the literature for these lenses include *monofocal-plus*, *enhanced monofocal* or *EDOF monofocal*. Other lenses that fit in this category are the Light Adjustable Lens (RxSight), RayOne EMV (Rayner), enVista IOL monofocal (Bausch + Lomb) and enVista Aspire IOL (Bausch + Lomb). We like to refer to these as monofocal-plus lenses to our patients.

Monofocal-plus IOLs lenses provide comparable distance visual acuity to a basic monofocal lens and improved intermediate visual acuity compared to a basic monofocal lens. The question is, do patients notice the difference in EDOF abilities between the monofocal plus lenses and the EDOF lenses? Three studies showed no significant differences for intermediate visual acuity between Eyhance and Vivity.<sup>20-22</sup> However, Eyhance was inferior to the EDOF lenses at near.

**Tecnis Eyhance IOL.** This is one of the most studied monofocal-plus lenses. Its unique design uses a modified anterior aspheric surface that leads to a progressive defocus of up to 1D. The advantage of Eyhance is its excellent distance vision with relatively good intermediate vision and a reduced risk of visual disturbances. Limitations for this lens, similar to the EDOF lenses, is the requirement for reading glasses for most near activities after surgery.



**Posterior capsular opacification can be seen in this image. In premium lenses, especially those correcting more than one vision zone such as an EDOF or trifocal lens, mild posterior capsular opacification can cause severe halo/glare effects.**

One study comparing Eyhance to Vivity looked at 76 eyes of 38 patients.<sup>20</sup> Uncorrected distance vision and uncorrected intermediate vision were comparable in both groups. The two groups had no difference between

halo and glare perception. However, Vivity provided better uncorrected near vision and higher spectacle independence for near vision. No difference in patient satisfaction was noted when comparing the lenses.

**Light-Adjustable Lens (LAL).** This IOL was approved by the FDA in 2017, and many doctors around the country have expressed their excitement for the lenses since then due to the ability to alter lens power after implantation.<sup>19</sup> The LAL offers the advantage of post-implantation adjustability, allowing for modifications of the patient's refraction using the Rx-Sight Light Delivery Device (LDD), wherein macromers within the lens can be precisely tuned using UV light delivered by the LDD device to achieve the targeted refraction.

For example, let's say you have a monovision patient who wants monovision after cataract surgery. One month after surgery, their distance eye is great with no complaints, but the patient desires more near vision. The

LAL has some EDOF technology in it, so we refer to this as a monofocal-plus lens, and you can actually induce more EDOF in the lens in the post-op adjustment by doing a specific light treatment.<sup>23</sup> Once the patient has a stable refraction, you can use the LDD to adjust the refraction from -1.25D sph to -1.75D sph to achieve the near vision the patient desires. After the patient is at their desired refractive status, the lens performance is locked in with the LDD.

The lock-in step of the Light-Adjustable Lens process uses the LDD to exhaust all macromers, thereby stabilizing the patient's refraction status and preventing subsequent changes. Before the lock-in step, the lens can be adjusted up to three times. In any given adjustment, the lens can be modified up to 2D of hyperopia, myopia or astigmatism.

Another example where the LAL could be used is a radial keratotomy patient or any post-refractive surgery patient.<sup>24</sup> These previous refractive

## Dos and Don'ts of Cataract Comanagement

By Katie Gilbert Spear, OD, JD, Pensacola, FL  
Assistant Professor at Nova Southeastern University

Comanagement has been, and continues to be, an integral part of many ODs' practices. It has become even more important as medical offices get busier and the ability to get patients into specialists like ophthalmologists in a timely manner becomes more challenging. A recent study projects that by 2035, the number of full-time ophthalmologists will decrease by 2,650, or 12%. However, 5,150 full-time ophthalmologists will be needed by 2035—an increase of 24%. This discrepancy results in a supply and demand mismatch of about 30%.<sup>1</sup> This shows that comanagement is needed now and will be needed even more in the future.

However, the comanagement relationship has come under scrutiny many times over the past two decades for potentially violating the Anti-Kickback Statute, which is a criminal statute that prohibits remuneration or payment of any kind in return for patient referrals or the generation of business that involves any service or item payable by federal health care programs. Recently, there have been high-profile cases settled against ophthalmologists for violating the Anti-Kickback Statute with the comanagement relationship being part of the complaints, along with claims of paying for expensive dinners, travel and entertainment.

The comanagement of patients is an essential and important part of patient care. As primary eyecare providers, optometrists know their patients well and understand their visual needs often

better than a surgeon, who only examines a patient briefly prior to surgery. Most patients desire to return to their optometrist as soon as they can because they either feel more comfortable in the office they are more familiar with or traveling to a specialist is burdensome. Regardless of the reasoning, many patients desire comanagement—and ODs desire to take care of their patients. So, considering the recent cases involving ophthalmologists and comanagement, how do we take care of patients and, at the same time, protect ourselves from potential issues with federal fraud and abuse laws? Let's start with the basics.

Comanagement is not illegal. What is illegal are relationships between optometrists and ophthalmologists that are labeled as "comanagement" but are in fact schemes to ensure optometrists will refer patients to ophthalmologists with the understanding that the ophthalmologist will, in return, comanage the patient regardless of the patient's clinical needs, consent or desire. In most situations, this is simply not the case. Most patients want to return to their optometrist for post-op and ongoing follow-up care. The reality is that a large number of patients are upset and annoyed that they must go back to the specialist for something that their family doctor of optometry can handle. However, rather than assume that every patient wants to be comanaged. Certain processes and procedures must be put in place to ensure the patient understands

procedures can make the postoperative refractive status less predictable. If a radial keratotomy patient ends up +2D sph or +3D sph one month postoperatively, if the LAL was used we will have a chance to achieve plano postoperatively through a series of LDD treatments without having to exchange the IOL.

This lens does have its own set of limitations, as it requires patients to wear specific UV-blocking glasses provided by RxSight in the post-op period. The lens must be worn while outdoors for the full length of postoperative care until the IOL is locked into place and can no longer be altered by UV light. The amount of time before the lens is locked in varies from patient to patient depending how many treatments are needed after surgery. This process can take anywhere from approximately one month to several months.

Many states and surgical practices have optometrists doing the post-op measurements and adjustments. One

open access center has two optometrists providing LAL postoperative care for 16 surgeons.<sup>25</sup> We only expect the role of the optometrist to increase in the LAL postoperative period.

As this article was under review, a new lens came out—the enVista Aspire (Bausch + Lomb), which “uses an optical modification of the posterior aspheric surface to create a small continuous increase in IOL power within the central 1.5mm diameter to slightly extend the depth of focus,” according to company literature.

We believe we will continue to see lenses that use spherical aberrations or lenses that slightly modify the central zone to provide more monofocal-plus or EDOF lens options.

### **Multifocals vs. EDOFs vs. Monofocal Plus**

Oftentimes when we are discussing lenses with patients, we come to the question, “Which lens is best for the patient—trifocal, EDOF or monofocal-plus?” We should first ask

what the patient is looking to achieve after surgery, then inquire about their personality and tolerance for possible halos after six months.

It’s good to keep a few facts and additional studies in mind when making this decision. First, a 2022 study looked at PanOptix and compared it to EDOF lenses such as Vivity, Symphony and Eyhance. There was no statistical difference between uncorrected binocular distance vision between any of the listed lenses.<sup>26</sup> Overall, these lenses have about the same distance vision if they are “on target,” meaning minimal to no residual refractive error, which means in a healthy eye, the amount of near vision demand, cost and tolerance to halos drive the lens type we choose. Secondly, some studies have shown EDOF lenses produce less dysphotopsias.<sup>14</sup> In one study, 85% of Vivity patients stated they had no or very little glare and halos compared to 69% of patients with PanOptix.<sup>14</sup>

Giving patients the ability to see at a distance and to be able to see the

comanagement and wants to move forward with it. This includes, among other things, written informed consent that educates the patient on comanagement, with the patient’s signature agreeing to such follow-up care by their doctor of optometry.

Not only should we not assume all patients want to be comanaged, we must also not assume every patient wants to go to one surgeon. Unless there is a clinical reason why a patient should only be referred to a specific surgeon, give the patient options. In my offices, I have several surgeons who I refer to and I ask the patient if they have a preference. If they don’t, then I ask if they have a preference of the location of the surgeon. Based on this and the clinical needs of the patient, I then make the referral with the proper documentation. The decision on where to refer the patient should never be made on whether the surgeon will comanage the patient. If the patient is comanaged, make sure you have the appropriate informed consent describing the patient’s options, any fees associated with comanagement and a transfer of care agreement between yourself and the surgeon.

Additionally, send a letter or your EMR notes with the patient that spell out to the surgeon what you talked to the patient about, what you recommended and what lens choice you think is best. For example, torics, multifocals, monovision or monofocals because they are fine wearing glasses, or whatever the circumstances may be.

Another potential issue with comanagement is fee splitting. When cataract patients are comanaged, insurers split the payments between the two doctors depending on when the patient returns to the comanaging optometrist. However, patients who opt for premium IOLs require more testing, education and follow-up,

and therefore pay an extra fee for these lenses and services.

The surgeon collects the additional payment from the patient on behalf of the optometrist, and if comanaged, pays the optometrist directly for their services in managing the patient. Even though the optometrist is providing additional services for the patient—which the patient has paid for—the fact that the surgeon, and not the patient, is paying the optometrist directly, invokes more scrutiny under the Anti-Kickback Statute. The fee should also be fair market value for the services and testing provided by the optometrist. Prior to surgery, the patient should be educated and given written documentation of the arrangement and all fees associated with the services, including the fees paid to the optometrist. The more transparency and education provided, the better.

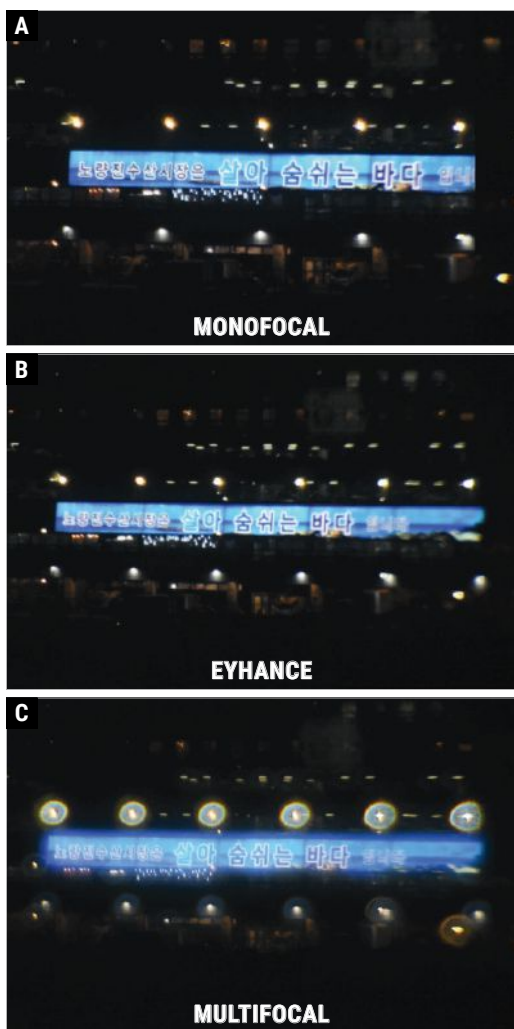
Comanagement is essential to patient care especially with the current scarcity of providers. Therefore, it is imperative that optometrists continue to provide this service for their patients, one that can only be done through strict compliant processes aligned with current laws.

1. Berkowitz ST, Finn AP, Parikh R, et al. Ophthalmology workforce projections in the United States, 2020 to 2035. September 20, 2023. Accessed November 19, 2023. [www.aojournal.org/article/S0161-6420\(23\)00677-2/pdf](http://www.aojournal.org/article/S0161-6420(23)00677-2/pdf).

2. Anti-Kickback Statute [42 U.S.C. § 1320a-7b(b)] (1972).

3. Ophthalmology practice agrees to pay over \$2.9 million to settle kickback allegations. U.S. Department of Justice. March 23, 2023. Accessed November 20, 2023. [www.justice.gov/usao-edtx/pr/ophthalmology-practice-agrees-pay-over-29-million-settle-kickback-allegations](http://www.justice.gov/usao-edtx/pr/ophthalmology-practice-agrees-pay-over-29-million-settle-kickback-allegations).

4. SouthEast Eye Specialists Pays \$17 million to Settle Anti-Kickback, False Claims Act Allegations. PR Newswire. May 1, 2023. Accessed November 20, 2023. [www.prnewswire.com/news-releases/southeast-eye-specialists-pays-17-million-to-settle-anti-kickback-false-claims-act-allegations-301812112.html](http://www.prnewswire.com/news-releases/southeast-eye-specialists-pays-17-million-to-settle-anti-kickback-false-claims-act-allegations-301812112.html).



**A recent study simulated images for patients when looking at a distance target at night. Oftentimes, visuals such as this can be helpful when describing to a patient what to expect postoperatively.**

EDOF and trifocal IOLs.<sup>26-28</sup> Ultimately, some doctors shy away from trifocals because of fear of halos, but these studies confirm what we see in clinical practice—patients do well with trifocal lenses. They also do well with EDOF lenses. As indicated by the study findings, patient contentment can be attained with any of these lens technologies, if expectations are effectively established and communicated.

**Takeaways**

Optometrists will continue to play a vital role in discussing the different types of IOL choices and setting expectations. By understanding the design philosophies and the clinical performance of newer IOLs, we can help guide patients toward the best visual outcome for each patient’s specific vision needs. With the advancements in scientific research, enhancements in intermediate vision have been achieved through the use of trifocal IOLs, trifocal-like IOLs, EDOF IOLs and monofocal-plus IOLs, offering the capacity to restore visual acuity in numerous patients and elicit a high level of satisfaction. ■

floor while walking or their computer with these EDOF or monofocal-plus lenses, with little to no side effects, is one of the biggest reasons these lenses have been taking the US and Europe by storm. If we have better options than just our traditional monofocal lenses, why not use them? In addition, many surgical groups have been doing blended vision or mini-monovision to provide these patients with more near vision. Typically, the dominant eye is targeted for plano and the non-dominant eye is targeted around -0.75D sph.

Interestingly, multiple recent meta-analyses have showed no difference in patient satisfaction or between

1. Rampat R, Gatinel D. Multifocal and extended depth-of-focus intraocular lenses in 2020. *Ophthalmology*. 2021;128(11):e164-85.
2. Zhu D, Ren S, Mills K, et al. Rate of complete spectacle independence with a trifocal intraocular lens: a systematic literature review and meta-analysis. *Ophthalmol Ther*. 2023;12(2):1157-71.
3. Pinheiro RL, Raimundo M, Gil JQ, et al. The influence of personality on the quality of vision after multifocal intraocular lens implantation. *Eur J Ophthalmol*. 2023;11206721231176313.
4. Kohnen T, Lwowski C, Hinzelmann L, et al. Presbyopia correction in astigmatic eyes using a toric trifocal intraocular lens with quadrifocal technology. *J Refract Surg*. 2020;36(10):638-44.
5. Ma J, Sun X, Liu Y, Liu Y. Observation of visual quality after femtosecond laser-assisted cataract surgery combined with trifocal intraocular lens implantation. *Comput Math Methods Med*. 2022(2):1-8.
6. Galvis V, Escaf LC, Escaf LJ. Visual and satisfaction results with implantation of the trifocal PanOptix intraocular lens in cataract surgery. *J Optom*. 2022;15(3):219-7.
7. Rosa AM, Miranda AC, Patrício MM, et al. Functional magnetic resonance imaging to assess neuroadaptation to multifocal intraocular lenses. *J Cataract Refract Surg*. 2017;43(10):1287-96.
8. Jeon S, Moon K, Kwon H. Long-term clinical outcomes after trifocal intraocular lens implantation: a retrospective observational study. *J Refract Surg*. 2023;39(4):236-41.
9. Łabuz G, Yan W, Baur ID, et al. Comparison of five presbyopia-correcting intraocular lenses: optical-bench assessment with visual-quality simulation. *J Clin Med*. 2023;12(7):2523.
10. Dick HB, Ang RE, Corbett D, et al. Comparison of three-month visual outcomes of a new multifocal intraocular lens vs a trifocal intraocular lens. *J Cataract Refract Surg*. 2022;48(11):1270-6.
11. Yan W, Łabuz G, Khoramnia R, Auffarth GU. Trifocal intraocular lens selection: Predicting visual function from optical quality measurements. *J Refract Surg*. 2023;39(2):111-8.
12. Moshirfar M, Stapley SR, Corbin WM, et al. Comparative visual outcome analysis of a diffractive multifocal intraocular lens and a new diffractive multifocal lens with extended depth of focus. *J Clin Med*. 2022;11(24):7374.
13. van der Mooren M, Alarcon A, Jenkins Sanchez MD, Chang DH. Effect of violet light-filtering and manufacturing improvements in an extended depth-of-focus IOL on visual performance. *Clin Ophthalmol*. 2023;17:701-9.
14. Hovanesian JA, Jones M, Allen Q. The Vivity extended range of vision IOL vs the PanOptix trifocal, ReSTOR 2.5 active focus and ReSTOR 3.0 multifocal lenses: a comparison of patient satisfaction, visual disturbances and spectacle Independence. *Clin Ophthalmol*. 2022;16:145-52.
15. IC-8 Aphera Intraocular Lens - P210005. FDA.gov. July 22, 2022. Accessed September 2023. [www.accessdata.fda.gov/cdrh\\_docs/pdf21/P210005B.pdf](https://www.accessdata.fda.gov/cdrh_docs/pdf21/P210005B.pdf).
16. Sánchez-González JM, Sánchez-González MC, De-Hita-Cantalejo C, et al. Small aperture IC-8 extended depth-of-focus intraocular lens in cataract surgery: a systematic review. *J Clin Med*. 2022;11(16):4654.
17. Ang RE. Small-aperture intraocular lens tolerance to induced astigmatism. *Clin Ophthalmol*. 2018;12:1659-64.
18. Guarro M, Sararols L, Londoño GJ, et al. Visual disturbances produced after the implantation of three extended depth-of-focus intraocular lenses vs one monofocal intraocular lens. *J Cataract Refract Surg*. 2022;48(12):1354-9.
19. Fernández J, Rocja-de-Lossada C, Zamorano-Martin F, et al. Positioning of enhanced monofocal intraocular lenses between conventional monofocal and extended depth-of-focus lenses: a scoping review. *BMC Ophthalmol*. 2023;23(1):101.
20. Sabur H, Unsal U. Visual outcomes of non-diffractive extended depth-of-focus and enhanced monofocal intraocular lenses: a case-control study. *Eur J Ophthalmol*. 2023;33(1):262-8.
21. Lee JH, Moon SY, Chung HS, et al. Clinical outcomes of a monofocal intraocular lens with enhanced intermediate function compared with an extended depth-of-focus intraocular lens. *J Cataract Refract Surg*. 2022;48:61-6.
22. Jeon YJ, Yoon Y, Kim T, Koh K. Comparison between an intraocular lens with extended depth-of-focus (Tecnis Symfony ZXR00) and a new monofocal intraocular lens with enhanced intermediate vision (Tecnis Eyhance ICB00). *Asia Pac J Ophthalmol*. 2021;10:542-7.
23. Villegas EA, Alcon E, Mirabet S, et al. Extended depth of focus with induced spherical aberration in light-adjustable intraocular lenses. *Amer J Ophthalmol*. 2014;157(1): 142-9.
24. Wong JR, Folden DV, Wandling GR, et al. Visual outcomes of a second-generation, enhanced UV protected light adjustable lens in cataract patients with previous LASIK and/or PRK. *Clin Ophthalmol*. 2023;17:3379-87.
25. Folden DV, Wong JR. Visual outcomes of an enhanced UV protected light adjustable lens using a novel co-managed, open-access methodology. *Clin Ophthalmol*. 2022;16:2413-20.
26. Puig M, Salem Y, Morrow M, Waldman C. Comparison of outcomes of trifocal and extended depth-of-focus intraocular lenses. *Invest Ophthalmol Vis Sci*. 2022;63:1706-F0024.
27. Zhong Y, Wang K, Yu X, et al. Comparison of trifocal or hybrid multifocal extended depth-of-focus intraocular lenses: a systematic review and meta-analysis. *Sci Rep*. 2021;11(1):6699.
28. Karam, M, Alkhowaiter N, Alkhabbaz A, et al. Extended depth-of-focus versus trifocal for intraocular lens implantation: an updated systematic review and meta-analysis. *Amer J Ophthalmol*. 2023;251(5).

# SECO2024

THE EDUCATION DESTINATION™  
FEBRUARY 28 – MARCH 3, 2024

TITLE PARTNER

## BAUSCH+LOMB

UNLOCK A WORLD OF LEARNING AT SECO 2024

# REGISTRATION NOW OPEN

Doctors can attend all five days and earn up to 36 hours of CE, or up to 20 hours over the weekend!



**SURGICAL & AESTHETICS  
SKILLS EDUCATION  
PAVILION**

Developed in partnership with the American Society of Optometric Surgeons, this dedicated pavilion in Optometry's Marketplace Exhibit Hall will feature a variety of hands-on experiences designed to familiarize or update attendees with a variety of surgical, laser and aesthetic procedures.



**SPECIAL  
SESSIONS**

These dynamic sessions provide an unmatched platform where attendees have the unique opportunity to learn from industry pioneers.



SECO is excited to once again present a series of Certificate Programs in 2024. These programs validate your commitment to continuous learning by acknowledging your mastery of specific subjects, as you accumulate essential course hours.

## Optometry's Marketplace™ Exhibit Hall

### The Launchpad for Tomorrow's Eye Care Innovations

Gain a first-hand view of tomorrow's breakthroughs in the Optometry's Marketplace™ Exhibit Hall. Propel your learning from our educational sessions into tangible action by making informed purchases. Engage in one-on-one discussions, witness live demonstrations, and attend special presentations directly on the exhibition floor.

THE  VIEW  
LUXURY EYEWEAR

Step into the world of luxury eyewear with The View, SECO's exclusive eyewear pavilion. Showcasing an array of innovative, fashionable, and luxury eyewear lines from around the globe.

Don't miss out on the chance to be part of one of the most anticipated eye care events of the year. Register now and secure your place at SECO 2024, where education, innovation, and community come together.



**REGISTER BEFORE JANUARY 20, 2024 TO TAKE ADVANTAGE OF OUR EARLY BIRD DISCOUNTS!**

**REGISTER TODAY AT [ATTENDSECO.COM](https://attendseco.com)**



SOUTHERN COUNCIL OF OPTOMETRISTS  
WORLD-CLASS EDUCATION FOR OPTOMETRY



# Ischemic Retinal Ordeal

*Neovascular glaucoma requires prompt and aggressive management of IOP and VEGF production.*

**A** 61-year-old male presented with blurred distance and near vision in the left eye with occasional dull ache for about one month. He had a history of glaucoma, diabetes mellitus type 2, hypercholesterolemia, and a reported minor stroke 10 years prior. He advised that he was prescribed an eye drop with a teal cap to use in each eye, but admittedly, had not been using it consistently and had been lost to follow-up from the prescribing physician. His pinhole visual acuity was 20/20 OD and 20/400 OS with afferent defect in the left eye. His left eye was diffusely hyperemic with moderate stromal edema, but without microcystic corneal edema. There was neovascularization of the left iris and a rare cell in the anterior chamber, but no hyphema. Intraocular pressures (IOPs) were 30mm Hg OD and 47mm Hg OS.

The right anterior chamber angle was open to posterior trabecular meshwork 360° with 1+ trabecular meshwork pigment and a flat iris approach without peripheral anterior synechiae, angle recession or neovascularization of the angle. In the left anterior chamber angle, anterior trabecular meshwork could be visualized 270° with no structures visible temporally. With compression, neovascularization was present temporal and inferior with peripheral anterior synechiae superiorly. Optic discs were sharp and pink, with inferior notching of the right neuroretinal rim and significant inferior and superior neuroretinal rim loss in the left eye. The right macula was unremarkable. The left macula was

diffusely irregular with few intraretinal hemorrhages scattered through the posterior pole and macula. Retinal arterioles were symmetrically attenuated, with increased venular dilation and tortuosity in the left eye. The retinal periphery was unremarkable in each eye.

## Sequelae of Ischemia

Neovascular glaucoma (NVG) is a result of chronic posterior segment ischemia, most commonly caused by proliferative diabetic retinopathy, retinal vaso-occlusive disease and ocular ischemic syndrome.<sup>1,2,3</sup> It is estimated to account for between 4% and 6% of all glaucoma diagnoses in Romania and China, with proliferative diabetic retinopathy as its leading cause.<sup>4,5</sup> Most patients who present with NVG do so late in the disease course with profound vision loss and ocular pain, but a progressive spectrum of disease exists beginning with early, asymptomatic neovascularization of the iris or angle without elevated IOP.<sup>1,2</sup>

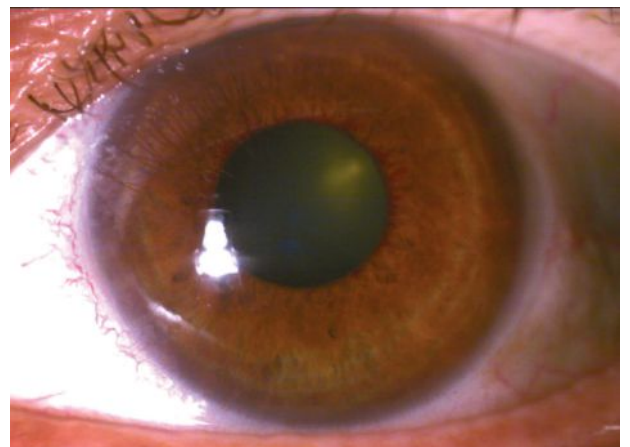
Iris neovascularization occurs in response to upregulation of a host of growth factors and inflammatory cytokines produced in response to oxidative stress, including vascular endothelial growth factor-A (VEGF-A) and erythropoietin in the anterior chamber due to chronic posterior segment ischemia,

which drives new blood vessel formation.<sup>1,3,6</sup> Early rubeosis may be visualized at the pupillary margin and base of the iris.

With progression, fibrovascular tissue extends through the anterior chamber angle, across the ciliary body band and trabecular meshwork. At this point, even without secondary angle closure, IOP increases due to reduced aqueous outflow. Increased inflammatory mediators drive synechial angle closure and posterior synechiae formation, and the fibrous scaffold that neovascular vessels use to advance through the angle mature and contract, zipping the angle closed in the process. This ultimately results in further release of pro-inflammatory cytokines, secondary angle closure, significant elevation in IOP and glaucomatous optic neuropathy.<sup>1-3</sup>

## Treatment

Goals of NVG therapy are twofold: to manage IOP and to reduce retinal ischemia and VEGF production.<sup>1-3,7</sup> The prognosis of NVG is generally poor with a recent study reporting 74% of patients diagnosed with NVG due to central retinal vascular occlusion had counting fingers or worse vision regardless therapy or

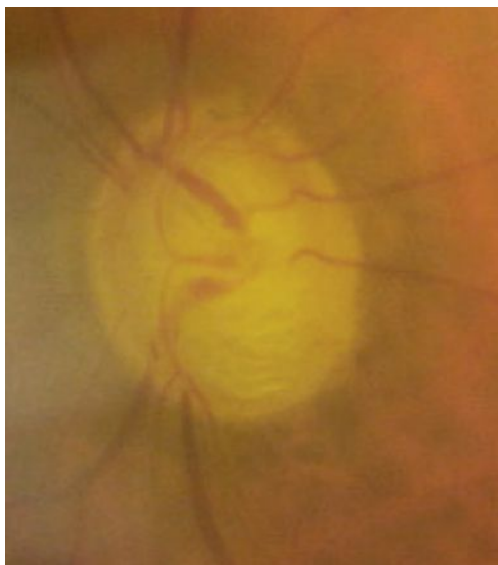


**Peripupillary iris neovascularization.**

### About Dr. Steen

**Dr. Steen** is an associate professor at Nova Southeastern University College of Optometry, where she serves as director of the Glaucoma Service, coordinator of the Primary Care with Emphasis in Ocular Disease Residency and teaches courses in glaucoma and ocular pharmacology. Her financial disclosures include Bausch + Lomb, Santen, Ocuphire, Carl Zeiss Meditec, Oyster Point Pharma, Ocuterra, Peripherex, Clearside Biomedical, Allergan, Iveric Bio, Alcon and Thea Pharma.





**Advanced glaucomatous optic neuropathy due to NVG two months following initial presentation.**

combination of therapy through five years of follow-up.<sup>7</sup> Considering the advanced optic neuropathy and vision loss often observed at initial presentation, the long-term practical goals of therapy are to prevent or improve severe ocular discomfort and to preserve any remaining visual function.<sup>1,2</sup>

Initial medical management of NVG is aimed at reducing IOP, as well as improving corneal clarity and patient comfort. IOP-lowering therapies that reduce aqueous production: beta-blockers, carbonic anhydrase inhibitors and alpha adrenergic agonists are generally our first-line choices, often in combination due to the significant IOP-lowering effect called for.<sup>1-3</sup> Despite their pro-inflammatory potential, prostaglandin analogs can also be considered as adjunctive therapy and have been demonstrated to have clinical effect in eyes with even complete synechial angle closure.<sup>8</sup> Pilocarpine should be avoided due to its ability to exacerbate angle closure and increase inflammation.<sup>1</sup> A strong topical steroid, prednisolone acetate 1% or difluprednate 0.05%, and a strong cycloplegic agent, atropine 1%, will help reduce inflammation and prevent ciliary spasm to improve comfort.<sup>1,3</sup>

Panretinal photocoagulation (PRP) aims to reduce ischemic stress and production of pro-angiogenic proteins

through destruction of retinal tissue.<sup>1,6</sup> Clear media is a requirement for PRP, and in individuals with vitreous hemorrhage or who have significant corneal edema, PRP will not be pursued until the media clears. While an effective therapy in reducing oxygen demand, and therefore oxidative stress, regression of abnormal new vessels may take four to six weeks, leaving a window for further disease progression and vision loss without adjunctive therapy.<sup>6</sup>

Anti-VEGF therapies in NVG treatment have shown to regress iris neovascularization and reduce IOP within days of injection, but have a short duration of action.<sup>6</sup>

Aqueous samples of patients with NVG contained approximately three-fold higher VEGF-A levels, and two-fold higher IL-8 levels in patients with newly diagnosed NVG in comparison to those following treatment (PRP, with or without intravitreal bevacizumab) and who were determined to be clinically stable.<sup>6</sup> VEGF-A and IL-8 levels were found to be positively correlated with IOP; that is, in NVG, eyes with higher IOP had higher levels of aqueous VEGF-A and IL-8.<sup>6</sup> Due to the central mechanistic but temporary effect of anti-VEGF agents in NVG management, they are most likely currently provided as initial retinal therapy for neovascular regression and are followed by PRP or other surgical procedures.<sup>9,10</sup>

Once the source of the retinal ischemia and underlying systemic risk factors have been managed, long-term treatment shifts back to managing IOP to preserve any remaining functional vision and to reduce ocular discomfort. Topical therapy alone may not be sufficient, and incisional filtration or aqueous shunt procedures may be necessary. For patients who have no visual potential and severe ocular discomfort, retrobulbar alcohol injection or enucleation are additional strategies that reflect the severity of the condition and the profound long-term discomfort which individuals may experience.<sup>1</sup>

## Bottom Line

Based on the NVG diagnosis of the left eye secondary to presumed retinal vascular occlusion and primary open-angle glaucoma of the right eye, our patient was prescribed dorzolamide-timolol fixed combination BID in each eye and latanoprost 0.005% QHS in each eye along with prednisolone acetate 1% QID OS and atropine 1% QD OS. Next-day retinal consultation was arranged, as was follow-up with his internist and a plan for continued care in our office of his primary open-angle glaucoma. At his initial visit with a retinal specialist approximately one week later, he received an intravitreal bevacizumab injection and was scheduled for PRP.

Identification of risk factors for the development of NVG, early recognition of anterior segment neovascularization and prompt, aggressive therapy and coordination of care is the core to preserving vision, where possible, and limiting ocular discomfort associated with the disease process and its underlying cause. ■

1. Sivak-Callcott JA, O'Day DM, Gass JD, et al. Evidence-based recommendations for the diagnosis and treatment of neovascular glaucoma. *Ophthalmology*. 2001;108(10):1767-76.

2. Havens SJ, Gulati V. Neovascular glaucoma. *Dev Ophthalmol*. 2016;55:196-204.

3. Tang Y, Shi Y, Fan Z. The mechanism and therapeutic strategies for neovascular glaucoma secondary to diabetic retinopathy. *Front Endocrinol (Lausanne)*. 2023;14:1102361.

4. Liao N, Li C, Jiang H, et al. Neovascular glaucoma: a retrospective review from a tertiary center in China. *BMC Ophthalmol*. 2016;16:14.

5. Mocanu C, Barăscu D, Marinescu F, et al. Glaucomul neovascular—studiu clinic retrospectiv [Neovascular glaucoma—retrospective study]. *Oftalmologia*. 2005;49(4):58-65.

6. Sun C, Zhang H, Tang Y, et al. Aqueous inflammation and ischemia-related biomarkers in neovascular glaucoma with stable iris neovascularization. *Curr Eye Res*. 2020;45(12):1504-13.

7. Casselholm de Salles M, Lindberg C, Epstein D. Neovascular glaucoma in patients with central retinal vein occlusion: a real-life study in the anti-VEGF era. *Acta Ophthalmol*. 2021;99(1):e7-12.

8. Vyas P, Naik U, Gangaiah JB. Efficacy of bimatoprost 0.03% in reducing intraocular pressure in patients with 360° synechial angle-closure glaucoma: a preliminary study. *Indian J Ophthalmol*. 2011;59(1):13-6.

9. Rittiphairoj T, Roberti G, Michelessi M. Anti-vascular endothelial growth factor for neovascular glaucoma. *Cochrane Database Syst Rev*. 2023;4(4):CD007920.

10. Ramji S, Nagi G, Ansari AS, et al. A systematic review and meta-analysis of randomised controlled trials in the management of neovascular glaucoma: absence of consensus and variability in practice. *Graefes Arch Clin Exp Ophthalmol*. 2023;261(2):477-501.

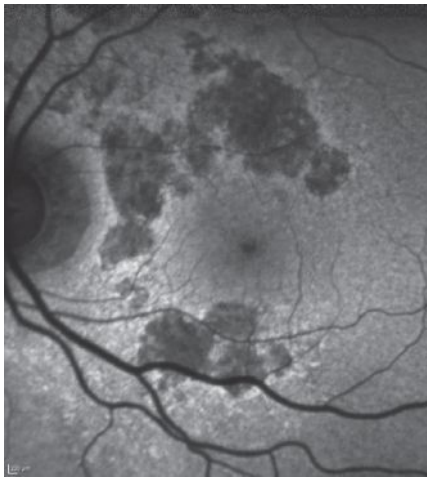


BY JAMES L. FANELLI, OD

## GLAUCOMA GRAND ROUNDS

# AMD Plus Glaucoma: Double Jeopardy

*Having both conditions can make it more difficult to determine the causes of changes seen in our testing.*



**Fig. 1. Fundus autofluorescence of the patient's left macula. Hypofluorescent areas are surrounding, but not involving, the foveal avascular zone, especially above the horizontal raphe. The patient maintains good visual acuity at 20/40 in this eye.**

As the patient population ages, the incidence of AMD increases with it. The combination of glaucoma with age-related macular degeneration (AMD) poses a challenge for us to preserve vision, although strides are always being made, like with the two recently approved medications for treatment of geographic atrophy (GA). As you know, GA is a progressive form of dry AMD, accounting for about 10% of dry AMD cases. Here is a case of an 82-year-old Caucasian woman with both advanced glaucoma and fortunately stable GA.

### Case

Last seen in October 2023, this pleasant 82-year-old patient was being medicated with 0.5% timolol QAM OU and generic latanoprost QHS OU. She had been on this regimen for the past six years and was maintaining good control of her glaucoma.

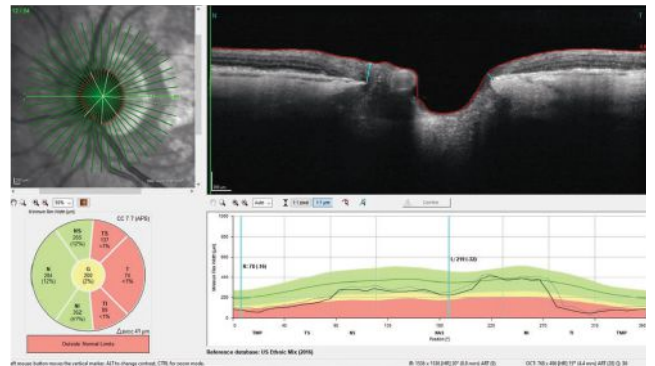
She had come to me several years prior as a new patient who carried a diagnosis of open-angle glaucoma, for which she had been medicated with Lumigan (bimatoprost, AbbVie) HS OU. Ultimately, due to increasing ocular surface issues as well as medication cost increases, we decided on the combination of latanoprost and timolol.

At the current visit, her medications included simvastatin, atenolol, metformin, amlodipine, Prozac (fluoxetine hydrochloride, Eli Lilly), lomitol and both ibuprofen and Flonase on a PRN basis with her reporting no allergies any medications. Best-corrected visual acuities were 20/40 OU through hyperopic astigmatic correction. Pupils were ERRLA with no afferent pupillary defect and extraocular movements were full in all positions of gaze.

The anterior segment evaluations at the patient's most recent visit were essentially unremarkable, though she has had the occasional bout of seborrheic blepharitis. Her corneas were clear, as were the anterior chambers. Angles were wide open in both eyes, as the patient was pseudophakic OU, having undergone cataract surgery five years earlier.

Through dilated pupils, I could see that her intraocular lenses were clear and centered and the posterior capsules were open. Bilateral posterior vitreous detachments were present. Her cup-to-disc ratio was 0.85x0.9 OD and 0.7x0.85 OS; both temporal neuroretinal rims were thinned and no disc hemorrhages were present. The retinal vasculature was slightly attenuated and there was mild arteriosclerosis noted.

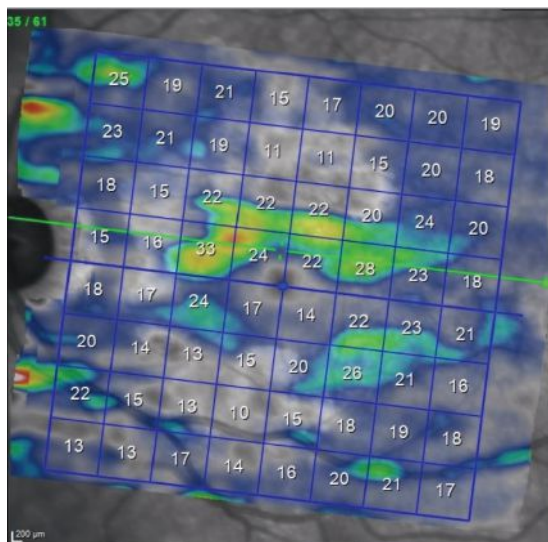
Both her maculae were characterized by GA, fortunately in a pattern encircling the foveal avascular zone but not extending into it; there were some drusen subfoveally OU but there was no evidence of choroidal neovascularization. The peripheral retinal examinations were essentially unremarkable, apart from reticular degeneration (Figure 1).



**Fig. 2. BMO-MRW measurements of the left neuroretinal rim. Note, especially inferotemporally, the erosion of the neuroretinal rim, which accounts for her superior nasal step field defect in the same eye.**

About Dr. Fanelli

Dr. Fanelli is the founder and director of the Cape Fear Eye Institute in Wilmington, NC. He is chairman of the EyeSki Optometric Conference and the CE in Italy/Europe Conference. He is an adjunct faculty member of PCO, Western U. and UAB School of Optometry. He is on advisory boards for Heidelberg Engineering and Glaukos.



**Fig. 3. OS macular ganglion cell layer thickness map. Note the paucity of the ganglion cell thickness below the horizontal raphe. This reduction in ganglion cells correlates well with the superior arcuate scotoma seen on the visual field. Note in Figure 1 the asymmetry between the superior and inferior hemispheres related to the GA; of particular importance, the GA is less evident inferiorly than superiorly, enabling us to isolate glaucomatous damage to the ganglion cell layer due to glaucoma rather than AMD.**

## Discussion

With advanced glaucoma at this stage, tight intraocular pressure (IOP) control is essential to preserve her remaining vision. Her pachymetry readings were 531 $\mu$ m OD and 540 $\mu$ m OS, and her treated IOPs over the last three years had averaged 11mm Hg OD and 12mm Hg OS. Her OCTs from a glaucoma perspective had remained stable with stable neuroretinal rims (BMO-MRW), retinal nerve fiber layer (RNFL) thicknesses in the circumpapillary region and ganglion cell macular evaluations. All were thin or reduced due to her advanced glaucoma, but they remained steady where they were.

What was somewhat different over the last four years were changes associated with AMD. Namely, the central subfoveal drusen had slightly increased over this period and the GA changed minimally over the same period. *Figure 2* shows the thinned neuroretinal rim of her left eye.

At this point, you're likely wondering about her visual fields: Were they stable?

What did they look like? As you can imagine, the fields were consistent with both advanced glaucomatous damage and central disruption owing to the AMD.

In cases like this, it can be difficult to sort out what part of the visual fields are related to AMD and, in particular, what part of the fields are indicative of glaucomatous loss involving fixation, or at least close to fixation. If you have been following a patient for many years, it is somewhat easier to see visual field changes over time correlated with posterior pole changes, as well as be better able to sort out worsening due to AMD, glaucoma or both. When I initially saw this patient, her fields were a mix of both types for field loss.

Glaucomatous field loss is rather predictive as the disease worsens, whereas

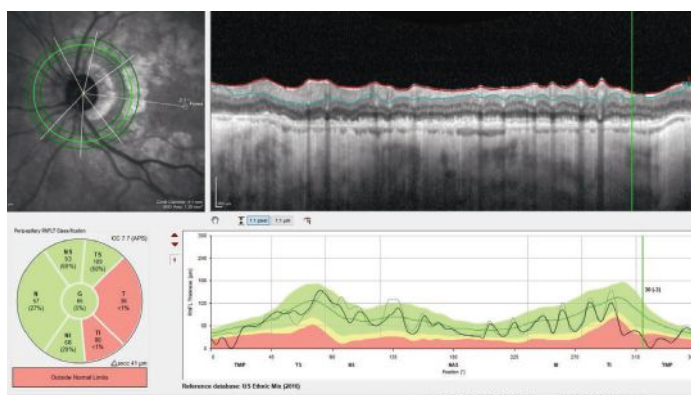
field loss due to AMD tends to vary. She does in fact have superior arcuate field defects, which do correlate to her neuroretinal rim findings and a visible nasal step in the left eye; however, central fields (within the central 10°) do show more defects associated with AMD than with glaucoma. Overall, it is difficult, if not impossible, to sort out which defects centrally are due to which disease. Fortunately, the patient does maintain relatively good visual acuity OU. At the end of the day, the visual fields can be difficult to dissect in cases like this.

That said, her fundus images fortunately show that the GA is in a perifoveal region and was

relatively stable over the past couple years. Neither the glaucoma nor the AMD will “get better,” as we know; the challenge is determining which, if either, are progressing. Luckily, the patient's macular ganglion scan correlates nicely with the glaucomatous damage (*Figure 3*) more so than the GA-related damage as seen in *Figure 1*. This helps tremendously in sorting out damage due to glaucoma vs. AMD. Further complicating interpretation, sometimes GA can interfere with RNFL analysis, too (*Figure 4*).

While there are current guidelines for administering the recently approved GA medications, those guidelines will invariably change once more patients have been treated. In this patient's case, she may very well be a good candidate for earlier intervention with these agents, given the advanced state of her glaucoma. We regularly use fundus autofluorescence in all our patients with geographic atrophy; this has a highly predictive benefit of identifying areas of GA more likely to progress. Should her FAF images indicate any move toward central macular progression, she'd be evaluated for possible treatment.

In the interim, serial IOPs, OCT scans and visual fields are still the standard, but at least we now have another tool in our toolbox to help preserve vision; in this case, agents to slow the GA progression. Close monitoring of patients on one of these therapies by a retina subspecialist is critical, as is monitoring done by you and I. ■



**Fig. 4. The RNFL circle scan of the left eye. Note that GA particularly can sometimes interfere with thickness readings of the RNFL if the circle scan encompasses areas affected by GA.**



EDITED BY DEREK N. CUNNINGHAM, OD,  
AND WALTER O. WHITLEY, OD, MBA

## SURGICAL MINUTE

# Step into the Vitreous

*Get to know this minimally invasive floaters procedure.*

BY JEFF BANAS, OD, AND JESSICA SCHIFFBAUER, OD  
KENOSHA, WI

**M**ost of us likely have at least one patient on a daily basis complain about floaters, such as black spots, bugs, spider webs and strings. These are frustrating symptoms that can be detrimental to a patient's quality of life. The last thing they want to hear is, "Your brain will get used to them."

Through the years, there has been more emphasis on treatment for this nuisance. While vitrectomy and vitreolysis are commonly used, there is another treatment available known as 1-Step limited vitreous removal (Vista Ophthalmics).

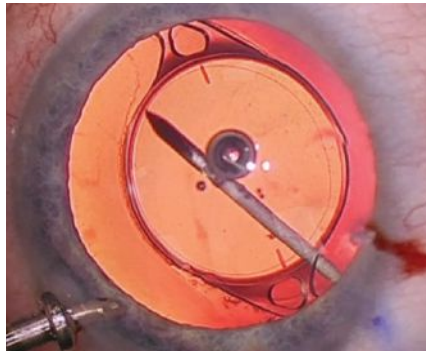
## Candidates

At this time, 1-Step is only approved in patients that are pseudophakic. While it is possible to perform in those with retinal pathology, it is best to avoid in patients with lattice degeneration, a history of retinal breaks, tears or holes or with an epiretinal membrane. Patients should be symptomatic for at least four months. Those with a new-onset posterior vitreous detachment should wait at least four to six months to prevent further traction on the retina. Make sure to perform a dilated eye exam to rule out any pathology.

## Procedure

1-Step can be performed in an office-based surgical suite with oral anesthe-

For a video of the procedure, read this article online at [www.reviewofoptometry.com](http://www.reviewofoptometry.com).



**1-Step limited vitreous removal allows surgeons to remove a significant portion of the vitreous without viscoelastic or sutures.**

sia and topical lidocaine. A single-use 27-gauge needle vitrector is used. With a typical vitrectomy, there is a three-port system. The vitrectomy probe is intended to remove the vitreous and dissect the tissue by vitreous aspiration and cutting.

Silk 6-0 sutures are placed to help keep the eye stable, in primary position and provide counter traction. A 1mm paracentesis is made through the clear cornea and preservative-free lidocaine is instilled into the anterior chamber. Then, the anterior chamber maintainer is inserted through the paracentesis wound. About 3.5mm from the limbus in the superior or inferior temporal region, the 1-step vitrector is inserted into the vitreous cavity in perpendicular fashion to the globe. The irrigation is set to about 60mm Hg to keep the globe formed. The liquified vitreous opacities come to the tip of the vitrector using low (100mm Hg or less) vacuum. The cut rate is defined by the phaco machine, typically ranging from 5,000 to 15,000

cuts per minute. The vitrector is kept in the middle of the anterior vitreous, and due to the length, it cannot reach the other side or posterior pole.

After a few minutes, once the view is clear, the irrigation is decreased and the 1-step vitrector is removed. The surgeon then checks for a leak, removes the anterior chamber maintainer and hydrates all wounds. Lastly, a subconjunctival injection of gentamicin and dexamethasone is completed.

## Post-operation

Patients are seen on the same day, one day, one week and one month post-op, and are on a combination drop of an antibiotic and steroid for one month. At each of these visits, visual acuity, IOP, aberrometry, dilated fundus exam and fundus photos are performed. Eyes are usually quiet but may experience a temporary IOP spike and can be treated with topical and/or oral ocular hypertensive medications.

Many who underwent 1-Step limited vitreous removal previously underwent vitreolysis treatments. While the risk is very low with 1-Step, as the vitreous being removed is primarily anterior and low vacuum, there is the chance of retinal breaks, holes and/or detachments.

A majority of our patients reported their floater symptoms have resolved and described the experience as life-changing. Seeing such incredible improvement reminds us how important it is to educate patients about all of the floater treatments available. ■

## ABOUT THE AUTHORS



**Dr. Banas** practices at The Eye Centers of Racine and Kenosha in Kenosha, WI. He is a key opinion leader for Alcon, Ziess and New World Medical. **Dr. Schiffbauer** practices at The Eye Centers of Racine and Kenosha in Kenosha, WI.

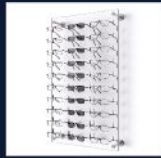
About Drs.  
Cunningham and Whitley

**Dr. Cunningham** is the director of optometry at Dell Laser Consultants in Austin. He has no financial interests to disclose. **Dr. Whitley** is the director of professional relations and residency program supervisor at Virginia Eye Consultants in Norfolk, VA. He is a consultant for Alcon.

**Merchandise Offered**

# FRAME DISPLAYS & OPTICAL INTERIORS

FrameDisplays.com is the one-stop-shop for all your optical displays, furniture, and design needs.



Wall Mount



Counter Top



Locking Rods



Trays & Frame Bags



Custom Frame Rods



Optical Cabinets




1-877-274-9300 • www.framedisplays.com



Trusted by more than 40,000 eye care professionals worldwide.

## COMPLIMENTARY DESIGN SERVICES



**Complimentary  
Zoom Design  
Session**



**0% Financing  
& Interest for  
36 Months\***

**Practice For Sale**



Practice Sales • Appraisals • Consulting  
www.PracticeConsultants.com

**PRACTICES FOR SALE  
NATIONWIDE**

Visit us on the Web or call us to learn more about our company and the practices we have available.

info@PracticeConsultants.com  
**925-820-6758**

[www.PracticeConsultants.com](http://www.PracticeConsultants.com)

Targeting Optometrists?

**CLASSIFIED ADVERTISING WORKS**

- JOB OPENINGS
- CME PROGRAMS
- PRODUCTS & SERVICES
- AND MORE...

Contact us today for classified advertising:  
Toll free: **888-498-1460**  
E-mail: [sales@kerhgroup.com](mailto:sales@kerhgroup.com)

# Do you have CE Programs?

## CONTACT US TODAY FOR CLASSIFIED ADVERTISING

**Toll free:  
888-498-1460**

**E-mail:  
[sales@kerhgroup.com](mailto:sales@kerhgroup.com)**



# Scarred Vision

*Inhaling a fungus may have led to this patient's infection.*

**A** 57-year-old Peruvian female presented with painless decrease in vision OD for one month. She reported a similar decline in vision in the same eye one year prior that was treated with intravitreal injections. Past medical, social and family histories were unremarkable. VA was 20/100 OD and 20/20 OS with no pinhole improvement. Pupils were equally round and reactive without a relative afferent pupillary defect, confrontation visual fields were full OU and extraocular motilities were full OU. IOP was 13mm Hg OD and 12mm Hg OS. Slit lamp exam was unremarkable.

## Take the Retina Quiz

1. *This patient's condition is most likely related to which organism?*

- a. *Borrelia burgdorferi*.
- b. *Histoplasma capsulatum*.
- c. *Toxocara canis*.
- d. *Toxoplasma gondii*.

2. *Which of the following findings would NOT be consistent with this patient's diagnosis?*

- a. Macular neovascularization (MNV).
- b. Midperipheral or peripheral atrophic chorioretinal lesions.
- c. Peripapillary atrophy.
- d. Vitritis.

3. *The causative organism is endemic to which of the following places?*

- a. Central America.
- b. South America.
- c. United States.
- d. All of the above.

4. *What is the most appropriate treatment for the acute management of this patient?*

- a. Intravitreal anti-vascular endothelial growth factor (VEGF).
- b. Intravitreal triamcinolone and oral prednisone.
- c. Laser photocoagulation.
- d. Photodynamic therapy.

5. *Which of the following is true?*

- a. Aggressive oral prednisone is necessary during the acute phase to minimize ocular sequelae.
- b. Moderate systemic signs and symptoms requires systemic treatment.
- c. Patients may contract this condition from soil contaminated by canine feces.
- d. Vision loss is primarily due to MNV, not direct chorioretinal inflammation.

*For answers to the quiz, see page 82.*

## Diagnosis

Fundus exam disclosed mild peripapillary atrophy OD, atrophic chorioretinal lesions dispersed throughout the midperipheral and peripheral fundus OU (only partially pictured OS) and subretinal fibrovascular membrane with accompanying subretinal fluid and hemorrhage OD (Figures 1 and 2). OCT confirmed subretinal fluid and hyperreflective material as well as a subretinal pigment epithelial hyperreflective lesion OD; macular OCT was normal OS (Figures 3 and 4).

The constellation of findings in a patient from a known endemic region

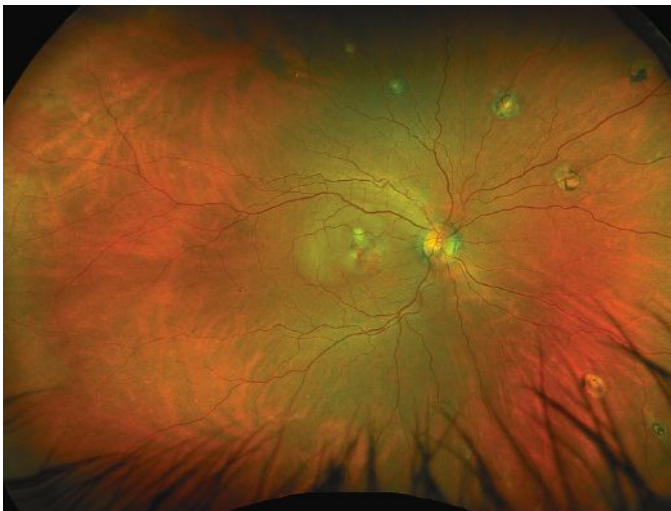

Fig. 1. Optos ultrawidefield fundus photo of the right eye.

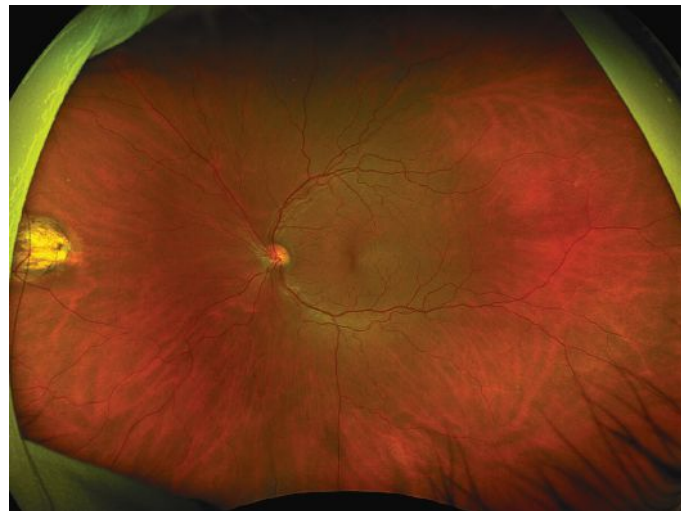


Fig. 2. Optos ultrawidefield fundus photo of the left eye.

About  
Dr. Aboumourad

Dr. Aboumourad currently practices at Bascom Palmer Eye Institute in Miami. He has no financial disclosures.

Medscape **LIVE!**

Presents

# Save the Date

## 2024 CE CONFERENCES


IN-PERSON 

*Review of Optometry*<sup>®</sup>  
presents a collaboration between



Spring | May 17–19, 2024

Fall | November 15–17, 2024



December 6–7, 2024

THE OPTOMETRIC RETINA SOCIETY AND REVIEW EDUCATION GROUP PRESENT

**RETINAUPDATE2024**

December 7–8, 2024

Locations to be announced.

Scan the QR Code or visit [www.reviewedu.com/events](http://www.reviewedu.com/events)  
for information as it becomes available.



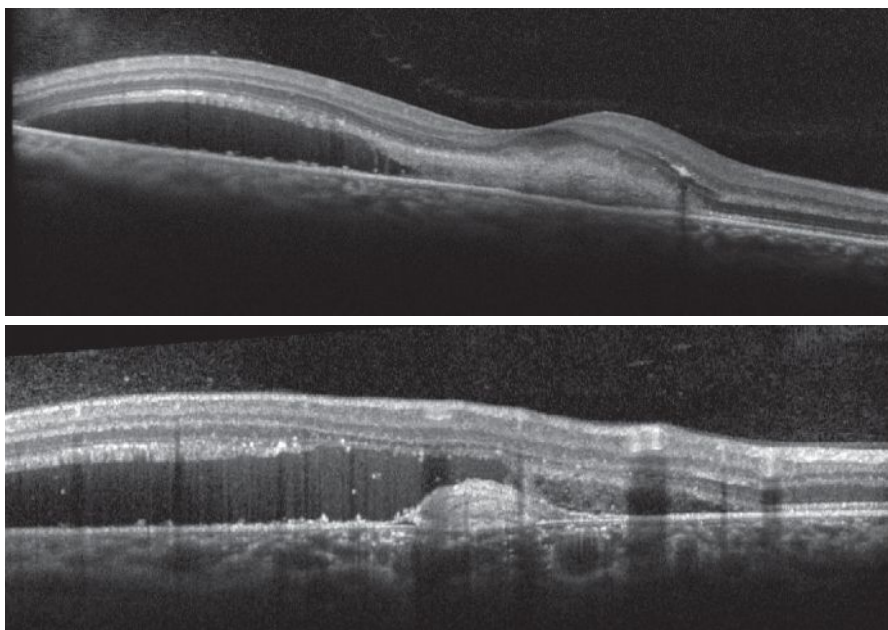
Follow us on social media!

Search: Review Education Group

Postgraduate Institute  
for Medicine

\*Accreditation pending

**REVIEW**  
Education GROUP



**Fig. 3. Heidelberg Spectralis OCT of the right macula (foveal and extrafoveal scan).**

of histoplasmosis suggested a diagnosis of presumed ocular histoplasmosis syndrome (POHS) with active MNV.

### Discussion

POHS is due to systemic infection by inhalation of *Histoplasma capsulatum* fungal spores present in soil contaminated by bat and bird droppings.<sup>1</sup> Primary infection is pulmonary, and this condition is thought to occur via hematogenous dissemination to the richly vascularized choroid.<sup>2</sup> It is termed “presumed” because there are no specific laboratory tests to confirm the ocular manifestations are secondary to histoplasma infection; however, there appears to be a positive association between POHS and histoplasmin skin testing positivity.<sup>3,4</sup>

In endemic regions, as much as 70% of the population with known exposure to the fungus had positive skin tests, and 100% of those with clinical findings consistent with POHS had positive skin tests. Conversely, only 4.4% of patients from the general population in non-endemic areas with positive histoplasmin skin testing had ocular findings consistent with a diagnosis of POHS.<sup>4</sup>

Histoplasmosis is the most common endemic mycosis in the world, with case reports spanning five continents

(North America, South America, Africa, Europe and Asia).<sup>5</sup> In North America, it is considered to be hyperendemic in the Midwestern US (Ohio and Mississippi River Valley) but is also highly endemic to South and Central America with 30% to 40% and 37% to 56% histoplasmin skin testing positivity, respectively.<sup>5,6</sup> As a result, it is a leading cause of irreversible vision loss in these regions.<sup>1,7</sup> Histoplasmosis is also one of the most frequent opportunistic infections in those infected with human immunodeficiency virus (HIV).<sup>5</sup>

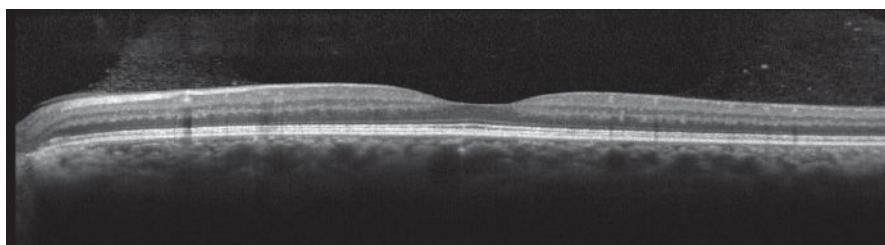
It is worth noting that 10% of POHS cases have been reported outside of known endemic areas, suggesting that clinicians must maintain an index of suspicion despite absence of supportive travel history; this may be related to climate change and subsequent altered migratory patterns of bats and birds.<sup>5,8</sup> Additionally, an association

with human leukocyte antigen subtypes DRw2 and B7 has been reported, which supports the hypothesis that the clinical manifestations may actually be an autoimmune reaction secondary to the infectious organism, though further pathophysiological studies are needed.<sup>4</sup>

The prevalence of POHS in the US is as high as 5.3%, but this is likely an underestimate due to its relatively asymptomatic nature until the development of MNV.<sup>2</sup> It typically occurs in the fourth to fifth decades of life with no gender predilection, which may portend socioeconomic challenges given it predominantly affects patients of working age.<sup>2,4</sup>

The differential diagnosis is very broad and varies based on the presence of MNV; it includes toxoplasma retinochoroiditis, sarcoidosis, punctate inner choroiditis, multifocal choroiditis, multifocal choroiditis with panuveitis, myopic degeneration, age-related macular degeneration, angioid streaks and acute posterior multifocal placoid pigment epitheliopathy.<sup>2,4,7,9</sup>

As the diagnosis is essentially clinical, a detailed case history and careful ophthalmic exam is critical. POHS is frequently bilateral and the classic findings are a triad of “punched out” chorioretinal lesions affecting the macula or midperipheral/peripheral fundus (also known as “histo spots”), peripapillary atrophy and MNV or subsequent disciform scarring all in the absence of vitritis.<sup>4,7,9</sup> Manifestation of two findings of the triad are typically sufficient to make the diagnosis.<sup>9</sup> Due to its asymptomatic nature in the early uveitic phase, acute chorioretinal lesions are rarely seen but would appear as discrete white foci that later atrophy and acquire pigment.<sup>2,10</sup>



**Fig. 4. Heidelberg Spectralis OCT of the left macula.**



Acute MNV formation often produces serosanguinous retinal detachment and subsequent subretinal fibrosis.<sup>2,10</sup> While less frequent and described in only about 5% of patients, a fourth clinical sign of pigmented curvilinear streaks in the equatorial fundus was described in 1981 and termed Schlaegel lines.<sup>11</sup>

Prior to the advent of OCT, fluorescein angiography was the only imaging modality to confirm the presence and activity of MNV.<sup>12</sup> However, spectral domain and swept source OCT now allow for more sensitive and early detection of MNV activity, and OCT-angiography has proven a safe, effective and less-invasive alternative modality to fluorescein angiography for assessing MNV activity.<sup>2,12</sup>

## Treatment

The Infectious Diseases Society of America concluded that systemic antifungal treatment is not indicated for mild-moderate acute pulmonary histoplasmosis.<sup>13</sup> However, systemic antifungal therapy with itraconazole may be indicated for patients with severe pneumonia, chronic pulmonary histoplasmosis, disseminated disease or compromised immune system.<sup>13</sup> Ophthalmologically, treatment is only indicated in the presence of active MNV.<sup>2,4,7</sup>

Historically, laser photocoagulation, photodynamic therapy, submacular surgery and macular translocation were all trialed with variable success, but intravitreal anti-VEGF has become the standard first-line therapy since the initial successful case report in 2007.<sup>2,7,9,14</sup> Over 80% of patients treated with intravitreal anti-VEGF show stability or improvement, with an average improvement of about three lines of Snellen best-corrected visual acuity (BCVA); average final BCVA of 20/40-20/60 is achieved with a mean of seven injections over a two-year period.<sup>2,3,7</sup>

Eyes with suboptimal response to intravitreal anti-VEGF monotherapy may be candidates for combination therapy with PDT.<sup>2,4,7,10</sup> A small retrospective series showed a possible role

for intravitreal steroid therapy though carries a risk of cataract development and ocular hypertension in a young, working age population.<sup>2,4,9</sup> Patients with MNV in one eye have a 12% and 22% chance of developing symptoms in the fellow eye at years five and 10, respectively.<sup>10</sup>

Our patient is still receiving serial intravitreal bevacizumab injections with trending improvement in the subretinal fluid and hemorrhage and mild eccentric subretinal fibrosis. She has received four injections so far with a BCVA of 20/40 at last follow-up. She will continue with this treatment until resolution and will then require monitoring for reactivation of the neovascular lesion, as well as involvement in the fellow eye.

This case was a reminder that histoplasmosis is truly a diffusely endemic infection that can present in patients outside of the Midwestern US. ■

- Xu TT, Reynolds MM, Hodge DO, Smith WM. Epidemiology and clinical characteristics of presumed ocular histoplasmosis in Olmsted County, Minnesota. *Ocul Immunol Inflamm*. 2022;30(5):1039-43.
- Ryan SJ, Davis JL, Flynn HW, et al. *Retina*, Fifth ed. London; New York: Saunders/Elsevier, 2013.
- Benedict K, Shantha JG, Yeh S, et al. Presumed ocular histoplasmosis syndrome in a commercially insured population, United States. *PLoS One*. 2020;15(3):e0230305.
- Prasad AG, Van Gelder RN. Presumed ocular histoplasmosis syndrome. *Curr Opin Ophthalmol*. 2005;16(6):364-8.
- Messina FA, Giusiano G, Santiso G. Endemic mycoses and COVID-19: a review. *Current Fungal Infection Reports*. 2022;16(3):98-106.
- Ashraf N, Kubat RC, Poplin V, et al. Re-drawing the maps for endemic mycoses. *Mycopathologia*. 2020;185(5):843-65.
- Thuruthumaly C, Yee DC, Rao PK. Presumed ocular histoplasmosis. *Curr Opin Ophthalmol*. 2014;25(6):508-12.
- McKinsey DS, Pappas PG. Histoplasmosis: Time to redraw the map and up our game. *Clin Infect Dis*. 2020;70(6):1011-3.
- Diaz RI, Sigler EJ, Rafieetary MR, Calzada JI. Ocular histoplasmosis syndrome. *Surv Ophthalmol*. 2015;60(4):279-95.
- Agarwal A, Gass JDM. *Gass' Atlas of Macular Diseases*, Fifth ed. London: Elsevier, 2011.
- Fountain JA, Schlaegel TF, Jr. Linear streaks of the equator in the presumed ocular histoplasmosis syndrome. *Arch Ophthalmol*. 1981;99(2):246-8.
- Liu TYA, Zhang AY, Wenick A. Evolution of choroidal neovascularization due to presumed ocular histoplasmosis syndrome on multimodal imaging including optical coherence tomography angiography. *Case Rep Ophthalmol*. Med 2018;2018:4098419.
- Wheat LJ, Freifeld AG, Kleiman MB, et al. Clinical practice guidelines for the management of patients with histoplasmosis: 2007 update by the Infectious Diseases Society of America. *Clinical Infectious Diseases*. 2007;45(7):807-25.
- Adán A, Navarro M, Casaroli-Marano RP, et al. Intravitreal bevacizumab as initial treatment for choroidal neovascularization associated with presumed ocular histoplasmosis syndrome. *Graefes Arch Clin Exp Ophthalmol*. 2007;245(12):1873-5.

## ADVERTISER INDEX

This index is published as a convenience and not as part of the advertising contract. Every care will be taken to index correctly. No allowance will be made for errors due to spelling, incorrect page number, or failure to insert.

Alcon .....	45, 46
	<a href="http://www.alcon.com">www.alcon.com</a>
Apellis .....	33
	<a href="http://www.apellis.com">www.apellis.com</a>
Bausch + Lomb .....	Cover Tip
	866-246-8245
	<a href="http://www.miebo-ecp.com">www.miebo-ecp.com</a>
Bausch + Lomb .....	21
	866-246-8245
	<a href="http://www.lumifydrops.com/">www.lumifydrops.com/</a>
Bausch + Lomb .....	39
	866-246-8245
	<a href="http://www.lumifydrops.com/">www.lumifydrops.com/</a>
Bruder Healthcare Company .....	17
	(888) 827-8337
	<a href="mailto:eyes@bruder.com">eyes@bruder.com</a>
	<a href="http://www.bruder.com">www.bruder.com</a>
Eyeficient .....	Cover 2
	800-417-8136
	<a href="https://www.eyeficient.com/">https://www.eyeficient.com/</a>
Glaukos .....	19
	(800) 452-8567
	<a href="http://www.glaukos.com">www.glaukos.com</a>
Iveric Bio .....	10-12
	<a href="http://www.ivericBio.com">www.ivericBio.com</a>
Meivertor .....	23
	<a href="http://Meivertor.com">Meivertor.com</a>
Menicon .....	Cover 3
	(800) 636-4266
	<a href="http://www.meniconamerica.com">www.meniconamerica.com</a>
Oyster Point .....	50, 51
	<a href="https://oysterpointrx.com/">https://oysterpointrx.com/</a>
Tarsus .....	82, Cover 4
	<a href="https://tarsusrx.com">https://tarsusrx.com</a>
Thea Pharma .....	25, 26
	781-832-3664
	<a href="https://ivuzeh.com/">https://ivuzeh.com/</a>
Thea Pharma .....	29
	781-832-3664
	<a href="https://www.ivizia.com/">https://www.ivizia.com/</a>
The Dry Eye Doctor .....	57
	833-437-9393
	<a href="mailto:sales@thedryeyedoctor.net">sales@thedryeyedoctor.net</a>
	<a href="http://www.thedryeyedoctor.net">www.thedryeyedoctor.net</a>
VSP .....	15
	<a href="http://vspeyecarecareers.com">vspeyecarecareers.com</a>



# The Ears Have It

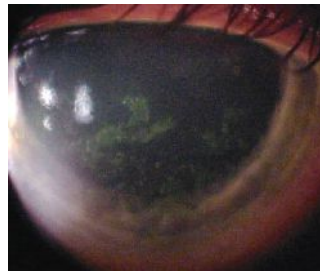
*A connection with the eyes can be present in more ways than one.*

**A** 27-year-old Caucasian female patient reported to the office with a chief complaint of dry, irritated eyes of two weeks' duration. She explained that her eyes became red over the previous two weeks and that use of Visine made them less red but didn't stop the discomfort.

The patient's systemic and ocular histories were unremarkable and she denied exposure to chemicals or allergies of any kind. However, she had recently started oral over-the-counter allergy medications for the symptoms of clogged ears.

Her best-corrected entering visual acuities were 20/20 OU at distance and near. External examination was normal with no evidence of afferent pupillary defect. The biomicroscopic examination of the anterior segment is demonstrated in the photograph. Goldmann applanation tonometry measured 15mm Hg OU. The dilated fundus findings were normal peripherally and centrally, with normal nerves and maculae.

Additional studies included examination of the eyelids for blepharitis, distichiasis or trichiasis. The phenylephrine blanch test could also be employed to assess the depth of the inflammation. Sodium fluorescein staining was completed to assess the status of the corneal epithelium. The lacrimal lake should be observed and Schirmer tear testing can be completed to quantify the volume of tear production.



**Slit lamp exam of the patient revealed these findings. What might be the origin?**

## Your Diagnosis

What would be your diagnosis based on the findings presented? What's the likely prognosis? To find out, read the online version of this article at [www.reviewofoptometry.com](http://www.reviewofoptometry.com). ■



Dr. Gurwood is a professor of clinical sciences at The Eye Institute of the Pennsylvania College of Optometry at Salus University. He is a co-chief of Primary Care Suite 3. He is attending medical staff in the department of ophthalmology at Albert Einstein Medical Center, Philadelphia. He has no financial interests to disclose.

**Retina Quiz Answers—Q1: b, Q2: d, Q3: d, Q4: a, Q5: d**

**XDEMY™ (lotilaner ophthalmic solution) 0.25%, for topical ophthalmic use**

**BRIEF SUMMARY OF PRESCRIBING INFORMATION**  
Please see the XDEMY™ package insert for full Prescribing Information.

**INDICATIONS AND USAGE**  
XDEMY is indicated for the treatment of *Demodex* blepharitis.

**CONTRAINDICATIONS**  
None.

**WARNINGS AND PRECAUTIONS**  
**Risk of Contamination** Do not allow the tip of the dispensing container to contact the eye, surrounding structures, fingers, or any other surface in order to minimize contamination of the solution. Serious damage to the eye and subsequent loss of vision may result from using contaminated solutions.

**Use with Contact Lenses** Contact lenses should be removed prior to instillation of XDEMY and may be reinserted 15 minutes following its administration.

**ADVERSE REACTIONS**  
Because clinical studies are conducted under widely varying conditions, adverse reaction rates observed in the clinical trials of a drug cannot be directly compared to rates in the clinical trials of another drug and may not reflect the rates observed in practice.

XDEMY was evaluated in 833 patients with *Demodex* blepharitis in two randomized, double-masked, vehicle-controlled studies (Saturn-1 and Saturn-2) with 42 days of treatment. The most common ocular adverse reaction observed in controlled clinical studies with XDEMY was instillation site stinging and burning which was reported in 10% of patients. Other ocular adverse reactions reported in less than 2% of patients were chalazion/hordeolum and punctate keratitis.

**USE IN SPECIFIC POPULATIONS**

**Pregnancy: Risk Summary** There are no available data on XDEMY use in pregnant women to inform any drug associated risk; however, systemic exposure to lotilaner from ocular administration is low. In animal reproduction studies, lotilaner did not produce malformations at clinically relevant doses.

**Data Animal Data** In an oral embryofetal developmental study in pregnant rats dosed during organogenesis from gestation days 6-19, increased post-implantation loss, reduced fetal pup weight, and incomplete skeletal ossification were observed at 50 mg/kg/day (approximately 1390 times the recommended human ophthalmic dose (RHOD) on a body surface area basis) in the presence of maternal toxicity (i.e., decreased body weight and food consumption). A rare malformation of situs inversus of the thoracic and abdominal viscera occurred in 1 fetus from a pregnant rat receiving 50 mg/kg/day; whether this finding was treatment-related could not be excluded. No maternal or embryofetal toxicity was observed at 18 mg/kg/day (approximately 501 times the RHOD on a body surface area basis). In an oral embryofetal development study in pregnant rabbits dosed during organogenesis from gestation days 7-19, no embryofetal toxicity or teratogenic findings were observed at 20 mg/kg/day (approximately 580-times the RHOD on an AUC basis), even in the presence of maternal toxicity (i.e., decreased food consumption and body weight).

In an oral two-generation reproductive toxicity study, F0 male and female rats were administered lotilaner at doses up to 40 mg/kg/day for 10 weeks before pairing and during the 2-week pairing period (3 weeks for males). Dosing for F0 females continued through lactation day 22. F1 male and female rats were administered lotilaner at 1 and 5 mg/kg/day post-weaning from day 23 for 10 weeks before pairing and during the 2-week pairing period (3 weeks for males). Dosing for F1 parenteral females continued through lactation day 22. There were no clear adverse effects on the F1 generation, and a slightly lower mean body weight during lactation was noted for F2 pups at 5 mg/kg/day. The no observed adverse effect level (NOAEL) was determined to be 5 mg/kg/day

(approximately 139 times the RHOD on a body surface area basis).

**Lactation: Risk Summary** There are no data on the presence of XDEMY in human milk, the effects on the breastfed infant, or the effects on milk production. However, systemic exposure to lotilaner following 6 weeks of topical ocular administration is low and is >99% plasma protein bound, thus it is not known whether measurable levels of lotilaner would be present in maternal milk following topical ocular administration. The developmental and health benefits of breastfeeding should be considered along with the mother's clinical need for XDEMY and any potential adverse effects on the breast-fed child from XDEMY.

**Pediatric Use:** Safety and effectiveness in pediatric patients below the age of 18 years have not been established.

**Geriatric Use:** No overall differences in safety or effectiveness have been observed between elderly and other adult patients.

**NONCLINICAL TOXICOLOGY**  
**Carcinogenesis, Mutagenesis, Impairment of Fertility**

**Carcinogenesis** Long-term studies in animals have not been performed to evaluate the carcinogenic potential of lotilaner.

**Mutagenesis** Lotilaner was not genotoxic in the following assays: Ames assay for bacterial gene mutation, *in vitro* chromosomal aberration assay in cultured human peripheral blood lymphocytes, and *in vivo* rat micronucleus test.

**Impairment of fertility** In a two-generation study of reproductive performance in rats, F0 male and female rats were administered lotilaner at oral doses of 40 mg/kg/day for 80 days reduced to 20 mg/kg/day for 47-50 supplementary days. Reduced pregnancy rates and decreased implantation rates were observed in F0 females at doses 20 mg/kg/day (approximately 556 times the RHOD on a body surface area basis), which were also associated with maternal toxicity (i.e., decreased body weight and food consumption). No effects on fertility were observed in F0 females at the dose of 5 mg/kg/day (approximately 139 times the MRHOD on a body surface area basis). No effects on fertility were observed in F0 males at the oral dose of 20 mg/kg/day (approximately 556 times the RHOD on a body surface area basis), and no effects on fertility were observed in F1 males and females at the oral dose of 5 mg/kg/day (approximately 139 times the RHOD on a body surface area basis).

**PATIENT COUNSELING INFORMATION**

**Handling the Container** Instruct patients to avoid allowing the tip of the dispensing container to contact the eye, surrounding structures, fingers, or any other surface in order to minimize contamination of the solution. Serious damage to the eye and subsequent loss of vision may result from using contaminated solutions.

**When to Seek Physician Advice** Advise patients that if they develop an intercurrent ocular condition (e.g., trauma or infection), have ocular surgery, or develop any ocular reactions, particularly conjunctivitis and eyelid reactions, they should immediately seek their physician's advice concerning the continued use of XDEMY.

**Use with Contact Lenses** Advise patients that XDEMY contains potassium sorbate, which may discolor soft contact lenses. Contact lenses should be removed prior to instillation of XDEMY and may be reinserted 15 minutes following its administration.

**Use with Other Ophthalmic Drugs** Advise patients that if more than one topical ophthalmic drug is being used, the drugs should be administered at least 5 minutes between applications.

**Missed Dose** Advise patients that if one dose is missed, treatment should continue with the next dose.

RX only

© 2023 Tarsus Pharmaceuticals, Inc. All rights reserved.

XDEMY is a trademark of Tarsus Pharmaceuticals, Inc.

US-2300345 9/23



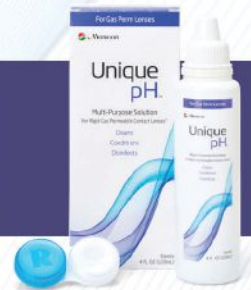# Unique never felt so good.

Unique pH™ is a highly effective multipurpose solution for gas permeable contact lenses that cleans, conditions, and disinfects in one bottle.

Unique pH™ conditions lenses by adjusting to the eye's natural tear pH to enhance the wettability and comfort of gas permeable contact lenses on insertion. The formula is designed to provide a soothing effect during lens wear.

Complimentary starter kits available!

**ORDER ONLINE**  
[www.meniconwebstore.com](http://www.meniconwebstore.com)



NOW AVAILABLE  
TO PRESCRIBE



Learn more at  
[XDEMZYHCP.com](https://www.XDEMZYHCP.com)



**xdemzy**<sup>™</sup>  
(lotilaner ophthalmic  
solution) 0.25%

# Might over mites

in just 6 weeks

1st &  
only

FDA-APPROVED TREATMENT FOR  
*DEMODEX* BLEPHARITIS (DB)

## INDICATIONS AND USAGE

XDEMZY (lotilaner ophthalmic solution) 0.25% is indicated for the treatment of *Demodex* blepharitis.

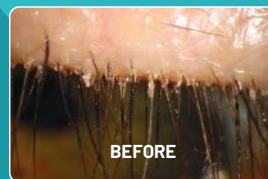
## IMPORTANT SAFETY INFORMATION:

### WARNINGS AND PRECAUTIONS

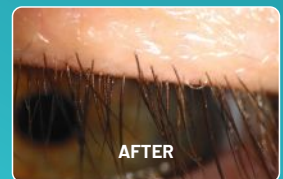**Risk of Contamination:** Do not allow the tip of the dispensing container to contact the eye, surrounding structures, fingers, or any other surface in order to minimize contamination of the solution. Serious damage to the eye and subsequent loss of vision may result from using contaminated solutions.

**Use with Contact Lenses:** XDEMZY contains potassium sorbate, which may discolor soft contact lenses. Contact lenses should be removed prior to instillation of XDEMZY and may be reinserted 15 minutes following its administration.

## Real results



BEFORE



AFTER

44% and 55% of patients taking XDEMZY in SATURN-1 (N=209) and SATURN-2 (N=193), respectively, achieved a significant improvement in their eyelids (reduction of collarettes to no more than 2 collarettes per upper lid) at Day 43 vs 7% (N=204) and 12% (N=200) of patients taking vehicle ( $P < 0.01$  in each trial).\*

All images are of actual patients who participated in clinical trials for Tarsus Pharmaceuticals.

**ADVERSE REACTIONS:** The most common adverse reaction with XDEMZY was instillation site stinging and burning which was reported in 10% of patients. Other ocular adverse reactions reported in less than 2% of patients were chalazion/hordeolum and punctate keratitis.

**Please see next page for a Brief Summary of the full Prescribing Information.**

**Reference:** XDEMZY [prescribing information]. Tarsus Pharmaceuticals, Inc; 2023.

\*The safety and efficacy of XDEMZY for the treatment of DB were evaluated in a total of 833 patients (415 of whom received XDEMZY) in two 6-week, randomized, multicenter, double-masked, vehicle-controlled studies (SATURN-1 and SATURN-2). Patients were randomized to either XDEMZY or vehicle at a 1:1 ratio, dosed twice daily in each eye for 6 weeks. All patients enrolled were diagnosed with DB. The primary efficacy endpoint was defined as the proportion of patients with collarette reduction to no more than 2 collarettes per upper eyelid at Day 43 (SATURN-1: XDEMZY N=209, vehicle N=204,  $P < 0.01$ ; SATURN-2: XDEMZY N=193, vehicle N=200,  $P < 0.01$ ).

© 2023 Tarsus Pharmaceuticals, Inc. All rights reserved.  
Tarsus, XDEMZY, and the associated logos are trademarks of  
Tarsus Pharmaceuticals, Inc. US—2300405 9/23

