


REVIEW of OPTOMETRY

January 15, 2024 • reviewofoptometry.com

Leadership in clinical care

A Visual Guide to Ocular Disease

More of
NOTHING
is coming soon



Get ready to discover seamless vision
near through far³ in a Multifocal lens that
FEELS LIKE NOTHING, even at day 30.⁴

*With two lenses or less per eye, at the initial fitting visit.

References: 1. Merchea M, Evans D, Kannarr S, Miller J, Kaplan M, Nixon L. Assessing a modified fitting approach for improved multifocal contact lens fitting success. Paper presented at Optometry's Meeting, the 121st Congress of the American Optometric Association; June 20-24, 2018; Denver, CO. 2. Bauman E, Lemp J, Kern J. Material effect on multifocal contact lens fitting of lenses of the same optical design with the same fitting guide. Poster presented at: British Contact Lens Association Clinical Conference & Exhibition; June 9-11, 2017; Liverpool, UK. 3. Alcon data on file, 2022. 4. In a clinical study wherein patients used CLEAR CARE® solution for nightly cleaning, disinfecting, and storing; Alcon data on file, 2021.

See product instructions for complete wear, care and safety information. 

©2023 Alcon Inc. US-T3M-2300009

Scan to learn more



Alcon

EARN 2 CE CREDITS: The Physical Manifestations of Glaucoma and What They Signify, p. 46

REVIEW *of* OPTOMETRY

January 15, 2024 • reviewofoptometry.com

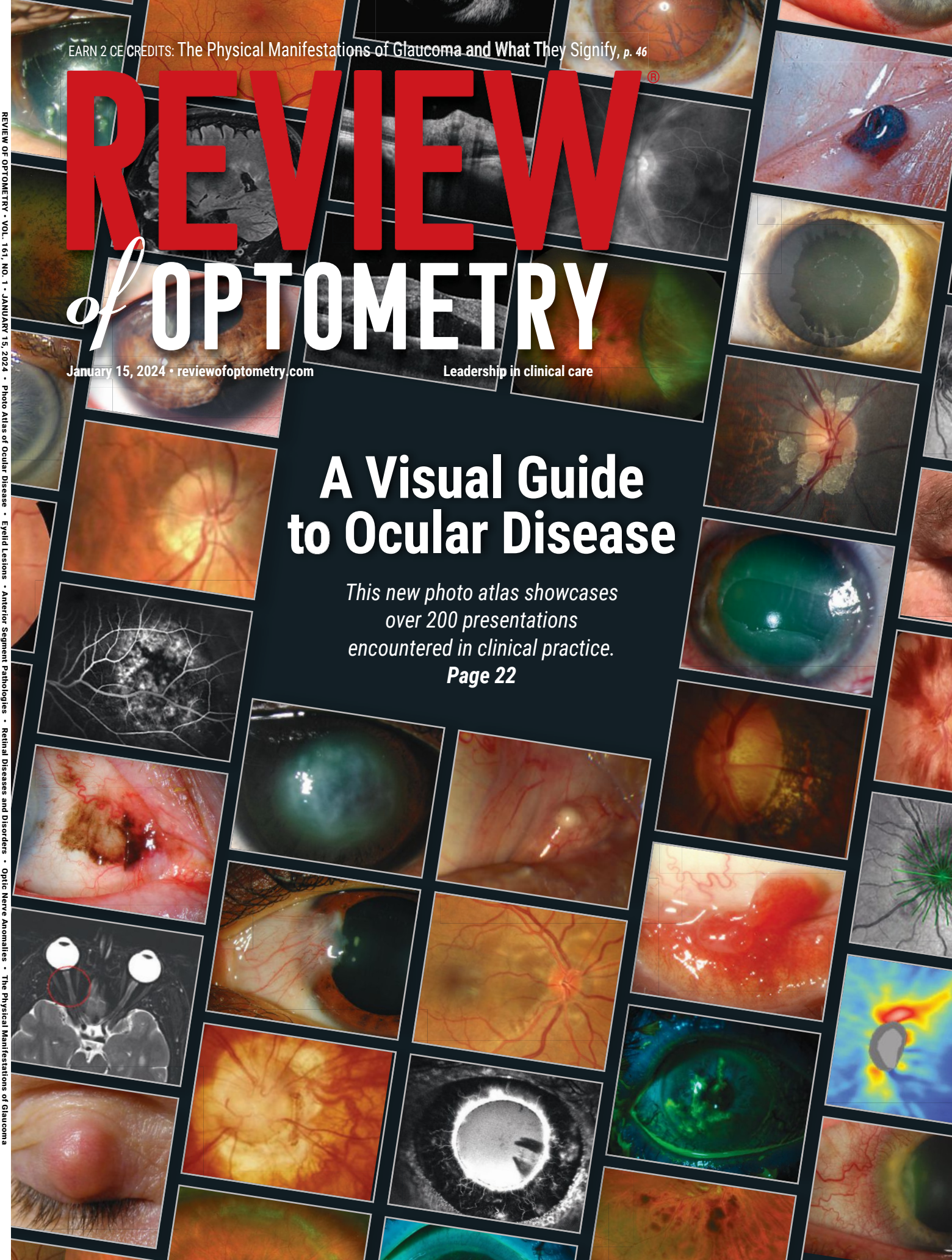
Leadership in clinical care

A Visual Guide to Ocular Disease

*This new photo atlas showcases
over 200 presentations
encountered in clinical practice.*

Page 22

REVIEW OF OPTOMETRY • VOL. 161, NO. 1 • JANUARY 15, 2024 • Photo Atlas of Ocular Disease • Eyelid Lesions • Anterior Segment Pathologies • Retinal Diseases and Disorders • Optic Nerve Anomalies • The Physical Manifestations of Glaucoma



Look for choroidal hypertransmission, a marker of Geographic Atrophy (GA) on OCT^{1*}

- While BCVA is poorly correlated to lesion size, visual function continues to decline as lesions grow^{2,3}
- It is critical to recognize GA and refer patients in a timely manner, as disease progression is relentless and irreversible^{1,3-7}

Learn more about identifying GA
at RecognizeAndReferGA.com



**RECOGNIZE
AND REFER**

*GA is defined by atrophic lesions, resulting from loss of photoreceptors, RPE, and underlying choriocapillaris. This results in a choroidal hypertransmission defect on OCT.^{1,8,9}
BCVA=best-corrected visual acuity; OCT=optical coherence tomography; RPE=retinal pigment epithelium.

References: 1. Fleckenstein M, Mitchell P, Freund KB, et al. The progression of geographic atrophy secondary to age-related macular degeneration. *Ophthalmology*. 2018;125(3):369-390. doi:10.1016/j.ophtha.2017.08.038. 2. Heier JS, Pieramici D, Chakravarthy U, et al. Visual function decline resulting from geographic atrophy: results from the chroma and spectri phase 3 trials. *Ophthalmol Retina*. 2020;4(7):673-688. doi:10.1016/j.oret.2020.01.019. 3. Sunness JS, Margalit E, Sirkumaran D, et al. The long-term natural history of geographic atrophy from age-related macular degeneration: enlargement of atrophy and implications for interventional clinical trials. *Ophthalmology*. 2007;114(2):271-277. 4. Boyer DS, Schmidt-Erfurth U, van Lookeren Campagne M, Henry EC, Brittain C. The pathophysiology of geographic atrophy secondary to age-related macular degeneration and the complement pathway as a therapeutic target. *Retina*. 2017;37(5):819-835. doi:10.1097/iae.0000000000001392. 5. American Optometric Association. AOA Comprehensive adult eye and vision examination. *Quick Reference Guide: Evidence-Based Clinical Practice Guideline*. 1st ed. Accessed July 13, 2023. https://www.aoa.org/documents/EBO/Comprehensive_Adult_Eye_and_Vision_%20QRG.pdf. 6. Holz FG, Strauss EC, Schmitz-Valckenberg S, van Lookeren Campagne M. Geographic atrophy: clinical features and potential therapeutic approaches. *Ophthalmology*. 2014;121(5):1079-1091. doi:10.1016/j.ophtha.2013.11.023. 7. Lindblad AS, Lloyd PC, Clemons TE, et al; Age-Related Eye Disease Study Research Group. Change in area of geographic atrophy in the age-related eye disease study: AREDS report number 26. *Arch Ophthalmol*. 2009;127(9):1168-1174. doi:10.1001/archophthol.2009.198. 8. van Lookeren Campagne M, LeCouter J, Yaspan BL, Ye W. Mechanisms of age-related macular degeneration and therapeutic opportunities. *J Pathol*. 2014;232(2):151-164. doi:10.1002/path.4266. 9. Chakravarthy U, Bailey CC, Scanlon PH, et al. Progression from early/intermediate to advanced forms of age-related macular degeneration in a large UK cohort: rates and risk factors. *Ophthalmol Retina*. 2020;4(7):662-672.

Apellis

The APELLIS® name and logo is a registered trademark of Apellis Pharmaceuticals, Inc.
©2023 Apellis Pharmaceuticals, Inc. 8/23 US-GA-2300089 v1.0

NEWS REVIEW

Clinical, legislative and practice development updates for ODs.



Get the latest at
www.reviewofoptometry.com/news
Stories post every weekday

CHECK PAPILLOMACULAR BUNDLE IN HIGHLY MYOPIC GLAUCOMA PATIENTS, P.4 >> METFORMIN SHOWS NO EFFECT AGAINST GEOGRAPHIC ATROPHY, P.4 >> OMEGA-3s COME UP SHORT IN DIABETIC RETINOPATHY STUDY, P.5

10-2 VF Not Useful in Routine Glaucoma Testing, AAOPhth Says

However, it may provide sufficient information for patients with a repeatable defect within the central 12 locations of the standard 24-2 VF grid.

In a new Ophthalmic Technology Assessment by the American Academy of Ophthalmology, researchers evaluated the current literature on the utility of the 10-2 visual field (VF) testing strategy for the evaluation and management of early glaucoma, defined here as mean deviation (MD) better than -6 dB. They concluded that 10-2 VF testing may not be the most useful routine test for patients with early glaucoma, but would provide sufficient additional information for patients with a repeatable defect on the pupillary distance (PD) plot among the central 12 points on the 24-2 or 24-2C VF test. Their results were recently published in *Ophthalmology*.

After review, 26 articles in the PubMed database were selected and rated for strength of evidence. Thirteen were rated level I and eight were rated level II, while five level III articles were excluded. Data from the 21 included articles were abstracted and reviewed.

Results from the study found that the central 12 locations on the 24-2 VF test grid lie within the central 10° covered by the 10-2 VF test. In early glaucoma, defects detected within the central 10° generally agree between the two tests. Defects within the central 10° of the 24-2 VF test can predict defects on the 10-2 VF test, though the 24-2 may miss defects detected on the 10-2 VF test.

“In addition, results from the 10-2 VF test show better association with findings from OCT scans of the macular

ganglion cell complex,” the authors noted in their report. “Modifications of the 24-2 test that include extra test locations within the central 10° improve detection of central defects found on 10-2 VF testing.”

The authors explained that central VF defects may be underappreciated in early glaucoma evaluation. “Although less common in cases in which MD is better than -6 dB, central defects may have a profound impact on a person’s visual function and quality of life. Thus, detection of central VF defects is essential in early stages,” they explained.

With the extra central test locations, the Zeiss 24-2C or the Octopus G1 test strategies can improve detection of central defects over the standard 24-2 VF, the authors added. Although the 10-2 VF is considered the gold standard for detecting central VF defects, it’s more involved for both patients and clinicians, as it entails additional time, cost and effort, and it may not always detect additional defects not already seen on 24-2 testing.

“Thus, the evidence to date does not support routine testing using 10-2 VF for patients with early glaucoma,” the authors concluded. “Recent studies

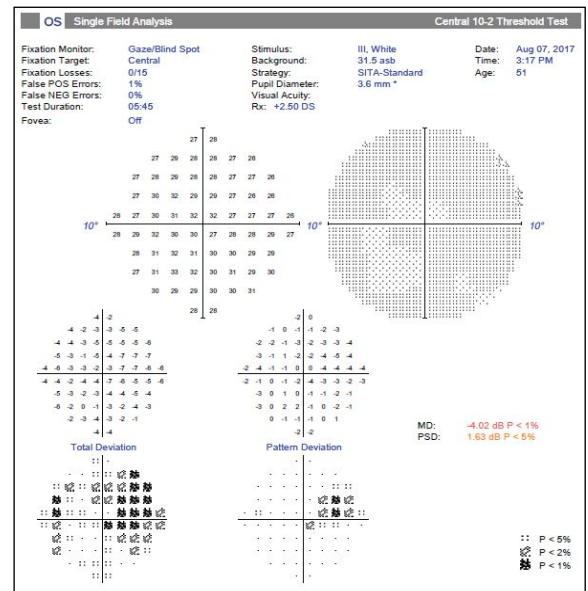


Photo: Danica Marrelli, OD

Study shows 10-2 VF testing doesn’t detect any additional defect not already seen on 24-2 testing.

(level I and II) provide some evidence on additional VF testing in some cases, however. Early 10-2 VF testing would provide sufficient additional information for any patient with a repeatable defect on the PD plot among the central 12 points on the 24-2 or 24-2C VF test or with a depressed average and/or minimum mGCIPL thickness on SD-OCT. A defect detected on SAP 10-2 VF warrants confirmation and potentially a lifelong commitment to serial 10-2 VF testing.”

WuDunn D, Takusagawa HL, Rosdahl JA, et al. Central visual field testing in early glaucoma. *Ophthalmology*. December 8, 2023. [Epub ahead of print].

REVIEW OF OPTOMETRY (ISSN 0147-7633) IS PUBLISHED MONTHLY, 12 TIMES A YEAR BY JOBSON MEDICAL INFORMATION LLC/WEBMD, 283-299 MARKET STREET, 2 GATEWAY CENTER, 4TH FLOOR, NEWARK, NJ 07102. PERIODICALS POSTAGE PAID AT NEWARK, NJ AND ADDITIONAL MAILING OFFICES. POSTMASTER: SEND ADDRESS CHANGES TO REVIEW OF OPTOMETRY, PO BOX 81, CONGERS, NY 10920-0081. SUBSCRIPTION PRICES: US: ONE YEAR \$56; TWO YEARS \$97, CANADA: ONE YEAR \$88, TWO YEARS \$160, INT’L: ONE YEAR \$209, TWO YEARS \$299. FOR SUBSCRIPTION INFORMATION CALL TOLL-FREE (877) 529-1746 (USA); OUTSIDE USA, CALL (845) 267-3065. OR EMAIL US AT REVOPOTOMETRY@CAMBIEWEST.COM. PUBLICATIONS MAIL AGREEMENT NO: 40612608. CANADA RETURNS TO BE SENT TO BLEUCHIP INTERNATIONAL, P.O. BOX 25542, LONDON, ON N6C 6B2.

Check the Papillomacular Bundle in Highly Myopic Glaucoma Patients

A defect here and/or at the lamina cribrosa possibly affecting central VF needs careful evaluation.

The papillomacular bundle plays an important role in central vision, so it is expected that a defect there can affect the quality of life of patients quite significantly. Little is known about these defects in glaucoma. Researchers in South Korea investigated the frequency of papillomacular bundle defects in glaucoma patients with high myopia and its risk factors. They observed a defect in 59.8% of patients, which was significantly correlated with

a larger parapapillary atrophy (PPA)-to-disc-area ratio, lamina cribrosa defect and central visual field defect.

The retrospective, cross-sectional study analyzed RNFL defect in 92 glaucomatous eyes with high myopia (axial length of 26.0mm or more or an average spherical value of -6D or less). After dividing the cohort into two groups with and without papillomacular bundle defect, the clinical characteristics of the groups were compared and analyzed.

They added, “the results of this study suggest that larger PPA area may be related to risk of RNFL thinning in the papillomacular bundle area.”

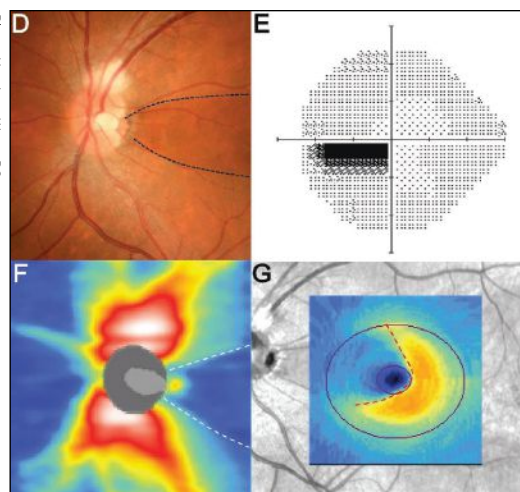
The study noted that swept-source OCT, used to image the lamina cribrosa, allows for deeper penetration of light for better delineation of more posterior structures of the optic nerve head and ocular wall, though there may still be limitations.

“Although we identified disc hemorrhage during follow-up, it is possible that instances that occurred before follow-up or between follow-up intervals could have been missed,” the authors wrote. “Therefore, it is possible that the number of disc hemorrhages in the total patient group was low; thus, more research with longer follow-up and a larger number of disc photo scans is necessary to further investigate the relationship between papillomacular defects and disc hemorrhages.”

The study concluded, “For highly myopic glaucoma patients, the presence of papillomacular bundle defect and/or lamina cribrosa defect possibly affecting the central visual field should be carefully evaluated.”

Huh MG, Shin YI, Jeong Y, et al. Papillomacular bundle defect (PMBD) in glaucoma patients with high myopia: frequency and risk factors. *Sci Rep.* 2023;13(1):21958.

Photo: Herietta Wang, Boprom



PPA-to-disc-area ratio (odds ratio; OR: 3.83), lamina cribrosa defect (OR: 2.92) and central visual field defect (OR: 3.56) were significantly associated with the papillomacular bundle defect. (The scans above depict papillomacular bundle RNFL loss).

The mean patient age was 52.1 years.

There was no significant intergroup difference in baseline or follow-up intraocular pressure. In this specific patient group, significant differences in PPA-to-disc-area ratio were found when dividing the population based on the presence or absence of a bundle defect.

“As larger PPA-to-disc-area ratio signals greater myopic deformation of the optic disc and peripapillary tissue, there must have been greater mechanical stress in the region of deformation,” the researchers wrote in their paper. “Therefore, the higher the myopia, the larger the PPA area that will be found.”

IN BRIEF

Metformin Shows No Effect Against GA. To test whether the type 2 diabetes drug metformin could slow geographic atrophy (GA) progression, a team of researchers conducted a randomized Phase II clinical trial that included 66 patients aged 55 or older without diabetes and with GA from atrophic AMD in at least one eye. Oral metformin at 1,000mg twice daily was given to 34 participants (57 eyes) and the

observation group included 32 participants (53 eyes). **The mean enlargement rate of GA area was 0.35±0.04mm/year in the observation group and marginally higher at 0.42±0.04mm/year in the treatment group. Mean decline in best-corrected visual acuity was 4.8±1.7 letters/year for the observational group and 3.4±1.1 letters/year in the treatment group.** Minimal improvement was also seen in **low-luminance visual acuity, of which decline was 7.3±2.5 letters/year in controls**

and 0.8±2.2 letters/year in the treatment group. Potential reasons for the marginal results seen may lie in limited statistical power, since the enrollment goal of 50 participants was not met, as well as the possibility that it may take longer than 18 months (the period observed) of oral metformin use to result in significant effects on GA. Other reasons for the lack of positive results could be due to those with more aggressive GA potentially being more likely to drop out of the

observational group for experimental treatment elsewhere and that the sheer advanced state of GA in these participants did not lend itself well to metformin's efficacy. **The results contrast with positive data seen for metformin use with wet AMD showing that the therapy reduced the odds of developing new-onset neovascular AMD.**

Shen LL, Keenan JD, Chahal N, et al. METformin FOR the MINimization of geographic atrophy progression (METforMIN)—a randomized trial. *Ophthalmol Sci.* November 2023. [Epub ahead of print].

Omega-3s Come Up Short in DR Study

The potential of omega-3 fatty acids (FAs) in treating diabetic eye disease has mainly been demonstrated in experimental models, in which the protective effects against diabetic retinopathy (DR) and diabetic maculopathy were mediated through antioxidant and anti-angiogenesis pathways. Researchers at the University of Oxford performed a sub-study of data from the A Study of Cardiovascular Events in Diabetes (ASCEND) trial to provide a large, well-conducted and prospective test of these potential benefits and the duration of exposure needed to convey them. They found no statistically significant effect of omega-3 FA allocation associated with lower incidence of referable eye disease.

ASCEND was a double-blind, randomized, placebo-controlled trial of 1g omega-3 FAs (containing 460mg eicosapentaenoic acid and 380mg docosahexaenoic acid) daily for the

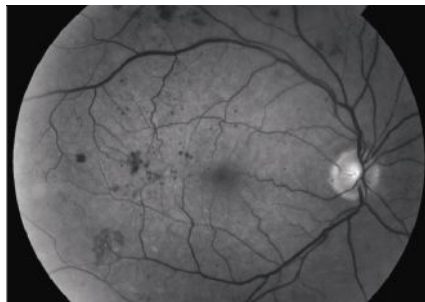


Photo: Steve Ferrucci, MD

Despite their likely supportive role in treating dry eye, omega-3 fatty acid supplements have yet to show evidence of an effect in diabetic retinopathy.

primary prevention of serious cardiovascular events in 15,480 UK adults at least 40 years old and with diabetes. The study average adherence with omega-3 FAs was 79.3%.

During the mean follow-up of 6.5 years, 14.8% of patients had a referable disease event in the omega-3 group, compared with 13.9% in the placebo group. There were no significant effects

of assignment to active omega-3 FAs compared with the placebo on worsening visual acuity equivalent to a loss of 15 or more ETDRS letters (35.0% vs. 36.9%, respectively). There were also no significant between-group differences in the proportion of events for secondary or tertiary outcomes, which included referable disease stratified by baseline DR severity, DR progression, incident diabetic maculopathy or duplex retinopathy grades at the final eye screening record.

“ASCEND-Eye has several strengths that facilitated a robust assessment of the effects of omega-3 fatty acids on DR, including its randomized design, a large number of participants and a long duration of near-complete follow-up,” the authors wrote in their paper. ◀

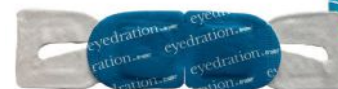Sammons EL, Buck G, Bowman LJ, et al.; on behalf of the ASCEND Study Collaborative Group. ASCEND-Eye: effects of omega-3 fatty acids on diabetic retinopathy. *Ophthalmology*. December 3, 2023. [Epub ahead of print].

OPEN YOUR EYES to Bruder

a Hilco Vision Company

HYGIENE | HEAT | HYDRATION

Open your eyes to Bruder.™ You know us for our #1 doctor-recommended microwave-activated Bruder® mask. Now we've added a new single-use, air-activated Eyedration™ mask, a convenient way for patients to maintain eye health when traveling, or where a microwave is not available. Eyedration begins heating once exposed to the air and maintains therapeutic moist heat on the eyelids for up to 20 minutes. Soft ear loops keep it in place when worn. The mask can also be used in-office to prepare the eye for manual expression or debridement procedures.



Read more about the mask



Stock up now on eye care essentials at order.bruder.com, eyes@bruder.com or 888-827-8337. Learn about the science behind Bruder products at bruder.com/pro.

CONTENTS

REVIEW OF OPTOMETRY • JANUARY 15, 2024

FOLLOW US ON SOCIAL MEDIA

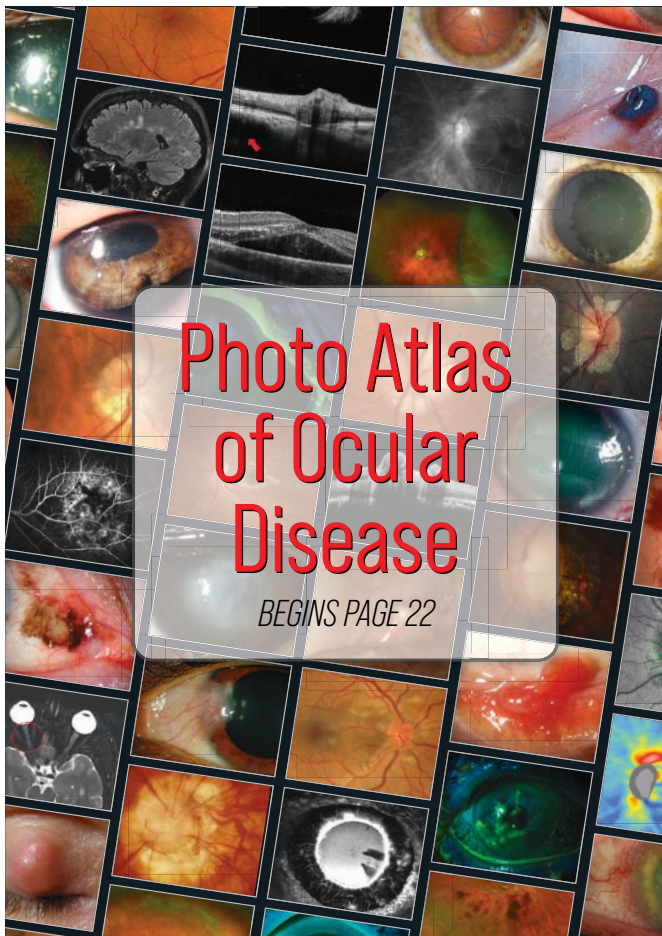
Facebook: revoptom

Twitter: revoptom

Instagram: revoptom

Threads: revoptom

LinkedIn: company/review-of-optometry



24 Eyelid Issues: Lumps, Bumps and Beyond

While these lesions tend to be benign, the wide array of presentations makes assessment tricky. Here's a visual reference to follow.

28 The Many Mishaps of the Anterior Segment

The eye's first line of defense against external threats is often compromised by infection or injury. Systemic conditions frequently also manifest changes here as well.

36 Navigate the Retinal Landscape With Confidence

The delicate anatomy here is prone to disruption in countless ways, including systemic and localized disease processes, trauma, congenital malformations, drug reactions and more.

44 Assessing the Optic Nerve

The stakes tend to be high with these conditions, and advanced imaging often plays a decisive role.

EARN 2 CE CREDITS:

46 The Physical Manifestations of Glaucoma and What They Signify

Understanding the range of structural findings associated with this condition is key to effective management.

With contributions from: Rami Aboumourad, OD, Rodney Bendure, OD, Alison Bozung, OD, Jackie Burrell, OD, Jessica Haynes, OD, Jack Phu, OD, PhD, Mohammad Rafieetary, OD, Christine Sindt, OD, Henrietta Wang, BOptom

DEPARTMENTS

6 NEWS REVIEW

Clinical, legislative and practice development updates for optometrists.

14 OUTLOOK, *By Jack Persico, Editor-in-Chief*

See For Yourself | Sharpen your disease detection skills with a new collection of images, then use it to explore our archive.

16 THROUGH MY EYES, *By Paul M. Karpecki, OD*

New Year, New Start | Add these trends to your list of goals to enhance your practice.

18 CHAIRSIDE, *By Montgomery Vickers, OD*

Pick Up the Phone | When a prospective patient calls your office, answer the ringer and be pleasant. It's not hard.

26 YOU BE THE JUDGE, *By Jerome Sherman, OD, and Sherry Bass, OD*

When a Routine Choroidal Nevus is Not | The occasional offhand comment about such a finding can prove disastrous if ignored.

20 CLINICAL QUANDARIES, *Edited by Paul C. Ajamian, OD*

Mean Streak | Timely referrals and testing can provide patients who experience these unique retinal anomalies with essential lifelong care.

116 URGENT CARE, *By Alison Bozung, OD*

The Giant in Your Chair | We are our patients' biggest advocated when triaging this ophthalmic emergency.

24 THE ESSENTIALS, *By Bisant Labib, OD*

Know Your Glow | Retroillumination can offer better examination of clear structures like the cornea and lens.

64 DIAGNOSTIC QUIZ, *By Andrew S. Gurwood, OD*

Toxic Relationship | A patient requires ongoing therapy to manage several systemic conditions. Does this make her eyesight vulnerable?

Could it be KC (KERATOCONUS)?

KC File #1: The Patient Who Corrects to 20/20



Mitch "Private Eye" Ibach OD, FAAO, Vance Thompson Vision

A 29-year-old patient came to our office for a LASIK consult because she was unhappy with fluctuating vision in her contact lenses. The patient had ocular allergies but had no other ocular diagnoses.

Her entering glasses prescription was a modest one and we were able to refract her to 20/20. However, the refraction in the right eye was our first clue that something was not quite right.

Not only is >2.00 D of refractive cylinder a warning signal for keratoconus, but the oblique axis is also unusual. About 90% of young corneas have with-the-rule (WTR) astigmatism.¹ The change in myopic spherical equivalent (SE) from baseline (the glasses prescription) was not what we would expect to see in an adult patient, either.

Autokeratometry from her referring optometrist was on the steeper side of normal, and our pachymetry measurements showed that both eyes had borderline thin corneas. Upon further questioning, the patient recalled that her sister had keratoconus. Having a first-degree relative (a parent, sibling, or child) with keratoconus increases the risk of developing the disease by 15- to 67-fold.²

At this point, we have some risk factors, but not a clear diagnosis. A closer look at topography, tomography, and anterior segment OCT epithelial mapping provided further information to make a decisive diagnosis of progressive keratoconus in the right eye.

This case illustrates that patients who see 20/20 at the phoropter can still have keratoconus. At 29, our patient was at an age where there is greater risk of progression,³ and her ocular allergies and family history elevate that risk. She was fortunate to be diagnosed and treated early in the course of her disease, while she was still correctible to 20/20. **Simply by following the KC clues that are hiding in plain sight, you can help patients like this one preserve their vision by referring them to a corneal specialist. If further testing confirms the patient has progressive KC, iLink® cross-linking could slow or halt its progression. Visit iDetectives.com to learn more.** ●

REFERENCES:

1. Kojima T, et al. *Am J Ophthalmol* 2020;215:127-34. 2. Wang Y, et al. *Am J Med Genet* 2000;93(5):403-9. 3. Ferdi AC, et al. *Ophthalmology* 2019;126(7):935-45.

#FollowTheClues



INDICATIONS Photrexa® Viscous (riboflavin 5'-phosphate in 20% dextran ophthalmic solution) and Photrexa® (riboflavin 5'-phosphate ophthalmic solution) are indicated for use with the iLink System in corneal collagen cross-linking for the treatment of progressive keratoconus and corneal ectasia following refractive surgery.

IMPORTANT SAFETY INFORMATION Corneal collagen cross-linking should not be performed on pregnant women. Ulcerative keratitis can occur. Patients should be monitored for resolution of epithelial defects. The most common ocular adverse reaction was corneal opacity (haze). Other ocular side effects include punctate keratitis, corneal striae, dry eye, corneal epithelium defect, eye pain, light sensitivity, reduced visual acuity, and blurred vision. These are not all of the side effects of the corneal collagen cross-linking treatment. For more information, go to www.livingwithkeratoconus.com to obtain the FDA-approved product labeling. You are encouraged to report all side effects to the FDA. Visit www.fda.gov/medwatch, or call 1-800-FDA-1088.

iLink | SPONSORED AND SUPPLIED BY GLAUKOS

© 2023 Glaukos PM-US-1553 Rev.1

Refraction and exam findings

| | RIGHT EYE | BCVA | LEFT EYE | BCVA |
|-------------------------|--------------------|-------|------------------|--------|
| Lensometry | -0.50 -1.50 x31 | 20/30 | -1.50 -0.50 x172 | 20/20- |
| Refraction at Phoropter | -0.75 -2.25 x34 | 20/20 | -1.75 -0.75 x160 | 20/20+ |
| Pachymetry | 478 µm | | 483 µm | |
| Autokeratometry | 45.5 / 47.50 x 112 | | 44.9 / 46.75 x80 | |

KC File #1: THE CLUES

- Large change in refraction from lensometer to phoropter
- High astigmatism (-2.25 D) with an oblique axis
- Borderline thin corneas (478/483 µm)
- Relatively steep auto Ks (47.5)



iDetective
Following the clues
for early KC detection

EDITOR-IN-CHIEF

JACK PERSICO
(610) 492-1006 • jpersico@jobson.com

SENIOR EDITOR

JULIE SHANNON
(610) 492-1005 • jshannon@jobson.com

SENIOR ASSOCIATE EDITOR

MARK DE LEON
(610) 492-1021 • mdeleon@jobson.com

ASSOCIATE EDITOR

LEANNE SPIEGLE
(610) 492-1026 • lspiegle@jobson.com

ASSOCIATE EDITOR

RACHEL RITA
(610) 492-1000 • rrita@jobson.com

SENIOR SPECIAL PROJECTS MANAGER

JILL GALLAGHER
(610) 492-1037 • jgallagher@jobson.com

ART DIRECTOR

LYNNE O'CONNOR
lyoconnor@jobson.com

DIRECTOR OF CE ADMINISTRATION

REGINA COMBS
(212) 274-7160 • rcombs@jobson.com

Clinical Editors

Chief Clinical Editor • Paul M. Karpecki, OD

Associate Clinical Editors
Joseph P. Shovlin, OD, Christine W. Sindt, OD

Clinical & Education Conference Advisor
Paul M. Karpecki, OD

Case Reports Coordinator • Andrew S. Gurwood, OD

Columnists

Advanced Procedures – Nate Lighthizer, OD

Chairside – Montgomery Vickers, OD

Clinical Quandaries – Paul C. Ajamian, OD

Cornea and Contact Lens Q+A – Joseph P. Shovlin, OD

Diagnostic Quiz – Andrew S. Gurwood, OD

The Essentials – Bisant A. Labib, OD

Focus on Refraction – Marc Taub, OD, Pamela Schnell, OD

Glaucoma Grand Rounds – James L. Fanelli, OD

Ocular Surface Review – Paul M. Karpecki, OD

Retina Quiz – Rami Aboumourad, OD

Surgical Minute – Derek Cunningham, OD, Walter Whitley, OD

Therapeutic Review – Jessica Steen, OD

Through My Eyes – Paul M. Karpecki, OD

Urgent Care – Alison Bozung, OD

You Be The Judge – Jerome Sherman, OD, Sherry Bass, OD

Editorial Offices

19 Campus Blvd., Suite 101 • Newtown Square, PA 19073

Jobson Medical Information/WebMD
283-299 Market Street, 2 Gateway Center, 4th Floor
Newark, NJ 07102

Subscription inquiries: (877) 529-1746
Continuing Education inquiries: (800) 825-4696

Printed in USA



BY JACK PERSICO
EDITOR-IN-CHIEF
OUTLOOK

See For Yourself

Sharpen your disease detection skills with a new collection of images, then use it as a springboard to explore our archives.

For the last two years, we've capped off our annual publishing slate with a digital-only issue of highlights in December called (appropriately enough) *The Year in Review*. You can find a link on our site to the newest one, which includes a feature from every 2023 issue, a standout installment of each column and a collection of news stories published over the course of the year.

Taking stock of *Review's* output over the previous 12 months, a few things jump out to me. First, we produce *a lot*. In 2023 we published just shy of one thousand articles—996, to be exact. (Yes, I'm anal retentive enough to wish we'd managed to eke out four more.)

If that number sounds high to you, it's because of another striking characteristic of the publication. In recent years, *Review* has quietly become a powerhouse of clinical news coverage in eye care, generating 754 news stories in 2023 alone; three items post every weekday morning in our online news feed. The remaining 242 articles we delivered last year comprise the monthly slate of features and columns that serve as the core of this publication. Our goal with this mix is to provide how-to clinical guidance from trusted experts through the monthly issues, while also keeping you up to date on the latest research and legislative developments in the daily news feed.

A final noteworthy aspect worth a mention is that our writers don't shy away from going deep every now and then. Last year, longtime contributor Jim Fanelli gave us 8,000 words on how to add labwork and radiologic imaging to your practice, while Associate Editor Rachel Rita dashed off an 8,400-word summary of the TFOS Lifestyle Report

on dry eye. In this issue, Henrietta Wang and Jack Phu provide an elegant 5,400-word CE course on how glaucoma manifests in the eye. Two months from now, Blair Lonsberry and Mitch Ibach will offer a 6,000-word breakdown of the do's and don'ts of oral medication use in our upcoming March issue. In short, we're not afraid to go all out once in a while to give you something comprehensive and packed with nitty-gritty details.

But sometimes, you just want to look at a cool photo. Or maybe 200.

That's why we created the photo atlas that forms the bulk of this month's issue. A group of nine ODs who've collectively "seen it all," as they say, organized the massive trove of images we share this month. From the daily staples of optometric practice to the rarest of the rare, you'll find remarkable examples in the pages to follow. We'll add to the online version continuously to keep on mapping out the world of ocular disease in as much detail as possible.

Nowadays, photos of even the rarest conditions aren't too hard to find. Want to refresh your memory on what Stargardt's, Leber's or RP looks like? Just google it. But those results aren't always reliable and, furthermore, they lack useful context or guidance. To address this, we're going to augment our photo atlas with links to articles from the magazine that teach you what to actually *do* when one of these conditions shows up in your chair. My hope is that this will help you navigate our content more easily by creating new pathways for exploration, one photo at a time.

And while you do that, we'll get back to work on our next thousand articles. Best wishes to all for a great 2024! ■



You're driven to improve people's lives through better vision.
We're driven to help you succeed.

Discover how VSP Vision™ Careers in Eye Care can help you find the job you want so you can pursue your passion as a Doctor of Optometry. Gain a competitive advantage through experienced, dedicated Talent Acquisition Specialists who can help you find your ideal position in private practice, medical, corporate, or retail.

The choice is yours. Get started on the professional opportunity that is right for you. Scan the QR code or visit vspeyecarecareers.com to find out more.



Private Practice | VSP® Ventures | Visionworks®
iCare Health Solutions | Onsite Clinics | Optical Outlets



BY PAUL M. KARPECKI, OD
CHIEF CLINICAL EDITOR

THROUGH MY EYES

New Year, New Start

Add these trends to your list of goals to enhance your practice.

The new year is always an incredible opportunity to make a new start; to dream of the potential you want to achieve and then make it happen. The journey and learning is as much of the experience as achieving the end goal. There are five key trends in eye care worth diving into and making your goals this year: virtual reality (VR), artificial intelligence (AI), myopia management, digital device use and efficiency.

FDA Approvals

Let's face it, digital device use is increasing and plays a role in MGD, blepharitis, DED and, likely, progressive myopia. Positioning your practice to address any of these conditions could be valuable.

New FDA approvals—for evaporative dry eye in Miebo (perfluorohexylcane ophthalmic, Bausch + Lomb) and *Demodex* blepharitis in Xdemvy (lotilaner ophthalmic solution, 0.25%)—are showing impressive and quick results.

Myopia management is also a major opportunity, and even Apple is addressing this with auto shutdown if children under the age of 13 don't hold the device an appropriate distance away from their eyes. The key may be having multiple options for myopia management, and an FDA-approved prescription possibly to become available this year would set the stage for a potential explosion in awareness.

VR

While this area includes big tech companies from Meta to Apple and Google/Alphabet, the optometry field is not without their own innovative technologies. One VR headset, Smart System

(M&S Technologies), has bridged the gap from a screening device to a glaucoma management tool. Whatever technology you're looking at, be sure it has active eye tracking with automated pause, otherwise you'll have patients moving their eyes within the device.

“**This will also be the year efficiency is essential, as we come off of COVID-19 and experience staffing turnover like never before.**”

NeuroLens moved from a stand-alone desktop to VR headset, allowing for rapid testing of misalignment/phorias in about three minutes, while educating patients how contoured prism may help alleviate headaches, dizziness, dry eye sensation and/or photophobia.

Dark adaptation for age-related macular degeneration (AMD) diagnosis uses VR headsets, making it easier for patients and doctors by not requiring a separate dark room. VR devices that look like normal glasses are showing significant improvement in vision and functionality for patients with advanced AMD (Eyedaptic).

AI

This fast-growing technology is already used in practical eyecare applications. One example mentioned earlier is NeuroLens; the instrument has collected over 10 million data points and has transformed the information through AI to provide the exact phoria correction

required with countered prism within minutes of measurement.

While VR headsets for VF testing mentioned above also incorporate AI, deep learning is going to be a common place for how primary eyecare doctors decide who to treat and who to refer in conditions ranging from glaucoma, diabetic macular edema, geographic atrophy, AMD and even dry eye. EHR systems and retinal imaging systems (*e.g.*, AI optics) will use this information to spot high-risk diabetic retinopathy, glaucoma and AMD patients, so appropriate referrals can be made. Low-risk patients will continue to be monitored by their optometrist, and specialists will only receive those who need advanced treatments. This is also a model for efficiency (more on that below).

Efficiency

This will also be the year when efficiency is essential, as we come off of COVID-19 and experience staffing turnover like never before. I don't just write these things; I live them. I see over 50 patients a day in my OSD clinic, thanks to an incredible staff and efficiency in every aspect of what we do. Examples include moving pre-testing to automated, higher resolution widefield imaging (Eidon), VR headsets for VF screening, rebound tonometers (iCare, Reichert), osmolarity in dry eye (TruKera Medical), streamline testing protocols and even EHR systems with significantly less clicks (Barti).

Patient education takes a significant portion of our time, but can be minimized with tools (Rendia) and/or slit lamp imaging (TelScreen). Technology itself solely serves to increase efficiency.

A new year is a wonderful time to begin implementing one or more of these ideas as these trends are not short-lived. Set your plans, get the team onboard and start making things happen. ■

About
Dr. Karpecki

Dr. Karpecki is the director of Cornea and External Disease for Kentucky Eye Institute and an associate professor at KYCO. He is the Chief Clinical Editor for Review of Optometry and chair of the New Technologies & Treatments conferences. A fixture in optometric clinical education, he consults for a wide array of ophthalmic clients, including ones discussed in this article. Dr. Karpecki's full disclosure list can be found in the online version of this article at www.reviewofoptometry.com.

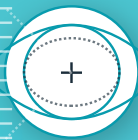LOOKING FOR A BETTER FIT FROM YOUR SCLERAL LENS?



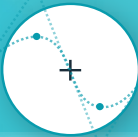Built-in oval optic zones
better centration



SmartSight®
superior visual acuity



Smart360®
free form digital lens design



SplineCurve®
*parameter independence
in a quad specific manner*



SmartChannel®
*vault anatomical obstacles
and reduce suction*

Extra Customization

- with Smart Features

Less than 2 cuts

- on average per eye

3 out of 4

- fits achieved with the standard lens in the FitKit®

16-19mm Diameters



Pick Up the Phone

When a prospective patient calls your office, answer the ringer and be pleasant. It's not hard.

Growing up, my family lived in a little but thriving town in the middle of West Virginia. We had a local phone company with human operators that we all knew from church and through their kids who went to school with us. Our landline (Google it, youngsters) phone number was “Hillside 29392” or “Hi-29392.” When we dialed someone else (which was a rare event, because we could pretty much talk to anyone in town person-to-person with a two-minute stroll) the operator would hook us up and something would happen that never happens nowadays; as long as they were home, the person would happily and immediately answer the single phone they had, usually in their kitchen, since that’s where everyone hung out anyway.

Now, everyone has a phone in their pocket that puts them in constant contact with anyone or anything in the whole universe and, that’s right, nobody ever answers. The people who don’t know your number think it’s a scam. The people who do know it’s you calling... well, they just know it’s a scam or you want something.

The only time they use their phone as a phone is when they call you or your office.

I’m on hold with the Social Security office. I am told over and over between the annoying, repetitive, so-called “musak” that I will be assisted within 57 minutes. Our tax dollars are at work, doing the only thing our government does flawlessly... keeping fake musicians employed.

Remember when actual humans answered phones? I hope it is still that way at your office, because if this old feller is impatient, imagine what a prospective 30-year-old patient who found you on his or her list of 3,000 eye doctors who accept his or her insurance must feel. That’s right, let’s just move down the list until someone human answers—see ya!

That first contact with your office is as important as any new technology you may use to determine a patient’s eye health and visual needs. You had better get it right. My idea is this: if you’re not sure what to do, call the Social Security office and just do the exact opposite.

I called a local ophthalmic surgeon’s office a few weeks ago. Here is an exact transcript of the call:

(phone rings five times)
They: “Hello.”
Me: “Hello.”
They: “Hello.”
Me: “Is this Dr. Eyebrow’s office?”
They: “Hello... uh... yeah?”
Me: “This is Dr. Vickers.”
They: “OK.”
Me: “I need to refer a patient.”
They: “OK.”
Me hanging up.

I happen to know the poor doctor has no clue what is going on at her front desk. Or does she? Back in the day, I wanted everyone to succeed and I would have moved heaven and earth to get the doctor on the phone to let them know how they could improve their staffer’s phone handling skills. I have done that very thing at least 100 times in my 45 years of practice and there has only been one doctor who thanked me and we have stayed friendly colleagues since. His personal cell phone is on speed dial on my cell phone.

The rest responded in one of three ways:

1. Don’t tell me how to run my practice.
2. We all have bad days sometimes.
3. Silence, followed by a hang up.

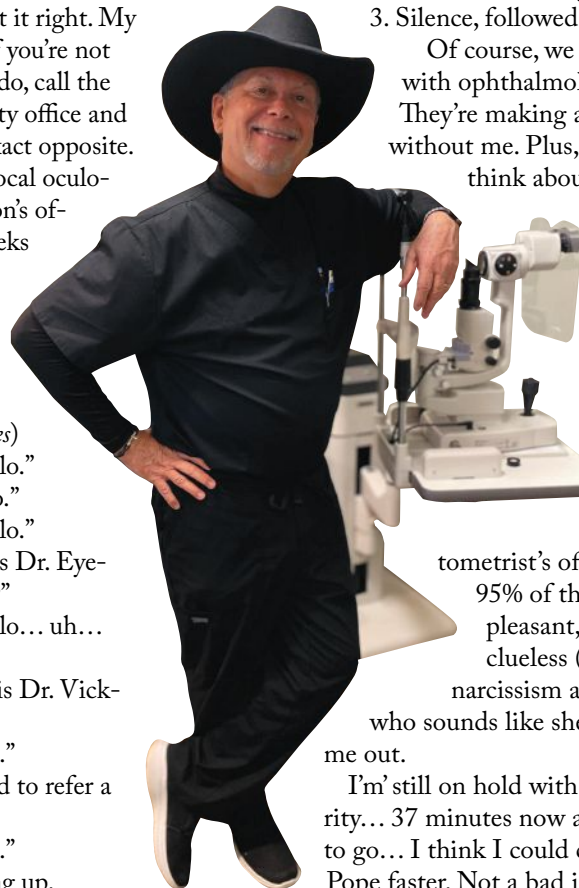
Of course, we ARE dealing with ophthalmologists here.

They’re making a decent living without me. Plus, when you

think about it, what kind of narcissistic jerk calls a “specialist” to help him improve his practice. Me, I guess.

The good news is when I call an optometrist’s office, well over 95% of the time I get a pleasant, if somewhat clueless (there goes that narcissism again) staffer who sounds like she wants to help me out.

I’m still on hold with Social Security... 37 minutes now and only 20 to go... I think I could chat with the Pope faster. Not a bad idea... ■



About Dr. Vickers

Dr. Vickers received his optometry degree from the Pennsylvania College of Optometry in 1979 and was clinical director at Vision Associates in St. Albans, WV, for 36 years. He is now in private practice in Dallas, where he continues to practice full-scope optometry. He has no financial interests to disclose.

From the makers of the #1-prescribed dry eye brand in Europe*

Covering the spectrum of Dry Eye Relief

Over-the-counter iVIZIA® lubricant eye drops deliver a unique combination of immediate and long-lasting relief and ocular surface protection in a preservative-free formulation.

- Advanced formulation offers a combination of povidone (active), hyaluronic acid (inactive), and trehalose (inactive)
- Proprietary, multi-dose bottle

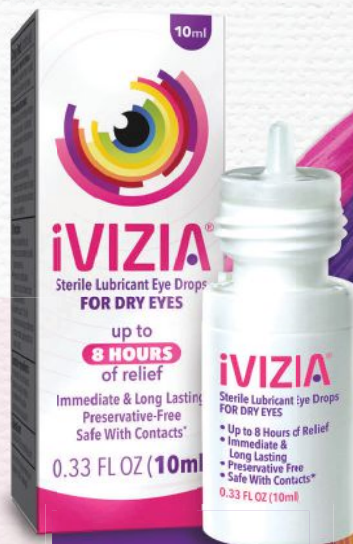Chronic Dry Eye Patient Usage Study†:

Up to
8 hours
of relief

as well as improved comfort during computer work, reading, and driving¹

84%

of users reported iVIZIA worked better than their previous eye drops¹



Safe for use with contact lenses‡



Scan here.

Recommend iVIZIA and request samples by visiting [iVIZIA.com/ECP](https://www.ivizia.com/ECP)

*Prescription market data, Dec. 2022 – S01K without cyclosporine.

¹In a chronic dry eye patient usage study, participants from a variety of socioeconomic backgrounds answered questions about iVIZIA. There were 203 chronic dry eye patients, ranging from ages 28-80, who used their current eye drops before switching to iVIZIA for 30 days.¹

[‡]To limit blurriness when using contact lenses, remove contacts, apply drops, then insert contacts.

Reference: 1. Data on file.

Copyright ©2023 Thea Pharma Inc. | All Rights Reserved. | PRC-IED-1030-v3 11.2023



BY JEROME SHERMAN, OD, AND SHERRY BASS, OD

YOU BE THE JUDGE

When a Routine Choroidal Nevus is Not

The occasional offhand comment about such a finding can prove disastrous if ignored.

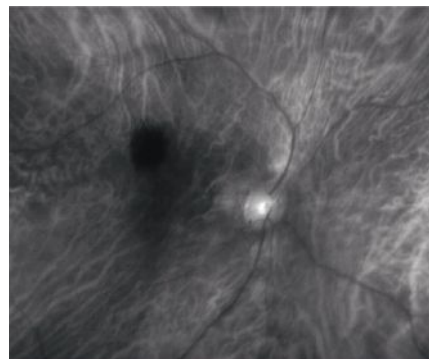
A 45-year-old well-educated Caucasian male presented for his first eye exam in a new state since moving across the country. His only complaint was slightly blurred vision at near in both eyes through his two-year-old scratched reading glasses. No significant eye or health problem was reported. He started wearing glasses after failing the vision screening in the first grade. His myopia increased for many decades, which required a new prescription every several years. He was advised previously by several ODs and MDs that he was developing minor peripheral retinal degeneration and that he should obtain emergent care if he experienced changes such as an increase in flashes, floaters, shadows, spots, cobwebs or curtains.

With a minor change in prescription, VA was correctable to 20/20 in each eye at distance and near. The dilated fundus exam revealed several patches of lattice degeneration in each eye without holes, tears or vitreal traction and a one-disc-diameter pigmented choroidal nevus that was sketched the same size as the optic disc in his right eye. The nevus was within the arcades and superior-temporal to the fovea. Fundus photos were reportedly taken.

Glasses and daily contact lenses were prescribed. The patient was told about the lattice degeneration and to report

any changes such as those discussed immediately because of the lattice degeneration in this 6D myope. A conversation about lattice degeneration sometimes resulting in peripheral retinal tears and the risk of retinal detachment was noted on the record.

When told about the small freckle in his right eye, the patient mentioned that none of the eye doctors he had seen over four decades mentioned seeing a small freckle. The eye doctor at this visit advised the patient that it was such a minor finding and present in about 10% of all patients that most eye doctors would not bother to alarm the patient with such a minor finding. The patient was scheduled for a comprehensive examination one year later.



Choroidal nevus in the right eye from a different patient that corresponds quite closely to the description and sketch documented by the first eye clinician.

About 10 months later, the patient began experiencing vague floaters and occasional flashes in his right eye. Erring on the side of caution, the patient called the group practice and was scheduled to be seen by their retina specialist the next morning. Best-corrected VA was 20/20 in each eye, and the symptomatic right eye was observed to have a temporal retinal detachment encroaching on the macula. However, a retinal tear was not observed, nor was the one-disc-diameter choroidal nevus as diagnosed nearly a year earlier. The fundus photos taken at the first visit were not commented on by the retina specialist.

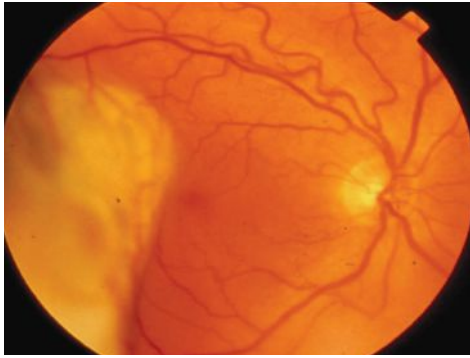You Be the Judge

In light of the facts presented thus far, consider the following questions:

- Was the freckle most likely a choroidal nevus that had been present for decades?
- Did the first eye clinician meet the existing standard of care? Would a like practitioner under like circumstances have performed any differently?
- Should the retinal detachment noted by the retina specialist have been reattached via surgery within a day?
- Since VA was 20/20 and the retinologist's exam noted that the macula was clinically normal, would the diagnosis be a macula "on" retinal detachment, which has a better prognosis, or a macula "off" retinal detachment?
- Since the retina surgeon could not find a retinal tear, would you consider a non-rhegmatogenous retinal detachment as the diagnosis? The diagnosis of a non-rhegmatogenous retinal detachment often does not require retinal surgery.
- Since the retina specialist could not find a retinal tear responsible for the retinal detachment, should this surgeon

About Drs. Sherman and Bass

Dr. Sherman is a Distinguished Teaching Professor at the SUNY State College of Optometry and editor-in-chief of *Retina Revealed* at www.retinarevealed.com. During his 53 years at SUNY, Dr. Sherman has published about 750 various manuscripts. He has also served as an expert witness in 400 malpractice cases, approximately equally split between plaintiff and defendant. Dr. Sherman has received support for *Retina Revealed* from Carl Zeiss Meditec, MacuHealth and Konan. **Dr. Bass** is a Distinguished Teaching Professor at the SUNY College of Optometry and is an attending in the Retina Clinic of the University Eye Center. She has served as an expert witness in a significant number of malpractice cases, the majority in support of the defendant. She serves as a consultant for ProQR Therapeutics.



The actual fundus photo of the patient's right eye taken that same day that patient was seen by the retinologist.

have obtained a B-scan ultrasound prior to retinal surgery?

Follow-Up

The retinologist performed a B-scan ultrasound and observed a large mass under the retina. The patient was evaluated by an ophthalmic oncologist the next day and diagnosed with an amelanotic choroidal malignant melanoma and a secondary retinal detachment. The opinion of several ophthalmic oncologists was that the lesion observed a year earlier was not a benign choroidal nevus but a small, pigmented choroidal malignant melanoma. Occasionally, a small pigmented choroidal melanoma transforms into an amelanotic malignant melanoma when the lesion enlarges, such as in this case.

Proton beam irradiation was performed at a major teaching institution in a big city. The patient was also evaluated for any metastasis to another part of the body; no other lesions were found after an extensive work-up. The patient lost vision in the right eye but retained 20/20 VA and a normal field in the left eye.

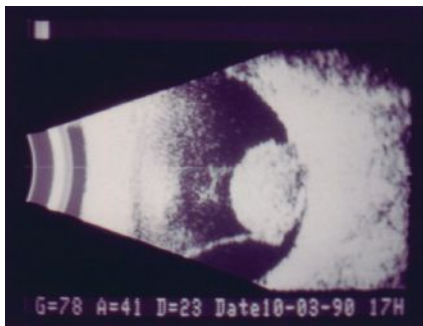
The patient traveled to the National Eye Institute in the Washington, DC area and received experimental treatments that appeared to have been successful for at least several years. The patient and his family were optimistic that the myriad treatments were successful. However, the patient woke up one morning and observed a new pigmented lesion on his left inner thigh. He died several months later due to metastasis to several major organs.

Malpractice Implications

One could argue that the first eye clinician should have taken seriously the patient's comments on the first visit that no previous eye doctor ever mentioned a "freckle" in the patient's right eye. This eye clinician could have obtained previous records, performed additional tests such as B-scan ultrasound and/or OCT and have the patient return in three months or so for a re-evaluation to determine if the lesion had increased in size, rather than waiting a year. According to the Blue Mountain Eye Study, choroidal nevi were present in 6.5% of the white population. In the United States, there are approximately only five cases of choroidal melanomas per year per million population.¹ Approximately 20% of choroidal melanomas are amelanotic and hence represent only one case per year per million population.^{2,3} As a deduction, this unfortunate patient had only a one-in-a-million chance of developing an amelanotic malignant melanoma of the choroid.

The retinologist initially detected a retinal detachment but could not find a tear responsible for the detachment. A rhegmatogenous retinal detachment by definition has a tear and is typically treated with scleral buckles, vitrectomy and pneumatic retinopexy. If no tear is discovered, the diagnosis is non-rhegmatogenous retinal detachment, and a mass under the retina must be considered. A B-scan ultrasound should be obtained immediately, as it was in this case.

The first eye clinician testified that she took fundus photos in addition to



A B-scan ultrasound from a different but similar case demonstrating a large mass and secondary retinal detachment.

her drawing. The retina surgeon testified that fundus photos were not included in the patient's chart a year later. The surgeon correctly diagnosed the melanoma and immediately referred to an ophthalmic oncologist and hence met the standard of care. However, it has been conjectured that the retinologist did review the fundus photo slides from a year earlier, found them to be suggestive or indicative of a melanoma and decided to discard the photos. The fundus photos have never been found. Not surprisingly, the first eye clinician, the retinologist as well as the large group practice were all sued.

If you are ever faced with a similar situation, knowledge of this case will likely result in you assuming that the lesion was indeed new and required further evaluation. The retinologist appeared to have met the standard of care, but one could argue that he discarded essential evidence that would have suggested that the lesion diagnosed as a nevus a year earlier was really a small melanoma. The practice had poorly documented records with regards to fundus photos, and it could not be determined whether fundus photos were ever taken or even billed. The first eye clinician is no longer with the practice and the practice is under new management. After the patient's death, the case was settled prior to a jury trial for several million dollars. ■

1. Sumich P, Mitchell P, Wang JJ. Choroidal nevi in a White population: The Blue Mountains Eye Study. *Arch Ophthalmol.* 1998;116(5):645-50.

2. Markiewicz A, Donizy P, Nowak M, et al. Amelanotic uveal melanomas evaluated by indirect ophthalmoscopy reveal better long-term prognosis than pigmented primary tumors—a single center experience. *Cancers (Basel).* 2022;14(11):2753.

3. Stuart K, Patel S. Amelanotic choroidal melanoma: a teaching case report. *J Optometric Ed.* 2021;46(2).

NOTE: This article is one of a series based on actual lawsuits in which the author served as an expert witness or rendered an expert opinion. These cases are factual, but some details have been altered to preserve confidentiality. The article represents the authors' opinion of acceptable standards of care and do not give legal or medical advice. Laws, standards and the outcome of cases can vary from place to place. Others' opinions may differ; we welcome yours.

IYUZEH™ (latanoprost ophthalmic solution) 0.005% is the first and only preservative-free latanoprost for patients with primary open-angle glaucoma (POAG) and ocular hypertension (OHT).



Transform how you lower IOP. POWER WITHOUT PRESERVATIVES.

INDICATIONS AND USAGE

IYUZEH™ is a prostaglandin analogue indicated for the reduction of elevated intraocular pressure in patients with open-angle glaucoma or ocular hypertension.

IMPORTANT SAFETY INFORMATION

CONTRAINDICATIONS

Known hypersensitivity to latanoprost or any other ingredients in this product.

WARNINGS AND PRECAUTIONS

Pigmentation: Topical latanoprost ophthalmic products, including IYUZEH™ have been reported to cause changes to pigmented tissues. The most frequently reported changes have been increased pigmentation of the iris, periorbital tissue (eyelid), and eyelashes. Pigmentation is expected to increase as long as latanoprost is administered.

The pigmentation change is due to increased melanin content in the melanocytes rather than to an increase in the number of melanocytes.

After discontinuation of latanoprost, pigmentation of the iris is likely to be permanent, while pigmentation of the periorbital tissue and eyelash changes have been reported to be reversible in some patients. Patients who receive treatment should be informed of the possibility of increased pigmentation. The long-term effects of increased pigmentation are not known.

Iris color change may not be noticeable for several months to years. Typically, the brown pigmentation around the pupil spreads concentrically towards the periphery of the iris and the entire iris or parts of the iris become more brownish. Neither nevi nor freckles of the iris appear to be affected by treatment. While treatment with IYUZEH™ can be continued in patients who develop noticeably increased iris pigmentation, these patients should be examined regularly.

Eyelash Changes: Latanoprost ophthalmic products, including IYUZEH™ may gradually change eyelashes and vellus hair in the treated eye; these changes include increased length, thickness, pigmentation, the number of lashes or hairs, and misdirected growth of eyelashes. Eyelash changes are usually reversible upon discontinuation of treatment.

IYUZEH™ HAD SIMILAR MEAN IOP REDUCTION WHEN COMPARED WITH XALATAN®

IN PHASE III TRIALS, REDUCED IOP WITH PROVEN EFFICACY

IYUZEH
LOWERED IOP
by 3-8 mmHg (n=165)
vs
4-8 mmHg (n=169)
for XALATAN¹

30 single-dose containers (0.2 mL each)
For Topical Ophthalmic Use - Rx only

“
We owe it to our patients with elevated intraocular pressure, with open-angle glaucoma or ocular hypertension to provide a new evidence-based best practice. It is an extremely exciting time to prescribe IYUZEH for my patients.

”
Monique M. Barbour
MD, MHA, FAAO

Dr. Barbour is a paid consultant of Thea Pharma Inc.



Intraocular Inflammation: IYUZEH™ should be used with caution in patients with a history of intraocular inflammation (iritis/uveitis) and should generally not be used in patients with active intraocular inflammation because inflammation may be exacerbated.

Macular Edema: Macular edema, including cystoid macular edema, has been reported during treatment with latanoprost ophthalmic products, including IYUZEH™. IYUZEH™ should be used with caution in aphakic patients, in pseudophakic patients with a torn posterior lens capsule, or in patients with known risk factors for macular edema.

Herpetic Keratitis: Reactivation of herpes simplex keratitis has been reported during treatment with latanoprost. IYUZEH™ should be used with caution in patients with a history of herpetic keratitis. IYUZEH™ should be avoided in cases of active herpes simplex keratitis because inflammation may be exacerbated.

Contact Lens Use: Contact lenses should be removed prior to the administration of IYUZEH™ and may be reinserted 15 minutes after administration.

ADVERSE REACTIONS

The following adverse reactions have been reported with the use of topical latanoprost products: iris pigmentation changes, eyelid skin darkening, eyelash changes (increased length, thickness, pigmentation, and number of lashes), intraocular inflammation (iritis/uveitis), and macular edema, including cystoid macular edema.

DRUG INTERACTIONS

The combined use of two or more prostaglandins, or prostaglandin analogs including IYUZEH™ is not recommended. It has been shown that administration of these prostaglandin drug products more than once daily may decrease the IOP lowering effect or cause paradoxical elevations in IOP.

Please see full Prescribing Information at www.iyuzeh.com and Brief Summary on the next page.

Explore the power of preservative-free latanoprost at iyuzeh.com



iyuzeh™

(latanoprost ophthalmic solution) 0.005%

HIGHLIGHTS OF PRESCRIBING INFORMATION

This brief summary does not include all the information needed to use IYUZEH safely and effectively. See full prescribing information for IYUZEH.

Initial U.S. Approval: 2022

INDICATIONS AND USAGE

IYUZEH is a prostaglandin F2α analogue indicated for the reduction of elevated intraocular pressure in patients with open-angle glaucoma or ocular hypertension.

CONTRAINDICATIONS

Known hypersensitivity to latanoprost or any other ingredients in this product.

WARNINGS AND PRECAUTIONS

Pigmentation: Topical latanoprost ophthalmic products, including IYUZEH have been reported to cause changes to pigmented tissues. The most frequently reported changes have been increased pigmentation of the iris, periorbital tissue (eyelid), and eyelashes. Pigmentation is expected to increase as long as latanoprost is administered.

The pigmentation change is due to increased melanin content in the melanocytes rather than to an increase in the number of melanocytes. After discontinuation of latanoprost, pigmentation of the iris is likely to be permanent, while pigmentation of the periorbital tissue and eyelash changes have been reported to be reversible in some patients. Patients who receive treatment should be informed of the possibility of increased pigmentation. The long-term effects of increased pigmentation are not known.

Iris color change may not be noticeable for several months to years. Typically, the brown pigmentation around the pupil spreads concentrically towards the periphery of the iris and the entire iris or parts of the iris become more brownish. Neither nevi nor freckles of the iris appear to be affected by treatment. While treatment with IYUZEH can be continued in patients who develop noticeably increased iris pigmentation, these patients should be examined regularly.

Eyelash Changes: Latanoprost ophthalmic products, including IYUZEH may gradually change eyelashes and vellus hair in the treated eye; these changes include increased length, thickness, pigmentation, the number of lashes or hairs, and misdirected growth of eyelashes. Eyelash changes are usually reversible upon discontinuation of treatment.

Intraocular Inflammation: IYUZEH should be used with caution in patients with a history of intraocular inflammation (iritis/uveitis) and should generally not be used in patients with active intraocular inflammation because inflammation may be exacerbated.

Macular Edema: Macular edema, including cystoid macular edema, has been reported during treatment with latanoprost ophthalmic products, including IYUZEH. IYUZEH should be used with caution in aphakic patients, pseudophakic patients with a torn posterior lens capsule, or in patients with known risk factors for macular edema.

Herpetic Keratitis: Reactivation of herpes simplex keratitis has been reported during treatment with latanoprost. IYUZEH should be used with caution in patients with a history of herpetic keratitis and should be avoided in cases of active herpes simplex keratitis because inflammation may be exacerbated.

Contact Lens Use: Contact lenses should be removed prior to the administration of IYUZEH and may be reinserted 15 minutes after administration.

ADVERSE REACTIONS

The following adverse reactions have been reported with the use of topical latanoprost products and are discussed in greater detail in the prescribing information:

- Iris pigmentation changes
- Eyelid skin darkening
- Eyelash changes (increased length, thickness, pigmentation, and number of lashes)
- Intraocular inflammation (iritis/uveitis)
- Macular edema, including cystoid macular edema

Because clinical trials are conducted under widely varying conditions, adverse reaction rates observed in the clinical trials of a drug cannot be directly compared to rates in the clinical trials of another drug and may not reflect the rates observed in practice.

In the two clinical trials conducted with IYUZEH (latanoprost ophthalmic solution) 0.005% comparing it to XALATAN the preserved 0.005% latanoprost reference product, the most frequently reported ocular adverse reactions were conjunctival hyperemia and eye irritation (Table 1).

Table 1. Adverse Reactions

| Symptom/Finding | Adverse Reactions [n (%)] | |
|--------------------------------|---------------------------|-----------------|
| | IYUZEH (n=378) | XALATAN (n=358) |
| Conjunctival hyperemia | 129 (34) | 133 (37) |
| Eye irritation | 72 (19) | 112 (31) |
| Eye pruritus | 57 (15) | 58 (16) |
| Abnormal sensation in eyes | 51 (14) | 52 (15) |
| Foreign body sensation in eyes | 44 (12) | 36 (10) |
| Vision blurred | 28 (7) | 30 (8) |
| Lacrimation increased | 19 (5) | 14 (4) |
| Photophobia | 13 (3) | 17 (5) |

POSTMARKETING EXPERIENCE

The following adverse reactions have been identified during post-approval use of topical latanoprost products. Because these reactions are reported voluntarily from a population of uncertain size, it is not always possible to reliably estimate their frequency or establish a causal relationship to drug exposure. The reactions, which have been chosen for inclusion due to either their seriousness, frequency of reporting, possible causal connection to ophthalmic latanoprost products, or a combination of these factors, include:

- Nervous System Disorders: Dizziness; headache; toxic epidermal necrolysis
- Eye Disorders: Eyelash and vellus hair changes of the eyelid (increased length, thickness, pigmentation, and number of eyelashes); keratitis; corneal edema and erosions; intraocular inflammation (iritis/uveitis); macular edema, including cystoid macular edema; trichiasis; periorbital and lid changes resulting in deepening of the eyelid sulcus; iris cyst; eyelid skin darkening; localized skin reaction on the eyelids; conjunctivitis; pseudophthalmic of the ocular conjunctiva.
- Respiratory, Thoracic and Mediastinal Disorders: Asthma and exacerbation of asthma; dyspnea
- Skin and Subcutaneous Tissue Disorders: Pruritis
- Infections and Infestations: Herpes keratitis
- Cardiac Disorders: Angina; palpitations; angina unstable
- General Disorders and Administration Site Conditions: Chest pain

DRUG INTERACTIONS

The combined use of two or more prostaglandins, or prostaglandin analogs including IYUZEH is not recommended, and administration of these prostaglandin drug products more than once daily may decrease the IOP lowering effect or cause paradoxical IOP elevations.

USE IN SPECIFIC POPULATIONS

Pregnancy: There are no adequate and well-controlled studies of IYUZEH administration in pregnant women to inform drug-associated risks.

Lactation: It is not known whether this drug or its metabolites are excreted in human milk. Because many drugs are excreted in human milk, caution should be exercised when IYUZEH is administered to a nursing woman. The developmental and health benefits of breastfeeding should be considered along with the mother's clinical need for IYUZEH and any potential adverse effects on the breastfed child from IYUZEH.

Pediatric Use: The safety and effectiveness of IYUZEH have not been established in pediatric patients.

Geriatric Use: No overall differences in the safety or effectiveness of IYUZEH have been observed between elderly and younger adult patients.

OVERDOSAGE

Intravenous infusion of up to 3 mcg/kg of latanoprost in healthy volunteers produced mean plasma concentrations 200 times higher than during clinical treatment with latanoprost ophthalmic solution and no adverse reactions were observed. IV dosages of 5.5 to 10 mcg/kg caused abdominal pain, dizziness, fatigue, hot flushes, nausea, and sweating.

HANDLING THE CONTAINER

IYUZEH is a sterile solution that does not contain a preservative supplied in a single-dose container. The solution from one individual container is to be used immediately after opening for administration to one or both eyes. Since sterility cannot be maintained after the individual container is opened, the remaining contents should be discarded immediately after administration. Open a new single-dose container every time you use IYUZEH.

Manufactured for: Thea Pharma Inc. Waltham, MA.

All rights reserved.

U.S. Patent N^o. 8,637,054.

Revised: 04/2023

©2021 Laboratoires Théa. All Rights Reserved. IYUZEH™ is a trademark of Laboratoires Théa.



EDITED BY PAUL C. AJAMIAN, OD

CLINICAL QUANDARIES

Mean Streak

Timely referrals and testing can provide patients who experience these unique retinal anomalies with essential lifelong care.

Q A patient presented to me with angioid streaks and no systemic diagnosis. I know the importance of diagnosing angioid streaks and monitoring for a potential choroidal neovascular membrane (CNVM), but should eyecare providers be further investigating systemic diagnoses related to the ocular findings?

A Angioid streaks can be idiopathic or related to systemic diseases that can cause significant morbidity and even death. “The goal is to provide the patient with the best ocular and systemic care, so further testing is essential,” says Caitlynn Estevez-Averhart, OD, an ocular disease resident at the Tuscaloosa Veterans Affairs Medical Center in Tuscaloosa, AL. “These patients are at risk for early death from the same disease process elsewhere in the body.”

Angioid streaks radiate from the optic disc, which result from breaks in a weakened Bruch’s membrane. New blood vessels can grow and break through the compromised choroid, causing a CNVM. “It is crucial to note the presence of angioid streaks and monitor these patients closely,” Dr. Estevez-Averhart adds. “CNVM can cause permanent vision loss.”

Conditions associated with angioid streaks include pseudoxanthoma elasticum (PXE), Ehler-Danlos, Paget’s disease and sickle cell; cases can also be idiopathic. These entities are known as the PEPSI conditions.

Differentials

PXE is the most common disease associated with angioid streaks. If undiagnosed

and untreated, results can be deadly. This genetic disease causes the accumulation of minerals and fragmentation of elastic fibers in the skin, Bruch’s membrane and the innermost layer of the blood vessels. Referrals to dermatology, cardiology and gastroenterology are most appropriate to confirm PXE as a diagnosis, and the goal is to prevent spontaneous hemorrhaging in the GI system and early heart disease. It is important to not only examine the eye itself but also perform an external examination of the patient. A common PXE finding is a subtle plucked-skin appearance on the neck, which is pathogenic for pseudoxanthoma. Dermatology can perform a biopsy of nodules which will show a thickening of the elastic fibers for a confirmatory diagnosis.

Paget’s is a chronic bone disease causing arthritis, bone deformities and fractures. Biopsies, lab tests and X-rays can confirm the diagnosis. The X-rays show increased bone density and deformities. Alkaline phosphatase is usually included in a comprehensive metabolic panel and a liver panel to monitor bone

and liver disorders. Levels will be elevated in Paget’s disease.

Sickle cell is an inherited red blood cell disorder where hemoglobin is abnormal. These sickled blood cells can clog small vessels and cause organ damage, pain in extremities and strokes. Diagnosis is made with a blood test called Sickledex. Case history and patient demographics can determine if further testing is necessary.

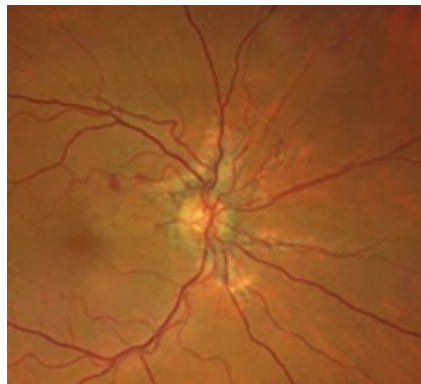Ehlers-Danlos is the least common condition associated with angioid streaks. This group of connective tissue disorders is often noticed first in children and can cause symptoms ranging from mildly loose joints to hypermobility and weak muscle tone that delays motor development. Proper diagnosis is made with genetic testing.

Angioid streaks and peau d’orange can be ocular findings without a related systemic diagnosis. Angioid streaks can be idiopathic and ultimately a diagnosis of exclusion.

Takeaways

Eyecare providers are well-versed in monitoring angioid streaks and potential complications such as CNVM. We can directly visualize the damage to the elastin layer in our retinal exam, so we are often the first physicians to raise the red flag. However, ensuring that the patient gets further testing and specialty care is the vital next step to potentially extending the lives of these angioid streak patients.

“Ordering blood work and further systemic testing is often not part of regular day-to-day primary eye care,” Dr. Estevez-Averhart says. “It is our responsibility as eyecare professionals to advocate for our patients.” Once the tests are ordered, be sure to follow through, make sure the patient gets the studies done in a timely manner and document everything in detail. ■



Angioid streaks associated with PXE.

About Dr. Ajamian

Dr. Ajamian is board certified by the American Board of Optometry and serves as Center Director of Omni Eye Services of Atlanta. He is vice president of the Georgia State Board of Optometry and general CE chairman of SECO International. He has no financial interests to disclose.

tyrvaya[®]
(varenicline solution)
nasal spray 0.03 mg

FOR THE SIGNS
& SYMPTOMS OF
DRY EYE DISEASE

SHE'S LOOKING TO YOU FOR A
DIFFERENT APPROACH WHEN
ARTIFICIAL TEARS ARE NOT ENOUGH.¹

BEFORE ANOTHER DROP

ACTIVATE REAL TEARS

WITH THE FIRST AND ONLY NASAL
SPRAY FOR DRY EYE²



Tyrvaya[®] is not another drop

It's an **ocular surface-sparing** nasal spray.²



Activates real, basal tears

Tyrvaya[®] is believed to work by activating the trigeminal parasympathetic pathway resulting in **basal tear production**.^{2*}



Real tears, real fast

In 2 clinical trials with **mild, moderate, and severe** dry eye disease patients, Tyrvaya increased tear production from baseline by **≥10 mm in Schirmer's Test Score (STS) in nearly 50% of patients at week 4**, with increased tears seen as early as the first dose and over 12 weeks.^{2-8†}

SEE WHAT
TYRVAYA
CAN DO



*The exact mechanism of action is unknown.

†Tyrvaya was evaluated across 3 randomized, vehicle-controlled, double-masked studies in which adults aged ≥22 years diagnosed with dry eye disease received 1 spray of either active drug or vehicle in each nostril twice daily. Primary endpoint: % of patients with mean change from baseline in STS of ≥10 mm at week 4 in ONSET-1: 52% with Tyrvaya (n=48) vs 14% with vehicle (n=43) and in ONSET-2: 47% with Tyrvaya (n=260) vs 28% with vehicle (n=252). Onset of action: mean change from baseline in STS ~5 minutes after first dose (not a prespecified endpoint) in ONSET-1 was 17.2 mm with Tyrvaya (n=48) vs 4.0 mm with vehicle (n=43) and in ONSET-2 was 16.5 mm with Tyrvaya (n=260) vs 6.9 mm with vehicle (n=251). Observed data. On Day 1 in clinical studies, a baseline anesthetized Schirmer's test was performed. Tyrvaya was then administered concurrently with Schirmer's test. Schirmer's test results were measured at ~5 minutes. Mean change from baseline in STS at week 12 in the MYSTIC study was 10.8 mm with Tyrvaya vs 6.0 mm with vehicle. Limitations: Ex-US, single-center study. All subjects were Hispanic or Latino. Tyrvaya group mean baseline STS 5.5 mm (n=41); vehicle group mean baseline STS 5.3 mm (n=41). All randomized and treated patients were included in the analysis and missing data were imputed using last-available data.²⁻⁸
See references on next page.

Indication

Tyrvaya[®] (varenicline solution) nasal spray is indicated for the treatment of the signs and symptoms of dry eye disease.

Important Safety Information

The most common adverse reaction reported in 82% of patients was sneezing. Events that were reported in 5-16% of patients were cough, throat irritation, and instillation-site (nose) irritation.

Please see Brief Summary of Prescribing Information on the next page and the full Prescribing Information at Tyrvaya-pro.com.

BRIEF SUMMARY: Consult the full Prescribing Information for complete product information available at www.tyrvaya-pro.com.

INDICATIONS AND USAGE

TYRVAYA[®] (varenicline solution) nasal spray is a cholinergic agonist indicated for the treatment of the signs and symptoms of dry eye disease.

ADVERSE REACTIONS

Clinical Trials Experience: Because clinical trials are conducted under widely varying conditions, adverse reaction rates observed in the clinical trials of a drug cannot be directly compared to rates in the clinical trials of another drug and may not reflect the rates observed in practice.

In three clinical trials of dry eye disease conducted with varenicline solution nasal spray, 349 patients received at least 1 dose of TYRVAYA. The majority of patients had 31 days of treatment exposure, with a maximum exposure of 105 days.

The most common adverse reactions reported in 82% of TYRVAYA treated patients was sneezing. Other common adverse reactions that were reported in >5% of patients include cough (16%), throat irritation (13%), and instillation-site (nose) irritation (8%).

USE IN SPECIFIC POPULATIONS

Pregnancy: Risk Summary: There are no available data on TYRVAYA use in pregnant women to inform any drug associated risks. In animal reproduction studies, varenicline did not produce malformations at clinically relevant doses.

All pregnancies have a risk of birth defect, loss, or other adverse outcomes. In the US general population, the estimated background risk of

major birth defects and miscarriage in clinically recognized pregnancies is 2% to 4% and 15% to 20%, respectively.

Data: Animal Data: Pregnant rats and rabbits received varenicline succinate during organogenesis at oral doses up to 15 and 30 mg/kg/day, respectively. While no fetal structural abnormalities occurred in either species, maternal toxicity, characterized by reduced body weight gain, and reduced fetal weights occurred in rabbits at the highest dose (4864 times the MRHD on a mg/m² basis).

In a pre- and postnatal development study, pregnant rats received up to 15 mg/kg/day of oral varenicline succinate from organogenesis through lactation. Maternal toxicity, characterized by a decrease in body weight gain, was observed at 15 mg/kg/day (1216 times the MRHD on a mg/m² basis). Decreased fertility and increased auditory startle response occurred in offspring at the highest maternal dose of 15 mg/kg/day.

Lactation: Risk summary: There are no data on the presence of varenicline in human milk, the effects on the breastfed infant, or the effects on milk production. In animal studies varenicline was present in milk of lactating rats. However, due to species-specific differences in lactation physiology, animal data may not reliably predict drug levels in human milk.

The lack of clinical data during lactation precludes a clear determination of the risk of TYRVAYA to an infant during lactation; however, the developmental and health benefits of breastfeeding should be considered along with the mother's clinical need for TYRVAYA and any potential adverse effects on the breastfed child from TYRVAYA.

Pediatric Use: Safety and efficacy of TYRVAYA in pediatric patients have not been established.

Geriatric Use: No overall differences in safety or effectiveness have been observed between elderly and younger adult patients.

References: **1.** Jones L, Downie LE, Korb D, et al. *Ocul Surf.* 2017;15(3):575-628. **2.** Tyrvaya. Prescribing Information. Oyster Point Pharma; 2021. **3.** Oyster Point Pharma. Data on file. OPP-002 (ONSET-1) Clinical Study Report. August 4, 2019. **4.** Oyster Point Pharma. Data on file. OPP-101 (ONSET-2) Interim Clinical Study Report. October 13, 2020. **5.** Quiroz-Mercado H, Hernandez-Quintela E, Chiu KH, Henry E, Nau JA. *Ocul Surf.* 2022;24:15-21. **6.** Wirta D, Torkildsen GL, Boehmer B, et al. *Cornea.* 2022;4(10):1207-1216. **7.** Wirta D, Vollmer P, Paauw J, et al. *Ophthalmology.* 2021;0(0):379-387. **8.** Oyster Point Pharma. Data on file. OPP-004 (MYSTIC) Clinical Study Report. March 19, 2020.

Manufactured for Oyster Point Pharma, Inc. 202 Carnegie Center, Suite 106, Princeton NJ 08540. For more information, visit www.tyrvaya-pro.com. To report an adverse event, contact 1-877-EYE-0123.

© 2023 Viatrix Inc. and/or its affiliates. All rights reserved. VIATRIS and the Viatrix Logo are trademarks of Mylan Inc., a Viatrix Company. Oyster Point[®], Tyrvaya[®], and the Tyrvaya logo are trademarks of Oyster Point Pharma, Inc., a Viatrix company, in the United States and certain jurisdictions. OP-TYR-002308 7/23

The Review of Optometry Photo Atlas of Ocular Disease

This new visual guide documents over 200 presentations encountered in clinical practice.

WITH CONTRIBUTIONS BY



Rami Aboumourad, OD, a practicing optometrist at Bascom Palmer who specializes in comprehensive and emergency eye care. He has a passion for detection and early identification of ocular disease.



Rodney Bendure, OD, staff optometrist and externship coordinator at Ernest Childers Veterans Affairs Outpatient Clinic in Tulsa, OK. He is a fellow of the American Academy of Optometry.



Alison Bozung, OD, currently practices at Bascom Palmer where she primarily sees patients in the hospital's 24/7 ophthalmic emergency department. She also serves as the optometry residency program coordinator.



Jackie Burress, OD, staff optometrist at the Jack C. Montgomery VA Medical Center in Muskogee, OK, and an executive member of the Oklahoma Association of Optometric Physicians Congress Committee.



Jessica Haynes, OD, consultative optometrist at the Charles Retina Institute in Germantown, TN, and consulting faculty at Southern College of Optometry in Memphis. She is a fellow of the American Academy of Optometry.



Jack Phu, OD, PhD, a clinician-scientist holding the positions of lecturer at the School of Optometry and Vision Science, University of New South Wales, and research fellow at Deakin University.



Mohammad Rafieetary, OD, consultative optometric physician at the Charles Retina Institute in Germantown, TN. He is a fellow of the American Academy of Optometry and the Optometric Retina Society.



Christine Sindt, OD, clinical professor of ophthalmology and visual sciences at the University of Iowa Carver College of Medicine. Her areas of expertise include corneal diseases and specialty contact lens design.



Henrietta Wang, BOptom, head of the Glaucoma/Neuro-ophthalmology unit at the Centre for Eye Health, University of New South Wales. Her clinical and research interests lie in glaucoma and other optic nerve diseases.

Eye doctors are fortunate to have the subject of their study readily available for visual inspection. The ocular anatomy is directly accessible for in-office examination, mostly just by using the standard battery of tests and tools you trained with in school. But this can create a deluge of visual information to process. You must have an explanation at your fingertips for every unusual lump, contour, discoloration and squiggle you see during an eye exam.

To help, *Review of Optometry* created the following new resource—a photo atlas of ocular diseases broad enough in scope to include conditions both commonplace and rare, benign and worrisome, chronic and acute, across the entire spectrum of eye care.

The nine optometrists featured here were instrumental in developing this atlas with us. They shared their time, expertise, patient records and, most of all, their photo libraries to create it. It's our hope that this issue can give you a quick refresher on the clinical features of many ocular diseases and will become a handy reference guide to aid future patient care responsibilities.

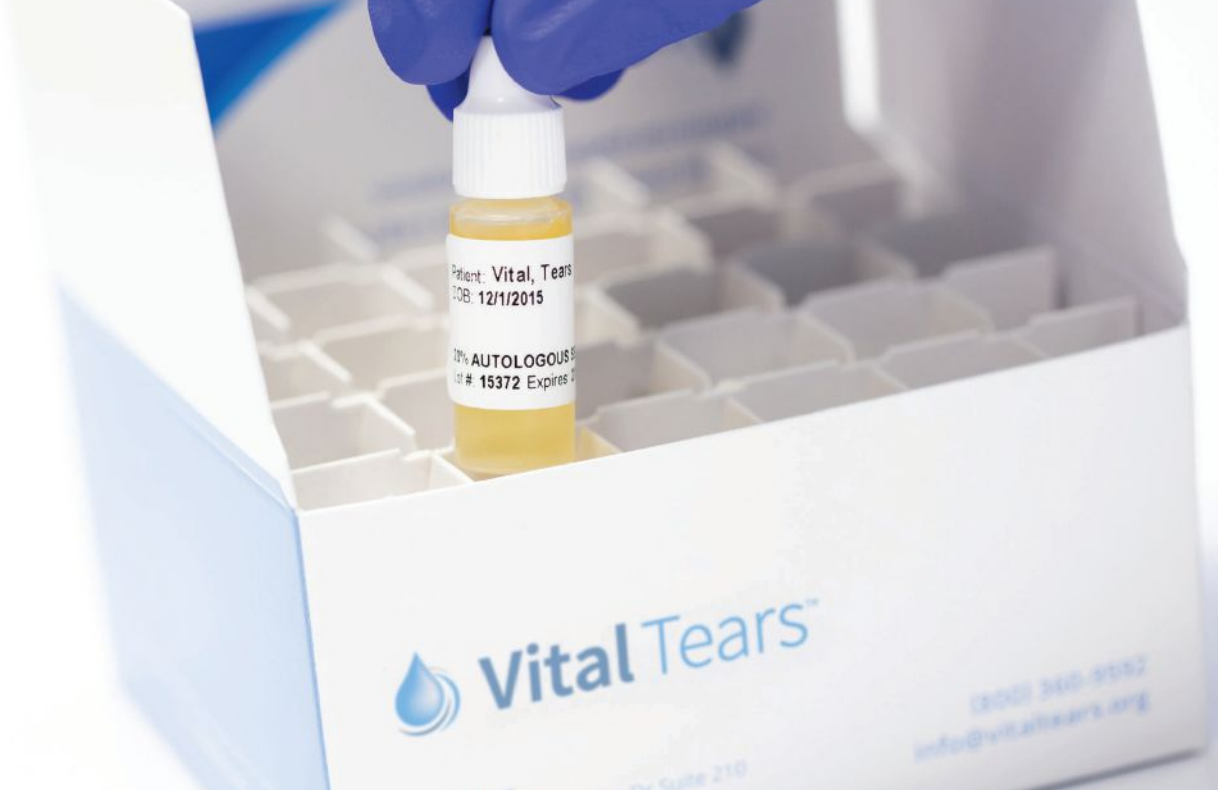Of course, keep in mind that nearly all conditions can present in a wide variety of ways and what's depicted here is often just one instance of many. In other words, these photos are representative, but rarely the final word.

The online version of *The Photo Atlas of Ocular Disease* will provide you with a deeper understanding of these conditions in a few ways. First, you'll be able to view the photos larger and in more detail. Second, we'll add to it over time, so that new conditions and alternative presentations can be included. Lastly, we will share links to articles from *Review's* archives that give in-depth clinical guidance on many of the included diseases and disorders. So, if you see an intriguing photo and would like more context, just follow the links for suggested reading.

I would like to thank all the contributors who made this atlas possible. Their experience and expertise shine through in every photo.

—Jack Persico, Editor-in-Chief

Additional photos: Aaron Bronner, OD, Greg Caldwell, OD, Paul Karpecki, OD, Stephanie Fromstein, OD, Mitch Ibach, OD, Nate Lighthizer, OD, Irving Martinez-Navé, OD, Suzanne Sherman, OD



Serum Tears Made **Easy, Fast & Safe**

We make it easy for you and your patients to get a **six-month supply of serum tears** from a single blood draw, with **turnaround times as quick as 48 hours** from the blood draw appointment.

Simply place your order online and then Vital Tears takes care of the rest.

1

We contact the patient to schedule the blood draw and collect payment.

2

Blood is drawn at one of our 400+ contracted facilities or by a mobile phlebotomist.

3

Serum tears are processed using rigorous, validated safety procedures then shipped directly to the patient.



EYELID ISSUES: LUMPS, BUMPS AND BEYOND

While these lesions tend to be benign, the wide array of presentations makes assessment tricky. Here's a visual reference to follow.

As primary eyecare providers, optometrists are responsible for the evaluation, management and, in many cases, the in-office treatment of a wide variety of eyelid lesions. Evaluation of the lids and adnexa is an important part of any eye exam and for us that begins with our initial face-to-face encounter with the patient. General characteristics such as symmetry (both inter-eye and intra-eye), skin color, loss of lashes, injection, bleeding and crusting are often evident by gross examination at a normal social distance.

A thorough slit lamp exam can then further inspect any areas of suspected pathology. It is important to look at the lids both closed and open to fully assess for any lesions and observe the apposition of the lids to the globe. In general,

it is best to begin your slit lamp exam at a low magnification (6.3x or 10x) with a broad beam providing diffuse illumination. The anatomy of the lids, with their wide array of tissue and gland types, as well as the recognition that eyelid skin is typically uncovered and exposed to environmental factors such as UV light, explains the variety of lumps and bumps encountered in optometric practice.

Documentation of these lesions, including measurement of both vertical and horizontal meridians, will allow the clinician to monitor for growth or potential change to malignancy at future exams. Lesions chosen for in-office removal should be sent for pathologic evaluation, as research has shown that a small percentage of these that present with only benign characteristics are

indeed cancerous. Those with malignant characteristics should be sent to a trusted oculoplastics ophthalmologist familiar with the appropriate comanagement of such conditions. When in doubt, it is wise to thoroughly document the lesion (photographic documentation is quite useful), educate the patient on malevolent signs of conversion to malignancy and ensure appropriate follow-up for clinical re-evaluation.

This section of photos should help distinguish eyelid/adnexal conditions that may have overlapping characteristics at presentation, as well as showcase more abnormal or rare presentations of frequent, common conditions. We hope to provide you a quick, convenient reference for all your eyelid evaluation needs!

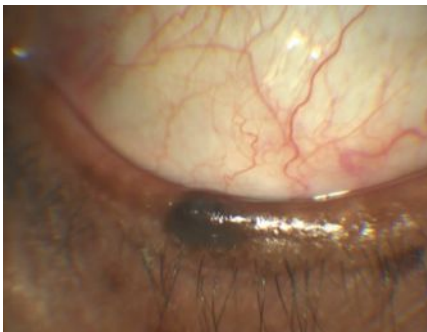

Photo: Rodney Bendure, OD Jackie Burruss, OD

In junctional nevi, melanocytes proliferate in the epidermis at the epidermal-dermal border, eventually migrating to the dermis.

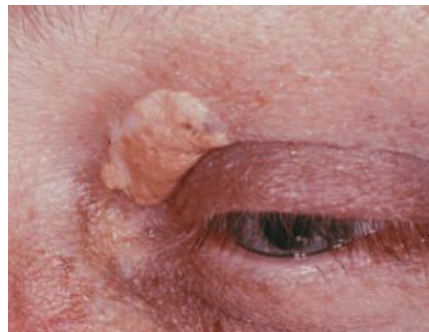


Photo: Rodney Bendure, OD Jackie Burruss, OD

Xanthelasma are plaques filled with lipid-laden macrophages. These may be surgically removed, but do tend to recur.

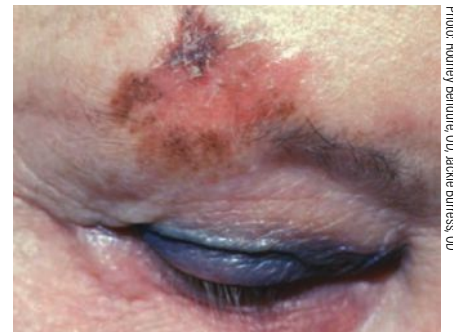
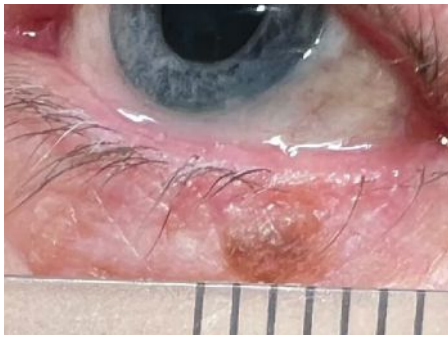
Photo: Rodney Bendure, OD Jackie Burruss, OD

Lentigo maligna tend to be flat brown-to-black macules in older patients. Slow growth and irregular borders are typical.



Seborrheic keratoses appear as elevated, pigmented, crusty, greasy, stuck-on plaques. While benign, a sudden increase in number or size could indicate a systemic malignancy. They develop from intradermal proliferation of basal cells within the epidermis.

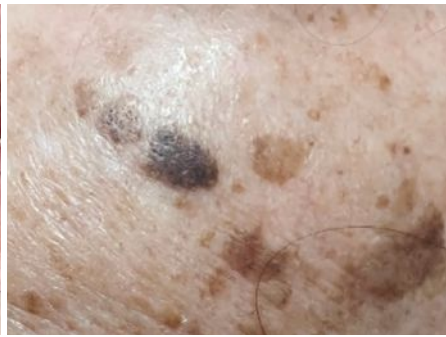


Photo: Rodney Bendure, OD, Jackie Burruss, OD

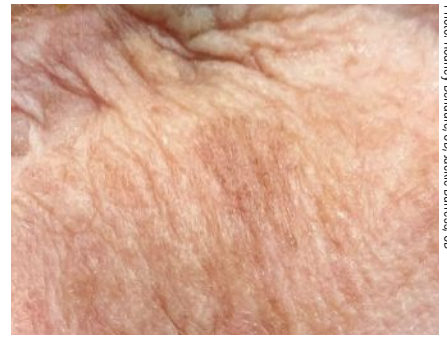

Photo: Rodney Bendure, OD, Jackie Burruss, OD

Solar lentigos are evenly hyperpigmented macules, while precancerous lesions have variable pigment and more irregular borders.

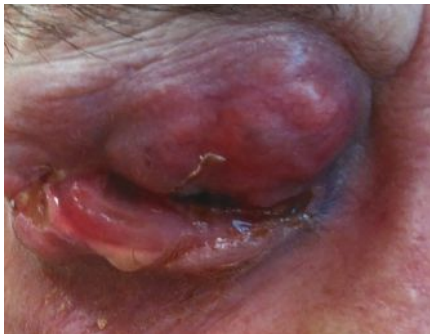
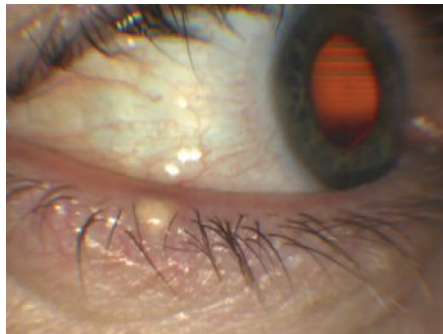
Photo: Rodney Bendure, OD, Jackie Burruss, OD

Sebaceous gland carcinoma—a rare, slow-growing tumor with predilection for the upper lid—can be mistaken for internal hordeola.



Sebaceous cysts, caused by blocked pilosebaceous follicles containing sebum, are more commonly found on lid margin structures such as the gland of Zeis (left) but may rarely also occur on the inner canthus, including the caruncle (right).

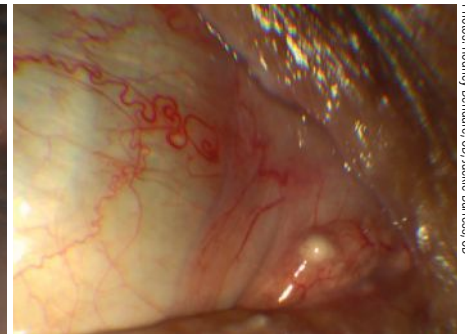
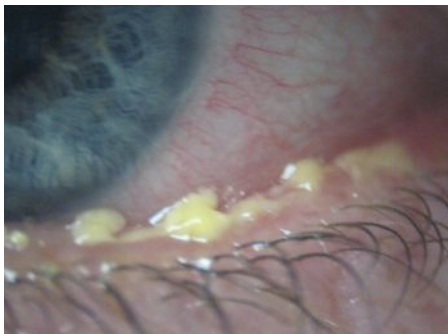

Photo: Rodney Bendure, OD, Jackie Burruss, OD



In posterior blepharitis (left), thick meibum secretions may be seen upon gland expression. Poor quality meibum in such patients can also lead to saponification of the lipid layer of the tear film. Blepharitis is part of the spectrum of ocular rosacea.

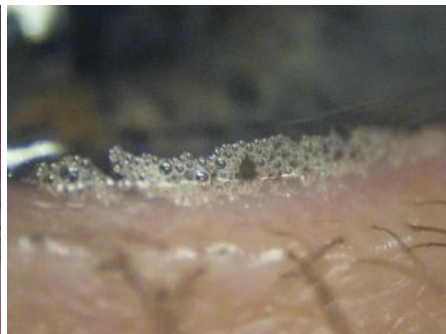

Photo: University of Iowa

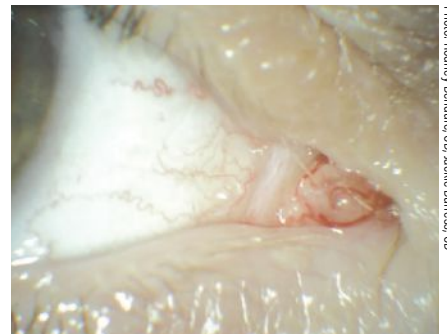


Photo: Rodney Bendure, OD, Jackie Burruss, OD

Caruncle squamous papillomas are benign and usually asymptomatic. They account for about 25% of all lesions involving the caruncle.

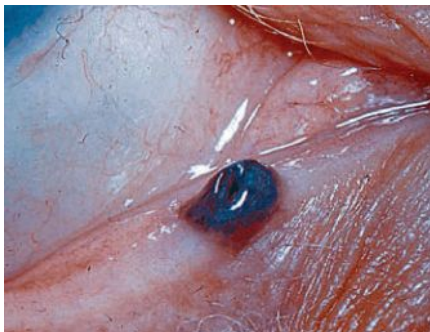


Photo: Rodney Bendure, OD, Jackie Burruss, OD

Eyelid melanomas can present variably, from darkly pigmented to amelanotic. They grow rapidly, with notable bleeding and ulceration.

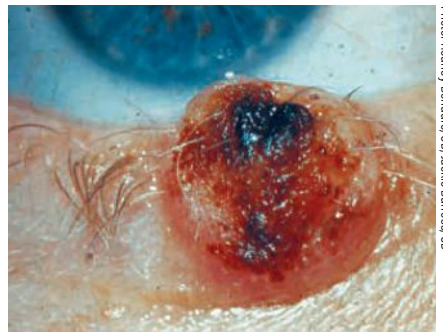


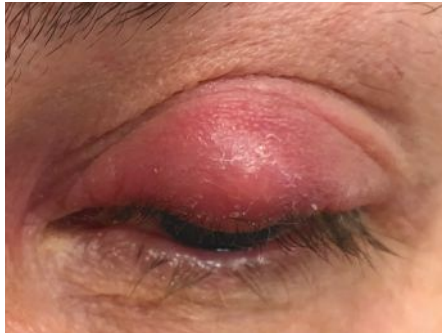
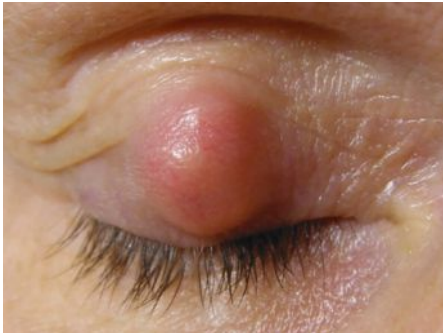
Photo: Rodney Bendure, OD, Jackie Burruss, OD

Keratoacanthoma presents as a dome-shaped nodule with a keratin-filled core on sun-exposed skin after age 50.

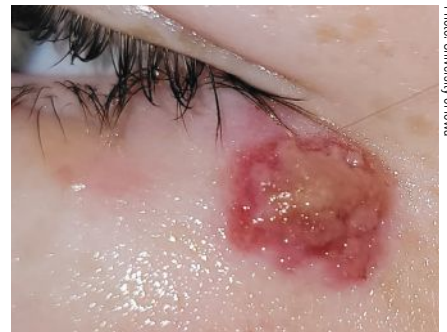

Photo: University of Iowa

Ecthyma contagiosum caused by a poxvirus (spread from sheep and goats to humans). Key differentials are HSV/HZV and tumor.



Photos: left, Nate Lightizer, OD; right, Greg Caldwell, OD

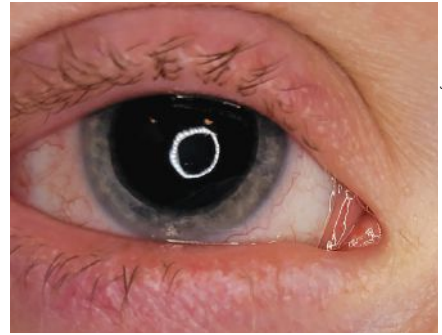

Photo: University of Iowa

Chalazion (left) and hordeolum (right) are often confused for each other. Chalazia may present with acute inflammation but more often are non-tender. External hordeola involve lash follicles, while internal forms are often due to bacterial infection of a meibomian gland.

Ocular rosacea, an oft-overlooked serious chronic inflammatory condition of the lid margins, causing blurred vision and pain.

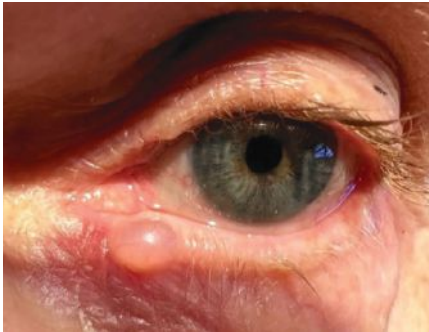


Photo: Rodney Bendure, OD; Jackie Burress, OD

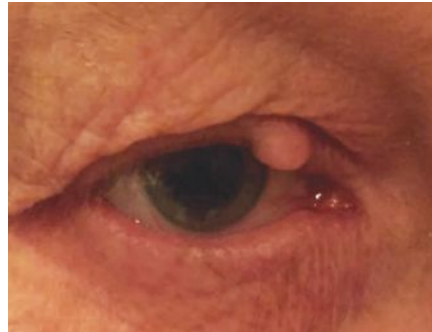


Photo: Rodney Bendure, OD; Jackie Burress, OD

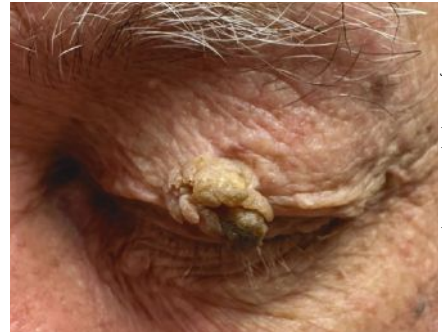


Photo: Rodney Bendure, OD; Jackie Burress, OD

Eccrine cysts are small, smooth, translucent nodules associated with sweat glands. They often grow in size during hot, humid weather.

Epidermal inclusion cysts are keratin-filled, white or light yellow vacuoles that arise from entrapment of epidermal tissue.

Verruca vulgaris (viral wart) is an epidermal growth caused by the human papilloma virus, typically types VI or XI.

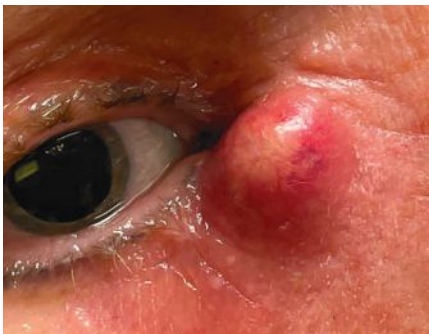


Photo: Alison Bozang, OD

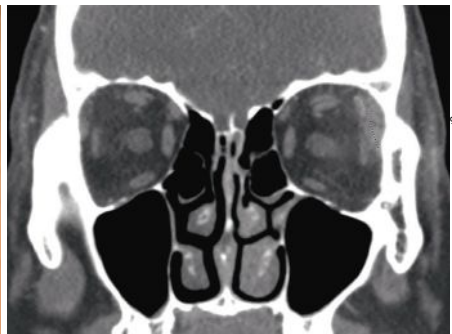
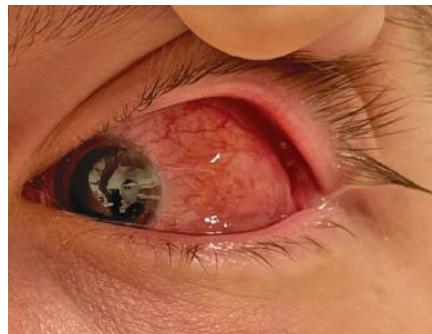
Photo: Alison Bozang, OD

Dacryocystitis is an infection of the lacrimal sac, commonly attributed to an acquired nasolacrimal duct obstruction.

Dacryoadenitis refers to inflammation of the lacrimal gland. It may be caused by an autoimmune condition (*i.e.*, sarcoidosis, Sjögren's syndrome, IgG4 disease), an infection (*i.e.*, Epstein-Barr Virus, adenoviral, bacterial) or can be idiopathic.

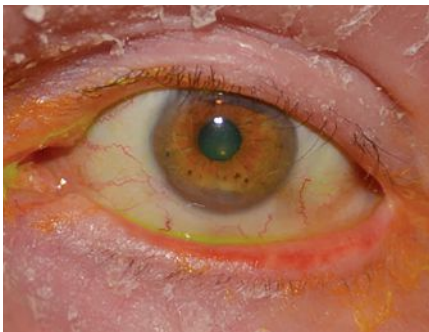


Photo: Alison Bozang, OD

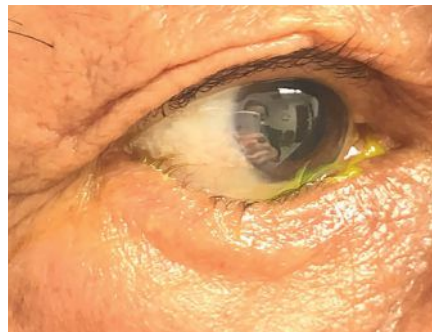

Photo: Alison Bozang, OD

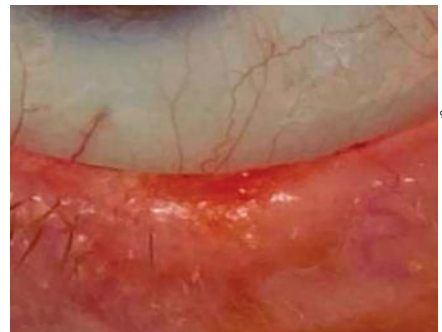


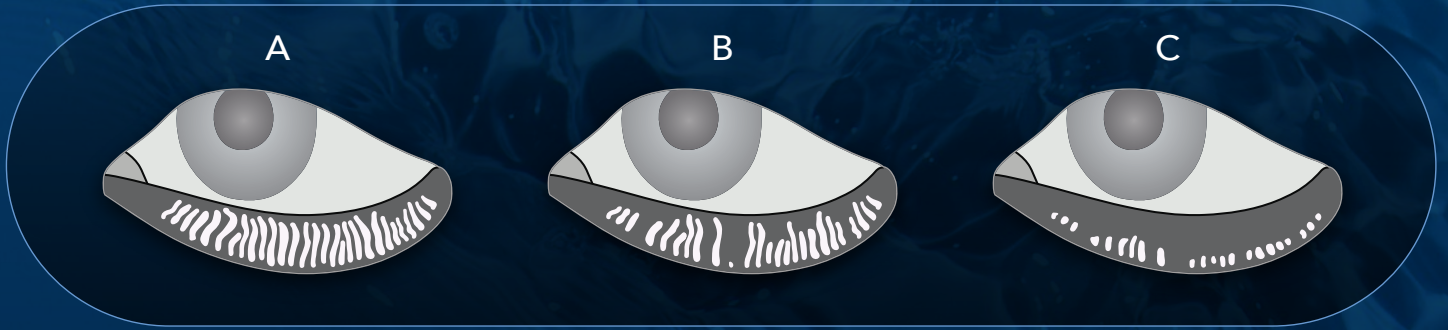
Photo: Alison Bozang, OD

Cicatricial ectropion, secondary here to cutaneous T-cell lymphoma, may lead to significant ocular surface exposure.

Spastic entropion is intermittent and may only be evident after squeezing the eyelids closed, as in this patient.

Basal cell carcinoma, the most common skin cancer, often has vascular pearly borders. Always assess for lid madarosis.

Who needs a lid hygiene regimen?



EVERYONE

ENCOURAGE FLOW

SCRUB & CLEANSE



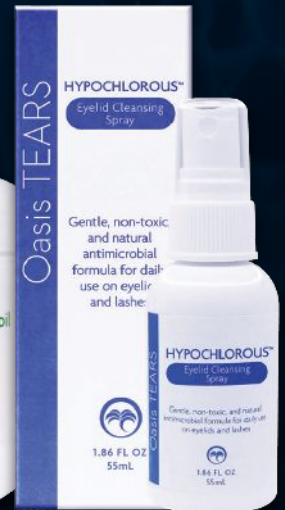ON3000
Oasis TEARS
OMEGA 3



OM8000
Oasis REST & RELIEF
Eye Mask



OT7300
Oasis TEARS
LID & LASH
+ Tea Tree Oil



OT7400
Oasis TEARS
HYPOCHLOROUS
Spray



SCAN HERE TO

**Receive a Lid Hygiene Kit and
Schedule a Lid Hygiene Workshop**

Call (844) 820-8940

Email customerservice@oasismedical.com

Visit www.oasismedical.com

THE MANY MISHAPS OF THE ANTERIOR SEGMENT

The eye's first line of defense against external threats is often compromised by infection or injury. Systemic conditions frequently also manifest changes here as well.

"Start on the outside and work your way in" has been the mantra of optometric educators, and that includes examination of the conjunctiva, cornea and iris. While it is easy to breeze by these structures on the way to the retina, the anterior segment holds vital information on the well-being of the patient. Inflammation, infection and malignancy may point to greater systemic concerns, as well as sight-threatening disease.

Under low magnification, the bulbar conjunctiva/sclera should appear white and moist. Non-wetting areas may point to exposure, vitamin deficiencies, functional eyelid anomalies or systemic autoimmune diseases. Color changes could reflect liver conditions (yellow), ultraviolet/exposure damage

(pinguecula, yellow), the potential for malignancy (primary acquired melanosis, brown; squamous cell carcinoma, pink). Dilated vessels, as well as chemosis, indicate inflammation and the root cause—such as infection, immune or dry eye—should be sought out.

The papillary conjunctiva should be free of inflammation and structural changes as well.

The visual examination of the cornea should go from the epithelium to the endothelium, as well as scanning the limbus 360 degrees. The cornea should be free of vessels (deep and superficial), infiltrates and foreign body material/deposits. It should have a uniform thickness, without thinning, edema, striae, folds or guttae. Additional testing with topography, OCT and specu-

lar microscopy are helpful for closer examination and to meet diagnostic criteria for many anterior segment diseases.

Like the cornea, the iris also benefits from both visual and tomographic examinations—for instance, to rule out neovascular and malignant lesions. In addition, gonioscopy is helpful for viewing the angle for the eye, which is a necessity for glaucoma management, post trauma evaluation and tumor concerns.

The anterior segment is easy to photodocument for comparison and communication. In the pages to follow, we share dozens of images of the disorders that can befall the structures of the anterior segment from a vast array of etiologies.

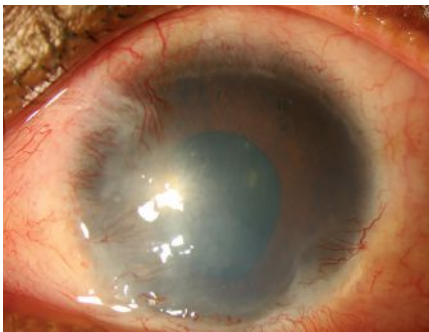


Photo: Alison Bozung, OD

Limbal stem cell deficiency occurs when damage to the limbal niche allows for conjunctivalization of the cornea.

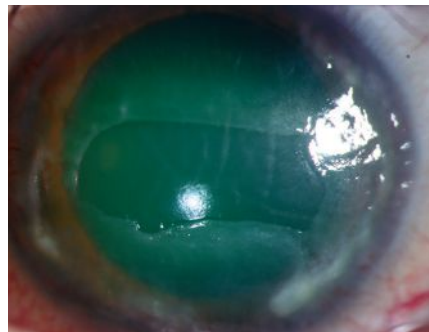


Photo: Alison Bozung, OD

Neurotrophic keratitis, characterized by poor epithelial healing and reduced sensation, results from damage to corneal nerves.

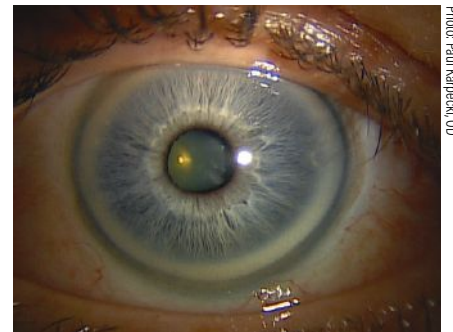
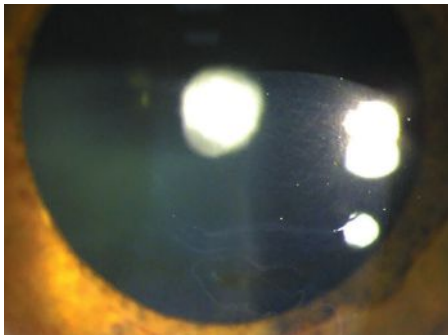


Photo: Paul Karpecki, OD

In arcus senilis, age-related deposition of lipids occurs in response to increased permeability of limbal blood vessels.



Epithelial basement membrane dystrophy, considered more of a degenerative condition due to its weak genetic association, presents with grayish dots and lines (left image). Thickened epithelium may be noted (right image, from a different patient).

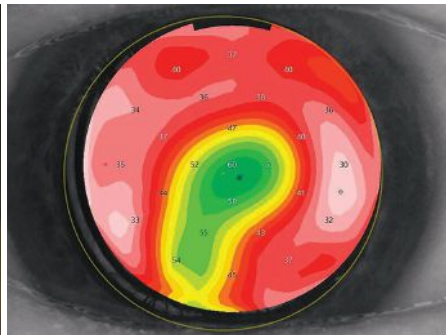
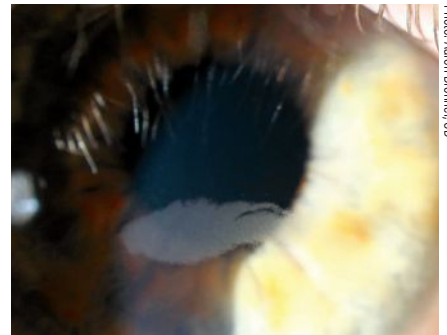


Photo: Mitch Ibach, OD



Lisch dystrophy produces feathery clusters of microcystic epithelial tissue in a whorled pattern sweeping centrally from the limbus.

Photo: Aaron Brenner, OD

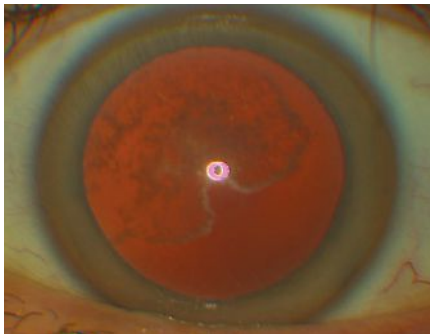
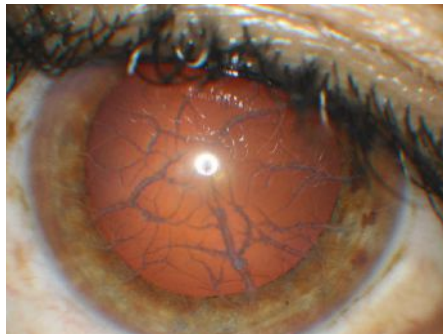
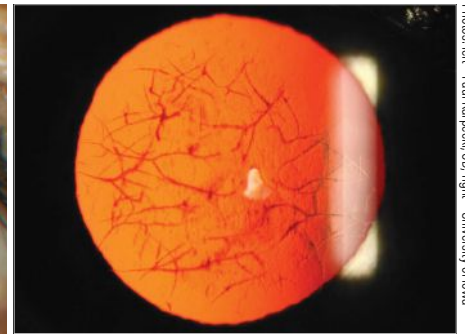


Photo: Suzanne Sherman, OD

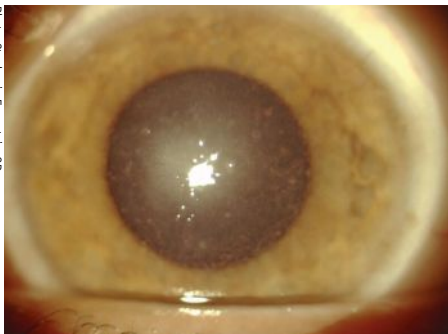
Schnyder's dystrophy presents in the first decade of life with central disciform opacities often surrounded by a dense arcus.



Lattice dystrophy represents deposition of amyloid in the anterior stroma, which forms a characteristic branching linear pattern. Most cases are inherited as an autosomal dominant trait (type I), but a rarer form arises from systemic amyloidosis (type II).



Photos: left - Paul Karpicki, OD; right - University of Iowa



In granular dystrophy type I (left), hyaline deposits form in the anterior stroma, eventually becoming more confluent as it progresses. Type II or Avellino dystrophy (right) also features lattice-like lesions of the mid-posterior stroma; however, these branches do not cross.

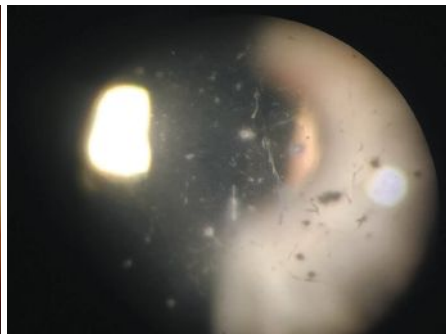
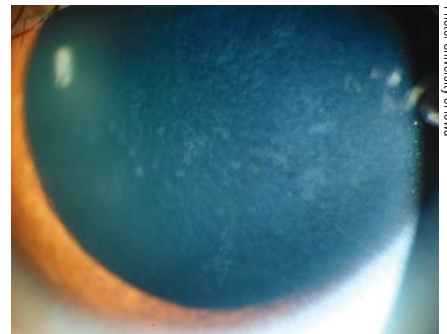



Photo: Mitch Ibach, OD



Reis-Bücklers causes reticular opacities in Bowman's that become less discrete over time, later extending into the stroma.

Photo: University of Iowa



Fuchs' endothelial corneal dystrophy (FECD), a bilateral genetic dystrophy characterized by progressing guttae leading to corneal edema and blurred vision. Patients may complain of worse vision in the morning, halos, dry eye and photophobia. In late-stage FECD with chronic corneal edema, patients may develop painful bullae.

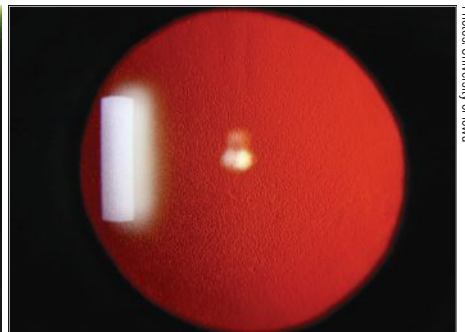
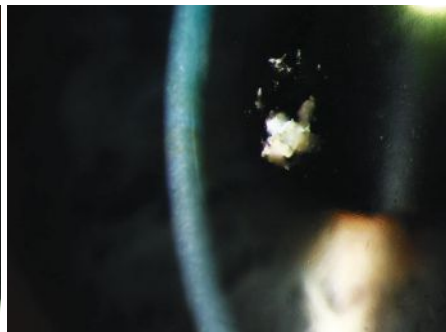

Photo: University of Iowa

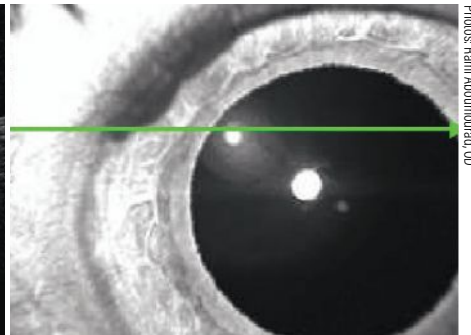
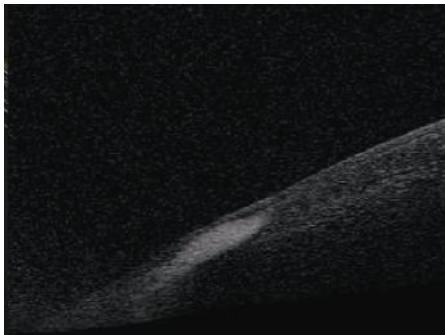
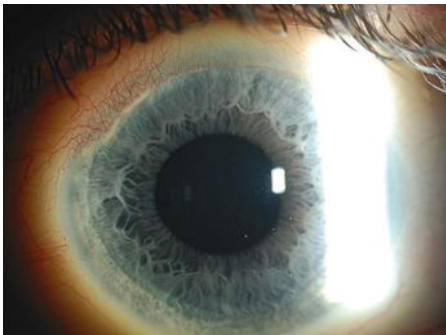


Photo: Rami Abounour, OD

Terrien's marginal degeneration is a progressive peripheral corneal disorder characterized by a paucity of inflammation in the setting of painless corneal thinning. Most patients have superior thinning with stromal lipid deposition and an overlying intact epithelium. Patients often develop high corneal astigmatism and may develop complications such as corneal perforation.

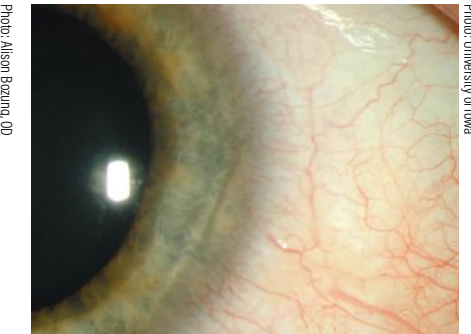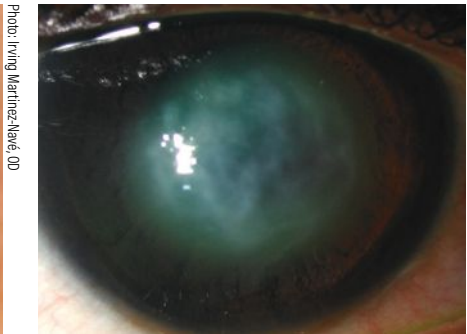
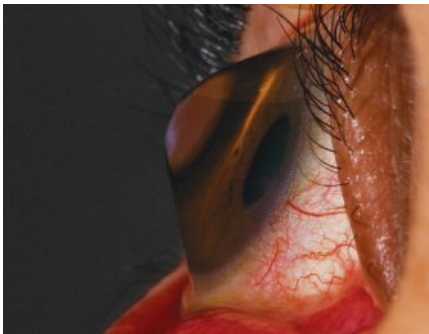


Photo: Irving Martinez-Nave, OD

Photo: Alison Bazing, OD

Photo: University of Iowa

In keratoconus, thinning of the cornea produces anterior bulging in a conical form, sometimes visible on gross examination.

Acute corneal hydrops occurs when a break in Descemet's membrane allows for stromal edema, seen here in keratoconus.

Mooren's ulcer, a circumferential corneal thinning near the limbus caused by immune-mediated eye disease.

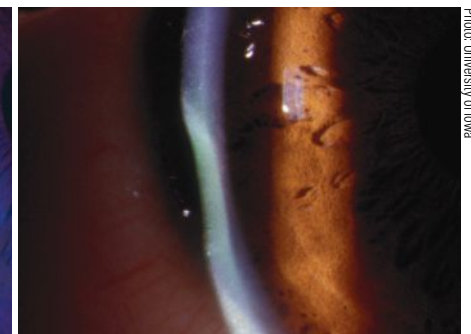
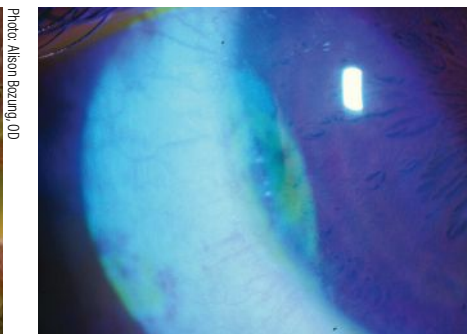
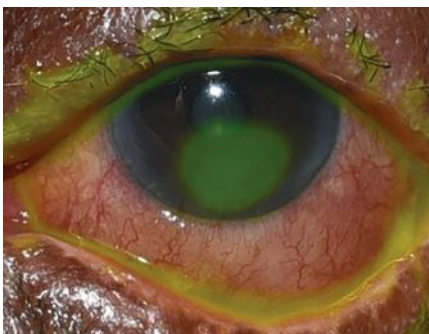


Photo: Alison Bazing, OD

Photo: University of Iowa

Exposure keratopathy in this case resulted from a severe surgically induced cicatricial ectropion.

Dellen is a form of localized corneal thinning caused by desiccation. The condition is most commonly associated with contact lens wear or conjunctival masses, which disrupt the normal tear film.

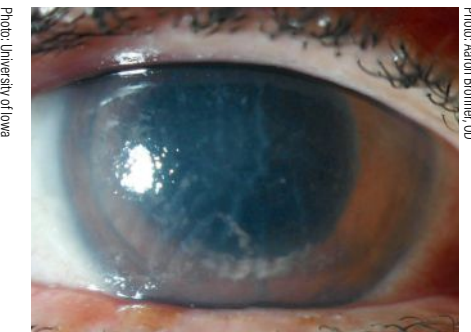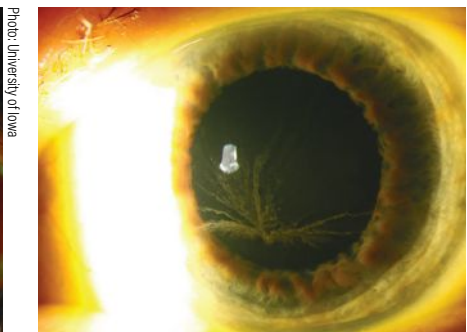

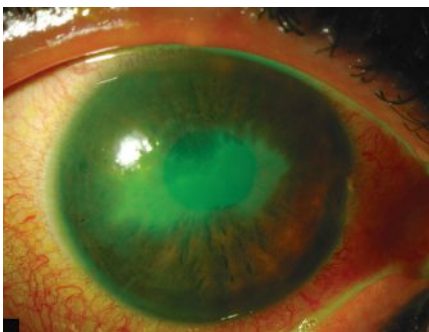
Photo: University of Iowa

Photo: University of Iowa

Photo: Aaron Bromer, OD

Graft-vs-host disease in an allogenic bone marrow stem cell recipient with immune-mediated destruction of the ocular surface.

Verticillata from amiodarone use. Deposits form in the inferior corneal basal epithelium and branch out from a central whorl.

HSV keratouveitis is an uncommon but severe manifestation of corneal herpetic disease.

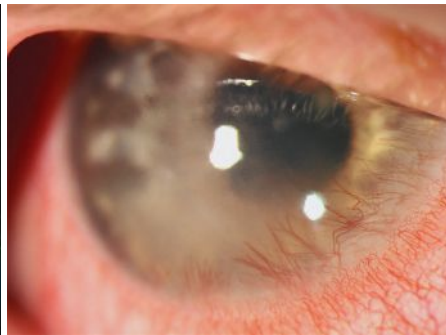
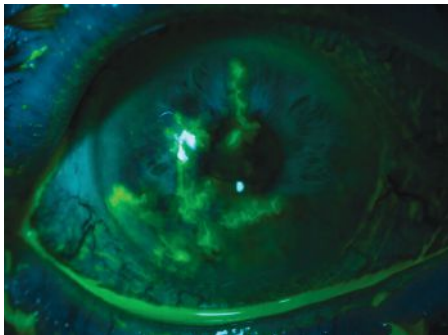


Photo: Alison Bazing, OD

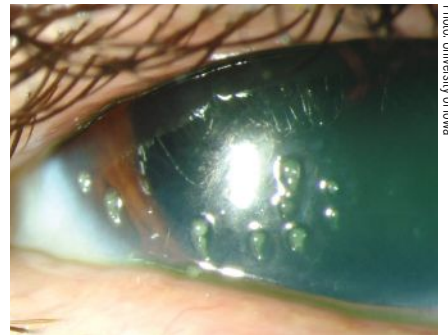


Photo: University of Iowa

Epithelial (left) and interstitial (right) HSV keratitis. Herpes simplex can take on many forms in the cornea including (but not limited to) classic “dendrites” as seen on the left image, stromal vascularization seen on the right and endotheliitis with corneal edema.

In filamentary keratitis, strands composed of epithelium, mucus and cellular debris form secondary to desiccation.

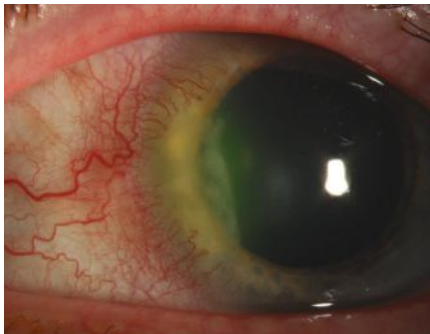

Photo: Suzanne Sherman, OD

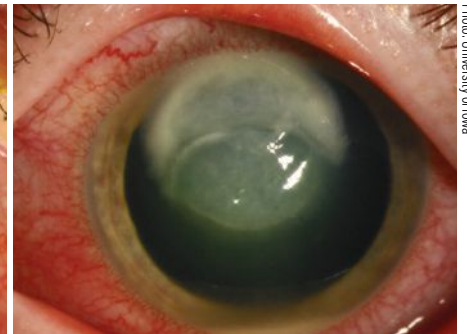
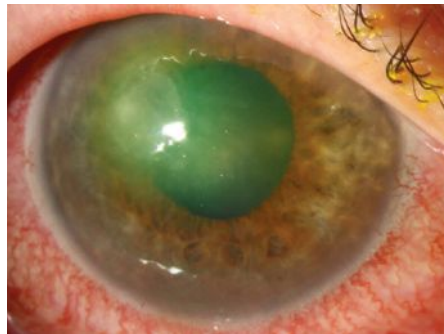

Photo: University of Iowa

Peripheral ulcerative keratitis is an inflammation of the peripheral cornea with destruction of the epithelium and stroma.

Pseudomonas keratitis (left) with hypopyon (right). This gram-negative pathogen often associated with contact lens wear presents with a ring of polymorphonuclear neutrophils around a central lesion.

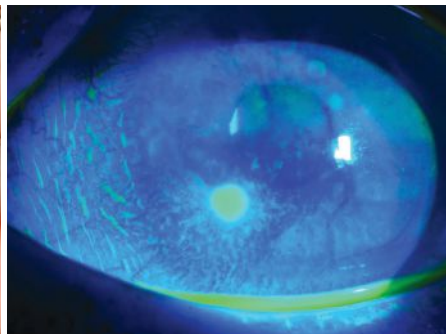
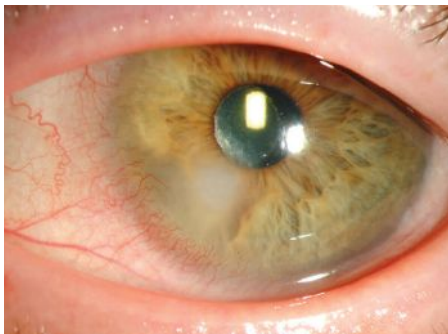

Photo: University of Iowa

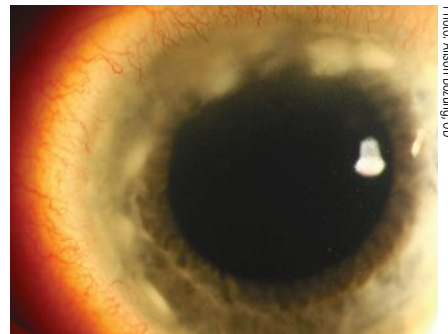


Photo: Alison Bazing, OD

Microbial keratitis viewed with white light (left) and fluorescein (right). In such cases, look for signs of a serious pathogen, including an infiltrate >1mm, presence of two or more lesions, central location, anterior chamber reaction and feathery borders.

This case of marginal keratitis has peripheral infiltrates with largely intact epithelium in a patient with blepharitis.

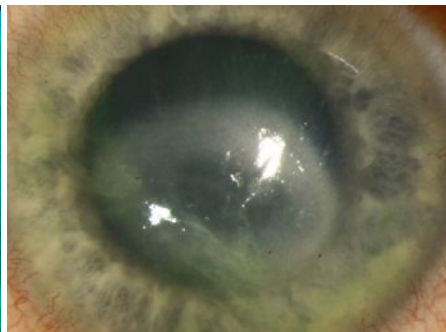
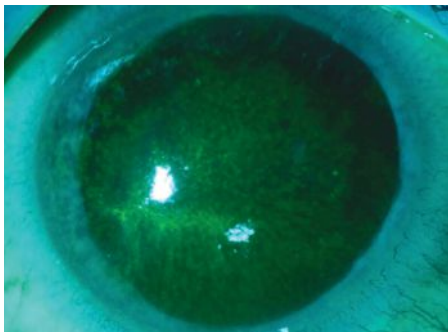


Photo: University of Iowa

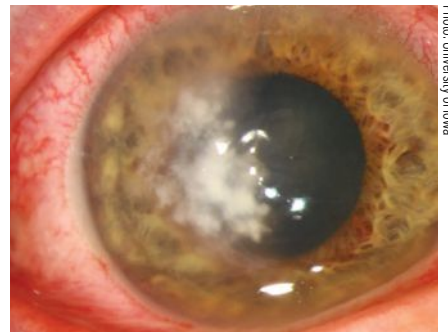


Photo: University of Iowa

Acanthamoeba keratitis. Consider a possible diagnosis of AK in any case where the pain out weighs the symptoms. AK often presents as diffuse punctate keratitis days or weeks before appearance of the classic stromal ring.

Fusarium ulcer. Consider the potential for fungal keratitis whenever multiple lesions are present.

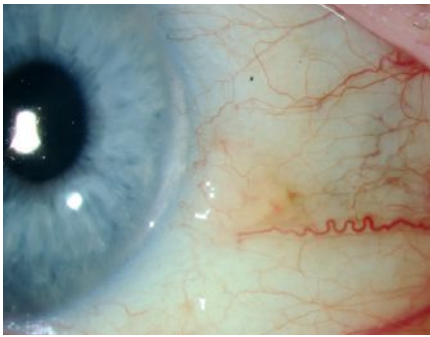


Photo: University of Iowa

Pinguecula results from normal collagen replacement by thicker fibers when exposed to dryness and UV light.

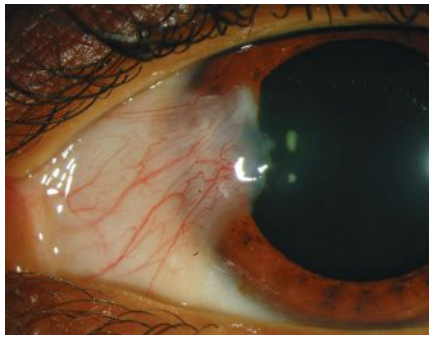


Photo: University of Iowa

Pterygium, also a response to UV light exposure, shows fibrovascular tissue crossing the limbal border onto the cornea.

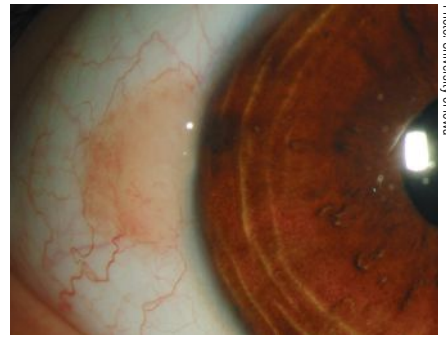


Photo: University of Iowa

Limbal dermoids are benign tumors that histologically may contain connective tissue, skin, fat, hair follicles and sweat glands.

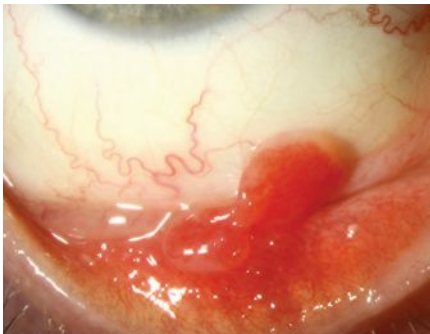

Photo: University of Iowa

Pyogenic granuloma is a rapidly growing tissue hypertrophy secondary to an inflammatory agent.

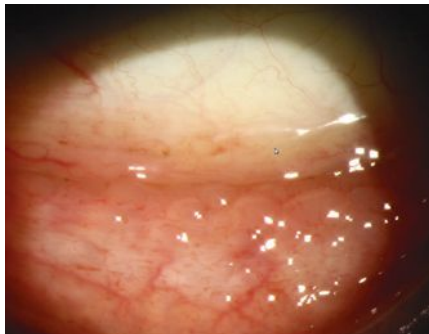


Photo: University of Iowa

Follicular conjunctivitis is an immunogenic activation of lymphoid follicles associated with many pathogens, drugs and allergies.

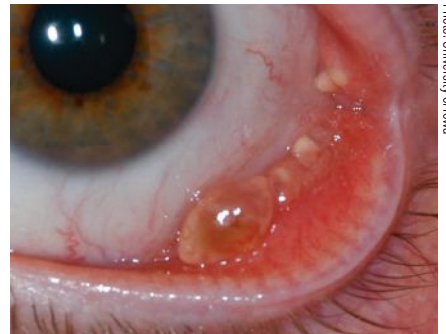

Photo: University of Iowa

Conjunctival cysts are harmless, painless fluid-filled vacuoles found on the ocular conjunctiva.

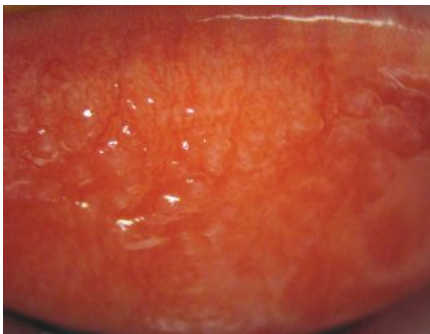


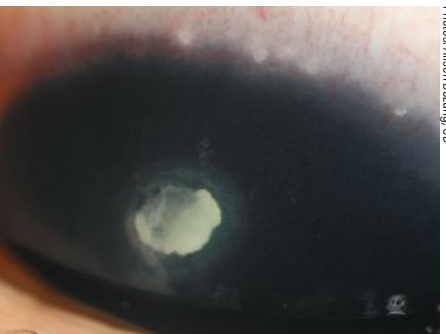
Photo: University of Iowa

Giant papillary conjunctivitis is on the decline thanks to daily disposable contact lens use, but can manifest in allergy cases.

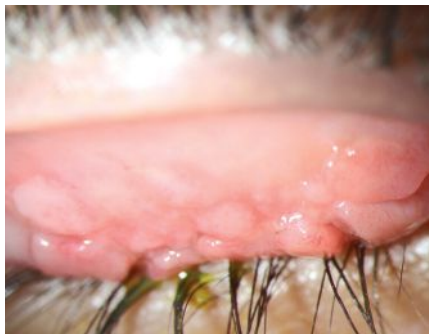

Photo: University of Iowa

Cobblestone-like papillae (left) are a hallmark of vernal keratoconjunctivitis. This teenage patient endorsed intense itching and ocular discomfort. The patient also had developed a small shield ulcer and had small Horner-Trantas dots visible at the limbus (right).



Photos: Alison Bozung, OD

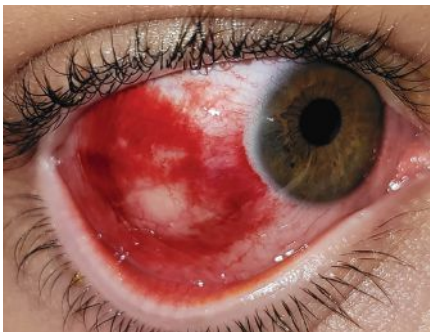

Photo: University of Iowa

Subconjunctival hemorrhage is a benign finding of trapped blood commonly from Valsalva maneuvers or anticoagulant use.

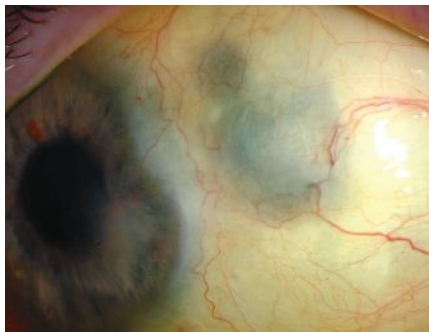
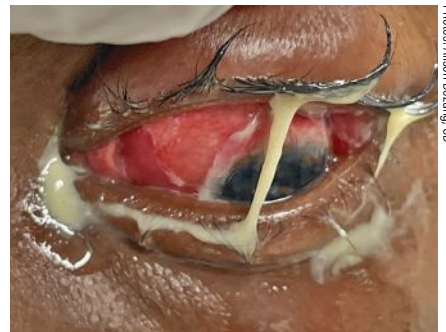

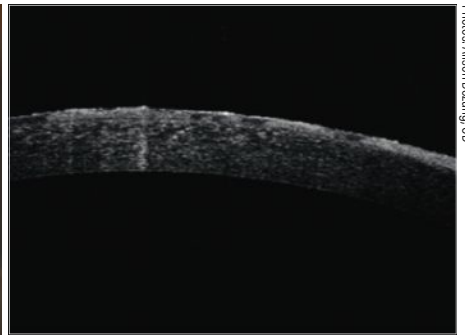
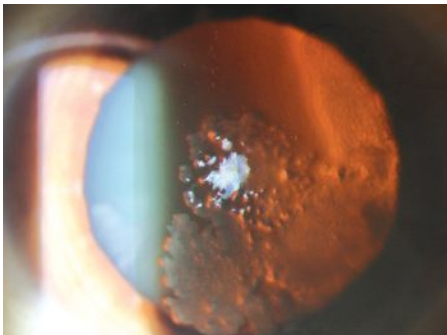
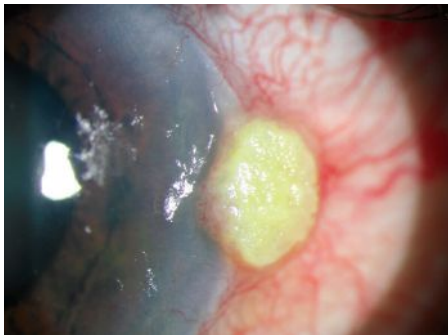Photo: University of Iowa

Scleral thinning in HSV scleritis. Differential includes congenital/degenerative diseases, immunocompromise, infection and trauma.



Photos: Alison Bozung, OD

Gonorrhea conjunctivitis is a hyper-purulent conjunctivitis with rapid onset. Patients require systemic treatment.

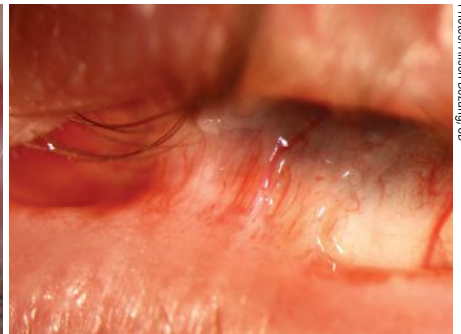


Photos: Alison Bozung, OD

Ocular surface squamous neoplasia (OSSN) is an umbrella term for an array of abnormal growths, and lacks well-defined characteristics as a result. The left photo shows a case of leukoplakic OSSN at the limbus. The center and right images show opalescent, flat corneal lesions. The AS-OCT highlights abrupt transitions between normal and irregular epithelium despite lacking significant thickness.

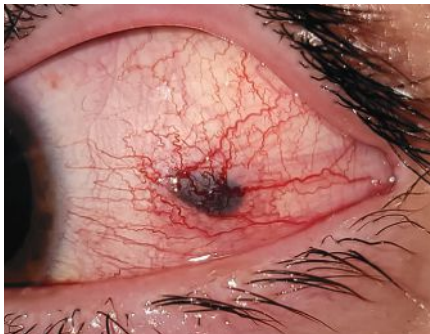

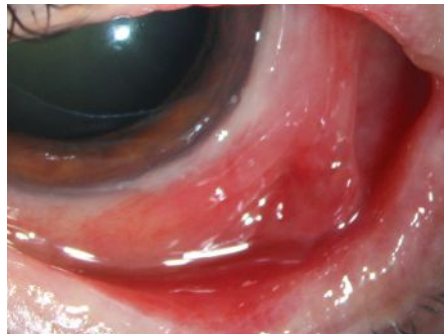Photo: University of Iowa



Photos: Alison Bozung, OD

Fireworks may cause globe rupture, chemical or thermal burns as well as corneal abrasion and retinal detachments.

At left, adherence of the bulbar and palpebral conjunctivae, or symblepharon, in a patient who would later be diagnosed with ocular cicatricial pemphigoid. At right, severe symblepharon in an advanced case of ectodermal dysplasia.

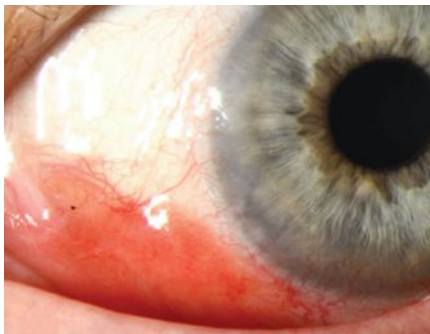


Photo: University of Iowa

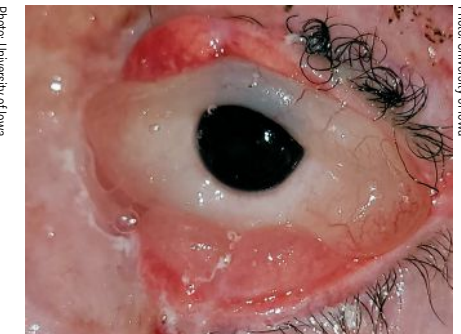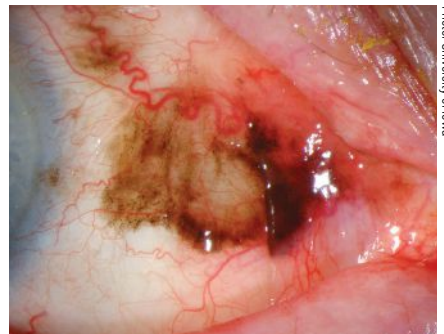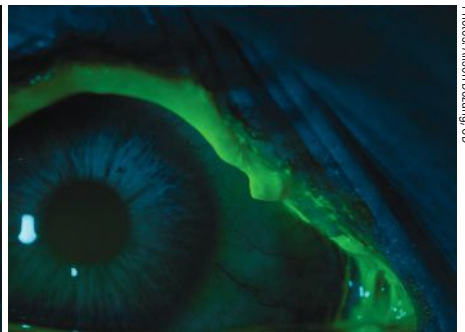


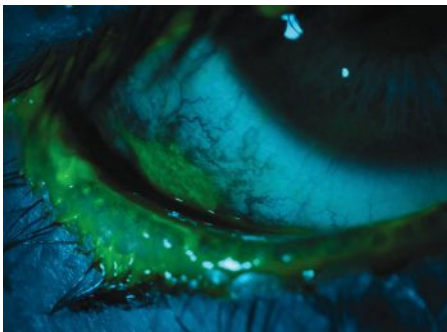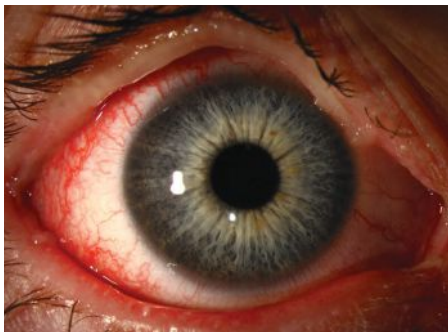Photo: University of Iowa

Amelanotic melanoma, a rare subtype of melanoma where the melanocytes fail to produce melanin.

Seen here is a conjunctival melanoma. Often, large feeder vessels will surround the pigmented area.

Severe conjunctival chemosis experienced by a burn victim who received copious fluid administration.



Photos: Alison Bozung, OD

Red, painful eyes in a Stevens-Johnson syndrome drug reaction. There is inflammatory epithelial sloughing along the mucous membranes, including the mucocutaneous lid margins and bulbar conjunctiva. SJS may cause blindness due to ocular surface scarring and must be treated aggressively. Cases with more extensive systemic/skin involvement are considered toxic epidermal necrolysis, a condition that can be fatal.

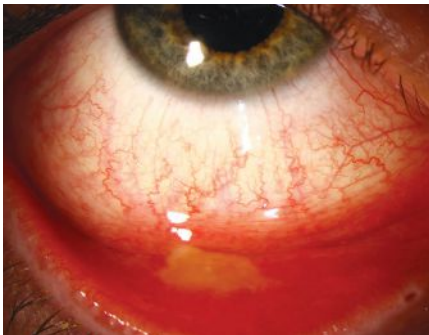

Photo: Alison Bozung, OD

Epidemic keratoconjunctivitis is often seen with pseudomembranes (stained with NaFl here) and subepithelial infiltrates.

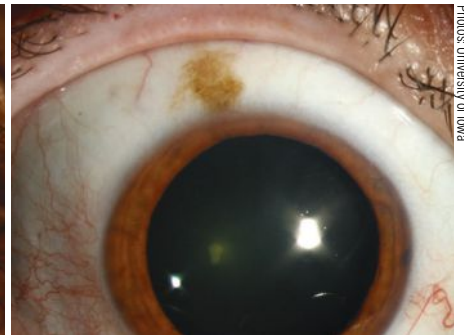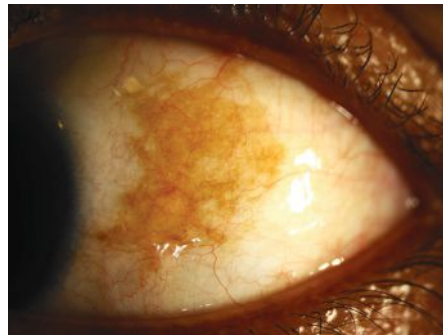


Photo: University of Iowa

Nevus of Ota (also called oculodermal melanosis) is a congenital hyperpigmentation of the sclera. The condition is usually benign but it may have a malignant transformation. Increased suspicion for eventual glaucoma development in these cases is also appropriate.

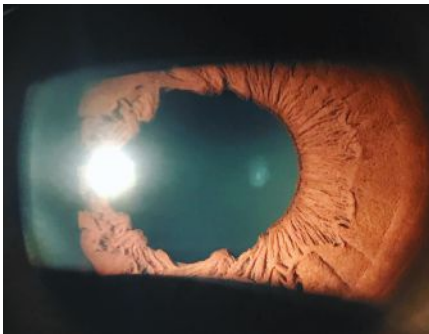


Photo: Alison Bozung, OD

Iris sphincter tears from blunt trauma may cause an irregular pupillary margin and permanent dilation.

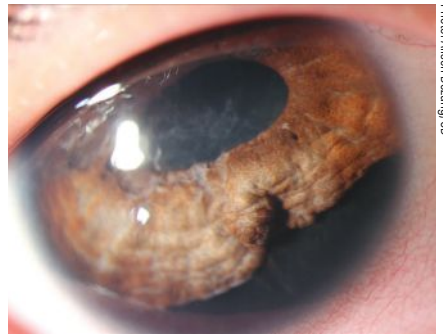

Photo: Alison Bozung, OD

In iridodialysis, the iris separates from the scleral spur. This patient was involved in a motor vehicle accident.

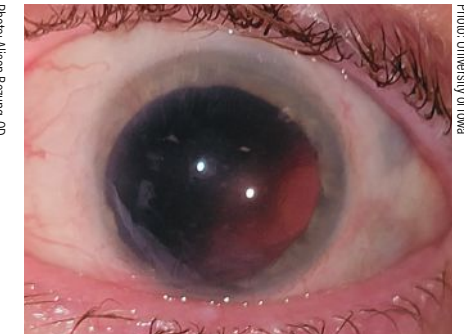


Photo: University of Iowa

Traumatic pupil represents a traumatic mydriasis that occurs in response to blunt force trauma.

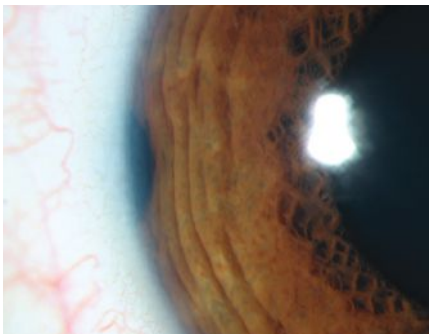


Photo: University of Iowa

Development of angle recession following blunt ocular trauma may cause glaucoma days or years after the injury.

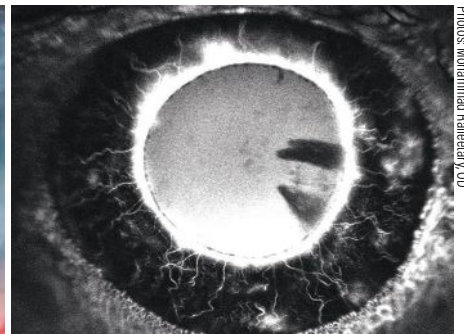
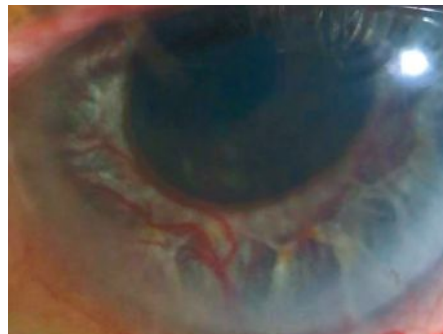

Photo: Mohammad Rafeeqy, OD

Rubeosis iridis requires careful evaluation to detect, as it may present very subtly, often initially at the pupillary margin. Gonioscopy may detect neovascularization in the angle. IVFA of the iris may be helpful to show hyperfluorescence from the irregular vasculature.

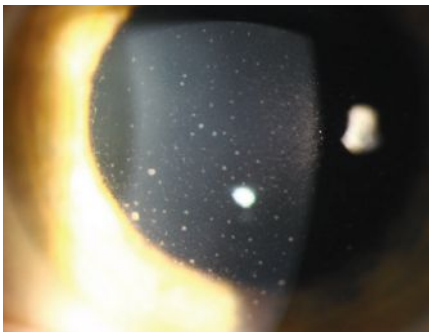


Photo: University of Iowa

Keratic precipitates in iridocyclitis are polymorphonuclear cells and lymphocytes located on the corneal endothelium.

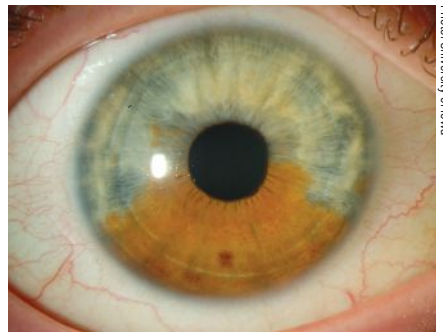

Photo: University of Iowa

Though usually considered benign, iris melanocytosis carries an increased lifetime risk for melanoma.

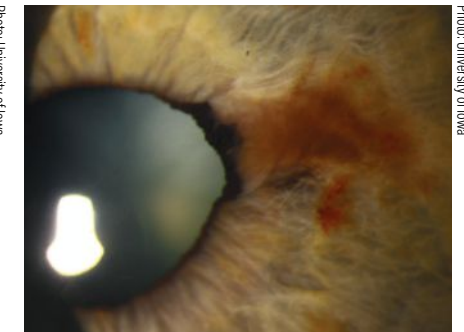



Photo: University of Iowa

Ectropion uvea may be acquired or congenital. Acquired cases may rise from inflammation, ischemia or neoplasm.

Medscape **LIVE!**

Presents

*Save the Date***2024 CE CONFERENCES****IN-PERSON** *Review of Optometry*[®]
presents a collaboration between**Spring | May 17–19, 2024****Fall | November 15–17, 2024****December 6–7, 2024**

THE OPTOMETRIC RETINA SOCIETY AND REVIEW EDUCATION GROUP PRESENT

RETINAUPDATE2024**December 7–8, 2024**

Locations to be announced.

Scan the QR Code or visit www.reviewedu.com/events
for information as it becomes available.

Follow us on social media!

Search: Review Education Group

Postgraduate Institute
for Medicine

*Accreditation pending

REVIEW
Education GROUP

NAVIGATE THE RETINAL LANDSCAPE WITH CONFIDENCE

The delicate anatomy here is prone to disruption in countless ways, including systemic and localized disease processes, trauma, congenital malformations, drug reactions and more.

Alterations of the retina can be caused by a wide variety of etiologies, ranging from benign findings to sight- or life-threatening pathologies, making it extremely important to make an accurate diagnosis. When examining the retina, dilation is often crucial as it allows for evaluation of more peripheral structures and the ability to obtain a steady stereoscopic view. Multiple fundus lenses are used to view the retina, including both contact and non-contact lenses, as well as techniques such as scleral depression, use of adjunct filters and exam techniques such as the Watzke-Allen sign. It is important to use the tools necessary to properly evaluate the retina clinically as you move towards ordering additional imaging.

Multiple options now exist for imaging the retina as well, with each technology giving a unique insight into the retina's structure. These include optical coherence tomography (OCT), OCT-angiography (OCT-A), fundus autofluorescence (FAF), fluorescein angiography (FA), indocyanine green angiography (ICGA) and multispectral imaging.

While some conditions can be accurately diagnosed and managed with fundus evaluation alone, others may be best visualized with advanced retinal imaging and some may require simultaneous use of multiple types (multimodal imaging) to arrive at an accurate diagnosis. Nevertheless, it is important to begin with a proper case history and clinical examination, first considering

the patient's complaints and demographics before moving forward with ordering retinal imaging. It is then crucial to accurately interpret the imaging obtained to arrive at a proper diagnosis.

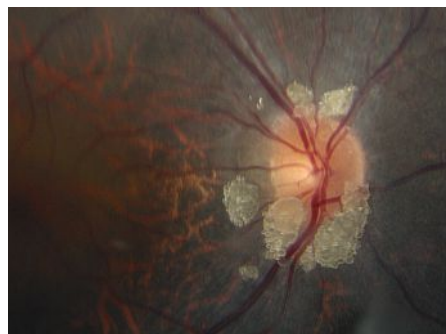
Primary care ODs with young, healthy patients may lack routine exposure to some of the retina's more exotic findings. The following section provides sample images of an array of retinal pathologies as they are seen both clinically and when imaging is used. It is important to keep in mind that the same condition can have a variety of presentations that may not be entirely captured by the sample image.

The online version of this article will include additional photos and more detailed captions for many of the conditions presented here.

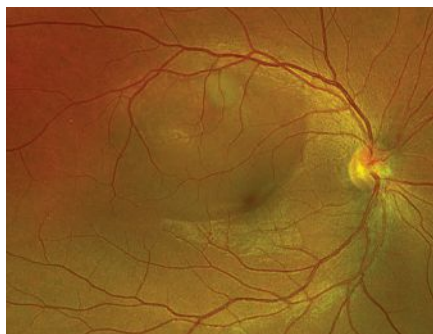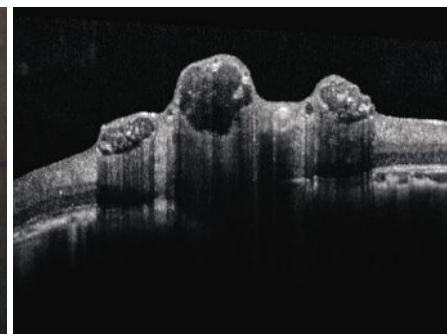


Photo: Ramli Abounourad, OD

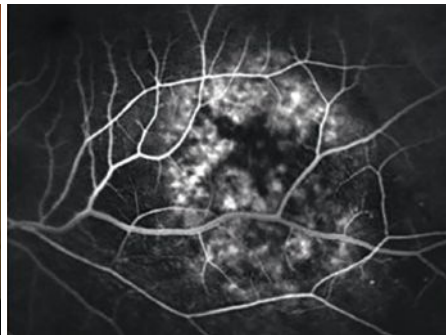
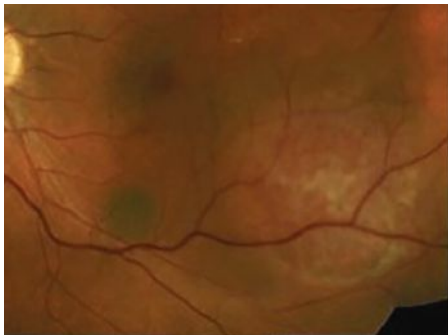
Central serous chorioretinopathy showing a well-demarcated area of subretinal fluid in the superior macula and involving the fovea.



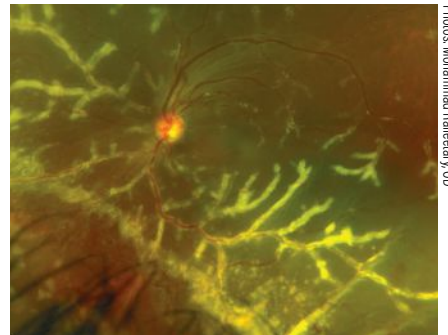
Retinal astrocytic hamartomas showing typical appearance of elevated, globular, yellow-white nodules. These lesions arise from glial tissue and will hyperautofluoresce once calcified. OCT shows characteristic "moth-eaten" or optically empty hyporeflective spaces.



Photos: Ramli Abounourad, OD



Photos: Mohammad Rafieary, OD



Photos: Mohammad Rafieary, OD

Choroidal hemangiomas are vascular tumors of the choroid that often appear as orange elevated choroidal masses. On IVFA, their most distinguishing characteristic is early lacy hyperfluorescence that continues to leak with time.

Cytomegalovirus retinitis with classic frosted branch angiitis—yellow lesions surrounding blood vessels.

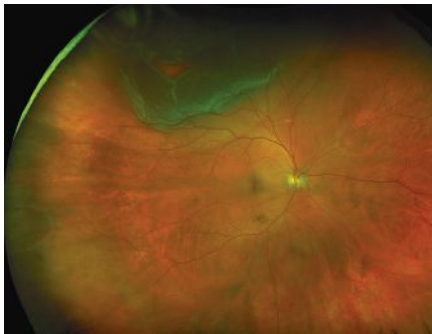
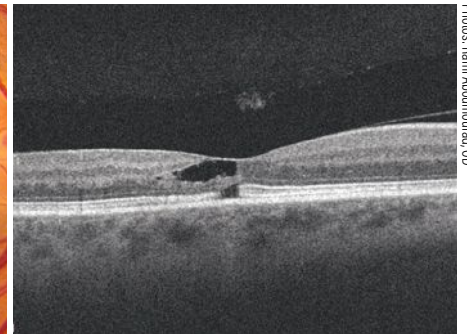
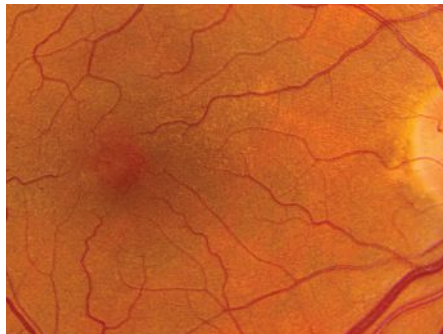


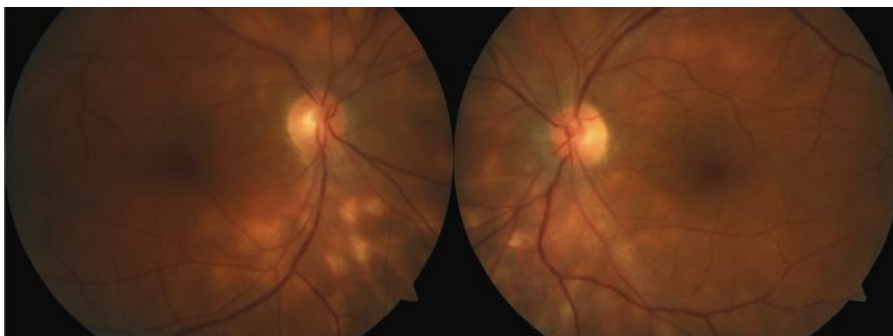
Photo: Rami Aboumourad, OD



Photos: Rami Aboumourad, OD

A macula-on rhegmatogenous detachment. The causative break is a horseshoe tear at 11 o'clock but others can be seen at 8, 9 & 10.

Macular telangiectasia. The telangiectatic vessels are unique because they make abrupt right angles. The OCT shows abrupt inner-retinal atrophy and cavitation with ILM-draping temporal to the fovea. There is also disruption in the IS/OS line temporal to the fovea.



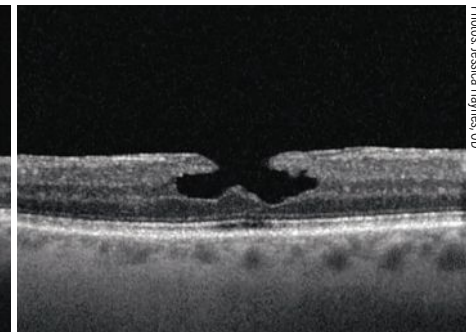
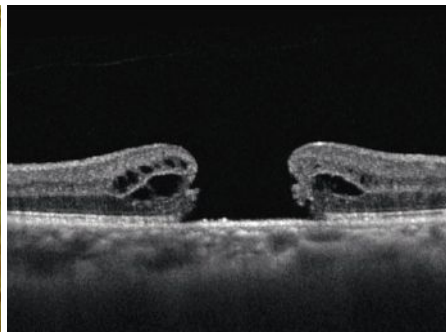
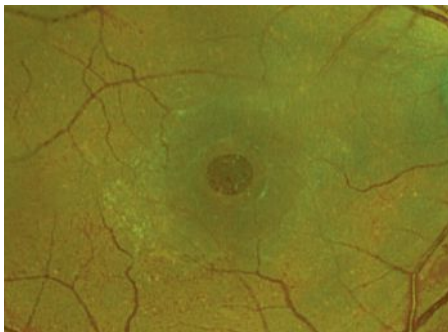
Photos: Jessica Haynes, OD

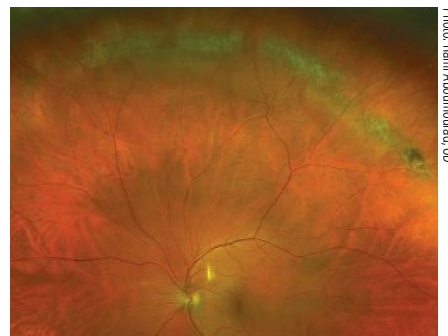

Photo: Rami Aboumourad, OD

Deep, yellow oval-shaped birdshot lesions radiating from the disc. These classic choroidal lesions may not appear initially during the course of the disease and patients may first present with non-specific symptoms such as photopsias, floaters and nyctalopia.

Photo shows 90° of circumferential midperipheral lattice retinal degeneration with atrophic holes and some pigmentation.



Photos: Jessica Haynes, OD

A full-thickness macular hole may appear as a round, reddish foveal lesion. The patient may also present with scotomas, metamorphopsia or decreased acuity. OCT is invaluable in confirming FTMH. There will be a gap in the entirety of the neurosensory retina. Lamellar hole (right), by contrast, consists of an irregular foveal contour and separation of inner and outer retinal layers without a full-thickness break.

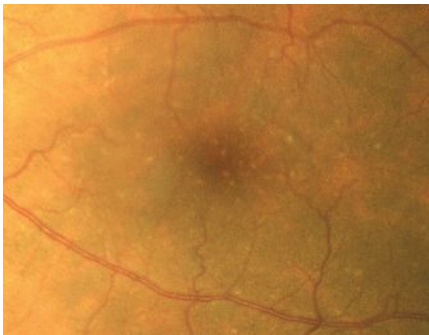
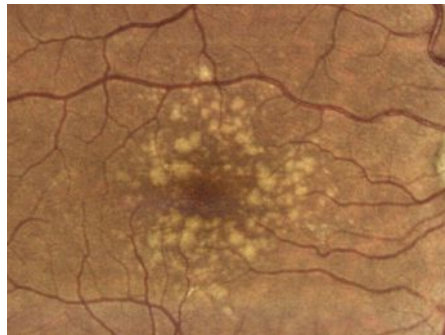


Photo: Jessica Hayes, OD

Early AMD is typically defined as having small to medium drusen, with no large drusen or pigmentary changes.



Intermediate AMD is defined by presence of large drusen (>125µm) and/or pigmentary changes. On OCT, drusen are typically moderately reflective deposits that sit under the RPE; however, some will have irregular reflectivity. Reticular pseudodrusen sit on top of the RPE.

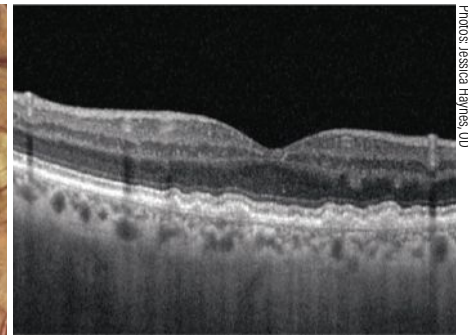
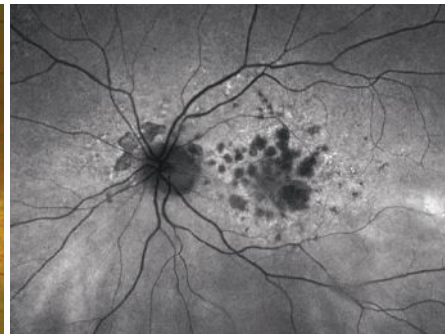
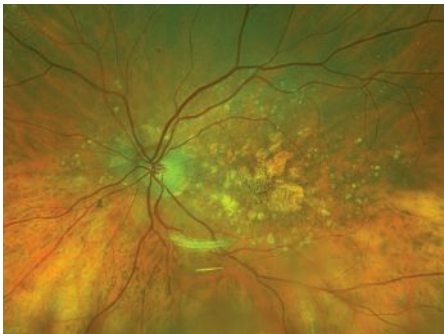


Photo: Jessica Hayes, OD



Photos: Ramli Abounour, OD

Advanced dry AMD with drusen, RPE changes and geographic atrophy. Note the absence of any subretinal or sub-RPE hemorrhage on fundus exam. FAF imaging (right) shows foci of hypoautofluorescence lesions with scattered hyperautofluorescence throughout the macula.

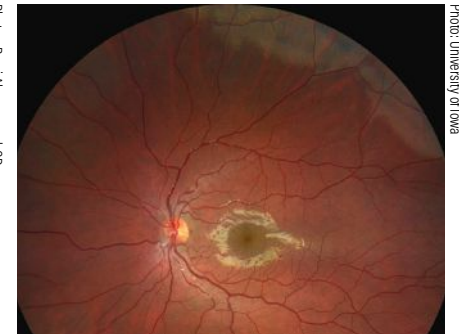

Photo: University of Iowa

Commotio retinae results from blunt trauma, causing transient damage that appears as areas of whitening or opacification.

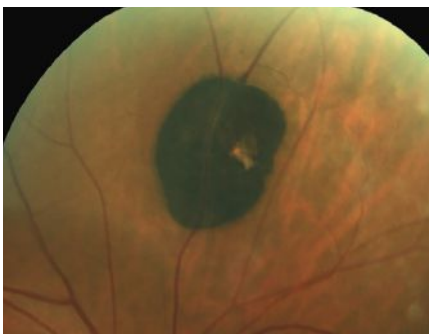

Photo: Jessica Hayes, OD

CHRPE are congenital benign lesions of the RPE. They are flat on clinical examination and do not disappear with a green filter.

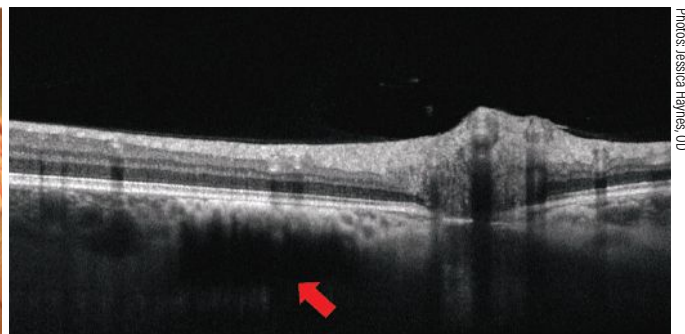
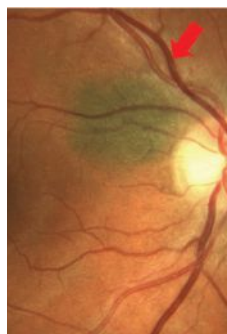


Photo: Jessica Hayes, OD

Choroidal nevi are benign tumors that present as pigmented lesions and may have overlying drusen. A green filter may help distinguish choroidal nevi from CHRPE. When a red filter is applied, choroidal nevi will become much less visible, whereas CHRPE will still be visible.

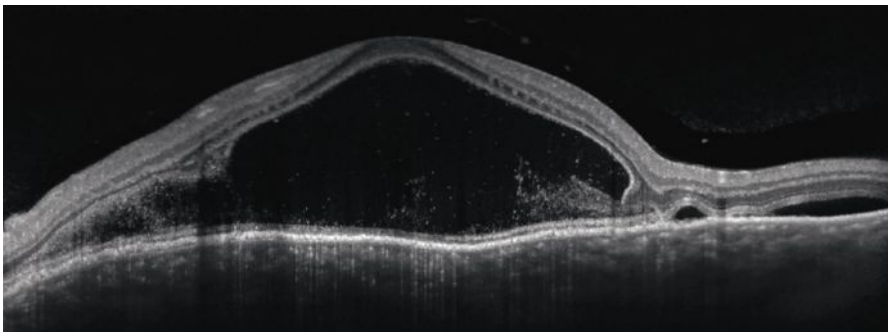


Photo: Ramli Abounour, OD

OCT of a patient with Vogt-Koyanagi-Harada syndrome—a rare granulomatous autoimmune disease and cause of noninfectious uveitis—showing extensive bacillary layer detachment involving the fovea with eccentric subretinal fluid present.

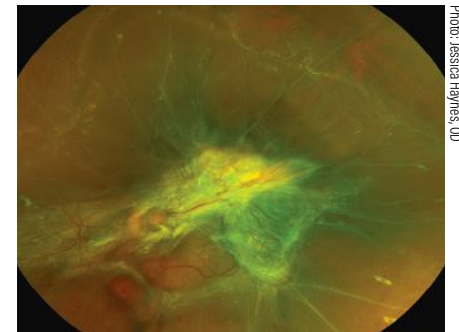

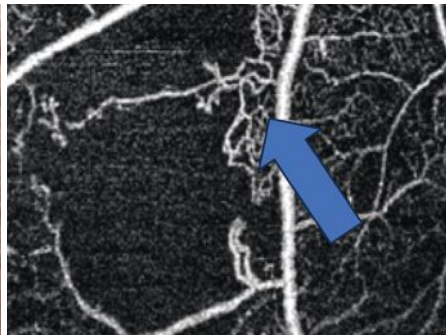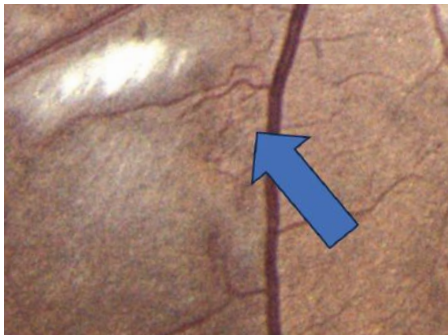


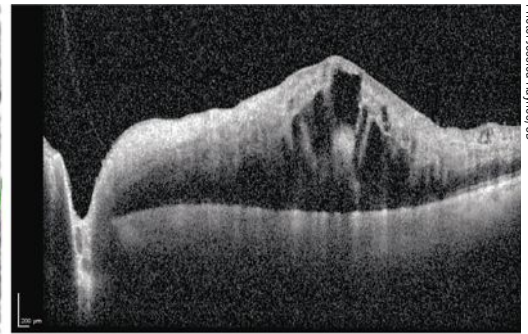

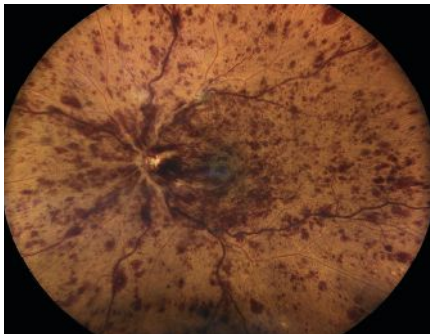
Photo: Jessica Hayes, OD

As neovascularization becomes fibrosed, it contracts and lifts the retina, causing tractional retinal detachment.



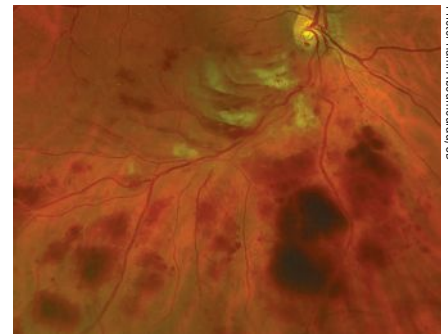
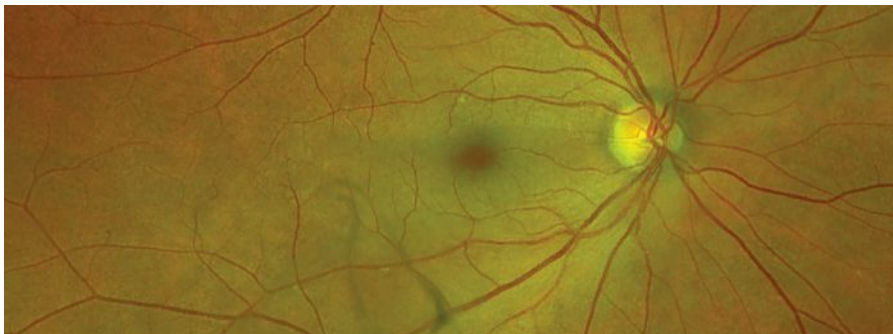
IRMA are small, telangiectatic vessels that form from damaged capillary beds. It is very easy to overlook and can be difficult to distinguish from NVE. On OCT-A, IRMA will be present in the superficial or deep capillary plexi while NVE will be present on the vitreoretinal interface.

Venous beading (blue arrows). This finding in two quadrants meets the criteria for the 4-2-1 rule for severe NPDR.



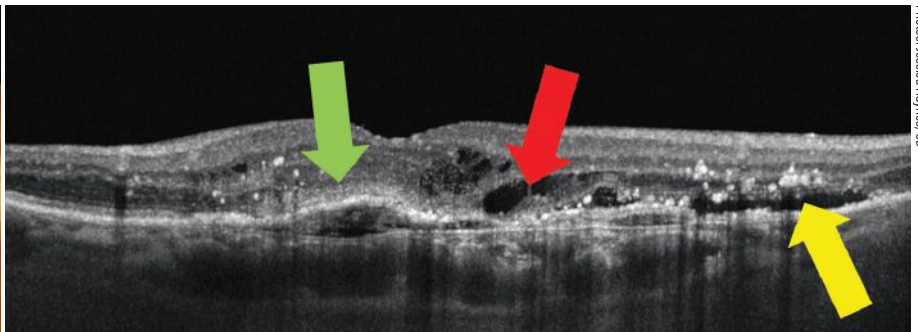
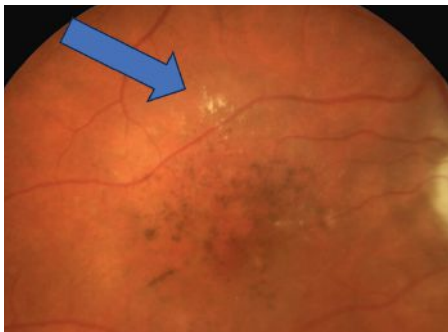CRVO presents with 360° tortuous retinal veins and hemorrhages; however, there can be various levels of hemorrhaging present.

Macular edema secondary to CRVO with macular thickening and intraretinal and subretinal fluid. Macular edema is a common complication of retinal vein occlusions that can lead to decreased acuity. On clinical examination, good stereopsis may help reveal the thickening.



Acute CRAO with diffuse macular whitening and a cherry red spot. The fovea remains perfused by the underlying choriocapillaris and is surrounded by ischemic (white) retina. It is important to inquire regarding symptoms of giant cell arteritis when no embolus is found.

BRVO, intraretinal hemorrhaging and cotton wool spots. Check patients for arteriovenous nicking, venous dilation and tortuosity.



A patient with exudative AMD. The blue arrow on the fundus photo points towards exudate—a clinical clue that choroidal neovascularization could be present. On OCT, there is a pigment epithelial detachment with overlying subretinal hyperreflective material (green arrow), intraretinal fluid (red arrow) and subretinal fluid (yellow arrow)—all suggestive of CNV.

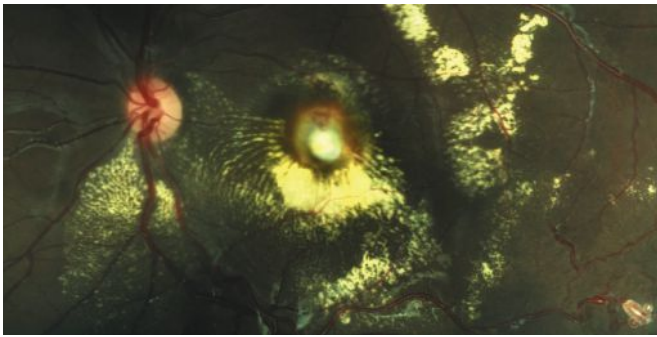


Photo: Mohammed Rafeeqy, OD

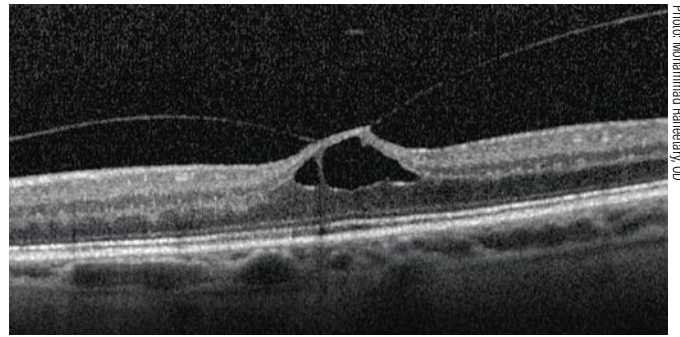


Photo: Mohammed Rafeeqy, OD

Coats disease's most striking findings are large areas of exudation and irregular, telangiectatic vessels or aneurysms. It most commonly presents unilaterally in young male patients.

OCT of vitreomacular traction will show a lifting of the posterior vitreous hyaloid with residual attachments to the macula that distort retinal anatomy. This traction may result in cystic spaces.

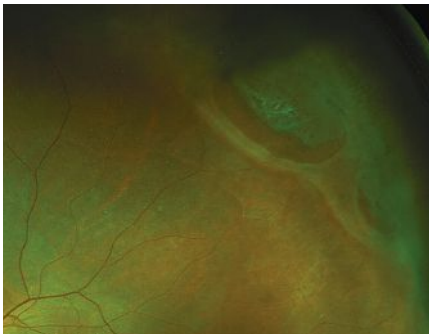
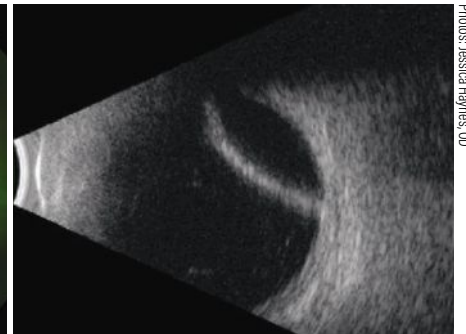
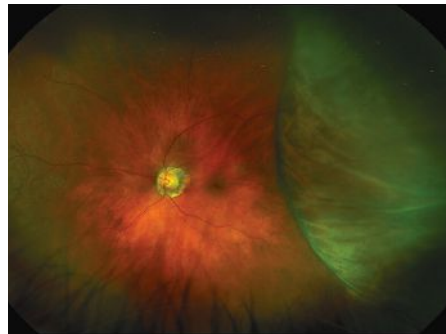


Photo: Rami Abounour, OD



Photos: Jessica Hayes, OD

Two horseshoe retinal tears within an area of lattice degeneration. These patients require careful scleral depressed examination.

Choroidal detachments or effusions occur when there is accumulation of fluid or blood in the suprachoroidal space due to hypotony (as in this patient), inflammation, metastasis or choroidal effusion syndrome. They are typically large, round, elevated, opaque lesions.

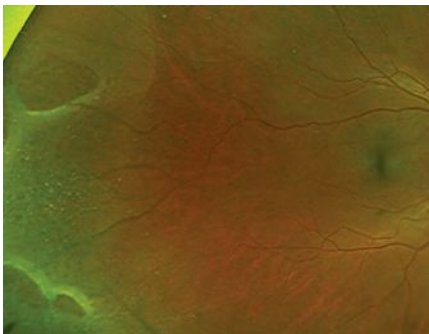


Photo: Mohammed Rafeeqy, OD

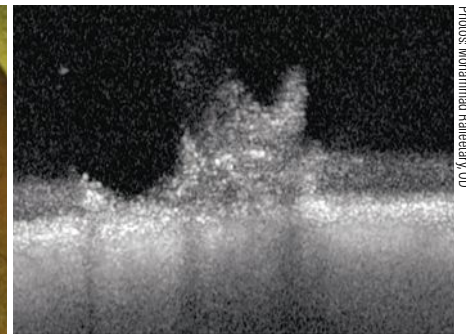
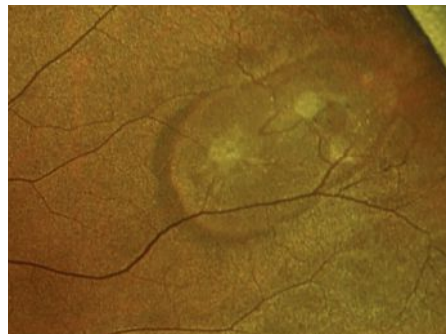


Photo: Mohammed Rafeeqy, OD

Peripheral retinoschisis most often occurs temporally, superior temporally or inferior temporal, and is most often bilateral.

Cystic retinal tufts often present as localized, fluffy white lesions in the peripheral retina. They may have associated RPE hyperplasia and be pigmented as well. On OCT, retinal tufts will show areas of vitreous adhesion to the retinal surface.

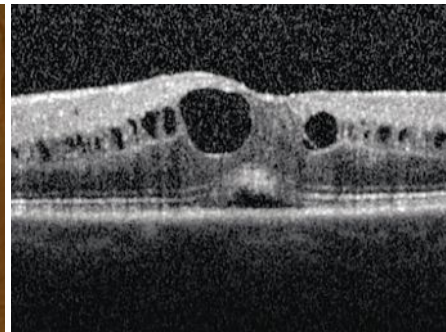
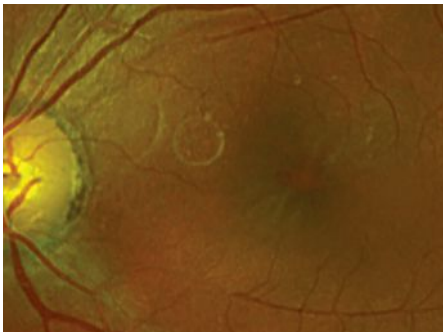


Photo: Rami Abounour, OD

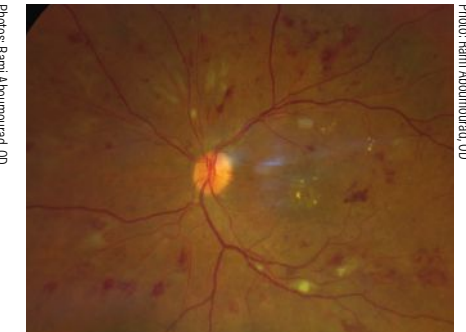

Photo: Rami Abounour, OD

Fundus photo of cystoid macular edema (left) showing a thickened and somewhat striated appearance to the macula. OCT scan of the patient (right) shows intraretinal cysts (fluid) and subretinal fluid.

Severe NPDR shows significant dot-blot hemorrhaging in all four quadrants, venous beading and multifocal IRMA in all quadrants.

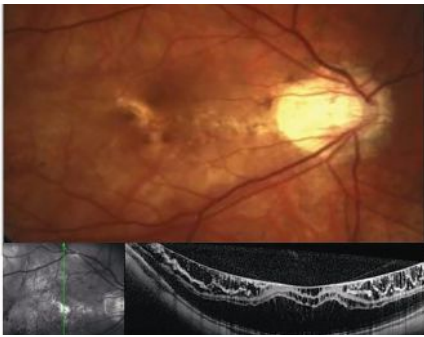
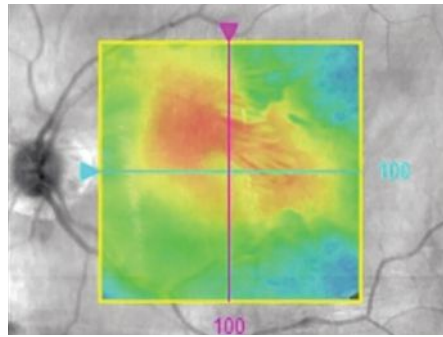
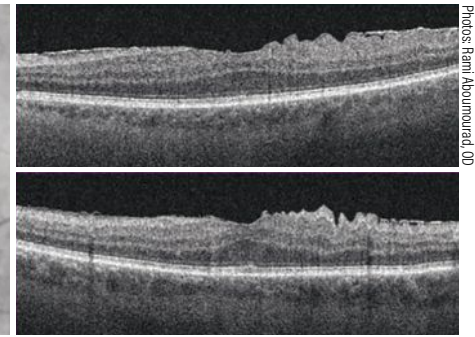


Photo: Mohammed Rafeeqy, OD

Myopic traction maculopathy leads to a splitting of retinal layers in the macular region. It is best visualized using OCT.



Cirrus OCT of an epiretinal membrane shows the presence of a preretinal hyperreflective membrane, inducing retinal traction and alteration of typical foveal architecture. The macular thickness map is particularly helpful for monitoring these patients over time.



Photos: Rami Abounour, OD

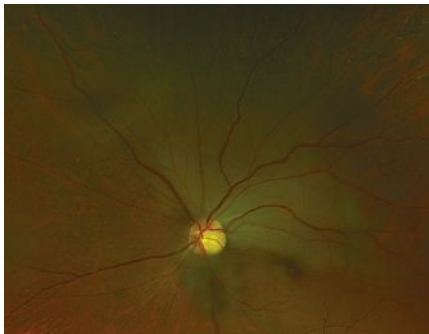
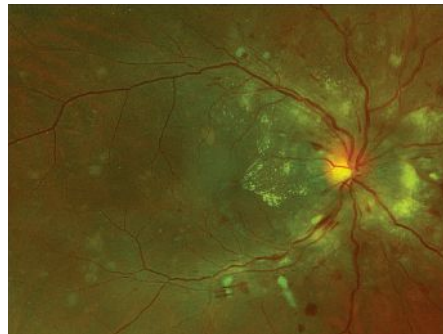
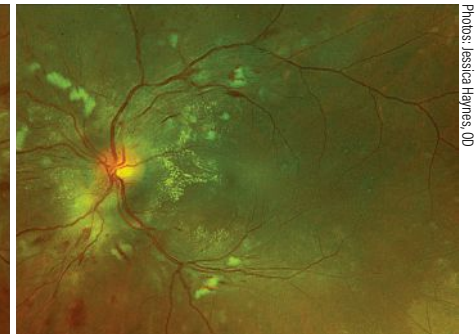


Photo: Rami Abounour, OD

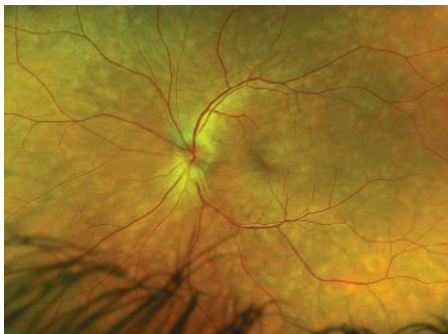
Acute BRAO with sectoral retinal whitening of the superotemporal quadrant. No embolus is visible on clinical exam.



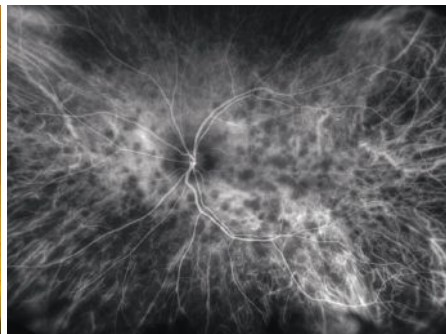
Stage 4 hypertensive retinopathy can present with bilateral disc edema, hemorrhages, cotton wool spots and exudates. It is imperative to identify this ocular emergency by checking the blood pressure. This presentation along with a severely elevated BP requires an ER referral.



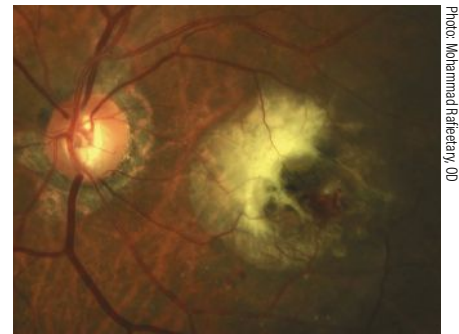
Photos: Jessica Hanes, OD



Sarcoidosis-associated panuveitis may present, as in this case, with scattered yellow lesions and vitritis. ICG is helpful to assess choroidal involvement, seen here as scattered hypocyanescent lesions more numerous than those seen on the dilated fundus exam.

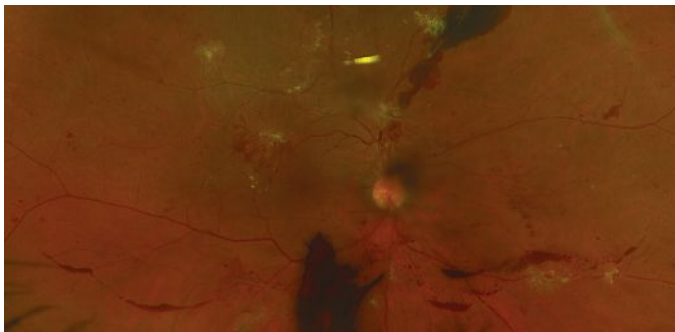


Photos: Alison Bozong, OD

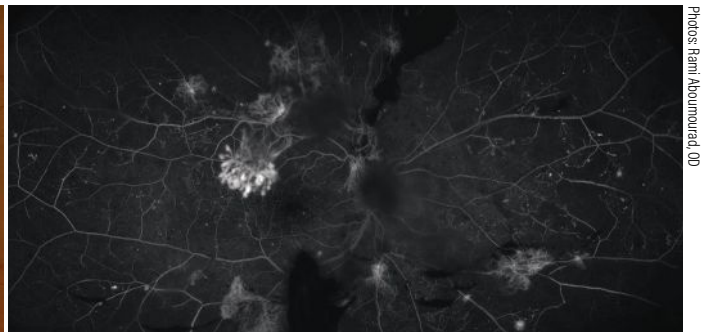


In RAP, abnormal vasculature proliferates from the retinal circulation and progresses posteriorly into the subretinal space.

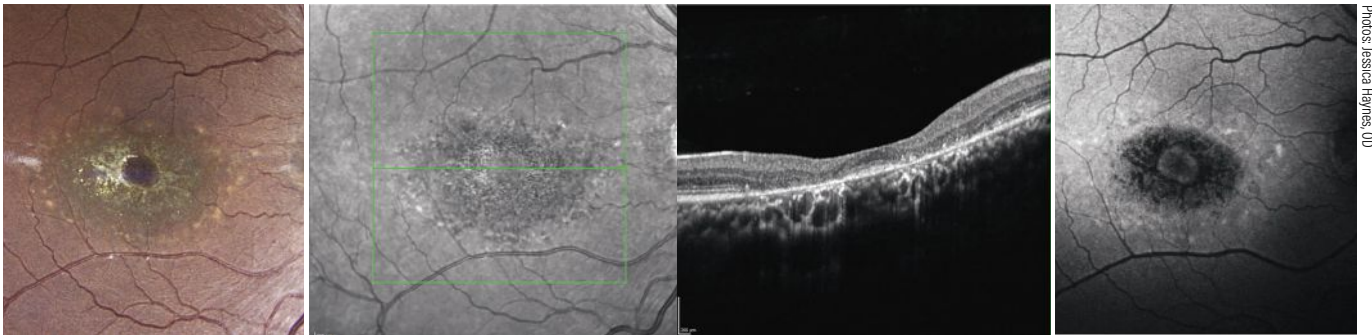
Photo: Mohammed Rafeeqy, OD



Widefield fundus photo of proliferative diabetic retinopathy (left) in a patient with vitreous, preretinal and intraretinal hemorrhaging, as well as multifocal fronds of retinal neovascularization. Fluorescein angiogram of the same patient (right) shows multifocal leakage consistent with neovascularization, IRMA, microaneurysms and peripheral capillary non-perfusion inferonasally.

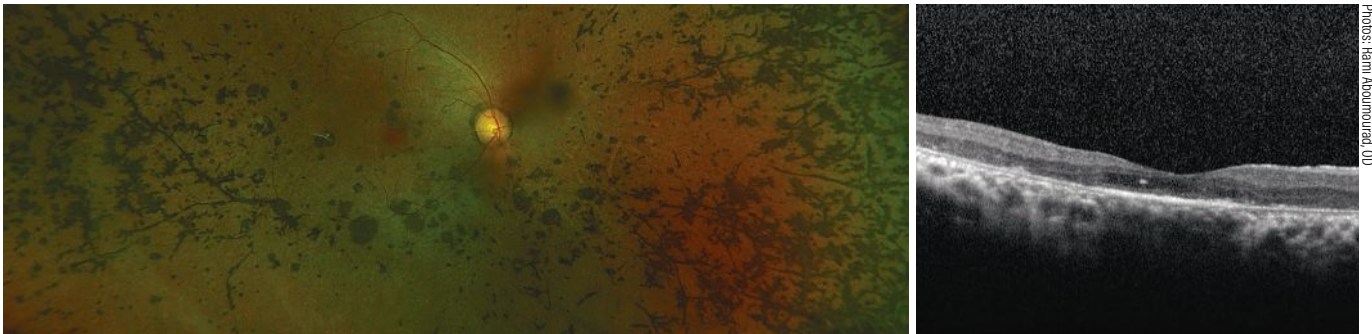


Photos: Rami Abounour, OD



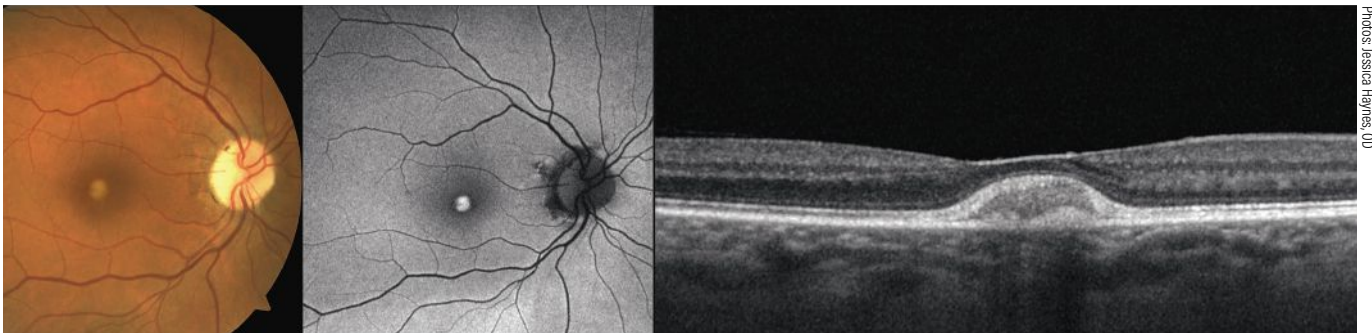
Photos: Jessica Hayes, OD

Stargardt's disease is the most common inherited macular dystrophy. The fundus photo shows the classic beaten bronze appearance of the macula with accompanying yellow deposits. OCT shows loss of outer retinal layers, including a loss of the photoreceptor integrity line. FAF demonstrates a bull's-eye pattern of hypoautofluorescence in areas of RPE atrophy and surrounding hyperautofluorescent pisciform lesions.



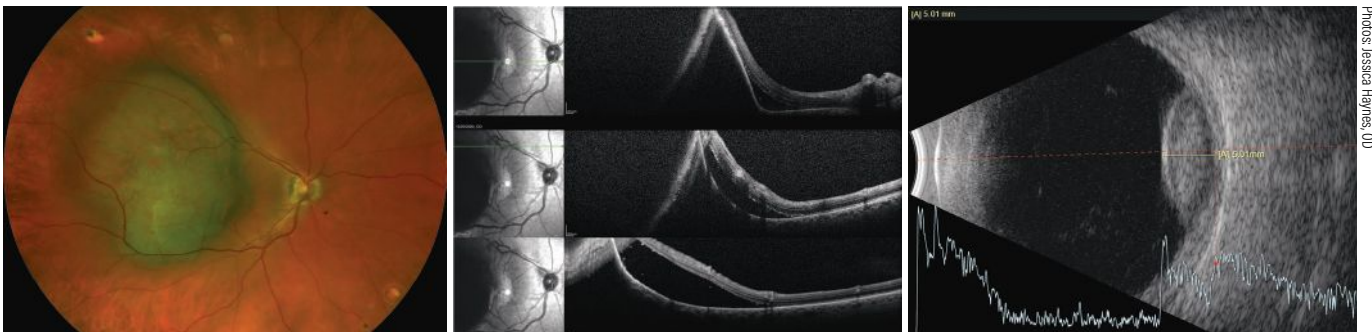
Photos: Hami Aoumourad, OD

Widefield fundus photo of a retinitis pigmentosa patient showing extensive retinal pigmentary changes (bone spicules) with a central island of remaining fovea. Of note, the optic nerve does not appear pale. The OCT scan shows a central foveal island of remaining IS/OS with otherwise diffuse outer-retinal and RPE atrophy.



Photos: Jessica Hayes, OD

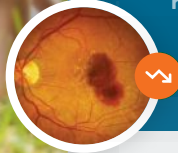Adult-onset vitelliform dystrophy is characterized by bilateral round, yellow lesions that present in adulthood and can easily be mistaken for choroidal neovascularizations. On FAF, these often appear hyperautofluorescent. On OCT, they present as hyperreflective mounds between the RPE and PIL. Patients often maintain reasonable visual acuity unless they develop CNV or photoreceptor atrophy.



Photos: Jessica Hayes, OD

This choroidal melanoma presents as an elevated lesion with overlying orange pigment. A dilated exam with good stereopsis will help determine elevation. OCT is very useful to demonstrate the finding of subretinal fluid. On ultrasound, the melanoma measures over 5mm thick with ultrasonographic hollowness. Thickness >2mm is a risk that a lesion is in fact a choroidal melanoma, as is ultrasound hollowness.

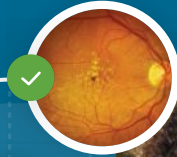Prevent AMD Vision Loss with Digital Healthcare



IRIS REGISTRY

20/83 VA

Average at wet AMD diagnosis according to IRIS Registry real-world data¹



ALOFT STUDY

≥20/40 VA

Average at wet AMD diagnosis with ForeseeHome²



ForeseeHOME™
AMD Monitoring Program

Early Detection Helps Preserve Vision

ForeseeHome is a **remote monitoring** program for at-risk dry AMD patients that helps **detect wet AMD earlier** and alerts you of changes.


Remote patient monitoring leads to better outcomes and stronger optometric practices

- ✓ FDA Cleared
- ✓ Medicare Covered

- Plug and play digital health solution for your patients
- Solidify long-term relationships with your patients
- No cost to your practice
- Strengthen your referral relationships with qualified wet AMD referrals

The Key to Successful Home Monitoring

NOTAL VISION MONITORING CENTER



Engagement & Education

Benefits Verification & Authorization

Continuous Monitoring



Practice Workflow Implementation

Remote Patient Management

Vision Alert Management



ForeseeHome is a registered trademark, and the ForeseeHome AMD Monitoring Program and logo and the Notal Vision logo are trademarks of Notal Vision. © 2023 Notal Vision, Inc. All rights reserved.

References: 1. Rao P et al. *Ophthalmology*. 2018;125(4):522-528. 2. Mathai M, Reddy S, Elman MJ, Garfinkel RA, Ladd B, Wagner A, Sanborn GE, Jacobs J, Busquets M, Chew EY; ALOFT study group. Analysis of the Long-term visual Outcomes of ForeseeHome Remote Telemonitoring - The ALOFT study. *Ophthalmology Retina*. 2022;6:922-929.

See website for FDA Indication for Use.

SM-169.3



GET STARTED TODAY

1-855-600-3112

Mon-Fri, 8 AM to 6 PM EST

notalvision.info/revopt

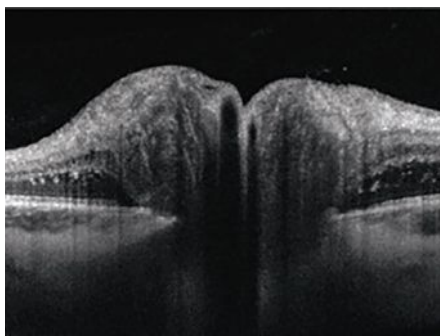
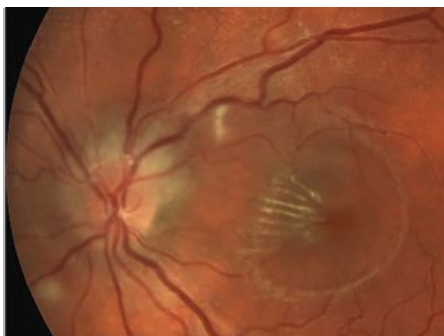
ASSESSING THE OPTIC NERVE

The stakes tend to be high with these conditions, and advanced imaging often plays a decisive role.

Sight, a remarkable sensation, involves a complex journey of light through the tear film, anterior chamber, pupil, crystalline lens and vitreous, followed by processing in the retina. While the interplay of these components is crucial for vision, the optic nerve holds an especially pivotal role in transmitting visual messages to the brain.

Often associated with glaucoma, the problems of the optic nerve encompass a broader spectrum of conditions beyond this common perception. Numerous conditions—ranging from congenital diseases like coloboma to toxic neuropathies, neurodegenerative diseases and ocular systemic disorders—affect the optic nerve’s structure and function.

The physical examination of the optic nerve, which has always been a critical part of an eye exam, has its limitations, primarily as we are confined to the observable optic nerve head. However, there are several functional and structural tests, including various photographic techniques and OCT, that can aid us in assessing the function of the optic nerve and in differential disease diagnosis.



Photos: Jessica Haynes, OD

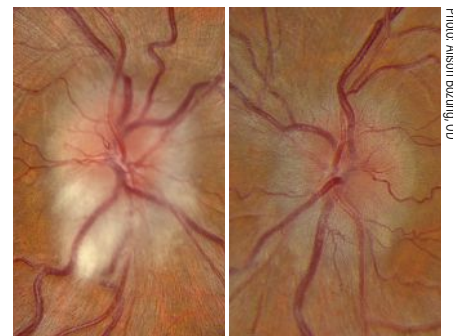
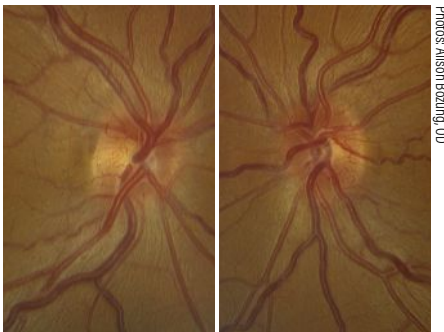


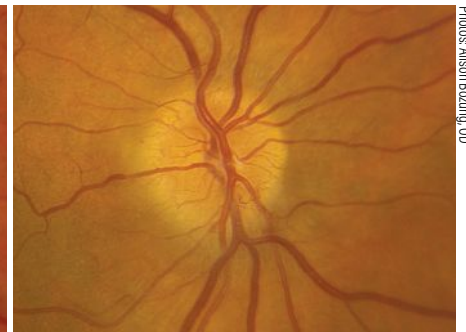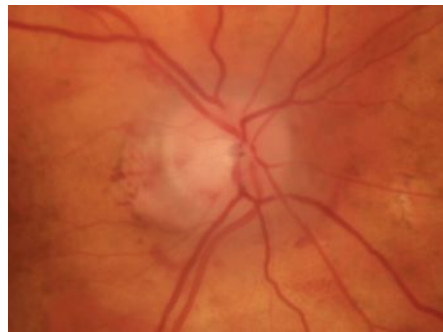
Photo: Alison Bzang, OD

Neuroretinitis is defined as inflammation or swelling of the anterior optic nerve and the macula. It has a wide range of etiologies from infectious to idiopathic, with cat scratch disease being the most common infectious cause. This patient also has a partial macular star forming.

IH typically presents with bilateral disc edema, transient visual obscurations, headaches and pulsatile tinnitus.



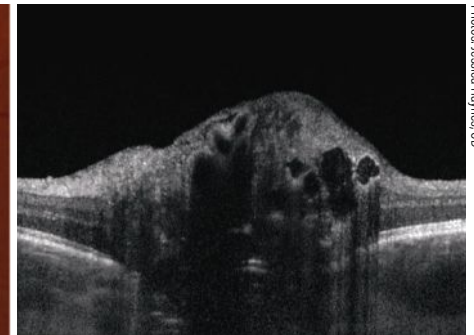
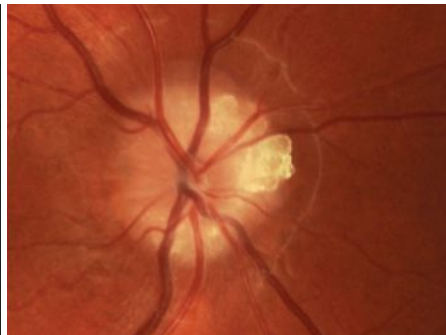
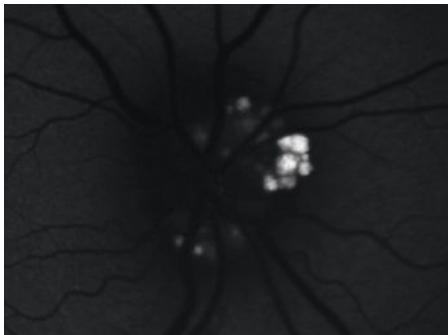
Photos: Alison Bzang, OD



Photos: Alison Bzang, OD

Leber's hereditary optic neuropathy begins unilaterally but rapidly involves the fellow eye. Patients develop painless central scotomas.

Left image is giant cell arteritis with arteritic anterior ischemic optic neuropathy (AAION). For more, see p. 58. **The non-arteritic form of AION (NAION, at right) is most common in those with a history of cardiovascular disease, sleep apnea and/or minimal optic nerve cupping.**



Photos: Jessica Haynes, OD

Optic disc drusen are proteinaceous deposits that become calcified with age. They can be buried or superficial. More superficial and calcified disc drusen are hyperautofluorescent as seen in the FAF image at left. They may be visible clinically as seen fundus photo (center). On OCT cross section scan (right), they may be visualized as internally hyporeflective lesions with a patchy/bumpy hyperreflective border.

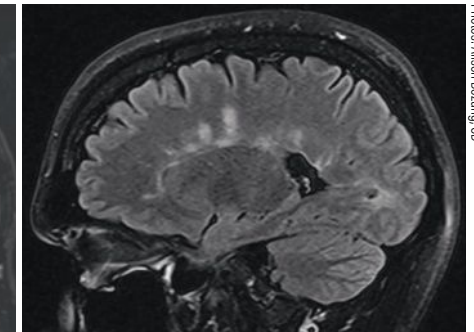
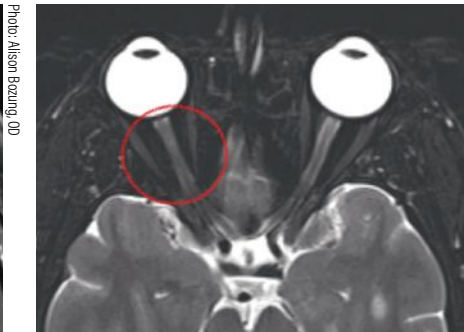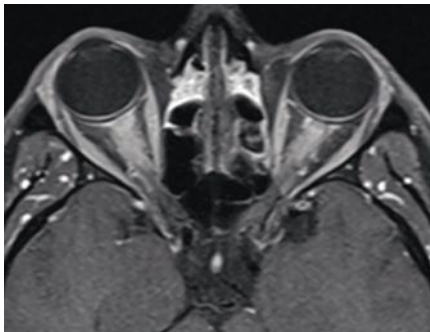
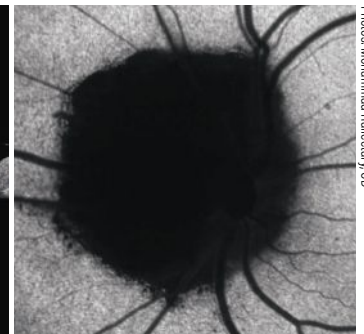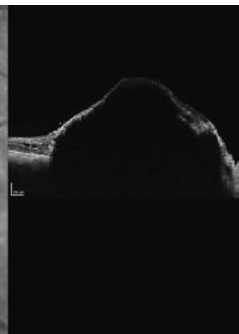
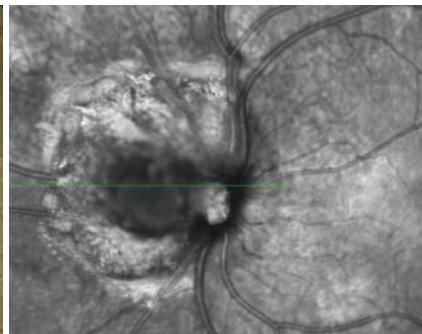
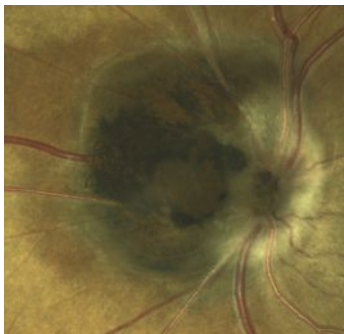


Photo: Alison Bozung, OD

Photos: Alison Bozung, OD

Bilateral extensive intraorbital optic nerve enhancement in myelin oligodendrocyte glycoprotein-associated optic neuropathy.

This patient with right retrobulbar optic neuritis presented with subacute vision loss and pain on eye movement. An MRI brain revealed periventricular white matter lesions, suggestive of a demyelinating disease.



Photos: Mohammad Rafieezy, OD

Optic nerve melanocytomas are rare, benign, deeply pigmented lesions. They are often distinguished by clinical appearance alone, which is quite striking, but additional testing could help differentiate them from other pigmented lesions. OCT of optic nerve melanocytoma shows elevated lesion with dense superficial hyperreflectivity and posterior shadowing. On FAF, the melanocytoma is hypoautofluorescent.

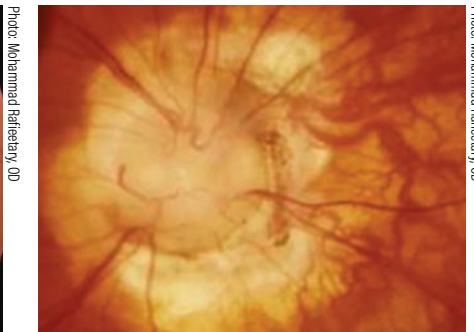
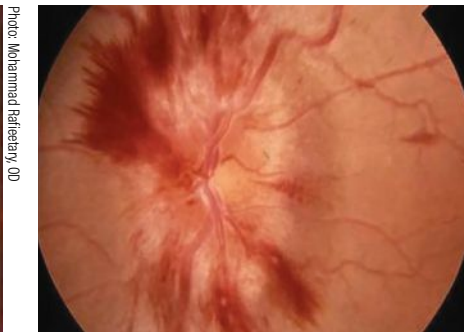
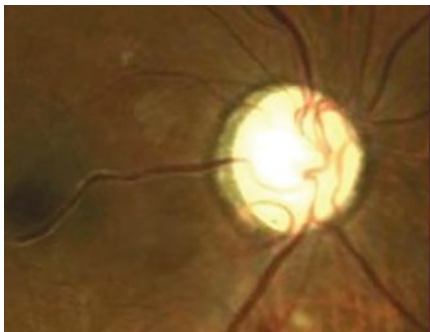


Photo: Mohammad Rafieezy, OD

Photo: Mohammad Rafieezy, OD

Photo: Mohammad Rafieezy, OD

This patient has optic atrophy and resultant disc pallor. It represents irreversible damage to the ganglion cell axons.

Papilledema may lead to elevation of the neuroretinal rim, indistinct disc margins, hemorrhages and Paton's lines.

Morning glory disc, a malformation in the spectrum of optic nerve coloboma, with straight vessels radiating from the disc.

Earn 2 CE Credits
(COPE APPROVED)

THE PHYSICAL MANIFESTATIONS OF GLAUCOMA AND WHAT THEY SIGNIFY

Understanding the range of structural findings associated with this condition is key to effective management.



BY HENRIETTA WANG, BOptom,
MPH, AND JACK PHU, OD, PhD
KENSINGTON, NSW,
AUSTRALIA

Despite advancements in ocular imaging over the past decade, there is no single parameter used for glaucoma diagnosis. Currently, it is usually made using a Bayesian approach whereby various components of a glaucoma examination such as intraocular pressure (IOP), visual field testing and structural assessment uniquely contribute to the diagnostic decision.¹ As such, the presentation of glaucoma and its physical manifestations can be diverse. This article will walk readers through the range of structural findings across the glaucoma spectrum using an illustrative approach and will also cover the pathophysiology of structural glaucomatous features.

Anterior Segment Examination

There are several conditions in this area that range from narrow angles to secondary conditions that can give rise to an increase in IOP. This section describes their key clinical features associated with glaucoma.

Angle closure spectrum disease. The first and arguably most important aspect of the anterior segment examination is to differentiate between open- and closed-angle disease.² Most patients with angle closure disease require immediate intervention to control IOPs and manage acute symptoms to prevent vision loss.³

Angle closure spectrum disease can be divided into primary and secondary.⁴ Pupillary blocks account for the majority of primary angle closure disease.^{5,6} In pupillary block, there is an increased pressure gradient that causes anterior bowing of the peripheral iris and subsequently iridotrabecular contact,

preventing aqueous outflow through the trabecular meshwork.⁶ In secondary angle closure, which typically presents more unilaterally compared to primary angle closure, iridotrabecular contact arises from other sources, such as ectopia lentis or neovascularization.⁷ Secondary angle closure may require different treatments than primary angle closure, thus it is important for clinicians to distinguish between the two.^{8,9}

Although slit lamp examination is not diagnostic for angle closure spectrum disease, it can be used to assess for features associated with acute angle closure attacks. Depending on the IOP and duration of angle closure, ocular signs may include conjunctival hyperemia, corneal edema, a fixed iris and/or anterior chamber inflammation. Clinicians need to assess the anterior segment carefully for these signs and exclude other conditions such as neovascular glaucoma that may share some these features.

About the authors

Dr. Wang is the head of Glaucoma/Neuro-ophthalmology unit at the Centre for Eye Health (UNSW). She received numerous clinical and academic awards during her undergraduate optometry degree, including a research scholarship for her work in the Retinal Networks Laboratory. Her clinical and research interests lie in the diagnosis as well as management of glaucoma and other optic nerve diseases. **Dr. Phu** is a clinician-scientist, holding the positions of lecturer at the School of Optometry and Vision Science, UNSW, and research fellow at Deakin University. His clinical, teaching and research activities are devoted almost exclusively to the understanding and care of patients with glaucoma and angle closure disease.

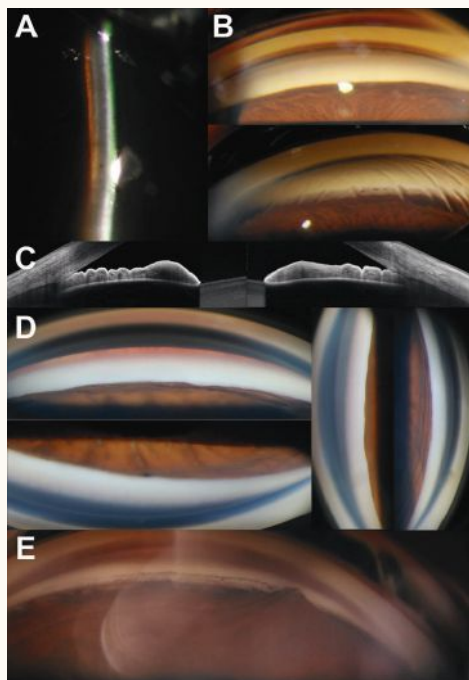


Fig. 1. (A) Narrow van Herick angle estimation of 0.1:1. (B) Gonioscopy with no angles visible in primary gaze without indentation (top) with deepening as well as increased visibility of angle structures with associated corneal stress lines on indentation (bottom). (C) Obvious iridotrabecular contact in both nasal and temporal angles on anterior segment OCT. (D) No visible structures in all quadrants in a patient with an acute angle closure attack. (E) Focal peripheral anterior synechiae in a patient with a history of an acute angle closure attack following clear lens extraction.

1. Gonioscopy should be performed both in primary gaze and with off-axis viewing or lens tilt. This allows for the differentiation between pseudo and true iridotrabecular contact in instances where the pigmented trabecular meshwork cannot be visualized in primary gaze. In patients with iridotrabecular contact, the next step of the gonioscopic examination is to assess for the presence or absence of synechiae. This is performed through indentation using the goniolens. In areas where the angle does not deepen with indentation, this is suggestive of synechial closure. An example of circumferential synechial closure is shown in *Figure 1*.

Peripheral anterior synechiae develop from prolonged contact between the trabecular meshwork and iris. On gonioscopy, iris imprinting manifests as focal patchy pigmentation on the trabecular meshwork.¹⁰ This can be used to identify areas at risk of developing synechiae as the pigment in this area is

thought to arise from intermittent touch between the trabecular meshwork and iris. Synechiae can develop in both broad and focal patterns. Interestingly, while the most common location for broad synechiae to develop is the superior quadrant, focal synechiae have no predilection for specific locations or clock hours.¹¹ The amount of IOP elevation corresponds to the extent of synechiae.¹¹ Clinical trials often deem one clock hour of synechiae as significant, but in clinical practice, IOP is also dependent on other factors and the functionality of the remaining non-occluded angle.

Secondary conditions. Although secondary glaucomas only account for approximately one-fifth of the glaucoma population, much like closed-angle glaucomas, they are associated with poorer visual outcomes, higher IOPs and more advanced disease at the time of diagnosis.¹² Given that the type of glaucoma has implications to guide intervention selection, optometrists must

While slit lamp examination can also be used to screen patients for narrow angles using the techniques such as van Herick estimation or anterior-segment optical coherence tomography (AS-OCT), gonioscopy remains the gold standard in staging and guiding management of angle closure.⁹ The classification and management for angle closure spectrum disease is summarized in *Table*

The Physical Manifestations of Glaucoma and What They Signify

Jointly provided by Postgraduate Institute for Medicine (PIM) and Review Education Group

Release Date: January 15, 2024

Expiration Date: January 15, 2027

Estimated Time to Complete Activity: two hours

Target Audience: This activity is intended for optometrists who want to learn more about and examine the structural findings of glaucoma.

Educational Objectives: After completing this activity, participants should be better able to:

- Recognize the pathophysiology of structural glaucomatous features.
- Identify the physical manifestations of glaucoma.
- Perform an ocular exam in a glaucoma patient or suspect.
- Make clinical decisions related to the diagnosis and treatment of glaucoma.

Faculty: Henrietta Wang, BOptom, MPH, and Jack Phu, OD, PhD

Disclosure of Conflicts of Interest: PIM requires faculty, planners and others in control of educational content to disclose all their financial relationships with ineligible companies. All identified conflicts of interest are thoroughly vetted and mitigated according to PIM policy. PIM is committed to providing its learners with high-quality, accredited CE activities and related materials that promote improvements or quality in health care and not a specific proprietary business interest of an ineligible company.

Those involved reported the following relevant financial relationships with ineligible entities related to the educational content of this CE activity: *Faculty* – Dr. Wang and Dr.

Phu have nothing to disclose. *Planners and Editorial Staff* – PIM has nothing to disclose. The Review Education Group has nothing to disclose.

Accreditation Statement: In support of improving patient care, this activity has been planned and implemented by PIM and the Review Education Group. PIM is jointly accredited by the Accreditation Council for Continuing Medical Education, the Accreditation Council for Pharmacy Education and the American Nurses Credentialing Center to provide CE for the healthcare team. PIM is accredited by COPE to provide CE to optometrists.

Credit Statement: This course is COPE-approved for two hours of CE credit. Activity #127478 and course ID 89016-GL. Check with your local state licensing board to see if this counts toward your CE requirement for relicensure.

Disclosure of Unlabeled Use: This educational activity may contain discussion of published and/or investigational uses of agents that are not indicated by the FDA. The planners of this activity do not recommend the use of any agent outside of the labeled indications. The opinions expressed in the educational activity are those of the faculty and do not necessarily represent the views of the planners. Refer to the official prescribing information for each product for discussion of approved indications, contraindications and warnings.

Disclaimer: Participants have an implied responsibility to use the newly acquired information to enhance patient outcomes and their own professional development. The information presented in this activity is not meant to serve as a guideline for patient management. Any procedures, medications or other courses of diagnosis or treatment discussed or suggested in this activity should not be used by clinicians without evaluation of their patient's condition(s) and possible contraindications and/or dangers in use, review of any applicable manufacturer's product information and comparison with recommendations of other authorities.



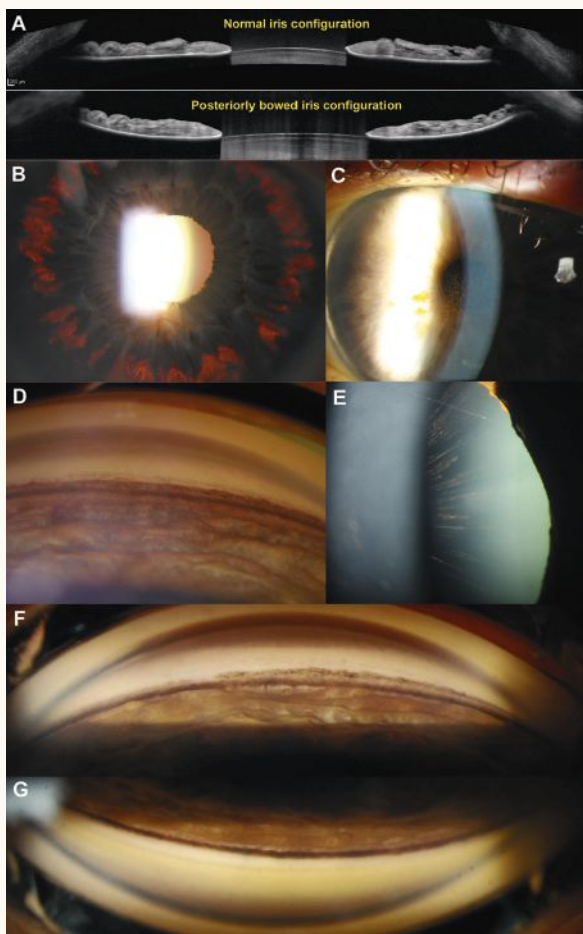


Fig. 2. (A) AS-OCT of a normal (top) and posteriorly bowed iris configuration in a patient with PDS (bottom) with contact between the mid-peripheral iris and anterior lens surface. (B) Retroillumination technique highlights mid-peripheral iris transillumination defects. (C) Endothelial pigment deposition (also known as Krukenberg’s spindle). The flow of aqueous convection currents results in denser central deposition, which gives rise to the spindle-like pattern. (D) Dense homogenous increased pigmentation within the angle, particularly along the trabecular meshwork and anterior to Schwalbe’s line (also known as Sampaolesi’s line). In active PDS, all four quadrants will have a similar extent of pigmentation. There is also posterior bowing of the iris profile. (E) Long anterior lens zonules (LAZs) with associated pigmentation. In PDS, the anterior lens zonules are more centrally located on the lens capsule and often appear pigmented due to contact with the posterior iris surface. (F) An example of “pigment reversal sign” in burnt out PDS, where the inferior angle appears less densely pigmented (top) compared with the superior angle (bottom). This is considered to be a sign of inactive disease.

Pigment dispersion syndrome (PDS) is characterized by abnormal liberation of pigment from the posterior iris pigment epithelium and resultant deposition of pigment on ocular structures such as the trabecular meshwork, corneal endothelium and the anterior chamber. Deposition of pigment within the trabecular meshwork can result in an increase in IOP

radial iris transillumination defects and homogeneously increased pigmentation of the trabecular meshwork. The clinical presentation may vary based on race.^{14,15} For example, in populations with more pigmented irises, it is less common to see mid-peripheral iris transillumination defects due to a greater iris thickness.¹⁵ In these patients, clinicians should instead look for the presence of peripheral iris bowing, Krukenberg’s spindle or radial lenticular pigmentation to reliably diagnose PDS. Other clinical features can include: the presence of long anterior lens zonules, pigment showers, anisocoria, heterochromia and deposition of pigmentation on the anterior and posterior surface of the crystalline lens.¹⁶

In addition to assisting in the diagnosis of PDS, careful gonioscopic examination of the trabecular meshwork can also help with disease prognostication. Glaucoma disease severity has been shown to correlate with the intensity of trabecular mesh-

work pigmentation whereby a heavier degree of pigmentation is associated with more advanced disease.¹⁷ While AS-OCT is not able to visualize the majority of PDS features, it may be useful in characterizing the iris-lens relationship to assess for peripheral iris bowing, similar to traditional ultrasound biomicroscopy.¹⁸ The clinical features associated with PDS are shown in *Figure 2*.

As pigment liberation is dependent on contact between the

be able to recognize relevant clinical signs and accurately diagnose secondary conditions. In this section, we will cover features in conditions such as pigment dispersion syndrome, pseudoexfoliation syndrome, blunt ocular trauma, anterior segment neovascularization and inflammation. A summary of the common presenting features of each condition is summarized in *Table 2*.

and subsequent development of glaucoma. Anatomically, posterior bowing of the peripheral iris is thought to give rise to increased mechanical friction between the peripheral iris and anterior lens zonule bundles.¹³

Active PDS most commonly presents with three classical signs: pigment deposition on the corneal endothelium in a spindle-like pattern, mid-peripheral

TABLE 1. CLASSIFICATION AND MANAGEMENT FOR ANGLE CLOSURE SPECTRUM DISEASE

| Gonioscopy findings | Diagnosis | Recommended management |
|--|----------------------------------|---|
| No iridotrabecular contact in any quadrant | Open angles | Continue routine optometric review |
| Iridotrabecular contact in two or fewer quadrants | Narrow but non-occludable angles | Review annually |
| Iridotrabecular contact in more than two quadrants BUT IOP/ONH/VF all normal without signs of PAS | Primary angle closure suspect | Consider prophylactic LPI |
| Iridotrabecular contact in more than two quadrants with elevated IOP or PAS is present BUT no glaucoma | Primary angle closure | Prophylactic LPI and consider glaucoma treatment to lower IOP if needed |
| Iridotrabecular contact in more than two quadrants with elevated IOP or PAS and glaucoma present | Primary angle closure glaucoma | Prophylactic LPI and glaucoma treatment |

Abbreviations: PAS = peripheral anterior synechiae, ONH = optic nerve head, VF = visual field, LPI = laser peripheral iridotomy

Adapted from Emanuel ME, Parrish RK 2nd, Gedde SJ. Evidence-based management of primary angle closure glaucoma. *Curr Opin Ophthalmol.* 2014;25(2):89-92.

peripheral iris and lens zonules, changes to this configuration associated with age can lead to disease inactivity, known as the “burnout phase.”^{19,20} This manifests with “filling in” of iris transillumination defects secondary to migration of iris pigment epithelial cells from adjacent areas.^{19,20} Gonioscopy reveals “pigment reversal sign” whereby the superior angle appears more heavily pigmented when compared to the inferior angle (*Figure 2*).^{19,20} This disparity between the superior and inferior angles is thought to arise from more rapid removal of pigment from the trabecular meshwork in the inferior angles due to the direction of aqueous convection currents. It is important to be able to differentiate between active and burnt out PDS given the implications for treatment intensity.

Pseudoexfoliation (PXF) syndrome is a systemic condition primarily affecting ocular structures through the deposition of white extracellular fibril material on various ocular structures.²¹ The primary sites of deposition include: the trabecular meshwork, corneal endothelium anterior chamber, anterior lens capsule as well as pupillary margin and anterior iris surface.²² The accumulation of PXF material with the trabecular meshwork results in focal collapse of Schlemm’s canal, subsequently reducing aqueous outflow facilities and increasing IOP.²³ Patients with PXF glaucoma may require a more aggressive approach to treatment as they have a poorer response to topical therapies and often require surgical intervention to sufficiently control IOP.

Anterior segment examination will reveal the following constellation of features: PXF material on the anterior lens capsule in a bull’s-eye pattern as well as on the pupillary margin, patchy increased pigmentation of the trabecular meshwork and peripupillary iris transillumination defects. The bull’s-eye pattern on the anterior lens surface can be broken down into three zones: central zone, middle and peripheral.²²

The central zone presents with a well-demarcated curled edge and corresponds with the resting position of the natural pupil. The middle clear zone arises from contact between posterior iris surface and

PXF material on the lens. As a result of this contact, there is loss of iris pigment in this area which gives rise to iris transillumination defects in a peripupillary location. Like PDS, the pigment liberated through this mechanism can also deposit on various ocular structures including the trabecular meshwork, usually more prominent in the inferior quadrant. The peripheral bull’s-eye zone is only visible with pupil dilation. The clinical features associated with PXF syndrome are shown in *Figure 3*.

The irises of patients with PXF typically dilate poorly due to atrophy of the iris dilator muscle. Additionally, zonular weakness presenting as phacodonesis can also be observed in PXF. This can be elicited by instructing the patient to initiate eye movements which results in vibrating-like movement of the lens. Zonular weakness is thought to arise from infiltration of PXF material into the zonular bundles at the zonule anchorage points in the ciliary body.²⁴ In extreme cases, secondary angle closure can occur with subluxation of the lens. Practically, the presence of PXF may also present as an obstacle to cataract surgery.²⁵

Angle recession. Blunt trauma to the globe can result in tearing of both longitudinal and circular fibers of ciliary body muscle.²⁶ This tearing within the ciliary

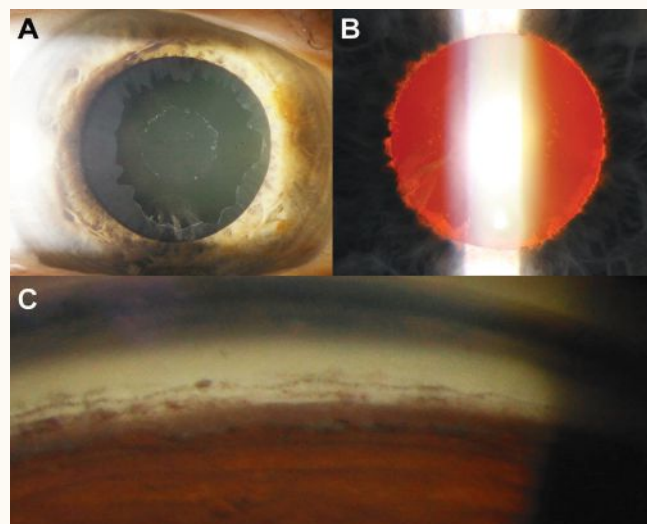


Fig. 3. (A) Bull’s-eye pattern of pseudoexfoliative material on the anterior lens capsule. (B) Retroillumination shows loss of the pupillary ruff as well as peripupillary iris transillumination defects. (C) There is increased but patchy pigmentation (brown sugar-like appearance) of the trabecular meshwork on gonioscopy as well as Sampaolesi’s line. The inferior angle typically appears more pigmented compared with the other angles.

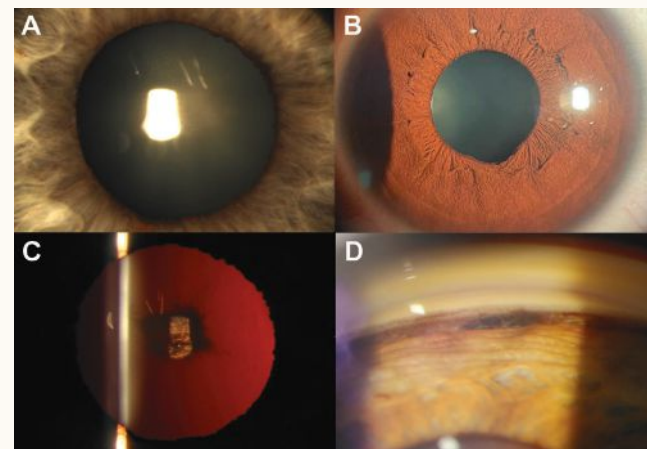


Fig. 4. (A) Nasal loss of the pupillary ruff in a patient with a history of blunt trauma to the eye. (B) Focal traumatic mydriasis between five and six o’clock suggest iris sphincter damage in this location. (C) Traumatic cataract with a petaloid pattern seen with retroillumination. (D) Focal widening of the ciliary body band observed in the superior mirror on gonioscopy.

body muscle has been thought to lower the muscle’s tension on the scleral spur, which results in subsequent narrowing Schlemm’s canal thus reducing aqueous outflow and increasing IOP.

Additionally, while there may also be associated damage to the trabecular meshwork and Schlemm’s canal affecting IOP from the initial trauma, alterations to these structures such as scarring or

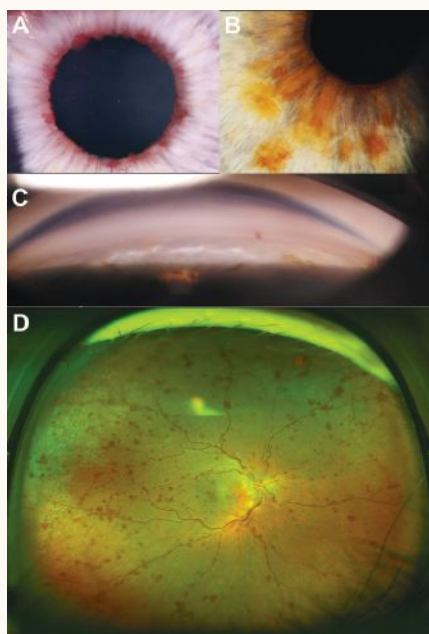


Fig. 5. (A) Tuft-like neovascularization along the pupillary margin. (B) Proliferation of the iris neovascularization from the across the anterior iris surface. (C) Neovascularization seen within the angle on gonioscopy. (D) Ultra-widefield imaging of the active central retinal vein occlusion in the right eye from the patient shown in B and C.

fibrosis that can give rise to elevated IOPs can occur up to decades post-injury.²⁷ Thus, patients with a history of blunt trauma require lifelong monitoring for angle recession and trabecular function. While not all patients develop angle recession, the presence of a hyphema at the time of trauma, alongside the extent of recession, is highly predictive of angle recession development in future.²⁸

Gonioscopy is the key clinical test to diagnose angle recession whereby clinicians will observe widening of the ciliary body band corresponding to the areas of recession. It should be noted that there is significant heterogeneity in the physiological width of the ciliary body between individuals thus it is critical to perform an intra-eye comparison to prevent misdiagnosis. While not diagnostic, slit lamp examination is useful to assess for other signs of previous ocular trauma. These include iris tears, focal or diffuse pupillary dilation, Vossius ring, iridodialysis, iridodonesis, corneal changes, phacodonesis or hyphema in more acute

instances of trauma.²⁹ This may be useful as some patients with clear signs of ocular trauma such as iris sphincter tears may not report a history of trauma. The anterior segment features of angle recession are shown in *Figure 4*.

Neovascularization of the iris occurs due to an increase in vasoproliferative factors such as inflammatory cytokine interleukin 6 and vascular endothelial growth factor (VEGF).²⁸ Causes of increased VEGF classically include diabetic retinopathy and retinal vascular occlusions but may also include pro-inflammatory conditions, such as chronic retinal detachment and intraocular tumors.³⁰ The increased level of VEGF interacts with iris' capillary endothelial cells to form new vessels without intracellular tight junctions which subsequently leak.

The natural history of iris neovascularization in the context of glaucoma can be broken down into three stages: (1) active neovascularization, (2) open-angle glaucoma and (3) closed-angle glaucoma.³¹ During the active neovascularization stage, tuft-like vessels are commonly observed along the pupillary margin of the anterior iris surface. As the condition

progresses to the open-angle glaucoma stage, the new vessels extend peripherally towards the angle and forming a fibrovascular membrane obstructing trabecular outflow.

In the closed-angle glaucoma stage, there is contraction of proliferated tissue distorting the natural iris contour, leading to synechiae-like angle closure. An example of a patient with a history of central retinal vein occlusion and subsequent iris neovascularization along the pupillary margin is shown in *Figure 5*. Patients with fully developed neovascular glaucoma typically present with very elevated IOPs, bulbar conjunctival hyperemia and corneal edema. This presentation may mimic an acute angle closure attack as corneal edema can confound iris and angle evaluation. The management of neovascular glaucoma includes management of IOP and a need to address the underlying disease.

Anterior segment inflammation (uveitis). Glaucoma can arise both directly and indirectly as a result of anterior segment inflammation.³² Broadly, uveitic glaucoma can be broken down into open-angle and closed-angle presentations. In open-angle

TABLE 2. CLINICAL FEATURES OF COMMON SECONDARY CONDITIONS ASSOCIATED WITH GLAUCOMA

| Condition | Slit lamp biomicroscopic features | Gonioscopy features |
|-------------------------------|--|--|
| Pigment dispersion syndrome | <ul style="list-style-type: none"> - Pigment deposition on anterior segment structures (e.g., anterior lens surface and corneal endothelium) - Mid-peripheral iris transillumination defects - Long anterior zonules (more central extension of the zonules) | <ul style="list-style-type: none"> - Active stage: dense homogenous pigmentation of the anterior angle - Inactive stage: pigment reversal sign (superior angle appears more pigmented than the inferior angle) |
| Pseudoexfoliative syndrome | <ul style="list-style-type: none"> - Extracellular fibril material deposition on anterior segment structures (e.g., anterior lens surface in a double-concentric pattern and corneal endothelium) - Peripupillary iris transillumination defects - Phacodonesis | <ul style="list-style-type: none"> - Deposition of exfoliative material in anterior chamber angle - Increased but patchy pigmentation of the trabecular meshwork |
| Anterior segment inflammation | <ul style="list-style-type: none"> - Anterior chamber cells or flare - Endothelial keratic precipitates - Posterior synechiae | <ul style="list-style-type: none"> - Peripheral anterior synechiae |
| Angle recession | <ul style="list-style-type: none"> - Acute trauma: hyphema and/or acute inflammation - Iris sphincter tears, mydriasis, phacodonesis/subluxated lens, iridodialysis or cyclodialysis | <ul style="list-style-type: none"> - Widening of the ciliary body band - Iridodialysis or cyclodialysis - Irregular hyperpigmentation of the angle - Whitening of the scleral spur (broken iris processes) |
| Neovascularization | <ul style="list-style-type: none"> - Iris rubeosis | <ul style="list-style-type: none"> - Neovascularization within the angle |

presentations, changes to the blood-
aqueous barrier during inflammation lead
to the accumulation of inflammatory cells
(such as keratic precipitates) within the
trabecular meshwork which can be ob-
served gonioscopically. This, in conjunc-
tion with swelling of the trabecular tissue,
leads to a reduction in aqueous outflow
facility. Over time, permanent trabecular
remodelling can lead to reduced func-
tionality in aqueous outflow.

Adjunctive to the inflammatory effects
of uveitis, corticosteroid medication used
in the management of anterior segment
inflammation may cause iatrogenic IOP
elevation. Several risk factors for local
corticosteroid responsiveness have been
proposed, such as the extremes of age, a
high baseline IOP, personal or family his-
tory of glaucoma and certain genotypes.³³
Local administration of corticosteroid
may be necessary over a long period of
time and at recurrent episodes. Thus,
there are more opportunities for cortico-
steroid responsiveness to lead to IOP-
mediated glaucomatous damage.

In closed-angle presentations, ante-
rior and posterior synechiae can lead to
elevations in IOP. Posterior synechiae are
characterized by adhesion between the
posterior iris surface and anterior lens
surface. Depending on the extent of ad-
hesion and interruption to aqueous flow
from the anterior chamber, this can result
in increased pressure behind the periph-
eral iris leading to iris bombe. Peripheral
anterior synechiae can also contribute to
increased IOP in closed-angle presenta-
tions. Anterior segment features associ-
ated with acute or chronic inflammation
are shown in *Figure 6*.

Funduscopy Assessment of the Optic Nerve

Stereoscopic examination of the optic
nerve head is another major compo-
nent of a comprehensive glaucoma
assessment. Glaucomatous optic nerve
changes are classically described as a
diverse range of “characteristic” features,
including diffuse or focal (notching) loss
of the neuroretinal rim, widening and
deepening of the optic cup, correspond-
ing retinal nerve fiber layer (RNFL) loss
touching the rim and disc hemorrhag-

es.³⁴ A reason for this spectrum
of features is because no single
feature offers adequate sensitivity
or specificity for diagnosis.^{35,36}
Also, some features may be seen
in other optic neuropathies.^{37,38}
Thus, it is the combination of
features that determines the like-
lihood of glaucoma. An example
of disc changes in early, moder-
ate and advanced glaucoma is
shown in *Figure 7*.

Neuroretinal rim changes.

A hallmark sign of glaucoma
is thinning of the neuroreti-
nal rim.³⁶ In this disease, the
inferotemporal sector is the most
common site of initial damage.³⁹
Classically, the vertical poles are
affected (inferior and superior)
more so than along the horizon-
tal axis. As glaucoma progresses,
the temporal rim is more likely
to demonstrate loss prior to nasal
involvement in later stages.³⁷

In clinical practice, several
techniques help identify these
changes. On fundoscopic exami-
nation, following the contour of
the cup to inspect for color and
contour changes in the ovality
of the cup carefully may help
find irregularities suggestive of
rim changes. It is important to
acknowledge that color is often
a challenging cue for judging
neuroretinal rim.⁴⁰ However, if
a clinician detects similarities in
the color of the cup and rim, it
may suggest pallor of the rim as it
should normally be more orange
or pink with perfusion, relative to the
cup.⁴¹ This would suggest an alternative
diagnosis to glaucoma.

Traditionally, blood vessel changes such
as baring and bayonetting have been pro-
posed as markers of glaucoma.^{42,43} These
terms are not part of current definitions
of structural changes in glaucoma because
they are poorly defined. For reference,
we refer to baring as the change in blood
vessel contour as it enters or exits the
optic cup as it touches the neuroretinal
rim, and bayonetting specifically refers
to the situation in which a sharp vertical

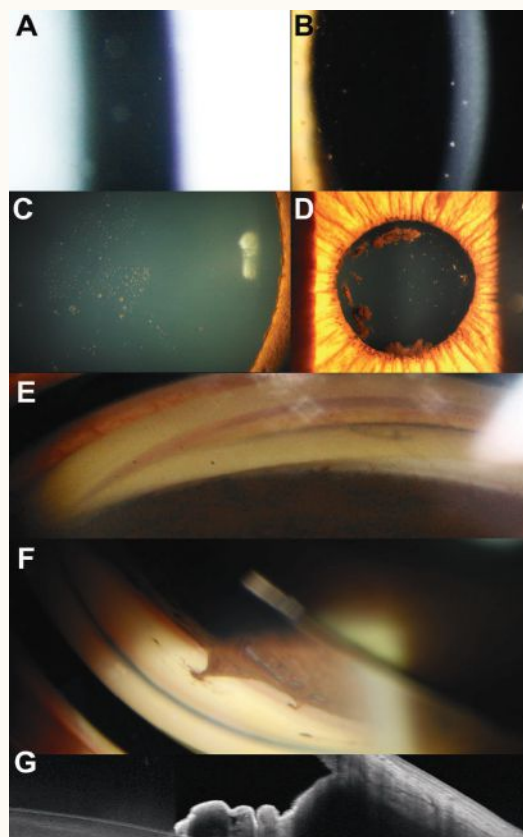


Fig. 6. (A) Assessment of the anterior chamber shows anterior chamber cells. (B) Keratic precipitates and pigment on the corneal endothelium. (C) Multifocal pigmentation on the anterior lens surface in a patient with recurrent uveitis. (D) Larger agglomerates of pigment on the anterior lens capsule suggestive of broken posterior synechiae. (E) Broad peripheral anterior synechiae manifesting with narrowing of the angle in the left side of the image. (F) Focal peripheral anterior synechiae adjacent to an area of iris atrophy. (G) AS-OCT through an area of peripheral anterior synechiae showing anterior displacement of the peripheral iris resulting in iridotrabecular contact.

drop (along the z-axis) at the margin of
the markedly thin neuroretinal rim.^{41,44}
Therefore, the latter would represent
advanced neuroretinal rim loss. Because
these blood vessel changes are poorly
defined and with no accepted grading
system, we suggest that these are used as
surrogates of neuroretinal rim integrity.

Neuroretinal rim changes may be focal
or diffuse in morphology.³⁹ Historically,
focal and diffuse changes have been as-
sociated with pressure-defined pheno-
types of glaucoma: normal or low-tension
and high-tension, respectively.⁴⁵ This
has remained a subject of debate in the

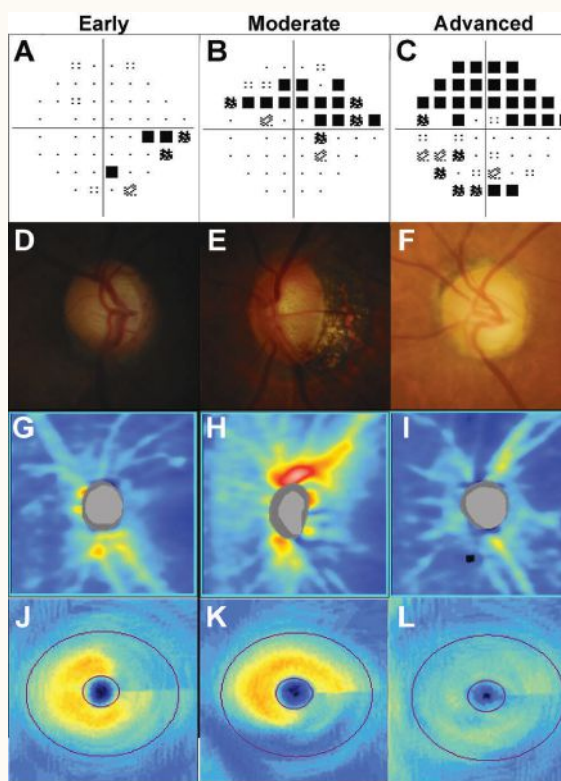


Fig. 7. Examples of early, moderate, and advanced glaucoma staged using visual field severity. In A to C, 24-2 visual field test results: (A) Inferior nasal step in early glaucoma. (B) Superior arcuate defect in moderate glaucoma. (C) Dense superior arcuate defect with an inferior cluster of reduction in advanced glaucoma.

In D to F, disc photographs: (D) Thin superior neuroretinal rim in early glaucoma, (E) Marking loss of the inferior neuroretinal rim with a disc hemorrhage at the inferior disc. (F) Generalized concentric loss of the neuroretinal rim. In G to I, OCT RNFL heat maps: (G) Superotemporal loss of the RNFL. (H) Deep inferior loss of the RNFL. (I) Supertemporal and inferotemporal loss of the RNFL.

In J to L, OCT ganglion cell analysis heat maps: (J) Superior arcuate wedge-like loss. (K) Wide inferior arcuate loss. (L) Generalized loss of the ganglion cell-inner plexiform layer.

literature.⁴⁶ An example of the proposed patterns of loss for low vs. high tension phenotypes of glaucoma is shown in *Figure 8*.

Due to conflicting evidence in the literature, it is important for clinicians to recognize that focal or diffuse changes may occur in various phenotypes of glaucoma, irrespective of the level of IOP. The extent of neuroretinal rim changes may provide insights into the expected stage of glaucoma (alongside other features as described below).³⁴ Since the neuroretinal

rim is a measure of retinal nerve fiber volume at the optic disc, its losses provide insight into the amount of neural tissue remaining. Therefore, focal losses may be more representative of an earlier stage of the disease process, and widespread diffuse defects may potentially indicate more extensive and advanced glaucoma.³⁹

Glaucomatous cupping and the cup-to-disc ratio.

Cupping is one of the quintessential descriptors of glaucoma and is synonymous with pathological neural tissue loss. Historically, clinical records of the optic nerve have been distilled into cup-to-disc ratio as a simplified metric of glaucoma likelihood. Current paradigms discourage the sole use of the cup-to-disc ratio because of its relative imprecision in differentially diagnosing glaucoma.

Like neuroretinal rim changes, cupping needs to be contextualized. The recommendation is that a record of cup-to-disc ratio must always be accompanied by a descriptor of disc size.⁴⁴ Relatively speaking, a larger disc size is more likely to be accompanied by a larger cup, and correspondingly for a smaller-sized disc. Therefore, an apparently large cup-to-disc ratio is more likely to be anomalous in a

relatively smaller disc instead of a larger disc.

Another feature that often accompanies a description of the cup-to-disc ratio is the visibility of the lamina cribrosa. Similar to the cup depth, visibility of the lamina cribrosa is also regarded as a surrogate for decreased volume of neural tissue.⁴⁷ Recently, there has been substantial research interest in lamina cribrosa parameters, such as thickness, curvature, orientation and pore size.^{48,49} As with cup-to-disc ratio, we recommend that

the visibility of the lamina cribrosa is documented as part of the comprehensive optic disc description.

RNFL defects. With visible changes at the optic nerve head (rim and cup), there must accordingly be upstream pathological features; these are the RNFL defects.⁵⁰ Typically, glaucomatous RNFL defects touch the optic disc, and non-contiguous defects are more likely to be attributable to other pathologies.

In the earlier stages of glaucoma, RNFL defects are described as wedge- or arcuate-shaped, following a course expected from focal defects at the optic nerve.⁵⁰ In diffuse phenotypes of glaucomatous damage, the RNFL may also be generally reduced in thickness.⁵¹ A notable feature of these defects that may be better appreciated using ocular imaging is the gradient of structural change at its borders.⁵⁰ This is defined as a gradual change from a region of normality (nerve fibers intact) to a region of pathology.⁵² The gradual change can be considered to resemble a “leading edge” where there are anatomical regions at risk of progression. This gradient of structural change is an important feature in glaucoma, as it contrasts profoundly with other retinal pathologies such as retinitis pigmentosa, in which there is a clear delineation between the region of normality and region of pathology. Therefore, the gradient of RNFL change may be used to differentiate glaucoma from non-glaucomatous causes of RNFL loss.

Disc hemorrhages. Sometimes eponymously referred to as Drance hemorrhages, this feature may be seen alongside other glaucomatous structural change. By definition, a disc hemorrhage associated with glaucoma is a linear hemorrhage following the trajectory of the RNFL bundles, occurring within the RNFL and within one disc diameter of the disc margin.⁵³ Therefore, other morphologies, such as splotchy, ill-defined and in the pre-retinal space, should not be considered to be related to glaucoma.

Their significance has been debated in the literature. Some studies have suggested that disc hemorrhages are harbingers of glaucomatous change, as they are an outward manifestation of ischemic stress

to the RNFL.⁵⁴ However, classically, the Ocular Hypertension Treatment Study suggested that disc hemorrhages may be an inevitable part of the glaucoma continuum and that detecting them is merely an incidental finding during a patient's follow-up.⁵⁵

While it may not compel the clinician to modify treatment (treatment changes are the domain of actual structural and/or functional progression), they may signal the need to consider alterations to follow-up or further investigations for vascular comorbidities.

Peripapillary atrophy (PPA). Like disc hemorrhages, this has been traditionally taught as a feature of glaucoma.⁵⁶ However, unlike disc hemorrhages, PPA is a very non-specific sign that may be present in a host of other conditions, including in a non-pathologic manner in otherwise healthy eyes.⁵⁷ PPA is described as a region of retinal atrophy involving various depths such as the neurosensory retina and retinal pigment epithelium touching the disc in various degrees. It is often described by clock hours and distance from the edge of the disc.

Recent studies supplemented by imaging modalities have enabled improved methods for classifying PPA into the alpha, beta and gamma zones.^{58,59} Its significance for glaucoma and key indices in such studies have also been mixed.⁶⁰ Based on the poor correlations with indices of glaucoma structure and function, we recommend that peripapillary atrophy, if documented, remains a cursory retinal feature not specific to the glaucoma assessment.

OCT

In the assessment of glaucoma, OCT allows for quantification of neural tissue affected in the disease, allowing clinicians to not only perform statistically based comparisons to normative databases but also quantitative progression analysis.⁶¹ These devices return several important parameters for clinical correlation. If we consider the framework for fundoscopic examination described previously, we can consider what are the pertinent features in the OCT result. Notably, clinicians

need to be mindful of the different strengths and weaknesses with respect to the examination of these parameters when interpreting the results. An example of OCT patterns of loss in early, moderate and advanced glaucoma is shown in *Figure 7*.

RNFL loss. This result on the OCT can be qualitatively and quantitatively appreciated. The two main methods for qualitative examination of the RNFL are using the heat map (raw thickness map) and the deviation map. The heat map provides an *en face* view of the scan area, highlighting areas with retinal thickening in warmer colors (and even more relative thickening towards white) and thinner areas in cooler colors. At a glance, this enables the clinician to examine for the morphology of RNFL loss and its contiguity with the optic nerve head.

The deviation map is a similar *en face* view but shows a grey scale scanning laser ophthalmoscopy image with superpixels superimposed. The superpixels—often yellow or red—represent comparisons of RNFL thicknesses against the normative database.⁶² Similar to the heat map, clinicians should inspect the deviation map for statistically significant thickness reductions relative to the normative database and their morphologies.⁶³ Additionally, B-scans can be leveraged to inspect for the gradient of structural change described above. Similarly, inspection of the retinal layers allows differential diagnosis of glaucoma from other retinal diseases.

One notable disadvantage of OCT quantitative parameters is the measurement floor effect.⁶⁴ This value represents the lower limit at which measurements are reliable or significant. This value varies across devices and different locations. Once the measurement floor is reached, OCT information at that location is likely no longer clinically useful.⁶⁵ While OCT may see more prevalent use in earlier stages of glaucoma, such as pre-perimetric glaucoma, advanced cases often require functional testing for progression analysis.

The TSNIT curve is often reported by OCT devices and represents an unfurled scan area at a fixed distance from the optic nerve head. This provides both qualitative and quantitative information

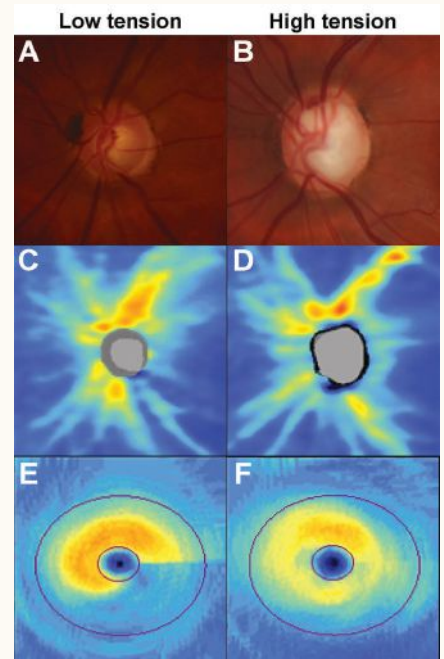


Fig. 8. Examples showing the patterns of loss in low- and high-tension glaucoma phenotypes. (A) Inferior neuroretinal rim thinning in a patient with pre-treatment intraocular pressures of 15mm Hg. (B) Neuroretinal rim thinning affecting the superotemporal, temporal and inferotemporal sectors in a patient with pre-treatment intraocular pressures of 47mm Hg. (C) OCT RNFL heat map shows deep but focal inferior loss in the low-tension phenotype. (D) OCT RNFL heat map shows diffuse but shallower loss in the high-tension phenotype. (E) Deep inferior arcuate loss in the OCT ganglion cell analysis heat map in the low-tension phenotype. (F) The heat map shows generalized but shallower loss is observed in the high-tension phenotype.

on a cross section of the RNFL layer thickness and at once allows visualization of localized structural loss. These are often usefully accompanied by bands of the instrument's normative limits.

Normative data. A core component of OCT analysis is the comparison of the individual patient's data against a reference normative database.⁶⁶ The parameters of the normative database differ across devices, so it is important to review this for any device in the practice. In most cases, OCT outputs use a traffic light or similar system (green indicating within the normative data range, yellow indicating borderline and red indicating outside

the reference range) to provide a quick visual indicator for the clinician.

As expected, the validity of the comparisons is dependent on the parameters of the normative database.⁶⁷ Variables such as age, sex, ethnicity/geographic region, refractive error and axial length (among others) are known to affect the measured structural values.⁶⁸ It is also arguable that the composition of normative database comprises of an unusually healthy cross section of the general community. Therefore, clinicians are encouraged to interpret the traffic signals with caution and to instead inspect for trends within the individual's results.

Takeaways

A glaucoma diagnosis draws upon several components of the optometric examination, ranging from slit lamp examination to interpretation of OCT findings. While no parameter can be used in isolation, they offer unique contributions to assist clinical decision-making related to both the diagnosis and treatment of glaucoma. ■

The authors would like to thank Nicola Lee for her assistance in identifying some of the clinical images included in this article.

- Stein JD, Khawaja AP, Weizer JS. Glaucoma in adults-screening, diagnosis and management: a review. *JAMA*. 2021;325(2):164-74.
- Varma DK, Simpson SM, Rai AS, Ahmed IJK. Undetected angle closure in patients with a diagnosis of open-angle glaucoma. *Can J Ophthalmol*. 2017;52(4):373-8.
- Andreatta W, Elaroud I, Nightingale P, Nessim M. Long-term outcomes after acute primary angle closure in a White Caucasian population. *BMC Ophthalmol*. 2015;15:108.
- Wright C, Tawfik MA, Waisbourd M, Katz LJ. Primary angle-closure glaucoma: an update. *Acta Ophthalmol*. 2016;94(3):217-25.
- Zhang N, Wang J, Chen B, et al. Prevalence of primary angle closure glaucoma in the last 20 years: a meta-analysis and systematic review. *Front Med (Lausanne)*. 2020;7:624179.
- Huang EC, Barocas VH. Active iris mechanics and pupillary block: steady-state analysis and comparison with anatomical risk factors. *Ann Biomed Eng*. 2004;32(9):1276-85.
- Parivadhini A, Lingam V. Management of secondary angle closure glaucoma. *J Curr Glaucoma Pract*. 2014;8(1):25-32.
- Ang LP, Aung T, Chua WH, et al. Visual field loss from primary angle-closure glaucoma: a comparative study of symptomatic and asymptomatic disease. *Ophthalmology*. 2004;111(9):1636-40.
- Bruno CA, Alward WL. Gonioscopy in primary angle closure glaucoma. *Semin Ophthalmol*. 2002;17(2):59-68.
- Rao HL, Mungale SC, Kumbhar T, et al. Evaluation of blotchy pigments in the anterior chamber angle as a sign of angle closure. *Indian J Ophthalmol*. 2012;60(6):535-9.
- Lee JY, Kim YY, Jung HR. Distribution and characteristics of peripheral anterior synechiae in primary angle-closure glaucoma. *Korean J Ophthalmol*. 2006;20(2):104-8.
- Gadia R, Sihota R, Dada T, Gupta V. Current profile of secondary glaucomas. *Indian J Ophthalmol*. 2008;56(4):285-9.
- Campbell DG. Pigmentary dispersion and glaucoma. A new theory. *Arch Ophthalmol*. 1979;97(9):1667-72.
- Roberts DK, Ho LA, Beedle NL, et al. Heritage characteristics reported by a group of African-Americans who exhibit the pigment dispersion syndrome: a case-control study. *Documenta Ophthalmologica*. 2000;101(3):179-93.
- Qing G, Wang N, Tang X, et al. Clinical characteristics of pigment dispersion syndrome in Chinese patients. *Eye (Lond)*. 2009;23(8):1641-6.
- Moroi SE, Lark KK, Sieving PA, et al. Long anterior zonules and pigment dispersion. *Am J Ophthalmol*. 2003;136(6):1176-8.
- Scheie HG, Cameron JD. Pigment dispersion syndrome: a clinical study. *Br J Ophthalmol*. 1981;65(4):264-9.
- Okafor K, Vinod K, Gedde SJ. Update on pigment dispersion syndrome and pigmentary glaucoma. *Curr Opin Ophthalmol*. 2017;28(2):154-60.
- Richter CU, Richardson TM, Grant WM. Pigmentary dispersion syndrome and pigmentary glaucoma. A prospective study of the natural history. *Arch Ophthalmol*. 1986;104(2):211-5.
- Migliazzo CV, Shaffer RN, Nykin R, Magee S. Long-term analysis of pigmentary dispersion syndrome and pigmentary glaucoma. *Ophthalmology*. 1986;93(12):1528-36.
- Naumann GO, Schlötzer-Schrehardt U, Kühle M. Pseudoexfoliation syndrome for the comprehensive ophthalmologist. Intraocular and systemic manifestations. *Ophthalmology*. 1998;105(6):951-68.
- Rao A, Padhy D. Pattern of pseudoexfoliation deposits on the lens and their clinical correlation-clinical study and review of literature. *PLoS One*. 2014;9(12):e113329.
- Rasmussen CA, Kaufman PL. The trabecular meshwork in normal eyes and in exfoliation glaucoma. *J Glaucoma*. 2014;23(8 Suppl 1):S15-9.
- Schlötzer-Schrehardt U, Naumann GO. A histopathologic study of zonular instability in pseudoexfoliation syndrome. *Am J Ophthalmol*. 1994;118(6):730-43.
- Sangal N, Chen TC. Cataract surgery in pseudoexfoliation syndrome. *Semin Ophthalmol*. 2014;29(5-6):403-8.
- Razeghinejad R, Lin MM, Lee D, Katz LJ, Myers JS. Pathophysiology and management of glaucoma and ocular hypertension related to trauma. *Surv Ophthalmol*. 2020;65(5):530-47.
- Tumbocon JA, Latina MA. Angle recession glaucoma. *Int Ophthalmol Clin*. 2002;42(3):69-78.
- Blanton FM. Anterior chamber angle recession and secondary glaucoma: a study of the aftereffects of traumatic hyphemas. *Arch Ophthalmol*. 1964;72:39-43.
- Canavan YM, Archer DB. Anterior segment consequences of blunt ocular injury. *Br J Ophthalmol*. 1982;66(9):549-55.
- Penn JS, Madan A, Caldwell RB, et al. Vascular endothelial growth factor in eye disease. *Prog Retin Eye Res*. 2008;27(4):331-71.
- Rodrigues GB, Abe RY, Zangalli C, et al. Neovascular glaucoma: a review. *Int J Retina Vitreous*. 2016;2:26.
- Siddique SS, Suelves AM, Baheti U, Foster CS. Glaucoma and uveitis. *Surv Ophthalmol*. 2013;58(1):1-10.
- Mitchell P, Cumming RG, Mackey DA. Inhaled corticosteroids, family history and risk of glaucoma. *Ophthalmology*. 1999;106(12):2301-6.
- Jonas JB, Budde WM. Diagnosis and pathogenesis of glaucomatous optic neuropathy: morphological aspects. *Prog Retin Eye Res*. 2000;19(1):1-40.
- Damms T, Dannheim F. Sensitivity and specificity of optic disc parameters in chronic glaucoma. *Invest Ophthalmol Vis Sci*. 1993;34(7):2246-50.
- Gundersen KG, Heijl A, Bengtsson B. Sensitivity and specificity of structural optic disc parameters in chronic glaucoma. *Acta Ophthalmol Scand*. 1996;74(2):120-5.
- Sotelo-Monge KG, Espinosa-Barberi G, Pinilla Cortés LM, et al. Compressive optic neuropathy. Not everything that progresses is glaucoma. *Arch Soc Esp Ophthalmol (Engl Ed)*. 2021;96(4):219-23.
- Yamamoto T. Superior segmental optic hypoplasia as a differential diagnosis of glaucoma. *Taiwan J Ophthalmol*. 2019;9(2):63-6.
- Jonas JB, Fernández MC, Stürmer J. Pattern of glaucomatous neuroretinal rim loss. *Ophthalmology*. 1993;100(1):63-8.
- Yang J, Qu Y, Zhao J, et al. Stereoscopic vs. monoscopic photographs on optic disc evaluation and glaucoma diagnosis among general ophthalmologists: a cloud-based real-world multicenter study. *Front Med (Lausanne)*. 2022;9:990611.
- Nakano E, Hata M, Oishi A, et al. Quantitative comparison of disc rim color in optic nerve atrophy of compressive optic neuropathy and glaucomatous optic neuropathy. *Graefes Arch Clin Exp Ophthalmol*. 2016;254(8):1609-16.
- Kim YW, Yun YI, Choi HJ. Screening fundus photography predicts and reveals risk factors for glaucoma conversion in eyes with large optic disc cupping. *Sci Rep*. 2023;13(1):81.
- Sutton GE, Motolko MA, Phelps CD. Baring of a circumlinear vessel in glaucoma. *Arch Ophthalmol*. 1983;101(5):739-44.
- Garway-Heath DF, Ruben ST, Viswanathan A, Hitchings RA. Vertical cup-disc ratio in relation to optic disc size: its value in the assessment of the glaucoma suspect. *Br J Ophthalmol*. 1998;82(10):1118-24.
- Thonginnetra O, Greenstein VC, Chu D, et al. Normal vs. high tension glaucoma: a comparison of functional and structural defects. *J Glaucoma*. 2010;19(3):151-7.
- Rafia D, Khuu SK, Kashyap S, et al. Visualizing structural and functional characteristics distinguishing between newly diagnosed high-tension and low-tension glaucoma patients. *Ophthalmic Physiol Opt*. 2023;43(4):771-87.
- Akagi T, Hangai M, Takayama K, et al. In vivo imaging of lamina cribrosa pores by adaptive optics scanning laser ophthalmoscopy. *Invest Ophthalmol Vis Sci*. 2012;53(7):4111-9.
- Downs JC, Girkin CA. Lamina cribrosa in glaucoma. *Curr Opin Ophthalmol*. 2017;28(2):113-9.
- Strickland RG, Garner MA, Gross AK, Girkin CA. Remodeling of the lamina cribrosa: mechanisms and potential therapeutic approaches for glaucoma. *Int J Mol Sci*. 2022;23(15):8068.
- Jonas JB, Schiro D. Localized wedge-shaped defects of the retinal nerve fiber layer in glaucoma. *Br J Ophthalmol*. 1994;78(4):285-90.
- Shin JW, Uhm KB, Seong M, Kim YJ. Diffuse retinal nerve fiber layer defects identification and quantification in thickness maps. *Invest Ophthalmol Vis Sci*. 2014;55(5):3208-18.
- Odstroliik J, Kolar R, Tomow R-P, et al. Thickness-related textural properties of retinal nerve fiber layer in color fundus images. *Comput Med Imaging Graph*. 2014;38(6):508-16.
- Drance SM. Disc hemorrhages in the glaucomas. *Surv Ophthalmol*. 1989;33(5):331-7.
- Sieger SW, Netland PA. Optic disc hemorrhages and progression of glaucoma. *Ophthalmology*. 1996;103(7):1014-24.
- Budenz DL, Anderson DR, Feuer WJ, et al. Detection and prognostic significance of optic disc hemorrhages during the Ocular Hypertension Treatment Study. *Ophthalmology*. 2006;113(12):2137-43.
- Jonas JB. Clinical implications of peripapillary atrophy in glaucoma. *Curr Opin Ophthalmol*. 2005;16(2):84-8.
- Liu W, Gong L, Li Y, et al. Peripapillary Atrophy in High Myopia. *Curr Eye Res*. 2017;42(9):1308-12.
- Rensch F, Jonas JB. Direct microperimetry of alpha zone and beta zone parapapillary atrophy. *Br J Ophthalmol*. 2008;92(12):1617-9.
- Zhang Q, Wang YX, Wei WB, et al. Parapapillary beta zone and gamma zone in a healthy population: The Beijing Eye Study 2011. *Invest Ophthalmol Vis Sci*. 2018;59(8):3320-9.
- Ahmad SS, Tanveer Y, Siddique M, Saleem Z. Controversies in the association of parapapillary atrophy with glaucoma. *Taiwan J Ophthalmol*. 2020;10(4):243-9.
- Ly A, Phu J, Katalinic P, Kalloniatis M. An evidence-based approach to the routine use of optical coherence tomography. *Clin Exp Optom*. 2019;102(3):242-59.
- Lee WJ, Oh S, Kim YK, et al. Comparison of glaucoma-diagnostic ability between wide-field swept-source OCT retinal nerve fiber layer maps and spectral-domain OCT. *Eye (Lond)*. 2018;32(9):1483-92.
- Jeoung JW, Park KH, Kim TW, Khwarg SI, Kim DM. Diagnostic ability of optical coherence tomography with a normative database to detect localized retinal nerve fiber layer defects. *Ophthalmology*. 2005;112(12):2157-63.
- Bowd C, Zangwill LM, Weinreb RN, et al. Estimating optical coherence tomography structural measurement floors to improve detection of progression in advanced glaucoma. *Am J Ophthalmol*. 2017;175:37-44.
- Moghimi S, Bowd C, Zangwill LM, et al. Measurement floors and dynamic ranges of act and oct angiography in glaucoma. *Ophthalmology*. 2019;126(7):980-8.
- Realini T, Zangwill LM, Flanagan JG, et al. Normative databases for imaging instrumentation. *J Glaucoma*. 2015;24(6):480-3.
- Nakayama LF, Zago Ribeiro L, de Oliveira JA, et al. Fairness and generalizability of OCT normative databases: a comparative analysis. *Int J Retina Vitreous*. 2023;9(1):48.
- Mehta N, Waheed NK. Diversity in optical coherence tomography normative databases: moving beyond race. *Int J Retina Vitreous*. 2020;6(1):5.

OPTOMETRIC STUDY CENTER QUIZ

To obtain CE credit through the Optometric Study Center, complete the test form on the following page and return it with the \$35 fee to: Jobson Healthcare Information, Attn.: CE Processing, Jobson Healthcare Information, LLC/WebMD, 283-299 Market Street, 2 Gateway Center, 4th Floor, Newark, NJ 07102. To be eligible, please return the card within three years of publication. You can also access the test form and submit your answers and payment via credit card online at revieweducationgroup.com. You must achieve a score of 70 or higher to receive credit. Allow four weeks for processing. For each Optometric Study Center course you pass, you earn two hours of credit. Please check with your state licensing board to see if this approval counts toward your CE requirement for relicensure.

- Which of the following anterior segment signs is most likely suggestive of acute angle closure?
 - Highly mobile pupil.
 - Iris transillumination defects.
 - Corneal edema.
 - Conjunctival blanching.
- Which of the following pathophysiological processes best describes neovascularization as a cause of secondary angle closure glaucoma?
 - Corneal neovascular invasion.
 - Iridocorneal adhesions through new blood vessel growth.
 - Hyphema.
 - Iris ischemia.
- What is the main advantage of tilting the gonioscopes (or off-axis viewing) when performing gonioscopy?
 - Distinguishes between pseudo and true iridotrabecular contact.
 - Distinguishes between anterior and posterior trabecular meshwork.
 - Breaks synechial angle closure.
 - Patient comfort.
- Clinical trials commonly deem what level of synechial formation as significant?
 - 10° (one-third clock hour).
 - 30° (one clock hour).
 - 90° (three clock hours).
 - 180° (six clock hours).
- Which of the following signs is not considered to be in the classic triad of pigment dispersion syndrome?
 - Vertical pigmentation on the corneal endothelium (Kruckenberg spindle).
 - Mid-peripheral iris transillumination defects.
 - Homogenous pigmentation on the trabecular meshwork.
 - Raised IOP.
- What anterior segment imaging sign is most likely present in pigment dispersion syndrome?
 - Angle closure (iridotrabecular contact).
 - Anteriorly bowed peripheral iris.
 - Posteriorly bowed peripheral iris.
 - Iridolenticular contact at the pupillary margin.
- What phase of pigment dispersion syndrome is suggested by the "pigment reversal sign"?
 - Active ocular hypertension.
 - Active pigmentary glaucoma.
 - Burn out phase.
 - None. No correlation with pigment dispersion syndrome phases.
- Which of the following is NOT a typical clinically appreciable site in the eye for deposition of extracellular fibril material in pseudoexfoliation syndrome?
 - Corneal endothelium.
 - Pupillary margin.
 - Anterior lens capsule.
 - Optic disc.
- Unilateral peripupillary iris transillumination defects is most suggestive of which of the following conditions predisposing to glaucoma?
 - Pseudoexfoliation syndrome.
 - Pigment dispersion syndrome.
 - Long anterior zonule phenotype.
 - Narrow angles.
- Which of the following factors in the post-injury period is most relevant for predicting the risk of angle closure following blunt trauma causing angle recession?
 - Hypotony following injury.
 - Iridodialysis.
 - Anterior chamber cells/flare.
 - Hyphaema.
- Which of the following factors is targeted by therapeutic intervention for treatment of ocular neovascularization?
 - VEGF.
 - IGF.
 - PDGF.
 - FGF.
- The presence of inflammatory cells within the trabecular meshwork leading to impaired outflow facility best describes which secondary cause of glaucoma?
 - Pseudoexfoliation syndrome.
 - Pigment dispersion syndrome.
 - Uveitis.
 - Neovascularization.
- Which of the following topical pharmacologic agents, used long-term, is most likely to lead to iatrogenic raised IOP and thus an increased risk of glaucoma?
 - Prednisolone acetate.
 - Ciprofloxacin.
 - Latanoprost.
 - Timolol.
- Which of the following is most pathognomonic for glaucomatous optic nerve head changes?
 - Disc hemorrhage.
 - Visibility of the lamina cribrosa.
 - Cup-to-disc ratio >0.7.
 - Neuroretinal rim notching.
- Which of the following optic disc changes most likely suggests a diagnosis other than glaucoma?
 - Neuroretinal rim thinning.
 - Cup widening and deepening.
 - Disc rim pallor.
 - Increased visibility of the lamina cribrosa.
- Which of the following best describes RNFL changes occurring in glaucoma?
 - They abut the neuroretinal rim.
 - They have a sharp transition from normality to abnormality.
 - They first appear nasally, before moving temporally.
 - They are independent of neuroretinal rim changes.
- Which of the following is considered a "soft sign" of glaucoma and may also appear in otherwise healthy eyes?
 - Disc hemorrhage.
 - Bayonetting of the blood vessel.
 - RNFL defect.
 - Peripapillary atrophy.
- In general, which of the following best describes what is shown by an OCT "deviation map"?
 - Quantitative thickness values of the retina.
 - Qualitative thickness values of the retina.
 - Comparisons with the underlying normative database.
 - Comparisons with the patient's own historical data.
- Which statement most correctly describes what is meant by "red" on a normative comparison when using OCT?
 - The result is within the normative range.
 - The result is borderline in normality.
 - The result is outside the normative range.
 - The result is pathological.
- Which of the following colors best indicates a retinal thickness value that is thicker than the normative range (such as in disc edema) when performing normative comparisons?
 - White.
 - Red.
 - Yellow.
 - Green.

Examination Answer Sheet

The Physical Manifestations of Glaucoma and What They Signify
Valid for credit through January 15, 2027

Online: This exam can be taken online at revieweducationgroup.com. Upon passing the exam, you can view your results immediately and download a real-time CE certificate. You can also view your test history at any time from the website.

Directions: Select one answer for each question in the exam and completely darken the appropriate circle. A minimum score of 70% is required to earn credit.

Mail to: Jobson Healthcare Information, LLC/WebMD, 283-299 Market Street, 2 Gateway Center, 4th Floor, Newark, NJ 07102.

Payment: Remit \$35 with this exam. Make check payable to Jobson Healthcare Information, LLC.

Credit: This course is COPE-approved for two hours of CE credit. Course ID 89016-GL.

Processing: There is a four-week processing time for this exam.

Jointly provided by PIM and the Review Education Group.

Answers to CE exam:

1. (A) (B) (C) (D)
2. (A) (B) (C) (D)
3. (A) (B) (C) (D)
4. (A) (B) (C) (D)
5. (A) (B) (C) (D)
6. (A) (B) (C) (D)
7. (A) (B) (C) (D)
8. (A) (B) (C) (D)
9. (A) (B) (C) (D)
10. (A) (B) (C) (D)
11. (A) (B) (C) (D)
12. (A) (B) (C) (D)
13. (A) (B) (C) (D)
14. (A) (B) (C) (D)
15. (A) (B) (C) (D)
16. (A) (B) (C) (D)
17. (A) (B) (C) (D)
18. (A) (B) (C) (D)
19. (A) (B) (C) (D)
20. (A) (B) (C) (D)

Post-activity evaluation questions:

Rate how well the activity supported your achievement of these learning objectives. 1=Poor, 2=Fair, 3=Neutral, 4=Good, 5=Excellent

21. Recognize the pathophysiology of structural glaucomatous features. ① ② ③ ④ ⑤
22. Identify the physical manifestations of glaucoma. ① ② ③ ④ ⑤
23. Perform an ocular exam in a glaucoma patient or suspect. ① ② ③ ④ ⑤
24. Make clinical decisions related to the diagnosis and treatment of glaucoma. ① ② ③ ④ ⑤
25. Based upon your participation in this activity, do you intend to change your practice behavior? (Choose only one of the following options.)
 - (A) I do plan to implement changes in my practice based on the information presented.
 - (B) My current practice has been reinforced by the information presented.
 - (C) I need more information before I will change my practice.
26. Thinking about how your participation in this activity will influence your patient care, how many of your patients are likely to benefit? (please use a number):
27. If you plan to change your practice behavior, what type of changes do you plan to implement? (Check all that apply.)

| | | |
|-----------------------------------|---|---|
| (A) Apply latest guidelines | (D) Change in current practice for referral | (G) More active monitoring and counseling |
| (B) Change in diagnostic methods | (E) Change in vision correction offerings | (H) Other, please specify: _____ |
| (C) Choice of management approach | (F) Change in differential diagnosis | _____ |
28. How confident are you that you will be able to make your intended changes?
 - (A) Very confident
 - (B) Somewhat confident
 - (C) Unsure
 - (D) Not confident
29. Which of the following do you anticipate will be the primary barrier to implementing these changes?

| | | |
|----------------------------|--|----------------------------------|
| (A) Formulary restrictions | (D) Insurance/financial issues | (G) Patient adherence/compliance |
| (B) Time constraints | (E) Lack of interprofessional team support | (H) Other, please specify: _____ |
| (C) System constraints | (F) Treatment related adverse events | _____ |
30. Additional comments on this course: _____

Please retain a copy for your records. Please print clearly.

First Name

Last Name

E-Mail

The following is your: Home Address Business Address

Business Name

Address

City State

ZIP

Telephone # - -

Fax # - -

OE Tracker Number

Rate the quality of the material provided:
1=Strongly disagree, 2=Somewhat disagree, 3=Neutral, 4=Somewhat agree, 5=Strongly agree

31. The content was evidence-based. ① ② ③ ④ ⑤

32. The content was balanced and free of bias. ① ② ③ ④ ⑤

33. The presentation was clear and effective. ① ② ③ ④ ⑤

By submitting this answer sheet, I certify that I have read the lesson in its entirety and completed the self-assessment exam personally based on the material presented. I have not obtained the answers to this exam by any fraudulent or improper means.

Signature _____ Date _____ Lesson 124578 RO-OSC-0124

SECO2024
THE EDUCATION DESTINATION™
FEBRUARY 28 – MARCH 3, 2024

TITLE PARTNER

BAUSCH+LOMB



**SURGICAL & AESTHETICS
SKILLS EDUCATION
PAVILION**



Developed in partnership with the American Society of Optometric Surgeons, this dedicated pavilion Optometry's Marketplace Exhibit Hall will feature a variety of presentations designed to familiarize or update attendees with a variety of surgical and advanced procedures.

LASER PROCEDURES

ANESTHESIA

**LATERAL CANTHOTOMY
AND CANTHOLYSIS**

CRYOSURGERY

SUTURING

BOTOX®

Visit SECO's Surgical and Aesthetics Skills Education Pavilion in Optometry's Marketplace™ Exhibit Hall to learn how these procedures could be incorporated into your practice. Feature areas, hands-on interaction and educational presentations will include topics such as laser procedures, cryosurgery, Botox®, anesthesia, Suturing, and Lateral Canthotomy and Cantholysis. Hear from industry experts how expanded scopes of practice may include these new opportunities to benefit patients through greater access to care.

REGISTER TODAY

attendseco.com





The Giant in Your Chair

We are our patients' biggest advocates when it comes to this ophthalmic emergency.

An 82-year-old woman presented to her local ophthalmologist for sudden and profound loss of vision in her right eye upon awakening. The doctor diagnosed right optic nerve edema, prescribed prednisone 60mg daily and referred the patient to a neuro-ophthalmologist. Unfortunately, the patient became symptomatic for vision loss in her left eye the very next day and sought care at our ophthalmic emergency department three days later.

Upon presentation, her vision was light perception with a dense RAPD in the right eye and 20/60 in the left eye. Extraocular motilities, intraocular pressures and external slit-lamp examination were all unremarkable. The dilated exam revealed optic nerve pallor OD>OS with disc edema OS>OD and fine peripapillary hemorrhages bilaterally (Figure 1).

The clinical vignette of an elderly woman with bilateral pallid nerve

edema in the setting of profound vision loss aroused suspicion for giant cell arteritis (GCA). A problem-focused review of systems was completed and revealed that the patient had been experiencing mild right brow and temporal headaches. She also endorsed 14 pounds of unintentional weight loss due to reduced appetite over the last six months, generalized fatigue and jaw claudication. Interestingly, four months prior to vision loss, she had been experiencing hand and hip girdle pain and was diagnosed with arthritis by her primary care provider; her symptoms abated with a course of oral steroids.

Laboratory studies and ophthalmic imaging were completed during her emergency department visit (Figures 2 and 3). The erythrocyte sedimentation rate (ESR) was 21mm/hour, C-reactive protein (CRP) was 0.4mg/dL, and a complete blood count revealed thrombocytosis (platelets 414x103/ μ L) and

neutrophilia. We suspected that her inflammatory markers could have been normalized by three days of oral corticosteroid use prior to presentation, and despite "normal" ESR and CRP values, an urgent temporal artery biopsy (TAB) was scheduled. Three days of intravenous (IV) corticosteroids were initiated.

Two days after her initial presentation, the TAB was completed and revealed transmural foci of granulomatous inflammation of the temporal artery, consistent with GCA. After receiving three days of IV corticosteroids, she was transitioned to 80mg prednisone. Although visual acuity did not significantly recover, the patient reported subjective improvement of vision OS. She was referred to a rheumatologist for continued management of GCA and continues follow-up care with our neuro-ophthalmology team.

Clinical Presentation

Due to its potential to cause permanent vision loss within days, GCA is a true ophthalmic emergency. Rather than an ophthalmic condition, it is a systemic autoimmune condition caused by inflammation within the walls of medium and large arteries.¹ It almost exclusively affects individuals aged 50 and older.

The most common symptom of GCA is headache, usually temporal or occipital and acute or subacute in onset. Others include lethargy, weight or appetite loss, fever, stroke symptoms, pain and stiffness in the hip girdle and shoulders and jaw claudication. Ask patients about each symptom specifically; most people would not associate unintentional weight loss or hip pain to an ophthalmic condition.

The most widely recognized ophthalmic manifestation of GCA is vision loss (amaurosis fugax or permanent) due to anterior ischemic optic neuropathy

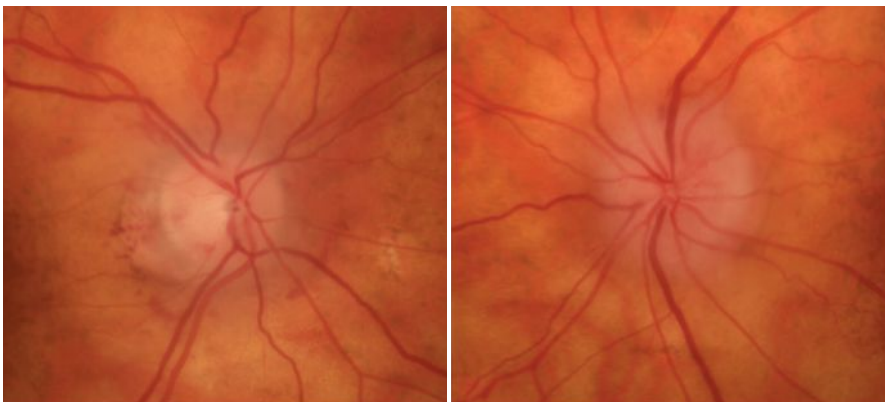


Fig. 1. Right (left) and left (right) optic nerves. The right nerve was pallid with resolving edema, and the left nerve was slightly pallid with significant edema. These clinical pictures support the time frame of the patient's vision loss.

About Dr. Bozung

Dr. Bozung currently practices at Bascom Palmer where she primarily sees patients in the hospital's 24/7 ophthalmic emergency department. She also serves as the optometry residency program coordinator. Dr. Bozung is a fellow of the American Academy of Optometry and a member of the Florida and American Optometric Associations. She is a founding board member of Young OD Connect and serves on the editorial board for *Review of Optometry*. She has no financial interests to disclose.

(AION). This is termed arteritic AION (A-AION) to differentiate it from non-arteritic AION (NA-AION), a much more common condition seen classically in patients with cardiovascular risk factors. A-AION presents with chalky white disc edema and profound vision loss in one or both eyes. There may or may not be disc hemorrhages and cotton wool spots.

Visual field testing may be helpful in distinguishing A-AION from NA-AION, but it is not diagnostic. An inferior altitudinal defect is common in NA-AION, but it may also be the presenting field defect in A-AION. We cannot, therefore, rely on any one clinical finding such as a lack of pallor or near-normal visual acuity, as this could misplace our suspicion and cause us to miss this critical diagnosis. I have seen a patient with GCA presenting with disc edema and 20/20 vision who unfortunately progressed to permanent and severe vision loss despite timely treatment.

Other neuro-ophthalmic symptoms of GCA include diplopia and scintillating scotoma. Consider this diagnosis in patients with new cranial neuropathies or visual aura-like symptoms, particularly if their review of systems is suggestive.² Lesser-known ophthalmic manifestations are those secondary to severe ocular ischemia, some of which include corneal edema, retinal artery occlusions, dilated pupils, peripheral retinal hemorrhages and Amalric choroidal infarcts.³⁻⁶ Posterior ischemic optic neuropathy can also be a diagnostically challenging feature of the disease, presenting with severe vision loss and a normal-appearing fundus exam.⁷

Workup for Suspected GCA

The recommended basic lab studies are ESR, CRP and complete blood count with differential. While there is no strict cutoff value for these tests, higher ESR and CRP values (especially simultaneously) increase the suspicion of GCA. One study revealed that the odds ratio of a positive TAB was 1.5 times greater with ESR >47mm/hour, 5.3 times greater with CRP >2.45mg/

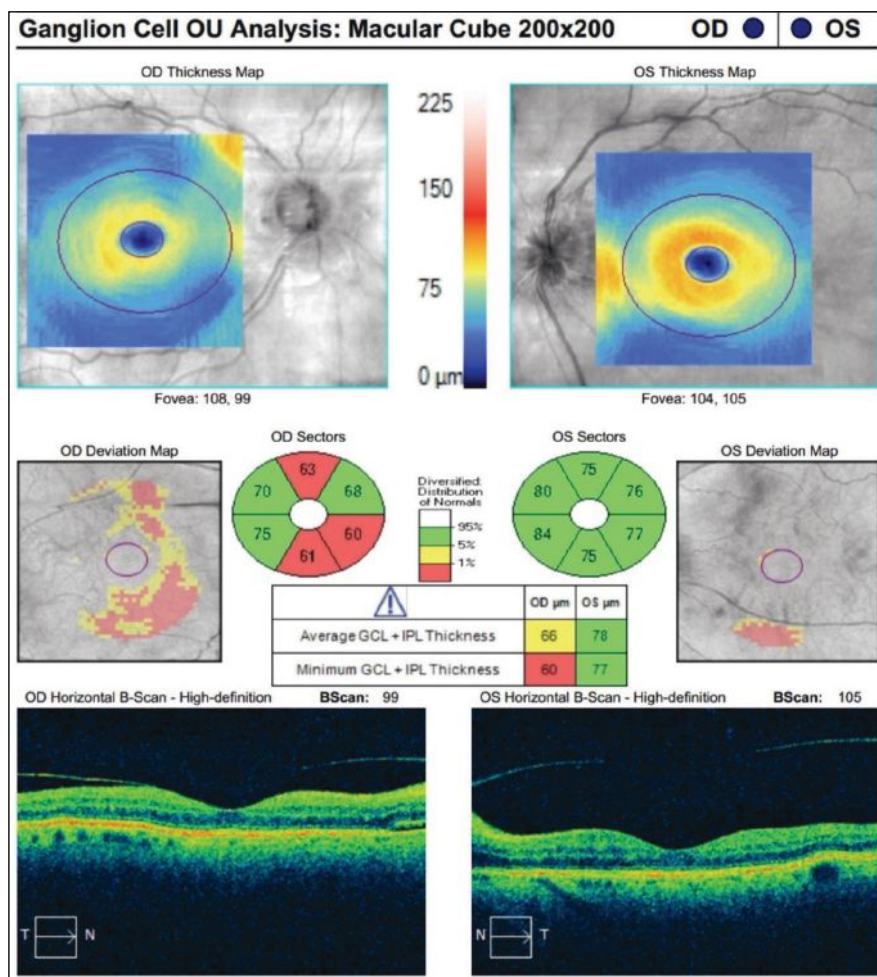


Fig. 2. The patient's OCT ganglion cell analysis reveals early thinning in the right eye but a normal study in the left.

dL and 4.2 times greater with platelet counts >400x103/ μL .^{8,9} Normal values do not rule out a GCA diagnosis, but they do make it less likely.¹⁰

The American College of Rheumatologists set the following criteria for GCA diagnosis (at least three must be met):

1. age ≥ 50 years at onset,
2. new onset of localized headache,
3. tenderness of temporal artery or decreased temporal artery pulsation,
4. elevated ESR and
5. positive TAB

These guidelines have a sensitivity of 93.5% and a specificity of 91.2%.¹¹ In the United States, a TAB is usually completed by oculoplastics and vascular surgeons and less often by general and plastic surgeons.¹² It is generally

performed ipsilateral to the affected eye. There is emerging evidence that non-invasive duplex sonography of the temporal arteries or high-resolution MRI can be useful in diagnosis.¹³ A TAB, if performed, should be completed within one to two weeks of initiating corticosteroids, as waiting too long can result in a false negative.^{14,15} In one study, the rate of positive test results fell from about 90% to 50% after only five or more days of corticosteroid use.¹⁶

If you don't have a laboratory on-site, send the patient to the emergency department for proper workup and treatment. Convey the suspected diagnosis and necessary labs to the receiving physician either via printed letter or phone call, but preferably both. It may also be helpful to provide your telephone number to facilitate the patient's

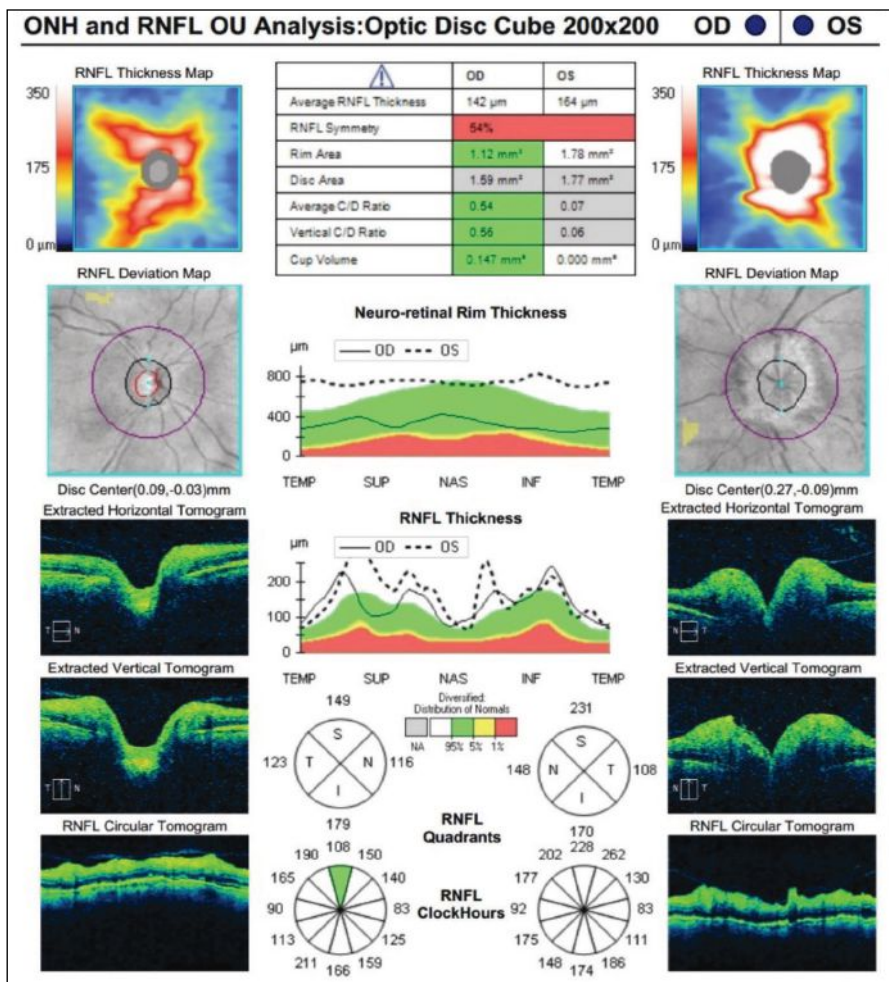


Fig. 3. OCT RNFL revealed thickening circumferentially, greater in the left eye than in the right.

care and field any questions that may arise. Remember that since the clinical vignette of GCA may mimic that of a stroke (*i.e.*, acute monocular or binocular vision loss, diplopia, amaurosis fugax), the emergency department provider may choose to also perform a stroke assessment.

Treatment

When GCA is suspected, time is of the essence. While a biopsy-proven diagnosis is the gold standard, we cannot afford to await the results. Positive lab testing combined with clinical suspicion is enough to initiate treatment. Recall that GCA is an autoimmune inflammatory disorder, so the treatment is immunosuppressive (high-dose corticosteroids). Patients with visual symptoms are generally treated with

500mg to 1,000mg IV methylprednisolone for three days followed by oral corticosteroids, usually starting with 60mg to 80mg prednisone daily with a protracted taper over two to three years. Some clinicians also advocate for low-dose aspirin use (100mg daily).¹⁷

Another therapeutic option is tocilizumab (Actemra, Genentech), an IL-6 receptor antagonist that is FDA-approved as a once-weekly subcutaneous injection to treat GCA, particularly when reduction of dependence on corticosteroids is desired. These patients should be comanaged with rheumatology, as well as neuro-ophthalmology, if possible.

A relapse of disease occurs in roughly 50% of GCA cases, so monitoring for this potential and educating patients about it is critical.

When patients present with any of the signs or symptoms discussed, it is important that we maintain GCA on our differential diagnosis list, ask appropriate follow-up questions and refer emergently for further testing and treatment. We have the potential to save patients' vision with this diagnosis. ■

- Smith JH, Swanson JW. Giant cell arteritis. *Headache*. 2014;54(8):1273-89.
- Caselli RJ, Hunder GG, Whisnant JP. Neurologic disease in biopsy-proven giant cell (temporal) arteritis. *Neurology*. 1988;38(3):352-9.
- Tran AQ, Yannuzzi NA, Motulsky EH, et al. Swept-source optical coherence tomography angiography of an Amalric choroidal infarction in a rare presentation of giant cell arteritis with bilateral corneal edema. *Ophthalmic Surg Lasers Imaging Retina*. 2018;49(10):e157-60.
- Pellegrini F, Prosdocimo G, Bonsanto D, Machin P, Foro-rozan R. Thick corneas, large pupils, and a giant problem. *Surv Ophthalmol*. 2018;63(4):595-9.
- Fineman MS, Savino PJ, Federman JL, Eagle RC Jr. Branch retinal artery occlusion as the initial sign of giant cell arteritis. *Am J Ophthalmol*. 1996;122(3):428-30.
- Williams ZR, Wang X, DiLoreto DA Jr. Central retinal artery occlusion with subsequent central retinal vein occlusion in biopsy-proven giant cell arteritis. *J Neuroophthal-mol*. 2016;36(3):290-1.
- Albarrak AM, Mohammad Y, Hussain S, Hussain S, Muayqil T. Simultaneous bilateral posterior ischemic optic neuropathy secondary to giant cell arteritis: a case presentation and review of the literature. *BMC Ophthalmol*. 2018;18(1):317.
- Walvick MD, Walvick MP. Giant cell arteritis: laboratory predictors of a positive temporal artery biopsy. *Ophthalmology*. 2011;118(6):1201-4.
- Foroozan R, Danesh-Meyer H, Savino PJ, et al. Thrombo-cytosis in patients with biopsy-proven giant cell arteritis. *Ophthalmology*. 2002;109(7):1267-71.
- Parikh M, Miller NR, Lee AG, et al. Prevalence of a normal C-reactive protein with an elevated erythrocyte sedimentation rate in biopsy-proven giant cell arteritis. *Ophthalmology*. 2006;113(10):1842-5.
- Hunder GG, Bloch DA, Michel BA, et al. The American College of Rheumatology 1990 criteria for the classification of giant cell arteritis. *Arthritis Rheum*. 1990;33(8):1122-8.
- Micieli JA, Micieli R, Margolin EA. A review of special-ities performing temporal artery biopsies in Ontario: a retrospective cohort study. *CMAJ Open*. 2015;3(3):E281-5.
- Hellmich B, Agueda A, Monti S, et al. 2018 Update of the EULAR recommendations for the management of large vessel vasculitis. *Ann Rheum Dis*. 2020;79(1):19-30.
- Maz M, Chung SA, Abril A, et al. 2021 American College of Rheumatology/Vasculitis Foundation guideline for the management of giant cell arteritis and Takayasu arteritis. *Arthritis Rheumatol*. 2021;73(8):1349-65.
- Jiang Z, Ji H, Dong J. Temporal artery biopsy for suspected giant cell arteritis: A mini review. *Indian J Ophthalmol*. 2023;71(10):3299-304.
- Hauenstein C, Reinhard M, Geiger J, et al. Effects of early corticosteroid treatment on magnetic resonance imaging and ultrasonography findings in giant cell arteritis. *Rheumatology (Oxford)*. 2012;51(11):1999-2003.
- Nesher G, Berkun Y, Mates M, et al. Low-dose aspirin and prevention of cranial ischemic complications in giant cell arteritis. *Arthritis Rheum*. 2004;50(4):1332-7.



Changing SIGHT Overnight.

Overnight Orthokeratology

1.

NCLE certified consultation experts to guide you through the entire fitting process

2.

Highly adjustable parameters with an online lens design calculator

3.

Dynamic Edge Profile™ delivers remarkable comfort

4.

Diameter & optic zone options allow the doctor to customize the lens to the patient



Scan to learn more about REMLens® and get certified today.



X-CEL
SPECIALTY CONTACTS

800.241.9312
xcelspecialtycontacts.com/remlens

Vision Shaping
Treatment VST®

MADE EXCLUSIVELY WITH
BOSTON® EQUALENS® II
LENS MATERIALS



BY BISANT A. LABIB, OD

THE ESSENTIALS

Know Your Glow

Retroillumination can offer better examination of clear structures like the cornea and lens.

Slit lamp biomicroscopy is an integral aspect of any standard ocular examination, whether routine or problem-focused. The slit lamp portion of an exam allows the clinician to evaluate anatomical structures and clinical features of pathologies that would otherwise be missed without magnification. The biomicroscope's utility comes not only from its ability to magnify, but also in its various illumination modalities. Each serves a unique viewing purpose and is based on the relationship between ocular structures and lighting techniques.

One often-underused slit lamp technique is retroillumination; mastering this technique and applying its refractive principles can help our examinations become more effective and efficient.

Clear the Way

Retroillumination is an indirect lighting technique used in slit lamp examination to assess the integrity and clarity of the cornea and crystalline lens by examining light reflected from posterior structures. Since both the cornea and lens are intrinsically clear in the absence of pathology, regular direct illumination techniques can be difficult to use for a thorough examination.

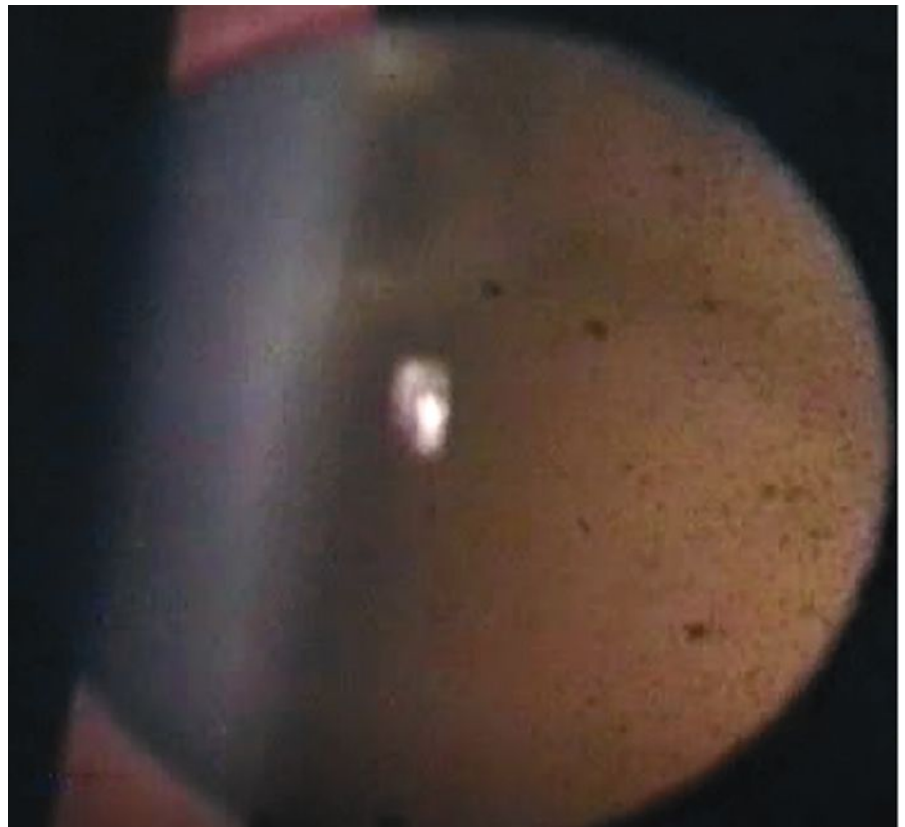
There are two main methods and procedures to achieve retroillumination:

- **Iris retroillumination.** Dim the room lights to optimize contrast for retroillumination and adjust the

slit lamp. The slit beam should be narrow, around 0.2mm, and defined. The height of the beam should be slightly longer than the pupil to allow enough light to pass through. Position the light source temporally, about 45.° To use iris retroillumination to examine an area of the cornea, the light beam should reflect off the iris while focus remains on the cornea; the reflected light from the iris will make subtle changes and opacities in the cornea more apparent.^{1,2}

- **Fundus retroillumination.** Using retroillumination from the fundus, the light beam and microscope are positioned along a similar axis and the light beam is adjusted to shine through the edge of the patient's dilated pupil. The light then passes through the pupil and into the fundus, creating a background glow. Using the red reflex or glow, opacities in all layers of the lens, as well as corneal opacities, are more easily distinguishable by the shadows they cast. If this procedure is performed through an undilated pupil, it is a way to check for iris transillumination defects.^{1,2}

The ability for retroillumination to serve as an effective examination technique is best explained through



Retroillumination using the background glow of the fundus, revealing dark opacities.

About
Dr. Labib

Dr. Labib graduated from Pennsylvania College of Optometry, where she now works as an associate professor. She completed her residency in primary care/ocular disease and is a fellow of the American Academy of Optometry and a diplomate in the Comprehensive Eye Care section. She has no financial interests to disclose.

the properties of refraction. Abnormalities within clear structures, such as the cornea and lens, are made apparent because of their interference with the emanating light as well as their refractive nature. Objects or opacities that have a higher or lower refractive index than that of their surrounding space will be distinguishable. There are two main effects that an object or opacity can elicit—acting as a diverging refractor or a converging refractor. If the abnormality embedded within the cornea or lens has a lower refractive index, it acts as a diverging lens. Conversely, that which possesses a higher refractive index than its medium would act as a converging lens.³

As a general example, the cornea possesses a high refractive index, higher than that of the aqueous. The corneal epithelial layer has a higher refractive index than the stroma. Opacities that arise within the cornea, such as blood vessels, striae and cysts, differ in refractive indices and are consequently made visible through retroillumination techniques.³

Another important principle in the visibility of pathologies using retroillumination is the projection or displacement of the abnormality. Whether the abnormality causes a displacement from the cornea and into the anterior tear film or posteriorly into the aqueous, it will enter an area of different refractive index, causing alterations in illumination. A clinical example would be bullae in the corneal epithelium.³

Prime Uses

Corneal dystrophies, such as posterior polymorphous corneal dystrophy, are best visualized using retroillumination, elucidating the classic peau d'orange that is commonly seen with this condition.⁴ The clinical use of retroillumination extends beyond optimizing an anterior segment slit lamp examination. In more recent years, it has been used in photography to enhance the identification and

progression of corneal disease. Retroillumination photography analysis has demonstrated more accuracy in the grading and classification of patients with Fuchs' endothelial corneal dystrophy.⁵

“Since both the cornea and the lens are intrinsically clear in the absence of pathology, regular direct illumination techniques can be difficult to use for a thorough examination.”

In addition to corneal opacities and irregularities, retroillumination focusing on the lens has long been established as the primary method of cataract grading. The Lens Opacities Classification System III is widely used today, consisting of five retroillumination images corresponding with various degrees of posterior subcapsular cataracts as well as five retroillumination images corresponding with various degrees of cortical cataracts. In clinical practice, the quantifiable grading of a patient's cortical and capsular cataracts are not permissible without a lens evaluation using retroillumination.^{6,7}

More recently, slit-beam associated retroillumination (SBAR) has been used in anterior segment surgery. A challenge associated with phacoemulsification is in patients with coexistent corneal opacities. To improve visibility and surgical outcomes, SBAR has demonstrated improved images and contrast through the opacified cornea, assisting in clarity during phacoemulsification by minimizing light scatter. While this technique is both cost effective and hands-free, its limitations lie in that it is dependent on flow of the red reflex, which is necessary for retroillumination.⁸

Aside from its various applications in anterior segment examinations,

retroillumination can also be paired with confocal scanning laser ophthalmoscopy to enhance posterior segment examinations. With the addition of retroillumination, these scanning laser ophthalmoscopies can provide “pseudo three-dimensional” images. This can be achieved through the use of the light's reflection from chorioretinal structures.

In another mode, these instruments are capable of using infrared radiation from the chorioretinal layers to create images. This type of image is useful in detecting abnormalities that exist deep within the chorioretinal areas, including small drusen, subretinal drusenoid deposits, subthreshold laser lesions and chorioretinal changes that would otherwise be missed using various en face imaging techniques.⁹

The current uses of retroillumination are great. It spans many categories and is still expanding with the help of combining use of other ophthalmic instruments. Besides its emerging applications, the technique should warrant consideration to use with everyday slit lamp examinations. ■

1. Kaur K, Gurnani B. Slit-lamp biomicroscope. In: StatPearls [Internet]. Treasure Island (FL): StatPearls Publishing. Updated June 11, 2023.

2. Martonyi CL, Bahn CF, Meyer RF. Clinical slit lamp biomicroscopy and photo slit lamp biomicrography. Time One Ink, Michigan. 1985.

3. Brown N. Visibility of transparent objects in the eye by retroillumination. Br J Ophthalmol. 1971;55(8):517-24.

4. Guier CP, Patel BC, Stokkermans TJ, Gulani AC. Posterior polymorphous corneal dystrophy. In: StatPearls [Internet]. Treasure Island (FL): StatPearls Publishing. August 8, 2023.

5. Eghrari AO, Garrett BS, Mumtaz AA, et al. Retroillumination photography analysis enhances clinical definition of severe Fuchs' corneal dystrophy. Cornea. 2015;34(12):1623-6.

6. Chylack LT Jr, Wolfe JK, Singer DM, et al. The Lens Opacities Classification System III. The Longitudinal Study of Cataract Study Group. Arch Ophthalmol. 1993;111(6):831-6.

7. Gali HE, Sella R, Afshari NA. Cataract grading systems: a review of past and present. Curr Opin Ophthalmol. 2019;30(1):13-8.

8. Kusumesh R, Prassan B, Ambastha A, Bhaskar G, Mohan N. Slit-beam retro-illumination assisted phacoemulsification for cataract with coexisting corneal opacity. Nepal J Ophthalmol. 2020;12(23):153-7.

9. Mainster MA, Desmetre T, Querques G, Turner PL, Ledesma-Gil G. Scanning laser ophthalmoscopy retroillumination: applications and illusions. Int J Retina Vitreous. 2022;8(1):71.



Toxic Relationship

A patient requires ongoing therapy to manage several systemic conditions. Does this make her eyesight vulnerable?

A 38-year-old African-American female presented to the eye clinic for a comprehensive eye exam with a complaint of blur while reading. During the history, she explained that she was using hydroxychloroquine 400mg daily by mouth for systemic lupus erythematosus control. Her systemic history also included hypertension and anemia, for which she was properly medicated. She reported no allergies to medicines or environmental factors.

Clinical Findings

Her best-corrected entering visual acuities were 20/20 at distance and near through +1.00/+2.25 spectacles, both eyes. External testing was normal, with no defects on confrontation fields or facial Amsler grid and no afferent pupil defect. Anterior segment evaluation was normal and Goldmann applanation tonometry measured 15mm Hg OD and 14mm Hg OS. The pertinent fundus findings are demonstrated in the photographs.

Additional Testing

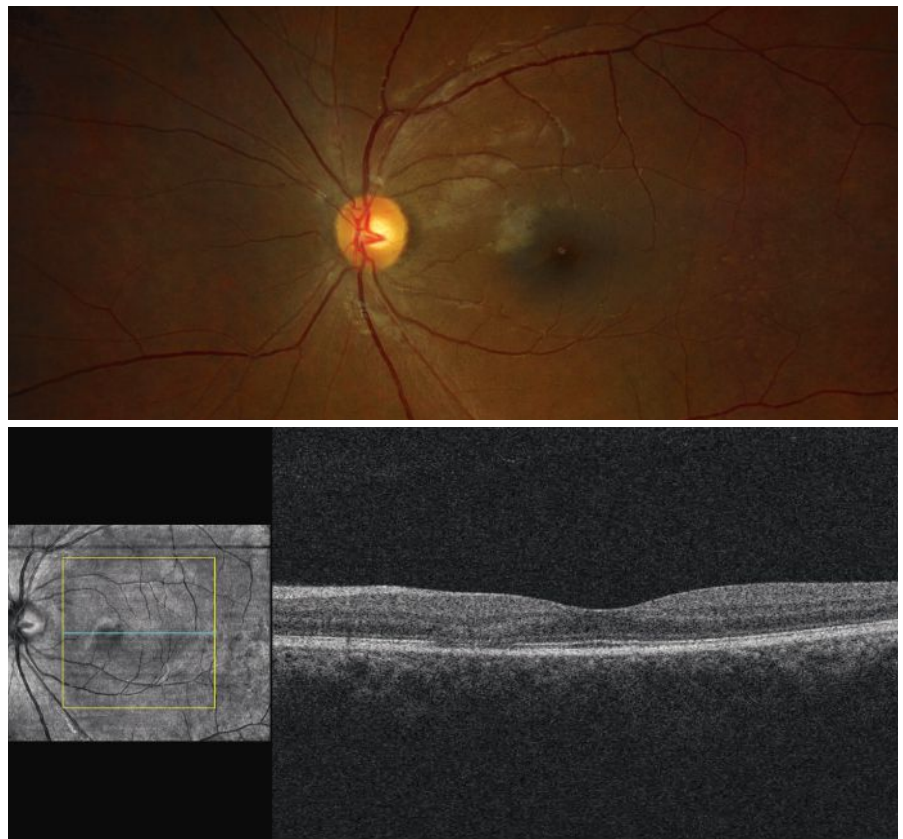
Other possible studies might include fundus autofluorescence, fundus

photodocumentation and automated (white and red sensitive) perimetry. If the acuity were reduced, laser interferometry may also be useful.

Your Diagnosis

What would be your diagnosis in this case based on the findings presented? What's the likely prognosis? Which interventions, if any, would you recommend? To find out, read the online version of this article at www.reviewofoptometry.com. ■

Dr. Gurwood thanks Karan Johal, OD, for contributing this case.



Does the appearance of the retina confirm any suspicions raised by the case history?

About Dr. Gurwood

Dr. Gurwood is a professor of clinical sciences at The Eye Institute of the Pennsylvania College of Optometry at Salus University. He is a co-chief of Primary Care Suite 3. He is attending medical staff in the department of ophthalmology at Albert Einstein Medical Center, Philadelphia. He has no financial interests to disclose.

NEXT MONTH IN THE MAG

In February, we present our annual issue devoted to diagnostic skills and techniques. Articles will include:

- Sharpen Your Slit Lamp Technique
- OCT Beyond the Basics: Unlock the Power of This Essential Tool

- Tools and Techniques for Better Peripheral Retinal Exams
- Glaucoma: Are Visual Field Headsets Ready for Prime Time?
- Optic Disc Swelling: Know These Critical Workup Steps

Also in this issue:

- A Deep Dive Into Complement System Function and Dysfunction

Merchandise Offered

FRAME DISPLAYS & OPTICAL INTERIORS

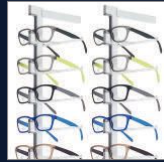FrameDisplays.com is the one-stop-shop for all your optical displays, furniture, and design needs.



Wall Mount



Counter Top



Locking Rods



Trays & Frame Bags



Custom Frame Rods



Optical Cabinets



1-877-274-9300 • www.framedisplays.com

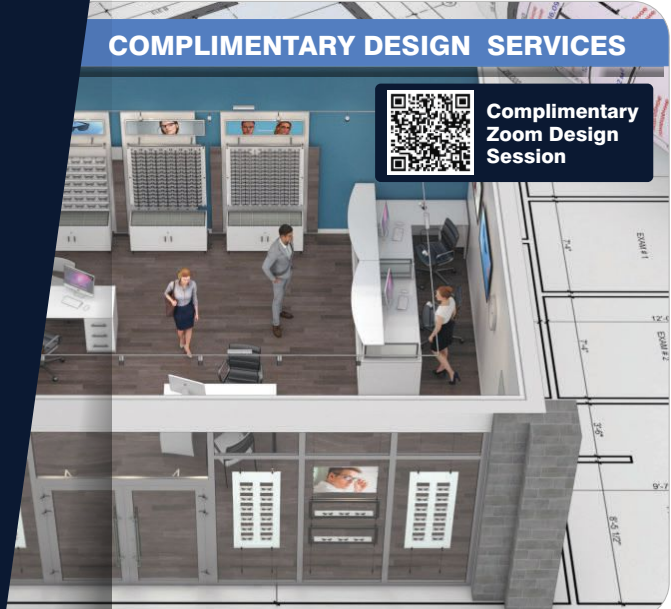

Trusted by more than 40,000 eye care professionals worldwide.

COMPLIMENTARY DESIGN SERVICES



Complimentary Zoom Design Session



0% Financing & Interest for 36 Months*

FREE SHIPPING

\$100+ Orders* *) Excludes Freight Shipments

Code: **FREESHIPROOP**

Practice For Sale



Practice Sales • Appraisals • Consulting
www.PracticeConsultants.com

PRACTICES FOR SALE NATIONWIDE

Visit us on the Web or call us to learn more about our company and the practices we have available.

info@PracticeConsultants.com
925-820-6758

www.PracticeConsultants.com

Targeting Optometrists?

CLASSIFIED ADVERTISING WORKS

- JOB OPENINGS
- CME PROGRAMS
- PRODUCTS & SERVICES
- AND MORE...

Contact us today for classified advertising:
Toll free: **888-498-1460**
E-mail: **sales@kerhgroup.com**

Do you have CE Programs?

CONTACT US TODAY FOR CLASSIFIED ADVERTISING

Toll free: 888-498-1460

E-mail: sales@kerhgroup.com

ADVERTISER INDEX

This index is published as a convenience and not as part of the advertising contract. Every care will be taken to index correctly. No allowance will be made for errors due to spelling, incorrect page number, or failure to insert.

| | |
|---------------------------------|---|
| Alcon | Cover Tip |
| | www.alcon.com |
| Apellis | Cover 2 |
| | www.apellis.com |
| Boston Sight | 11 |
| | 888-725-3725 |
| | www.bostonsightsoptical.com |
| Bruder Healthcare Company | 5 |
| | (888) 827-8337 |
| | eyes@bruder.com |
| | www.bruder.com |
| CooperVision | Cover 3 |
| | 800-341-2020 |
| | https://coopervision.com/ |
| Glaukos | 7 |
| | (800) 452-8567 |
| | www.glaukos.com |
| Notal Vision | 43 |
| | 1-855-600-3112 |
| | https://notalvision.com/ |
| Oasis Medical | 27 |
| | (844) 820-8940 |
| | (844) 820-8940 |
| | www.oasismedical.com |
| Oyster Point | 20, 21 |
| | https://oysterpointrx.com/ |
| Tarsus | 66, Cover 4 |
| | https://tarsusrx.com |
| Thea Pharma | 16-18 |
| | 781-832-3664 |
| | https://ivyze.com/ |
| Thea Pharma | 13 |
| | 781-832-3664 |
| | https://www.ivizia.com/ |
| Thea Pharma | Insert |
| | 781-832-3664 |
| | https://theapharmainc.com/preservative-free/ |
| Vital Tears | 23 |
| | https://vitaltears.org/ |
| VSP | 9 |
| | vspyecarecareers.com |
| X-Cel | 61 |
| | 800-241-9312 |
| | www.xcelspecialtycontacts.com/ |

XDEMYV™ (lotilaner ophthalmic solution) 0.25%, for topical ophthalmic use

BRIEF SUMMARY OF PRESCRIBING INFORMATION Please see the XDEMYV™ package insert for full Prescribing Information.

INDICATIONS AND USAGE

XDEMYV is indicated for the treatment of *Demodex* blepharitis.

CONTRAINDICATIONS

None.

WARNINGS AND PRECAUTIONS

Risk of Contamination Do not allow the tip of the dispensing container to contact the eye, surrounding structures, fingers, or any other surface in order to minimize contamination of the solution. Serious damage to the eye and subsequent loss of vision may result from using contaminated solutions.

Use with Contact Lenses Contact lenses should be removed prior to instillation of XDEMYV and may be reinserted 15 minutes following its administration.

ADVERSE REACTIONS

Because clinical studies are conducted under widely varying conditions, adverse reaction rates observed in the clinical trials of a drug cannot be directly compared to rates in the clinical trials of another drug and may not reflect the rates observed in practice.

XDEMYV was evaluated in 833 patients with *Demodex* blepharitis in two randomized, double-masked, vehicle-controlled studies (Saturn-1 and Saturn-2) with 42 days of treatment. The most common ocular adverse reaction observed in controlled clinical studies with XDEMYV was instillation site stinging and burning which was reported in 10% of patients. Other ocular adverse reactions reported in less than 2% of patients were chalazion/hordeolum and punctate keratitis.

USE IN SPECIFIC POPULATIONS

Pregnancy: Risk Summary There are no available data on XDEMYV use in pregnant women to inform any drug associated risk; however, systemic exposure to lotilaner from ocular administration is low. In animal reproduction studies, lotilaner did not produce malformations at clinically relevant doses.

Data Animal Data In an oral embryofetal developmental study in pregnant rats dosed during organogenesis from gestation days 6-19, increased post-implantation loss, reduced fetal pup weight, and incomplete skeletal ossification were observed at 50 mg/kg/day (approximately 1390 times the recommended human ophthalmic dose (RHOD) on a body surface area basis) in the presence of maternal toxicity (i.e., decreased body weight and food consumption). A rare malformation of situs inversus of the thoracic and abdominal viscera occurred in 1 fetus from a pregnant rat receiving 50 mg/kg/day; whether this finding was treatment-related could not be excluded. No maternal or embryofetal toxicity was observed at 18 mg/kg/day (approximately 501 times the RHOD on a body surface area basis). In an oral embryofetal development study in pregnant rabbits dosed during organogenesis from gestation days 7-19, no embryofetal toxicity or teratogenic findings were observed at 20 mg/kg/day (approximately 580-times the RHOD on an AUC basis), even in the presence of maternal toxicity (i.e., decreased food consumption and body weight).

In an oral two-generation reproductive toxicity study, F0 male and female rats were administered lotilaner at doses up to 40 mg/kg/day for 10 weeks before pairing and during the 2-week pairing period (3 weeks for males). Dosing for F0 females continued through lactation day 22. F1 male and female rats were administered lotilaner at 1 and 5 mg/kg/day post-weaning from day 23 for 10 weeks before pairing and during the 2-week pairing period (3 weeks for males). Dosing for F1 parenteral females continued through lactation day 22.

There were no clear adverse effects on the F1 generation, and a slightly lower mean body weight during lactation was noted for F2 pups at 5 mg/kg/day. The no observed adverse effect level (NOAEL) was determined to be 5 mg/kg/day

(approximately 139 times the RHOD on a body surface area basis).

Lactation: Risk Summary There are no data on the presence of XDEMYV in human milk, the effects on the breastfed infant, or the effects on milk production. However, systemic exposure to lotilaner following 6 weeks of topical ocular administration is low and is >99% plasma protein bound, thus it is not known whether measurable levels of lotilaner would be present in maternal milk following topical ocular administration. The developmental and health benefits of breastfeeding should be considered along with the mother's clinical need for XDEMYV and any potential adverse effects on the breast-fed child from XDEMYV.

Pediatric Use: Safety and effectiveness in pediatric patients below the age of 18 years have not been established.

Geriatric Use: No overall differences in safety or effectiveness have been observed between elderly and other adult patients.

NONCLINICAL TOXICOLOGY

Carcinogenesis, Mutagenesis, Impairment of Fertility

Carcinogenesis Long-term studies in animals have not been performed to evaluate the carcinogenic potential of lotilaner.

Mutagenesis Lotilaner was not genotoxic in the following assays: Ames assay for bacterial gene mutation, *in vitro* chromosomal aberration assay in cultured human peripheral blood lymphocytes, and *in vivo* rat micronucleus test.

Impairment of fertility In a two-generation study of reproductive performance in rats, F0 male and female rats were administered lotilaner at oral doses of 40 mg/kg/day for 80 days reduced to 20 mg/kg/day for 47-50 supplementary days. Reduced pregnancy rates and decreased implantation rates were observed in F0 females at doses 20 mg/kg/day (approximately 556 times the RHOD on a body surface area basis), which were also associated with maternal toxicity (i.e., decreased body weight and food consumption). No effects on fertility were observed in F0 females at the dose of 5 mg/kg/day (approximately 139 times the RHOD on a body surface area basis). No effects on fertility were observed in F0 males at the oral dose of 20 mg/kg/day (approximately 556 times the RHOD on a body surface area basis), and no effects on fertility were observed in F1 males and females at the oral dose of 5 mg/kg/day (approximately 139 times the RHOD on a body surface area basis).

PATIENT COUNSELING INFORMATION

Handling the Container Instruct patients to avoid allowing the tip of the dispensing container to contact the eye, surrounding structures, fingers, or any other surface in order to minimize contamination of the solution. Serious damage to the eye and subsequent loss of vision may result from using contaminated solutions.

When to Seek Physician Advice

Advise patients that if they develop an intercurrent ocular condition (e.g., trauma or infection), have ocular surgery, or develop any ocular reactions, particularly conjunctivitis and eyelid reactions, they should immediately seek their physician's advice concerning the continued use of XDEMYV.

Use with Contact Lenses Advise patients that XDEMYV contains potassium sorbate, which may discolor soft contact lenses. Contact lenses should be removed prior to instillation of XDEMYV and may be reinserted 15 minutes following its administration.

Use with Other Ophthalmic Drugs Advise patients that if more than one topical ophthalmic drug is being used, the drugs should be administered at least 5 minutes between applications.

Missed Dose Advise patients that if one dose is missed, treatment should continue with the next dose.

RX only

© 2023 Tarsus Pharmaceuticals, Inc. All rights reserved.

XDEMYV is a trademark of Tarsus Pharmaceuticals, Inc.

US--2300345 9/23



MAKE CHILDREN'S SIGHT



YOUR FIGHT™.



Protect their vision from getting worse as they grow.

Meet MiSight® 1 day: the only dual purpose contact lens to both **correct vision and control myopia.**^{§1}

Through early intervention, **you have the power** to protect their vision from worsening with the **first and only*** FDA approved[†] product proven to slow the progression of myopia in children, aged 8-12 at the initiation of treatment.^{§1} MiSight®, for the love of sight.



**SEE
MORE**



MiSight® 1 day
for daily wear

* Only FDA approved soft contact lens designed for myopia control in the U.S.

† Indications for Use: MiSight® 1 day (omafilcon A) soft (hydrophilic) contact lenses for daily wear are indicated for the correction of myopic ametropia and for slowing the progression of myopia in children with non-diseased eyes, who at the initiation of treatment are 8-12 years of age and have a refraction of -0.75 to 4.00 diopters (spherical equivalent) with ≤ 0.75 diopters of astigmatism. The lens is to be discarded after each removal.

§ Compared to a single vision 1 day lens over a 3-year period.

1. Chamberlain P et al. A 3-year Randomized Clinical Trial of MiSight® Lenses for Myopia Control. Optom Vis Sci. 2019;96(8):556-567

©2023 CooperVision 14556ROO 10/23



NOW AVAILABLE
TO PRESCRIBE



Learn more at
XDEMZYHCP.com



xdemzy™
(lotilaner ophthalmic
solution) 0.25%

Might over mites

in just 6 weeks

1st &
only

FDA-APPROVED TREATMENT FOR
DEMODEX BLEPHARITIS (DB)

INDICATIONS AND USAGE

XDEMZY (lotilaner ophthalmic solution) 0.25% is indicated for the treatment of *Demodex* blepharitis.

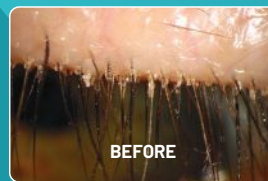
IMPORTANT SAFETY INFORMATION:

WARNINGS AND PRECAUTIONS

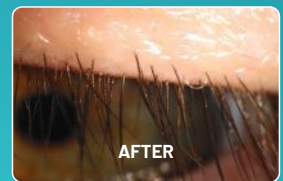Risk of Contamination: Do not allow the tip of the dispensing container to contact the eye, surrounding structures, fingers, or any other surface in order to minimize contamination of the solution. Serious damage to the eye and subsequent loss of vision may result from using contaminated solutions.

Use with Contact Lenses: XDEMZY contains potassium sorbate, which may discolor soft contact lenses. Contact lenses should be removed prior to instillation of XDEMZY and may be reinserted 15 minutes following its administration.

Real results



BEFORE



AFTER

44% and 55% of patients taking XDEMZY in SATURN-1 (N=209) and SATURN-2 (N=193), respectively, achieved a significant improvement in their eyelids (reduction of collarettes to no more than 2 collarettes per upper lid) at Day 43 vs 7% (N=204) and 12% (N=200) of patients taking vehicle ($P < 0.01$ in each trial).*

All images are of actual patients who participated in clinical trials for Tarsus Pharmaceuticals.

ADVERSE REACTIONS: The most common adverse reaction with XDEMZY was instillation site stinging and burning which was reported in 10% of patients. Other ocular adverse reactions reported in less than 2% of patients were chalazion/hordeolum and punctate keratitis.

Please see next page for a Brief Summary of the full Prescribing Information.

Reference: XDEMZY [prescribing information]. Tarsus Pharmaceuticals, Inc; 2023.

*The safety and efficacy of XDEMZY for the treatment of DB were evaluated in a total of 833 patients (415 of whom received XDEMZY) in two 6-week, randomized, multicenter, double-masked, vehicle-controlled studies (SATURN-1 and SATURN-2). Patients were randomized to either XDEMZY or vehicle at a 1:1 ratio, dosed twice daily in each eye for 6 weeks. All patients enrolled were diagnosed with DB. The primary efficacy endpoint was defined as the proportion of patients with collarette reduction to no more than 2 collarettes per upper eyelid at Day 43 (SATURN-1: XDEMZY N=209, vehicle N=204, $P < 0.01$; SATURN-2: XDEMZY N=193, vehicle N=200, $P < 0.01$).

© 2023 Tarsus Pharmaceuticals, Inc. All rights reserved.
Tarsus, XDEMZY, and the associated logos are trademarks of
Tarsus Pharmaceuticals, Inc. US—2300405 9/23

