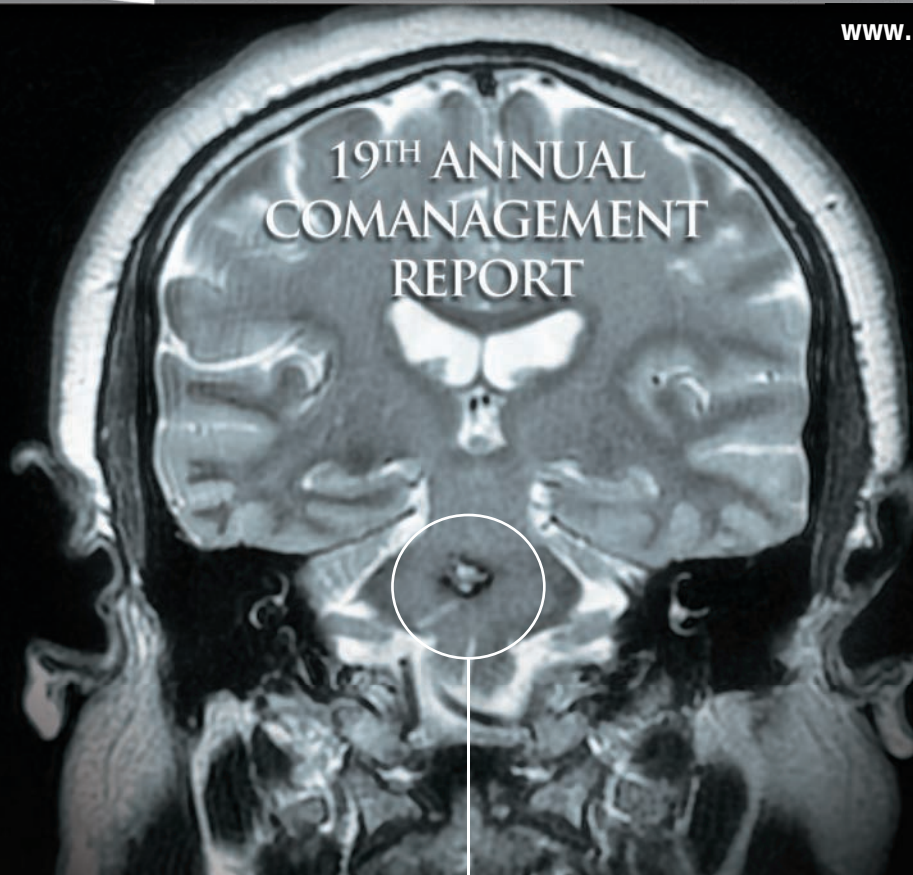


May 15, 2014

# REVIEW<sup>®</sup> OF OPTOMETRY

www.revoptom.com



19<sup>TH</sup> ANNUAL  
COMANAGEMENT  
REPORT

---

## BE A NEURO-OPHTH 'FIRST RESPONDER'

---

When the eye—and even the patient—hangs in the balance, prompt action and careful collaboration could save the day. *Page 52*

Can You Crack These Challenging  
Comanagement Cases?

*Page 38*



Glaucoma Comanagement  
in the MIGS Era

*Page 44*

**ALSO INSIDE:**

"Patients From Hell"—How Would You Handle These Awkward Encounters?, p. 24 • Spotlight on Sickle-cell Retinopathy, p. 30



# Monotherapy Maintained.

Proven IOP reduction<sup>1</sup>

Established tolerability with  
low discontinuation rate<sup>2</sup>

## On Your Terms.

Broad preferred coverage<sup>3</sup>

Comprehensive patient support

**Indication:** LUMIGAN® (bimatoprost ophthalmic solution) 0.01% is indicated for the reduction of elevated intraocular pressure in patients with open-angle glaucoma or ocular hypertension.

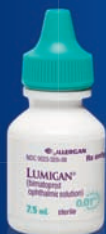### Important Safety Information

**Warnings and Precautions:** LUMIGAN® 0.01% causes changes to pigmented tissues, mostly increased pigmentation of the iris, eyelid, and eyelashes as long as LUMIGAN® 0.01% is administered. Iris color change may not be noticeable for several months to years. After discontinuation of bimatoprost, iris pigmentation is likely to be permanent, while eyelid and eyelash changes have been reported to be reversible in some patients. Patients should be informed of the possibility of increased pigmentation. The long-term effects of increased pigmentation are not known.

LUMIGAN® 0.01% should be used with caution in patients with active intraocular inflammation (eg, uveitis) because the inflammation may be exacerbated. Macular edema, including cystoid macular edema, has been reported with LUMIGAN® 0.01%. LUMIGAN® 0.01% should be used with caution in aphakic patients, in pseudophakic patients with a torn posterior lens capsule, or in patients with known risk factors for macular edema. LUMIGAN® 0.01% has not been studied to treat types of glaucoma other than open-angle glaucoma. Remove contact lenses prior to instillation of LUMIGAN® 0.01% and reinsert after 15 minutes.

**Adverse Reactions:** The most common (25%-45%) adverse event with LUMIGAN® 0.01% was conjunctival hyperemia. Approximately 0.5% to 3% of patients discontinued therapy due to conjunctival hyperemia. Other common events (> 10%) included growth of eyelashes and ocular pruritus.

Please see Brief Summary of the full  
Prescribing Information on adjacent page.



# LUMIGAN® 0.01%

(bimatoprost ophthalmic solution) 0.01%

1. LUMIGAN® Prescribing Information. 2. Katz LJ, Cohen JS, Batoosingh AL, Felix C, Shu V, Schiffman RM. Twelve-month, randomized, controlled trial of bimatoprost 0.01%, 0.0125%, and 0.03% in patients with glaucoma or ocular hypertension. *Am J Ophthalmol.* 2010;149(4):661-671. 3. Managed Markets Insight & Technology, LLC, database, as of November 2013.

 ALLERGAN ©2013 Allergan, Inc., Irvine, CA 92612 ® marks owned by Allergan, Inc.  
Managed Markets Insight & Technology is a portfolio company of  
Susquehanna Growth Equity. [www.lumigan.com](http://www.lumigan.com) APC88J013 133927

Allergan at your service

# LUMIGAN® 0.01% AND 0.03%

(bimatoprost ophthalmic solution)

**Brief Summary—Please see the LUMIGAN® 0.01% and 0.03% package insert for full Prescribing Information.**

## INDICATIONS AND USAGE

LUMIGAN® 0.01% and 0.03% (bimatoprost ophthalmic solution) is indicated for the reduction of elevated intraocular pressure in patients with open angle glaucoma or ocular hypertension.

## CONTRAINDICATIONS

None

## WARNINGS AND PRECAUTIONS

**Pigmentation:** Bimatoprost ophthalmic solution has been reported to cause changes to pigmented tissues. The most frequently reported changes have been increased pigmentation of the iris, periorbital tissue (eyelid) and eyelashes. Pigmentation is expected to increase as long as bimatoprost is administered. The pigmentation change is due to increased melanin content in the melanocytes rather than to an increase in the number of melanocytes. After discontinuation of bimatoprost, pigmentation of the iris is likely to be permanent, while pigmentation of the periorbital tissue and eyelash changes have been reported to be reversible in some patients. Patients who receive treatment should be informed of the possibility of increased pigmentation. The long term effects of increased pigmentation are not known.

Iris color change may not be noticeable for several months to years. Typically, the brown pigmentation around the pupil spreads concentrically towards the periphery of the iris and the entire iris or parts of the iris become more brownish. Neither nevi nor freckles of the iris appear to be affected by treatment. While treatment with LUMIGAN® 0.01% and 0.03% (bimatoprost ophthalmic solution) can be continued in patients who develop noticeably increased iris pigmentation, these patients should be examined regularly.

**Eyelash Changes:** LUMIGAN® 0.01% and 0.03% may gradually change eyelashes and vellus hair in the treated eye. These changes include increased length, thickness, and number of lashes. Eyelash changes are usually reversible upon discontinuation of treatment.

**Intraocular Inflammation:** LUMIGAN® 0.01% and 0.03% should be used with caution in patients with active intraocular inflammation (e.g., uveitis) because the inflammation may be exacerbated.

**Macular Edema:** Macular edema, including cystoid macular edema, has been reported during treatment with bimatoprost ophthalmic solution. LUMIGAN® 0.01% and 0.03% should be used with caution in aphakic patients, in pseudophakic patients with a torn posterior lens capsule, or in patients with known risk factors for macular edema.

**Angle-closure, Inflammatory, or Neovascular Glaucoma:** LUMIGAN® 0.01% and 0.03% has not been evaluated for the treatment of angle-closure, inflammatory or neovascular glaucoma.

**Bacterial Keratitis:** There have been reports of bacterial keratitis associated with the use of multiple-dose containers of topical ophthalmic products. These containers had been inadvertently contaminated by patients who, in most cases, had a concurrent corneal disease or a disruption of the ocular epithelial surface.

**Use With Contact Lenses:** Contact lenses should be removed prior to instillation of LUMIGAN® 0.01% and 0.03% and may be reinserted 15 minutes following its administration.

## ADVERSE REACTIONS

**Clinical Studies Experience:** Because clinical studies are conducted under widely varying conditions, adverse reaction rates observed in the clinical studies of a drug cannot be directly compared to rates in the clinical studies of another drug and may not reflect the rates observed in practice.

In clinical studies with bimatoprost ophthalmic solutions (0.01% or 0.03%) the most common adverse reaction was conjunctival hyperemia (range 25%–45%). Approximately 0.5% to 3% of patients discontinued therapy due to conjunctival hyperemia with 0.01% or 0.03% bimatoprost ophthalmic solutions. Other common reactions (>10%) included growth of eyelashes, and ocular pruritus.

Additional ocular adverse reactions (reported in 1 to 10% of patients) with bimatoprost ophthalmic solutions included ocular dryness, visual disturbance, ocular burning, foreign body sensation, eye pain, pigmentation of the periocular skin, blepharitis, cataract, superficial punctate keratitis, periorbital erythema, ocular irritation, eyelash darkening, eye discharge, tearing, photophobia, allergic conjunctivitis, asthenopia, increases in iris pigmentation, conjunctival edema, conjunctival hemorrhage, and abnormal hair growth. Intraocular inflammation, reported as iritis, was reported in less than 1% of patients.

Systemic adverse reactions reported in approximately 10% of patients with bimatoprost ophthalmic solutions were infections (primarily colds and upper respiratory tract infections). Other systemic adverse reactions (reported in 1 to 5% of patients) included headaches, abnormal liver function tests, and asthenia.

**Postmarketing Experience:** The following reactions have been identified during postmarketing use of LUMIGAN® 0.01% and 0.03% in clinical practice. Because they are reported voluntarily from a population of unknown size, estimates of frequency cannot be made. The reactions, which have been chosen for inclusion due to either their seriousness, frequency of reporting, possible causal connection to LUMIGAN® or a combination of these factors, include: dizziness, eyelid edema, hypertension, nausea, and periorbital and lid changes associated with a deepening of the eyelid sulcus.

## USE IN SPECIFIC POPULATIONS

### Pregnancy: Pregnancy Category C

Teratogenic effects: In embryo/fetal developmental studies in pregnant mice and rats, abortion was observed at oral doses of bimatoprost which achieved at least 33 or 97 times, respectively, the maximum intended human exposure based on blood AUC levels.

At doses at least 41 times the maximum intended human exposure based on blood AUC levels, the gestation length was reduced in the dams, the incidence of dead fetuses, late resorptions, peri- and postnatal pup mortality was increased, and pup body weights were reduced.

There are no adequate and well-controlled studies of LUMIGAN® 0.01% and 0.03% (bimatoprost ophthalmic solution) administration in pregnant women. Because animal reproductive studies are not always predictive of human response LUMIGAN® should be administered during pregnancy only if the potential benefit justifies the potential risk to the fetus.

**Nursing Mothers:** It is not known whether LUMIGAN® 0.01% and 0.03% is excreted in human milk, although in animal studies, bimatoprost has been shown to be excreted in breast milk. Because many drugs are excreted in human milk, caution should be exercised when LUMIGAN® is administered to a nursing woman.

**Pediatric Use:** Use in pediatric patients below the age of 16 years is not recommended because of potential safety concerns related to increased pigmentation following long-term chronic use.

**Geriatric Use:** No overall clinical differences in safety or effectiveness have been observed between elderly and other adult patients.

**Hepatic Impairment:** In patients with a history of liver disease or abnormal ALT, AST and/or bilirubin at baseline, bimatoprost 0.03% had no adverse effect on liver function over 48 months.

## OVERDOSAGE

No information is available on overdosage in humans. If overdose with LUMIGAN® 0.01% and 0.03% (bimatoprost ophthalmic solution) occurs, treatment should be symptomatic.

In oral (by gavage) mouse and rat studies, doses up to 100 mg/kg/day did not produce any toxicity. This dose expressed as mg/m<sup>2</sup> is at least 70 times higher than the accidental dose of one bottle of LUMIGAN® 0.03% for a 10 kg child.

## NONCLINICAL TOXICOLOGY

**Carcinogenesis, Mutagenesis, Impairment of Fertility:** Bimatoprost was not carcinogenic in either mice or rats when administered by oral gavage at doses of up to 2 mg/kg/day and 1 mg/kg/day respectively (at least 192 and 291 times the recommended human exposure based on blood AUC levels respectively) for 104 weeks.

Bimatoprost was not mutagenic or clastogenic in the Ames test, in the mouse lymphoma test, or in the *in vivo* mouse micronucleus tests.

Bimatoprost did not impair fertility in male or female rats up to doses of 0.6 mg/kg/day (at least 103 times the recommended human exposure based on blood AUC levels).

## PATIENT COUNSELING INFORMATION

**Potential for Pigmentation:** Patients should be advised about the potential for increased brown pigmentation of the iris, which may be permanent. Patients should also be informed about the possibility of eyelid skin darkening, which may be reversible after discontinuation of LUMIGAN® 0.01% and 0.03% (bimatoprost ophthalmic solution).

**Potential for Eyelash Changes:** Patients should also be informed of the possibility of eyelash and vellus hair changes in the treated eye during treatment with LUMIGAN® 0.01% and 0.03%. These changes may result in a disparity between eyes in length, thickness, pigmentation, number of eyelashes or vellus hairs, and/or direction of eyelash growth. Eyelash changes are usually reversible upon discontinuation of treatment.

**Handling the Container:** Patients should be instructed to avoid allowing the tip of the dispensing container to contact the eye, surrounding structures, fingers, or any other surface in order to avoid contamination of the solution by common bacteria known to cause ocular infections. Serious damage to the eye and subsequent loss of vision may result from using contaminated solutions.

**When to Seek Physician Advice:** Patients should also be advised that if they develop an intercurrent ocular condition (e.g., trauma or infection), have ocular surgery, or develop any ocular reactions, particularly conjunctivitis and eyelid reactions, they should immediately seek their physician's advice concerning the continued use of LUMIGAN® 0.01% and 0.03%.

**Use with Contact Lenses:** Patients should be advised that LUMIGAN® 0.01% and 0.03% contains benzalkonium chloride, which may be absorbed by soft contact lenses. Contact lenses should be removed prior to instillation of LUMIGAN® and may be reinserted 15 minutes following its administration.

**Use with Other Ophthalmic Drugs:** Patients should be advised that if more than one topical ophthalmic drug is being used, the drugs should be administered at least five (5) minutes between applications.

©2012 Allergan, Inc., Irvine, CA 92612

® marks owned by Allergan, Inc

Patented. See: [www.allergan.com/products/patent\\_notices](http://www.allergan.com/products/patent_notices)

Made in the U.S.A.

APC70EN12 based on 71807US13.

Rx only

 ALLERGAN

## IN THE NEWS

Contact lenses coated with melamine, an **anti-microbial peptide**, may potentially **reduce the risk of contact lens-related infections**, according to a study published in *Optometry and Vision Science*. The researchers studied the peptide-coated lenses in both rabbits and humans, and compared them to conventional contact lenses.

The melamine-coated lenses exhibited similar wettability, comfort, lens fitting and corneal coverage to the conventional lenses. The only reported difference between the two modalities was increased corneal staining caused by the melamine-coated lenses. Further clinical trials are required to study the lens' ability to reduce adverse events in extended wear.

Following an unsolicited **\$45.7 billion** bid from **Valeant Pharmaceuticals Inc., Allergan Inc.** has begun early discussions with companies such as **Sanofi** and **Johnson & Johnson** to gauge their interest in acquiring the pharmaceutical company. Allergan has yet to respond to Valeant's offer, and is currently exploring all available options.

The University of Pikeville recently announced that **Andrew Buzzelli, OD, MS**, will be the **Founding Dean of the Kentucky College of Optometry**. Dr. Buzzelli is a member of the ASCO Board of Directors and currently serves as the Dean of the University of the Incarnate Word Rosenberg School of Optometry. He will assume his new position in July.

## Nebraska Increases Scope of Practice for ODs

Optometrists in the Cornhusker State gain minor surgical, injection privileges. **By Erin Kelly, Senior Associate Editor**

**O**ptometrists in Nebraska will be able to perform minor surgical procedures and injections under a new law recently signed by Gov. Dave Heineman.

Oppositional lobbying by ophthalmologists threatened to stagnate the bill, which was presented for second-round consideration on the 58th day of the 60-day session—the last day a bill could advance and still have a chance. But it ultimately passed after ophthalmologists and optometrists reached a compromise, according to Christopher Wolfe, OD, legislative committee chair of the Nebraska Optometric Association (NOA).

The compromise, which enabled NOA to assure expedited approval in the waning hours of the session,

lifts remaining restrictions of oral drugs (steroids, glaucoma meds and immunosuppressives), authorizes injections for treating anaphylaxis and removes provisions involving minor surgical procedures and injections into the eyelid.

“It certainly doesn't accomplish all of our goals,” Dr. Wolfe says. But, “our legislative committee and board remain committed to the pursuit of the additional updates to [this bill] that will enable our doctors to serve primary care needs of their patients.”

Dubbed the “Better Access to Quality Eye Care” bill, the legislation was originally introduced by Omaha Sen. Sara Howard, who noted that the expanded OD services would benefit underserved areas of the state where no ophthalmology services are available.

### Arizona ODs Gain Expanded Prescribing Rights

Optometrists in Arizona can now write prescriptions for several additional medications, including carbonic anhydrase inhibitors that help glaucoma patients in emergencies. With the new legislation, Arizona joins 40 other states that allow ODs to prescribe oral glaucoma meds.

“This primarily helps patients in pain or at risk of loss of sight who need urgent care medications,” says Annette Hanian, OD, legislative chair of the Arizona Optometric Association. “It adds another tool to our toolbox. We're not treating things that we haven't already treated. This just gives us the ability to respond more quickly in emergency situations.”

This legislation is particularly critical in Arizona, which has just 320 ophthalmologists but more than 900 ODs.

Part of HB 2380 also allows optometrists to continue writing prescriptions for hydrocodone. The opioid-based pain medication fell out of optometrists' prescriptive power after the federal government changed its designation to Schedule II.

# Protect Eyes from Ultraviolet (UV) Radiation All Day, Every Day



## Research has found unexpected risks to the eyes from ultraviolet (UV) radiation. Innovative technology from Essilor can help reduce those at risk and protect eyes from UV 365 days a year.

Eyecare professionals know that the cornea, crystalline lens, and even the retina can be damaged by long-term UV exposure, which has been implicated in a variety of severe ocular conditions, including pterygium, climatic droplet keratopathy, cortical cataract, and possibly age-related macular degeneration. Scientific studies have found additional UV dangers that were previously unknown.

Fortunately, Essilor scientists have found an effective way to counter these hazards, and patients can now buy lenses that give them the most complete protection from UV 365 days a year. What we need going forward is greater public awareness of the dangers of UV and more widespread adoption of lenses with most complete UV protection.

### Indirect Risks

One thing we have learned is that UV risk to the eyes isn't greatest when the sun's energy is strongest. Because they are set into the orbit and protected by the upper lid, the eyes are shielded from direct sunlight when the sun is high in the sky, which is when it causes most damage to the skin. For the eyes, the risk is greatest when the sun is a bit lower in the sky—in mid-morning and mid-afternoon—times when people are less likely to wear sunglasses.<sup>1</sup> Thus, the need for UV protection is not limited to sunglasses: people need UV protection in every pair of lenses they wear outside.

Direct UV exposure is not the only danger. Indirect UV (that is scattered by clouds and reflected from the ground and other surfaces) actually accounts for nearly half of an individual's annual UV dose.<sup>2</sup> This UV is a particular threat to spectacle wearers because UV coming from the side and behind the wearer can be reflected into the eye by the back surface of the spectacle lens. Although most higher-quality lens materials do a good job of blocking UV *transmission* (ie, stopping UV from passing through the lens), they can still reflect a significant amount of UV from the back surface of the lens directly into the eye.

The public is fully aware of the risks associated with skin exposure to UV, but the ocular hazards—and how to protect against them—are much less known. The dangers of back surface UV reflection, for example, are

not well known. Eyecare professionals have a key role to play in creating awareness of the importance of maximum eye protection from UV.

### Technology

Work by Karl Citek, OD, PhD, Professor of Optometry, has established that traditional anti-reflective or No-Glare lenses, although they transmit almost 100% of visible light, actually reflect considerable UV.<sup>3</sup> Some No-Glare lenses reflect up to 50% of incident UV.<sup>3</sup>

This important discovery was the stimulus for development of Essilor's patented Broad

nea with and without a lens in place. E-SPF accounts for both transmission and backside reflection of UV, and higher values of E-SPF indicate greater levels of protection.

Integrating all these factors into a single measure helps eyecare practitioners communicate the importance of ocular UV protection, and lets them (and their patients) compare the protection offered by different lenses.

Talking to patients about the E-SPF will reinforce the message that UV protection is every bit as important for eyes as it is for skin. Discussing UV hazards with every pa-

## Superior Visual Clarity and UV Protection

Essilor's patented Broad Spectrum Technology™ minimizes reflected UV exposure and maximizes visible light transmission for safe, clear vision all day long. Introduced in all Crizal® lenses, Broad Spectrum Technology adds exceptional UV protection to the features and benefits of all Crizal lenses.

**Crizal**  
**SAPPHIRE<sup>UV</sup>**

Crizal Sapphire UV™ lenses provide the best protection against glare and reflections.

**Crizal**  
**PREVENCIA**

Crizal® Prevenia™ lenses selectively deflect harmful Blue-Violet and UV light, providing improved protection for eyes.

**Crizal**  
**AVANCÉ<sup>UV</sup>**

Crizal Avance UV™ lenses are 2x more scratch-resistant than Crizal Alize UV™ lenses.

**Crizal**  
**ALIZÉ<sup>UV</sup>**

Crizal Alize UV™ lenses set the bar for smudge resistance.

**Crizal**  
**easy<sup>UV</sup>**

Crizal Easy UV™ lenses give you reliable, No-Glare protection that is easy to clean.

**Crizal**  
**kids<sup>UV</sup>**

Crizal Kids UV™ No-Glare lens package is specially designed to meet kids' vision needs.



All Crizal® No-Glare lenses provide the most complete daily UV protection, with an Eye-Sun Protection Factor (E-SPF®) of 25.

Spectrum Technology™, which reduces UV reflection. This technology has been incorporated across the entire portfolio of Crizal® lenses, allowing them to offer the most complete UV protection on No-Glare lenses.

### Clear Patient Benefits

To help patients understand the value of this protection, Essilor developed the Eye-Sun Protection Factor (E-SPF®).

Like the well-established index used to rate skin care and sunscreen products' efficiency, E-SPF provides consumers and eyecare professionals with a simple way to select the highest level of complete UV protection. E-SPF is defined as the ratio of UV reaching the cor-

nea as a normal part of the comprehensive eye exam—and recommending glasses that provide the most complete UV protection—are simple and meaningful steps to better ocular health for everyone.

### REFERENCES

1. Sasaki H, Sakamoto Y, Schnider C, et al. UV-B exposure to the eye depending on solar altitude. *Eye Contact Lens*. 2011;37(4):191-5.
2. Baldy C, Greenstein V, Holopigian K, et al. Light, Sight, and Photochromics. Pinellas Park, Florida: Transitions Optical Inc. 2002.
3. Citek K. Anti-reflective coatings reflect ultraviolet radiation. *Optometry*. 2008;79(3):143-8.

**The AOA Inducts Three Members to its Hall of Fame**

The American Optometric Association (AOA) and Optometry Cares—The AOA Foundation have selected three members for the prestigious National Optometry Hall of Fame. Since 1998, the National Optometry Hall of Fame has recognized and honored optometrists who have made significant and long-lasting contributions to the optometric profession. The 2014 inductees are:

**Arol R. Augsburger, OD, of Chicago**

Dr. Augsburger is president and professor of optometry at the Illinois College of Optometry. He was named Optometrist of the Year by the AOA in 1986, and received a Distinguished Service Award in 2008. He was also named Optometrist of the Year in Ohio in 1985, Alabama in 2000 and Illinois in 2007.



**Ron Fair, OD, of Brighton, Colo.**

Dr. Fair served as president of the AOA in 1976, the Colorado Optometric Association in 1968 and the National Academies of Practice from 1996 to 1999. He received a Distinguished Service Award in 2000 and was named the Colorado Optometric Association's Optometrist of the Year in 1970.



**Karla Zadnik, OD, PhD, of Worthington, Ohio**

Dr. Zadnik is associate dean of the Ohio State University College of Optometry and Glenn A. Fry Professor in Optometry and Physiological Optics. She is immediate past president of the American Academy of Optometry. Additionally, Dr. Zadnik served the AOA's Contact Lens and Cornea Section and received its Dr. Donald R. Korb Award for Excellence in 2009. She also received the Young Optometrist of the Year Award in 1989 from the California Optometric Association and the Distinguished Scholar Award from the Ohio State University in 2010.



# Adaptive Optics Improves DR Detection

Indiana University researchers used a novel imaging device to detect microscopic signs of early diabetic eye disease, according to a study in *Biomedical Optics Express*. The instrument, known as a confocal adaptive optics scanning laser ophthalmoscope (AOSLO), was able to capture more precise, detailed views of retinal microvasculature blood flow than previously could be seen via conventional funduscopy.

The researchers used the AOSLO to image the retinæ of patients with non-proliferative diabetic retinopathy (NPDR). The researchers noted that many patients with only mild or moderate NPDR exhibited extensive microvascular changes, including the formation of corkscrew-shaped capillaries.

“We had not expected to see such striking changes to the retinas at such early stages,” said lead author Ann Elsner, PhD, professor and associate dean of IU’s School of Optometry. “There was damage spread widely across the retina, including changes to blood vessels that were not thought to occur until the more advanced disease states.”

In addition to capturing evidence of capillary remodeling, the AOSLO provided enhanced detail of clinically detectable microaneurysms and hemorrhages in NPDR patients. Further, it was able to detect early signs of vascular wall thickening and capillary closure.

“It is shocking to see that there can be large areas of retina with insufficient blood circulation [this

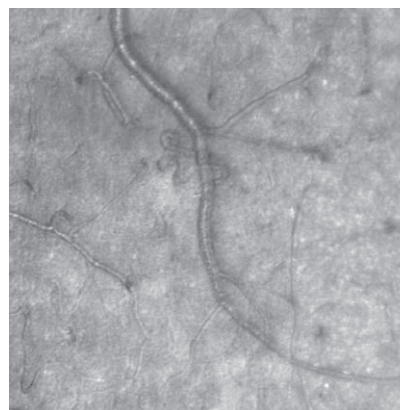


Photo: The Burns Lab, Indiana University School of Optometry

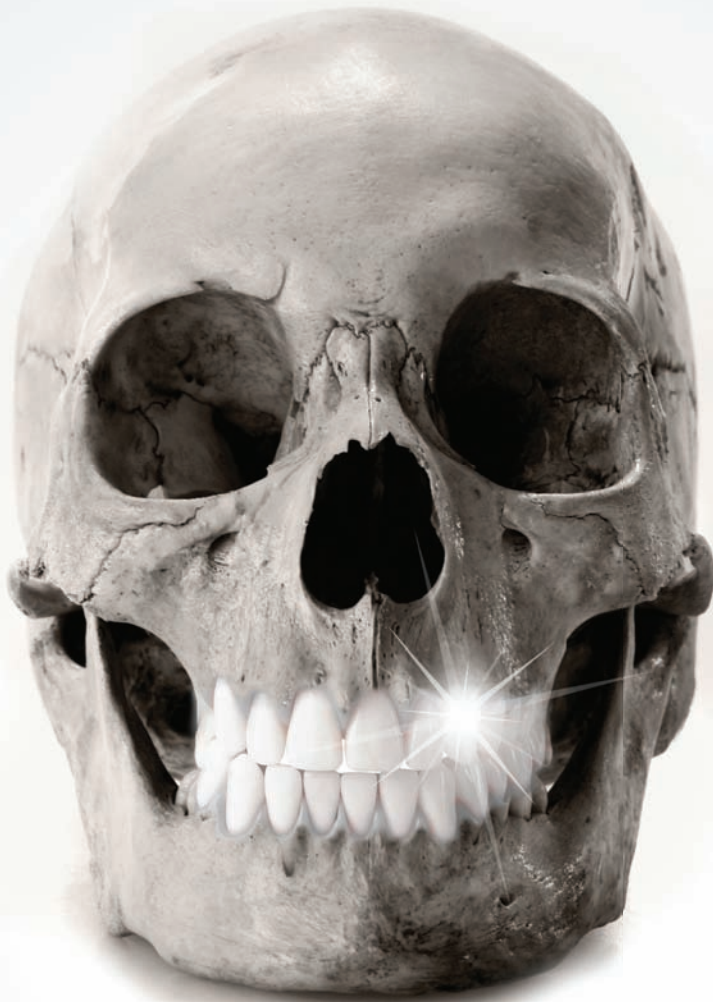**AOSLO image of a diabetes patient shows a retinal capillary with multiple loops. Such microvascular remodeling prohibits direct blood flow to the retinal cells.**

early in the disease process],” said study coauthor Stephen Burns, PhD, IU School of Optometry professor and principal developer of the AOSLO.

While most of the study subjects were believed to have fairly mild symptoms based upon clinical findings, the AOSLO showed that oxygen and glucose transport to the retina was already partially compromised.

The researchers concluded that simply magnifying retinal fundus images of NPDR patients is insufficient for accurate detection of disease progression. Further research using the AOSLO could potentially help clinicians determine which patients have the most severe diabetic eye damage, and whether the microvascular changes could be treated or even reversed.

Burns SA, Elsner AE, Chui TY, et al. In vivo adaptive optics microvascular imaging in diabetic patients without clinically severe diabetic retinopathy. *Biomed Opt Express*. 2014 Feb 27;5(3):961-74.



He obviously thought a lot  
**ABOUT HIS TEETH.**

But his eyes?  
**NOT SO MUCH.**

What will it take to make Americans  
think as much about their eyes as  
they do their teeth?

## **We need you to help increase the importance of annual eye exams.**

- **Think About Your Eyes**, the multi-million dollar ad campaign, has increased eye exams for practices just like yours by 4 to 8%
- Your support helps **Think About Your Eyes** grow funding from industry partners
  - Get your practice listed on the **DOCTOR LOCATOR TODAY!**

**Join ThinkAboutYourEyes TODAY!**

Keep this vital campaign going! Sign up at:  
[ThinkAboutYourEyes.com/Enroll](http://ThinkAboutYourEyes.com/Enroll)

**think**about  
your**eyes**.com

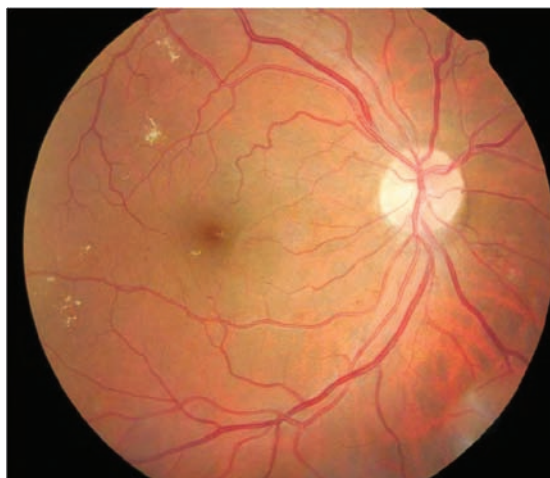# Remote Screening May Help Detect DME

**R**esearchers at UC Berkeley School of Optometry have found that digital photos can help detect hard exudates—a key early sign of diabetes-related macular edema. Their findings were published in the April issue of *Optometry and Vision Science*.

Macular edema is one of the most threatening visual conditions faced by people with diabetes. Unfortunately, about 20% of patients already have early signs of the condition when they're diagnosed, and many aren't under the continued care of an eye care professional.

The researchers took magnified retinal images of 103 adults with type 2 diabetes who were considered at risk for macular edema. Researchers did not use drops to dilate the eye and took the images at a public health clinic using the EyePACS teleophthalmology system. The photos were then sent to eye specialists online, who looked for hard exudates close to the line of sight as an indicator of clinically significant macular edema.

Follow-up dilated exams by eye specialists showed clinically significant macular edema in about 15% of patients, suggesting that hard exudates detected on the digital photographs were an accurate indicator of macular edema.



**UC Berkeley researchers determined that the presence of hard exudates within one disc diameter of the foveola is indicative of diabetic macular edema, as seen here.**

“Since the completion of that study, we have looked at whether the presence of hard exudates within 500µm of the fovea is associated with greater retinal thickness measured by OCT,” says lead author Taras Litvin, OD. “We found that patients had greater central macular thickness on the OCT thickness maps if they had exudates less than 500µm from the fovea on OCT scans.”

The presence of hard exudates located within one disc diameter of the foveola in diabetes patients is a reliable marker for clinically significant macular edema. This diagnostic method, however, shouldn't replace a dilated fundus exam, which includes careful biomicroscopy when such an exam is possible, Dr. Litvin added. ■

Litvin TV, Ozawa GY, Bresnick GH, et al. Utility of hard exudates for the screening of macular edema. *Optom Vis Sci*. 2014 Apr;91(4):370-5.

**REVIEW**<sup>®</sup>  
OF OPTOMETRY

**Jobson**  
Professional Publications Group

**BUSINESS OFFICES**  
11 CAMPUS BLVD., SUITE 100  
NEWTOWN SQUARE, PA 19073

**CEO, INFORMATION SERVICES GROUP**  
MARC FERRARA  
(212) 274-7062 • MFERRARA@JOBSON.COM

**SALES MANAGER, NORTHEAST, OHIO**  
JAMES HENNE  
(610) 492-1017 • JHENNE@JOBSON.COM

**SALES MANAGER, SOUTHEAST, WEST**  
MICHELE BARRETT  
(610) 492-1014 • MBARRETT@JOBSON.COM

**VICE PRESIDENT, OPERATIONS**  
CASEY FOSTER  
(610) 492-1007 • CFOSTER@JOBSON.COM

**VICE PRESIDENT, CLINICAL CONTENT**  
PAUL M. KARPECKI, OD, FFAO  
PKARPECKI@JOBSON.COM

**PRODUCTION MANAGER**  
SCOTT TOBIN  
(610) 492-1011 • STOBIN@JOBSON.COM

**SENIOR CIRCULATION MANAGER**  
HAMILTON MAHER  
(212) 219-7870 • HMAHER@JHIHEALTH.COM

**CLASSIFIED ADVERTISING**  
(888) 498-1460

**SUBSCRIPTIONS**  
\$56 A YEAR, \$88 (US) IN CANADA,  
\$209 (US) IN ALL OTHER COUNTRIES.

**SUBSCRIPTION INQUIRIES**  
(877) 529-1746 (US ONLY);  
OUTSIDE US, CALL (847) 763-9630

**CIRCULATION**  
PO Box 2025  
SKOKIE, IL 60076  
TEL: (TOLL FREE) 1-877-529-1746  
OUTSIDE US: (847)763-9630  
FAX: (847)763-9631



**CEO, INFORMATION SERVICES GROUP**  
MARC FERRARA

**SENIOR VICE PRESIDENT, OPERATIONS**  
JEFF LEVITZ

**SENIOR VICE PRESIDENT, HUMAN RESOURCES**  
LORRAINE ORLANDO

**VICE PRESIDENT, CREATIVE SERVICES & PRODUCTION**  
MONICA TETTAMANZI

**VICE PRESIDENT, CIRCULATION**  
EMELDA BAREA



# Don't just meet the needs of your patients— exceed them.



**New Bausch + Lomb PeroxiClear™ – the most advanced\* peroxide solution.**

	PeroxiClear™	Clear Care
Delivers Exceptional Disinfection	✓	✓
Preservative Free	✓	✓
Provides Superior All-Day Comfort <sup>1,2*</sup>	✓	
Keep Lenses Cleaner and Moister for Longer <sup>1-5*</sup>	✓	
Lenses Are Ready to Wear in Only 4 Hours	✓	

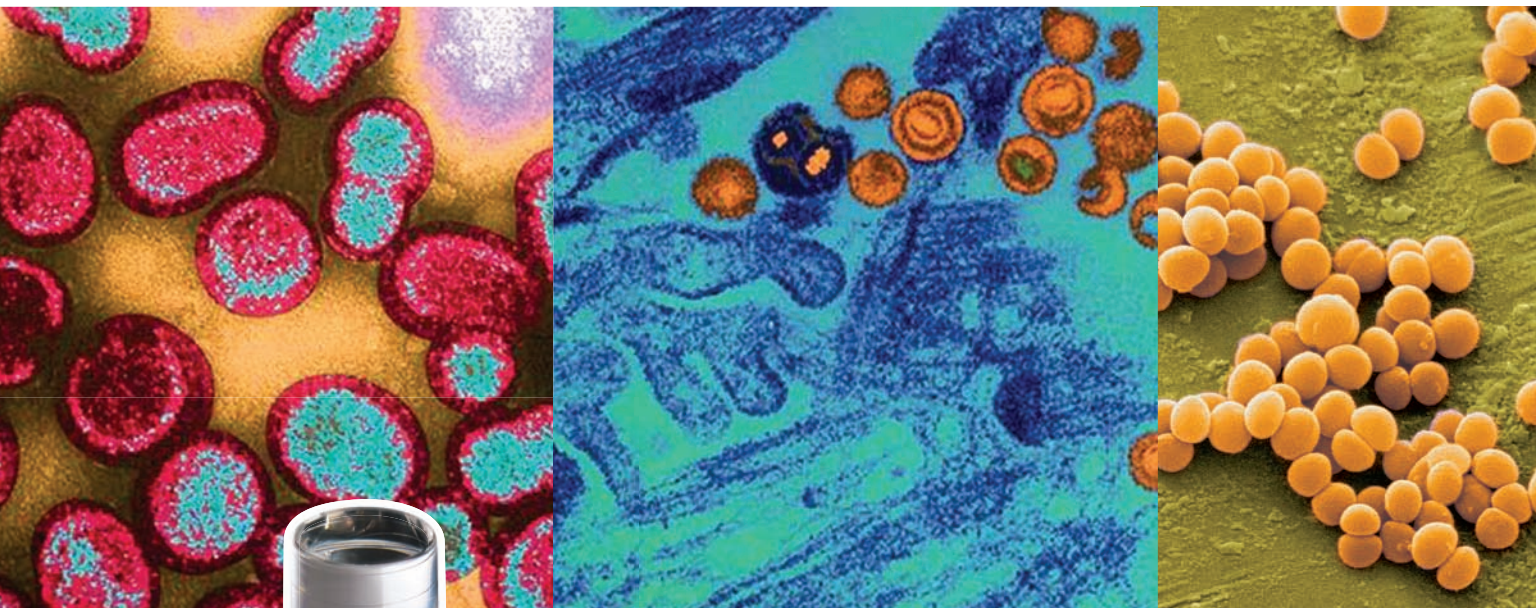
**Switch your patients to the most advanced\* peroxide solution. Request your care kits today at [Bausch.com/Peroxiclear](http://Bausch.com/Peroxiclear).**

\*Compared to Clear Care

**REFERENCES:** **1.** Results from a 22-investigator, multi-site study of PeroxiClear™, with a total of 440 eligible subjects. Subjects were randomized to use either PeroxiClear™ or Clear Care for 3 months. Subjects completed performance surveys at 2-week, 1-month, 2-month, and 3-month visits. **2.** Results from a 21-investigator, multi-site study of PeroxiClear™, with a total of 297 eligible subjects who were habitual Clear Care users. After 7 days of use, subjects completed an online survey. Consumers rated the performance of PeroxiClear™ across a range of attributes and compared the performance to their habitual Clear Care solution. **3.** High-resolution/accurate-mass (HR/AM) mass spectrometry was used to detect and quantitate the relative amounts of surfactant retained on lenses from PeroxiClear™ and Clear Care solutions after 20 hours of wear. PureVision<sup>®</sup>2, ACUVUE OASYS, and AIR OPTIX AQUA lenses were soaked in solutions for 12 hours prior to patients wearing lenses for 20 hours. **4.** Results of an in vitro study measuring deposits on ACUVUE OASYS lenses. Lenses were subjected to 14 cycles of deposition with a lipid and protein solution mimicking the human tear film followed by a cleaning regimen with either PeroxiClear™ or Clear Care 3% hydrogen peroxide systems. Each deposition/cleaning cycle was representative of one day of patient use. Cycled lenses (n=3) were analyzed for deposits using image analysis. After 14 cycles, lenses cleaned with PeroxiClear™ had only 8.0% surface coverage compared to 33.0% for lenses cleaned with Clear Care. **5.** Results of an ex vivo study measuring deposits on worn contact lenses to compare the clinical performance of PeroxiClear™ and Clear Care solutions. Lenses were worn daily for 1 month (silicone hydrogel and Group IV hydrogel lenses) or 3 months (gas permeable lenses). A total of 374 lenses were randomly selected for image analysis. Lenses were scored for mean density of deposits and percent coverage of deposits.

Distributed by Bausch + Lomb, a Division of Valeant Pharmaceuticals, North America LLC, Bridgewater, N.J. PeroxiClear and PureVision are trademarks of Bausch & Lomb Incorporated or its affiliates. All other brand/product names are trademarks of their respective owners. ©2014 Bausch & Lomb Incorporated. BLS07185 US/OC/14/0002

**BAUSCH + LOMB**  
See better. Live better.



## Block cross-infection without interfering with IOP.

Alcohol wipes are just not sufficient to prevent cross-infection on tonometer tips. Enter Tonosafe™ disposable prisms. According to a study in the British Journal *Eye*<sup>1</sup>, they're just as accurate as their reusable counterparts. Your patients will thank you, too, for not passing on bacterial thugs.

### *Order a Free Box of 20 Tonosafes*

Try Tonosafe disposable prisms for yourself. Call 1-800-787-5426, or visit **hs-tonosafe.com**

<sup>1</sup> The Scientific Journal of the Royal College of Ophthalmology

The Superior Practice.

# Contents

Review of Optometry May 2014

## 19<sup>th</sup> Annual Comanagement Report

### 52 Be a Neuro-ophth 'First Responder'

When the eye—and even the patient—hangs in the balance, prompt action and careful collaboration could save the day.

By Andrew J. Rixon, OD, and Andrew S. Gurwood, OD

### 38 Can You Crack These Tough Comanagement Cases?

When encountering a tricky case that might require other doctors, don't lead from behind—take charge of the comanagement effort. By Jane Cole and Colleen Mullarkey

### 44 Comanaging MIGS: The Birth of the Middle Class

No longer is surgery a high-risk, high-reward venture. Safer—but more modestly beneficial—options are emerging. Here's a look at the OD's role.

By Lisa M. Young, OD

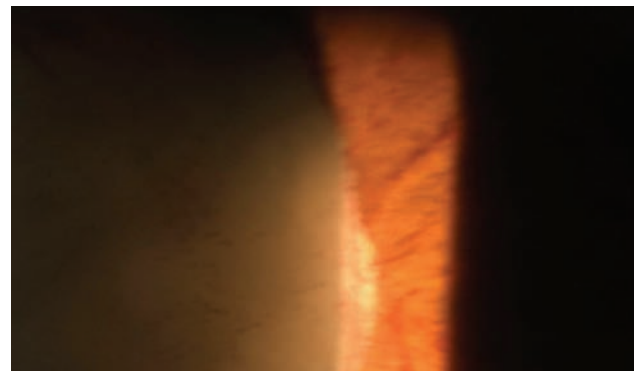
### 24 "Patients from Hell:" How Would You Handle These Awkward Encounters?

Needy, noncompliant, angry and obnoxious—these patients can turn an easygoing day into an impossible afternoon. Here's how to deal with them.

By Erin Kelly, Senior Associate Editor

### 30 Spotlight on Sickle-Cell Retinopathy

Know the essentials to treating and diagnosing this hereditary disorder. By Marlon J. Demeritt, OD, Diana L. Shechtman, OD, and Sherrol A. Reynolds, OD



### 61 Ocular Herpes Management: Simplex Made Simple

A detailed history and a thorough workup can make the diagnosis and treatment of herpes simplex keratitis a lot easier on you—and the patient. By William Marcolini, OD

### 68 CE Takes Center Stage at Vision Expo East

'Healthy bodies and healthy eyes' was a recurring theme at this year's VEE.

By Cheryl G. Murphy, OD, Contributing Editor


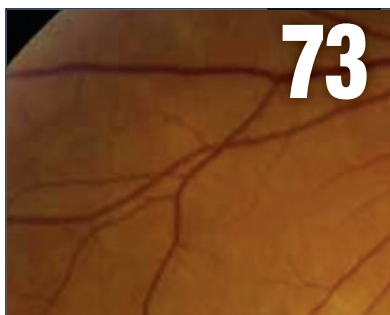


Earn 2 CE Credits:

# Departments

Review of Optometry May 2014

- 4** **News Review**
- 16** **Outlook**  
Conscious Coupling  
**JACK PERSICO**
- 18** **Chairside**  
Engineers Do It Better  
**MONTGOMERY VICKERS, OD**
- 20** **Coding Abstract**  
WTF About Fundus Photos?  
**JOHN RUMPAKIS, OD, MBA**
- 73** **Comanagement Q+A**  
Rock the Vogt  
**PAUL C. AJAMIAN, OD**
- 75** **Cornea + Contact Lens Q+A**  
The Bilateral Baffle  
**JOSEPH P. SHOVLIN, OD**
- 76** **Review of Systems**  
The Miniature Multitasker  
**CARLO J. PELINO, OD**  
**JOSEPH J. PIZZIMENTI, OD**
- 78** **Retina Quiz**  
A Disease of Diversity  
**MARK T. DUNBAR, OD**
- 81** **Therapeutic Review**  
NVG: A Titanic Disaster?  
**ALAN G. KABAT, OD**  
**JOSEPH W. SOWKA, OD**
- 84** **Product Review**
- 88** **Meetings + Conferences**
- 89** **Advertisers Index**
- 91** **Classifieds**
- 96** **Surgical Minute**  
Sealed for Your Protection  
**DEREK N. CUNNINGHAM, OD**  
**WALTER O. WHITLEY, OD, MBA**
- 98** **Diagnostic Quiz**  
A Rookie Mistake  
**ANDREW S. GURWOOD, OD**



## On The Web >>

Check out our multimedia and continuing education @ [www.revoptom.com](http://www.revoptom.com)

### Digital Edition



Left your *Review of Optometry* at the office? No problem! Access *Review* on your computer or mobile device!

Go to [www.revoptom.com](http://www.revoptom.com) and click on the digimag link to for the current issue.

### Facebook and Twitter



For daily updates, "Like" our page on Facebook or "Follow" us on Twitter!

- [www.facebook.com/revoptom](http://www.facebook.com/revoptom)
- <http://twitter.com/#!/revoptom>

# REVIEW<sup>®</sup>

OF OPTOMETRY



PRINTED IN U.S.A.

**FOUNDING EDITOR**  
FREDERICK BOGER  
1891-1913

#### EDITORIAL OFFICES

11 CAMPUS BLVD., SUITE 100  
NEWTOWN SQUARE, PA 19073

EMAIL • [REVIEWOFOPTOMETRY@JOBSON.COM](mailto:REVIEWOFOPTOMETRY@JOBSON.COM)

WEBSITE • [WWW.REVOPTOM.COM](http://WWW.REVOPTOM.COM)

#### SUBSCRIPTION INQUIRIES

1-877-529-1746

#### CONTINUING EDUCATION INQUIRIES

1-800-825-4696

**EDITOR-IN-CHIEF** • JACK PERSICO  
(610) 492-1006 • [JPERSICO@JOBSON.COM](mailto:JPERSICO@JOBSON.COM)

**EXECUTIVE EDITOR** • JOHN MURPHY  
(610) 492-1021 • [JMURPHY@JOBSON.COM](mailto:JMURPHY@JOBSON.COM)

**MANAGING EDITOR** • MICHAEL HOSTER  
(610) 492-1028 • [MHOSTER@JOBSON.COM](mailto:MHOSTER@JOBSON.COM)

**SENIOR ASSOCIATE EDITOR/WEB EDITOR** • ERIN KELLY  
(610) 492-1005 • [EKELLY@JOBSON.COM](mailto:EKELLY@JOBSON.COM)

**ASSOCIATE EDITOR** • FRANK AULETTA  
(610) 492-1043 • [FAULETTA@JOBSON.COM](mailto:FAULETTA@JOBSON.COM)

**DIRECTOR ART/PRODUCTION** • JOE MORRIS  
(610) 492-1027 • [JMORRIS@JOBSON.COM](mailto:JMORRIS@JOBSON.COM)

**ART DIRECTOR** • JARED ARAUJO  
(610) 492-1032 • [JARAUJO@JOBSON.COM](mailto:JARAUJO@JOBSON.COM)

**DIRECTOR OF CE ADMINISTRATION** • REGINA COMBS  
(212) 274-7160 • [RCOMBS@JOBSON.COM](mailto:RCOMBS@JOBSON.COM)

**SPECIAL PROJECTS** • JANE COLE  
(610) 492-1043 • [JCOLE@JOBSON.COM](mailto:JCOLE@JOBSON.COM)

#### EDITORIAL BOARD

**CHIEF CLINICAL EDITOR** • PAUL M. KARPECKI, OD  
**ASSOCIATE CLINICAL EDITORS** • JOSEPH P. SHOVLIN, OD;  
ALAN G. KABAT, OD; CHRISTINE W. SINDT, OD  
**DIRECTOR OPTOMETRIC PROGRAMS** • ARTHUR EPSTEIN, OD  
**CLINICAL & EDUCATION CONFERENCE ADVISOR** •  
PAUL M. KARPECKI, OD  
**CASE REPORTS COORDINATOR** • ANDREW S. GURWOOD, OD  
**CLINICAL CODING EDITOR** • JOHN RUMPAKIS, OD, MBA  
**CONSULTING EDITOR** • FRANK FONTANA, OD  
**EMERITUS CLINICAL EDITOR** • ROBERT M. COLE, III, OD

#### COLUMNISTS

**CHAIRSIDE** • MONTGOMERY VICKERS, OD  
**COMANAGEMENT Q+A** • PAUL C. AJAMIAN, OD  
**CORNEA & CONTACT LENS Q+A** • JOSEPH P. SHOVLIN, OD  
**DIAGNOSTIC QUIZ** • ANDREW S. GURWOOD, OD  
**GLAUCOMA GRAND ROUNDS** • JAMES L. FANELLI, OD  
**RESEARCH REVIEW** • PAUL M. KARPECKI, OD;  
DIANA L. SHECHTMAN, OD  
**RETINA QUIZ** • MARK T. DUNBAR, OD  
**REVIEW OF SYSTEMS** • CARLO J. PELINO, OD;  
JOSEPH J. PIZZIMENTI, OD  
**SURGICAL MINUTE** • DEREK N. CUNNINGHAM, OD;  
WALTER O. WHITLEY, OD, MBA  
**THERAPEUTIC REVIEW** • JOSEPH W. SOWKA, OD;  
ALAN G. KABAT, OD

**Jobson**  
Professional Publications Group

JOBSON MEDICAL INFORMATION LLC





For patients with decreased tear production presumed to be due to  
ocular inflammation associated with Chronic Dry Eye

## THE DRY EYE TREATMENT SHE NEEDS TODAY. BECAUSE TOMORROW MATTERS.



### RESTASIS® twice a day, every day, helps patients experience increased tear production

Increased tear production was seen at 6 months.<sup>1</sup>

#### Indication and Usage

RESTASIS® (cyclosporine ophthalmic emulsion) 0.05% is indicated to increase tear production in patients whose tear production is presumed to be suppressed due to ocular inflammation associated with keratoconjunctivitis sicca. Increased tear production was not seen in patients currently taking topical anti-inflammatory drugs or using punctal plugs.

#### Important Safety Information

##### Contraindications

RESTASIS® is contraindicated in patients with known or suspected hypersensitivity to any of the ingredients in the formulation.

##### Warnings and Precautions

**Potential for Eye Injury and Contamination:** To avoid the potential for eye injury and contamination, individuals prescribed RESTASIS® should not touch the vial tip to their eye or other surfaces.

**Use With Contact Lenses:** RESTASIS® should not be administered while wearing contact lenses. If contact lenses are worn, they should be removed prior to the administration of the emulsion.

##### Adverse Reactions

In clinical trials, the most common adverse reaction following the use of RESTASIS® was ocular burning (upon instillation)—17%. Other reactions reported in 1% to 5% of patients included conjunctival hyperemia, discharge, epiphora, eye pain, foreign body sensation, pruritus, stinging, and visual disturbance (most often blurring).

**Please see Brief Summary of the full Prescribing Information on adjacent page.**

Reference: 1. RESTASIS® Prescribing Information.



©2014 Allergan, Inc., Irvine, CA 92612  
® marks owned by Allergan, Inc.  
APC20AF14 141005

## RESTASIS® (Cyclosporine Ophthalmic Emulsion) 0.05%

BRIEF SUMMARY—PLEASE SEE THE RESTASIS® PACKAGE INSERT FOR FULL PRESCRIBING INFORMATION.

### INDICATION AND USAGE

RESTASIS® ophthalmic emulsion is indicated to increase tear production in patients whose tear production is presumed to be suppressed due to ocular inflammation associated with keratoconjunctivitis sicca. Increased tear production was not seen in patients currently taking topical anti-inflammatory drugs or using punctal plugs.

### CONTRAINDICATIONS

RESTASIS® is contraindicated in patients with known or suspected hypersensitivity to any of the ingredients in the formulation.

### WARNINGS AND PRECAUTIONS

#### Potential for Eye Injury and Contamination

To avoid the potential for eye injury and contamination, be careful not to touch the vial tip to your eye or other surfaces.

#### Use with Contact Lenses

RESTASIS® should not be administered while wearing contact lenses. Patients with decreased tear production typically should not wear contact lenses. If contact lenses are worn, they should be removed prior to the administration of the emulsion. Lenses may be reinserted 15 minutes following administration of RESTASIS® ophthalmic emulsion.

### ADVERSE REACTIONS

#### Clinical Trials Experience

Because clinical trials are conducted under widely varying conditions, adverse reaction rates observed in the clinical trials of a drug cannot be directly compared to rates in the clinical trials of another drug and may not reflect the rates observed in practice.

In clinical trials, the most common adverse reaction following the use of RESTASIS® was ocular burning (17%).

Other reactions reported in 1% to 5% of patients included conjunctival hyperemia, discharge, epiphora, eye pain, foreign body sensation, pruritus, stinging, and visual disturbance (most often blurring).

#### Post-marketing Experience

The following adverse reactions have been identified during post approval use of RESTASIS®. Because these reactions are reported voluntarily from a population of uncertain size, it is not always possible to reliably estimate their frequency or establish a causal relationship to drug exposure.

Reported reactions have included: hypersensitivity (including eye swelling, urticaria, rare cases of severe angioedema, face swelling, tongue swelling, pharyngeal edema, and dyspnea); and superficial injury of the eye (from the vial tip touching the eye during administration).

### USE IN SPECIFIC POPULATIONS

#### Pregnancy

##### Teratogenic Effects: Pregnancy Category C

Adverse effects were seen in reproduction studies in rats and rabbits only at dose levels toxic to dams. At toxic doses (rats at 30 mg/kg/day and rabbits at 100 mg/kg/day), cyclosporine oral solution, USP, was embryo- and fetotoxic as indicated by increased pre- and postnatal mortality and reduced fetal weight together with related skeletal retardations. These doses are 5,000 and 32,000 times greater (normalized to body surface area), respectively, than the daily human dose of one drop (approximately 28 mL) of 0.05% RESTASIS® twice daily into each eye of a 60 kg person (0.001 mg/kg/day), assuming that the entire dose is absorbed. No evidence of embryofetal toxicity was observed in rats or rabbits receiving cyclosporine at oral doses up to 17 mg/kg/day or 30 mg/kg/day, respectively, during organogenesis. These doses in rats and rabbits are approximately 3,000 and 10,000 times greater (normalized to body surface area), respectively, than the daily human dose.

Offspring of rats receiving a 45 mg/kg/day oral dose of cyclosporine from Day 15 of pregnancy until Day 21 postpartum, a maternally toxic level, exhibited an increase in postnatal mortality; this dose is 7,000 times greater than the daily human topical dose (0.001 mg/kg/day) normalized to body surface area assuming that the entire dose is absorbed. No adverse events were observed at oral doses up to 15 mg/kg/day (2,000 times greater than the daily human dose).

There are no adequate and well-controlled studies of RESTASIS® in pregnant women. RESTASIS® should be administered to a pregnant woman only if clearly needed.

#### Nursing Mothers

Cyclosporine is known to be excreted in human milk following systemic administration, but excretion in human milk after topical treatment has not been investigated. Although blood concentrations are undetectable after topical administration of RESTASIS® ophthalmic emulsion, caution should be exercised when RESTASIS® is administered to a nursing woman.

#### Pediatric Use

The safety and efficacy of RESTASIS® ophthalmic emulsion have not been established in pediatric patients below the age of 16.

#### Geriatric Use

No overall difference in safety or effectiveness has been observed between elderly and younger patients.

### NONCLINICAL TOXICOLOGY

#### Carcinogenesis, Mutagenesis, Impairment of Fertility

**Carcinogenesis:** Systemic carcinogenicity studies were carried out in male and female mice and rats. In the 78-week oral (diet) mouse study, at doses of 1, 4, and 16 mg/kg/day, evidence of a statistically significant trend was found for lymphocytic lymphomas in females, and the incidence of hepatocellular carcinomas in mid-dose males significantly exceeded the control value.

In the 24-month oral (diet) rat study, conducted at 0.5, 2, and 8 mg/kg/day, pancreatic islet cell adenomas significantly exceeded the control rate in the low-dose level. The hepatocellular carcinomas and pancreatic islet cell adenomas were not dose related. The low doses in mice and rats are approximately 80 times greater (normalized to body surface area) than the daily human dose of one drop (approximately 28 mL) of 0.05% RESTASIS® twice daily into each eye of a 60 kg person (0.001 mg/kg/day), assuming that the entire dose is absorbed.

**Mutagenesis:** Cyclosporine has not been found to be mutagenic/genotoxic in the Ames Test, the V79-HGPRT Test, the micronucleus test in mice and Chinese hamsters, the chromosome-aberration tests in Chinese hamster bone-marrow, the mouse dominant lethal assay, and the DNA-repair test in sperm from treated mice. A study analyzing sister chromatid exchange (SCE) induction by cyclosporine using human lymphocytes *in vitro* gave indication of a positive effect (i.e., induction of SCE).

**Impairment of Fertility:** No impairment in fertility was demonstrated in studies in male and female rats receiving oral doses of cyclosporine up to 15 mg/kg/day (approximately 2,000 times the human daily dose of 0.001 mg/kg/day normalized to body surface area) for 9 weeks (male) and 2 weeks (female) prior to mating.

### PATIENT COUNSELING INFORMATION

#### Handling the Container

Advise patients to not allow the tip of the vial to touch the eye or any surface, as this may contaminate the emulsion. To avoid the potential for injury to the eye, advise patients to not touch the vial tip to their eye.

#### Use with Contact Lenses

RESTASIS® should not be administered while wearing contact lenses. Patients with decreased tear production typically should not wear contact lenses. Advise patients that if contact lenses are worn, they should be removed prior to the administration of the emulsion. Lenses may be reinserted 15 minutes following administration of RESTASIS® ophthalmic emulsion.

#### Administration

Advise patients that the emulsion from one individual single-use vial is to be used immediately after opening for administration to one or both eyes, and the remaining contents should be discarded immediately after administration.

### Rx Only



Based on package insert 71876US17

© 2013 Allergan, Inc.

Irvine, CA 92612, U.S.A.

® marks owned by Allergan, Inc. APC37BD13

Patented. See [www.allergan.com/products/patent\\_notices](http://www.allergan.com/products/patent_notices)

Made in the U.S.A.

## CONTRIBUTING EDITORS

PAUL C. AJAMIAN, OD, ATLANTA  
JEFFREY R. ANSHEL, OD, CARLSBAD, CALIF.  
JILL AUTRY, OD, RPH, HOUSTON  
SHERRY J. BASS, OD, NEW YORK  
MILE BRUIJC, OD, BOWLING GREEN, OHIO  
WALTER L. CHOATE, OD, MADISON, TENN.  
ROBERT M. COLE, III, OD, BRIDGETON, NJ  
DEREK N. CUNNINGHAM, OD, AUSTIN, TEXAS  
ANTHONY S. DIECIDUE, OD, STROUDSBURG, PA.  
MARK T. DUNBAR, OD, MIAMI  
S. BARRY EIDEN, OD, DEERFIELD, ILL.  
ARTHUR B. EPSTEIN, OD, PHOENIX  
JAMES L. FANELLI, OD, WILMINGTON, NC  
FRANK FONTANA, OD, ST. LOUIS  
GARY S. GERBER, OD, HAWTHORNE, NJ  
ANDREW S. GURWOOD, OD, PHILADELPHIA  
MILTON HOM, OD, AZUSA, CALIF.  
ALAN G. KABAT, OD, FORT LAUDERDALE, FLA.  
PAUL M. KARPECKI, OD, LEXINGTON, KY.  
JEROME A. LEGERTON, OD, MBA, SAN DIEGO  
THOMAS L. LEWIS, OD, PHD, PHILADELPHIA  
DOMINICK MAINO, OD, MED, CHICAGO  
JASON R. MILLER, OD, MBA, POWELL, OHIO  
PAMELA J. MILLER, OD, JD, HIGHLAND, CALIF.  
CHERYL G. MURPHY, OD, HOLBROOK, NY  
JOHN W. POTTER, OD, MA, DALLAS  
CHRISTOPHER J. QUINN, OD, ISELIN, NJ  
JOHN L. SCHACHET, OD, ENGLEWOOD, COLO.  
JACK SCHAEFFER, OD, BIRMINGHAM, ALA.  
CAROL SCHWARTZ, OD, MBA, SAN JOSE DEL CABO, MEXICO  
JEROME SHERMAN, OD, NEW YORK  
JOSEPH P. SHOVLIN, OD, SCRANTON, PA.  
JOSEPH W. SOWKA, OD, FORT LAUDERDALE, FLA.  
LORETTA B. SZCZOTKA, OD, PHD, CLEVELAND  
MONTGOMERY VICKERS, OD, ST. ALBANS, W.VA.  
KATHY C. WILLIAMS, OD, SEATTLE

## EDITORIAL REVIEW BOARD

EDWARD S. BENNETT, OD, ST. LOUIS  
MARC R. BLOOMENSTEIN, OD, SCOTTSDALE, ARIZ.  
CHRIS J. CAKANAC, OD, MURRYSVILLE, PA.  
JERRY CAVALLERANO, OD, PHD, BOSTON  
BRIAN CHOU, OD, SAN DIEGO  
A. PAUL CHOUS, MA, OD, TACOMA, WASH.  
GLENN S. CORBIN, OD, WYOMISSING, PA.  
STEVEN FERRUCCI, OD, SEPULVEDA, CALIF.  
MURRAY FINGERET, OD, HEWLETT, NY  
IAN BEN GADDIE, OD, LOUISVILLE, KY.  
MATTHEW J. GARSTON, OD, BOSTON  
ROBERT M. GROHE, OD, HOMEWOOD, ILL.  
ANDREW S. GURWOOD, OD, PHILADELPHIA  
NICKY HOLDEMAN, OD, MD, HOUSTON  
MILTON HOM, OD, AZUSA, CALIF.  
WILLIAM L. JONES, OD, ALBUQUERQUE, NM  
ALAN G. KABAT, OD, FORT LAUDERDALE, FLA.  
PAUL M. KARPECKI, OD, LEXINGTON, KY.  
RICHARD B. MANGAN, OD, LEXINGTON, KY.  
RON MELTON, OD, CHARLOTTE, NC  
BRUCE MUCHNICK, OD, COATESVILLE, PA.  
MARC MYERS, OD, COATESVILLE, PA.  
CARLO J. PELINO, OD, JENKINTOWN, PA.  
JOSEPH PIZZIMENTI, OD, FORT LAUDERDALE, FLA.  
WILLIAM B. POTTER, OD, FREEHOLD, NJ  
JOHN RUMPAKIS, OD, MBA, PORTLAND, ORE.  
MICHAEL C. RADOIU, OD, STAUNTON, VA.  
LEO P. SEMES, OD, BIRMINGHAM, ALA.  
DIANA L. SHECHTMAN, OD, FORT LAUDERDALE, FLA.  
LEONID SKORIN, JR., OD, DO, ROCHESTER, MINN.  
JOSEPH W. SOWKA, OD, FORT LAUDERDALE, FLA.  
RANDALL THOMAS, OD, CONCORD, NC  
WALTER O. WHITLEY, OD, MBA, VIRGINIA BEACH, VA.

IN THE NEW ERA OF MANAGED CARE,  
**WHAT'S YOUR PLAN**  
**TO WIN:**

- More Patients
- More Profits
- More Time
- All of the Above

Go To **VisionSourcePlan.com** and  
We'll Give You Ours





# Conscious Coupling

Comanagement efforts work best when each party brings mutual respect and a spirit of collaboration to the enterprise. **By Jack Persico, Editor-in-Chief**

No sooner had Gwyneth Paltrow coined the phrase “conscious uncoupling”—a typically Hollywood euphemism for what anyone else would call *divorce*—than it had become a cliché. The Internet erupted in snarky comments and riffs on the concept. Even the fusty old *Economist* joined in the fun, using the phrase to describe Europe’s delicate pullback in its relations with Russia after the Crimea takeover.

I’ll bet you can think of a few professional partners you’d like to consciously uncouple from, like mediocre vision plans that put their interests above your own. But as we turn our attention to comanagement for this month’s 19th annual report on the topic, “conscious *coupling*” seems to be the watchword. Optometry is more integrated into the fabric of medical care than ever before, and needs to work at keeping those relationships strong.

Consider how far we’ve come on this front. As noted in a sidebar on page 41, back in 1984 this publication profiled the Omni model of diagnostic referral centers, a concept that rightfully can be called a game-changer in the history of optometric practice. It was among the first models of comanagement that allowed optometrists to be integral to the delivery of ocular disease care without losing patients to ophthalmology practices.

But, 30 years ago, the language we used to discuss comanagement was a tad belligerent. “Optometry is trying out a promising new strat-

egy in its war with ophthalmology: Cutting off its supply lines,” began that 1984 article. Chalk it up to the antagonism of the times, as TPA legislative efforts were a source of much vitriolic back-and-forth.

Eleven years later, in 1995, we launched an annual comanagement-themed issue to help ODs harness their burgeoning power as primary eye care providers. In another sign of the times, our inaugural comanagement issue focused on how to ensure optometric involvement in the brand-new field of excimer laser refractive surgery procedures.

Again, the tone was perhaps a bit combative. “There’s no question that, down the line, optometrists could be cut out of the picture,” one source observed. “Consumer marketing by PRK companies may eventually drive patients right into their centers, bypassing the independent practitioners.” Optometry survived refractive surgery’s well-known boom and bust just fine, and still plays a central role in educating patients about LASIK and managing their eye care postoperatively.

Over the years, the focus of our comanagement coverage moved to the ocular and systemic health issues that are most pressing in the 21st century: age-related eye disease, diabetes and other systemic health risks. Neuro-ophthalmic emergencies grace the cover of our 19th comanagement report, and I’m pleased that the tone is positive and collaborative, featuring optometrists who have earned the trust of ophthalmologists and internists.

## Coming This Summer: The Empire Strikes Back?

What might derail this détente? A controversial website will begin to offer online refractions this summer, and it’s courting ophthalmologists to be “network partners.” Benefits to the MDs include “passive income and/or a steady patient flow into your office” and a chance to “be a part of the biggest change in eye care!” Optometrists get no such invitation, at least on the website.

Will ophthalmologists go along, in a push for greater efficiency—and maybe to strike back at optometry?

Let’s hope not, for everyone’s sake. Just consider the inability of an online vision test to screen for eye diseases. The site’s consumer testimonials are sure to irritate most optometrists—and, I hope, ophthalmologists, too. One early user touts it as “incredibly convenient and incredibly accurate in its assessment of my vision.” Another declares that “this is by far the easiest and fastest way to get an accurate prescription.” Fast, yes. Accurate? Hmm. Thorough exam? Surely not.

Several MDs just helped get Arizona’s TPA expansion law passed. That’s the kind of multidisciplinary unity that deserves, well, some conscious coupling if it is going to last.

As optometric scope of practice victories continue to be won, perhaps its time to beat those swords into ploughshares and work for the common good of both professions. And maybe even the decades-long OD-MD rivalry might one day have a Hollywood ending. ■





# ANATOMY OF A GREAT EXAM LANE

*Quality or Value - go ahead you can have both*

S4OPTIK products are the perfect blend of extraordinary Value and Quality. Instruments which satisfy even the most discerning practitioner.

## H + Z SERIES SLIT LAMPS

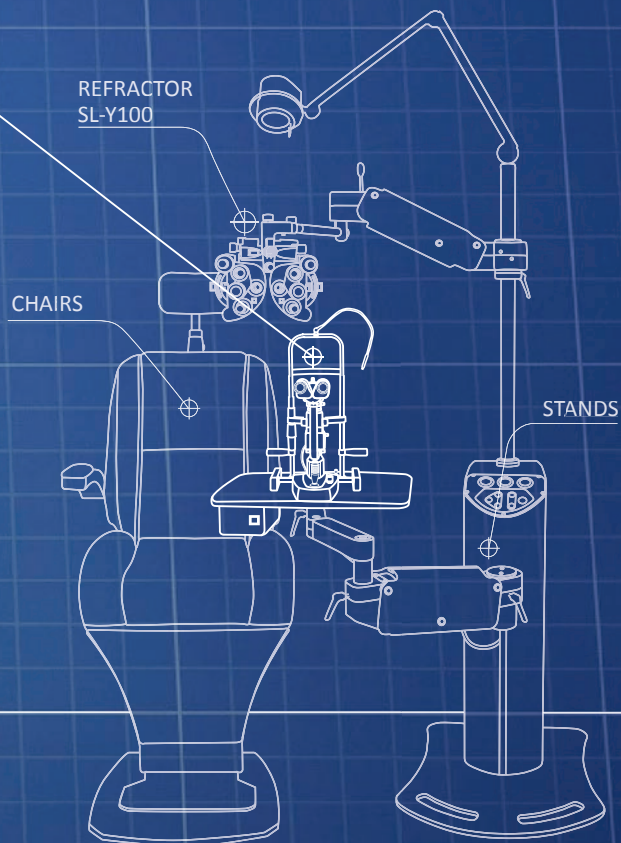
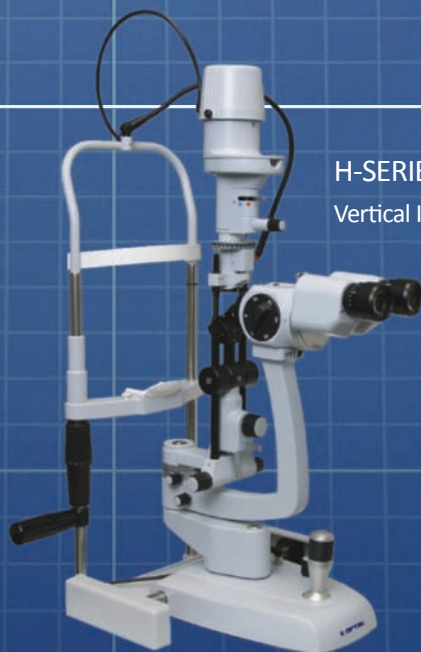### Z-SERIES

Compact Illumination Models



### H-SERIES

Vertical Illumination Models



### SLIT LAMP FEATURES

- Multilayered anti-reflective coatings
- Stunning optical quality allowing clear visualization and depth of field
- 20% increase in optical transmission
- 10% increase to the depth of field

[www.s4optik.com](http://www.s4optik.com) | [info@s4optik.com](mailto:info@s4optik.com)

# Engineers Do It Better

Just don't ask them what "it" is, because they'll be happy to explain "it" to you. They'll also tell you you're doing "it" wrong and how to do "it" right. **By Montgomery Vickers, OD**

I love engineers. There's this optometric legend that engineers are notoriously difficult to please. I have found this to be patently false.

However, *never* say the word "patent" unless you have an hour to listen to descriptions of the 432 patents that your engineer has and how each one solved some glitch. Try instead, "Your tear duct is *open*," or you will be schooled in valve reversal gradient theory.

You will also get "the look." You know the look. It's the one that an engineer gives you when you suggest he might consider a PAL instead of his tried-and-true flat-top trifocal—the look that hovers between bemusement and disgust. What are you? Stupid?

To avoid "the look," here are some ways to communicate with engineers to make your life easier:

**1. Use initials.** AMD. SLK. IOL. LOL. PPM. M-I-C-K-E-Y. Just leave 'em hanging in the air like ripe peaches. Oh, and be prepared to explain what they stand for, unless you want your ego emulsified like peach puree blended at 1,000 RPMs.

**2. Say "I don't know" when you don't know.** You cannot BS a PhD in civil engineering. I have two BS degrees and I am as helpless as a newborn blind fawn if an engineer figures out I'm full of crap. My favorite response is, "If I knew that, I'd win the Nobel Prize in Medicine." (Oh, but make sure your engineer has not actually won a Nobel Prize. Nobel Prize

winners are notorious condescending braggarts.)

**3. Smile.** I know this seems lame in the face of a skeptical engineer, but I've learned that engineers have hearts too. They may even smile back when confronted with a genuinely kind smile that is less than two meters from their own plane of reference.

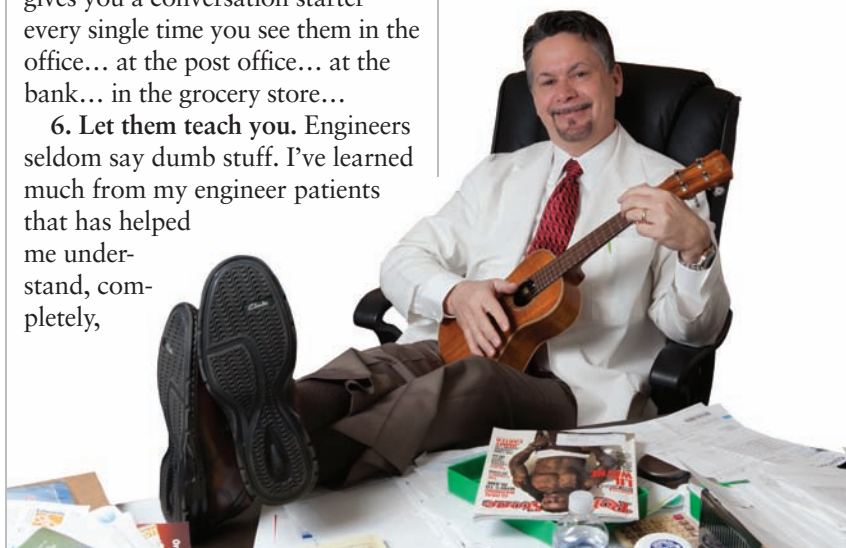**4. NEVER NEGOTIATE THE FEE!** Lordy, engineers always ask about this. Now, does their training turn them into pennypinchers, or were they always folks who wore the same pocket protector, same blue button-down shirt and same saggy khaki pants for their 30-year career, into retirement, and at their own funeral?

**5. Get this through your thick skull: Their seg height is *not right!*** Doesn't matter where you put it. High... low... on center... 3 below. It's wrong. The good news is this gives you a conversation starter every single time you see them in the office... at the post office... at the bank... in the grocery store...

**6. Let them teach you.** Engineers seldom say dumb stuff. I've learned much from my engineer patients that has helped me understand, completely,

that it is good that we have these folks engineering all over the place. I have also learned that the world is a better place that THEY are engineers and that I am NOT an engineer.

**7. Engineers will adore your OCT.** My OCT even comes with a folder that explains how the stupid thing works just in case the engineer there asks you how it works. Of course, that becomes a 30-minute delay as they chat about Fourier Domain Analysis. Fortunately, you can get around this by saying: "I can't even get my toilet to flush right and some brilliant engineer figured out how to make near infrared light show me the layers of the retina." When they proudly grin, **RUN FROM THE ROOM** and just pray they follow! Let your receptionist listen to the engineer's analysis of the Fourier Domain Analysis analysis. ■



19<sup>TH</sup> ANNUAL  
OPHTHALMIC  
PRODUCT  
GUIDE



Innovative products to  
enhance your practice

The **future**  
is in your  
hands. One  
tap, many  
possibilities.

Experience the digital edition on your handheld device.  
Use your smart device to scan the code below or visit:



[www.revoptom.com/supplement\\_toc/s/259/](http://www.revoptom.com/supplement_toc/s/259/)

Download a QR scanner app. Launch app and hold your mobile device over  
the code to view [http://www.revoptom.com/supplement\\_toc/s/259/](http://www.revoptom.com/supplement_toc/s/259/).

**REVIEW**<sup>®</sup>  
OF OPTOMETRY



# WTF About Fundus Photos?

Can retinal screening be coded and billed as fundus photography? What're The Facts?

By John Rumpakis, OD, MBA, Clinical Coding Editor

It's time for another WTF column. (Keep in mind that WTF stands for "What're The Facts?") This time, the facts focus on some recent buzz about fundus photography (CPT code 92250).

A recent webinar on diabetic screening indicated that the Centers for Medicare & Medicaid Services (CMS) and the American Academy of Ophthalmology had formal positions regarding the use of specific instrumentation to qualify an image as a fundus photograph.

Unfortunately, for many who attended the webinar, the information was misleading and led to a significant amount of confusion about which instruments could or could not be used for a fundus photograph.

So, what're the facts?

## No CMS Policy

According to my research, CMS does not currently have any national policy regarding specific instrumentation that can be used as a fundus camera. Remember that the Current Procedural Terminology (CPT), developed by the American Medical Association, defines a procedure and then CMS develops coverage rules and reimbursements based on that definition.

CPT defines code 92250 as: "Fundus photography with interpretation and report."<sup>1</sup> It doesn't specify if it is stereo or not, if it has to be recorded on film or digitally, and so forth.

However, one CMS carrier—

Palmetto GBA (not CMS, as represented in the webinar) whose geographical jurisdiction includes Virginia, West Virginia, North Carolina and South Carolina—does have a local coverage determination that states: "Fundus photography uses a special camera to photograph structures behind the lens of the eye, including vitreous, retina, choroids and optic nerve. This procedure does not include laser scanning of the retina."<sup>2</sup>

The presenters of the webinar apparently interpreted this to mean that any instrument that uses a laser would not qualify as a fundus camera, therefore an image created by a laser would not qualify as a fundus photograph. In my opinion, the intent of this carrier's language was to prevent incidental images produced by an OCT instrument from being billed as a fundus photograph—not to dictate which type of instrumentation must be used for fundus photography.

Subsequently, the carrier has been asked to clarify its policy and provide additional guidance.

## No AAO Position

The second statement and reference contained within the webinar was an implication that the American Academy of

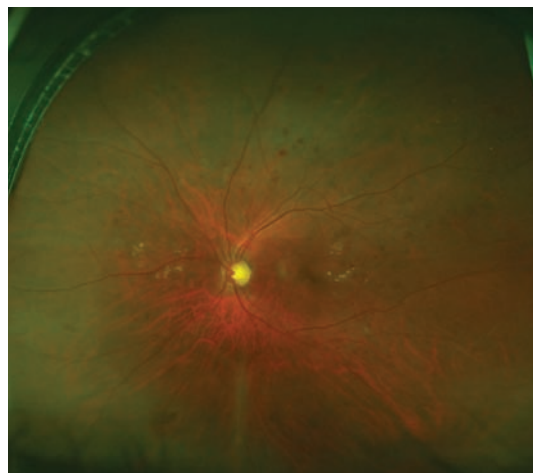


Image: Optos

**A recent webinar on diabetic screening has raised questions about whether certain screening imaging qualifies as a fundus photo for billing purposes.**

Ophthalmology had taken a formal stance as an organization on this specific fundus photography issue. In checking the reference provided in the webinar, that is not the case.

The actual reference was an article written by an AAO Coding Executive that stated "The Optos Optomap is image-assisted ophthalmoscopy for evaluation of ocular health. It does not meet the criteria for the CPT code for fundus photography (92250) or the codes for OCT of the posterior segment (92133 for the optic nerve; 92134 for the retina). If you rely on the Optos technique, rather than dilating the patient, then you must bill a lower level eye code or E&M exam. The Optos can be used for a non-covered screening exam, in which case the patient is responsible for payment."<sup>3</sup>

Again, in my opinion, this is not

# icare

news. The basic Optos has never been advocated for use with CPT code 92250 or as a replacement for dilation. Rather, it has been used as a screening device and with the code S9986 (not medically necessary services). It is always paid for by the patient regardless of any pathology discovered, and should not be converted into a billable (carrier-responsible) procedure based on findings.

Be aware that the Optos devices, as well as other manufacturers' devices, have the capability to do more than one type of test. Any secondary (medical) test must meet the requirement of medical necessity, must be ordered by the physician, must produce additional information that wasn't available in the screening image, and requires an interpretation and report to be billable to a medical carrier.

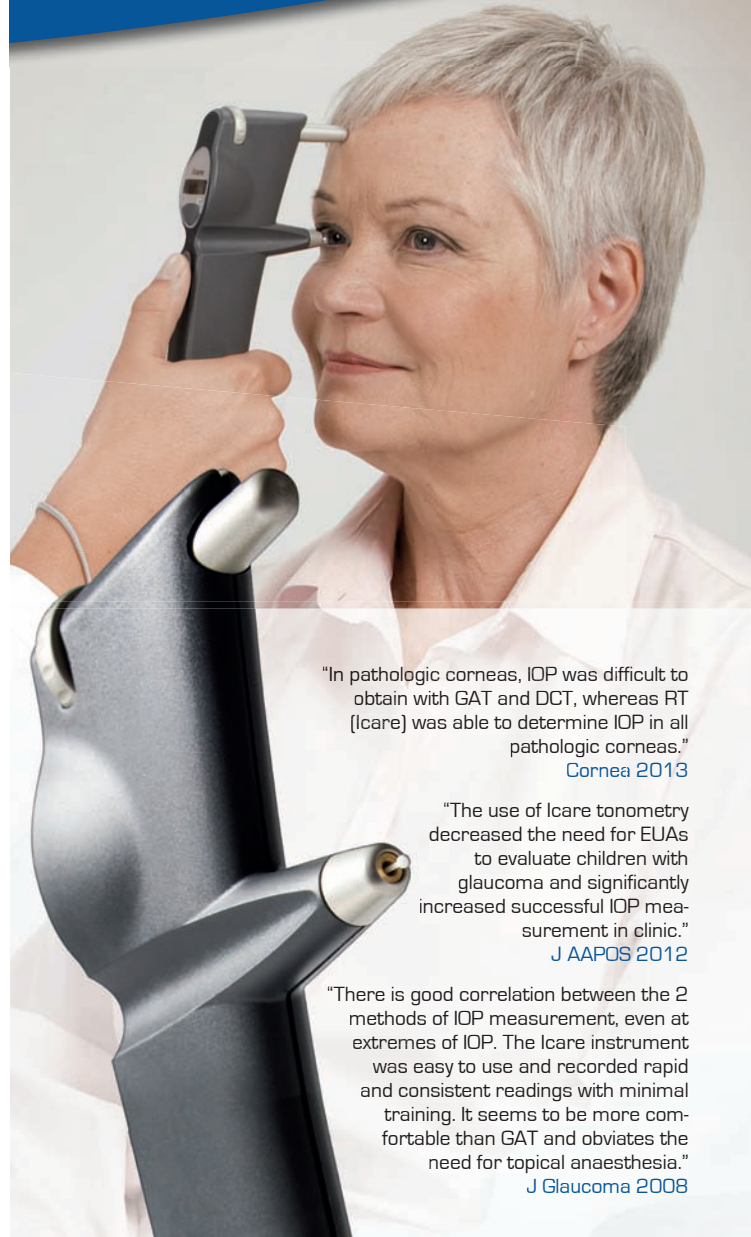
Although Optos was singled out in the Academy publication, this requirement applies to all devices that provide both screening and non-screening services. There are numerous instruments, in addition to Optos, that capture retinal images (not OCT) that use "scanning laser technology" for image acquisition, and thousands of optometrists and ophthalmologists have been properly billing for and being reimbursed for 92250 with them. Nowhere within this referenced article did the American Academy of Ophthalmology state that "use of pseudo-photography does not meet the requirements for the billing of 92250" as represented in the webinar. (In fact, neither CMS nor the AAO refer to the term "pseudo-photography" as referenced in the webinar.)

Technology is developing at an accelerating rate in our profession. Rules and regulations should always be vetted by the practicing physician before using any technology in practice. Keep in mind that rules are geographically specific and that you, not the salesperson or anyone else, is responsible for knowing and following them.

I'm sure that this is not the last statement on this currently controversial topic, but for the time being, I needed (and so did you) to know WTF. ■

*Please send your questions and comments to [CodingAbstract@gmail.com](mailto:CodingAbstract@gmail.com).*

1. CPT 2014 Professional Edition. Chicago, IL: American Medical Association. 2013: 538.
2. Centers for Medicare & Medicaid Services website. Available at: [www.cms.gov/medicare-coverage-database/details/lcd-details.aspx?LCDId=32953&ContrlId=233&ver=8&ContrlVer=1&CntrctrSelected=233\\*1&Cntrctr=233&name=Palmetto+GBA+\(11502%2c+MAC++Part+B\)&DocType=Active&LCntrctr=233\\*1&bc=AgCAAIAAAAAA%3d%3d&](http://www.cms.gov/medicare-coverage-database/details/lcd-details.aspx?LCDId=32953&ContrlId=233&ver=8&ContrlVer=1&CntrctrSelected=233*1&Cntrctr=233&name=Palmetto+GBA+(11502%2c+MAC++Part+B)&DocType=Active&LCntrctr=233*1&bc=AgCAAIAAAAAA%3d%3d&) Accessed April 3, 2014.
3. Vicchirilli S. Testing Services, Part One: Selecting the CPT Code. EyeNet. 2012 May; 61. Available at: [www.aao.org/publications/eyenet/201205/upload/Coding-for-Testing-Services-Part-One-CPT-Codes-PDF.pdf](http://www.aao.org/publications/eyenet/201205/upload/Coding-for-Testing-Services-Part-One-CPT-Codes-PDF.pdf). Accessed April 14, 2014.



"In pathologic corneas, IOP was difficult to obtain with GAT and DCT, whereas RT [icare] was able to determine IOP in all pathologic corneas."  
Cornea 2013

"The use of Icare tonometry decreased the need for EUAs to evaluate children with glaucoma and significantly increased successful IOP measurement in clinic."  
J AAPOS 2012

"There is good correlation between the 2 methods of IOP measurement, even at extremes of IOP. The Icare instrument was easy to use and recorded rapid and consistent readings with minimal training. It seems to be more comfortable than GAT and obviates the need for topical anaesthesia."  
J Glaucoma 2008

**FAST, EASY, PAINLESS.  
GOOD COMPLIANCE AND  
RELIABLE RESULTS.**



**NO ANESTHESIA  
NO AIR PUFF**

[www.icare-usa.com](http://www.icare-usa.com)

# Guarding Your Patients' Eyes from Harmful Light

## Part Three: Point-Counterpoint

By Mark Dunbar, OD, and Diana Shechtman, OD

Parts one and two of this three-part series reviewed the risks and benefits associated with ultraviolet (UV) and blue light, as well as how different factors play a role in protecting and preventing against the development of age-related macular degeneration. The final article in this series rounds out the discussion of the effects of UV and blue light on eye health with an engaging point-counterpoint.

**L**ight is a biological requirement essential to health. As practitioners, we know that light is both beneficial and harmful to vision and to our patients' overall health. Too much light exposure can lead to cumulative damage to the eye tissue. Ultraviolet (UV) light can damage the cornea and the lens, and at certain wavelengths, blue light can damage the retina and is a risk factor for age-related macular degeneration (AMD). Light also plays an essential role in visual functions, such as color perception, contrast sensitivity and visual acuity, as well as sleep-wake cycles.

In this article, Mark T. Dunbar, OD, and Diana Shechtman, OD, debate the significance of blue light and whether current blue-blockers and No-Glare (anti-reflective, or AR) lenses are doing a sufficient job in protecting patients' vision against these potentially harmful forms of light.

### Topic #1: Indoor Exposure to Blue Light

**B**lue light is part of the visible light spectrum, and like UV, is present everywhere: both indoors and outdoors. Solar radiation consists of 25% to 30% blue light, but what about indoor exposure to blue light?

**POINT (Dr. Shechtman): The amount of blue light received indoors is not significant.** We are all aware of the role of UV radiation in the development of a host of ocular conditions. Most UV light is absorbed by the cornea and lens, and hence excess exposure over time may play a role in the pathogenesis of conditions such as pterygium and cataracts. On the other hand, indoor light, which is in part comprised of high-energy blue-violet visible light lying just outside the UV band, is not filtered out by the cornea or lens. Hence, blue light is recognized as being harmful to the posterior segment tissue (such as the retina). Blue light may in fact result in cellular oxidative stress, which has been linked to conditions such as AMD.

While direct correlation between blue light and AMD remains controversial, a number of epidemiological studies, including the Beaver Dam Study, contribute to the fact that cumulative exposure to blue light increases the risk of AMD.<sup>1,2</sup> Yet, photochemical damage of the retina resulting from blue light still remains uncertain.

**COUNTERPOINT (Dr. Dunbar):** According to the literature, the amount of blue light from LED and compact fluorescent light (CFL) sources is substantial and can pose a risk of retinal damage to the eye.<sup>3</sup> Many of these devices emit an extremely high level of blue light. Approximately 26% of the light from the energy-efficient and increasingly popular CFLs is in the blue portion of the spectrum, and 35% of the optical radiation from cool white LEDs is blue.<sup>4</sup>

By 2020, it is estimated that 90% of all light sources will be based on LED products and LED light is expected to increase in residential settings by 50% for 2016 and 70% for 2020.<sup>5</sup> Moreover, by 2016, traditional incandescent light sources will, by law, no longer be available for domestic lighting in Europe.<sup>6</sup> LEDs are also becoming progressively more popular in backlit mobile phones, televisions, and computer displays.<sup>6</sup> Note: the cooler the white LED, the higher the blue proportion.

### Topic #2: No-Glare Lenses vs. Blue Blockers

**W**hile the need for good preventative measures is given urgency by the rapid growth of the elderly population and the prevalence of AMD within that population, the effects of chronic UV and blue light exposure on the cornea and lens are cumulative, so effective protection of the eyes is important for all age groups. Typically, we turn to No-Glare lenses or blue-blocking lenses for this task.

**POINT (Dr. Dunbar): No-Glare lenses are not as effective as more traditional “blue blockers”.**

Several new products and technologies have been developed to protect our patients' eyes from blue light's harmful effects, including specialized spectacle lenses. The early blue blockers typically featured amber lenses that filtered out 100% of all blue light. Today, the traditional melanin-tinted blue blockers have advanced and are designed to protect the eyes from blue light, improve contrast, reduce eye fatigue and maintain color balance. These lenses contain melanin and deflect 45% of the blue light spectrum, so for argument's sake, No-Glare lenses are not as effective as blue-blocking lenses.

**COUNTERPOINT (Dr. Shechtman):** Remember, not all blue light is believed to be harmful. In fact, visible light is a necessity for functional vision, including color vision discrimination. Studies have isolated a specific narrow band of blue light (435 nm ± 20 nm), which may contribute to AMD. Thus, selectively blocking the deleterious blue light bands while preserving visual function is critical.

An optimal solution would preserve visual function while effectively blocking detrimental blue light. This may potentially provide a major breakthrough within the ophthalmic community. Today, Essilor's Crizal® Previncia™ No-Glare lenses selectively deflect the blue light wavelengths that can damage retinal cells, while maintaining transmittance of visible blue light that is essential for color vision discrimination, as well as critical chronobiological processes. Crizal® Previncia™ No-Glare lenses offer the most selective eye protection on the market today. Patients wearing these lenses benefit from increased comfort, enhanced clarity and durability while also protecting their eyes.

### Topic #3: Reducing Blue Light Exposure

The serious dangers that UV radiation presents to eyes are well established, but scientists and clinicians are now aware of the damage that long-term exposure to blue light may cause to retinal photoreceptors.

**POINT (Dr. Dunbar): A 20% reduction in harmful blue light is not significant enough.** Exposure to high-energy blue light is likely to increase significantly as people convert from incandescent and halogen lighting. Also, the growing use of digital products has increased our daily exposure to blue wavelengths.

As stated earlier, most UV light primarily affects the anterior portion of the eye, so the UV protection ratings of spectacle lenses primarily measure light transmitting to parts of the eye such as the cornea and crystalline lens. However, high-energy blue light reaches deeper into the eye, and its cumulative effect can cause damage to the retina. Thus, the reduction in harmful blue

light of a spectacle lens should also be measured to ensure it is significant enough to help protect against the exposure that will “accumulate” and possibly cause damage in the long term.

**COUNTERPOINT (Dr. Shechtman):** Certain wavelengths of blue light are necessary for color perception and physiological functions such as the regulation of circadian rhythms; therefore, selectively blocking only the dangerous band(s) of blue light is critical.

To delineate the damaging bands within the blue light spectrum, research scientists from Essilor partnered with the Paris Vision Institute to create an *in vitro* model for the study of retinal phototoxicity.<sup>7</sup> This seminal research found a damaging band of blue light (Blue-Violet). Many other studies support the benefit of Blue-Turquoise light that is necessary for visual acuity and color perception. Our industry has launched groundbreaking new lens technologies, such as Crizal® Previncia™ No-Glare lenses, which block the harmful Blue-Violet light but allow the beneficial Blue-Turquoise light in, thus the superior selective filtering.

Crizal Previncia lenses are proven to deflect harmful Blue-Violet light by 20%.<sup>8</sup> This number is significant, as the Paris Vision Institute's research also showed that this amount of deflection reduced retinal cell death by 25%.<sup>9</sup> No other lens on the market offers this much deflection and protection from the specific harmful Blue-Violet wavelengths. Additionally, this 20% reduction mirrors what we expect with AREDS formulations that we recommend to our patients.

*Dr. Dunbar serves as the director of Optometric Services and the optometric residency supervisor at the University of Miami's Bascom Palmer Eye Institute.*

*Dr. Shechtman is an associate professor of Optometry at Nova Southeastern University College of Optometry, where she serves as an attending optometric physician at the eye institute and diabetic/macula clinic.*

1. Sunlight and the 10-year incidence of age-related maculopathy. The Beaver Dam Eye Study. *Arch Ophthalmol.* 2004;122:750-757.
2. Sui GY, Liu GC, Deng Y, et al. Is sunlight exposure a risk factor for age-related macular degeneration? A systemic review and meta-analysis. *Br J Ophthalmol.* 2013;97(4):389-94.
3. Light-emitting diodes in retinal and eye research. 30 (2011)239-57.
4. Barrau C, Villette T, Cohen-Tannoudji D. Blue light: Scientific discovery. *Essilor.* 2013 February; 1-49.
5. Lighting the way: perspectives on the global lighting market. Second edition. August 2012. McKinsey & Company Inc.
6. Behar-Cohen F, Martinsons C, Viénot F, et al. Light-emitting diodes (LED for domestic lighting: any risks for the eye? *Prog Retin Eye Res.* 2011;30(4):239-57.
7. Blue light hazard: New knowledge, new approaches to maintaining ocular health. Report of a Roundtable. March 16, 2013, New York City, NY, USA.
8. Arnault E, Barrau C, Nanteau C, et al. Characterization of the blue light toxicity spectrum on A2E-loaded RPE cells in sunlight normalized conditions. Poster presented at: Association for Research and Vision in Ophthalmology Annual Meeting; May 5-9, 2013; Seattle, Wash.
9. Smick K, et al. Blue light hazard: new knowledge, new approaches to maintaining ocular health. Report of a roundtable sponsored by Essilor of America. March 16, 2013, NYC, NY.

The opinions expressed in this supplement to *Review of Optometry*® do not necessarily reflect the views, or imply endorsement, of the editor or publisher. Copyright 2014, Jobson Medical Information LLC. All rights reserved.

# “Patients From Hell”

## How Would You Handle These Awkward Encounters?

Needy, non-compliant, angry and obnoxious—these patients turn an easygoing day into an impossible afternoon. Here’s how to deal with them.

By Erin Kelly, Senior Associate Editor

**A** new patient—let’s call her Jane—recently requested a same-day appointment at the New Jersey practice of Sara Erlich, OD. The staff fit her in, despite a busy day and crowded schedule, because Jane implied that it was an emergency. When Jane arrived, she deemed the discussion of her medical history unnecessary for “only an optometrist,” and told

**“This patient wasn’t worth even the referrals she brought to my office.”**

Dr. Erlich that she didn’t know her multifocal contact lens prescription. The discussion of costs made her combative; she insisted ODs were “scamming the public with their pretend fitting fees.”

At the end of the hour-long exam, Jane revealed that she had her prescription all along. She just wanted to “test” Dr. Erlich’s skills as an optometrist.

“She then pulls out her check-

book, pays me half-price for the multifocal exam, but states that my exam was far better and more thorough than any ophthalmologist she’s ever seen and she’s going to refer her entire office to me,” Dr. Erlich says. “To me, this patient wasn’t worth even the referrals she brought to my office.”

Chances are, you’ve encountered a Jane or two at some point in your career.

You don’t have to be an OD very long before problem patients find their way in your exam lane—those who

refuse to properly care for their contact lenses, linger in the chair with a hundred questions they gleaned from the Internet, refuse to comply with medical recommendations, or throw tantrums over your fitting fees.

“Some people are genuine jerks and others just have complex clinical issues that interfere with commonly accepted social behaviors,” says Gary Gerber, OD, of the

consulting firm The Power Practice. “Others have stuff going on in their private lives, and the OD’s practice is, unfortunately, a target on that particular day.”

### The Angry Patient

Whether it’s fitting fees, new prescriptions or a long wait, disgruntled patients can find something to make them angry. Fees are a common trigger.

Patients with vision insurance often assume that their visit will be 100% covered, according to Jack Schaeffer, OD, of Birmingham, Ala. “That’s just not possible, especially with contact lens fees,” Dr. Schaeffer says. “So, we deal with all that at the front-end. We tell them up front what all our fees and services are.”

Rather than facing the prospect of an upset patient later, Dr. Schaeffer’s practice gives them the opportunity to choose a practice more in line with what they need.

“We make sure everybody’s on the same page, and we do everything with a smile.”



The **world's first**  
and only silicone hydrogel,  
daily disposable family.



Affordable Innovation

SINGLE VISION

ASTIGMATISM

PRESBYOPIA



Exclusively for Eye Care Professionals

For more information contact Sauflon at:  
T: 800-682-3240 E: [info@sauflon.com](mailto:info@sauflon.com) [www.sauflonusa.com](http://www.sauflonusa.com)

## Takeaway Tips

Few ODs go their entire careers without encountering difficult patients. Here are a few survival tips to help avoid—or at least manage—the battles.

- **Be proactive.** This is probably the most effective way to avoid future problems. Explain any fees, difficult treatment regimens or uncomfortable therapies up front. Make sure the patient understands what to expect.
- **Be honest.** Don't sugarcoat for their benefit. Tell them about their condition. Again, it's all about giving them realistic expectations.
- **Show patience and understanding.** This can be tricky, but try to be as tolerant and patient as possible. You never know what kind of emotional baggage a patient carries into your office.
- **Develop and/or maintain company policy.** You should have specific policies in place, including a mission statement. These guidelines not only help you understand your practice's boundaries—they help your staff. It's effective to know the core mission of your practice, and how you plan to carry it out.
- **Have well-trained staff.** Your staff helps create a positive practice environment. When they're well trained and have a positive, synergistic relationship, it can help deflect some common problems. Make sure they understand how to deal with tricky personalities—and then make sure they do it professionally and effectively.
- **Practice reflection.** Interrupt factual exchanges to acknowledge a patient's emotional state. Reflective statements, such as "I can see this is upsetting to you," identify the observed emotions of patients. These statements show the patient that it's okay to talk about their concerns and fears.
- **Legitimize the experience.** For example: "I can understand why this upset you." You don't have to agree with the patient, but instead demonstrate a willingness to understand the situation from their point of view.
- **Partner with the patient.** This technique can be used to increase a patient's participation in their own care by involving them in the decision-making processes. An example: "After we finish the examination, let's see if we can come up with some solutions."

Building patient rapport is as important as any prescription, says Andrew Gurwood, OD, of Salus University in Philadelphia.

Dr. Gurwood has treated patients in a variety of environments and has taught patient communication with Neal Nyman, OD, at Salus University. In Dr. Gurwood's experience, patients who are angered when they don't get the results they expected from a prescription or procedure respond positively when the clinician recognizes their concerns.

His suggestion: Tell the patient that you understand and explain what you can do for them, without reacting to their anger.

"When patients encounter unex-

pected responses from their physician, they can become offended or defensive," Dr. Gurwood says. "A physician should always display a calm and situational appropriate demeanor."

It's also critical to be honest with patients about what they can and should expect.

"The doctor should give patients the facts. Explaining things and providing clarity is as important a task as gathering and analyzing the exam data," he says. "I always try to be honest and straight-forward. If I have to tell patients bad news, I try to keep the explanation simple and always include the potential solutions and prognosis. I try to make sure patients understand

what to expect, how quickly or how long it will take their malady to go away and how completely it will go away. For my own peace of mind I always end the interaction with three important 'check' questions: Was everyone in the office nice to you? Did I answer all your questions? When I answered your questions, did I give you an answer that you understand?"

Unfortunately, even the most proactive approach won't placate some patients. There are rare occurrences when you're faced with an unreasonable individual.

"This is a patient that the office manager or optical staff has taken time to listen to, has heard all their complaints and issues, and done the best they can to keep the office systems intact," Dr. Schaeffer says.

Once that patient has been given every possible courtesy and the practice has made every effort to accommodate their needs within the broad guidelines for the practice, "we may suggest that they find a practice that better meets their needs," Dr. Schaeffer says.

It's true that there may come a time when ODs need to "fire" their patients, Dr. Gerber says. Borrowing a phrase from Disney, he adds: "Those patients need to be politely asked to seek their happiness elsewhere."

## The Needy Patient

Dr. Gurwood has a patient with chronic dry eye who calls him every few weeks—to report the same symptoms. Dr. Gurwood gives him the same recommendations every time, but the call eventually comes around again.

"I have patients who are needy," Dr. Gurwood says. "So, I try to give them what they need." Sometimes it's as simple as just being nice.



# THE TRAINING YOU NEED TO GROW YOUR MEDICAL PRACTICE

## Attention All Optometrists

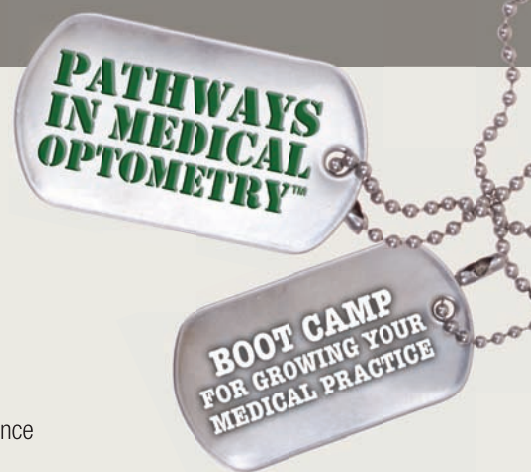
Attend a boot camp to receive a step-by-step implementation plan that will take your practice to the next level by:

- Taking charge of your schedule
- Determining vision plan vs medical plan
- Gaining access to insurance panels
- Improving billing and medical records
- Understanding ICD-10 codes
- Maximizing practice productivity and performance

Expert faculty:

**Scot Morris, OD, FAAO**  
**John Rumpakis, OD, MBA**  
Allergan Eye Care Business Advisors

Register today at [AllerganODPathways.com](http://AllerganODPathways.com)



### Upcoming PATHWAYS IN MEDICAL OPTOMETRY™ Course Schedule

City	Level 1	Level 2
Charlotte, NC	Sat, 2/1/14	Sat, 4/12/14
Atlanta, GA	Tue, 3/11/14	Sat, 5/17/14
Columbus, OH	Sat, 4/19/14	Sat, 6/21/14
Pittsburgh, PA	Sat, 5/31/14	Sat, 8/2/14
Seattle, WA	Sat, 8/9/14	Sat, 10/18/14
Dallas, TX	Sat, 9/13/14	Sat, 11/8/14

*Level 1 is a prerequisite to Level 2. Each boot camp consists of 1 full-day course.*

*Cost per course:*

*First OD registration per practice  
**\$399 per course\****

*All additional practice registrations  
**\$199 per course\****

*\*Costs required per PhRMA guidelines.*



This is easier said than done, of course.

These often well-meaning patients can be masters of self-diagnosis with 500 questions from Internet research, or they can be patients who appreciate the insights of their doctor a little too much. Either way, demanding or “needy” patients can gobble up a significant amount of time if you let them.

The key is negotiation.

“I have patients who come in with 100 questions. So I negotiate time. I tell them, ‘You’re asking me a lot of questions and I want to answer all of them, but I only have time for two more.

If you have more questions after that, we can schedule another appointment. Maybe you can schedule something for next week,” Dr. Gurwood says.

James Fanelli, OD, of Wilmington, NC, says he answers as many questions as he can, but makes sure to take ownership of the conversation.

“I listen, and then I tell them: ‘I understand what you’ve said and your concerns. Now, here’s what we need to do. If you feel this isn’t the best way to proceed, that’s certainly your right. But here’s what I think.’”

## The Non-Compliant Patient

The best possible eye health is always a top priority, so if patients cannot overcome chronic non-compliance, Dr. Schaeffer eventually recommends that they find a practice that better suits their needs. But that recommendation only comes after he and his staff have exhausted all avenues to improve the patient’s ocular health.

“We have an established proto-

col for at-risk patients, particularly as it relates to contact lenses. This means children, teenagers, anyone who sleeps in their contacts, and those with eye disease.”

These patients are expected to follow a medical protocol, he explains.

“We absolutely make everything clear up-front. We’re very tolerant and we understand that there are patients who won’t be compliant. We have patience with them. We treat them until they basically decide they won’t be compliant,” Dr. Schaeffer says.

When that time comes, “we tell

## Rather than view these patients as “problems” or “patients from hell,” approach them as patients in need.

them that they may be better off using another facility. We will not tolerate non-compliance because it could put the patient’s eye health at risk and it’s our job to provide quality care.”

To combat non-compliance, try to be as proactive and informative as possible. Review the elements of the treatment plan and the goals of therapy, check the patient’s understanding of the illness as well as the treatment, and reaffirm the patient’s commitment and intent with respect to the plan.

Let them know that you can’t help them if they aren’t willing to help themselves.

## The Obnoxious Patient

As an OD, you see an array of patients in all walks of life—from plumbers to politicians, from academics to mechanics, from high school seniors to senior citizens.

With such a wide swath of the

population capable of walking through your door, it’s inevitable that some patients will harbor inappropriate prejudices, beliefs or behaviors that make their visits uncomfortable for you and your staff.

These are the patients who make sexist or racist comments, refer to others in the office inappropriately, or use profanity—the obnoxious ones, basically.

Dr. Gurwood had a patient who didn’t hesitate to share his off-putting viewpoints during his visits. He would sit in Dr. Gurwood’s chair and inevitably make offensive jokes and remarks.

“But I’m a professional. My job was to fix his eye, not his prejudices. Some of my colleagues who witnessed the behaviors asked, ‘How can you treat that guy?’ And I responded with, ‘How could I not?’ My goal was to fix his eye problem,” he says.

“Remember, eyeballs don’t roll into your chair on their own. They come connected to patients,” Dr. Gurwood continues. “The doctor’s role is to find a solution that works for their eyes in a non-judgmental way while considering the whole person.”

If you can’t tolerate the remarks, be honest, yet professional. Tell the patient that their behavior is inappropriate or unwelcome.

If it gets to the point where the offensive remarks and inappropriate behavior become so overwhelming that you no longer wish to treat the patient, consider asking them to “seek their happiness elsewhere,” as Dr. Gerber puts it.

## No Difficult Patients?

Although few ODs would argue that difficult patients don’t exist, there are some who take exception to the concept of “problem

patients.”

Rather than view these patients as “problems” or “patients from hell,” approach them as patients in need.

Dr. Schaeffer says his reaction to hearing the term “problem patient” is a bit like hearing fingernails run down a chalkboard.

“Too many times, doctors and their staff hide behind the concept that they have a ‘problem patient,’ rather than understanding that this is a patient who doesn’t understand the practice,” Dr. Schaeffer says.

“There are patients you may not want to have as part of your practice family, but we never approach our patients as ‘problems.’”

Patients have varied needs, especially in how they prefer to receive your education and communication. Some want “just the facts,” while others like to be chatty and sociable.

It’s the duty of the practitioner to try to understand and meet those various needs, according to Dr. Gurwood.

Thus, there’s really no such thing as a “problem patient,” Dr. Gurwood says—just patients with different needs.

“Patients come to your office with problems that you can and can’t see,” he says. “Some of them have family members who have died from a certain condition, and they’re afraid they may have it. Some have suffered from unforeseen complications and they are afraid the current problem is an extension of that issue. Some are worried because they saw what happened to a friend and they don’t want it to happen to them. Some come in with their own prejudices or unrealistic expectations.”

All of these situations create anxiety for the patient, which can manifest in many different ways.

The key to quality optometric eye care is to understand the patient to the best of your ability and do your best to meet their needs, the doctors say.

“Doctors are healers,” Dr. Gurwood says. “If I can heal by providing additional medical advice or just by listening, I try. I treat them all like they’re family.”

Unfortunately, every family has its Chatty Cathy or embarrassing uncle. You may only see them on holidays, but their visits can feel like a lifetime, especially if you’re not well-equipped to handle it.

But if you’re prepared, proactive and persistent, you can avoid some disharmony and focus more on what you do best—providing quality eye care. ■



## *Unique As A Fingerprint*

*HUMAN EYE IS UNIQUE AS A FINGERPRINT AND REQUIRES A CUSTOM CORRECTIVE SOLUTION. FOR THIS REASON, WE NEED FAST, VERSATILE AND ACCURATE METHODOLOGIES FOR EYE EXAMINATION ACCORDING TO EACH INDIVIDUAL PATIENT'S UNIQUE VISION CORRECTION NEEDS.*

### **WAVEFRONT REFRACTION TECHNOLOGY**

*IN THE NEW HRK-8000A AUTO REF/KERATOMETER IS THE ANSWER FOR MEASURING A HUMAN EYE WITH ULTRA-PRECISION*



**Huvitz**

**COBURN  
TECHNOLOGIES**

**NEW PARTNERS IN DIAGNOSTIC INNOVATION  
CALL FOR DETAILS AND SPECIAL OFFERS**

**1-800-COBURN-1 (800-262-8761)**

**[www.coburntechnologies.com](http://www.coburntechnologies.com)**



# Spotlight on Sickle-cell Retinopathy

A thorough patient history and appropriate laboratory testing are essential to treat and diagnose this hereditary blood disorder.

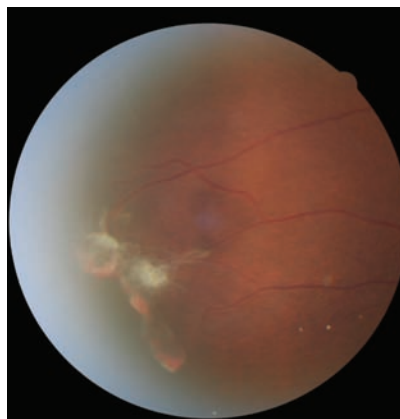
By Marlon J. Demeritt, OD, Diana L. Shechtman, OD, and Sherrol A. Reynolds, OD

**S**ickle-cell disease (SCD), a hereditary autosomal recessive condition, is characterized by the presence of crescent- or sickle-shaped red blood cells. These anomalous cells prevent normal blood flow and promote increased blood viscosity, hypoxia, venous stasis, acidosis and inflammation associated with varied systemic and ocular complications.<sup>1</sup>

SCD is one of the most prevalent genetic disorders in the US, predominantly affecting people of African or Mediterranean descent.

More than two million people—about 8.5% of the US population of African ancestry—have sickle-cell trait, and as many as 100,000 African Americans currently have the condition.<sup>2</sup>

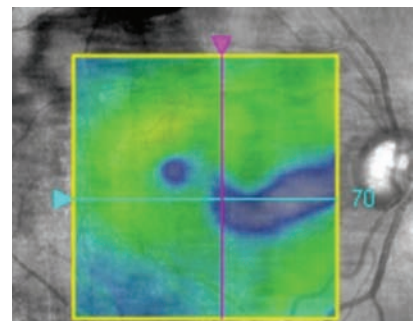
Here, we examine the cases of two black females who experienced ocular complications secondary to SCD.



**1. Sea-fan neovascularization associated with subhyaloid hemorrhage and retinal fibrosis.**

## Case #1 History

A 43-year-old black female presented with a chief complaint of foreign body sensation and burning that had persisted for three days. Her medical history was remarkable for sickle cell trait. Further, her



**2. Paramacular thinning on OCT in the right eye.**

ocular history was significant for a diagnosis of sickle-cell retinopathy in 2006.

## Diagnostic Data

Her best-corrected visual acuity was 20/25-3 OD, 20/25-2 OS. Pupils were equal, round and reactive to light, with no evidence of relative afferent defect. Confrontation fields were full to finger counting in both eyes, and extraocular motility testing showed full range

of motion.

Biomicroscopy evaluation revealed a yellowish scleral hue, as well as subconjunctival hemorrhages located near the inferior palpebral conjunctiva OU.

Intraocular pressure measured 17mm Hg OD and 18mm Hg OS. Dilated fundus examination revealed normal physiological optic nerve cupping with pink and distinct margins in both eyes. Both maculae were flat and intact, and her vessels exhibited a normal caliber OU.

Examination of the peripheral retina revealed the presence of intraretinal hemorrhages (salmon patches), arteriovenous anastomoses, sea-fan neovascularization and retinal fibrosis OD (*figure 1*), with temporal fibrosis located near an area of sea-fan neovascularization OS.

### Diagnosis

We educated the patient on the findings, notified her primary care provider and referred her to a retina specialist for evaluation and possible treatment with anti-VEGF therapy. We scheduled a follow-up examination in four weeks.

### Case #2

#### History

A 65-year-old black female presented with complaints of decreased vision in her right eye. Her medical history was remarkable for type 2 diabetes, hypertension and hypercholesterolemia—all of which were controlled with oral medications. Her family history was positive for sickle cell trait.

#### Diagnostic Data

Her best-corrected visual acuity was 20/30 OD and 20/25+ OS. Pupils and ocular motilities were unremarkable. Intraocular pressure

### Differential Diagnosis of Sickle Cell Retinopathy

Central retinal vein occlusion	Central retinal artery occlusion
Diabetic retinopathy	Anemia retinopathy
Hypertensive retinopathy	Ocular ischemic syndrome
Radiation retinopathy	Leukemia retinopathy
Sarcoidosis	Rheumatic fever
Hyperviscosity retinopathy	Retinopathy of prematurity
Branch retinal vein occlusion	Eales disease
Branch retinal artery occlusion	Talc embolization

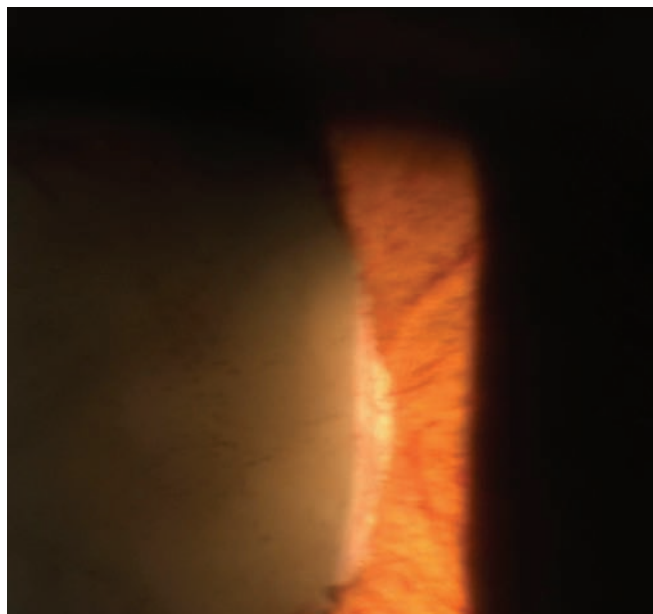
measured 19mm Hg OU.

Dilated fundus examination revealed mild cataracts and non-proliferative diabetic retinopathy in both eyes. Optical coherence tomography (OCT) revealed no clinically significant macular edema, but we noted

paramacular thinning in the right eye (*figure 2*). This warranted further evaluation; however, she was lost to follow-up.

### Discussion

Sickle-cell disease is a complex disorder with distinct variants that occur when a single-point mutation of normal hemoglobin results in a sickle hemoglobin gene.<sup>3</sup> Inheritance of this gene from both parents results in a homozygote condition known as sickle-cell anemia (HbSS). There are several heterozygous forms of SCD, including sickle-hemoglobin C disease (HbSC) and sickle beta-thalassemia



3. Iris neovascularization.

(SThal).

HbSC is associated with a substitution of lysine for glutamic acid, and SThal occurs from a point mutation in the beta globin subunit affecting the amino acid sequence. The most common variant is the carrier-state known as sickle-cell trait (HbAS) (*see “Differential Diagnosis of Sickle Cell Retinopathy”*).

Systemic and ocular manifestations vary. While sickle-cell anemia is associated with life-threatening systemic conditions, ocular complications are comparatively milder.<sup>4</sup> On the other hand, SCD and SThal are associated with more severe

## Case Report

ocular disease, yet have far fewer systemic manifestations. Further, the incidence of proliferative sickle-cell retinopathy in sickle-cell disease and thalassemia is higher than in sickle-cell anemia.<sup>1</sup>

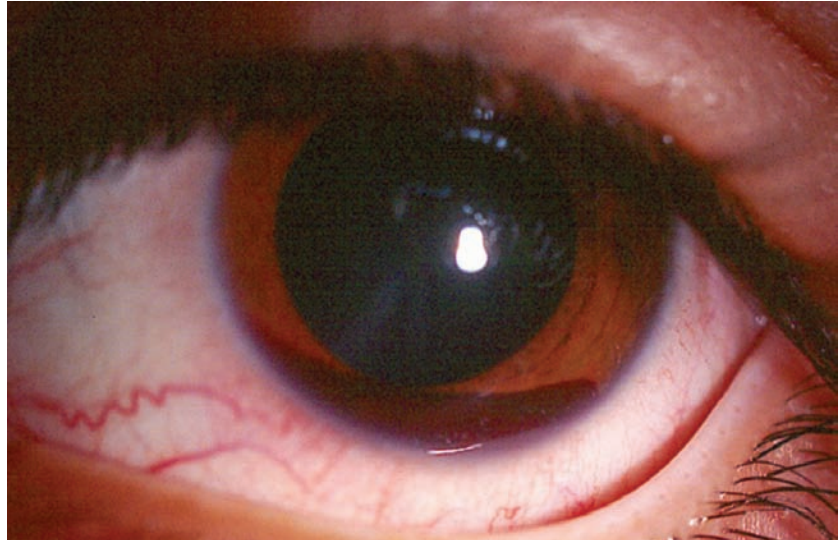It is important to note that a carrier of the sickle-cell trait may also experience both systemic and ocular complications.<sup>5</sup>

• **Ocular findings.** Resultant vaso-occlusive changes yield several anterior segment complications, such as the “conjunctival sickling sign,” which is characterized by capillary vessel segmentation. Iris changes manifest as atrophy with or without anterior or posterior synechiae. Additionally, the development of iris neovascularization (INV) could lead to secondary glaucoma and severe vision loss (*figure 3*).<sup>6,7</sup>

The presence of a spontaneous hyphema in black patients could be indicative of underlying SCD (*figure 4*). Even a small hyphema potentially could precipitate significant IOP increase and/or glaucomatous development.<sup>8</sup> Hyphemic glaucoma is a direct result of blood cell obstruction within the trabecular meshwork, as well as pupillary block secondary to large blood clots.<sup>9</sup> A sickle-cell patient who presents with hyphema is at risk for rebleed, and should be educated and monitored closely.

Although glaucoma medications may be required when treating a patient with hyphema and concomitant increase in IOP, the use of acetazolamide is contraindicated in SCD patients. This is related to the CAI effects on lowering pH as well as increasing ascorbate concentration in the aqueous, promoting sickling of red blood cells in the anterior chamber, which may obstruct the trabecular meshwork.

Posterior segment findings

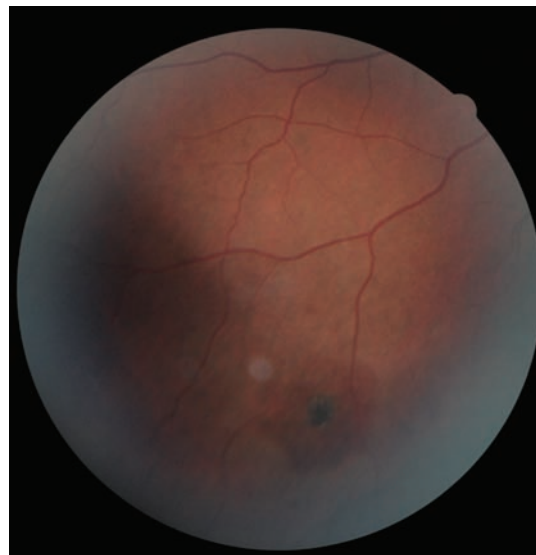


**4. Spontaneous hyphema.**

include optic neuropathies, retinopathies, maculopathies, retinal hemorrhages, choroidopathy, vascular changes associated with tortuosity, “silver-wire” arterioles, angioid streaks, and arterial and vein occlusions.<sup>10</sup> Given the spectrum of posterior ocular findings, you must consider several differential diagnoses.

The clinical features of sickle-cell retinopathy may be either nonproliferative or proliferative. Nonproliferative retinal changes include intra-retinal salmon-patch hemorrhages, which may develop into a “black sunburst” upon resolution (*figure 5*). Iridescent spots, representing a collection of hemosiderin-laden macrophages, also may be noted.

Other retinal manifestations and vasculopathies also may be noted in patients with SCD. Although a Roth’s spot hemorrhage may be associated with bacterial endocarditis, it may also occur in patients



**5. Sunburst.**

with SCD (*figure 6*). Its presence should alert the physician for possible underlying vascular and hyperviscosity conditions, including SCD.

Angiopathies are also common, and venous tortuosity may be observed in up to 47% of HbSS and 32% of HbSC patients.<sup>11</sup> Angioid streaks, a defect within Bruch’s membrane, can be seen in 1% to 2% of patients with SCD and warrant an OCT evaluation to rule out

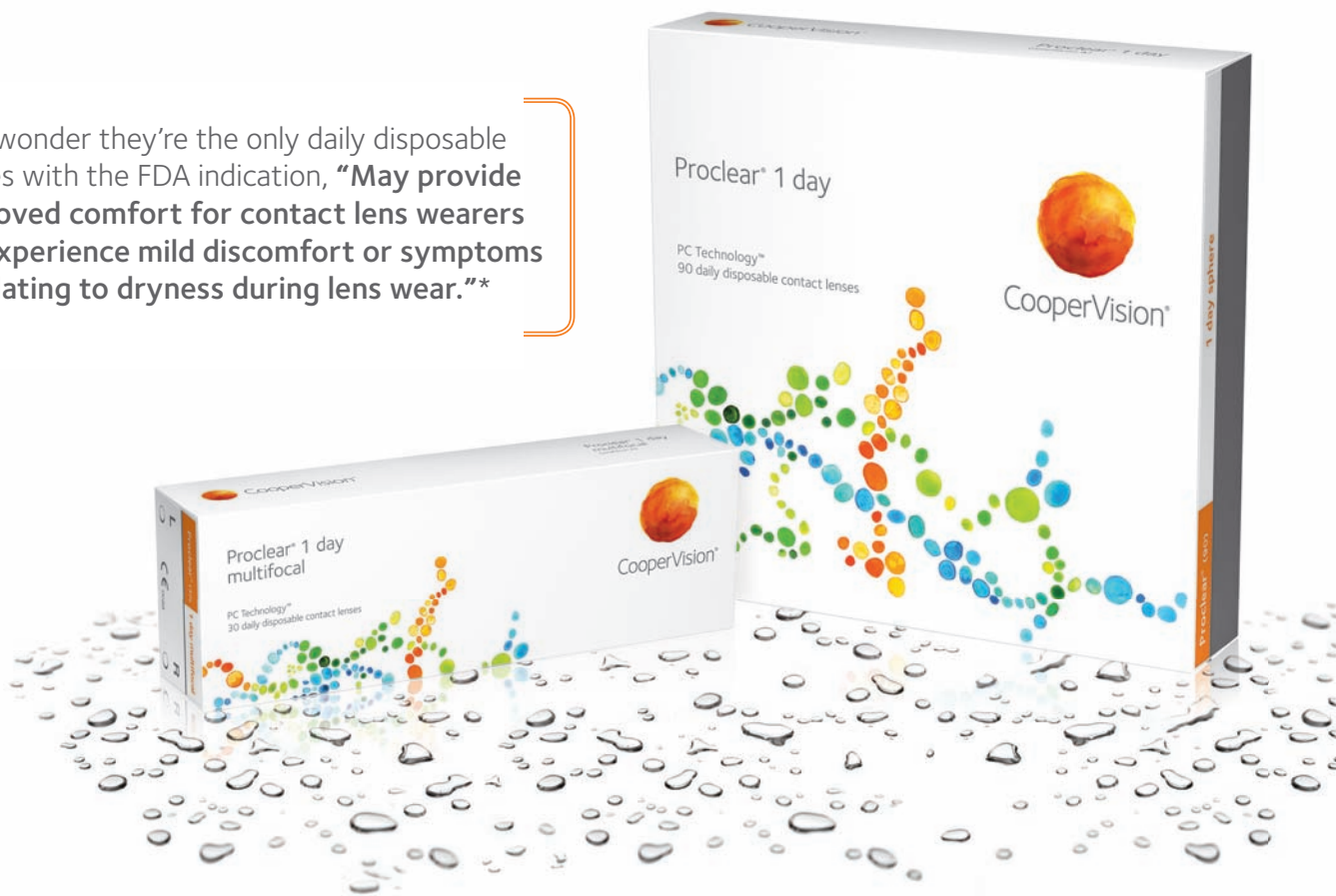

# Eyes Need Water.

## Proclear® 1 day Lenses Attract Water.

# Natural Comfort by Design.

No wonder they're the only daily disposable lenses with the FDA indication, **"May provide improved comfort for contact lens wearers who experience mild discomfort or symptoms relating to dryness during lens wear."**\*



Proclear 1 day lenses use exclusive PC Technology™ to recreate the phosphorylcholine found naturally in human tears. So, like eyes, they capture a protective film of water.

**Comfort all day in an affordable 1-day lens.**

- » Keeps lenses comfortably hydrated (96% even after 12 hours of wear)
- » Reduces protein and lipid deposits
- » Sustains oxygen flow
- » Mimics natural cell membrane chemistry, reducing chances of rejection and discomfort

Ask your CooperVision sales representative about current programs and promotions.

\*Evaporative Tear Deficiency or Aqueous Tear Deficiency (non-Sjogren's only).  
©2014 CooperVision, Inc. 0991 03/14



CooperVision®  
Live Brightly.®



# Navigate into new educational terrain with the American Academy of Optometry!

The Academy's annual meeting brings you clinically relevant education, pioneering speakers, fascinating papers and posters, and unforgettable social events! Join us in the beautiful setting of Denver for four days of unparalleled education. See you there!

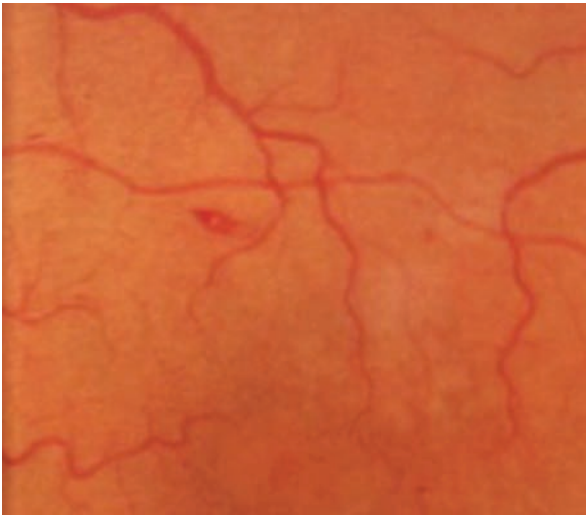
Early Bird Registration Ends  
September 9, 2014!

[www.aaopt.org](http://www.aaopt.org)



Academy 2014 Denver  
Colorado Convention Center

Visit [www.aaopt.org](http://www.aaopt.org)



**6. Roth spot hemorrhage.**

associated choroidal neovascular membrane (CNVM).<sup>12-14</sup>

In addition to the aforementioned findings, the appearance of a dark hyphema in the absence of increased intraocular pressure has been linked to a diagnosis of SCD since the mid-1970s.<sup>15</sup>

Proliferative sickle-cell retinopathy is initially characterized by the presence of arterial occlusion, leading to arteriovenous anastomoses (see “Proliferative Retinopathy: Goldberg Classification”). This is in response to localized peripheral ischemia from repeated episodes of arteriolar closure, which is presumed to trigger angiogenesis through the production of endogenous vascular growth factors.<sup>22</sup> Disease progression leads to the formation of sea-fan neovascularization (as was documented in Case #1), fibrosis (figure 7), vitreous hemorrhage and tractional retinal detachment.

• **New developments.** Given the direct effect of SCD on the retinal vascular pathway, an array of maculopathies—including hairpin-shaped venular loops and irregularities of the foveal avascular zone—have been reported.<sup>21</sup> The

advent of OCT has led to better evaluation of macular morphological changes associated with SCD. Choroidal neovascular membrane occurs in 72% to 86% of cases with angioid streaks. If left untreated, the visual prognosis for SCD patients who present with angioid streaks is poor.<sup>27-29</sup> Affected individuals should undergo an OCT evaluation.

Ancillary OCT has demonstrated a recent finding associated with macular (paramacula) thinning.<sup>16,17</sup> A study using spectral-domain optical coherence tomography (SD-OCT) showed correlating macular thinning in about 50% of eyes with SCD.<sup>18</sup> This may be a direct result of chronic ischemia affecting the retinal ganglion cells and retinal nerve fibers as they course temporally toward the optic nerve (as seen in Case #2).<sup>19</sup>

Macular ischemia typically develops along the temporal horizontal raphe, sparing the fovea and central visual acuity.<sup>20</sup>

• **Lab analysis.** It is helpful to know which laboratory tests most frequently are used to diagnose sickle-cell anemia and trait. Consider ordering lab tests if you observe the following:

- **Dark hyphema** without increased intraocular pressure or angioid streaks in black or Carib-

bean patients.

- **Retinal vasculopathies** in the absence of other associated systemic-related diseases.

- **Presence of salmon-patch hemorrhages**, sunbursts or comma-shaped conjunctival vessels.

A complete blood count (CBC) is used to evaluate a wide range of hyperviscosity-related disorders, including anemia, infection and leukemia.

A CBC with differential measures several components and features of blood, including red and white blood cells, hemoglobin, hematocrit and platelets—all of which may be abnormal in patients with SCD.

Hemoglobin electrophoresis is used to measure differences in the distinct oxygen-carrying protein. There are a number of different types of hemoglobin associated with SCD. A sickle cell test looks for abnormal hemoglobin in the blood, causing sickle-cell anemia. This test is run with concomitant abnormal hemoglobin.

• **Management.** Conservative management with close observation is warranted for nonproliferative SCR; however, various treatment modalities are frequently employed for proliferative SCR.

Patients who present with stage 3 to 5 proliferative disease should be referred to a retina specialist due to the potential risk of severe vision loss.

Conventional treatment includes panretinal photocoagulation.

## Proliferative Retinopathy: Goldberg Classification

Peripheral arteriolar occlusions

Peripheral arteriovenous anastomoses

Sea-fan neovascularization

Vitreous hemorrhage

Tractional retinal detachment

Additionally, anti-VEGF therapy is regarded as a potential treatment option for proliferative disease.<sup>24-26</sup>

Our role as eye care providers is multidisciplinary. A patient may present with the established diagnosis of sickle-cell disease, which will require continuous communication with the PCP. The patient's PCP should be made aware of all findings—even in the absence of any ocular manifestations. Moreover, we should be diligent in obtaining accurate case histories in SCD patients.

We must be familiar with the lab analysis used to diagnose sickle-cell anemia in order rule out other disease states and more effectively comanage the patient with his or her PCP.

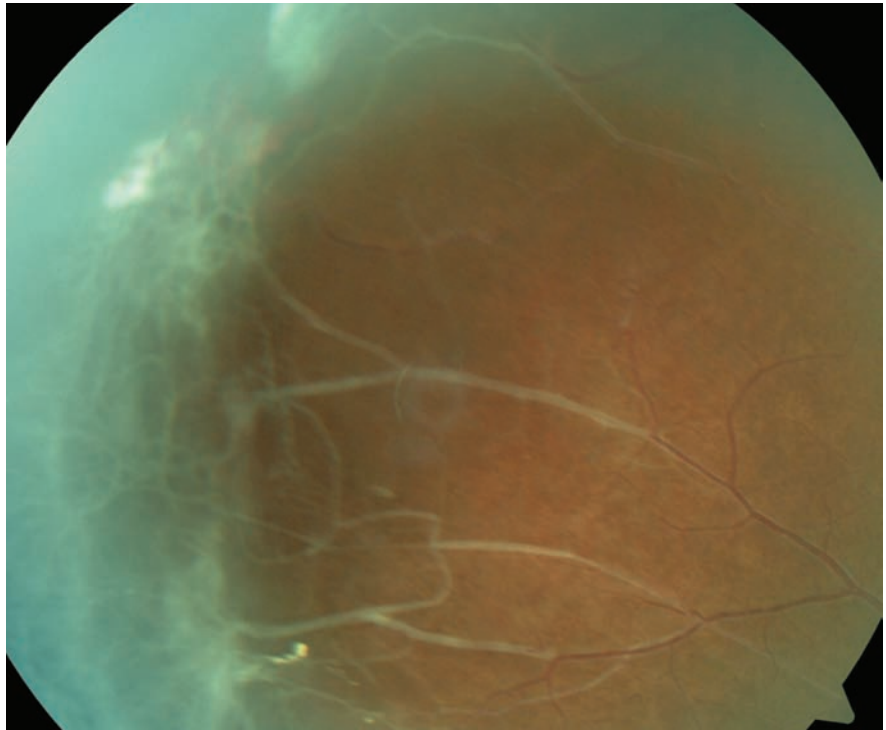
Further, we must be able to recognize the presence of proliferative SCR and make a swift referral to prevent severe vision loss. ■

*Dr. Demeritt is an assistant professor and attending optometrist at Nova Southeastern College of Optometry/The Eye Care Institute.*

*Dr. Shechtman is an associate professor of optometry at Nova Southeastern University College of Optometry, where she serves as an attending optometric physician at the Eye Institute and Diabetic/Macula Clinic.*

*Dr. Reynolds is an Associate Professor at Nova Southeastern University College of Optometry, where she is a clinical attending in the diabetes clinic and is a member of the Optometric Retina Society.*

- Emerson GG, Harlan JB, Fekrat S, et al. Hemoglobinopathies. In: Ryan SJ, ed. Retina. 4th ed. Philadelphia: Elsevier; 2006.
- Sickle Cell Disease: Data & Statistics. Centers for Disease Control and Prevention. Available at: [www.cdc.gov/ncbddd/sicklecell/data.html](http://www.cdc.gov/ncbddd/sicklecell/data.html). Accessed July 2013.
- Schnog JB, Duits AJ, Muskiet FA, et al. Sickle cell disease; a general overview. Neth J Med. 2004 Nov;62(10):364-74.



**7. PSCR with neovascularization and fibrosis.**

- Gill FM, Sleeper LA, Weiner SJ, et al. Clinical events in the first decade in a cohort of infants with sickle cell disease: Cooperative Study of Sickle Cell Disease. Blood. 1995 Jul 15;86(2):776-83.
- Sowka J, Gurwood A, Kabat A. Sickle Cell Disease. Handbook of Ocular Disease Management. Rev Optom. Suppl. 1992;90:481-504.
- Serjeant GR. The sickle cell trait. In: Serjeant GR (ed.). Sickle Cell Disease, 2nd Ed. New York: Oxford University Press; 1992.
- Clarkson JG. The ocular manifestations of sickle-cell disease: a prevalence and natural history study. Trans Am Ophthalmol Soc. 1992;90:481-504.
- Goldberg MF. Sickled Erythrocytes, hyphema, and secondary glaucoma: I. The diagnosis and treatment of sickled erythrocytes in human hyphemas. Ophthalmic Surg. 1979 Apr;10(4):17-31.
- Gottsch JD. Hyphema: diagnosis and management. Retina. 1990;10 Suppl 1:S65-71.
- Sayag D, Binaghi M, Souied EH, et al. Retinal photocoagulation for proliferative sickle cell retinopathy: a prospective clinical trial with new sea fan classification. Eur J Ophthalmol. 2008 Mar-Apr;18(2):248-54.
- Welch RB, Goldberg MF. Sickle cell hemoglobin and its relation to fundus abnormality. Arch Ophthalmol. 1966 Mar;75(3):353-62.
- Clarkson JG. The ocular manifestations of sickle cell disease: a prevalence and natural history study. Trans Am Ophthalmol Soc. 1992;90:481-504.
- Condon PI, Serjeant GR. Ocular findings in elderly cases of homozygous sickle cell disease in Jamaica. Br J Ophthalmol. 1976 May;60(5):361-4.
- Nagpal KC, Asdourian G, Goldbaum M, et al. Angioid streaks and sickle hemoglobinopathies. Br J Ophthalmol. 1976 Jan;60(1):31-4.
- Nagpal KC, Goldberg MF, Asdourian G, et al. Dark-without-pressure fundus lesions. Br J Ophthalmol. 1975 Sep;59(9):476-9.
- Nagpal KC, Goldberg MF, Rabb MF. Ocular Manifestations of sickle hemoglobinopathies. Surv Ophthalmol. 1977 Mar-Apr;21(5):391-411.
- Acacio I, Goldberg MF. Peripapillary and macular vessel occlusion in sickle cell anemia. Am J Ophthalmol. 1973 May;75(5):861-6.
- Chou FY, et al. Hemoglobinopathies [ARVO abstract 3554]. Invest Ophthalmol Vis Sci. 2010;51.
- Murthy RK, Grover S, Chalam KV. Temporal Macular Thinning on Spectral-Domain Optical Coherence Tomography in Proliferative Sickle Cell Retinopathy. Arch Ophthalmol. 2011 Feb;129(2):247-9.
- Jampol LM. Arteriolar occlusive diseases of the macula. Ophthalmology. 1983 May;90(5):534-9.
- Joussen AM, Gardner TW, Kirchhof B, Ryan AJ (eds.). Retinal Vascular Disease. Berlin: Springer; 2007.
- Gitter KA. Dominantly inherited peripheral retinal neovascularization. Arch Ophthalmol. 1978 Sep;96(9):1601-5.
- Jampol LM, Goldbaum MH. Peripheral proliferative retinopathies. Surv Ophthalmol. 1980 Jul-Aug;25(1):1-14.
- Shaikh S. Intravitreal bevacizumab (Avastin) for the treatment of proliferative sickle retinopathy. Indian J Ophthalmol. 2008 May-Jun;56(3):259.
- Siqueira RC, Costa RA, Scott IU, et al. Intravitreal bevacizumab (Avastin) injection associated with regression of retinal neovascularization caused by sickle cell retinopathy. Acta Ophthalmol Scand 2006;84:834-5.
- Siqueira RC, Costa RA, Scott IU, et al. Intravitreal Bevacizumab (Avastin) Injection associated with regression of retinal neovascularization caused by sickle cell retinopathy. Acta Ophthalmol Scand. 2006 Dec;84(6):834-5.
- Piro PA, Scheraga D, Fine SL. Angioid Streaks natural history and visual progression. In: Fine SL, Owens SL (eds.). Management of Retina Vascular and Macular Disorders. Baltimore: Williams and Wilkins; 1983.
- Mansour AM, Shields JA, Annesley WH, et al. Macular degeneration in angioid streaks. Ophthalmologica. 1988;197(1):36-41.
- Singerman LJ, Hatem G. Laser treatment of choroidal neovascular membranes in angioid streaks. Retina. 1981;1(2):75-83.

# Peroxide Lens Care Solutions

## Is there room for improvement?



BY KEITH  
BASINGER, OD

The last 10 years have seen changes in contact lens materials, designs, and multipurpose solutions (MPS) – many with the ultimate goal of making the lenses more comfortable, increasing wearing time, and improving the patient’s overall lens wearing experience. Despite advances on these fronts, there’s been a surprising lack of innovation in the hydrogen peroxide category for almost a decade. Is there not room for improvement there as well?

Like most ECPs, I tend to recommend peroxide solutions to my patients who are experiencing issues of discomfort, dryness or irritation with an MPS while wearing frequent replacement lenses. Yet a recent survey suggests that more than half of patients using peroxide solutions still experience issues or symptoms of discomfort, most notably associated with dryness.<sup>1</sup> Equally disconcerting is that many patients fail to raise these issues with their provider, perhaps because expectations are limited as to the degree of relief they can expect or the perception that the peroxide solution is their last good option if they want to stay in contact lenses. I’d like to share with you some recent study findings on the performance of PeroxiClear™ hydrogen peroxide solution, and why it has become my first choice for patients who are experiencing issues with their MPS.

PeroxiClear provides the disinfection efficacy one would expect from a peroxide solution, with some important improvements. Study data demonstrate that PeroxiClear kills 99.9% of microorganisms and neutralizes in 4 hours so that patients can reinsert their lenses sooner.<sup>2</sup> PeroxiClear utilizes a combination of three different wetting agents to help attract, spread and retain moisture on the surface of the lens. Following neutralization, data indicate that the surfactant in PeroxiClear remains on the lens to deliver moisture for up to 20 hours of wear; in contrast, lenses soaked in Clear Care retain less than 3% of surfactant after only an hour of wear.<sup>3</sup> Additionally, an ex vivo study designed to evaluate cleaning efficacy using Acuvue Advance and Oasys lenses, found that with PeroxiClear, lenses remained cleaner for longer, with a lower area of surface coverage of deposits compared to Clear Care (28% vs 51% after 30 days of wear).<sup>4,5</sup>

The significance of these findings to me is that they represent advances in three main areas where improvements in peroxides would be desirable – patient convenience, increased moisture on the lens surface and improved cleaning. Indeed, my own experience with PeroxiClear™ solution supports these advantages in clinical practice.

One patient who comes to mind is a 57-year-old male patient wearing multifocal contact lenses whose eyes are getting just a bit drier as he gets older. I switched him to a peroxide solution a couple of years ago; it helped, but in order not to experience burning, he has had to rinse the lens with an MPS before insertion. I switched him to PeroxiClear and he reports being able to insert the lenses directly onto his eyes without any issues of burning.

Another example is a female patient in her mid-40’s who wears Acuvue Oasys contact lenses and was using Clear Care peroxide solution. She had good wearing time when the lenses were new, but complained of discomfort and decreased wearing time as her lenses got older. I switched her to PeroxiClear and she reported that the lenses now feel better at the end of the 2-week wearing cycle, and with no decrease in wearing time like she had previously experienced.

Traditionally, I think we’ve tended to use peroxides as troubleshooting solutions or as something of a last resort – as an alternative that hopefully will work for patients who are having issues with their MPS. Given its comfort, convenience and disinfection characteristics, PeroxiClear has become my peroxide of choice for my patients. ■

Reference: 1. Millward Brown Healthcare. A multi-country market research study conducted online amongst 300 soft contact lens wearers, all wearing their lenses for at least 4 days a week and using HP solution. May/June 2011. 2. Results of in vitro study following FDA/ISO stand-alone procedure for disinfecting products. Test solutions were modified with organic soil to create a more rigorous test condition. Primary criteria for effective disinfection are defined as a reduction in the number of bacteria by a minimum of 3 logs (99.9%) and a reduction of mold and yeast by a minimum of 1 log (90%) within the recommended disinfection time. Graphs depict mean log reduction measured after manufacturers’ recommended disinfecting time (soak only). 3. High-resolution/accurate-mass (HR/AM) mass spectrometry was used to detect and quantify the relative amounts of surfactant retained on lenses from PeroxiClear™ and Clear Care solutions after 20 hours of wear. PureVision®2, Acuvue Oasys, and Air Optix Aqua lenses were soaked in solutions for 12 hours prior to patients wearing lenses for 20 hours. 4. Results from a 22-investigator, multi-site study of PeroxiClear™, with a total of 440 eligible subjects. Subjects were randomized to use either PeroxiClear™ solution or Clear Care for 3 months. Subjects completed performance surveys at 2-week, 1-month, 2-month, and 3-month visits. 5. Results of an ex vivo study measuring deposits on worn contact lenses to compare the clinical performance of PeroxiClear™ and Clear Care solutions. Lenses were worn daily for 1 month (silicone hydrogel and Group IV hydrogel lenses) or 3 months (gas permeable lenses). A total of 374 lenses were randomly selected for image analysis. Lenses were scored for mean density of deposits and percent coverage of deposits.

# Can You Crack These Tough Comanagement Cases?

19th Annual Comanagement Report

When encountering a tricky case that might require other doctors, don't lead from behind—take charge of the comanagement effort. **By Jane Cole and Colleen Mullarkey**

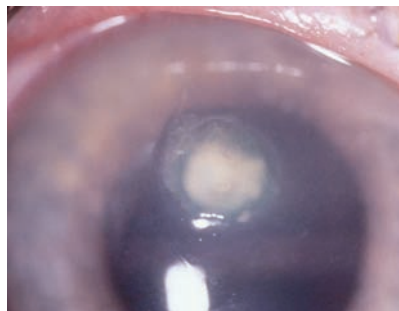**W**hat do you do when that stubborn corneal infection just won't go away, despite throwing in everything but the kitchen sink?

It's time to refer the patient.

Not that long ago, such a referral meant you'd never see the patient again. The corneal specialist would take charge—and take the patient. But, if you send the patient to an optometric referral center, that's no longer the case. The patient will return to you for follow-up comanagement, explains Christopher Quinn, OD, president of one such referral center, Omni Eye Services of New Jersey, in Iselin, NJ.

To be an active partner in a comanagement arrangement—and indeed to lead the effort—you'll need to be able to size up all the patient care options, including those you may have to coordinate with another doctor.

Four leaders in optometric comanagement offer their views of how they'd manage several tough cases that have presented a conun-



**A suspicious white lesion was visible on this contact lens wearer's cornea.**

**How should you manage this patient?**

drum to either an optometric referral center or to practitioners who refer patients in to the comanagement center. Learning the ins and outs of complex cases that involve more than one eye care professional will better prepare you to direct the course of patient care in comanagement situations, so that the patient remains a part of your practice.

## Call in the Calvary for Corneal Ulcer?

• **Diagnostic data.** A 26-year-old white female presented to her

optometrist with a complaint of significant pain in the right eye that had lasted for a day. She reported that her pain had worsened after she took out her soft contact lenses that morning. Best-corrected acuity in that eye was 20/40. A suspicious white lesion was visible on her cornea. How should you treat this young patient?

• **Discussion.** It's not strange that the patient reported feeling worse after removing the contacts. "It's like a bandage essentially, and that's where it just keeps getting worse," says Brian Den Beste, OD, founder of Lasik Pro Eye Consultants in Orlando, Fla. To avoid further problems, reiterate that she needs to discontinue wearing her lenses.

Next, culture the eye to figure out whether the lesion is an infectious ulcer or sterile inflammatory infiltrate. If you're not equipped to perform the culture and suspect it could be more than a simple infiltrate, refer the patient to someone who can.

But, don't wait for the culture results before starting the patient on antibiotics. "This is an infection until proven otherwise," says Daryl Mann, OD, chief manager of SouthEast Eye Specialists in Tennessee. "If you look at the anterior chamber and you see too many cells to count, it points to an infectious etiology, along with the pain and appearance."

Dr. Mann says it's never a mistake to put the patient on a broad-spectrum antibiotic in the first 24 hours. You'll likely have the lab results within a day or two, and then you can tailor therapy depending on whether it's gram-positive or gram-negative.

While all of the doctors agree that antibiotic treatment is the way to go, each has a different preference. Dr. Mann opts for fortified antibiotics from his compounding pharmacist—using 25mg/ml vancomycin and 14mg/ml tobramycin. He prescribes one on the hour and one on the half hour for the first 24 hours, with immediate follow-up the next day.

Dr. Den Beste, on the other hand, would prescribe a fluoroquinolone to be instilled every five minutes for the first 35 minutes or hour, and then every half an hour for the first 24 hours. "This class of drugs has changed the game since the 1990s," he says. For instance, a recent 20-year review of multiple, head-to-head studies on fortified antibiotics vs. fluoroquinolones found no substantial difference in outcomes.<sup>1</sup> These results, plus easy accessibility and affordability for patients, are the factors that make a fluoroquinolone Dr. Den Beste's first choice.

Robert Vandervort, OD, director of Heartland Eye Consultants, in Omaha, Neb., would consider using Polytrim (polymyxin B/

trimethoprim, Allergan) or another adjunctive medication in addition to the fluoroquinolone. "When I culture these, I'm always surprised at how many times the cultures do come back that they show sensitivity to trimethoprim and polymyxin B," he says.

Although the doctors vary in their approaches, they almost unanimously agree on one treatment you should avoid. "Probably the biggest mistake clinicians make is to put steroids on an unidentified ulcer," Dr. Den Beste says. "You'll make the patient feel better, but you're really helping the bug, particularly in fungal cases."

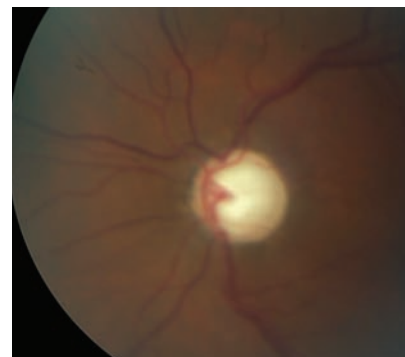
There's always been some controversy about using steroids when managing infectious keratitis, presumably to prevent scarring and vision loss. However, the Steroids for Corneal Ulcers Trial (SCUT) found that adjunctive topical corticosteroid use did not improve three-month vision in patients with bacterial corneal ulcers.<sup>2</sup> "We're not too worried about lessening that scarification, at least in my mind. It's more about saving an eye," Dr. Den Beste says. "We're trying to put out the fire; we're trying to keep the cornea from perforating."

To do that, you'll want to watch this patient like a hawk—see her back within a day and follow up often. And if in doubt, refer it out. But send to a corneal specialist if available, so that targeted care can be provided, knowing that long-term management will revert back to your practice.

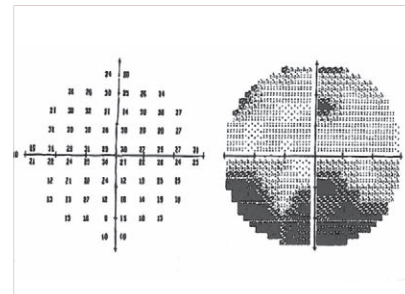
## Two Bottles Too Many

• **Diagnostic data.** A 42-year-old black male treated by his optometrist for primary open-angle glaucoma (POAG) for the past four years presented without complaints.

His current medications included Lumigan (bimatoprost, Allergan) QD OU, Cosopt (dorzolamide/timolol, Merck) BID OU, and Alphagan P (brimonidine, Allergan) BID OU. His family history was significant; his grandmother was treated for glaucoma prior to her death.



**This 42-year-old patient exhibited advanced cupping in both eyes.**



**Visual field testing showed advanced loss OS approaching fixation. What is the best management for this young patient?**

The patient's best-corrected visual acuity was 20/20 OU. He had a slightly thin cornea, with pachymetry readings of 539 $\mu$ m OD and 529 $\mu$ m OS. His intraocular pressure measured 14mm Hg OD and 16mm Hg OS. His slit-lamp exam was unremarkable.

Imaging showed advanced cupping in both eyes. Visual field testing showed advanced loss OS approaching fixation.

What is the most appropriate management for this young glaucoma patient?

• **Discussion.** When three bottles are needed to control IOP, the question becomes: Is the patient on too many medications? As the number of medications increases, studies have shown non-compliance becomes a big concern.<sup>3-5</sup>

Maximum medical therapy in patients with POAG generally means a prostaglandin and a combination drug such as Cosopt or Combigan (brimonidine/timolol, Allergan), says Dr. Vandervort. “Once you start getting to a third medication, your back is against the wall,” he says. “You can have a patient on three different medications but compliance goes way down. If I have someone on a prostaglandin of some kind and then add Cosopt or Combigan, we’re getting close to the end of medical therapy.”

Considering the patient’s relatively young age, family history and multiple medications, continuing this course of medical polytherapy is not a long-term solution and surgical intervention should be pursued—especially if there is any hint of progression, says Dr. Mann.

Once you make the decision, your comanagement role should include recommending that the patient undergo surgical intervention as soon as possible, the doctors suggest.

But the surgical options vary. Selective laser trabeculoplasty (SLT) is often the first surgical choice for most glaucoma patients. However, SLT may not be the best course of action in this case, Dr. Quinn says. “We don’t have a lot of time for this patient,” he says, noting that while the risks associated with SLT may be quite low, “there is also a risk we could further delay a more appropriate intervention for this patient that would really get his pressure where we need it.”

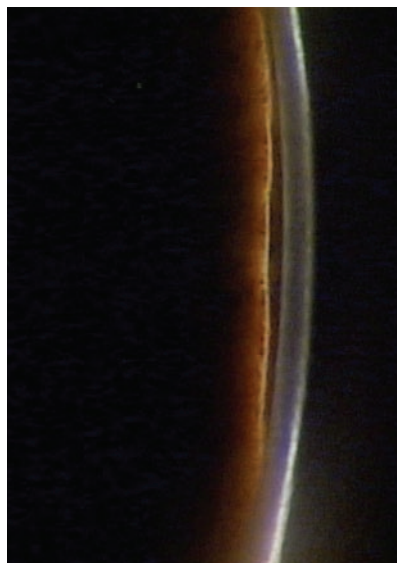
Other surgical options for this patient include trabeculectomy with mitomycin (MMC) or a tube shunt procedure, Dr. Quinn adds.

The Tube Versus Trabeculectomy (TVT) study found the two procedures are almost equivalent in terms of IOP lowering.<sup>6</sup> “So, in my mind, a tube is probably a better option for this patient, since there is a lower risk of failure,” Dr. Quinn says.

If a patient must wait for surgical intervention at a busy clinic, consider prescribing an oral carbonic anhydrase inhibitor in the interim, such as a half-tablet of Diamox (acetazolamide, Duramed) TID, says Dr. Den Beste. “It’s a great drug to get the IOP down short-term,” he says.

## Look at Glaucoma from Every Angle

• **Diagnostic data.** A 66-year-old white female was referred for an evaluation of her glaucoma status. Upon examination, her best-corrected visual acuity was 20/25 OU, and she had a mild cataract. She had no afferent pupillary defect



**Gonioscopic view of the patient’s angle. What’s causing this patient’s glaucoma?**

in either eye. Pachymetry readings showed normal corneal thickness. Medications included a prostaglandin analog, yet her IOP measured 29mm Hg OD and 28mm Hg OS. Her visual fields were full.

What’s causing this patient’s glaucoma?

• **Discussion.** If you think this patient has undergone all the necessary tests, think again. In this patient’s case, further examination with gonioscopy revealed she had angle-closure glaucoma.

Gonioscopy is an art many optometrists and ophthalmologists don’t employ, but it’s a critical tool in the initial evaluation of a glaucoma patient, particularly the primary open-angle glaucoma patient, Dr. Mann says. However, fewer than half of clinicians perform gonioscopy during the initial evaluation of primary open-angle glaucoma.<sup>7</sup> Gonioscopy can also assist in the diagnosis of pseudoexfoliation, pigmentary glaucoma and comparing a healthy angle vs. a diseased angle.

“Patients come in and primary care optometrists can’t consistently get them to respond to medication. And lo and behold, you look with a gonioscopy lens, and you don’t see any angle structures,” Dr. Mann says.

As a long-term glaucoma patient develops cataracts, an open but narrow angle can actually convert over to a chronic angle-closure state during a period of 10 to 20 years, says Dr. Quinn.

“It’s amazing how long an angle can survive before it gives up the ghost and causes pupillary block,” says Dr. Den Beste. As such, preventative care is essential. “I had a patient with cataracts. She was wearing a +8.00D sphere and had gone her whole life without angle closure. She had cataract surgery and was so happy. But a few years



go by and she comes back with a steamy cornea and a pressure of 50mm Hg—she had angle closure. So, just because the patient is pseudophakic doesn't mean that peripheral anterior synechiae can't occur. That's a rare case, but clearly we need to put that gonio prism on these patients more often."

Just how often should gonioscopy be repeated? For patients with a grade 3 or 4 angle to start, Dr. Vandervort will repeat gonioscopy every few years.

However, for patients with recurrent uveitis, he performs gonioscopy once or twice a year. "Those angles can trick you. It happened to me one time," he says. "I wasn't paying attention to doing repetitive gonioscopy on a chronic uveitis patient and her angles zippered shut. And uveitic glaucoma due to angle closure is a mess to take care of."

Anterior segment OCT is an additional test that can help a clinician examine angle configurations and document whether an angle is at risk for occlusion, Dr. Mann says. "Explaining a prophylactic iridotomy for a narrow angle is one of the most difficult discussions to have with a patient (for them) to understand why we are doing surgery when there's not really a problem now, but they may have a problem in the future. Having that OCT to show them helps."

Even so, OCT should not replace gonioscopy, he adds. If this skill is not in your wheelhouse, start practicing on staff members and patients, and get comfortable with a test that is a basic part of the optometric exam.

### Don't Let Sudden Floaters Slide

• **Diagnostic data.** A 56-year-old white male reported to his optom-

### Comanagement Then and Now: The Omni Story

In the early 1980s, optometrists in most states had no therapeutic privileges, so referrals to MDs were necessary for even routine cases—such as pink eye—that are routinely handled by ODs today. This "one-way street" led to lost patients, in addition to family members who might be encouraged to see the MD for future care.

But thanks to a frustrated and forward-thinking group of optometrists in Georgia, the comanagement model was born. Led by the late Bill Cuthbertson, OD, Center Director William Wallace, OD, and two courageous ophthalmologists named Bob Lennon, MD and Ralph Dilorio, MD, an innovative concept grew into a thriving practice, which spread like wildfire to 14 centers nationwide. This new model of an optometrically-run referral practice focused on high-quality care and cooperation, with top notch surgeons recruited to provide advanced secondary care. Patients were sent back to the referring OD, with a meaningful letter explaining the diagnosis and treatment.

"The original comanagement center concept has taught ophthalmologists that if you want to have a high-volume surgical practice and deliver efficient care, then you need to work with optometry. You need to play nice, respect them, and let them do what they are trained to do," says optometrist Paul C. Ajamian, whose Atlanta-based Omni Eye Services was the first comanagement center in the country. "We've proven that it works for the benefit of all, especially patients who have access to care close to home by the optometrist that they know and trust."

Some 30 years after the comanagement model was introduced, there are still ophthalmologists who won't embrace the concept, Dr. Ajamian adds. For example, an MD may refuse to send the patient back to the referring optometrist following cataract surgery, citing ethical or legal reasons. "This is of course not true, because CMS/Medicare recognizes the comanagement arrangement," Dr. Ajamian says.


Fortunately, many surgeons have embraced this model, and relationships are better than they have been in the past. Dr. Ajamian reminds everyone, especially new graduates, to refer patients to doctors who are the most progressive, the most skilled, and the most open to working with and supporting optometrists and the optometric profession. "Sometimes the closest and most convenient option is not the best for your patients!" he says.

erist that he had been experiencing sudden floaters and decreased vision OS for the past day. He denied having any photopsia, or any previous trauma or comparable episodes.

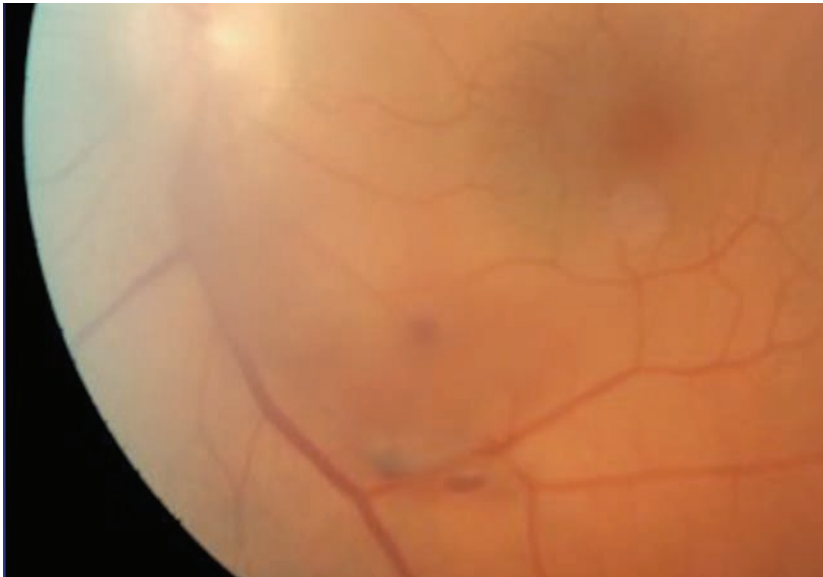
Best-corrected visual acuity was 20/20 OD and 20/40 OS, with no afferent pupillary defect. Visual confrontation fields were full, and the slit-lamp examination was normal. A fundus exam of the left eye showed blood in the vitreous.

What could be causing this vitreous hemorrhage?

• **Discussion.** "Always use caution in making a presumption that this is related to a vitreous detachment," Dr. Quinn says. If your patient has venous-occlusive disease, diabetic retinopathy, sarcoid, retinopathy of prematurity or sickle-cell disease, you could be looking at bleeding caused by retinal neovascularization. It could also be blood from an adjacent source,



In 1984, *Review* told the story of the new model of optometric referral centers.



**This patient had sudden floaters and decreased vision. Fundus exam showed blood in the vitreous. What could have caused it? And what do you do about it?**

such as macroaneurysms, tumors or choroidal neovascularization.

But, you're most likely dealing with a posterior vitreous detachment (PVD) with a small surface vessel that broke.

Regardless, all four doctors agree you need to see the patient immediately to make sure. If your patient does have a PVD, your next concern is to look for a retinal tear. "Most of the time, when you have blood in the eye, your expectations of tears go way up," Dr. Den Beste says. "And you don't want to miss a tear because it can lead to a retinal detachment, which of course is a much more serious condition."

Concern is warranted. About 15% of patients who present with acute, symptomatic PVD have a retinal tear—and as many as half have more than one.<sup>8</sup> When vitreous bleeding is present with acute PVD, the incidence of retinal tears jumps to 70%.<sup>8</sup>

Carefully examine the vitreous for pigment: Shafer's sign is an indicator of a retinal tear. You'll also need to take a close look at the

peripheral retina. The doctors recommend a 360° exam with binocular indirect ophthalmoscopy (BIO) and scleral depression. For the best view, have the patient recline or lie down in the exam chair, Dr. Mann says.

If the patient has a small pupil, a 30D lens may be helpful for better visualization. Dr. Vandervort also suggests using a three-mirror fundus lens for a more detailed view. "I am amazed at how many times I will find a small tear with a three-mirror lens that I missed on BIO," he says. This may take a little extra time, but it's worth the effort.

Also, look in the other eye. "You might get a better view without the vitreous hemorrhage to see if this patient has risk factors," Dr. Den Beste says. But if you're not able to get a good look, he stresses that you shouldn't hesitate to refer the patient to a retinal specialist for further evaluation.

Even if you don't detect any tears in a patient with acute PVD initially, don't rule out the possibility of a late retinal tear. Diligent fol-

low-up is just as crucial as careful diagnostic evaluation with vitreous hemorrhage.

Schedule follow-up within seven to 10 days, but emphasize that patients need to see you immediately if symptoms worsen or they experience any changes, i.e., more floaters or obscuration of vision.

"If you get new people on staff, make sure they understand the protocol for symptoms and the protocol for follow-up," Dr. Den Beste says. "A leading cause of malpractice in eye care is inappropriate scheduling of the patient."

A little tear is an easy fix compared to a vitrectomy or retinal detachment repair, he says. Early identification and active oversight at your clinic could limit the need for a retina specialist to perform more risky, interventional procedures later. ■

*This article was adapted from the Special Session, "Comanagement Conundrums," at SECO 2014, which was sponsored by VSP. However, this article has no commercial sponsorship.*

1. Hanet M, Jamart J, Chaves AP. Fluoroquinolones or fortified antibiotics for treating bacterial keratitis: systematic review and meta-analysis of comparative studies. *Canad J Ophthalmol.* 2012 Dec;47(6):493-9.
2. Srinivasan M1, Mascarenhas J, Rajaraman R, et al. Corticosteroids for bacterial keratitis: the Steroids for Corneal Ulcers Trial (SCUT). *Arch Ophthalmol.* 2012 Feb;130(2):143-50.
3. Robin AL, Covert D. Does adjunctive glaucoma therapy affect adherence to the initial primary therapy? *Ophthalmology.* 2005 May;112(5):863-8.
4. Dasgupta S, Oates V, Bookhart BK, et al. Population-based persistency rates for topical glaucoma medications measured with pharmacy claims data. *Am J Manag Care.* 2002 Aug;8(10 Suppl):S255-61.
5. Spooner JJ, Bullano MF, Ikeda LI, et al. Rates of discontinuation and change of glaucoma therapy in a managed care setting. *Am J Manag Care.* 2002;8:S262-0.
6. Gedde SJ, Schiffman JC, Feuer WJ, et al; Tube versus Trabeculectomy Study Group. Treatment outcomes in the Tube Versus Trabeculectomy (TVT) study after five years of follow-up. *Am J Ophthalmol.* 2012 May;153(5):789-803.
7. Fremont AM, Lee PP, Mangione CM, et al. Patterns of care for open-angle glaucoma in managed care. *Arch Ophthalmol.* 2003 Jun;121(6):777-83.
8. Sharma MC, Regillo CD, Shuler MF, et al. Determination of the incidence and clinical characteristics of subsequent retinal tears following treatment of the acute posterior vitreous detachment-related initial retinal tears. *Am J Ophthalmol.* 2004 Aug;138(2):280-4.

# Deposit Resistance: A Factor in Successful Overnight Lens Wear

Overnight contact lens wear can be a good option for selected patients—as long as they are properly educated and have the correct lens. **Brian D. Rosenblatt, OD**

While the risks of overnight contact lens wear are well known, the reality is that many patients sleep in their lenses—occasionally or routinely, with or without their doctor's blessing. The benefits to a patient are evident: convenience and continuous vision correction. For patients with certain occupations (eg, nurses who routinely work overnight shifts) or refractive conditions (eg, high myopia or aphakia), being able to keep their lenses in overnight is almost a necessity.

## PROGRESSIVE LIPID DEPOSITION

The advent of highly oxygen-permeable silicone hydrogel contact lens materials reduced the risk of hypoxic complications in both daily and overnight wear. However, the use of silicone, which gave these lenses their exceptional oxygen transmissibility, also made them inherently more hydrophobic—and thus, more prone to lipid adsorption—than the hydrogel lenses that preceded them.<sup>1</sup> And because lipid deposition is a cumulative process, continuous wear without daily removal and cleaning puts overnight wearers at increased risk for lipid deposits.

Deposits can contribute to lens discomfort, poor vision, and inflammatory reactions.<sup>1,2</sup> Lipid deposits, in particular, affect comfort and vision by adhering to and enlarging hydrophobic spots on the lens surface, making it less optically precise and less wettable.<sup>3</sup> Long-term deposit buildup can contribute to inflammatory events of the palpebral conjunctiva and may even facilitate microbial adhesion to the lens surface.<sup>3,4</sup>

## LENS SELECTION

All contact lens wearers—and especially those who wear lenses overnight—can benefit from a silicone hydrogel lens designed to resist lipid deposits. To reduce the hydrophobic effects of silicone, all silicone hydrogel lenses must undergo some modification (a coating, surface treatment, or internal wetting agent). Different lens materials and treatments, however, result in different lens surface characteristics—and

hence differences in the degree to which each attracts lipid deposits.<sup>1</sup>

In an analysis of lipid deposits on lenses worn continuously for 30 days, lower levels were found on lotrafilcon A than a comparator silicone hydrogel.<sup>1</sup> Researchers attribute this difference to lotrafilcon A's uniform, hydrophilic plasma surface treatment, permanently anchored to the lens matrix for wettability and deposit resistance through the entire wear cycle.<sup>1</sup>

- ▶▶ Be proactive: Ask patients about sleeping in lenses
- ▶▶ Identify patients who want or need overnight wear
- ▶▶ Select a lens that combines high oxygen permeability with a hydrophilic, deposit-resistant surface
- ▶▶ Explain and emphasize the benefits of AIR OPTIX® NIGHT & DAY® AQUA

I choose AIR OPTIX® NIGHT & DAY® AQUA contact lenses for any patient with an established need or desire for overnight wear. AIR OPTIX® NIGHT & DAY® AQUA lenses combine proven lipid resistance<sup>5\*\*</sup> and the highest-available Dk/t (175 at the center of a -3.00 D lens).<sup>6†</sup> These lenses are FDA-approved for both daily wear and up to 30 days and nights of continuous wear.<sup>†</sup> They offer excellent wettability, consistent comfort, and great vision.

## IDENTIFY AND EDUCATE

As many as one third of contact lens wearers may be sleeping in their lenses, but few will report doing so, either because we do not ask or because they are afraid to admit it.<sup>7</sup> Probing patients for their lens-wearing habits is essential, and begins with asking the right questions. Instead of "Are you sleeping in your lenses?" I ask questions like "When was the last time you fell asleep in your lenses?" or "How many nights in a row do you sleep in your lenses?"

Once we know which patients

are sleeping in lenses, and which are interested in doing so, we can prescribe the lenses best suited for overnight wear—and give clear instructions about how to use and care for them. In the real world, patients may be challenged to change their lens wearing habits; for appropriate patients, it makes sense to prescribe a lens designed for successful overnight wear.

With the highest oxygen transmission<sup>6\*</sup> and maximal resistance to lipid deposition,<sup>5\*\*</sup> AIR OPTIX® NIGHT & DAY® AQUA is my lens of choice for overnight wear.

\*Dk/t = 175 @ -3.00D. \*\*Lipid deposition compared to Biofinity^, PureVision^, ACUVUE^ OASYS^, ACUVUE^ ADVANCE^ and Avaira^ contact lenses. †Extended wear for up to 30 continuous nights, as prescribed by an eye care practitioner. ^Trademarks are the property of their respective owners.

**Important information for AIR OPTIX® NIGHT & DAY® AQUA (lotrafilcon A) contact lenses:** Indicated for vision correction for daily wear (worn only while awake) or extended wear (worn while awake and asleep) for up to 30 nights. **Relevant Warnings:** A corneal ulcer may develop rapidly and cause eye pain, redness or blurry vision as it progresses. If left untreated, a scar, and in rare cases loss of vision, may result. The risk of serious problems is greater for extended wear vs. daily wear and smoking increases this risk. A one-year post-market study found 0.18% (18 out of 10,000) of wearers developed a severe corneal infection, with 0.04% (4 out of 10,000) of wearers experiencing a permanent reduction in vision by two or more rows of letters on an eye chart. **Relevant Precautions:** Not everyone can wear for 30 nights. Approximately 80% of wearers can wear the lenses for extended wear. About two-thirds of wearers achieve the full 30 nights continuous wear. **Side Effects:** In clinical trials, approximately 3-5% of wearers experience at least one episode of infiltrative keratitis, a localized inflammation of the cornea which may be accompanied by mild to severe pain and may require the use of antibiotic eye drops for up to one week. Other less serious side effects were conjunctivitis, lid irritation or lens discomfort including dryness, mild burning or stinging. **Contraindications:** Contact lenses should not be worn if you have: eye infection or inflammation (redness and/or swelling); eye disease, injury or dryness that interferes with contact lens wear; systemic disease that may be affected by or impact lens wear; certain allergic conditions or using certain medications (ex. some eye medications). **Additional Information:** Lenses should be replaced every month. If removed before then, lenses should be cleaned and disinfected before wearing again. Always follow the eye care professional's recommended wear, care and replacement schedule. Consult package insert for complete information, available without charge by calling (800) 241-5999 or go to [myalcon.com](http://myalcon.com).

Brian D. Rosenblatt, OD, owns and practices at Rosenblatt Family Eye Care Associates, in Raritan, NJ.



## REFERENCES

1. Jones L, Senchyna M, Glasier MA, et al. Lysozyme and lipid deposition on silicone hydrogel contact lens materials. *Eye Contact Lens*. 2003;29(1S):S75-79.
2. Panaser A, Tighe BJ. Function of lipids—their fate in contact lens wear: an interpretive review. *Cont Lens Anterior Eye*. 2013;35(3):100-11.
3. Carney FP, Nash WE, Sentell KB. The adsorption of major tear film lipids in vitro to various silicone hydrogels over time. *Invest Ophthalmol Vis Sci*. 2008;49(1):120-4.
4. Zhao Z, Carrt NA, Aliwarga Y, et al. Care regimen and lens material influence on silicone hydrogel contact lens deposition. *Optom Vis Sci*. 2009;86(3):251-9.
5. Nash W, Gabriel M, Mowrey-McKee M. A comparison of various silicone hydrogel lenses; lipid and protein deposition as a result of daily wear. *Optom Vis Sci*. 2010;87:E-abstract 105110.
6. Based on the ratio of lens oxygen transmissibilities; Alcon data on file, 2009, 2010.
7. In a survey of 2,115 daily and extended wear contact lens patients; Alcon data on file, 2012.



## 19th Annual Comanagement Report

# Comanaging MIGS: The Birth of the Middle Class

No longer is glaucoma surgery a high-risk, high-reward venture. Safer—but more modestly beneficial—options are emerging. Here’s a look at the OD’s role.

By Lisa M. Young, OD

**B**ecause intraocular pressure remains the only modifiable aspect of glaucoma, decades of clinical effort and billions of research dollars have been directed at achieving ever-greater precision in controlling this lone variable.<sup>1,2</sup> Although alternative targets for medical or surgical intervention have remained elusive, a recent trend has been to exert IOP control through the most anatomically sparing means possible. Thus was born “minimally invasive” glaucoma surgery (MIGS), a movement to offer IOP lowering that’s more modest than conventional tube or trab procedures but in a far more patient-friendly way. Glaucoma surgeons—and the optometrists who refer to them—now have a mid-tier option to consider.

How should ODs approach glaucoma comanagement in the MIGS era? Let’s first review the conventional IOP-lowering modalities, then look at how MIGS fits in.

### The Old Standbys

The goal of glaucoma therapy, of course, is to preserve visual function by lowering IOP to a level less likely to produce further damage to the

optic nerve, based on many patient-specific factors (e.g., age, ability to tolerate chronic medication use, disease severity and progression). Traditionally, we have managed patients with topical or oral therapy, trabeculoplasty, and incisional glaucoma surgeries (trabeculectomy or drainage devices).

- **Medical therapy.** Topical anti-hypotensive agents remain the first-line therapy in lowering IOP, thanks to their favorable balance of clinical benefit vs. risk, as well as their cost effectiveness and reversibility. However, optometrists must assess the potential for patient non-compliance, inability to instill drops, medication side effects or preservative sensitivities to thwart long term success in medical management alone. This clinical judgment will factor in to the decision on whether—and when—to recommend a MIGS procedure.

Typical medication non-adherence is between 50% and 60%.<sup>3</sup> Persistent use of topical therapy may lead to ocular surface disruption and conjunctival inflammation, potentially impacting future surgical options if the condition continues to progress.<sup>4</sup> Oral carbonic anhydrase

inhibitors are beneficial for patients in need of a significant reduction in IOP, but are typically reserved for emergent situations due to their numerous systemic side effects.

- **Laser.** Argon or selective laser trabeculoplasty targets pigmented trabecular meshwork cells, administered as an outpatient single-session therapy. It has been shown to lower IOP by 20% to 30%, with efficacy maintained at a success rate of about 75% after 2.5 years.<sup>5,6</sup> There are no post-op changes in vision, although patients may note mild discomfort for the first 24 hours and have the potential to develop a low-grade iritis.

Patients may be sent home with a topical NSAID or steroid, or even without drops, based on the doctor’s preference. IOP is monitored seven to 10 days postoperatively.

Pretreatment glaucoma medications are continued for two to three months until the effect of the

**All intraoperative images courtesy of Derek Cunningham, OD, and Walter Whitley, OD. Narrated videos of these surgical procedures can be found online in the Surgical Minute archive at [www.revoptom.com/multimedia](http://www.revoptom.com/multimedia).**

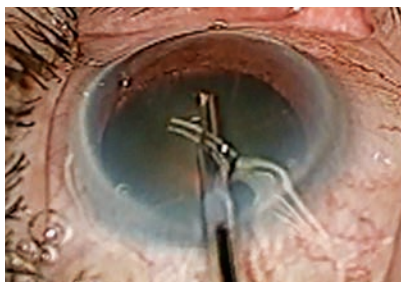
laser therapy can be fully assessed. Although there are no adverse effects with this intervention, about 20% of patients will demonstrate no change in IOP.<sup>7</sup> This procedure may be repeated, although it is thought to be less effective with each additional session.

• **Incisional surgery.** Trabeculectomy, considered the gold standard of glaucoma surgery, creates an additional source of aqueous drainage, bypassing the trabecular meshwork and ultimately creating a “bleb.” An adjunctive antimetabolite is commonly used by the surgeon to help prevent fibrosis and subsequent failure of the bleb.

Trabeculectomy is typically used for moderate to advanced glaucoma (i.e., one to two quadrants of field loss). This procedure may be advantageous—or perhaps necessary—when trying to achieve a target IOP less than 12mm Hg to 14mm Hg.

One shortcoming of this procedure is its demanding postoperative course. The patient is asked to refrain from bending over, stooping or lifting anything greater than 10 pounds up to three weeks following surgery. These limitations can affect the patient’s ability to work and ultimately function independently. Patients are instructed to use a topical antibiotic drop for the first seven to 10 days, and a topical steroid for the first four to six weeks.

A comanaging optometrist, if involved in the post-op care, would follow the patient very closely in the first few weeks (often one to two times per week for the first two to three weeks after surgery) to monitor the outflow of aqueous, formation of the bleb and to remove sutures. The placement of sutures may affect the patient’s vision and refractive error. Visual recovery and stability often takes two to three months. The postoperative course



**The Trabectome procedure ablates 60° to 120° of trabecular meshwork tissue.**

for these patients is somewhat unpredictable; risks include wound leakage, excessive filtration (leading to hypotony), bleb dysesthesia, bleb failure and the need for subsequent revisions and endophthalmitis.

Glaucoma drainage devices (GDD) aid in the filtration process by shunting aqueous from the anterior chamber to an extraocular reservoir through a tube. This procedure is typically reserved for patients with moderate to advanced glaucoma who have a target IOP less than 12mm Hg to 14mm Hg and may not do well with a trabeculectomy. This procedure is indicated in patients who have uveitis, neovascular glaucoma, aphakia, inadequate conjunctival tissue or a previously failed trabeculectomy.

The postoperative period includes the use of topical corticosteroids for four to six weeks, antibiotics for seven to 10 days and cycloplegics for three to six weeks. Complications of a GDD include over-filtration, tube obstruction, migration or erosion, motility disturbances and endophthalmitis.

### MIGS in the Middle

Due to the arduous nature of traditional glaucoma surgery, the search continues for newer procedures that may suffice as a safer alternative to trabeculectomy for patients with mild to moderate glaucoma. The minimally-invasive

glaucoma surgeries are a subset of newly developed procedures that offer a faster recovery, lower complication rates, minimal impact on refractive error and preservation of the conjunctival tissue, should filtering surgery be warranted in the future. But, their IOP lowering effect is less robust than incisional surgery as well. These procedures are optimal for patients with a target IOP in the mid/high teens to low 20s, with better IOP control seen when the target IOP is at the higher end of that range.<sup>8</sup>

Given their comparatively modest benefit in IOP reduction, MIGS procedures are typically combined with cataract surgery to spare the patient another surgical procedure that may otherwise be difficult to justify on IOP modification alone. Indeed, a recent retrospective analysis of the Ocular Hypertension Treatment Study found that cataract surgery itself confers about a 16.5% reduction in IOP.<sup>9</sup> The MIGS procedures can be seen as additive to that effort rather than a primary surgery in some cases.

Currently, the Trabectome (NeoMedix) and iStent (Glaukos) are two FDA-approved MIGS devices that modify the trabecular meshwork, either by removing (Trabectome) or bypassing (iStent) the affected tissue, thought to be the major source of outflow resistance.

When a MIGS procedure is being performed in conjunction with cataract surgery, surgeon preference based on individual patient characteristics dictates which procedure will be performed first. While it is often recommended to perform the glaucoma procedure first, the surgeon may elect to begin with cataract extraction on a patient with a shallow anterior chamber or short axial length. Removing the cataract first potentially allows the surgeon


improved visualization of the trabecular meshwork and ease the process of the glaucoma procedure.

Prior to these surgical procedures, thorough gonioscopy should be performed to rule out peripheral anterior synechia, neovascularization, angle closure or any other abnormality that would prohibit visualization of the angle or alteration of the trabecular meshwork during the surgery.

- **Trabectome.** In this procedure, a 19.5-gauge instrument is inserted temporally through a clear corneal incision and directed towards the nasal anterior chamber. Using a surgical gonio lens, the footplate of the device is inserted through the trabecular meshwork into Schlemm's canal. This procedure ablates 60° to 120° of trabecular meshwork and the inner wall of Schlemm's canal. The clear corneal incision is then closed with a suture.

Following the procedure, patients are maintained on a topical antibiotic for one week and a topical corticosteroid for three to four weeks. They continue their preoperative glaucoma medications for the first four to six weeks and are instructed to use a topical parasympathomimetic agent (e.g., pilocarpine 1-2% QID or isopto-carbachol 1.5% BID) for the first six to eight weeks. These patients are typically seen for follow-up in one day, five to seven days, two to three weeks and two to three months after the surgery. The most common complications of the Trabectome include early IOP spikes and hyphema.<sup>10</sup>

The use of a parasympathomimetic drop is to help open the trabecular meshwork, prevent fibrosis and ultimately increase aqueous outflow after the Trabectome procedure. Due to the potential retinal side effects associated with this therapy, a thorough fundus



**The iStent is placed in Schlemm's canal to augment aqueous outflow.**

examination is indicated prior to the procedure. Referral to a retina specialist for clearance may need to be considered in patients with high myopia, lattice degeneration or a history of retinal breaks.

Patients may complain of side effects associated with the subsequent miosis of the parasympathomimetic, most commonly a head or brow ache. When comanaging the post-op care, you can alleviate this by gradually increasing the strength of the medication or switching to a different drug in the same class.

For instance, if a patient is having difficulty with pilocarpine 2%, it may be worthwhile to drop down to pilocarpine 0.5% to 1% for the first week and then gradually increasing back to 2% once the patient has acclimated. Another alternative may be to switch from pilocarpine to isopto-carbachol. It is important to educate patients on the importance of this medication on the long term outcome of this surgery, as this often improves compliance with this drop.

- **iStent.** This device is a 1mm heparin-coated stent inserted with an applicator through a clear corneal incision. Also using a surgical gonioscopy lens, the device is implanted through the nasal aspect of the trabecular meshwork into Schlemm's canal after being released


from the applicator. Recent studies have demonstrated the potential benefit of implanting more than one stent for an additional degree of IOP reduction.<sup>11</sup> The iStent can be difficult for surgeons to place, especially in restless patients or those with peripheral anterior synechia or corneal edema. The clear corneal incision is then closed with a suture.

Following the procedure, patients are placed on a topical antibiotic for one week and topical corticosteroid for three to four weeks, and continue their preoperative glaucoma medications for the first three to six weeks. They are typically seen for follow up in one day, seven days, three weeks and two to three months after the surgery. The most common complications of the iStent include elevated IOP and stent obstruction or malposition.<sup>12</sup>

- **Express mini-shunt.** While Alcon's device is sometimes classified within the MIGS category, its similarities to incisional procedures (e.g., bleb formation, postoperative course, potential complications and greater IOP-lowering effect) make it more akin to trabeculectomy. Indeed, one study found better IOP control among Express patients than those who had undergone conventional trabeculectomy.<sup>13</sup>

The Express is a non-valved stainless steel shunt inserted under a conjunctival flap to shunt aqueous from the anterior chamber towards a subconjunctival reservoir, in a manner very similar to a traditional partial-thickness filter. In practice, the Express mini-shunt is often used in conjunction with a trabeculectomy. The benefit of this device stems from its potential ability to better regulate the outflow of aqueous, presumably decreasing the risk of hypotony and hypotony-related complications that are experienced with a trabeculectomy.

# The Rock 'em Sock 'em Glaucoma Machine



## The Octopus 600 Perimeter

It's working. Thanks to doctors like you and early diagnosis, the risk of blindness due to glaucoma has been cut by 50%. But Octopus can do better. It's the all-in-one early detection and management device with the most accurate and reproducible data. Take your best shot at one soon.

Call Haag-Streit for an online demo at 800-787-5426.



Tradition & Innovation.

800-787-5426  
[haag-streit-usa.com](http://haag-streit-usa.com)

© 2014 Haag-Streit USA. All Rights Reserved.

 **HAAG-STREIT**  
USA

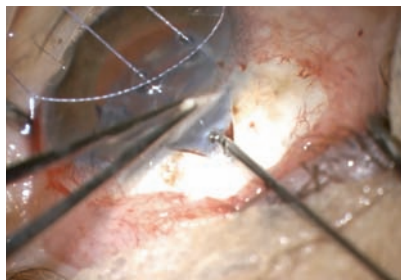## Managing MIGS Post-op

It is important to perform gonioscopy within the first few weeks following these surgeries, as it is the best way to visualize the surgical result. Following the Trabectome procedure, note the clock hours of trabecular meshwork that were removed and monitor for alterations, such as fibrosis of the tissue. While visualization of the iStent may be possible at the slit lamp, a gonioscopic view is required to monitor the stent for potential obstruction or malpositioning.

Fluctuations in IOP are often noted after these procedures. In the first few days following surgery, increased IOP may be related to retained viscoelastic or red blood cells in the anterior chamber, which can clog the trabecular meshwork and cause an obstruction of aqueous outflow. Increased IOP after iStent implantation may be caused by obstruction or malpositioning of the stent. IOP spikes following the surgery should be addressed accordingly through observation, the addition of topical or oral therapy, paracentesis or repositioning/replacement of the iStent by the surgeon, depending on the severity of individual's glaucoma and the magnitude of the IOP spike.

An IOP response to a steroid should be considered if the IOP elevates after three to six weeks of prolonged steroid use. At this point, tapering off the steroid would be the most effective way to stabilize the IOP.

A hyphema during these procedures is common and usually caused by reflux from Schlemm's canal. The Trabectome affects a larger area of trabecular meshwork and typically creates a larger blood reflux than the iStent. This most commonly resolves within the first week.



**The Express mini-shunt, sometimes considered to be a MIGS procedure, is a safer alternative to trabeculectomy.**

As in cataract surgery, vision should stabilize in the first one to two weeks following these procedures. Patients with a hyphema should be educated that the vision may have more drastic fluctuations until the blood clears, especially after bending over or changing head positions. Patients who are using a miotic should be educated on the effects of the drug and subsequent miosis on the visual system.

A single suture is often used to close the wound for a larger clear corneal incision, complex cataract surgery with phaco, and with some of the MIGS procedures. They are typically left in place long term and should not disrupt the ocular surface or patient comfort. It is critical to stain sutures with sodium fluorescein to examine for breaks and to monitor for exposure. Patients may report pain or a foreign body sensation if a suture has broken and become exposed. Due to the risk of infection by an exposed suture, a topical antibiotic should be used until the surgeon can remove it.

The ultimate goal of treatment should be to achieve the target IOP with the least amount of risk and impact to the patient. With the arrival of the MIGS options, safe and effective surgical alternatives are now available in early to moderate glaucoma. These procedures potentially open the door to earlier

prevention of glaucoma-related vision loss. Current research is being directed at improving their IOP reduction without a commensurate increase in risk profile. Investigational devices (e.g., CyPass microstent, Hydrus II, SolX Gold shunt) as well as next-generation versions of the currently approved devices give optometrists and their patients reasons to remain optimistic about the burgeoning field of newer, safer surgeries. ■

*Dr. Young is in practice at Chicago Glaucoma Consultants in Glenview, Ill. and is an assistant professor, adjunct faculty at the Illinois College of Optometry.*

1. Hejil A, Leske MC, Bengtsson B, et al. Reduction of intraocular pressure and glaucoma progression: Results from The Early Manifest Glaucoma Trial. *Arch Ophthalmol.* 2002 Oct;120(10):1268-79.
2. The Advanced Glaucoma Intervention Study (AGIS): 7. The relationship between control of intraocular pressure and visual field deterioration. The AGIS Investigators. *Am J Ophthalmol.* 2000 Oct;130(4):429-40.
3. Rees G1, Chong XL, Cheung CY. Beliefs and Adherence to Glaucoma Treatment: A Comparison of Patients From Diverse Cultures. *J Glaucoma.* 2013 Jan 31.
4. Baudouin C, Pisella PJ, Fillacier K, et al. Ocular surface inflammatory changes induced by topical antiglaucoma drugs: human and animal studies. *Ophthalmology.* 1999;106(3):556-63.
5. Damji KF, Shah KC, Rock WJ, et al. Selective laser trabeculoplasty v argon laser trabeculoplasty: a prospective randomized clinical trial. *Br J Ophthalmol.* 1999;83:718-722.
6. Melamed S, Ben Simon GJ, Levkovitch-Verbin H. Selective laser trabeculoplasty as primary treatment for open angle glaucoma: a prospective, nonrandomized pilot study. *Arch Ophthalmol.* 2003 Jul;121(7):957-60.
7. McIlraith I, Strasfeld M, Colev G, Hutnik CM. Selective laser trabeculoplasty as initial and adjunctive treatment for open-angle glaucoma. *J Glaucoma.* 2006 Apr;15(2):124-30.
8. Ahuja Y1, Ma Khin Pyi S, Malih M, et al. Clinical results of ab interno trabeculectomy using the trabectome for open-angle glaucoma: the Mayo Clinic series in Rochester, Minnesota. *Am J Ophthalmol.* 2013;156(5):927-35.
9. Mansberger SL, Gordon MO, Jampel H, et al. Reduction in intraocular pressure after cataract extraction: the Ocular Hypertension Treatment Study. *Ophthalmology* 2012 Sept;119(9):1826-31.
10. Mosaed S, Rhee DJ, Filippopoulos T, et al. Trabectome outcomes in adult open-angle glaucoma patients: One-year follow-up. *Clin Surg Ophthalmol.* 2010;28(8/9):182-6.
11. Hays CL, Gulati V, Fan S, et al. Improvement in Outflow Facility by Two Novel Microinvasive Glaucoma Surgery Implants. *Invest Ophthalmol Vis Sci.* 2014 Feb 18. pii: iovs.13-13353v1. doi: 10.1167/iov.13-13353.
12. Craven ER, Katz LJ, Welss MW, et al. Cataract surgery with trabecular micro-bypass stent implantation in patients with mild-to-moderate open-angle glaucoma and cataract: two-year follow-up. *J Cataract Refract Surg.* 2012 Aug;38(8):1339-45.
13. De Jong L, Lafuma A, Aguade AS, Berdeaux G. Five-year extension of a clinical trial comparing the EX-PRESS glaucoma filtration device and trabeculectomy in primary open-angle glaucoma. *Clin Ophthalmol.* 2011;5:527-33.



He switched  
from clear lenses.  
And it changed  
his life.



*"I rely on Transitions lenses to help me see my best so I can truly enjoy what I do."*

*—Robert Irvine*

*Official Sponsor of Sightseeing™ Ambassador*

**NEW**

**Transitions®**  
**Signature™ VII**

ADAPTIVE LENSES

For more than 10 years, celebrity chef Robert Irvine has counted on authentic Transitions® lenses to enhance his vision. He only chooses the breakthrough technology of Transitions® Signature™ VII lenses. He loves having full clarity indoors and just the right amount of tint outdoors.

Hear Robert's personal vision story and how he lives a Life well lit™ at

[TransitionsPRO.com/Robert](http://TransitionsPRO.com/Robert)

Transitions and the swirl are registered trademarks and Life well lit, Transitions Adaptive Lenses, Transitions Signature and The Official Sponsor of Sightseeing are trademarks of Transitions Optical, Inc. ©2014 Transitions Optical, Inc. Photochromic performance is influenced by temperature, UV exposure and lens material.

**100%**  
UV BLOCK

# The Solution Choice is Clear

Artis L. Beatty, MS, OD, MBA

Sensitivity to the preservatives in multi-purpose contact lens solutions can compromise patients' wearing experience—but a switch to CLEAR CARE® can boost comfort while offering exceptional disinfection efficacy.

Dozens of times each week, I ask patients who are new to our practice about their contact lens care solutions. Most often, I receive a predictable and uniform response, "Whatever is on sale — aren't they all the same?"

Patients typically aren't aware of which solutions they use, and without clear, repeated instruction from us, will often choose the cheapest multi-purpose solution they can find. Perhaps unsurprisingly, these patients also often have complaints about their contact lens comfort, consistency, and longevity. Of all the things we recommend for patients in order to maintain vision quality, the proper contact lens solution is extremely important, but too easily overlooked.

CLEAR CARE® Solution delivers proven antimicrobial protection, while virtually eliminating preservative impact on the ocular surface

## The Problem

Advances in contact lens material development have been aimed at providing wearers with a healthy option and comfortable experience. Attempts have been made to update contact lens care products in tandem with lens materials to enhance comfort, but the unique formulation of CLEAR CARE® Solution continues to offer an excellent option for a wide variety of patients and lens materials — delivering proven antimicrobial efficacy while minimizing preservative impact on the ocular surface.<sup>1</sup> Perhaps that is why CLEAR CARE® is the lens care solution most trusted by eyecare practitioners.<sup>2</sup>

## Solution Sensitivity

Patients using multi-purpose solutions may complain

### Consider CLEAR CARE®

Patients are often unaware of the contact lens care solution they use

Sensitivity to solution preservatives can manifest as early-day stinging and late-day discomfort

CLEAR CARE® provides powerful disinfection and neutralizes to a gentle saline solution with no added preservatives

A switch to CLEAR CARE® can alleviate solution sensitivity issues

Lenses feel "like new" after cleaning with CLEAR CARE®

that their contact lenses seem to burn or sting during and just after insertion. These patients will complain that their eyes become red, irritated, and uncomfortable. When I examine their eyes, I often find mild to moderate staining of the cornea.

These symptoms and signs suggest contact lens solution sensitivity. When used with certain lens materials, some of the disinfectant preservatives in multi-purpose solutions can cause punctate corneal staining; which, particularly when severe, may be accompanied by discomfort.<sup>3</sup>

## Making a Switch

The good news is that solution sensitivity is one of the more manageable causes of contact lens associated discomfort. For many patients, a switch to CLEAR CARE® for contact lens disinfection and cleaning can make all the difference in their experience of contact lens wear. The unique formulation and efficient, reliable neutralization of CLEAR CARE® to a gentle saline solution combine to keep lenses comfortable and gentle on the cornea. In fact, the neutralization process leaves a solution virtually free of residual peroxide — far less than the eye can feel when used as directed.<sup>4</sup>

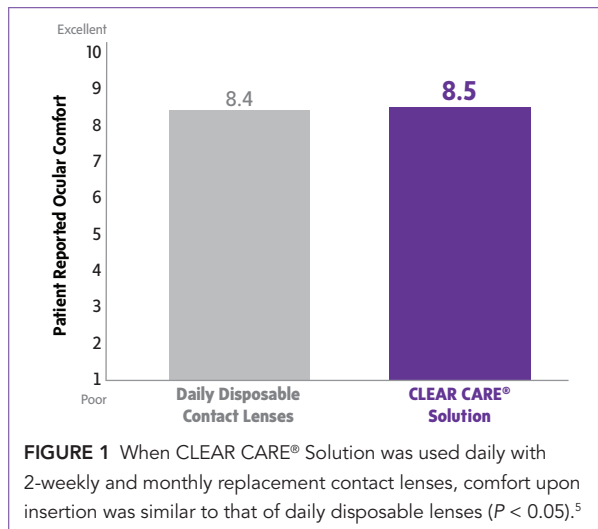
CLEAR CARE® has no added preservatives, and so leaves no irritating residue on lens surfaces or within the polymer matrix. As a result, after disinfection in CLEAR CARE®, contact lenses are left feeling more like new, ocular tissues are not compromised by residual preservative, and wearers experience enhanced comfort on insertion (Figure 1).<sup>5</sup> In a market research study of CLEAR CARE® users, 4 out of 5 agreed that cleaning and disinfecting their lenses with CLEAR CARE® got their

lenses so fresh, they felt like new.<sup>6</sup>

We know that, in addition to purchasing contact lens solutions without much thought about what they contain, our patients may not reliably follow the manufacturers' instructions for using these solutions. Another reason I favor CLEAR CARE® is the need to disinfect lenses for a full 6 hours; I'm reassured that when I recommend and explain the use of CLEAR CARE® to my patients, they will understand that CLEAR CARE® is different — and will more readily follow my instructions. Indeed, the broad antimicrobial activity of CLEAR CARE® — even against the difficult-to-eradicate cyst form of *Acanthamoeba castellanii* — is unmatched by most multi-purpose solutions.<sup>7</sup>

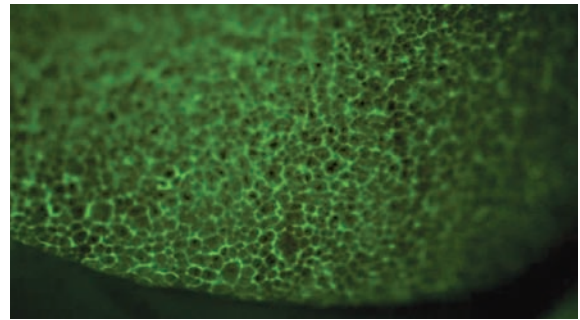
### A Clean Lens Surface

In addition to disinfection, the right contact lens solution and cleaning regimen is also necessary for deposit removal. The persistent foreign body sensation and mechanical irritation (even, in some cases, papillary conjunctivitis) that can come from significant contact lens deposits may be ameliorated by a change to CLEAR CARE® (Figure 2).<sup>8,9</sup>



**FIGURE 1** When CLEAR CARE® Solution was used daily with 2-weekly and monthly replacement contact lenses, comfort upon insertion was similar to that of daily disposable lenses ( $P < 0.05$ ).<sup>5</sup>

The unique, patented formulation of CLEAR CARE® — a formulation often imitated, but never duplicated by other hydrogen peroxide solutions — contains the surfactant Pluronic 17R4, which enhances cleaning and removal of protein and lipid deposits. The bubbling action of the neutralizing peroxide also provides a mechanical force to further boost lens cleaning.



**FIGURE 2** A papillary reaction on the superior tarsal conjunctiva, made visible with fluorescein dye. Printed with permission of Cecile Maissa, PhD

### The Clear Choice

With so many contact lens solution options available, it is critical that we educate our patients appropriately about what to buy and how to use it. Just as we prescribe contact lenses that provide the best comfort, fit, and vision for our patients, we must also educate our patients on the solution best suited to meet their needs. With proven disinfection capability, surfactant-enhanced lens cleaning, and minimal impact on ocular surface tissues, CLEAR CARE® is the obvious choice.<sup>10</sup>



Artis L. Beatty, MS, OD, MBA, is the associate director of clinical operations at Eye Care Associates in Raleigh, NC.

### REFERENCES

1. Konyonenbelt BJ, Minarik DS, Ubels JL. Effects of peroxide-based contact lens-disinfecting system on human corneal epithelial cells in vitro. *Eye Contact Lens*. 2011;37(5):286-97.
2. Alcon data on file, 2013.
3. Andrasko G, Ryan K. Corneal staining and comfort observed with traditional and silicone hydrogel lenses and multipurpose solution combinations. *Optometry*. 2008;79(8):444-54.
4. Paugh JR, Brennan NA, Efron N. Ocular response to hydrogen peroxide. *Am J Optom & Physiol Optics*. 1988;65:2,91-8.
5. Diec J, Papas E, Naduvilath T, et al. Combined effect of comfort and adverse events on contact lens performance. *Optom Vis Sci*. 2013;90(7):674-81.
6. A market research study conducted amongst 107 US contact lens wearers representative of CLEAR CARE® purchasers in the United States, 2007.
7. Mowrey-McKee M, George M. Contact lens solution efficacy against *Acanthamoeba castellanii*. 2007;33(5):211-5.
8. Maissa C, Guillon M, Wong S, Lane A, Patel T, Garofalo R. Silicone hydrogel contact lens effects on eyelid tissues: lens care influence. Poster presented at BCLA 2013;E-Abstract 72.
9. Maissa C, Guillon M, Wong S, Lane A, Patel T, Garofalo R. Effect of lens care system on silicone hydrogel contact lens wettability. Poster presented at ARVO 2013;E-Abstract 491-B0128.
10. Amos C. Comparing lens care systems for silicone hydrogel contact lenses. *Contact Lens Spectrum*. 2007 [www.clspectrum.com/printarticle.aspx?articleID=101185](http://www.clspectrum.com/printarticle.aspx?articleID=101185). Accessed December 5, 2013.



# Be a Neuro-ophth 'First Responder'

When the eye—and even the patient—hangs in the balance, prompt action and careful collaboration could save the day. **By Andrew J. Rixon, OD, and Andrew S. Gurwood, OD**

**T**he prospect of a patient presenting with an acute neuro-ophthalmic disorder can be intimidating. As primary eye care providers, it is important to embrace the full breadth of our role—uncovering the cause, making the diagnosis, providing first aid and stabilizing the issue, developing the initial management plan, contacting the appropriate specialty care practitioner, and educating the patient about the condition and the comprehensive management process. Also, it is your responsibility to inform the individual's primary care provider (PCP) of any neuro-ophthalmic diagnosis, because he or she likely will have the responsibility of following the patient once specialty care is delivered.

Here, we'll review some of the most common neuro-ophthalmic emergencies and describe the role that optometrists play in the referral and comanagement processes.

## Neuro-Ophthalmic Emergencies

Neuro-ophthalmic emergencies are conditions that pose a sudden

threat to visual system function and/or systemic wellbeing.<sup>1</sup> Some examples include acute painful Horner's syndrome, painful cranial nerve palsies, optic disc edema, acute painless vision loss and severe headaches.

Once uncovered, time is of the essence. As a matter of reference, emergencies are classified into one of five triage levels:<sup>2</sup>

- *Immediate*
- *Emergent* (required evaluation within one to 14 minutes)
- *Urgent* (treatment required within 60 minutes)
- *Semi-urgent* (required evaluation within one to two hours)
- *Non-urgent* (a delay of up to 24 hours would make no appreciable difference in the overall clinical management of the condition)

It is generally accepted that the hallmark of a true eye care emergency is the potential for loss of sight (or even life) within 48 hours. By comparison, an ocular urgency is regarded as a condition that may result in significant morbidity or progress to an emergency at a later time (likely greater than 48 hours).<sup>3</sup>

The literature widely substanti-

ates good decision making among optometrists. In a retrospective review of optometric malpractice payments from 1991-2008, researchers showed that less than 2% of payments stemmed from a failure or delay in the referral/consultation process.<sup>4</sup>

While knowledge of the condition and the associated standard of care can raise awareness of how rapidly the condition should be referred, consultation with a specialist via personal contact or phone conversation is the best method of determining the proper timetable.

• *Giant cell arteritis (GCA)* is the quintessential medical emergency in eye care, because blindness is imminent without proper disease recognition and prompt treatment.<sup>5</sup> According to Sohan S. Hayreh, MD, there is no definitive "safe intervention period" that will ensure visual preservation between the time of GCA diagnosis and the initiation of corticosteroid therapy.<sup>6</sup> Nevertheless, permanent sequelae from GCA are reported to occur in 30% to 60% of patients who do not receive prompt treatment.<sup>6</sup>

Once a patient has lost vision in one eye, the risk of GCA-related visual loss in the fellow eye is highest within hours to days.<sup>5</sup> Contralateral eye involvement occurs in up to 75% of untreated patients.<sup>7</sup> Timely corticosteroid use reduces the percentage of devastating visual loss by 14% to 20%.<sup>6</sup> When patients present with any associated vision loss, the primary treatment goal is to retard the process—namely, reducing the risk of disease progression in the affected eye and preventing any vision loss from occurring in the fellow eye.

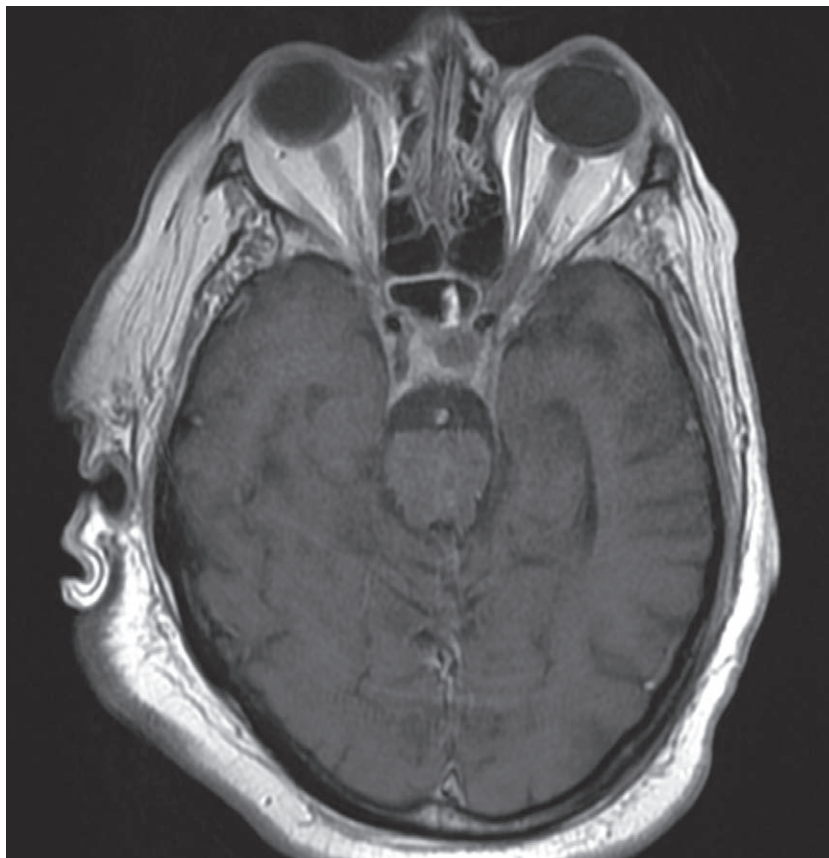
- **Pituitary tumor apoplexy** is a rare neurosurgical emergency that results from an acute ischemic or hemorrhagic infarction within pre-existing pituitary adenomas.<sup>8</sup> It is one of the most serious, life-threatening complications of pituitary adenoma.

The term “pituitary tumor apoplexy” should be reserved for cases that feature an abrupt onset of the most common signs and symptoms, including headache (92%), nausea and vomiting (54%), oculomotor paresis (54%), visual disturbances (50%) and/or altered mental state (42%).<sup>9</sup> In more than 60% to 80% of documented cases, pituitary tumor apoplexy occurs spontaneously in previously asymptomatic patients or in those with undiagnosed adenomas.<sup>10,11</sup>

The extent of neurological and neuro-ophthalmological improvement following surgical intervention was reported to be higher when decompression was performed within one week of symptom manifestation.<sup>11</sup>

Mortality occurs in up to 12.5% of those with pituitary tumor apoplexy. Patients with signs/symptoms must be referred for an immediate neuro-ophthalmic work-up.

- **Cervical carotid artery dis-**



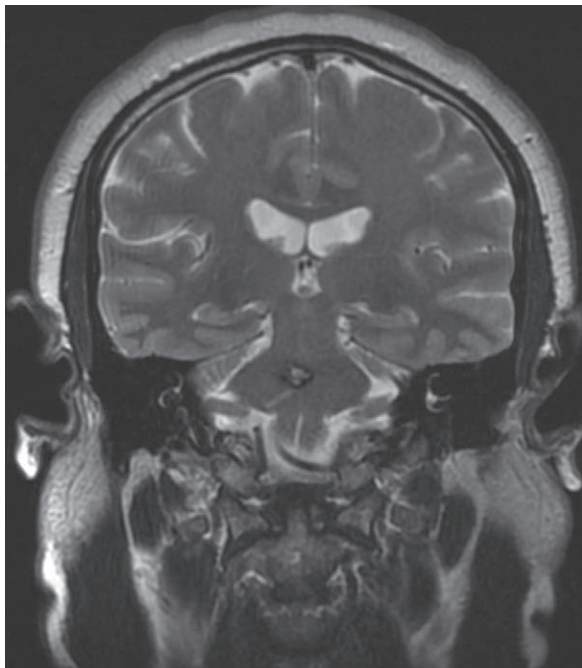
**Axial T1-weighted image of a necrotic pituitary macroadenoma. Apoplexy onset was considered to be subacute. The patient presented with a severe headache and incomplete left CN III palsy. Symptoms of diplopia had substantially increased in both frequency and magnitude over the previous four days. The patient underwent surgical resection of the macroadenoma within 72 hours of diagnosis, which yielded diplopia resolution.**

*section* is the underlying cause of approximately 2.5% of all strokes. More specifically, it accounts for 10% to 25% of ischemic cerebral events in patients younger than 45 years old.<sup>12</sup> More than a quarter of patients with stroke secondary to cervical artery dissection develop relevant disability, while almost half report a decreased quality of life.<sup>13</sup>

Headache is reported in up to 69% of affected patients, and neck pain has been found in up to 49% of patients—typically in the ipsilateral upper anterolateral cervical region.<sup>14</sup> Additionally, Horner’s syndrome may be found in up to 50% patients with carotid artery

dissection.<sup>14</sup> Patients who present with sudden-onset, painful, unilateral Horner’s syndrome should be suspected of carotid artery dissection until proven otherwise.<sup>12-14</sup>

Because most carotid artery dissections heal spontaneously, timely treatment is aimed at limiting neurological deficits by preventing thromboembolic complications and restoring blood flow.<sup>14</sup> Meta-analyses that compare antiplatelet to anticoagulant therapy conclude that the former should be first-line treatment in these cases. Remember that hyperacute management of ischemic stroke restricts the use of antiplatelet medications to eligible



Coronal T2-weighted image of a cavernous pontine angioma.

candidates to within 4.5 hours of the event.<sup>15</sup> Immediate referral is the standard of care.<sup>12-15</sup>

- **Papilledema** refers to swelling of the optic disc as a consequence of increased intracranial pressure (ICP). This is in contrast to papillitis, where disc edema is associated with inflammation or infection. In either case—visual loss occurs secondary to neuronal dysfunction after axoplasmic stasis. Typically, visual prognosis correlates to optic disc appearance during the acute presentation.<sup>16</sup>

Increased ICP with subsequent papilledema is observed in many conditions, including idiopathic intracranial hypertension, intracranial tumors, shunt obstruction, subdural hematoma, intracranial inflammation and subarachnoid hemorrhage.<sup>20</sup> Clearly, the sequelae from these processes can threaten vision and signal the development of fatal disease. Observation of the condition requires an emergent response, including transfer of care

to a neurology subspecialist. In some instances, an emergency department visit may be required to first establish the patient in that facility's health system. The emergency physician can then obtain a consultation from the appropriate specialist.

- **Aneurysm** of an undiagnosed origin has been reported to cause mortality in up to 20% of affected individuals within 48 hours of onset. The incidence of third nerve palsy associated with

internal carotid artery-posterior communicating artery (ICA-PCoA) aneurysm has been reported to be as high as 56%.<sup>18</sup>

Recent studies have shown that posterior circulation aneurysms (specifically, those of the posterior communicating artery) are more likely to rupture than others.<sup>18-21</sup> Treatment of unruptured intracranial aneurysms in the setting of third nerve palsy is aimed at preventing rupture.

However, in patients with subarachnoid hemorrhage secondary to aneurysmal rupture, aneurysm treatment is intended to prevent a rebleed.<sup>19</sup>

Early endovascular management (within one week following CN III symptom onset) likely is the strongest positive predictor of clinical outcome.<sup>18</sup> One study indicated that 50% of patients with ruptured PCoA and 48% of patients with unruptured ICA aneurysms had incomplete third nerve palsy at admission.<sup>20</sup> Painful third nerve

palsy must be considered to have an aneurysmal etiology, and always requires emergent referral.<sup>21</sup>

## How to Inform the Patient

Prior to transferring a patient's care, it is necessary to educate them regarding their condition. Inadequate physician-patient communication can result in poor compliance, as well as increased morbidity and mortality.<sup>22</sup>

The literature also recommends assessing the patient's frame of mind, along with his or her ability to understand the alternatives and choices.<sup>22</sup> If the individual is of sound mind, a patient-oriented approach can be used. In fact, "patient-centered care" is now the gold standard in Europe and the United States, and widely embraces the notion that "there should be no decision about me, without me."<sup>23</sup>

When educating a patient, the standard informed consent process requires full disclosure of findings, a clinical justification for referral to another provider or facility, and a recommendation regarding the timeliness of that referral.<sup>24</sup> Even in cases where the diagnosis isn't firm, the potential issues must be discussed and the reason for referral must be explained.

To ensure that the patient is adequately informed, you should make a reasonable effort to overcome problems associated with intellect, language and/or impairment associated with illness.<sup>25</sup>

Further, you must always be considerate of any unique wishes articulated by individual patients. For example, some may prefer to use a local doctor, while others may prefer a doctor who is a member of a certain hospital network. Once the decision to refer occurs, or is denied against medical advice, that informed decision must be meticu-



# Break the Cycle of Discomfort for unsurpassed comfort & vision all day<sup>1</sup>



Introducing Bausch + Lomb ULTRA<sup>TM</sup> contact lenses with MoistureSeal<sup>TM</sup> technology.

- Features MoistureSeal technology to help prevent lens dryness<sup>2</sup>
- Unique combination of Dk/t, modulus, and water content<sup>3</sup>
- Provides superior end-of-day vision\* for digital device users<sup>1</sup>

Learn more, and see why you should upgrade your patients at [BLultra.com](http://BLultra.com).

1. Results from a 22-investigator, multi-site study of Bausch + Lomb ULTRA<sup>TM</sup> contact lenses with MoistureSeal<sup>TM</sup> technology, on 327 current silicone hydrogel lens wearers. After 7 days of wear, subjects completed an online survey. Subjects rated performance across a range of attributes. Preference comparisons represent only those subjects expressing a preference. Ratio is based on the average across the silicone hydrogel lenses represented in the study. 2. Results of an in vitro study in which Bausch + Lomb ULTRA<sup>TM</sup>, ACUVUE OASYS, AIR OPTIX AQUA, and Biofinity contact lenses were placed on a model cornea with 0.18  $\mu\text{m}$  of spherical aberration. Images were acquired every 10 seconds up to 30 seconds and analyzed using pattern matching algorithms. A score for each 10-second interval is determined by comparing how closely the test image matches the time 0 image. Mean scores over the 30-second interval were determined and compared. 3. Data on file. Bausch + Lomb Incorporated, Rochester, NY, 2013. \*Among the leading silicone hydrogel lenses.

Bausch + Lomb ULTRA and MoistureSeal are trademarks of Bausch + Lomb Incorporated or its affiliates. All other brand/product names are trademarks of their respective owners. © 2014 Bausch + Lomb Incorporated. US/ZUS/14/0064 PNP04611

**BAUSCH + LOMB**  
See better. Live better.



lously documented in the medical record.

## Necessary Information

Previously established relationships with various generalists, specialists and subspecialists will help you more effectively navigate the entire neuro-ophthalmic comanagement process. Knowing the expectations and abilities of local experts can help streamline the referral process.

Extraneous diagnostic data takes time to gather and has the potential to confound the problem. For example, it is unnecessary to send an optical coherence tomography image of retinal nerve fiber layer thickening the patient's PCP in a case of a presumed optic neuropathy. That image cannot be interpreted by the physician and may, in fact, create more questions. A fundus photograph would be a far superior choice. Additionally, a suspected diagnosis, recommended systemic workups and specific testing protocols should be included in any referral letter to a specialist.

## An Efficient Referral Letter

Today's technology permits multiple ways to communicate with other health care providers. In non-urgent cases, writing a letter or report is still common. In emergent cases, personal or phone communication with an accompanying letter is preferred.

When generating calls and letters, it is commonplace to communicate with more than one care provider. In cases where both primary and specialty care is necessary, two calls and/or letters can be generated to briefly describe the discovery and outline the suggested testing strategy for each participant on the management team (see "Referral Letter Goals: Be Tailored, Swift," below). Phone calls allow a more direct question-and-answer approach, with the primary benefit of immediate feedback. However, written communication often will include more detailed diagnostic information, and can be invaluable in the rare event of medicolegal action.

In either case, your communication should be specifically detailed,

yet brief. The longwinded, four-paragraph narrative—with the classic introduction, the findings stanza, the treatment and prognosis section and the obligatory, "if you have any questions, do not hesitate to call," closing—is passé.

It takes a lot of time to listen to or read, and often provides information that is already known by the recipient or has no relevance to them because he or she is unfamiliar with the terminology. Simply stated: the person on the receiving end wants to get a brief report about the patient's condition and what you want him or her to do.

For simple referrals, one or two lines may be sufficient to describe the problem and what is necessary to complete all aspects of care. For more complex cases, a larger volume of information will be necessary. Be sure to include photographs of key examination elements. Such imagery will help illustrate the clinical severity of the presentation, as well as provide supplementary documentation.<sup>26</sup> Also, write the patient's identity and the date of

### Referral Letter Goals: Be Tailored, Swift

In your communications with other care providers, one size doesn't fit all. Be mindful of the audience, brief but substantive, and prompt in conveying your findings.

Here's an example of a referral letter sent to an internist regarding a patient with a branch artery occlusion:

*Branch retinal artery occlusion in the right eye. First aid dispensed (IOP lowering with digital massage), with no change in function. We are referring him to you to rule out embolic sources with systemic laboratory testing, electrocardiogram (ECG) and Doppler imaging. Suggest CBC with differential and platelets, blood pressure measurement, Westergren sedimentation rate, C-reactive protein, lipid panel, 2D echocardiogram (transeophageal echocardiogram optional at this juncture) and carotid Doppler.*

*We will emergently refer him to retinology to rule out treatable sequelae, and see him back in two weeks to assess his status, rule out additional events and evaluate for the presence of iris or retinal neovascularization.*

For comparison, here's an example of a letter sent to a retina specialist regarding the same patient:

*Branch retinal artery occlusion in the right eye. First aid dispensed at the time of the discovery (IOP pressure lowering and aggressive digital massage). The total elapsed time between the patient noticing an issue and his presentation to the office was four hours. Laboratory work, ECG and Doppler were ordered in our correspondence with the internist and included: CBC with differential and platelets, blood pressure measurement, Westergren sedimentation rate, C-reactive protein, lipid panel, 2D echocardiogram (transeophageal echocardiogram optional at this juncture) and carotid Doppler. We are emergently referring him to you to rule out paracentesis and treatable retinopathy. Please establish a follow-up schedule to rule out complications. We scheduled him to return in two weeks to assess his status, rule out additional events and evaluate for the presence of iris or retinal neovascularization.*



service at the top of the page.

In some instances, your referral letter to the internist may include recommendations for additional testing and/or a specialist's opinion.<sup>26</sup> It is ideal for the patient's internist to have a relationship with any specialist involved in the comanagement process.

However, if the patient's insurance won't cover a visit to that specialist, or the patient is uncomfortable with that individual or the practice's location, alternatives must be handy.

If the case is non-urgent, the letter can be dictated or written during call-back time and sent via fax or traditional mail. Written reports should be copied and kept with the chart. Patients sent for immediate referral or treatment can transport the note to the specialist or internist directly.

### Use the Phone for Emergencies

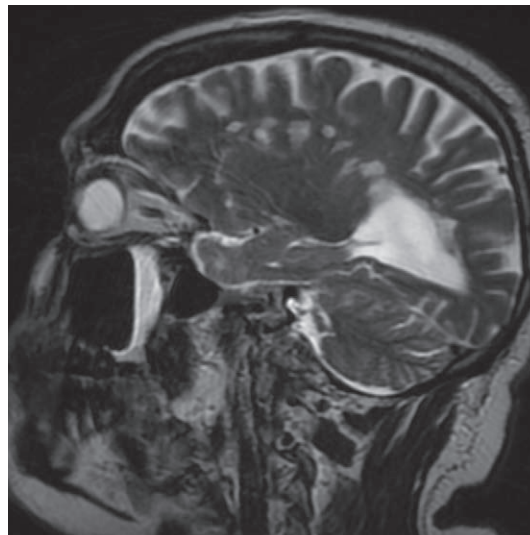
A phone conversation is the fastest way to communicate your findings to a consulting doctor, and is

considered mandatory in emergent cases. Phone calls should be documented for time of day, date and conversation content. Also, it is critical to note the names and titles of the individuals you speak with

A research group from Australia sought to determine the impact of physician communication on emergent patient management during a one-month period.<sup>27</sup> They concluded that telephone calls from referring physicians resulted in significantly decreased emergency room wait times and more efficient patient management.<sup>27</sup>

Interestingly, the researchers determined that written communication did not, in fact, decrease wait times or enhance patient management efficiency.<sup>27</sup>

Therefore, in cases of true ocular emergency, a phone call is highly



**Sagittal T2-weighted image of multiple enhancing white matter lesions, consistent with multiple sclerosis. This patient presented with a recent onset of diplopia secondary to internuclear ophthalmoplegia.**

recommended to accelerate and improve patient care.

### Ordering Tests


Ordering laboratory and imaging studies are part of ophthalmic practice. However, because the optometrist often isn't an expert in treating

*Headaches with evidence of bilateral disc edema in the setting of otherwise normal visual function (good acuity, color and visual fields, with no cranial nerve palsies). We are urgently referring this patient to neuro-ophthalmology to rule out the need for laboratory testing and neuroimaging. We have enclosed copies of his fields and photographs of his discs. We will ask the neuro-ophthalmologist to select the most appropriate lab work and imaging studies..*

**For comparison, here's an example of a letter sent to a neuro-ophthalmologist regarding the same patient:**

*This 5'4," right-handed, 187-pound male has bilateral disc edema in the setting of otherwise normal visual function (good acuity, color and visual fields, with no cranial nerve palsies). He presented with a chief complaint of headache that had persisted for three months. He reported that coughing exacerbated the headache. We are urgently referring him to you to rule out the need for laboratory testing and neuroimaging. We have enclosed copies of his fields and photographs of his discs. We leave the selection of lab work and imaging studies to your discretion.*

**Here's an example of a referral letter sent to an internist regarding a patient with newly discovered disc edema:**





underlying systemic etiologies or interpreting the results of the studies compiled, you may wish to consider asking the internist or specialist to order the appropriate tests. The subtleties of knowing how much a test costs, how fast the data will come back, the invasiveness and/or specificity of a study, and how to interpret its findings are all relevant considerations.

The radiology literature reports an interpretation error rate ranging between 3% and 30%.<sup>28,29</sup> If the ordering clinician cannot inspect the image and potentially detect an error, the patient's life could be in jeopardy. Thus, a good rule of thumb: If you can't interpret the testing results accurately, you should ask someone who can to order the study for you.

Keep in mind that it's still reasonable (and helpful) to provide a list of potential differential diagnoses, as well as recommendations for supportive lab work. However, as a non-expert, basic medical ethics suggests that this part of the comanagement process should be left to those with specific training and experience.<sup>24,25,28,29</sup>

## Scheduling a Follow-Up

Our primary goal in the neuro-ophthalmic management process is to prevent the loss of vision and life. Once this is accomplished, and confirmed via communication with our comanagement partners, ongoing ophthalmic management will remain essential for complete visual recovery.

Monitoring the progression of recovery also helps ensure that no new events or complications occur. So, it is advisable to schedule a follow-up visit based on the severity of the presentation:

- *24 to 48 hours for an ophthalmic emergency.*

- *One to two weeks for a systemic emergency with an ocular manifestation.*

- *Two to four weeks for a retinal or neuro-ophthalmic emergency.*

- *Two to four weeks after any visit with a specialist.*

If it appears that the patient will not be compliant with a recommended follow-up schedule, you must send a certified letter that explains the condition as well as the need for medical and/or ophthalmic care. This provides medicolegal documentation of the quality care you provided, and officially establishes a paper trail regarding your concerns and attempted communications.

The primary care optometrist has a unique opportunity to both direct and participate in the care of patients with neuro-ophthalmic disease. Your level of involvement may vary depending on the practitioner's location, setting and training, as well as the nature of the patient's condition and his or her insurance.

Optometrists need to develop strong relationships within their medical community to provide prompt, effective care within a cohesive comanagement team. The influential role that we play in this partnership can be instrumental in preventing devastating visual compromise, or even mortality. ■

*Dr. Rixon is an attending optometrist at the Memphis VA Medical Center in Tennessee.*

*Dr. Gurwood is a professor at Salus University in Elkins Park, Pa.*

1. Khare GD, Symons RC, Do DV. Common ophthalmic emergencies. *Int J Clin Pract* 2008 Nov;62(11):1776-84.
2. Honigman LS, Wiler JL, Rooks S, Ginde AA. National study of non-urgent emergency department visits and associated resource utilization. *West J Emerg Med*. 2013 Nov;14(6):609-16.
3. Blaho K, Winbery S. How to prepare your office for medical emergencies. Available at: [www.healio.com/optometry/practice-management/news/print/primary-care-optometry-news/%7B5f9b95b0-f1e6-4fd1-aeed-0b3864a3f344%7D/how-to-prepare-your-office-for-medical-emergencies](http://www.healio.com/optometry/practice-management/news/print/primary-care-optometry-news/%7B5f9b95b0-f1e6-4fd1-aeed-0b3864a3f344%7D/how-to-prepare-your-office-for-medical-emergencies). Accessed April 15, 2014.
4. Duszak RS, Duszak R. Malpractice payments by optometrists:

- An analysis of the national practitioner databank over 18 yrs. *Optometry*. 2011 Jan;82(1):32-7
5. Hayreh SS, Zimmerman B. Management of giant cell arteritis. Our 27-year clinical study: new light on old controversies. *Ophthalmologica*. 2003 Jul-Aug;217(4):239-59.
  6. Hayreh SS, Bioussé V. Treatment of acute vision loss in giant cell arteritis: Should we prescribe high-dose intravenous steroids or just oral steroids? *J Neuroophthalmol*. 2012 Sep;32(3):278-87.
  7. Liu GT, Volpe NJ, Galetta S. Visual Loss: Optic Neuropathies. *Neuro-ophthalmology: Diagnosis and Management*, 2nd ed. Philadelphia: Saunders Elsevier; 2010:155-63.
  8. Simon S. Neuro-ophthalmic manifestations and outcomes of pituitary apoplexy—a life threatening and sight-threatening emergency. *N Z Med J*. 2011 May 27;124(1335):52-9.
  9. Dubuisson AS. Classic pituitary tumour apoplexy: Clinical features, management and outcomes in a series of 24 patients. *Clin Neurol Neurosurg* 2007 Jan;109(1):63-70.
  10. Muthukumar N, Rossette D, Soundaram M, et al. Blindness following pituitary apoplexy: timing of surgery and neuro-ophthalmic outcome. *J Clin Neurosci*. 2008 Aug; 15(8):873-9.
  11. Nawar RN, AbdelMannan D, Selman WR, Arafah BM. Pituitary tumor apoplexy: a review. *J Intensive Care Med*. 2008 Mar-Apr; 23(2):75-90.
  12. Rao A, Makaroun M, Marone L, et al. Long-term outcomes of internal carotid artery dissection. *J Vasc Surg*. 2011 Aug;54(2):370-4.
  13. Sarikaya K. Antiplatelets versus anticoagulants for the treatment of cervical artery dissection: Bayesian meta-analysis. *PLoS One*. 2013 Sep 5;8(9):e72697.
  14. Patel RR, Adam R, Maldjian C, et al. Cervical carotid artery dissection: current review of diagnosis and treatment. *Cardiol Rev*. 2012 May-Jun;20(3):145-52.
  15. Song S. Hyperacute management of ischemic stroke. *Semin Neurol* 2013 Nov;33(5):427-35.
  16. Zhang J, Forozaan R. Optic disc edema from papilledema. *Int Ophthalmol Clin*. 2014 Winter; 54(1):13-26.
  17. Gray L. A clinical guide to third nerve palsy: How to spot the signs of oculomotor nerve compromise. *Rev Optom*. 1994 Jan;131(1):86-94.
  18. Santillan A, Zink WE, Knopman J, et al. Early endovascular management of oculomotor palsy associated with posterior communicating artery aneurysms. *Interv Neuroradiol*. 2010 Mar; 16(1):17-21.
  19. Matsukawa H, Fujii M, Akaike G, et al. Morphological and clinical risk factors for posterior communicating artery aneurysm rupture. *J Neurosurg*. 2014 Jan;120(1):104-10.
  20. Guresir E, Schuss P, Seifert V, Vatter H. Oculomotor nerve palsy by posterior communicating artery aneurysms: influence of surgical strategy on recovery. *J Neurosurg* 2012 Nov;117(5):904-10.
  21. Purvin V, Kawasaki A. Neuro-ophthalmic emergencies for the neurologist. *Neurologist* 2005 Jul;11(4):195-233.
  22. Siegel AM, Barnwell AS, Sisti DA. Assessing decision-making capacity: A primer for the development of hospital practice guidelines. *HEC Forum*. 2014 Jan 14. [Epub ahead of print]
  23. Kramer MH, Bauer W, Dicker D, et al. The changing face of internal medicine: Patient centered care. *Eur J Intern Med*. 2014 Feb;25(2):125-7.
  24. Hammami MM, Al-Gaai EA, Al-Jawameh Y, et al. Patients perceived purpose of clinical informed consent: Mill's individual autonomy model is preferred. *BMC Med Ethics*. 2014 Jan 10;15:2.
  25. Bush WH, Albright DE, Sather JS. Malpractice issues and contrast use. *J Am Coll Radiol*. 2005 Apr;2(4):344-7.
  26. Wagman, L. How to write GP referral letters. *GP Online*. Available at: [www.gponline.com/Education/article/655978/how-write-gp-referral-letters/](http://www.gponline.com/Education/article/655978/how-write-gp-referral-letters/). Accessed April 15, 2014.
  27. Montalto M, Harris P, Rosengarten P. Impact of general practitioners' referral letters to an emergency department. *Aust Fam Physician*. 1994 Jul;23(7):1320-1, 1324-5, 1328.
  28. Raskin MM. Survival strategies for radiology: some practical tips on how to reduce the risk of being sued and losing. *J Am Coll Radiol*. 2006 Sep;3(9):689-93.
  29. Lee CS, Nagy PG, Weaver SJ, Newman-Toker DE. Cognitive and system factors contributing to diagnostics errors in radiology. *AJR Am J Roentgenol*. 2013 Sep;201(3):611-7.

## WHAT'S THE SOLUTION?

By Gary Andrasko, OD, MS



# Improve Comfort with the Right Combination

Understanding how contact lens and multi-purpose disinfection solution combinations impact comfort can help improve your patient's lens wearing experience.

Contact lens patients typically want two things from their lenses: great vision and optimal comfort. While patients may sometimes tolerate a little blur, they rarely accept discomfort, at least not for long. Among patients who discontinue lens wear, discomfort is cited more often than any other reason.<sup>1</sup> Ensuring the biocompatibility of contact lenses and care solutions is critical to help patients stay comfortable.

## DISTINGUISHING DISCOMFORT

For contact lens wearers it is important to distinguish end-of-day discomfort from discomfort on insertion. End-of-day discomfort is relatively common and can result from multiple patient-, lens-, and lens care-based factors.

Discomfort that is most pronounced at insertion or shortly thereafter, on the other hand, can be the result of an interaction between the contact lens and lens care solution.

## SOLUTION-INDUCED STAINING

Mounting evidence indicates that, to varying degrees, soft contact lenses can absorb the biocide preservatives contained in lens care solutions.<sup>2</sup> Preservatives can then release from the lens into the tear film.

If the preservative is sufficiently cytotoxic and its uptake and release by the lens sufficiently high, diffuse punctate corneal staining, a phenomenon called solution-induced corneal staining (SICS), can occur.<sup>2</sup> When it is mild, the corneal compromise may be small and transient enough to go unnoticed. In my research, moderate to severe staining was associated with lower patient comfort ratings after two hours of wear

## KEY POINTS

- Contact lenses can absorb and release preservatives from care solutions.
- Severe SICS can be associated with discomfort.
- A grid showing lens-solution combinations demonstrates this phenomenon.
- In general, some PHMB disinfection solutions show more staining than those with the POLYQUAD® and ALDOX® dual disinfection system or hydrogen peroxide.
- Since patients are the ones who must buy and use solutions, a clear recommendation (written down and reiterated at follow-up visits) is imperative.

time.<sup>3</sup> A study presented at AAO in 2012 by CCLR, School of Optometry and Vision Science, University of Waterloo, also found SICS to be associated with specific symptoms of stinging and burning after two hours of wear time.<sup>4</sup>

## DEVELOPING THE STAINING GRID

Around the year 2000, I became curious about numerous anecdotal reports of staining and discomfort when certain lens care solutions were paired with certain lenses. A few published reports investigated the phenomenon, which mainly appeared to involve the preservative polyhexamethylene biguanide (PHMB) and certain lens materials.<sup>5,6</sup>

I decided to quantify the staining induced when popular lens materials were paired with each of the lens care solutions then available in the US. The results were striking, and it was readily apparent that the important factor in determining staining (or lack of it) was

the pairing of specific solutions with specific lens materials.

To gain a readily apprehensible picture of the staining induced by each lens/solution combination, I charted a grid comparing relative amounts of staining. Cells within the grid indicate minimal (under 10% of the cornea), moderate (10% to 20%), or excessive (over 20%) staining.<sup>7</sup> Subjective comfort ratings correlate inversely with corneal staining area—particularly among patients with severe (>20%) staining at 2 hours.<sup>3</sup>

## INSIGHTS FROM THE GRID

Looking at the grid, differences between solutions are stark. Multi-purpose solutions containing POLYQUAD® and ALDOX® dual disinfection system consistently show minimal staining across all lens types tested (as does hydrogen peroxide).<sup>7</sup> In contrast, solutions that contain PHMB show less consistency—patients experienced more moderate to severe staining in combination with many of the lenses tested.<sup>7</sup> The staining grid can help determine an initial care solution recommendation for biocompatible lens wear.

A challenge remains in conveying the importance of lens/solution biocompatibility to contact lens wearers, many of whom believe that all lens care solutions are alike. To maximize the chances of success, practitioners must make a specific (and, ideally, written) recommendation of the lens care system to be used. Because this requires patient cooperation and understanding, giving a clear solution recommendation—and an explanation of why it is important—is as essential as prescribing the right lens. ■

*Dr. Andrasko leads a private research practice in Columbus, OH. He serves as a lecturer, consultant, and researcher to the contact lens industry.*

1. Rumpakis J. New data on contact lens dropouts: an international perspective. *Rev Optom.* 2010;147(1):37-42.

2. Jones L, Powell CH. Uptake and release phenomena in contact lens care by silicone hydrogel lenses. *Eye Contact Lens.* 2013;39:29-36.

3. Andrasko G, Ryen K. Corneal staining and comfort observed with traditional silicone hydrogel lenses and multipurpose solution combinations. *Optometry.* 2008;79:444-54.

4. Woods J, Keir NJ, Jones LW. Solution-induced corneal staining (SICS): symptoms and staining patterns. Poster presented at the American Academy of Optometry Annual Meeting, October 24-27, 2012; Phoenix, AZ.

5. Garofalo RJ, Dassanayake N. Corneal response of chemical agents released by hydrogel and silicone hydrogel lenses as a function of time. Presented at the Association for Research in Vision and Ophthalmology, April 25-29, 2004; Ft. Lauderdale, FL.

6. Jones L, MacDougall N, Sorbara LG. Asymptomatic corneal staining associated with the use of balafocon silicone-hydrogel contact lenses disinfected with a polyaminopropyl biguanide-preserved care regimen. *Optom Vis Sci.* 2002;79:753-61.

7. Andrasko Corneal Staining Grid. <http://www.staininggrid.com/>. Accessed October 16, 2013.

**Alcon**  
a Novartis company

© 2014 Novartis 4/14 OPM13105AD



## Go Further—Without Leaving Home



Expand your clinical skills and catch up on your CE requirements, all from the comfort of your own home.

*Review* offers **nearly 100 hours** of COPE-approved continuing education — right now! It's **just a click away**. Our extensive library of exams runs the gamut from keratoconus to fundus autofluorescence, and everything in between.



[www.revoptom.com/continuing\\_education](http://www.revoptom.com/continuing_education)

Download a QR scanner app. Launch app and hold your mobile device over the code to view [www.revoptom.com/continuing\\_education](http://www.revoptom.com/continuing_education).

**REVIEW**<sup>®</sup>  
OF OPTOMETRY

2 CE  
Credits  
(COPE approval pending)



# Ocular Herpes Management: Simplex Made Simple

A detailed history and a thorough workup can make the diagnosis and treatment of herpes simplex keratitis a lot easier on you—and the patient. **By William Marcolini, OD**

**N**o doubt—it's one of the most awkward conversations that you'll ever have as an optometrist. Just the mere mention of herpes to my patients sends them recoiling in horror. The look of shock sets in as they contemplate exactly what it means.

Inevitably, a herpes patient will nervously rattle off a series of rapid-fire questions: Is it a sexually transmitted disease? Am I contagious? Can I go blind? Then, he or she often will go through a process simi-

lar to the stages of grieving—beginning with denial, eventually leading to acceptance.

Often, your first step as a medical professional begins with a little handholding and a lot of educating. Even before you initiate such a conversation, you'll likely be asking yourself, "Is this presentation truly herpes?" If I've learned one thing in a decade of clinical practice, it's that things are hardly as they seem. In other words, sometimes we have to play detective. By taking a step back, documenting a good history,

evaluating the patient as a whole, and then focusing in on specific ocular structures—you will be able to make the diagnosis with confidence.

## The Nuts and Bolts of Herpes Simplex

When initially addressing a herpes suspect, I find it best to adhere to a narrative that clearly explains the basic etiology and epidemiology of the virus itself. Then, I discuss the course of the infection as well as the potential therapeutic options.

Herpes simplex is a DNA virus,

**Release Date:** May 2014

**Expiration Date:** May 1st, 2017

**Goal Statement:** Herpes simplex should never be far from your mind when encountering patients with complex corneal presentations. With the relatively excellent safety profile of both topical and oral antivirals, you should be fairly comfortable initiating treatment—even when the diagnosis may be unclear. In any suspected case of herpes simplex, however, be sure to monitor the patient very carefully and frequently, and be prepared to make a referral should conditions warrant.

**Faculty/Editorial Board:** William Marcolini, OD

**Credit Statement:** COPE approval for 2 hours of CE credit is pending for this course. Check with your local state licensing board to see if this counts toward your CE requirement for relicensure.

**Joint-Sponsorship Statement:** This continuing education course is joint-sponsored by the Pennsylvania College of Optometry.

**Disclosure Statement:** Dr. Marcolini has no relationships to disclose.

and is in the same family as varicella zoster (which causes chicken pox and shingles), Epstein-Barr and cytomegalovirus.<sup>1</sup> The virus is carried by more than 90% of humans, and an estimated 20,000 new cases and 48,000 recurrences of HSV are reported annually in the United States.<sup>1-4</sup>

Herpes simplex can be categorized into two forms: HSV-1 and HSV-2. Type 1 typically affects the eye and oropharynx, and type 2 usually affects the genital region. Patients frequently associate the stigma of any herpes infection with sexual transmission. While this notion is somewhat inaccurate, their fears are not entirely unfounded, because both HSV-1 and HSV-2 can infect either the eye or genitals.<sup>1</sup>

Following primary infection, the HSV virus remains dormant in the trigeminal ganglion. Primary infection can present either asymptotically or actively, followed by a latent period.<sup>1</sup> Recurrent flare-ups of HSV can manifest for years after the primary infection, and resultant symptoms often are very difficult to manage.

### Primary vs. Recurrent Infection

Numerous clinical signs may help you differentiate primary from recurrent herpetic infections. Here's a concise overview:

- **Primary infection** may present either unilaterally or bilaterally, and may or may not be associated with skin lesions; a tender, palpable pre-auricular node; a follicular conjunctival response; a membranous conjunctival response; or a transient, mild epithelial keratitis.<sup>5</sup> These signs are very similar to those caused by adenoviral infection, and the presence of skin lesions often is your only guide during the differential.

Additionally, in somewhat rare

### Clinical Pearl

Always suspect herpes simplex as an etiology in any instance of keratitis where the history doesn't seem to fit. For example, you may wish to consider HSK in a patient who exhibits a significant corneal pathology yet demonstrates no history of trauma, has good contact lens hygiene and does not sleep in his or her lenses.

instances, primary ocular herpes simplex may cause epithelial dendritic keratitis. These lesions typically begin as tiny epithelial vesicles, which can subsequently coalesce to form the classic microdendritic ulcerations. Nonetheless, researchers suggest that primary HSV is confined to the epithelium, and does not have the potential for stromal involvement.<sup>1</sup>

Primary infection clinically manifests in approximately 6% of the population.<sup>1</sup> The virus is transferred via personal contact with saliva or genital secretions, and the major portal of entry is the mucous membranes.<sup>1</sup> So, kissing, drinking from someone else's glass or putting contaminated objects in your mouth can spread HSV. Because it is so easy to transfer, clinical researchers estimate that by age five, 60% of Americans have experienced primary infection with HSV.<sup>6</sup>

The course of primary infection usually persists for one to four weeks and rarely yields significant sequelae, such as visual loss due to corneal scarring.<sup>5</sup> Because 94% of the population is asymptomatic upon primary infection, eye care providers rarely see this manifestation and probably don't even recognize it in their exam chairs.

- **Recurrent infection**, on the other hand, is much more likely to cause severe visual consequences from scarring and inflammation. Therefore, it is essential to make a prompt diagnosis and initiate treat-

ment immediately.

While some people joke that herpes is "the gift that keeps on giving," affected patients find it to be no laughing matter. Recurrent ocular herpes simplex of the anterior segment may cause blepharitis, conjunctivitis, keratitis, iris atrophy and iridocyclitis. And because of the significant potential for scarring, often our principal goal is to protect patients' corneal health. Therefore prompt recognition is paramount.

The incidence of disease recurrence is not affected by race and age; however, the condition does have a slight male predilection.<sup>7</sup> Additionally, clinical evidence suggests that more HSV outbreaks occur between November and February than at any other time of the year.<sup>7</sup>

Finally, in suspected cases of recurrent herpes simplex virus, you must be certain to carefully evaluate each ocular structure—from the lids to the retina. Although uncommon, HSV retinitis may be found in neonates as part of disseminated systemic disease.<sup>1</sup> Also, acute retinal necrosis may develop as a rare, but potentially visually devastating, manifestation in genetically predisposed adults.

### Herpes Simplex Keratitis

It is estimated that 72% of recurrent HSV disease involves the corneal epithelium.<sup>8</sup> Affected individuals often will present with tearing, photophobia, pain and redness.

Unfortunately, the aforementioned symptoms also are present in myriad ocular conditions. So, it often is helpful to ask the patient if he or she has a history of a recurrent red eye.

In addition, be sure to document corneal sensitivity, examine for other areas of corneal scarring in both eyes, and look for arborization and terminal bulbs.

## Diagnostic Considerations

All types of recurrent infectious epithelial keratitis are caused by reactivation of a live virus.<sup>1</sup> The classic epithelial defect is characterized by infected, raised, swollen epithelial cells that are grouped in a dendritic (“tree-like”) shape with terminal end bulbs. Vision can be affected, depending on the amount of tearing and the location of the dendrite.

Typically, the earliest clinical sign of herpes simplex keratitis (HSK) is raised epithelial vesicles. Within 24 hours, these vesicles coalesce to form the characteristic dendritic configurations, which may progress to geographic lesions in those who are immunocompromised and/or do not receive prompt treatment.<sup>1</sup>

Like a brush fire, the herpes virus spreads and leaves destruction in its wake. True dendritic ulcers extend through the basement membrane.<sup>1</sup> This clinical feature helps distinguish them from pseudodendrites and healing epithelium, which simply appear elevated—not ulcerated.<sup>1</sup>

Staining patterns also can help guide your differential (see “How to Differentiate Herpes Simplex from Varicella Zoster,” right). In cases of true dendritic ulceration, you’ll notice positive staining located along the length of the dendrite. At the borders, however, you will see raised, swollen epithelial cells that negatively stain. Rose bengal likely will help reveal the diagnosis, because it is absorbed by swollen, devitalized cells at the ulcer’s border.

Most HSK patients can be diagnosed on clinical appearance alone. Nevertheless, corneal scraping may be necessary to visualize or identify the virus via polymerase chain reaction testing or the Enzyme-Linked Virus Inducible System (ELVIS, Diagnostic Hybrids, Inc.).

Hypoesthesia is often present in patients who present with chronic

### How to Differentiate Herpes Simplex from Varicella Zoster<sup>14</sup>

Similar to an active varicella zoster infection, herpes simplex keratitis subsequently may invade neighboring epithelial cells. Fortunately, however, there are a few distinguishing characteristics:

Feature	Herpes Simplex	Varicella Zoster
Epithelium	Linear defect with bare stroma that is surrounded by edematous epithelial cells.	Elevated, painted-on appearance.
Staining	Ulcer base stains with fluorescein; diseased borders of epithelial cells stain with rose bengal.	Minimal fluorescein staining.
Terminal bulbs	Frequent.	Absent.

stromal disease. When you encounter a likely HSK suspect, an evaluation of corneal sensitivity may help you arrive at a diagnosis. In these individuals, corneal sensitivity can be minimal to totally absent, and can be either transient or permanent.<sup>5</sup>

Checking for hypoesthesia may be accomplished via rolling up the edge of a facial tissue and then gently touching the patient’s cornea. (Alternatively, you can use an esthesiometer.) During testing, a normal patient will blink or recoil upon the slightest touch. However, individuals with chronic herpetic disease will feel reduced sensation similar to that experienced after instillation of a topical anesthetic.

Corneal sensitivity testing is critical for two reasons: it will aid in your diagnosis of potential herpetic infection, and the presence of chronic denervation suggests that the patient is at an elevated risk for neurotrophic keratitis. Take note that neurotrophic keratitis is neither infectious nor inflammatory. It leads to a loss of epithelium and a chronic, oval-looking epithelial defect. This differs from a geographic ulcer, which features an irregular shape

with scalloped borders.<sup>1</sup> The sensory innervation from the trigeminal nerve typically is damaged in HSK patients, which causes decreased tearing and an unhealthy epithelium.

Also, be on the lookout for herpetic epithelial marginal ulcers. We are all familiar with the intense marginal infiltration that’s often associated with a sterile, staphylococcal infiltrate. Take note that a true HSV infection located near the limbus can cause an epithelial defect first, followed by peripheral inflammation and neovascularization that progresses centrally. By contrast—a staphylococcal marginal infiltrate will not exhibit an epithelial defect until later in the process (if at all), will not produce neovascularization, and often will yield circumferential inflammation.

### Stromal Involvement

Patients who present with significant stromal involvement are at a higher risk for corneal scarring and neovascularization. Stromal keratitis may present in two forms:

- **Necrotizing stromal keratitis** is a primary infection of the stroma, and can cause intense inflammation,

## Five Diagnostic Considerations for Herpes Patients

When examining an HSK suspect, you should take the time to address these fundamental questions:

1. Is the epithelium involved?
2. Is there a loss of corneal sensitivity?
3. Is the stroma involved?
4. Is there an endotheliitis?
5. Is there iridocyclitis, and what is the intraocular pressure?

scarring or perforation. Because of the elevated potential for severe visual compromise, this presentation likely should be managed by an experienced clinician and/or corneal specialist.

- **Immune stromal keratitis** is a common, chronic, recurrent manifestation of HSV infection—occurring in 20% of patients with ocular herpes simplex.<sup>1,4,9</sup> Studies suggest that the viral antigen remains dormant in the stromal tissue, and causes corneal infiltration and edema during episodes of disease recurrence.<sup>4,9</sup> Further, neovascularization of any corneal layer may be present in affected individuals.

According to the Herpetic Eye Disease Study (HEDS), oral antiviral therapy for up to one year significantly reduced the risk of stromal recurrence.<sup>10</sup> Recommended dosages include 400mg Zovirax (acyclovir, GlaxoSmithKline) BID or 500mg Valtrex (valacyclovir, GlaxoSmithKline) QD.

Patients may still develop stromal edema without evidence of infiltration or neovascularization. Such individuals typically exhibit these findings: keratic precipitates (KPs), overlying stromal and epithelial edema, and iritis.<sup>1</sup> Careful inspection of the endothelium will reveal an irregular (circular) disciform pattern with a demarcation line that separates the normal and edematous endothelium. The stromal edema will be above the affected endothelium. It is worth noting that iritis

usually accompanies the endotheliitis.

Patients who present with immune stromal keratitis or endotheliitis often manifest concomitant iritis. Any such inflammatory chamber reaction may range from mild to severe. These patients also may experience KPs or iris atrophy.

Clearly, any form of uveitis can significantly increase the patient's intraocular pressure, as well as yield posterior synechiae or secondary angle closure. Topical corticosteroids and aqueous suppressants (e.g., beta blockers) often are employed to lower pressure rapidly. However, upon steroidal tapering, the pressure can be difficult to manage and may take months to control effectively.

In addition to topical steroids, oral acyclovir may be of some benefit in HSK patients who develop iritis. Specifically, HEDS researchers showed that patients who had an iridocyclitis achieved better clinical outcomes when oral acyclovir was added to topical steroids and antivirals.<sup>11</sup>

## Treatment Options

Treatment of HSK has changed within the last few years. If you diagnosed a dendritic ulcer between 1970 and 2010, you likely prescribed topical Viroptic (trifluridine, Monarch Pharmaceuticals). And why not? It worked just fine more than 40 years ago, and still does today.

The recommended dosage of Viroptic is one drop every two hours for a week, until the corneal epithelium is healed. Upon dendrite resolution, Viroptic should be continued four times a day for one more week. Take note that significant epithelial toxicity can occur following Viroptic doing—particularly if the drug is used in excess of 21 days. In such cases, the virus may be eliminated, but the epithelium will not heal as anticipated, complicating the treatment result.

The introduction of Zirgan (ganciclovir, Bausch + Lomb) in 2009 has fundamentally changed the way I manage herpes simplex keratitis. With its prolonged contact time and lower incidence of epithelial toxicity, it is now my drug of choice when I suspect HSK. It selectively targets viral infected cells and is well tolerated. Zirgan is dosed five times per day until the dendritic ulcer resolves, and then TID for one week after.<sup>12</sup>

Keep in mind that topical steroids should be avoided to reduce the risk of further epithelial complications. Should the patient already be taking topical steroids, a rapid tapering is indicated if clinically appropriate.

Oral medications can be used in the treatment of epithelial HSK—although I typically reserve them for more severe or recalcitrant cases that don't respond well to topical monotherapy. Occasionally, I've used oral and topical antivirals concurrently.

There isn't tremendous literature support for using only oral medications to treat herpes simplex keratitis. Remember, oral medications are subject to absorption, metabolism and transport, and must reach therapeutic levels in the pre-corneal tear film to effectively treat the epithelium.

Recommended oral treatments for HSK include:<sup>3</sup>



- 400mg Zovirax five times per day for seven to 10 days.
- 500mg Valtrex three times per day for seven to 10 days.
- 250mg Famvir (famciclovir, Novartis) three times per day for seven to 10 days.

Remember that the use of oral antivirals for herpes simplex keratitis does not prevent progression to stromal keratitis or uveitis.

Another potential treatment option is physical debridement to reduce the viral load. This should be performed by an experienced clinician, and followed by appropriate topical antiviral therapy.

Just keep in mind that although herpes simplex may have been the initial etiology, ocular symptoms secondary to a neurotrophic ulceration typically aren't managed with antiviral agents.

Instead, supportive therapy with antibiotic ointments (e.g., erythromycin four to eight times per day), artificial tears, bandage contact lenses and amniotic therapeutic lenses frequently are employed. Ironically, the use of topical antiviral medications actually may prolong epithelial healing.

## Herpetic Blepharitis and Conjunctivitis

While less potentially visually devastating than HSK, secondary blepharitis and conjunctivitis may develop in herpes simplex patients. Here's what to look for:

- **Herpetic blepharitis** presents as clear vesicles on a red or erythematous base in the eyelid region. These lesions resemble "cold sores," which are characteristically observed in and around the oral regions.

The lesions progress through various stages of healing and become crusty. Typically, they are documented in groups located in or around a specific sector, rather than scattered across the entire lid.

Herpetic blepharitis lesions do not frequently cause scarring, but they can become secondarily infected. For this reason, topical antibiotic ointments, such as erythromycin or bacitracin, are often prescribed BID.<sup>13</sup> Additionally, warm or cool soaks TID may help provide relief from redness and itching.<sup>13</sup>

If the patient exhibits eyelid margin involvement, the potential for corneal migration is reasonably high. In such instances, a topical antiviral, such as Viroptic or Zirgan, may be added as a prophylactic measure.

- **Herpetic conjunctivitis** typically causes unilateral red eye, follicular conjunctivitis and conjunctival dendritic ulcers. Results from one study indicated that up to 23% of all conjunctivitis cases may be caused by the herpes simplex virus.<sup>1</sup> No doubt, herpetic conjunctivitis goes underdiagnosed in the daily clinical setting. Therefore, careful inspection of the conjunctiva with sodium fluorescein is important.

Treatment should consist of Viroptic or Zirgan five times per day until the conjunctivitis resolves (typically in seven to 14 days). Take note that treating red eyes with topical steroids can lead to potential exacerbation of herpetic eye disease.

The essential take-home message: Herpes simplex should never be far

from your mind when encountering patients with complex corneal presentations. With so much clinical overlap between other disease processes, we will be ahead of the game if we keep HSK on our short list of differentials.

So—take a step back, evaluate each layer individually, document a good history, test for sensitivity and use good judgment. With the relatively excellent safety profile of both topical and oral antivirals, you should be fairly comfortable initiating treatment—even when the diagnosis may not be 100% clear.

In any suspected case of herpes simplex, however, be sure to monitor the patient very carefully and frequently, and be prepared to make a referral should conditions warrant. ■

*Dr. Marcolini is in a group practice at Omni Eye Services in Iselin, NJ, and in private practice in Clinton, NJ.*

1. Holland Ed, Brilakis H, Schwartz G. Herpes Simplex Keratitis. In: Cornea (2nd ed.). Philadelphia: Mosby 2005;83:1043-74.
2. National Eye Institute. Facts About the Cornea and Corneal Disease. Available at: [www.nei.nih.gov/health/cornealdisease](http://www.nei.nih.gov/health/cornealdisease). Accessed April 17, 2014.
3. Potter WB. An overview of ocular herpetic disease. Rev Optom. 2010 May;147(5):76-83.
4. Liesegang TJ, Melton LJ 3rd, Daly PJ, Ilstrup DM. Epidemiology of ocular herpes simplex. Incidence in Rochester, Minn, 1950 through 1982. Arch Ophthalmol. 1989 Aug;107(8):1155-9.
5. Brightbill F, Lanier JD. Corneal Surgery: Theory, Technique and Tissue (4th Ed.). Herpetic Eye Disease: Ocular Herpes Simplex and Herpes Zoster. Philadelphia: Mosby; 2009:277-81.
6. Goodman JL. Infections Caused by Herpes Simplex Viruses. In: Hoeprich PD, Jordan C, Ronald AR (eds.). Philadelphia: JB Lippincott; 1994.

### Clinical Pearl

While a few exceptions exist, most immune stromal keratitis patients present with an intact epithelium. This can be confusing for the clinician, because these patients often exhibit an intense inflammatory reaction, with stromal infiltration and edema.

Conventional treatment for immune stromal keratitis includes:<sup>13</sup>

1. Scopolamine 0.25% TID
2. Prednisolone acetate 1% or difluprednate 0.05% QID
3. Trifluridine 1% TID or QID, ganciclovir 0.15% QID or 400mg acyclovir PO BID

Because you are treating inflammation and not active disease, antiviral agents are prescribed prophylactically at this stage. However, because of the immunosuppressive action of the steroids, antiviral coverage is necessary to prevent disease reactivation.

7. Bell DM, Holman RC, Pavan-Langston D. Herpes simplex keratitis: epidemiological aspects. *Ann Ophthalmol*. 1982 May;14(5):421-2, 424.
8. Pavan-Langston D. Part one: the research perspective. *Advances in the management of ocular herpetic disease*. *Candao Clin Sci Comm*. 2011;1-9.
9. Wilhelmus KR, Coster DJ, Donovan HC, et al. Prognostic indicators

- of herpetic keratitis: analysis of a five-year observation period after corneal ulceration. *Arch Ophthalmol*. 1981 Sep;99(9):1578-82.
10. Herpetic Eye Disease Study Group. Acyclovir for the prevention of recurrent herpes simplex virus eye disease. *N Engl J Med*. 1998 Jul 30;339(5):300-6.
11. Herpetic Eye Disease Study Group. A controlled trial of oral acyclovir for iridocyclitis caused by herpes simplex virus. *Arch Ophthalmol*.

- 1996 Sep;114(9):1065-72.
12. Zirgan (ganciclovir ophthalmic gel 0.15%) prescribing information. Tampa, Fla: Bausch + Lomb; 2010.
13. Ehlers JP, Shah C. *The Wills Eye Manual* (5th Ed.). Baltimore: Lippincott, Williams and Wilkins; 2008:70-4.
14. Yanoff M, Duker JS. *Infectious Keratitis*. In: *Ophthalmology*, 2nd ed. Philadelphia: Mosby; 2004:469-81.

## OSC QUIZ

**Y**ou can obtain transcript-quality continuing education credit through the Optometric Study Center. Complete the test form (page 67), and return it with the \$35 fee to: Optometric CE, P.O. Box 488, Canal Street Station, New York, NY 10013. To be eligible, please return the card within one year of publication.

You can also access the test form and submit your answers and payment via credit card at *Review of Optometry* online, [www.revoptom.com](http://www.revoptom.com).

You must achieve a score of 70 or higher to receive credit. Allow eight to 10 weeks for processing. For each Optometric Study Center course you pass, you earn 2 hours of transcript-quality credit from Pennsylvania College of Optometry and double credit toward the AOA Optometric Recognition Award—Category 1.

Please check with your state licensing board to see if this approval counts toward your CE requirement for relicensure.

1. What percentage of adults is estimated to carry the herpes simplex virus (HSV)?
- 6%.
  - 50%.
  - 90%.
  - None of the above.

2. Approximately how many new cases of HSV are reported in the United States each year?
- 5,000.
  - 10,000.
  - 20,000.
  - 50,000.

3. The presence of which clinical sign can help you differentiate between primary HSV and adenoviral infections?
- Transient, mild epithelial keratitis.
  - Skin lesions.
  - Follicular conjunctival response.
  - Tender, palpable pre-auricular node.

4. Primary herpes simplex infection clinically manifests in what percentage of the American population?

- 6%.
- 50%.
- 90%.
- 100%.

5. Which statement is FALSE regarding primary ocular HSV infection?

- It may be associated with skin lesions.
- It may feature a tender, pre-auricular node.
- It is confined to the epithelium.
- It typically causes severe corneal scarring and subsequent blindness.

6. A recurrence of ocular HSV is most likely to occur in:

- Whites.
- Blacks.
- Males.
- Females.

7. What is the classic presentation of herpes simplex keratitis (HSK)?

- A round, oval pattern.
- Intense infiltration.
- A dendritic pattern, with terminal end bulbs.
- None of the above.

8. Typically, what is the earliest clinical sign of HSK?

- Geographic lesions.
- Increased intraocular pressure.
- Iritis.
- Raised epithelial vesicles.

9. In comparison to pseudo-dendrites caused by varicella zoster virus, herpes simplex dendritic ulcers are:

- Usually treated with antibiotics.
- Associated with interstitial neovascularization.
- Only present on the conjunctiva.
- Likely to extend through the basement membrane.

10. Which vital dye will most effectively help you differentiate herpes simplex from varicella zoster?

- Fluorescein.
- Rose bengal.
- Lissamine green.
- Trypan blue.

11. How do neurotrophic ulcers differ from geographic ulcers?

- They are oval-shaped, with regular borders.
- They exhibit a classic dendritic shape.
- They are irregular, with scalloped edges.
- They always perforate the cornea.

12. Studies have indicated that recurrence rates of immune stromal keratitis can be reduced by:

- Taking oral antivirals every day for one year.
- Using topical antivirals every day for one year.
- Undergoing a prophylactic corneal transplant.
- Using topical fluoroquinolones daily for one month.

13. When treating immune stromal keratitis, steroids should:

- Never be used.
- Only be administered orally.
- Be employed to prevent visually devastating inflammation.
- Be used in conjunction with topical NSAIDs to enhance epithelial healing.

14. What initial treatment regimen for HSK is NOT advisable?

- Zirgan (ganciclovir, Bausch + Lomb) five times daily.
- Viroptic (trifluridine, Monarch Pharmaceuticals) every two hours.
- Vigamox (moxifloxacin, Alcon) q1h.
- 500mg Valtrex (valacyclovir, GlaxoSmithKline) TID.



# CE Takes Center Stage at Vision Expo East

‘Healthy bodies and healthy eyes’ was a recurring theme at this year’s VEE.

By Cheryl G. Murphy, OD, Contributing Editor

**A**t this year’s Vision Expo East, eye care professionals from around the world congregated a day earlier than usual for the new Global Contact Lens Forum, a two-day continuing education program on the latest in contact lens technologies and prescribing techniques. Lecturers discussed and debated the best designs, materials and modalities of present day contact lenses.

However, it was the future of contact lenses that proved to be an area of great interest.

## Future of Contacts

This topic was addressed by Lyndon Jones, PhD, FCOptom, professor at the University of Waterloo, Ontario, Canada, and director of its Centre for Contact Lens Research. First, Dr. Jones underscored that the future of contact lenses includes managing myopia control. “The number of myopes will grow from



**Myopia control was one of the leading topics during Vision Expo East’s new Global Contact Lens Forum.**

1.6 to 2.5 million by 2020,” he said.

But what can practitioners do to slow this looming epidemic? Undercorrecting myopes is not the answer, Dr. Jones said. The once-held theory of undercorrecting myopia to slow its progression has been proven to be ineffective; in fact, it may even accelerate it.<sup>1</sup>

Recently, CooperVision has developed a daily disposable lens called MiSight, currently available in Asia. The lens corrects myopia and eliminates aberrations on the peripheral

retina that are thought to be one of the triggers of myopic progression, he explained.

“In addition to this product, many companies are currently testing various spectacle and contact lens designs in animal and human studies to investigate methods to slow the progression of myopia,” Dr. Jones said. “These include soft lens multifocal designs and also orthokeratology, with

some studies showing up to 50% reduction in myopia progression.”<sup>2-4</sup>

Along with correcting vision and possibly slowing myopic progression, contact lenses that detect disease and monitor health are on the horizon. For example, Google’s Smart Contact Lens—which garnered a lot of press recently, although it’s still a prototype—would be used by diabetic patients to track the glucose content of their tears in order to better manage their disease.

In addition to helping people with diabetes, other contact lens innovations are in the works to help monitor health, Dr. Jones said. These include contact lenses paired with devices that check the intraocular pressure in the eyes of glaucoma patients and suspects, and even contact lenses with sensors that watch for specific biomarkers in tears that may indicate the presence of breast, colon, lung, prostate and ovarian cancers in the body.<sup>5</sup>

### Healthy Eyes, Healthy Bodies

The notion that “healthy eyes are connected to healthy bodies” echoed throughout the CE courses at this year’s Vision Expo East.

In his lecture, “East Meets West: Effective Management of Ocular Conditions,” Aaron Lech, OD, of ClearVue Eye Care, in Roseville, Calif., explained how a personal experience that happened early in his career taught him a lot. He was working in an overseas clinic with an Indian ophthalmologist who saw 150 patients a day. Before even examining a particular patient’s eyes, the ophthalmologist told Dr. Lech that this patient probably had diabetic retinopathy.

“The patient had distended parotid glands, which are typically bilateral and asymptomatic in diabetics who are latent or physically asymptomatic (typically after 10 years),” Dr. Lech recalls.<sup>6</sup> The ophthalmologist had noted the patient’s distended parotid glands and had reasoned that patients with longstanding, uncontrolled diabetes are more likely to have diabetic retinopathy.



**Many attendees got their first chance to test out Google Glass.**

This experience taught Dr. Lech that observing and treating a patient as a whole can not only provide clues about the patient’s overall health, but about eye health as well.

He also discussed the ocular and systemic health benefits patients can gain by eating a healthy diet, exercising, reducing stress and avoiding smoking, and he spoke about how proper nutrition and supplements can influence common ocular conditions such as AMD, cataracts, dry eye syndrome, lid disease and glaucoma.<sup>7-12</sup>



**Charles Posternack, MD, gave the keynote address on health care reform.**

**High-Tech Eye Tech**

The latest in wearable technologies were on display at Vision Monday’s Eye<sup>2</sup> Zone. Google Glass demonstrations were a big draw, but the Eye<sup>2</sup> Zone also featured technological advances that can help eye care providers deliver better care, such as Eyes-On Glasses (Evena Medical). No more guessing which is the best vein to draw blood from—these glasses allow health care professionals to



**David Yeh of Evena Medical demonstrates the Eyes-On Glasses at the Eye<sup>2</sup> Zone.**

“see right through the skin” and easily image the vasculature beneath it, which can optimize care and minimize discomfort to patients.

Low vision specialists were introduced to OrCam, a frame-mounted device that uses advanced computer vision to “read” text and recognize objects, and then voices that information via an earpiece. Its goal is to help the visually impaired and blind regain functionalities and independence. ■

1. Adler D, Millodot M. The possible effect of undercorrection on myopic progression in children. *Clin Exp Optom.* 2006 Sep;89(5):315-21.
2. Smith EL, 3rd, Campbell MC, Irving E. Does peripheral retinal input explain the promising myopia control effects of corneal reshaping therapy (CRT or ortho-K) & multifocal soft contact lenses? *Ophthalmic Physiol Opt.* 2013 May;33(3):379-84.
3. Sivak J. The cause(s) of myopia and the efforts that have been made to prevent it. *Clin Exp Optom.* 2012 Nov;95(6):572-82.
4. Walline JJ, Lindsley K, Vedula SS, et al. Interventions to slow progression of myopia in children. *Cochrane Database Syst Rev.* 2011 Dec 7;(12):CD004916.
5. Von Thun Und Hohenstein-Blaul N, Funke S, Grus FH. Tears as a source of biomarkers for ocular and systemic diseases. *Exp Eye Res.* 2013 Dec;117:126-37.
6. Russotto SB. Asymptomatic parotid gland enlargement in diabetes mellitus. *Oral Surg Oral Med Oral Pathol.* 1981 Dec;52(6):594-8.
7. Age-Related Eye Disease Study 2 Research Group. Lutein + zeaxanthin and omega-3 fatty acids for age-related macular degeneration: the Age-Related Eye Disease Study 2 (AREDS2) randomized clinical trial. *JAMA.* 2013 May 15;309(19):2005-15.
8. Chew EY. Nutrition effects on ocular diseases in the aging eye. *Invest Ophthalmol Vis Sci.* 2013 Dec 13;54(14):ORSF42-7.
9. Rand AL, Asbell PA. Nutritional supplements for dry eye syndrome. *Curr Opin Ophthalmol.* 2011 Jul;22(4):279-82.
10. Olerik A, Jiménez-Alfaro I, Alejandre-Alba N, Mahillo-Fernández I. A randomized, double-masked study to evaluate the effect of omega-3 fatty acids supplementation in meibomian gland dysfunction. *Clin Interv Aging.* 2013;8:1133-8.
11. Renard JP, Rouland JF, Bron A, et al. Lifestyle and environmental factors in ocular hypertension and primary open-angle glaucoma: an exploratory case-control study. *Acta Ophthalmol.* 2013 Sep;91(6):505-13.

14 CE/  
8 CEE  
Credits  
(COPE Approval Pending)

# NEW TECHNOLOGIES AND TREATMENTS IN VISION CARE

... Review Meetings of Clinical Excellence

JUNE 19-22

## ORLANDO

### CE COURSE TOPICS:

Managing Ocular Manifestations of Systemic Disease  
Oral Pharmaceuticals in Optometric Practice  
Glaucoma Management Insights  
Ocular Surface Disease Management Update  
New Technologies in Eye Care  
Retinal Disease Grand Rounds  
Surgical Comanagement Pearls  
Anterior Segment Disease Grand Rounds

## Disney's Yacht and Beach Club

### Faculty:

Paul Karpecki, OD  
(Program Chair)

Marc Bloomenstein, OD

Doug Devries, OD

Steve Ferrucci, OD

### 5 WAYS TO REGISTER:

ONLINE: [www.revoptom.com/ORLANDO2014](http://www.revoptom.com/ORLANDO2014)

EMAIL Lois DiDomenico: [ReviewMeetings@Jobson.com](mailto:ReviewMeetings@Jobson.com)

MAIL: Review Group Meetings c/o Jobson

11 Campus Blvd., Ste. 100

Newtown Square, PA 19073

PHONE: 866-658-1772

FAX: 610-492-1039

**REVIEW**  
OF OPTOMETRY

**cope**  
Approval Pending

Thank You to our Sponsors

 ALLERGAN

 Bruder

 AMD ECR Vault

 hydrogel vision

 TOPCON

 Reichert  
Ophthalmic Instruments

 THERA  
TEARS

 ZEISS

# DISNEY'S YACHT CLUB

Discounted Room Rate: \$199/night

For reservations, call: 407-939-4686

Discounted room rates limited.

Identify yourself as a participant of "Review of Optometry" for group rate.

Room rates available 3 days pre/post conference.

## Registration Information

Name \_\_\_\_\_ NPI # (NPI numbers are now required for HCP reporting and will only be used for this purpose.) \_\_\_\_\_

Practice Affiliation \_\_\_\_\_

Mailing Address \_\_\_\_\_ City \_\_\_\_\_ State \_\_\_\_\_ Zip Code \_\_\_\_\_

Telephone \_\_\_\_\_ Fax \_\_\_\_\_ Email \_\_\_\_\_

## Name Badge Information (please print clearly)

My Name \_\_\_\_\_ My Guest \_\_\_\_\_ Additional Guests \_\_\_\_\_

## Payment Information

OD Registration - \$595

(includes 14 hours of CE, breakfasts, cocktail reception)

*Call for daily rates. See website for student pricing.*

Additional Guest(s) - \$45 (12 years and older, includes cocktail reception)

Rate per person	No. in party	Subtotal
\$595	x _____	= \$ _____
\$45	x _____	= \$ _____
	TOTAL	= \$ _____

Check enclosed (make checks payable to *Review of Optometry*)

Charge my:  American Express  Mastercard  Visa

Credit Card Number \_\_\_\_\_ Exp Date \_\_\_\_\_

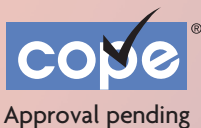Cardholder (print name) \_\_\_\_\_

Signature \_\_\_\_\_

### CONFERENCE CANCELLATION POLICY

- Full refund of registration fee until April 21, 2014
- 50% refund of registration fee until May 19, 2014
- No refund past May 20, 2014

For more information or to register,  
contact Lois DiDomenico at 866-658-1772  
or at [ReviewMeetings@Jobson.com](mailto:ReviewMeetings@Jobson.com).



# NEW

## Lombart CS-5 Package

Quality, Style & Value

Package includes:

- The Lombart CS-5 Chair & Stand 
- Topcon VT-10 Refractor
- Topcon SL-2G Slit Lamp
- Reichert LongLife Chart Projector   
with mount, slide & screen
- Upgrade to the Lombart CVS-PC for only \$1500  
or to the CVSi21 for only \$2000 more
- Additional upgrades & configurations available.

# \$13,595

Or lease for \$265/mo.  
for 60 months\*

\*Lease rate subject to credit approval, 1st payment is due at signing with 59 remaining rental payments of \$265 and a \$1.00 purchase option. Taxes, freight and installation additional. Hand Instruments optional. Subject to change without notice.

1-800-566-2278

## Call 1-800-Lombart

Or Your Local Lombart Representative

Corporate Office - 5358 Robin Hood Road, Norfolk, VA 23513-2430  
757-853-8888 | FAX 757-855-1232 | 800-566-2278

[www.lombartinstrument.com](http://www.lombartinstrument.com)  
[lombart@lombartinstrument.com](mailto:lombart@lombartinstrument.com)



Sales and Service Centers Coast to Coast

ATLANTA • BALTIMORE/WASHINGTON D.C. • BOSTON • BOYNTON BEACH/MIAMI • BRADENTON • CHARLOTTE • CHICAGO • CINCINNATI • DALLAS • DENVER • DETROIT • GREENSBORO • HOUSTON  
JACKSON • KANSAS CITY • KNOXVILLE • LOS ANGELES • MILWAUKEE • MINNEAPOLIS • NEW JERSEY/NEW YORK/PENNSYLVANIA • NORFOLK • PORTLAND • SAN ANTONIO • SAN DIEGO • SAN FRANCISCO





# Rock the Vogt

A patient with painful uveitis suggested an infectious etiology—until ringing in the ears rang a bell for this OD. **Edited by Paul C. Ajamian, OD**

**Q** I had a patient with uveitis of unknown etiology, which turned out to be Vogt-Koyanagi-Harada (VKH) syndrome. In the future, when should I think about comanaging uveitis?

**A** “Panuveitis with associated neurological symptoms should always be comanaged with a retinal or uveitis specialist due to the threat of vision loss and, even worse, death from an underlying systemic infection,” says Kristen Spears, OD, of Omni Eye Services, in Atlanta.

Dr. Spears recently had a case with a very similar presentation. The patient was a 35-year-old male of Indian descent whose chief complaint was progressive blurry vision over the prior four to six weeks. “Upon further questioning, he complained of eye pain and ringing in his ears that had started one week before,” Dr. Spears says.

Best-corrected visual acuity was 20/400 in each eye. Anterior segment exam showed posterior synechia, 2+ cell and flare and mutton-fat keratic precipitates on the inferior endothelium in both eyes. Posterior segment exam revealed bilateral disc edema, macular edema, diffuse vitritis and inferior temporal serous retinal detachments.

“An infectious etiology was at the top of my list of differentials, but the lack of systemic symptoms really threw me off,” Dr. Spears says. “The signs that led me to suspect Vogt-Koyanagi-Harada syndrome were his hearing loss and bilateral serous detachments.

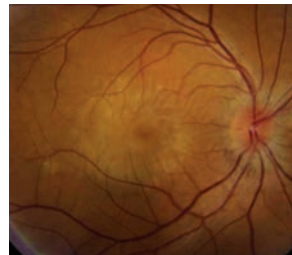
My first thought was that he needed a strong dose of oral prednisolone, but because of the potential for an infectious etiology, I knew I needed the help of a specialist.”

Fortunately, a retinal specialist was available at Omni. “Had I been in a private practice, I would have started the patient on topical therapy—with a corticosteroid, atropine and phenylephrine—ordered extensive blood work that day, and sent the patient to a retinal or uveitis specialist right away,” she says.

Vogt-Koyanagi-Harada syndrome is a rare systemic disease involving various melanocyte-containing organs. There are four distinct stages of the disease: prodromal, acute uveitic (Dr. Spears’ patient presented at this stage), convalescent and chronic recurrent. VKH is more common in Asian, Middle Eastern, Hispanic and Native American populations.<sup>1</sup>

The hallmark ocular signs are bilateral serous retinal detachments, panuveitis and a “sunset glow” fundus. VKH is highly correlated with the HLA-DR4 haplotype and many other antigens associated with autoimmune diseases.

“We ran a battery of lab tests on this patient, including a complete blood count, rapid plasma reagin, FTA-ABS, angiotensin-converting enzyme, purified protein derivative, chest X-ray, and checked for mul-



**One clue to VKH: a “sunset glow” fundus.**

Photo: Mark T. Dunbar, OD

tiply HLA haplotypes,” Dr. Spears says. “The only significant finding from his lab testing was the presence of the HLA-DR4 antigen. But, that combined with his presentation and case history is about as diagnostic as you can get for VKH.”

The retinal specialist agreed with the diagnosis, and prescribed 20mg oral prednisolone five times a day, Pred Forte (prednisolone acetate 1%, Allergan) every hour and homatropine 5% TID. The specialist saw him again four days after his first visit and weekly thereafter for two months.

Regarding follow-up, “optometrists should see these patients every one to two months for the first nine months after discontinuing the oral steroids. Biannual visits are sufficient after that,” she says. “Be sure to educate patients with VKH about their increased risk for glaucoma, cataracts and development of neovascularization.”

Her patient is doing well now. “The patient had an incredibly successful recovery,” Dr. Spears says. “His vision improved from 20/400 OD, OS, to 20/25 OD, OS, during the course of a 40-day treatment. His hearing also returned within that time period. We’re still seeing him monthly and expect him to continue to do well.” ■

1. Sakata VM, da Silva FT, Hirata CE, et al. Diagnosis and classification of Vogt-Koyanagi-Harada disease. *Autoimmun Rev.* 2014 April - May;13(4-5):550-5.

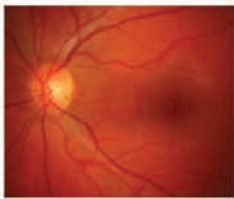
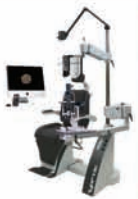

*A Company with an **Eye** for Good Service*



**THIS IS HOW WE ROLL!**

*Consulting for your equipment needs*



**WWW.VOI2020.COM**  
**888.959.5173**

Digital Imaging | Exam Lanes | Consulting | Services | Supplies



# The Bilateral Baffle

Corneal endothelial dysfunction secondary to systemic medications is a rare complication—but we must be aware of the possibility. **Edited by Joseph P. Shovlin, OD**

**Q** I have a young, female patient who wears a contact lens in one eye but presented with diffuse corneal edema (800 $\mu$ m) in both eyes. She is taking amantadine for her Parkinson's-type tremors secondary to use of risperidone. Is the amantadine responsible for her acute corneal edema?

**A** “Bilateral corneal edema in a young, monocular contact lens patient is a head-scratcher,” says Brett G. Bence, OD, Director of Optometry at Northwest Eye Surgeons in Seattle.

Dr. Bence recently saw a patient with a similar presentation. The patient was a 30-year-old white female referred from her optometrist for a second opinion concerning recent corneal edema. She was a high myope (-18D), with a large angle esotropia and hand motion vision in the amblyopic eye.

She wore a soft contact lens in her better eye, with a visual acuity of 20/100. Her best-corrected visual acuity (VA) prior to corneal edema was 20/30. Her medical history was significant for bipolar disorder, anxiety, hypothyroidism, gastroparesis and exercise-induced asthma. Her medications included Nexium, risperidone, acetaminophen with codeine and trazodone.

“Review of her health history reveals an unfortunate but anticipated side effect of risperidone use—muscle tremors,” says Dr. Bence. “For treatment of these Parkinson-like tremors, she was prescribed 150mg amantadine BID. About two

to three months prior to this visit, she independently increased the dose to 150mg three times a day to lessen the tremors without her prescribing physician's knowledge.”

A reasonable differential diagnosis for corneal edema can include endothelial dystrophy; infectious and/or inflammatory causes, such as HSV endotheliitis, interstitial keratitis or keratouveitis; endothelial cell loss from trauma or chronic corneal hypoxia secondary to contact lens overwear; or toxic endothelial dysfunction from systemic medications.

In this particular case, corneal endothelial dystrophy seemed unlikely, “due to the patient's young age, absence of clinical guttata and the seemingly abrupt onset,” says Dr. Bence.

Endotheliitis or keratouveitis from HSV was also unlikely, due to the absence of keratic precipitates, endothelial white cells, concomitant anterior uveitis/AC cells or prior HSV keratitis.

Aside from corneal stromal edema, the patient did not present with any signs of interstitial keratitis (e.g., peripheral-to-central corneal neovascularization, mild conjunctival injection, endothelial and stromal precipitates, and scarring).

“She had no history of corneal trauma, corneal surgery or endothelial damage,” says Dr. Bence. Her referring optometrist shared concern that contact lens overwear may have caused the corneal edema in the contralateral amblyopic eye, noting that she may not have reported contact lens wear on that eye. “However,

the patient adamantly denied this,” he says.

The working diagnosis became toxic endothelial dysfunction secondary to amantadine use. Her prescribing psychiatrist was contacted and amantadine was discontinued. She was also asked to stop contact lens wear, use Muro 128 ophthalmic ointment (Bausch + Lomb) HS and initiate one drop Durezol (difluprednate, Alcon) TID OU.

Following one week of treatment, she showed slight improvement; however, after two weeks, pachymetry showed her corneal edema regressed significantly to 605 $\mu$ m in the amblyopic eye and 521 $\mu$ m in her better eye. Her best VA improved to 20/60 with glasses. Durezol use was tapered, but Muro 128 was continued.

“Interestingly, her optometrist reported that at follow-up a few weeks later, her refractive error had reduced from -18D to -16D,” he says. “This raises the possibility that chronic, perhaps subclinical, corneal edema was slowly altering the curvature and refractive error.”

Toxic corneal endothelial dysfunction from systemic medications is uncommon. In this particular case, amantadine induced bilateral endothelial dysfunction with secondary corneal edema.

“We can be lulled to sleep on some of these mystifying cases,” says Dr. Bence. “Reviewing side effects of systemic medications remains a vital consideration when ocular history and findings don't immediately answer the question.” ■

# The Miniature Multitasker

What makes the hypothalamus so important to the eye and visual system?

By Carlo J. Pelino, OD, and Joseph J. Pizzimenti, OD

As optometric physicians, we manage a wide variety of patient cases that involve systems beyond the eye, from diabetic retinopathy and obesity-related ocular disease to cataracts, diplopia and neurologic diseases such as Horner syndrome. At the heart of all of these conditions is a small yet critical part of the brain—the hypothalamus.

You'll recall from anatomy and physiology primers that the hypothalamus links the nervous system to the endocrine system via the pituitary gland, making it one of the most important transmitters in our bodies. When you understand the intricacies of the hypothalamus, you gain a greater understanding of the body's systems and how that physiology relates to the eye.

## Neuroanatomy Refresher

The hypothalamus is located below the thalamus on either side of the third ventricle, between the optic chiasm and midbrain. It forms the walls and floor of the inferior portion of the third ventricle.<sup>1</sup> A shallow groove on the wall of the third ventricle—the hypothalamic sulcus—separates it from the thalamus situated directly above. The hypothalamus is the most inferior of the four longitudinal divisions of the brain's diencephalon.<sup>2</sup>

The hypothalamus has three regions:

- The anterior or “supraoptic” region includes the suprachiasmatic, supraoptic, anterior and paraven-

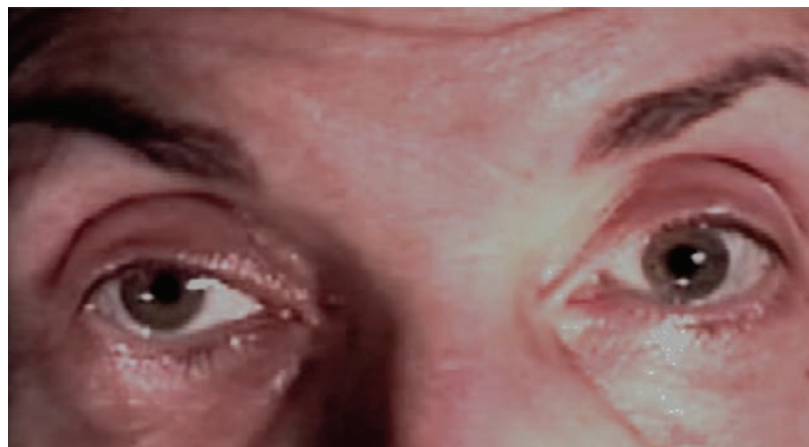

Photo: Albert D. Woods, OD

The image indicates Horner syndrome in the right eye. Pupillary dilation is mediated by a sympathetic pathway that originates in the hypothalamus.

tricular nuclei. This is where axons are projected to the posterior pituitary and other sites such as the spinal cord.

- The middle or “tuberal” region consists of the dorsomedial, ventromedial and arcuate nuclei.
- The posterior or “mammillary” region includes the medial, lateral and intermediate mammillary nuclei, and the posterior nuclei that project to the thalamus and tegmentum regions of the midbrain.<sup>2,3</sup>

## Many Jobs

The hypothalamus is only about the size of a pearl, yet it is a master multitasker. Neuroanatomists refer to it as the “homeostatic head ganglion” because it serves as the central regulator of homeostasis. Basically, it's charged with maintaining balance under ideal physiological conditions and in times

of emotional stress, known as a “stress response.”

The hypothalamus receives information from the limbic system (concerned with mood and emotion) and retina.<sup>1,2</sup> It helps control pituitary endocrine function and has an efferent relationship with the autonomic nervous system (ANS) (see “What Does the Hypothalamus Do?,” right). Hypothalamic nuclei are sensitive to changes in hormone levels, electrolytes and body temperature.

The ventromedial part of the hypothalamus has an important function in controlling the sympathetic nervous system (SNS), which is responsible for pupil dilation, while the lateral hypothalamic area controls the parasympathetic nervous system (PNS), responsible for pupil constriction. The hypothalamus secretes and inhibits hormones



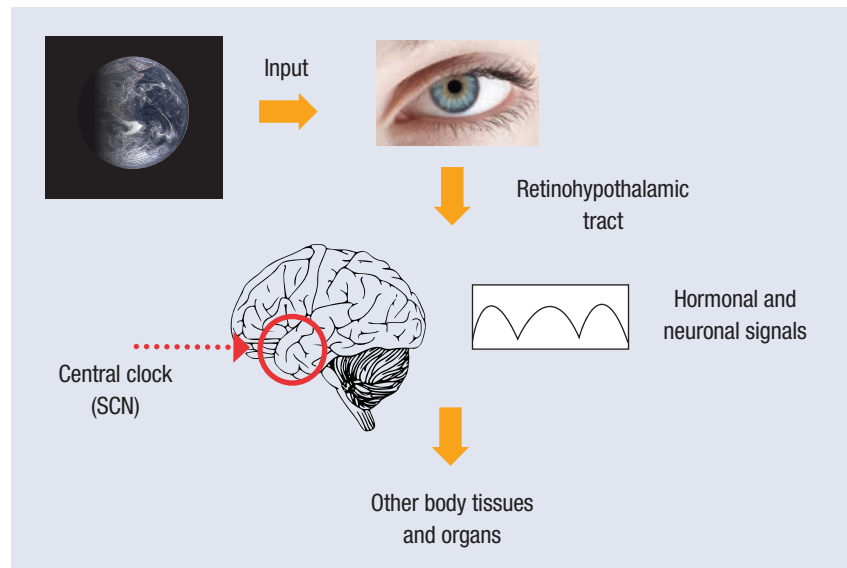
that control endocrine functions and produces antidiuretic hormone, also known as ADH or vasopressin, and oxytocin. Loss of ADH is known as neurogenic diabetes insipidus.

The hypothalamus helps control hunger, thirst, water and thermoregulation. The ventromedial hypothalamus is often called the satiety center, while the lateral hypothalamic region is involved with hunger. These areas operate under the influence of several hormones, including insulin, leptin and ghrelin.<sup>1,4</sup> Osmoreceptor input from atrial stretch receptors in the heart and arterial baroreceptors, along with hypothalamic hormone receptors such as angiotensin II, help regulate thirst.<sup>1</sup> The hypothalamus, along with the limbic system, may also be involved in memory and play a role in sexual and emotional behavior, independent of its endocrine influences.<sup>1</sup>

### A New Pathway

The discovery of inner retinal ganglion cell photoreceptors (RGCPs) in 2002 gave clinical investigators a better understanding of retinal photoreception. No longer were rods and cones accepted as the only sources of human photoreception.

The primary function of RGCPs is gross detection of environmen-



**The suprachiasmatic nucleus of the anterior hypothalamus receives light stimuli from the retina via the retinohypothalamic tract.**

tal light with eventual input to non-visual brain centers. About 3,000 RGCPs, with large receptive fields, exist in each human retina and express the blue-light sensitive photopigment melanospin in their dendrites, cell bodies and axons. This relatively newly discovered pathway is called the retinohypothalamic tract.<sup>1,2,5</sup> Age-related crystalline lens yellowing and other cataractous changes reduce circadian photoreception. This is why cataract surgery provides older adults with more youthful circadian photoreception, resulting in improved sleep patterns.<sup>6</sup>

Ambient illumination is transmitted not only to the hypothalamus, but also to more than a dozen brain centers, including the pretecal nucleus, which is involved in the pupillary light reflex.

The suprachiasmatic nucleus (SCN) of the hypothalamus plays a major role in setting an

individual's circadian rhythm. The SCN controls circadian rhythms for optimal physiology, neurobiologic behavior and hormonal secretion. Synchronization of internal biology and external environmental depends heavily on RGP photoreception.<sup>7</sup>

The next time you diagnose pupil abnormality, thyroid eye disease or diabetic cataract, think about that small, vital part of the brain that is involved in the mediation of endocrine, autonomic and behavioral functions. ■

### What Does the Hypothalamus Do? HEAL

The hypothalamus maintains homeostasis of the body by working with and influencing four other systems.

Remember: HEAL.<sup>2</sup>

- Homeostatic mechanisms that control hunger, thirst and sexual desire
- Endocrine control (via the pituitary)
- Autonomic nervous system control
- Limbic system

1. Barker FA, Barasi S. Anatomical and functional organization. The hypothalamus. In: Neuroscience at a Glance. 3rd ed. Malden, MA: Neal Blackwell; 2008.
2. Blumenfeld H. Neuroanatomy through Clinical Cases. In: Pituitary and Hypothalamus. Sunderland, MA: Sinauer Associates; 2010.
3. Nolte J, Angevine JB, The Human Brain. In: Photographs and Diagrams. Chicago, IL: Mosby; 1995.
4. Magee E. Your 'Hunger Hormones.' WebMD website. Available at: [www.webmd.com/diet/features/your-hunger-hormones](http://www.webmd.com/diet/features/your-hunger-hormones). Accessed April 15, 2014.
5. Do MT, Yau KW. Intrinsically photosensitive retinal ganglion cells. *Physiol Rev.* 2010;90:1547-81.
6. Herljevic M, Middleton B, Thapan K, Skene DJ. Light-induced melatonin suppression: age-related reduction in response to short wavelength light. *Exp Gerontol.* 2005 Mar;40(3):237-42.
7. Brown TM, Gias C, Hatori M et al. Melanopsin contributions to irradiance coding in the thalamo-cortical visual system. *PLoS Biol.* 2010 Dec 7;8(12).

# A Disease of Diversity

AMD most commonly affects white patients. But, this strikingly similar condition often manifests in pigmented individuals. What is it? **By Mark T. Dunbar, OD**

**A** 65-year-old Hispanic female presented with a chief complaint of blurred vision at distance and near that had persisted for one year. Her medical history was significant for controlled hypertension and type 2 diabetes.

On examination, her best-corrected visual acuity measured 20/20-2 OD and 20/20- OS. Ocular motility testing was normal. Confrontation visual fields were full to careful finger counting OU. Her pupils were equally round and reactive, with no evidence of afferent defect OU. The anterior segment examination was significant for 2+ nuclear sclerotic cataracts in both eyes.

Dilated fundus exam revealed flat and clear maculae, with a positive foveal reflex OU. Upon examination of the nerves, we noted minimal cupping with good rim coloration and perfusion. However, we documented peculiar lesions located adjacent to both optic nerves (*figures 1 and 2*). We also

performed a fluorescein angiogram (*figures 3 and 4*).

## Take the Retina Quiz

1. Based on the optic nerve head photographs and fluorescein angiogram, the peripapillary lesions are most consistent with:

- a. Hemorrhagic pigment epithelial detachments.
- b. Intraretinal hemorrhages and exudation.
- c. Choroidal neovascular membranes.
- d. Intraretinal edema and subretinal hemorrhages.

2. What is the correct diagnosis for this condition?

- a. Coats' disease.
- b. Cystoid macular edema.
- c. Diabetic papillopathy.
- d. Polypoidal choroidal vasculopathy (PCV).

3. Which ancillary test is the standard of care for confirming the presence of this condition?

- a. Fluorescein angiography (FA).
- b. Indocyanine green (ICG) angiography.
- c. Optical coherence tomography.
- d. B-scan ultrasonography.

4. How should this patient be managed?

- a. Laser photocoagulation.
- b. Photodynamic therapy.
- c. Intravitreal anti-VEGF injection.
- d. Observation.

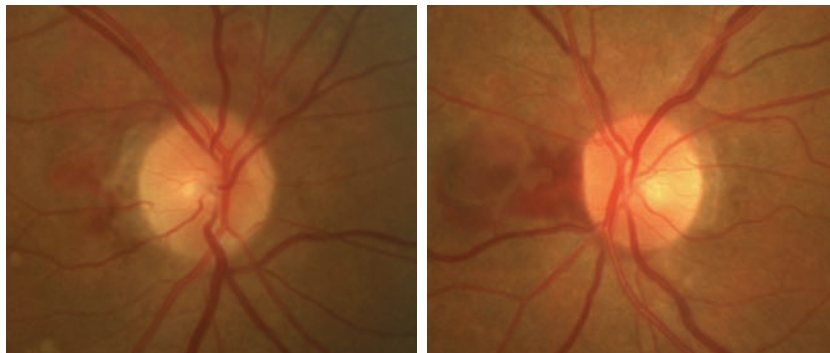
*For answers, turn to page 98.*

## Discussion

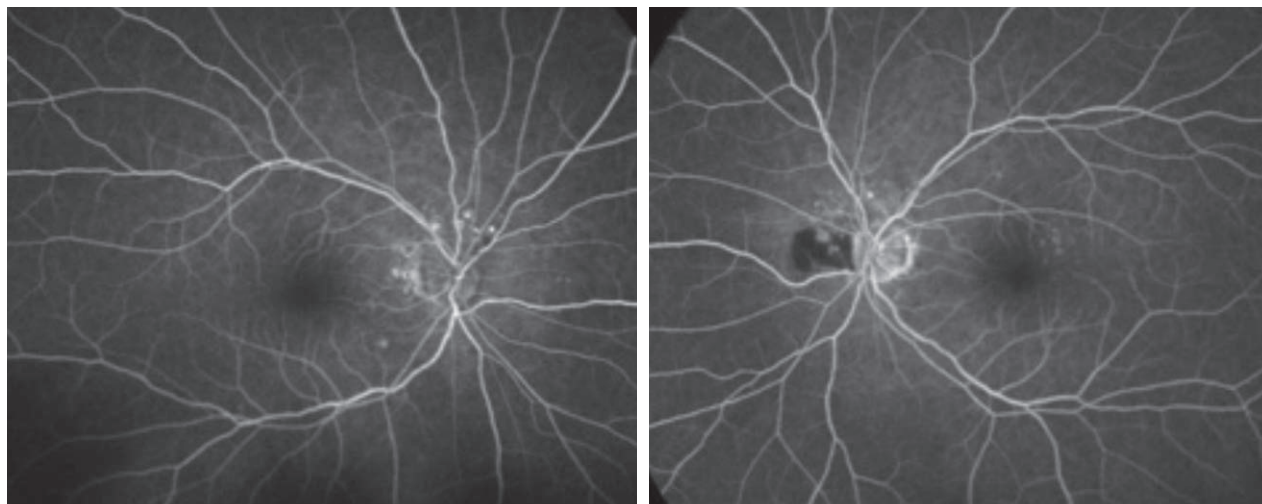
We diagnosed our patient with polypoidal choroidal vasculopathy. This condition was first described by Lawrence A. Yannuzzi, MD, and associates in 1982, and was shown to cause multiple, recurrent, serosanguineous detachments of the retinal pigment epithelium (RPE) and the neurosensory retina.<sup>1</sup>

Since initial discovery, the disease has been given several different names, including “idiopathic polypoidal choroidal vasculopathy,” “posterior uveal bleeding syndrome” and “multiple serosanguineous retinal pigment epithelial detachment syndrome.” Today, the condition is universally known as PCV, and is recognized as a unique form of occult choroidal neovascular membrane.<sup>2</sup>

PCV is characterized by branching choroidal networks that terminate in outward-reaching vessel projections. Clinically, these vas-



**1. Optic nerve photographs of our 65-year-old Hispanic patient show peculiar peripapillary lesions (OD left, OS right).**



## 2. What clinical findings are evident via fluorescein angiography (OD left, OS right)?

cular networks appear as reddish-orange, polyp-like structures. The nodular lesions are associated with serous exudation and hemorrhage, as well as pigment epithelial and neurosensory detachments. Additionally, vitreous and subretinal hemorrhages are common features.

The condition principally manifests in the macular and peripapillary areas.<sup>3</sup> When it occurs in the macula, some clinicians misdiagnose PCV as AMD.

However, in stark contrast to macular degeneration, PCV tends to occur in darker pigmented individuals. In fact—although researchers haven't yet determined the true incidence of PCV in blacks—some studies suggest that nearly all African-American patients who present with “neovascular AMD” likely have PCV.<sup>2</sup>

Initially, researchers believed that PCV occurred exclusively in black females. But, we now know that the condition affects both males and females of several pigmented races, including Hispanics and Asians. For example, one study indicated that 54.7% of Japanese patients previously diagnosed with neovascular AMD actually had PCV.<sup>4</sup>

Fluorescein angiography, ICG angiography and spectral-domain optical coherence tomography are the most useful ancillary tests for diagnosing PCV. It is worth noting that ICG angiography can be more effective for visualizing PCV than FA. This is because indocyanine green absorbs and emits near-infrared light, which penetrates the RPE and allows the practitioner to see choroidal abnormalities, branching networks of inner choroidal vessels and focal nodular areas of hyperfluorescence arising from the choroidal circulation.<sup>3</sup> Fortunately, we were able to appreciate these changes in our patient using fluorescein angiography alone.

Appropriate management of PCV is dictated by several disease variables, including location (peripapillary vs. macular), lesion size, and the presence of secondary bleeding and/or exudation. However, for those who develop vision loss as a result of serosanguineous RPE and neurosensory retina detachments, laser photocoagulation can be used. (Laser treatment is only recommended when the entire polypoidal lesion can be treated effectively.<sup>2</sup>) Because thermal laser causes

retinal damage, directly targeting the choroidal vessels via photodynamic therapy (PDT) is preferable.

Intravitreal anti-VEGF injection for PCV may help resolve macular edema, as well as provide a modest decrease in polypoidal complexes. However, recent studies evaluating a combination of PDT and anti-VEGF therapy have documented more pronounced polyp regression when compared to anti-VEGF injection alone.<sup>3</sup>

Because our patient presented with non-visually significant peripapillary lesions, her retinal specialist opted for observation at this time. We will schedule her for a follow-up evaluation in our office in four to six weeks. ■

*Thanks to Angela DiMarco, OD, optometric resident at Bascom Palmer Eye Institute in Miami, for contributing to this case.*


1. Yannuzzi LA, Sorenson J, Spaide RF, Lipson B. Idiopathic polypoidal choroidal vasculopathy. *Retina*. 1990;10(1):1-8.
2. Imamura Y, Engelbert M, Iida T, et al. Polypoidal choroidal vasculopathy: A review. *Surv Ophthalmol*. 2010 Nov-Dec;55(6):501-15.
3. Ryan SJ, Sadda SR, Hinton DR. Polypoidal Choroidal Vasculopathy. *Retina*, 5th Ed. London: Elsevier, 2013;1285-90.
4. Maruko I, Iida T, Saito M, et al. Clinical characteristics of exudative age-related macular degeneration in Japanese patients. *Am J Ophthalmol*. 2007 Jan;144(1):15-22.

Up to  
15 CE\*  
Credits

**REVIEW**<sup>®</sup>  
OF OPTOMETRY

# 2014 NEW TECHNOLOGIES AND TREATMENTS IN VISION CARE

...*Review Meetings of Clinical Excellence*



**ORLANDO, FL**  
June 19-22



**MINNEAPOLIS, MN**  
July 17-20



**TYSONS  
CORNER, VA**  
(Washington, DC area)  
September 12-14

**UP TO 15 CE CREDITS PER MEETING**

\*COPE approval pending



Program Chair:  
Paul Karpecki, OD

For more information visit [www.revoptom.com](http://www.revoptom.com)





# NVG: A Titanic Disaster?

The thought of treating neovascular glaucoma used to give us a sinking feeling. But today, anti-VEGF therapy may help keep hope afloat.

By Alan G. Kabat, OD, and Joseph W. Sowka, OD

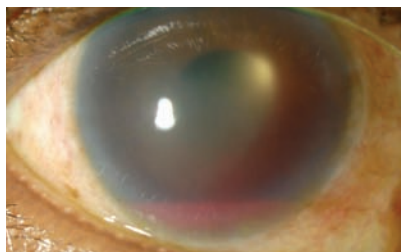
A 65-year-old black female presented emergently with pain and redness in her right eye that persisted for four days. She denied any history of trauma, but reported that she was hospitalized recently for gastrointestinal issues. And, it was during this time that she noticed her eye and vision were “not quite right.”

Further, she underwent uncomplicated cataract surgery in her right eye just two months prior. She was seen for a one-day post-op visit, at which time her visual acuity measured 20/60 OD. However, she did not return subsequently because of the aforementioned stomach issues.

Her medical history was significant for type 2 diabetes, which was controlled with Amaryl (glimepiride, Sanofi Aventis) and Byetta (exenatide, Amylin Pharmaceuticals).

On examination, her best-corrected visual acuity was hand motion at three feet OD and 20/40 OS. The right pupil was fixed at 4mm and was unresponsive to light; however, the left pupil was reactive. Ocular motility testing was normal OU.

Biomicroscopy of the right eye revealed a hazy, edematous cornea with mild conjunctival injection. The anterior chamber appeared deep, but was clouded with red blood cells. Additionally, we noted a 2mm layered hyphema located inferiorly. There was rubeosis along the nasal pupillary margin on the right iris. The posterior chamber IOL was in good position. Biomicroscopy of the



**Our patient's right eye exhibited hyphema and corneal edema secondary to neovascular glaucoma.**

left eye was unremarkable, and its angles were open.

Intraocular pressure measured 72mm Hg OD and 20mm Hg OS. Gonioscopy of the right eye revealed a dense hyphema located inferiorly, but no other angle structures could be visualized in the remaining quadrants. Funduscopy of the right eye was unattainable; however, photographs taken at a visit five months earlier revealed moderate, non-proliferative diabetic retinopathy as well as a few cotton-wool spots OU.

We diagnosed the patient with neovascular glaucoma (NVG). We attempted to reduce her IOP immediately using topical and oral medications, but achieved limited success. The next day, we referred her to a glaucoma specialist who performed a paracentesis, lowering her IOP to the single digits. Also, he delivered an injection of Avastin (bevacizumab, Genentech) OD, and subsequently assumed her care.

In the past, we've made the comment that managing NVG is “like rearranging deck chairs on the

Titanic.” It's a pointless or insignificant act, because the condition will soon be overtaken by the natural course of events—in other words, a no-win scenario. However, recent advances in the area of antiangiogenesis therapy have made the dreaded process of ocular neovascularization significantly more manageable than it was even 10 years ago. In this month's column, we'll explore some of the newest strategies for NVG management, including the use of antiangiogenic drugs.

## The 411 on NVG

Neovascular glaucoma ultimately is attributed to ocular ischemia. The most common etiologies include ischemic central retinal vein occlusion, diabetic retinopathy, carotid artery disease and ocular ischemic syndrome.<sup>1-6</sup> Retinal hypoxia provokes the release of vascular endothelial growth factor (VEGF), an angiogenic peptide that acts upon healthy endothelial cells of viable capillaries to stimulate the formation of neovascular buds.<sup>7-9</sup>

In cases of extreme retinal hypoxia, there are few viable retinal capillaries available—so VEGF often diffuses forward to the nearest region of viable capillaries, the iris. Neovascularization may form along the iris surface, pupillary margin and/or the angle.

Initially, invasion by these new vessels and their fibrovascular supporting membranes physically block the trabecular meshwork, obstruct-

ing aqueous outflow in an open-angle fashion.<sup>10</sup> Over time, however, the membranes bridge the angle and physically pull the iris and cornea into apposition, consequently drawing the angle closed via peripheral anterior synechiae (PAS). This is seen clinically as secondary angle closure without pupillary block.

## Conventional Management

Acute management of NVG involves topical cycloplegia (e.g., atropine 1% BID) and corticosteroids (e.g., difluprednate 0.05% QID) to address the attendant inflammation and enhance patient comfort.<sup>11</sup> While it may seem counterintuitive to employ a drug like atropine to induce pupillary dilation in a patient with a closed angle, this measure is crucial to help diminish ocular congestion in an NVG patient, and may even serve to decrease the IOP via enhanced uveoscleral outflow.<sup>12</sup> Further, the mechanism of angle closure in NVG is not pupillary block, which would be a relative contraindication to a mydriatic/cycloplegic agent.

Topical aqueous suppressants and oral carbonic anhydrase inhibitors may be used to further reduce IOP, and the practitioner may elect to perform a controlled anterior chamber paracentesis in extreme cases.<sup>13</sup> Realize, however, that such therapy is merely a means to temporarily control the markedly elevated IOP and provide pain relief. Ultimately, it is the neovascular process that must be arrested in order to prevent catastrophic damage.

In years past, this could only be accomplished by selectively destroying large areas of retinal tissue through panretinal photocoagulation (PRP) in an effort to extinguish the release of VEGF. Indeed, PRP has been shown to cause regression and involution of anterior segment

neovascularization in approximately 60% of cases.<sup>14</sup>

While PRP is effective for both prophylaxis and treatment of NVG, it does have its limitations. Most obviously, it destroys healthy retinal cells and results in permanent vision loss in those corresponding areas. Also, PRP may not be possible in patients with an obstructed view of the posterior pole (e.g., those with cataract or vitreous hemorrhage). Further, PRP does not induce rapid regression of neovascular membranes—so patients often remain uncomfortable with a high IOP for up to a week before results are seen, frequently requiring concurrent topical and oral glaucoma medications.

## Anti-VEGF Therapy For NVG

Recently, the use of adjunctive antiangiogenic drugs, such as Avastin, has been shown to be extremely beneficial in the early management of NVG.<sup>15</sup> Although still considered an off-label application, Avastin injections have been used for nearly a decade to treat various ophthalmic disorders, including macular degeneration, diabetic retinopathy and central retinal vein occlusion.<sup>16-18</sup>

Several reports have documented the benefits of Avastin injection in the setting of NVG, showing reversal of iris neovascularization as well as a rapid IOP reduction.<sup>19-24</sup> Decreased leakage from new iris vessels may occur as early as one day after intracameral Avastin injection, and reversal of neovascularization has been confirmed using iris fluorescein angiography.<sup>15,23</sup>

In one particular case series, patients with iris neovascularization (but normal IOP) showed disease regression after a single injection—although some eyes required repeat injection due to recurrence.<sup>24</sup> Eyes with NVG that had not progressed to angle closure exhibited rapid

iris neovascularization regression and IOP lowering, but 7/17 eyes (41%) eventually required glaucoma surgery.<sup>24</sup> Finally, eyes with NVG and secondary angle closure had persistently elevated IOP despite resolution of iris neovascularization following Avastin treatment, and 14/15 (93%) of these eyes required surgery within two months of the initial injection.<sup>24</sup> As this study shows, the value of antiangiogenic drugs is greatest before NVG progresses to involve secondary angle closure and PAS formation.

Because our patient presented during an active angle closure secondary to NVG, she likely will have a long road ahead with regard to treatment. The surgeon indicated that several more Avastin injections may be necessary, and she will likely need to undergo IOL explantation before PRP can be performed. It should be remembered that while the antiangiogenic drugs are very effective at reducing neovascularization, their effects are ephemeral. Additionally, the precipitating factor of ocular ischemia still must be addressed—likely with PRP.

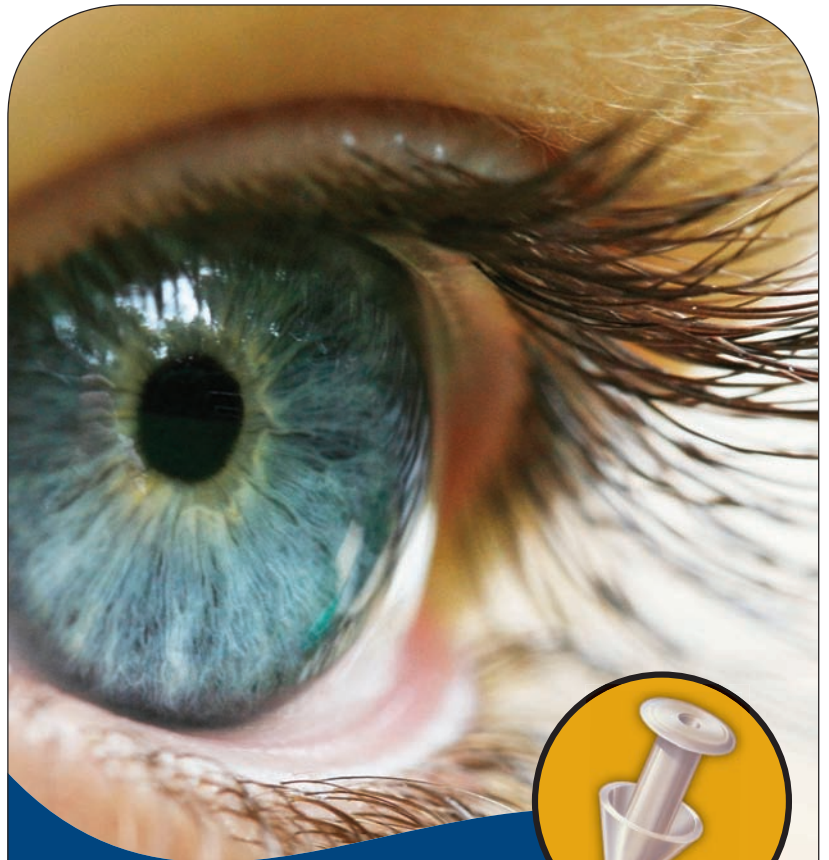She will require continued medical therapy and/or surgery to maintain an acceptable IOP level. Appropriate surgical interventions may include a trabeculectomy with antimetabolites, a glaucoma drainage implant or even transscleral diode laser cyclophotocoagulation to arrest aqueous production.<sup>25-27</sup>

Nevertheless, it is important for practitioners to realize that NVG and iris neovascularization need not inevitably result in blindness. With early detection and initiation of appropriate therapy, we can conceivably right the sinking ship that is neovascular glaucoma. ■

*Dr. Kabat is a paid consultant for Alcon Laboratories. Neither he nor*

*Dr. Sowka has any direct financial interest in the products mentioned.*

1. Kuang TM, Liu CJ. Clinical experience in the management of neovascular glaucoma. *J Chin Med Assoc.* 2004 Mar;67(3):131-5.
2. Nabili S, Kirkness CM. Trans-scleral diode laser cyclophotocoagulation in the treatment of diabetic neovascular glaucoma. *Eye.* 2004 Apr;18(4):352-6.
3. Al-Shamsi HN, Dueker DK, Nowlaty SR, Al-Shahwan SA. Neovascular glaucoma at King Khaled Eye Specialist Hospital - etiologic considerations. *Middle East Afr J Ophthalmol.* 2009 Jan;16(1):15-9.
4. Lawrence PF, Oderich GS. Ophthalmologic findings as predictors of carotid artery disease. *Vasc Endovascular Surg.* 2002 Nov-Dec;36(6):415-24.
5. Chen KJ, Chen SN, Kao LY, et al. Ocular ischemic syndrome. *Chang Gung Med J.* 2001 Aug;24(8):483-91.
6. Detry-Morel M. Neovascular glaucoma in the diabetic patient. *Bull Soc Belge Ophthalmol.* 1995;256:133-41.
7. Tripathi RC, Li J, Tripathi BJ, Adamis AP. Increased level of vascular endothelial growth factor in aqueous humor of patients with neovascular glaucoma. *Ophthalmology.* 1998 Feb;105(2):232-7.
8. Tolentino MJ. Vascular endothelial growth factor is sufficient to produce iris neovascularization and neovascular glaucoma in a non-human primate. *Arch Ophthalmol.* 1996 Aug;114(8):964-70.
9. Scholl S, Kirshof J. Antivascular endothelial growth factors in anterior segment diseases. *Dev Ophthalmol.* 2010;46:133-9.
10. Shazly TA, Latina MA. Neovascular glaucoma: etiology, diagnosis and prognosis. *Semin Ophthalmol.* 2009 Mar-Apr;24(2):113-21.
11. Löffler KU. Neovascular glaucoma: aetiology, pathogenesis and treatment. *Ophthalmologie.* 2006 Dec;103(12):1057-63.
12. Dubej S, Pegu J. Management of neovascular glaucoma. *J Cur Glaucoma Pract.* 2009 Sep-Dec;3(3):27-34.
13. Arnavielle S, Creuzot-Garcher C, Bron AM. Anterior chamber paracentesis in patients with acute elevation of intraocular pressure. *Graefes Arch Clin Exp Ophthalmol.* 2007 Mar;245(3):345-50.
14. Hamard P, Baudouin C. Consensus on neovascular glaucoma. *J Fr Ophthalmol.* 2000 Mar;23(3):289-94.
15. SooHoo JR. Recent advances in the management of neovascular glaucoma. *Semin Ophthalmol.* 2013 May;28(3):165-72.
16. Rosenfeld PJ, Moshfeghi AA, Puliafito CA. Optical coherence tomography findings after an intravitreal injection of bevacizumab (avastin) for neovascular age-related macular degeneration. *Ophthalmic Surg Lasers Imaging.* 2005 Jul-Aug;36(4):331-5.
17. Haritoglou C. Intravitreal bevacizumab therapy for persistent diffuse diabetic macular edema. *Retina.* 2006;26(9):999-1005.
18. Iturralde D, Spaide RF, Meyerle CB, et al. Intravitreal bevacizumab (Avastin) treatment of macular edema in central retinal vein occlusion: a short-term study. *Retina.* 2006;26(3):279-84.
19. Kahook MY, Schuman JS, Noecker RJ. Intravitreal bevacizumab in a patient with neovascular glaucoma. *Ophthalmic Surg Lasers Imaging.* 2006;37(2):144-6.
20. Oshima Y, Sakaguchi H. Regression of iris neovascularization after intravitreal injection of bevacizumab in patients with proliferative diabetic retinopathy. *Am J Ophthalmol.* 2006;142(1):155-8.
21. Grover S. Intracameral bevacizumab effectively reduces aqueous vascular endothelial growth factor concentrations in neovascular glaucoma. *Br J Ophthalmol* 2009;93(2):273-4.
22. Yazdani S, Hendi K, Pakravan M, et al. Intravitreal bevacizumab for neovascular glaucoma: a randomized controlled trial. *J Glaucoma.* 2009 Oct;18(8):632-7.
23. Grisanti S, Biester S, Peters S, et al. Intracameral bevacizumab for iris rubeosis. *Am J Ophthalmol.* 2006;142(1):158-60.
24. Wakabayashi T, Oshima Y, Sakaguchi H, et al. Intravitreal bevacizumab to treat iris neovascularization and neovascular glaucoma secondary to ischemic retinal diseases in 41 consecutive cases. *Ophthalmology.* 2008;115(9):1571-80, e1571-3.
25. Mandal AK, Majji AB, Mandal SP, et al. Mitomycin-C-augmented trabeculectomy for neovascular glaucoma. A preliminary report. *Indian J Ophthalmol.* 2002 Dec;50(4):287-93.
26. Nettland PA, Ishida K, Boyle JW. The Ahmed glaucoma valve in patients with and without neovascular glaucoma. *J Glaucoma.* 2010 Dec;19(9):581-6.
27. Ghosh S. Combined diode laser cyclophotocoagulation and intravitreal bevacizumab (Avastin) in neovascular glaucoma. *Clin Experiment Ophthalmol.* 2010 May;38(4):353-7.



Parazol®

## A PERFECT FIT

ODYSSEY MEDICAL + BEAVER VISITEC

The Odyssey Parazol® Punctal Occluder is now part of Beaver-Visitec International (BVI), a world leader of trusted ophthalmic brands. Not only is the Parazol® a perfect fit for your dry eye patients, but combining BVI with the outstanding success of the Parazol®, continues the tradition of superior knowledge, products and services.

For those of you who depend on a quality product from Odyssey Medical, WELCOME TO BVI.

Your new ordering information:

866-906-8080

customersupport@beaver-visitec.com

www.odysseymed.com

www.beaver-visitec.com



Beaver Visitec

Keeping Your Vision in Sight

Beaver-Visitec International, Inc. | 411 Waverley Oaks Road Waltham, MA 02454 USA | BVI, BVI Logo and all other trademarks (unless noted otherwise) are property of a Beaver-Visitec International ("BVI") company © 2014 BVI

# Product Review

## Ocular Nutrition

### Easy AREDS 2 Delivery

Two new products by Macular Health—MacuSpray and MacuStrip Premier—provide easier ways for AMD patients to get the nutrients they need while eliminating pills, capsules or transdermal patches, the company says.

MacuSpray and MacuStrip bypass the gastrointestinal tract and transport essential nutrients through the blood, allowing for an absorption rate nine times better than that of pills, the company says. Macular Health



notes that this will provide maximum delivery of the nutrients found in the AREDS 2 study to be most effective in slowing or preventing vision loss due to AMD.

Visit [www.macularhealth.com](http://www.macularhealth.com).

## Telemedicine

### There's an App for That

A newly developed app connects patients with practitioners for diagnoses, medical questions, appointments and prescription refills. It's available for any medical specialty and most medical conditions, according to AppMedicine, the developer of AppVisit.

Through AppVisit, patients answer providers' questions, including diagnostic-specific pictures. The provider then determines any next steps, be it a diagnosis, in-person appointment or immediate prescription. According to AppMedicine, research has shown that up to 50% of face-to-face doctor visits can be thoroughly and safely handled this way. It lists ophthalmology as one specialty that has demonstrated strong acceptance of such patient encounter solutions.

Visit [www.appmedicine.com](http://www.appmedicine.com).

## Research Funding

### Get Innovative

Clinicians who can demonstrate significant potential for research discoveries and technological advance-

ments are encouraged to submit proposals to CooperVision's Science and Technology Awards Program.

The Seedling Award allows for a one-year collaboration and enables investigators to generate preliminary data that could be used toward a future CooperVision Translational Research Award. The maximum total cash amount is \$100,000, including indirect costs.

The CooperVision Translational Research Award is a multi-year award for a substantive translational research project. Research under this award is milestone driven. Funding is provided for up to two years, totaling up to \$400,000, including indirect costs.

Visit [www.coopervision.com/](http://www.coopervision.com/).

## Contact Lens Care

### You'll "Flip" for Flip-Top

Users of Alcon's Clear Care Solution will notice updated packaging, which includes a convenient flip-top cap in lieu of its current screw top. The new bottle is also slightly shorter and wider.

Alcon notes that these changes have no effect on the product itself—just the packaging and design. Another thing that will stay the same: the flip-top will stay red to help remind consumers about the potential consequences of misusing hydrogen peroxide eye care products.

Visit [www.alcon.com](http://www.alcon.com).

## Diagnostics

### FDA Green Light

The FDA has given its stamp of approval to Paragon BioTeck's Phenylephrine Hydrochloride Ophthalmic Solution for in-office pupillary dilation. With this formulation now available (through Bausch + Lomb) in concentrations of 2.5% and 10%, there's no longer a need for practitioners to use unapproved versions of the solution, Paragon says.

Phenylephrine constricts ophthalmic blood vessels and the radial muscle of the iris to induce vasoconstriction and mydriasis.

Visit [www.paragonbioteck.com](http://www.paragonbioteck.com).

## Augment Your Assessments

For practices that do visual evoked potentials as part of a comprehensive visual pathway assessment, the new EvokeDx system could help simplify the test procedure and interpretation of the results, according to Konan Medical. With the visual stimulus, analysis software and data display options integrated into one device, the EvokeDx is faster, less expensive, and easier to use and

interpret than other modalities, Konan says.

Results of a recent US multi-center clinical trial showed that EvokeDx technology provided strong differentiation between normal eyes and glaucoma-affected eyes with an overall accuracy estimate of 89%, according to the company.

Visit [www.KonanMedical.com](http://www.KonanMedical.com).

## Ophthalmic Lenses

### Polycarbonate Photochromic PhotoViews



Polycarbonate has been added to the PhotoViews photochromic lenses material options. This gives patients two lens material options for comfy vision indoors and outdoors, Signet Armorlite says.

PhotoViews photochromic lenses were first

launched in standard resin, offering a faster fade time, over previous generations of photochromics, and 100% direct UV protection.

The addition of polycarbonate expands its use for drill mount frames.

Visit [www.SignetArmorlite.com/PhotoViews](http://www.SignetArmorlite.com/PhotoViews).

## Go Green

Graphite green has now been added to Essilor's offerings of Transitions Signature VII lenses.

Using a special dye formulation, these new lenses provide natural vision and true color perception in a variety of light conditions.

The iconic green color of the lens dates back to the 1930s, when it was applied to sunglasses worn by US Navy pilots. The gray-green color was originally developed based on research that showed how human eyes respond differently to various colors in the visual spectrum.

The gray-green lenses were then formulated to emphasize certain colors to help pilots locate and track objects.

Visit [www.EssilorTransitions.com](http://www.EssilorTransitions.com). ■

# EYE CARE HAS ADVANCED



## HAS YOUR HIRING STRATEGY?

Modernize your staffing efforts by downloading our **FREE 2014 Hiring Trends** guide today!

Download available at [localeyesite.com/c/guide](http://localeyesite.com/c/guide)

**14 CE/  
7 CEE  
Credits**

(COPE Approval Pending)

# 2014 NEW TECHNOLOGIES AND TREATMENTS IN VISION CARE

... Review Meetings of Clinical Excellence

July 17 – 20

## MINNEAPOLIS

### CE COURSE TOPICS:

Anterior and Posterior Disease Management  
New Advances in the Management of Lid Margin Disease  
Anterior Segment Disease Grand Rounds  
New Contact Lens Technology Highlights  
Posterior Pole Observations and Their Management  
Glaucoma Management  
Pain Management in Ocular Disease

### Minneapolis Hilton

#### Faculty:

Paul Karpecki, OD  
(Program Chair)

Paul Ajamian, OD

Joseph Shovlin, OD

Robert Wooldridge, OD

### 5 WAYS TO REGISTER:

ONLINE: [www.revoptom.com/minneapolis](http://www.revoptom.com/minneapolis)

EMAIL Lois DiDomenico: [ReviewMeetings@Jobson.com](mailto:ReviewMeetings@Jobson.com)

MAIL: Review Group Meetings c/o Jobson

11 Campus Blvd., Ste. 100

Newtown Square, PA 19073

PHONE: 866-658-1772

FAX: 610-492-1039

REVIEW  
OF OPTOMETRY

cope  
Approval Pending

Thank You to our Sponsors

ALLERGAN **Bruder**

AMD ECR Vault

essilor

hydrogelvision  
CORPORATION

TOPCON

STEREO OPTICAL

ZEISS

# MINNEAPOLIS HILTON

Discounted Room Rate: \$139/night  
For reservations, call: 888-933-5363

Discounted room rates limited.  
Identify yourself as a participant of "Review of Optometry"  
and reference group code ROO for group rate.  
Room rates available 3 days pre/post conference.

## Registration Information

Name		NPI # (NPI numbers are now required for HCP reporting and will only be used for this purpose.)	
Practice Affiliation			
Mailing Address		City	State Zip Code
Telephone	Fax	Email	

## Name Badge Information (please print clearly)

My Name	My Guest	Additional Guests
---------	----------	-------------------

## Payment Information

OD Registration - \$595  
(includes 14 hours of CE, breakfasts, cocktail reception)  
*Call for daily rates. See website for student pricing.*  
Additional Guest(s) - \$45 (12 years and older, includes cocktail reception)

Rate per person	No. in party	Subtotal
\$595	x _____	= \$ _____
\$45	x _____	= \$ _____
	TOTAL	= \$ _____

Check enclosed (make checks payable to *Review of Optometry*)  
Charge my:  American Express  Mastercard  Visa

Credit Card Number	Exp Date
Cardholder (print name)	
Signature	

### CONFERENCE CANCELLATION POLICY

- Full refund on registration fee until June 17, 2014
- 50% refund on registration fee until July 6, 2014
- No refund past July 6, 2014

For more information or to register,  
contact Lois DiDomenico at 866-658-1772  
or at [ReviewMeetings@Jobson.com](mailto:ReviewMeetings@Jobson.com).



**REVIEW**  
OF OPTOMETRY

# Meetings + Conferences

## May 2014

■ **29-31.** *Oregon's Meeting.* Bend Riverhouse Hotel and Conference Center, Bend, Ore. Hosted by: Oregon Optometric Physicians Association. Key faculty: Jane Weissman, MD, Thomas Hwang, MD, Greg Kaultz, OD, Ryan Bulson, OD, Mark Andre, FFAO. CE hours: 11. Contact Lynne Olson at [lynne@oregonoptometry.org](mailto:lynne@oregonoptometry.org) or call (800) 922-2045.

■ **30-June 1.** *Ocular Symposium: Pearls in Ocular Diagnosis.* San Francisco, Calif. CE hours: 24. Contact Lorraine Geary at [ocularsymp@aol.com](mailto:ocularsymp@aol.com) or call (415) 278-9940.

## June 2014

■ **6-8.** *Summer Conference.* Harborside Hotel & Marina, Harbor, Maine. Hosted by: Maine Optometric Association. Call (800) 328-5033. Visit [www.MaineEyeDoctors.org](http://www.MaineEyeDoctors.org).

■ **8.** *Resident Forum.* UC Berkeley Campus, Berkeley, Calif. Hosted by: University of California, Berkeley, School of Optometry. CE hours: 8. Email [mmoy@berkeley.edu](mailto:mmoy@berkeley.edu) or call (510) 642-8802. Visit [optometry.berkeley.edu/ce/introduction](http://optometry.berkeley.edu/ce/introduction).

■ **13-14.** *Northwest Residents Conference.* Jefferson Hall on Pacific University Campus, Forest Grove, Ore. Hosted by: Pacific University College of Optometry. CE hours: 10. Email Martina Fredericks at [frederim@pacificu.edu](mailto:frederim@pacificu.edu) or call (503) 352-2207. Visit [www.pacificu.edu](http://www.pacificu.edu).

■ **20-22.** *100th Anniversary Annual Convention.* Crowne Plaza Hotel, Baton Rouge, La. Hosted by: Optometry Association of Louisiana. Featured speakers: Larry Alexander, OD, James Thimons, OD, Randall Thomas, OD, Ron Melton, OD. CE hours: 16. Email [optla@bellsouth.net](mailto:optla@bellsouth.net) or call (318) 335-0675. Visit [www.optla.org](http://www.optla.org).

■ **20-22.** *VOA Annual Conference.* Richmond, Va. Hosted by: Virginia Optometric Association. CE hours: 15. Email [office@thevoa.org](mailto:office@thevoa.org) or call (804) 643-0309. Visit [www.thevoa.org](http://www.thevoa.org).

■ **25-28.** *2014 Optometry's Meeting.* Pennsylvania Convention Center, Philadelphia. Hosted by: AOA. CE hours: 180. Email Frances Ghannam at [fghannam@aoa.org](mailto:fghannam@aoa.org) or call (314) 983-4214. Visit [www.optometrysmeeting.org](http://www.optometrysmeeting.org).

■ **29-July 14.** *AEA Cruises.* Grand Princess, Alaska. Hosted by: AEA Cruises. CE hours: 10. Email [aeacruises@aol.com](mailto:aeacruises@aol.com) or call (888) 638-6009. Visit [www.optometriccruiseseminars.com](http://www.optometriccruiseseminars.com).

## July 2014

■ **10-13.** *Colorado Vision Summit.* Steamboat Grand Hotel, Steamboat Springs, Colo. Hosted by: Colorado Optometric Association and Mountain States Congress of Optometry. Featured speakers: Andrew Gurwood, OD, Marc Myers, OD, Marc Bloomenstein, OD, Leo Semes, OD, Cathy Stern, OD, WC Maples, OD, Kyle Cheatham, OD, Mile Brujic, OD, Steve Devick, OD. CE hours: 52. Email [CVSummit@visioncare.org](mailto:CVSummit@visioncare.org) or call (877) 691-2095. Visit [www.coloradovisionssummit.org](http://www.coloradovisionssummit.org).

■ **10-19.** *Therapeutic Pharmaceutical Agents Certification*

*Course.* Nova Southeastern University, Fort Lauderdale, Fla. Hosted by: Nova Southeastern University. Featured speakers: Bruce Onofrey, OD, Kim Reed, OD, Joseph Sowka, OD. CE hours: 100. Email [oceaa@nova.edu](mailto:oceaa@nova.edu) or call (954) 262-4224. Visit [optometry.nova.edu/ce/index.html](http://optometry.nova.edu/ce/index.html).

■ **24-27.** *Florida Optometric Association's Annual Convention.* Boca Raton Resort & Club, Boca Raton, Fla. Hosted by: Florida Optometric Association. CE hours: 22. Email Blake Moore, [blake@floridaeyes.org](mailto:blake@floridaeyes.org) or call (850) 877-4697. Visit [www.florida-eyes.org](http://www.florida-eyes.org).

■ **25-27.** *Tahoe Summit.* Hyatt Regency, Incline Village, Nev. Hosted by: Sacramento Valley Optometric Society. CE hours: 12. Email Jerry Sue Hooper at [jerrysue13@comcast.net](mailto:jerrysue13@comcast.net) or call (916) 446-2331.

■ **26-28.** *National Glaucoma Symposium.* Ocean Edge Resort, Brewster (Cape Cod), Mass. Hosted by: National Glaucoma Society. CE hours: 18. Email Blake Moore at [info@NationalGlaucomaSociety.org](mailto:info@NationalGlaucomaSociety.org) or call (877) 825-2020. Visit [www.NationalGlaucomaSociety.org](http://www.NationalGlaucomaSociety.org).

## August 2014

■ **1-3.** *South Seas Educational Retreat.* South Seas Island Resort, Captiva Island, Fla. Hosted by: Southwest Florida Optometric Association. Featured speakers: Ben Gaddie, OD, Carlo Pelino, OD, April Jasper, OD, Ron Foreman, OD. CE hours: 18. Email [swfoa@att.net](mailto:swfoa@att.net) or call (239) 481-7799. Visit [www.swfoa.com](http://www.swfoa.com).

■ **1-3.** *Smoky Mountain Summer.* Grove Park Inn, Asheville, NC. Hosted by: Nova Southeastern University. Featured speakers: Diana Shechtman, OD, Bill Jones, OD. CE hours: 14. Email [oceaa@nova.edu](mailto:oceaa@nova.edu) or call (954) 262-4224. Visit [optometry.nova.edu/ce/index.html](http://optometry.nova.edu/ce/index.html).

## September 2014

■ **12-14.** *Fall Conference.* Point Lookout, Northport, Maine. Hosted by: Maine Optometric Association. Call (207) 789-2000. Visit [www.MaineEyeDoctors.org](http://www.MaineEyeDoctors.org).

■ **12-14.** *Review of Optometry New Technologies and Treatments.* Tysons Corner, Va. Hosted by: Review of Optometry. Email Lois DiDomenico at [ldidomenico@jobson.com](mailto:ldidomenico@jobson.com). Call (610) 492-1000. Visit [www.revoptom.com](http://www.revoptom.com).

■ **13-14.** *Diabetic Management Update and Annual Glaucoma Meeting.* Nova Southeastern University, Ft. Lauderdale, Fla. CE hours: 12. Email [oceaa@nova.edu](mailto:oceaa@nova.edu) or call (954) 262-4224. Visit [optometry.nova.edu/ce/index.html](http://optometry.nova.edu/ce/index.html).

■ **17-20.** *Envision Conference 2014.* Hyatt Regency Minneapolis, Minneapolis, Minn. Hosted by: Envision University. CE hours: 23. Email [michael.epp@envisionus.com](mailto:michael.epp@envisionus.com) or call (316) 440-1515. Visit [www.envisionconference.org](http://www.envisionconference.org).

■ **17-20.** *Vision Expo West 2014.* Sands Expo & Convention Center, Las Vegas, Nev. CE hours: 350+. Hosted by:



# Advertisers Index

International Vision Expo and Conference. Visit [www.visionexpowest.com](http://www.visionexpowest.com).

■ **18. IOA Annual Conference.** Crowne Plaza Hotel, Springfield, Ill. Hosted by: Illinois Optometric Association. CE hours: 15. Email Charlene Marsh at [ioabb@ioaweb.org](mailto:ioabb@ioaweb.org) or call (217) 525-8012. Visit [www.ioaweb.org](http://www.ioaweb.org).

■ **19-20. New Mexico Optometric Association Mid-Year Convention.** Inn of the Mountain Gods, Mescalero, NM. Hosted by: New Mexico Optometric Association. CE hours: 8. Email Richard Montonya at [newmexicooptometry@gmail.com](mailto:newmexicooptometry@gmail.com) or call (575) 751-7542. Visit [www.newmexicooptometry.org](http://www.newmexicooptometry.org).

■ **19-21. KOA 2014 Fall Congress.** Marriott River Center Hotel, Covington, Ky. Hosted by: Kentucky Optometric Association. CE hours: 20. Email Sarah Unger at [sarah@kyeyes.org](mailto:sarah@kyeyes.org) or call (502) 875-3516. Visit [www.kyeyes.org](http://www.kyeyes.org).

■ **21. CPOS Annual CE Forum.** Hotel Hershey, Hershey, Pa. Hosted by: Central Pennsylvania Optometric Society. CE hours: 6. Email Mary Good, OD, at [cposrsvp@gmail.com](mailto:cposrsvp@gmail.com).

■ **21-23. CE in Italy.** Rome, Italy. Hosted by: James Fanelli, OD. CE hours: 12. Key faculty: Leonard Messner, OD, Lorraine Lombardi, PhD, James Fanelli, OD. Email [jamesfanelli@CEItaly.com](mailto:jamesfanelli@CEItaly.com). Visit [www.CEItaly.com](http://www.CEItaly.com).

■ **25-27. CE in Italy.** Florence, Italy. Hosted by: James Fanelli, OD. CE hours: 12. Key faculty: Leonard Messner, OD, Lorraine Lombardi, PhD, James Fanelli, OD, Carlo Pelino, OD. Email [jamesfanelli@CEItaly.com](mailto:jamesfanelli@CEItaly.com). Visit [www.CEItaly.com](http://www.CEItaly.com).

■ **26-28. NOA Fall Convention.** Younes Conference Center, Kearney, Neb. Hosted by: Nebraska Optometric Association. CE hours: 10. Contact Alissa Johnson at [noa@assocoffice.net](mailto:noa@assocoffice.net). Call (402) 474-7716. Visit [nebraska.aoa.org/fallconvention](http://nebraska.aoa.org/fallconvention).

■ **28-30. CE in Italy.** Tuscany, Italy. Hosted by: James Fanelli, OD. CE hours: 12. Key faculty: Leonard Messner, OD, James Fanelli, OD, Carlo Pelino, OD. Email [jamesfanelli@CEItaly.com](mailto:jamesfanelli@CEItaly.com). Visit [www.CEItaly.com](http://www.CEItaly.com).

## October 2014

■ **2-4. OAOP Fall Conference.** Renaissance Tulsa Hotel & Convention Center, Tulsa, Okla. Hosted by: Oklahoma Association of Optometric Physicians. CE hours: 18. Email Heatherlyn Burton at [heatherlyn@oaop.org](mailto:heatherlyn@oaop.org) or call (405) 524-1075. Visit [www.oaop.org](http://www.oaop.org).

■ **2-5. 2014 Missouri Optometric Association Annual Conference.** University Plaza Hotel, Springfield, Mo. Hosted by: Missouri Optometric Association. CE hours: 14. Email Sue Brown at [sue@moeyecare.org](mailto:sue@moeyecare.org) or call (573) 635-6151. Visit [www.moeyecare.org](http://www.moeyecare.org).

### To list your meeting, please send the details to:

Erin Kelly, Senior Associate Editor

Email: [ekelly@jobson.com](mailto:ekelly@jobson.com)

Phone: (610) 492-1005

For advertising opportunities contact:

Michelle Barrett (610) 492-1014 or [mbarrett@jobson.com](mailto:mbarrett@jobson.com)

James Henne (610) 492-1017 or [jhenne@jobson.com](mailto:jhenne@jobson.com)

Scott Tobin (610) 492-1011 or [stobin@jobson.com](mailto:stobin@jobson.com)

**Alcon Laboratories** ..... **18 A-H, 43, 50, 51, 59, 100**  
Phone ..... (800) 451-3937  
Fax ..... (817) 551-4352

**Allergan, Inc.**..... **2, 3, 13, 14, 27**  
Phone ..... (800) 347-4500

**Bausch + Lomb** ..... **9, 25, 37**  
Phone ..... (800) 323-0000  
Fax ..... (813) 975-7762

**Coburn Technologies** ..... **29**  
Phone ..... (800) 262-8761  
..... [www.coburntechnologies.com](http://www.coburntechnologies.com)

**CooperVision** ..... **33**  
Phone ..... (800) 341-2020

**Essilor of America**..... **5, 22-23**  
..... [www.essilorusa.com](http://www.essilorusa.com)

**Foundation for Eye Health Awareness** ..... **7**

**Haag-Streit** ..... **10, 47**  
Phone ..... (800) 627-6286  
Fax ..... (603) 742-7217

**Icare USA** ..... **21**  
Phone ..... (888) 389-4022  
[www.icare-usa.com](http://www.icare-usa.com)

**Keeler Instruments**..... **99**  
Phone ..... (800) 523-5620  
Fax ..... (610) 353-7814

**Lombart Instruments** ..... **72**  
Phone ..... (800) 446-8092  
Fax ..... (757) 855-1232

**Odyssey Medical (now part of Beaver-Visitec International, Inc.)** ..... **83**  
Phone ..... (866) 906-8080  
..... [www.odysseymed.com](http://www.odysseymed.com)

**S4OPTIK**..... **17**  
Phone ..... (888) 224-6012

**Sauflon** ..... **55**  
Phone ..... (800) 682-3240  
Fax ..... (800) 644-3622  
[info@sauflon.com](mailto:info@sauflon.com) ..... [SauflonUSA.com](http://SauflonUSA.com)

**Transitions Optical**..... **49**  
Phone ..... (800) 848-1506  
Fax ..... (813) 546-4732

**Veatch**..... **74**  
Phone ..... (800) 447-7511  
Fax ..... (602) 838-4934

**Vision Source** ..... **15**  
Phone ..... (281) 312-1111  
Fax ..... (281) 312-1153  
..... [www.visionsource.com](http://www.visionsource.com)

*This advertiser index is published as a convenience and not as part of the advertising contract. Every care will be taken to index correctly. No allowance will be made for errors due to spelling, incorrect page number, or failure to insert.*



**Storage and Design**

**presenta nova**  
interior & product design



Visit our Showroom in New York City!

**European Design**



**Presenta Nova Inc.**  
13-17 Laight Street, # 504  
New York City, NY 10013  
USA

p +1 888 959 1471  
f +1 888 959 1471  
info@presenta-nova.com  
www.presenta-nova.com



**Planning**

- space plan
- 3D realistic planning – virtual tour through the space
- design concepts

**Display**

- world leader in innovation
- clean presentation
- focus on displayed frames

**Realization**

- in-house manufacturing and production
- experienced installation crew
- high quality products

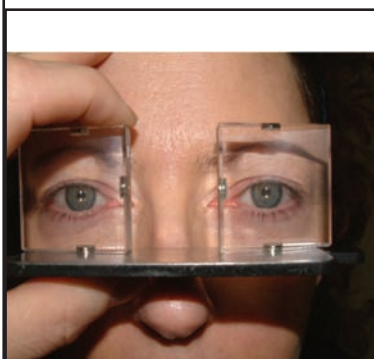
**Equipment and Supplies**



It's What the Best  
Pretest on!  
**(800) 522-2275**  
www.optinomics.com  
sales@optinomics.com

**Equipment and Supplies**

**New! Bishop Alignment Prism Set**



- For measuring large deviations between eyes.
- Prisms can be placed base in, base out, spaced for the patient's PD, and held correctly in the horizontal and frontal planes by magnetic fixation to the plate.
- For combined vertical and horizontal deviations.
- Works well on patients wearing trial frames.

Easily held & positioned using only one hand.

**Gulden Ophthalmics**  
time saving tools  
800-659-2250 www.guldenophthalmics.com

Website search "11311"



Do you have CE or CME Programs?

CONTACT US TODAY  
FOR CLASSIFIED ADVERTISING  
Toll free: 888-498-1460  
E-mail: sales@kerhgroup.com

Do you have Equipment  
and Supplies for Sale?



Contact us today for classified advertising:  
Toll free: 888-498-1460 • E-mail: sales@kerhgroup.com

Merchandise Offered

**EYE|DESIGNS**  
CUSTOM INTERIORS • FURNITURE

SPACE PLANNING INTERIOR DESIGN  
DISPLAY INNOVATION MANUFACTURING

**PROFIT BY DESIGN**

WWW.EYEDESIGNS.COM // 800.346.8890



**SHOWCASE PRODUCT  
IN STYLE**



**opticaldisplays.com**  
610.489.7620



EMAIL  
INFO@OPTICALDISPLAYS.COM  
TO REQUEST OUR  
NEW 2014 CATALOG



Merchandise Offered

**www.eyewear4less.com**

EVERYDAY LOW PRICES - HUGE SELECTION  
"Per Uomo" FACTORY DIRECT ITALIAN EYEWEAR  
BRAND NAME OVERSTOCKS,  
CLOSE-OUTS & SPECIALS  
"YOUR PRACTICE YOUR PROFIT"  
**800-762-0480**

Equipment and Supplies

SOFT CONTACTS • SOFT PRICES

***Bradford Optical, Inc.***

**800.435.5535**

[www.BradfordOpticalInc.com](http://www.BradfordOpticalInc.com)

**REVIEW**  
OF OPTOMETRY



**Looking to  
increase sales?**

**Place Your Ad here.**

Contact us today for  
classified advertising:  
**888-498-1460**  
E-mail: [sales@kerhgroup.com](mailto:sales@kerhgroup.com)

Merchandise Offered




Optical Space Planning & Design  
**1-877-274-9300**



An Essilor Company 



**0%** FINANCING FOR 36 MONTHS\*  
OPTICAL DISPLAYS & FURNITURE

\* Limited-time offer, Minimum purchase of \$10K required. Offer Expires May 30, 2014.

**FREE DISPENSARY / PRACTICE DESIGN SERVICE**



**Frame Displays.com**

Call Now **1-877-274-9300**

Software



**QUIKEYES ONLINE**  
**WEB-BASED OPTOMETRY EHR**

- \$99 per month after low cost set-up fee
- Quick Set-Up and Easy to Use
- No Server Needed
- Corporate and Private OD practices
- 14 Day Free Demo Trial
- Users Eligible for 44K incentives

[www.quikeyes.com](http://www.quikeyes.com) 

Software

Secure Access Anytime  
EHR Certified  
Industry Experts





**Web-based Platform**  
**Certified Complete Exam Module**  
**Secure & Scalable**

800.788.3356  
[www.eyecom3.com](http://www.eyecom3.com)

**REVIEW**  
OF OPTOMETRY

**Do you have CE or CME Programs?**

CONTACT US TODAY  
FOR CLASSIFIED ADVERTISING  
Toll free: 888-498-1460  
E-mail: [sales@kerhgroup.com](mailto:sales@kerhgroup.com)

**Continuing Education**

Dr. Travel, LLC  
 In Partnership With The NJ Society of Optometric Physicians  
**New Year's Seminar Cruise**  
**Beverage Package Included**

**MSC Divina Sailing from Miami**  
 December 27, 2014 - January 3, 2015



New Deluxe Ship Special Group Pricing

16 CE

COPE  
 Dr. TRAVEL, LLC  
 is a COPE approved provider

Celebrating 20 years Continuing Education

**A Clinical Compendium - presented by Leo Semes, O.D., F.A.A.O.**

Additional Seminar Cruises (12-16 CE):  
 Bermuda Cruise from NYC - July 27, 2014 - Aug 3, 2014  
 President's Week Caribbean Cruise from Miami - February 14 - 21, 2015  
 4<sup>th</sup> Of July Week Baltic Sea Cruise from Copenhagen- June 26 - July 5, 2015:  
 - Imperatives in Primary Eye Care - Presented by Randall Thomas, O.D.  
**www.DrTravel.com 800-436-1028**

**Continuing Education**

**FOUNDATION FOR OCULAR HEALTH**

**19th Annual Key West Educational Conference**  
 August 8th & 9th, 2014

<p><b>FRIDAY, AUGUST 8, 2014</b>                  KEN LAWSON, O.D.                  Medicare Compliance-                  50 Shades of Questions (Part I)                  1 Hr CE</p> <p><b>APRIL JASPER, O.D.</b>                  Creating Distinction in Eye Care                  Through Dry Eye, Allergy and                  Glaucoma Treatment &amp; Protocols                  2 Hr CE/ITQ</p> <p><b>CARL SPEAR, O.D.</b>                  Grand Rounds in Anterior Segment Disease                  2 Hr CE/ITQ</p>	<p><b>SATURDAY, AUGUST 9, 2014</b>                  KEN LAWSON, O.D.                  Medicare Compliance-                  50 Shades of Questions (Part II)                  1 Hr CE</p> <p><b>MARK DUNBAR, O.D., FAAO</b>                  Understanding and Interpreting OCT                  2 Hr CE/ITQ</p> <p><b>MARK DUNBAR, O.D., FAAO</b>                  Clinical Decisions in Glaucoma                  2 Hr CE/ITQ</p>
--	---

**CASA MARINA**

THE WALDORF ASTORIA COLLECTION  
 1500 Reynolds Street  
 Key West, FL 33040  
 1.888.318.4237

For more information contact:  
 Gloria Ayan @ 786.405.9723  
 E-Mail: [ocularhealthfoundation@gmail.com](mailto:ocularhealthfoundation@gmail.com)

10 Hours 8 TQ

**Continuing Education**

**Medical Facility Optometrists**

The American Board of Certification in Medical Optometry is utilized at accredited medical facilities to verify specialist-level competence in medical optometry. ABCMO certifies specialized competence of a higher level than that required for licensure and general practice.

Visit [www.abcmo.org](http://www.abcmo.org) to learn why medical facilities require board certification of specialists and why only ABCMO board certification in the specialty of medical optometry is accepted. Questions? [myers.kenj@gmail.com](mailto:myers.kenj@gmail.com).

**NOTICE:** After August 1, 2003, all applicants for ABCMO board certification must have completed an ACOE residency in medical optometry and passed the Advanced Competence in Medical Optometry examination of the NBEO.

[www.abcmo.org](http://www.abcmo.org)



*Scientia est Potentia*

Contact us today for classified advertising:  
 Toll free: **888-498-1460**  
 E-mail: [sales@kerhgroup.com](mailto:sales@kerhgroup.com)

**Products and Services**

**ACCESS HEALTHCARE CAPITAL**

The key to making Professional Healthcare Practice Financing simple. Whether you are buying, starting, or updating your practice, Access Healthcare capital is here to help you with your financing needs with one common goal. We want to help you maximize your cash flow. Let us help you unleash your Entrepreneurial Spirit:

**Easy App Up To \$250,000**

- 100% Financing plus working capital
- Simplified Processing for loans up to \$350,000
- Partnership Buy-In Programs
- Terms up to 15 years
- Application Only for equipment and technology purchases

[www.accesshealthcarecapital.com](http://www.accesshealthcarecapital.com) • [info@narxeye.com](mailto:info@narxeye.com)

Access Healthcare Capital • 1-888-727-4470 • P.O. Box 349, Gladwyne, PA 19035

**Practice For Sale**

**PRACTICE SALES & APPRAISAL**

Expert Services for:

- ✓ **Buying or Selling a Practice**
- ✓ **Practice Appraisal**
- ✓ **Practice Financing**
- ✓ **Partner Buy-in or Buy-out**

Call for a Free Consultation  
**(800) 416-2055**

[www.TransitionConsultants.com](http://www.TransitionConsultants.com)

**Professional Opportunities**

**OPTOMETRISTS WANTED**

HealthDrive Eye Care Group provides optometric care to very deserving elderly patients residing in nursing homes and assisted living facilities. We currently have the following positions available:

**POSITION LOCATIONS AND DETAILS:**

**Location: Hartford, CT**

- Full-Time, 5 Days a Week
- Typical Hours: 8am or 9am to 3pm
- Full Benefits including Dental and 401K
- Full Malpractice Coverage
- Generous Six Figure Revenue Potential!!
- Requires EMR/EHR documentation
- Requires Glaucoma Certification

Join our practice and benefit from our management expertise and commitment to quality care.

Please contact Tanya Jones at **857-255-0293** or **tjones@healthdrive.com** if you are interested in hearing more about our opportunities.

*HealthDrive is an Equal Opportunity Employer.*

**Practice For Sale**



Practice Sales • Appraisals • Consulting  
[www.PracticeConsultants.com](http://www.PracticeConsultants.com)

**PRACTICES FOR SALE  
 NATIONWIDE**

Visit us on the Web or call us to learn more about our company and the practices we have available.

info@PracticeConsultants.com  
**800-576-6935**

[www.PracticeConsultants.com](http://www.PracticeConsultants.com)

Contact us today for classified advertising:  
 Toll free: **888-498-1460**  
 E-mail: [sales@kerhgroup.com](mailto:sales@kerhgroup.com)

**Professional Opportunities**



**EXCEPTIONAL OPPORTUNITIES**  
 Available for Doctors of Optometry

**AMERICA'S BEST**  
 CONTACTS & EYEGLASSES.

**EYEGLOSS WORLD®**

**Vision Center**

Brought to you by Walmart\*



**MORE THAN 750**  
**PRIME LOCATIONS**  
**IN OVER 43 STATES**

[www.NVIOPTOMETRY.COM](http://www.NVIOPTOMETRY.COM)



## Sealed for Your Protection

Post-cataract infection rates are up. Here's a new way to create watertight wounds.

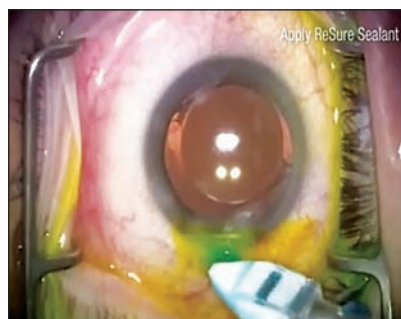The biggest success story in ophthalmic surgery has to be cataract extraction and IOL implantation. The procedure has evolved from the ancient (and rather barbaric) couching technique to a high-tech marvel that benefits millions today. Once considered major surgery, cataract extraction has become routine—banal, even.

Still, the procedure is *real* surgery, with all its attendant risks. Despite advancements in surgical technology, refinements of the procedure and the expanded skill-set of our surgeons, the most devastating and feared of all complications has actually increased in the last 20 years.

### Clear and Present Danger

The late 1990s saw a rise in endophthalmitis rates from 0.087% to 0.265% that corresponded with the popularization of sutureless clear corneal incisions.<sup>1</sup> This surgical technique is thought to give exogenous microorganisms easier access to the anterior chamber than scleral tunnel incisions.<sup>1</sup> Clear corneal incisions typically allow for quicker healing and more aesthetically pleasing postoperative eyes. The problem, however, is that even with good wound architecture, certain angles of pressure can open the wound with relative ease (as seen in the accompanying video). In cases of poor wound architecture or poor collagen synthesis, wound leakage is a much greater concern.

Wound leak with clear corneal incisions is usually not visible to the surgeon perioperatively because of a wound hydration technique that



Go to [www.revoptom.com](http://www.revoptom.com) or scan the QR code at left to see a video of the ReSure gel used for wound closure.

creates a temporary seal. The onset of clinically identifiable endophthalmitis is typically several days to a week after surgery—putting this devastating complication front and center for comanaging ODs, since most patients are seen only at one-day and one-week follow-ups.

Endophthalmitis—characterized by acute pain, photophobia, decreased vision, increased anterior chamber reaction, hypopyon and conjunctival injection—is immediately sight threatening and thus a time-sensitive emergency. Consultation with the surgeon should be made at the earliest suspicion of occurrence.

In 2005, Taban found a higher rate of endophthalmitis with use of clear corneal incisions (0.19%) vs. traditional scleral tunnel incisions (0.06% to 0.07%).<sup>2</sup> However, no prospective clinical trials have evaluated the risk associated with clear corneal incisions.<sup>2</sup> Although very rare, the serious nature and small but measurable increased frequency of this complication should keep every comanaging OD vigilant.

Surgeons can decrease the risk of communication between the intraocular space and surface microbes by using a temporary wound sealant after the surgery. In the video, ReSure Sealant (Ocular Therapeutix) is prepared and applied in approximately 20 seconds. It forms a gel in situ, protecting incisions in the immediate post-op period, when wounds are most vulnerable. The hydrogel material contains a blue visualization aid to assist with placement over the incision; it dissipates in a few hours. The hydrogel gradually sloughs off in the tears during reepithelialization, so there is no need for removal of the device.

In our experience this has been well tolerated by patients, with most feeling no different than others who did not experience the gel application. To date, we have yet to see any significant complications with the device. Although our patient volume is entirely too small to get a statistically significant sample size of efficacy, further surgical advancements like this should stem the increase of endophthalmitis cases, while affording our patients the quick, painless recovery they have become accustomed to.

The ReSure gel was just approved in January of this year, reminding us that even an ancient, near-perfect procedure like cataract surgery remains amenable to innovation. ■

1. Maalouf F, Abdulaal M, Hamam RN. Chronic postoperative endophthalmitis: a review of clinical characteristics, microbiology, treatment strategies, and outcomes. *Int. J. Inflamm.* 2012;313248.

2. Taban M, Behrens A, Newcomb RL et al. Acute endophthalmitis following cataract surgery: a systematic review of the literature. *Arch. Ophthalmol.* 2005;123(5):613-620.





The first optometrists in Mozambique graduated in 2013!

Photo credit: Mozambique Eyecare Project

## 2013 Project Highlights – Your Donations at Work!

With your help, Optometry Giving Sight was able to allocate \$1.6 million to 46 eye and vision care projects in 28 countries in 2013, impacting on tens of thousands of individuals.

Thank you for your support.

### Highlights:

- 34 students graduated from degree and diploma Optometry programs in Africa
- 12 Schools of Optometry received ongoing and new funding support\*
- 2,440 people were given direct training and skills development
- 139,450 children were screened as part of Child Eye Health Programs
- 44,268 people received direct access to eye and vision care

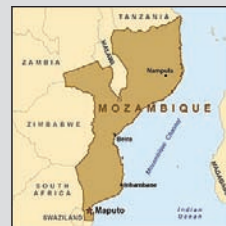\* Ongoing funding:



New schools:



Nine students graduated from Universidade Lúrio in Nampula in 2013, becoming the very first degree-qualified optometrists in Mozambique. Four of the graduates have been employed at the university and will become the first local members of staff.



Joel de Melo Bambamba graduated top of the class, he decided to study optometry because his grandfather was blind and his brother has serious vision impairment.



“I am very happy to have finished,” he said. “To have reached a dream of mine, and for my parents.”

Joel was also awarded the Jill and George Mertz Fellowship by the American Optometric Foundation and is currently studying for his Masters.

For more 2013 highlights, check the news story on our homepage, [givingsight.org](http://givingsight.org)



# OPTOMETRYGIVINGSIGHT

*Transforming lives through the gift of vision*



Watch Video

To donate visit [www.givingsight.org](http://www.givingsight.org) or call 888-OGS-GIVE



## A Rookie Mistake

By Andrew S. Gurwood, OD

### History

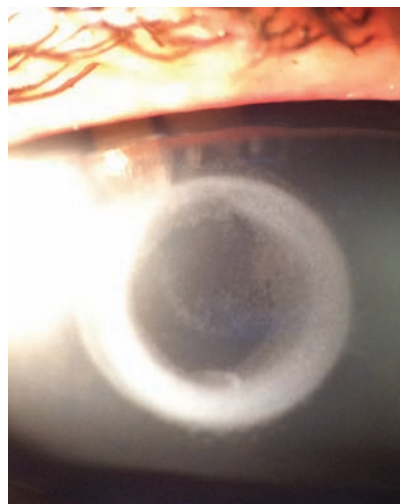
A 47-year-old black female presented for a routine eye examination. Her systemic history was unremarkable. She reported no known allergies of any kind.

### Diagnostic Data

Her best-corrected entering visual acuity measured 20/20 OU at distance and near. Her external examination was normal, with no evidence of afferent pupillary defect OU.

The biomicroscopic examination of the anterior segment was normal in both eyes.

Intraocular pressure measured 15mm Hg OU. We documented no



**Anterior segment image of our 47-year-old patient who presented for a routine exam. What is the correct diagnosis?**

peripheral pathologies in either eye. The pertinent clinical findings are illustrated in the photograph.

### Your Diagnosis

How would you approach this case? Does the patient require any additional tests? What is your diagnosis? How would you manage this patient? What is the likely prognosis?

To find out, please visit [www.revoptom.com](http://www.revoptom.com). Click on the cover icon for this month's issue, and then click "Diagnostic Quiz" under the table of contents. ■

*Thanks to Brendan Pancott, OD, of Philadelphia for his contributions to this case.*

**Retina Quiz Answers** (from page 78): 1) a; 2) d; 3) b; 4) d.

### Next Month in the Mag

June features our 5th Annual Retina Report.

Topics include:

- *Congenital Anomalies of the Posterior Segment*
- *Dry AMD Therapies in the Pipeline: Where Do They Stand?*
- *Learn to Recognize Macular Disease Earlier*
- *Anti-VEGF Drugs: Are Prescribing Habits, or Outcomes, Changing?*

Changing?

- *Optometric Study Center: Diagnosis and Management of VMI Disorders* (earn 2 CE credits)

Also Inside:

- *Femto Cataract Removal: How is it Faring With Surgeons?*
- *Give Your Instruments—and Office—This Tune-Up*

### And, Don't Miss:

- *Our 16th Edition of the Handbook of Ocular Disease Management* by Joseph W. Sowka, OD, Andrew S. Gurwood, OD, and Alan G. Kabat, OD.

- The latest issues of *Review of Cornea & Contact Lenses* and *Women in Optometry*.

### Feedback

*Review of Optometry* welcomes questions and comments. E-mail Jack Persico, editor-in-chief, [jpersico@jobson.com](mailto:jpersico@jobson.com), with "Letter to the Editor" as the subject line.

Or, write to *Review of Optometry*, 11 Campus Blvd., Suite 100, Newtown Square, PA 19073.

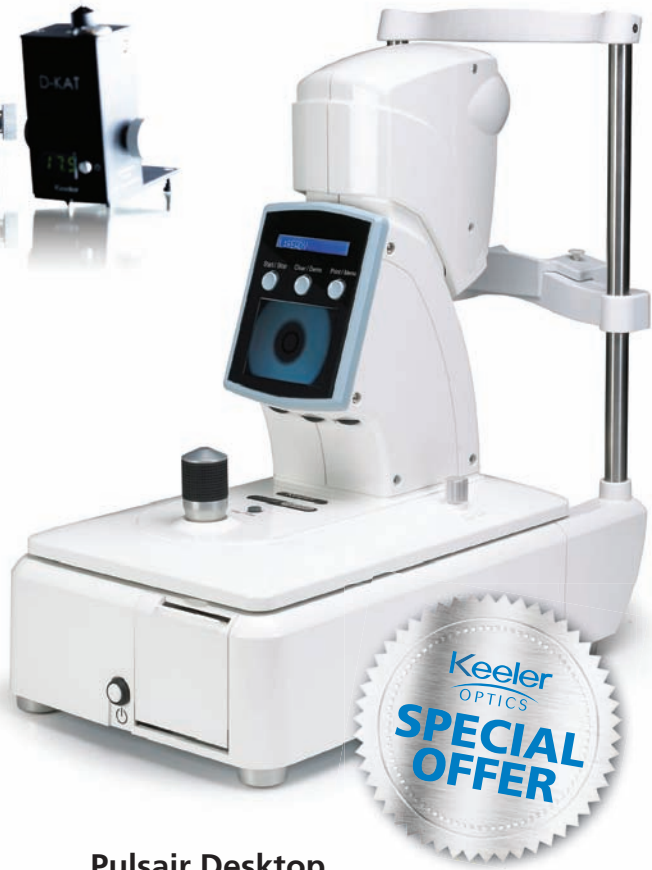REVIEW OF OPTOMETRY (ISSN 0147-7633) IS PUBLISHED MONTHLY, 12 TIMES A YEAR BY JOBSON MEDICAL INFORMATION LLC, 100 AVENUE OF THE AMERICAS, NEW YORK, NY 10013-1678. PERIODICALS POSTAGE PAID AT NEW YORK, NY AND ADDITIONAL MAILING OFFICES. POSTMASTER: SEND ADDRESS CHANGES TO REVIEW OF OPTOMETRY, PO BOX 2025, SKOKIE, IL 60076. SUBSCRIPTION PRICES: US: ONE YEAR \$56; TWO YEARS \$97, CANADA: ONE YEAR \$88, TWO YEARS \$160, INT'L: ONE YEAR \$209, TWO YEARS \$299. FOR SUBSCRIPTION INFORMATION CALL TOLL-FREE (877) 529-1746 (USA ONLY); OUTSIDE USA, CALL (847) 763-9630 OR FAX (847) 763-9631. PUBLICATIONS MAIL AGREEMENT NO: 40612608. CANADA RETURNS TO BE SENT TO BLEUCHIP INTERNATIONAL, P.O. BOX 25542, LONDON, ON N6C 6B2.

# Tonometry Done Right

**new**



**D-KAT Digital**  
Keeler quality.



**Pulsair Desktop**  
Smallest footprint and simple to use!

*Purchase a Pulsair Desktop  
by July 31, 2014 and get  
a \$1,300 Instant Rebate!*

**Intellipuff**  
The standard for hand held mobility.

Buy Online!  
[keelerusa.com](http://keelerusa.com)



**Keeler**  
OPTICS

PERMANENT PLASMA |  
SURFACE TECHNOLOGY |

# THIS IS WHY the smallest details make the biggest difference in patients' comfort.

AIR OPTIX® AQUA contact lenses feature our unique permanent plasma treatment, creating a hydrophilic layer that leaves **less than 1% surface silicon**<sup>1</sup>. Less silicon helps to resist lipid deposits, which can reduce lens comfort. Now your patients can experience **consistent comfort from day 1 to day 30**<sup>2</sup>.

## Permanent Plasma Surface Technology



Ask your sales representative about AIR OPTIX® family of contact lenses or visit MYALCON.COM

PERFORMANCE DRIVEN BY SCIENCE™



\*AIR OPTIX® AQUA (lotrafilcon B) and AIR OPTIX® AQUA Multifocal (lotrafilcon B) contact lenses: Dk/t = 138 @ -3.00D. AIR OPTIX® NIGHT & DAY® AQUA (lotrafilcon A) contact lenses: Dk/t = 175 @ -3.00D. AIR OPTIX® for Astigmatism (lotrafilcon B) contact lenses: Dk/t = 108 @ -3.00D -1.25 x 180.

**Important information for AIR OPTIX® AQUA (lotrafilcon B), AIR OPTIX® AQUA Multifocal (lotrafilcon B) and AIR OPTIX® for Astigmatism (lotrafilcon B) contact lenses:** For daily wear or extended wear up to 6 nights for near/far-sightedness, presbyopia and/or astigmatism. Risk of serious eye problems (i.e., corneal ulcer) is greater for extended wear. In rare cases, loss of vision may result. Side effects like discomfort, mild burning or stinging may occur.

**Important information for AIR OPTIX® NIGHT & DAY® AQUA (lotrafilcon A) contact lenses:** Indicated for vision correction for daily wear (worn only while awake) or extended wear (worn while awake and asleep) for up to 30 nights. **Relevant Warnings:** A corneal ulcer may develop rapidly and cause eye pain, redness or blurry vision as it progresses. If left untreated, a scar, and in rare cases loss of vision, may result. The risk of serious problems is greater for extended wear vs. daily wear and smoking increases this risk. A one-year post-market study found 0.18% (18 out of 10,000) of wearers developed a severe corneal infection, with 0.04% (4 out of 10,000) of wearers experiencing a permanent reduction in vision by two or more rows of letters on an eye chart. **Relevant Precautions:** Not everyone can wear for 30 nights. Approximately 80% of wearers can wear the lenses for extended wear. About two-thirds of wearers achieve the full 30 nights continuous wear. **Side Effects:** In clinical trials, approximately 3-5% of wearers experience at least one episode of infiltrative keratitis, a localized inflammation of the cornea which may be accompanied by mild to severe pain and may require the use of antibiotic eye drops for up to one week. Other less serious side effects were conjunctivitis, lid irritation or lens discomfort including dryness, mild burning or stinging. **Contraindications:** Contact lenses should not be worn if you have: eye infection or inflammation (redness and/or swelling); eye disease, injury or dryness that interferes with contact lens wear; systemic disease that may be affected by or impact lens wear; certain allergic conditions or using certain medications (ex. some eye medications). **Additional Information:** Lenses should be replaced every month. If removed before then, lenses should be cleaned and disinfected before wearing again. Always follow the eye care professional's recommended lens wear, care and replacement schedule. Consult package insert for complete information, available without charge by calling (800) 241-5999 or go to myalcon.com.

**Alcon**  
a Novartis company

**References:** 1. Alcon data on file, 2011. 2. Eiden SB, Davis R, Bergenske P. Prospective study of lotrafilcon B lenses comparing 2 week versus 4 weeks of wear for objective and subjective measures of health, comfort and vision. Eye & Contact Lens. 2013; 39(4):290-294.

See product instructions for complete wear, care, and safety information. © 2014 Novartis 1/14 AOA14005JAD