

# REVIEW<sup>®</sup> of OPTOMETRY

May 15, 2024 • reviewofoptometry.com

Leadership in clinical care

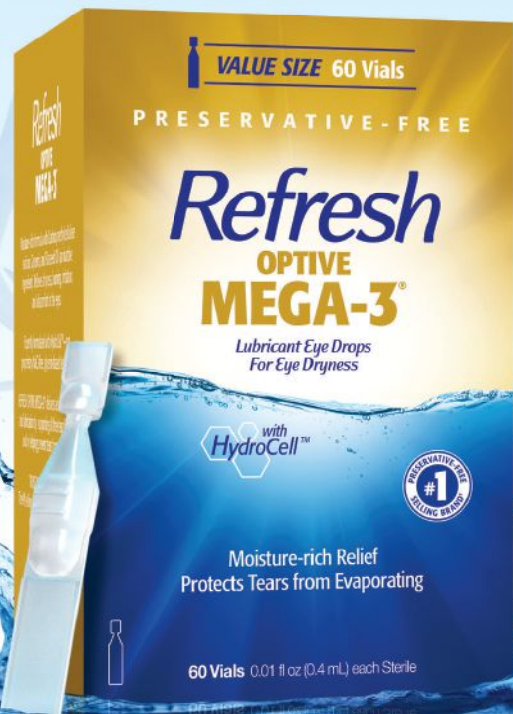EARN 2 CE CREDITS  
Ocular Manifestations of  
Autoimmune Diseases  
PAGE 72

25TH ANNUAL DRY EYE REPORT

## ALL EYES ON OMEGAS

Despite some controversy,  
OFAs continue to play a role in the mitigation of dry eye. PAGE 64

# EVAPORATIVE DRY EYES? LOOK TO MEGA-3



RELIEF FOR DRY EYES THAT  
MAY BE DUE TO MGD



Stabilizes the tear film



Fortifies the lipid layer



Includes Flaxseed Oil<sup>†</sup>  
and antioxidants<sup>†</sup>

[refresheyedrops.com/doc](https://www.refresheyedrops.com/doc)

abbvie



The Five-Minute Peds Exam, p. 36 • Glaucoma: Improving the Patient Experience, p. 42

# REVIEW<sup>®</sup> *of* OPTOMETRY

May 15, 2024 • reviewofoptometry.com

Leadership in clinical care

EARN 2 CE CREDITS

Ocular Manifestations of  
Autoimmune Diseases

PAGE 72

25TH ANNUAL DRY EYE REPORT

## ALL EYES ON OMEGAS

Despite some controversy,  
OFAs continue to play a role in the mitigation of dry eye. PAGE 64

PLUS:

*An Action Plan for Managing Dry Eye*, PAGE 50

*Dry Eye: Matching Patients and Treatments*, PAGE 58

REVIEW OF OPTOMETRY • VOL. 161, NO. 5 • MAY 15, 2024 • An Action Plan For Managing Dry Eye • Dry Eye: Matching Patients and Treatments • OFAs in Dry Eye Therapy • Speedy Pediatric Exams • Glaucoma Patient Experience • Autoimmune Diseases and the Eye

IYUZEH™ (latanoprost ophthalmic solution) 0.005% is the first and only preservative-free latanoprost for patients with open-angle glaucoma (OAG) and ocular hypertension (OHT).

**iyuzeh**™  
(latanoprost ophthalmic solution) 0.005%



Transform how you lower IOP.

**POWER  
WITHOUT  
PRESERVATIVES.**



*Having the opportunity to prescribe IYUZEH for my patients is a game-changer. With IYUZEH, I can confidently prescribe an efficacious treatment to help lower IOP without preservatives.*



**Michael Chaglasian, OD, FAAO**

*Dr. Chaglasian is a paid consultant of Thea Pharma Inc.*



## INDICATIONS AND USAGE

IYUZEH™ (latanoprost ophthalmic solution) 0.005% is a prostaglandin F2a analogue indicated for the reduction of elevated intraocular pressure in patients with open-angle glaucoma or ocular hypertension.

## IMPORTANT SAFETY INFORMATION

### CONTRAINDICATIONS

Known hypersensitivity to latanoprost or any other ingredients in this product.

### WARNINGS AND PRECAUTIONS

IYUZEH may cause changes to pigmented tissues. Most frequently reported changes are increased pigmentation of the iris, periorbital tissue (eyelid), and eyelashes. Pigmentation is expected to increase as long as IYUZEH is administered. Iris pigmentation is likely to be permanent. Eyelid skin darkening and eyelash changes may be reversible.

IYUZEH may cause gradual change to eyelashes including increased length, thickness, and number of lashes. These changes are usually reversible upon discontinuation of treatment.

IYUZEH should be used with caution in patients with a history of intraocular inflammation (iritis/uveitis) and should generally not be used in patients with active intraocular inflammation.

IYUZEH should be used with caution in aphakic patients, in pseudophakic patients with a torn posterior lens capsule, or in patients with known risk factors for macular edema.

Reactivation of herpes simplex keratitis has been reported during treatment with latanoprost. IYUZEH should be used with caution in patients with a history of herpetic keratitis.

Contact lenses should be removed prior to the administration of IYUZEH and may be reinserted 15 minutes after administration.

### ADVERSE REACTIONS


The most common adverse reactions (5% to 35%) for IYUZEH are: conjunctival hyperemia, eye irritation, eye pruritus, abnormal sensation in eye, foreign body sensation in eyes, vision blurred, and lacrimation increased.

### DRUG INTERACTIONS

The combined use of two or more prostaglandins or prostaglandin analogs including IYUZEH is not recommended. It has been shown that administration of these prostaglandin drug products more than once daily may decrease the IOP lowering effect or cause paradoxical elevations in IOP.

**Please see full Prescribing Information at [www.iyuzeh.com](http://www.iyuzeh.com) and Brief Summary on the next page.**

Explore the power of preservative-free latanoprost at [iyuzeh.com](http://iyuzeh.com)



**Théa**  
let's open our eyes

IYUZEH is a trademark of Laboratoires Théa.  
Copyright ©2024 Thea Pharma Inc. | All Rights Reserved. | PRC-IYZ-1953-v1 03.2024

# iyuzeh™

(latanoprost ophthalmic solution) 0.005%

## HIGHLIGHTS OF PRESCRIBING INFORMATION

This brief summary does not include all the information needed to use IYUZEH safely and effectively. See full prescribing information for IYUZEH.

Initial U.S. Approval: 2022

### INDICATIONS AND USAGE

IYUZEH is a prostaglandin F<sub>2α</sub> analogue indicated for the reduction of elevated intraocular pressure in patients with open-angle glaucoma or ocular hypertension.

### CONTRAINDICATIONS

Known hypersensitivity to latanoprost or any other ingredients in this product.

### WARNINGS AND PRECAUTIONS

**Pigmentation:** Topical latanoprost ophthalmic products, including IYUZEH have been reported to cause changes to pigmented tissues. The most frequently reported changes have been increased pigmentation of the iris, periorbital tissue (eyelid), and eyelashes. Pigmentation is expected to increase as long as latanoprost is administered.

The pigmentation change is due to increased melanin content in the melanocytes rather than to an increase in the number of melanocytes. After discontinuation of latanoprost, pigmentation of the iris is likely to be permanent, while pigmentation of the periorbital tissue and eyelash changes have been reported to be reversible in some patients. Patients who receive treatment should be informed of the possibility of increased pigmentation. The long-term effects of increased pigmentation are not known.

Iris color change may not be noticeable for several months to years. Typically, the brown pigmentation around the pupil spreads concentrically towards the periphery of the iris and the entire iris or parts of the iris become more brownish. Neither nevi nor freckles of the iris appear to be affected by treatment. While treatment with IYUZEH can be continued in patients who develop noticeably increased iris pigmentation, these patients should be examined regularly.

**Eyelash Changes:** Latanoprost ophthalmic products, including IYUZEH may gradually change eyelashes and vellus hair in the treated eye; these changes include increased length, thickness, pigmentation, the number of lashes or hairs, and misdirected growth of eyelashes. Eyelash changes are usually reversible upon discontinuation of treatment.

**Intraocular Inflammation:** IYUZEH should be used with caution in patients with a history of intraocular inflammation (iritis/uveitis) and should generally not be used in patients with active intraocular inflammation because inflammation may be exacerbated.

**Macular Edema:** Macular edema, including cystoid macular edema, has been reported during treatment with latanoprost ophthalmic products, including IYUZEH. IYUZEH should be used with caution in aphakic patients, pseudophakic patients with a torn posterior lens capsule, or in patients with known risk factors for macular edema.

**Herpetic Keratitis:** Reactivation of herpes simplex keratitis has been reported during treatment with latanoprost. IYUZEH should be used with caution in patients with a history of herpetic keratitis and should be avoided in cases of active herpes simplex keratitis because inflammation may be exacerbated.

**Contact Lens Use:** Contact lenses should be removed prior to the administration of IYUZEH and may be reinserted 15 minutes after administration.

### ADVERSE REACTIONS

The following adverse reactions have been reported with the use of topical latanoprost products and are discussed in greater detail in the prescribing information:

- Iris pigmentation changes
- Eyelid skin darkening
- Eyelash changes (increased length, thickness, pigmentation, and number of lashes)
- Intraocular inflammation (iritis/uveitis)
- Macular edema, including cystoid macular edema

Because clinical trials are conducted under widely varying conditions, adverse reaction rates observed in the clinical trials of a drug cannot be directly compared to rates in the clinical trials of another drug and may not reflect the rates observed in practice.

In the two clinical trials conducted with IYUZEH (latanoprost ophthalmic solution) 0.005% comparing it to XALATAN the preserved 0.005% latanoprost reference product, the most frequently reported ocular adverse reactions were conjunctival hyperemia and eye irritation (Table 1).

Table 1. Adverse Reactions

Symptom/Finding	Adverse Reactions [n (%)]	
	IYUZEH (n=378)	XALATAN (n=358)
Conjunctival hyperemia	129 (34)	133 (37)
Eye irritation	72 (19)	112 (31)
Eye pruritus	57 (15)	58 (16)
Abnormal sensation in eyes	51 (14)	52 (15)
Foreign body sensation in eyes	44 (12)	36 (10)
Vision blurred	28 (7)	30 (8)
Lacrimation increased	19 (5)	14 (4)
Photophobia	13 (3)	17 (5)

### POSTMARKETING EXPERIENCE

The following adverse reactions have been identified during post-approval use of topical latanoprost products. Because these reactions are reported voluntarily from a population of uncertain size, it is not always possible to reliably estimate their frequency or establish a causal relationship to drug exposure. The reactions, which have been chosen for inclusion due to either their seriousness, frequency of reporting, possible causal connection to ophthalmic latanoprost products, or a combination of these factors, include:

- Nervous System Disorders: Dizziness; headache; toxic epidermal necrolysis
- Eye Disorders: Eyelash and vellus hair changes of the eyelid (increased length, thickness, pigmentation, and number of eyelashes); keratitis; corneal edema and erosions; intraocular inflammation (iritis/uveitis); macular edema, including cystoid macular edema; trichiasis; periorbital and lid changes resulting in deepening of the eyelid sulcus; iris cyst; eyelid skin darkening; localized skin reaction on the eyelids; conjunctivitis; pseudopemphigoid of the ocular conjunctiva.
- Respiratory, Thoracic and Mediastinal Disorders: Asthma and exacerbation of asthma; dyspnea
- Skin and Subcutaneous Tissue Disorders: Pruritus
- Infections and Infestations: Herpes keratitis
- Cardiac Disorders: Angina; palpitations; angina unstable
- General Disorders and Administration Site Conditions: Chest pain

### DRUG INTERACTIONS

The combined use of two or more prostaglandins, or prostaglandin analogs including IYUZEH is not recommended, and administration of these prostaglandin drug products more than once daily may decrease the IOP lowering effect or cause paradoxical IOP elevations.

### USE IN SPECIFIC POPULATIONS

**Pregnancy:** There are no adequate and well-controlled studies of IYUZEH administration in pregnant women to inform drug-associated risks.

**Lactation:** It is not known whether this drug or its metabolites are excreted in human milk. Because many drugs are excreted in human milk, caution should be exercised when IYUZEH is administered to a nursing woman. The developmental and health benefits of breastfeeding should be considered along with the mother's clinical need for IYUZEH and any potential adverse effects on the breastfed child from IYUZEH.

**Pediatric Use:** The safety and effectiveness of IYUZEH have not been established in pediatric patients.

**Geriatric Use:** No overall differences in the safety or effectiveness of IYUZEH have been observed between elderly and younger adult patients.

### OVERDOSAGE

Intravenous infusion of up to 3 mcg/kg of latanoprost in healthy volunteers produced mean plasma concentrations 200 times higher than during clinical treatment with latanoprost ophthalmic solution and no adverse reactions were observed. IV dosages of 5.5 to 10 mcg/kg caused abdominal pain, dizziness, fatigue, hot flushes, nausea, and sweating.

### HANDLING THE CONTAINER

IYUZEH is a sterile solution that does not contain a preservative supplied in a single-dose container. The solution from one individual container is to be used immediately after opening for administration to one or both eyes. Since sterility cannot be maintained after the individual container is opened, the remaining contents should be discarded immediately after administration. Open a new single-dose container every time you use IYUZEH.

Manufactured for: Thea Pharma Inc. Waltham, MA.

All rights reserved.

U.S. Patent N<sup>o</sup>. 8,637,054.

Revised: 04/2023

©2021 Laboratoires Théa. All Rights Reserved. IYUZEH™ is a trademark of Laboratoires Théa.



## Meds that Induce Angle-Closure Glaucoma Identified

*Topiramate tops the list for specific agents, while sulfonamides was the largest drug class overall.*

Many medical treatments can induce angle-closure in susceptible patients, mainly through pupil dilation or anterior displacement of the lens-iris diaphragm. Medications used for weight loss, epilepsy and over-the-counter cold treatments, among others, are known to induce angle-closure glaucoma. As angle-closure constitutes an ophthalmic emergency with the potential for blindness, it is key to recognize medications associated with this condition. Researchers at the Rutgers New Jersey Medical School in Newark, NJ, used a pharmacovigilance database to identify and quantify the significance of drug-induced angle-closure glaucoma at a national level. Their retrospective analysis, published in *Ophthalmology Glaucoma*, identified positive safety signals for both well-known drugs such as topiramate, escitalopram and tiotropium, as well as lesser-known drugs such as olanzapine, phentermine and ranibizumab.

The study used data from the FDA Adverse Event Reporting System and identified a total of 1,629 adverse event reports linked to 611 suspected drugs over the course of 20 years. To determine if these reports yielded statistically significant signals, the researchers used the proportional reporting ratio, reporting odds ratio, empirical Bayes geometric mean and information component as part of a disproportionality analysis. A signal was detected when all four disproportionality analysis metrics were positive. The cohort of angle-closure glaucoma cases demonstrated that the most common age

group was patients between the ages of 40 and 65. The cohort included more women (66.1%) than men. On average, patients were exposed to 3.09 medications prior to the adverse event (a total of 5,035 drug entries were associated with the 1,629 cases).

Frequently reported drugs included topiramate (520 reports) and citalopram (69 reports), amongst many others. The study found that several medications yielded a positive signal, including ones with lesser-known associations like olanzapine, phentermine and ranibizumab. It did not observe notable reports for metoclopramide or lactulose. Tropicamide exhibited the most robust statistical significance, while acetazolamide was the second strongest.

The most frequently reported drug category was sulfonamides (642 reports), though the majority of reports in this category came from topiramate. Serotonergic agents were the second-most commonly reported class of drugs, with 318 reports.

“Sympathomimetic agents, anticholinergic agents and serotonergic agents can induce pupillary dilation and block, leading to acute angle closure by inducing constriction of the iris dilator muscles,” the researchers wrote in their paper. “This may induce acute angle closure in patients by thickening the base of the iris, resulting in iridotrabecular adhesions, or by bringing the lens in close proximity to the iris in mid-dilation.”

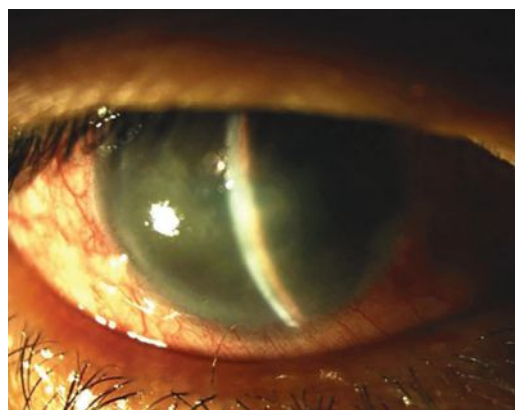

Photo: Joseph W. Sowka, OD

**Understanding the mechanisms, risks and management of drug-induced angle-closure glaucoma is vital for patient safety.**

The researchers highlighted that olanzapine exerted its effects through a combination of dopamine, serotonin, histamine and adrenergic antagonism, accompanied by a mild anticholinergic impact. They believed that it may be fruitful to further explore medications exhibiting mild anticholinergic effects and evaluate whether these pharmacological agents have the potential to trigger or worsen angle-closure glaucoma.

“It is crucial to recognize preventable causes like medications that have the potential to induce angle closure,” the team wrote. “As these therapy options play a pivotal role in various therapeutic interventions, understanding the mechanisms, risks and management of drug-induced angle-closure glaucoma is vital for patient safety.” ◀

Aftab OM, Khan H, Khouri AS. Blind spots in therapy: unveiling drug-induced angle-closure glaucoma through a national analysis. *Ophthalmol Glaucoma*. April 26, 2024. [Epub ahead of print].

# Could it be KC (KERATOCONUS)?

## KC File #2: Autorefractor Clues That Were Ignored

**Susan J. “Super Sleuth” Gromacki, OD, MS, FAAO, FSLs**, First Sight Vision Care  
Dr. Gromacki is a paid consultant for Glaukos.



A young woman who had relocated to my area for her first job after college was referred to me by the hometown optometrist who had seen her regularly since childhood. She was a high myope, wearing a spectacle prescription of -4.75 sphere OD and -9.25 -1.25 x003 OS.

The optometrist’s records showed a slow but steady decline in best-corrected visual acuity (BCVA). This went unremarked until 2022, when the patient’s OS could not be corrected even to 20/30. At that point, she was referred to a retina specialist, who ruled out a suspected epiretinal membrane and reported other findings all within normal limits.

In retrospect, there were three clues that could have alerted the practitioner to the possibility of keratoconus. First, when a young person can’t be corrected to 20/20, the cornea is a more likely culprit than the retina. The patient’s vision in the left eye hadn’t been a sharp 20/20 for several years. Secondly, an increase of 0.5 D of astigmatism between annual visits is a significant red flag. And finally, another clue came from the simplest diagnostic tool in the office—the autorefractor. The autorefraction in 2022 showed 2.75 D of astigmatism—a full diopter more than the spectacle prescription—and the quality score was only 8 out of 10. I would expect it to be 10/10 in a healthy young person.

A history of “lazy eye” as a child may be why the declining BCVA in her left eye was not taken very seriously at first. This was noted in her chart, although there was no evidence of binocular vision testing, no mention of exophoria or esophoria, and she didn’t have the typical hyperopic refraction we usually see in a lazy eye. Sometimes practitioners label a worse-seeing eye as a “lazy eye.” While this certainly may be the case, that label threw off her long-time optometrist. The clues could have led the optometrist to a KC diagnosis.

In 2023, when I first saw this patient, corneal topography showed 2.80 D of astigmatism OS with a classic pattern of inferior steepening that is pathognomonic for progressive KC. She was treated with iLink® corneal cross-linking in the left eye and we continue to follow her right eye closely because KC is a bilateral, asymmetric, disease. Recently the patient shared with me that her uncle has KC, something she didn’t know when I asked her initially.

**By following the KC clues that are hiding in plain sight, you can help patients like this one avoid years of declining vision—and sleuth out the right specialists to treat the underlying progressive condition that is stealing her sight. Visit [iDetectives.com](https://www.idetectives.com) to learn more.**

### #FollowTheClues



**INDICATIONS** Photrexa® Viscous (riboflavin 5'-phosphate in 20% dextran ophthalmic solution) and Photrexa® (riboflavin 5'-phosphate ophthalmic solution) are indicated for use with the KXL System in corneal collagen cross-linking for the treatment of progressive keratoconus and corneal ectasia following refractive surgery.

**IMPORTANT SAFETY INFORMATION** Corneal collagen cross-linking should not be performed on pregnant women. Ulcerative keratitis can occur. Patients should be monitored for resolution of epithelial defects. The most common ocular adverse reaction was corneal opacity (haze). Other ocular side effects include punctate keratitis, corneal striae, dry eye, corneal epithelium defect, eye pain, light sensitivity, reduced visual acuity, and blurred vision. These are not all of the side effects of the corneal collagen cross-linking treatment. For more information, go to [www.livingwithkeratoconus.com](http://www.livingwithkeratoconus.com) to obtain the FDA-approved product labeling.

You are encouraged to report all side effects to the FDA. Visit [www.fda.gov/medwatch](http://www.fda.gov/medwatch), or call 1-800-FDA-1088.



SPONSORED AND SUPPLIED BY GLAUKOS

© 2024 Glaukos PM-US-1824 Rev.2

### KC File #2: **THE CLUES**

- A surprising autorefraction with a low reliability score
- History of “lazy eye”
- Doesn’t correct to 20/20
- 0.5 D increase in astigmatism in 1 year

### Changing refractive astigmatism and vision:

YEAR	DC	BCVA
2014	1.00	20/20
2015	1.25	20/20
2017	1.25	20/20
2018	1.25	20/20-1
2019	1.25	20/25
2021	1.25	20/20-2
2022	1.75	20/30-1
2023	2.25	20/30



**iDetective**  
Following the clues  
for early KC detection

# Uveitis Recurrence Risk Elevated After COVID-19 Vaccine

*More than half of cases occurred in the early post-vaccination period, suggesting close clinical monitoring is essential for at-risk patients.*

The deployment of COVID-19 vaccines across the world made an undeniable positive impact on the spread and severity of symptoms, yet the further we get from that initial rollout, the more we're learning about the vaccines' short- and long-term effects in special patient populations. Although rare, ocular adverse events have been reported, including facial nerve palsy, uveitis and retinal vascular occlusion. Further research is warranted to determine if these events could be associated with other factors, and if vaccine type or dosing are contributing factors.

An investigation into non-infectious uveitis in particular, published in *JAMA Ophthalmology*, looked at the incidence and risk of post-vaccination uveitis in individuals with a history of the disease. The retrospective population-based cohort study included 473,934 patients from both the Korean National Health Insurance Service and Korea Disease Control and Prevention Agency databases who had a history of uveitis and documented at least one dose of COVID-19 vaccination, including a messenger RNA (Pfizer-BioNTech, Moderna) or adenovirus vector-based (AstraZeneca, Janssen). The cumulative incidence of post-vaccination uveitis was 8.6% at three months, 12.5% at six months and 16.8% at one year, predominantly of the anterior type.

The risk of early post-vaccination uveitis was increased for individuals receiving all four vaccines, with hazard ratios (HRs) at the following levels: Pfizer 1.68 HR, Moderna 1.51 HR, AstraZeneca 1.60 HR and Janssen 2.07 HR. The risk of uveitis was higher particularly between the first and second vaccination doses (1.64 HR). There was also a higher risk of uveitis for individuals with systemic disease but

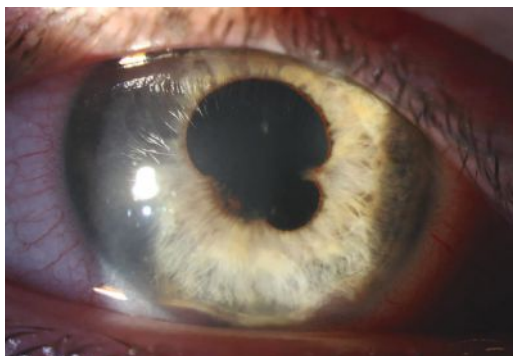


Photo: Aaron Bonner, MD

**A study published in *JAMA Ophthalmology* investigated nearly 500,000 South Korean patients with a history of uveitis and a record of COVID-19 vaccination and found an increased risk of disease recurrence, especially in the time period between the first and second dose.**

only during the early post-vaccination period.

The authors said this study answers several clinical questions. First, the discovery that more than half of the incidents occurred during the early period and the observed higher hazard ratios during this time period signifies an increased risk within the initial 30 days after vaccination. "The close temporal relationship between COVID-19 vaccination and incidence of uveitis supports their association," they wrote.

They also found the risk was higher between the first and second doses but decreased following subsequent vaccinations. "The increased immune response after the initial dose might activate inflammatory pathways, resulting in conditions like uveitis, particularly in individuals prone to autoimmune reactions with a uveitis history," stated the authors in their paper. "We hypothesize that the decline in risk with subsequent doses may stem from the immune system adapting to the vaccine antigen, resulting in a more controlled immune response that mitigates inflammatory side effects, a possibility that should be validated by future studies."

The Pfizer vaccine exhibited a greater risk in the post-vaccination period compared with others, followed by Moderna and Janssen. Precisely why remains unclear, the researchers say; "however, our data may be helpful in estimating the risk of post-vaccination uveitis for each vaccine and assisting clinical decision making regarding the choice of COVID-19 vaccines in patients with a history of uveitis."

The study may be limited by reliance on data from the Korean NHIS database, which may suffer from underreporting or misclassification bias, they continued. "Influence of medications used during

both the pre-vaccination and post-vaccination periods remains an important consideration, as anti-inflammatory medications may decrease the rate of post-vaccination uveitis," they added.<sup>1</sup>

A commentary also published in *JAMA Ophthalmology* expanded on the original study's limitations, namely the reliance on diagnostic coding for its outcome definition. "Additionally, the study did not account for the healthy vaccine bias, which refers to how individuals in better health are more likely to receive vaccinations," they wrote.

"Nonetheless, the utility of these population-based vaccine association study designs is broad, as they can be translated to investigations of virtually any adverse event after any vaccination, provided outcome and vaccine classifications can be appropriately indexed in a database." The commentary concluded, "These studies are foundational in helping to guide clinical decisions relating to post-vaccine monitoring, counseling, and risk mitigation."<sup>2</sup> ◀

1. Kim J, Kwon HY, Ahn SJ. COVID-19 vaccine-associated uveitis in patients with a history of uveitis. *JAMA Ophthalmol*. April 25, 2024. [Epub ahead of print].

2. Kumar A, Acharya NR. Real-world vaccine research and clinical practice. *JAMA Ophthalmol*. April 25, 2024. [Epub ahead of print].



# veveye™

(cyclosporine ophthalmic solution) 0.1%

## NOW AVAILABLE!

## A Different Cyclosporine

VEVYE® (cyclosporine ophthalmic solution) 0.1% is the first and only water-free cyclosporine dissolved in a semifluorinated alkane (perfluorobutylpentane) approved to treat both the signs and symptoms of dry eye disease.<sup>1-3</sup>

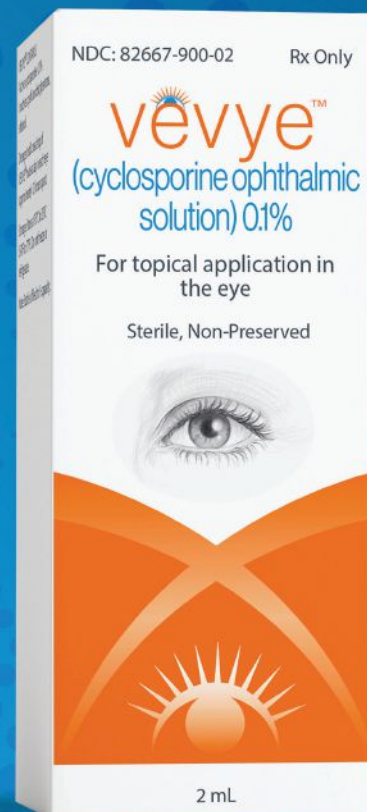
In clinical studies,

- Over 50% of patients had 3 grades of total corneal fluorescein staining improvement at Day 15\*<sup>4</sup>
- 72% of patients showed at least 3 grades of improvement in corneal staining at day 29\*<sup>4</sup>
- 99.8% of patients experienced no or mild instillation site irritation\*<sup>4</sup>
- VEVYE provided sustained improvement over 12 months\*\*<sup>4</sup>

\* A Phase 3, multi-center, randomized, double-masked, vehicle-controlled clinical trial

\*\* An open-label, single-arm, extension study

Scan or visit [veveye.com](http://veveye.com) to learn more or request FREE samples



**INDICATION AND USAGE:** VEVYE (cyclosporine ophthalmic solution) 0.1% is indicated for the treatment of the signs and symptoms of dry eye disease.

### IMPORTANT SAFETY INFORMATION

#### Warnings and Precautions

- **Potential for Eye Injury and Contamination** – To avoid the potential for eye injury and/or contamination, patients should not touch the bottle tip to the eye or other surfaces.
- **Use with Contact Lenses** – VEVYE should not be administered while wearing contact lenses. If contact lenses are worn, they should be removed prior to administration of the solution. Lenses may be reinserted 15 minutes following the administration of VEVYE.

#### Adverse Reactions

In clinical trials with 738 subjects receiving at least 1 dose of VEVYE, the most common adverse reactions were instillation site reactions (8%) and temporary decreases in visual acuity (3%).

You are encouraged to report negative side effects of prescription drugs to the FDA. Visit [www.fda.gov/medwatch](http://www.fda.gov/medwatch), or call 1-800-FDA-1088.

**For additional information about VEVYE, please see Brief Summary on adjacent page and Full Prescribing Information at [veveye.com](http://veveye.com).**

References: 1. Vevye (cyclosporine ophthalmic solution) 0.1% [package insert]. Harrow IP, LLC; 2023. 2. Cequa (cyclosporine ophthalmic solution) .09% [package insert]. Sun Ophthalmics, LLC; 2023. 3. Restasis (cyclosporine ophthalmic emulsion) 0.05% [package insert]. Allergan, LLC; 2023. 4. Data on file. Vevye and the Vevye logo are trademarks of Novaliq GmbH.

Harrow and the Harrow logo are registered trademarks of Harrow IP, LLC. ©2023 Harrow. All Rights Reserved. VYE-00051 01/24



# vevye™

(cyclosporine ophthalmic solution) 0.1%

## BRIEF SUMMARY – PLEASE SEE THE VEVYE® PACKAGE INSERT FOR FULL PRESCRIBING INFORMATION

### INDICATIONS AND USAGE:

VEVYE® (cyclosporine ophthalmic solution) 0.1% is indicated for the treatment of the signs and symptoms of dry eye disease.

### DOSAGE AND ADMINISTRATION:

Instill one drop of VEVYE® twice a day in each eye approximately 12 hours apart.

### WARNINGS AND PRECAUTIONS

- **Potential for Eye Injury and Contamination** – To avoid the potential for eye injury and/or contamination, patients should not touch the bottle tip to the eye or other surfaces.
- **Use with Contact Lenses** – VEVYE® should not be administered while wearing contact lenses. If contact lenses are worn, they should be removed prior to administration of the solution. Lenses may be reinserted 15 minutes following the administration of VEVYE®.

### ADVERSE REACTIONS

**Clinical Trial Experience** – Because clinical trials are conducted under widely varying conditions, adverse reaction rates observed in the clinical trials of a drug cannot be directly compared to rates in the clinical trials of another drug and may not reflect the rates observed in practice.

In clinical trials with 738 subjects receiving at least 1 dose of VEVYE®, the most common adverse reactions were instillation site reactions (8%) and temporary decreases in visual acuity (3%).

### USE IN SPECIFIC POPULATIONS

#### PREGNANCY

##### Risk Summary

There are no adequate and well-controlled studies of VEVYE® administration in pregnant women to inform a drug-associated risk. Oral administration of cyclosporine to pregnant rats or rabbits did not produce teratogenicity at clinically relevant doses. VEVYE® doses are approximately 4,700 times lower than recommended oral doses, with blood concentrations being undetectable after topical administration.

##### Data

*Animal Data:* Oral administration of cyclosporine oral solution to pregnant rats or rabbits was teratogenic at maternally toxic doses of 30 mg/kg/day in rats and 100 mg/kg/day in rabbits, as indicated by increased pre- and postnatal mortality, reduced fetal weight and skeletal retardations. These doses (normalized to body weight) were approximately 7,250 and 48,000 times higher than the daily maximum recommended human ophthalmic dose (MRHOD) of 0.67 mcg/kg/day, respectively.

No adverse embryofetal effects were observed in rats or rabbits receiving cyclosporine during organogenesis at oral doses up to 17 mg/kg/day or 30 mg/kg/day, respectively (approximately 4,100 and 14,500 times higher than the MRHOD, respectively).

An oral dose of 45 mg/kg/day cyclosporine (approximately 10,900 times higher than MRHOD) administered to rats from Day 15 of pregnancy until Day 21 postpartum produced maternal toxicity and an increase in postnatal mortality in offspring. No adverse effects in mothers or offspring were observed at oral doses of up to 15 mg/kg/day (3600 times greater than MRHOD).

### LACTATION

#### Risk Summary

Cyclosporine is known to be excreted in human milk following systemic administration but excretion in human milk after topical treatment has not been investigated. VEVYE® doses are approximately 4,700 times lower than recommended oral doses of cyclosporine, with blood concentrations being undetectable after topical administration. However, caution should be exercised when VEVYE® is administered to a nursing woman.

### PEDIATRIC USE

Safety and effectiveness in pediatric patients below the age of 18 years have not been established.

### GERIATRIC USE

No overall difference in safety or effectiveness has been observed between elderly and younger patients.

### NONCLINICAL TOXICOLOGY

#### Carcinogenesis, Mutagenesis, Impairment of Fertility

##### Carcinogenesis

Evaluation of the potential carcinogenicity of cyclosporine was conducted in male and female mice and rats. In a 78-week oral (diet) mouse study, at doses of 1, 4, and 16 mg/kg/day, evidence of a statistically significant trend was found for lymphocytic lymphomas in females, and the incidence of hepatocellular carcinomas in mid-dose males significantly exceeded the control value.

In a 24-month oral (diet) rat study, conducted at 0.5, 2, and 8 mg/kg/day, pancreatic islet cell adenomas significantly exceeded the control rate in the low dose level. The hepatocellular carcinomas and pancreatic islet cell adenomas were not dose related. The low doses in mice and rats were approximately 120 times higher than the maximum recommended human ophthalmic dose (0.67 mcg/kg/day), normalized to body surface area.

##### Mutagenesis

In genetic toxicity tests, cyclosporine has not been found to be mutagenic/genotoxic in the Ames Test, the V79-HGPRT Test, the micronucleus test in mice and Chinese hamsters, the chromosome-aberration tests in Chinese hamster bone-marrow, the mouse dominant lethal assay, and the DNA-repair test in sperm from treated mice. Cyclosporine was positive in an in vitro sister chromatid exchange (SCE) assay using human lymphocytes.

##### Impairment of Fertility

Oral administration of cyclosporine to rats for 12 weeks (male) and 2 weeks (female) prior to mating produced no adverse effects on fertility at doses up to 15 mg/kg/day (approximately 3,600 times higher than the maximum recommended human ophthalmic dose).

### PATIENT COUNSELING INFORMATION

#### Risk of Contamination

Advise patients to wash their hands well before each use. Advise patients not to allow the dropper tip to touch the eye or any other surface, as this may contaminate the solution.

#### Contact Lens Wear

Advise patients not to touch the dropper tip to any surface to avoid contaminating the contents.



Distributed by  
Harrow Eye, LLC  
102 Woodmont Blvd. Suite 610  
Nashville, TN 37205  
USA  
©2023

# Study Compares PDR, DME Risk Between Two Popular Diabetes Drugs

In the past few years, the FDA has approved several novel hypoglycemic medications, such as GLP-1 agonists or SGLT-2 inhibitors, indicated for patients with diabetes to help improve glucose control, consequently helping stave off disease-related complications like diabetic retinopathy (DR). While keeping blood sugars in range reduces long-term risks of microvascular complications in diabetes, the specific effects of these popular new drugs on DR progression is unclear. To investigate, the authors of a new clinical cohort study published in *American Journal of Ophthalmology* evaluated the effects of both GLP-1 agonists and SGLT-2 inhibitors on DR and its progression using a large, diverse, real-world population database.

Included patients had an ICD-10 code of nonproliferative DR (NPDR) and monotherapy treatment, excluding insulin, with GLP-1 agonists or SGLT-2 inhibitors. The researchers compared the rate of progression to PDR and rate of development of diabetic macular edema between patients on GLP-1

agonists vs. those on SGLT-2 inhibitors. After propensity score matching, 6,481 patients made up each medication group.

The data showed that patients on monotherapy with GLP-1 agonists had a higher rate of progression to PDR compared to those on SGLT-2 inhibitors, demonstrated at years one and three after initiation of therapy. The GLP-1 agonist group also had a higher rate of new-onset DME than the SGLT-2 inhibitor group, observable at three months, six months, one year and three years after initiation of therapy. Importantly, the researchers noted in their paper, “This class-specific difference in developing vision-threatening complications was more pronounced over time.”

There was no significant difference in mean HbA1c levels or the need for secondary interventions such as anti-VEGF, panretinal laser photocoagulation or pars plana vitrectomy between the GLP-1 agonist and SGLT-2 inhibitor groups.

“Our large retrospective cohort study found that GLP-1 agonists carried a higher rate of progression to PDR and

DME compared to SGLT-2 inhibitors,” the authors concluded. They encouraged clinicians “to be aware of these potential effects and consider retinopathy status when initiating treatment with newer hypoglycemic agents to ensure patients are appropriately monitored for potential vision-threatening complications.” ◀

Wai KM, Mishra K, Koo E, et al. Impact of GLP-1 Agonists and SGLT-2 inhibitors on diabetic retinopathy progression: an aggregated electronic health record data study. *Am J Ophthalmol*. April 2024. [Epub ahead of print].

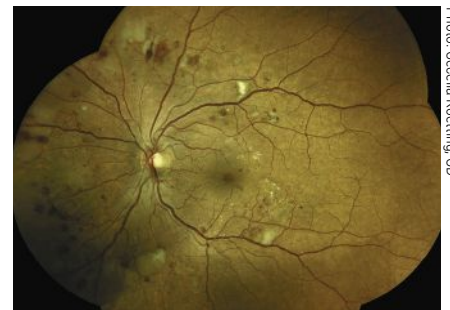

Photo: Cecelia Koetting, OD

**When treating patients with DR, consider the type of medication they take along with their current retinopathy status, as drug class can influence progression to PDR or new-onset DME.**

## Diabetes Patients Show Choroidal Microvascular Alterations Before DR

Given the severity of possible ocular complications of diabetes, clinical methods of early identification are critical. As such, researchers of one new retrospective study in *Retina* investigated associations between choroidal alterations and the reduction of peripapillary RNFL (pRNFL) thickness in patients with diabetes without DR (non-diabetic retinopathy, NDR).

Included were 143 eyes from 83 NDR patients and 124 control eyes from 82 individuals. Ultra-widefield SS-OCT angiography measured retinal and choroidal thickness, retinal vascular density and choroidal vascular metrics.

NDR patients displayed significant reductions in perifoveal choroidal thickness, a decrease in choroidal vascular

index and an increase in choroidal stromal index. The average pRNFL thickness, outer nuclear layer thickness and total retina were also reduced in NDR patients. Total choroidal thickness was correlated with pRNFL thickness, even after confounder adjustment.

The authors observed a decrease of about 20µm in NDR patients’ choroidal thickness, suggesting this has already decreased before substantial alterations are observed in retinal perfusion. Since the choroid mainly consists of vessels, choroidal thickness reduction, to a degree, signifies decrease in choroidal perfusion.

Significant pRNFL thinning was seen in the superior, nasal and inferior sectors but not in the temporal sector. Another neurodegenerative eye disease, glaucoma,

also displays the temporal pRNFL as the best-preserved sector, the authors point out. Due to the findings on choroidal thickness, they believe “a decrease in pRNFL thickness may indicate early retinal neurodegeneration.”

The authors concluded, “Since the choroid supplies most of the oxygen and nutrients required by the outer retinal layers, we propose a hypothesis: chronic hyperglycemia leads to the atrophy of choroidal arterioles, causing choroidal thinning. This may result in hypoxia of retinal cell nuclei located in the ONL and INL layers, leading to retinal neurodegeneration.” ◀

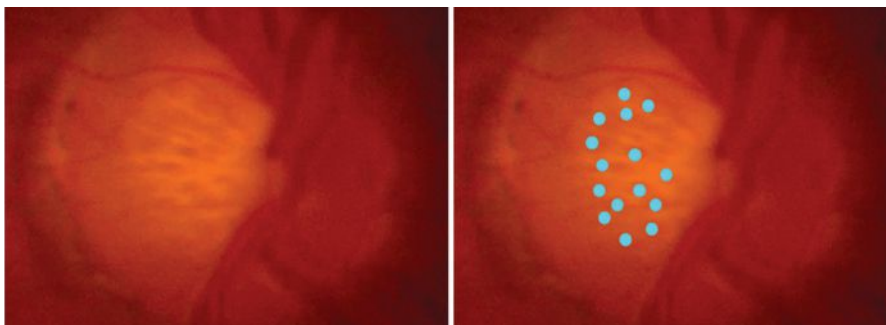
Li Z, Yang F, Deng X, et al. Associations between choroidal alterations and early neurodegeneration in diabetes without diabetic retinopathy: insights from ultra-widefield OCTA imaging. *Retina*. April 4, 2024. [Epub ahead of print].

# Lamina Cribrosa Pores May Help Identify Severe Glaucoma

Primary open-angle glaucoma (POAG) disproportionately affects individuals with African ancestry, who are four- to five-times more likely to have POAG and up to 15 times more likely to experience vision loss from the disease when compared with Americans with European ancestry. Structural changes to the lamina cribrosa in glaucomatous eyes have been reported, including more frequent slit-shaped lamina cribrosa pores, posterior displacement and thinner thickness.

Although several studies have characterized the changes to the lamina cribrosa pores in patients with glaucoma, few have investigated these associations in African-ancestry populations. Researchers from the University of Pennsylvania looked at the prevalence of and factors associated with visible optic disc lamina cribrosa pores in a large cohort of these individuals. They found in POAG cases that visible lamina cribrosa pores may be an important risk factor in identifying severe disease, potentially warranting closer monitoring by physicians.

All participants were ≥35 years old and self-identified as Black (African ancestry, Afro-Caribbean or African-American). A multivariate analysis of 1,187 glaucomatous eyes revealed that lamina cribrosa pores were more likely to be present in eyes with cup-to-disc ratios of ≥0.9 (adjusted risk ratio; aRR: 1.11), eyes with cylindrical-shaped (aRR: 1.22) and bean pot cups (aRR:



**Fundus image of optic nerve head (ONH) with multiple lamina cribrosa pores (left). Blue dots highlight the location of the pores at the ONH (right). This finding was associated with extremely large c/d ratio, deep optic disc cups, cylindrical and bean pot-shaped cups, the nasalization of central retinal vessels and higher degrees of African ancestry.**

1.24) vs. conical cups, moderate cup depth (aRR: 1.24) and deep cups (aRR: 1.27) compared with shallow cups and the nasalization of central retinal vessels (aRR: 1.33). Eyes with lamina cribrosa pores were more likely to have a higher degree of African ancestry, as determined by genetic analysis (aRR: 0.96).

Cylinder-shaped and bean pot-shaped cups possibly have more severe deformation of the lamina cribrosa. “Although this has not been proven, longitudinal studies of glaucomatous eyes with imaging modalities such as spectral-domain OCT should inform us in the future as to whether conical cups progress to cylinder-shaped cups and then to bean pot cups—and whether the lamina cribrosa pores start appearing at this point,” the researchers wrote in their paper for the journal *Vision*. “The depth of the cups was independently associ-

ated with the presence of visible pores after adjusting for the shape of cups.”

The team noted that several morphological changes to the optic cup were associated with the presence of visible lamina cribrosa pores. These associated cup features could be surrogates for the thinning and posterior displacement of the lamina cribrosa, laminar deformation and the structure’s curvature, which have been described by SS-OCT.

“These results should inform those who manage patients with glaucoma, encouraging them to carefully follow patients who manifest lamina cribrosa pores in order to allow for timely treatment to prevent progression of the disease,” the study concluded. ◀

Jordan JA, Daniel E, Chen Y, et al. Features associated with visible lamina cribrosa pores in individuals of African ancestry with glaucoma: Primary Open-Angle African Ancestry Glaucoma Genetics (POAAGG) Study. *Vision*. 2024;8(2):24.

Photo: Jordan JA, et al. *Vision*. 2024;8(2):24

## IN BRIEF

**Normal-Tension Glaucoma Exhibits Reduced Cerebrospinal Fluid Flow Dynamics.** Although lowering IOP has been shown to slow VF loss in normal-tension glaucoma (NTG), even if successful, some patients still have retinal ganglion cell loss with consecutive VF defects, calling into question other pathophysiological mechanisms, including cerebrospinal fluid (CSF) dynamics within the subarachnoid space of the optic nerve.

**A prospective study was done to measure CSF flow rates in**

**the subarachnoid space of the optic nerve using noninvasive diffusion-weighted MRI in NTG patients vs. controls.** Included were 49 optic nerves of 26 NTG patients and 52 of age-matched controls. Subjects were divided into four groups by age:

- group I, age 50 to 59 (12 eyes)
- group II, age 60 to 69 (16 eyes)
- group III, age 70 to 79 (18 eyes)
- group IV, age 80+ (6 eyes)

Using MRI imaging, the researchers devised a metric they called flow-range ratio (FRR) to estimate flow velocity of moving particles

between the frontal lobe and optic nerve subarachnoid spaces.

**The FRR was reduced in NTG patients vs. controls,** but there was no difference within age categories or the control group, nor between subgroups when comparing FRR of NTG patients by age category. **The mean FRR by age group for NTG patients vs. controls, respectively, was: (I) 0.54 and 0.62, (II) 0.56 and 0.63, (III) 0.54 and 0.62 and (IV) 0.61 and 0.61.**

The authors proposed two possible mechanisms for the decreased CSF flow observed within the subarachnoid space along the

optic nerve in NTG patients. One is compartmentalization of the optic nerve sheath, while the other explanation could be the effect of low CSF pressure.

The authors concluded, **“Given the physiological importance of CSF for the integrity of neurons, axons and glial cells, reduced CSF flow dynamics might be part of the underlying neurodegenerative process of NTG.”**

Berberat J, Pircher A, Remonda L, Killer HE. Age related cerebrospinal fluid flow dynamics in the subarachnoid space of the optic nerve in patients with normal tension glaucoma, measured by diffusion weighted MRI. *Eye (Lond)*. April 25, 2024. [Epub ahead of print].

**BAUSCH + LOMB**

# The trifecta of **dry eye relief**

The first and only over-the-counter drop for dry eyes to combine hyaluronic acid and lipid nanoemulsion to relieve both evaporative and aqueous deficient symptoms.

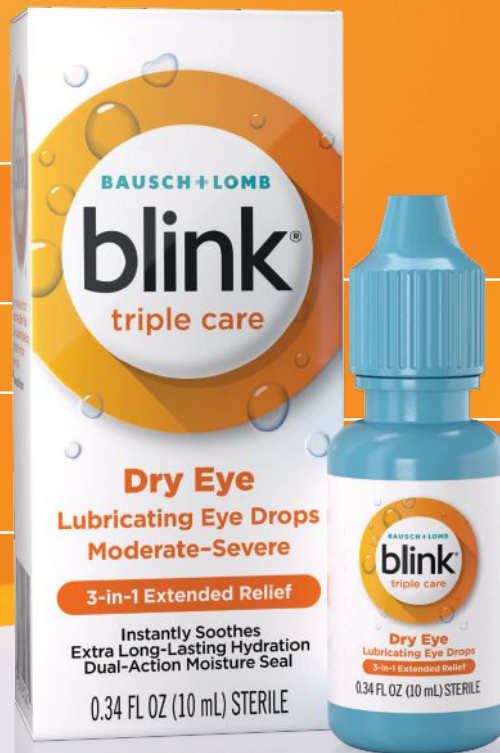

Instantly soothes



Extra long-lasting hydration

Locks in moisture



**Call 1-855-542-5682 for samples!**

# Meta-analysis Credits Trifocal IOLs as Best for Postoperative Near Vision Correction

Choosing the appropriate intraocular lens (IOL) for a patient isn't as straightforward as it used to be with the myriad options now available for presbyopia correction. To obtain a "credible evidence-based medical foundation for choosing clinical IOLs," researchers in China evaluated the safety (optical quality) and efficacy (visual acuity, spectacle independence) of common presbyopia-correcting IOLs, with an emphasis on intermediate and near visual ranges due to our reliance on digital devices today. The meta-analysis, published in *BMC Ophthalmology*, encompassed 28 randomized controlled trials with 2,465 subjects.

Findings demonstrated that trifocal IOLs confer superior uncorrected near visual acuity vs. monofocals, and that both trifocals and EDOFs offer better uncorrected intermediate visual acuity

than monofocals. At various distances, trifocals provided the best spectacle independence. Despite these findings, the researchers noted that the neuroadaptation required for trifocals may be "time-consuming and frustrating" for patients.

The researchers concluded in their paper that "for patients with bilateral cataracts, binocular implantation of trifocal IOLs can give higher spectacle independence and good vision at intermediate and near distances, but need to overcome the decrease of optical quality, and EDOF and enhanced monofocal IOLs are also good choices if there are more activities in daily life at intermediate distances. At the same time, enhanced monofocals IOLs are a better option for patients who are sensitive to decreased visual quality."

Ultimately, they explained that more large-scale studies are needed and "the

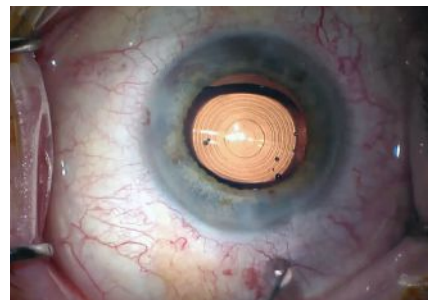

Photo: Ethan Zimmerman, OD

**For clear distance vision, monofocal IOLs still reign supreme but trifocals offer good near vision correction for those patients interested in presbyopia correction.**

optimal treatment regimen should be determined on an individual patient basis, safety outcomes and patient and caregiver decisions." ◀

Li J, Sum B, Zhang Y, et al. Comparative efficacy and safety of all kinds of intraocular lenses in presbyopia-correcting cataract surgery: a systematic review and meta-analysis. *BMC Ophthalmology*. 2024;24:172.

# MGD: A Condition with Multiple Disease Pathways?

As with dry eye itself, meibomian gland disease (MGD) is an umbrella term comprising various abnormalities. In a recent *Cornea* paper, experts wrote that separating various MGD signs and their relationship to different aspects of the disease pathophysiology is key to develop targeted therapeutics to improve patient care and quality of life. The paper evaluated associations between MGD signs, dry eye metrics and inflammatory proteins, finding that MGD features are driven by different pathophysiological mechanisms.

In the study, a total of 40 South Florida veterans (95% male) with signs of MGD were administered symptom questionnaires and given ocular surface evaluations. The researchers also extracted tear proteins from Schirmer strips and analyzed them for 23 human inflammation-related proteins.

They reported that eyelid vascularity, meibum quality and meibomian gland dropout correlated with higher corneal staining and reduced tear production. MG plugging wasn't associated with these dry eye signs.

The researchers also found that MGD features differentially related to tear cytokines. Eyelid vascularity emerged as the sign most closely associated with inflammation, with significant correlations with several inflammatory cytokines, including interleukin-4, which multivariate models showed was significantly related to eyelid vascularity. The other signs were less related to inflammation.

This study demonstrates that "various aspects of MGD may have different underlying contributors, with inflammation relating most strongly to the presence of eyelid vascularity," the researchers concluded in their *Cornea* paper. "Our current treatment of MGD doesn't

differentiate between various presentations, and it's still unclear which patients would benefit most from anti-inflammatory vs. another treatment modality, such as heat and massage." ◀

Kim CK, Locatelli EVT, Prislowsky A, et al. Is meibomian gland dysfunction one disease? Heterogeneity among phenotypes. *Cornea*. April 2, 2024. [Epub ahead of print].

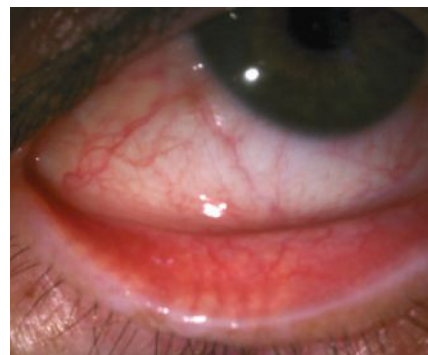


Photo: Mia Ioussifova, OD, and Hardeep Kataria, OD

**Eyelid vascularity, the sign most closely tied to inflammation in this study, is also the MGD sign most closely linked with rosacea.**

# Dry Eye Patients Have Worse Sleep Quality

Currently, there is conflicting data concerning possible associations of dry eye and sleep quality.

Thus, researchers from Beijing conducted a meta-analysis of the evidence across existing studies focused on sleep disorders and found that those with dry eye have a higher risk of unhealthy sleep duration.

A total of 21 studies with 419,218 participants were included. The results showed that the dry eye subjects had a worse sleep quality than the unaffected population, with poorer subjective sleep quality, longer sleep latency and a higher risk of unhealthy sleep duration such as insufficient sleep or excessive sleep.

Scores on a metric called the Pittsburgh Sleep Quality Index (PSQI) were higher for the dry eye subjects in sleep quality, latency and disturbance. There was no difference between the dry eye individuals and control subjects in sleep duration, sleep efficiency, daytime dysfunction and sleep medication scores.

The authors noted there is a slight discrepancy regarding whether dry eye patients are more prone to daytime

issues. “Au et al. believed that dry eye patients are more likely to have daytime sleepiness, while we found no difference between dry eye patients and the healthy population in terms of daytime dysfunction,” the researchers wrote in their paper. “This is related to our different definitions of daytime behavior.”

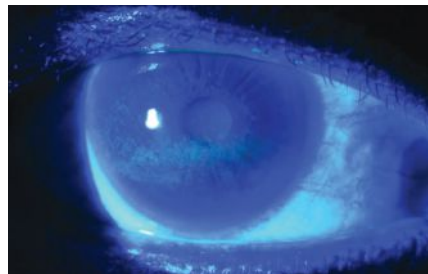


Photo: WR Blue 00

**Those with dry eye have worse sleep quality, longer sleep latency and higher risk of insufficient sleep or excessive sleepiness vs. healthy individuals.**

The authors added that there are some contradictions in the conclusions of this study, explaining that based on the PSQI questionnaire, there is no difference in total sleep duration between dry eye patients and healthy people, but dry eye

patients are more likely to have extreme sleep duration according to statistics.

Poor sleep qualities in dry eye patients may be due to light exposure and discomfort from incomplete eyelid closure or pain caused by inflammation, a prior study showed. Dry mouth discomfort experienced by dry eye patients is also a contributing factor, the authors noted.

Additionally, there is a bidirectional association between dry eye and sleep disorders; poor sleep or sleep deprivation may also lead to the onset or exacerbation of dry eye symptoms.

“An intervention study by Lee et al. showed that sleep deprivation induces increased tear osmolarity, shortened tear break-up time and reduced tear secretion, thereby further triggering the onset and development of dry eye,” the authors explained. “Physiologically, sleep disorders often lead to autonomic nervous system dysfunction, affecting the parasympathetic function in the lacrimal gland and reducing tear secretion.” ◀

Gu Y, Cao K, Li A, et al. Association between sleep quality and dry eye disease: a literature review and meta-analysis. *BMC Ophthalmol.* April 5, 2024. [Epub ahead of print].

# Brimonidine Explored as Potential Myopia Treatment

With myopia’s increasing prevalence, researchers are looking at various ways to mitigate early progression. Although atropine is the only pharmaceutical currently used for such a purpose, its mechanism of action in myopia mitigation is poorly understood. Researchers have considered the idea of using brimonidine to slow myopia due to its IOP-lowering effects; however, as with atropine, myopia and its relationship with IOP are not well understood.

A recent study explored the efficacy of brimonidine in countering the effects of form-deprivation myopia (FDM) and the relationship between IOP and myopia development in male guinea pigs. Monocular FDM was induced in three-week-old guinea pigs, who were

then dosed with brimonidine for 21 days using either eye drops, subconjunctival injection or intravitreal injection. Four concentrations were tested for each method: 2µg/µL, 4µg/µL, 20µg/µL and 40µg/µL.

Upon completion, the authors saw that subconjunctival brimonidine treatment at 40µg/µL and intravitreal treatment at 2µg/µL and 4µg/µL inhibited FDM development. Myopic refraction, excessive axial length and IOP elevation were also decreased. Notably, the eye drop method of brimonidine was ineffective.

Off-target binding of high-concentration drugs may explain the fact that subconjunctival 40µg/µL injection and 2µg/µL intravitreal injection were effective in myopia development suppression

but higher concentrations of intravitreal were not, the researchers suggest.

The authors acknowledge that while it remains unclear whether there is a causal relationship between IOP and AL, there are two main possibilities that might contribute to their link: “It has been suggested that lowering IOP inhibits the activation of scleral fibroblasts, thereby reducing scleral remodeling, and that a decrease in scleral dilation force retards the balloon-like expansion of the scleral coat. It has also been suggested that lowering IOP leads to increased choroidal blood perfusion, which reduces scleral hypoxia and is accompanied by decreases in scleral remodeling.” ◀

Peng Z, Xiang A, He H, et al. Brimonidine as a possible treatment for myopia. *BMC Ophthalmol.* April 11, 2024. [Epub ahead of print].

**tyrvaya**<sup>®</sup>  
(varenicline solution)  
nasal spray 0.03 mg

FOR THE SIGNS  
& SYMPTOMS OF  
DRY EYE DISEASE

SHE'S LOOKING TO YOU FOR A  
DIFFERENT APPROACH WHEN  
ARTIFICIAL TEARS ARE NOT ENOUGH.<sup>1</sup>

BEFORE ANOTHER DROP

# ACTIVATE REAL TEARS

WITH THE FIRST AND ONLY NASAL  
SPRAY FOR DRY EYE<sup>2</sup>



## Tyrvaya<sup>®</sup> is not another drop

It's an **ocular surface-sparing** nasal spray.<sup>2</sup>



## Activates real, basal tears

Tyrvaya<sup>®</sup> is believed to work by activating the trigeminal parasympathetic pathway resulting in **basal tear production**.<sup>2\*</sup>



## Real tears, real fast

In 2 clinical trials with **mild, moderate, and severe** dry eye disease patients, Tyrvaya increased tear production from baseline by **≥10 mm in Schirmer's Test Score (STS) in nearly 50% of patients at week 4**, with increased tears seen as early as the first dose and over 12 weeks.<sup>2-8†</sup>

SEE WHAT  
TYRVAYA  
CAN DO



\*The exact mechanism of action is unknown.

†Tyrvaya was evaluated across 3 randomized, vehicle-controlled, double-masked studies in which adults aged ≥22 years diagnosed with dry eye disease received 1 spray of either active drug or vehicle in each nostril twice daily. Primary endpoint: % of patients with mean change from baseline in STS of ≥10 mm at week 4 in ONSET-1: 52% with Tyrvaya (n=48) vs 14% with vehicle (n=43) and in ONSET-2: 47% with Tyrvaya (n=260) vs 28% with vehicle (n=252). Onset of action: mean change from baseline in STS ~5 minutes after first dose (not a prespecified endpoint) in ONSET-1 was 17.2 mm with Tyrvaya (n=48) vs 4.0 mm with vehicle (n=43) and in ONSET-2 was 16.5 mm with Tyrvaya (n=260) vs 6.9 mm with vehicle (n=251). Observed data. On Day 1 in clinical studies, a baseline anesthetized Schirmer's test was performed. Tyrvaya was then administered concurrently with Schirmer's test. Schirmer's test results were measured at ~5 minutes. Mean change from baseline in STS at week 12 in the MYSTIC study was 10.8 mm with Tyrvaya vs 6.0 mm with vehicle. Limitations: Ex-US, single-center study. All subjects were Hispanic or Latino. Tyrvaya group mean baseline STS 5.5 mm (n=41); vehicle group mean baseline STS 5.3 mm (n=41). All randomized and treated patients were included in the analysis and missing data were imputed using last-available data.<sup>2-8</sup>

See references on next page.

## Indication

Tyrvaya<sup>®</sup> (varenicline solution) nasal spray is indicated for the treatment of the signs and symptoms of dry eye disease.

## Important Safety Information

The most common adverse reaction reported in 82% of patients was sneezing. Events that were reported in 5-16% of patients were cough, throat irritation, and instillation-site (nose) irritation.

Please see Brief Summary of Prescribing Information on the next page and the full Prescribing Information at [Tyrvaya-pro.com](http://Tyrvaya-pro.com).



**BRIEF SUMMARY:** Consult the full Prescribing Information for complete product information available at [www.tyrvaya-pro.com](http://www.tyrvaya-pro.com).

### **INDICATIONS AND USAGE**

TYRVAYA<sup>®</sup> (varenicline solution) nasal spray is a cholinergic agonist indicated for the treatment of the signs and symptoms of dry eye disease.

### **ADVERSE REACTIONS**

**Clinical Trials Experience:** Because clinical trials are conducted under widely varying conditions, adverse reaction rates observed in the clinical trials of a drug cannot be directly compared to rates in the clinical trials of another drug and may not reflect the rates observed in practice.

In three clinical trials of dry eye disease conducted with varenicline solution nasal spray, 349 patients received at least 1 dose of TYRVAYA. The majority of patients had 31 days of treatment exposure, with a maximum exposure of 105 days.

The most common adverse reactions reported in 82% of TYRVAYA treated patients was sneezing. Other common adverse reactions that were reported in >5% of patients include cough (16%), throat irritation (13%), and instillation-site (nose) irritation (8%).

### **USE IN SPECIFIC POPULATIONS**

**Pregnancy:** Risk Summary: There are no available data on TYRVAYA use in pregnant women to inform any drug associated risks. In animal reproduction studies, varenicline did not produce malformations at clinically relevant doses.

All pregnancies have a risk of birth defect, loss, or other adverse outcomes. In the US general population, the estimated background risk of

major birth defects and miscarriage in clinically recognized pregnancies is 2% to 4% and 15% to 20%, respectively.

Data: Animal Data: Pregnant rats and rabbits received varenicline succinate during organogenesis at oral doses up to 15 and 30 mg/kg/day, respectively. While no fetal structural abnormalities occurred in either species, maternal toxicity, characterized by reduced body weight gain, and reduced fetal weights occurred in rabbits at the highest dose (4864 times the MRHD on a mg/m<sup>2</sup> basis).

In a pre- and postnatal development study, pregnant rats received up to 15 mg/kg/day of oral varenicline succinate from organogenesis through lactation. Maternal toxicity, characterized by a decrease in body weight gain, was observed at 15 mg/kg/day (1216 times the MRHD on a mg/m<sup>2</sup> basis). Decreased fertility and increased auditory startle response occurred in offspring at the highest maternal dose of 15 mg/kg/day.

**Lactation:** Risk summary: There are no data on the presence of varenicline in human milk, the effects on the breastfed infant, or the effects on milk production. In animal studies varenicline was present in milk of lactating rats. However, due to species-specific differences in lactation physiology, animal data may not reliably predict drug levels in human milk.

The lack of clinical data during lactation precludes a clear determination of the risk of TYRVAYA to an infant during lactation; however, the developmental and health benefits of breastfeeding should be considered along with the mother's clinical need for TYRVAYA and any potential adverse effects on the breastfed child from TYRVAYA.

**Pediatric Use:** Safety and efficacy of TYRVAYA in pediatric patients have not been established.

**Geriatric Use:** No overall differences in safety or effectiveness have been observed between elderly and younger adult patients.

**References:** **1.** Jones L, Downie LE, Korb D, et al. *Ocul Surf.* 2017;15(3):575-628. **2.** Tyrvaya. Prescribing Information. Oyster Point Pharma; 2021. **3.** Oyster Point Pharma. Data on file. OPP-002 (ONSET-1) Clinical Study Report. August 4, 2019. **4.** Oyster Point Pharma. Data on file. OPP-101 (ONSET-2) Interim Clinical Study Report. October 13, 2020. **5.** Quiroz-Mercado H, Hernandez-Quintela E, Chiu KH, Henry E, Nau JA. *Ocul Surf.* 2022;24:15-21. **6.** Wirta D, Torkildsen GL, Boehmer B, et al. *Cornea.* 2022;4(10):1207-1216. **7.** Wirta D, Vollmer P, Paauw J, et al. *Ophthalmology.* 2021;0(0):379-387. **8.** Oyster Point Pharma. Data on file. OPP-004 (MYSTIC) Clinical Study Report. March 19, 2020.

Manufactured for Oyster Point Pharma, Inc. 202 Carnegie Center, Suite 106, Princeton NJ 08540. For more information, visit [www.tyrvaya-pro.com](http://www.tyrvaya-pro.com). To report an adverse event, contact 1-877-EYE-0123.

© 2023 Viatrix Inc. and/or its affiliates. All rights reserved. VIATRIS and the Viatrix Logo are trademarks of Mylan Inc., a Viatrix Company. Oyster Point<sup>®</sup>, Tyrvaya<sup>®</sup>, and the Tyrvaya logo are trademarks of Oyster Point Pharma, Inc., a Viatrix company, in the United States and certain jurisdictions. OP-TYR-002308 7/23

# FEATURES

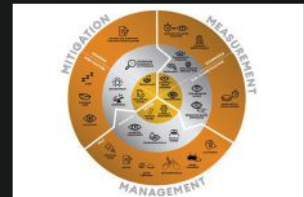REVIEW OF OPTOMETRY • Vol. 161, No. 5 • MAY 15, 2024

25TH ANNUAL DRY EYE REPORT

## 50 An Action Plan for Managing Dry Eye

Use this new resource to help navigate the many tools and techniques available to us.

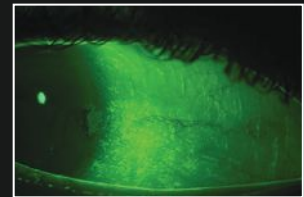
By James S. Wolffsohn, PhD, Jennifer P. Craig, PhD, and Lyndon Jones, PhD



## 58 Dry Eye: Matching Patients and Treatments

Experts present real cases and offer direction on management strategies and considerations for dealing with various types of ocular surface disease.

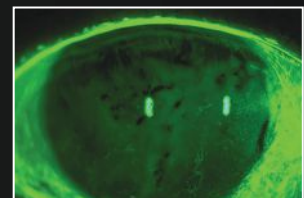
By Harriette Canellos, OD, and Miranda Koehler, OD



## 64 All Eyes on Omegas

Despite some controversy, omega-3 fatty acids continue to play a role in the mitigation of dry eye.

By Hamza Shah, OD, MS

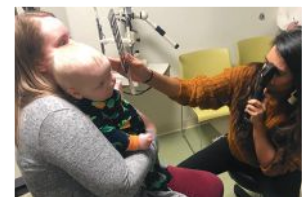


Cover photo by Luis Rojas, OD

## 36 How to Perform a Peds Exam in Under Five Minutes

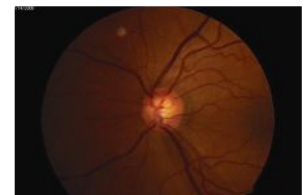
Have no fear. Learn the keys to examining pediatric patients for the generalist optometrist.

By Samantha Krueger, OD, MS, and Erin Jenewein, OD, MS



## 42 Glaucoma: Pearls for Improving the Patient Experience

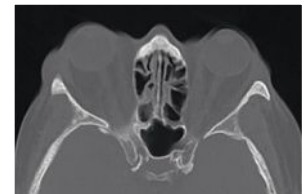ODs play a key role in helping individuals adapt to this life-changing diagnosis and navigating them through the challenges they will face. By Catlin Nalley, Contributing Editor



## 72 Ocular Manifestations of Autoimmune Diseases: How to Understand and Identify – EARN 2 CE CREDITS

Optometrists have a key role to play when it comes to the overall health of their patients.

By Melissa Chen, OD, Theresa Jay, OD, Steve Njeru, OD, and Eric Spotts, OD



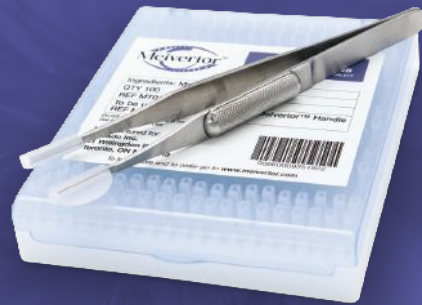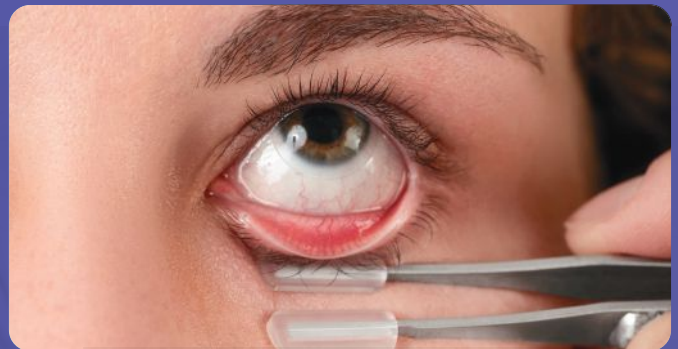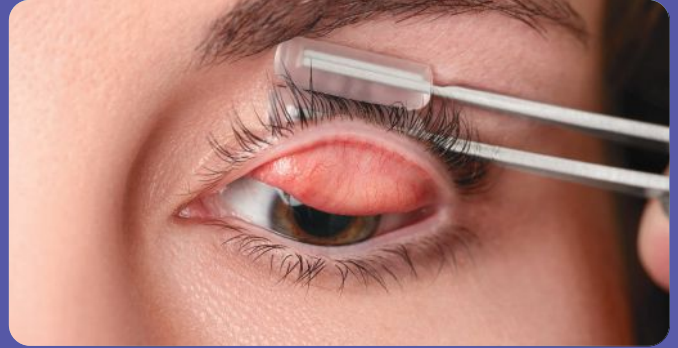REVIEW OF OPTOMETRY (ISSN 0147-7633) IS PUBLISHED MONTHLY, 12 TIMES A YEAR BY JOBSON MEDICAL INFORMATION LLC/WebMD, 283-299 MARKET STREET, 2 GATEWAY CENTER, 4TH FLOOR, NEWARK, NJ 07102. PERIODICALS POSTAGE PAID AT NEWARK, NJ AND ADDITIONAL MAILING OFFICES. POSTMASTER: SEND ADDRESS CHANGES TO REVIEW OF OPTOMETRY, PO BOX 81, CONGERS, NY 10920-0081. SUBSCRIPTION PRICES: US: ONE YEAR \$56; TWO YEARS \$97; CANADA: ONE YEAR \$88, TWO YEARS \$160, INT'L: ONE YEAR \$209, TWO YEARS \$299. FOR SUBSCRIPTION INFORMATION CALL TOLL-FREE (877) 529-1746 (USA); OUTSIDE USA, CALL (845) 267-3065. OR EMAIL US AT REVOPOTOMETRY@CAMBEYWEST.COM. PUBLICATIONS MAIL AGREEMENT NO: 40612608. CANADA RETURNS TO BE SENT TO BLEUCHIP INTERNATIONAL, P.O. BOX 25542, LONDON, ON N6C 6B2.



US Patent 11,446,017

# The ONLY SINGLE-HANDED UPPER and lower eyelid EVERSION TOOL

- Optimize the functionality of your meibographer
- Empower your technician to take the images you need – flipping a lid has never been easier
- Whenever you evert an upper eyelid – AND need a free hand – use your Meivertor



“Amazingly well designed, incredible balance to the instrument, and ease of use. I would recommend every technician who does meibography have one.”

-Dr. Paul Karpecki, OD, FAAO



“Love the Meivertor. First true game changer in the meibography game in my opinion.”

-Dr. Bradley Barnett, MD



“The Meivertor is a terrific product that has become one of my staff’s favourite in a very short time!”

-Dr. Kimberly K. Friedman, OD, FAAO



“Anyone struggle with lid eversion for meibomian gland imaging? Try using the Meivertor. Teaching techs has been a breeze and we can image both the upper and lower lids with ease!”

-Dr. Preeya Gupta, MD



For more information and to purchase go to [meivertor.com](http://meivertor.com)

# DEPARTMENTS

REVIEW OF OPTOMETRY • MAY 15, 2024

FOLLOW US ON SOCIAL MEDIA

Facebook: revoptom

Twitter: revoptom

Instagram: revoptom

Threads: revoptom

LinkedIn: company/review-of-optometry

4

## NEWS REVIEW

Clinical, legislative and practice updates for ODs.

21

## OUTLOOK

### The Elephant in the Exam Room

ODs' contributions to eye care are conspicuously absent from ophthalmology's worldview.

*Jack Persico, Editor-in-Chief*

22

## THROUGH MY EYES

### My Favorite Things

In the OSD/DED world of products, these reign supreme.

*Paul M. Karpecki, OD*

24

## CHAIRSIDE

### Focus on You

Don't get distracted by all the hubbub.

*Montgomery Vickers, OD*

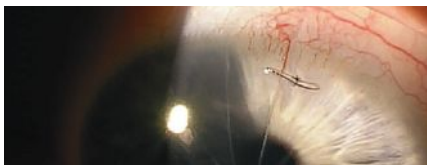26

## CLINICAL QUANDARIES

### When is RK Not OK?

Refractive surgery performed years ago can come back to haunt patients undergoing cataract extraction.

*Paul C. Ajamian, OD*



29

## YOU BE THE JUDGE

### Puppy Love Blindness

The rare case of red eye that does not respond to treatment can have a disastrous outcome.

*Jerome Sherman, OD, and Sherry Bass, OD*

32

## THE ESSENTIALS

### Provoked Proteins

Two blood tests can offer insight about whether an inflammation-causing eye condition is present.

*Bisant A. Labib, OD*



82

## OCULAR SURFACE REVIEW

### As Smooth as Silk

This unique protein is a brand new DED treatment.

*Paul M. Karpecki, OD*

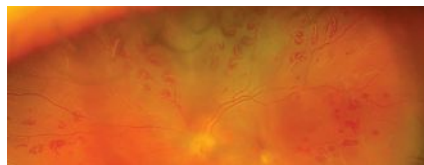84

## URGENT CARE

### Hemes and Cells and Sheathing—Oh, My!

A unique presentation of a rare postoperative complication.

*Alison Bozung, OD*



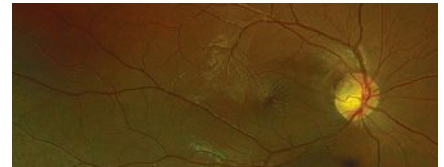
88

## RETINA QUIZ

### It's the Pits

Managing this condition can be quite challenging.

*Rami Aboumourad, OD*



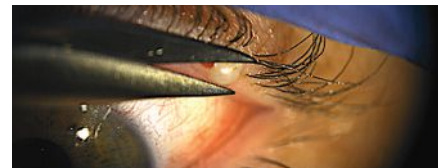
92

## ADVANCED PROCEDURES

### Oust the Cyst

Integrate these eyelid lesion removals into your surgical arsenal.

*Bradley A. Daniel, OD*



97

## PRODUCT REVIEW

New items to improve clinical care.


98

## DIAGNOSTIC QUIZ

### Sugar Crash

Significant corneal concerns and a collapsed AC.

*Andrew S. Gurwood, OD*



**xdemvy**<sup>®</sup>  
(lotilaner ophthalmic  
solution) 0.25%



Learn more at  
[XDEMZYHCP.com](https://XDEMZYHCP.com)

XDEMZY gives you  
**might over mites**  
to eradicate *Demodex* blepharitis.<sup>1,2</sup>

**Lotilaner, the active ingredient in XDEMZY<sup>1,3,4</sup>:**



Is a lipophilic agent in an aqueous drop that...



Acts specifically via mite GABA-gated  
chloride channels to...



Target, paralyze, and kill *Demodex* mites

GABA=gamma-aminobutyric acid.

#### INDICATIONS AND USAGE

XDEMZY (lotilaner ophthalmic solution) 0.25% is indicated for the treatment of *Demodex* blepharitis.

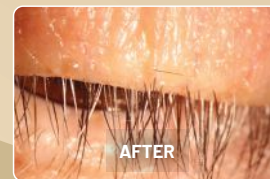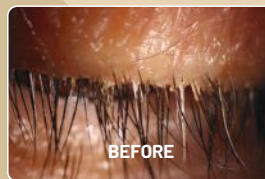#### IMPORTANT SAFETY INFORMATION:

#### WARNINGS AND PRECAUTIONS

**Risk of Contamination:** Do not allow the tip of the dispensing container to contact the eye, surrounding structures, fingers, or any other surface in order to minimize contamination of the solution. Serious damage to the eye and subsequent loss of vision may result from using contaminated solutions.

**Use with Contact Lenses:** XDEMZY contains potassium sorbate, which may discolor soft contact lenses. Contact lenses should be removed prior to instillation of XDEMZY and may be reinserted 15 minutes following its administration.

#### Real results



44% and 55% of patients taking XDEMZY in SATURN-1 (N=209) and SATURN-2 (N=193), respectively, achieved a significant improvement in their eyelids (reduction of collarettes to no more than 2 collarettes per upper lid) at Day 43 vs 7% (N=204) and 12% (N=200) of patients taking vehicle ( $P<0.01$  in each trial).<sup>1\*</sup>

All images are of actual patients who participated in clinical trials for Tarsus Pharmaceuticals.

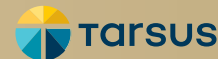**ADVERSE REACTIONS:** The most common adverse reaction with XDEMZY was instillation site stinging and burning which was reported in 10% of patients. Other ocular adverse reactions reported in less than 2% of patients were chalazion/hordeolum and punctate keratitis.

**Please see next page for a Brief Summary of the full Prescribing Information.**

**References:** 1. XDEMZY [prescribing information]. Tarsus Pharmaceuticals, Inc; 2023. 2. Gao YY et al. *Invest Ophthalmol Vis Sci.* 2005;46(9):3089-3094. 3. Yeu E et al. *Cornea.* 2022;42:435-443. 4. Toutain CE et al. *Parasit Vectors.* 2017;10(1):522.

\*The safety and efficacy of XDEMZY for the treatment of DB were evaluated in a total of 833 patients (415 of whom received XDEMZY) in two 6-week, randomized, multicenter, double-masked, vehicle-controlled studies (SATURN-1 and SATURN-2). Patients were randomized to either XDEMZY or vehicle at a 1:1 ratio, dosed twice daily in each eye for 6 weeks. All patients enrolled were diagnosed with DB. The primary efficacy endpoint was defined as the proportion of patients with collarette reduction to no more than 2 collarettes per upper eyelid at Day 43.

© 2024 Tarsus Pharmaceuticals, Inc. All rights reserved.  
Tarsus, XDEMZY, and the associated logos are trademarks of  
Tarsus Pharmaceuticals, Inc. US--2300617 1/24



**XDEMYV® (lotilaner ophthalmic solution) 0.25%, for topical ophthalmic use**

**BRIEF SUMMARY OF PRESCRIBING INFORMATION**

Please see the XDEMYV® package insert for full Prescribing Information.

**INDICATIONS AND USAGE**

XDEMYV is indicated for the treatment of Demodex blepharitis.

**CONTRAINDICATIONS**

None.

**WARNINGS AND PRECAUTIONS**

**Risk of Contamination** Do not allow the tip of the dispensing container to contact the eye, surrounding structures, fingers, or any other surface in order to minimize contamination of the solution. Serious damage to the eye and subsequent loss of vision may result from using contaminated solutions.

**Use with Contact Lenses** Contact lenses should be removed prior to instillation of XDEMYV and may be reinserted 15 minutes following its administration.

**ADVERSE REACTIONS**

Because clinical studies are conducted under widely varying conditions, adverse reaction rates observed in the clinical trials of a drug cannot be directly compared to rates in the clinical trials of another drug and may not reflect the rates observed in practice.

XDEMYV was evaluated in 833 patients with Demodex blepharitis in two randomized, double-masked, vehicle-controlled studies (Saturn-1 and Saturn-2) with 42 days of treatment. The most common ocular adverse reaction observed in controlled clinical studies with XDEMYV was instillation site stinging and burning which was reported in 10% of patients. Other ocular adverse reactions reported in less than 2% of patients were chalazion/hordeolum and punctate keratitis.

**USE IN SPECIFIC POPULATIONS**

**Pregnancy: Risk Summary** There are no available data on XDEMYV use in pregnant women to inform any drug associated risk; however, systemic exposure to lotilaner from ocular administration is low. In animal reproduction studies, lotilaner did not produce malformations at clinically relevant doses.

**Data Animal Data** In an oral embryofetal developmental study in pregnant rats dosed during organogenesis from gestation days 6-19, increased post-implantation loss, reduced fetal pup weight, and incomplete skeletal ossification were observed at 50 mg/kg/day (approximately 1390 times the recommended human ophthalmic dose (RHOD) on a body surface area basis) in the presence of maternal toxicity (i.e., decreased body weight and food consumption). A rare malformation of situs inversus of the thoracic and abdominal viscera occurred in 1 fetus from a pregnant rat receiving 50 mg/kg/day; whether this finding was treatment-related could not be excluded. No maternal or embryofetal toxicity was observed at 18 mg/kg/day (approximately 501 times the RHOD on a body surface area basis). In an oral embryofetal development study in pregnant rabbits dosed during organogenesis from gestation days 7-19, no embryofetal toxicity or teratogenic findings were observed at 20 mg/kg/day (approximately 580-times the RHOD on an AUC basis), even in the presence of maternal toxicity (i.e., decreased food consumption and body weight).

In an oral two-generation reproductive toxicity study, F0 male and female rats were administered lotilaner at doses up to 40 mg/kg/day for 10 weeks before pairing and during the 2-week pairing period (3 weeks for males). Dosing for F0 females continued through lactation day 22. F1 male and female rats were administered lotilaner at 1 and 5 mg/kg/day post-weaning from day 23 for 10 weeks before pairing and during the 2-week pairing period (3 weeks for males). Dosing for F1 parenteral females continued through lactation day 22. There were no clear adverse effects on the F1 generation, and a slightly lower mean body weight during lactation was noted for F2 pups at 5 mg/kg/day. The no observed adverse effect level (NOAEL) was determined to be 5 mg/kg/day

(approximately 139 times the RHOD on a body surface area basis).

**Lactation: Risk Summary** There are no data on the presence of XDEMYV in human milk, the effects on the breastfed infant, or the effects on milk production. However, systemic exposure to lotilaner following 6 weeks of topical ocular administration is low and is >99% plasma protein bound, thus it is not known whether measurable levels of lotilaner would be present in maternal milk following topical ocular administration. The developmental and health benefits of breastfeeding should be considered along with the mother's clinical need for XDEMYV and any potential adverse effects on the breast-fed child from XDEMYV.

**Pediatric Use:** Safety and effectiveness in pediatric patients below the age of 18 years have not been established.

**Geriatric Use:** No overall differences in safety or effectiveness have been observed between elderly and other adult patients.

**NONCLINICAL TOXICOLOGY**

**Carcinogenesis, Mutagenesis, Impairment of Fertility**

**Carcinogenesis** Long-term studies in animals have not been performed to evaluate the carcinogenic potential of lotilaner.

**Mutagenesis** Lotilaner was not genotoxic in the following assays: Ames assay for bacterial gene mutation, *in vitro* chromosomal aberration assay in cultured human peripheral blood lymphocytes, and *in vivo* rat micronucleus test.

**Impairment of fertility** In a two-generation study of reproductive performance in rats, F0 male and female rats were administered lotilaner at oral doses of 40 mg/kg/day for 80 days reduced to 20 mg/kg/day for 47-50 supplementary days. Reduced pregnancy rates and decreased implantation rates were observed in F0 females at doses 20 mg/kg/day (approximately 556 times the RHOD on a body surface area basis), which were also associated with maternal toxicity (i.e., decreased body weight and food consumption). No effects on fertility were observed in F0 females at the dose of 5 mg/kg/day (approximately 139 times the MRHOD on a body surface area basis). No effects on fertility were observed in F0 males at the oral dose of 20 mg/kg/day (approximately 556 times the RHOD on a body surface area basis), and no effects on fertility were observed in F1 males and females at the oral dose of 5 mg/kg/day (approximately 139 times the RHOD on a body surface area basis).

**PATIENT COUNSELING INFORMATION**

**Handling the Container** Instruct patients to avoid allowing the tip of the dispensing container to contact the eye, surrounding structures, fingers, or any other surface in order to minimize contamination of the solution. Serious damage to the eye and subsequent loss of vision may result from using contaminated solutions.

**When to Seek Physician Advice**

Advise patients that if they develop an intercurrent ocular condition (e.g., trauma or infection), have ocular surgery, or develop any ocular reactions, particularly conjunctivitis and eyelid reactions, they should immediately seek their physician's advice concerning the continued use of XDEMYV.

**Use with Contact Lenses** Advise patients that XDEMYV contains potassium sorbate, which may discolor soft contact lenses. Contact lenses should be removed prior to instillation of XDEMYV and may be reinserted 15 minutes following its administration.

**Use with Other Ophthalmic Drugs** Advise patients that if more than one topical ophthalmic drug is being used, the drugs should be administered at least 5 minutes between applications.

**Missed Dose** Advise patients that if one dose is missed, treatment should continue with the next dose.

RX only

© 2024 Tarsus Pharmaceuticals, Inc. All rights reserved.

XDEMYV is a trademark of Tarsus Pharmaceuticals, Inc.

US--2300345 1/24



## CLINICAL EDITORS

CHIEF CLINICAL EDITOR ~ PAUL M. KARPECKI, OD

ASSOCIATE CLINICAL EDITORS ~ JOSEPH P. SHOVLIN, OD, CHRISTINE SINDT, OD

## CONTRIBUTING EDITORS

RAMI ABOUMOURAD, OD	NATE LIGHTHIZER, OD
PAUL C. AJAMIAN, OD	PAMELA H. SCHNELL, OD
SHERRY J. BASS, OD	JOSEPH P. SHOVLIN, OD
ALISON BOZUNG, OD	JEROME SHERMAN, OD
DEREK N. CUNNINGHAM, OD	JESSICA STEEN, OD
JAMES L. FANELLI, OD	MARC TAUB, OD
ANDREW S. GURWOOD, OD	MONTGOMERY VICKERS, OD
PAUL M. KARPECKI, OD	WALTER O. WHITLEY, OD, MBA
BISANT LABIB, OD	

## EDITORIAL ADVISORY BOARD

JEFFREY R. ANSHEL, OD	KELLY A. MALLOY, OD
JILL AUTRY, OD, RPH	DANICA MARRELLI, OD
SHERRY J. BASS, OD	RON MELTON, OD
EDWARD S. BENNETT, OD	PAMELA J. MILLER, OD, JD
MARC R. BLOOMENSTEIN, OD	MARC MYERS, OD
ALISON BOZUNG, OD	CARLO J. PELINO, OD
MILE BRUJIC, OD	JOSEPH PIZZIMENTI, OD
CHRIS J. CAKANAC, ODA	CHRISTOPHER J. QUINN, OD
JERRY CAVALLERANO, OD, PhD	MOHAMMAD RAFIETARY, OD
BRIAN CHOU, OD	JOHN L. SCHACHET, OD
MICHAEL CHAGLASIAN, OD	JACK SCHAEFFER, OD
A. PAUL CHOUS, MA, OD	PAMELA H. SCHNELL, OD
GLENN S. CORBIN, OD	LEO P. SEMES, OD
MARK T. DUNBAR, OD	DIANA L. SHECHTMAN, OD
S. BARRY EIDEN, OD	JEROME SHERMAN, OD
STEVEN FERRUCCI, OD	LEONID SKORIN, JR., OD, DO
MURRAY FINGERET, OD	JOSEPH W. SOWKA, OD
IAN BEN GADDIE, OD	JESSICA STEEN, OD
GARY S. GERBER, OD	BRAD M. SUTTON, OD
JESSICA HAYNES, OD	LORETTA B. SZCZOTKA, OD, PhD
MILTON HOM, OD	MARC TAUB, OD
DAVID KADING, OD	TAMMY P. THAN, MS, OD
JEROME A. LEGERTON, OD, MBA	RANDALL THOMAS, OD, MPH
THOMAS L. LEWIS, OD, PhD	SARA WEIDMAYER, OD
BLAIR B. LONSBERRY, MS, OD, MED	KAREN YEUNG, OD

## EDITOR-IN-CHIEF

**JACK PERSICO**

(610) 492-1006 • jpersico@jobson.com

## SENIOR EDITOR

**JULIE SHANNON**

(610) 492-1005 • jshannon@jobson.com

## SENIOR ASSOCIATE EDITOR

**MARK DE LEON**

(610) 492-1021 • mdeleon@jobson.com

## ASSOCIATE EDITOR

**LEANNE SPIEGLE**

(610) 492-1026 • lspiegle@jobson.com

## ASSOCIATE EDITOR

**RACHEL RITA**

(610) 492-1000 • rrita@jobson.com

## SENIOR SPECIAL PROJECTS MANAGER

**JILL GALLAGHER**

(610) 492-1037 • jgallagher@jobson.com

## ART DIRECTOR

**LYNNE O'CONNOR**

lyconnor@jobson.com

## GRAPHIC DESIGNER

**JAIINE KOPALA**

jkopala@jobson.com

## DIRECTOR OF CE ADMINISTRATION

**REGINA COMBS**

(212) 274-7160 • rcombs@jobson.com

**Clinical Editors**

Chief Clinical Editor • Paul M. Karpecki, OD

## Associate Clinical Editors

Joseph P. Shovlin, OD, Christine W. Sindt, OD

Clinical & Education Conference Advisor  
Paul M. Karpecki, OD

Case Reports Coordinator • Andrew S. Gurwood, OD

**Columnists***Advanced Procedures* – Nate Lighthizer, OD*Chairside* – Montgomery Vickers, OD*Clinical Quandaries* – Paul C. Ajamian, OD*Cornea and Contact Lens Q+A* – Joseph P. Shovlin, OD*Diagnostic Quiz* – Andrew S. Gurwood, OD*The Essentials* – Bisant A. Labib, OD*Focus on Refraction* – Marc Taub, OD, Pamela Schnell, OD*Glaucoma Grand Rounds* – James L. Fanelli, OD*Ocular Surface Review* – Paul M. Karpecki, OD*Retina Quiz* – Rami Aboumourad, OD*Surgical Minute* – Derek Cunningham, OD, Walter Whitley, OD*Therapeutic Review* – Jessica Steen, OD*Through My Eyes* – Paul M. Karpecki, OD*Urgent Care* – Alison Bozung, OD*You Be The Judge* – Jerome Sherman, OD, Sherry Bass, OD**Editorial Offices**

19 Campus Blvd., Suite 101 • Newtown Square, PA 19073

Jobson Medical Information/WebMD  
283-299 Market Street, 2 Gateway Center, 4th Floor  
Newark, NJ 07102Subscription inquiries: (877) 529-1746  
Continuing Education inquiries: (800) 825-4696

Printed in USA

BY JACK PERSICO  
EDITOR-IN-CHIEF**OUTLOOK**

# The Elephant in the Exam Room

*Optometrists deliver a sizable percentage of eye care, yet remain conspicuously absent from ophthalmology's worldview.*

I read a lot of journal articles. As I mentioned in my January column, we publish about 750 news stories every year, and nearly all are reports on research papers. Every one of those is selected by me. My morning routine is to scan more than 40 eyecare journals for new research that contains some clinical relevance to everyday practice or a better understanding of the finer points of pathophysiology. So, trust me when I tell you that I'm well-travelled in the world of ophthalmic research.

One thing that I find increasingly galling is the conspicuous lack of representation of optometry. I don't mean on the bylines of journal articles, though I would love to see more of that, too. I recognize that research is still predominantly conducted in ophthalmology practices for all sorts of reasons. It's easier to access a sizable patient base of subjects for the condition in question by going to a retina subspecialist, for instance, rather than a primary care optometrist. MDs also have big staffs capable of running a study, proficiency working with institutional review boards and name recognition with funding sources. There's also just a lot of inertia that keeps an established system humming along as is.

No, what I mean is the persistent blind spot the ophthalmologist authors of these journal articles have toward the very existence of optometry. The discussion section of a paper is where the researchers put their findings into context. Time and time again, they describe the significance of their work not for *eyecare providers* or *eye doctors* or *physicians* but for *ophthalmologists*. End of story.

Ophthalmologists overall and the research community in particular pride themselves on adhering to evidence-based principles. And yet, here's some evidence that seems to escape them:

- Optometrists provide 34% of all medically focused eye exams and 76% of all comprehensive exams when combining routine and medical services.

- ODs outnumber ophthalmologists in the US by more than two to one. In fact, the ratio is fast approaching three to one. Current workforce estimates put the number of ophthalmologists at 17,246 and optometrists at 48,792. That means there are 2.83 practicing ODs for every ophthalmologist right now.

- All the growth in eyecare capacity for decades to come will happen within optometry. A study published last year in *Ophthalmology* projected a 12% decrease in the ophthalmology workforce by 2035 and the second-lowest rate of workforce adequacy among all medical specialties. Optometry, if anything, may have the opposite problem, as some worry that there's a glut of optometry colleges.

All this capacity and potential requires diligence from ODs to pursue education and training on medical eyecare. But the ophthalmology profession remains a walled garden that gives ODs the cold shoulder in both practical and symbolic ways. Acknowledging the reality of optometry's significance in medical care, and being more open to educate the profession, would be in the best interests of both MDs and the patients they serve. ■

*Many thanks to Richard Edlow, OD, "the Eyeconomist," for assistance with the statistics mentioned here.*



BY PAUL M. KARPECKI, OD  
CHIEF CLINICAL EDITOR

## THROUGH MY EYES

# My Favorite Things

*In the OSD/DED world of products, these reign supreme.*

The world of dry eye disease (DED) is exploding, with an estimated 40 million Americans having the condition.<sup>1</sup> The good news—the recent release of new products into the market has dramatically improved our ability to treat patients. Yet, there are a number of lesser known products you should know about. Taking a page from Oprah Winfrey, listed below are my favorite things (in ocular surface disease).

### New Kids on the Block

The three most recent OSD/DED drugs made a big impact in the short time since FDA approval. Xdemvy (lotilaner ophthalmic solution 0.25%, Tarsus Pharmaceuticals) has shown remarkable success in eradicating *Demodex* blepharitis and lid erythema, as well as in improving meibomian gland dysfunction (MGD). Miebo (perfluorohexyloctane, Bausch + Lomb), which targets tear evaporation, has had incredible patient uptake. By preventing evaporation four times more than healthy meibum, this drug has achieved that feat. Finally, Vevye (cyclosporine 0.1%, Harrow Health) is showing rapid results on symptoms and ocular surface staining, greater bioavailability compared to the original cyclosporine 0.05% and with few, if any, side effects.

### Lesser Known But Equally Impressive

Speaking of *Demodex*, one of the more impressive hygiene products for *Demodex* blepharitis maintenance is based on a very effective anti-parasitic known as Manuka honey extract—MyboClean (Danelli Ocular Creations). Manuka

was found to be equal to tea tree oil in effectiveness, but unlike tea tree oil, there is no burning, discomfort or irritation.<sup>2</sup> In fact, the combination of Manuka, aloe and coconut oil in MyboClean makes it a comfortable treatment.

“**The Dry Eye Drink (Bruder Healthcare) has greatly helped my dry eye patients, especially those with Sjögren’s syndrome.**”

Another addition is light modulation low-level light therapy, which works as a stand-alone or adjunctive therapy to intense pulsed light (IPL) therapy. I regularly see resolution of hordeola and early chalazion for MGD, and when combined with IPL, it dissolves ocular rosacea signs and symptoms. I am partial to IPL systems that have self-cooling heads and don’t require conductive gel, as they allow treatment of far more skin types, no messy gel removal and, in my experience, excellent results. It’s one of the few technologies that can take patients with no MG expression and after four weekly treatments have them functioning at optimal expression levels.

The Dry Eye Drink (Bruder Healthcare) has greatly helped my dry eye patients, especially those with Sjögren’s syndrome. These nutritional hydration drinks show significant increased water absorption combined with key anti-inflammatory ingredients. Sjögren’s syndrome patients frequently tell me they have decreased the need for water intake.

Vitamin A ointment QHS (Hyo Night, Optase) has been a savior for many patients when it comes to mucin-deficient DED.<sup>3,4</sup>

Inadequate lid seal, the number one cause for non-responsive DED, is highly underdiagnosed. Morning symptoms are pathognomonic, and the hypoallergenic, oxygen-permeable, latex-free SleepTite/SleepRite (Eye SleepTite) night seals have “cured” more dry eye than almost any product in my clinic.

### Oldies But Goodies

I continue to be impressed with the improvement in MG secretions after patients use the Bruder Moist Heat Eye Compress (Bruder Healthcare).

Punctal plugs have risen to a new level with tapered six-month dissolvable plugs (Oasis Medical) and Form Fit long-term intracanalicular plugs (Oasis Medical). The latter innovation has moved me away from surface plugs that have poor retention and may irritate the ocular surface. Vertical canal punctal occlusion technologies have provided a solid treatment option for patients with a negligible tear meniscus, with little to no complications.

DED is optometry’s domain, which is confirmed with the fact that our profession prescribes over 60% of all OSD and DED drops. Managing this immensely large patient population takes knowing about the new and effective options. ■

1. Paulsen AJ, Cruickshanks KJ, Fischer ME, et al. Dry eye in the beaver dam offspring study: prevalence, risk factors and health-related quality of life. *Am J Ophthalmol.* 2014;157(4):799-806.

2. Frame K, Cheung IMY, Wang MTM, et al. Comparing the in vitro effects of MGO Manuka honey and tea tree oil on ocular *Demodex* viability. *Cont Lens Anterior Eye.* 2018;41(6):527-30.

3. Tseng SC, Maumenee AE, Stark WJ, et al. Topical retinoid treatment for various dry eye disorders. *Ophthalmology.* 1985;92(6):717-27.

4. Kim EC, Choi JS, Joo CK. A comparison of vitamin A and cyclosporine a 0.05% eye drops for treatment of dry eye syndrome. *Am. J Ophthalmol.* 2009;147(2):206-13.e3.

About  
Dr. Karpecki

Dr. Karpecki is the director of Cornea and External Disease for Kentucky Eye Institute and an associate professor at KYCO. He is the Chief Clinical Editor for Review of Optometry and chair of the New Technologies & Treatments conferences. A fixture in optometric clinical education, he consults for a wide array of ophthalmic clients, including ones discussed in this article. Dr. Karpecki’s full disclosure list can be found in the online version of this article at [www.reviewofoptometry.com](http://www.reviewofoptometry.com).





# More Moisture<sup>1</sup> for Your Contact Lens Patients

## Biotrue® Hydration Plus Multi-Purpose Solution



### More Moisture for Contact Lenses<sup>1</sup>

- **25% MORE** hyaluronan (HA)<sup>2</sup> means **MORE MOISTURE** to lenses in the first 12 hours of wear<sup>3</sup>



### Ingredients Informed by TFOS DEWS II

- Essential electrolyte (potassium) found in natural tears
- Osmoprotectant/antioxidant<sup>4</sup> (erythritol) helps maintain ocular surface homeostasis under hyperosmotic stress<sup>5</sup>



### Exceptional Cleaning and Disinfection

- Removes dirt and protein buildup for clear, clean lenses
- Kills 99.9% of germs tested<sup>6</sup>



### Clinically Tested for Comfort

- Excellent patient ratings for overall comfort, cleanliness at removal and overall impressions

<sup>1</sup>For up to 12 hours compared to original Biotrue Multi-Purpose Solution, based on a laboratory study.

<sup>2</sup>Compared to original Biotrue Multi-Purpose Solution.

<sup>3</sup>Based on a laboratory study.

<sup>4</sup>Antioxidant protects hyaluronan against free radicals.

<sup>5</sup>Data on file. Bausch & Lomb Incorporated. Rochester, NY.

<sup>6</sup>Standardized Testing (ISO 14729) against *S. aureus*, *P. aeruginosa*, *S. marcescens*, *C. albicans*, *F. solani*.

Discover our extended line of Biotrue® products at

[biotrue.com](https://biotrue.com)

**BAUSCH + LOMB**



# Focus on You

*Don't get distracted by all the hubbub.*

To be successful in optometry, focus all of your attention on one thing and one thing only. No, not the patient... that's the easy part. Not vision plans. Not location, location, location. Not online marketing, websites, TikTok, X (formerly known as Twitter) or Instagram.

It's YOU. Focus on YOU.

We verge off track every time we lose sight of this simple fact. Now, I am old and crotchety... and I always had the crotchety part down since I was, oh, nine years old when I realized I had nearly zero control over so many things and could only control one thing (barely)—ME. Well, "control" might not be the most accurate analysis of what I did to make sure everyone knew I was in the room, applying my self-proclaimed intelligence in any manner that made me feel important—no matter what the cost.

So, the young and crotchety me learned a lot as the old and still crotchety me slowly developed so I could focus on myself by not focusing on inserting ME on everyone else, which is what I naively and selfishly thought I had to do.

You simply cannot be successful in optometry if your joy in practicing wraps solely around what your patients, staff, vendors, financial advisors, bankers, lawyers, the lady who gives you cheese samples at the local farmer's market, kids, spouse and dog... what THEY do for you. (I may make an exception for the cheese lady.) Joy in our (and anybody's) profession comes from YOU—your growth, heart, actions and, very often, your grateful and humble acceptance of your superpowers and foibles as equally

dangerous when applied incorrectly.

The wonderful, late Dr. Burt Hooten tried to beat this into our rigid undergrad heads (and therefore competition-addicted mounds of mush) by reminding us that we each are unique and we would find patients who liked this about each us. Wish I had listened better. Could have saved me many sleepless nights when I did everything right and the patient still thought I was an ignoramus.

What steps can you take to change your focus from all the hubbub to YOU?

1. Quit the search for perfection. Even Steph Curry and Caitlin Clark miss foul shots occasionally. Ask anybody betting on the spread in Vegas.

2. Read something that's not on a device. Anything. Read a pickle jar label or something and then work your way up to James Michener's *Centennial*. May take a while.

3. Men—stop shaving for a couple weeks. No, once I think about it, don't do that. You'll look like a bum.

4. Women—I have been married for almost 44 years. I know better than to give any woman advice. Y'all just do what you want and it will be OK.

5. Laugh uncontrollably. Giggles and little smiles don't count. If that seems impossible for you, eat a gummi and go to any random CE meeting. Of course I am recommending a Haribo gummi bear. What did you think I meant, anyway?

6. Make someone else laugh. OK, not everyone is funny and not everyone who IS funny is ALWAYS funny. My column is proof enough of that. But EVERYONE can stick two straws up their nose and burp. Works every time and I WILL get that into this column one day.

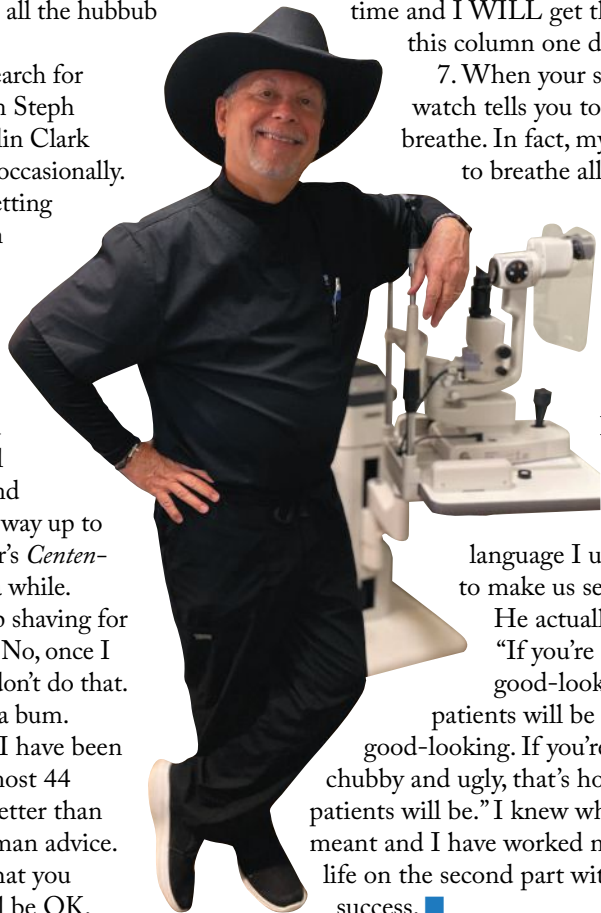
7. When your smart-watch tells you to breathe, breathe. In fact, my advice is to breathe all the time.

Does that make me smarter than my watch? Dr.

Hooten didn't precisely use the

language I used above to make us self-aware.

He actually said, "If you're tall and good-looking, your patients will be tall and good-looking. If you're short, chubby and ugly, that's how your patients will be." I knew what he meant and I have worked my entire life on the second part with much success. ■



About  
Dr. Vickers

Dr. Vickers received his optometry degree from the Pennsylvania College of Optometry in 1979 and was clinical director at Vision Associates in St. Albans, WV, for 36 years. He is now in private practice in Dallas, where he continues to practice full-scope optometry. He has no financial interests to disclose.

From the makers of the #1-prescribed dry eye brand in Europe\*

## Covering the spectrum of

# Dry Eye Relief

Over-the-counter iVIZIA® lubricant eye drops protect the ocular surface and deliver a unique combination of immediate and long-lasting relief in a **preservative-free** formulation.

- A unique formulation—including povidone (active), trehalose (inactive), and hyaluronic acid (inactive)
- Proprietary, **multi-dose preservative-free (MDPF)** bottle

### Chronic Dry Eye Patient Usage Study†:

Up to  
**8 hours**  
of relief

as well as improved comfort during computer work, reading, and driving¹

**84%**

of users reported iVIZIA worked better than their previous eye drops¹



Safe for use with contact lenses‡



Recommend iVIZIA and request samples by visiting [iVIZIA.com/ECP](https://www.theapharma.com/iVIZIA.com/ECP)

Scan here.

\*Prescription market data, Dec. 2022 - S01K without cyclosporine.

†In a chronic dry eye patient usage study, participants from a variety of socioeconomic backgrounds answered questions about their experience with iVIZIA lubricant drops. In the study, 203 chronic dry eye patients, 28-80 years old, switched from their dry eye artificial tears to iVIZIA for a month.¹

‡To limit blurriness when using contact lenses, remove contacts, apply drops, then insert contacts.

Reference: 1. Thea Data on File.

Copyright ©2024 Thea Pharma Inc. | All Rights Reserved. | PRC-IED-1030-v4 1.2024





EDITED BY PAUL C. AJAMIAN, OD

## CLINICAL QUANDARIES

# When is RK Not OK?

*Refractive surgery performed years ago can come back to haunt patients undergoing cataract extraction.*

**Q I have a patient who had radial keratotomy (RK) many years ago who now needs cataract surgery. Are there any special considerations?**

**A** “RK, photorefractive keratectomy (PRK) and LASIK can have a profound effect on cataract surgery outcomes, says Tania Patel, OD, of Commonwealth Eye Surgery in Lexington, KY.

Patients with RK have irregular and fluctuating corneas that can change through the course of the day, affecting initial measurements, IOL calculations and post-op outcomes. The RK cuts that were made change the entire structure of the cornea.<sup>1</sup> The integrity of the cornea is never the same with someone who has had RK, no matter when it was performed. LASIK and PRK can also affect cataract outcomes, and patients need to be warned that their post-op journey may not be as smooth.

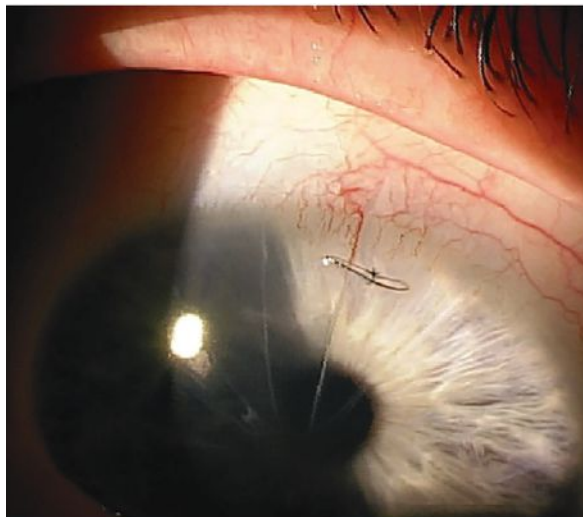
“I always discuss the whole process with the patient during their initial cataract surgery evaluation,” says Dr. Patel. “I inform the patient that their cornea is irregular from the RK or other refractive surgery and that we modify our formulas and IOL calculations to account for that.” A step beyond formula adjustment is Alcon’s ORA system, which takes intraoperative refraction and wavefront aberrometry measurements prior to lens placement to reduce refractive surprise.

Dr. Patel usually does not recommend femtosecond laser-assisted cataract surgery

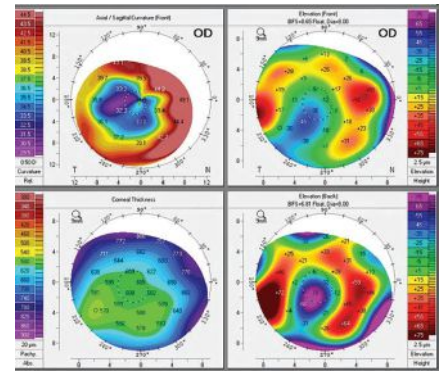
(FLACS) or “premium” lenses in post-RK eyes. Thickened incisional scars are potential sources of incomplete laser penetration, and imperfect ocular surfaces do not fare well with multifocal implants. Toric lens implantation in RK eyes may provide unpredictable astigmatism correction and should be avoided in most cases.<sup>2</sup>

“The best option for patients with RK is usually a standard monofocal lens,” Dr. Patel says. “We have also had success with the Light Adjustable Lens (LAL) in patients who are status post-RK, -LASIK or -PRK and are willing to pay significant out-of-pocket money for an adjustable monofocal.

Though rare, there is the chance that the RK cuts may open during cataract surgery and require suturing. Higher numbers of RK cuts increase the chance of the cuts unzipping during surgery. With an eight-cut-or-fewer RK inci-



**Cataract surgery patient with sutured RK cut.**



**Corneal topography of a patient with RK.**

sion, the surgeon can usually slip the incisions in between two of the RK cuts. With 12 cuts or more, they may have to revert to a scleral tunnel incision.<sup>1</sup>

ODs can remove the suture in clinic four to six weeks after surgery using a beaver blade and jeweler’s forceps behind the slit lamp. Prescribe an antibiotic drop or ointment in the eye for a few days following.

“I believe that the most important task for the OD performing the pre-surgical evaluation and then referring the patient for cataract surgery is educating the patient about the possible complications due to their history of RK and LASIK and setting realistic expectations,” Dr. Patel says.

“Educate your post-refractive surgery patient that their vision may fluctuate significantly after cataract surgery, and they will need to exercise patience before achieving their final visual goal.” Let the surgeon know what you discussed by sending a detailed referral form or letter, which will make everyone look better in the long run. ■

1. Stephenson, M. Cataract/IOL surgery after RK. *Rev Ophthalmol.* 2021;28(10):38-40.

2. Trinh T, Solomon B, Mimouni M, et al. Outcomes of femtosecond laser-assisted cataract and refractive lens surgery in patients with prior radial keratotomy. *J Cataract Refract Surg.* 2022;48(4):449-55.

**About Dr. Ajamian**

**Dr. Ajamian** is board certified by the American Board of Optometry and serves as Center Director of Omni Eye Services of Atlanta. He is vice president of the Georgia State Board of Optometry and general CE chairman of SECO International. He has no financial interests to disclose.

# Better Together

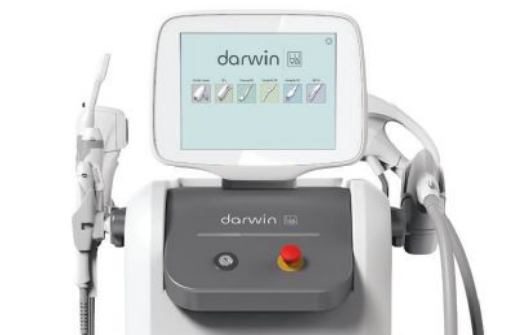

DARWIN™ IPL & RF Treatments in One Device from OCULUS

darwin™



Scan here to  
learn more



 OCULUS®

[www.oculususa.com](http://www.oculususa.com)  
425-670-9977

Medscape **LIVE!** PRESENTS

# 2024 CE CONFERENCES

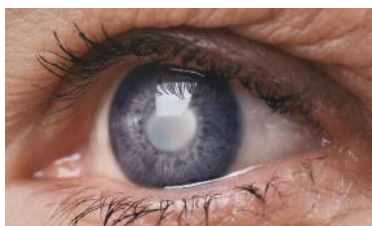## IN-PERSON



### CULAR SURFACE SYMPOSIUM

**SEPTEMBER 8, 2024**RENAISSANCE CHICAGO DOWNTOWN HOTEL  
CHICAGO, ILLINOIS[www.reviewedu.com/oss](http://www.reviewedu.com/oss)

NEW  
TECHNOLOGIES  
& TREATMENTS IN  
EYE CARE 

**NOVEMBER 15–17, 2024**GRAND HYATT NASHVILLE  
NASHVILLE, TENNESSEE[www.reviewedu.com/ntt\\_ies\\_fall](http://www.reviewedu.com/ntt_ies_fall)

 WEST COAST  
OPTOMETRIC GLAUCOMA  
SYMPOSIUM

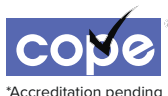**DECEMBER 6–7, 2024**THE WESTIN CARLSBAD  
CARLSBAD, CALIFORNIA[www.reviewedu.com/wcogs](http://www.reviewedu.com/wcogs)

THE OPTOMETRIC RETINA SOCIETY AND REVIEW EDUCATION GROUP PRESENT

### RETINAUPDATE2024

**DECEMBER 7–8, 2024**THE WESTIN CARLSBAD  
CARLSBAD, CALIFORNIA[www.reviewedu.com/orsretupdate](http://www.reviewedu.com/orsretupdate)

For a full list of Review Education Group CE events,  
scan the QR code or visit: [www.reviewedu.com/events](http://www.reviewedu.com/events)

Postgraduate Institute  
for Medicine**REVIEW**  
Education GROUP



BY JEROME SHERMAN, OD, AND SHERRY BASS, OD

## YOU BE THE JUDGE

# Puppy Love Blindness

*The rare case of red eye that does not respond to treatment can have a disastrous outcome.*

**A**n 18-year-old male college student presented early on a Monday morning to his hometown eye clinician in New York City with a one-day history of what he believed was likely a corneal infection after being scratched in his left eye by the nose of his beloved puppy. He was a low myope who occasionally wore contact lenses (CLs) for driving and in class but was not wearing them at the time of the incident. However, he immediately recognized that inserting his CLs after the scratch from the nose of his dog would not be wise.

At presentation, he noted mild discomfort in his left eye that had not changed since the previous day. His unaided VA was 20/25 in each eye, which improved to 20/20 with a pinhole. Biomicroscopy revealed a 2mm abrasion slightly nasal to the visual axis in his left eye only, which did stain with fluorescein dye. Intraocular pressure measurements were not taken. His record contained a sketch of the abrasion, but anterior segment photos were not obtained. The left eye was slightly more hyperemic than the right eye. There was no anterior chamber reaction in either eye. The remainder of the external exam was normal, as was the undilated fundus exam in both eyes. The diagnosis was a mild corneal abrasion in the left eye, and the clinician decided to prescribe an antibiotic/corticosteroid drop (Blephamide, Allergan) in the left eye QID for five days.

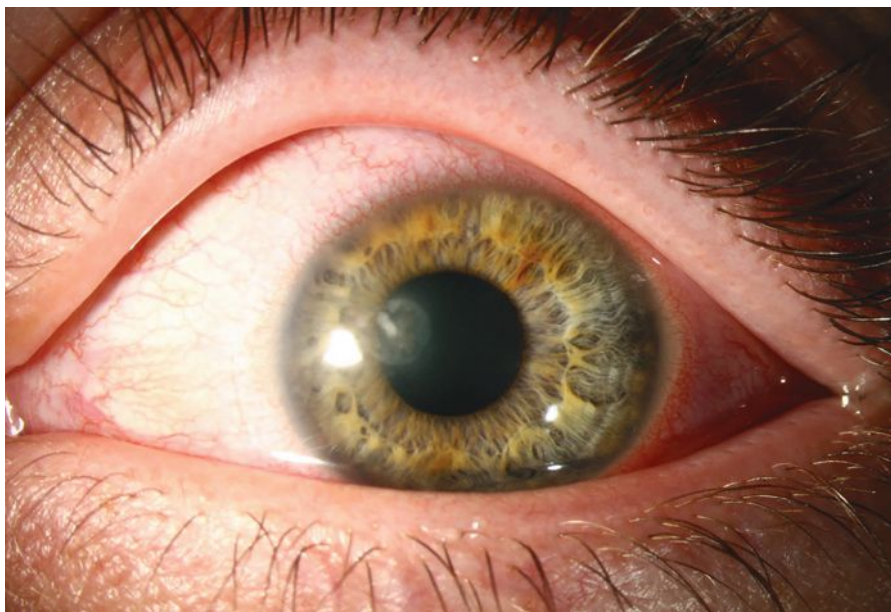A follow-up exam was scheduled the next day, but no improvement in symptoms or clinical exam were noted. A second follow-up exam the following day yielded the same findings. Because of the failure to improve, the patient was seen two more times, but the exam results were essentially unchanged. On Saturday morning on the sixth consecutive daily visit, the eye clinician observed what he thought might be a very small and shallow infiltrate at the same location of the initial lesion. After discussing the options with the college student, the patient was sent to the emergency department (ED)

of a large hospital, requesting a corneal culture. A consultant cornea specialist at the hospital evaluated the patient late Saturday afternoon, obtained a culture and speculated that the corneal abrasion from the dog's nose may have contained a fungus and immediately began local and systemic antifungal treatment. The corneal culture later confirmed the presence of a fungus, specifically *Fusarium*.

### You Be the Judge

Considering the facts presented thus far, opine on the following questions:

- Are fungal infections from a scratch caused by a dog's nose a common clinical encounter?
- Will treating a superficial corneal abrasion with antibiotic/corticosteroid eye drops allow the fungus (if present) to infect deeper layers of the cornea?
- Do cornea specialists recommend not to treat a corneal infection with



**A corneal infiltrate (in a different patient) resembling an abrasion in a mildly hyperemic left eye confirmed later to be fungal keratitis.**

Photo: University of Iowa

#### About Drs. Sherman and Bass

**Dr. Sherman** is a Distinguished Teaching Professor at the SUNY State College of Optometry and editor-in-chief of *Retina Revealed* at [www.retinarevealed.com](http://www.retinarevealed.com). During his 53 years at SUNY, Dr. Sherman has published about 750 various manuscripts. He has also served as an expert witness in 400 malpractice cases, approximately equally split between plaintiff and defendant. Dr. Sherman has received support for *Retina Revealed* from Carl Zeiss Meditec, MacuHealth and Konan. **Dr. Bass** is a Distinguished Teaching Professor at the SUNY College of Optometry and is an attending in the Retina Clinic of the University Eye Center. She has served as an expert witness in a significant number of malpractice cases, the majority in support of the defendant. She serves as a consultant for ProQR Therapeutics.

steroids until a fungal infection has been ruled out?

- How much experience with fungal corneal infections do eye clinicians have practicing in New York?
- Regardless of the outcome, should the eye clinician not be held culpable of malpractice, since he examined the patient for six consecutive days and then referred to an ED for a corneal culture?

### Follow-Up and Allegations

Although the patient was treated aggressively for the fungal infection about a week after the abrasion, the patient's condition worsened. After three corneal transplants and two glaucoma procedures, the patient still had profound loss of vision. Additional surgery was being contemplated. The eye clinician who provided the care for six consecutive visits was sued for misdiagnosis, not considering a fungal contamination, treating the patient with antibiotic/corticosteroid eye drops without first ruling out a fungal infection and failure to refer to a cornea specialist in a timely manner. The specialist who performed the three corneal transplants was also sued for incompetent surgery.

### Opinion

I (JS) was requested to review all the available information, including the surgical notes and most recent exams. Prior to completing my review of the numerous documents, reading several of the depositions that had already been obtained, review of the literature and furnishing an opinion, the case was settled for an undisclosed substantial amount against the eye clinician and the cornea surgeon.

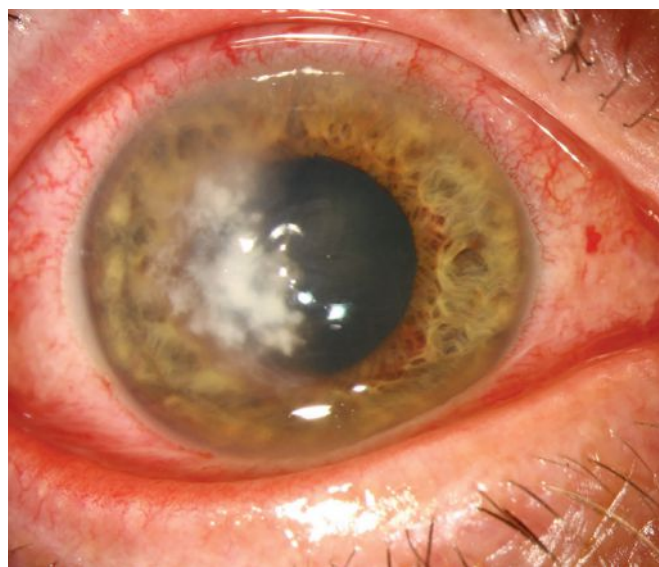### Comments

Fungal keratitis is typically a slow, relentless corneal infection that can easily be misdiagnosed as a bacterial infection, which accounts for the majority of the microbial corneal infections. Suspicion should be high in cases of trauma with vegetable matter and around the holiday season, as Christmas tree branch-induced abrasion has been suspected and confirmed in a significant number of cases.

Vegetative ocular trauma is undoubtedly the most common risk factor for fungal keratitis. In contrast, a less-than-extensive review of the world's literature yielded virtually nothing about a corneal abrasion from a dog's nose resulting in a fungal corneal infection. In most cases, eye trauma, corticosteroid use and/or contact lenses are predisposing factors.<sup>1</sup>

In the United States, incidence of fungal keratitis as the etiology of all cases of keratitis varies dramatically. In New York, only 2% of cultured keratitis cases are proven to be due to a fungus, but in Florida 35% are proven to be of fungal etiology. Eye clinicians practicing at Bascom Palmer Eye Institute in Miami report encountering corneal abrasions due to a fungus as rather routine. *Fusarium* species are the most common cause of fungal keratitis infection in the South; *Candida* and *Aspergillus* species are more common in northern states.

Antifungal topical agents include natamycin (Natacyn, Alcon) and amphotericin B (Fungisone, Apoteco) as well as at least five systemic medicines, but eye drops alone may have limited corneal penetration. Symptoms of fungal keratitis include foreign body sensation, increasing pain or discomfort, decrease in vision and hypersensitivity to light. But of course, these symptoms do not differentiate between fungal, bacterial and viral etiologies. Feathery margins of the corneal infiltrate and elevated edge are more helpful signs for the differential diagnosis. Many conservative cornea specialists advise against using a steroid eye drop until a fungal infection has been ruled out, especially if the history yields any evidence of a possible fungal infection.



**A corneal infiltrate with feathery edges in a red eye of a different patient proven to be due to a fungal infection.**

Photo: University of Iowa

In another illustrious case, a woman working at Disney World in Orlando presented with a history of "dirt" in her eye kicked up by an elephant. This patient was also treated with an antibiotic/corticosteroid drop with similar disastrous results. It appears that the topical steroid allows the fungal infection to invade the corneal stroma even though this may go undetected with a biomicroscopic exam. The steroid helps mask the symptoms while, simultaneously, the condition worsens.

In the real world, combination eye drops containing an antibiotic and a steroid are enormously popular and effective in many cases. However, if the history in any way suggests a possible fungal infection, beware. ■

1. Moon C. Fungal keratitis. EyeWiki. [eyewiki.aao.org/fungal\\_keratitis](http://eyewiki.aao.org/fungal_keratitis). November 9, 2023. Accessed March 20, 2024.

NOTE: This article is one of a series based on actual lawsuits in which the author served as an expert witness or rendered an expert opinion. These cases are factual, but some details have been altered to preserve confidentiality. The article represents the authors' opinion of acceptable standards of care and do not give legal or medical advice. Laws, standards and the outcome of cases can vary from place to place. Others' opinions may differ; we welcome yours.



# Perspectives on **lasting comfort** for **contact lens wearers**




**Eric Brooker, OD**

Advanced Vision Institute, Las Vegas, Nevada

## White Paper: **Improving contact lens comfort through dry eye management**

**Dr. Eric Brooker** unveils the hidden challenges behind contact lens dropouts and offers actionable insights for clinics seeking to transform patient experiences.

Discover practical techniques for diagnosing and treating underlying dry eye conditions, fostering long-term patient satisfaction and growth for your practice.



**Get the free PDF:** [lacrivera.com/Brooker](https://lacrivera.com/Brooker)

A FRESH PERSPECTIVE™

[lacrivera.com](https://lacrivera.com) (855) 857-0518

2500 Sandersville Rd • Lexington KY 40511 USA





BY BISANT A. LABIB, OD

## THE ESSENTIALS

# Provoked Proteins

*Two blood tests can offer greater insight about whether an inflammation-causing eye condition is present.*

One unique thing about an ocular examination is its ability to elucidate features of underlying systemic health. As such, laboratory testing is commonly used to confirm or augment clinical findings. A frequently ordered set of laboratory tests are the erythrocyte sedimentation rate (ESR) and C-reactive protein (CRP). To best optimize the use of these tests in clinical practice, it is important to understand how and why they are measured as well as the significance of their values.

Both the ESR and CRP are basic blood tests used to assess the presence of inflammation in the body. However, they have low specificity, making it somewhat difficult to effectively employ in the diagnosis of a specific disease. Though they are both general markers for inflammation, their mechanisms are different, allowing for some interpretation in their respective values, both separately and together.<sup>1,2</sup>

## ESR

The principle of this lab test depends primarily on the properties of red blood cells. Also known as erythrocytes, they typically possess a negative charge and repel each other, keeping them suspended in blood. In the case of inflammation or injury, the liver produces increased levels of proteins such as fibrinogen and immunoglobulins. These proteins are positively charged and act as bridges between erythrocytes, causing them to clump them together. This leads to red blood cells becoming heavier and settling more quickly at the bottom of a test tube.

The rate of sedimentation of red blood cells over time, usually over 60 minutes, is the basis of the ESR test, measured in millimeters per hour (mm/hr).<sup>1,2</sup> Elevations in fibrinogen levels are not limited to inflammatory diseases alone, but also exist in conditions such as systemic infection, malignancy, diabetes or collagen vascular disease—all of in which inflammation is a byproduct.<sup>3</sup>

A unique distinguishing feature of the aforementioned plasma proteins is that many possess a long half-life and subsequently longer, amplified response time. As a result, ESR values will often have a slow initial rise, then slowly

normalize, when compared with other acute phase proteins. This also allows for its use not only in the diagnosis of underlying inflammatory conditions, but also in monitoring disease activity.<sup>2,4,5</sup>

ESR values naturally increase with age as well as in pregnant patients.<sup>6,7</sup> Due to these typical fluctuations of erythrocytes, the general calculation to determine the normal or reference range involves dividing the age—in number of years—by two for men, and the age plus 10 divided by two for women. Other factors contributing to abnormal ESR values include conditions that impact the quality and quantity of red blood cells in general, such as anemia, polycythemia and other erythrocyte hemoglobinopathies.<sup>3</sup>

## CRP

This blood test is another way to measure inflammation in the body. Much

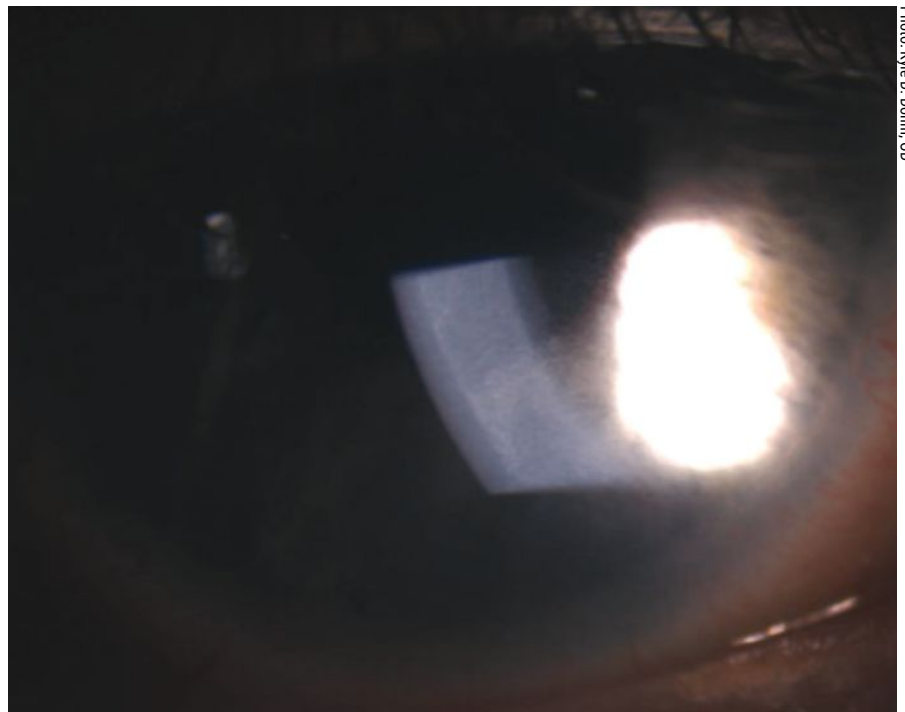


Photo: Kyle D. Dohm, OD

**Uveitis, pictured here, is one ocular condition with marked inflammation, which would be indicated upon ESR or CRP testing.**

About  
Dr. Labib

Dr. Labib graduated from Pennsylvania College of Optometry, where she now works as an associate professor. She completed her residency in primary care/ocular disease and is a fellow of the American Academy of Optometry and a diplomate in the Comprehensive Eye Care section. She has no financial interests to disclose.

## LANDMARK CLINICAL TRIAL DEMONSTRATES POSITIVE IMPACT ON GLAUCOMA TREATMENT

A new study published in *Ophthalmology* concluded that timolol microdrops delivered with the Nanodropper® Adaptor appear to be as effective in ocular hypotensive action as conventional drops with improved resting heart rate and blood pressure stability.

**N**anodropper, Inc., an ophthalmic device company announced publication of “An Evaluation of the Efficacy and Safety of Timolol Maleate 0.5% Microdrops Administered with the Nanodropper” in the journal *Ophthalmology*. The Nanodropper® Adaptor has been shown to reduce eyedrop size by 62% on average. A smaller drop extends the number of doses yielded per medication bottle (up to 100 drops/mL).

The study found that timolol microdrops had an improved safety profile in the form of less heart rate reduction yet did not significantly differ from conventional drops in intraocular pressure (IOP)-lowering efficacy.

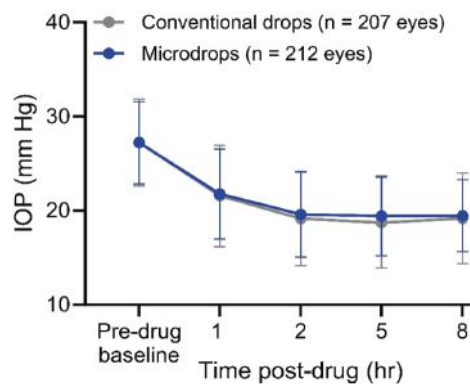
“We are thrilled, albeit not surprised, by these encouraging results demonstrating the Nanodropper Adaptor’s capacity to improve patient safety.”

-Jennifer Steger, PhD  
CSO of Nanodropper

### Study Design

The study employed a prospective, non-inferiority, parallel, multicenter, single-masked, active-controlled,

randomized trial design. Treatment-naïve subjects received either one commercially available drop (28 µL) or one microdrop (12.5 µL) of timolol — IOP, resting heart rate, and blood pressure were measured at baseline and 1, 2, 5, and 8 hours after administering the drop.



### Findings

Nanodropper established IOP non-inferiority to conventional drops at three of four timepoints, and the average heart rate decrease with Nanodropper was around three beats per minute less than in the conventional drops group, meaning heart rate fluctuated less and thus remained more stable with administration of microdrops.

The conclusion supports the Nanodropper Adaptor as a tool for optimizing topical management of ophthalmic conditions, particularly in enhancing safety profiles and reducing waste.



### Bring Nanodropper to Your Practice

Thousands of eyecare clinics in the U.S., and tens of thousands of patients worldwide, are already utilizing the Nanodropper Adaptor.

Join the Nanodropper partner clinic network and the movement towards reducing the waste and cost of eyedrop medications while improving patient outcomes. As a partner clinic, you can utilize Nanodropper on in-office drops and dispense to patients for home medications.

Use discount code **ROM10** for 10% off your order



[nanodropper.com/ReviewOptpro@nanodropper.com](https://nanodropper.com/ReviewOptpro@nanodropper.com)  
**(507) 405-5676 ext.2**

TABLE 1. SUMMARIZATION OF THE INTRICACIES BETWEEN BOTH TESTS

Laboratory Test	Protein Interaction	Timing	Associated Conditions
ESR	Red blood cell clumping with fibrinogen and immunoglobulin	24 to 48 hour rise and slow normalization	<ul style="list-style-type: none"> <li>• Temporal arteritis</li> <li>• Uveitis secondary to infectious etiologies</li> </ul>
CRP	Release of CRP to aid in immune response	Four to six hour rise and fast normalization	<ul style="list-style-type: none"> <li>• Temporal arteritis</li> <li>• Uveitis secondary to autoimmune or collagen vascular disease</li> </ul>

like the basis of ESR, this measurement relies on release of CRP by the liver in response to inflammation caused by infection, tissue injury or autoimmune diseases.<sup>8</sup>

CRP is a pattern-recognition protein that is part of the acute phase of the innate immune response. It is produced in the liver in inflammatory conditions to assist in cellular processes such as complement binding and phagocytosis, and potentially in the clearance of apoptotic cells. In contrast to ESR, CRP levels typically rise within a few hours of inflammation and decrease as the body heals.<sup>9</sup> Additionally, the CRP level is proportional to the intensity of inflammation.<sup>3</sup>

There are two main types of CRP measurements. The first is standard, measuring the overall level of CRP in the blood. There is an additional high-sensitivity CRP that detects even minor CRP elevations, making it particularly useful for assessing cardiovascular disease risk.<sup>10</sup>

CRP levels are typically reported in milligrams per liter (mg/L) and can vary slightly depending on the lab with regards to the normal or reference range. Generally speaking, low CRP is classified to be below 10mg/L and is suggestive of minimal inflammation. Moderately elevated CRP is approximately 10mg/L to 20mg/L, indicating possible infection or inflammation, while highly elevated levels are usually above 20mg/L, suggestive of significant inflammation.<sup>11</sup>

### Ocular Connection

Both ESR and CRP provide similar information, are relatively inexpensive, readily available and have low specificity. However, using both tests in tandem can offer the most clinical utility in diagnoses and monitoring of inflammatory disease processes. As previously mentioned, these two tests differ in peak measurement. CRP is initially elevated and serves as an acute marker for disease, typically within four to six hours; ESR often peaks later on, around 24 to 48 hours. CRP will also normalize much quicker with treatment, whereas the ESR levels can take weeks, allowing for better long-term disease monitoring.<sup>3</sup>

There are many ocular diseases in which inflammation is a key factor, potentially leading to abnormalities in these ancillary tests. The two most common and relevant clinical scenarios are temporal arteritis and uveitis. Elevations in ESR and CRP levels, for example, are often diagnostic for temporal arteritis or polymyalgia rheumatica in conjunction with the clinical picture.<sup>12</sup>

Uveitis is a manifestation of numerous underlying systemic conditions, many of which would result in elevated ESR and/or CRP values. While uveitis in and of itself is inflammation, regardless of cause, studies have shown that first attacks of uveitis do not often lead to abnormal laboratory values. However, elevated levels of ESR and CRP suggest a systemic process causing uveitis. Further investigation has also

attributed elevations in ESR to be due to autoimmune or collagen vascular disease etiologies, whereas abnormal CRP was more associated with trauma and infectious causes.<sup>3,13</sup>

When taken together, both ESR and CRP laboratory tests can be helpful in the clinical setting. Understanding the nuances of each test and why they are measured will give the clinician the highest yield in the diagnosis and monitoring of diseases with inflammatory components. ■

“ Both ESR and CRP provide similar information, are relatively inexpensive, readily available and have low specificity. ”

1. Lee, GR. Erythrocyte sedimentation rate. *Korean J Lab Med.* 2011;31(6):438-46.
2. Sed rate (erythrocyte sedimentation rate). Mayo Clinic. [www.mayoclinic.org/tests-procedures/sed-rate/about/pac-20384797](http://www.mayoclinic.org/tests-procedures/sed-rate/about/pac-20384797). September 21, 2023. Accessed March 20, 2024.
3. Bray C, Bell LN, Liang H, et al. Erythrocyte sedimentation rate and C-reactive protein measurements and their relevance in clinical medicine. *WMJ.* 2016;115(6):317-21.
4. Erythrocyte sedimentation rate (ESR). National Library of Medicine. [medlineplus.gov/lab-tests/erythrocyte-sedimentation-rate-esr](https://medlineplus.gov/lab-tests/erythrocyte-sedimentation-rate-esr). Last updated November 8, 2022. Accessed March 20, 2024.
5. Mittal S, Gupta N, Awasthi S. Erythrocyte sedimentation rate in normal pregnancy. *J Clin Diagn Res.* 2014;8(8):CL01-03.
6. McPherson RA, Pincus MR. *Henry's clinical diagnosis and management by laboratory methods.* 23rd edition. Elsevier Inc.; 2017.
7. Singh G, Bombardier C, Clégg LA, et al. Defining clinically important improvement in rheumatoid arthritis. *Arthritis Rheum.* 2000;43(2):343-51.
8. Pepys MB, Hirschfield GM. C-reactive protein: a critical update. *J Clin Invest.* 2003;111(12):1805-12.
9. Ridker PM. C-reactive protein: a simple test to identify a greater risk of future cardiovascular disease. *J Clin Invest.* 2003;111(6):977-83.
10. Pearson TA, Mensah GA, Alexander RW, et al. American Heart Association C-Reactive Protein Writing Group. Markers of inflammation and cardiovascular disease: application to clinical and public health practice: a statement for healthcare professionals from the Centers for Disease Control and Prevention and the American Heart Association. *Circulation.* 2003;107(3):499-511.
11. C-reactive protein test. Mayo Clinic. [www.mayoclinic.org/tests-procedures/c-reactive-protein-test/about/pac-20385228](http://www.mayoclinic.org/tests-procedures/c-reactive-protein-test/about/pac-20385228). December 22, 2022. Accessed March 20, 2024.
12. Chan FLY, Lester S, Whittle SL, Hill CL. The utility of ESR, CRP and platelets in the diagnosis of GCA. *BMC Rheumatol.* 2019;10(3):14.
13. Groen-Hakan F, Eurelings L, van Laar J, Rothova A. Relevance of erythrocyte sedimentation rate and C-reactive protein in patients with active uveitis. *Graefes Arch Clin Exp Ophthalmol.* 2019;257(1):175-80.


## EXPERTS:




Esen Karamursel Akpek,  
MD (Moderator)  
Wilmer Eye Institute



Giacomina Massaro-  
Giordano, MD  
Scheie Eye Institute



Paul Karpecki, OD  
Kentucky Eye  
Institute



Jacob Lang, OD  
Associated Eye Care

# Reaping the Benefits of Serum Tears In Practice

How leaders in ocular surface care are incorporating this important tool

**R**esearch has revealed the positive safety and efficacy profile of autologous serum eye drops (ASEDs) and their ability to improve the signs and symptoms of ocular surface manifestations.<sup>1,2</sup> Autologous serum eye drops have been shown to be particularly useful in patients who don't improve sufficiently with first-line therapy.<sup>1,2</sup>

A number of studies reveal that autologous serum drops perform better than conventional eyedrops in improving ocular surface health and patient comfort.<sup>3-5</sup> Significant improvements in tear stability, ocular surface vital staining scores, and pain symptom scores have been documented in patients treated with autologous serum compared to those treated with non-preserved artificial tears.<sup>6</sup> Patients with chronic and severe ocular surface disease report a 58% decrease in Ocular Surface Disease Index (OSDI) score as a result of using autologous serum eye drops.<sup>7</sup>

As more eye care providers include autologous serum tears in their armamentarium of therapeutic agents, they will want to identify the right patient candidates to try the therapy and consider how best to incorporate autologous serum tears into existing treatment protocols. This panel of eye care leaders has successfully added autologous serum eye drops into practice, and offers clinical and practical considerations on optimally using autologous serum tears in eye care practice today.

## Patient Considerations

**DR. AKPEK:** What types of patients would benefit from autologous serum tears?

**DR. MASSARO-GIORDANO:** Most patients with varying degrees (mild to severe) of ocular surface disease can benefit. These are patients with conditions that range from dry eye due to autoimmune conditions such as Sjögren's syndrome, rheumatoid arthritis, and thyroid eye disease, etc., in addition to those with graft-versus-host disease (GVHD), neurotrophic keratitis (NK), recurrent erosions, neuropathic pain, chemical burns, and Stevens-Johnson syndrome.

**DR. LANG:** Autologous serum eye drops (ASEDs) have very broad anti-inflammatory and regenerative properties, which give them a widespread application profile in eye care. I tend to reach for ASEDS in patients who have an inability to supplement their own cornea and ocular surface with the proper nutrients and growth factors found in healthy, natural tears. This includes many autoimmune patients, aqueous deficient dry eye patients, anyone with neurologic abnormalities (neurotrophic and neuropathic) of their cornea that may affect the supply of nerve growth factors and neurotrophins, as well as patients with other inflammatory corneal conditions including corneal erosions, and even poor wound healing after injury or surgery.

**DR. KARPECKI:** The great thing about autologous serum is that it can be utilized for many patient conditions. The obvious is dry eye disease,

especially keratoconjunctivitis sicca (KCS) and Sjögren's syndrome KCS. But other conditions also benefit significantly, such as NK, limbal stem cell deficiency, neuropathic corneal pain, GVHD, and superior limbic keratoconjunctivitis (SLK), to name a few.

**DR. AKPEK:** Autologous serum eye drops are particularly beneficial in healing punctate erosions or non-healing epithelial defects in the cornea and for maintenance treatment for patients who make no tears, among other uses.

**DR. AKPEK:** How do your patients benefit from autologous serum tears?

**DR. MASSARO-GIORDANO:** Often my patients report their eyes feel more comfortable after using autologous serum tears. The eyes look less irritated, and my patients are not using their artificial tears as often.

**DR. KARPECKI:** Most patients prefer serum tears over artificial tears for comfort. They like the fact that they are natural and derived from their own blood serum. And while patients experience the comfort of the drops upon instillation, the therapeutic benefits continue to help treat the disease.

**DR. LANG:** Patients benefit from a natural, biological therapeutic that is preservative-free and delivers the nutrients and biochemical support that their eye is unable to produce, or adequately produce. The

## CASE: Sjögren's Disease-Related DED

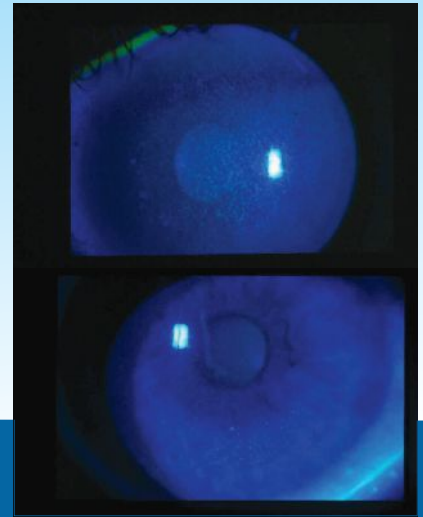
By Esen Karamursel Akpek, MD

A 63-year old female patient with Sjogren's disease-related dry eye presented for cataract surgery evaluation. Slit-lamp examination demonstrated significant corneal punctate erosions highlighted with topical fluorescein.

The patient, who had been on topical cyclosporine drops and over-the-counter preserved artificial tears for several years prior to presentation, was advised to switch to preservative-free artificial tears, and increase the topical cyclosporine drops from 2 to 4x daily. In addition, inferior permanent tear duct plugs were inserted and autologous serum tears at 50% concentration 4x daily were added to the regimen.

Eight weeks into the new treatment using autologous serum tears, slit-lamp appearance of the corneal fluorescein staining demonstrated significant improvement.

Slit-lamp examination demonstrated significant corneal punctate erosions highlighted with topical fluorescein (top). Eight weeks into the new treatment using autologous serum tears, slit-lamp appearance of the corneal fluorescein staining demonstrated significant improvement (bottom).



dosing schedule is also somewhat beneficial as the frequent instillation promotes hydrating effects as well.

**DR. AKPEK:** Autologous serum tears help optimally heal the patient's ocular surface and restore the homeostasis of the corneal epithelialization process in this important segment of patients.

## Prescribing Insights

**DR. AKPEK:** When prescribing autologous serum tears for dry eye, where do they fit into your treatment protocol?

**DR. MASSARO-GIORDANO:** They are the second step after the patient has tried artificial tears, immunomodulators, steroids, and more viscous tears and or ointments.

**DR. KARPECKI:** With some conditions, such as Sjögren's syndrome KCS, autologous serum tears are my initial or primary treatment. For other forms of dry eye, they become an option when corneal staining is not resolved with other drops. In these cases, I might begin with topical corticosteroids but if after one month I am seeing minimal resolution, I immediately start to add autologous serum tears.

**DR. LANG:** I find ASEDs lend themselves well when chronic and ongoing therapy is needed. This is not typically a pulsed or flare treatment, but an ongoing supplement and supportive therapy for the ocular surface. Many ocular conditions are chronic, and "cure" is not a common word in my clinics (unfortunately). In these cases, ongoing therapy with ASEDs makes a lot of sense. I also find myself discussing ASEDs more once the initial presentation is stabilizing but not resolving. It's a good option to keep the healing going.

**DR. AKPEK:** I follow the TFOS DEWS II guidelines in that we use a sliding scale to first address environmental factors, followed by preservative-free over-the-counter drugs, then prescription drugs, and treatments specifically for meibomian gland dysfunction. If the patient continues to exhibit corneal epithelial fluorescein staining despite the previous interventions, I find that autologous serum tears are often highly effective at this stage in alleviating symptoms and promoting healing of the ocular surface.

**DR. AKPEK:** How do you determine what concentration to order? How many times per day are your patients using autologous serum tears?

**DR. MASSARO-GIORDANO:** Studies vary. I do 50% 4x daily, although some other practitioners do 20% 6-8x daily, based on the significant effect that 50% concentration has had in several studies.<sup>1</sup>

**DR. KARPECKI:** It depends on the condition. For most dry eye patients, I typically begin with 20% or 25% concentration. However, if I'm dealing with NK or GVHD, I typically begin at 40% or 50%. I recommend 6 drops per day spaced out about every 2 hours while awake. Once the condition is showing improvement, patients may taper down to QID. However, many patients tell me that 6 times per day works best for them and continue with that dosing long-term. The 20% concentration, when the condition allows for it, enables the patient to obtain an ample amount of autologous serum drops.

**DR. LANG:** In general, much of the clinical research around ASEDs utilizes 20% serum,<sup>8</sup> although concentrations up to 100% have been used. Twenty percent tends to be the starting point as it mimics the concentrations of biologically active components in natural tears. I start with 30%, 6-8x per day, every 2 hours during waking hours, for most conditions.

**DR. AKPEK:** There's no evidence-based answer to these questions. It's based on experience. I believe that putting too many drops on the eye surface is detrimental, especially to meibum- or mucin-deficient dry eye patients. I would rather deliver the same amount of nutrients using a less frequent regimen, so I use 50% concentration and have patients use it only 4x a day. Usually, these patients also wear some kind of therapeutic contact lens. If that is the case, I ask them to place a couple of drops into the reservoir of the contact lens as well, so they use even less, maybe 2 or 3x a day.

## Management of the Patient Using Serum Tears

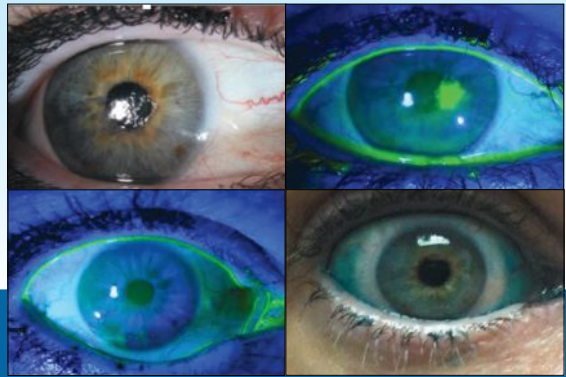
**DR. AKPEK:** How long do you keep your patients on autologous serum tears?

## CASE: The Perfect Storm

By *Giacomina Massaro-Giordano, MD*

A 57-year-old female and former LASIK patient presented to the clinic with Sjögren's syndrome, herpes keratitis, NK, and allergic conjunctivitis. She was prescribed autologous serum tears, anti-inflammatory medications, and a mini-scleral lens. The patient returned for follow up after five weeks of treatment. Staining showed that the corneal surface was much smoother with significantly less punctate staining.

These photos show staining of the patient's ulcer before (top) and after (bottom) treatment with serum, anti-inflammation medications, and a scleral lens. Note the improvement of stain in the second set of photos.



**DR. KARPECKI:** For most patients, especially those with KCS, GVHD, neuropathic pain, etc., autologous serum tears are a lifetime medication, unless their lacrimal glands somehow can improve on their own. When treating conditions like NK, mild/moderate LSCD, or SLK, patients can discontinue use once the condition has improved or resolved.

**DR. LANG:** This is definitely a marathon, not a sprint. I suggest patients take ASEDs for 6 months before deciding to continue therapy. I hope for some improvements around 3 months but typically stay the course for 6 months. If we are seeing improvements, I usually continue therapy with ASEDs for the foreseeable future.

**DR. MASSARO-GIORDANO:** I keep them on for 3-6 months depending on severity and response. I may repeat the cycle 1-2x a year. Cost is an issue so I will usually give patients prescription drops in the winter months when dryness may be worse.

**DR. AKPEK:** What do you look for at follow up to determine whether autologous serum tears are an effective therapy?

**DR. MASSARO-GIORDANO:** I look for subjective improvements on questionnaires, in addition to objective signs, i.e., corneal stain with fluorescein and conjunctival stain with lissamine green, as well as overall conjunctival hyperemia.

**DR. KARPECKI:** I look at corneal and conjunctival staining, and also monitor osmolarity. An improvement in either indicates they are working. I don't expect symptoms to improve until I've improved the ocular surface and provided a homeostatic tear environment. At that point the nerves begin to normalize and symptom improvement follows. Most patients are encouraged by the improvement in signs knowing that symptom resolution may lag. Fortunately, autologous serum tears are very comfortable as a drop, which helps the patient while their dry eye disease continues to improve.

**DR. LANG:** I evaluate symptoms by using a symptom survey (typically SPEED) although other surveys, such as the Ocular Pain Assessment Survey (OPAS), may have more merit when treating neuropathic eye pain. Regarding clinical signs, corneal and conjunctival staining, tear break-up time, conjunctival erythema, and visual acuity are all measures I lean on.

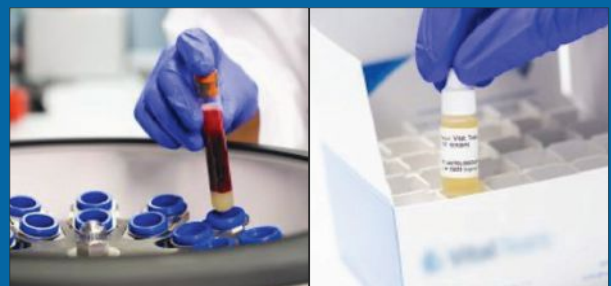## Practical Guidance

**DR. AKPEK:** How do you present autologous serum tears to your patients?

**DR. MASSARO-GIORDANO:** I simply state that I feel that they will benefit from this treatment and, unlike artificial tears, serum tears contain growth factors and proteins that may indirectly help with inflammation and promote healing. I explain that the serum facilitates the repopulation of epithelial cells on the surface of the eye.

**DR. KARPECKI:** It is an easy recommendation in dry eye and other advanced ocular surface disease conditions because I explain how, for example, this autoimmune disease has damaged the patient's lacrimal glands. These glands once served to take the serum from their blood to make tears but they can no longer do that, so we will have their blood drawn and use the serum within it to make their own personalized tears. I then discuss how this will typically lessen or eliminate the need for artificial tears, which is a cost savings, and how autologous serum tears are typically more comfortable than artificial tears, are a natural biologic, and are far more effective. From there I discuss how tears and medications can cost over \$100 per month and patients often nod in agreement. I then state that this option will offset much of that and although the cost is similar, autologous serum tears are far more effective and biocompatible having come from their own serum.

**DR. LANG:** I usually review how patients' eyes are unable to produce the necessary nutrients that their ocular surface needs to stay healthy



Vital Tears are prepared in a medical laboratory using validated safety procedures and delivered throughout the US. Vital Tears autologous serum eye drops can be obtained in as little as 48 hours from the patient's blood draw.

## CASE: "Severe Dry Eye," Likely Sjögren's KCS

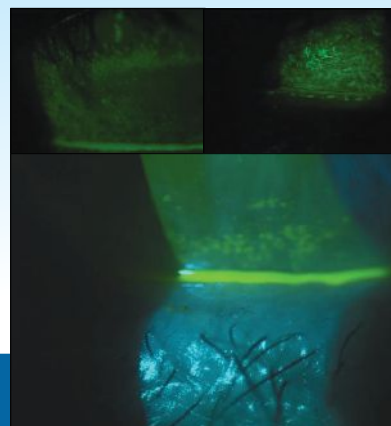
By Paul Karpecki, OD

A 78-year-old female was referred to the clinic for severe dry eye. She was an avid reader and had not been able to read for over a year. Her current medications included artificial tears every one to two hours and erythromycin ointment twice daily.

The patient was diagnosed with keratoconjunctivitis sicca (KCS) and superficial punctate keratitis (SPK). A lab test for Sjogren's Syndrome was ordered and later returned positive.

Steroid drops, preservative-free artificial tears, vitamin A ointment, and nutritional supplements provided minimal improvements. She was then prescribed serum tears at 20% concentration twice daily. Six weeks later, she reported a noticeable improvement in symptoms.

The patient presented with grade 3+ corneal staining and a relatively low tear meniscus height (top). At the final exam, significantly reduced staining and normal tear meniscus height were observed (bottom).



because of their disease state and explain that many of the healing components of tears are the same as blood. By utilizing this natural therapy, we can harness the power of the patient's own blood in a drop form to help the eye and rehabilitate the ocular surface.

Even though autologous serum tears have been around for many years and proven to be safe and effective, insurance companies do not pay for them. This doesn't surprise most patients because many are used to getting denial letters and prior authorization forms for everything from antibiotics to cold medicine. Compared with some of the other therapeutic options in this space, cost is usually not too much of a shock to the patient.

**DR. AKPEK:** If patients still have significant corneal, or central corneal, staining after having tried environmental modulations, over-the-counter eyedrops, and prescription medications, then I will bring it up to them. Most of my patients are referrals and have talked to people who are on serum tears; they usually come in asking for them. Or when I bring it up, they usually say, "Oh okay. I heard about them." So it's not

very difficult for me to explain that they are going to take eye drops made out of their own blood. In general, dry eye patients are pretty educated, and they understand how autologous serum tears can help heal the surface vs. just artificial tears.

**DR. AKPEK:** How does your practice order/source autologous serum tears for your patients?

**DR. MASSARO-GIORDANO:** I have used various compounding companies in the past but now use Vital Tears, a national company with numerous labs and a mobile phlebotomy service to aid in collection.

**DR. KARPECKI:** Vital Tears is a national outfit that provides incredible customer service and uses trained phlebotomists, the highest level of care and safety, and a sterile environment to process the serum tears. They are experts at this. They can also do the blood draw from the patient's home or office, offering convenience for busy people. And they have renewal plans, which makes it easy to follow and maintain your supply of serum tears.

**DR. LANG:** I utilize Vital Tears for all my ASEDs orders. Their program and organization streamline my staff's workflow and make the process easy for both doctor and, more importantly, patient.



### Simplifying Serum Tears Sourcing

Ophthalmologists and optometrists have offered serum tears to patients with ocular surface conditions for over 30 years, but access has been limited to this important therapy. With Vital Tears, eye care providers and their patients now have access to:

- Rapid serum drop delivery
- Convenient blood draw options
- Affordable payment options
- Superior customer service

For additional cases, see <https://info.vitaltears.org/case-studies>



1. Semeraro F, Forbice E, Braga O, et al. Evaluation of the efficacy of 50% autologous serum eye drops in different ocular surface pathologies. *Biomed Res Int.* 2014;2014:826970.
2. Soni NG, Jeng BH. Blood-derived topical therapy for ocular surface diseases. *Br J Ophthalmol.* 2016 Jan;100(1):22-7.
3. Noble BA, Loh RS, MacLennan S, et al. Comparison of autologous serum eye drops with conventional therapy in a randomised controlled crossover trial for ocular surface disease. *Br J Ophthalmol.* 2004 May;88(5):647-52.
4. Celebi AR, Ulusoy C, Mirza GE. The efficacy of autologous serum eye drops for severe dry eye syndrome: a randomized double-blind crossover study. *Graefes Arch Clin Exp Ophthalmol.* 2014 Apr;252(4):619-26.
5. Urzua CA, Vasquez DH, Huidobro A, et al. Randomized double-blind clinical trial of autologous serum versus artificial tears in dry eye syndrome. *Curr Eye Res.* 2012 Aug;37(8):684-8.
6. Kojima T, Higuchi A, Goto E, et al. Autologous serum eye drops for the treatment of dry eye diseases. *Cornea.* 2008 Sep;27 Suppl 1:S25-30.
7. Lomas RJ, Chandrasekar A, Macdonald-Wallis C, et al. Patient-reported outcome measures for a large cohort of serum eye drops recipients in the UK. *Eye (Lond).* 2021 Dec;35(12):3425-32.
8. Pan Q, Angelina A, Marrone M, et al. Autologous serum eye drops for dry eye. *Cochrane Database Syst Rev.* 2017 Feb 28;2(2):CD009327.



**SAVE THE DATE**  
*for*  
**ACADEMY 2024**  
**INDIANAPOLIS**

presented by the American Academy of Optometry **NOVEMBER 6-9**



**REGISTRATION AND HOUSING  
OPEN ON MAY 27, 2024.**

Learn more at [www.aaopt.org/2024](http://www.aaopt.org/2024)



**AMERICAN ACADEMY  
of OPTOMETRY**

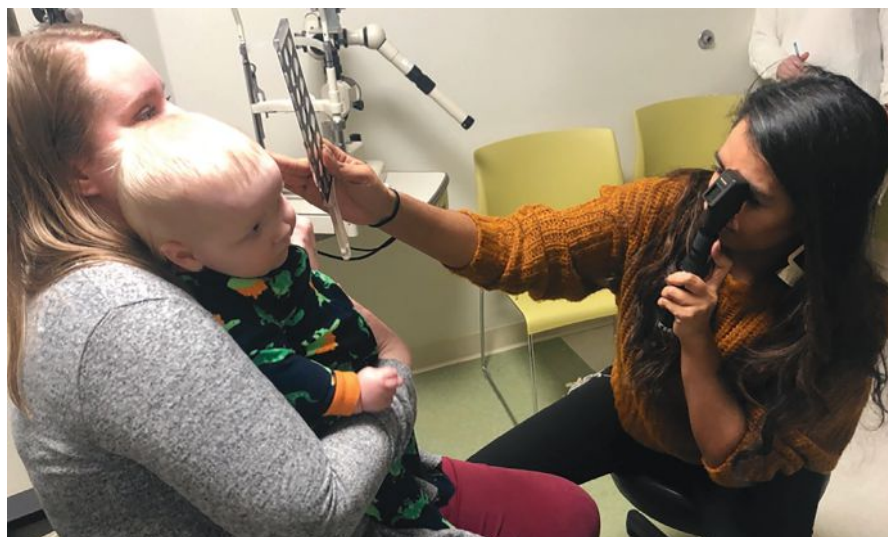# HOW TO PERFORM A PEDS EXAM IN UNDER FIVE MINUTES

Have no fear. Learn the keys to examining pediatric patients for the generalist optometrist.



BY SAMANTHA KRUEGER, OD, MS,  
AND ERIN JENEWEIN, OD, MS  
FORT LAUDERDALE, FL; ELKINS PARK, PA

**M**any practitioners panic when they see a child on the schedule. Have no fear! Children are often easier to examine than adults once you get some practice under your belt. Getting comfortable with examining them allows practitioners to serve an important need in the medical community. It is crucial to perform eye examinations on children to ensure their visual system is properly developing. Visual acuity, stereopsis and oculomotor skills develop rapidly throughout childhood. It is critical to catch any potential barriers to normal visual development as early as possible. The American Optometric Association (AOA) recommends a child's first eye exam occur between six to 12 months of age. Subsequently, asymptomatic or low risk children should be seen at least once between three and five years of age and before beginning first grade. Annual eye exams are



**Retinoscopy performed out-of-phoropter using a skiascopy bar.**

recommended for all children between ages six and 18.<sup>1</sup> This can also help build your practice, as many parents and other family members will often seek care from you once you have successfully examined their child.

Throughout a child's development there are key visual milestones that op-

tometrists look for, which are reflected in our chosen examination procedures. An eye exam on an infant will be very different than the eye exam we perform on a typical schoolchild. During the initial eye exam between six and 12 months of age, be concerned about significant abnormalities in the visual system such as high

*About  
the author*

**Dr. Krueger** is an assistant professor at Nova Southeastern University and serves as site coordinator for the school's pediatric and binocular vision residency. She is also the site coordinator for the Pediatric Eye Disease Investigator Group (PEDIG). Her special interests include binocular vision, pediatrics and learning-related vision problems. She recently earned her master's degree in special education. She is a fellow of the American Academy of Optometry and an active member of the College of Optometrists in Vision Development. Dr. Krueger is actively involved in volunteering through the Special Olympics International organization as a clinical director. **Dr. Jenewein** is an associate professor at Salus University and serves as the principal site investigator for PEDIG and the coordinator for the school's pediatric/vision therapy residency program. Her research interests include myopia control, strabismus, and amblyopia. Dr. Jenewein is a fellow of the American Academy of Optometry and a diplomate in the Binocular Vision, Perception and Pediatric Optometry Section. They have no financial disclosures.

refractive error, binocular vision disorders, strabismus or presence of ocular disease. These examinations are completely objective and generally very short, focusing on retinoscopy, cover test, pupil and extra-ocular muscle function and anterior and posterior segment health. In toddlers and preschoolers, we can begin getting some subjective feedback. The exam will still mainly consist of objective measurements and ensuring the child's visual development is appropriate for their age. When examining school-aged children, we need to ensure they are meeting the visual demands required for school. This should include a full assessment of refractive error, binocular vision and ocular health.

### Keep It Fun

Eye exams on children need to be fast paced and fun! The more fixation targets you can acquire, the better. Switching the target frequently increases child engagement and move the exam along faster, as well as ensuring that the patient is focusing on it. Fixation toys do not need to be an expensive investment. A simple rubber duck can be used as a fixation target on your transilluminator. Spinning light toys and finger puppets from local toy stores are very useful as well. Small, detailed stickers work well to create fun accommodative targets for patients. Nail stickers or small stickers can be placed on popsicle sticks and contain the perfect amount of fine detail to act as an accommodative target. Kids YouTube or a favorite television program or movie on a device can serve as an excellent tool during retinoscopy. During the ocular health evaluation, a parent or assistant can hold a phone or tablet at different locations to direct fixation and allow you to easily examine your patient.

An investment in some additional equipment might ensure a successful pediatric examination. When examining young children or patients with developmental disabilities, Snellen or ETDRS targets are often not ideal for measuring visual acuity because they rely on letter recognition. Teller Acuity Cards use a forced choice preferential looking technique and are a quick way to evaluate



Using a variety of fixation targets helps engage the patient.

visual acuity in infants and very young children. Teller cards are commonly used in patients less than one year of age, but may be used to evaluate acuity in children 36 months and younger, and also older children or adults with developmental disabilities.<sup>2</sup> Cardiff cards contain vanishing optotypes of familiar shapes and are ideal for children ages one to three, who may not attend to the gratings on Teller cards.<sup>3</sup> The technique for testing acuity is forced choice preferential looking and the test can be performed at 50cm or one meter.

Using Lea symbols or an HOTV chart can be helpful for testing children ages three to seven years. Lea symbols consist of four calibrated shapes that are easily recognized by most children. A matching card or matching puzzle helps with testing acuity in children who are shy or do not know their letters. HOTV testing also uses a matching card, which allows for testing even in children who do not know their letters. The Vision in Preschoolers study group found that both Lea and HOTV can be used in most three- to five-year-old children, but three-year-old children had more difficulty with the HOTV chart.<sup>4</sup> Both Lea and HOTV charts are commonly included in electronic acuity chart pro-

grams making them easy to use in most clinics.

Stereoacuity is a useful test in pediatric eye examinations because you can gain insight into different aspects of the child's visual system with one test. When evaluating stereoacuity, it is important to remember that a random dot stereogram, or global stereopsis test, requires the patient to be bifoveal to appreciate the random dot shape. Local or lateral disparity stereopsis tests, such as the Wirt circles or the fly test, have monocular cues, so even patients with constant strabismus (or patients who are not bifoveal) can often correctly identify some of the coarser degrees of stereopsis in this test. Random dot stereopsis can be reliably tested even in young children.

Most preschool aged children without strabismus or a high degree of uncorrected refractive error or unequal visual acuity are able to successfully complete the test, demonstrating that the child has normal binocularity (no constant strabismus) and likely does not have high degrees of uncorrected refractive error or poor acuity in one or both eyes.<sup>5,6</sup> Stereoacuity develops in the first six months of life, and most children between five and six months of age have been shown to have stereopsis.<sup>7</sup>

**TABLE 1. CHILD CASE HISTORY QUESTIONS**

Developmental	
Birth History	<ul style="list-style-type: none"> <li>• Was the child born full-term or premature?</li> <li>• What was the child's weight at birth?</li> </ul>
Milestones	<ul style="list-style-type: none"> <li>• When did the child first walk?</li> <li>• When did the child first crawl?</li> <li>• When did the child say their first single word?</li> </ul>
Academic	
Performance	<ul style="list-style-type: none"> <li>• Is the child performing on grade level?</li> <li>• Is the child's reading performance on grade level?</li> </ul>
Visual efficiency	<ul style="list-style-type: none"> <li>• Does the child have difficulty copying from the board?</li> <li>• Does the child have poor handwriting?</li> <li>• Does the child have difficulty copying from the board?</li> </ul>

The Pediatric Assessment of Stereopsis with a Smile (PASS) test is an excellent tool to assess stereoacuity in young children. This test can easily be administered by the doctor or support staff and uses a preferential looking technique, which makes it easier when testing younger children.<sup>8</sup> The Preschool Stereo test has a matching card, which makes it easy to test preschool aged children, and the Randot butterfly has a large stereopsis butterfly target and is also easy to use in young children. It is helpful to prompt the child to look for the smiley face that is “popping out,” and there is a demonstration card available to help small children know what they are looking for.

Many parents seek care because they are concerned their child may have a color vision defect. In younger children, traditional measures of color vision can be cumbersome and time consuming. The Color Vision Testing Made Easy (CTVME) is a much more suitable test for them. It consists of child-friendly shapes, can generally be completed in 60 seconds or less and can accurately identify color vision deficits in children as young as five years old.<sup>9</sup> Color vision

defects are commonly worrisome to parents. It is important to counsel parents that while colors may not appear normal to their child, it should not have severe implications for quality of life, but some limitations—such as career limitations—may exist.

### Testing Sequence

Children have limited attention spans so the key to successfully examining this population is to keep the exam moving quickly and prioritizing certain exam elements. Unlike traditional eye exam sequencing, in infants and young children, visual acuity is not the first test to be completed. Visual acuity can be a challenging test, and it may be frustrating for the child. Additionally, some children may become upset when an eye is occluded during monocular acuity testing. For this reason, we recommend the following examination sequence for young children: entrance testing (confrontation visual fields, extraocular motility and pupil function), Hirschberg testing, stereopsis testing, color vision testing, retinoscopy, visual acuity, IOP and dilated fundus evaluation with cycloplegic refraction.

Depending on the child you are working with and their age, it may not always be possible to complete the entire exam in one visit. Do not be afraid to suggest completing the exam on a separate visit if you notice a child is becoming agitated or upset. Parents are usually understanding and willing to bring the child back to get accurate testing data. When scheduling young children, it is also important to avoid nap time or meal time when possible.

In older children, ages six to 13, the exam sequence is similar to an adult exam, with the addition of binocular vision testing. Screening school-aged patients for binocular vision disorders is important, and even patients who do not have symptoms consistent with a binocular vision disorder should have basic screening, as most children do not realize their symptoms are associated with their eyes or may avoid near work to avoid symptoms.

### Case History

To maximize children's attention in the exam room, it is best to have parents fill out information on developmental and academic history prior to the examination. There are some important milestones in development you would like to inquire about with parents (*Table 1*).

The College of Optometrists in Vision Development Quality of Life survey can also be used as a screening tool prior to examining children ages six and up. It has been found to be a reliable screening tool to identify visual symptoms in children who may have a vision disorder.<sup>10</sup>

### Refractive Error Assessment

When examining children, place greater emphasis on objective testing measurements. Retinoscopy is crucial to look for the presence of a significant refractive error or anisometropia and to determine if the patient has a significant or amblyogenic refractive error (*Table 2*). In younger children, ages four and younger, subjective refraction is not possible, so retinoscopy results are used for prescribing glasses. Children have a very active accommodative system, which can make determining refractive error challenging. During dry retinoscopy, using videos at distance will help to control accommodation.

Once you have obtained a solid retinoscopy, trial frame the prescription and check ocular alignment and any binocular vision testing through the trial framed prescription. In very young children, it may be difficult to get a corrected visual acuity during the first visit (it's more a bonus, if possible!), and these patients will likely have to return for a follow-up exam. A cycloplegic refraction is also essential to determine accurate refractive error, and is recommended for all new pediatric patients.<sup>1</sup>

### Binocular Vision Assessment

Many children with binocular vision issues will not report traditional symptoms to a practitioner during case history. More often than not, children have been used to seeing the world one



# Unique never felt so good.

Unique pH™ is a highly effective multipurpose solution for gas permeable contact lenses that cleans, conditions, and disinfects in one bottle.

Unique pH™ conditions lenses by adjusting to the eye's natural tear pH to enhance the wettability and comfort of gas permeable contact lenses on insertion. The formula is designed to provide a soothing effect during lens wear.

Complimentary starter kits available!

**ORDER ONLINE**  
[www.meniconwebstore.com](http://www.meniconwebstore.com)

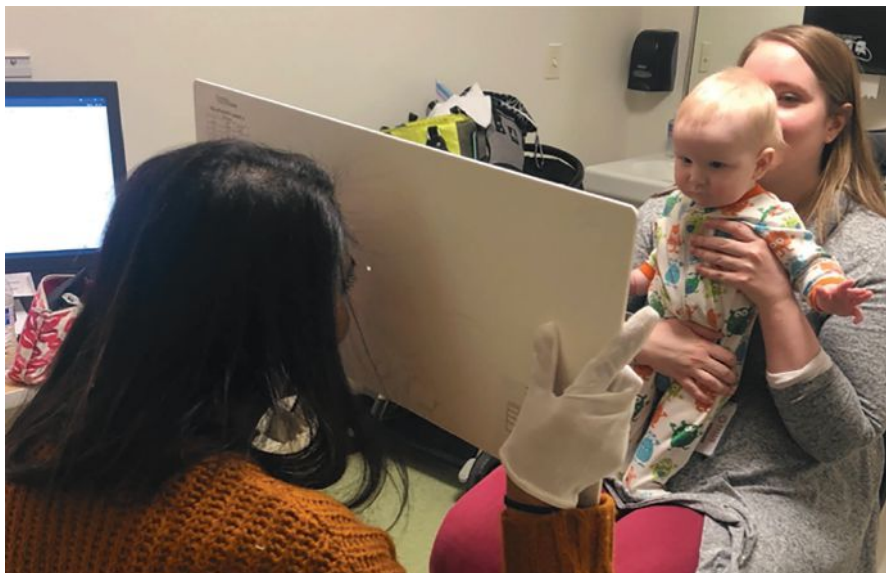

way for their entire lives, and they may not know this is abnormal. For this reason, it is imperative that a binocular vision assessment is performed on all children. To maximize efficiency considering the limited attention span in pediatric patients, we want to choose binocular vision tests that will give us the most bang for our buck. At a minimum, we need to make sure we have assessed vergence ability and amplitude, oculomotor skills and accommodation amplitude, facility and posture. Although this seems like a lot of testing, with practice a good binocular vision screening can be performed very quickly.

Accommodative amplitudes give us information about our patient's ability to stimulate accommodation. Donders' pull away amplitude testing can be viewed as a fun game for kids. Ask the patient to tell you when they can first see the mystery letter or shape as you pull the fixation target away from the patient's eye monocularly.

A minimum accommodative amplitude for each child can be calculated using Hofstede's formula,  $15 - 0.25(\text{age})$ . An amplitude that is 2D below this value is considered abnormal.<sup>11</sup> Posture of accommodation can be quickly evaluated using the Monocular Estimation Method (MEM) retinoscopy. This technique can be used even in young children who cannot read and may be unable to do other tests of accommodation. Binocular accommodative facility (BAF) using  $\pm 2.00$  flippers is another great test for screening for binocular vision disorders because it probes both the vergence and accommodative systems.

If a patient can successfully perform BAF, they have good ability to converge, diverge, stimulate and relax accommodation. If BAF is abnormal, performing the



**Teller acuity (preferential looking) performed on an infant.**

monocular version of this test (MAF) helps to determine if your patient has an accommodative dysfunction. This test is performed monocularly, so it isolates the accommodative system. An abnormality found during amplitude, MEM or BAF testing can be further probed at a follow-up binocular vision evaluation.

Stereopsis can be administered as a preliminary test prior to refractive error assessment. If the child did not perform well on this test, or if a significant refractive error is detected on retinoscopy, repeat the test with the trial frame refraction to see if there are any improvements.

To assess binocularity, cover test and near point of convergence should be performed on all patients. Don't forget to use your fun fixation targets to make this an engaging activity. Based on the cover test value obtained, it is worthwhile to ensure your patient has the vergence ranges needed to compensate for their phoria and meet their visual demand. For patients presenting with an eso posture, perform base-in vergence ranges, and, for exo posture patients, perform base-out vergence ranges to screen for any binocular vision issues.

Step vergence ranges using your prism bar in free space are efficient and typically work better than smooth vergence range testing in this population. Ad-

ditionally, step vergence range testing allows you to make objective assessments of the patient's break and recovery that cannot be seen in the phoropter. This allows testing even in patients that have difficulty giving a subjective response. Sheard's criteria suggests that a patient should have double their phoric value in reserves to maintain comfortable binocularity.<sup>12</sup> If a binocular vision issue is suspected, further testing of all distance and near vergence ranges and vergence facility is recommended at a follow-up visit.

Oculomotor skills can be grossly assessed during extraocular motility testing as a part of your preliminary workup. When eye tracking is indicated as a concern based on the case history or screening assessments, an NSUCO saccades and pursuits test can allow for a quantitative assessment. This can be performed at the initial examination or at a follow-up.

A quick assessment of accommodation, oculomotor skills and vergence is recommended at any initial evaluation. If any testing comes back abnormal, consider bringing the patient back or refer to a colleague for a more extensive binocular vision workup. Additionally, if the patient has a significant refractive error that is being corrected for the first time or a significant change in refractive

**TABLE 2. AMBLYOGENIC REFRACTIVE ERRORS**

	Isoametropic	Anisometropic
Astigmatism	$\geq 2.50D$	$\geq 4.00$
Myopia	$\geq 6.00$	$\geq 3.00$
Hyperopia	$\geq 4.00$	$\geq 1.00$

error, a follow-up visit after the patient has been wearing the prescription for at least two weeks is recommended to evaluate the binocular vision system.



**Fixation target displayed on transilluminator, which can be ideal for performing Hirschberg and pupillary testing.**

## Takeaways

When a red flag presents itself, make sure to bring the patient back for a more extensive binocular vision examination or refer out as appropriate. It is beneficial to know the local doctors in your area to refer to. It is crucial to know local pediatric ophthalmologists to refer to for ocular diseases. If you are not in a practice setting that is able to offer vision therapy, use the “locate a doctor” feature on the website for the College of Optometrists in Vision Development to find optometrists in your area to refer to. An excellent reference book is *Applied Concepts in Vision Therapy* by Leonard Press.

All optometrists can examine a child efficiently with the right tools and practice. Access to vision care for young patients is important, and providers that are comfortable examining children are always in demand. Examining pediatric patients can be both rewarding and practice building. ■

1. AOA. Evidence-based clinical practice guideline: comprehensive pediatric eye and vision examination. *Optometric Clinical Practice*. 2020;2:7.
2. Teller DY, McDonald MA, Preston K, et al. Assessment of Visual acuity in infants and children; the acuity card procedure. *Dev Med Child Neurol*. 1986;28(6):779-89.
3. Woodhouse JM, Adoh TO, Oduwaye KA, et al. New acuity test for toddlers. *Ophthalmic Physiol Opt*. 1992;12(2):249-51.
4. Vision in Preschoolers Study Group. Preschool visual acuity screening with HOTV and Lea symbols: testability and between-test agreement. *Optom Vis Sci*. 2004;81(9):678-83.
5. Kulp MT, Mitchell GL. Randot stereoacuity testing in young children. *J Pediatr Ophthalmol Strabismus*. 2005;42(6):360-4.
6. Manny RE, Martinez AT, Fern KD. Testing stereopsis in the preschool child: is it clinically useful? *J Pediatr Ophthalmol Strabismus*. 1991;28(4):223-31.
7. Birch E, Shimojo S, Held R. Preferential-looking assessment of fusion and stereopsis in infants aged one to six months. *Invest Ophthalmol Vis Sci*. 1985;26(3):366-70.
8. Schmidt PP, Maguire MG, Moore B, Cyert L; Vision in Preschoolers Study Group. Testability of preschoolers on stereotests used to screen vision disorders. *Optom Vis Sci*. 2003;80(11):753-7.
9. Cotter SA, Lee DY, French AL. Evaluation of a new color vision test: color vision testing made easy. *Optom Vis Sci*. 1999;76(9):631-6.
10. Bakar NFA, Chen AH, Noor ARM, Goh PP. The use of COVID-QOL questionnaire in school vision screening. *Iperception*. 2011;2(4):310.
11. Scheiman M, Wick B. *Clinical Management of Binocular Vision: Heterophoric, Accommodative and Eye Movement Disorders*. Philadelphia, PA: Lippincott Williams & Wilkins; 1994.
12. Sheard C. Zones of ocular comfort. *Optom Vis Sci*. 1930;7(1):9-25.

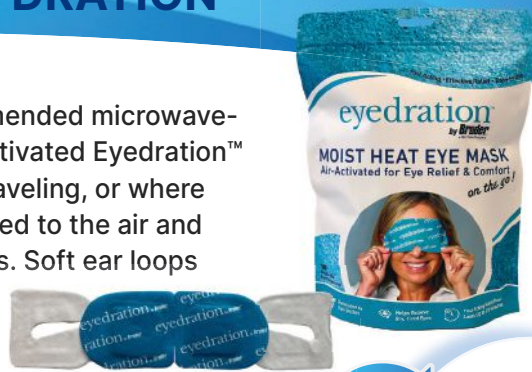**OPEN YOUR EYES to Bruder™**  
a Hilco Vision Company

**HYGIENE | HEAT | HYDRATION**

Make Bruder part of your dry eye treatment protocol

**Open your eyes to Bruder.™** You know us for our #1 doctor-recommended microwave-activated Bruder® mask. Now we've added a new single-use, air-activated Eyedration™ mask, a convenient way for patients to maintain eye health when traveling, or where a microwave is not available. Eyedration begins heating once exposed to the air and maintains therapeutic moist heat on the eyelids for up to 20 minutes. Soft ear loops keep it in place when worn. The mask can also be used in-office to prepare the eye for manual expression or debridement procedures.

Contains 10 individually wrapped masks per pouch.



Read more about the mask



Stock up now on eye care essentials at [order.bruder.com](http://order.bruder.com), [eyes@bruder.com](mailto:eyes@bruder.com) or 888-827-8337. Learn about the science behind Bruder products at [bruderpro.com](http://bruderpro.com).

# GLAUCOMA: PEARLS FOR IMPROVING THE PATIENT EXPERIENCE

ODs play a key role in helping individuals adapt to this life-changing diagnosis and navigating them through the challenges they will face.

BY CATLIN NALLEY  
CONTRIBUTING EDITOR

As frontline eyecare providers, optometrists are tasked not only with diagnosing and managing various conditions, but also understanding and addressing the unique challenges faced by their patients. Glaucoma, a condition with a host of potential hurdles from psychological impacts and financial burdens to treatment adherence and lifestyle adjustments, is a perfect example of the important role ODs play in the overall health and quality of life of their patients.

Optometrists hold the key to managing the clinical aspects of glaucoma, and at the same time, fostering a supportive and empowering journey for those affected by it. In this article, we delve into the multifaceted challenges that glaucoma patients encounter, offering insights to help ODs provide tailored care and support as well as strategies and practical advice to improve the patient experience.

## Contending With a New Diagnosis

Any medical condition comes with a variety of difficulties; however, a glaucoma diagnosis—a disease that causes

irreversible vision loss—is particularly challenging for patients.

“Initially, as with the diagnosis of any chronic illness, I think there is denial, fear and uncertainty,” says Danica Marrelli, OD, clinical professor at the University of Houston, while noting that this is especially true with a condition like glaucoma, which often has no symptoms at the time of diagnosis. “It can be hard for patients to believe that they have it. They hear glaucoma and think, ‘I’m going blind.’ They can shut down and not really be able to hear or process what you are telling them, at least at first.”

The emotional toll of living with a chronic condition should not be underestimated, and glaucoma can have a significant psychological burden on patients. A strong support system will be a key component of success, and that begins with the eyecare team.

Optometrists can offer empathy, support and access to resources to help patients navigate these emotional challenges. Delivering information should be done confidently and compassionately, says James Fanelli, OD, founder and director of the Cape Fear Eye Institute in Wilmington, NC. “Look your patients in the eye and give them the one-on-one attention that shows you are invested in their care.”

When first diagnosing a patient with glaucoma, it is important to give them time to digest the news, says Andrew Rixon, OD, who practices at the Lt. Col. Luke Weathers, Jr. Medical VA Center in Memphis. “We need to acknowledge how they are feeling in that moment and be careful not to share too much information all at once. It takes time and you have to build their trust, help your patients feel empowered and make sure they know that this is a team effort, and you are available to answer any questions.”

Dr. Marrelli tries to provide information about glaucoma in little “bites” using relatively simple terms. “I don’t avoid the word ‘blindness,’ but I put it in perspective,” she explains. “This is especially important for those who have mild disease. I might say something like, ‘untreated glaucoma can lead to blindness, but we’ve detected yours very early. If we are able to control your eye pressure, I think you have a very good chance of keeping the vision that you have.’”

It is also important to help patients understand the link between intraocular pressure (IOP) and glaucoma, she notes. “I usually tell them that we have three ways to lower IOP: drops, laser and surgery. If surgery is not something I’m considering right away,



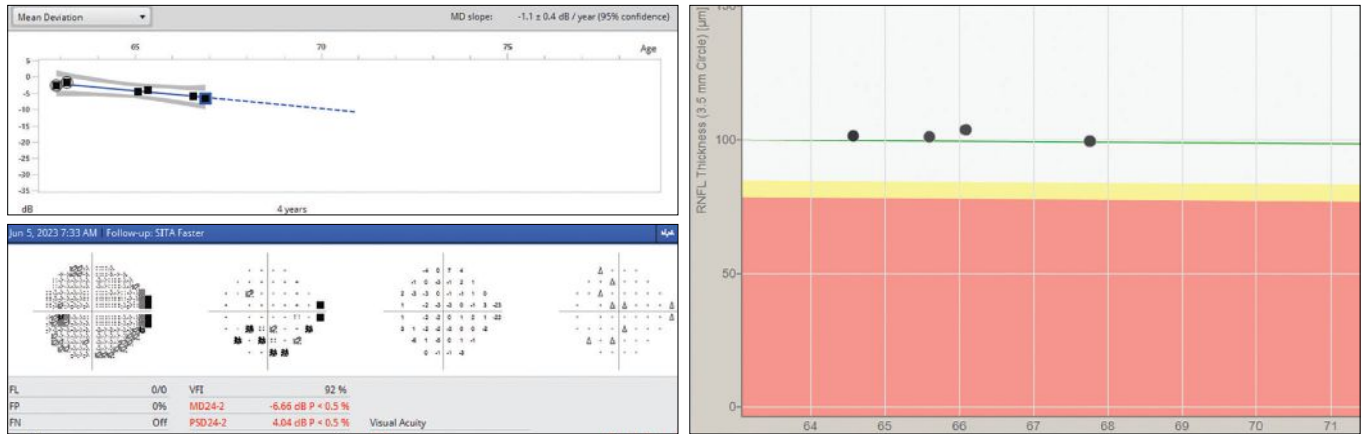


Photo: Andrew Rixon, OD

**Fig. 1. Demonstrating to patients how their disease is progressing/remaining stable by showing them the actual resources we use to determine treatment success/failure can take some of the mystery out of the process and generate talking points that can help reinforce their knowledge of how their glaucoma is evolving.**

I usually put that to the side (‘we don’t need to talk about surgery right now; we’ll talk about it later if we need to’).

Taking a straight-forward yet encouraging approach can help patients faced with a daunting diagnosis. “Glaucoma is a lifelong disease that has a significant impact on daily life,” says Marcus Gonzales, OD, clinical associate professor at the University of Houston. “As optometrists, it is important to provide both medical and emotional support. Our patients are looking to us for guidance—be reassuring. When communicating with them, acknowledge the impact of this diagnosis while also discussing their options for adapting their lives to it and transitioning to management.”

From the start, Dr. Marrelli reminds her patients that they also have a role to play in management. “I can make recommendations about the best way to lower IOP, but they have the day-to-day role of using their medication,” she says. “I talk about the importance of not only keeping up with eye drops, but also keeping up with appointments. I let them know that initially there will be quite a few visits, but often those start to spread out once things stabilize.”

When discussing a glaucoma diagnosis for the first time, Dr. Marrelli always ends by asking the patient what questions they have. However, she

notes, they often feel too overwhelmed to have questions. “I tell them to keep a notebook and jot down questions as they come up and to bring the notebook with them to the next appointment so that we can discuss them,” she says.

“Finally, I try to go back and revisit these things on subsequent visits. The ‘information dump’ or telling them everything the first time can be overwhelming, so I’ll do a little at first and add/clarify at subsequent visits.”

### Treatment Adherence & Costs

Compliance with treatment regimens poses a significant challenge. However, fostering open dialogue, addressing concerns and providing practical strategies can help improve adherence.

“The first step is to develop a good doctor-patient relationship,” notes Dr. Fanelli, while emphasizing the importance of creating trust with patients. “This becomes more of a psychological approach rather than a medical approach.

Different people are motivated by different things. Find something you can relate to them with then use it to help gain their trust.”

Several factors can contribute to low treatment adherence, including side effects, high costs, denial or avoidance and a lack of understanding. Remembering to take medications at the correct times can also be challenging, especially for elderly patients. Education and open lines of communication can help mitigate some of these factors, notes Dr. Gonzales.

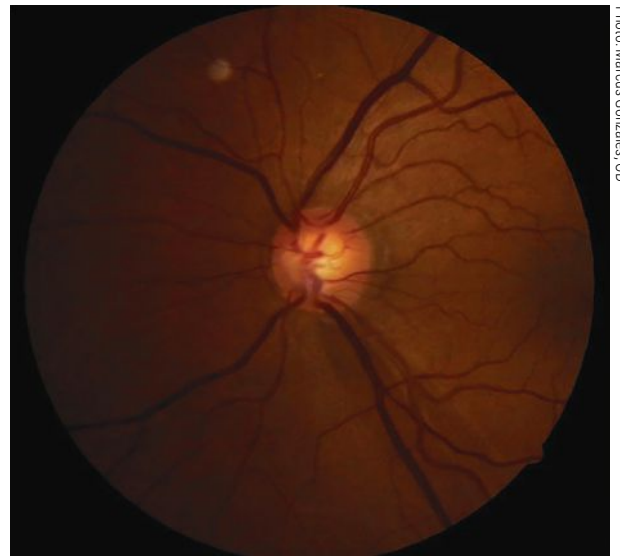

Photo: Marcus Gonzales, OD

**Fig. 2. Optic nerve head photo OS of a 59-year-old Black female with a notch noted along the inferior temporal neuroretinal rim with an associated nerve fiber layer wedge defect.**

“Side effects are a common reason patients stop their medication, and they should be addressed from the start,” he says, while underscoring the value of patient education. “It is important that your patients aren’t caught off guard, and this also helps build

trust—another key aspect of treatment adherence.”

Dr. Marrelli recommends using open-ended questions when asking patients about their medication use (e.g., “tell me how you use your drops” rather than “are you using your drops?”).

“Use language that normalizes missing drops. ‘No one is perfect... everyone misses a dose now and then... I need to know how you are using your medications so I can make the best decisions about the next steps in your care,’” she says.

## An OD Patient Perspective on Glaucoma Management

*Hear what living with the condition is like from someone who’s been on both sides of the slit lamp.*



BY LESLIE P. BRODSKY, OD  
WAYNE, PA

Having the opportunity to manage glaucoma both as a clinician and a patient has afforded me a connection to experience challenges patients face with the condition and come up with logical solutions based on my clinical knowledge. I would like to share my personal experience in the hope that this perspective may help other clinicians and patients with their glaucoma management and success.

Currently, my glaucoma is being managed medically with drops, so my focus will be on what I have found helpful to facilitate this form of management. What I have determined to be most critical in long-term drop tolerance has been employing lid hygiene. I usually apply my drops about 10 minutes apart (the package inserts advise at least five-minute intervals). Drops typically leave a residue on the eyelids and the skin of the eyelid is very thin and sensitive. About 10 minutes following my final drop instillation at each session, I use a clean damp washcloth to gently remove any residue from my lids, especially the lower lids and canthi; this has made a tremendous improvement in my tolerance. Prior to appreciating this, I was experiencing an increasing degree of inferior periorbital inflammation, which I thought might eventually cause my medical treatment to fail.

Another approach to consider is using lid cleansing pads for this purpose. I am careful with the washcloth so I do not get any liquid in my eye, and this should hold true with any cleansing method. The washcloth is wrung out, so it is just damp and not dripping liquid.

I highly recommend taking a moment when prescribing any eye drop to ask the patient if they know how to instill it. In my personal experience, holding the dropper

bottle perpendicular to the eye, preferably in a supine position, while gently pulling down the lower lid to form a pocket gives the most ideal approach. Then, I close the eyelid and move my eye behind it for at least 15 to 30 seconds. Placing an index finger with a clean tissue at the outer canthus to prevent the drop from dripping down the cheek is sometimes helpful. Instruct patient to always wash their hands before this process. If a supine position is not feasible, they should lean the head back to the degree possible and keep the dropper vertical.

Having to instill eye drops once or twice a day is seemingly a simple task to remember, but I have learned to appreciate that this is far from reality. What I have found most useful is using a phone app as a reminder. I have used the Medisafe app for years and it has become crucial to my compliance. It allows you to set individual daily time notifications for each medication and you must interact with the app to show that the medication has been taken. There are several other apps like this available, and I feel they are invaluable for good management.

Keeping dropper bottles intact and clean is important; I have found prescription pill bottles with childproof lids very useful, with the 10-dram size adequate for most dropper bottles. This also keeps the bottle from inadvertently opening.

Eye drops have different temperature ranges in which they must be stored. The package insert provides the details and patients should understand the storage requirements for each drop. I avoid getting any drops by mail-order because of this. The drops should also be protected from light, so I keep the dropper bottles in foil packets inside the pill bottles I have discussed above. Alternatively, the pill bottles can be stored in a lightproof bag. When traveling, I keep my drops in an insulated lightproof bag in the pill bottle with a reusable freezer

pack to maintain appropriate temperature. When camping, I make sure I have a cooler to avoid extremes of temperature.

I always take non-preserved artificial tears with me to my appointments and it is helpful to have these individual vials available for patient use. This facilitates keeping eyes comfortably open for diagnostic tests such as OCTs and visual fields.

One very important point unrelated to eyedrop management that became relevant to me—and I believe may affect other patients—is consideration of sleep position. I tend to sleep on my left side. One morning I woke up noticing my left eye was pressed against the pillow. My vision was blurred in that eye for at least an hour. At my next appointment, I had a new visual field defect. Since then, I have worn glasses to bed, which prevents any undue orbital pressure from my sleep position. Either wraparound safety glasses or a frame with a total front width that conforms with your face width so it does not shift is appropriate. With this approach, my visual fields in both eyes have been relatively stable. I should add that prior to this acute episode, which alerted me to the association, my primary visual field changes were occurring in my left eye. Based on my experience, I believe it would merit a discussion if a patient were showing a unilateral progressing field defect to analyze their sleep position. We know the glaucomatous nerve is at greater risk and likely more sensitive to these types of variables.

A good exercise for all ODs would be to try taking artificial tears at arranged times for a week to get a better appreciation of some of the challenges mentioned above.

I hope some of my experiences as a patient and clinician will help to increase the efficacy and compliance of your patient’s medical glaucoma management. Sometimes, seemingly simple measures can have significant results, as I have found out through my own experience as a patient.

# INTRODUCING

## THE RYZUMVI™ DIFFERENCE

Reverse dilation and reimagine  
the post-dilation experience  
for patients.<sup>1,2</sup>

REDEFINE  
the **PATIENT**  
EXPERIENCE  
POST-DILATION



 **Ryzumvi**™  
(phentolamine  
ophthalmic solution) 0.75%



RYZUMVI is the first and only relatively non-selective alpha-1 and alpha-2 adrenergic antagonist approved to reverse pharmacologically-induced mydriasis.<sup>1</sup>



RYZUMVI reversibly binds to alpha-1 adrenergic receptors on the radial iris dilator muscle, thereby reducing pupil diameter, and indirectly reverses mydriasis induced by muscarinic antagonist effects on the iris sphincter muscle.<sup>1</sup>



The onset of action after administration of RYZUMVI generally occurs in 30 minutes, with the maximal effect seen in 60 to 90 minutes, and the effect lasting at least 24 hours.<sup>1</sup>

### INDICATION

RYZUMVI™ (phentolamine ophthalmic solution) 0.75% is indicated for the treatment of pharmacologically-induced mydriasis produced by adrenergic agonists (e.g., phenylephrine) or parasympatholytic (e.g., tropicamide) agents.

### IMPORTANT SAFETY INFORMATION

#### Warnings and Precautions

- **Uveitis:** RYZUMVI is not recommended to be used in patients with active ocular inflammation (e.g., iritis).
- **Potential for Eye Injury or Contamination:** To avoid the potential for eye injury or contamination, care should be taken to avoid touching the vial tip to the eye or to any other surface.
- **Use with Contact Lenses:** Contact lens wearers should be advised to remove their lenses prior to the instillation of RYZUMVI and wait 10 minutes after dosing before reinserting their contact lenses.

#### Adverse Reactions

The most common adverse reactions that have been reported are instillation site discomfort (16%), conjunctival hyperemia (12%), and dysgeusia (6%).

Please see Brief Summary of Prescribing Information on the adjacent page and the full Prescribing Information at [RYZUMVI.com](http://RYZUMVI.com).



Visit [RYZUMVI.com](http://RYZUMVI.com)



# Ryzumvi™

(phentolamine  
ophthalmic solution) 0.75%

**BRIEF SUMMARY:** Consult the full Prescribing Information for complete product information available at [www.RYZUMVI.com](http://www.RYZUMVI.com)

**INDICATIONS AND USAGE:** RYZUMVI is indicated for the treatment of pharmacologically-induced mydriasis produced by adrenergic agonists (e.g., phenylephrine) or parasymphatholytic (e.g., tropicamide) agents.

**CONTRAINDICATIONS:** None.

#### WARNINGS AND PRECAUTIONS

- **Uveitis:** RYZUMVI is not recommended when active ocular inflammation (e.g., iritis) is present because adhesions (synechiae) may form between the iris and the lens.
- **Potential for Eye Injury or Contamination:** To avoid the potential for eye injury or contamination, care should be taken to avoid touching the vial tip to the eye or to any other surface.
- **Use with Contact Lenses:** Contact lens wearers should be advised to remove their lenses prior to the instillation of RYZUMVI and wait 10 minutes after dosing before reinserting their contact lenses.

#### ADVERSE REACTIONS

**Clinical Trials Experience:** Because clinical trials are conducted under widely varying conditions, adverse reaction rates observed in the clinical trials of a drug cannot be directly compared to rates in the clinical trials of another drug and may not reflect the rates observed in practice.

RYZUMVI was evaluated in 642 subjects in clinical trials across various subject populations. The most common ocular adverse reactions reported in >5% of subjects were instillation site discomfort including pain, stinging, and burning (16%) and conjunctival hyperemia (12%). The only non-ocular adverse reaction reported in >5% of subjects was dysgeusia (6%).

#### USE IN SPECIFIC POPULATIONS

**Pregnancy:** *Risk Summary:* There are no available data with RYZUMVI administration in pregnant women to inform a drug-associated risk. In animal toxicology studies, when phentolamine was administered orally to pregnant mice and rats during the period of organogenesis skeletal immaturity and decreased growth was observed in the offspring at doses at least 24-times the recommended clinical dose. Additionally, a lower rate of implantation was seen in pregnant rats treated with phentolamine administered at least 60-times the recommended clinical dose. No malformations or embryofetal deaths were observed in the offspring of pregnant mice, rats, and rabbits administered phentolamine during the period of organogenesis at doses of at least 24-, 60-, and 20-times, respectively, the recommended clinical dose (see Data). RYZUMVI should only be used during pregnancy if the potential benefit justifies the potential risk to the fetus.

**Data Animal Data** Oral administration of phentolamine to pregnant rats and mice at doses at least 24-times the recommended clinical dose (based on a body weight per surface area (mg/m<sup>2</sup>) comparison with a 60-kg human)

**References:** **1.** RYZUMVI (phentolamine ophthalmic solution). Prescribing Information. Ocuphire. **2.** Boyd K. Mendoza O. What are dilating eye drops? American Academy of Ophthalmology. Available at: <https://www.aaopt.org/eye-health/drugs/dilating-eyedrops>. Accessed February 8, 2024.

resulted in slightly decreased growth and slight skeletal immaturity of the fetuses. Immaturity was manifested by increased incidence of incomplete or unossified calcanei and phalangeal nuclei of the hind limb and of incompletely ossified sternebrae. At oral phentolamine doses at least 60-times the recommended clinical dose (based on a mg/m<sup>2</sup> comparison with a 60-kg human), a slightly lower rate of implantation was found in rats. Phentolamine did not affect embryonic or fetal development in rabbits at oral doses at least 20-times the recommended dose (based on a mg/m<sup>2</sup> comparison with a 60-kg human). No malformations or embryofetal deaths were observed in the rat, mouse or rabbit studies.

**Lactation:** *Risk Summary:* There is no information regarding the presence of phentolamine in human milk, the effects on the breastfed infants, or the effects on milk production during lactation to inform risk of phentolamine ophthalmic solution 0.75% to an infant. The developmental and health benefits of breastfeeding should be considered along with the mother's clinical need for RYZUMVI and any potential adverse effects on the breastfed child from RYZUMVI.

**Pediatric Use:** The safety and effectiveness of RYZUMVI have been established in pediatric patients aged 3 to 17 years. No overall differences have been observed between pediatric and adult subjects.

**Geriatric Use:** No overall differences in safety and effectiveness have been observed between elderly and younger adult subjects.

#### OVERDOSAGE

No deaths due to acute poisoning with phentolamine have been reported. Overdosage with parenterally administered phentolamine is characterized chiefly by cardiovascular disturbances, such as arrhythmias, tachycardia, hypotension, and possibly shock. In addition, the following might occur: excitation, headache, sweating, visual disturbances, nausea, vomiting, diarrhea, or hypoglycemia. There is no specific antidote; treatment consists of appropriate monitoring and supportive care. Substantial decreases in blood pressure or other evidence of shock-like conditions should be treated vigorously and promptly.

#### CARCINOGENESIS, MUTAGENESIS, IMPAIRMENT OF FERTILITY

**Carcinogenesis:** Carcinogenicity studies with RYZUMVI have not been conducted.

**Mutagenesis:** Phentolamine was not mutagenic in the in-vitro bacterial reverse mutation (Ames) assay. In the in-vitro chromosomal aberration study in Chinese hamster ovary cells, numerical aberrations were slightly increased after a 4-hour exposure to phentolamine without metabolic activation, and structural aberrations were slightly increased after a 4-hour exposure to phentolamine with metabolic activation only at the highest concentrations tested, but neither numerical nor structural aberrations were increased after a 20-hour exposure without metabolic activation. Phentolamine was not clastogenic in two in-vivo mouse micronucleus assays.

**Impairment of Fertility:** The effect of phentolamine on female fertility has not been studied. Male rats treated with oral phentolamine for nine weeks (four weeks prior to mating, 3 weeks during the mating period and 2 weeks after mating) were mated with untreated females. At doses up to 648-times human therapeutic exposure levels at the C<sub>max</sub>, no adverse effects on male fertility parameters or on reproductive parameters in the untreated females mated with the treated males were observed.

Marketed by: Oyster Point Pharma, Inc., a Viatris company



If the patient is non-adherent, it is important to find out why. Ask them, “What do you think is standing in the way of you getting your drops in each day?” Optometrists, Dr. Marrelli notes, should try to work with their patients to find solutions, such as tying their drop use to other daily tasks (e.g., other medication use, brushing teeth, watching the evening news).

In some cases, she says, it may be warranted to look for other medications that are less expensive or don't have as many side effects. “We have a lot of options today.”

The asymptomatic nature of glaucoma can lead some patients to underestimate the seriousness of the disease and the necessity of treatment. ODs play a critical role in helping their patients understand the importance of treatment adherence.

“I do my best to be proactive from day one,” says Dr. Rixon. This includes thorough patient education and ongoing communication. “I have my patients look at the testing with me. This helps them understand the process and recognize that they are a critical member of the team.”

Patients with glaucoma often feel a sense of powerlessness and lack of control. A recent study identified modifiable behavioral factors that could increase patients' self-perceived ability and confidence to manage their own eye care.<sup>1</sup> Data showed that locus of control, level of depression and self-rated functional vision were each associated with patient behaviors, attitudes and beliefs needed for health self-management and may be important determinants of adherence behaviors. Targeting change in patients'

care beliefs and behaviors may improve activation and treatment outcomes, according to the study authors.

“Our study underscores the importance of identifying modifiable behavioral attributes to improve patients' activation levels and lead to increased involvement with their own care,” they concluded, while offering the following recommendations:<sup>1</sup>

- communicate an understanding of each patient's perspective and factors that impact their lives by linking treatment plans to patient goals
- educate patients about their condition and the need treatment adherence and for regular follow-up exams
- identify underlying patient beliefs and behaviors needed for their appropriate involvement in their own care

The financial implications of glaucoma care, including treatment costs and frequent follow-up visits, can also pose a significant burden, particularly on those without adequate insurance coverage. Cost barriers can prevent patients from accessing or adhering to necessary treatments. Optometrists should collaborate with patients to explore cost-effective treatment options, navigate insurance complexities and connect them with financial assistance programs when needed.

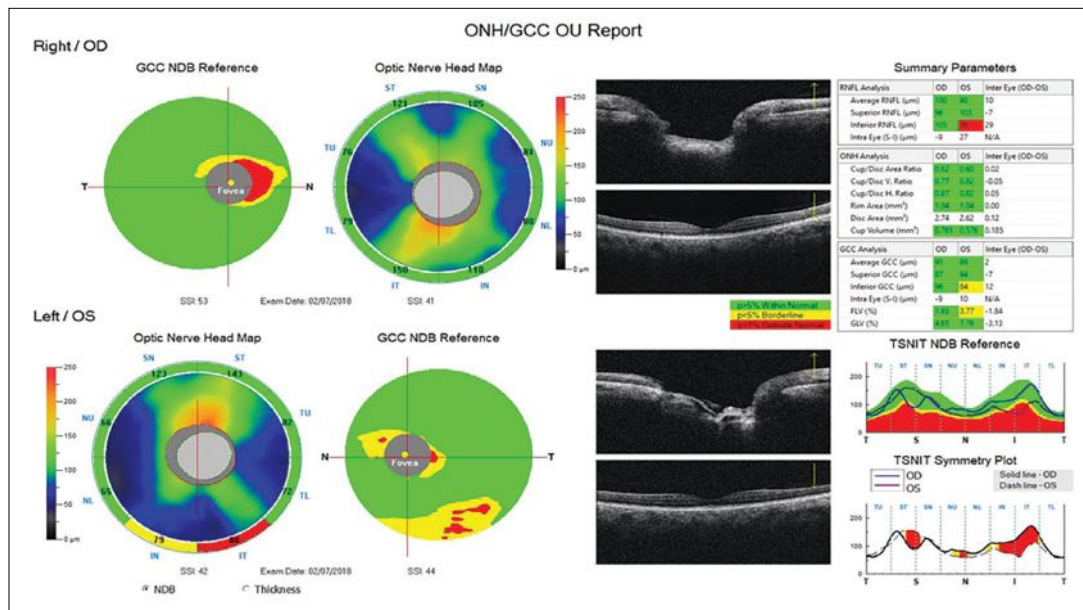


Fig. 3. This ONH/ganglion cell complex (GCC) analysis of the patient in Figure 2 demonstrates peripapillary nerve fiber layer and GCC defects correlating to the glaucomatous notch noted on the optic nerve.

### Supporting Underserved Communities

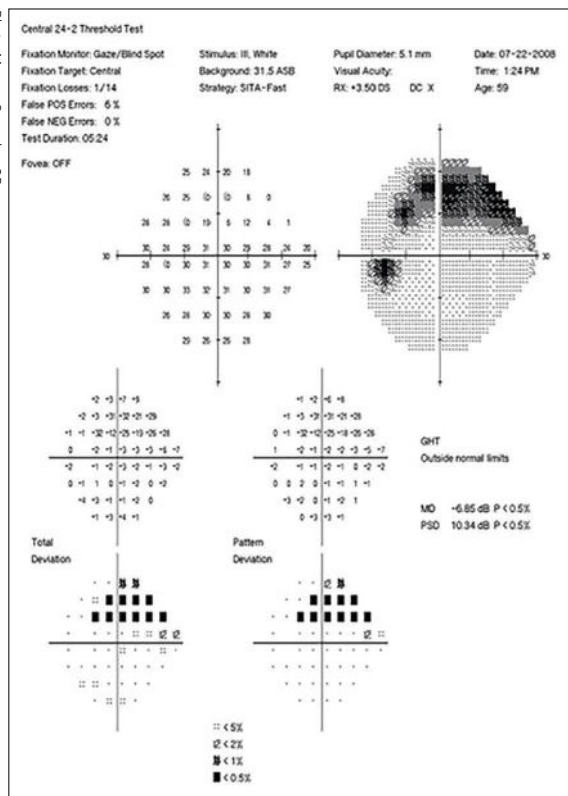
Individuals from these and/or minority communities must often contend with additional challenges, such as lack of insurance coverage, difficulty taking time off work for doctor visits, child-care issues and reliance on public transportation. These patients may also be hesitant to seek care due to a distrust of the medical establishment.

Research has shown that the prevalence of glaucoma in the United States is higher in Black and Hispanic patients compared to their white counterparts; however, these groups are less likely to receive preventive and ongoing care.

A recent analysis highlighted the existence of significant disparities in eye care among Black, Hispanic and Native American patients. Data demonstrated that glaucoma is undertreated in these racial minority groups, with Black and Hispanic individuals less likely to receive eye exams and imaging tests. These groups also have higher counts of emergency care and laser procedures.<sup>2</sup>

“Our results also demonstrate a significant disparity in care for Native American patients who were more likely to have poor vision and had

Photo: Marcus Gonzales, OD



**Fig. 4. Visual field associated with glaucomatous optic nerve seen in figures 2 and 3. This 24-2 Humphrey visual field OS demonstrating a superior temporal arcuate defect correlating to the notch noted on the optic nerve and to the NFL/GCC defects noted on the OCT.**

substantially lower utilization of almost all eyecare services, indicating that glaucoma may be undertreated in this population,” the study authors wrote.<sup>2</sup>

There are number of factors that could account for these disparities. For instance, Black patients have been found to have reduced medication adherence, which may contribute to glaucoma progression and poor vision outcomes.

“Lower adherence to medication regimens and follow-up appointments may be due, in part, to lower trust in the healthcare system among racial and ethnic minorities as mentioned previously,” the researchers noted.<sup>2</sup>

As the director of a charity eye clinic just north of downtown Dallas, Dr. Gonzales works closely with underserved communities. “In these patient populations, I have found that there can be a real distrust of doctors. They often feel neglected or treated poorly

by the medical community,” he says. “This is a hurdle that must be overcome and it takes time. We have to break down those trust barriers and show that we not only care but are invested in helping them achieve the best possible outcomes.”

When it comes to other challenges, like transportation to appointments, Dr. Gonzales is upfront with patients about the need for various exams and testing. Initially, he notes, a glaucoma diagnosis will require frequent appointments. By giving patients a heads up, they can coordinate with families or friends if they need rides to and from appointments. “At the same time, I will make it clear that this frequency will not always be necessary,” he says. “Once we start scheduling appointments three or six months out, I direct them to commu-

nity resources. For example, we have city-based transportation that can be scheduled in advance for patients who don’t have reliable access to transportation.”

Dr. Marrelli also sees a lot of patients from underserved areas who often don’t have insurance and/or find the cost of glaucoma medications and care to be challenging. “I work with companies to see if the patient might qualify for patient assistance to receive their medications for free,” she says. “If they don’t qualify, I look at generic possibilities to reduce the cost of medications as much as I can.

“Laser, while costing more initially, may ulti-

mately be more cost-effective for some glaucoma patients,” she adds. “For patients within our larger county, I often try to refer them in to our county system, which can provide comprehensive care on a sliding scale.”

Optometrists must be aware of such disparities to ensure they can properly care for these populations and help them navigate an already challenging diagnosis.

### AI’s Role in Glaucoma

Discussions around artificial intelligence (AI) and its potential use continue across various professions, including optometry, is no exception. A recent study published in *JAMA Ophthalmology* suggests that AI was able to match or outperform human specialists in glaucoma and retinal disease management.<sup>3</sup>

The overall pairwise comparisons revealed that both trainees and specialists rated the chatbot’s accuracy and completeness more favorably than those of their specialist counterparts, with specialists noting a significant improvement in the chatbot’s accuracy.

While acknowledging that further testing is needed, Andy Huang, MD, lead author explained, “For patients, the integration of AI into mainstream ophthalmic practice could result in quicker access to expert advice, coupled



**Fig. 5. Chronic use of preserved topical glaucoma drugs can lead to punctate keratitis. Options to reduce exposure include sustained-release agents, nonpreserved therapies and SLT.**

Photo: Paul Karpecki, OD

with more informed decision-making to guide their treatment.”

Although Dr. Gonzales has not used AI in his own practice, a preliminary look at the tool highlighted some of its potential. “When I asked the chatbot questions regarding glaucoma, such as ‘What can you tell me about glaucoma?’ or ‘How can I best manage my glaucoma?’ I received good information,” he says. “The responses to my questions were very broad, but it offered a starting point.”

Where does he think AI might be useful? “I think this could be helpful for young doctors or those who may not have a lot of experience with this condition. It could be a resource that assists ODs in the development of a concise initial discussion about glaucoma,” Dr. Gonzales suggests, while emphasizing that the nuances of individual patients must be taken into account.

Dr. Rixon says that he believes that AI and chatbots could be helpful

additions to patient education with the caveat that there is still a need for oversight. “We are in the fourth industrial revolution, and that’s AI,” he says. “There’s a lot of concern surrounding this technology, but I think that we have to be willing to embrace the positives while still recognizing and prioritizing human skill.”

### Takeaways

The various challenges associated with managing patients suffering from glaucoma, including psychological impacts, financial burdens and treatment adherence struggles go hand-in-hand and all have an effect on the patient experience. Through a holistic approach, optometrists can not only provide comprehensive clinical care, but also help their patients adapt to a life-changing diagnosis.

“Empowering your patients is an important part of glaucoma management,” says Dr. Rixon. “From the beginning, help them understand that

they can take control over their disease and find ways to empower them as they adjust to their ‘new normal.’”

ODs have a responsibility to help these patients navigate a multitude of challenges on their journey to help preserve vision and maintain a good quality of life by addressing the clinical aspects of this condition and also understanding and supporting them through the emotional, practical and financial obstacles they face.

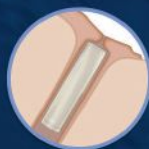By fostering a compassionate and collaborative approach, ODs can help their patients to overcome these challenges and thrive despite the diagnosis of glaucoma. ■

1. Morse AR, Hark LA, Gorrochurn P, et al. Association of psychosocial factors with activation among patients with glaucoma. 2024;S2589-4196(24)00027-9.

2. Ciociola EC, Sekimitsu S, Smith S, et al. Racial disparities in glaucoma vision outcomes and eye care utilization: an IRIS registry analysis. Am J Ophthalmol. 2024;S0002-9394(24)00126-0.

3. Huang AS, Hirabayashi K, Barna L, et al. Assessment of a large language model’s responses to questions and cases about glaucoma and retina management. JAMA Ophthalmol. 2024;142(4):371-5.

# OASIS® PUNCTAL PLUG COLLECTION

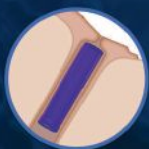

Up to 5 days  
SOFT PLUG®  
COLLAGEN  
PLUGS

Short-Term

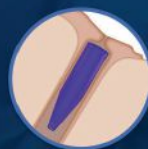

Up to 3 months  
SOFT PLUG®  
EXTENDED  
DURATION

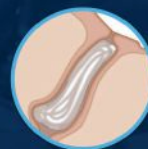

Up to 6 months  
SOFT PLUG®  
EXTENDED  
DURATION 180

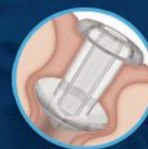Medium-Term



Up to 6 months  
SOFT PLUG®  
EXTENDED  
DURATION  
180-T TAPERED



FORM FIT®  
HYDROGEL  
PLUGS



SOFT PLUG®  
SILICONE  
PLUGS

Long-Term

OASIS Medical offers the broadest range of punctal occlusion options as a treatment for chronic dry eye, enhancing quality of life and visual comfort.



**Learn More:** Schedule a Punctal Plug Workshop with OASIS Medical

### To Order:

Call **844.820.8940**

Visit **[oasismedical.com](https://oasismedical.com)**

Email **[customerservice@oasismedical.com](mailto:customerservice@oasismedical.com)**

# AN ACTION PLAN FOR MANAGING DRY EYE

Use this new resource to help navigate the many tools and techniques available to us.



BY JAMES S. WOLFFSOHN, PhD,<sup>1</sup>  
JENNIFER P. CRAIG, PhD,<sup>2</sup>  
AND LYNDON JONES, PhD<sup>3</sup>

1. BIRMINGHAM, 2. AUCKLAND, 3. WATERLOO

It should come as no surprise that dry eye disease (DED) is a pressing global issue. Just look at these statistics for the United States alone: The prevalence of DED approximately tripled between 2005 and 2012, possibly due in part to increased awareness by patients and clinicians but attributed largely to changes in lifestyle.<sup>1</sup> More recent studies have estimated prevalence to be anywhere from 18% to 58%.<sup>2-5</sup>

DED has a profound detrimental impact on patients' quality of life.<sup>6</sup> Moderate dry eye has been likened to living with conditions such as moderate angina, while severe cases rate as equivalent to a disabling hip fracture.<sup>7</sup> Dry eye is the sixth most common presentation (accounting for 5.3%) for ocular medical services in the US.<sup>8</sup> An

estimated 9.2 million American and 5.2 million British individuals suffer from moderate-to-severe DED.<sup>9,10</sup> The economic burden to the US healthcare system was estimated over a decade ago to be approximately \$3.84 billion annually, while the overall societal cost was around \$55.4 billion.<sup>8,11</sup>

None of these numbers are meant to scare but rather to remind that this condition should not be dismissed as a trivial inconvenience. Diagnosing dry eye and prescribing the correct treatment is crucial for both patients and doctors alike. DED's pervasive impact on global populations has prompted the development of more diagnostic methods and treatments than those found in most other ocular conditions. For this reason, some clinicians may feel overwhelmed by the task, fearful of neglecting some unavailable tool or intervention.

To help, in 2023 the three of us and a number of colleagues worked

at the behest of the World Council of Optometry (WCO) to develop a new resource suitable for use by all optometrists, irrespective of any limitations on access to equipment and techniques. Alcon supported the effort and its aims. Below, we will explain the value and clinical use of the result of this collaboration, known as the WCO Alcon Dry Eye Wheel (*Figure 1*). An online version available at [dryeye.worldcouncilofoptometry.info/dry-eye-wheel](http://dryeye.worldcouncilofoptometry.info/dry-eye-wheel) offers an interactive experience with clickable segments revealing additional detail and professional guidance.

Bottom line: You needn't have the most expensive equipment in your practice to give a proper diagnosis and offer appropriate treatment. With just a few simple diagnostic tools and tests and the Wheel as guidance, you can have the confidence to take on virtually every dry eye patient that walks through your door.

## About the authors

**Dr. Wolffsohn** is a professor at the School of Optometry and Vision Science, College of Health and Life Science at Aston University in the United Kingdom. He is the academic Chair of the British Contact Lens Association, having been a past president and is on the executive of TFOS. Dr. Wolffsohn is also a Diplomate with Cornea, Contact Lenses and Refractive Technologies. He is a founder of Aston Vision Sciences, Eyoto and Wolffsohn Research Limited. His research team has received research support or lectureship honoraria from 3M, AOS, Alcon, Allergan, Bausch + Lomb, BCLA, CooperVision, CSIDryEye, DopaVision, Essilor, Espansione, International Myopia Institute, Johnson & Johnson Vision, Rayner, M2C Pharmaceuticals, Medmont, Novartis, NuVision, Santen, Scope Ophthalmics, SightGlass, Théa, Topcon and The Eye Doctor. **Dr. Craig** is a professor in the Department of Ophthalmology at the University of Auckland in New Zealand, where she heads the Ocular Surface Laboratory. She has served as vice chair of TFOS DEWS II and chair of the TFOS Lifestyle Workshop. The Ocular Surface Laboratory has received research support or lectureship honoraria from Alcon, Azura Ophthalmics, Resono Ophthalmic, Photon Therapeutics, Topcon and TRG Natural Pharmaceuticals. **Dr. Jones** is a professor at the School of Optometry and Vision Science, University Professor and Director of the Centre for Ocular Research & Education (CORE) at the University of Waterloo in Ontario, Canada. CORE has received research support or lectureship honoraria from Alcon, Azura Ophthalmics, Bausch Health, CooperVision, Essilor, Hoya, i-Med Pharma, Integral Biosystems, Johnson & Johnson Vision, Menicon, Novartis, Ophtecs, Oté Pharma, Santen, SightGlass, SightSage, Topcon and Visioneering. Dr. Jones is also a consultant and/or serves on an advisory board for Alcon, CooperVision, Johnson & Johnson Vision, Novartis and Ophtecs.



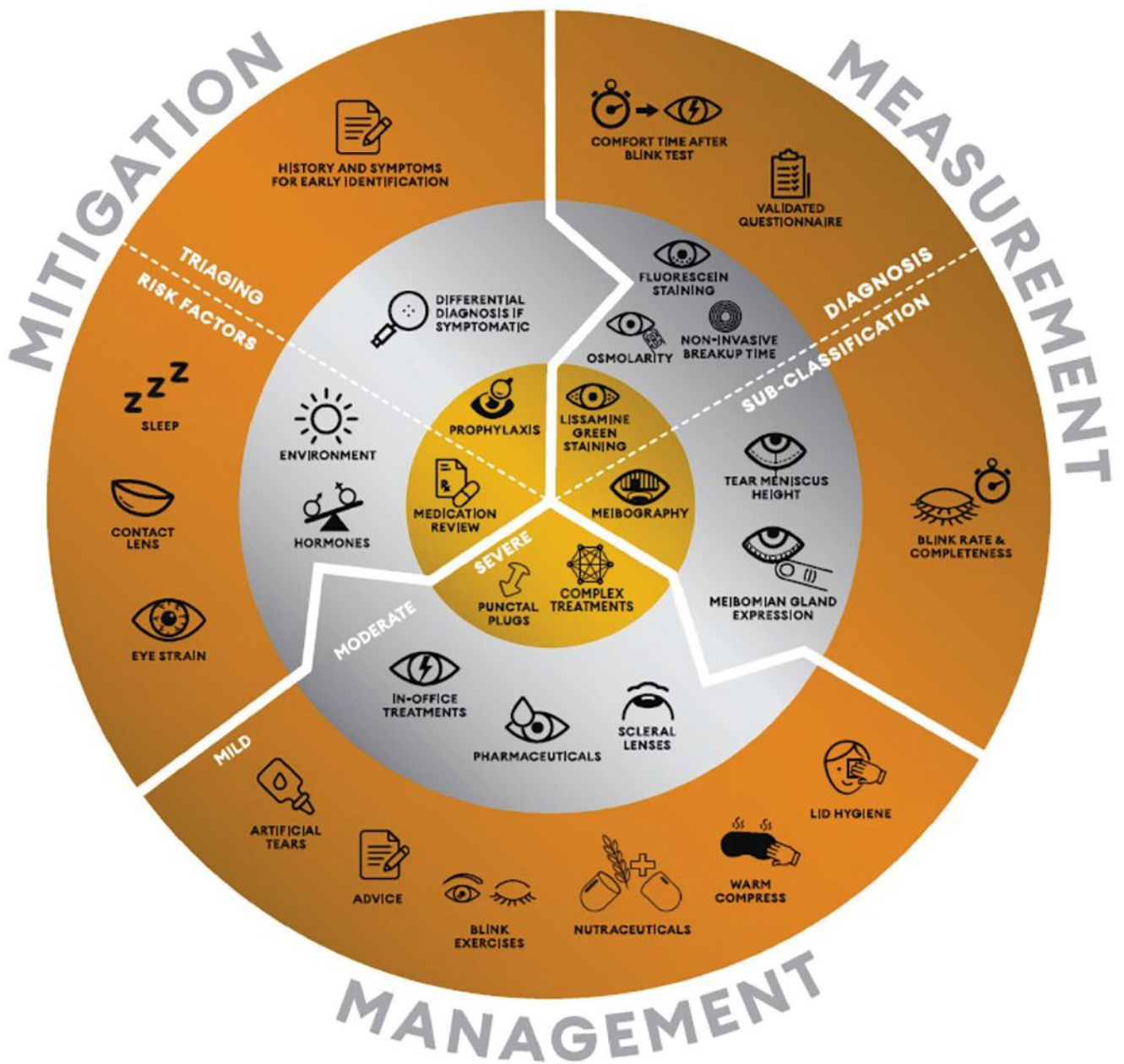


Fig. 1. The WCO Alcon Dry Eye Wheel distills much of the TFOS DEWS II report's clinical guidance into a simple conceptual model to follow.

### Proper Diagnosis

How can we define what dry eye is? A well-accepted definition, promulgated by the Tear Film and Ocular Surface Society (TFOS), states that, “Dry eye is a multifactorial disease of the ocular surface characterized by a loss of homeostasis of the tear film and accompanied by ocular symptoms, in which tear film instability and hyperosmolarity, ocular surface inflammation and damage, and neurosensory abnormalities play etiological roles.”<sup>12</sup> That’s been our operating prin-

ciple since the 2017 TFOS Dry Eye Workshop (TFOS DEWS II) report.

The pathogenesis of DED is driven by both inflammation and damage to the ocular surface.<sup>13,14</sup> Tear film instability promotes excessive tear evaporation and hyperosmolarity and exacerbates friction between the eyelids and the ocular surface, resulting in corneal, conjunctival and lid wiper epitheliopathy, which can be observed as ocular surface staining with the addition of ophthalmic dyes. Deterioration in cor-

neal nerves—vital in mediating inflammatory and nociceptive pathways—can also occur, perpetuating ocular surface damage, inflammation and symptoms.<sup>15</sup>

The tear film is complex in structure and less than one-tenth the thickness of a human hair.<sup>16</sup> It’s no wonder that with dry eye being multifactorial in nature, the balance (homeostasis) of the tear film can be easily disrupted. By definition, DED represents a subset of the umbrella term *ocular surface disease* (diagnosed on the basis of clinical

**TABLE 1. TFOS DEWS II CHECKLIST FOR DIFFERENTIALLY DIAGNOSING DRYNESS SYMPTOMS<sup>22</sup>**

<b>How severe is the eye discomfort?</b>	Unless severe, dry eye presents with signs of irritation such as dryness and grittiness rather than 'pain.' If the eye is painful, investigate for signs of trauma, infection or ulceration.
<b>How long have your symptoms lasted and was there any event that seem to be linked?</b>	Dry eye is a chronic condition and generally worse at the end of the day, so if sudden onset or linked with an event, examine the eye for trauma, infection or ulceration.
<b>Is your vision affected and does it clear on blinking?</b>	Vision is generally impaired with prolonged staring but should largely recover after blinking. Permanent reduction in vision requires an urgent ophthalmic examination.
<b>Are the symptoms or any redness much worse in one eye than the other?</b>	Dry eye is generally a bilateral condition, so if symptoms or redness are much greater in one eye than the other, a detailed eye examination is required to exclude trauma and infection.
<b>Do the eyes itch, are swollen, crust or have given off any discharge?</b>	Itch is usually associated with allergies and mucopurulent discharge with ocular infection.
<b>Are you a contact lens wearer?</b>	Contact lenses can induce dry eye symptoms, so lens wear should be optimized. <sup>17,29</sup>
<b>Have you recently had a respiratory infection, close contact with someone with a red eye, been diagnosed with any general health conditions or currently taking any medications?</b>	Patients should be advised to mention their symptoms to the health professionals managing their condition, as modified treatment may minimize or alleviate their dry eye.

signs). For dry eye to be a confirmed diagnosis, symptoms must also be present. This means that patients with observable clinical signs but no presenting symptoms should not receive a diagnosis of DED.

To that end, it's vital that clinicians remember to ask questions about how the eyes feel, including visual symptoms. It is recognized that a patient can become symptomatic if the ocular surface is challenged through contact lenses, environmental changes, chronic medication use (e.g., preserved topical drops for glaucoma) or undergoing refractive or cataract surgery.<sup>17-19</sup> In these cases of asymptomatic ocular surface disease, the treatment prescribed may be consistent with that recommended for someone with DED; however, the premise for, and potential benefits of, treatment to an asymptomatic patient would be expected to differ, as might the time frame for treatment in line with the planned intervention.

The latter half of the TFOS DEWS II dry eye definition relates to the pathophysiological features specifically associated with DED, to limit confusion with conditions that might masquerade as dry eye, such as ocular allergy or infection. TFOS DEWS II proposed key questions to help inform

the differential diagnosis, which may be of particular value to healthcare professionals who have a role in dry eye management and triaging, such as general practitioners and pharmacists.<sup>13,20,21</sup>

Accurate diagnosis is critical. For patients, it initiates access to the support they need; for practitioners, it enables consistency in approach and offers an evidence-based management plan. Defining diagnostic criteria is not without challenges, though. The diagnostic accuracy of a test should be compared to a "gold standard," but no such definitive test exists in the clinical setting; therefore, the dry eye diagnostic gold standard needs to be defined via expert consensus based on the best available scientific evidence.<sup>22</sup>

Approaches to setting diagnostic criteria based on an assumed dry eye prevalence are understandably flawed when this prevalence in itself is based on outcomes from a range of non-evidence-based and non-consensus-derived diagnostic criteria.<sup>23</sup> Increasing the number of tests can increase the sensitivity and specificity of a diagnosis relative to a pre-defined gold standard but decreases the practicality of making a firm diagnosis due to the testing time and cost burden, which can be counterproductive.<sup>22,23</sup> An additional consid-

eration in testing is the risk of induced reflex tearing distorting the assessment, as observed in clinical techniques that destabilize the natural tear film or irritate the eye, such as instillation of fluorescein dye or application of the Schirmer test.<sup>24-26</sup> Most importantly, unity in diagnostic testing is critical for the reasons highlighted, regardless of a practitioner's preferred tests.

### Dry Eye Wheel

The WCO Alcon Dry Eye Wheel is organized around two categorical frameworks. First, the doctor's clinical responsibilities are divided into three areas—mitigation, measurement and management—arranged in a circular form with arrows indicating that these efforts should be considered as a continuum. The second framework categorizes the work of DED care into three levels—simple, intermediate and advanced—and represents these, visually, as a series of concentric rings. Thus, you can think of the WCO Alcon Dry Eye Wheel as a 3x3 grid in a more dynamic form. Subdivisions add additional nuance to understanding the mitigation and measurement components, and it's important to note that all entries should be considered by the healthcare practitioner in relation to the ocular surface health, general health, environment and lifestyle of their individual patients.

Let us now consider the Wheel's components in more detail, with particular emphasis on the outermost ring, as that is the most broadly applicable.

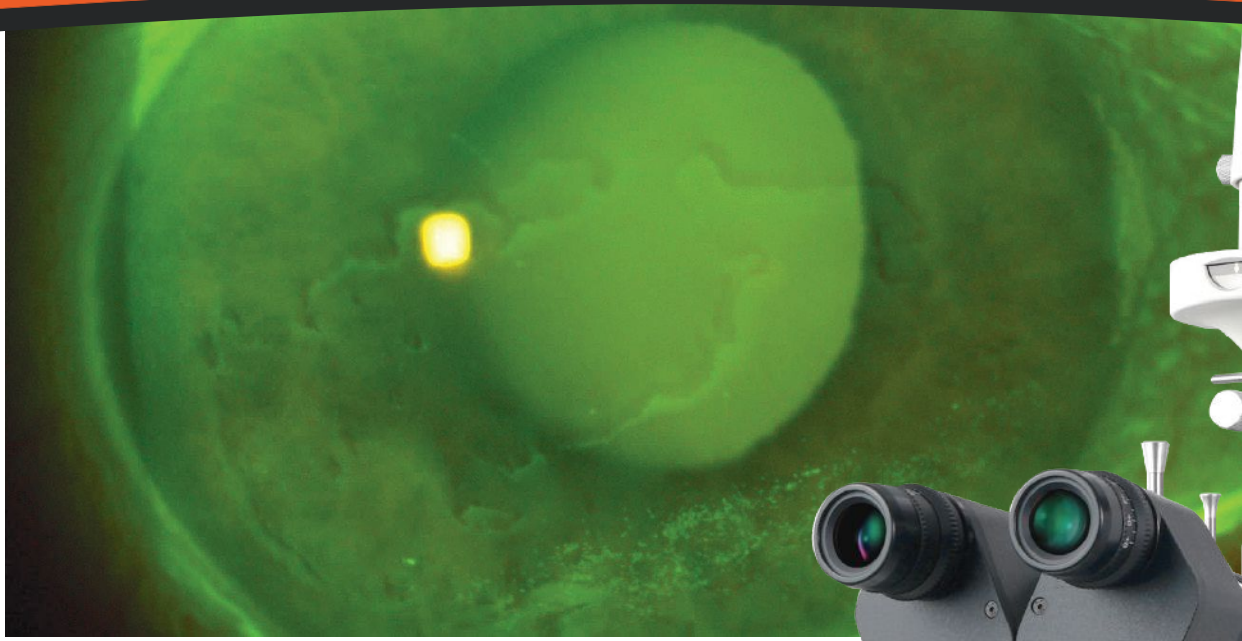
### The Outer Ring

This level of care, denoted in bronze, reflects the most widely accessible strategies and represents the simplest level to master. Within it, the three components of care comprise the following:

- **Mitigation.** This clinical responsibility requires thorough history and symptom-taking to identify any ocular symptoms, when and for how long they occur and any relevant inciting incident, such as trauma to the eye.

# The Anterior Segment Virtuoso

Firefly®



Nothing performs better in the anterior chamber than the Firefly® Imaging System. Using wavelengths similar to natural light, it delineates eye anatomy with an optical resolution of 200 lp/mm.

The standard Firefly comes fully loaded with video capture, automatic exposure, artificial intelligence, meibography, and a Wratten yellow filter. Optional Dry Eye Diagnostic module.

See Firefly's online image gallery, and we're sure you'll applaud the performance. Visit [eyefficient.com](https://www.eyefficient.com)



FIREFLY'S ONLINE GALLERY



EYEFFICIENT<sup>SM</sup>

© 2023 EYEFFICIENT, ALL RIGHTS RESERVED

**Ocular Surface Disease Index® (OSDI®)**  
 Ask your patients the following 12 questions, and circle the number in the box that best represents each answer. Then, fill in boxes A, B, C, D, and E according to the instructions beside each.

Have you experienced any of the following during the last week?	All of the time	Most of the time	Half of the time	Some of the time	None of the time
1. Eyes that are sensitive to light?	4	3	2	1	0
2. Eyes that feel gritty?	4	3	2	1	0
3. Painful or sore eyes?	4	3	2	1	0
4. Blurred vision?	4	3	2	1	0
5. Poor vision?	4	3	2	1	0

Subtotal score for answers 1 to 5 (A) \_\_\_\_\_

Have problems with your eyes limited you in performing any of the following during the last week?	All of the time	Most of the time	Half of the time	Some of the time	None of the time	N/A
6. Reading?	4	3	2	1	0	N/A
7. Driving at night?	4	3	2	1	0	N/A
8. Working with a computer or bank machine (ATM)?	4	3	2	1	0	N/A
9. Watching TV?	4	3	2	1	0	N/A

Subtotal score for answers 6 to 9 (B) \_\_\_\_\_

Have your eyes felt uncomfortable in any of the following situations during the last week?	All of the time	Most of the time	Half of the time	Some of the time	None of the time	N/A
10. Windy conditions?	4	3	2	1	0	N/A
11. Places or areas with low humidity (e.g., dry)?	4	3	2	1	0	N/A
12. Areas that are air conditioned?	4	3	2	1	0	N/A

Subtotal score for answers 10 to 12 (C) \_\_\_\_\_

Add subtotals A, B, and C to obtain D (D = sum of scores for all questions answered) (D) \_\_\_\_\_

Total number of questions answered (do not include questions answered N/A) (E) \_\_\_\_\_

Please turn over the questionnaire to calculate the patient's final OSDI score.

**DRY EYE QUESTIONNAIRE (DEQ-5)**

Name: \_\_\_\_\_

1. Questions about **EYE DISCOMFORT**:  
 a. During a typical day in the past month, how often did your eyes feel discomfort?  
 NEVER  RARELY  1  SOMETIMES  2  FREQUENTLY  3  CONSTANTLY  4

b. When your eyes feel discomfort, how intense was this feeling of discomfort at the end of the day, within two hours of going to bed?  
 NEVER HAVE IT  NOT INTENSE AT ALL  1  2  3  4  5  VERY INTENSE

2. Questions about **EYE DRYNESS**:  
 a. During a typical day in the past month, how often did your eyes feel dry?  
 NEVER  RARELY  1  SOMETIMES  2  FREQUENTLY  3  CONSTANTLY  4

b. When your eyes felt dry, how intense was this feeling of dryness at the end of the day, within two hours of going to bed?  
 NEVER HAVE IT  NOT INTENSE AT ALL  1  2  3  4  5  VERY INTENSE

3. Questions about **WATERY EYES**:  
 a. During a typical day in the past month, how often did your eyes look or feel excessively watery?  
 NEVER  RARELY  1  SOMETIMES  2  FREQUENTLY  3  CONSTANTLY  4

Score:  
 1a  1b  2a  2b  3  TOTAL  0

The OSDI and DEQ surveys collect vital information that can help clinicians assess dry eye symptoms at baseline and then track response to treatment. You can download these forms in the online version of this article at [www.reviewofoptometry.com](http://www.reviewofoptometry.com).

The other pressing aspect of mitigation is evaluation of each patient’s risk factors, particularly those that could be modified, such as sleep duration (e.g., less than six hours a night increases the odds of having dry eye), contact lens wear (where mitigation strategies to improve comfort have previously been published) or digital screen use, recognizing that digital eye strain is now very common and the evidence-based effectiveness of treatment strategies has recently been reported.<sup>17,20,27,28-30</sup>

• **Measurement.** The chief task here is to quantify both symptoms and signs of dry eye. The former can be documented by using the Ocular Surface Disease Index (cut-off  $\geq 13$ ) or 5-Item Dry Eye Questionnaire (cut-off  $\geq 6$ ) based on the TFOS DEWS II diagnostic criteria.<sup>22</sup> For the latter responsibility—documenting signs—establishing how long after a blink a patient remains comfortable with their eyes open has been shown to serve as a simple and rapid proxy for tear film stability assessment. This offers sensitivity of 71% and specificity of 90% compared to the full diagnostic workup when using a cut-off of <10 seconds in combination with meeting the symptoms criteria.<sup>31</sup> In terms of subclassification, evaporative dry eye impacts blink rate and com-

pleteness, which can be easily observed surreptitiously during history and symptom-taking.<sup>32</sup>

• **Management.** These recommendations align with the TFOS DEWS II stepwise treatment approach for DED and include advice about relevant risk factors and the impact of the patient’s lifestyle, the use of artificial tears (recognizing that effectiveness depends on the composition chosen for the patient), blink exercises—particularly for those demonstrating partial blinking—nutrition, warm compresses and lid wipes (avoid use of baby shampoo for lid cleansing, as it risks promoting ocular inflammation).<sup>33,34</sup>

Favorable responders to artificial tears typically report a reduction in symptoms within one month.<sup>45</sup> In studies with assessment up to six months, regular ongoing use of artificial tears can result in improved ocular signs over the ensuing months, highlighting the need for eyecare practitioners to encourage good compliance by promoting the use of the drops on an ongoing basis, at least four times a day.<sup>45</sup> A global survey of current practice in the management of DED showed that these simple treatments are recommended by practitioners across virtually the full range of dry eye severities and subtypes.<sup>46</sup>

## Middle Ring

This level—the silver ring—incorporates additional aspects to mitigation such as careful differential diagnosis (Table 1) and delves deeper into more complex aspects such as a patient’s environment and the impact of hormones on their dry eye-related symptoms.<sup>18,47</sup> Diagnostic measurements requiring a slit-lamp biomicroscope or specialist dry eye instrumentation include noninvasive break-up time assessment, epithelial fluorescein staining (corneal, bulbar and lid margin conjunctival staining at the lid wiper zone) and tear osmolarity. Bear in mind that lid wiper epitheliopathy (a presumed marker of cellular stress) presents much earlier than corneal staining in the natural history of DED development.<sup>45</sup>

Tests used to subtype aqueous-deficient dry eye include noninvasive tear meniscus height measurement (where less than 0.2mm is indicative of aqueous deficiency) and inspection of meibum secretions.<sup>22</sup> Patients with evaporative dry eye commonly present with meibum that is no longer clear but is cloudy, viscous or unable to be expelled by lid expression.<sup>48</sup> Other management options for patients where the bronze outer level management and therapy approaches do not offer sufficient relief include pharmacological approaches, in-office light, heat and massaging therapies, and the fitting of scleral lenses to protect and promote hydration of the ocular surface.<sup>33</sup>

## Central Ring

More advanced mitigations, shown in the central gold circle of the WCO Alcon Dry Eye Wheel, include prophylaxis discussions with a patient, such as those who are heavy gamers and smokers, and a possible medication review to limit iatrogenic effects.<sup>19,49</sup> Multidisciplinary interaction with the patient’s medication prescribers may be warranted to consider options with less impact on the ocular surface health. Lissamine green staining, both on the bulbar conjunctiva and lid margin, is diagnostic for dry eye, but it should

be noted that not all brands stain the ocular surface well.<sup>50</sup>

Meibography is a useful prognostic test that allows meibomian gland morphology and dropout to be visualized, with remaining gland length in particular associated with gland functionality, which can help inform appropriate treatment selection.<sup>51</sup> Viewing the images together with patients can serve as an excellent communication tool and aid with treatment compliance, particularly when considering prophylactic measures for those with less marked symptoms.

Finally, more complex management includes topical therapeutics, punctal plugging, biologic agents (including autologous serum or amniotic membrane) or surgical techniques, but these are required by only a small proportion of patients with dry eye.<sup>33</sup>

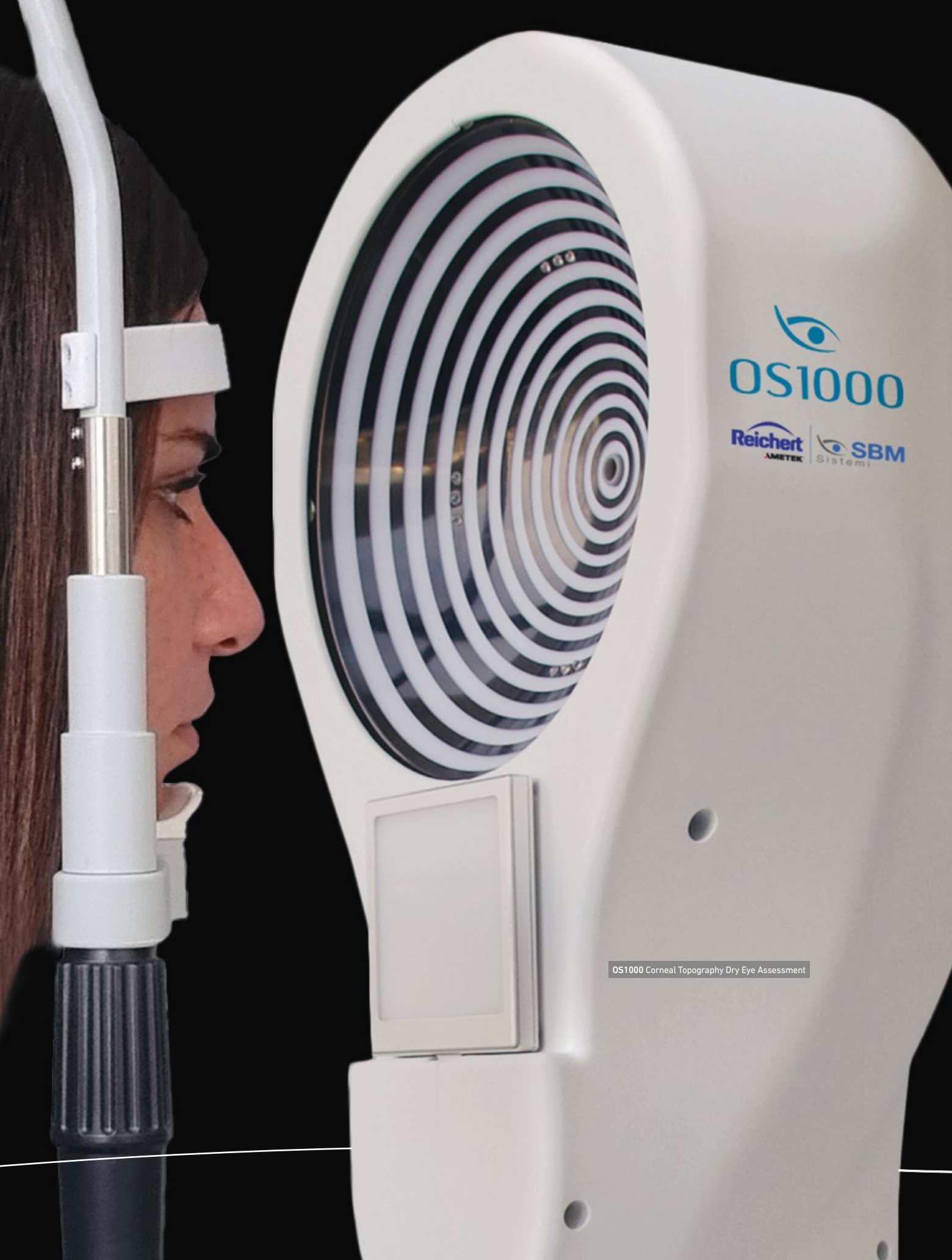## Takeaways

With an aging population, alongside challenges presented to the ocular surface by modern lifestyles, dry eye is a rapidly growing burden on individual patients and the healthcare system as a whole. Offering strategies to help manage DED is a duty of care for the eyecare professional, and can easily be accomplished with just a few simple tools at your disposal. Standardized diagnosis across the world is critical to ensure consistency in patient messaging and to avoid under-recognition and inadequate management of DED. The Dry Eye Wheel offers a practical, interactive tool highlighting, to all optometrists who encounter individuals with dry eye, ways in which they can get involved to improve quality of life for affected patients. ■

*The authors thank the WCO and Alcon for recognizing the need for a globally applicable dry eye mitigation, measurement and management tool, and supporting its conceptualization and development.*

1. Dana R, Bradley JL, Guerin A, et al. Estimated prevalence and incidence of dry eye disease based on coding analysis of a large, all-age United States health care system. *Am J Ophthalmol*. 2019;202:47-54.

2. Vidal-Rohr M, Craig JP, Davies LN, Wolffsohn JS. The epidemiology of dry eye disease in the UK: The Aston dry eye study. *Cont Lens Anterior Eye*. 2023;46(3):101837.
3. García-Marqués JV, Talens-Estarellas C, García-Lazaro S, et al. Systemic, environmental and lifestyle risk factors for dry eye disease in a mediterranean caucasian population. *Cont Lens Anterior Eye*. 2022;45(5):101539.
4. Wang MTM, Vidal-Rohr M, Muntz A, et al. Systemic risk factors of dry eye disease subtypes: a New Zealand cross-sectional study. *Ocul Surf*. 2020;18(3):374-80.
5. Cai Y, Wei J, Zhou J, Zou W. Prevalence and incidence of dry eye disease in Asia: a systematic review and meta-analysis. *Ophthalmic Res*. 2022;65(6):647-58.
6. Hossain P, Siffel C, Joseph C, et al. Patient-reported burden of dry eye disease in the UK: a cross-sectional web-based survey. *BMJ Open*. 2021;11(3):e039209.
7. Gayton JL. Etiology, prevalence and treatment of dry eye disease. *Clin Ophthalmol*. 2009;3:405-12.
8. Bradley JL, Ozer Stillman I, Pivneva I, et al. Dry eye disease ranking among common reasons for seeking eye care in a large US claims database. *Clin Ophthalmol*. 2019;13:225-32.
9. Farrand KF, Fridman M, Ozer Stillman I, Schaumberg DA. Prevalence of diagnosed dry eye disease in the United States among adults aged 18 years and older. *Am J Ophthalmol*. 2017;182:90-8.
10. Vehof J, Kozareva D, Hysi PG, et al. Prevalence and determinants of dry eye disease in a British female cohort. *Invest Ophthalmol Vis Sci*. 2013;54:2665.
11. Yu J, Asche CV, Fairchild CJ. The economic burden of dry eye disease in the United States: a decision tree analysis. *Cornea*. 2011;30(4):379-87.
12. Craig JP, Nichols KK, Akpek EK, et al. TFOS DEWS II definition and classification report. *Ocul Surf*. 2017;15(3):276-83.
13. Bron AJ, de Paiva CS, Chauhan SK, et al., TFOS DEWS II pathophysiology report. *Ocul Surf*. 2017;15(3):438-510.
14. De Paiva CS, Corrales RM, Villarreal AL, et al. Corticosteroid and doxycycline suppress MMP-9 and inflammatory cytokine expression, MAPK activation in the corneal epithelium in experimental dry eye. *Exp Eye Res*. 2006;83(3):526-35.
15. Belmonte C, Nichols JJ, Cox SM, et al. TFOS DEWS II pain and sensation report. *Ocul Surf*. 2017;15(3):404-37.
16. Willcox MDP, Argueso P, Georgiev GA, et al. TFOS DEWS II tear film report. *Ocul Surf*. 2017;15(3):366-403.
17. Jones L, Efron N, Bandamwar K, et al. TFOS lifestyle: impact of contact lenses on the ocular surface. *Ocul Surf*. 2023;29:175-219.
18. Alves M, Asbell P, Dogru M, et al. TFOS lifestyle report: impact of environmental conditions on the ocular surface. *Ocul Surf*. 2023;29:1-52.
19. Gomes JAP, Azar DT, Baudouin C, et al. TFOS lifestyle: impact of elective medications and procedures on the ocular surface. *Ocul Surf*. 2023;29:331-85.
20. Wolffsohn JS, Lingham G, Downie LE, et al. TFOS lifestyle: impact of the digital environment on the ocular surface. *Ocul Surf*. 2023;28:213-52.
21. Bilkhu PS, Wolffsohn JS, Tang GW, Naroo SA. Management of dry eye in UK pharmacies. *Cont Lens Anterior Eye*. 2014;37(5):382-7.
22. Wolffsohn JS, Arita R, Chalmers R, et al. TFOS DEWS II diagnostic methodology report. *Ocul Surf*. 2017;15(3):539-74.
23. Papas EB. Diagnosing dry-eye: which tests are most accurate? *Cont Lens Ant Eye*. 2023;46(5):102048.
24. Pauk SV, Petricek I, Tomic M, et al. Manual interferometric device for routine non-invasive tear film break-up time assessment. *Semin Ophthalmol*. 2021;36(3):94-102.
25. Cho P, Douthwaite W. The relationship between invasive and noninvasive tear break-up time. *Optom Vis Sci*. 1995;72(1):17-22.
26. Raj A, Dhasmana R, Nagpal RC. Anterior segment optical coherence tomography for tear meniscus evaluation and its correlation with other tear variables in healthy individuals. *J Clin Diagn Res*. 2016;10(5):NC1-4.
27. Papas EB, Ciolino JB, Jacobs D, et al. The TFOS International Workshop on Contact Lens Discomfort: report of the management and therapy subcommittee. *Invest Ophthalmol Vis Sci*. 2013;54(11):TFOS183-203.
28. Ayaki M, Kawashima M, Negishi K, Tsubota K. High prevalence of sleep and mood disorders in dry eye patients: survey of 1,000 eye clinic visitors. *Neuropsychiatr Dis Treat*. 2015;11:889-94.
29. Ayaki M, Tsubota K, Kawashima M, et al. Sleep disorders are a prevalent and serious comorbidity in dry eye. *Invest Ophthalmol Vis Sci*. 2018;59(14):DES143-50.
30. Li A, Zhang X, Guo Y, et al. The association between dry eye and sleep disorders: the evidence and possible mechanisms. *Nat Sci Sleep*. 2022;14:2203-12.
31. Wolffsohn JS, Craig JP, Vidal-Rohr M, et al. Blink test enhances ability to screen for dry eye disease. *Cont Lens Anterior Eye*. 2018;41(5):421-5.
32. Portello JK, Rosenfield M, Chu CA. Blink rate, incomplete blinks and computer vision syndrome. *Optom Vis Sci*. 2013;90(5):482-7.
33. Jones L, Downie LE, Korb D, et al. TFOS DEWS II management and therapy report. *Ocul Surf*. 2017;15(3):575-628.
34. Stapleton FJ, Alves M, Bunya VY, et al. TFOS DEWS II epidemiology report. *Ocul Surf*. 2017;15(3):334-65.
35. Galor A, Britten-Jones AC, Feng Y, et al., TFOS lifestyle: impact of lifestyle challenges on the ocular surface. *Ocul Surf*. 2023;28:262-303.
36. Kim M, Lee Y, Mehra D, et al. Dry eye: why artificial tears are not always the answer. *BMJ Open Ophthalmol*. 2021;6(1):e000697.
37. Pucker AD, Ng SM, Nichols JJ. Over-the-counter artificial tear drops for dry eye syndrome. *Cochrane Database Syst Rev*. 2016;2(2):CD009729.
38. Semp DA, Beeson D, Sheppard AL, et al., Artificial tears: a systematic review. *Clin Optom (Auckl)*. 2023;15:9-27.
39. Kim AD, Muntz A, Lee J, et al. Therapeutic benefits of blinking exercises in dry eye disease. *Cont Lens Anterior Eye*. 2021;44(3):101329.
40. Markoulli M, Ahman S, Arcot J, et al. TFOS Lifestyle: impact of nutrition on the ocular surface. *Ocul Surf*. 2023;29:226-71.
41. Bitton E, Lacroix Z, Leger S. *In vivo* heat retention comparison of eyelid warming masks. *Cont Lens Anterior Eye*. 2016;39(4):311-5.
42. Magno MS, Olafsson J, Beining M, et al. Chambered warm moist air eyelid warming devices - a review. *Acta Ophthalmol*. 2022;100(5):499-510.
43. Borchman D. The optimum temperature for the heat therapy for meibomian gland dysfunction. *Ocul Surf*. 2019;17(2):360-4.
44. Sung J, Wang MTM, Lee SH, et al. Randomized double-masked trial of eyelid cleansing treatments for blepharitis. *Ocul Surf*. 2018;16(1):77-83.
45. Craig JP, Muntz A, Wang MTM, et al. Developing evidence-based guidance for the treatment of dry eye disease with artificial tear supplements: a six-month multicentre, double-masked randomised controlled trial. *Ocul Surf*. 2021;20:62-9.
46. Wolffsohn JS, Trave Huarte S, Jones L, et al. Clinical practice patterns in the management of dry eye disease: a TFOS international survey. *Ocul Surf*. 2021;21:78-86.
47. Sullivan DA, Rocha EM, Aragona P, et al. TFOS DEWS II sex, gender and hormones report. *Ocul Surf*. 2017;15(3):284-333.
48. Tomlinson A, Bron AJ, Korb D, et al. The international workshop on meibomian gland dysfunction: report of the diagnosis subcommittee. *Invest Ophthalmol Vis Sci*. 2011;52(4):2006-49.
49. Muntz A, Turnbull PR, Kim AD, et al. Extended screen time and dry eye in youth. *Cont Lens Anterior Eye*. 2022;45(5):101541.
50. Delaveris A, Stahl U, Madigan M, Jalbert I. Comparative performance of lissamine green stains. *Cont Lens Anterior Eye*. 2018;41(1): 23-7.
51. Bilkhu P, Vidal-Rohr M, Trave-Huarte S, Wolffsohn JS. Effect of meibomian gland morphology on functionality with applied treatment. *Cont Lens Ant Eye*. 2022;45(2):101402.



OS1000 Corneal Topography Dry Eye Assessment

**NEW!**

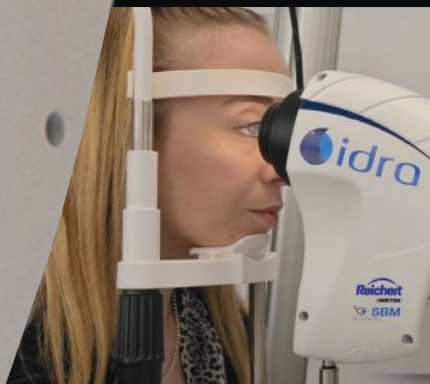# GROW YOUR DRY EYE PRACTICE

From effortless evaluation to soothing therapy, choose from a full spectrum of devices to start or expand your ocular surface and dry eye services.

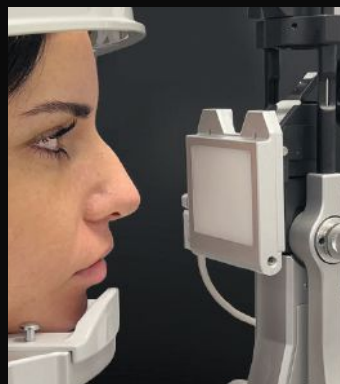LEARN MORE



**START TODAY! REICHERT.COM/DRYEYE**



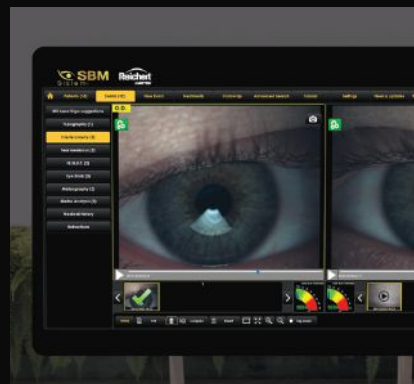Idra Comprehensive Dry Eye Assessment



DEM100-DSL200 Anterior Segment Imaging with Dry Eye Assessment



Activa Med Dry Eye Relief



Ocular Surface Analysis Software



*passionate about eye care*

# DRY EYE: MATCHING PATIENTS AND TREATMENTS

Experts present real cases and offer direction on management strategies and considerations for dealing with various types of ocular surface disease.



BY HARRIETTE CANELLOS, OD,  
AND MIRANDA KOEHLER, OD  
NEW YORK CITY; LEXINGTON, KY

Treating patients with dry eye is hardly ever straightforward, given the condition's widely varying presentations and lengthy list of potential causes. Even once you pin down the root cause of a patient's ocular surface disease, a second challenge awaits: deciding on a treatment approach that will effectively target their unique set of signs and symptoms. While it's certainly positive that a wide range of pharmaceuticals and in-office procedures is available today, clinicians must be able to use patients' clinical data to match them with the most appropriate intervention.

Here, we will present several clinical scenarios involving patients with various forms of dry eye, from the most common and obvious to the more rare and insidious. For each case, we'll discuss the workup and treatment options, as well as share how we would proceed.

## Case 1: Garden Variety Dry Eye

A postmenopausal woman in her mid-50s presents with a chief complaint of fluctuating vision and says she thinks her prescription glasses need updating. Meibomian gland expression is paste-like and there is only trace corneal staining and nasal conjunctival staining (*Figures 1a and 1b*). The patient reports that her symptoms worsen as the day progresses.

Our routine initial dry eye workup for a patient who presents like this always includes meibography. It is important to show patients the damage to their meibomian glands; think of this step as being equivalent to the OCT of the optic nerve head in glaucoma. A picture can educate a patient in a powerful way. As we know, 86% of all dry eye patients have meibomian gland dysfunction (MGD), and prevalence is higher in menopausal and postmenopausal women.<sup>1</sup>

Our recommended treatment plan would include a combination of an in-office thermal-pulsation treatment such as LipiFlow (Johnson & Johnson

Vision) and a prescription dry eye medication, which in this case would be Miebo QID OU (perfluoroheptyloctane ophthalmic solution; Bausch + Lomb), the first FDA-approved drop to target evaporative dry eye. The drug mimics the function of the lipid layer and thus is especially suited to patients experiencing symptomatic MGD.

In addition, we would recommend the patient take an oral omega-3 fatty acid supplement. Although there has been some controversy concerning the value of omega-3s in dry eye disease, most studies demonstrating its benefit recommend 3,000mg per day (2000mg of EPA and 1000mg of DHA).<sup>2</sup> Consider starting out with 2,000mg per day and go from there depending on tolerability and result.

It is also important to educate this patient that use of at-home warm compresses should be maintained; we would suggest a Bruder mask (Bruder Healthcare) or similar moist heat compress. It is important to educate our patients that the traditional warm washcloth does not provide the same

### About the authors

**Dr. Canellos** is a full-time faculty member of SUNY State College of Optometry. She is an associate clinical professor, instructor of record of the Fourth Year Program and director of the University Eye Center's Referral Service. She supervises interns and residents in the anterior segment/cataract clinics of the Advanced Care Service. Dr. Canellos is a Fellow of the Academy of Optometry, a member of the American Optometric Association, NY State Optometric Association, Diplomate of the American Board for Optometry and a former member of the New York State Board of Optometry. **Dr. Koehler** is an optometry resident focusing on ocular surface disease and cornea at Kentucky Eye Institute. She works with Paul Karpecki, OD, in clinical practice and research. Dr. Koehler graduated from Kentucky College of Optometry and is a member of the Kentucky Optometric Association. She has no financial disclosures.



heat retention.<sup>3</sup> Depending on the severity of the MGD, we recommend anywhere from five to 10 minutes daily or every other day sessions. It is important to note that in some cases, such as in ocular rosacea patients, the heat may exacerbate the inflammation and regular warm compresses may not be recommended.

Many dry eye patients assume that once they are treated with the Lipi-Flow procedure, they will no longer need to do the warm compresses. This is incorrect. Patient education is key to assure these individuals understand that they're dealing with a chronic condition, and consequently, the combination of in-office and at-home therapy is essential to keep irritating symptoms at bay.

## Case 2: Systemic Disease Origin (e.g., Sjögren's Syndrome)

A patient presents with photophobia, extreme dryness and difficulty keeping her eyes open, in addition to blurred vision. Gland expression is slightly turbid but expresses easily, and the patient has grade 3+ patchy corneal staining, grade 3 conjunctival staining and a scant tear meniscus (*Figures 2a and 2b*). She has been on cyclosporine drops in the past with no improvement and is currently using artificial tears every one to two hours during the day and a bland ointment at night.

Our first step would be to ask a few additional questions; for one, what concentration of cyclosporine was she using, and how long was she taking it? It's also beneficial to ask questions regarding the patient's systemic health, such as any personal history of dry mouth or joint pain and any family history of autoimmune disease.

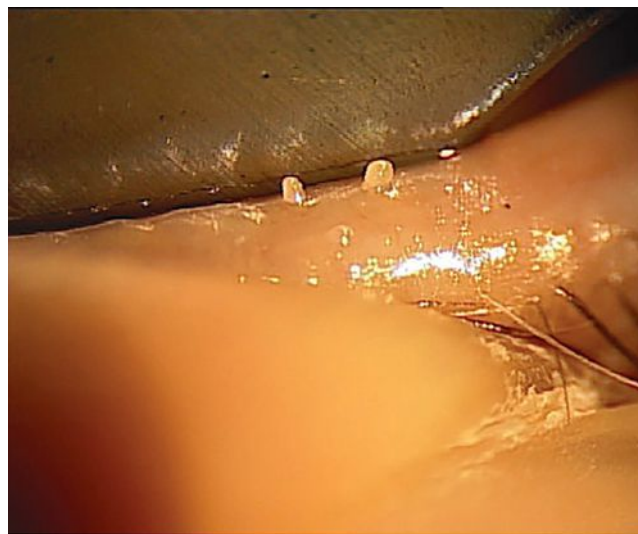
Our routine initial dry eye workup also includes the Schirmer test of tear volume. While there are certainly differing opinions on the validity of this test, at our practice we teach our students and residents that this, along with a reduced tear meniscus, is a good way to know that you are dealing with aqueous-deficient dry eye.

Another test included in our initial dry eye workup is InflammDry (Quidel), which helps guide the decision of whether to prescribe an anti-inflammatory drop. The test quantifies the level of MMP-9 (an inflammatory marker) in the tear film. "Soft" steroids such as loteprednol are widely used on- and off-label to treat inflammation associated with dry eye.<sup>4</sup>

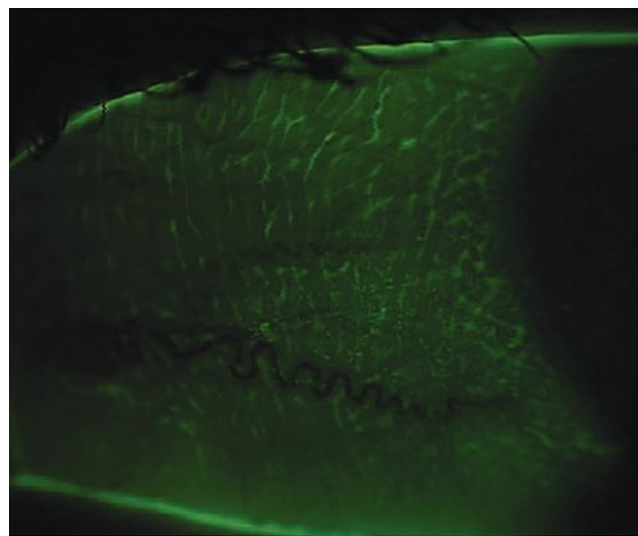
Although we tend to manage these types of patients aggressively, we do prefer a stepwise approach. In this case, our treatment strategy would be to start with a prescribed dry eye drop for her significant ocular surface disease. If she was on 0.05% cyclosporine, we would recommend either 0.09% cyclosporine or the latest topical cyclosporine, Vevye (cyclosporine 0.1%, Harrow Health). Lifitegrast (Xiidra, Bausch + Lomb) is also an option. In

conjunction, we would prescribe a topical steroid such as Eysuvis (loteprednol etabonate 0.25%, Kala Pharma) QID for at least two weeks with a taper. Of course, insurance coverage is always a factor in these decisions.

Punctal plugs are certainly an option after the patient's inflammation has improved. At SUNY, we prefer to use the six-month dissolvable plugs as opposed to silicone plugs due to occasional issues such as infection,



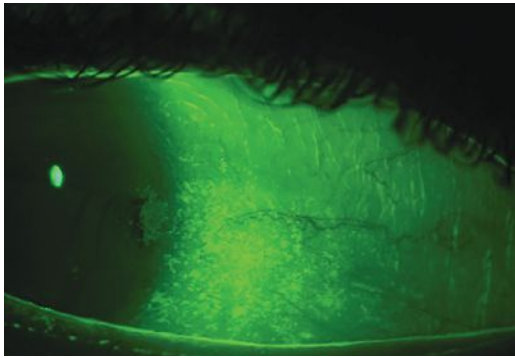
**Fig. 1a.** Expression shows thick and turbid meibum, indicating MGD. This patient would benefit from routine warm compresses.



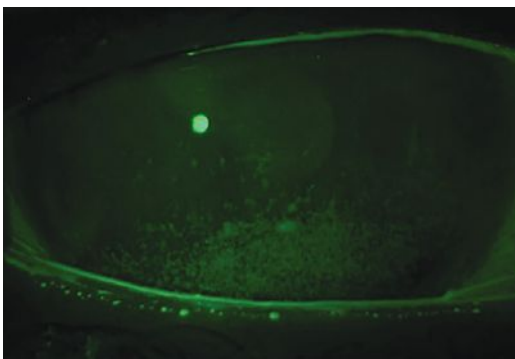
**Fig. 1b.** Trace conjunctival staining with NaFl and a Wratten filter, the latter of which helps to detect subtle conjunctival staining without using other irritating dyes. Conjunctival staining indicates damage to the mucin-producing goblet cells. A nighttime ointment with vitamin A is a useful treatment for this type of staining.

irritation, retention issues and granulomatous formation that can arise when silicone plugs are left in for prolonged periods of time.<sup>5</sup>

This is the type of patient who would require more clinic time. It is important that she understands that her condition is lifelong, and there are no quick fixes to permanently alleviate her discomfort. It is also important to explain that artificial tears will not resolve the underlying problem and, in



**Fig. 2a.** Grade 2-3+ conjunctival staining with patchy corneal staining. This is a common staining pattern seen in Sjögren's syndrome. NaFl and a Wratten filter highlight conjunctival staining and show damage to the goblet cells and mucin layer of the tear film. Significant temporal conjunctival staining, patchy corneal staining and a reduced tear meniscus seen together warrant testing for Sjögren's syndrome.



**Fig. 2b.** Grade 3+ coalesced corneal staining and a reduced tear meniscus in a patient with Sjögren's syndrome.

fact, may mislead her to neglect a more serious health issue. We would educate her that there may be a systemic association with her dry eye and, given this possibility, order lab work such as antinuclear antibody, rheumatoid factor and Sjögren's testing, along with a possible referral to a rheumatologist.

There are many treatment options for this patient, such as amniotic membrane placement as a short-term option for the keratitis, scleral contact lenses for long-term symptom management and vision correction if needed and, lastly, Regener-Eyes (Regener-Eyes) and blood-based drops such as autologous serum for longer-term treatment of ocular surface disease.

### Case 3: Post-LASIK

A 43-year-old male, s/p LASIK, complains of long-standing severe dry eye since undergoing LASIK OU. He has seen multiple doctors and reports that he has "tried everything." Exam findings show LASIK corneal scars, reduced tear film break-up time, no corneal staining and minimal MGD. His main complaint is "constant burning" in both eyes.

The first thing we ask patients is, "Can you tell me what bothers you the most about your eyes?" or "If you could only list one symptom, what would it be?" In this case, the patient complains of burning, which is one of the classic symptoms of neuropathic pain, aside from photophobia.

Next, we ask patients to tell us in detail exactly what they have tried and for how long. The second part of this question is vital, as some patients will prematurely stop taking a medication if they haven't received realistic expectations about how long it takes for the full therapeutic effect to kick in. Though many patients think they have "tried everything," there are often many treatment options left to tap into.

Our workup for this patient would include meibography, tear osmolarity, MMP-9 testing with InflammDry, fluorescein and lissamine green vital dyes, tear meniscus height measurement, Schirmer or phenol red thread tests and meibomian gland expression. In this specific case, we would also perform an additional test known as the proparacaine challenge test. This is completed by asking patients to rate their pain level from one to 10. Then, a drop of proparacaine is placed in their eyes, and they are asked once again to rate their pain. If the pain is due to ocular surface disease, their pain score will improve after the instillation of the topical anesthetic. In patients with

### Built for Speed

In practices with a high patient volume, performing a full battery of tests on every dry eye patient that walks in the door may not be realistic or efficient. Paul Karpecki, OD, points out that his referral OSD clinic, which sees more than 50 patients per day on average, has streamlined its dry eye workup to better accommodate the high patient volume. For example, he notes that his clinic has replaced Schirmer's testing with an evaluation of the tear meniscus height. Additionally, they use a Wratten filter and fluorescein dye in place of lissamine green dye. Every dry eye evaluation also includes meibomian gland expression, debridement, osmolarity and meibography, he says.

neuropathic pain, the pain score will remain similar.

The TFOS DEWS II report helped us to better understand neuropathic pain or "pain without stain" where the symptoms greatly outweigh the signs.<sup>6</sup> There are multiple causes for this, and ocular surgery is one of them. These patients are our most difficult to manage, so our approach is to aggressively treat the ocular surface and any ocular inflammation. Preservative-free artificial tears and a topical steroid, such as loteprednol etabonate, are good starting points. We have used everything from topical cyclosporine and lifitegrast, amniotic membranes and scleral contact lenses to help these patients' symptoms and have found particularly good success with the use of autologous serum drops.

To help improve these patients' quality of life, some may also benefit from comanagement with a pain management specialist and treatment with medications such as gabapentin.<sup>7</sup> It's critical to spend the time to educate these patients on the root cause of their discomfort, as they often bounce from one doctor to the next for "dry eye" treatments when what they actually have is centralized neuropathic pain rather than peripherally located dry eye disease.

## Case 4: Demodex and Ocular Rosacea

A 57-year-old male patient presents with complaints of dry, gritty eyes and fluctuating vision. His complaints are worse in the morning, but he reports that his symptoms don't improve much as the day progresses. Collarettes are noted on the eyelashes and telangiectasia on the eyelids with grade 2+ erythema (Figures 3a and 3b). Meibomian gland expression is minimal to none, with meibography showing more than 50% gland loss. However, tear meniscus height is close to normal. The patient has grade 2+ inferior corneal staining and trace conjunctival staining on the nasal and temporal areas. He reports that he has already tried artificial tears, hot compresses and lid scrubs, but he has not seen significant improvement.

First, we would look carefully at the skin around his face for signs of rosacea, a practice known as "external observation," which we personally don't think we do enough as optometrists.

We would also ask the patient if he is under the care of a dermatologist. Then, we would perform the Korb-Blackie light test to look for an incomplete lid seal. The inferior superficial punctate keratitis (SPK) may be indicative of poor lid closure, which can cause patients to experience worse symptoms in the morning.

It's also appropriate to evaluate this patient for lid laxity and suspect floppy eyelid syndrome. We would ask if he has a history of deep snoring and/or sleep apnea; if a patient answers "yes," ask about CPAP use, as misdirected air can cause severe inferior SPK in addition to the existing ocular surface condition.

This case represents a condition that is commonly seen yet often underdiagnosed. We are fortunate to have multiple treatment options for *Demodex* blepharitis and ocular rosacea. We would prescribe Xdemvy (lotilaner ophthalmic solution 0.25%; Tarsus Pharmaceuticals) BID for six weeks.

Prior authorization is required and, currently, the prescription is sent in via online pharmacies such as Blink Rx, CVS Specialty, Carepoint and Alliance Rx. Although we have both found great success with Xdemvy, we still perform the in-office treatment for more advanced *Demodex* blepharitis patients, such as a 50% tea tree-based (Ocusoft) or okra-based product (Zest). The combination of both prescription ectoparasiticide medication and in-office blepharoxfoliation can also be a successful approach. Additionally, we would encourage the patient to use a lid scrub such as Ocusoft Plus (Ocusoft), MyboClean (Danelli Ocular Creations) or a lid spray such as Avenova (NovaBay Pharmaceuticals) or HypoChlor (Ocusoft).

Topical azithromycin 1.0% (AzaSite, Thea Pharma) is one of our favorite topical medications for rosacea-related blepharitis (not demodicosis). We tend to prescribe it once at bedtime for two weeks. Since this is a thick drop, we ask

# Elevate Your Practice With 4 Easy Steps

Like a well-oiled machine, the  Zea Performance System™ components are designed to support and elevate each other and your practice.

## 1. MEASURE

Measure macular pigment optical density (MPOD), a critical biomarker for eye and overall health, with the new Zx Pro™.



## 3. ENROLL

Enroll patients into the Auto Refill Program, the industry-leading compliance solution that benefits practice and patient.



## 2. PRESCRIBE

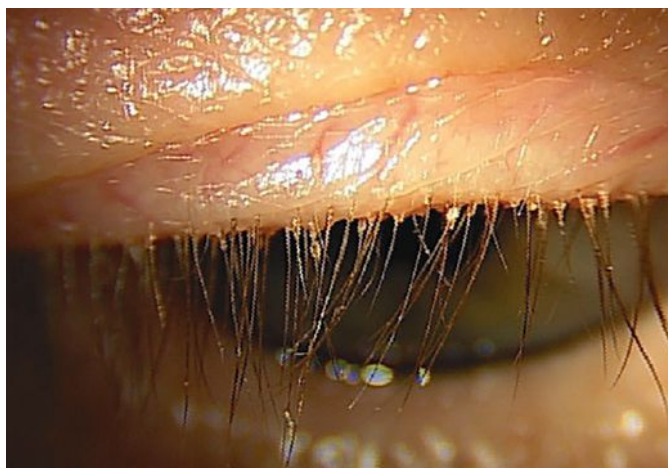Prescribe EyePromise nutraceuticals, the most clinically backed and comprehensive line of eye health nutraceuticals available and the only products guaranteed to increase MPOD.

## 4. MONITOR

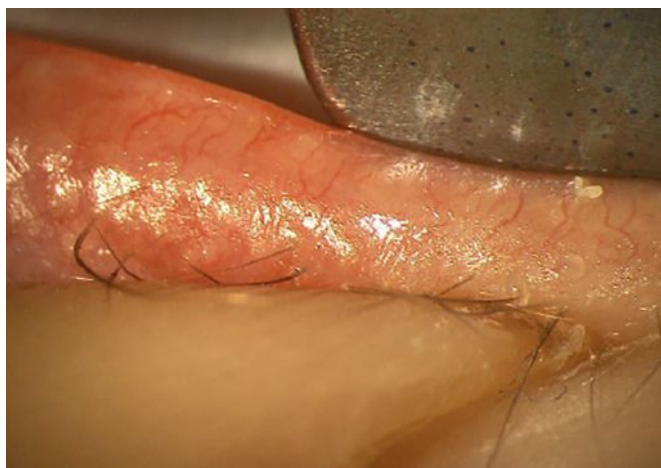Monitor patients' progress with 6-month MPOD retests using the Zx Pro to help ensure patients are getting the results you expect.

Find out how the Zea Performance System can take your practice success to the next level.





**Fig. 3a.** Grade 3+ collarettes at the base of a patient's eyelashes. Collarettes are pathognomonic for *Demodex* blepharitis. It is important to have patients look down to examine the base of the eyelashes, as this finding is easily missed when the patient is looking straight ahead.



**Fig. 3b.** Poor paste-like meibum expression and grade 2+ telangiectasia at the eyelid margin. Eyelid telangiectasia indicates ocular rosacea. Warm compresses would not be ideal for this type of MGD patient, as the heat exacerbates inflammation in ocular rosacea.

patients to close their eyes, smear the excess on their lids and lashes and then go to bed, since it can blur vision. After the course of AzaSite is complete, we ask that patients with floppy eyelids and incomplete lid closure use a lubricating ointment at night.

Patients with nocturnal inadequate lid closure benefit from using night seals to keep the eyelids closed while sleeping. SleepTite/SleepRite (Eye SleepTite) is a hypoallergenic, latex-free, oxygen-permeable patch that we recommend. We educate patients to tape one eye and use ointment in the other eye for patient safety and alternate eyes each night. Taping one eye at a time at night is safer to start with as a precaution, as patients may get up in the middle of the night to use the restroom and forget their eyelids are taped. Once the patient is comfortable with this regimen, we can consider patching both eyes overnight.

Once again, it's important to reiterate that it's best to steer clear of warm compresses in patients with ocular rosacea to avoid increasing inflammation and discomfort.

We would offer four sessions of intense pulsed light (IPL) for this patient to help treat the ocular rosacea and facial rosacea.<sup>8</sup> Oral doxycycline is also great option for this patient, and

we would likely wait to perform the IPL once they have been off doxycycline for at least a month. The decision to offer doxycycline before or after IPL, or not at all, is case-dependent. When there is both significant ocular and facial involvement, we start the doxycycline first to calm down the overall inflammation. Another reliable option is azithromycin, which may allow for a shorter treatment course and lower incidence of gastrointestinal issues.<sup>9</sup>

Finally, this patient should be comanaged with dermatology and referred for a sleep study if sleep apnea is suspected.

### Case 5: Glaucoma

A 62-year-old patient complains of dry, red irritated eyes for many years. She has been diagnosed with primary open-angle glaucoma and her current medications include Combigan BID OU and Travatan qHS OU. The slit lamp exam reveals diffuse SPK, erythema of the inferior palpebral conjunctiva and diffuse conjunctival injection, especially inferiorly OU.

We receive many referrals from doctors who treat glaucoma. Managing patients with both glaucoma and Ocular surface disease can be quite complicated. We know that their glaucoma

medications are the main culprit, but also recognize that their intraocular pressure must be controlled.

It may sound simple, but everting the upper eyelid is essential when evaluating ocular surface disease. It is important to look for any asymmetry in the superior and inferior palpebral conjunctiva. In cases of medication toxicity, we often see more inferior palpebral conjunctival inflammation.

We tend not to prescribe an additional topical medication for their ocular surface disease in fear that the drops will affect their adherence to the glaucoma therapy that they are already prescribed. If the patient was only on one drop at night, then we might consider adding cyclosporine or lifitegrast BID OU.

Our first step in treating this patient would be to switch to preservative-free glaucoma medications if possible, or consider Vyzulta (Bausch + Lomb), which we have found to be less toxic to the ocular surface than latanoprost. In clinical trials, Vyzulta also showed greater eye pressure-lowering ability compared to latanoprost, which could help take patients off some of their glaucoma drops. We would also recommend selective laser trabeculoplasty, with the same hope of reducing or eliminating topical medications.

If the patient still feels that they need artificial tears, we recommend they use preservative-free formulations to minimize toxicity. Patients are educated to space out their lubricating drops with their glaucoma medications and reminded that no dry eye drop should ever replace their prescribed glaucoma therapy.

Tyrvaya (varenicline solution 0.03mg, Oyster Point Pharma), the first approved nasal spray for the treatment of dry eye disease, has become our top treatment choice for managing the ocular surface of patients who use topical glaucoma medications. It is a nicotinic acetylcholine receptor agonist that stimulates the trigeminal parasympathetic pathway and is prescribed for twice-daily use intranasally.<sup>10</sup> Tyrvaya can also be beneficial to prescribe to patients who have difficulty instilling drops, such as patients with significant arthritis causing dexterity issues in their hands. One thing to remember when pre-

scribing this medication is to educate patients on proper instillation to the lower turbinates and avoid inhalation to minimize side effects such as excessive sneezing.

Who would have thought we would be prescribing a neurostimulator in the form of a nasal spray to our patients? This innovation is just one example of how considerably ocular surface treatment options have evolved compared to only five or 10 years ago.

### Takeaways

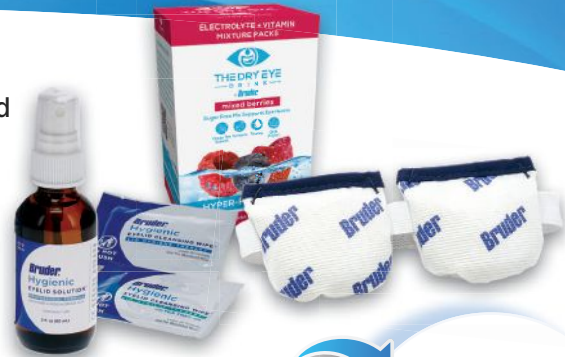Dry eye disease is chronic and multifactorial, presenting with a wide array of signs and symptoms and arising from multiple etiologies. As a result, it is critical to evaluate each unique patient to determine the best treatment, since in dry eye, “one size” certainly does not fit all. Fortunately, today, the availability of new diagnostics, treatments and pharmaceuticals has given us a greater armamentarium to care for these patients. ■

1. Lemp MA, Crews LA, Bron AJ, et al. Distribution of aqueous-deficient and evaporative dry eye in a clinic-based patient cohort: a retrospective study. *Cornea*. 2012; 31(5):472-8.
2. Dry Eye Assessment and Management Study Research Group N-3 fatty acid supplementation for the treatment of dry eye disease. *N Engl J Med*. 2018;378(18):1681-90.
3. Bitton E, Lacroix Z, Léger S. In-vivo heat retention comparison of eyelid warming masks. *Cont Lens Anterior Eye*. 2016;39(4):311-5.
4. Beckman K, Katz J, Majmudar P, Rostov A. Loteprednol etabonate for the treatment of dry eye disease. *J Ocul Pharmacol Ther*. 2020;36(7):497-511.
5. Horwath-Winter J, Thaci A, Gruber A, Boldin I. Long-term retention rates and complications of silicone punctal plugs in dry eye. *Am J Ophthalmol*. 2007;144(3):441-4.
6. Belmonte C, Nichols JJ, Cox SM, et al. TFOS DEWS II pain and sensation report. *Ocul Surf*. 2017;15(3):404-37.
7. Yoon H-J, Kim J, Yoon KC. Treatment response to gabapentin in neuropathic ocular pain associated with dry eye. *J Clin Med*. 2020; 9(11):3765.
8. Seo KY, Kang SM, Ha DY, Chin HS, Jung JW. Long-term effects of intense pulsed light treatment on the ocular surface in patients with rosacea-associated meibomian gland dysfunction. *Cont Lens Anterior Eye*. 2018;41(5):430-5.
9. Upaphong P, Tangmonkongvoragul C, Phinyo P. Pulsed oral azithromycin vs 6-week oral doxycycline for moderate to severe meibomian gland dysfunction: a randomized clinical trial. *JAMA Ophthalmol*. 2023;141(5):423-9.
10. Yu, M, Park, JK, Kossler, A. Stimulating Tear Production: Spotlight on Neurostimulation. *Clin Ophthalmol*. 2021;15:4219-26.



Make Bruder part of your dry eye treatment protocol

**Open your eyes to Bruder.™** You know us for our #1 doctor-recommended moist heat mask. But did you know we also offer a comprehensive line of science-based products for lid hygiene and hydration? Your patients' healthy eyes start here, with Hygiene and the Bruder Hygienic Eyelid Solution and Cleansing Wipes (with or without tea tree oil). And don't forget to Hydrate with The Dry Eye Drink™ by Bruder, specially formulated to help improve the ocular surface.



Read more about our expanding line of products



Stock up now on eye care essentials at [order.bruder.com](http://order.bruder.com), [eyes@bruder.com](mailto:eyes@bruder.com) or 888-827-8337. Learn about the science behind Bruder products at [bruderpro.com](http://bruderpro.com).

# ALL EYES ON OMEGAS

Despite some controversy, OFAs continue to play a role in the mitigation of dry eye.



BY HAMZA SHAH, OD, MS  
CARMEL, IN

**D**ry eye syndrome is one of the most prevalent ocular conditions, affecting people across age groups and lifestyles. Its commonality is a testament to the evolving landscape of modern living as well as an important reminder of the intricate balance required for optimal ocular health. Experiencing the digital era's relentless screen time demands and other environmental stressors, the discomfort of dry eyes has become more than just an inconvenience—it has evolved into a persistent challenge that demands timely chronic treatment.

To manage the condition effectively, traditional approaches such as artificial tears and prescription medications often take center stage; however, navigating the systemic underpinnings of ocular health reveals an obvious connection between dietary choices and the well-being of our eyes. Many practitioners have long considered nutritional supplements such as omega-3 fatty acids (O3FAs) to be a viable aid

not only in management of dry eye but prevention as well. This conventional wisdom has been challenged in recent years; however, leaving clinicians with some uncertainty. Let's delve into the topic of support for—and skepticism of—omega fatty acid use in dry eye.

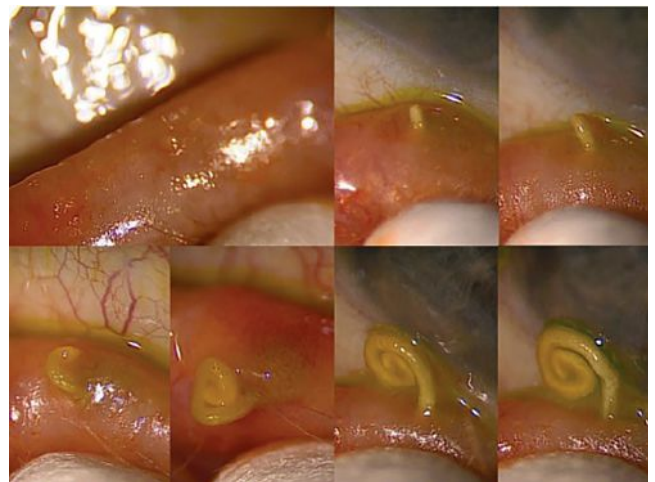## Dietary Significance

Fatty acids are an essential building block to maintain proper human function. O3FAs comprise alpha-linolenic acid, eicosapentaenoic acid (EPA) and docosahexaenoic acid (DHA). Omega-6 FAs (O6FAs), which conversely possess proinflammatory properties, consist of linoleic acid, gamma-linolenic acid, dihomo-gamma-linolenic acid and arachidonic acid.<sup>1,2</sup>

It is suspected that humans evolved to intake a ratio of O6FAs to O3FAs close to 1:1. The

Western diet typically maintains a ratio around 15:1, resulting in an excessive proinflammatory environment.<sup>3</sup> This skewed ratio is believed to contribute significantly to the elevated prevalence observed of cardiovascular diseases, autoimmune conditions, cancers and other inflammatory conditions within the Western population.<sup>4</sup>

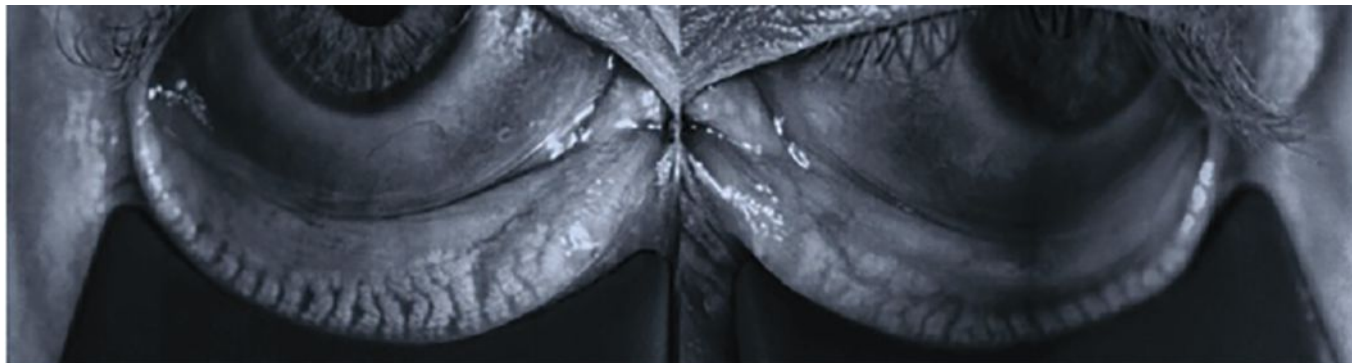
It is important to convey to patients the dietary need for consuming foods rich in O3FAs. Widely available options include salmon, herring, tuna,



Expression of a gland experiencing obstruction.

### About the author

**Dr. Shah** graduated from the Illinois College of Optometry before practicing full-scope optometry in the Chicagoland area. He later joined the Center for Sight and Dry Eye Institute in Carmel, Indiana, as the Ocular Disease Resident. His primary focus is in perioperative care, glaucoma and ocular surface disease. He has no financial disclosures.



**Meibography revealing characteristic signs of meibomian gland dysfunction: gland loss, truncation and tortuosity.**

sardines, flaxseed oil, edamame, walnuts, soybeans and fortified foods such as eggs, yogurt, juices, milk and infant formulas.<sup>5-7</sup> If patients cannot achieve a healthy O3FA intake, a supplement may be advised.

Omega-3 and omega-6 are essential fatty acids (EFAs) needed to produce eicosanoids, a class of hormone-like lipids that help regulate inflammation and provide local neutrophil migration. There are multiple types of eicosanoids: prostaglandins, thromboxanes and leukotrienes.<sup>8</sup> O3FAs and O6FAs physiologically have different purposes. O3FAs have anti-inflammatory and anticoagulant properties, whereas O6FAs promote inflammation and platelet aggregation.<sup>5</sup>

O3FAs may be anti-inflammatory through numerous mechanisms. O3FAs and O6FAs compete for the same enzyme to produce their respective eicosanoids. Note that eicosanoids are local signaling molecules needed to regulate different homeostatic processes. O3FAs tend to produce anti-inflammatory eicosanoids, whereas O6FAs tend to produce inflammatory eicosanoids. There is some evidence linking O3FAs to downregulating the production of inflammatory signaling molecules such as cytokines and chemokines.<sup>9</sup> These molecules are needed for homeostasis, but an overproliferation can lead to a chronic inflammatory environment. O3FAs also interact with genes influencing the production of inflammatory proteins.<sup>6</sup>

Other than producing inflammatory eicosanoids and competitively inhibit-

ing O3FA metabolism, O6FAs are also proinflammatory through cellular signaling. O6FAs can interact with cellular receptors to enhance production of inflammatory proteins like cytokines.

Resolvins are a group of O3FA metabolite molecules present in the liver, lungs and eyes. These molecules possess special properties for controlling the length and density of inflammation.<sup>3</sup> They have shown positive effects on goblet cell preservation, proper tear secretion and reduction of antigen-presenting cells into the cornea.<sup>10</sup>

### **Link to Dry Eye**

Because of the well-known anti-inflammatory effect of O3FAs, it is accepted by many that an oral supplement may provide a therapeutic effect for patients suffering from dry eye. O6FAs and O3FAs compete for the same enzyme (desaturase) that allows for their digestion. Breakdown of these EFAs presents with their respective inflammatory or noninflammatory effects.<sup>11,12</sup> This leads to two theories for why O3FAs are beneficial. One is that O3FAs compete with O6FAs, allowing for competitive inhibition. An alternative theory stems from evidence suggesting that O3FA supplementation can impact meibum composition, potentially aiding in the prevention and treatment of meibomian gland dysfunction.<sup>13</sup>

One study analyzed meibum composition using a technique called high-pressure liquid chromatography,

focusing on the peak profiles of polar lipids in patients with Sjögren's syndrome. Findings revealed patients with higher O3FA intake exhibited more single peaks as opposed to multiple peaks in their meibum composition. A single peak of polar lipids suggests the meibum is composed of one distinct type or pattern of polar lipids, whereas multiple peaks indicate a variety of polar lipid types—the latter suggesting less homogeneity in the lipid profile.<sup>14</sup> Lack of homogeneity might affect tear film stability, and if the tears' lipid layer is composed of a variety of polar lipids rather than a more uniformed composition, it might be less effective in preventing tear evaporation.

Controversially, the Dry Eye Assessment and Management (DREAM) study, conducted by the National Institute of Health, was released in 2019 and concluded O3FAs serve no benefit over the placebo of refined olive oil within a real world setting.<sup>15</sup> This study and its preliminary findings have provided room for clinicians to question whether to prescribe O3FAs to their dry eye patients. The study used olive oil, which is primarily n-9 oleic acid, as the placebo. Olive oil has been a placebo used in other clinical studies as well, but it does bring its own criticism. Oleic acid is thought to possess anti-inflammatory properties similar to O3FAs.<sup>16</sup> Subsequently, the DREAM study may have displayed the benefit of olive oil and other types of fats rather than proving that O3FAs are not beneficial for dry eye patients.

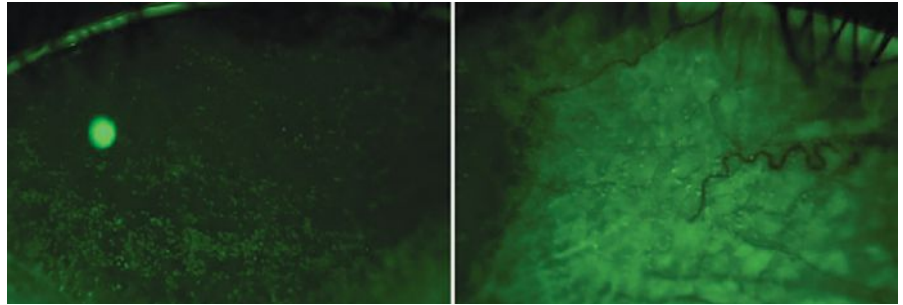
The study was also conducted in a real world setting, allowing for influences from factors that were not controlled (*e.g.*, other treatments, diet). A knee-jerk reaction to the study may cause some clinicians to overlook a great natural tool. Do note that this is just one study; more and similar studies are needed to gain a better idea regarding the precision of the results.

In contradistinction to the DREAM study's results, several studies have demonstrated benefits of omega EFAs in treating dry eye. A cross-sectional study using questionnaire-based data revealed a ratio of O6FA to O3FA greater than 15:1 was associated with a twofold higher prevalence of dry eye syndrome. Furthermore, women with greater O3FA intake exhibited reduced syndrome risk.<sup>17</sup> In a separate placebo-controlled study spanning 12 weeks, those taking O3FAs showed improvements in dry eye signs and symptoms; these included increased tear break-up time (TBUT), decreased ocular surface disease index score and reduced matrix metalloproteinase-9 positivity.<sup>18</sup> Yet another randomized, controlled study saw symptom improvement, reduced osmolarity, increased Schirmer test scores, improved TBUT and increased goblet cell density among patients taking omega EFAs.<sup>19</sup>

Taken together, these studies suggest an improvement across all three tear layers upon O3FA use. Given the substantial body of published clinical research, it becomes challenging to refute the therapeutic advantages of O3FAs when addressing dry eye.

## Clinical Use

When contemplating timing and dosage of an O3FA recommendation, it is crucial to consider an individual's needs. As discussed by the studies in the previous section, O3FAs have demonstrated benefits across all facets of dry eye. Therefore, it is advisable to introduce omega fatty acid supplementation early in the treatment paradigm. Dosages ranging from 1,000mg to 3,000mg of O3FA (EPA/DHA) per day are commonly prescribed for dry



**Corneal and conjunctival staining can serve as indicators of a patient's ocular dryness and the specific type of dry eye they may be experiencing.**

eye, reflecting a spectrum of patient needs and clinical considerations. One study concluded a dosage of 1,000mg of O3FA once daily may not be sufficient to yield therapeutic benefits, suggesting instead an intake of 2,000mg or greater to achieve therapeutic concentrations.<sup>20</sup>

The FDA has classified the acceptable daily intake of O3FAs to be up to 3,000mg per day with physician monitoring.<sup>9</sup> Consequently, any dosage exceeding 3,000mg should be prescribed with caution, considering both individual patients' needs and heightened risk of bleeding and side effects from O3FA.

It is imperative to educate patients that the adjustment of serum O3FA levels can span several months, so symptoms may not improve immediately. Clinicians have access to convenient in-office or home tests provided by third party companies such as OmegaQuant, Lipid Technologies and Carlson Labs, enabling them to conduct quantitative analyses and monitor patients' omega EFA levels. By integrating these easy-to-use testing options into their practices, clinicians can obtain valuable insights into an individual patient's nutritional status, thereby facilitating targeted interventions and personalized treatment plans.

It is the prescriber's responsibility to educate patients in how to select and handle the supplement. Although the intervention is quite safe, the patient should be educated on associated side effects of the supplement. These may include dyspepsia, diarrhea, gas, nausea, fishy taste and arthralgia.<sup>21-23</sup> These side effects can be reduced if

the supplement is taken with food. It is recommended to stay with brands that conduct testing for the purity of their product. Certain brands available in the US market, including but not limited to Nordic Naturals, Nature Made, Nature Bounty and Sundown, undergo third-party quality testing to ensure their products meet stringent quality standards. The product should be kept in its container and away from light and highly heated environments to reduce oxidation.

Along with its anti-inflammatory properties, O3FAs are also a natural anticoagulant.<sup>24</sup> When prescribing them to patients who are already on antiplatelet or anticoagulant medications or who have hemophilia, do so with caution. Always consider consulting the patient's primary physician if necessary.

Along with taking an oral supplementation, patients may also have access to topical eye drops containing O3FAs specifically derived from flaxseed oil. There have only been limited studies exploring the use of O3FAs in a topical formulation to date, but the ones that do exist show a reduction in inflammatory markers such as interleukin-17. Along with the reduction in inflammatory markers, human studies have also displayed improvements in dry eye symptoms, corneal staining and TBUT.<sup>25-28</sup> Refresh Optive Mega-3 (Allergan) is a readily available and preservative-free ocular lubricant that uses flaxseed oil in its formulation; this may offer amplified clinical value over other lubricants on the market.<sup>28</sup> Topical O3FAs have great potential and can be used in conjunction with oral O3FA



# Addressing Digital Eye Strain Starts with the Eye Care Professional

As digital device use continues to rise, more patients need tools and techniques to address symptoms of digital eye strain—but they are not talking to their eye care professionals.<sup>1</sup> New research shows it's time for change.<sup>2</sup>

■ **By Michele Andrews, OD**

In today's "always on" society, eye care professionals can assume that every patient in the chair is a digital device user. With this widespread use, it is no surprise that many are experiencing digital eye strain—and they are looking for solutions.<sup>3,4</sup>

"A New Look at Digital Eye Strain," a recent research report from CooperVision, examines whether patients are talking to their eye care professionals about digital device use and the impact to their eyes, and ultimately what that means for eye care practices. It also explores what tools and techniques people are using to try to reduce digital eye strain and demonstrates that there is plenty of opportunity for eye care professionals to help.<sup>1</sup>

## Digital Device use—and Digital Eye Strain—are Prolific

When asked to quantify their time in front of screens, over half of survey respondents said they spend on average six or more hours a day on digital devices, and one in four said they spend an average of a whopping nine hours or more looking at a screen.<sup>5,6</sup> While smartphones are the most used<sup>7</sup>—and the device on which the most respondents reported increased screen time over the past two years<sup>8</sup>—screen time has escalated on other devices as well.<sup>9</sup>

With prevalent digital device use, it comes as no surprise that seven in 10 respondents reported experiencing symptoms associated with digital eye strain.<sup>10</sup> Today's patients are also more aware of the connection between digital device use and ocular discomfort, with nearly half of patients indicating they believe their eye tiredness is caused by screen time.<sup>11</sup>



## Patients Seek Tools & Techniques to Help, but Aren't Talking to ECPs

Now that so many patients understand the effect digital device use can have on their eyes, they are pursuing various methods to help. Of the survey respondents who have digital eye strain, 99% had tried at least one method for reducing symptoms associated with the condition.<sup>12</sup> The specific tools and techniques vary significantly, and overall, awareness or implementation of each method remains low.

**Contact lenses designed to help with the symptoms associated with digital eye strain were the least known tool, with half of respondents reporting they had never heard of them—though a majority said they would be interested.<sup>13,14</sup>**

To learn more about contact lenses designed for this purpose—or any of the other tools and techniques—patients could speak with their eye care professionals about digital eye strain. Yet nearly 60% of respondents said they have never talked to an eye care professional about how digital device use affects their eyes.<sup>15</sup> Of those respondents who had the conversation, only 19% said that contact lenses designed to help with the symptoms of digital eye strain had been recommended.<sup>16</sup>

## Proactively Start the Conversation

### 1. Understand the patient's lifestyle and experience with digital eye strain.

"How many hours per day do you think you spend on all digital devices? How often do you experience the symptoms of digital eye strain—most commonly eye tiredness and dryness—during or after digital device use?"

### 2. Determine what they're doing to cope.

"What have you tried to help with these digital eye strain symptoms? How effective has this been for you?"

### 3. Establish a partnership with the patient.

"Together, let's find a solution that works best for you."

### 4. Be the expert. Provide recommendations for addressing digital eye strain.

"Here is what I recommend..." and "Did you know that there are contact lenses designed to help?"

## Breakthrough Contact Lenses Designed to Help

CooperVision's MyDay Energys® daily disposable and Biofinity Energys® monthly replacement contact lenses combine an **innovative aspheric lens design and advanced material technology** to address eye tiredness and dryness associated with digital eye strain.

The lenses feature **DigitalBoost™ Technology**, a single vision aspheric lens design unique to MyDay Energys® and Biofinity Energys® that delivers a +0.3D boost, which may help ease strain so the wearer can shift focus from on screen to off with less effort.\*<sup>17</sup> In addition, **Aquaform® Technology** retains water from core to surface without the need for surface coating or added wetting agents in the lens material.<sup>18</sup> This can help eyes feel less dry, even during times of reduced blinking, such as when on digital devices.



Eye care professionals have a unique opportunity to educate about digital eye strain, while also possibly growing their business. **With MyDay Energys® and Biofinity Energys® in the toolbox, eye care professionals have the power to make a difference in the lives of many of their patients. That's a win-win.**

For more information and to download the full research report, visit [coopervision.com/practitioner](https://coopervision.com/practitioner).



\*Based on a statistically significant difference of the mean change in Accommodative Microfluctuations and when compared to a lens without DigitalBoost™ /Digital Zone Optics® after reading on an iPhone 5 for 20 minutes held at a distance of 25 cm. Study conducted with Biofinity Energys® and sphere.

#### References

All figures are from Prodege. Total sample size was 750 vision corrected adults ages 18–44 in the United States. Fieldwork was undertaken October 16–22, 2023. The survey was conducted online.

**1.** CVI data on file 2023. US online survey: N=750, Vision corrected patients. US Adults Ages 18–44 who wear corrective spectacles and/or contact lenses. 58% haven't talked to their eye doctor. **2.** CooperVision (February 2024). "A New Look at Digital Eye Strain". Report of online survey results (2023): N=750, Vision corrected patients. US Adults Ages 18–44 who wear corrective spectacles and/or contact lenses. **3.** Coles-Brennan C, Sulley A, Young G. Management of digital eye strain. *Clinical and Experimental Optometry*. 2019;102(1):18–29. **4.** Vision Council 2016 Digital Eye Strain Report: Eyes overexposed, the digital device dilemma. **5.** CVI data on file 2023. US online survey: N=750, Vision corrected patients. US Adults Ages 18–44 who wear corrective spectacles and/or contact lenses. 52% say they spend 6 hours or more. **6.** CVI data on file 2023. US online survey: N=750, Vision corrected patients. US Adults Ages 18–44 who wear corrective spectacles and/or contact lenses. 25% say they send 9 hours or more. **7.** CVI data on file 2023. US online survey: n=750, Vision corrected patients. US Adults Ages 18–44 who wear corrective spectacles and/or contact lenses. **8.** CVI data on file 2023. US online survey: n=738, Vision corrected patients. US Adults Ages 18–44 who wear corrective spectacles and/or contact lenses and use a smartphone. 62% greatly increased/increased for both work and personal use. **9.** CVI data on file 2023. US online survey: N=750, Vision corrected patients. US Adults Ages 18–44 who wear corrective spectacles and/or contact lenses. 62% increased smart phone screen time, 41% increased TV screen time, 39% increased laptop screen time for both work and personal use. **10.** CVI data on file 2023. US online survey: N=750, Vision corrected patients. US Adults Ages 18–44 who wear corrective spectacles and/or contact lenses. 31% experience at least once a week or less, 32% experience a few days a week and 6% experience every day. **11.** CVI data on file 2023. US online survey: n=586, Vision corrected patients US Adults Ages 18–44 who wear corrective spectacles and/or contact lenses and experience eye tiredness. 48% responded that excessive screen time is what causes their eye tiredness. **12.** CVI data on file 2023. US online survey: N=516, Vision corrected patients US Adults Ages 18–44 who have digital eye strain at least once a week or less and who wear corrective spectacles and/or contact lenses. **13.** CVI data on file 2023. US online survey: N=750, Vision corrected patients. US Adults Ages 18–44 who wear corrective spectacles and/or contact lenses. 50% never heard. **14.** CVI data on file 2023. US online survey: N=750, Vision corrected patients. US Adults Ages 18–44 who wear corrective spectacles and/or contact lenses. Regardless of recommendations from their eye doctor, 56% interested/ very interested. **15.** CVI data on file 2023. US online survey: N=750, Vision corrected patients. US Adults Ages 18–44 who wear corrective spectacles and/or contact lenses. 58% haven't talked to their eye doctor. **16.** CVI data on file 2023. US online survey: n=294, Vision corrected patients. US Adults Ages 18–44 who wear corrective spectacles and/or contact lenses and talked to their doctor about their digital eye strain. **17.** Kajita M et al. Changes in accommodative micro-fluctuations after wearing contact lenses of different optical designs. *Cont Lens Ant Eye* (2020) In Press <https://doi.org/10.1016/j.clae.2020.03.003>. **18.** CVI data on file 2022.

A Medscape **LIVE!** CONFERENCE

Use discount  
code **SUMMER**  
for **20% OFF**  
registration!

# OCULAR SURFACE SYMPOSIUM

**SEPTEMBER 8, 2024**

RENAISSANCE CHICAGO DOWNTOWN HOTEL | CHICAGO, ILLINOIS

IN-PERSON 

## OVERVIEW

This comprehensive one-day event is designed to provide optometrists with a deep dive into ocular surface disease with an emphasis on dry eye, MGD, and blepharitis.

Experts will share the latest data, research, and current treatment strategies. Numerous clinical cases will be shown to demonstrate critical advances in diagnostic and therapeutic options for ocular surface disease, MGD, and blepharitis.

## CONFERENCE CHAIR



### Paul Karpecki, OD, FAAO

Director of Cornea and External Disease  
Kentucky Eye Institute  
Lexington, Kentucky  
Associate Professor  
University of Pikeville Kentucky  
College of Optometry  
Pikeville, Kentucky  
Director, Cornea and External Disease  
Center for Sight  
Carmel, Indiana

## wine AND WORKSHOPS

During the Wine and Workshops session, you'll be able to enjoy a glass of your favorite wine while you check out and demo a wide array of devices and instruments that are essential to any dry eye practice.



To register, scan the QR code, or visit:  
[www.reviewedu.com/oss](http://www.reviewedu.com/oss)



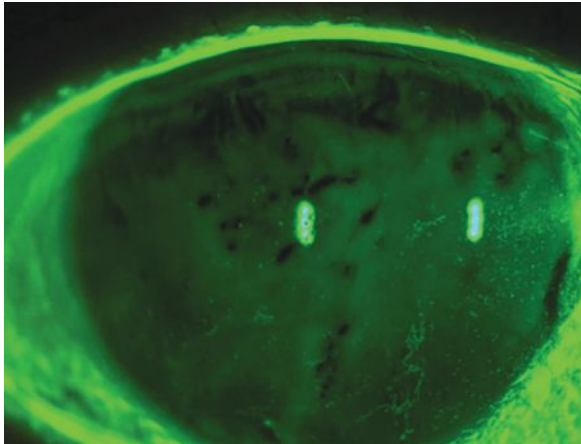
Postgraduate Institute  
for Medicine



\*Accreditation pending



Photo: Luis Rojas, OD



**Evaporative dry eye syndrome with reduced tear break-up time and punctate epithelial erosions. Many studies demonstrate O3FAs may help with mitigating signs and/or symptoms.**

benefits. From improving tear film stability to reducing inflammatory markers, O3FA supplementation offers a more holistic approach in managing dry eye. As eyecare professionals, it is incumbent upon us to integrate this knowledge into our practice, not only for treating this condition but also for promoting overall well-being. By embracing these insights, we can enhance the quality of life for countless patients troubled by dry eyes. ■

supplements. However, further human studies are necessary to fully evaluate the efficacy of topical O3FAs for dry eye.

In addition to its potential mediation of dry eye, oral O3FA supplementation has demonstrated a capacity to lower the risk for other medical conditions, including atrial fibrillation, chronic kidney disease, dementia, stroke, breast cancer and retinal diseases.<sup>29-34</sup> An eyecare professional's responsibility extends beyond mere ocular health—O3FAs could be recommended for use in patients beyond those solely afflicted with dry eye, given their potential for enhancing overall health and mitigating risks associated with various systemic conditions.

## Takeaways

The management of dry eye is far from clear cut; however, O3FAs present as one promising avenue for effective intervention. With an understanding of the intricate balance between omega-6 and omega-3 EFAs and their respective roles in inflammation modulation, clinicians can recommend nutritional supplementation to assist patients with their dry eye discomfort. Despite recent research like the DREAM study questioning the efficacy of O3FAs, the broader spectrum of evidence overwhelmingly supports their therapeutic

patients with dry eye disease. *Ocul Surf.* 2020;18(1):47-55.

16. Bermudez B, Lopez S, Ortega A, et al. Oleic acid in olive oil: from a metabolic framework toward a clinical perspective. *Curr Pharm Des.* 2011;17(8):831-43.

17. Miljanović B, Trivedi KA, Dana MR, et al. Relation between dietary n-3 and n-6 fatty acids and clinically diagnosed dry eye syndrome in women. *Am J Clin Nutr.* 2005;82(4):887-93.

18. Epitropoulos AT, Donnenfeld ED, Shah ZA, et al. Effect of oral re-esterified omega-3 nutritional supplementation on dry eyes. *Cornea.* 2016;35(9):1185-91.

19. Bhargava R, Pandey K, Ranjan S, Mehta B, Malik A. Omega-3 fatty acids supplements for dry eye—are they effective or ineffective? *Indian J Ophthalmol.* 2023;71(4):1619-25.

20. Christen WG, Cook NR, Manson JE, et al; VITAL Research Group. Efficacy of marine ω-3 fatty acid supplementation vs placebo in reducing incidence of dry eye disease in healthy US adults: a randomized clinical trial. *JAMA Ophthalmol.* 2022;140(7):707-14.

21. Skulas-Ray AC, Wilson PWF, Harris WS, et al; American Heart Association Council on Arteriosclerosis, Thrombosis and Vascular Biology; Council on Lifestyle and Cardio-metabolic Health; Council on Cardiovascular Disease in the Young; Council on Cardiovascular and Stroke Nursing; and Council on Clinical Cardiology. Omega-3 fatty acids for the management of hypertriglyceridemia: a science advisory from the American Heart Association. *Circulation.* 2019;140(12):e673-91.

22. Brinton EA, Mason RP. Prescription omega-3 fatty acid products containing highly purified eicosapentaenoic acid (EPA). *Lipids Health Dis.* 2017;16(1):23.

23. Fabian CJ, Kimler BF, Hursting SD. Omega-3 fatty acids for breast cancer prevention and survivorship. *Breast Cancer Res.* 2015;17(1):62.

24. Downie LE, Ng SM, Lindsley KB, Akpek EK. Omega-3 and omega-6 polyunsaturated fatty acids for dry eye disease. *Cochrane Database Syst Rev.* 2019;12(12):CD010116.

25. Jacobi C, Angstrom-Mehr S, Lange A, Kaercher T. A water-free omega-3 fatty acid eye drop formulation for the treatment of evaporative dry eye disease: a prospective, multicenter noninterventive study. *J Ocul Pharmacol Ther.* 2022;38(5):348-53.

26. Yilmaz FO, Yildiz BK, Tunc U, et al. Comparison of topical omega-3 fatty acids with topical sodium hyaluronate after corneal crosslinking: short term results. *Ocul Immunol Inflamm.* 2022;30(4):959-65.

27. Cagini C, Messina M, Torroni G, et al. Efficacy of topical microemulsion of fatty acids of the ω-3 series on the sub-epithelial corneal nerves regeneration after epithelium-off corneal collagen cross-linking for keratoconus. *Int Ophthalmol.* 2020;40(1):205-12.

28. Downie LE, Hom MM, Berdy GJ, et al. An artificial tear containing flaxseed oil for treating dry eye disease: a randomized controlled trial. *Ocul Surf.* 2020;18:148-57.

29. Qian F, Tintle N, Jensen PN, et al; Fatty Acids and Outcomes Research Consortium (FORCE). Omega-3 fatty acid biomarkers and incident atrial fibrillation. *J Am Coll Cardiol.* 2023;82(4):336-49.

30. Ong KL, Marklund M, Huang L, et al. Association of omega-3 polyunsaturated fatty acids with incident chronic kidney disease: pooled analysis of 19 cohorts. *BMJ.* 2023;380:e072909.

31. O'Keefe JH, Tintle NL, Harris WS, et al. Omega-3 blood levels and stroke risk: a pooled and harmonized analysis of 183,291 participants from 29 prospective studies. *Stroke.* 2024;55(1):50-8.

32. Sala-Vila A, Tintle N, Westra J, Harris WS. Plasma omega-3 fatty acids and risk for incident dementia in the UK Biobank Study: a closer look. *Nutrients.* 2023;15(23):4896.

33. Weir NL, Guan W, Karger AB, et al. Omega-3 fatty acids are associated with decreased presence and severity of diabetic retinopathy: a combined analysis of MESA and GOLDR cohorts. *Retina.* 2023;43(6):984-91.

34. Zhang ZL, Ho SC, Shi DD, et al. Erythrocyte membrane n-3 PUFA are inversely associated with breast cancer risk among Chinese women. *Br J Nutr.* 2024;131(1):103-12.

1. Takahata K, Monobe K, Tada M, Weber PC. The benefits and risks of n-3 polyunsaturated fatty acids. *Biosci Biotechnol Biochem.* 1998;62(11):2079-85.

2. Sadvovsky R, Collins N, Tighe AP, et al. Dispelling the myths about omega-3 fatty acids. *Postgrad Med.* 2008;120(2):92-100.

3. Simopoulos AP. The importance of the ratio of omega-6/omega-3 essential fatty acids. *Biomed Pharmacother.* 2002;56(8):365-79.

4. Simopoulos AP. The importance of the omega-6/omega-3 fatty acid ratio in cardiovascular disease and other chronic diseases. *Exp Biol Med (Maywood).* 2008;233(6):674-88.

5. Omega-3 fatty acids fact sheet for consumers. National Institutes of Health. [ods.od.nih.gov/pdfs/factsheets/Omega3FattyAcids-Consumer.pdf](https://ods.od.nih.gov/pdfs/factsheets/Omega3FattyAcids-Consumer.pdf). Updated July 18, 2022. Accessed March 14, 2024.

6. Harris WS. Fish oil supplementation: evidence for health benefits. *Cleve Clin J Med.* 2004;71(3):208-10,212,215-8 passim.

7. Jenkins DJA, Josse AR. Fish oil and omega-3 fatty acids. *CMAJ.* 2008;178(2):150.

8. Lewin GA, Schachter HM, Yuen D, et al. Effects of omega-3 fatty acids on child and maternal health. *Evid Rep Technol Assess (Summ).* 2005;(118):1-11.

9. Krupa K, Fritz K, Parmar M. Omega-3 fatty acids. In: *StatPearls*. Treasure Island (FL): StatPearls Publishing. [www.ncbi.nlm.nih.gov/books/NBK564314](https://www.ncbi.nlm.nih.gov/books/NBK564314). Updated January 17, 2023. Accessed March 14, 2024.

10. Paik B, Tong L. Topical omega-3 fatty acids eyedrops in the treatment of dry eye and ocular surface disease: a systematic review. *Int J Mol Sci.* 2022;23(21):13156.

11. Endres S, Ghorbani R, Kelley VE, et al. The effect of dietary supplementation with n-3 polyunsaturated fatty acids on the synthesis of interleukin-1 and tumor necrosis factor by mononuclear cells. *N Engl J Med.* 1989;320(5):265-71.

12. Calder PC. Polyunsaturated fatty acids, inflammation, and immunity. *Lipids.* 2001;36(9):1007-24.

13. Macsai MS. The role of omega-3 dietary supplementation in blepharitis and meibomian gland dysfunction (an AOS thesis). *Trans Am Ophthalmol Soc.* 2008;106:336-56.

14. Sullivan BD, Cermak JM, Sullivan RM, et al. Correlations between nutrient intake and the polar lipid profiles of meibomian gland secretions in women with Sjögren's syndrome. *Adv Exp Med Biol.* 2002;506(Pt A):441-7.

15. Hussain M, Shtein RM, Pistilli M, et al; DREAM Study Research Group. The Dry Eye Assessment and Management (DREAM) extension study—a randomized clinical trial of withdrawal of supplementation with omega-3 fatty acid in

Indicated for the  
treatment of the signs  
and symptoms of DED

**Miebo**<sup>™</sup>  
(perfluorohexyloctane  
ophthalmic solution)

**MIEBO is the first and only Rx eye drop for DED that directly targets evaporation<sup>1</sup>**



### Inhibits tear evaporation<sup>1-3\*</sup>

- Forms a monolayer at the air-liquid interface of the tear film which can be expected to reduce evaporation



### Rapid and sustained relief<sup>††</sup>

- Improvement in tCFS and eye dryness as early as Day 15 continued through Day 57 in 2 pivotal studies



### Excellent tolerability<sup>1,4-6‡</sup>

- Low rate of burning or stinging on instillation
- Blurred vision and conjunctival redness were reported in 1%-3% of individuals

**\*The exact mechanism of action for MIEBO in DED is not known.<sup>1</sup>**

**†Study design:** Two 57-day, multicenter, double-masked, saline-controlled studies (GOBI and MOJAVE) were conducted in adults ≥18 years old with a self-reported history of DED in both eyes. Across GOBI and MOJAVE, 614 patients received MIEBO and 603 patients received control with 591 and 575, respectively, assessed on Day 57. **Primary endpoints were change from baseline in tCFS and change from baseline in eye dryness score at Day 57.** Day 15 was the earliest time point at which signs and symptoms were evaluated in the trials. Day 57 was the last.<sup>1,5,6</sup>

**‡In 2 pivotal studies of >1200 patients (614 patients received MIEBO), there were no incidences of serious ocular AEs with MIEBO. Most AEs were considered mild. The discontinuation rate for MIEBO was comparable to control (pooled: 0.2% vs 0.5%; GOBI: 0.3% vs 1.0%; MOJAVE: 0% vs 0%). 0.5% (pooled) of patients experienced instillation site pain AEs, such as burning or stinging (GOBI: 1.0%; MOJAVE: 0%). Blurred vision (pooled: 2.1%; GOBI: 3.0%; MOJAVE: 1.3%) and conjunctival redness (pooled: 0.8%; GOBI: 0%; MOJAVE: 1.3%) were reported in 1%-3% of individuals.<sup>1,4-6</sup>**

AE, adverse event; DED, dry eye disease; tCFS, total corneal fluorescein staining.

#### INDICATION

MIEBO<sup>™</sup> (perfluorohexyloctane ophthalmic solution) is a semifluorinated alkane indicated for the treatment of the signs and symptoms of dry eye disease.

#### IMPORTANT SAFETY INFORMATION

- MIEBO should not be administered while wearing contact lenses. Contact lenses should be removed before use and for at least 30 minutes after administration of MIEBO
- Instruct patients to instill one drop of MIEBO into each eye four times daily
- The safety and efficacy in pediatric patients below the age of 18 have not been established
- The most common ocular adverse reaction was blurred vision (1% to 3% of patients reported blurred vision and conjunctival redness)

You are encouraged to report negative side effects of prescription drugs to the FDA. Visit [www.fda.gov/medwatch](http://www.fda.gov/medwatch) or call 1-800-FDA-1088.

**Please see accompanying Brief Summary of full Prescribing Information for MIEBO.**

**References:** **1.** MIEBO. Prescribing Information. Bausch & Lomb, Inc; 2023. **2.** Sheppard JD, Nichols KK. Dry eye disease associated with meibomian gland dysfunction: focus on tear film characteristics and the therapeutic landscape. *Ophthalmol Ther.* 2023;12(3):1397-1418. doi:10.1007/s40123-023-00669-1 **3.** Vittitow J, Kissling R, DeCory H, Borchman D. In vitro inhibition of evaporation with perfluorohexyloctane, an eye drop for dry eye disease. *Curr Ther Res Clin Exp.* 2023;98:100704. doi:10.1016/j.curtheres.2023.100704 **4.** Data on file. Bausch & Lomb, Inc; 2023. **5.** Tauber J, Berdy GJ, Wirta DL, Krösser S, Vittitow JL; GOBI Study Group. NOV03 for dry eye disease associated with meibomian gland dysfunction: results of the randomized phase 3 GOBI study. *Ophthalmology.* 2023;130(5):516-524. doi:10.1016/j.ophtha.2022.12.021 **6.** Sheppard JD, Kurata F, Epitropoulos AT, Krösser S, Vittitow JL; MOJAVE Study Group. NOV03 for signs and symptoms of dry eye disease associated with meibomian gland dysfunction: the randomized phase 3 MOJAVE study. *Am J Ophthalmol.* 2023;252:265-274. doi:10.1016/j.ajo.2023.03.008

**BAUSCH + LOMB**

©2024 Bausch + Lomb  
MBO.0098.USA.23 V2.0



Learn more at  
**MIEBO-ECP.COM**

## BRIEF SUMMARY OF PRESCRIBING INFORMATION

This Brief Summary does not include all the information needed to use MIEBO safely and effectively. See full Prescribing Information for MIEBO.

### MIEBO™ (perfluorohexyloctane ophthalmic solution), for topical ophthalmic use

Initial U.S. Approval: 2023

## 1 INDICATIONS AND USAGE

MIEBO™ (perfluorohexyloctane ophthalmic solution) is indicated for the treatment of the signs and symptoms of dry eye disease (DED).

## 4 CONTRAINDICATIONS

None.

## 5 WARNINGS AND PRECAUTIONS

MIEBO should not be administered while wearing contact lenses. Advise patients that contact lenses should be removed prior to and for at least 30 minutes after administration of MIEBO.

## 6 ADVERSE REACTIONS

### 6.1 Clinical Trials Experience

Because clinical trials are conducted under widely varying conditions, adverse reaction rates observed in clinical trials of a drug cannot be directly compared to rates in the clinical trials of another drug and may not reflect the rates observed in practice.

In patients with DED, 614 patients received at least one dose of MIEBO in two randomized controlled clinical trials across 68 sites in the United States. The most common ocular adverse reaction was blurred vision. Blurred vision and conjunctival redness were reported in 1-3% of individuals.

## 8 USE IN SPECIFIC POPULATIONS

### 8.1 Pregnancy

#### Risk Summary

There are no adequate and well controlled studies with MIEBO in pregnant women.

In animal reproduction studies with oral administration of perfluorohexyloctane during the period of organogenesis, no adverse maternal or developmental effects were observed in rats at doses up to 162 times the recommended human ophthalmic dose (RHOD) (*see Data*). Maternal toxicity, miscarriages and reduced fetal weights were observed in rabbits at all doses tested, with the lowest dose as 41 times the RHOD.

All pregnancies have a risk of birth defect, loss, or other adverse outcomes. In the US general population, the estimated background risk of major birth defects is 2 to 4%, and of miscarriage is 15 to 20%, of clinically recognized pregnancies.

#### Data

##### *Animal Data*

An embryofetal study was conducted in pregnant rabbits administered perfluorohexyloctane by oral gavage on gestation days 6 to 19, to target the period of organogenesis.

Perfluorohexyloctane produced maternal toxicity, characterized by reduced body weight gain and food consumption, and miscarriages at all doses tested, with the lowest dose as  $\geq 250$  mg/kg/day (41 times the RHOD based on body surface area). Reduced fetal weights were also observed at  $\geq 250$  mg/kg/day but no fetal mortality or malformations. A no observed adverse effect level (NOAEL) for maternal toxicity was not established in rabbits.

An embryofetal study was conducted in pregnant rats administered perfluorohexyloctane by oral gavage on gestation days 6 to 17, to target the period of organogenesis. There was no evidence of embryofetal toxicity or teratogenicity at doses up to 2,000 mg/kg/day (162 times the RHOD).

### 8.2 Lactation

There are no data on the presence of perfluorohexyloctane in human milk, the effects on the breastfed infant, or the effects on milk production. The lack of clinical data during lactation precludes a clear determination of the risk of MIEBO to an infant during lactation; however, the developmental and health benefits of breastfeeding should be considered along with the mother's clinical need for MIEBO.

### 8.4 Pediatric Use

The safety and effectiveness of MIEBO in pediatric patients below the age of 18 years have not been established.

### 8.5 Geriatric Use

No overall differences in safety and effectiveness have been observed between elderly and younger patients.

## 12 CLINICAL PHARMACOLOGY

### 12.3 Pharmacokinetics

The pharmacokinetics of perfluorohexyloctane following topical ocular administration of MIEBO has not been quantitatively characterized in humans. A single pharmacokinetic (PK) study was conducted that showed low systemic perfluorohexyloctane blood levels after topical ocular administration. Perfluorohexyloctane was not metabolized by human liver microsomes in vitro.

## 13 NONCLINICAL TOXICOLOGY

### 13.1 Carcinogenesis, Mutagenesis, Impairment of Fertility

Long-term studies in animals have not been conducted to evaluate the carcinogenic potential of perfluorohexyloctane.

Perfluorohexyloctane was not mutagenic or clastogenic in a standard battery of genotoxicity tests, including a bacterial mutagenicity assay (Ames assay), an in vitro chromosome aberration assay using human peripheral lymphocytes, and an in vivo bone marrow micronucleus assay in rats.

## 17 PATIENT COUNSELING INFORMATION

#### Use with Contact Lenses

Advise patients that contact lenses should be removed prior to and for at least 30 minutes after administration of MIEBO.

#### Administration Instructions

Advise patients to instill one drop of MIEBO four times daily into each eye as depicted in the Administration Instructions.

#### **Distributed by:**

Bausch & Lomb Americas Inc. Bridgewater, NJ 08807 USA

Patented. See <https://patents.bausch.com> for US patent information.

©2023 Bausch + Lomb

MBO.0046.USA.23 Issued: 5/2023



# Hire qualified opticians with Eyes On Eyecare

If you're frustrated by the hiring game, partner with Eyes On Eyecare® to find qualified candidates for your practice. For more than 10 years, Eyes On Eyecare has helped busy practice owners take the headaches out of hiring with specialized job posting and recruiting services.

## SOURCE OPTICAL TALENT MORE EFFICIENTLY WITH OUR:

- ✓ Engaged audience of licensed opticians - including active and passive job seekers
- ✓ Enhanced exposure of your job listing with syndication to top job platforms and our affiliate network
- ✓ Specialized recruiting team with years of eyecare experience to source and screen candidates

*I was able to attract good quality candidates to fill my openings.*

- Paul Naftali, OD

*"I had such a wonderful experience using Eyes On Eyecare. It was so easy to post a job and they walk you through the entire process. I recommend them to everyone I know."*

- Ashley Wojcik

PROUD PARTNER OF JOBSON OPTICAL GROUP

Learn more at [eyesoneyecare.com/hire-now](https://eyesoneyecare.com/hire-now)



# OCULAR MANIFESTATIONS OF AUTOIMMUNE DISEASES: HOW TO UNDERSTAND AND IDENTIFY

Optometrists have a key role to play when it comes to the overall health of their patients.



BY MELISSA CHEN, OD,<sup>1</sup> THERESA JAY, OD,<sup>2</sup> STEVE NJERU, OD,<sup>3</sup> AND ERIC SPOTTS, OD<sup>2</sup>

<sup>1</sup>CHARLOTTE, NC; <sup>2</sup>KERNERSVILLE, NC; <sup>3</sup>CHILLICOTHE, OH

A number of autoimmune diseases may initially present with only ocular manifestations prior to any systemic involvement. Common ocular manifestations of autoimmune diseases include keratitis sicca, peripheral ulcerative keratitis, episcleritis, scleritis, optic nerve edema, vision loss, diplopia or eyelid ptosis. Maintaining a high index of suspicion allows optometrists to further investigate the etiology of ocular findings and coordinate prompt management and treatment for autoimmune conditions in order to reduce systemic or ocular impairment. Here, we will discuss various autoimmune diseases and how they may present in the eye.

## Graves' Disease (GD)

This autoimmune disorder involves the thyroid gland, characterized by the presence of circulating autoantibodies that bind to and stimulate the thyroid-stimulating hormone receptor (TSHR), resulting in hyperthyroidism and inflammation.<sup>1</sup> Although most often associated with hyperthyroidism, Graves' may present in euthyroid or hypothyroid conditions. Thyroid eye disease (TED), also known as Graves' ophthalmopathy, is a disease that primarily targets retrobulbar tissue leading to ocular complications.<sup>1</sup> TED is characterized by autoantibodies targeting and activating orbital fibroblasts causing enlargement of extraocular muscles and connective tissues.<sup>2</sup>

Graves' disease and TED can occur at any age but most commonly occur within the third to fifth decade of life, with women at a higher risk than men by sixfold.<sup>3-6</sup> Despite a higher incidence in females, men who are diagnosed are

four-times more likely to have severe TED complications.<sup>3</sup> Other risks include genetic, environmental and immune factors. Smoking is the most consistently linked environmental factor, with an increase in risk by seven to eight times.<sup>3</sup>

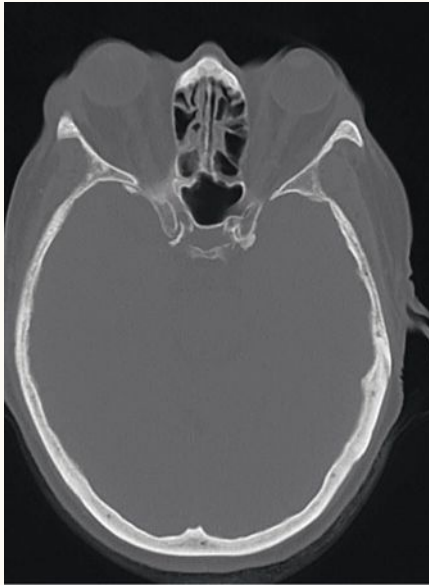
While TED pathophysiology is not well established, the most accepted mechanism involves robust activation of orbital fibroblasts.<sup>4</sup> These orbital fibroblasts play a critical role in the activation of autoantibodies to TSHR and insulin-like growth factor-1 (IGF-1R).<sup>2,7</sup> The orbital infiltration cascade then leads to development of extracellular matrices and fibroblast proliferation, causing water retention, edema and connective tissue remodeling.<sup>3,7</sup> This results in extraocular muscle enlargement and orbital fat expansion.

Ophthalmic manifestations vary by case but may include periorbital edema and erythema, eyelid retraction, proptosis, restrictive strabismus, chemosis,

### About the authors

**Dr. Chen** is a staff optometrist at the Charlotte VA Health Care Center. She received her Doctor of Optometry from Salus University, Pennsylvania College of Optometry in 2019. She then went on to complete her residency at the W.G. (Bill) Hefner VA Medical Center. She also serves as an examiner at the National Board of Examiners in Optometry and as secretary of the North Carolina Chapter of American Academy of Optometry. **Dr. Jay** is an active staff optometrist at the Kernersville VA Health Care Center in Kernersville, NC. She received her Doctor of Optometry from The Ohio State University College of Optometry in 2020. She then went on to complete her ocular disease/primary eye care residency at the W.G. (Bill) Hefner VA Medical Center. She is a fellow of the American Academy of Optometry and serves as vice president of the North Carolina Chapter of American Academy of Optometry. **Dr. Njeru** is a staff optometrist at the Chillicothe VA Medical Center. He graduated from The Ohio State University College of Optometry and completed his ocular disease residency at the Chillicothe and Columbus VA. He is a fellow of the American Academy of Optometry. **Dr. Spotts** graduated from Pennsylvania College of Optometry in 2001 and went on to complete a primary care residency at Northeastern State University Oklahoma College of Optometry from 2005 to 2006. He is currently an optometrist at Charlotte VA Health Care Center. They have no financial disclosures.





**A computed tomography head scan of a patient with known thyroid eye disease, who was symptomatic for dryness and irritation. There is proptosis of both eyes with the right eye displaying more protrusion. The patient's exophthalmometry reading was 31.5mm OD and 28mm OS.**

increased intraocular pressure, exposure keratopathy and, rarely, reduced vision from corneal ulceration or compressive optic neuropathy.<sup>8-9</sup> Management for mild orbitopathy may include ocular surface lubrication and prismatic correction of binocular diplopia. Progression to moderate or severe disease stages may require treatment with corticosteroids, teprotumumab-trbw (Tepezza, Horizon Therapeutics), orbital irradiation or orbital decompression.<sup>10-12</sup> Early

detection and treatment along with comanagement with endocrinology and ophthalmology are key to preventing long-term complications and improved patient quality of life.

### Rheumatoid Arthritis (RA)

This chronic, inflammatory autoimmune condition primarily involves the synovial joints.<sup>13</sup> Its prevalence is much higher in regions with people of European descent and the worldwide prevalence is an estimated 0.51%.<sup>13</sup> The yearly rate for people developing RA in the US and other northern European nations is about 40 per 100,000 persons and often affects women more than men.<sup>1</sup> The risk for developing RA increases with age, as those who are between the age of 65 to 80 years old are often most affected.

RA will start out in the small peripheral joints symmetrically and then

eventually affect the proximal joints if left untreated. The risk for developing this condition has been connected to HLA-DRB1, which contains a stretch of amino acids known as the shared epitope.<sup>13</sup> This genetic competent combined with environmental factors, such as cigarette smoking, has shown to increase the risk for developing RA as it causes a repeated activation of the innate immunity.<sup>13</sup>

The classification criteria to be diagnosed with RA includes number and size of involved joints, serological testing for rheumatoid factor or anti-citrullinated peptide/protein antibody, elevated erythrocyte sedimentation rate (ESR) or C-reactive protein (CRP) and a symptom duration of at least six weeks.<sup>13</sup>

The eye is sensitive, just like other tissues in the body, to widespread systemic inflammation. The most common ocular complications from RA include keratitis sicca, peripheral ulcerative keratitis (PUK), episcleritis and scleritis.<sup>14</sup> Less common ocular complications may include uveitis and retinal vasculitis.

Keratitis sicca is by far the most common complication as 10% to 35% of patients with RA will experience dry

#### Ocular Manifestations of Autoimmune Diseases: How to Understand and Identify

Jointly provided by Postgraduate Institute for Medicine (PIM) and Review Education Group

**Release Date:** May 15, 2024

**Expiration Date:** May 15, 2027

**Estimated Time to Complete Activity:** two hours

**Target Audience:** This activity is intended for optometrists interested in identifying and managing patients that present with ocular symptoms and signs from an autoimmune condition.

**Educational Objectives:** After completing this activity, participants should be better able to:

- Recognize the ocular manifestations of various autoimmune diseases.
- Determine when a referral to primary care or a specialist is necessary.
- Effectively treat patients with the ocular manifestations of autoimmune conditions.
- Comanage these patients with a specialist as needed.

**Faculty:** Melissa Chen, OD, Theresa Jay, OD, Steve Njeru, OD, and Eric Spotts, OD

**Disclosure of Conflicts of Interest:** PIM requires faculty, planners and others in control of educational content to disclose all their financial relationships with ineligible companies. All identified conflicts of interest are thoroughly vetted and mitigated according to PIM policy. PIM is committed to providing its learners with high-quality, accredited CE activities and related materials that promote improvements or quality in health care and not a specific proprietary business interest of an ineligible company.

Those involved reported the following relevant financial relationships with ineligible

entities related to the educational content of this CE activity: *Faculty* – Drs. Chen, Jay, Njeru and Spotts have nothing to disclose. *Planners and Editorial Staff* – PIM has nothing to disclose. The Review Education Group has nothing to disclose.

**Accreditation Statement:** In support of improving patient care, this activity has been planned and implemented by PIM and the Review Education Group. PIM is jointly accredited by the Accreditation Council for Continuing Medical Education, the Accreditation Council for Pharmacy Education and the American Nurses Credentialing Center to provide CE for the healthcare team. PIM is accredited by COPE to provide CE to optometrists.

**Credit Statement:** This course is COPE-approved for two hours of CE credit. Activity #128431 and course ID 91421-SD. Check with your local state licensing board to see if this counts toward your CE requirement for relicensure.

**Disclosure of Unlabeled Use:** This educational activity may contain discussion of published and/or investigational uses of agents that are not indicated by the FDA. The planners of this activity do not recommend the use of any agent outside of the labeled indications. The opinions expressed in the educational activity are those of the faculty and do not necessarily represent the views of the planners. Refer to the official prescribing information for each product for discussion of approved indications, contraindications and warnings.

**Disclaimer:** Participants have an implied responsibility to use the newly acquired information to enhance patient outcomes and their own professional development. The information presented in this activity is not meant to serve as a guideline for patient management. Any procedures, medications or other courses of diagnosis or treatment discussed or suggested in this activity should not be used by clinicians without evaluation of their patient's condition(s) and possible contraindications and/or dangers in use, review of any applicable manufacturer's product information and comparison with recommendations of other authorities.



JOINTLY ACCREDITED PROVIDER  
INTERPROFESSIONAL CONTINUING EDUCATION

eye secondary to B and T cells attacking the lacrimal gland, which in turn causes a decrease in tear production.<sup>14</sup> Episcleritis and scleritis differ both in the level of inflammation and patient symptoms and may occur in up to 10% of patients with RA.<sup>14</sup> It is especially important to be aware of scleritis as it is much more painful than episcleritis and affects both the superficial and deep episcleral vessels.

RA accounts for 34% of PUK cases.<sup>14</sup> Patients will present with pain, blurred vision and/or photophobia. PUK is a rare type of corneal melt secondary to immune complexes that attack the vascular arcades in the peripheral cornea. When examining cases of this condition, optometrists should monitor for stromal thinning, neovascularization of the cornea, juxtalimbal ulcers and corneal perforation.

### Systemic Lupus Erythematosus (SLE)

This systemic inflammatory disease affects multiple tissues of the body including the eye. Its prevalence has been reported to be 20 to 150 per 100,000 persons, and women are nine times more likely to develop SLE than men.<sup>15</sup> The pathophysiology of SLE is complex, and it is believed that those who are more genetically susceptible will have an immune response that leads to the creation of self-antigens from cell

damage due to factors like infections or smoking.<sup>15</sup> These self-antigens are presented to T cells, which accelerates the production of self-antibodies by B cells and ultimately leads to chronic self-induced inflammation and organ damage.

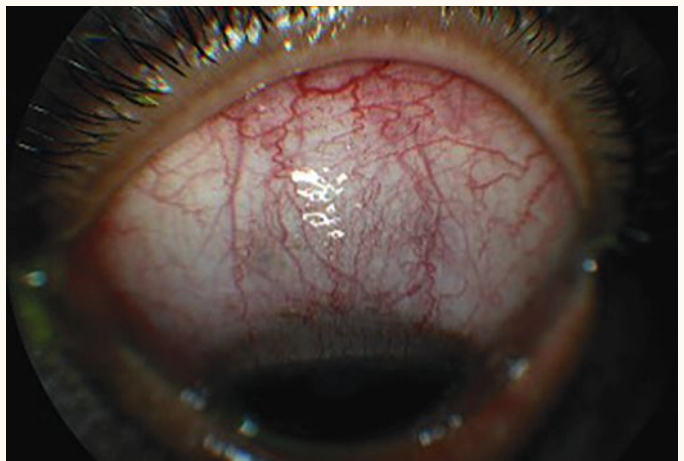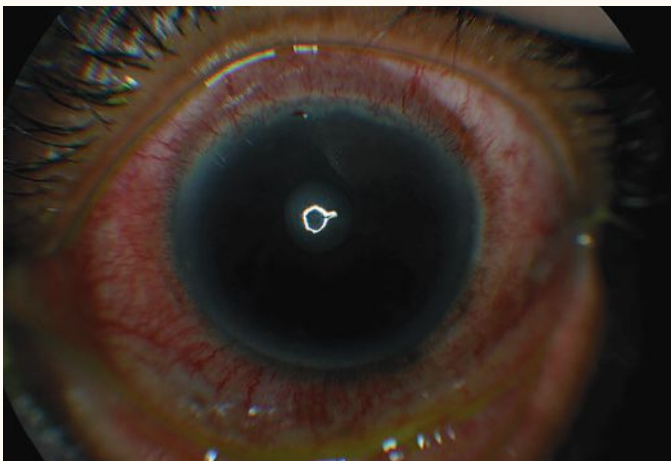
Patients must be positive for at least four out of eleven defined criteria by the American College of Rheumatology to be officially diagnosed with SLE.<sup>15</sup> This includes malar rash, discoid rash, skin photosensitivity, oral ulcers, nonerosive arthritis, serositis, renal dysfunction, neurological derangements like seizures, hematologic disorder like anemia, immunologic disorder like anti-DNA antibody and presence of antinuclear antibodies (ANA).<sup>15</sup> Meeting at least four criteria has a sensitivity of 85% and specificity of 95% for SLE.<sup>16</sup>

While the criteria do not mention any ocular findings, an estimated 33% of patients with SLE will experience ocular symptoms.<sup>16</sup> These symptoms will differ in severity and can even cause permanent visual impairment. Keratoconjunctivitis sicca is one of the most common findings. Approximately 25% of SLE patients will be affected, and proinflammatory markers can be found within the tear film.<sup>16</sup> Periorbital edema is a fairly uncommon presentation in those with SLE, but it has an overall incidence of 4.8% and is more common in those of African descent.<sup>17</sup> These

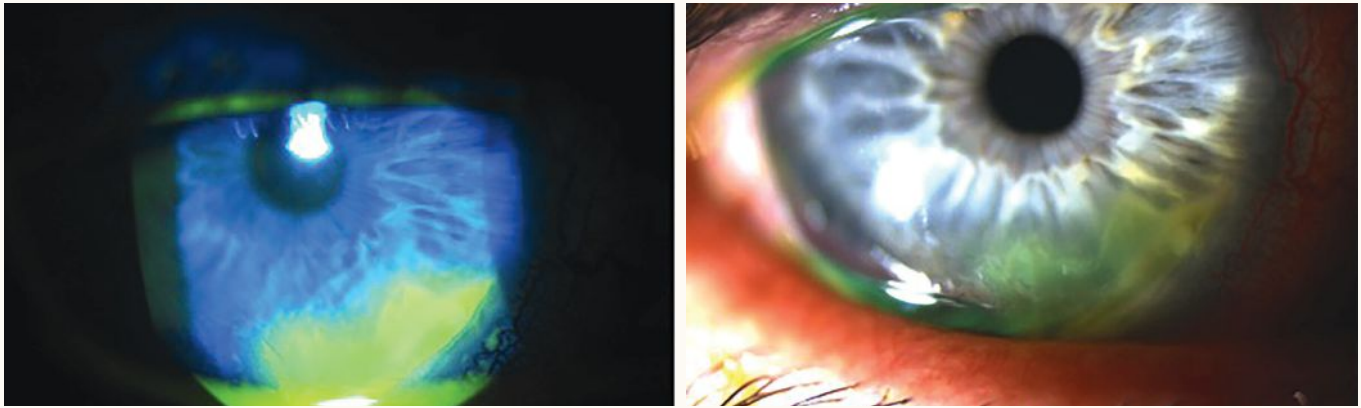
patients will present with swelling that has overlying eczema-like changes and can be commonly mistaken as chronic blepharitis. In cases of scleritis associated with SLE, anterior scleritis is a more common presentation than posterior scleritis. It is considered a sight-threatening condition since nodular inflammation can lead to tissue necrosis. Patients with SLE can also present with uveitis, which occurs in roughly 0.1% to 4.8% of patients. It is usually mild in presentation and typically non-granulomatous.<sup>16</sup>

Lupus retinopathy can develop in an estimated 29% of patients who have active SLE vs. 3% of patients who have well-controlled SLE.<sup>17</sup> These retinal changes are due to deposition of immune complexes in the vessel walls, which can lead to microangiopathy, vaso-occlusions and vasculitis. The most common findings may be microangiopathy. This has a similar appearance to diabetic or hypertensive retinopathy with intraretinal hemorrhages, exudates and/or cotton wool spots. Vaso-occlusion and vasculitis are rare clinical appearances but have a worse visual prognosis. This may result in widespread capillary nonperfusion, neovascularization and/or vein/artery occlusions.

Lupus choroidopathy with an exudative retinal detachment is a rare complication of SLE and typically is seen in patients who have highly active SLE.<sup>17</sup>



**A 65-year-old African American male presented with a red eye OS that started one month ago and reported eye pain, a foreign body sensation and light sensitivity. He was diagnosed with diffuse non-necrotizing anterior scleritis and was treated with oral NSAIDs. He was also referred to rheumatology due to a positive ANA and elevated ANCA testing.**



**A 49-year-old Caucasian male who presented with a painful red eye. He was diagnosed and treated for PUK, as his symptoms progressed after initially being diagnosed with a corneal abrasion. He had no prior autoimmune conditions but was diagnosed with RF due to elevated RF, CRP, CCP, ANA and ESR.**

It is important to monitor these patients for glaucoma, as choroidal effusion may occur and cause angle closure due to the anterior shift of the lens.

Neuro-ophthalmic complications have been reported in roughly 3.6% of adults with SLE.<sup>15</sup> Abnormalities with eye movements are the most common, as they have been reported in up to 29% of patients with third and sixth nerve palsies being the most common presentation.<sup>15,17</sup> Notably, optic nerve complications are rare with only 1% of patients being affected by conditions such as optic neuritis, which can have a very poor prognosis as most patients present with 20/200 or worse vision when associated with SLE.<sup>16</sup>

### Sjögren's Syndrome

Primary presentation of this chronic systemic autoimmune disorder commonly involves sicca symptoms (*i.e.*, dryness involving the eyes and mouth secondary to inflammation and resultant pathology of the lacrimal and salivary glands).<sup>18</sup> Sjögren's syndrome is classified as either primary (condition occurs by itself) or secondary (accompanied by other systemic autoimmune conditions such as RA and SLE).<sup>19</sup>

Sjögren's syndrome has a 9:1 ratio predilection for women.<sup>20,21</sup> This condition can affect people of any age, although symptoms usually appear in the fourth to fifth decade of life.<sup>22</sup> The exact pathophysiology is unknown; however, the current hypothesized mechanism

includes the destruction of exocrine gland epithelium due to B and T cell autoantigen responses.<sup>23</sup> Antibodies being produced may target the epithelium of salivary ducts and lacrimal glands or against nucleus/cellular antigens such as anti-Ro/SS-A, anti-La/SS-B, rheumatoid factor (RF) and ANA.<sup>19</sup> This ultimately results in diminished tear production by the lacrimal glands and diminished saliva production by the salivary glands.

In-office testing may include Schirmer testing, fluorescein staining, rose bengal staining, lissamine green staining, phenol red thread test and tear osmolarity to determine aqueous deficiency. Serologic testing may also be performed including ANA, RF or Sjögren's syndrome specific antibodies (*i.e.*, anti-Ro [SS-A], anti-La [SS-B]).<sup>19,23</sup>

A significant number of patients with this condition will have normal serology and are therefore not definitive. While several studies have aimed to identify biomarkers and molecules to diagnose the condition, biopsy of the minor salivary glands remains the gold standard for Sjögren's syndrome confirmation.<sup>23-25</sup> However, a biopsy is not mandatory in all cases if the clinical and laboratory findings are suggestive of the syndrome.

Management of Sjögren's syndrome includes both local and systemic approaches. Locally targeted ocular treatments may include artificial tears/

ointments, punctal occlusion, lateral tarsorrhaphy, bandage contact lenses, prophylactic antibiotic drops, amniotic membranes, oral pilocarpine, immunomodulators, cyclosporine A, filament mechanical removal and autologous serum eye drops.<sup>26</sup> Establishing early diagnosis and treatment can help prevent severe complications, vision loss and improve patient quality of life.

### Myasthenia Gravis

This autoimmune condition disrupts the normal ability for acetylcholine to bind to acetylcholine receptors in the postsynaptic membrane at the neuromuscular junction. The presence of antibodies bound to acetylcholine receptors leads to weakness of skeletal muscles.<sup>27</sup> Ocular myasthenia gravis (OMG) is characterized by ocular symptoms only. The disease may manifest initially with localized ocular symptoms such as ptosis, diplopia and orbicularis weakness. Generalized myasthenia gravis (GMG) symptoms include dysphagia, dyspnea, dysphonia, dysarthria and weakness of extremities. The overall incidence of OMG is 1.13 per 100,000 per year, while the range of MG is 0.17 to 7 per 100,000 per year.<sup>28</sup> It is imperative for eyecare professionals to recognize signs that may lead to the challenging diagnosis of MG.

The presence of antibodies exerts its pathogenic effect at the neuromuscular junction by impeding on normal acetylcholine binding to its respective

receptor. It can do so through various mechanisms such as internalizing or reducing acetylcholine receptors, increasing the synaptic distance or reduction of postsynaptic junctional folds. Similarly, presence of low-density lipoprotein receptor-related protein 4 (LRP4) and muscle-specific kinase (MuSK) antibodies reduces the receptor availability for binding. A thymoma is a paraneoplastic source of antibody production, which can be found in 10% of patients with MG.<sup>27</sup>

Ahead of laboratory testing, in-office testing, not limited to ice test, sleep test or Cogan's lid twitch, may aid in clinical suspicion. The ice test is performed by placing an ice pack over the patients' closed eyelids for two minutes. A positive test is denoted as unequivocal improvement of palpebral fissure. The sleep test is comparable to the ice test. A positive sleep test is based on recovery of eyelid posture or diplopia with 30 minutes of rest. Cogan's lid twitch can be observed as a quick upward overshoot of eyelid on return to primary gaze, following rest in downgaze for 15 seconds. Acetylcholine receptor antibodies in MG are detected in approximately 85% of those with GMG. The remainder of patients may test positive for either MuSK, LRP4

or remain seronegative. Those who remain seronegative should be retested or referred to neurology for trial of treatment.

Optometrists frequently encounter complaints of diplopia or lid droop. However, the hallmark of OMG is variable ptosis and/or diplopia, which exhibits fatigability with sustained muscle usage. Approximately 50% of all MG patients present initially with ocular symptoms.<sup>29</sup> Over time, those who present with ocular symptoms have the potential to convert to generalized disease. Only about 15% of patients with MG have symptoms confined to ocular muscles.<sup>27</sup> About 90% of patients who continue to have symptoms restricted to ocular muscles over the course of two years will continue as OMG and not convert to generalized disease.<sup>27</sup>

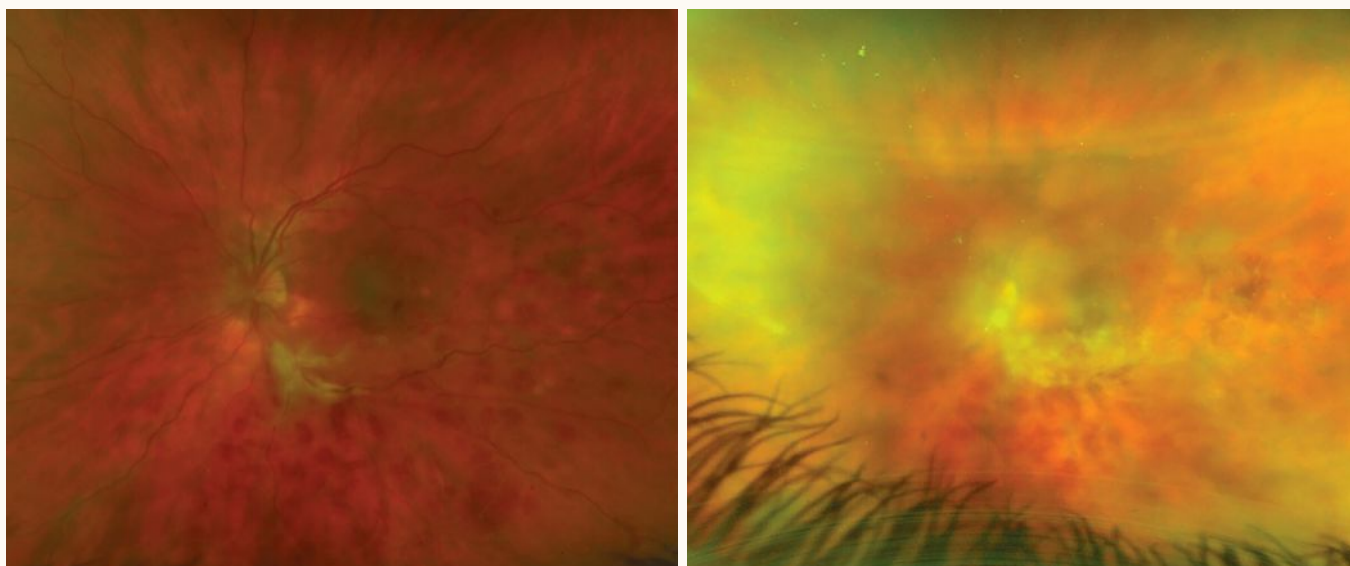
### Multiple Sclerosis (MS)

This neurodegenerative disease leads to debilitating symptoms due to demyelination and progressive axonal degeneration of the central nervous system. MS is considered an autoimmune condition due to the activation of the inflammatory cascade, caused by T cells that identify myelin as foreign, leading to the formation of inflammatory lesions and sclerosed plaques.<sup>30</sup>

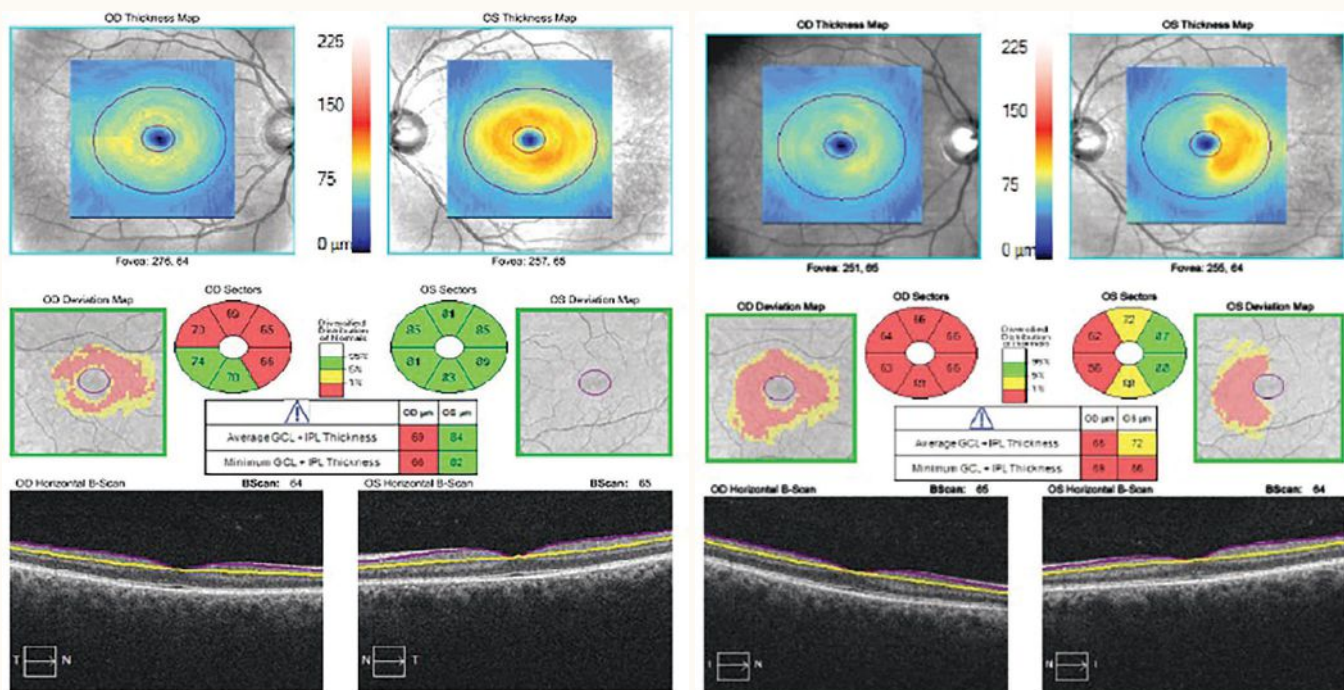
An estimated 400,000 people in the US are affected by MS, with a higher rate of prevalence among those who live in higher altitudes.<sup>30</sup> The average onset age is typically young at around 20 to 50 years old and women are three times more likely than men to develop MS.<sup>30</sup> At this time, the condition's etiology is not very well known due to multiple contributing factors such as genetics, stress, diet, viral infections like Epstein-Barr virus, geographical location, ultraviolet light exposure and smoking.

Optic neuritis is a common initial manifestation of MS, which occurs in up to 20% of patients who have no known diagnosis of the condition.<sup>30</sup> The overall risk of developing MS within 10 years following optic neuritis is an estimated 38%.<sup>30</sup> Roughly 75% of patients who have a diagnosis of MS may experience at least one episode of optic neuritis.<sup>30</sup>

Patients with optic neuritis will present with monocular vision loss that can occur over hours to days and reach peak vision loss within two weeks of onset and then spontaneously improve or resolve within the first month. Papillitis or optic nerve swelling has been reported to occur in up to 33% of patients. The severity of vision impairment can vary with 35% being 20/40 or better and



A 40-year-old Caucasian male reported a lightning streak in his left eye that started two days ago with worsening blurred vision, loss of the upper portion of his vision and a red eye. The photo on the left shows vasculitis with disc edema, macular edema, vessel sheathing and hemorrhaging. The photo on the right shows progression of his retinal vasculitis that involved a new complication of panuveitis after four days.



**A 45-year-old male with known MS presented to the eye clinic for his yearly exam with no new symptoms, but his exam showed new ganglion cell loss OS, as seen in the two photos.**

36% being 20/200 or worse as described in the Optic Neuritis Treatment Trial (ONTT).<sup>30,31</sup>

Additionally, patients can experience periorbital or ocular pain either before or during the initial vision loss, which commonly presents as being worse during eye movements. This was reported in up to 92% of cases during the ONTT.<sup>30</sup> This pain can last for several days but is not correlated with the severity of vision loss. Visual field defects can also vary in presentation as diffuse loss, central scotomas and/or altitudinal defects. Color vision and contrast sensitivity changes can also be observed as patients will often complain about dullness to colors or dimmed vision, which is often tested with the red cap test to observe desaturation. The changes in color vision can occur in up to 88% of patients, whereas contrast sensitivity changes can occur in up to 51% of patients.<sup>30</sup>

MS may also lead to ocular motor deficits that can be associated with acute exacerbations. Cranial nerve palsies caused by MS are typically isolated and commonly affect the abducens nerve rather than the oculomotor or trochlear

nerve.<sup>30</sup> Impairment of the abducens nerve will lead to difficulties with eye movements like pursuits and saccades which can affect daily activities, such as reading or driving.

Another complication to be aware of is internuclear ophthalmoplegia (INO), a hallmark neurological finding for MS that is present in 17% to 41% of patients.<sup>30</sup> An INO is an abnormal horizontal deficit with adduction impairment of the ipsilateral eye and a horizontal abducting nystagmus of the contralateral eye. This impairment involves a lesion of the medial longitudinal fasciculus. Lesions that cause bilateral INO carry an increased risk for MS. Patients with INO will complain of diplopia, nystagmus and loss of depth perception.

### Scleroderma

Also known as systemic sclerosis, this is a severe connective tissue disorder that involves the skin, musculoskeletal, gastrointestinal, pulmonary and renal systems.<sup>32-34</sup> The pathophysiology of scleroderma is not entirely understood but it is hypothesized that immune activation leads to vasculopathy and

excess fibrosis due to an overproduction and accumulation of collagen and other extracellular matrix proteins.

It is a rare condition with an estimated incidence of 19.3 new cases per million persons per year.<sup>33</sup> It typically affects those between 30 to 50 years old and women are three times more likely to develop scleroderma than their male counterparts.<sup>33</sup> Patients are diagnosed with scleroderma when they meet the major criteria of thickening of the skin that affects the arms, face and/or neck, as well as minor criteria such as digital pitting scars, sclerosis of the fingers and toes or pulmonary fibrosis.<sup>33</sup>

Ocular manifestations for scleroderma are rare but can involve both the anterior and posterior segment. Eyelid changes are well documented in cases of scleroderma due to the sclerosis of connective tissue in the eyelid which can lead to stiffness and tightness.<sup>32-34</sup> Lid stiffness has been found in 29% to 65% of patients and is associated with a hardened-like feeling on palpation and difficulty with lid eversion.<sup>33</sup>

Telangiectatic vessels on the lids may also be present in 17% to 21% of patients.<sup>33</sup> Ocular surface disease has been

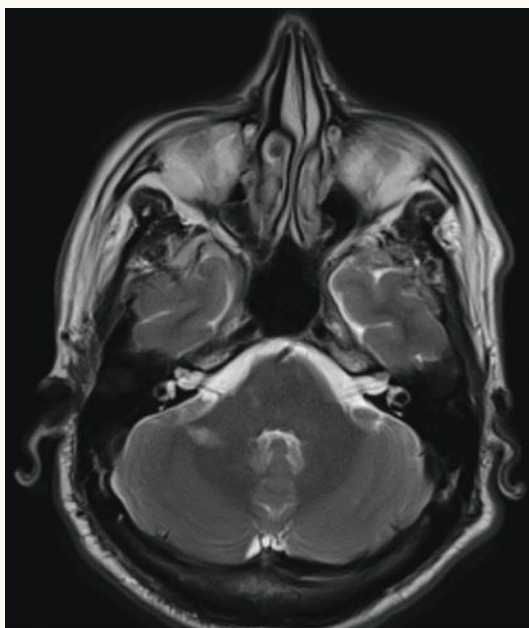
found to occur in 37% to 79% of patients due to fibrotic impairment to the lacrimal gland that leads to reduced tear production.<sup>33</sup> Although the collagen rich cornea is not often directly affected by scleroderma, eyelid changes and ocular surface disease can lead to corneal issues such as exposure keratitis, filamentous keratitis and PUK.

The association between glaucoma and scleroderma is still being researched, but it is believed that patients with scleroderma can have changes in vascular perfusion to the nerve and/or fibrotic-restricted outflow of the aqueous humor, which could lead to normal tension or open-angle glaucoma depending on the mechanism.<sup>32-35</sup> The retina and choroid are highly vascularized structures; however, the retina may not be as affected by scleroderma when compared to the choroid due to immunologically favored microcirculation and a lack of resident fibroblasts.<sup>32</sup>

## Psoriasis

This immune-mediated inflammatory skin condition may present in a variety of erythematous lesions. Some variants of psoriasis may present with scaly patches or plaques, confetti-like scaly patches, coalescent erythematous scales or pustules. Psoriasis affects 3.2% of adults and 0.13% of children in the US population and about 125 million people worldwide.<sup>35</sup> It is imperative to recognize signs of psoriasis as patients can have ocular manifestations along with joint involvement, cardiometabolic disease, inflammatory bowel disease, and mental illness.<sup>36</sup>

The most common variant of psoriasis is plaque psoriasis, and it accounts for 80% to 90% of all psoriasis cases.<sup>36</sup> The pathogenesis of psoriasis is characterized by excessive activation of the adaptive immune system. Specifically, a variety of innate immune cells such as keratinocytes, macrophages, natural killer T cells and plasmacytoid cells secrete cytokines that activate myeloid dendritic cells to further secrete excess cytokines, which then allows for dif-



**Due to history of known MS and new ganglion cell loss OS, an updated MRI was ordered, which showed progression with new active demyelinating lesions.**

ferentiation of T cells. The maturation of T cells then secrete cytokines that begin the inflammatory cascade causing keratinocyte proliferation, angiogenesis, vasodilation, skin thickening and erythema.<sup>36</sup>

Contrary to the very apparent erythematous scaly lesions seen in psoriasis, ocular manifestations of psoriasis are subtle. Diagnostic workup for psoriasis requires a systemic and family history, as well as a skin and nail examination. Referral for a lesion skin biopsy may be required for definitive diagnosis.<sup>36</sup>

Ocular manifestations are wide ranging and may present as chronic conjunctivitis, blepharitis, keratitis sicca, madarosis, trichiasis, uveitis and symblepharon.<sup>37</sup> The most common ocular presentation is chronic blepharoconjunctivitis, and this condition presents in up to 64.5% of patients.<sup>37</sup> Psoriasis induced blepharitis is secondary to abnormal epidermal turnover that interferes with normal meibomian gland function. Conjunctivitis presenting with palpebral plaques or an accompanying symblepharon should raise suspicion for psoriasis. Uveitis and keratitis sicca have been reported in up to 20% and 18.75% of patients, respectively.<sup>37</sup>

## Vasculitis

The vasculitides include a diverse list of conditions such as giant cell arteritis (GCA), granulomatosis with polyangiitis, polyarteritis nodosa, Bechet's disease and Kawasaki's disease. These conditions are affected by immune-mediated vessel inflammation, which leads to the compromise of the normal vessel lumen, resulting in stenosis, occlusion, or aneurysmal formation. As a result, a range of tissue ischemia and/or necrosis of organs can occur. Overall, the pathophysiology of vasculitis is hypothesized to be due to an immunological component that plays an active role in inflammation of vessels. These cytokine-mediated changes along with inappropriate activation of leukocytes and endothelial cells are key factors that cause vessel inflammation and damage.<sup>38</sup> As an eyecare provider, failure to recognize

ocular signs related to vasculitis can be devastating, if not fatal.

The orbital fat, orbital nerves, extraocular muscles, lacrimal gland, the optic nerve and adnexa are all susceptible to ischemia and necrosis. Patients suffering from vasculitis can present with a range of symptoms from mild ocular pain to severe vision loss. Inflammatory vasculitides include many conditions which we review here:

**GCA.** This is the most common of the systemic vasculitides and considered to be a medical emergency.<sup>39</sup> GCA is characterized by segmental inflammation, necrosis of smooth muscles and thickening of internal elastic lamina of medium to large caliber arteries.<sup>40</sup> Symptoms of GCA include unilateral temporal headache, scalp tenderness, stiffness of neck, shoulder pain, jaw claudication and vision loss. Laboratory results include elevated c-reactive protein and erythrocyte sedimentation rate. Arteritic anterior ischemic optic neuropathy is a common ocular manifestation of GCA that may develop in approximately 80% of patients who have been diagnosed with GCA.<sup>41</sup>

**Granulomatosis with polyangiitis.** This is a common vasculitis characterized by necrosis of tissue

and granulomatous inflammation of the small to medium blood vessels. GPA is strongly associated with anti-neutrophil cytoplasmic antibodies (ANCA), as it can be identified in 80% to 90% of cases.<sup>40</sup> This disease most often affects the respiratory system and kidneys but could have orbital manifestations in 15% to 20% of patients. Orbital involvement may include optic nerve compression and/or infiltration, mass effect on extraocular muscles and inflammation of lacrimal glands.<sup>40</sup>

**Polyarteritis nodosa.** This is a rare necrotizing vasculitis of small and medium arteries. The vasculitis is segmental and focal and can be found in any artery throughout the body. In late stages, the necrotizing lesions begin to heal and fibrose, leading to vessel occlusion. This condition can affect multiple organ systems such as joints/bones, peripheral nervous system, central nervous system, kidneys, heart and gastrointestinal system. Ocular manifestations include retinal vasculitis, ischemic optic neuropathy, extraocular muscle dysfunction, peripheral ulcerative keratitis or scleritis.<sup>40,42</sup>

**Behçet's disease.** This condition has been known to affect the small- and medium-sized vessels due to neutrophil and fibrin invasion of the vessel lumen, leading to thrombosis and occlusion of vessels.<sup>40</sup> Behçet's disease is associated with positive HLA-B51 in laboratory testing. Ocular involvement has been reported in approximately 70% of patients with uveitis as the most common ocular manifestation.<sup>42,43</sup> Less commonly, those with Behçet's disease can also present with retinal vasculitis.

**Kawasaki's disease.** This is a systemic vasculitis that affects the medium sized vessels and predominately occurs in children under the age of five. This form of vasculitis mainly affects the coronary arteries and if left untreated, aneurysms can form in roughly 30% of patients.<sup>40</sup> The most common ocular manifestation is conjunctivitis, but anterior uveitis, macular edema and optic nerve edema have been reported.<sup>42</sup>

Ocular presentation of the vasculitides is varied and requires a thorough history, evaluation, laboratory testing, imaging and occasionally a biopsy to determine the underlying etiology. Often the ocular findings are the initial presentation of what may be a life-threatening condition and optometrists must be diligent to ensure patients receive appropriate and timely referrals.<sup>42</sup>

## Takeaways

Autoimmune conditions are frequently associated with various comorbidities and systemic complications that have an impact on quality of life. Optometrists can play an important role in comanaging their patients' general health alongside other specialties such as rheumatology by monitoring for common ocular signs and symptoms of autoimmune diseases. ■

- Davies TF, Andersen S, Latif R, et al. Graves' disease. *Nat Rev Dis Primers*. 2020;6(1):52.
- Szczapa-Jagustyn J, Gotz-Wieckowska A, Kociecki J. An update on thyroid-associated ophthalmopathy in children and adolescents. *J Pediatr Endocrinol Metab*. 2016;29(10):1115-22.
- McAlinden C. An overview of thyroid eye disease. *Eye Vis (Lond)*. 2014;1:9.
- Douglas RS, Gupta S. The pathophysiology of thyroid eye disease: implications for immunotherapy. *Curr Opin Ophthalmol*. 2011;22(5):385-90.
- Bartalena L. Diagnosis and management of Graves' disease: a global overview. *Nat Rev Endocrinol*. 2013;9(12):724-34.
- Shan SJ, Douglas RS. The pathophysiology of thyroid eye disease. *J Neuro-Ophthalmol*. 2014;34(2):177-85.
- Bahn RS. Graves' ophthalmopathy. *New Engl J Med*. 2010;362(8):726-38.
- Bartalena L, Baldeschi L, Dickinson A, et al. Consensus statement of the European Group on Graves' orbitopathy (EUGOGO) on management of GO. *Eur J Endocrinol*. 2008;158(3):273-85.
- Bartalena L, Baldeschi L, Boboridis K, et al. The 2016 European Thyroid Association/European Group on Graves' orbitopathy guidelines for the management of Graves' Orbitopathy. *Eur Thyroid J*. 2016;5(1):9-26.
- Verity DH, Rose GE. Acute thyroid eye disease (TED): principles of medical and surgical management. *Eye (Lond)*. 2013;27(3):308-19.
- Stan MN, Garrity JA, Bahn RS. The evaluation and treatment of graves ophthalmopathy. *Med Clin North Am*. 2012;96(2):311-28.
- Marcocci C, Marino M. Treatment of mild, moderate-to-severe and very severe Graves' orbitopathy. *Best Pract Res Clin Endocrinol Metabol*. 2012;26(3):325-37.
- Chauhan K, Jandu JS, Brent LH, et al. Rheumatoid arthritis. In: *StatPearls* [Internet]. Treasure Island (FL): StatPearls Publishing. [www.ncbi.nlm.nih.gov/books/NBK441999/](http://www.ncbi.nlm.nih.gov/books/NBK441999/). Last updated May 25, 2023. Accessed March 15, 2024.
- Glover K, Mishra D, Singh TRR. Epidemiology of ocular manifestations in autoimmune disease. *Front Immunol*. 2021;12:744396.
- Silpa-archa S, Lee JJ, Foster CS. Ocular manifestations in systemic lupus erythematosus. *Br J Ophthalmol*. 2016;100(1):135-41.
- Shoughy SS, Tabbara KF. Ocular findings in systemic lupus erythematosus. *Saudi J Ophthalmol*. 2016;30(2):117-21.

- Palejwala NV, Wallia HS, Yeh S. Ocular manifestations of systemic lupus erythematosus: a review of the literature. *Autoimmune Dis*. 2012;2012:290898.
- Jonsson R, Brokstad KA, Jonsson MV, et al. Current concepts on Sjögren's syndrome – classification criteria and biomarkers. *Eur J Oral Sci*. 2018;126(Suppl. 1):37-48.
- Feltsan T, Stanko P, Mračna J. Sjögren's syndrome in present. *Bratisl Lek Listy*. 2012;113(8):514-6.
- García-Carrasco M, Ramos-Casals M, Rosas J, Pallarés L, et al. Primary Sjögren syndrome: clinical and immunologic disease patterns in a cohort of 400 patients. *Medicine (Baltimore)*. 2002;81(4):270-80.
- Alamanos Y, Tsifetaki N, Voulgari PV, et al. Epidemiology of primary Sjögren's syndrome in north-west Greece, 1982-2003. *Rheumatology (Oxford)*. 2006;45(2):187-91.
- Patel R, Shahane A. The epidemiology of Sjögren's syndrome. *Clin Epidemiol*. 2014;6:247-55.
- Both T, Dalm VA, van Hagen PM, Van Daele PLA. Reviewing primary Sjögren's syndrome: beyond the dryness-from pathophysiology to diagnosis and treatment. *Int J Med Sci*. 2017;14(3):191-200.
- Mathews PM, Robinson SA, Gire A, et al. Extraglandular ocular involvement and morbidity and mortality in primary Sjögren's syndrome. *PLoS ONE*. 2020;15(9):e0239769.
- Roszkowska AM, Oliverio GW, Aragona E, et al. Ophthalmologic manifestations of primary Sjögren's syndrome. *Genes (Basel)*. 2021;12(3):365.
- Foulks GN, Forstot SL, Donshik PC, et al. Clinical guidelines for management of dry eye associated with Sjögren disease. *Ocul Surf*. 2015;13(2):118-32.
- Gilhus NE, Skeie GO, Romi F, et al. Myasthenia gravis-autoantibody characteristics and their implications for therapy. *Nat Rev Neurol*. 2016;12(5):259-68.
- Behbehani R. Ocular myasthenia gravis: a current overview. *Eye Brain*. 2023;15:1-13.
- Hendricks TM, Bhatti MT, Hodgo DJ, Chen JJ. Incidence, epidemiology and transformation of ocular myasthenia gravis: a population-based study. *Am J Ophthalmol*. 2019;205:99-105.
- Chen L, Gordon LK. Ocular manifestations of multiple sclerosis. *Curr Opin Ophthalmol*. 2005;16(5):315-20.
- The clinical profile of optic neuritis. Experience of the Optic Neuritis Treatment Trial. *Optic Neuritis Study Group. Arch Ophthalmol*. 1991;109(12):1673-8.
- Kozikowska M, Luboń W, Kucharz EJ, Mrukwa-Kominek E. Ocular manifestations in patients with systemic sclerosis. *Reumatologia*. 2020;58(6):401-6.
- Taylor R, Gupta A, Herrick A, Kwartz J. Ocular manifestations of scleroderma. *Surv Ophthalmol*. 2009;54(2):292-304.
- Szucs G, Szekanez Z, Aszalos Z, et al. A wide spectrum of ocular manifestations signify patients with systemic sclerosis. *Ocul Immunol Inflamm*. 2021;29(1):81-9.
- Michalek IM, Loring B, John SM. A systematic review of worldwide epidemiology of psoriasis. *J Eur Acad Dermatol Venereol*. 2017;31(2):205-12.
- Armstrong AW, Read C. Pathophysiology, clinical presentation, and treatment of psoriasis: a review. *JAMA*. 2020;323(19):1945-60.
- Algarni A, Almuqrin A, Alarwan A. Association between psoriasis and ocular disorders: a narrative review. *Clin Med Invest*. 2017;2(2):1-4.
- Langford CA. Vasculitis. *J Allergy Clin Immunol*. 2003;111(2 Suppl):S602-12.
- González-Gay MA, García-Porrúa C. Systemic vasculitis in adults in northwestern Spain, 1988-1997. Clinical and epidemiologic aspects. *Medicine (Baltimore)*. 1999;78(5):292-308.
- Perumal B, Black EH, Levin F, et al. Non-infectious orbital vasculitides. *Eye (Lond)*. 2012;26(5):630-9.
- Hayreh SS, Podhajsky PA, Zimmerman B. Ocular manifestations of giant cell arteritis. *Am J Ophthalmol*. 1998;125(4):509-20.
- Papaliadis GN. Ophthalmologic manifestations of systemic vasculitis. *Curr Opin Ophthalmol*. 2017;28(6):613-6.
- Verity DH, Wallace GR, Vaughan RW, Stanford MR. Behçet's disease: from Hippocrates to the third millennium. *Br J Ophthalmol*. 2003;87(9):1175-83.

OPTOMETRIC STUDY CENTER QUIZ

To obtain CE credit through the Optometric Study Center, complete the test form on the following page and return it with the \$35 fee to: Jobson Healthcare Information, Attn.: CE Processing, Jobson Healthcare Information, LLC/WebMD, 283-299 Market Street, 2 Gateway Center, 4th Floor, Newark, NJ 07102. To be eligible, please return the card within three years of publication. You can also access the test form and submit your answers and payment via credit card online at [revieweducationgroup.com](http://revieweducationgroup.com). You must achieve a score of 70 or higher to receive credit. Allow four weeks for processing. For each Optometric Study Center course you pass, you earn two hours of credit. Please check with your state licensing board to see if this approval counts toward your CE requirement for relicensure.

1. The most common ocular presentation in patients with psoriasis is which of the following?
  - a. Chronic blepharoconjunctivitis.
  - b. Episcleritis.
  - c. Ischemic optic neuropathy.
  - d. Retinal vasculitis.
2. The diagnostic workup for psoriasis includes all of the following EXCEPT:
  - a. Family history of psoriatic disease.
  - b. Comprehensive skin and nail examination.
  - c. Skin biopsy for atypical cases.
  - d. Genetic testing.
3. All the following are signs and symptoms that can present in myasthenia gravis EXCEPT:
  - a. Difficulty swallowing.
  - b. Ptosis.
  - c. Binocular internuclear ophthalmoplegia.
  - d. Increased sweating.
4. Which of the following is FALSE regarding antibodies against acetylcholine receptors?
  - a. Increased synaptic distance.
  - b. Increased acetylcholine receptors.
  - c. Reduced junctional folds.
  - d. Activation of complement pathway.
5. Myasthenia gravis (MG) is a disorder of the neuromuscular junction that involves \_\_\_\_\_ muscles.
  - a. Smooth muscles.
  - b. Skeletal muscles.
  - c. Cardiac muscles.
  - d. None of the above.
6. Which of the following systemic vasculitides is considered a true ocular and medical emergency?
  - a. Polyarteritis nodosa.
  - b. Behcet's disease.
  - c. Giant cell arteritis.
  - d. Kawasaki's disease.
7. What is the most common ocular manifestation in a patient with Behcet's disease?
  - a. Uveitis.
  - b. Episcleritis.
  - c. Ischemic optic neuropathy.
  - d. Retinal vasculitis.
8. The diagnostic criteria for systemic lupus erythematosus includes all of the following EXCEPT:
  - a. Malar rash.
  - b. Presence of antinuclear antibodies.
  - c. Lupus retinopathy.
  - d. Skin photosensitivity.
9. Which of the following conditions are woman are more likely to develop than men?
  - a. Rheumatoid arthritis.
  - b. Multiple sclerosis.
  - c. Systemic lupus erythematosus.
  - d. All of the above.
10. Which thyroid condition is associated with Graves' disease?
  - a. Euthyroidism.
  - b. Hyperthyroidism.
  - c. Hypothyroidism.
  - d. All of the above.
11. Thyroid eye disease is characterized by all of the following EXCEPT:
  - a. A sixfold higher risk in women than men.
  - b. Smoking is the most consistently linked environmental factor.
  - c. Exposure keratopathy.
  - d. Deactivation of the orbital fibroblasts.
12. The risk for developing rheumatoid arthritis increases with all of the following EXCEPT:
  - a. Living in a higher altitude.
  - b. Increased age.
  - c. Biological women.
  - d. Smoking.
13. Peripheral ulcerative keratitis is most often associated with which of the following systemic conditions?
  - a. Grave's disease.
  - b. Rheumatoid arthritis.
  - c. Multiple sclerosis.
  - d. Sjögren's syndrome.
14. The classification criteria for diagnosis of rheumatoid arthritis includes which of the following?
  - a. Duration of symptoms.
  - b. Number and size of joint involvement.
  - c. Serological testing.
  - d. All the above.
15. Sjögren's syndrome has a \_\_\_\_\_ ratio predilection for women.
  - a. 7:1.
  - b. 3:1.
  - c. 1:9.
  - d. 9:1.
16. What is the gold standard for diagnosing Sjögren's syndrome?
  - a. Sjögren's syndrome specific antibodies.
  - b. Biopsy of the minor salivary glands.
  - c. Antinuclear antibody.
  - d. Rheumatoid factor.
17. Which of the following is FALSE about multiple sclerosis?
  - a. Uveitis is a common presenting symptom of MS.
  - b. Periorbital pain follows vision loss in 92% of cases in the ONTT.
  - c. Contrast sensitivity is maintained, while color vision is reduced.
  - d. All the above.
18. The overall risk of developing MS is \_\_\_\_\_% within 10 years after initial episode of optic neuritis.
  - a. 50%.
  - b. 15%.
  - c. 38%.
  - d. 25%.
19. Common ocular manifestations of scleroderma include all of the following EXCEPT:
  - a. Lid stiffness.
  - b. Telangiectatic vessels on lids.
  - c. Uveitis.
  - d. Ocular surface disease.
20. Which inflammatory vasculitides is most commonly associated with scleritis?
  - a. Giant cell arteritis.
  - b. Behcet's disease.
  - c. Granulomatosis with polyangiitis.
  - d. Kawasaki's disease.



# Examination Answer Sheet

## Ocular Manifestations of Autoimmune Diseases: How to Understand and Identify

Valid for credit through May 15, 2027

**Online:** This exam can be taken online at [revieweducationgroup.com](http://revieweducationgroup.com). Upon passing the exam, you can view your results immediately and download a real-time CE certificate. You can also view your test history at any time from the website.

**Directions:** Select one answer for each question in the exam and completely darken the appropriate circle. A minimum score of 70% is required to earn credit.

**Mail to:** Jobson Healthcare Information, LLC/WebMD, 283-299 Market Street, 2 Gateway Center, 4th Floor, Newark, NJ 07102.

**Payment:** Remit \$35 with this exam. Make check payable to Jobson Healthcare Information, LLC.

**Credit:** This course is COPE-approved for two hours of CE credit. Course ID 91421-SD.

**Processing:** There is a four-week processing time for this exam.

Jointly provided by PIM and the Review Education Group.

### Answers to CE exam:

1. (A) (B) (C) (D)
2. (A) (B) (C) (D)
3. (A) (B) (C) (D)
4. (A) (B) (C) (D)
5. (A) (B) (C) (D)
6. (A) (B) (C) (D)
7. (A) (B) (C) (D)
8. (A) (B) (C) (D)
9. (A) (B) (C) (D)
10. (A) (B) (C) (D)
11. (A) (B) (C) (D)
12. (A) (B) (C) (D)
13. (A) (B) (C) (D)
14. (A) (B) (C) (D)
15. (A) (B) (C) (D)
16. (A) (B) (C) (D)
17. (A) (B) (C) (D)
18. (A) (B) (C) (D)
19. (A) (B) (C) (D)
20. (A) (B) (C) (D)

### Post-activity evaluation questions:

Rate how well the activity supported your achievement of these learning objectives. 1=Poor, 2=Fair, 3=Neutral, 4=Good, 5=Excellent

21. Recognize the ocular manifestations of various autoimmune diseases. (1) (2) (3) (4) (5)
22. Determine when a referral to primary care or a specialist is necessary. (1) (2) (3) (4) (5)
23. Effectively treat patients with the ocular manifestations of autoimmune conditions. (1) (2) (3) (4) (5)
24. Comanage these patients with a specialist as needed. (1) (2) (3) (4) (5)
25. Based upon your participation in this activity, do you intend to change your practice behavior? (Choose only one of the following options.)
  - (A) I do plan to implement changes in my practice based on the information presented.
  - (B) My current practice has been reinforced by the information presented.
  - (C) I need more information before I will change my practice.
26. Thinking about how your participation in this activity will influence your patient care, how many of your patients are likely to benefit? (please use a number):
27. If you plan to change your practice behavior, what type of changes do you plan to implement? (Check all that apply.)
  - (A) Apply latest guidelines
  - (B) Change in diagnostic methods
  - (C) Choice of management approach
  - (D) Change in current practice for referral
  - (E) Change in vision correction offerings
  - (F) Change in differential diagnosis
  - (G) More active monitoring and counseling
  - (H) Other, please specify: \_\_\_\_\_
28. How confident are you that you will be able to make your intended changes?
  - (A) Very confident
  - (B) Somewhat confident
  - (C) Unsure
  - (D) Not confident
29. Which of the following do you anticipate will be the primary barrier to implementing these changes?
  - (A) Formulary restrictions
  - (B) Time constraints
  - (C) System constraints
  - (D) Insurance/financial issues
  - (E) Lack of interprofessional team support
  - (F) Treatment related adverse events
  - (G) Patient adherence/compliance
  - (H) Other, please specify: \_\_\_\_\_
30. Additional comments on this course: \_\_\_\_\_

Please retain a copy for your records. Please print clearly.

First Name

Last Name

E-Mail

The following is your:  Home Address  Business Address

Business Name

Address

City  State

ZIP

Telephone #  -  -

Fax #  -  -

OE Tracker Number

### Rate the quality of the material provided:

1=Strongly disagree, 2=Somewhat disagree, 3=Neutral, 4=Somewhat agree, 5=Strongly agree

31. The content was evidence-based.

(1) (2) (3) (4) (5)

32. The content was balanced and free of bias.

(1) (2) (3) (4) (5)

33. The presentation was clear and effective.

(1) (2) (3) (4) (5)

By submitting this answer sheet, I certify that I have read the lesson in its entirety and completed the self-assessment exam personally based on the material presented. I have not obtained the answers to this exam by any fraudulent or improper means.

Signature

Date

Lesson 124897 RO-OSC-0524



BY PAUL M. KARPECKI, OD  
CHIEF CLINICAL EDITOR

## OCULAR SURFACE REVIEW

# As Smooth as Silk

*This unique protein is a brand new DED treatment.*

As the clinical battle against the growing prevalence of dry eye continues, the industry has responded with new products and novel approaches to address this debilitating condition afflicting millions of patients. The most common approach begins with an artificial tear regimen, and, if ineffective, a prescription eye drop. Continued dosing compliance remains challenging, as over two-thirds of patients using topical agents terminate their use within one year.<sup>1</sup> This high discontinuation rate is owed in part to medication side effects or perceived lack of effectiveness.

Artificial tears and eye drops are formulated to readily wet, spread and adhere to the ocular surface in mild-to-moderate dry eye disease (DED) patients. However, although new products continue to advance, evidence shows they do not provide the necessary relief to the severe dry eye patients who are most in need.<sup>2</sup>

Simply put, the ingredients used in over-the-counter lubricant and emulsion eye drops lack the biochemistry to provide the necessary coating properties to both protect and heal the ocular surface. The creation of novel excipients that meet the FDA safety criteria under the artificial tear monograph provides an expedient path to market the product over-the-counter. But there is a unique and possibly game-changing eye drop that's

likely to become available in the next six months—SilkTears (Silk Technologies). Studies show promising results for the use of silk-derived protein (SDP) as a novel wetting agent in dry eye drops, which also demonstrates natural anti-inflammatory and wound healing properties in both *in vitro* and *in vivo* animal studies.

### Importance of Mucin in Tear Film

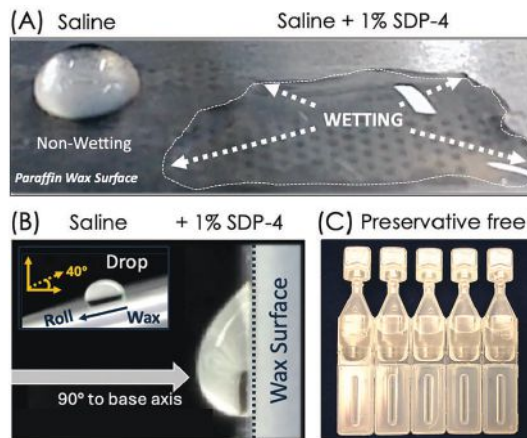
The natural tear film is complex, multilayered and multifunctional, and crucial in protecting the corneal surface from both physical and biological harm. It uses mucin protein to maintain a healthy ocular surface, which provides the innermost tear film complex, adherent to and in contact with the superficial epithelial layer of the hydrophobic cor-

neal surface. Mucin creates a biological surface that simultaneously adheres to the cornea and aqueous tear layer to aid wetting and tear film spreading over the ocular surface.<sup>3</sup> Its bimodal function minimizes light scatter through the cornea and provides comfort as a protective coating over the ocular surface. This coating creates a smooth refractive surface, covers the sensitive nerve endings that integrate with the epithelial layer and shields the ocular surface from the potentially abrasive inner eyelid motion. In many severe dry eye patients, mucin production and tear secretion are highly dysregulated and unable to coat the ocular surface effectively. The development of biological ingredients, such as proteins, is paramount to recreate the natural tear film.

Until now, the use of proteins has been largely relegated to autologous serum eye drops. There has been increasing promise in eye drops containing exosomes derived from explanted human placental mesenchymal stromal cells.<sup>5</sup> However, the regulatory pathway to FDA approval for highly heterogeneous blood-derived products is arduous and expensive. The introduction of better characterized, non-blood or animal tissue-derived proteins with mucin-like properties represents a significant advancement in eye drop formulation.

### SDP

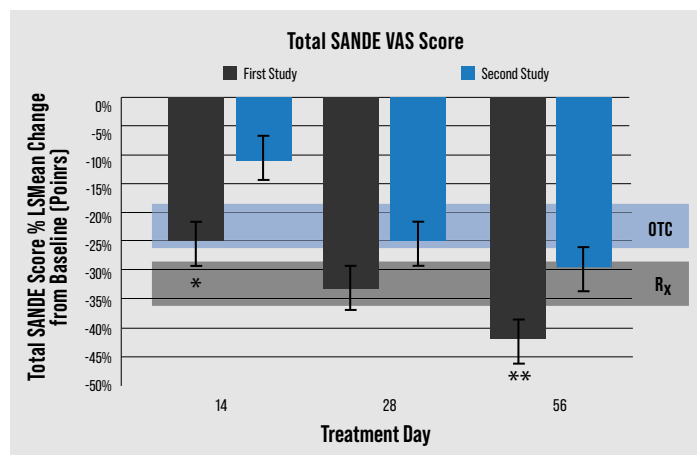
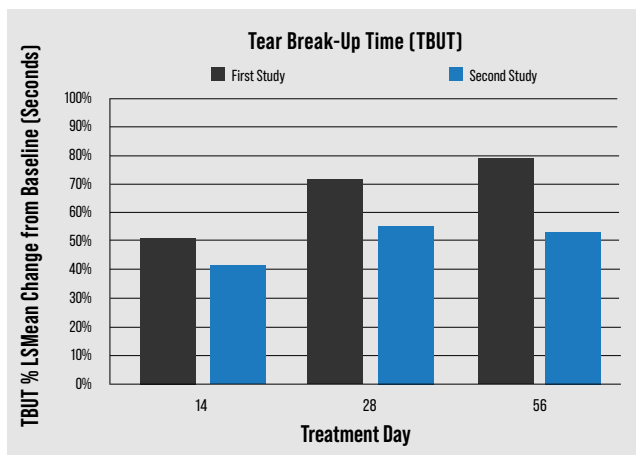
One such material that meets these criteria is called silk fibroin protein, which is non-toxic and non-immunogenic. Fibroin utility in biomedical applications has been under development for the past three decades, including applications in corneal tissue engineering, ocular surface repair and regenerating the corneal endothelium.<sup>6-8</sup> Fibroin has been successfully shown in a mouse model to increase tear



**SDP-4 (1% w/w) was formulated within a preservative-free artificial tear formulation (SilkTears). SDP-4 improves formulation (A) surface wetting and (B) coating adherence properties as demonstrated when added to saline, and then placed on a wax surface.**

#### About Dr. Karpecki

Dr. Karpecki is the director of Cornea and External Disease for Kentucky Eye Institute and an associate professor at KYCO. He is the Chief Clinical Editor for *Review of Optometry* and chair of the New Technologies & Treatments conferences. A fixture in optometric clinical education, he consults for a wide array of ophthalmic clients, including ones discussed in this article. Dr. Karpecki's full disclosure list can be found in the online version of this article at [www.reviewofoptometry.com](http://www.reviewofoptometry.com).



**Results of two FDA clinical trials showing improvement in signs (TBUT) and symptoms (SANDE).**

production, improve corneal smoothness and provide a complete recovery of both corneal epithelial and conjunctival goblet cells.<sup>9</sup> In addition, the expression of inflammatory factors was inhibited across the ocular surface and in the lacrimal glands. However, fibroin is highly unstable in solution and irreversibly aggregates after only a few weeks, making it impractical for use in shelf-stable commercial eye drops in the past.

To overcome solution instability, SDP, a novel, hydrolysate derived from fibroin, is highly soluble and stable in aqueous formulation and acts as a wetting agent with known anti-inflammatory activity. SDP has been shown to enhance wound healing and reduce inflammatory markers both *in vitro* and *in vivo*.<sup>10</sup> When evaluating the use of SDP *in vitro* on a human corneal limbal-epithelial scratch assays, cell migration increased over 50%, with an approximate 60% increase in proliferation and nearly 30% decrease in scratch wound closure time.<sup>10</sup> These results were corroborated *in vivo* using a rabbit model, in which there was a three-fold increase in the acute wound healing and an improved tissue healing profile through the formation of healthy epithelium and increased tight junctions.<sup>11</sup> Additional biological effects included increased epithelial proliferation with a concomitant reduction in the presence of MMP-9, a known pro-inflammatory mediator of DED.

### SDP-4 in SilkTears

Further work was performed in which a clinical-grade version of SDP, termed SDP-4, was formulated as an excipient into a topical formulation containing polysorbate as the active agent, and then used to treat moderate-to-severe dry eye in FDA-sponsored clinical trials. Patients diagnosed with dry eye for up to over six months were enrolled for 12 weeks in a dual cohort, multi-center, double-masked and vehicle-controlled study. The first cohort of subjects had moderate to severe baseline symptoms while the second had moderate baseline symptoms.

Eye drops containing 1% SDP-4 significantly increased tear break-up time (TBUT) from baseline, even for severe patients. On average, patients treated with the 1% SDP-4 concentration witnessed a 78% improvement. In addition, patient symptomatology from baseline continued to improve throughout the 84-day study, reaching an average total SANDE score reduction of 30 points, which was equivalent to a 46% average reduction in symptoms across the treated patient population. Patients with more severe baseline dry eye symptoms experienced significantly improved relief as early as day 14 and continued to day 56. Lastly, all SDP-4 treatment groups were well-tolerated with a low (2.6%) discontinuation rate across both cohorts. Collectively, the results strongly suggest that SDP-

4-containing eye drop formulations offer a safe approach to aid in the relief of severe dry eye symptoms.

SDP-4 allows for the reduction of formulated excipients for a simpler—and ultimately healthier—approach to recreate the natural tear film chemistry, which is critical in formulations destined for chronic conditions such as DED and will provide a much-needed treatment in the battle against ocular surface disease. ■

- White DE, Zhao Y, Ogundele A, et al. Real-world treatment patterns of cyclosporine ophthalmic emulsion and lifitegrast ophthalmic solution among patients with dry eye. *Clin Ophthalmol*. 2019;13:2285-92.
- Semp DA, Beeson D, Sheppard AL, et al. Artificial tears: a systematic review. *Clin Optim (Auckl)*. 2023;15:9-27.
- Baudouin C, Rolando M, Castillo JMBD, et al. Reconsidering the central role of mucins in dry eye and ocular surface diseases. *Prog Retin Eye Res*. 2019;71:68-87.
- Quan NG, Leslie L, Li T. Autologous serum eye drops for dry eye: systematic review. *Optom Vis Sci*. 2023;100(8):564-71.
- Zhou T, He C, Lai P, et al. miR-204-containing exosomes ameliorate GVHD-associated dry eye disease. *Sci Adv*. 2022;8(2):eabj9617.
- Bhattacharjee P, Ahearne M. Silk fibroin based interpenetrating network hydrogel for corneal stromal regeneration. *Int J Biol Macromol*. 2022;223(Pt A):583-94.
- Liu J, Lawrence BD, Liu A, et al. Silk fibroin as a biomaterial substrate for corneal epithelial cell sheet generation. *Invest Ophthalmol Vis Sci*. 2012;53(7):4130-8.
- Ramachandran C, Gupta P, Hazra S, Mandal BB. *In vitro* culture of human corneal endothelium on non-mulberry silk fibroin films for tissue regeneration. *Transl Vis Sci Technol*. 2020;9(4):12.
- Kim CE, Lee JH, Yeon YK, et al. Effects of silk fibroin in murine dry eye. *Sci Rep*. 2017;7:44364.
- Abdel-Naby W, Cole B, Liu A, et al. Silk-derived protein enhances corneal epithelial migration, adhesion and proliferation. *Invest Ophthalmol Vis Sci*. 2017;58(3):1425-33.
- Abdel-Naby W, Cole B, Liu A, et al. Treatment with solubilized silk-derived protein enhances rabbit corneal epithelial wound healing. *PLoS One*. 2017;12:e0188154.



# Hemes and Cells and Sheathing—Oh, My!

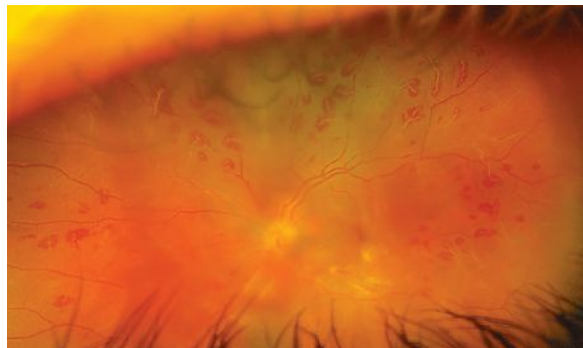
*A unique presentation of a rare postoperative complication.*

**A** 53-year-old man presented with three days of pain and redness in the left eye. He denied loss of vision and reported he had undergone uncomplicated cataract surgery at an outside facility one week prior to presentation. The right eye had also undergone cataract surgery three weeks prior to presentation and was asymptomatic.

His past medical history was significant for alcoholic cirrhosis and hypertension.

On examination, his visual acuities were 20/20 OD and 20/25 OS. Intraocular pressures were 17mm Hg and 14mm Hg, and pupils were equally reactive to light. The left eye had significant conjunctival injection with ciliary flush and 4+ cell in both the anterior chamber and vitreous cavity. The posterior segment exam disclosed mild optic nerve edema, diffuse arterial sheathing and salient perivascular hemorrhaging throughout the fundus. Fundus photos and OCT scans were acquired (*Figures 1 and 2*).

Differential diagnoses for this case were post-op endophthalmitis, viral retinitis, hemorrhagic occlusive retinal vasculitis (HORV) and toxic anterior segment syndrome. Given the proximity to surgery, there was a high concern for infection. HORV was not favored, given no intravitreal or intracameral antibiotics (vancomycin) were administered at



**Fig. 1. Fundus photo of the left eye on presentation reveals hemorrhagic vasculitis with mild diffuse vitreous haze.**

the time of surgery. Viral retinitis was less likely, given the clinical appearance and absence of immunocompromise. The patient did endorse a history of intravenous drug use, but stated his last use was six months prior to surgery. Upon further review of his cataract surgery post-op meds, he admitted to self-discontinuing topical antibiotics and steroids in the left eye just two days after surgery.

## Next Steps

A vitreous tap was performed on the left eye and sent for bacterial and fungal cultures. An anterior chamber tap was also performed and sent for viral cultures. Empiric intravitreal vancomycin and ceftazidime were injected. Voriconazole, an antifungal agent, was also administered given the reported history of intravenous drug use. The patient was started on topical prednisolone acetate hourly, cyclopentolate twice daily and oral valacyclovir 2,000mg three times daily.

The patient missed his one-day follow-up but presented two days later with a significant decline in vision, from 20/25 to hand motion. There was an appreciable increase in intraocular inflammation including a hypopyon and vitreous membranes (*Figure 3*). A second round of intravitreal antibiotics was recommended, but the patient refused. The following day, lacking any clinical improvement, the patient agreed to undergo pars plana vitrectomy (PPV) with intravitreal antibiotics and silicone oil placement. A vitreous sample taken at the time of surgery was positive for *Serratia marcescens*, confirming a diagnosis of a gram-negative bacterial endophthalmitis.

The patient's infection was cleared, and the eye healed well after surgery. The patient eventually underwent silicone oil removal, which resulted in a final visual acuity of 20/40.

## Endophthalmitis

Our patient's presentation was interesting because of the excellent visual acuity at presentation, clear fundus visualization and atypical retinal findings. "Sometimes, early endophthalmitis can present with mild vitritis but exhibit salient retinal findings such as hemorrhage or vasculitis," comments Jesse Sengillo, MD, to whom I referred this patient. "You always need to maintain a high suspicion in the setting of recent ophthalmic surgery."

Endophthalmitis after an intraocular procedure or surgery is a devastating complication. Based on a review of over 8.5 million cataract surgeries performed in the United States, the prevalence of postoperative endophthalmitis is very low, hovering around 0.04%.<sup>1</sup> Despite its rarity, as the rate of surgical comanagement is increasing, it becomes even more important for optometrists to recognize signs and symptoms of endophthalmitis.

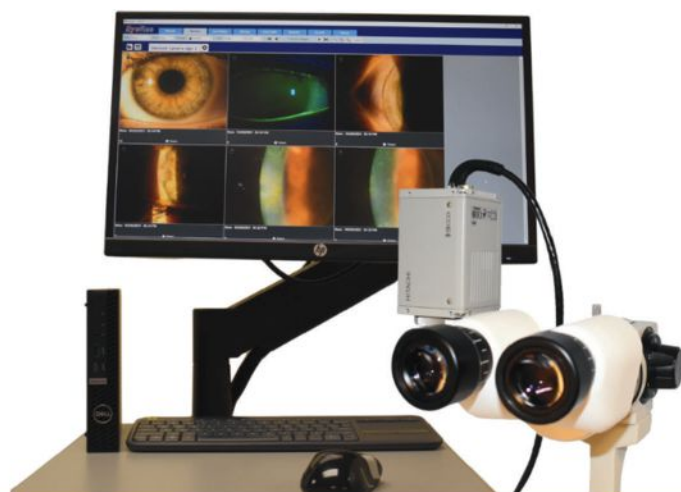
### About Dr. Bozung

Dr. Bozung practices at Bascom Palmer where she primarily sees patients in the hospital's 24/7 ophthalmic emergency department. She also serves as the optometry residency program coordinator. Dr. Bozung is a fellow of the American Academy of Optometry and a member of the Florida and American Optometric Associations. She is a founding board member of Young OD Connect and serves on the editorial board for *Review of Optometry*. She has no financial interests to disclose.



**FASTER FOR DOCTORS,  
BETTER FOR PATIENTS**

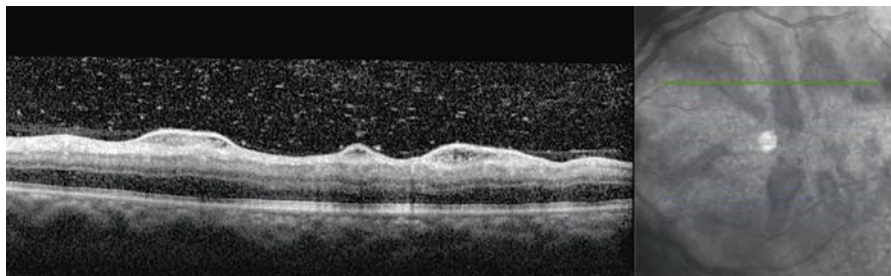
TelScreen creates  
tools that enable you  
to communicate with  
patients efficiently  
and effectively.



502-515-1806



[www.telscreen.com](http://www.telscreen.com)



**Fig. 2. OCT of the left eye at presentation reveals perivascular serous extravasation and vitreous cell.**

Acute postoperative endophthalmitis occurs within six weeks of surgery, and the most frequently experienced symptoms are blurred vision, pain and photophobia. Classic exam findings of endophthalmitis include anterior chamber cell with or without hypopyon, progressive vitritis, conjunctival injection and ciliary flush. Delayed or chronic postoperative endophthalmitis is that which occurs after six weeks. These cases may present with slow progression of these findings as well as granulomatous keratic precipitates and inflammatory deposits on the intraocular lens surface.<sup>2</sup>

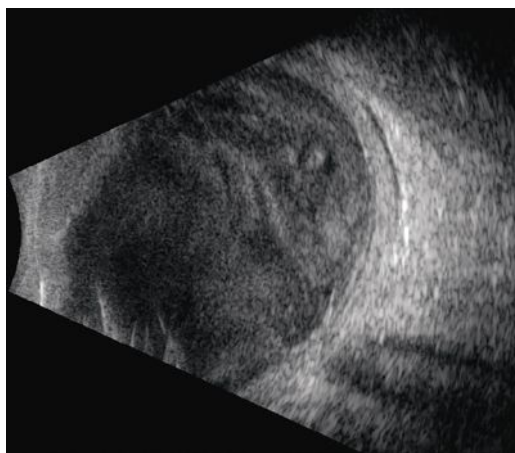
The most common causative pathogens are gram-positive bacteria of the ocular surface and adnexa, given their ubiquitous nature.<sup>3,4</sup> Gram-negative bacteria are generally considered to present with worse visual acuities and portend a poorer prognosis due to their production of endotoxins and phagocytosis-resistant capsules, which leads to increased virulence.<sup>5</sup> Fungal endophthalmitis is quite rare but may be slightly more common in tropical regions. Compared to bacterial endophthalmitis, fungal cases develop more slowly, over days to weeks, and are likely to have “clumps” of inflammatory material inside the eye as opposed to diffuse inflammation.<sup>6</sup>

## Management

When a patient presents with findings suspicious for postoperative endophthalmitis, comanaging providers should have a very low threshold to contact the surgeon and/or refer to a retina specialist on an emergent basis. A combi-

nation of intravitreal antibiotics potent against gram-positive (*e.g.*, vancomycin) and gram-negative (*e.g.*, ceftazidime) bacteria is typically administered. Antivirals can be added if there is high concern for viral retinitis masquerading as bacterial endophthalmitis. Antifungals may be used in atypical cases or if clinical suspicion is high, particularly if the patient’s history supports this etiology (*e.g.*, trauma, intravenous drug use).

Surgical management for endophthalmitis may be undertaken, as well. Vitrectomy can debulk the infection, provide a better culture sample, allow for direct visualization of the retina, and hasten visual recovery. The landmark 1995 Endophthalmitis Vitrectomy Study showed that for patients with very poor vision (light perception), the combination of early core vitrectomy with intravitreal antibiotics was superior to a vitreous tap and antibiotic injections alone in terms of final visual outcomes. A significant improvement in visual outcome was not



**Fig. 3. Ultrasonography was performed due to severely reduced vision at follow-up. Dense vitreous opacities and early membranes are appreciable.**

seen for patients with hand motion or better visual acuity regardless of whether vitrectomy was performed.<sup>7</sup>

That study led to the wide adoption of “tap and inject” as the mainstay of treatment for postoperative endophthalmitis. Some specialists consider early surgical intervention, given the improved safety profile of modern vitrectomy compared to 30 years ago. One study from 2020 suggests early surgical intervention increases the likelihood of patients with postoperative endophthalmitis achieving 20/40 or better vision from an average of 50% to almost 80%.<sup>8</sup>

Regardless of the approach taken to manage endophthalmitis, the first step is recognition. Careful evaluation of clinical signs and symptoms of endophthalmitis combined with a high level of suspicion can allow for early identification of this visually devastating disease. Proper triage and referral can provide the best possible outcome for our patients. ■

1. Pershing S, Lum F, Hsu S, et al. Endophthalmitis after cataract surgery in the United States: a report from the Intelligent Research in Sight Registry, 2013-2017. *Ophthalmology*. 2020;127(2):151-8.
2. Simakurthy S, Tripathy K. Endophthalmitis. In: StatPearls [Internet]. Treasure Island (FL): StatPearls Publishing. Updated August 25, 2023. [www.ncbi.nlm.nih.gov/books/NBK559079](http://www.ncbi.nlm.nih.gov/books/NBK559079). Accessed March 15, 2024.
3. Kernt M, Kampik A. Endophthalmitis: Pathogenesis, clinical presentation, management, and perspectives. *Clin Ophthalmol*. 2010;4:121-35.
4. Wilson BD, Relhan N, Miller D, Flynn HW. Gram-negative bacteria from patients with endophthalmitis: distribution of isolates and antimicrobial susceptibilities. *Retin Cases Brief Rep*. 2019;13(1):54-6.
5. Tiecco G, Laurenda D, Mulè A, et al. Gram-negative endogenous endophthalmitis: a systematic review. *Microorganisms*. 2022;11(1):80.
6. Durand ML. Bacterial and fungal endophthalmitis. *Clin Microbiol Rev*. 2017;30(3):597-613.
7. Endophthalmitis Vitrectomy Study Group. Results of the Endophthalmitis Vitrectomy Study: a randomized trial of immediate vitrectomy and of intravenous antibiotics for the treatment of postoperative bacterial endophthalmitis. *Arch Ophthalmol*. 1995;113(12):1479-96.
8. Dib B, Morris RE, Oltmanns MH, et al. Complete and early vitrectomy for endophthalmitis after cataract surgery: an alternative treatment paradigm. *Clin Ophthalmol*. 2020;14:1945-54.

## ABOUT THE CONTRIBUTOR



**Dr. Sengillo** currently serves as chief resident at Bascom Palmer after finishing a vitreoretinal surgery fellowship. He will join faculty upon completion. His practice will focus on surgical retina and inherited retinal disease. He has no financial disclosures.

# Bio-inspired hydration for dry eyes and contacts



Preservative free



pH balanced to match healthy tears



Hyaluronan (HA), a natural moisturizer†



Enhanced with an antioxidant and an electrolyte‡

## Recommend Biotrue® Drops to your patients today

\*Based on a laboratory study.

†Sourced from a large scale natural fermentation process.

‡Antioxidant protects HA from free radicals.

© 2024 Bausch + Lomb. BDB.0151.USA.23

**BAUSCH + LOMB**



# It's the Pits

*Managing this condition can be quite challenging.*

**A** 16-year-old male presented with blurry vision OU. His best-corrected visual acuity (VA) was 20/40 OD and 20/50 OS. He had an unremarkable birth history and no known medical conditions. IOP was 19mm Hg OD and 18mm Hg OS, extraocular motilities were full in all gazes, confrontation visual fields were full and pupils were equally round and reactive to light. Anterior segment exam revealed inferocentral corneal thinning, steepening and Vogt's striae OS>OD with anterior stromal scarring OS.

## Take the Retina Quiz

1. What is the most likely diagnosis for this patient's posterior segment?
  - a. Central serous retinopathy.
  - b. Exudative peripapillary neovascular membrane.
  - c. X-linked juvenile retinoschisis.
  - d. Optic disc pit maculopathy (ODP-M).
2. Which modality is most useful for detecting this maculopathy?
  - a. B-scan ultrasound.
  - b. Fluorescein angiography.
  - c. Fundus autofluorescence.
  - d. OCT.
3. Which is not a proposed source for this patient's maculopathy?
  - a. Vitreous humor.
  - b. Cerebrospinal fluid.
  - c. Vitreoretinal traction.
  - d. All of the above have been proposed.
4. Which is not considered to be a reasonable management option?
  - a. Observation.
  - b. Oral corticosteroids.
  - c. Macular buckle.
  - d. Pars plana vitrectomy (PPV).

5. What is the general prognosis for similarly presenting patients?
  - a. Excellent, 20/20 in nearly all cases.
  - b. Good, 20/70 or better in most cases.
  - c. Poor, 20/200 or worse in many cases.
  - d. Very poor in many cases.

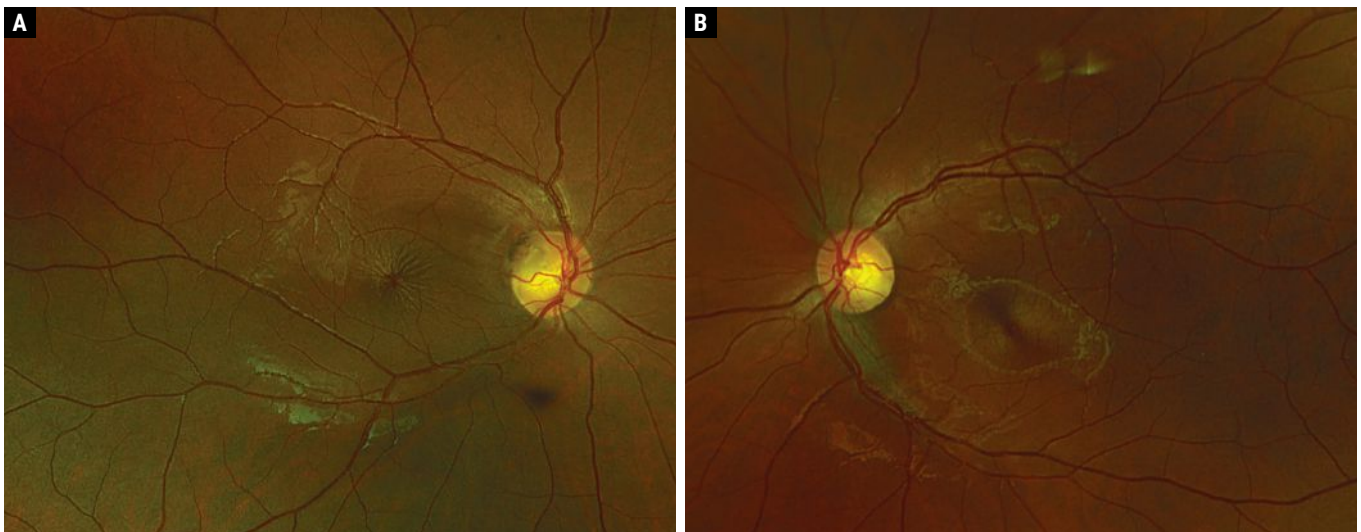*For answers to the quiz, see page 98.*

## Diagnosis

Regarding the anterior segment status, corneal topography confirmed a diagnosis of keratoconus. Careful examination of the fundus revealed a superotemporal optic pit OD with fluid extending into the superonasal macula and a central spoke-like appearance of the fovea; OS was normal with absence of an optic pit (*Figure 1*). OCT confirmed the presence of intraretinal (both inner and outer retinal) fluid extending from the pit into the fovea OD with no fluid present OS (*Figure 2*). A diagnosis of ODP-M was made.

## Discussion

ODPs are rare congenital optic nerve anomalies that were first described by



**Fig. 1.** Optos widefield fundus photography of the right (A) and left (B) eyes.

About  
**Dr. Aboumourad**

Dr. Aboumourad currently practices at Bascom Palmer Eye Institute in Miami. He has no financial disclosures.



# LACRIMEDICS<sup>®</sup>

## Punctum Plugs for Occlusion Therapy

### VisiPlug<sup>®</sup>

✓ **Dissolvable Occlusion Therapy.**

Lasting for up to 180 days.

### ComfortTip<sup>™</sup>

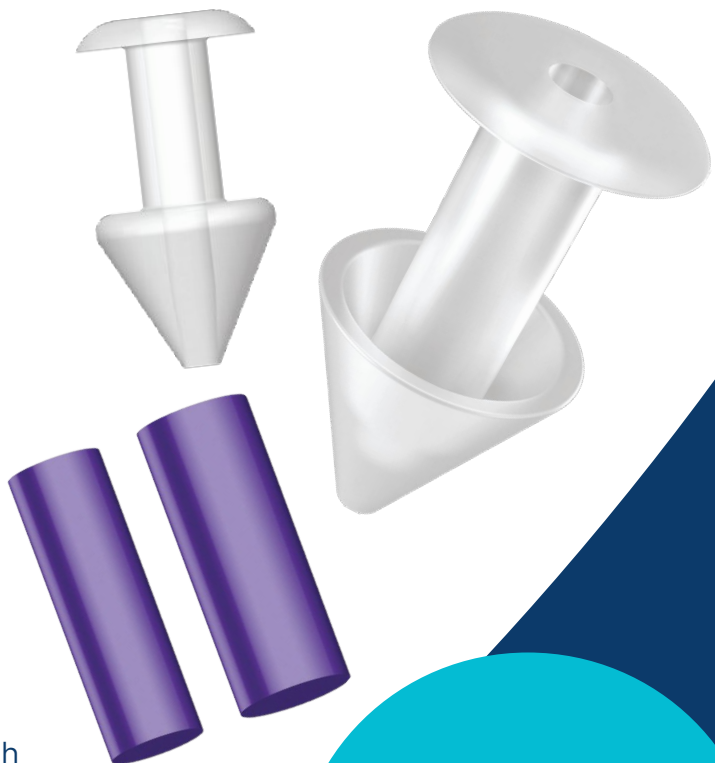✓ **Non-dissolvable Occlusion Therapy.**

Collapsible tip to aid ease of insertion and retention.

### AccuFlo<sup>™</sup>

✓ **Non-dissolvable Occlusion Therapy.**

Designed to allow tears to flow through the punctal opening.



[innoviamedical.com/lacrimedics](http://innoviamedical.com/lacrimedics)

Distributed by Summit Medical, an Innovia Medical Company

815 Vikings Parkway, Suite 100, St. Paul, MN 55121

T: 1-888-229-2875 | E: [customerservice@innoviamedical.com](mailto:customerservice@innoviamedical.com)

[www.innoviamedical.com](http://www.innoviamedical.com)

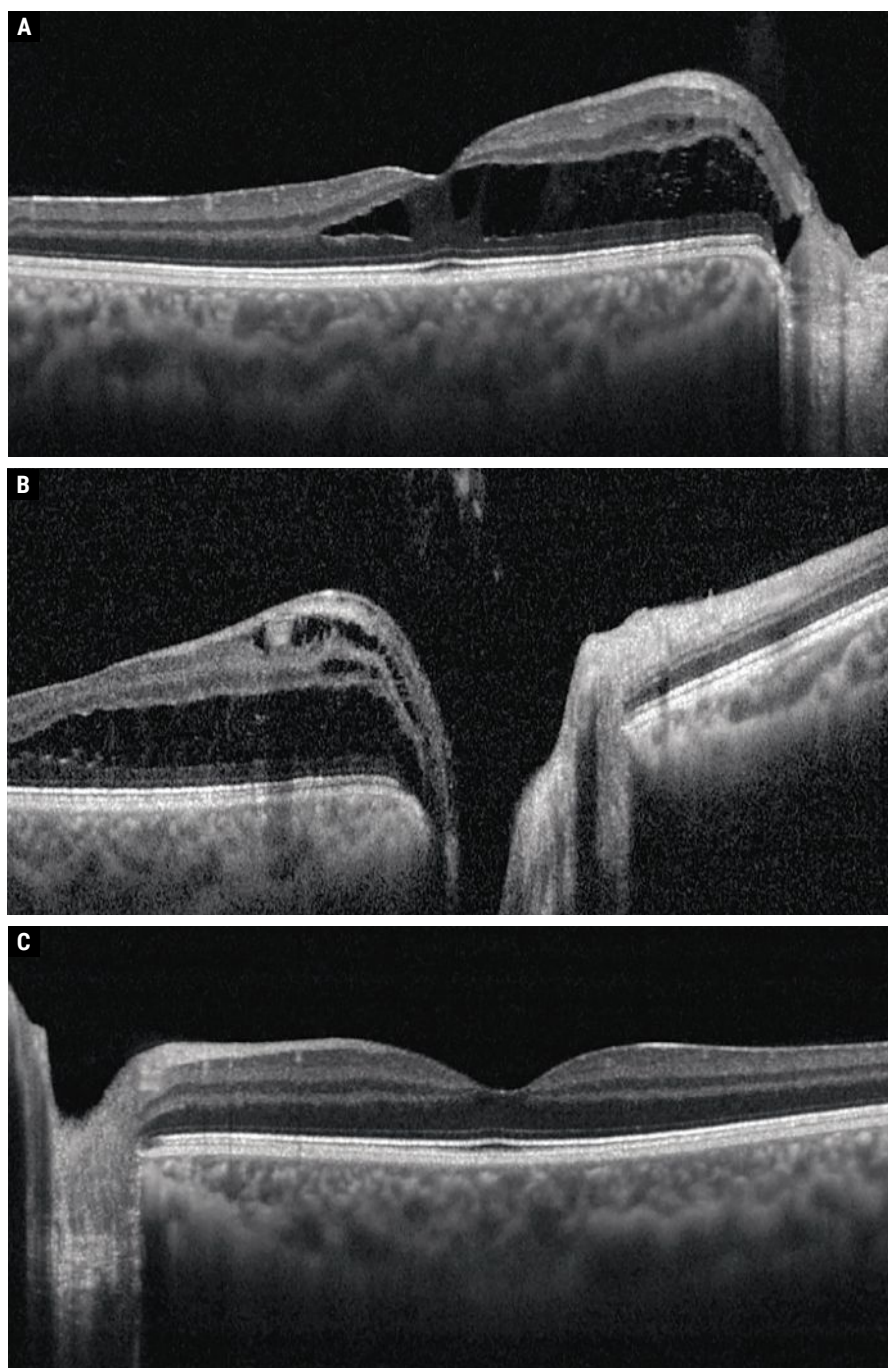
**LACRIMEDICS<sup>®</sup>**  
**DISSOLVABLE AND**  
**NON-DISSOLVABLE**  
**LACRIMAL PLUGS**

Wiethe in 1882.<sup>1,2</sup> The reported incidence is less than one in 10,000 and over 85% are noted to be unilateral in presentation with no racial or sex predilections.<sup>1,2</sup> The presence of optic disc pits appears to be sporadic with no associated genetic variant.<sup>1,3</sup> An acquired etiology has also been described in patients with (normal tension) glaucoma, producing a peripapillary retinoschisis appearance on OCT.<sup>4</sup>

Clinically, ODPs present as gray-brown, round-oval depressions found most frequently at the temporal or inferotemporal disc margin measuring approximately one-eighth to one-fourth disc diameter; central and nasal pits are less likely to produce maculopathy.<sup>1,3,5,6</sup> Affected patients are generally asymptomatic in the absence of maculopathy, though reports suggest that ODP-M occurs in up to 75% of patients with ODP.<sup>1,3</sup> Patients with optic disc pit maculopathy are most likely to present during the third to fourth decade of life (mean age of 31 years) with an average VA of 20/70 or worse.<sup>1,7</sup> Serous retinal detachments are generally confined within the temporal arcades.<sup>2</sup>

While the exact pathophysiology of optic disc pit maculopathy is not well understood, the leading theories are a communication between the vitreous cavity and subretinal space, between the subretinal and subarachnoid spaces or a three-fold vitreous-subretinal-subarachnoid fistula.<sup>4</sup> Gass reviewed a histopathological specimen of an enucleated globe with ODP-M and found a somewhat fibrous capsule over the pit, theorizing this could present a barrier into the intra- and subretinal spaces.<sup>4</sup> As he also was unable to identify vitreous glycosaminoglycans within the optic pit or the macular fluid, he postulated that cerebrospinal fluid would be most likely to enter the subretinal space through bypassing the pit's fibrous capsule and approaching either between the capsule and scleral rim or by entering directly beneath invaginated neuroectodermal tissue.<sup>1,4</sup>

The hypothesis of vitreous subarachnoid fistulization was supported



**Fig. 2.** OCT raster through the OD fovea (A), OD optic nerve (B) and OS fovea (C).

by documented migration of silicone oil from the vitreous cavity into both the subretinal space and intracranial cavity.<sup>1,4</sup> There is also a consensus that vitreous traction likely plays a mechanistic role in the development of maculopathy, suggesting that treatments targeted at relieving traction may subsequently resolve the serous detachments.<sup>1,2</sup>

OCT is perhaps the most useful imaging modality for evaluating these patients, as fluid generally accumulates to produce a schisis-like cavity within the inner retina first, followed by the outer retina; this correlates with the clinical spoke-like appearance.<sup>2</sup> However, there are reports of patients presenting with combined outer-retinal schisis and subretinal fluid,

notably without inner-retinal schisis.<sup>2</sup> It has been suggested that chronic outer-retinal schisis eventually results in lamellar hole formation, which provides an alternative pathway for the accumulation of subretinal fluid.<sup>1,2,8</sup>

## Management

Controlling ODP-M is challenging, and numerous therapeutic interventions have been attempted with variable success, indicating there is no standard of care. Oral corticosteroids have been trialed without success.<sup>1</sup> Retinal photocoagulation has been applied in both an arcuate pattern temporal to the disc as well as circumferential to the disc with intent to create chorioretinal adhesions to barricade the pit from the macula with mixed results regarding efficacy and consistency.<sup>1,4,5,7</sup>

Intravitreal gas tamponade has also been tried in isolation and in combination with retinal photocoagulation or PPV, both serving to relieve

vitreoretinal traction.<sup>1,2,7,8</sup> Other surgical ideas that have been explored include macular buckling (technically difficult with steep learning curve) and inner-retinal fenestrations, which have shown moderate success rates.<sup>2,7</sup> Gass proposed an algorithm for ODP-M of initial observation for at least one month, followed by one to two applications of retinal photocoagulation and ultimately intravitreal gas tamponade with or without PPV.<sup>5</sup> Overall, PPV has a favorable safety profile, though no therapeutic approach has been shown to be uniformly successful.<sup>2,5</sup> A prospective trial would be useful in comparing surgical options to determine an algorithmic approach for managing these patients.

## Prognosis

Unfortunately, it is relatively poor, with many patients suffering irreversible VA loss of 20/200 or worse, especially in cases with chronic detachment.<sup>7</sup> It has been argued that

earlier intervention may presumably yield greater visual recovery.<sup>2,7</sup> Our patient was recommended observation given the good presenting VA. Furthermore, his ODP-M is confounded by keratoconus, making it difficult to discern the visual significance of his maculopathy. ■

1. Kalogeropoulos D, Ch'ng SW, Lee R, et al. Optic disc pit maculopathy: a review. *Asia Pac J Ophthalmol (Phila)*. 2019;8(3):247-55.

2. Shah SD, Yee KK, Fortun JA, Albini T. Optic disc pit maculopathy: a review and update on imaging and treatment. *Int Ophthalmol Clin*. 2014;54(2):61-78.

3. Brown GC, Shields JA, Goldberg RE. Congenital pits of the optic nerve head. II. Clinical studies in humans. *Ophthalmology*. 1980;87(1):51-65.

4. Gass JD. Serous detachment of the macula. Secondary to congenital pit of the optic nervehead. *Am J Ophthalmol*. 1969;67(6):821-41.

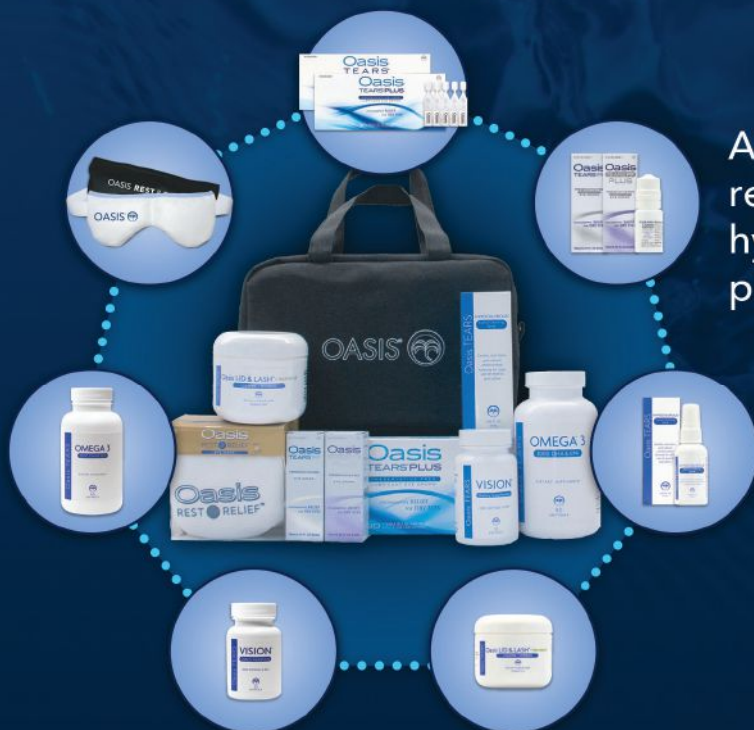5. Agarwal A, Gass JDM. *Gass' Atlas of Macular Diseases*. 5th ed. London: Elsevier; 2011.

6. Gordon R, Chatfield RK. Pits in the optic disc associated with macular degeneration. *Br J Ophthalmol*. 1969;53(7):481-9.

7. Chatziralli I, Theodosiadis P, Theodosiadis GP. Optic disc pit maculopathy: current management strategies. *Clin Ophthalmol*. 2018;12:1417-22.

8. Christoforidis JB, Terrell W, Davidorf FH. Histopathology of optic nerve pit-associated maculopathy. *Clin Ophthalmol*. 2012;6:1169-74.

# OASIS® DRY EYE SOLUTIONS



A diverse range of solutions for dry eye relief, including lubricating drops, eyelid hygiene, eye health nutraceuticals and punctal occlusion.



Have an Experience.  
Scan Here.

To Order/Learn More:

Call 844.820.8940

Visit [oasismedical.com](http://oasismedical.com)

Email [customerservice@oasismedical.com](mailto:customerservice@oasismedical.com)



EDITED BY NATE LIGHTHIZER, OD

## ADVANCED PROCEDURES

# Oust the Cyst

*Integrate these eyelid lesion removals into your surgical arsenal.*

BY BRADLEY A. DANIEL, OD  
EDMOND, OK

As the scope of optometry broadens across the nation, more optometrists now have access to an expanding array of simple yet highly effective treatments that they can seamlessly integrate into their practice. ODs having the capability to practice to the full extent of their training can offer their patients the highest caliber of care. Optometric surgery consisting of minor surgical procedures such as eyelid cyst removals should be integrated into the practice of every medical optometrist practicing in states where scope has expanded to include these procedures.

## Background

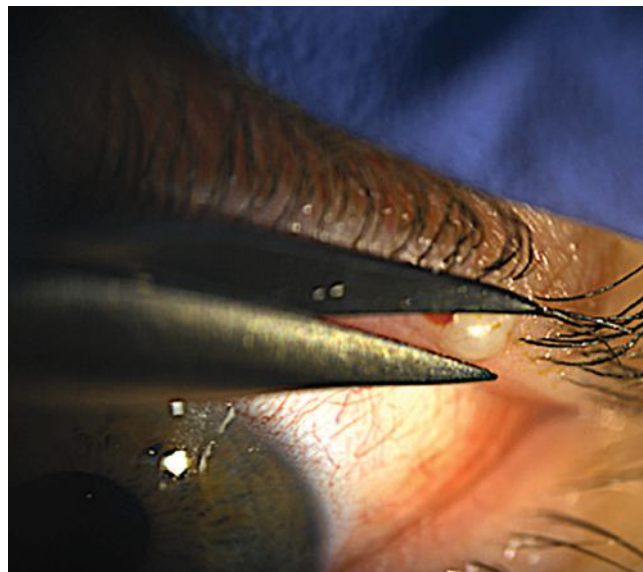
Encountered frequently on the eyelids, cystic growths can originate from various glands surrounding the ocular adnexa. These can include sebaceous glands, namely the glands of Zeis and meibomian glands.<sup>1</sup> Cysts of Zeis are sebaceous cysts of the eyelid that present as solitary lesions found at the base of eyelashes near the eyelid margin. They are filled with yellow or turbid material and do not transilluminate. The most common type of sebaceous cyst of the eyelids affects the meibomian gland and is known as a chalazion.<sup>1</sup>

Cysts of the sweat glands of the eyelids can be categorized into two categories depending on the type of sweat gland it affects. The apocrine sweat glands of Moll open into the hair follicle, while the eccrine sweat glands open directly on the skin's surface.<sup>1,2</sup> These sweat gland cysts are collectively known as hidrocystomas. Apocrine hidrocystomas, also known as cysts of Moll, commonly manifest as sudoriferous cysts at the base of the eyelash or in the inner canthus as clear papules or nodules ranging from 1mm to 3mm in size. They may appear flesh-colored, blue or black and will transilluminate, while their size remains unaffected

by temperature variations.<sup>1-4</sup> Eccrine hidrocystomas typically present as clear cysts ranging from 4mm to 10mm in size and are located on the nasal or temporal side of the eyelid close to, but not on, the eyelid margin. These cysts exhibit transillumination and undergo size fluctuations in response to temperature shifts.<sup>1-4</sup>

Cyst formation is caused from a blockage or obstruction in the duct, impeding the normal flow of sweat. Histologically, hidrocystomas present with a thin, non-keratinized epithelium lining and the cystic cavity holds clear or slightly turbid fluid. Surrounding the cyst wall are myoepithelial cells.<sup>3</sup> Suspected to involve a chronic inflammatory process, various factors like genetics, sun exposure and age may contribute to their development. Additionally, epidermal inclusion cysts commonly develop on or around the eyelids, stemming from hair follicle obstruction or skin trauma, accumulating keratin, sebum and debris within a sac-like structure.<sup>1,5,6</sup> While generally considered benign, the cysts described above can cause ocular discomfort and elicit cosmetic concerns for most patients.

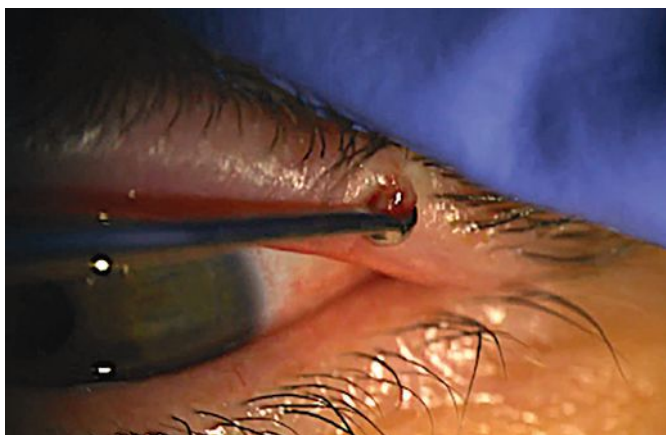
Generally, a simple excision is the treatment of choice for these cystic eyelid lesions.<sup>1-6</sup> Due to high rates of recurrence, complete removal of the capsule and contents needs to be achieved. The superficial nature of these growths still can warrant localized anesthesia as an incision or "unroofing" is performed followed by an excision of deeper tissue. Hemostasis is



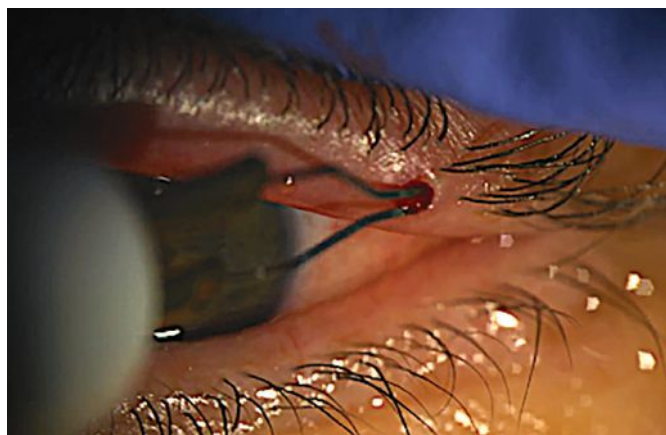**A superficial eccrine cyst "unroofed" using Wescott surgical scissors. A characteristic clear blister bubble is present superficially. The patient stated it would grow in size with hotter temperatures. Topical anesthetic ointment was used rather than an injection of a localized anesthetic.**

About  
Dr. Lighthizer

Dr. Lighthizer is the associate dean, director of continuing education and chief of specialty care clinics at the NSU Oklahoma College of Optometry. He is a founding member and immediate past president of the Intrepid Eye Society. Dr. Lighthizer's full disclosure list can be found in the online version of this article at [www.reviewofoptometry.com](http://www.reviewofoptometry.com).



**Using a foreign body curette can help excavate cystic capsules and contents.**



**Handheld thermal cautery pen used for hemostasis. Note to not turn on the pen until the wires are on the targeted tissue. A quick touch usually gets the job done. Apply antibiotic ointment after.**

achieved with epinephrine and pressure; however, thermal cautery is usually warranted to achieve proper tissue destruction and hemostasis. Biopsies are recommended for atypical growths but cannot be achieved if a radiofrequency (RF) surgical unit is used in the excisional process, especially for small lesions. However, one may use an RF unit directly after a simple excision to “clean up” the operated area for improved cosmesis postoperatively.

### **Preoperative Procedures and Considerations**

The equipment needed is readily available in most office settings. The simple excision procedure can be performed in an in-office setting where no surgical suite is necessarily needed. In a standard exam room, the patient can be supine in the chair is adequate. A surgical microscope is not needed, but loops are recommended to enhance precision. Alternatively, an RF unit can be used instead of the Westcott scissors and thermal cautery pen. Having a device that uses high-frequency electrical currents to cut, coagulate or ablate tissues, enables precise and controlled tissue removal while minimizing bleeding and promoting quicker healing.

When using an RF unit, it's imperative to observe additional precautions, including keeping the target tissue wet with saline solution before ablation, avoiding use on patients with pace-

makers or other electronic implanted devices and employing a smoke evacuator or vacuum system. Taking vitals, such as blood pressure and pulse rate, is recommended prior to performing any minor surgical procedures in the office. If a patient is on blood-thinning medications, it is not required to discontinue them prior to the procedure. Taking preoperative photos as well as obtaining proper informed consent are also part of the usual preoperative process.

### **Procedural Technique**

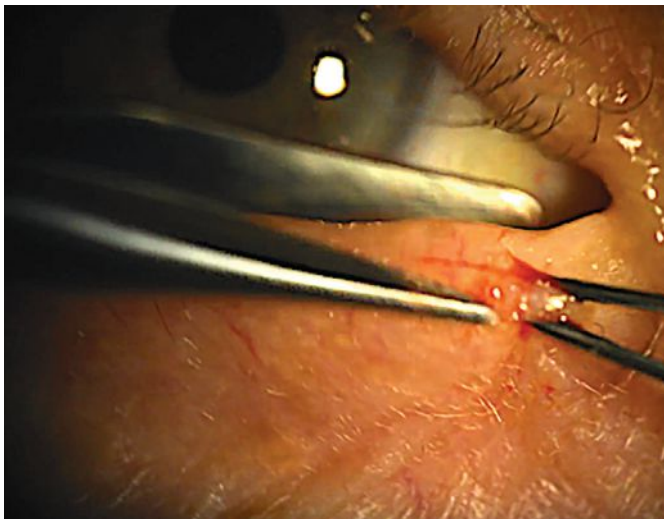
To optimize patient comfort and procedural efficacy, the choice to administer localized anesthetic via intradermal injection hinges on factors

such as lesion size, location and patient preference. Deeper cysts necessitating aggressive tissue manipulation and cautery will require the use of localized anesthetic. Conversely, superficial “bubble” cysts can be readily unroofed using surgical scissors post-topical anesthetic application with minimal discomfort.

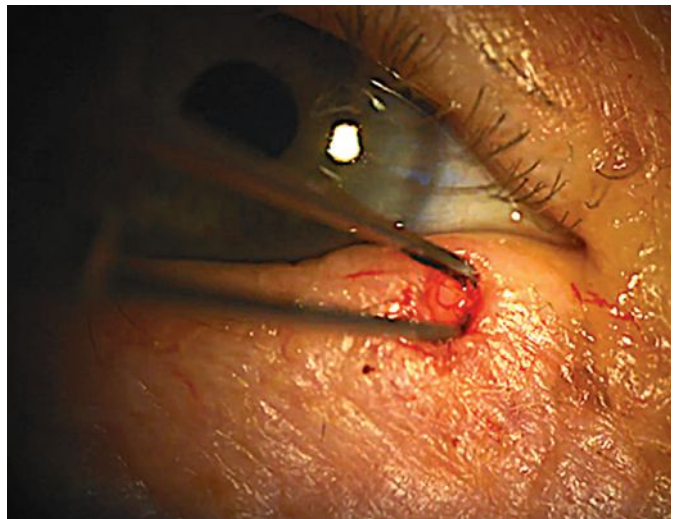
When local anesthesia is deemed necessary, it's helpful to delineate the lesion's borders using surgical markers before administering any injections. This process follows the sterilization of the operative lid with povidone-iodine or alcohol swabs. After the lid has been sterilized and the cystic borders marked, a 27- to 30-gauge needle attached to a syringe containing

#### **EQUIPMENT NEEDS**

- Local anesthetic 0.5%, 1% or 2% lidocaine with epinephrine (1:100,000 or 1:200,000)
- 18-gauge needle for draw up
- 27- to 30-gauge needle for anesthetic
- 1cc or 3cc syringe
- Povidone-iodine swab/pad for lid disinfection
- Forceps with or without teeth
- Foreign body curette
- Westcott surgical scissors
- Thermal cautery pen or RF device (Soniquence unit or Ellman unit)
- Cotton-tipped applicator or gauze for any bleeding and needed pressure
- Eyepad and tape
- Topical ophthalmic antibiotic ointment (good gram+ coverage)
- Sharps container
- Specimen collection for biopsies, if warranted
- Surgical loupes (recommended)



Grabbing taut the apex of the cyst and pulling anteriorly while moving Westcott surgical scissors in position for initial “unroofing.”



The cystic capsule is extracted using forceps with teeth to ensure the entire contents are removed to prevent recurrence.

0.5%, 1% or 2% lidocaine HCl with 1:100,000 epinephrine is carefully inserted into the subciliary skin adjacent to the cyst, with the bevel up angled at 10° to 15° degrees. Then, 0.3mL to 0.5mL of anesthetic is administered continuously as the needle is gradually withdrawn until a bolus of anesthetic is seen under and around the lesion, which is the injection endpoint. Pull the targeted lid taut with the free hand while using the other to inject the anesthetic. Prior to proceeding, test the anesthesia by palpating the target tissue with sterile forceps. Digital palpation over the injected area helps enhance anesthesia. Using toothed forceps to grip the apex of the cyst and pulling upward with one hand, Westcott surgical scissors are wielded in the dominant hand to “unroof” the lesion. Alternatively, RF could also be used with a “bent tip” electrode to make an incision into the cyst.

Once the incision has been made, the forceps can then grab the contents of the cyst, ensuring the removal of the capsule and capsule wall entirely. Any excess cystic material is removed using a curette to minimize the chance of recurrence. The center of the cystic pocket is cauterized using a handheld thermal cautery pen (or alternatively RF).

Ensure that the cautery wires are on the tissue before activation to

treat only the targeted tissue. Debris or blood is cleaned off using cotton-tipped applicators while applying slight pressure to the area to aid in hemostasis.

Finally, a single layer of topical ophthalmic antibiotic ointment is applied to the treated area. The ointment should have good gram-positive coverage, such as erythromycin 0.5% ophthalmic ointment.

### Follow-Up

A topical antibiotic ointment with good gram-positive coverage is prescribed. Instruct the patient to apply a small layer to the treated area twice daily for one week. Educate them with post-op care instructions, including recommendations for managing any discomfort or swelling and instructions for proper wound care, as well as to contact the office readily if any issues are noted between visits. Recommended follow-up should typically be scheduled in two to four weeks for a recheck to ensure proper healing and to discuss pathology reports if a biopsy was obtained at the time of the excision. It is recommended to take photos of the lesion preoperatively and postoperatively for documentation purposes.

### Takeaways

As medical optometrists incorporate eyelid cyst removal procedures into

their practice, they will find that, with experience the process becomes increasingly manageable. Confidence grows with each successful removal performed, paving the way for more opportunities to provide patients with the highest level of medical eye care. By integrating eyelid cyst removals, medical optometrists can enhance their ability to treat a broader range of ocular diseases, ultimately bolstering the overall quality of care received by patients. ■

1. Stokermans TJ, Prendes M. Benign Eyelid Lesions. In: StatPearls [Internet]. Treasure Island (FL): StatPearls Publishing. [www.ncbi.nlm.nih.gov/books/NBK582155](http://www.ncbi.nlm.nih.gov/books/NBK582155). Last updated May 29, 2023. Accessed March 19, 2024.
2. Couto Júnior Ade S, Batista GM, et al. Hidrocystoma: surgical management of cystic lesions of the eyelid. *An Bras Dermatol*. 2010;85(3):368-71. English, Portuguese.
3. Penne R. *Oculoplastics*. 2nd ed. Philadelphia: Wolters Kluwer Health/Lippincott Williams & Wilkins Health; 2012.
4. Yanoff M, Duker J. *Ophthalmology*. 4th ed. Philadelphia: Elsevier Saunders; 2014.
5. Cape HT, Mukit FA, Mukit M, et al. Apocrine hidrocystoma of the upper eyelid. *Eplasty*. 2022;22:ic13.
6. Trischman T, Scott JF. Comparative Efficacy of hidrocystoma treatments: a systematic review. *J Cutan Med Surg*. 2020;24(5):474-80.

### ABOUT THE AUTHOR



**Dr. Daniel** specializes in ocular disease and refractive surgery at Edmond Regional Eye Associates in Edmond, Oklahoma, having received advanced clinical training in the diagnosis and management of ocular disease. He is also certified in laser vision correction, anterior segment laser procedures and other minor surgical procedures. Dr. Daniel is a fellow of the American Academy of Optometry, as well as a diplomate of the American Board of Optometry. He has no financial disclosures.

Practice For Sale



Practice Sales • Appraisals • Consulting  
[www.PracticeConsultants.com](http://www.PracticeConsultants.com)

**PRACTICES FOR SALE  
 NATIONWIDE**

Visit us on the Web or call us to learn more about our company and the practices we have available.  
[info@PracticeConsultants.com](mailto:info@PracticeConsultants.com)  
**925-820-6758**

[www.PracticeConsultants.com](http://www.PracticeConsultants.com)

**Optometric practice in Del Norte Ca is selling a very potentially profitable practice.**

There are no other optometry, ophthalmology or optical offices in the city or county. The office is 5 blocks from an amazing coastline with beautiful forest, beaches and rivers. 1250 sf office with a wonderful staff.

Any reasonable offer will be seriously appreciated.

If interested, please contact [sinouye7@gmail.com](mailto:sinouye7@gmail.com)

**Private Practice for Sale at the Jersey Shore!**

40 year old, 2 Doctor Practice

Fully equipped including a pre-test room, separate specialty testing room, 3 full exam lanes & a beautiful optical dispensary.

If you are motivated and dedicated to your profession and sensitive to your patient's needs, this practice will give you a lifetime of rewards and happiness.

Call 732-349-2020  
 or email [KASLLP@comcast.net](mailto:KASLLP@comcast.net)



Contact us today for classified advertising:  
 Toll free: **888-498-1460**  
 E-mail: [sales@kerhgroup.com](mailto:sales@kerhgroup.com)

**REVIEW**  
*of* OPTOMETRY



**REVIEW**  
*of* OPTOMETRY

Targeting Optometrists?

**CLASSIFIED ADVERTISING WORKS**

- JOB OPENINGS • CME PROGRAMS
- PRODUCTS & SERVICES • AND MORE...

Contact us today for classified advertising:  
 Toll free: **888-498-1460**  
 E-mail: [sales@kerhgroup.com](mailto:sales@kerhgroup.com)


**KERHGROUP**

Merchandise Offered

**FRAME DISPLAYS & OPTICAL INTERIORS**



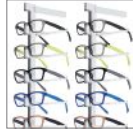
Optical Displays • Furniture • Design  
Professional US Based Customer Service



Wall Mount



Counter Top



Locking Rods



Trays & Frame Bags



Custom Frame Rods



Optical Cabinets



Trusted by more than 40,000 eye care professionals worldwide.



1-877-274-9300 • www.framedisplays.com

**FREE SHIPPING \$100+ Orders\***

\*Excludes Freight Shipments

Code: **FREESHIPROP**



Complimentary  
Zoom Design  
Session



0% Financing  
& Interest for  
36 Months\*

Online Auction

**BID DEADLINE: 3 PM ON TUESDAY, MAY 28**

**LIQUIDATION  
SALE**

State-of-the-Art Optometric Testing Equipment  
**EVERYTHING MUST GO!**

**PLACE YOUR BID  
TODAY**

ALL ITEMS HAVE CLEAN TITLES • BID DEADLINE: 3 PM ON TUESDAY, MAY 28  
ACT FAST BEFORE THESE EXCEPTIONAL DEALS ARE GONE!

[WWW.PHGAUCTION.COM](http://WWW.PHGAUCTION.COM)



**HERE ARE JUST A FEW  
OF THE EXCEPTIONAL  
ITEMS AVAILABLE**

Marco TS-610 Tabletop Refractors  
DRS Plus Centervue Fundus Cameras  
Nidek Tonoref II's

FOR ANY INQUIRIES, CONTACT PAUL AT 813-748-8586 OR EMAIL [PREMIERHEALTHCAREGROUPLLC@GMAIL.COM](mailto:PREMIERHEALTHCAREGROUPLLC@GMAIL.COM)  
ALL SALES ARE FINAL. PRICES AND AVAILABILITY SUBJECT TO CHANGE WITHOUT NOTICE.

DON'T MISS THIS OPPORTUNITY TO ACQUIRE TOP-OF-THE-LINE EQUIPMENT IN BARELY USED OR OPEN BOX CONDITION.

**Do you have  
CE Programs?**

**CONTACT US TODAY  
FOR CLASSIFIED  
ADVERTISING**

Toll free:  
**888-498-1460**

E-mail:

**[sales@kerhgroup.com](mailto:sales@kerhgroup.com)**



# PRODUCT REVIEW

New items to improve clinical care and strengthen your practice.




**ONLINE FIRST:**  
GET THE LATEST  
PRODUCT NEWS AT  
[www.reviewofoptometry.com](http://www.reviewofoptometry.com)

## ► DRY EYE

### Nutraceutical for Dry Eye Coming This Fall

Bausch + Lomb plans to launch a new oral OTC therapy for dry eye this fall called Blink NutriTears, a company press release revealed. The product combines lutein/zeaxanthin, curcumin and vitamin D3. The carotenoids were included for their antioxidant and anti-inflammatory properties. Curcumin is a polyphenol extracted from turmeric known to inhibit pro-inflammatory mediators. Vitamin D can improve tear secretion and quality, and also possesses anti-inflammatory effects.

B+L conducted a study wherein 77 subjects used the formulation daily for eight weeks and showed improvements in tear volume by Schirmer's score and ocular surface staining, as well as reductions in tear osmolarity and MMP-9 concentration, according to data from the company.



### Punctal Plug Features Tapered End for Easier Insertion

Oasis Medical now offers a disposable tapered punctal insert, called Soft Plug Extended Duration 180-T Tapered Plug, that is engineered to gradually degrade in about 180 days. The

0.25mm tapered end goes into the punctal opening and gradu-

ally widens to a diameter of 0.6mm at the top end to occlude the canaliculus. The plug is made with degradable polydioxanone monofilament that Oasis says lasts up to six months before becoming absorbed into the body.

### New Dry Eye Treatment Pairs with BlephEx

The developers of the BlephEx device for performing blepharofoliation introduced a new product called OptiVize that uses a method called biofilm vaporization to help loosen and extract oil from clogged meibomian glands. The result is then expressed from the glands using heated ultrasonic forceps.



In patients with poor quality meibum production, the company recommends the second procedure be performed once per month immediately after blepharofoliation. The goal is to get patients to a state where they can produce their own healthy meibum. Once clear oil is expressed at consecutive visits, the company recommends performing BlephEx (without OptiVize) every four to six months to keep the biofilm contained.

BlephEx is currently conducting a pilot study on this paired treatment protocol involving 50 patients, the results of which will be published in a few months. ■

## ADVERTISER INDEX

This index is published as a convenience and not as part of the advertising contract. Every care will be taken to index correctly. No allowance will be made for errors due to spelling, incorrect page number, or failure to insert.

Alcon ..... Cover 4	CooperVision ..... Insert	Oasis Medical ..... 91
<a href="http://www.alcon.com">www.alcon.com</a>	800-341-2020	(844) 820-8940
	<a href="https://coopervision.com">https://coopervision.com</a>	<a href="http://www.oasismedical.com">www.oasismedical.com</a>
Allergan ..... Cover Tip	CooperVision ..... Cover 3	<a href="mailto:customerservice@oasismedical.com">customerservice@oasismedical.com</a>
<a href="http://www.allergan.com">www.allergan.com</a>	800-341-2020	
	<a href="https://coopervision.com">https://coopervision.com</a>	Oculus ..... 27
Bausch + Lomb ..... 11	Eyefficient ..... 53	(800) 347-4500
866-246-8245	800-417-8136	<a href="https://www.oculus.de/us">https://www.oculus.de/us</a>
<a href="https://www.bausch.com">https://www.bausch.com</a>	<a href="https://www.eyefficient.com">https://www.eyefficient.com</a>	Oyster Point ..... 14, 15
Bausch + Lomb ..... 23	Glaukos ..... 5	<a href="https://oysterpointrx.com">https://oysterpointrx.com</a>
866-246-8245	(800) 452-8567	Reichert Technologies ..... 56, 57
<a href="https://www.bausch.com">https://www.bausch.com</a>	<a href="http://www.glaukos.com">www.glaukos.com</a>	(888) 849-8955
Bausch + Lomb ..... 87	Harrow ..... 7, 8	<a href="http://www.reichert.com">www.reichert.com</a>
866-246-8245	<a href="https://www.harrow.com/">https://www.harrow.com/</a>	Tarsus ..... 19, 20
<a href="https://www.bausch.com">https://www.bausch.com</a>	Innovia Medical ..... 89	<a href="https://tarsusrx.com">https://tarsusrx.com</a>
Bausch + Lomb ..... 69, 70	Lacrivera ..... 31	TelScreen ..... 85
866-246-8245	855-857-0518	502-515-1806
<a href="https://www.bausch.com">https://www.bausch.com</a>	<a href="http://www.lacrivera.com">www.lacrivera.com</a>	<a href="http://www.TelScreen.com">www.TelScreen.com</a>
Bruder Healthcare Company ..... 41	Meivertor ..... 17	Thea Pharma ..... Cover 2, 3
(888) 827-8337	<a href="http://Meivertor.com">Meivertor.com</a>	781-832-3664
<a href="http://www.bruder.com">www.bruder.com</a>	Menicon ..... 39	<a href="https://iyuzeh.com">https://iyuzeh.com</a>
<a href="mailto:eyes@bruder.com">eyes@bruder.com</a>	(800) 636-4266	Thea Pharma ..... 25
Bruder Healthcare Company ..... 63	<a href="http://www.meniconamerica.com">www.meniconamerica.com</a>	781-832-3664
(888) 827-8337	Nanodropper ..... 33	<a href="https://www.lvzia.com">https://www.lvzia.com</a>
<a href="http://www.bruder.com">www.bruder.com</a>	(507) 405-5676	Viatris ..... 45, 46
<a href="mailto:eyes@bruder.com">eyes@bruder.com</a>	<a href="http://www.nanodropper.com/ReviewOpt">www.nanodropper.com/ReviewOpt</a>	<a href="https://www.viatris.com/en">https://www.viatris.com/en</a>
	<a href="mailto:pro@nanodropper.com">pro@nanodropper.com</a>	Vital Tears ..... Insert
	Oasis Medical ..... 49	<a href="https://vitaltears.org">https://vitaltears.org</a>
	(844) 820-8940	Zeavision ..... 61
	<a href="http://www.oasismedical.com">www.oasismedical.com</a>	<a href="http://www.eyepromise.com">www.eyepromise.com</a>
	<a href="mailto:customerservice@oasismedical.com">customerservice@oasismedical.com</a>	



# Sugar Crash

*Significant corneal concerns and a collapsed anterior chamber manifested in this patient. What conditions should be considered?*

**A** 68-year-old woman presented to the ophthalmology department after being referred by a local optometrist. She was homebound and received home care. She wore spectacles for both distance and near viewing. The doctor had diagnosed her with a nonspecific corneal infection/inflammation OD and placed her on topical antibiotics, but she failed to fill the prescriptions. Upon observation, her eye was red and photophobic. She was in substantial pain. Her vision was poor. She was COVID negative. Her systemic history was positive for poorly controlled hypertension and diabetes. She denied trauma or the use of contact lenses. She denied allergies of any kind.

## Clinical Findings

Her best uncorrected entering visual acuities were light perception at three feet OD and 20/30 OS. There was no retinoscopic reflex in the right eye. The reflex in the left eye was normal, indicating gross emmetropia. Her extraocular motilities were intact in both eyes. Her confrontation fields demonstrated awareness to finger-size isopters OD with the confrontation field in the left eye being normal. There was an afferent pupil defect in the right eye. The gross examination of the anterior segment is demonstrated in the photograph.

Her intraocular pressures measured 2mm Hg in the right eye and 16mm Hg in the left with Goldmann applan-

tion. There was no evidence of rubeosis or ectropion uvea in either eye. The right eye was not dilated and no view of the posterior pole was possible. Dilated examination of the left eye demonstrated a cup-disc ratio measuring 0.2 round, with distinct margins and normal grounds with no macular edema or proliferative diabetic retinopathy.

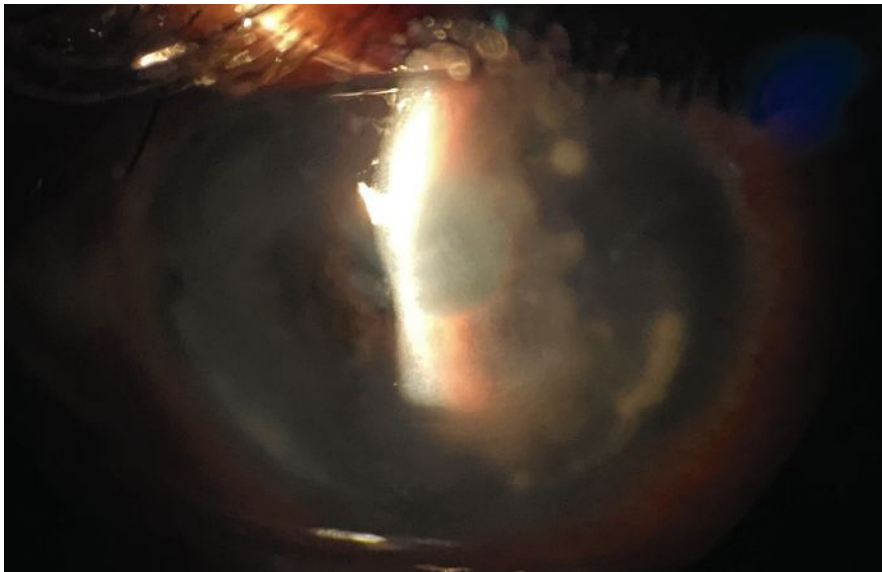
## Additional Testing

Dilation and cycloplegia are contraindicated in these cases. The collapsed anterior chamber indicates a full-thickness perforation. The iris apposition to the central corneal depression suggests incarceration. This should not be altered. Corneal sensitivity was measured and found to be present only to exaggerated stimuli OD. Anterior segment photography was completed. B-scan ultrasonography was considered but postponed in favor of emergency referral to the anterior segment service of the local eye hospital. A Seidel sign was completed, demonstrating no leakage; however, it was clear the collapsed anterior chamber and forward movement of the iris created a plugging effect to the full-thickness perforation in the center of the central depression.

While no additional topical medications were recommended, in the setting of no toxic or traumatic etiology with data not demonstrating a central dense infiltrate indicating infectious etiology, vascular testing was suggested to rule out asymmetric vascular disease and vascular insufficiency on the ipsilateral side.

## Your Diagnosis

What would be your diagnosis in this case based on the presentation? To find out, read the online version of this article at [www.reviewofoptometry.com](http://www.reviewofoptometry.com). ■




She presented with this appearance and reports of significant pain. What might be the cause?

### About Dr. Gurwood

Dr. Gurwood is a professor of clinical sciences at The Eye Institute of the Pennsylvania College of Optometry at Salus University. He is a co-chief of Primary Care Suite 3. He is attending medical staff in the department of ophthalmology at Albert Einstein Medical Center, Philadelphia. He has no financial interests to disclose.

**Retina Quiz Answers (from page 88)—Q1: d, Q2: d, Q3: d, Q4: b, Q5: c**

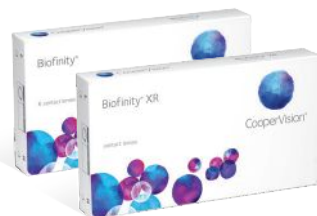

Looking to bring even more patients into  
the incredible comfort of Biofinity®?<sup>1</sup>

# YOU'RE GOLDEN

Biofinity® and Biofinity® XR together offer sphere powers from +15.00D to -20.00D; 1.5x greater than some other monthly replacement spherical silicone hydrogel lenses.<sup>2</sup> With Biofinity® contact lenses, you can provide vision correction for 99.9% of spherical prescriptions.<sup>3</sup> And these lenses are now available at an equal price and with equal patient rebates across the full range, providing greater support across the full range of sphere powers. With Biofinity®, you're golden.

EXPLORE A  
GOLDEN  
OPPORTUNITY



Biofinity®  
sphere | XR



CooperVision®

1. CVI Data on file, 2022. Based on global product sales and internal estimates of products using Aquaform® Technology over 12 months in 2022.

2. CVI data on file, 2023. US market data. Products are Ultra Sphere and Acuvue Vita sphere. December 2023.

3. CVI data on file, 2020. Rx coverage database; 14 to 70 years; Rx with <0.75DC.

OFFER YOUR PRESBYOPIC PATIENTS  
**SEAMLESS VISION<sup>1</sup> WITH A  
 LENS THAT FEELS LIKE NOTHING,  
 EVEN AT DAY 30<sup>2</sup>**




**96%**  
 FIT SUCCESS<sup>1,3,4\*</sup>

Recommend TOTAL30<sup>®</sup> Multifocal contact lenses for  
**TOTAL comfort<sup>2</sup> and seamless vision near through far<sup>1</sup>**




**#1 Selling Multifocal Lens Design**

In the U.S.<sup>5\*\*</sup> with Proven Fit Success<sup>13,4\*</sup>



**Water Gradient**

Nearly 100% water at the outermost surface, so all that touches the eye is a gentle cushion of moisture.



**Blue-Violet Light Filtering<sup>6,7†</sup> and UV Blocking<sup>6,7†</sup>**

**Total30<sup>®</sup> Multifocal** contact lenses filter 34% of blue-violet light rays (BVL) while blocking more than 90% of UVA and 99% of UVB rays.


\*With two lenses or less per eye, at the initial fitting visit.

\*\*Internal estimates based on internal and third-party data.

†There is no demonstrated clinical benefit to a 34% reduction in visible light at wavelengths below 450 nm.

††UV absorbing contact lenses are NOT substitutes for protective UV absorbing eyewear, such as UV absorbing goggles or sunglasses because they do not completely cover the eye and surrounding area. The patient should continue to use UV absorbing eyewear as directed.

**References:** **1.** Alcon data on file, 2022. **2.** In a clinical study wherein patients used CLEAR CARE<sup>®</sup> solution for nightly cleaning, disinfecting, and storing; Alcon data on file, 2021. **3.** Merchea M, Evans D, Kannarr S, Miller J, Kaplan M, Nixon L. Assessing a modified fitting approach for improved multifocal contact lens fitting success. Paper presented at Optometry's Meeting, the 121st Congress of the American Optometric Association; June 20-24, 2018; Denver, CO. **4.** Bauman E, Lemp J, Kern J. Material effect on multifocal contact lens fitting of lenses of the same optical design with the same fitting guide. Poster presented at: British Contact Lens Association Clinical Conference & Exhibition; June 9-11, 2017; Liverpool, UK. **5.** Alcon data on file, 2023. **6.** ISO 18369-2:2017 Ophthalmic optics - Contact lenses Part 2: Tolerances. **7.** ANSI Z80.20-2016 ophthalmic contact lens UV transmittance.

See product instructions for complete wear, care and safety information. 

©2023 Alcon Inc. US-T3M-2300064

Scan to learn more



**Alcon**