


SUPPLEMENT TO

APRIL 2013

REVIEW[®] OF OPTOMETRY

www.revoptom.com



RETINAL DISEASE

The 10th Annual Guide to • The 10th Annual Guide to

Contemporary Testing Procedures for AMD

By Amanda S. Legge, OD

Earn 1 CE Credit: Imaging Techniques and Therapeutic Strategies for Geographic Atrophy

*By Carolyn Majcher, OD, FAAO, and
Andrew S. Gurwood, OD, FAAO, Dipl.*

Two Cases of VMT, Two Different Management Approaches

*By Steven Ferrucci, OD, FAAO, and
Julia Coulter, OD*





JETREA™

(ocriplasmin)

Intravitreal Injection, 2.5 mg/mL

NOW AVAILABLE

**VISIT JETREACARE.COM
FOR REIMBURSEMENT AND
ORDERING INFORMATION**

©2013 ThromboGenics, Inc. All rights reserved.
ThromboGenics, Inc., 101 Wood Avenue South, Suite 610, Iselin, NJ 08830 - USA

JETREA and the JETREA logo are trademarks or registered trademarks of ThromboGenics NV in the United States, European Union, Japan, and other countries.

THROMBOGENICS and the THROMBOGENICS logo are trademarks or registered trademarks of ThromboGenics NV in the United States, European Union, Japan, and other countries.

 **ThromboGenics®**

03/13 OCRVMA0068 JA1

Contemporary Testing Procedures for AMD

By Amanda S. Legge, OD

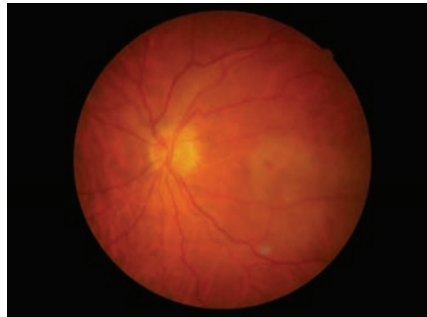
AGE-RELATED MACULAR DEGENERATION (AMD) is the leading cause of blindness in Americans aged 65 and older. During the last two decades, extensive research has led to significant advancements in both the diagnosis and management of this visually devastating condition.

The accepted standards of care for the detection and evaluation of AMD are fundus photography, optical coherence tomography (OCT) and fluorescein angiography (FA). But newer diagnostic modalities that complement and enhance AMD management are now commercially available, including macular pigment optical density (MPOD) scoring, genetic testing, fundus autofluorescence (FAF) imaging, multispectral imaging (MSI) and macular microperimetry. Here, we'll review the use of these advanced technologies in clinical practice.

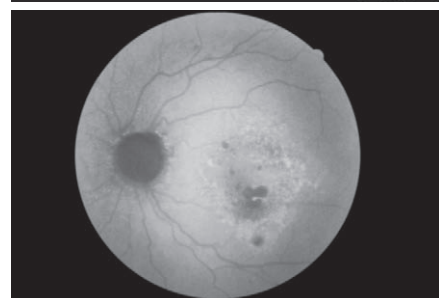
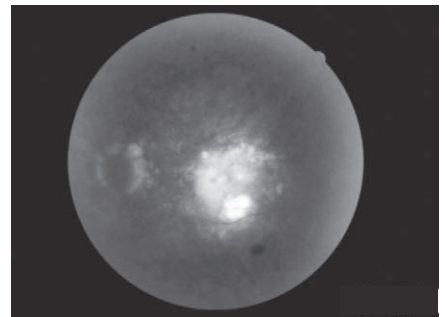
Standards of Care for AMD

Current modalities used to closely follow and monitor AMD progression include fundus photography, OCT and, if neovascularization is suspected, FA.

Imaging the macula over time with fundus photography permits measurement and comparison of structural changes as AMD progresses. An assessment of the rate and risk of progression can be made, based on the change in size, number and type of drusen; retinal pigment epithelium (RPE) hyperpigmentation or migration; presence and size of macular atrophy; and retinal changes as a result of choroidal neovascular membrane (CNVM) formation. Many currently available fundus cameras allow side-by-side comparisons between photographs over time.



Color fundus photograph (above), fluorescein angiography (FA, above right) and fundus autofluorescence (FAF, right) of a RAP lesion in recent-onset neovascular AMD. The area of leakage is seen as hyperfluorescence in the FA and hypoautofluorescence in the FAF; however, the areas correlate well.



Additionally, some cameras include tools within the software to measure the size and borders of lesions, which allows the clinician to document and compare between serial imaging.

The advent and maturation of OCT technology has decreased the frequency of invasive FA to detect subretinal fluid or neovascular membrane—especially when treating with intravitreal anti-VEGF agents. The cross-sectional, semi-histological images obtained via OCT have become invaluable to the management of AMD and other macular diseases over time.

Not only does OCT report qualitative data similar to that generated by FA, it also yields quantitative measurements of macular thickness. If fluid is present, OCT can localize and detect RPE detachments, subretinal fluid, intraretinal fluid, retinal angiomatous proliferation, RPE tears, disciform scars and neovascular membranes.

FA still plays a vital role in the management of macular degeneration—particularly neovascular AMD. It is the modality that is used to categorize CNVM into classic, occult or RAP lesions. This is

an important distinction to make when determining which type of treatment to implement—especially with regard to photodynamic therapy and thermal laser photocoagulation. FA becomes particularly important with initial or off-axis development of CNVM that can be missed with OCT, but when metamorphopsia or a slight visual decrease is noted. Early identification of new leakage and prompt treatment thereafter statistically yields the best visual outcomes for patients.

MPOD Scoring

The macula exhibits one of the highest concentrations of carotenoids in the human body.¹ Dietary carotenoids in the eye, such as lutein, zeaxanthin and meso-zeaxanthin, serve as an optical filter for blue light and help protect the retina from oxidative damage secondary to AMD.

Epidemiologic studies have shown that low plasma concentrations and limited dietary intake of

ADx
Advanced Diagnostic Laboratories National Jewish Health®

MACULA RISK TEST REPORT
AGE-RELATED MACULAR DEGENERATION DNA TEST

Reported to:
 WYOMISSING OPTOMETRIC CENTER
 Attention: CORBIN, GLENN
 50 BERKSHIRE CT
 WYOMISSING, PA 19610
 Fax: 6103740484

Date of Report: 8/8/2012 4:19:12 PM

Patient Name:

Date of Birth: 07/30/1937 **Smoking History:** Quit

Age: 75 **Sex:** Male **Ethnicity:** Caucasian

Collection Date: 08/01/2012 **Specimen Type:** Buccal Swab

Received Date: 08/06/2012 **Accession Number:** M4550

PATIENT TEST RESULTS

OVERALL RESULTS SUMMARY **TOTAL RISK SCORE¹:** 44.6
RISK CATEGORY: 3 **LIFETIME RISK:** 16 - 40% (24.1% median)

¹Your total risk score was calculated using your genotypes for the 8 SNPs listed below and your smoking history. For detailed information on how your risk score was derived please refer to the "Explanation of risk score calculation used in this test" on page 3 - 4.

GENE	SNP ²	GENOTYPE	HAPLOTYPE ³	COMMENT
Complement Factor H (CFH)	rs1048663	GG	H1/H1	This haplotype is associated with high risk for AMD
	rs3766405	CC		
	rs412852	CC		
	rs11582939	CC		
	rs1066420	AA		
Complement Component 3 (C3)	rs2230199	GC	One copy for high risk allele detected	

GENE	SNP ²	GENOTYPE	COMMENT
Age-Related Maculopathy Susceptibility 2 (ARMS2)	NM_001099667.1:C.*372_815del443ins54	Wildtype	Two copies for non risk variant detected
Mitochondrially encoded NADH dehydrogenase 2 (MT-ND2)	rs28357980	A	Low risk allele detected

²SNP (Single nucleotide polymorphism) refers to a common genetic variation that occurs when a single nucleotide, such as an A, replaces one of the other three nucleotide letters (C, G, or T).
³Haplotype refers to SNPs on a single strand of DNA that are inherited together

Science Transforming Life®
T8009-01-0911

1400 Jackson St
Denver, CO 80206
800.550.6227 | NJlabs.org
CLIA ID: 06D0644307

Page 1 of 6

lutein) to the parafovea (an area deficient in carotenoids).⁷

According to documentation from ZeaVision, low MPOD scores range from 0.00 to 0.21, moderate scores range from 0.21 to 0.44 and high scores constitute a measurement of 0.45 or greater.⁵

In patients with low or moderate MPOD scores, consider recommending nutritional supplementation with 6mg to 20mg of lutein and 2mg to 10mg of zeaxanthin per day.⁸ This suggestion should be individually tailored, based on the complete clinical picture of patient's current diet, overall risk of AMD progression and baseline MPOD.

It is best to retest the MPOD six to nine months after supplement initiation.⁹ Once an MPOD score of 0.45 or above is achieved, adjust the dosage of lutein and zeaxanthin as needed for long-term maintenance.^{5,10}

Additionally, be sure to recommend UV- and blue light-filtering lenses to patients who exhibit MPOD scores below 0.45 and/or any additional risk factors for AMD. An increased MPOD also can enhance contrast, decrease glare and improve visual function.⁹

Patients with any risk factors for (or a standing diagnosis of) AMD—including family history, smoking, photophobia or advanced age—should undergo an MPOD evaluation to assess this modifiable risk.

Currently, MPOD testing does not have an associated CPT code and is not billable to insurance. It is often offered as an in-office screening for an out-of-pocket fee ranging between \$35 and \$50 per test. If baseline screening reveals a decreased MPOD and treatment is initiated, the test often is repeated in six months, and then annually or biannually thereafter.

carotenoids are correlated with an increased incidence of AMD.^{2,3} Research also has indicated that cigarette smoking, increased BMI (> 30), poor diet, oxidative stress, fair complexion and advanced age decreases carotenoid concentration in the macula, thus increasing an individual's risk for AMD.⁴

Measuring an individual's MPOD facilitates independent evaluation of this risk factor for AMD. Commercially available diagnostic instruments, including QuantifEye (ZeaVision) and MacuScope

(MacuChek), use heterochromatic flicker photometry to measure pigment density.^{5,6} This psychophysical technique alternates blue and green light of varying intensities and frequencies, which the patient observes as flicker. Blue wavelengths are absorbed by the macular pigment, while green wavelengths are not.

The MPOD score is reported as the blue light absorption ratio of the central fovea (host to the highest concentration of carotenoids, with a 2:1 ratio of zeaxanthin to

Genetic Testing

Several single nucleotide polymorphisms (SNPs) have been associated with the development and progression of AMD. Any combination of risk alleles, along with certain environmental factors (e.g., smoking), influences a patient's overall potential to develop AMD and the likelihood of subsequent progression to geographic atrophy or neovascular AMD. SNPs located within the genes of CFH, C3, C2, CFB, ARMS2, ND2 and LOC, as well as mitochondrial DNA mutation (A4917G), have been implicated in this process.¹¹⁻¹³ Assessment of these particular alleles helps determine the risk of progression to advanced AMD, potential visual impact and long-range management strategies.

Macula Risk (ArcticDx) and RetnaGene (Sequenom) are two current commercially available genetic screening processes for AMD. Macula Risk effectively groups patients into one of five ascending risk categories, based on the presence of genetic markers CFH, C3, ARMS2 and ND2 in addition to smoking history.¹⁴

One study published by Johanna M. Seddon, MD, ScM, and associates in 2009 showed that Macula Risk has an overall predictive value of 83% for determining which patients will progress to visually-disturbing atrophic or exudative AMD.¹⁵

The screening is performed via in-office cheek swab, which is sent directly to the Macula Risk lab for genetic testing. An analytic report is sent back to the requesting office within two to three weeks. The report specifies the patient's risk category and details the results in both patient-friendly and scientific terminology. The results also are accompanied by a recommended

follow-up and testing schedule.

In our office, we call the patient directly and discuss his or her results. During the phone call, we schedule an appropriate follow-up appointment based on our clinical findings and the results of the genetic test. We then mail a copy of the results to the patient for review, and instruct them to write down any further questions for review at the next office exam.

Patients in Macula Risk categories 3, 4 and 5 are considered to be at moderate to high risk for AMD progression.¹⁴ In addition to fundus findings and imaging results, the assigned risk category helps determine how often a patient should be examined to monitor for change. This includes an increased frequency of dilated fundus exams, OCT scans, MPOD screening and fundus photography.

Anyone may elect to undergo genetic testing with Macula Risk. However, insurance covers the procedure only if a patient has a diagnosis code of drusen (362.57 [of any type, including pinpoint or peripheral]) or AMD (362.50, 362.51 or 362.52). Otherwise, the patient is responsible for the fee of approximately \$750.¹⁴

This test is performed once; however, if a patient is found to be in a high risk category, it is important to educate his or her immediate family members about the potential risk in their genetic make-up and recommend the screening as appropriate.

Fundus Autofluorescence

A relatively new and non-invasive imaging modality for AMD is fundus autofluorescence. Unlike other imaging techniques, FAF permits interpretation of retinal pigment epithelium pathophysiology in AMD. Because the RPE plays a

significant role in the development and advancement of AMD, understanding its metabolic health is imperative to managing disease progression.

When stimulated with blue light in the range of 488nm on FAF imaging, the resultant yellow fluorescence is caused by the presence of lipofuscin—a membrane-bound cellular waste product. Lipofuscin is a retinal fluorophore that ultimately accumulates in RPE lysosomes during phagocytosis of photoreceptor outer segments. This physiology allows indirect interpretation of the RPE's metabolic activity.¹⁶

Autofluorescence imaging can be obtained in two ways: cSLO systems and filter-based cameras. Technologies that employ cSLO, such as Daytona (Optos), HRA2 (Heidelberg) and RcSLO (Rodentstock), capture retinal autofluorescence with a low-energy laser that excites lipofuscin. Filter-based FAF cameras, such as Canon CX-1 (OptiMed) and TRC-50DX (Topcon), use a wideband exciter filter with high-energy white flash. The sensor in these systems views only the lipofuscin activity that passes through the filter.

FAF imaging of a disease-free retina yields a uniform, granular, slightly hyperfluorescent signal. This is due to the levels of lipofuscin present in RPE lysosomes during normal phagocytosis and metabolism. The optic nerve and blood vessels appear black due to signal blockage. The central fovea is also dark due to the presence of pigment in the central macula.

Photoreceptor cell loss results in decreased autofluorescence secondary to diminished or non-existent metabolic demand on the RPE. Moreover, decreased autofluorescence is indicative of

dead or dying retinal tissue as well as a correspondingly poor visual prognosis in that location. Hypoautofluorescence also is seen in any retinal pathology that blocks the normal signal, such as dense/hard drusen, new hemorrhage and exudation.

An increase in autofluorescence is due to rapid photoreceptor turnover or an abnormality in the phagosomal uptake of lipofuscin. Therefore, such an increase denotes compromised RPE and active retinal disease.¹⁷ Other causes of increased autofluorescence include fluorophores that are not within the RPE lysosomes, optic nerve head drusen, astrocytic hamartomas, chronic hemorrhage or deposition in exudative retinopathies, such as Best disease or Stargardt macular dystrophy.^{18,19}

FAF has potential applications in detecting macular changes present in advancing AMD, which can aid prognosis and treatment. Studies have shown specific patterns in both choroidal neovascularization (CNV) and geographic atrophy (GA). On FAF, classic CNV is represented as focal darkening in an area of confirmed retinal thickening—likely due to the position of CNV and blockage of natural autofluorescence. An increase in autofluorescence may be noted inferior to the precise location of leakage, illustrating a gravitational pooling of lipofuscin. These findings are inconsistent for recent-onset, small-area, occult CNV or retinal angiomatous proliferative lesions.²⁰ If CNV is suspected, fluorescein angiography remains the gold standard for detecting leakage and determining disease severity.

Currently, FAF imaging in AMD is most helpful for documenting the development and progression of GA. Imaging of GA reveals a

markedly decreased (black) signal with sharp borders. In some cases, a border of hyperautofluorescence is seen around the GA lesion, indicating lipofuscin-rich RPE. This is a strong indicator of potential GA progression. In fact, hyperautofluorescent borders of GA are a better predictor of dry AMD advancement than the size of baseline atrophy, smoking, age or family history.²¹ The exact borders of GA are more easily identified by FAF than by color funduscopy, yielding a more accurate assessment of the extent and anticipated progression of atrophy.

Funduscopy and standard fundus photography provide information about the macula's anatomy and structure, while FAF shows metabolic activity. Because of this, it is assumed that the clinical picture and FAF photography represent independent measures of age-related macular changes, which should be interpreted in isolation then compared and contrasted. Unexpected findings often are seen on FAF that cannot be visualized using conventional techniques.

Patients at any stage of AMD should be photographed using color and FAF modalities (although both techniques are billed as 92250). No additional CPT code exists solely for FAF imaging at this time. Most AMD patients are examined several times per year, and some medical insurances allow fundus photography to be billed only twice per year. Considering that you cannot bill for both screenings if performed the same day, it would be wise to perform color photography at one visit and autofluorescence at the next.

Multispectral Imaging

MSI is a noninvasive technique that permits individual assess-

ment of the retinal layers and choroid for structural changes, based on their absorption spectra. Monochromatic LED wavelengths ranging from 450nm to 800nm dissect the retina and choroid into spectral slices.²² This allows a gradual, microscopic examination of different tissue depths. The en face progressive imaging technique of MSI enhances the localization, and therefore interpretation, of retinal pathologies—which is especially important when accessing multiple variations of AMD.

MSI takes advantage of five light-absorbing molecules in the eye, including retinal hemoglobins, choroidal hemoglobins, choroidal melanin, RPE melanin and macular pigment.²³ Each of these chromophores absorbs a different wavelength of light, and thus can be imaged separately. Generally, longer wavelengths—including those beyond the human visible spectrum—image deeper elements of the posterior segment. Compiling these pixels renders a topographical map appearance of each retinal layer—from the inner limiting membrane through the choroid.

When evaluating macular degeneration, MSI allows a detailed analysis of the RPE and choroid without interference from the anterior retinal structures. It's important to note that MSI can directly visualize RPE structural changes. In early AMD, the RPE undergoes subtle changes that are only anatomically imaged through an MSI modality. Focal hyperpigmentation seen in long-wavelength spectral slices on MSI can be the earliest sign of clinical AMD.²⁴ The opportunity to educate, counsel and begin treatment can be initiated much earlier in the disease process, potentially preventing sight-threatening consequences of delayed intervention.

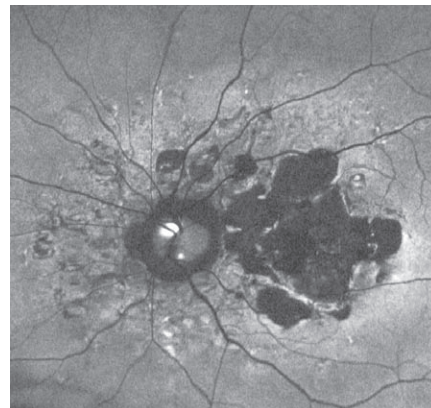
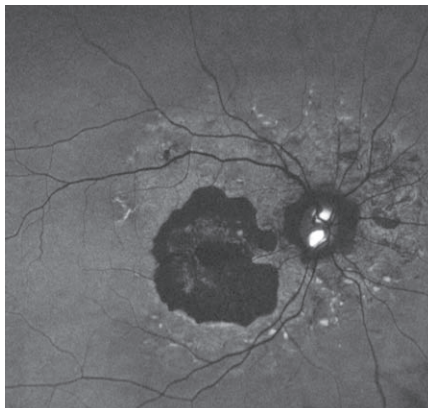Once AMD is apparent, MSI can identify subtle progression that standard methods cannot. Clear evidence of GA can be seen with green-to long red-wavelength scans, which can localize the atrophy to the anterior or posterior retina and/or RPE. These observed differences can be used to track AMD progression on a microscopic level.

In addition to tracking GA, Annidis Health System's RHA multispectral imaging device specifically offers a perfusion map feature that can identify exudative retinopathy. Perfusion mapping examines oxygenated vs. deoxygenated hemoglobin to assess change in retinal vasculature. Specific to AMD, this feature can identify choroidal neovascular membranes noninvasively.

In the normal eye, retinal arteries appear brighter (hypersaturated) compared to veins because of their oxygenation level. The choriocapillaris also may be evaluated with this technique, which has been described as virtual indocyanine green imaging. If leakage is present from a neovascular membrane, the area would appear hypersaturated. The hypersaturation in perfusion mapping of AMD tends to agree with late-phase fluorescein angiography leakage, which is indicative of an active choroidal neovascular membrane.

MSI can be used to evaluate any stage of AMD. In early disease phases, unexpected RPE structural alterations may be found that cannot be viewed with other modalities, including funduscopy. Further, MSI can distinguish overlapping or occult disease and can evaluate retinal vasculature abnormalities.

Similar to FAF, no unique CPT code is assigned to MSI. It is therefore billed as fundus photography (92250). Consequently, color photographs, FAF or MSI cannot be performed and billed to medical



FAF images of a patient with bilateral geographic atrophy (OD left, OS right). Additionally, this individual exhibits disc drusen and angiod streaks.

insurance on the same day. MSI can be offered as a proactive screening technique, which is not covered by insurance. In this event, the patient pays an out-of-pocket cost typically ranging from \$39 to \$59.

Microperimetry

Macular microperimetry is a specific test of retinal function that correlates sensitivity abnormalities to a precise fundus location.²⁵ This is a unique advantage over other macular functional tests, such as conventional visual field testing, color vision, visual acuity, contrast sensitivity function, electroretinogram or electrooculogram. By correlating function to structure, early change can be identified and confirmed with other imaging techniques. This is similar to the structure/function relationship of OCT or disc photos/24-2 visual field testing in glaucoma, where the results are compared in order to make a definitive diagnosis of disease onset or progression.

Similar to glaucoma visual field testing, microperimetry is a static psychophysical method used to measure retinal sensitivity. The patient fixates on a central target and presses a button when a stimulus is perceived. The instrument then

calculates the threshold for each macular locale. In a patient with advanced AMD, the central target can be modified to be larger, thicker or a different shape to aid in fixation. Most microperimetry instruments are able to perform testing and imaging without dilation. This includes OCT SLO (Optos), MP1 (Nidek) and MAIA (Haag-Streit).

Microperimetry can be used to evaluate many maculopathies, as well as any phase of AMD. In early AMD, microperimetry can detect localized functional changes for atrophy or neovascularization. By comparing functional changes to a specific retinal locale, OCT, FAF or MSI can confirm structural initiation or progression of retinal disturbance. It also has the ability to track progression over time by determining what changes are statistically significant and not an inherent variation.

Because the systems monitor which retinal points are being tested through imaging, the same locus is tested with each follow up—even if fixation changes between tests.²⁶ This becomes especially important when testing advanced AMD with eccentric fixation, which can vary between stimuli.

In addition to monitoring for

progression in advanced stages of AMD, microperimetry has several other clinical uses. It can detect fixation stability and location—whether central or extrafoveal. It can also quantify scotomas, monitor scotoma progression, and measure the therapeutic impact of laser or intravitreal injection. Some studies have shown improvement in microperimetry results, but not in visual acuity, after treatment. This allows clinicians to evaluate otherwise undetected functional vision improvement.²⁷ Such information can help guide low vision therapy decisions.

Although limited at this time, a few studies have correlated microperimetry with other AMD imaging modalities.^{26,28} Stable, central fixation and normal values on microperimetry correlate with preservation of the outer retinal signal and an intact photoreceptor integrity line on OCT. Studies are now also connecting FAF changes with functional decline.²⁸ Loss of foveal autofluorescence is associated with a higher rate of unstable fixation and abnormal microperimetry results. Patients with GA are shown to have reduced sensitivity along the borders of the scotoma, which closely correlates with areas of hyperautofluorescence on FAF. This is another indication of likely GA progression. As retinal function continues to decline, hypoautofluorescence becomes evident while extension of the scotoma occurs.²⁶

Similar to glaucoma, functional decline frequently is evident on microperimetry before structural damage is seen. Thus, microperimetry can be an important adjunct in the monitoring and treatment of early to moderate AMD. In later disease stages, microperimetry results can impact the role of low vision rehabilitation and eccentric fixation counseling.

Microperimetry can be billed with CPT codes for visual field testing (92081, 92082 and 92083). The most appropriate code is determined by the complexity of the exam. In most instances, 92083 will be used for a full microperimetry evaluation, because it is a threshold test that uses multiple stimuli to determine the numerical threshold for each locale tested. Any AMD diagnosis code (362.50, 362.51, 362.52) or drusen code (362.57) can be used for billing. Typically, this is an annual test. But, if changes are noted or new neovascularization is present, it can be performed up to four times per year.

The prevalence of AMD is growing in the United States. Additionally, visual function is becoming more important in the daily activities of the elderly as society and technology evolve co-dependently. These are driving factors to detect and manage AMD at the earliest detectable signs.

The five novel diagnostic procedures highlighted above have dramatically advanced our understanding of AMD's pathophysiology when used in conjunction with current standards of care. An accurate assessment of associated genetic risk factors, metabolic changes, localized structural disturbances and specific macular functionality gives the eye care practitioner an arsenal of tools to preserve vision with early preventative care. ■

Dr. Legge is in private practice at Wyomissing Optometric Center in Pennsylvania. She has no direct financial interest in any of the products mentioned.

1. Khachik F, de Moura FF, Zhao DY, et al. Transformations of selected carotenoids in plasma, liver, and ocular tissues of humans and in nonprimate animal models. *Invest Ophthalmol Vis Sci.* 2002 Nov;43(11):3383-92.
2. Snodderly DM. Evidence for protection against age-related macular degeneration by carotenoids and antioxidant vitamins. *Am J Clin Nutr.* 1995 Dec;62(6 Suppl):1448S-61S.

3. Mares-Perlman JA, Fisher AI, Klein R, et al. Lutein and zeaxanthin in the diet and serum and their relation to age-related maculopathy in the third national health and nutrition examination survey. *Am J Epidemiol* 2001 Mar 1;153(5):424-32.
4. Hammond BR, Wooten BR, Snodderly DM. Cigarette smoking and retinal carotenoids: Implications for age-related macular degeneration. *Vis Res.* 1996 Sept;36(18):3003-9.
5. ZeaVision, LLC. ZeaVisions QuantifEYE Program: First of its kind for assessing risk of developing age-related macular degeneration (AMD). Available at: www.zeavision.com (Accessed March 14, 2013).
6. MacuScope. Macular Pigment. Available at: www.macuscope.com/macscope.php. Accessed March 14, 2013.
7. Wooten BR, Hammond BR Jr, Land RI, Snodderly DM. A practical method for measuring macular pigment optical density. *Invest Ophthalmol Vis Sci* 1999 Oct;40(11):2481-89.
8. van der Veen RL, Berendschot TT, Makridaki M, et al. Correspondence between retinal reflectometry and a flicker-based technique in the measurement of macular pigment spectral profiles. *J Biomed Opt.* 2009 Nov-Dec;14(6):064046.
9. Bernstein PS, Delori FC, Richey S, et al. The value of measurement of macular carotenoid pigment optical densities and distributions in age-related macular degeneration and other retinal disorders. *Vision Res.* 2010 Mar 31;50(7):716-28.
10. Landrum JT, Bone RA, Kilburn MD. The macular pigment: a possible role in protection from age related macular degeneration. *Adv Pharmacol.* 1997;38:537-56.
11. Klein RJ. Complement factor H polymorphism in age-related macular degeneration. *Science.* 2005 Apr 15;308(5720):385-9.
12. Kanda A, Chen W, Othman M, et al. A variant of mitochondrial protein LOC387715/ARMS2, not HTRA1, is strongly associated with macular degeneration. *Proc Natl Acad Sci U S A.* 2007 Oct 9;104(41):16227-32.
13. Francis PJ, Hamon SC, Ott J, et al. Polymorphisms in C2, CFB, and C3 are associated with progression to advanced age-related macular degeneration associated with vision loss. *J Med Genet.* 2009 May;46(5):300-7.
14. Macula Risk. Primer on genetics. Available at: www.macularisk.com/genetics-of-amd/primer-on-genetics. Accessed March 18, 2013.
15. Seddon JM, Reynolds R, Maller J, et al. Prediction model for prevalence and incidence of advanced age-related macular degeneration based on genetic, demographic and environmental values. *Invest Ophthalmol Vis Sci.* 2009, May;50(5):2044-53.
16. Wing GL, Blanchard GC, Weiler JJ. The topography and age relationship of lipofuscin concentration in the retinal pigment epithelium. *Invest Ophthalmol Vis Sci.* 1978 Jul;17(7):601-7.
17. von Rückmann A, Fitzke FW, Bird AC. Distribution of fundus autofluorescence with a scanning laser ophthalmoscope. *Br J Ophthalmol.* 1995 May;79(5):407-12.
18. Eldred GE, Katz ML. Fluorophores of the human retinal pigment epithelium: separation and spectral characterization. *Exp Eye Res.* 1988 Jul;47(1):71-86.
19. Rufino S, Bاندello F, Cunha-Vaz JG. AMD Book. Available at: www.amdbook.org/content/amd-book. Accessed March 18, 2013.
20. McBain VA, Townend J, Lois N. Fundus autofluorescence in exudative age-related macular degeneration. *Br J Ophthalmol.* 2007 Apr;91(4):491-6.
21. Holz FG, Bindewald-Wittich A. Progression of geographic atrophy and impact of fundus autofluorescence patterns in age-related macular degeneration. *Am J Ophthalmol.* 2007 Mar;143(3):463-72.
22. Anidid Health Systems. The Technology. Available at: www.anidid.com/?q=technology. Accessed March 18, 2013.
23. Everdell NL, Styles IB, Calcagni A, et al. Multispectral imaging of the ocular fundus using LED illumination. *Rev Sci Instrum.* 2010 Sep;81(9):093706.
24. Bone RA, Brenner B, Gilbert JC. Macular pigment, photopigments, and melanin: Distributions in young subjects determined by four-wavelength reflectometry. *Vision Res.* 2007 Dec;47(26):3259-68.
25. Nidek Technologies. MP1 Microperimeter. Available at: www.nidektechnologies.it/ProductsMP1All.htm. Accessed March 18, 2013.
26. Meleth AD, Mettu P, Agrón E, et al. Changes in sensitivity in geographic atrophy progression as measured by microperimetry. *Invest Ophthalmol Vis Sci.* 2011 Feb 28;52(2):1119-26.
27. Crossland MD, Culham LE, Kabanarou SA, Rubin GS. Preferred retinal locus development in patients with macular disease. *Ophthalmology.* 2005 Sep;112(9):1579-85.
28. Mathew R, Pearce E, Sivaprasad S. Determinants of fixation in eyes with neovascular age related macular degeneration treated with intravitreal ranibizumab. *Am J Ophthalmol.* 2012 Mar;153(3):490-496.e1.

Imaging Techniques and Therapeutic Strategies for Geographic Atrophy

By Carolyn Majcher, OD, FAAO, and Andrew S. Gurwood, OD, FAAO, Dipl.



Release Date

April 2013

Expiration Date

April 1, 2016

Goal Statement

The pathogenesis of geographic atrophy is complex and multifactorial. Recent advancements in retinal imaging technology have indicated that FAF and OCT have useful roles in both diagnosing and monitoring GA. New pharmaceutical treatments hold considerable promise and provide hope to those affected by this visually devastating condition.

Faculty/Editorial Board

Carolyn Majcher, OD, and
Andrew S. Gurwood, OD

Credit Statement

This course is COPE-approved for 1 hour of CE credit. COPE ID is 37494-LV. Please check your state licensing board to see if this approval counts toward your CE requirement for relicensure. There is a \$20 fee to take this course.

Joint Sponsorship Statement

This continuing education course is joint-sponsored by the Pennsylvania College of Optometry.

Disclosure Statement

Drs. Majcher and Gurwood have no financial relationships to disclose.

AGE-RELATED MACULAR DEGENERATION (AMD) is one of the most common causes of visual disability in Americans over age 60.^{1,3} The disease is characterized by retinal pigment epithelium (RPE) degeneration and photoreceptor (PR) dysfunction in the setting of drusen formation at the level of Bruch's membrane. In more advanced stages, AMD may lead to geographic atrophy (GA) and choroidal neovascularization (CNV). When located on the visual axis, GA has the potential to severely affect visual function.

AMD is the leading cause of severe vision loss and legal blindness in developed countries.^{1,2} Late-stage disease was estimated to affect more than 1.75 million individuals in the United States in the year 2000.³ In cases of advanced, late-stage disease, approximately one-third of patients exhibit GA, while the remaining two-thirds develop CNV.^{1,3} The prevalence of GA increases markedly with advanced age.³ One report published in 2000 indicated that just 0.15% of the US population younger than age 40 exhibited GA, compared to 6.89% of those aged 80 years or more.³ In another report, 22% of individuals over age 90 were estimated to have GA.^{4,5} Further, researchers from the Beaver Dam Eye Study noted that the development of GA was four times more likely than CNV in individuals over age 84.^{1,6}

By the year 2020, it is estimated that 2.95 million Americans will have either GA or CNV secondary to late-stage AMD.³

Geographic Atrophy

GA is characterized by single or multiple well-demarcated patches of partially or completely depigmented RPE in the presence of adjacent choriocapillaris and PR

loss.^{1,7-9} Clinically, GA appears as hypopigmented, circular patches of decreased retinal thickness, through which the choroidal vasculature is visible.^{7,8,10}

Although GA is most commonly associated with AMD, several other ocular diseases may cause similar deterioration. These conditions include adult-onset foveomacular vitelliform dystrophy, pattern dystrophy, choroideremia, central areolar choroidal sclerosis, degenerative myopia and Zermatt's macular dystrophy.¹⁰⁻¹² GA also may occur in conjunction with neovascular AMD or the involution of a CNV membrane, as a consequence of RPE tears, as a complication of photodynamic therapy and as a sequellae of CNV photocoagulation.¹⁰

In all the aforementioned instances, the pathological advancement to GA may induce additional visual deterioration.¹

Signs and Symptoms of GA

The principal symptoms of patients with GA range from metamorphopsia and visual distortion to acuity loss and visual disability.⁷ GA is responsible for approximately 20% of all cases of legal blindness secondary to advanced AMD.¹⁰ Patients with GA often report slow and indolent vision loss, while visual compromise caused by CNV typically occurs more suddenly.^{7,10,13}

Almost half of eyes affected by GA demonstrate vision acuity (VA) worse than 20/200.^{10,14} While the median VA tends to decrease as the total atrophy area increases, a wide range of acuity levels have been found for comparable lesions—depending upon whether the fovea is involved.⁴ Unfortunately, VA measurements often overestimate practical visual function, because the

fovea is frequently spared until the end-stages of disease.^{1,15} Half of eyes with a VA greater than or equal to 20/50 exhibit reduced reading rates (less than 100 words per minute).¹⁶ Paracentral GA seems to be associated with very little change in VA until the fovea is affected.¹⁵ In general, however, changes in VA are a poor indication of GA progression—particularly in patients who exhibit early foveal involvement or significant VA impairment at the time of diagnosis.¹⁵

Associated vision loss occurs gradually over a period of years, as the area of GA progressively advances.⁷ AREDS researchers found that VA decreased by an average of 22 letters within five years following diagnosis.⁷

Similarly, another research group found that patients with a VA better than 20/50 had a 41% risk of a doubling of the visual angle during the two years following diagnosis.⁴ Alarming, this risk increased to 70% within four years after initial diagnosis.⁴ Further, this research showed that GA located within 250 μ m of the foveal center increased the risk of a doubling of the visual angle by almost seven times.⁴ Other statistically significant risk factors for a doubling of the visual angle included low foveal dark-adapted sensitivity, scotoma located within 1° of fixation (as measured by scanning laser ophthalmoscopy) and reduced reading rates.¹⁶

Patients affected by GA demonstrate reduced contrast sensitivity and reading speed as well as dense

scotomas that generally correspond with the spatial extent of the atrophic areas.^{1,7,10,15,17} Maximum reading rates are highly correlated with the size of the atrophy in patients with moderate to severe vision loss.^{15,18} Multiple studies have uncovered delayed rod and cone dark adaptation times, resulting in a significant VA decrease in low-lighting conditions.^{1,7,10,16,19}

Natural Course

In cases of AMD, GA formation typically occurs in areas of pre-existing drusen.^{9,10,20,21} Eyes with very large drusen (greater than 250 μ m in diameter), pigmentary alterations, delayed choroidal vascular filling as visualized via fluorescein angiography (FA), and a total area of drusen greater than 0.2 disc areas are also at high risk for GA development.^{9,10,22}

GA typically originates from multiple, small parafoveal lesions that progressively enlarge and coalesce to form a horseshoe- or ring-shaped lesion surrounding the fovea.⁹ Small islands of viable retina usually are present centrally for several years before the lesion completely encroaches upon the foveola.^{7,10,23} Less commonly, GA may begin centrally within the fovea or adjacent to the foveola.^{7,9} Eyes with foveal-involved GA are more likely to have a larger, single lesion as opposed to multifocal, parafoveal lesions.^{7,9}

A recent prospective study evaluating the natural history of bilateral GA found that nearly 70% of eyes had multifocal patches of GA, with a mean number of five lesions

per eye.⁹ Eyes with multifocal GA are more likely to experience an enlargement in the GA area, have the atrophy progress into the foveal center, and subsequently experience a resultant visual decrease.²⁴

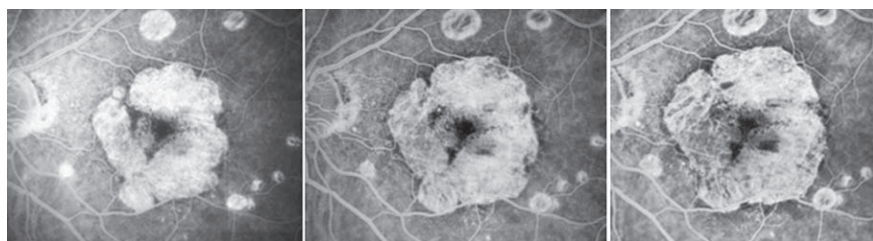
While the enlargement rates of GA vary from person to person, studies have shown that both eyes tend to progress symmetrically.^{9,15} More than half of GA eyes exhibit an enlargement rate ranging between 1.8mm² per year and 5.3mm² per year.⁴ AREDS researchers, for example, reported an enlargement rate of 1.78mm² per year in 181 patients who presented with an median initial lesion size of 4.3mm².⁷

In a separate study of 212 eyes from 131 GA patients conducted by Janet Sunness, MD, and associates, the mean area of expansion rate was 2.6mm² per year—with a larger median initial lesion size of about 8.3mm².¹⁵

They also found a high correlation between the initial two-year enlargement rate and the rate of the subsequent enlargement, with a mean difference of just -0.3mm² per year.¹⁵ Enlargement rates in patients with GA in one eye and drusen alone in the fellow eye generally are slower than enlargement rates in patients with bilateral GA.^{4,15} This difference may be caused by a discrepancy in baseline GA area, such that patients with bilateral GA tend to have larger lesions.¹⁵

Enlargement rates between patients with GA in one eye and CNV in the fellow eye and those with bilateral GA do not seem to differ significantly.^{4,15} Furthermore, similar enlargement rates have been found in eyes with GA that subsequently develop CNV, and eyes with GA that remain atrophic.¹⁵

Controversy exists as to whether the enlargement rate of GA is linear, or if it exponentially increases over time as the circumference of the lesion continues to expand.



Fluorescein angiography demonstrates GA progression in a patient with AMD. (Photos: Stephen Sinclair, MD, and Britt Parvus, MD.)

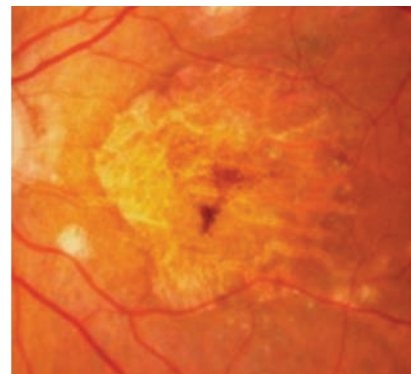
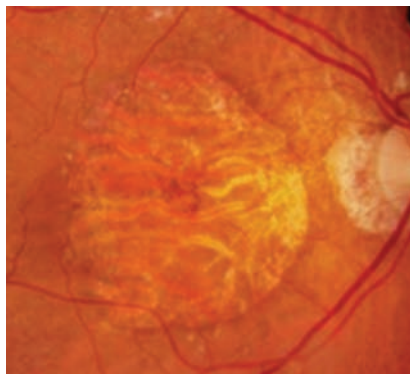
Although several studies have indicated that GA expansion rates are dependent upon the baseline size of the atrophy, it is generally believed that a constant enlargement rate exists and is specific to each individual's eye.^{4,15,25} Some studies agree that the enlargement rate eventually stabilizes between 8mm² per year and 10mm² per year for larger areas of GA.^{4,15}

Approximately 90% of patients with GA have advanced bilateral AMD, with either GA or CNV in the fellow eye.⁴ Seven percent of GA cases are bilateral at the initial presentation.⁷ GA in patients without evidence of CNV becomes bilateral in approximately one-half to two-thirds of cases.^{9,15,23} When GA presents unilaterally, the individual has a median duration of seven years before the fellow eye exhibits its first signs of disease.^{4,7}

A high degree of symmetry has been found in the size/configuration of atrophy, lesion number and enlargement rate when bilateral GA exists.^{4,7,9,10,15} In a recent study of the long-term natural history of GA secondary to AMD in patients with a follow-up time of two years or more, a difference of just 0.6mm² per year or less was observed in the enlargement rates for 58% of patients.¹⁵

Studies evaluating fundus autofluorescence (FAF) imaging in patients with bilateral GA have found a high degree of symmetry not only in the GA lesions, but also in the surrounding areas of retinal tissue throughout the posterior pole.^{9,26} This suggests that metabolic changes of the RPE occur bilaterally in the AMD process.^{9,26}

The risk of developing CNV in an eye with GA is three times greater in patients whose fellow eye has CNV as opposed to atrophy alone.^{1,10} In eyes with bilateral GA, without evidence of CNV, the risk of developing CNV is approximately 10% over a four-year period.^{1,10,27}



Bilateral GA in a patient with AMD. (Photos: Stephen Sinclair, MD, and Britt Parvus, MD.)

On the other hand, when the fellow eye is already affected by neovascular disease, the risk of developing CNV in an eye with GA increases to 34%.^{1,10,27}

When CNV occurs, it often spares the area of GA where the choriocapillaris is absent.^{10,28} Instead, it begins in regions of viable retina surrounding the GA lesion or within a zone of foveal sparing.^{10,27} There are few reports of retinal hemorrhages occurring in cases of GA without angiographic evidence of CNV.^{10,27} Despite these reports, hemorrhages should raise significant suspicion for the presence of CNV until proven otherwise.¹²

Pathophysiology

The pathogenesis of atrophic AMD is multifactorial and includes innate and environmental influences. Several key components include genetic mutation, oxidative damage, lipofuscin accumulation, chronic inflammation, RPE and PR apoptosis and potential choroidal vascular insufficiency.^{10,29,31} Given the symmetry of bilateral GA, as well as inter-individual variation of the disease, genetic mutations likely account for a large portion of the disease processes and pathophysiology.⁹ Defects in several genes have already been identified, including ABCR, which encodes a rod photoreceptor-specific membrane protein, PLEKHA1/LOC387715/

HTRA1, and other genes in the complement pathway (e.g., complement factor H).^{10,29,32,35}

Oxidative damage occurs when reactive oxygen species, such as singlet oxygen and hydrogen peroxide, are created.^{1,29,36} These compounds damage polyunsaturated fatty acids (PUFAs) located in the membrane of PR outer segments.^{1,29,36} The macula is particularly prone to oxidative stress, given its high concentration of PUFAs, significant oxygen consumption and frequent exposure to sunlight.¹ In the disease condition, byproducts of damaged PUFAs (lipofuscin) are ingested by the RPE but cannot be degraded.¹ Progressive accumulation of lipofuscin within RPE cells leads to a reduction in phagosomal activity and possibly even cell death.^{1,37} The major fluorophore of lipofuscin is N-retinylidene-N-retinylethanolamine (A2E), and it is found in high concentrations within the RPE cells of patients suffering from AMD.^{1,29}

Clinical investigators postulate that chronic inflammation exists secondary to these errant processes in compromised eyes.³⁸ This is supported by research that has uncovered the presence of inflammatory cells and/or components of the activated complement cascade within the RPE, Bruch's membrane, choriocapillaris and drusen.^{29,39,40} Without a stable and optimally functioning RPE, the PRs degenerate

and die.¹ One study found markers of apoptosis on rod and RPE cells near the leading border of cases involving GA, revealing a potential role of apoptosis in GA expansion.⁴¹

Many risk factors have been linked to AMD, such as hypertension, increased body mass index, abnormal cholesterol levels and tobacco smoking.^{1,5,42-44} Among these, only smoking is a specific risk factor for GA; smokers show a trend toward more rapid enlargement of GA.^{4,24,43,45} Further, it is essential to note that the incidence of AMD is higher in whites and Asians than blacks.^{1,10,46}

Diagnostic Testing

Traditional retinal imaging methods, such as FA, and newer diagnostic technologies, such as spectral-domain optical coherence tomography (SD-OCT) and FAF, have yielded valuable insight about the pathogenesis of AMD. Studies also have suggested that these instruments provide prognostic information—including anticipated disease progression—on both the AMD and GA processes.^{47,48} Emerging technology with overlay and registration capabilities readily allow comparison between FA, FAF and SD-OCT images to better define GA margins and advancement over time.

• *Fluorescein angiography.*

With FA imaging, areas of GA are characterized by discrete and early hyperfluorescence that occurs during the choroidal filling phase of the angiogram.¹⁰ This specific type of hyperfluorescence is referred to as a transmission or window defect due to the loss of RPE, which permits visualization of the underlying choroidal fluorescence.^{10,49}

While the delineation and quantification of GA is more apparent with FA compared to standard color fundus photography, other areas of hyperfluorescence caused by staining of coexisting drusen or fibrotic CNV may be mistaken

for GA—unless the FA is compared simultaneously with color fundus photography or ophthalmoscopy.⁴⁹ FA remains the test of choice for eyes with GA that are suspected to have CNV.⁴⁹

• *Fundus autofluorescence.*

FAF is a simple, rapid, non-invasive imaging technique that is similar to standard fundus photography.⁵⁰ It detects and illustrates metabolic changes within the PR/RPE complex by exploiting the properties of inherent fluorophores (mainly lipofuscin) within the RPE.⁵⁰⁻⁵² When excited by light in the blue-green spectrum, these naturally existing fluorophores emit light of a longer wavelength—a process known as fluorescence.⁵⁰

No intermediary dyes or added agents are required to produce the phenomenon.⁵⁰ FAF imaging is accomplished by transmitting an exciting light, via a light emission filter, into the eye that is being evaluated. The light that returns to the instrument passes through a barrier filter, which is designed to limit the rays that reach the detector to just the longer autofluoresced wavelengths.⁵⁰ FAF may be accomplished via a confocal scanning laser ophthalmoscope or with fundus cameras that have FAF capabilities.^{50,53}

The normal retina exhibits a background level of autofluorescence that decreases in the macular area due to an increased density of absorbing macular pigments.⁵⁰ The retinal vasculature appears dark secondary to blockage of the background autofluorescence.⁵⁰ Abnormalities are classified as either increased or decreased autofluorescence.

GA appears as an area of decreased autofluorescence due to the absence of RPE and corresponding lipofuscin.^{9,15,54} Like FA, caution must be applied when using FAF alone to delineate and quantify areas of GA, because drusen also may cause decreased autofluores-

cence.^{15,54}

Several studies have shown that patterns of increased autofluorescence predict the development of future GA lesions and subsequent enlargement of pre-existing atrophy.^{15,47,51,55} These findings reinforce the significance of excessive RPE lipofuscin accumulation in the pathogenesis of GA.

While GA may arise from localized areas of increased autofluorescence, one study described several distinct phenotypic FAF patterns that are generally associated with more rapid disease progression.^{47,51} These include:

- *FAF trickling*, which is defined by high-intensity autofluorescence located at the margins of the GA area that exudes out towards the periphery.^{26,47} This pattern is associated with the highest median GA enlargement rate.⁴⁷ GA lesions demonstrating diffuse trickling exhibit a distinct grayish FAF appearance.^{26,47,48} Funduscopically, the retinal borders of GA appear hyperpigmented with corresponding dense, granular hyperpigmentary changes located in the central macula.⁴⁸

- *Increased autofluorescence* that is oriented in a seemingly continuous ring configuration, surrounding the margin of GA.⁴⁷

- *Diffuse patterns of increased autofluorescence* involving not only GA margins, but also other areas throughout the posterior pole.⁴⁷ FAF patterns associated with the slowest rates of GA progression include those without FAF abnormalities (other than anomalies seen within the GA lesion itself) or those with only small, focal spots of increased autofluorescence located directly adjacent to the margin of GA.⁴⁷ Unfortunately, low-risk FAF patterns are estimated to represent just 16% of all cases.⁴⁷

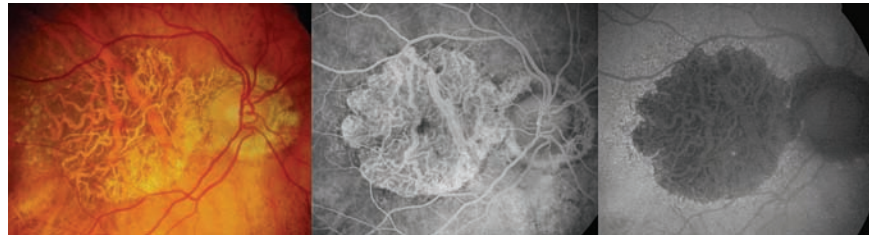
Other studies have found that areas of increased autofluorescence in eyes with GA are associated with impaired PR function and reduced

retinal sensitivity, which has been confirmed with microperimetry testing.^{47,56}

• **Optical coherence tomography.** In 2006, the advent of SD-OCT enabled clinicians to obtain rapid, high-resolution, three-dimensional images of the individual retinal layers.^{57,58} Areas of GA are visualized by SD-OCT as a loss or thinning of the RPE, outer nuclear layer (ONL), inner segment/outer segment junction or photoreceptor integrity line (PIL), and external limiting membrane (ELM).⁵⁹ The loss of the hyper-reflective outer retinal layers allows light to penetrate deeper beyond the RPE, resulting in increased choroidal transmission.⁵⁹

One study evaluated simultaneous FAF and SD-OCT imaging in eyes with GA.⁵⁹ The researchers observed that areas of increased autofluorescence at the margins of GA were associated with alterations of the outer retinal layers in more than 90% of cases.⁵⁹ These alterations included thickening at the RPE and loss of the ELM.⁵⁹ Conversely, smooth GA margins without RPE irregularities on OCT were correlated with normal autofluorescence signals.⁵⁹ The researchers concluded that the outer retinal alterations seen on the located at the junction zone between normal and atrophic retina likely anatomically corresponded to excessive lipofuscin accumulation and RPE hypertrophy.^{23,59}

Another study using SD-OCT demonstrated splitting of the RPE/Bruch's membrane complex at the border of GA area in eyes with the rapidly progressing, "diffuse trickling" FAF phenotype.⁴⁸ The authors speculated that the RPE/Bruch's membrane splitting was secondary basal laminar deposits that had accumulated between the plasma and basement membranes of the RPE.⁴⁸ Moreover, they hypothesized that the basal laminar deposits had the potential to promote rapid GA



Color fundus photography, fluorescein angiography and fundus autofluorescence in a patient with GA. (Photos: Stephen Sinclair, MD, and Britt Parvus, MD.)

advancement by detaching the RPE and PRs from the choroidal blood supply, thus further compromising their metabolic functions.^{48,60}

Finally, one additional study indicated that PR and ONL loss typically bridges across or is located entirely within the GA's margins.⁶¹ Because PR survival is dependent upon supportive RPE functions, the researchers believed that the probable initiating event in early GA is RPE loss, followed shortly thereafter by PR death.^{23,41,61} Further, this study suggests that any portions of the RPE located just outside the margins of an area compromised by GA remain intact but dysfunctional—resulting in PR loss that frequently extends beyond the GA lesion itself.⁶¹ This may explain the exaggerated visual function loss associated with some lesions.

Therapeutic Strategies

Numerous pharmaceutical agents targeted at reducing and/or eliminating the development and progression of GA currently are under investigation. Given the significant correlation of disease progression in eyes with bilateral GA, the contralateral eye is often chosen as a control for therapy trials.^{1,15}

One challenge has been choosing adequate functional endpoints for clinical trials.¹ This has been difficult, considering the disease's variable pattern of vision loss and poor correlation of structural damage to visual function.¹

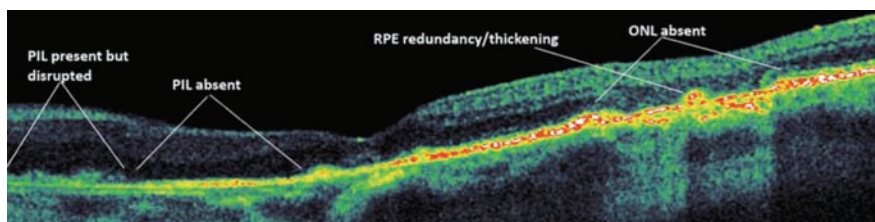
Aside from VA, alternative functional outcomes that may be beneficial include reading speed,

visual field, dark adaptation and subjective visual function survey.¹ The pharmaceutical agents being investigated for the treatment of GA can be divided into five different categories of varying therapeutic strategies: antioxidants, neuroprotective agents, anti-inflammatory medications, PR byproduct accumulation reducers and visual cycle inhibitors.^{1,29,62}

• **Antioxidants.** The Age-Related Eye Disease Study (AREDS) was a multi-center, randomized trial sponsored by the National Eye Institute that investigated the benefit of nutritional supplementation with vitamins C and E, beta-carotene, zinc and copper in 3,640 individuals with AMD.^{7,63} The researchers determined that while the AREDS formula reduced the risk of advanced AMD in patients with category 3 or 4 disease (extensive intermediate-sized drusen, at least one large druse, non-central GA and/or advanced AMD), nutritional supplementation did not significantly reduce the likelihood of GA progression.^{7,63}

When comparing the mean growth of GA over a three-year period, only a nominally significant reduction was documented in the antioxidants plus zinc group compared to the placebo group (5.05mm² with antioxidants and zinc vs. 5.98mm² with placebo).⁷

The Age-Related Eye Disease Study II (AREDS II) is another multi-center, randomized trial sponsored by the National Eye Institute. The project began in 2008 and has since enrolled 4,000 patients.^{1,62,64,65}



OCT image of GA demonstrates disruption and absence of the photoreceptor integrity line, loss of the outer nuclear layer (ONL) and areas of retinal pigment epithelium redundancy/thickening within and lining the GA lesion. Increased choroidal transmission can be seen in the area of ONL loss. (Photos: Stephen Sinclair, MD, and Britt Parvus, MD.)

The purpose of AREDS II is to evaluate the role of lutein and zeaxanthin and/or long-chain omega-3 fatty acids on the progression of AMD.^{1,64,65} Phase III clinical trial results are anticipated shortly.²⁹

• **Neuroprotective agents.**

Neuroprotective agents may be used to prevent or delay PR and RPE apoptosis.¹ Three pharmaceutical agents being evaluated in this capacity: Renexus (formerly NT-501, Neurotech Pharmaceuticals), a sustained release intravitreal implant containing brimonidine tartrate (Allergan) and topical tandospirone (AL-8309B, Alcon).^{1,29,62,66-69}

Renexus is a genetically engineered RPE agent that permits use of the naturally occurring ciliary neurotrophic factor (CNTF), a neuroprotective cytokine produced by the retina and RPE that inhibits PR apoptosis and increases the ONL thickness.^{1,29,62,70} Using encapsulated cell technology, this sustained-release CNTF intravitreal implant already has been studied in patients with retinitis pigmentosa during a Phase I trial.^{1,29,62,71} The implanted capsule contains genetically modified RPE cells that secrete CNTF at an increased rate.^{1,29}

A Phase II multicenter, randomized and double-masked study already has been completed that evaluated the benefit of Renexus in patients suffering from GA secondary to AMD.^{29,62,66,67} Although no decrease in GA progression was documented at one year, a trend toward VA stabilization existed—particularly in eyes with good

baseline acuity.^{62,67} Furthermore, the patients exhibited a dose-dependent, statistically significant increase in OCT retinal thickness.^{29,62,67}

Brimonidine tartrate is an alpha-2 adrenergic receptor agonist that is well known for widespread topical use in the treatment of glaucoma.⁶² Neuroprotective effects have been demonstrated in animal models of ischemia-induced injury, optic nerve compression or optic nerve crush injury, PR degeneration, and ocular hypertension and glaucoma.^{29,62,72}

Currently, Allergan is conducting a Phase II trial investigating the use of a sustained released brimonidine tartrate intravitreal implant in patients with bilateral GA.^{29,62,68} This sustained release implant has a similar design to Ozurdex (dexamethasone). Results of this study have yet to be released.⁶²

The use of the selective serotonin 1A agonist tandospirone as a potential treatment for GA recently surfaced following the release of data that highlighted its neuroprotective benefit in an animal model of excitotoxic neuronal damage.^{29,62,73} A randomized, multi-center, placebo-controlled Phase III trial (the Geographic Atrophy Treatment Evaluation [GATE]) was recently completed.⁶⁹ GATE researchers evaluated the use of topical tandospirone in patients suffering from GA secondary to AMD.^{29,62,69} Results should be published within the year.

• **Anti-inflammatory agents.**

Anti-inflammatory agents being investigated for the treatment of GA can be divided into two main groups: glucocorticoids and

complement inhibitors.^{1,62} The glucocorticoid fluocinolone acetonide (Iluvien, Alimera Sciences) is formulated as an extended release intravitreal implant that is already FDA approved as an investigational new drug for the treatment of posterior noninfectious uveitis.^{62,74} A Phase II clinical trial currently is recruiting patients in an effort to investigate the effect of Iluvien on the GA enlargement rate of 40 patients with bilateral GA.^{29,62,75}

The complement system is comprised of more than 30 components and related proteins.³⁸ It is an essential element of the human immune system.^{38,62} Multiple studies have indicated that drusen contain several complement components, such as C5 and membrane attack complex, suggesting that local inflammation and subsequent complement activation plays a role in AMD pathogenesis.^{38-40,62} In fact, striking compositional similarities have been found between drusen and the deposits associated with Alzheimer's disease and atherosclerosis.³⁸

Two pharmaceutical agents are being studied that inhibit complement components. The first is a humanized monoclonal antibody eculizumab (Soliris, Alexion Pharmaceuticals), which blocks the complement component C5 when administered intravenously.^{1,29,62} A Phase II study evaluating the safety and efficacy of eculizumab for the treatment of dry AMD (Complement Inhibition With Eculizumab for the Treatment of Non-Exudative Macular Degeneration [COMPLETE]) currently is underway at the Bascom Palmer Eye Institute.^{62,76} Primary study outcomes include change in drusen volume and area of GA.⁷⁶

The second agent, POT-4 (Potentia Pharmaceuticals), is designed to target the complement component C3.^{29,62} POT-4 is an intravitreal injection that forms gel-like precipitates within the vitreous, resulting in sustained drug release

over a three- to six-month duration.^{29,62} A completed Phase I trial of 27 patients with neovascular AMD already has established the safety of intravitreal POT-4.^{29,62,77} Further investigations in patients suffering from both neovascular and non-exudative AMD are anticipated to begin within the foreseeable future.⁶²

• **Photoreceptor byproduct accumulation reducers.** Photoreceptor byproduct accumulation reducers are designed to reduce or prevent the accumulation of amyloid beta (A β).⁶² A β has been found in drusen and represents the end product of protein/peptide misfolding.^{29,62,78} Extracellular deposits of A β are potentially toxic to RPE cells, and their persistent nature promotes chronic inflammation.^{29,62,78,79}

Copaxone (glatiramer acetate injection, Teva Pharmaceuticals) currently is FDA approved for the treatment of multiple sclerosis.^{29,62} It reduces A β cytotoxicity by activating/transforming microglial cells and inducing glatiramer acetate-specific suppressor T-cells.^{29,62,80} A Phase I study of 14 eyes with non-exudative AMD treated with subcutaneous glatiramer acetate documented shrinking and elimination of a larger percentage of drusen after 12 weeks compared to those who received sham treatment (19.2% vs. 6.5%).^{29,62,81} The results were statistically significant for shrinking drusen that exhibited low to medium internal reflectivity via SD-OCT imaging.⁸¹

RN6G (Pfizer) is a humanized monoclonal antibody that targets two specific sequences of A β known as A β 40 and A β 42.^{29,62} These compounds have been implicated in the formation of neurodegenerative disease.^{29,62} A Phase I study already has been completed that established the safety of intravenously administered RN6G.^{29,62,82} A Phase II study of patients with GA secondary to AMD is underway.^{29,83}

• **Visual cycle modulators.** The rationale of visual cycle modulators

essentially is to delay the aging process by slowing the phototransduction activity of PRs.⁷⁷ This, in turn, reduces the metabolic stress on RPE cells as well as the accumulation of byproducts (e.g., lipofuscin and A2E).^{29,62}

The most well-known visual cycle inhibitor is fenretinide (4-hydroxy[phenyl]retinamide, Sirion Therapeutics).^{29,62} Fenretinide is a synthetic vitamin A derivative that competitively inhibits the action of retinol-to-retinol binding protein (RBP) in the serum.^{62,84} Ultimately, the level of photosensitive 11-cis-retinal available for incorporation into the visual cycle by PRs becomes reduced, because the RPE requires that all-trans retinol is bound to RBP for uptake.^{62,85} Additionally, fenretinide is thought to possess anti-apoptotic, anti-angiogenic and anti-inflammatory properties, and has been used for several systemic conditions—including rheumatoid arthritis, psoriasis and certain types of cancer.^{62,84}

The results of a Phase II, placebo-controlled, double-masked trial of 246 patients with GA who received oral fenretinide were published in 2012.⁸⁴ The investigators found a decline in the GA enlargement rate, which correlated with reduced serum levels of retinol and RBP.⁸⁴ Additionally, treatment with fenretinide appeared to protect against the development of CNV.⁸⁴ Unfortunately, a well-known side effect of visual cycle modulator use is dark adaptation impairment—which may further hinder visual function in patients with GA.^{29,62,84} A Phase III study is anticipated in the near future.⁶²

Another visual cycle modulator is ACU-4429 (Acucela, Inc.). This oral agent specifically targets the rod visual cycle to reduce lipofuscin and A2E accumulation in the RPE.^{29,62} A Phase II study (ENVISION-CLARITY) evaluated the safety, tolerability and pharmacodynamics of ACU-4429 in subjects with GA

has been completed.^{62,86} The results have yet to be released, however.

Low Vision Therapy

Low vision and visual rehabilitation therapy employs multiple devices and techniques for enhancing functional lifestyles. It remains an essential treatment option for patients with significant visual impairment. Even in the circumstance where a therapeutic agent arrests or slows progression of GA, optical/non-optical devices as well as visual and mobility training will be required to improve day-to-day quality of life. Whether it's spotting at distance, improving acuity at near, improving mobility or refining tracking, low vision services provided by certified and experienced experts should not be overlooked.

GA secondary to AMD has a characteristic bilateral and symmetric presentation. The natural course is somewhat predictable, with the fovea being spared until end-stages of disease. Documented visual acuity loss typically is gradual and significantly underestimates true visual function in these patients. The pathogenesis of GA is complex and multifactorial, involving genetic mutation, oxidative damage, lipofuscin accumulation, chronic inflammation, and RPE and PR apoptosis.^{10,29,31}

A host of recent advancements in retinal imaging technology have indicated that FAF and OCT have useful roles in both diagnosing and monitoring GA. New pharmaceutical treatments hold considerable promise and provide hope to those affected by this visually devastating condition. ■

Dr. Majcher is a senior clinical instructor and externship program director at the Rosenberg School of Optometry University of the Incarnate Word in San Antonio. Dr. Gurwood is a professor of clinical sciences at the Eye Institute of Salus University in Elkins Park, Pa.

1. Biarnés M, Monés J, Alonso J, et al. Update on geographic atrophy in age-related macular degeneration. *Optom Vis Sci.* 2011 Jul;88(7):881-9.
2. Klaver CC, Wolfs RC, Vingerling JR, et al. Age specific prevalence and causes of blindness and visual impairment in an older population: the Rotterdam Study. *Arch Ophthalmol* 1998;116:653-8.
3. Friedman DS, O'Colmain BJ, Muñoz B, et al. Prevalence of age-related macular degeneration in the United States. *Arch Ophthalmol.* 2004 Apr;122(4):564-72.
4. Sunness JS, Gonzalez-Baron J, Applegate CA, et al. Enlargement of atrophy and visual acuity loss in the geographic atrophy form of age-related macular degeneration. *Ophthalmology.* 1999 Sep;106(9):1768-79.
5. Hirvela H, Luukinen H, Laara E, et al. Risk factors of age-related maculopathy in a population 70 years of age or older. *Ophthalmology.* 1996 Jun;103(6):871-7.
6. Klein R, Klein BE, Knudtson MD, et al. Fifteen-year cumulative incidence of age-related macular degeneration: the Beaver Dam Eye Study. *Ophthalmology.* 2007 Feb;114(2):253-62.
7. Lindblad AS, Lloyd PC, Clemons TE, et al. Change in area of geographic atrophy in the age-related eye disease study: AREDS report number 26. *Arch Ophthalmol.* 2009 Sep;127(9):1168-74.
8. Lujan BJ, Rosenfeld PJ, Gregori G, et al. Spectral domain optical coherence tomographic imaging of geographic atrophy. *Ophthalmol Surg Lasers Imaging.* 2009 Mar-Apr;40(2):96-101.
9. Bellmann C, Jorzik J, Spital G, et al. Symmetry of bilateral lesions in geographic atrophy in patients with age-related macular degeneration. *Arch Ophthalmol.* 2002 May;120(5):579-84.
10. Sunness JS. The natural history of geographic atrophy, the advanced atrophic form of age-related macular degeneration. *Mol Vis.* 1999 Nov 3;5:25.
11. Marmor MF, McNamara JA. Pattern dystrophy of the retinal pigment epithelium and geographic atrophy. *Am J Ophthalmol.* 1996 Sep;122(3):382-92.
12. Piguet B, Heon E, Munier FL, et al. Full characterization of the maculopathy associated with an Arg-172-Trp mutation in the RDS/peripherin gene. *Ophthalmic Genet.* 1996 Dec;17(4):175-86.
13. Sunness JS, Bressler NM, Maguire MG. Scanning laser ophthalmoscopic analysis of the pattern of visual loss in age-related geographic atrophy of the macula. *Am J Ophthalmol.* 1995 Feb;119(2):143-51.
14. Klein R, Wang Q, Klein BE, et al. The relationship of age-related maculopathy, cataract, and glaucoma to visual acuity. *Invest Ophthalmol Vis Sci.* 1995 Jan;36(1):182-91.
15. Sunness JS, Margalit E, Srikanmaran D, et al. The long-term natural history of geographic atrophy from age-related macular degeneration: enlargement of atrophy and implications for interventional clinical trials. *Ophthalmology.* 2007 Feb;114(2):271-7.
16. Sunness JS, Rubin GS, Applegate CA, et al. Visual function abnormalities and prognosis in eyes with age-related geographic atrophy of the macula and good visual acuity. *Ophthalmology.* 1997 Oct;104(10):1677-91.
17. Sunness JS, Schuchard RA, Shen N, et al. Landmark-driven fundus perimetry using the scanning laser ophthalmoscope. *Invest Ophthalmol Vis Sci.* 1995 Aug;36(9):1863-74.
18. Sunness JS, Applegate CA, Haselwood D, et al. Fixation patterns and reading rates in eyes with central scotomas from advanced atrophic age-related macular degeneration and Stargardt disease. *Ophthalmology.* 1996 Sep;103(9):1458-66.
19. Brown B, Tobin C, Roche N, et al. Cone adaptation in age-related maculopathy. *Am J Optom Physiol Opt.* 1986 Jun;63(6):450-4.
20. Schatz H, McDonald HR. Atrophic macular degeneration. Rate of spread of geographic atrophy and visual loss. *Ophthalmology.* 1989 Oct;96(10):1541-51.
21. van Leeuwen R, Klaver CC, Vingerling JR, et al. The risk and natural course of age-related maculopathy: follow-up at 6 1/2 years in the Rotterdam study. *Arch Ophthalmol.* 2003 Apr;121(4):519-26.
22. Klein R, Klein BE, Jensen SC, et al. The five-year incidence and progression of age-related maculopathy: the Beaver Dam Eye Study. *Ophthalmology.* 1997 Jun;104(11):77-21.
23. Sarks JP, Sarks SH, Killingsworth MC. Evolution of geographic atrophy of the retinal pigment epithelium. *Eye (Lond).* 1994;8 (Pt 3):269-83.
24. Klein R, Meuer SM, Knudtson MD, et al. The epidemiology of progression of pure geographic atrophy: the Beaver Dam Eye Study. *Am J Ophthalmol.* 2008 Nov;146(5):692-9.
25. Dreyhaupt J, Mansmann U, Pritsch M, et al. Modelling the natural history of geographic atrophy in patients with age-related macular degeneration. *Ophthalmic Epidemiol.* 2005 Dec;12(6):353-62.
26. Bindewald A, Schmitz-Valckenberg S, Jorzik JJ, et al. Classification of abnormal fundus autofluorescence patterns in the junctional zone of geographic atrophy in patients with age related macular degeneration. *Br J Ophthalmol.* 2005 Jul;89(7):874-8.
27. Sunness JS, Gonzalez-Baron J, Bressler NM, et al. The development of choroidal neovascularization in eyes with the geographic atrophy form of age-related macular degeneration. *Ophthalmology.* 1999 May;106(5):910-9.
28. Green WR, Key SN 3rd. Senile macular degeneration: a histopathologic study. *Trans Am Ophthalmol Soc.* 1977;75:180-254.
29. Zarbin MA, Rosenfeld PJ. Pathway-based therapies for age-related macular degeneration: an integrated survey of emerging treatment alternatives. *Retina.* 2010 Oct;30(9):1350-67.
30. Holz FG, Pauleikhoff D, Klein R, Bird AC. Pathogenesis of lesions in late age-related macular disease. *Am J Ophthalmol.* 2004 Mar;137(3):504-10.
31. Friedman E, Krusky S, Lane AM, et al. Ocular blood flow velocity in age-related macular degeneration. *Ophthalmology.* 1995 Apr;102(4):640-6.
32. Allikmets R, Shroyer NF, Singh N, et al. Mutation of the Stargardt disease gene (ABCR) in age-related macular degeneration. *Science.* 1997 Sep 19;277(5333):1805-7.
33. Allikmets R, Wasserman WW, Hutchinson A, et al. Organization of the ABCR gene: analysis of promoter and splice junction sequences. *Gene.* 1998 Jul 17;215(1):111-22.
34. Antoniak K, Bienias W, Nowak JZ. Age-related macular degeneration—a complex genetic disease. *Klin Oczna.* 2008;110(4-6):211-8.
35. Klein RJ, Zeiss C, Chew EY, et al. Complement factor H polymorphism in age-related macular degeneration. *Science.* 2005 Apr 15;308(5720):385-9.
36. Kennedy CJ, Rakoczy PE. Lipofuscin of the retinal pigment epithelium: a review. *Eye (Lond).* 1995;9 (Pt 6):763-71.
37. Zarbin MA. Current concepts in the pathogenesis of age-related macular degeneration. *Arch Ophthalmol.* 2004 Apr;122(4):598-614.
38. Anderson DH, Mullins RF, Hageman GS, et al. A role for local inflammation in the formation of drusen in the aging eye. *Am J Ophthalmol.* 2002 Mar;134(3):411-31.
39. Johnson LV, Leitner WP, Staples MK, et al. Complement activation and inflammatory processes in drusen formation and age related macular degeneration. *Exp Eye Res.* 2001 Dec;73(6):887-96.
40. Nozaki M, Raisler BJ, Sakurai E, et al. Drusen complement components C3a and C5a promote choroidal neovascularization. *Proc Natl Acad Sci U S A.* 2006 Feb 14;103(7):2328-33.
41. Dunaief JL, Denteche T, Ying GS, et al. The role of apoptosis in age-related macular degeneration. *Arch Ophthalmol.* 2002 Nov;120(11):1435-42.
42. Thapa R, Paudyal G, Shrestha MK, et al. Age-related macular degeneration in Nepal. *Kathmandu Univ Med J (KUMJ).* 2011 Jul-Sep;9(35):165-9.
43. Smith W, Assink J, Klein R, et al. Risk factors for age-related macular degeneration: Pooled findings from three continents. *Ophthalmology.* 2001 Apr;108(4):697-704.
44. Tian J, Fang K, Qin XY, et al. Case-control study of risk factors in age-related macular degeneration. *Beijing Da Xue Xue Bao.* 2012 Aug 18;44(4):588-93.
45. Tomany SC, Wang JJ, van Leeuwen R, et al. Risk factors for incident age-related macular degeneration: pooled findings from 3 continents. *Ophthalmology.* 2004 Jul;111(7):1280-7.
46. Klein R, Klein BE, Knudtson MD, et al. Prevalence of age-related macular degeneration in 4 racial/ethnic groups in the multi-ethnic study of atherosclerosis. *Ophthalmology.* 2006 Mar;113(3):373-80.
47. Holz FG, Bindewald-Wittich A, Fleckenstein M, et al. Progression of geographic atrophy and impact of fundus autofluorescence patterns in age-related macular degeneration. *Am J Ophthalmol.* 2007 Mar;143(3):463-72.
48. Fleckenstein M, Schmitz-Valckenberg S, Martens C, et al. Fundus autofluorescence and spectral-domain optical coherence tomography characteristics in a rapidly progressing form of geographic atrophy. *Invest Ophthalmol Vis Sci.* 2011 Jun 15;52(6):3761-6.
49. Göbel AP, Fleckenstein M, Schmitz-Valckenberg S, et al. Imaging geographic atrophy in age-related macular degeneration. *Ophthalmologica.* 2011;122(4):182-90.
50. Fleckenstein M, Schmitz-Valckenberg S, Holz FG. Fundus autofluorescence imaging in clinical use. *Rev Ophthalmol.* Available at: www.revoophth.com/content/dm/imaging_and_diagnostic_instruments/c22655/. Accessed March 7, 2013.
51. Holz FG, Bellman C, Staedt S, et al. Fundus autofluorescence and development of geographic atrophy in age-related macular degeneration. *Invest Ophthalmol Vis Sci.* 2001 Apr;42(5):1051-6.
52. Delori FC, Dorey CK, Staurenghi G. In vivo fluorescence of the ocular fundus exhibits retinal pigment epithelium lipofuscin characteristics. *Invest Ophthalmol Vis Sci.* 1995 Mar;36(3):718-29.
53. Bennett T. The ophthalmic photographers' society. Fundus autofluorescence. Available at: www.onpweb.org/?page=Autofluorescence. Accessed January 20, 2013.
54. Sunness JS, Ziegler MD, Applegate CA. Issues in quantifying atrophic macular disease using retinal autofluorescence. *Retina.* 2006 Jul-Aug;26(6):666-72.
55. Schmitz-Valckenberg S, Bindewald-Wittich A, Dolar-Szczyznay J, et al. Correlation between the area of increased autofluorescence surrounding geographic atrophy and disease progression in patients with AMD. *Invest Ophthalmol Vis Sci.* 2006 Jun;47(6):2648-54.
56. Schmitz-Valckenberg S, Büttmann S, Dreyhaupt J. Fundus autofluorescence and fundus perimetry in the junctional zone of geographic atrophy in patients with age-related macular degeneration. *Invest Ophthalmol Vis Sci.* 2004 Dec;45(12):4470-6.
57. Murphy E. The evolution of spectral domain OCT. *Ophthalmology Management; 2008 Jul.* Available at: www.opthalmologymmanagement.com/articleviewer.aspx?articleid=101888. Accessed January 20, 2013.
58. Yehoshua Z, Rosenfeld PJ, Gregori G, et al. Spectral domain optical coherence tomography imaging of dry age-related macular degeneration. *Ophthalmol Surg Lasers Imaging.* 2010 Nov-Dec;41 Suppl:S6-11.
59. Brar M, Kozak K, Cheng L, et al. Correlation between spectral-domain optical coherence tomography and fundus autofluorescence at the margins of geographic atrophy. *Am J Ophthalmol.* 2009 Sep;148(3):439-44.
60. Sarks S, Cherepanoff S, Killingsworth M, et al. Relationship of basal laminar deposit and membranous debris to the clinical presentation of early age-related macular degeneration. *Invest Ophthalmol Vis Sci.* 2007 Mar;48(3):968-77.
61. Bareilly S, Chau FY, Korishi A, et al. Spectral domain optical coherence tomography imaging of geographic atrophy margins. *Ophthalmology.* 2009 Sep;116(9):1762-9.
62. Boyer D. Emerging treatments for dry AMD: A number of early clinical trials are under way. *Retina Today.* 2011 Oct. Available at: <http://bmctoday.net/retinatoday2011/10/article.asp?i=emerging-treatments-for-dry-amd>. Accessed January 20, 2013.
63. Age-Related Eye Disease Study Research Group. A randomized, placebo-controlled, clinical trial of high-dose supplementation with vitamins C and E, beta carotene, and zinc for age-related macular degeneration and vision loss: AREDS report no. 8. *Arch Ophthalmol.* 2001 Oct;119(10):1417-36.
64. The Age-Related Eye Disease Study Group. Age-related eye disease study 2. The lutein/zeaxanthin and omega-3 supplementation trial. Available at: www.areds2.org/. Accessed January 20, 2013.
65. Age-related eye disease study 2 (AREDS 2). *Clinicaltrials.gov.* Available at: <http://clinicaltrials.gov/ct2/show/NCT00345176?term=AREDS2&rank=1>. Accessed January 20, 2013.
66. A study of an encapsulated cell technology (ECT) implant for patients with atrophic macular degeneration. *Clinicaltrials.gov.* Available at: <http://clinicaltrials.gov/ct2/show/NCT00447954?term=CNIF&rank=2>. Accessed January 20, 2013.
67. Zhang K, Hopkins JJ, Heier JS, et al. Ciliary neurotrophic factor delivered by encapsulated cell intraocular implants for treatment of geographic atrophy in age-related macular degeneration. *Proc Natl Acad Sci U S A.* 2011 Apr 12;108(15):6241-5.
68. Safety and efficacy of brimonidine intravitreal implant in patients with geographic atrophy due to age-related macular degeneration (AMD). *Clinicaltrials.gov.* Available at: <http://clinicaltrials.gov/ct2/show/NCT00658619?term=brimonidine&rank=6>. Accessed January 20, 2013.
69. Geographic atrophy treatment evaluation (GATE). *Clinicaltrials.gov.* Available at: <http://clinicaltrials.gov/ct2/show/NCT00890097?term=AL-8309B&rank=1>. Accessed January 20, 2013.
70. Tao W, Wen R, Goddard MB, et al. Encapsulated cellbased delivery of CNTF reduces photoreceptor degeneration in animal models of retinitis pigmentosa. *Invest Ophthalmol Vis Sci.* 2002 Oct;43(10):3292-8.
71. Sieving PA, Caruso RC, Tao W, et al. Ciliary neurotrophic factor (CNTF) for human retinal degeneration: phase I trial of CNTF delivered by encapsulated cell intraocular implants. *Proc Natl Acad Sci U S A.* 2006 Mar 7;103(10):3896-901.
72. Saylor M, McLoon LK, Harrison AR, et al. Experimental and clinical evidence for brimonidine as an optic nerve and retinal neuroprotective agent: an evidence-based review. *Arch Ophthalmol.* 2009 Apr;127(4):402-6.
73. Semkova I, Wolz P, Krieglstein J. Neuroprotective effect of 5-HT1A receptor agonist, Bay X 3702, demonstrated in vitro and in vivo. *Eur J Pharmacol.* 1998 Oct 23;359(2-3):251-60.
74. Psvidia Corp. Focused therapeutics/visionary science. Available at: <http://www.psvida.com/>. Accessed January 20, 2013.
75. Fluocinolone acetonide intravitreal inserts in geographic atrophy. *Clinicaltrials.gov.* Available at: www.clinicaltrials.gov/ct2/show/NCT00695318?term=fluocinolone+acetonide&rank=15. Accessed January 20, 2013.
76. Complement inhibition with eculizumab for the treatment of non-exudative macular degeneration (COMPLETE). *Clinicaltrials.gov.* Available at: <http://clinicaltrials.gov/ct2/show/NCT00935883?term=complete&rank=5>. Accessed January 20, 2013.
77. Safety of intravitreal P0T-4 therapy for patients with neovascular age-related macular degeneration (AMD) (ASA-P). *Clinicaltrials.gov.* Available at: <http://clinicaltrials.gov/ct2/show/NCT00473928>. Accessed January 20, 2013.
78. Johnson LV, Leitner WP, Rivest AJ, et al. The Alzheimer's A beta -peptide is deposited at sites of complement activation in pathologic deposits associated with aging and age-related macular degeneration. *Proc Natl Acad Sci U S A.* 2002 Sep 3;99(18):11830-5.
79. Isaac JM, Luijck V, Johnson LV, et al. Soluble and mature amyloid fibrils in drusen deposits. *Invest Ophthalmol Vis Sci.* 2010 Mar;51(3):1304-10.
80. Copaxone in age related macular degeneration. *Clinicaltrials.gov.* Available at: <http://clinicaltrials.gov/ct2/show/NCT00466076?term=copaxone&rank=10>. Accessed January 20, 2013.
81. Landa G, Rosen RB, Patel A, et al. Qualitative spectral OCT/SLO analysis of drusen change in dry age-related macular degeneration patients treated with Copaxone. *J Ocul Pharmacol Ther.* 2011 Feb;27(1):77-82.
82. Safety and tolerability study of RN6G in patients with dry, age-related macular degeneration. *Clinicaltrials.gov.* Available at: <http://clinicaltrials.gov/ct2/show/NCT00877032?term=RN6G&rank=1>. Accessed January 20, 2013.
83. Efficacy, safety and tolerability study of RN6G in subjects with geographic atrophy secondary to age-related macular degeneration. *Clinicaltrials.gov.* Available at: <http://clinicaltrials.gov/ct2/show/NCT01577381?term=RN6G&rank=1>. Accessed January 20, 2013.
84. Mata NL, Lichter JB, Vogel R, et al. Investigation of oral fenretinide for treatment of geographic atrophy in age-related macular degeneration. *Retina.* 2013 Mar;33(3):498-507.
85. Parker R, Crouch R. The visual cycle: Generation of 11-cis retinal for photoreceptors. Available at: www.photobiology.info/Parker-Crouch.html. Accessed January 20, 2013.
86. Study of the safety, tolerability, pharmacokinetics and pharmacodynamics of ACU-4429 in subjects with geographic atrophy. *Clinicaltrials.gov.* Web site. Available at: www.clinicaltrials.gov/ct2/show/NCT01002950?term=ACU-4429&rank=1. Accessed January 20, 2013.

Questions

1. Which definition best classifies geographic atrophy (GA)?

- Depigmentation of the RPE, with subsequent loss of the adjacent choriocapillaris and photoreceptors.
- Degeneration of the retinal nerve fiber layer.
- A decrease of retinal ganglion cell density.
- An increase in choroidal thickness associated with neovascularization.

2. Which statement is TRUE?

- Vision loss associated with GA usually occurs suddenly.
- GA is responsible for 90% of legal blindness caused by AMD.
- Change in visual acuity usually correlates well with the enlargement of GA.
- GA is associated with decreased contrast sensitivity and visual acuity in dim lighting conditions.

3. Which statement regarding the natural history of GA is FALSE?

- In most cases, the fovea is spared until late stages of the disease.
- When GA is bilateral, enlargement rates are asymmetric.
- Most eyes have multifocal lesions, opposed to a single locus of GA.
- GA enlargement rates are highly correlated with subsequent enlargement rates.

4. All of the following are risk factors for GA development, EXCEPT:

- Drusen greater than 250µm in diameter.
- Retinal pigmentary changes.
- Delayed choroidal vascular filling, as seen on fluorescein angiogram.
- Increased macular pigment density.

5. The risk of developing neovascularization in an eye with GA is _____ times greater in patients whose contralateral eye already has choroidal neovascularization (CNV).

- Zero.
- Three.
- Five.
- Seven.

6. Which finding has been implicated in the pathogenesis of AMD?

- Genetic mutation.
- Oxidative damage.
- Lipofuscin accumulation.
- All of the above.

7. Which statement is FALSE regarding areas of increased fundus autofluorescence located at the margins of GA?

- They frequently are associated with OCT alterations of the outer retinal layers and retinal pigment epithelium (RPE).
- Increased autofluorescence is indicative of the anatomical accumulation of lipofuscin within the RPE.
- They have been shown to predict the development of future GA lesions and subsequent enlargement of pre-existing atrophy.
- Increased autofluorescence suggests that the patient likely will not develop CNV.

8. Risk factors for vision loss in GA include all of the following, EXCEPT:

- Low foveal dark-adapted sensitivity.
- Geographic atrophy located within 250µm of the foveal center.
- Increased reading rates.
- Scotoma located within 1° of fixation.

9. The AREDS II study is investigating the potential benefit of _____ in patients suffering from AMD.

- Lutein.
- Zeaxanthin.
- Long-chain omega-3 fatty acids.
- All of the above.

10. Which agent is a visual cycle modulator that is currently being investigated for the treatment of GA?

- Fluocinolone acetate.
- Fenretinide.
- Brimonidine tartrate.
- OT-551.

Examination Answer Sheet

Valid for credit through April 1, 2016

Imaging Techniques and Therapeutic Strategies for Geographic Atrophy

Directions: Select one answer for each question in the exam and completely darken the appropriate circle. A minimum score of 70% is required to earn credit. There is a \$20 fee to take this course

Mail to: Optometric CE, PO Box 488, Canal Street Station, New York, NY 10013
COPE-approved for 1 hour of CE Credit. COPE ID: 37494-LV.

There is an eight-to-ten week processing time for this exam.

- (A) (B) (C) (D) 11. The goal statement was achieved:
Very Well Adequately Poorly
- (A) (B) (C) (D) 12. The information presented was:
Very Useful Useful Not Very Useful
- (A) (B) (C) (D) 13. The difficulty of the course was:
Complex Appropriate Basic
- (A) (B) (C) (D) 14. Your knowledge of the subject was increased:
Greatly Somewhat Hardly
- (A) (B) (C) (D) 15. The quality of the course was:
Excellent Fair Poor
- (A) (B) (C) (D) How long did it take to complete this course?

- (A) (B) (C) (D) Comments on this course:

- (A) (B) (C) (D) Topics you would like in the future CE articles:

Please retain a copy for your records. Please print clearly.

You must choose and complete one of the following three identifier types:

① SS # _____ - _____ - _____

Last 4 digits of your SS # and date of birth State Code and License #: (Example: NY12345678)

② _____ - _____ ③ _____

First Name _____

Last Name _____

E-Mail _____

The following is your: Home Address Business Address

Business Name _____

Address _____

City _____ State _____

ZIP _____

Telephone # _____ - _____ - _____

Fax # _____ - _____ - _____

By submitting this answer sheet, I certify that I have read the lesson in its entirety and completed the self-assessment exam personally based on the material presented. I have not obtained the answers to this exam by any fraudulent or improper means.

Signature _____ Date _____

Lesson 109012

RO-ARG-0413

Two Cases of VMT, Two Different Management Approaches

By Steven Ferrucci, OD, FAAO, and Julia Coulter, OD

VITREOMACULAR TRACTION (VMT) results when a patient experiences an incomplete posterior vitreous detachment from the macula. The vitreous induces tractional forces on the retinal surface, causing distortion and cystic changes.

In general, a diagnosis of VMT should be considered when a patient presents with a unilateral decrease in visual acuity and metamorphopsia. Often, VMT is undetectable via fundoscopic examination alone. The use of optical coherence tomography (OCT) can, however, illustrate detailed microstructural changes and may help yield a diagnosis.

When choosing a management plan, important factors to consider are the extent of vitreous attachment, as well as the symptom duration and presenting visual acuity. Traditional treatment ranges from close observation to pars plana vitrectomy (PPV) to a new pharmacological agent—ocriplasmin.

Here, we review the work-up and management of two patients who presented with VMT.

Case I

History

A 64-year-old white male presented with complaints of visual distortion in his left eye that had persisted for two weeks. He visited our clinic two months earlier for a comprehensive vision exam. At that time, his visual acuity measured 20/20 OU. No ocular complications were documented.

The patient's ocular history was unremarkable. His medical history was significant for hyperbilirubinemia, hypertension and gout. Current medications included allopurinol and hydrochlorothiazide.

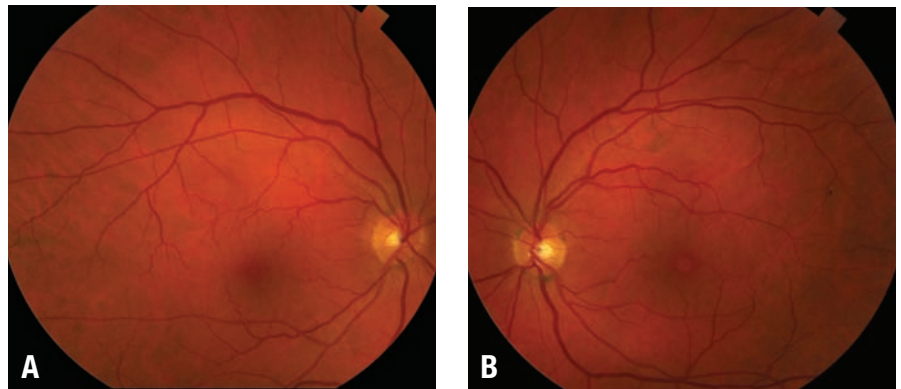


Figure 1. a) Our 64-year-old patient's right macula was healthy. b) But, his left macula showed RPE mottling.

Diagnostic Data

His best-corrected visual acuity was 20/20 OD and 20/40 OS, with no improvement upon pinhole testing. Amsler grid of the right eye uncovered no metamorphopsia or scotomas; however, the left eye exhibited a central area of distortion without scotoma. Anterior segment examination was unremarkable. Intraocular pressure measured 16mm Hg OD and 17mm Hg OS.

An examination of his right eye revealed a healthy peripheral retina, with a flat and avascular macula and a positive foveal reflex. The optic nerve head margin was distinct with pink and healthy rim tissue, and a cup-to-disc ratio of 0.15 x 0.15.

The examination of his left eye showed a healthy retina; however, we noted a blunted foveal reflex as well as retinal pigment epithelium mottling located within the macular region. The optic nerve head margin was distinct with pink and

healthy rim tissue, and a cup-to-disc ratio of 0.20 x 0.20 (figure 1a and 1b).

OCT imaging of the right macula revealed a normal foveal contour. The left macula, however, exhibited an impending posterior vitreous detachment with focal attachment of the posterior hyaloid at the macula as well as a large foveal cyst. Central macular thickness was 196µm OD and 309µm OS (figure 2a and 2b).

Diagnosis and Follow-up

Based on these findings, we diagnosed the patient with VMT syndrome OS. We discussed the findings with him and decided upon a conservative approach of monitoring. We scheduled him for a one-month follow-up examination.

One month later, the patient presented for follow-up reporting only slight visual distortion in his left eye. Best-corrected visual acuity

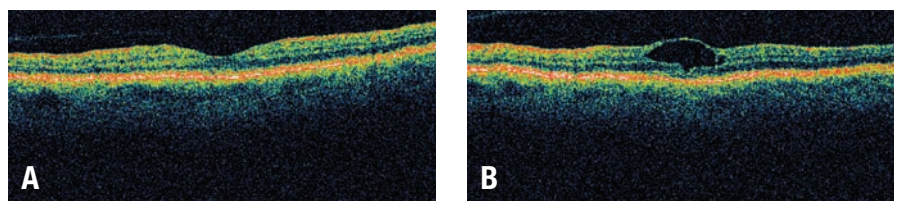
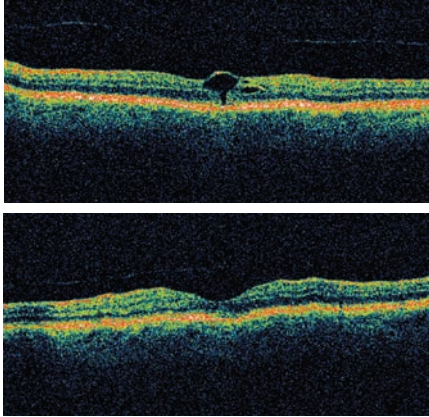


Figure 2. a) OCT scan of the right eye revealed a normal foveal contour and a central macular thickness of 196µm. b) OCT of the left eye showed persistent vitreous attachment at the macula, resulting in cystic changes, macular distortion and a central macular thickness of 309µm.



Figures 3, 4. OCT scan of his left eye at the one-month follow-up shows release of the posterior hyaloid with residual macular thickening of 231µm (top). Normal macular contour with central macular thickness of 202µm was observed in his left eye 10 months after initial presentation (bottom).

now measured 20/30 OS. Macular thickness was unchanged OD, but decreased to 241µm OS. OCT imaging revealed a release of the posterior hyaloid in the left eye (*figure 3*).

We instructed the patient to return for follow-up in three months, or sooner if he noted any visual changes. Nine months later, the patient presented for a comprehensive eye exam and reported no visual distortion in either eye. Visual acuity measured 20/20 OU. Additionally, OCT indicated that his macular thickness had decreased to 202µm OS (*figure 4*).

Case II

History

An 80-year-old white male presented to the eye clinic, complaining of decreased vision in his left eye that had persisted for the last four weeks. His ocular history was significant for mild nonproliferative diabetic retinopathy (NPDR) in both eyes. His medical history was remarkable for type 2 diabetes mellitus, hypertension, hyperlipidemia and stroke. Current medications included acarbose, metformin, carvedilol, furosemide and lisinopril.

Diagnostic Data

His best-corrected visual acuity was 20/40 OD and 20/125 OS, with no improvement upon pinhole testing. (At an examination just five months earlier, his best-corrected visual acuity measured 20/50 OS.) Intraocular pressure measured 18mm Hg OU.

Fundus examination of the right eye revealed moderate scattered microaneurysms (MAs) and blot hemorrhages. The macula was flat and avascular, with a positive foveal reflex. Fundus examination of the left eye also revealed moderate scattered MAs and blot hemorrhages. Assessment of the left macula revealed a large, fluid-filled foveal cyst with an overlying epiretinal membrane (ERM).

The optic nerve head margins were distinct with healthy rim tissue and a cup-to-disc ratio of 0.30 x 0.30 OU. We documented no apparent posterior vitreous detachment OU (*figure 5a and 5b*).

Diagnosis and Follow-up

We diagnosed the patient with mild NPDR, ERM and cystoid macular edema in his left eye that potentially was caused by VMT. We discussed our findings with the patient, and scheduled him for fluorescein angiography (FA) and OCT at one-week follow-up.

One week later, the patient underwent an FA, which was well

tolerated. FA testing of the right eye revealed normal vessel filling with areas of early hyperfluorescence that corresponded to scattered MAs. FA of the left eye revealed normal vessel filling with angiographic macular edema and peripheral ischemia. OCT imaging revealed a normal central macular thickness of 228µm OD and a markedly increased macular thickness of 558µm OS. Additionally, the OCT revealed a vitreal attachment to the left macula (*figure 6a and 6b*). We educated the patient on our findings and instructed to him return for a retinal surgery consultation and possible PPV with membrane peel.

The patient was seen by retinal services and was scheduled for a PPV with membrane peel. PPV was performed without complications approximately four months after he was diagnosed with VMT. However, the surgeon uncovered two unrelated peripheral retinal tears in his left eye, which required laser repair. Postoperative examination revealed a final best-corrected visual acuity of 20/40 OD and 20/150 OS. A subsequent OCT scan revealed a flat left macula with no subretinal fluid. There was, however, an irregular foveal contour that was consistent with post-surgical changes (*figure 7*).

Discussion

VMT syndrome was first described as a complication of

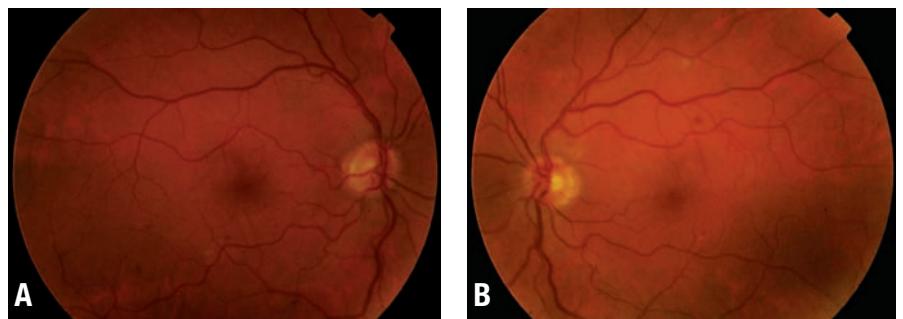


Figure 5. a) An 80-year-old male with mild nonproliferative diabetic retinopathy and normal macular contour of the right eye. b) We noted cystic changes of the left macula, with overlying epiretinal membrane.

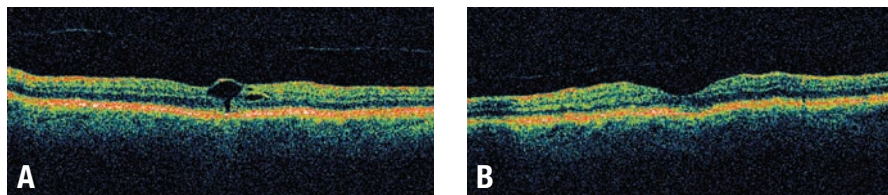


Figure 6. a) OCT image of the right eye revealed a central macular thickness of 228µm. b) OCT of the left eye revealed an epiretinal membrane, a posterior vitreous attachment at the macula causing a large foveal cyst, and a central macular thickness of 558µm.

incomplete posterior vitreous detachment with resulting macular traction by Norman S. Jaffe, MD, in 1967.¹ The presence of VMT was later confirmed by Algernon B. Reese, MD, and associates with histological studies.^{2,3} Today, VMT syndrome is a diagnosis facilitated by the use of OCT.

Due to the nature of VMT, its incidence is not well documented. Further, prior estimations of prevalence likely are inaccurate, because the condition is difficult to visualize on direct fundoscopic examination. However, with the wide use of advanced diagnostic imaging modalities, such as OCT, the diagnosis of VMT likely is more prevalent than previously thought. One study found that with the use of OCT, VMT was detected in 30% (39 of 132) of eyes compared to just 8% of cases detected biomicroscopically.⁴

VMT is more common in older females than males, and has no known racial predilection. Both aphakic and pseudophakic eyes appear to have a lower rate of VMT, due to a greater chance of complete posterior vitreous detachment (PVD) during cataract extraction.^{5,6}

• **Pathophysiology.** PVD is a normal, age-related ocular change—occurring in more than 67% of patients over age 65.⁷ Early in life, there is strong adhesion between the vitreous humor and the retina. Over time, however, this bond weakens. Age-related changes, such

as vitreal liquefaction (synchysis) and shrinkage (syneresis), cause separation and collapse of the vitreous cortex—slowly compromising its adherence to the retinal surface.⁷⁻⁹

The outer section of the vitreous is known as the cortex or posterior hyaloid. It is comprised of densely packed collagen fibrils.⁹ These collagen fibrils are bound to the internal limiting membrane (ILM) of the retina by proteoglycans, including laminin and fibronectin.^{10,11} The adhesion between the ILM and the vitreous cortex is stronger at specific points in the retina. The vitreous cortex is most adherently attached at the vitreous base, followed by major retinal vessels, the optic disc margin and a 500µm-diameter area surrounding the most central part of the macula—the foveola.¹¹⁻¹³

These adhesions pull apart over time, inducing common symptoms of flashes and floaters. Normal detachment of the vitreous results in a complete PVD, where the vitreous is fully detached from the retina all the way to the vitreous base located adjacent to the ora serrata. When anterior detachment occurs, but there is incomplete separation of the posterior hyaloid membrane from the macula, VMT syndrome occurs. The remaining area of attachment has anteroposterior and tangential tractional forces acting upon it. These tractional forces induce structural changes at the macula.¹⁰ It is theorized that the tractional forces induce cell migra-

tion to the vitreoretinal interface, causing an even firmer attachment at these areas.¹⁴

There is a great deal of variability in the extent of vitreal detachment and area of retinal traction. Common forms of vitreal adhesion include: attachment surrounding the macula and the optic nerve head, vitreous detachment temporal to the macula, and thin focal attachment to the macula only.^{8,14,17} The stability of retinal structures, as well as the area of VMT, may determine the manifestation of symptoms and macular changes that ensue. Although the exact mechanism is not fully understood, it appears that the diameter of attachment at the macula may be inversely related to the amount of macular deformity.^{6,15-17}

VMT is associated with a wide variety of maculopathies, such as macular holes, cystoid macular edema, foveal cavitation and epiretinal membranes (ERM).^{6,8,16,18} It also has been proposed that VMT may contribute to the advancement of age-related macular degeneration (AMD) as well as diabetic retinopathy.^{10,16,19,20} Studies have found that a complete PVD occurs less frequently in patients with both exudative AMD as well as nonexudative AMD, compared to those in a healthy, age-matched populations. These results suggest that vitreous adhesion is a risk factor for AMD.^{20,21}

Evidence also shows that there is a higher rate of vitreous adhesion in exudative AMD patients compared to nonexudative AMD, suggesting that VMT may be a significant risk factor in the progression of dry to wet AMD.^{19,21} One such study found that VMT was present in 59% of eyes with exudative AMD compared to just 13% of eyes with nonexudative AMD.²⁰ Similar

results were documented in another study, which indicated that vitreal adhesion occurred in 36% of eyes with exudative AMD compared to just 7% of eyes with nonexudative AMD.¹⁹ In these studies, the location of vitreous adhesion corresponded to the area of choroidal neovascularization, suggesting a possible causal relationship.¹⁹

Whether the relationship between AMD and VMT is pathogenic or merely associative remains unclear. Multiple theories highlight how the condition may play a role in the development of AMD.

- VMT may induce chronic, low-grade inflammation in the macular area.

- VMT may prevent normal oxygen and nutrient supply to the macula.

- VMT may maintain macular exposure to proangiogenic cytokines or free radicals, contributing to neovascularization.^{19,20}

- The inflammation from AMD causes the vitreous to have a tighter adherence to the retina, causing an incomplete PVD and subsequent VMT.^{1,21}

• **Diagnostic strategies.** Patients with vitreomacular traction may present with complaints such as visual decrease, metamorphopsia, photopsia and micropsia. Traditional diagnosis is made with Amsler grid testing, slit lamp biomicroscopy and B-scan ultrasonography. The presence of a subtle traction ridge in the retina is a helpful clinical finding, although the changes often are imperceptible.^{12,22,23} This makes it difficult to determine the cause of such patient complaints upon clinical examination alone.

Currently, however, the diagnosis of VMT is more routinely made with the use of OCT.^{6,16} OCT imaging permits a detailed view of the posterior hyaloid membrane, which is

seen as a thin line located anterior to the retina with persistent adhesion to the macula. As described in the cases discussed above, OCT can show a steeply sloping macular surface with a focal area of persistent vitreous traction pulling at the retinal surface. This creates a cystic space that is illustrated on OCT as an intraretinal hyporeflective area. In other instances, macula scans can show a more diffusely attached area of vitreoretinal traction, creating a wide variety of cystic changes ranging from an isolated cyst to diffuse cystic spaces in the retina.

In the diagnosis of VMT, it is important to consider other pathological processes. One will need to differentiate the cystoid space in the macula that can result from VMT from other causes, such as postoperative Irvine-Gass syndrome or uveitic macular edema. In Irvine-Gass syndrome, for example, there is no adhesion at the vitreoretinal interface. Additionally, the fluorescein pattern will exhibit a characteristic stellate or flower petal pattern—compared to VMT, which demonstrates little to no fluorescein leakage in the macula.^{1,12}

Central serous choroidopathy also may present with monocular metamorphopsia and visual decrease. In this case, fluorescein angiography will show the characteristic smoke-stack appearance, and OCT will reveal no vitreal adhesion to the area of elevated macula.¹

• **Treatment.** Management options of VMT range from a more conservative strategy of observation to a surgical approach of PPV with membrane peel. Additionally, a new pharmacological agent indicated to spontaneously induce PVD received FDA approval in January of 2013—Jetrea (ocriplasmin, Thrombogenics).

When choosing a management

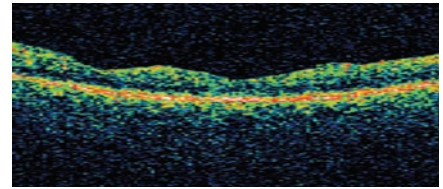


Figure 7. Post-surgical OCT of the left macula shows irregular macular contour.

plan, you must consider the extent of vitreous attachment as well as the duration of symptoms and presenting visual acuity. One study indicated that, if left untreated, eyes with VMT will have a continual and progressive vision loss secondary to cystic macular changes as well as eventual vascular incompetence and leakage.^{8,16,24}

Since the dawn of spectral-domain optical coherence tomography (SD-OCT), however, we now suspect that more cases of VMT spontaneously resolve than previously thought. Earlier studies showed that just 11% of untreated cases of VMT resolved spontaneously.^{16,25} With the use of SD-OCT, however, a more recent study found that 9 of 19 eyes (47%) exhibited complete spontaneous vitreous detachment in the macula area.¹⁸ Both studies show that the rate of spontaneous resolution is greater in eyes with small separate focal area of traction. In cases of VMT where there is an associated ERM, spontaneous detachment is less likely. In these instances, there may be stronger and closer adhesion between the vitreous and the retina—posing a greater risk for continued visual decline. So, it may be most appropriate to consider PPV for these patients.¹⁸

Traditionally, PPV is the standard treatment for persistent, symptomatic VMT. The goal of PPV is to release traction at the macula and restore vision. One study of 24 eyes indicated that 87.5% gained one line of acuity and 54% gained two lines after PPV. Similar results were

documented in a second study of 15 eyes, which showed that 75% improved by two lines or more after PPV.²⁴

Patients who undergo PPV experience a significant, consequent decrease in central macular thickness.^{8,22} The final visual outcome following surgery depends on the amount of preoperative macular damage.^{14,16} Smaller areas of adhesion—specifically at the macula and optic disc—yield a substantially larger gain in postoperative visual acuity than those with a broader attachment. This may be because smaller areas of adhesion tend to have worse preoperative vision with greater macular thickening.⁸ Patients with a longer duration of symptoms and worse preoperative visual acuity tend to have less favorable results.^{8,26} Other changes in retinal structure, such as lamellar separation between inner/outer foveal layers and subretinal fluid, have worse postoperative visual outcome.²²

Complications of PPV include infection, retinal break or detachment, hemorrhage and cataracts. More specifically, multiple study groups have observed nuclear and/or posterior subcapsular cataract progression in as many as 44% to 83% of all postoperative eyes.^{24,26}

Jetrea is a truncated form of the human serine protease plasmin. It is thought to act on fibronectin and laminin—both of which are components of the vitreo-retinal interface, and dissolve the protein matrix responsible for vitreal adhesion.^{10,27,28} Studies have shown that 26.5% of eyes with VMT experienced symptomatic resolution following an 125µg injection of Jetrea compared to 10.1% of eyes that received a sham injection.^{27,28} These reports also indicated that best-corrected visual acuity was

more likely to improve by at least three lines in the treatment population compared to the placebo group.^{27,28}

Side effects of Jetrea injection include vitreous floaters, photopsia, ocular pain, conjunctival hemorrhage and increased IOP.^{27,28} Although its use has not been widely adopted due to its recent approval, Jetrea may be an attractive option for patients and clinicians who prefer a nonsurgical alternative to PPV for VMT resolution. Jetrea injection also may permit intervention at an earlier stage of VMT than PPV, which typically is performed after visual acuity has deteriorated significantly.¹⁰

These two cases of VMT syndrome illustrate two widely different management strategies. In both individuals, the presence of VMT was confirmed by OCT imaging. The structural changes that ensued resulted in divergent visual outcomes. Eye care providers must recognize the clinical benefit of OCT when a patient presents with monocular metamorphopsia, decreased vision and a grossly normal clinical exam.

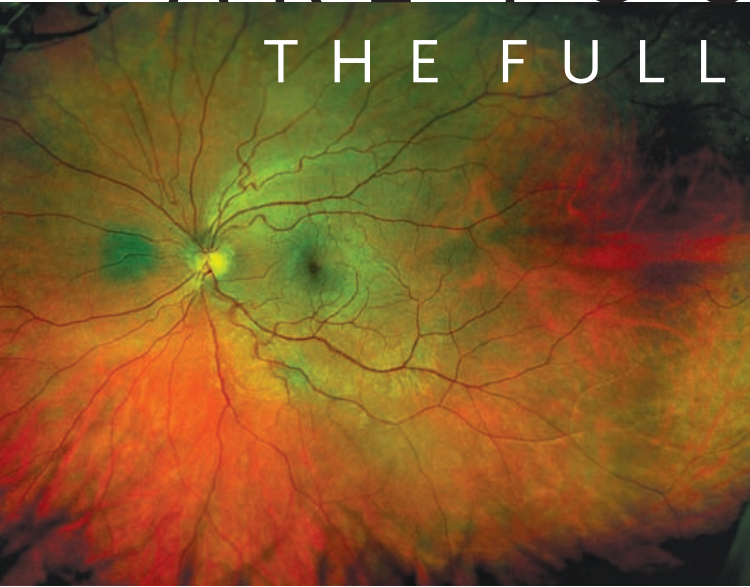Such cases may have been more difficult to definitively diagnose in the past; however, OCT now makes it possible to accurately view the vitreoretinal interface and observe dynamic pathological changes. And, when VMT is detected early, less invasive treatments such as Jetrea may prove to play a more significant role in symptomatic patients than PPV. ■

Dr. Ferrucci is chief of optometry at the Sepulveda VA Ambulatory Care Center and Nursing Home in North Hills, Calif., as well as an associate professor at Southern California College of Optometry. Dr. Coulter currently is completing her residency in

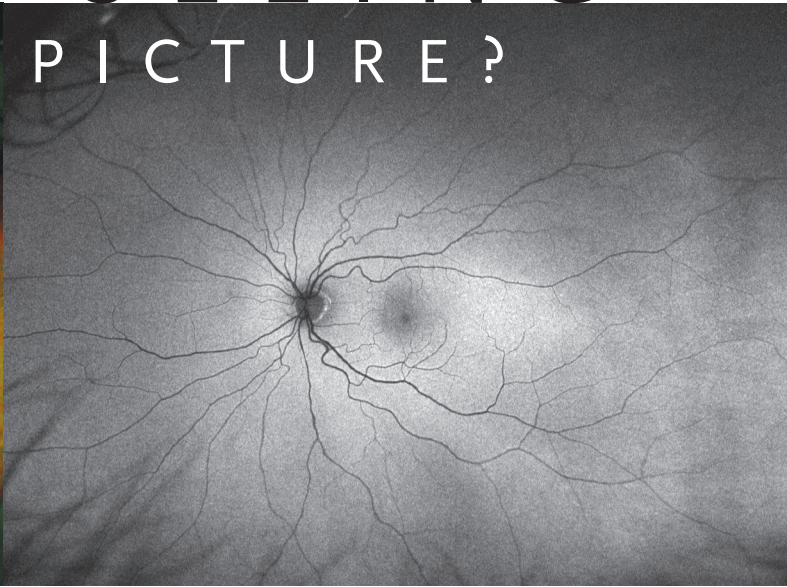
primary care/geriatric optometry at the Sepulveda VA.

- Jaffe NS. Vitreous traction at the posterior pole of the fundus due to alterations in the vitreous posterior. *Trans American Academy Ophthalmology Otol* 1967;642-52.
- Reese AB, Jones IS, Cooper WC. Vitreomacular traction syndrome confirmed histologically. *Am J Ophthalmol*. 1970 Jun;69(6):975-7.
- Reese AB, Jones IS, Cooper WC. Macular changes secondary to vitreous traction. *Am J Ophthalmol*. 1967 Sep;64(3):Suppl:544-9.
- Gallimore RP, Jumper JM, McCuen BW, et al. Diagnosis of vitreoretinal adhesions in macula diseases with optical coherence tomography. *Retina*. 2000;20(2):115-20.
- Smiddy WE, Michels RG, Glaser BM, deBustos S. Vitrectomy for macular traction caused by incomplete vitreous separation. *Arch Ophthalmol*. 1988 May;106(5):624-8.
- Shechtman DL, Dunbar MT. The expanding spectrum of vitreomacular traction. *Optometry*. 2009 Dec;80(12):681-7.
- Foos RY, Wheeler NC. Vitreoretinal juncture. Synchysis senilis and posterior vitreous detachment. *Ophthalmology*. 1982 Dec;89(12):1502-12.
- Sonmez K, Capone A, Trese MT, Williams GA. Vitreomacular traction syndrome: impact of anatomical configuration on anatomical and visual outcomes. *Retina*. 2008 Oct;28(9):1207-14.
- Levin L, Nilsson S, Ver Hoeve J, Wu S. *Adlers Physiology of the Eye*, 11th ed. Amsterdam, Netherlands: Saunders Elsevier; 2011.
- Stalmans P, Benz MS, Gandorfer A, Kampik A, et al. Enzymatic vitreolysis with ocriplasmin for vitreomacular traction and macular holes. *N Engl J Med*. 2012 Aug 16;367(7):606-15.
- Tsui I, Pan CK, Rahimy E, Schwartz SD. Ocriplasmin for vitreoretinal diseases. *J Biomed Biotechnol*. 2012;2012:354979.
- Johnson MW. Tractional cystoid macular edema: A subtle variant of the vitreomacular traction syndrome. *Am J Ophthalmol*. 2005 Aug;140(2):184-92.
- Sebag J. *The Vitreous: Structure, Function and Pathobiology*. New York: Springer-Verlag; 1989:17-58.
- Smiddy WE. Morphology, pathology and surgery of idiopathic vitreoretinal macular disorders. *Retina*. 1990;10(4):288-96.
- Smiddy WE, Green WR, Michels RG, de la Cruz Z. Ultrastructural studies of vitreomacular traction syndrome. *Am J Ophthalmol*. 1989 Feb 15;107(2):177-85.
- Hikichi T, Yoshida A, Trempe C. Course of vitreomacular traction syndrome. *Am J Ophthalmol*. 1995 Jan;119(1):55-61.
- Koizumi H. Three-dimensional evaluation of vitreomacular traction and epiretinal membrane using spectral-domain optical coherence tomography. *Am J Ophthalmol*. 2008 Mar;145(3):509-17.
- Odobina D, Michalewska Z, Michalewski J, et al. Long-term evaluation of vitreomacular traction disorder in spectral-domain optical coherence tomography. *Retina*. 2011 Feb;31(2):324-31.
- Krebs I, Brannath W, Glittenberg C, et al. Posterior vitreomacular adhesion: a potential risk factor for exudative age-related macular degeneration? *Am J Ophthalmol*. 2007 Nov;144(5):741-6.
- Mojana F, Cheng L, Bartsch DU, et al. The role of abnormal vitreomacular adhesion in age-related macular degeneration: spectral optical coherence tomography and surgical results. *Am J Ophthalmol*. 2008 Aug;146(2):218-27.
- Simpson AR, Petrarca R, Jackson TL. Vitreomacular adhesion and neovascular age-related macular degeneration. *Surv Ophthalmol*. 2012 Nov;57(6):498-509.
- Witkin AJ, Patron ME, Castro LC, et al. Anatomic and visual outcomes of vitrectomy for vitreomacular traction syndrome. *Ophthalmic Surg Lasers Imaging*. 2010 Jul-Aug;41(4):425-31.
- Rodriguez A, Infante R, Rodriguez F, Valencia M. Spontaneous separation in idiopathic vitreomacular traction syndrome associated with contralateral full-thickness macular hole. *Eur J Ophthalmol*. 2006 Sep-Oct;16(5):733-40.
- McDonald HR, Johnson RN, Schatz H. Surgical results in the vitreomacular traction syndrome. *Ophthalmology*. 1994 Aug;101(8):1397-402.
- Hung K, Yang C, Lin T, et al. Optical coherence tomography in spontaneous resolution of vitreomacular traction syndrome. *J Chin Med Assoc*. 2010 Jun;73(6):334-7.
- Koerner F. Vitrectomy for macular pucker and vitreomacular traction syndrome. *Doc Ophthalmol*. 1999;97(3-4):449-58.
- De Smet MD, Gandorfer A, Stalmans P, et al. Microplasmin intravitreal administration in patients with vitreomacular traction scheduled for vitrectomy: the MIVI I trial. *Ophthalmology*. 2009 Jul;116(7):1349-55.
- ThromboGenics. Jetrea: Full prescribing information. Available at: <http://jetrea.com/JETREAPrescribingInformation.pdf>. Accessed March 25, 2013.

ARE YOU SEEING THE FULL PICTURE?



optomap® Ultra-Widefield Color Image



optomap® *af* Ultra-Widefield Autofluorescence Image



Daytona

- Up to 200° of the retina in a single capture
- Ultra-high resolution digital images
- Non-mydrriatic, through 2mm pupils
- In less than a second
- Color, red-free, autofluorescence images

For more information

call **800-854-3039**

or email: **BDS@optos.com**

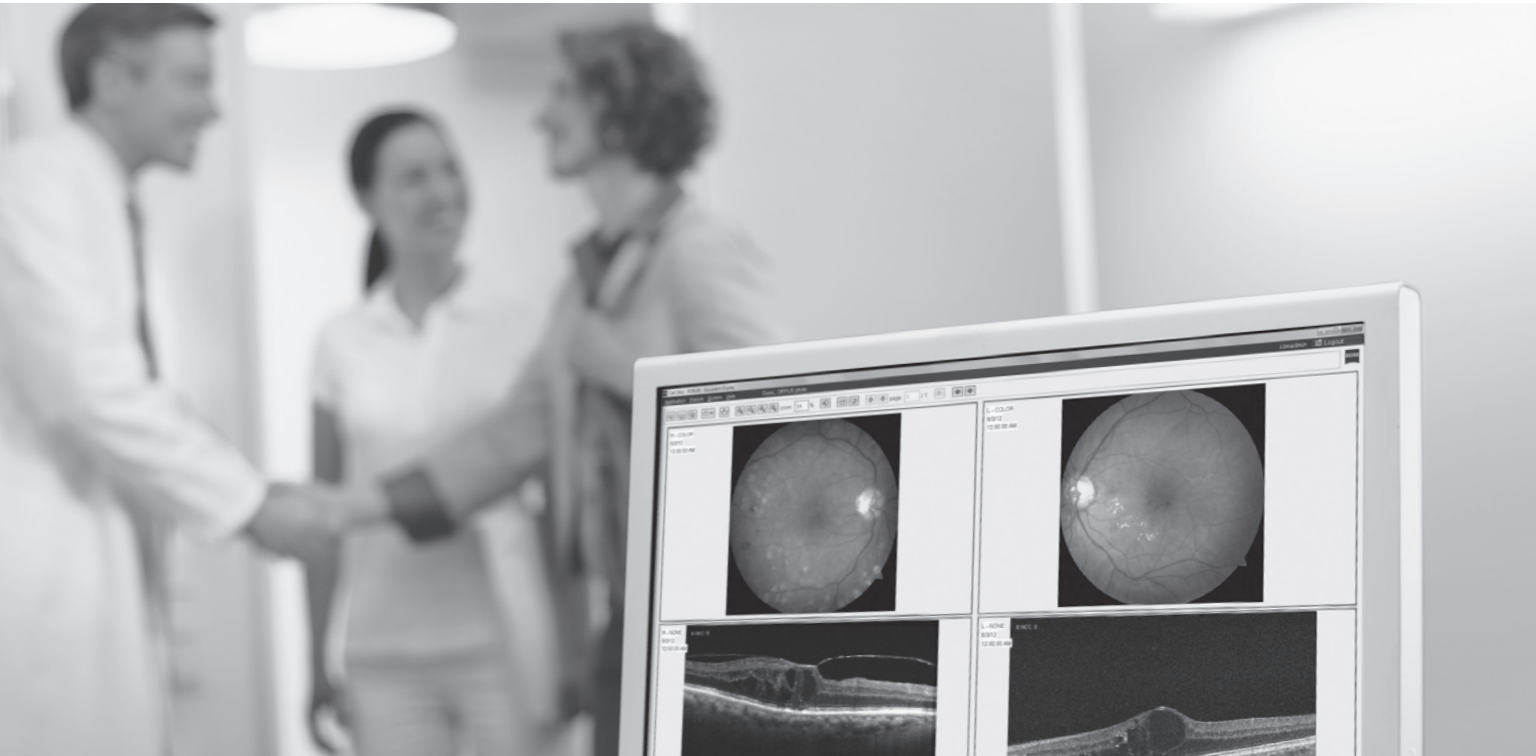Building *The* Retina Company




optos.com

When is fundus imaging
more than fundus imaging?

When it adds the power of CIRRUS OCT



Introducing the NEW CIRRUS™ Photo



CIRRUS™ photo
Models 800 and 600

The Smart Imaging Combo OCT & Fundus Camera

- Full non-mydratric color camera with FAF, FA and ICG options.
- View Fundus and OCT scans on one screen using MultiMode Navigator.
- Efficient cross modality analysis in one compact system.
No need to move your patient.

