Innovations in Retina:

Impressions From a Blue Collar Lunch Pail Optometrist

Mark T. Dunbar, O.D., F.A.A.O.
Bascom Palmer Eye Institute
University of Miami, Miller School of Medicine
Miami, FL

Disclosures

Mark T. Dunbar, OD is on the Advisory Boards for Carl Zeiss Meditec, Allergan, Inspire, and Eye Solutions.

I have received honorarium from some but not all of these companies

I do not own stock in any of the companies/technologies discussed today

Please silence all mobile devices

New Technology Winners

- Imaging
  - SDOCT
  - FAF
  - Annidis
  - Maia
- Disease Management
  - Ocriplasmin
  - Genetics
  - Treatments for Dry AMD

We've Come a Long Way Baby….

Innovations in Imaging

Spectral Domain OCT

Spectral Domain OCT
The Competition

- Carl Zeiss: Cirrus
- OptiVue:
  - RtVue and the iVue
- Heidelberg: Spectralis
- Topcon
- Optos
  - Made by OPKO
- SOCT Copernicus
  - Now owned by Cannon

SD-OCT Differences

- Hardware is relatively similar
  - Tracking capabilities
  - Ancillary image capabilities
- Device should be easy to use and patient friendly
- Should be competitively priced
- It's all about the software!

SD-OCT Differences

- Heidelberg Spectralis still has the best quality images – but not by much
  - Probably not so much that you should pick it vs. other SD-OCT
- Zeiss Cirrus has better software for both retina and glaucoma
  - Comparable image…very good
- Spectralis has FAF capabilities

SD-OCT Differences

- OptiVue is the least expensive with a very good quality SD-OCT
  - Very good glaucoma package
  - 1st to have ganglion cell layer analysis with normative data base
  - iVue is a smaller "portable" SD-OCT at a great price and will do almost everything
    - May not have as good reproducibility

SD-OCT Differences

- Topcon SD-OCT is very good and includes a fundus camera
  - They still don't have a normative data base for glaucoma
- Optos has now entered into the OCT market
  - It is too new to know anything about
  - No normative data base for anything

67 y/o Hispanic Male

Told that he had a retinal problem

VA: 20/25!

High Definition Images: HD 5 Line Raster

OD ● ○ OS

Scan Angle: 0° Spacing: 0.25 mm Length: 6 mm

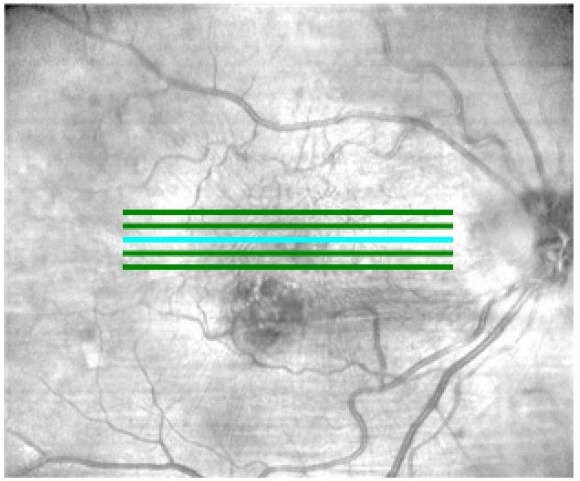

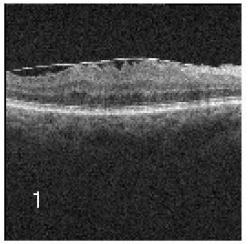

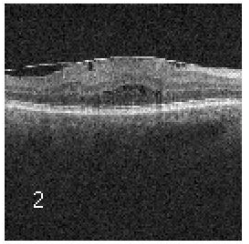

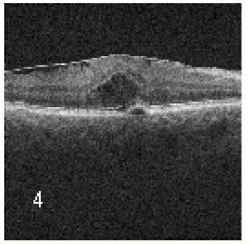

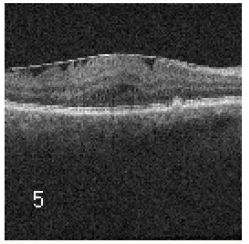

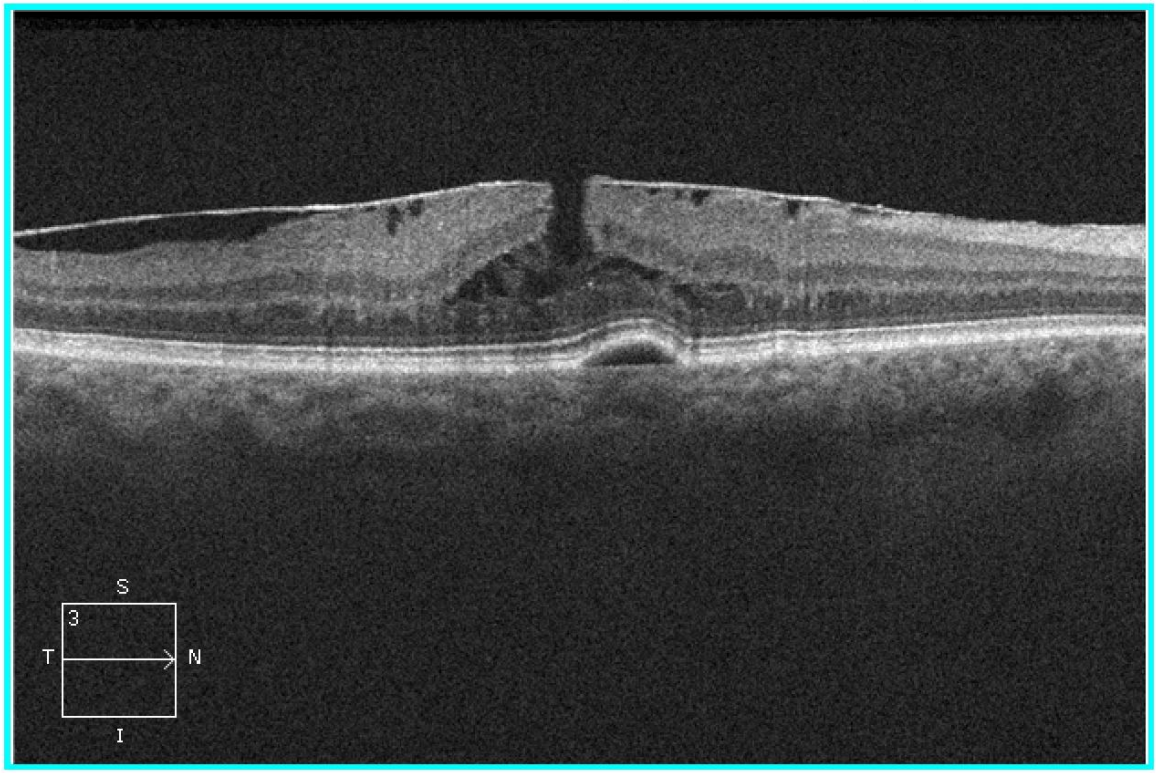

High Definition Images: HD 5 Line Raster

OD ● ○ OS

Scan Angle: 0° Spacing: 0.25 mm Length: 6 mm

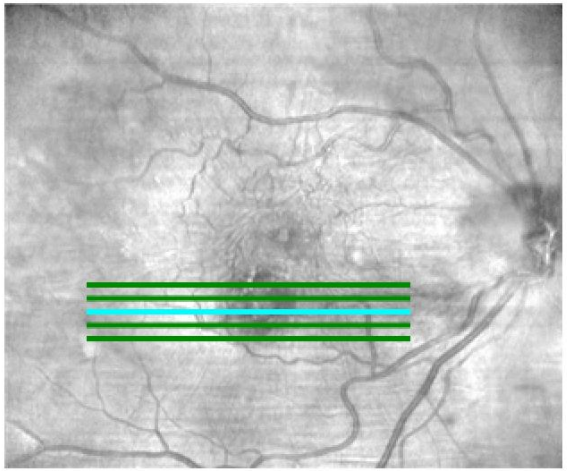

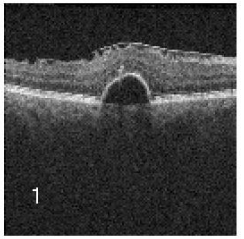

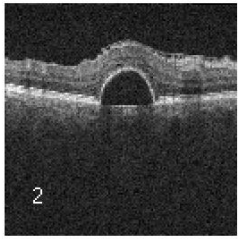

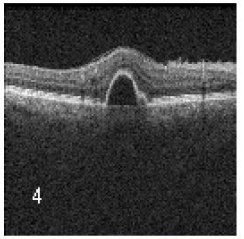

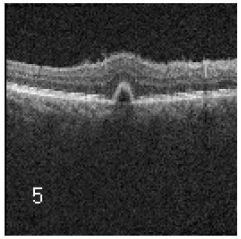

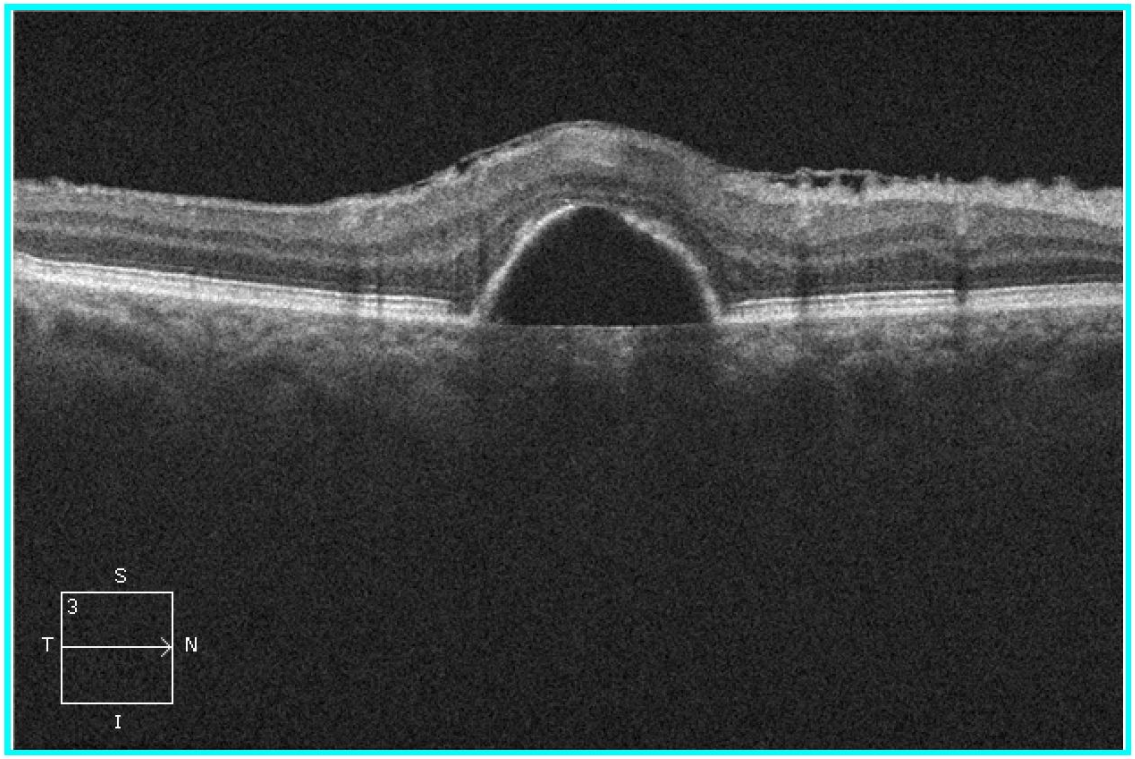

BRVO with Mac Edema

20/80

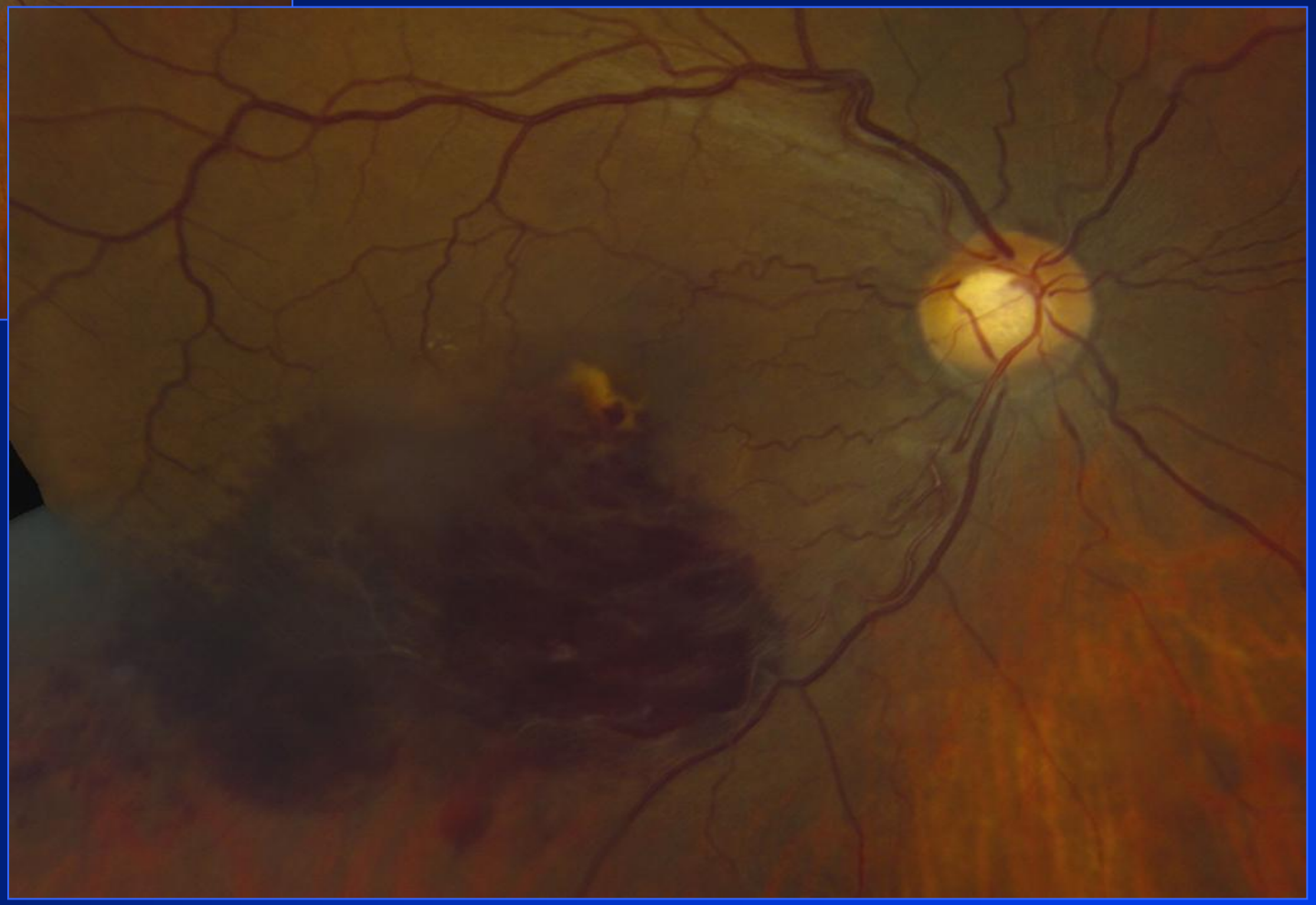

Decreased VA X 3 mo
Was 20/20 the year before

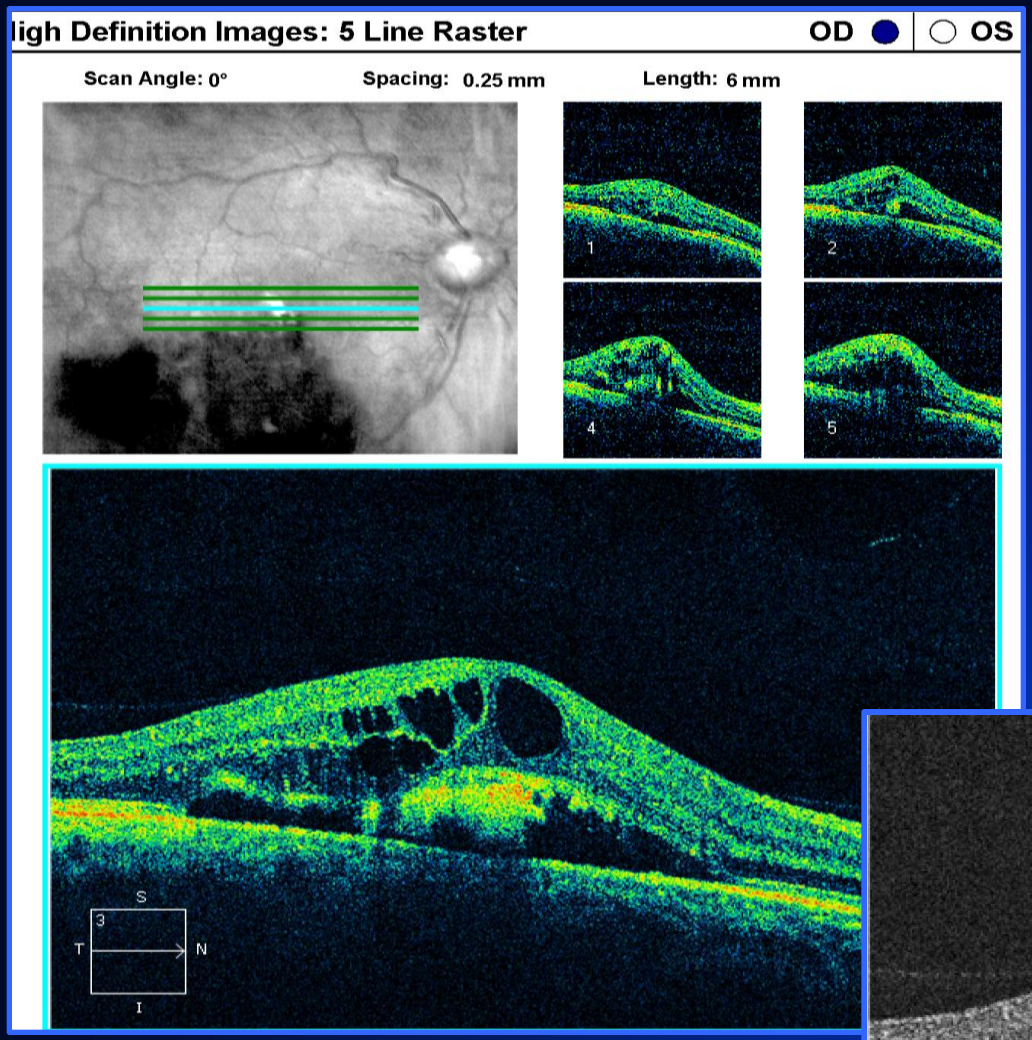
ligh Definition Images: 5 Line Raster
OD
OS
Scan Angle: 0°
Spacing: 0.25 mm
Length: 6 mm
1
2
4
5
S
3
T
N
I

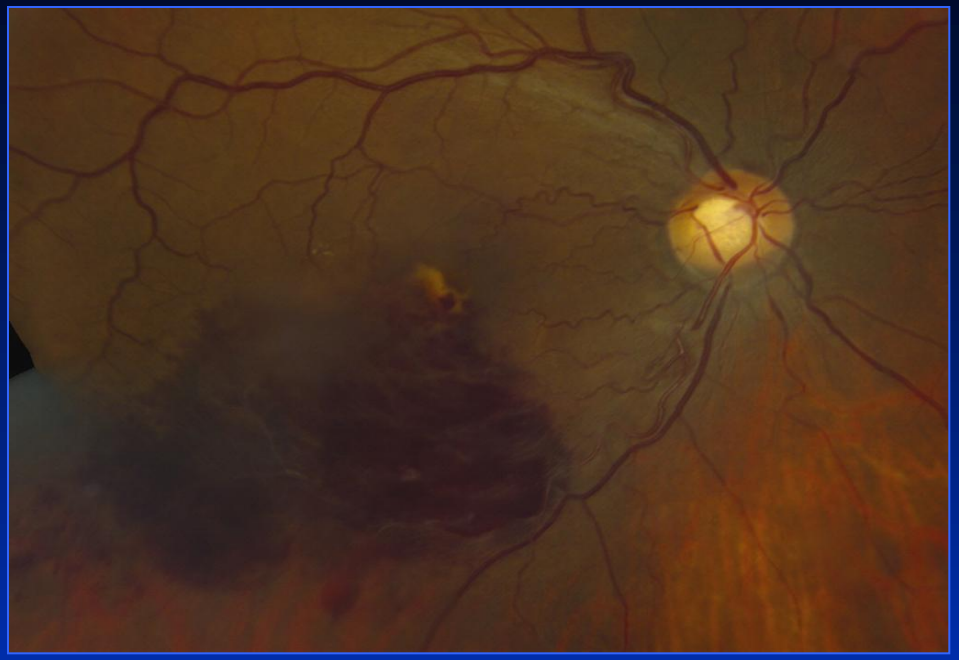

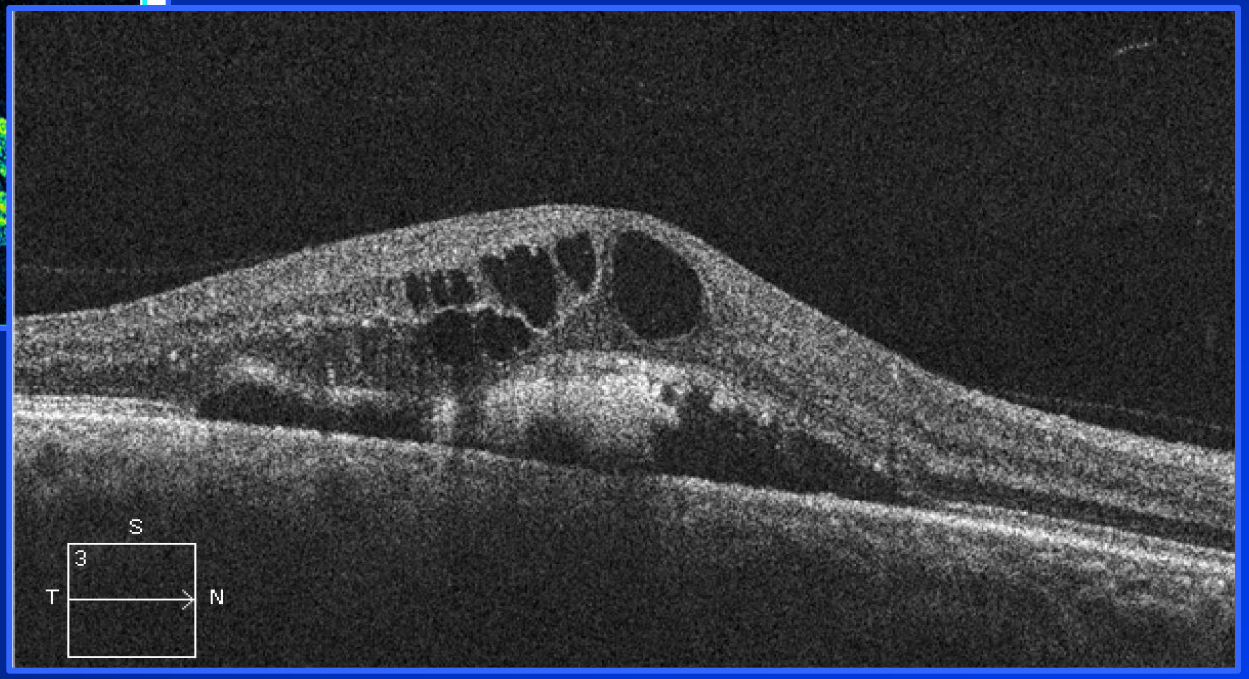
S
3
T
N

Advances in SD-OCT

- Improving software
- Noise reduction/over sampling technology that provides higher resolution imaging
- Improvements in 3D rendering
- Enhanced depth imaging – imaging choroid
- Automatic Fovea Finding
- Progression analysis software
- Expanded normative data bases

Initial

3 Months

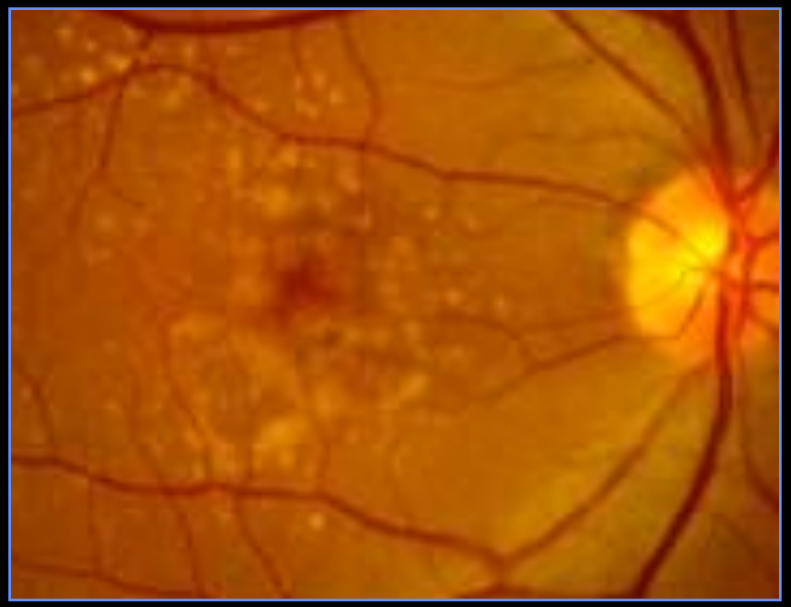

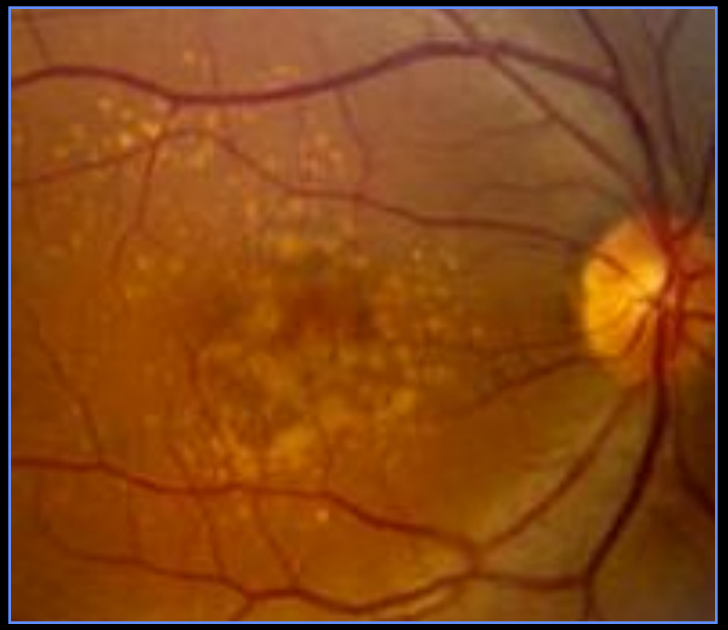

Volume = 0.212 mm^3

Volume = 0.257 mm3

Documenting Progression in Dry/Atrophic AMD

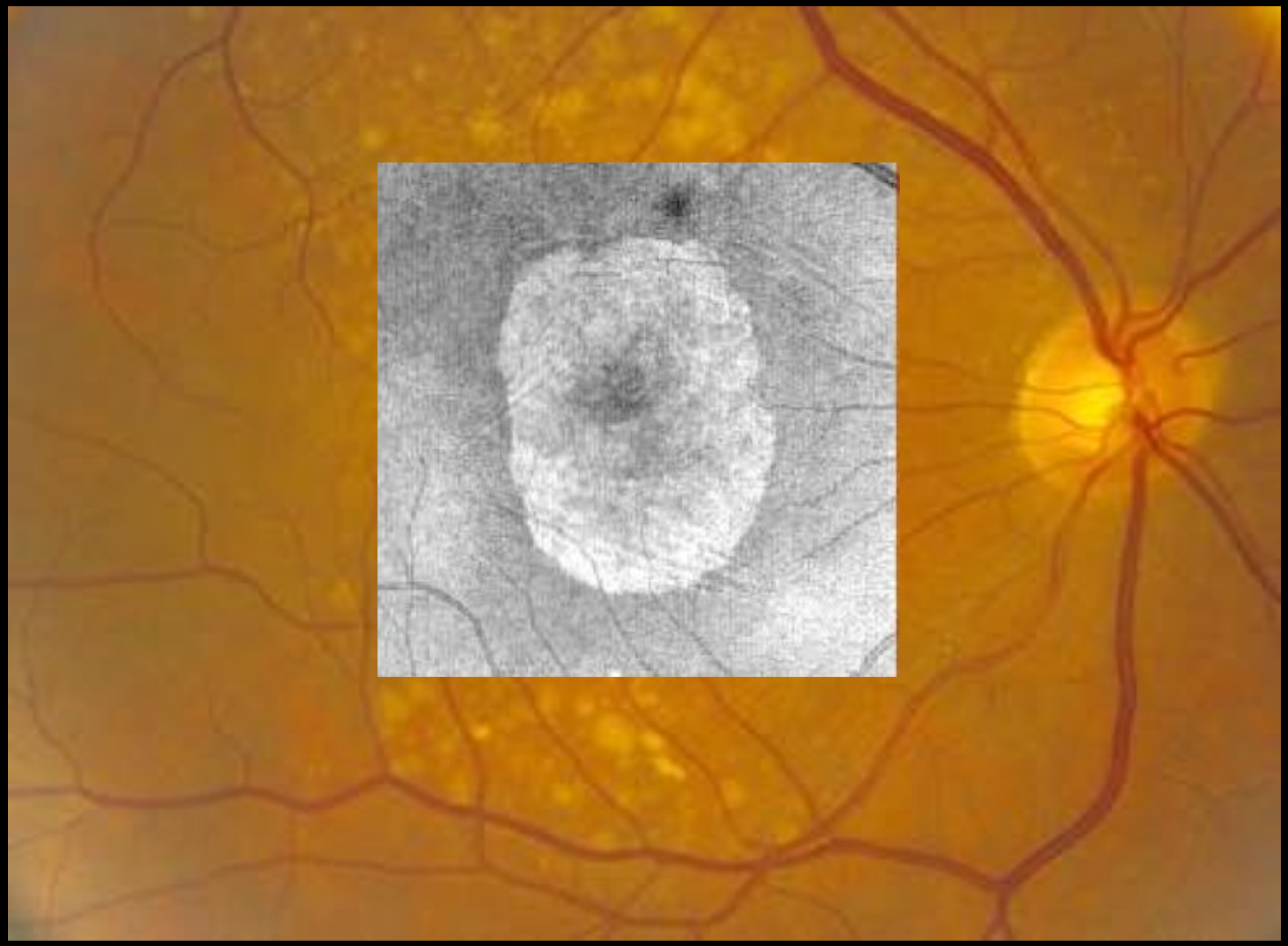

Documenting Progression in Dry/Atrophic AMD

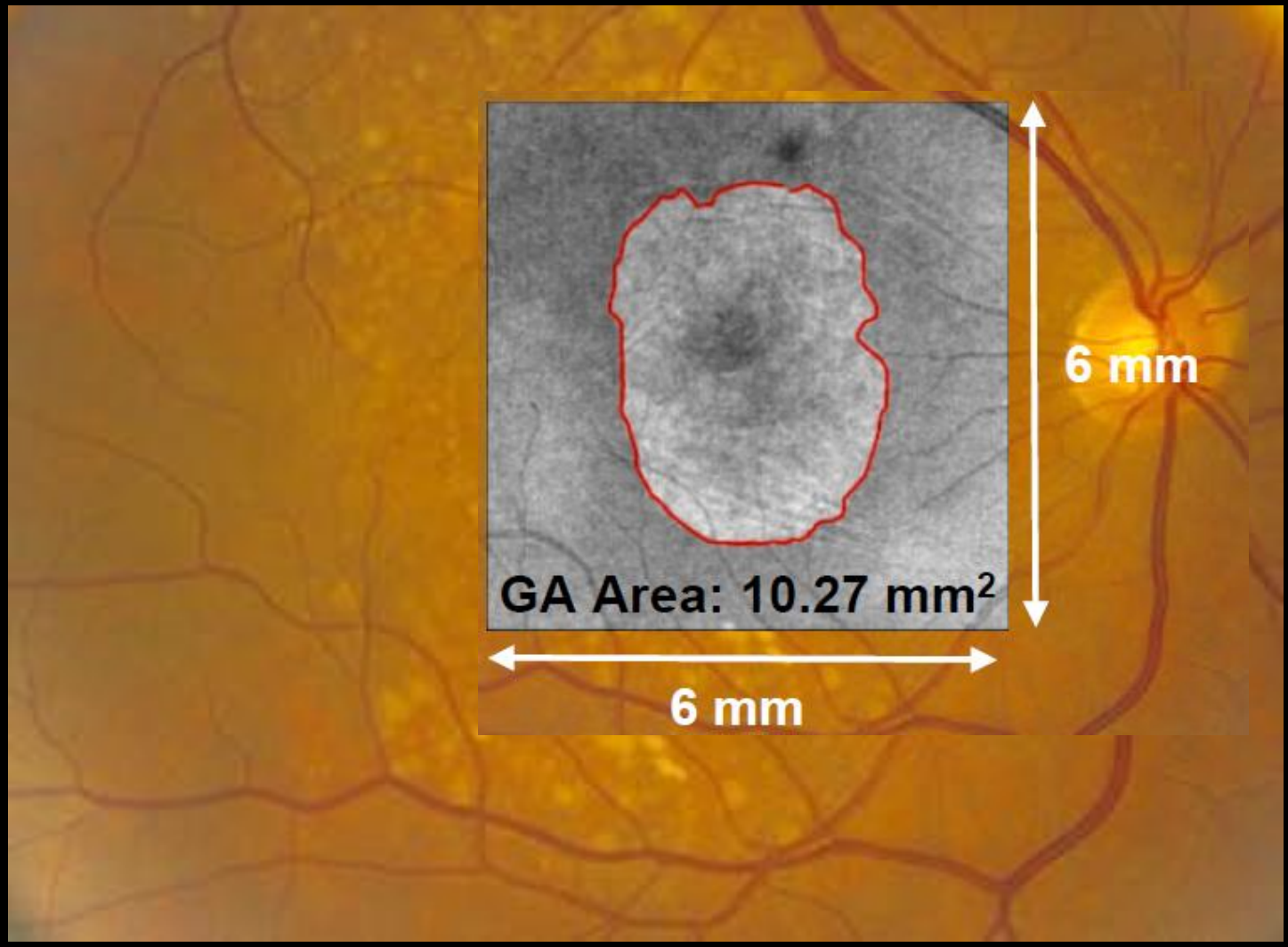

Advanced RPE Analysis

Gain new insights on your AMD patients

- **RPE Elevations:** If the RPE is raised, a new proprietary algorithm for Cirrus maps and measures the area and volume of the elevations.

- **Sub-RPE Illumination.** If the RPE is absent or has lost integrity a new proprietary algorithm for Cirrus can map and measure the affected area.

RPE Elevations

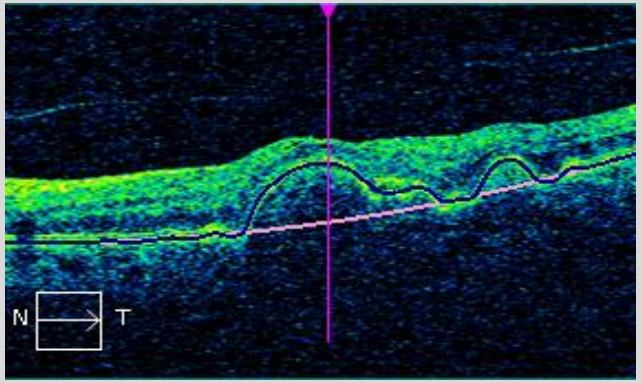

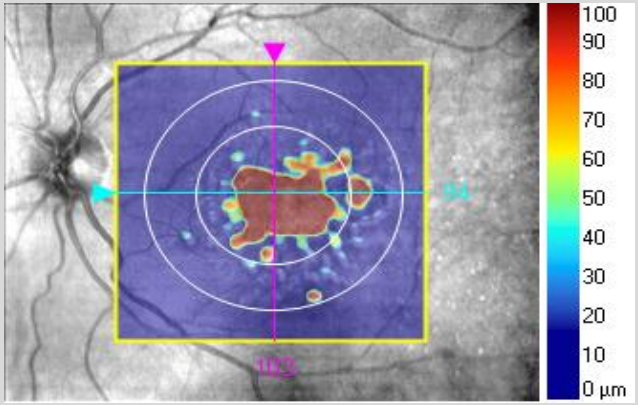

RPE Elevations	Prior	Current	Difference	% Change
Area in 3 mm Circle (mm2)	3.2	3.9	0.7	21.9%
Area in 5 mm Circle (mm2)	3.7	4.7	1.0	27.0%
Volume in 3 mm Circle (mm3)	0.32	0.53	0.21	65.6%
Volume in 5 mm Circle (mm3)	0.34	0.58	0.24	70.6%

Sub-RPE Illumination

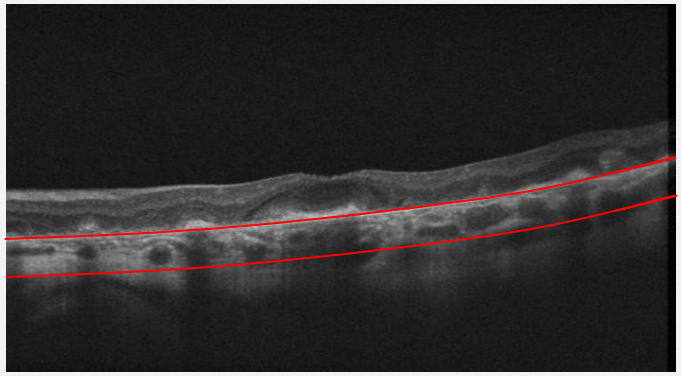

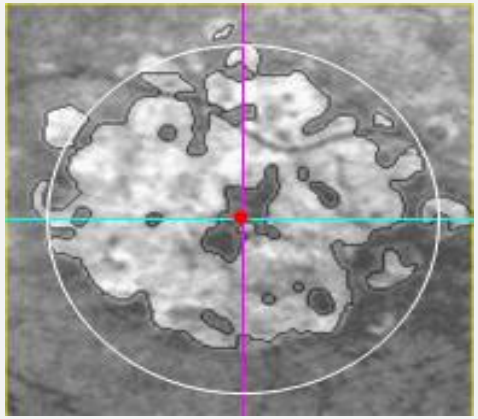

Sub-RPE Illumination	Prior	Current	Difference	% Change
Area in 5 mm Circle (mm2)	10.2	12.1	1.90	18.6%
Closest distance to Fovea (mm)	0.6	0.0	-0.60	-100.0%

Advanced RPE Analysis

Screen 1

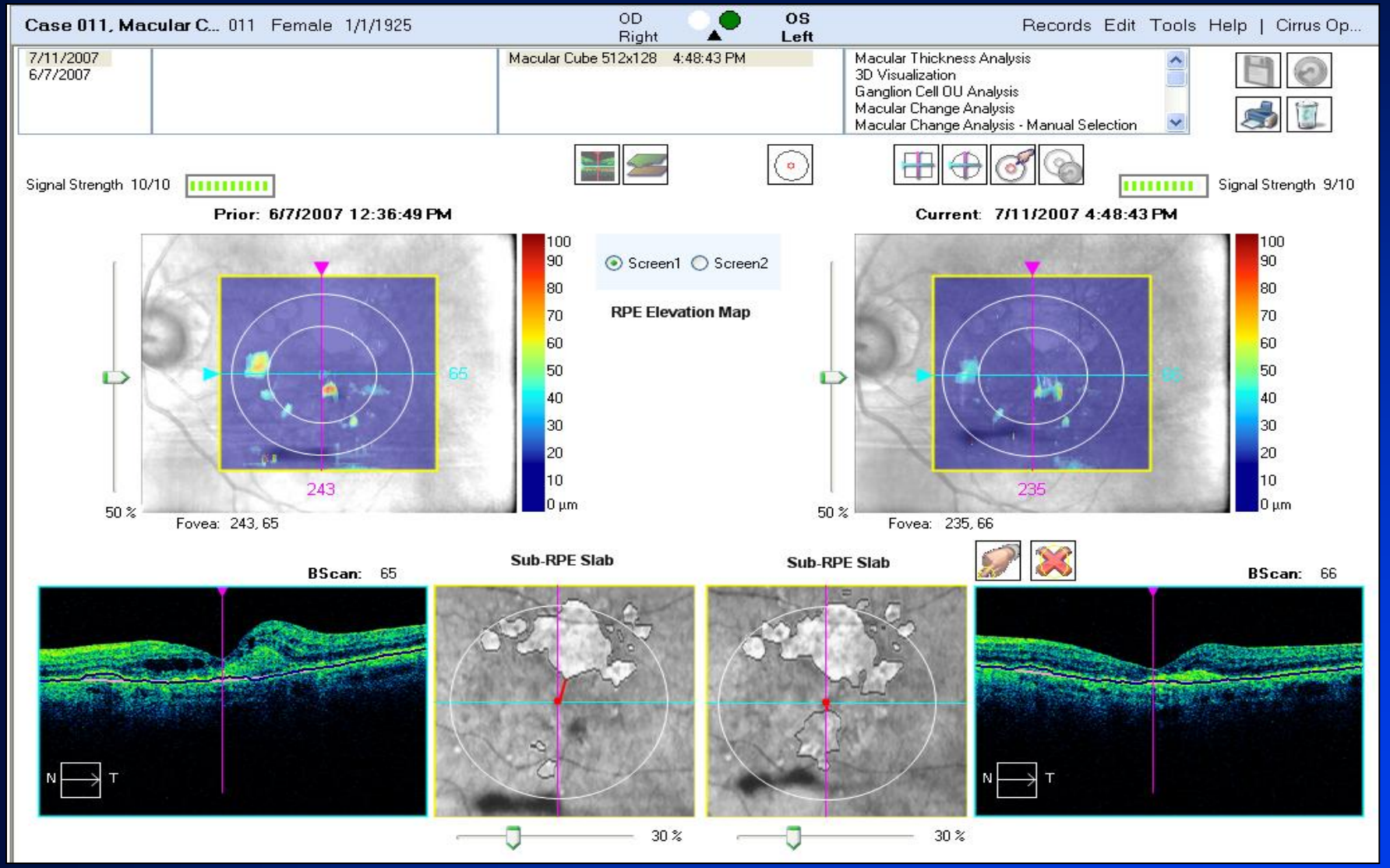

Advanced RPE Analysis

Screen 2

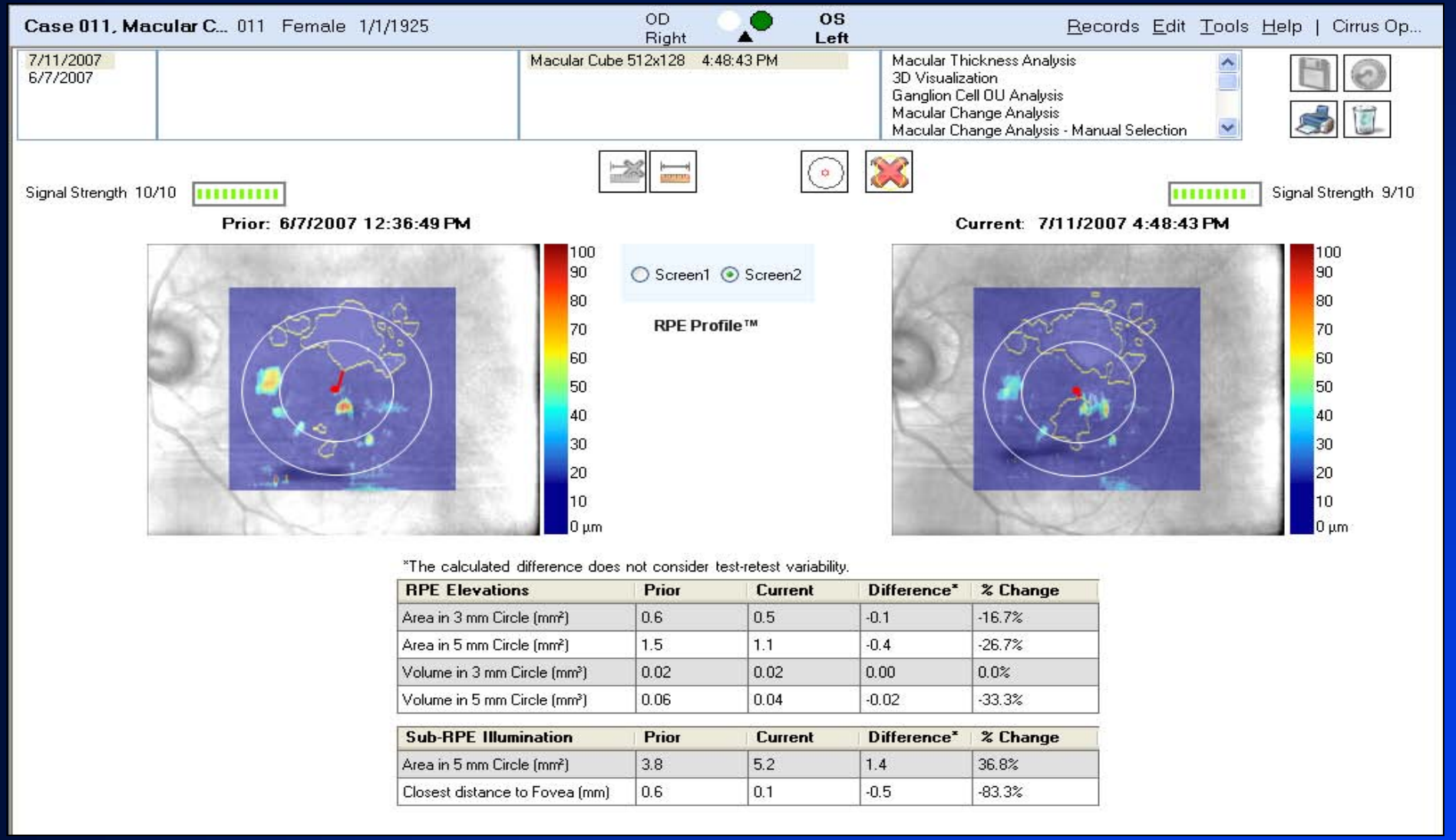

*The calculated difference does not consider test-retest variability.

RPE Elevations	Prior	Current	Difference*	% Change
Area in 3 mm Circle (mm²)	0.6	0.5	-0.1	-16.7%
Area in 5 mm Circle (mm²)	1.5	1.1	-0.4	-26.7%
Volume in 3 mm Circle (mm³)	0.02	0.02	0.00	0.0%
Volume in 5 mm Circle (mm³)	0.06	0.04	-0.02	-33.3%

Sub-RPE Illumination	Prior	Current	Difference*	% Change
Area in 5 mm Circle (mm²)	3.8	5.2	1.4	36.8%
Closest distance to Fovea (mm)	0.6	0.1	-0.5	-83.3%

73 y/o Hispanic Female

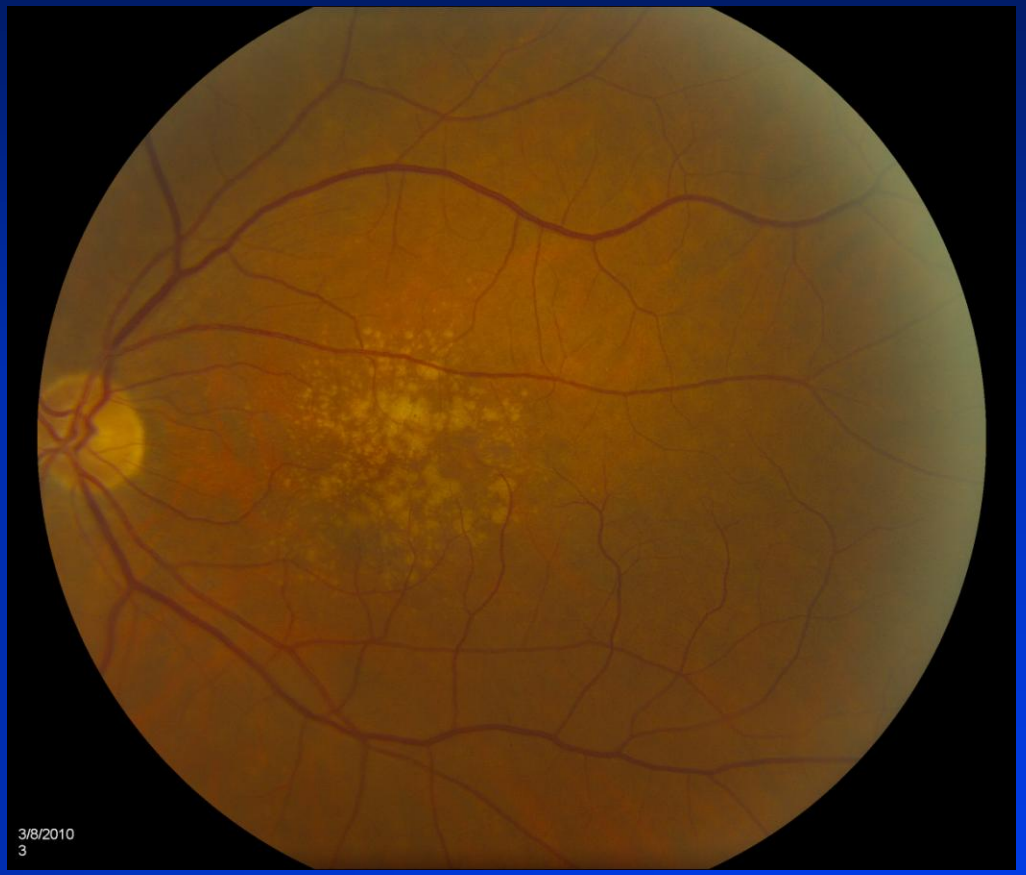

73 y/o Hispanic Female

Smoker, h/o CVA, paralyzed on the R side

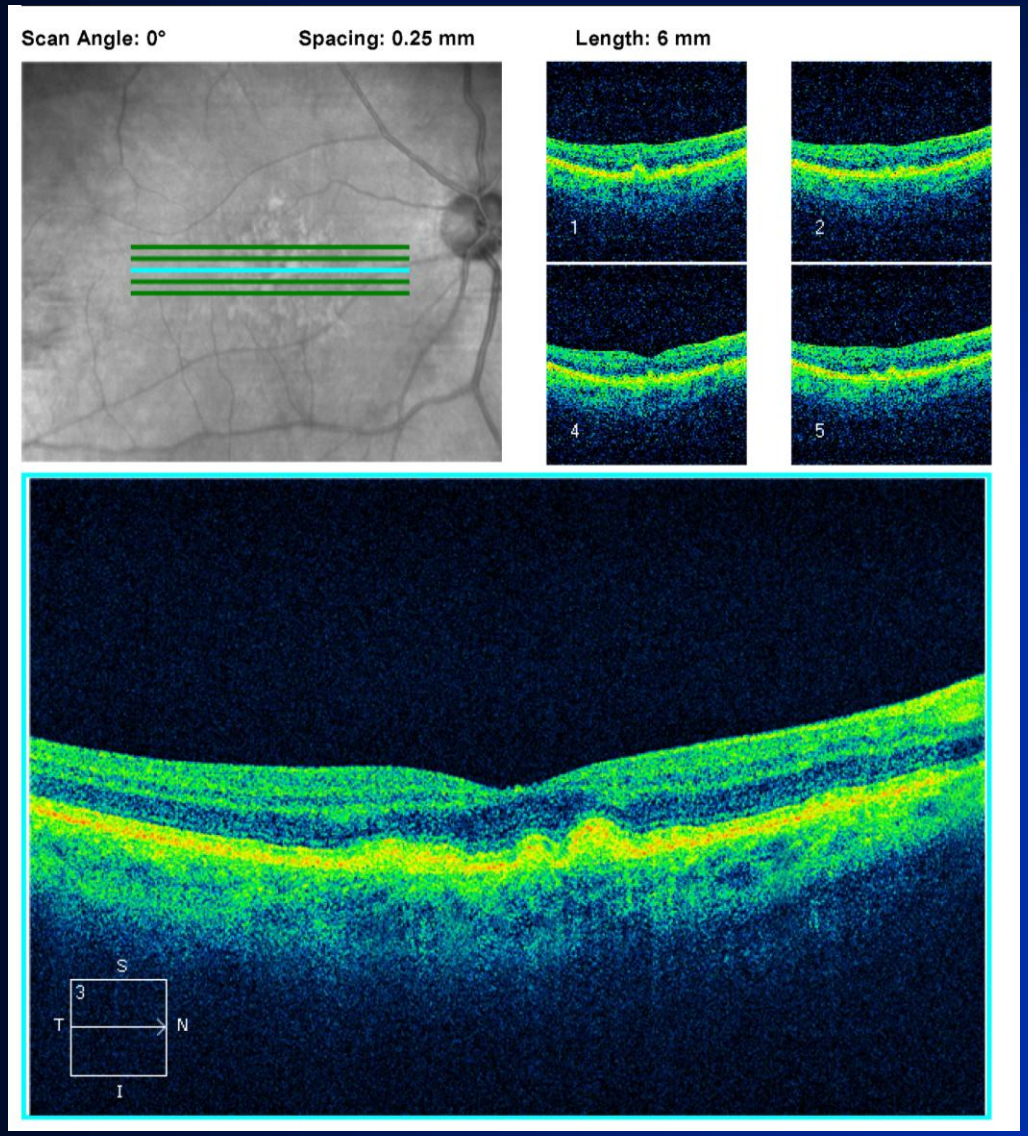
Scan Angle: 0°
Spacing: 0.25 mm
Length: 6 mm
1
2
4
5
S
3
T
N
I

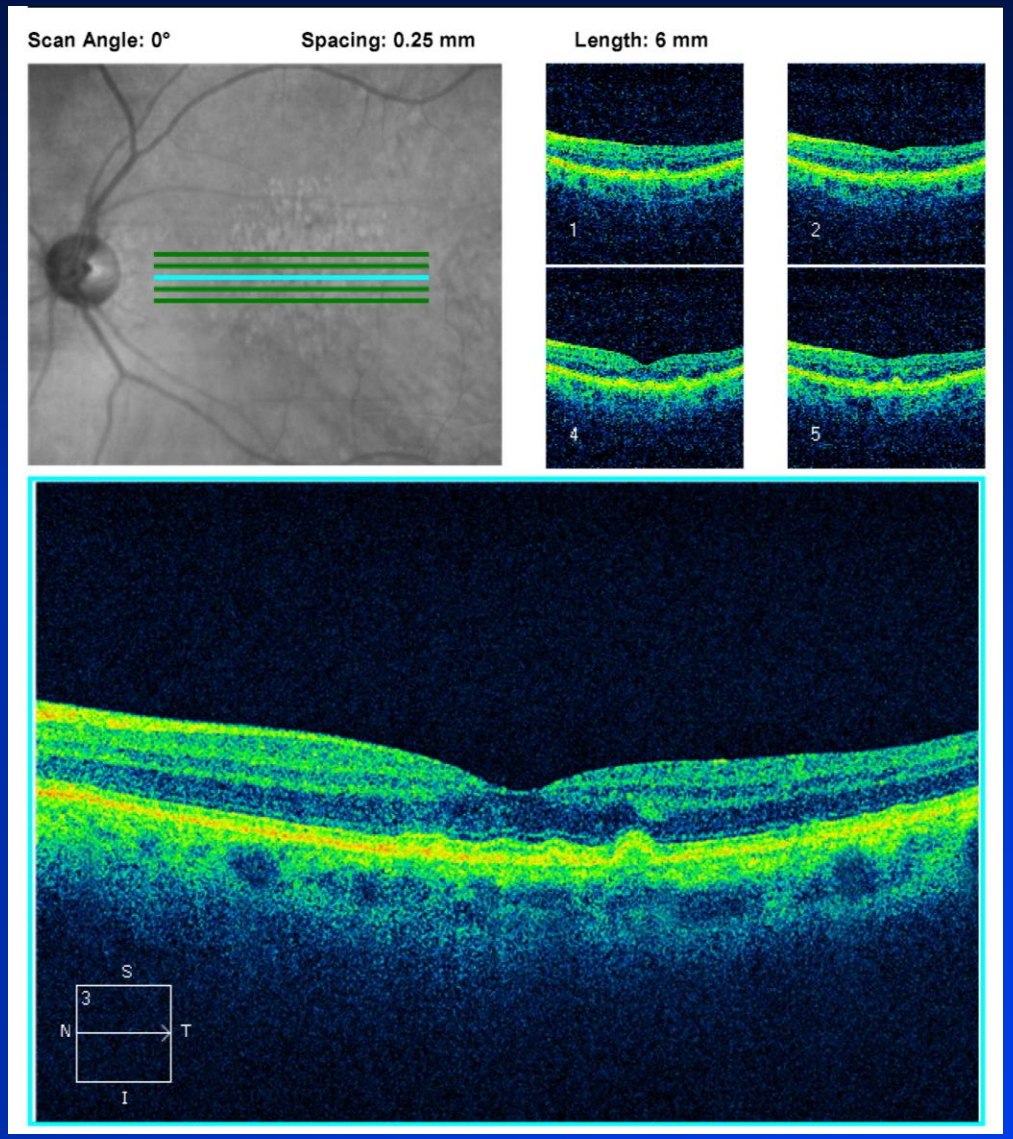
Scan Angle: 0°
Spacing: 0.25 mm
Length: 6 mm
1
2
4
5
S
3
N
T
I

6/5/2012

6/5/2012

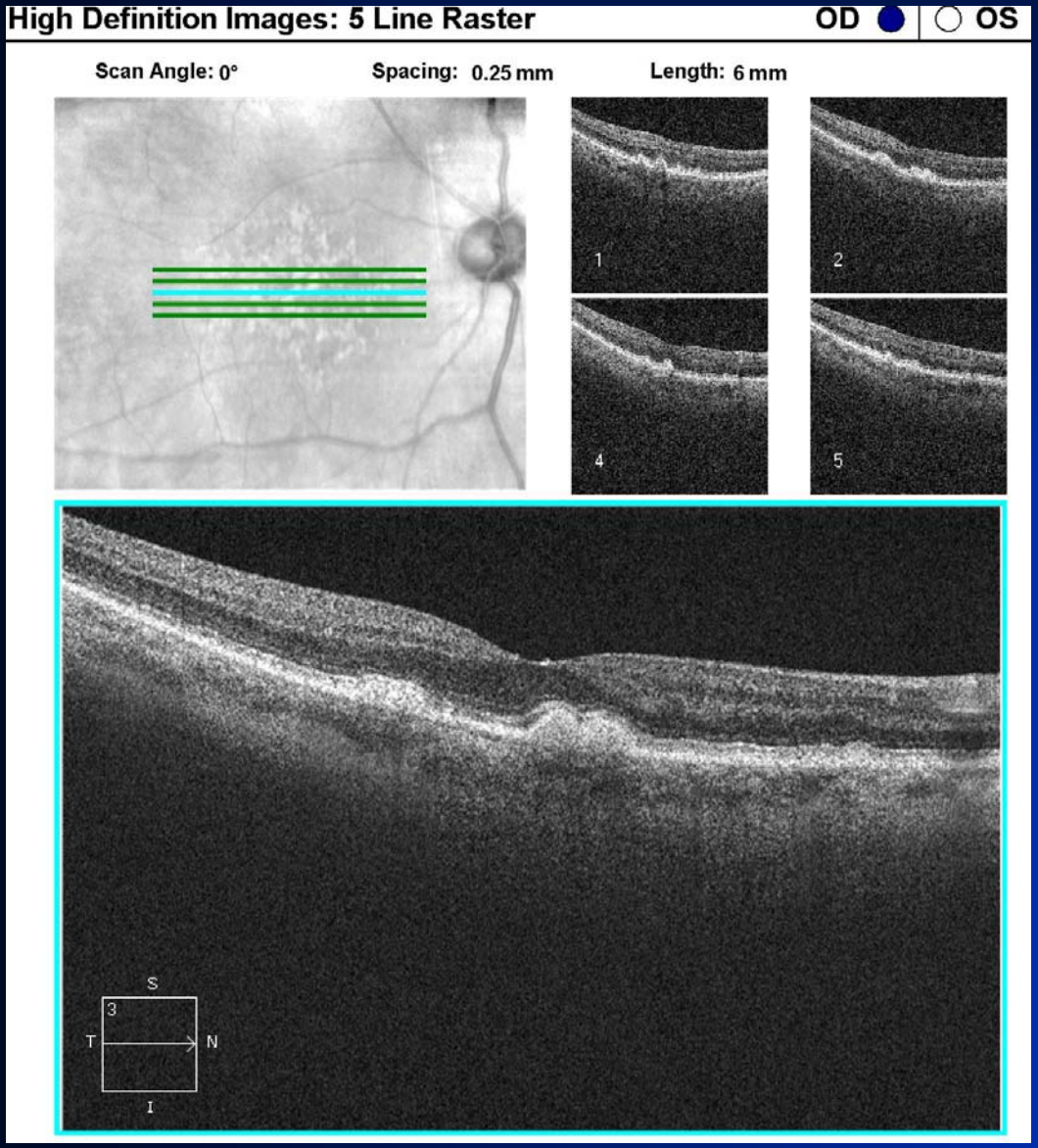
High Definition Images: 5 Line Raster
OD
OS
Scan Angle: 0°
Spacing: 0.25 mm
Length: 6 mm
1
2
4
5
S
3
T
N
I

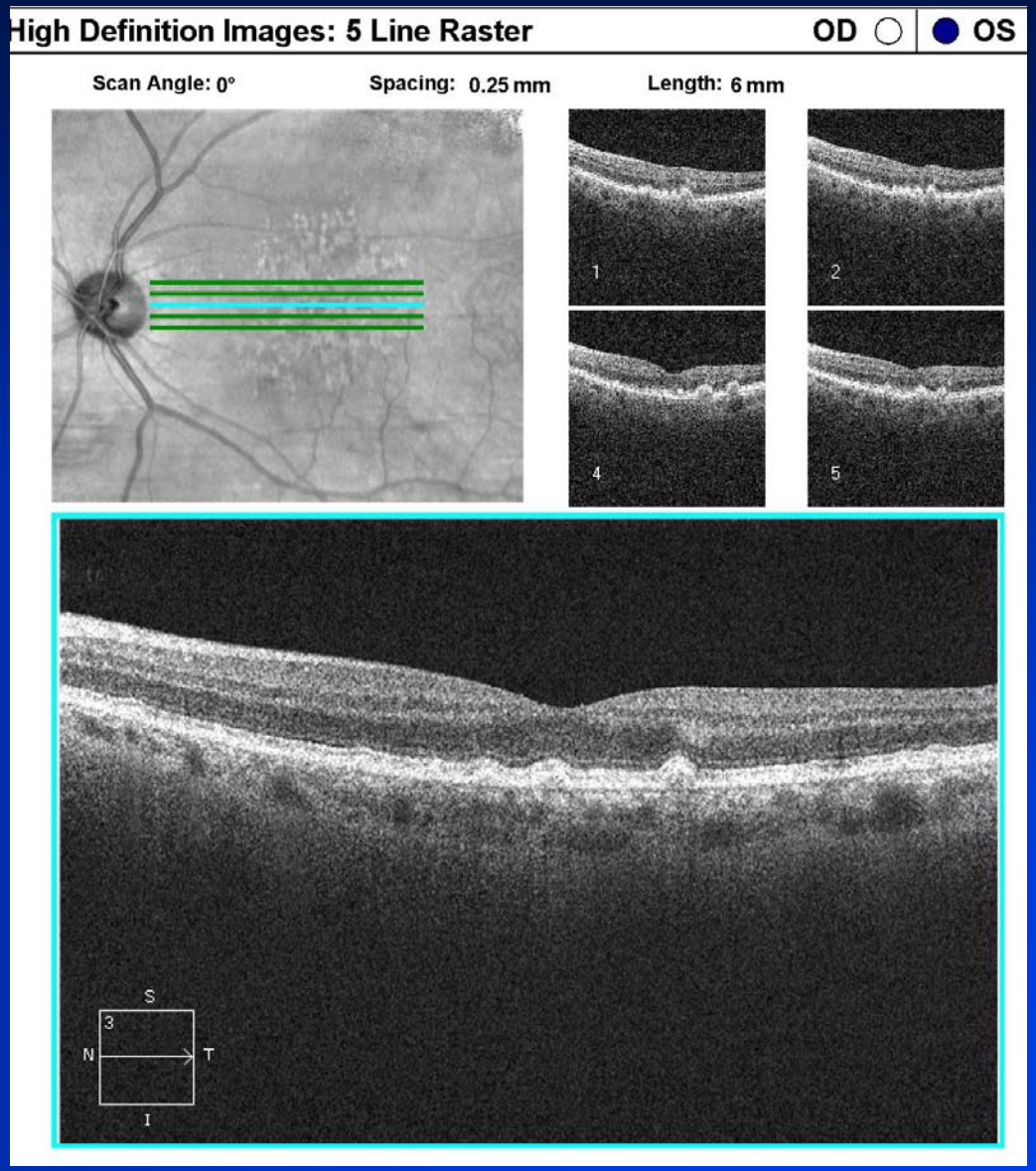
High Definition Images: 5 Line Raster
OD
OS
Scan Angle: 0°
Spacing: 0.25 mm
Length: 6 mm
1
2
4
5
S
3
N
T
I

3/20/10

6/5/2012

3/20/10

6/5/2012

Doctor: Signal Strength: 6/10 6/10

Advanced RPE Analysis : Macular Cube 200x200 OD ● ○ OS

Prior Visit		Current Visit
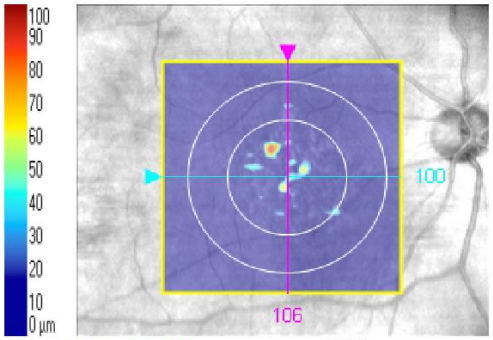	RPE Elevation Map	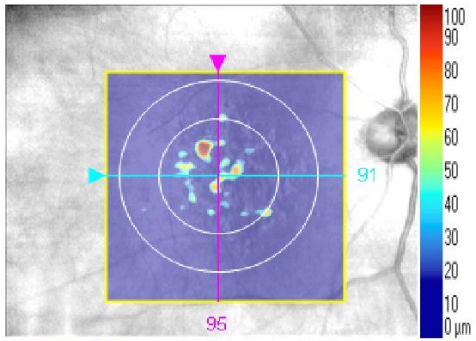
Fovea: 106, 100 50% Transparency		Fovea: 95, 91 50% Transparency
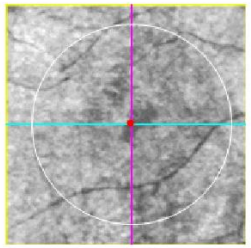	Sub-RPE Slab	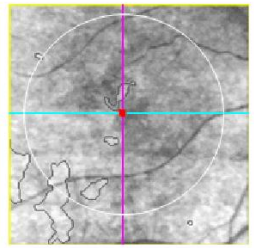
30% Transparency		30% Transparency
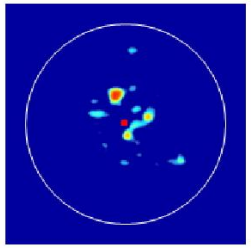	RPE Profile ™	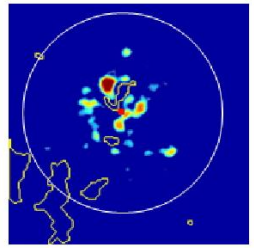

*The calculated difference does not consider test-retest variability.

RPE Elevations	Prior	Current	Difference*	% Change
Area in 3 mm Circle (mm²)	0.6	1.2	0.6	100.0%
Area in 5 mm Circle (mm²)	0.7	1.3	0.6	85.7%
Volume in 3 mm Circle (mm³)	0.02	0.05	0.03	150.0%
Volume in 5 mm Circle (mm³)	0.03	0.06	0.03	100.0%
Sub-RPE Illumination	**Prior**	**Current**	**Difference***	**% Change**
Area in 5 mm Circle (mm²)	0.0	0.8	0.8	xxx
Closest distance to Fovea (mm)	xxx	0.2	xxx	xxx

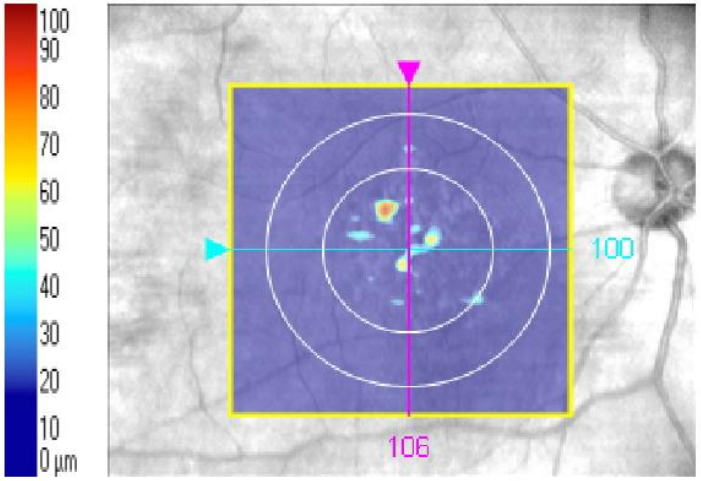

Fovea: 106, 100

50% Transparency

RPE Elevation Map

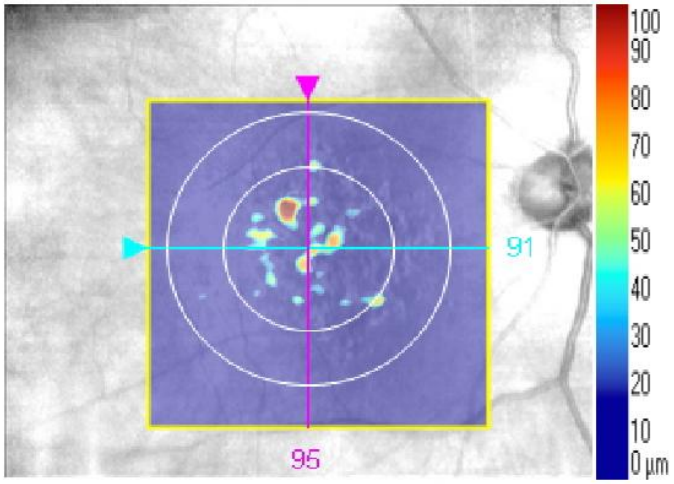

Fovea: 95, 91

50% Transparency

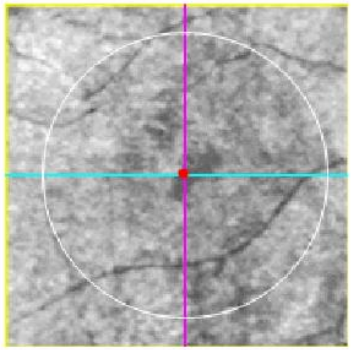

30% Transparency

Sub-RPE Slab

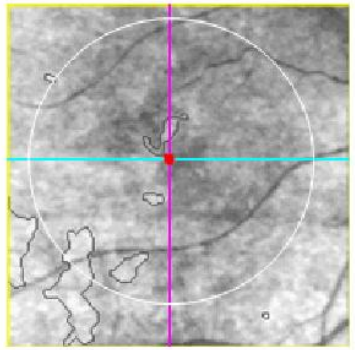

30% Transparency

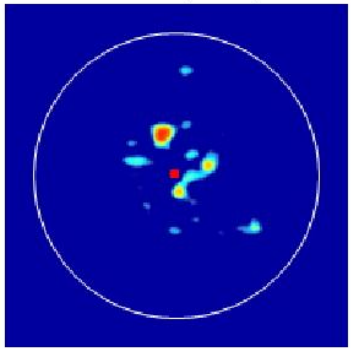

RPE Profile ™

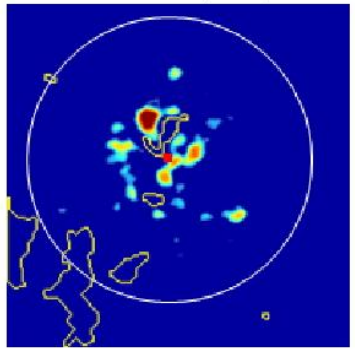

*The calculated difference does not consider test-retest variability.

RPE Elevations	Prior	Current	Difference*	% Change
Area in 3 mm Circle (mm^2)	0.6	1.2	0.6	100.0%
Area in 5 mm Circle (mm^2)	0.7	1.3	0.6	85.7%
Volume in 3 mm Circle (mm^3)	0.02	0.05	0.03	150.0%
Volume in 5 mm Circle (mm^3)	0.03	0.06	0.03	100.0%
Sub-RPE Illumination	**Prior**	**Current**	**Difference***	**% Change**
Area in 5 mm Circle (mm^2)	0.0	0.8	0.8	xxx
Closest distance to Fovea (mm)	xxx	0.2	xxx	xxx

Gender: Female Serial Number: 4000-4438 4000-4438
Doctor: Signal Strength: 6/10 8/10

Advanced RPE Analysis : Macular Cube 200x200 OD ○ ● OS

Prior Visit		Current Visit
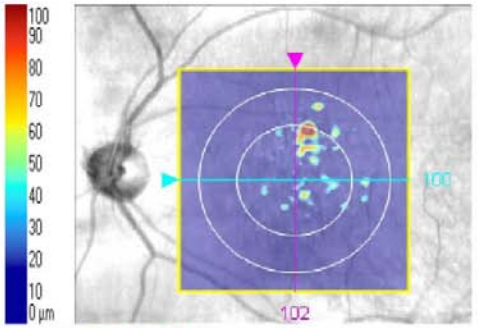	RPE Elevation Map	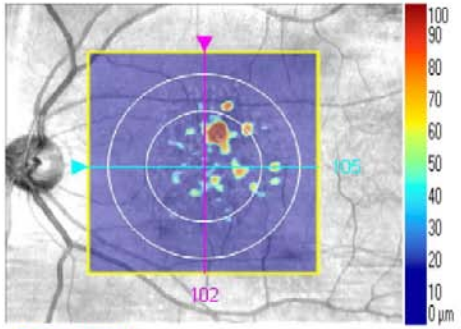
Fovea: 102, 100 50% Transparency		Fovea: 102, 105 50% Transparency
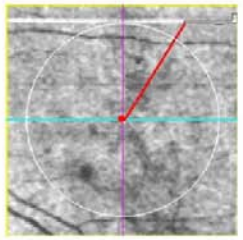	Sub-RPE Slab	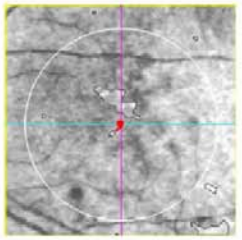
30% Transparency		30% Transparency
	RPE Profile ™	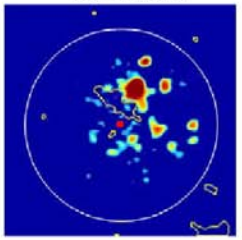

*The calculated difference does not consider test-retest variability.

RPE Elevations	Prior	Current	Difference*	% Change
Area in 3 mm Circle (mm²)	1.2	1.5	0.3	25.0%
Area in 5 mm Circle (mm²)	1.5	2.0	0.5	33.3%
Volume in 3 mm Circle (mm³)	0.05	0.08	0.03	60.0%
Volume in 5 mm Circle (mm³)	0.06	0.10	0.04	66.7%
Sub-RPE Illumination	**Prior**	**Current**	**Difference***	**% Change**
Area in 5 mm Circle (mm²)	0.0	0.5	0.5	xxx
Closest distance to Fovea (mm)	3.0	0.2	-2.8	-93.3%

Macular Change:Macular Cube 200x200

OD ● ○ OS

Registration : Manual

Exam from 3/8/2010 1:44 PM

Fovea: 106, 100

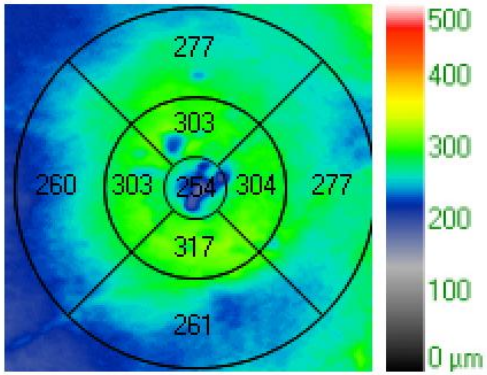

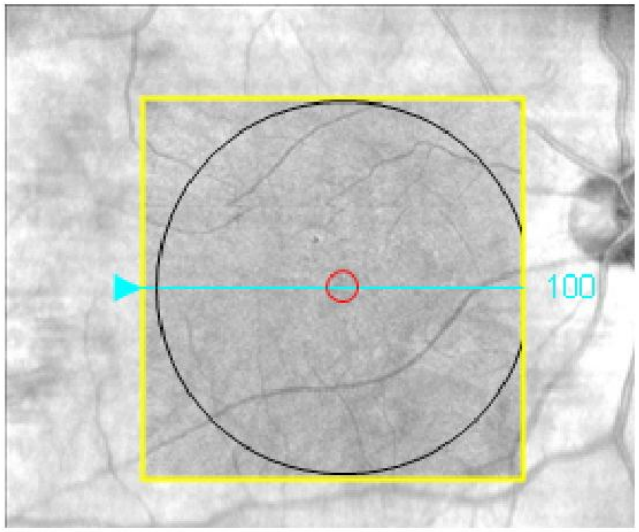

Overlay: OCT Fundus Transparency: 0 %

Exam from 6/5/2012 3:46 PM

Fovea: 106, 100

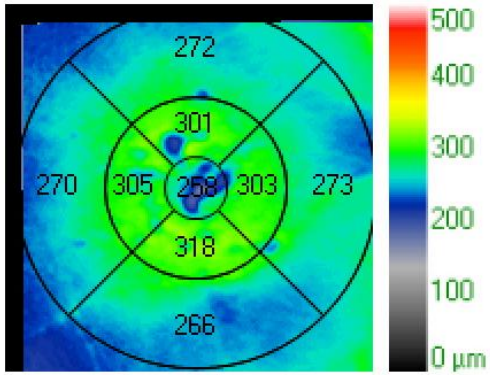

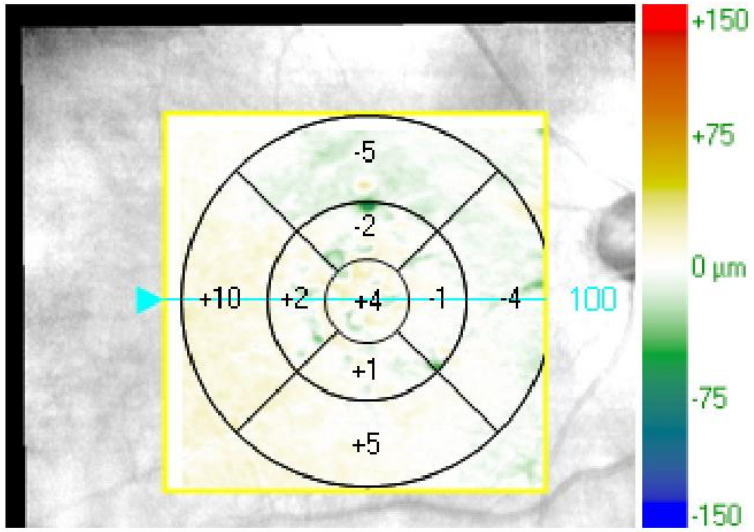

Overlay: ILM-RPE Difference Transparency: 0 %

Extracted B-Scan

Doctor: Signal Strength: 6/10 8/10

Macular Change:Macular Cube 200x200

OD ○ ● OS

Registration : Manual

Exam from 3/8/2010 1:45 PM

Fovea: 102, 100

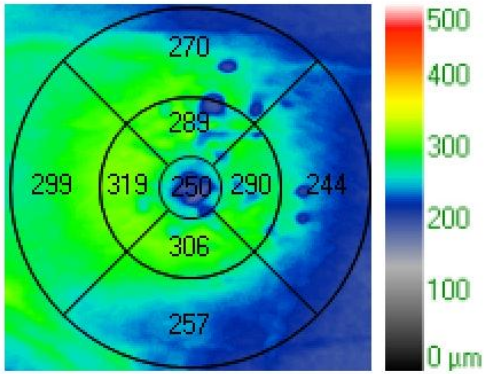

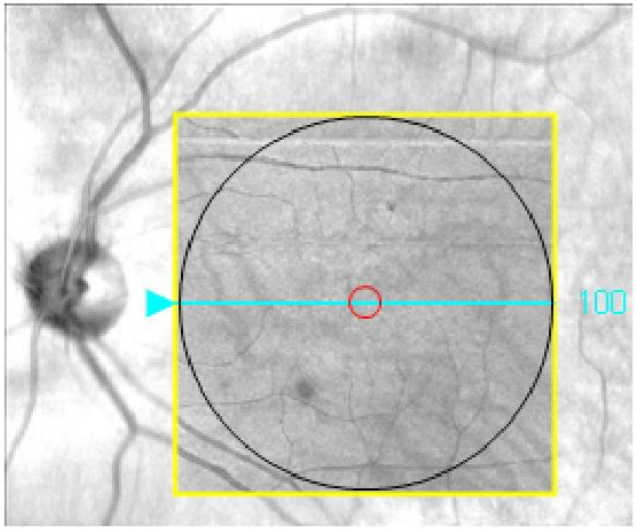

Overlay: OCT Fundus Transparency: 0 %

Exam from 6/5/2012 3:47 PM

Fovea: 102, 100

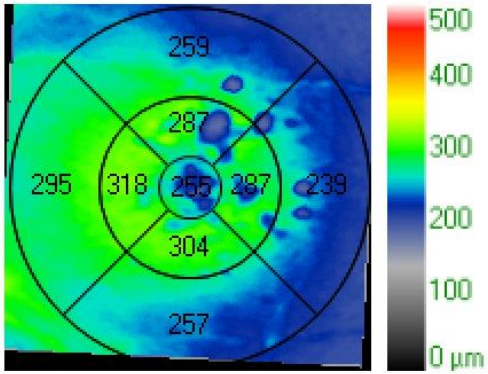

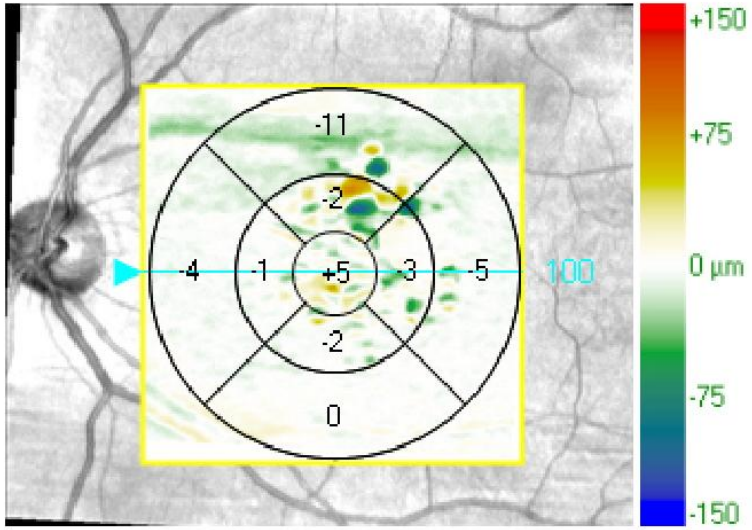

Overlay: ILM-RPE Difference Transparency: 0 %

Enhanced Depth Imaging Imaging the Choroid



Central Serous

What about choroidal thickness?

28 eyes of 19 patients Mean choroidal thickness

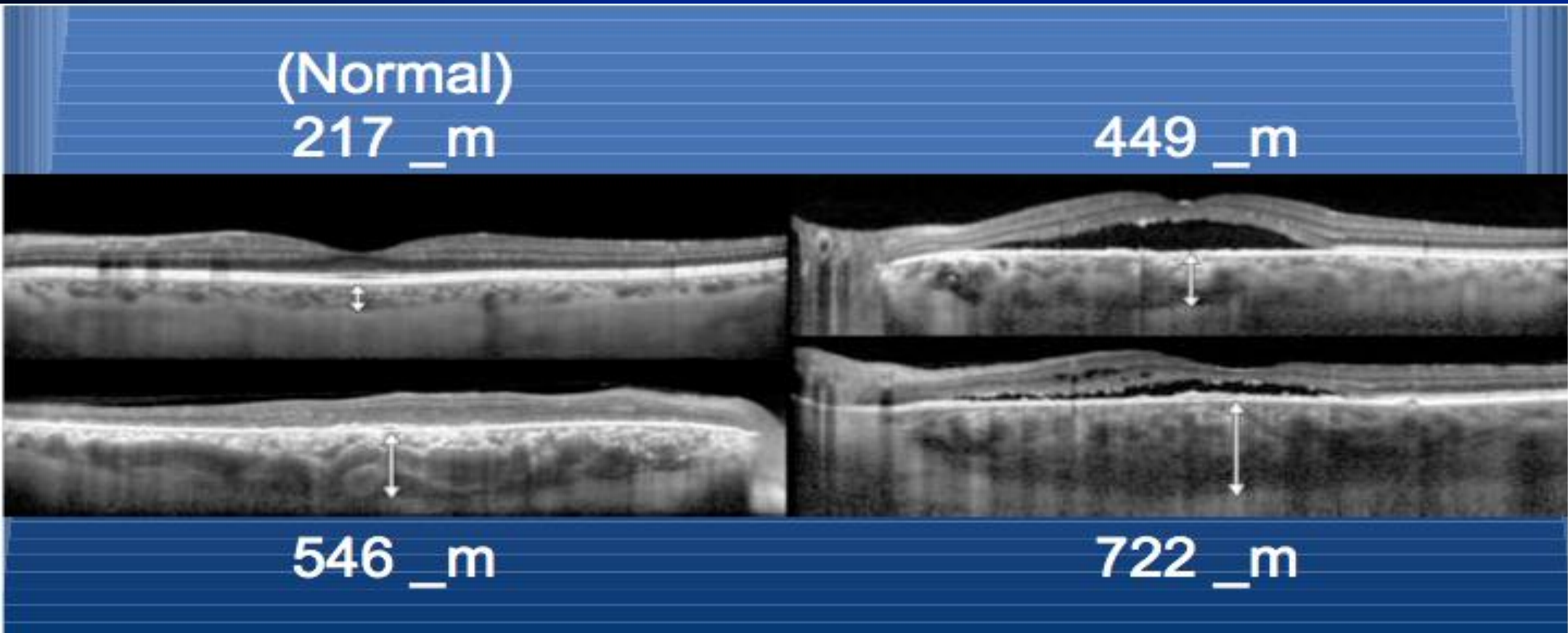

Fundus Autofluorescence (FAF)

- FAF is an imaging technique that uses the fluorescent properties of lipofuscin to study retinal disease in vivo
- FAF imaging has become an important modality for documenting the presence of lipofuscin in the retinal pigment epithelium (RPE)
  - Lipofuscin indicates degenerative changes and injury due to tissue oxidation in pts with exudative ARMD

Fundus AutoFluorescence (FAF)

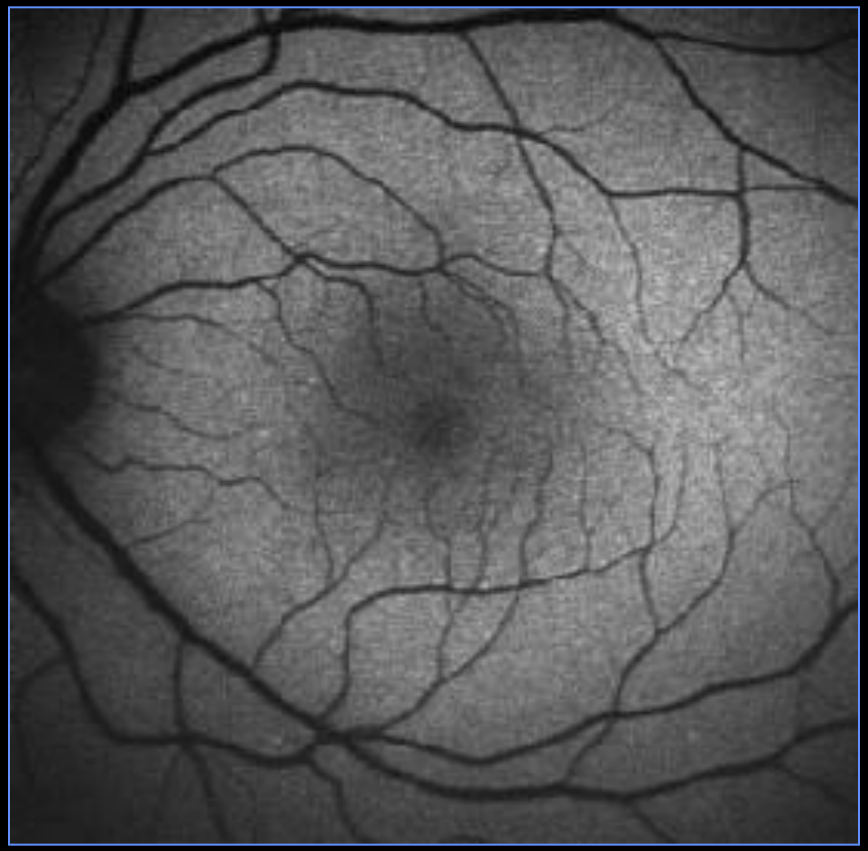

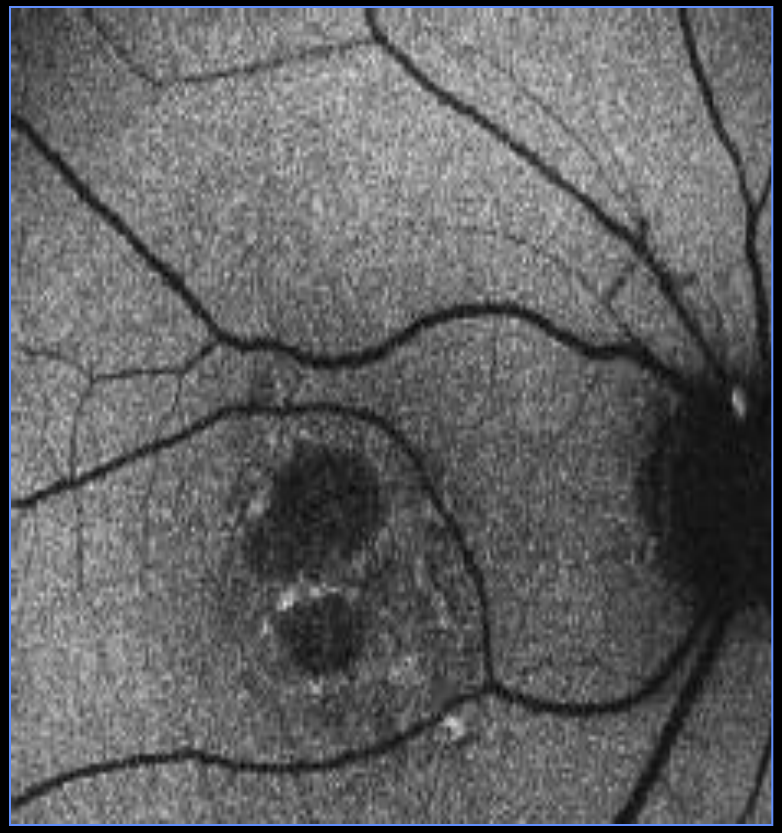

Increased FAF

- **Increased FAF represents lipofuscin accumulation that develops from:**
  - **Disruption of the RPE ability to phagocytize/ completely digest the disc membranes**
  - **Increased shedding of photoreceptor outer segments**
  - **An inability of the RPE to recycle metabolites**

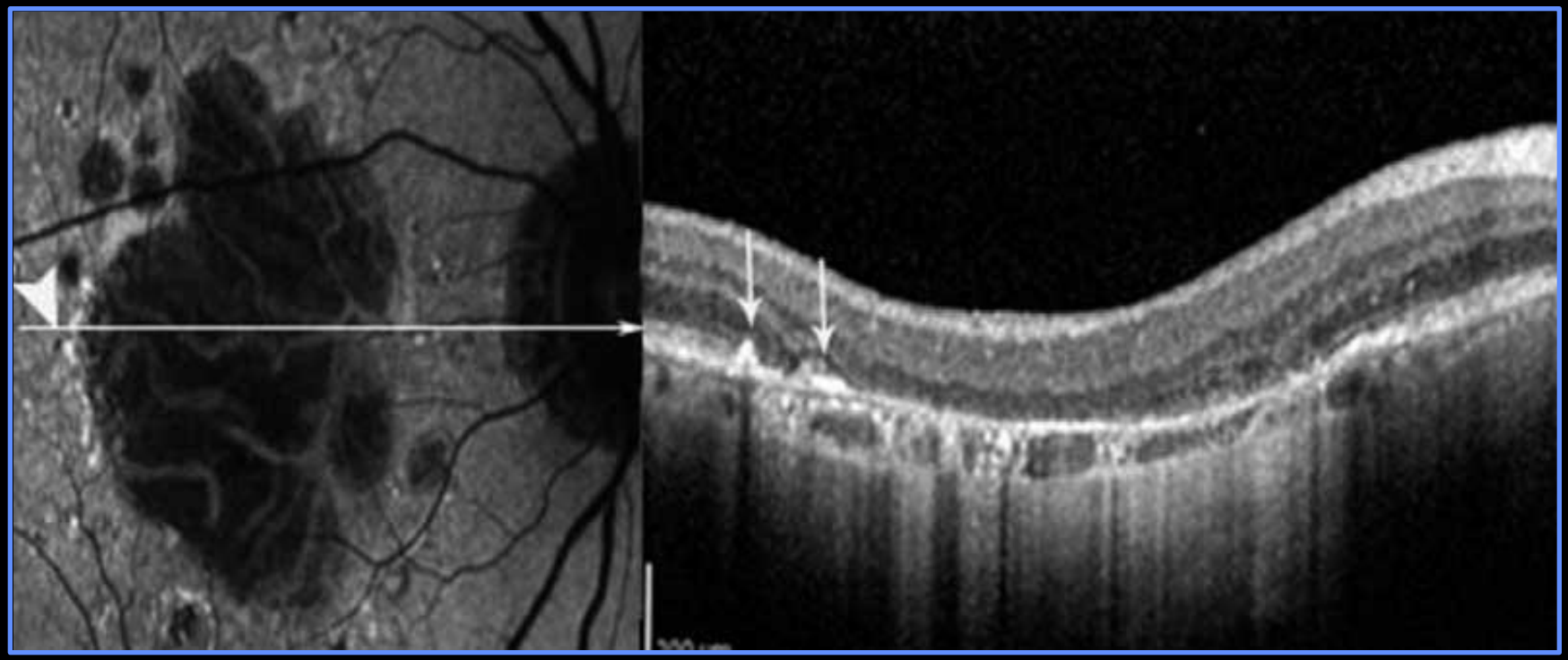

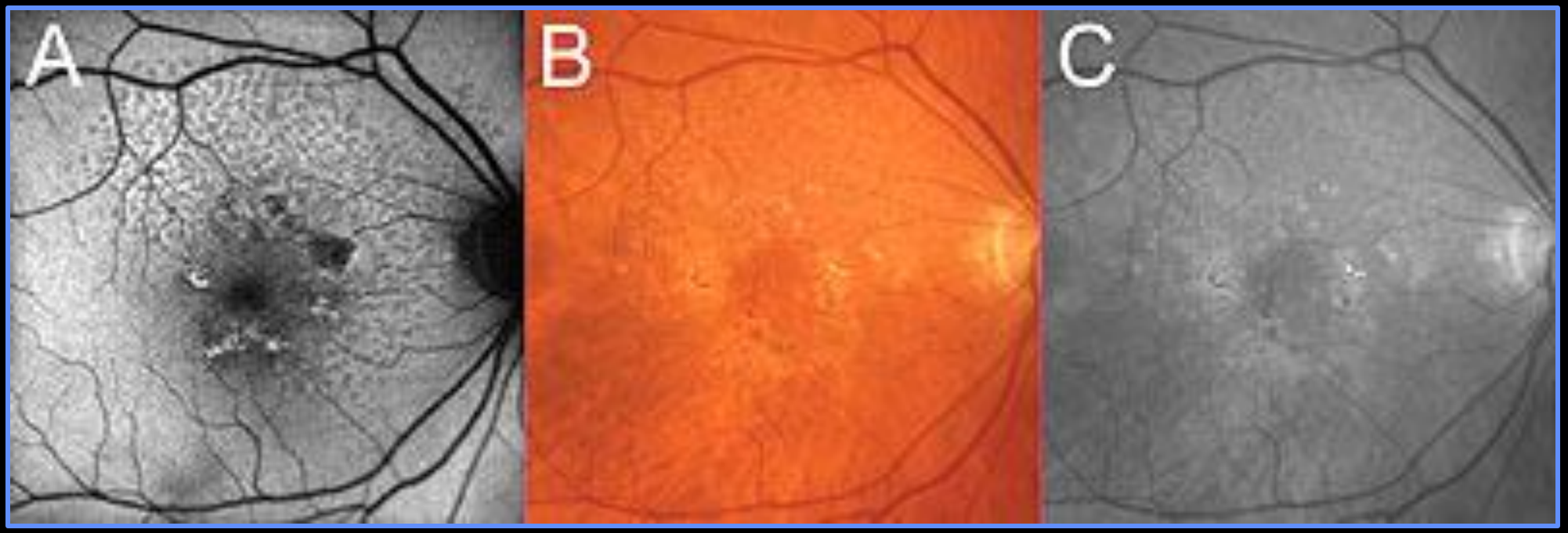
A
B
C

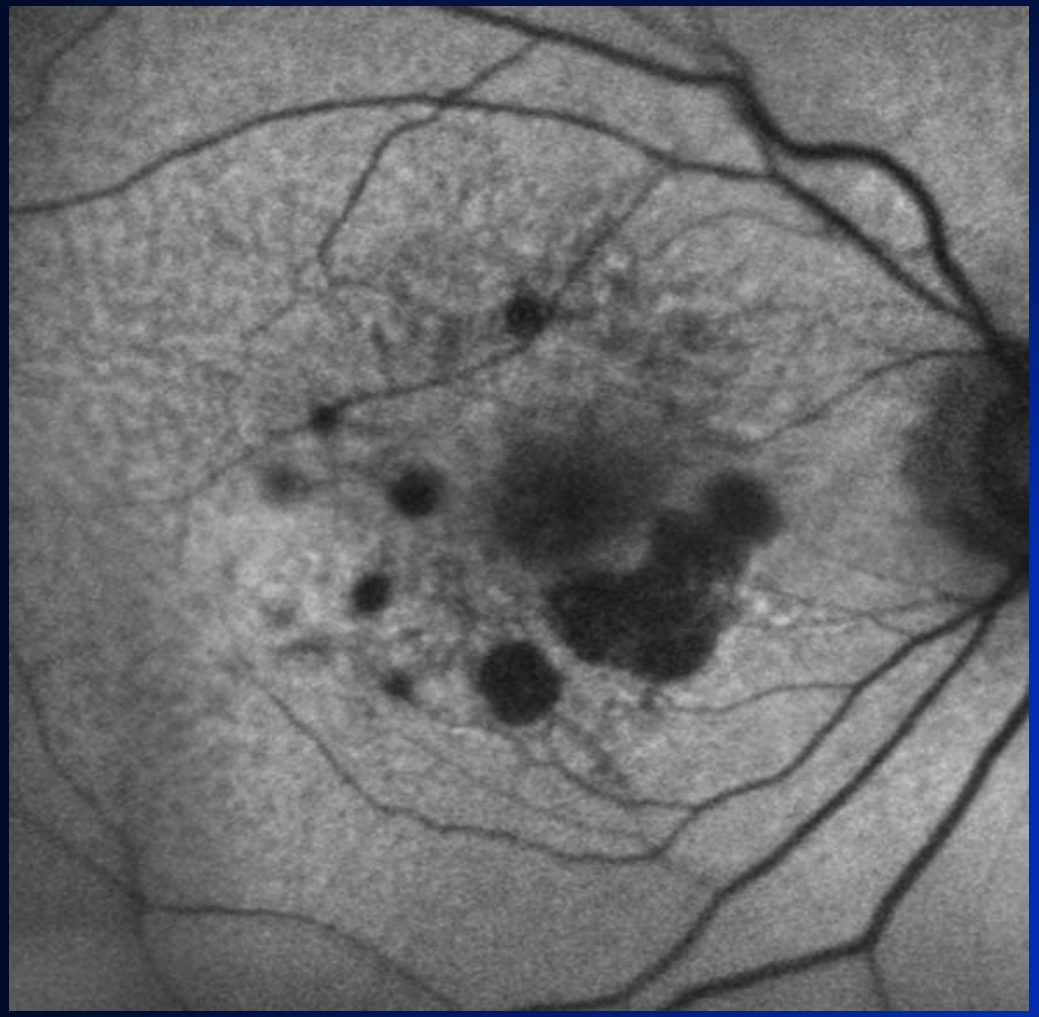

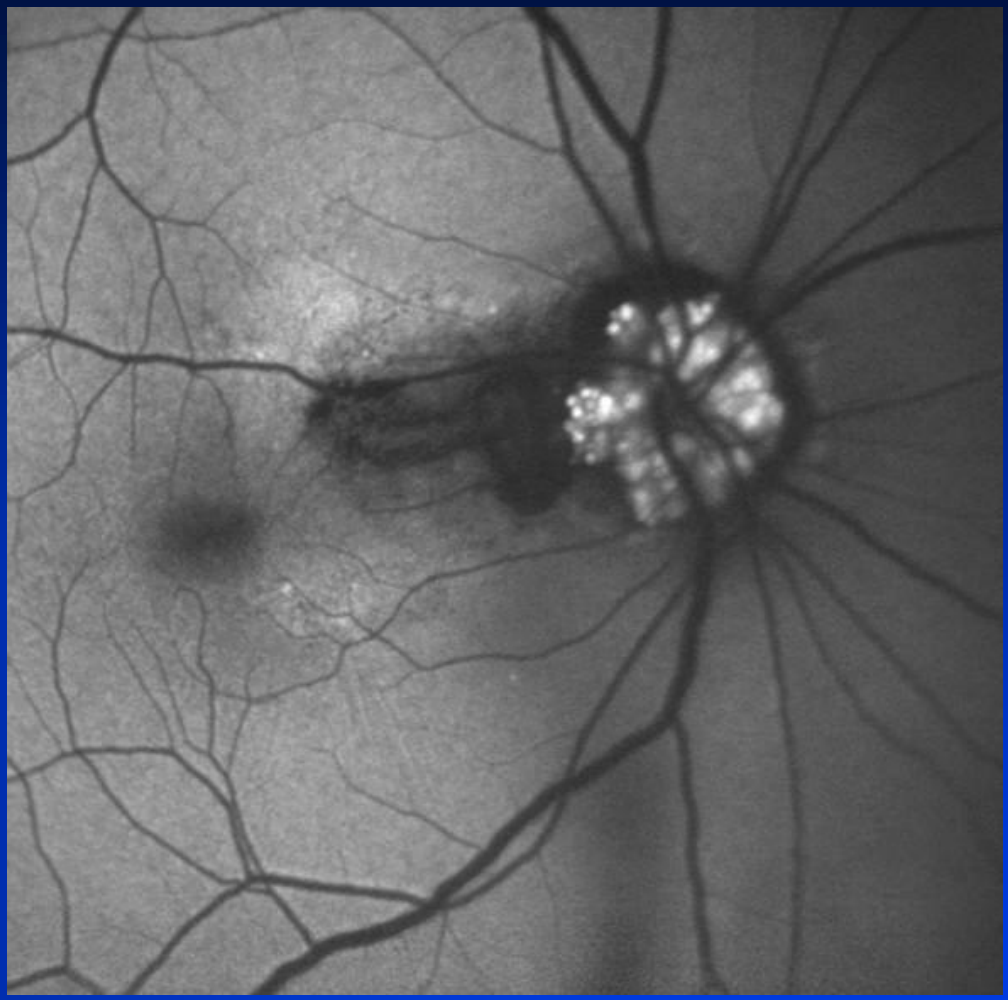

BluePeak FAF

- Heidelberg's proprietary software for FAF

Differences in Image Quality and Content

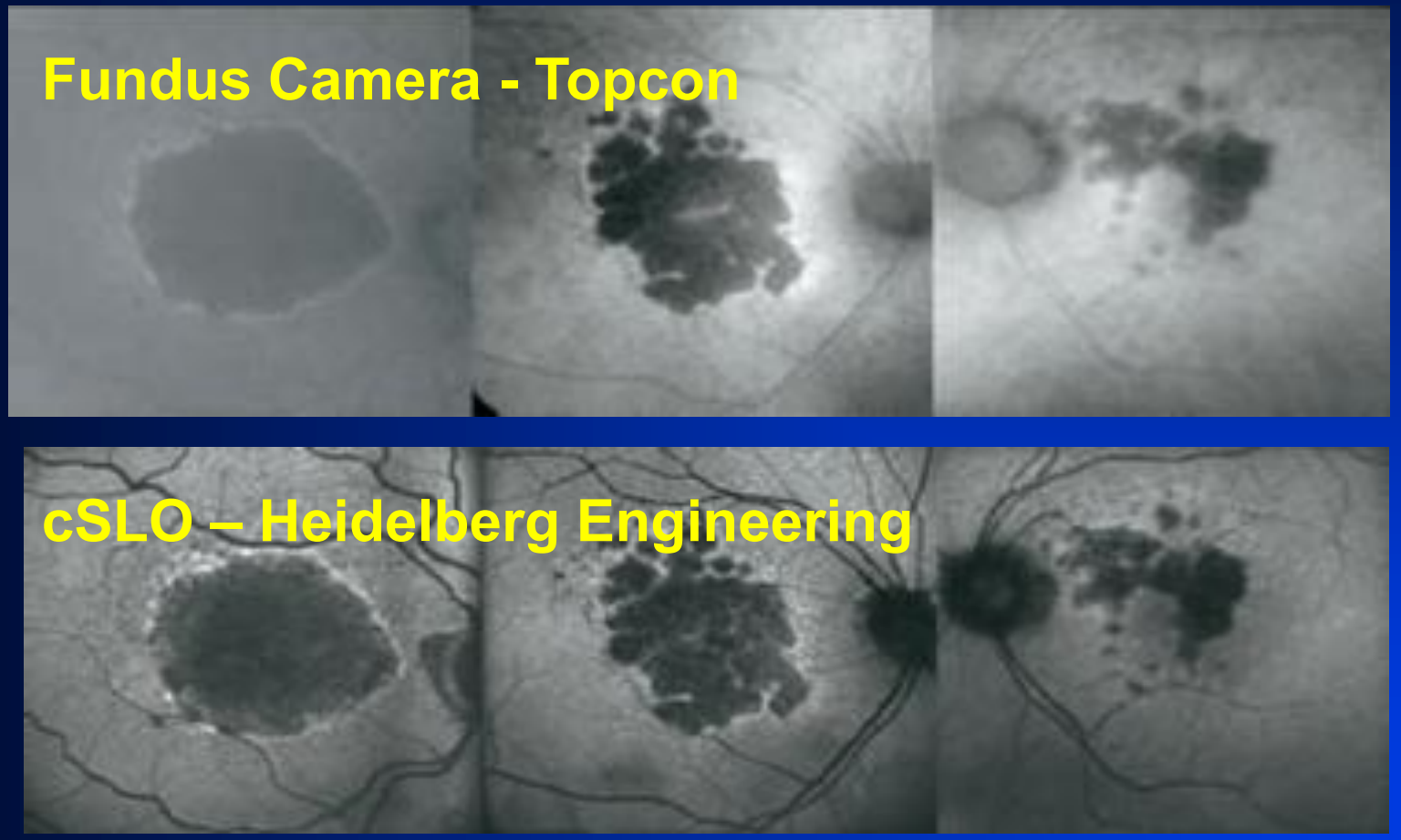

Schmitz-Valckenberg et al., Am J Ophthalmol 2008;146:183–192

BluePeak vs. Color Fundus Images

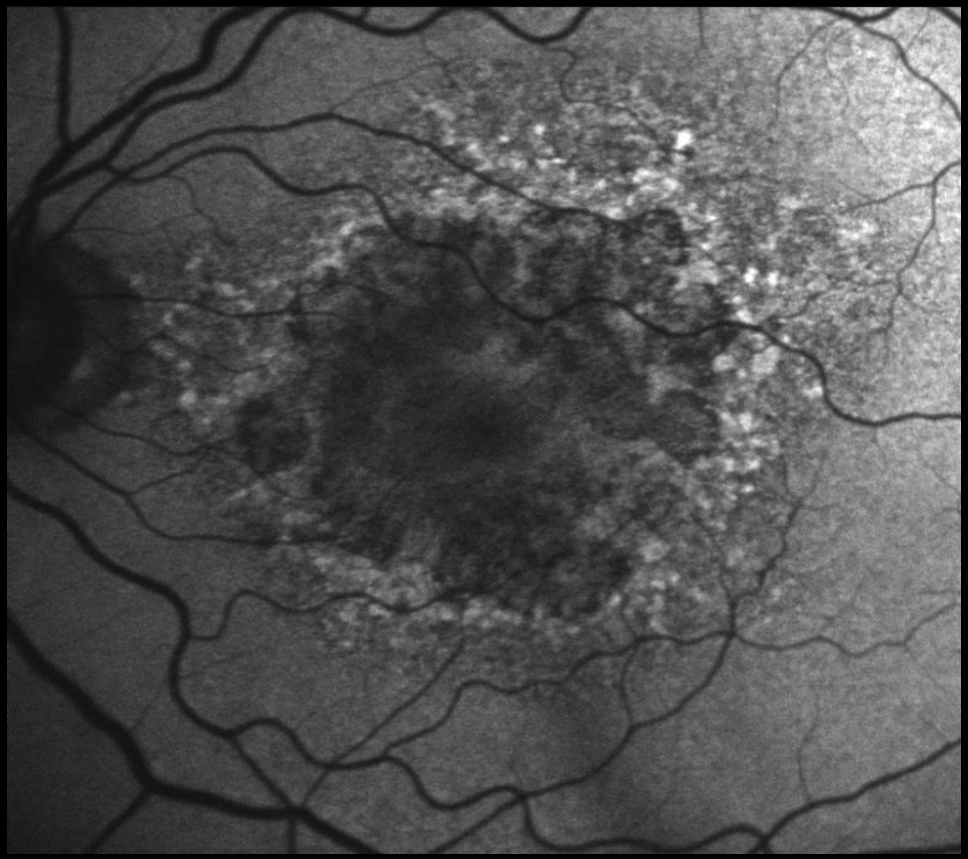

BluePeak vs. Color Fundus Images

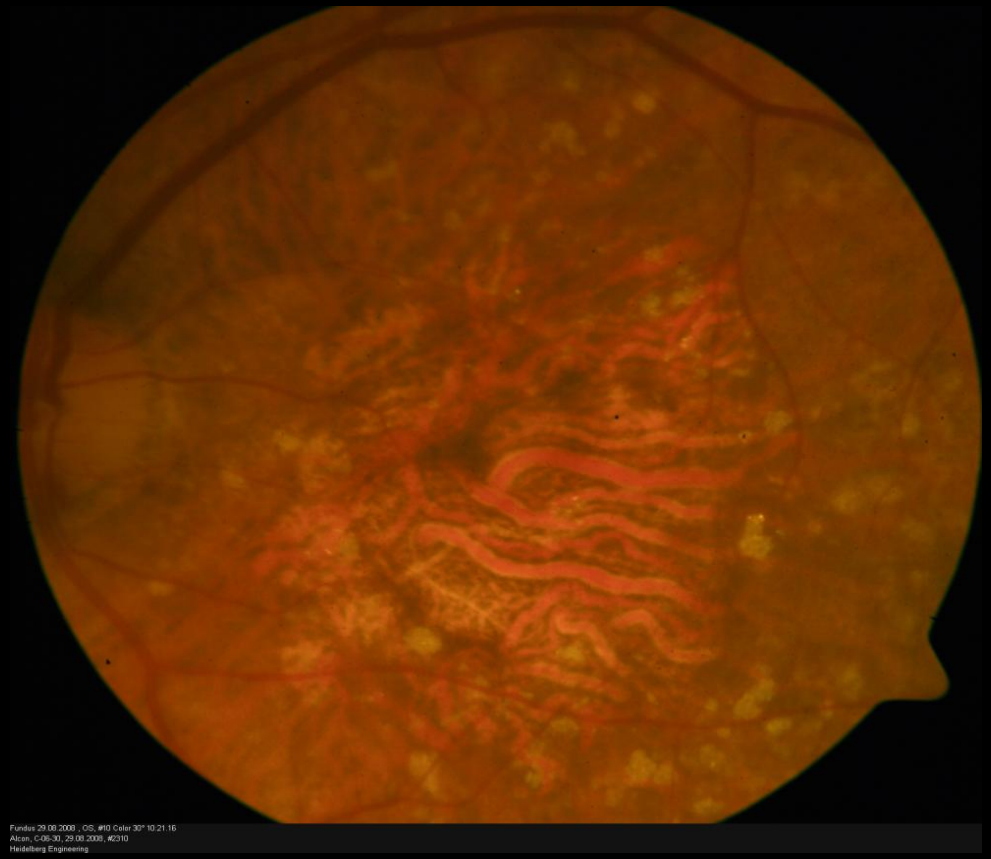

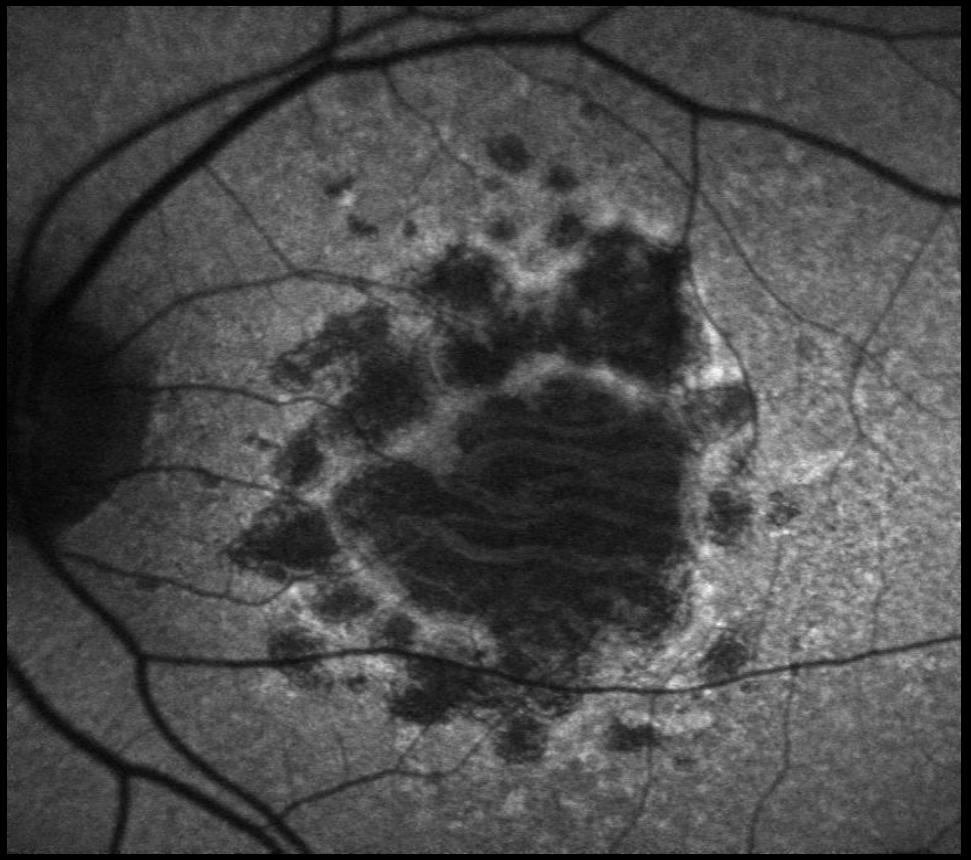

BluePeak GA Progression Over Time

- Geographic atrophy has characteristic FAF patterns
- Growth increase is mainly towards regions of increased hyperfluorescence
- Hyperfluorescence caused by lipofuscin accumulation is a prognostic factor for progression

FAF helps identify fast progressing patients for trials

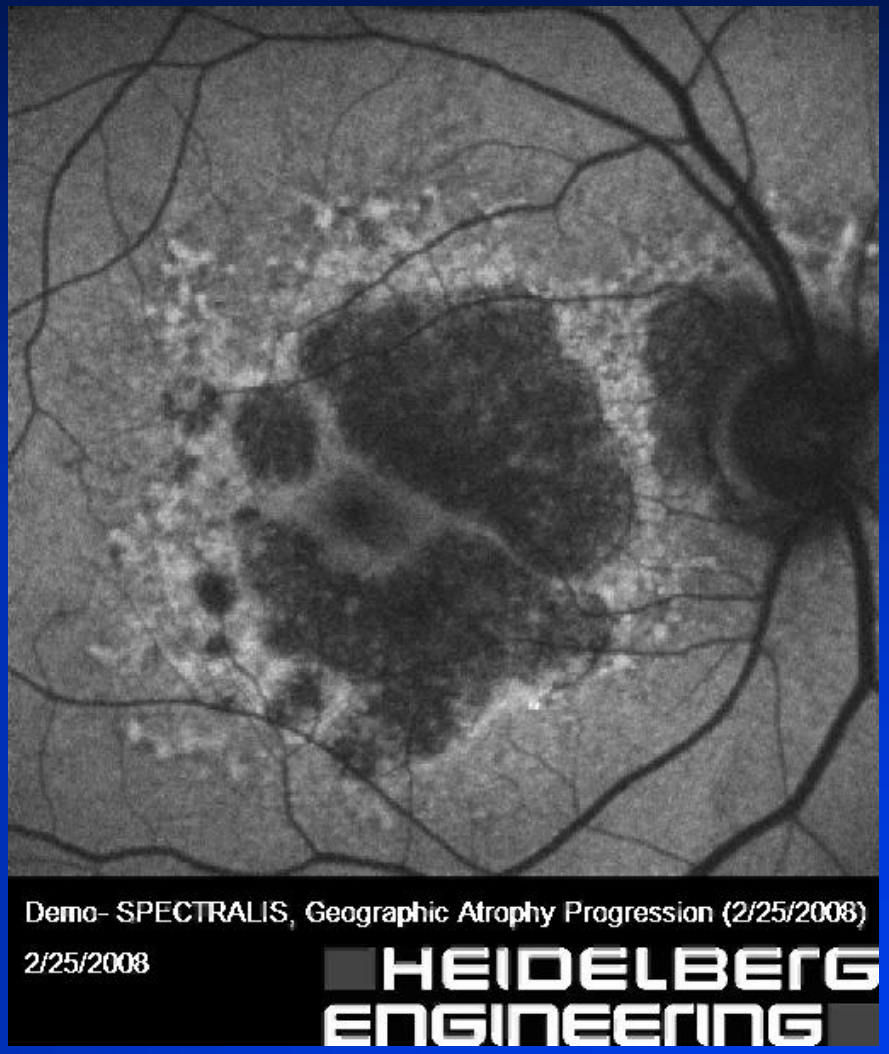

Increased hyperfluorescence in BluePeak images has been shown to correlate with higher rate of GA progression

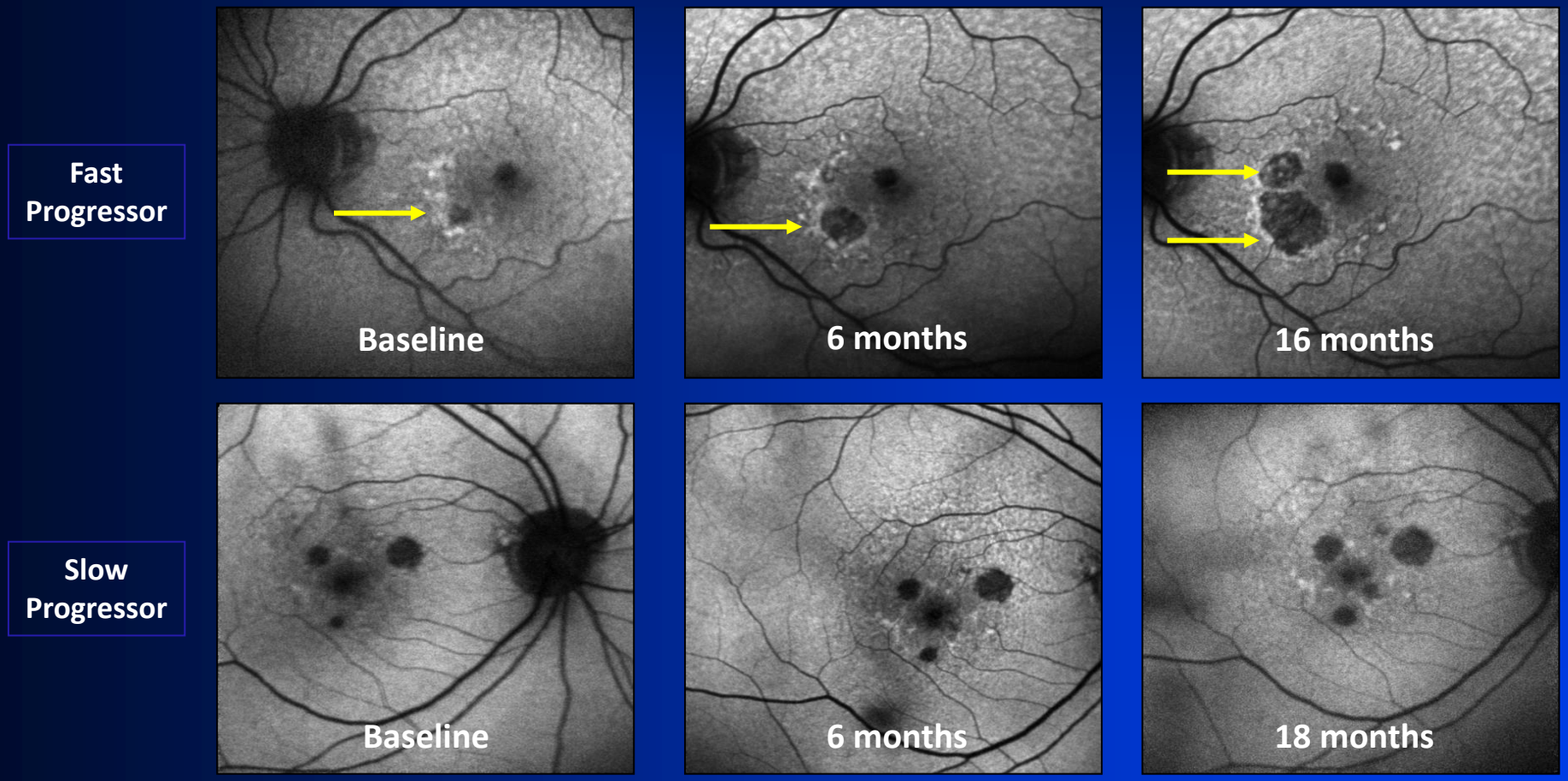

*Holz, et. al.

Different BluePeak patterns are present in GA

Diffuse Increased

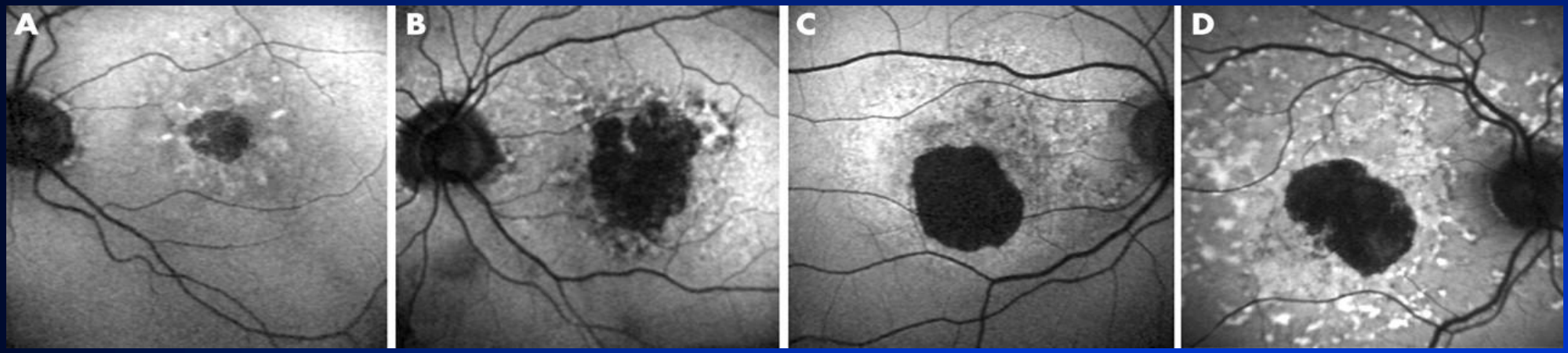

Reticular

Branching

Fine Granular

Fine Granular with punctate spots

Bindewald, BJO, 2005

BluePeak in AMD

- SD-OCT and BluePeak together "may serve as determinants of progression of geographic atrophy."[9]
- In AMD, BluePeak "FAF patterns have an impact on disease progression" and "may serve as prognostic determinants."
- BluePeak "FAF characteristics that are not identified by fundus photography or fluorescein angiography may serve as a prognostic determinant in advanced atrophic AMD."
- The development of "visual acuity is less favorable in eyes with initially increased central [BluePeak FAF signal]."

BluePeak GA Progression Over Time

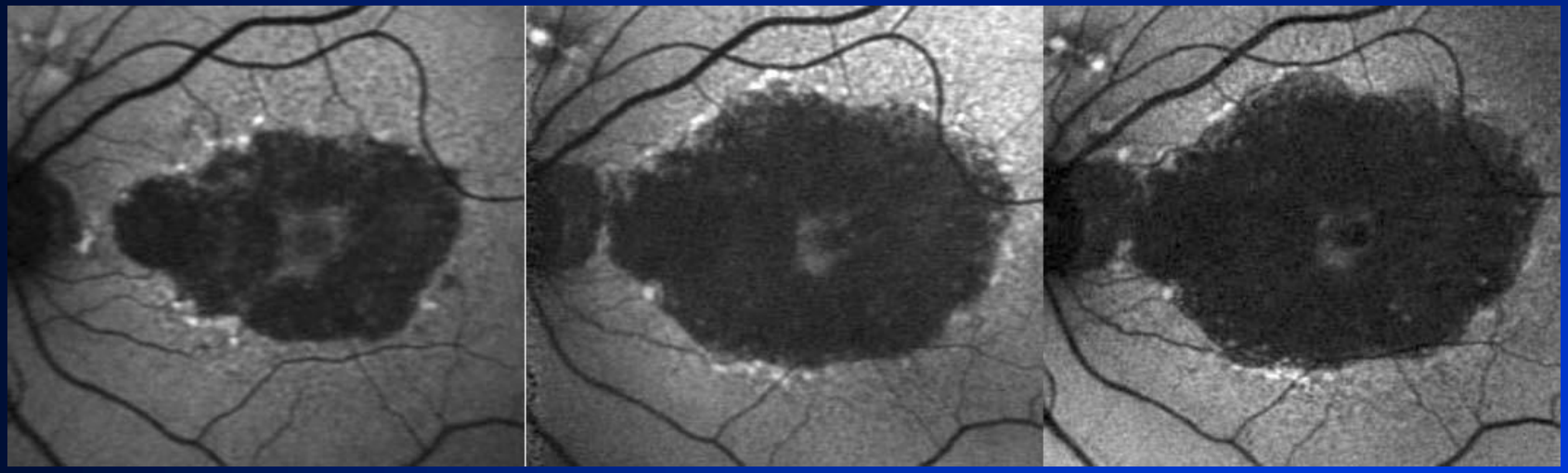

BluePeak Correlates with Visual Function

GA on FAF-images correlates with loss of retinal sensitivity

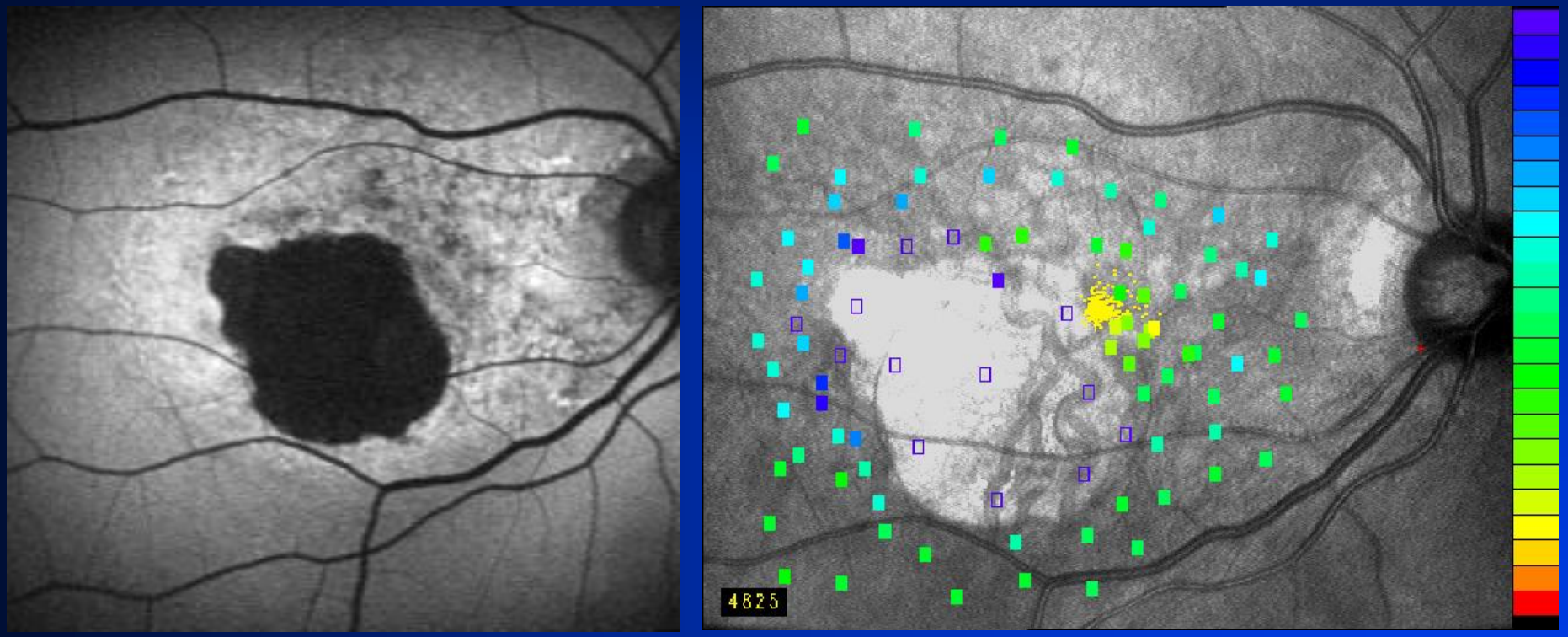

S. Schmitz-Valckenberg et al. IOVS45:4470-6,2004

SPECTRALIS® RegionFinder
Change Report

HEIDELBERG ENGINEERING

Patient: Demo- SPECTRALIS, Geographic Atrophy Progression **DOB:** 2/25/2008 **Sex:** F
Patient ID: BluePeak FAF
Diagnosis: **Comment:**

OD

Original	RegionFinder	Change from Reference

2/25/2008 Reference

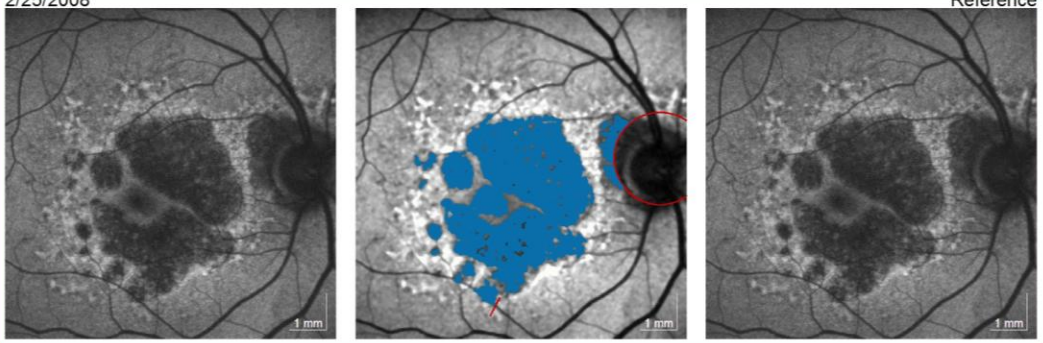

Follow-Up #1 - 10/29/2008

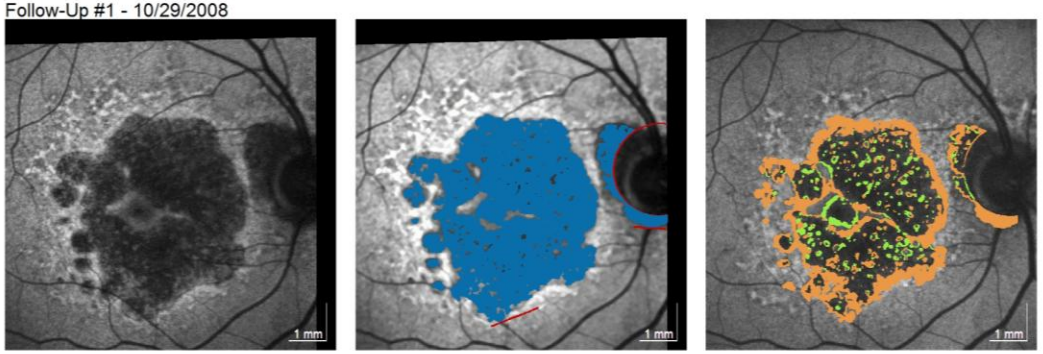

Follow-Up #2 - 2/26/2009

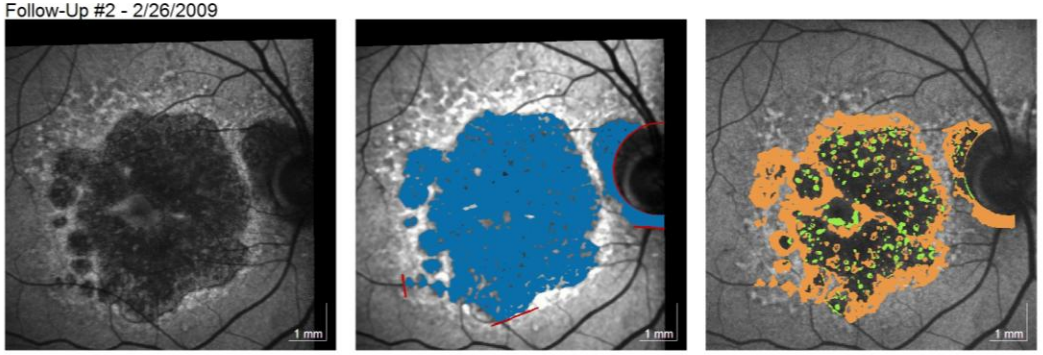

bluepeak™

SPECTRALIS® RegionFinder
Trend Report

HEIDELBERG ENGINEERING

Patient: Demo- SPECTRALIS, Geographic Atrophy Progression **DOB:** 2/25/2008 **Sex:** F
Patient ID: BluePeak FAF
Diagnosis: **Comment:**

OD

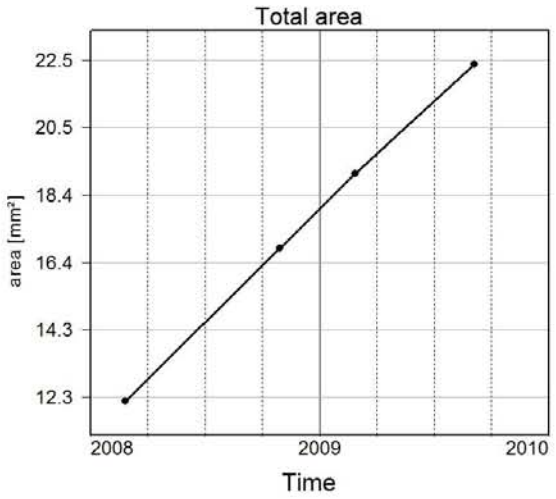

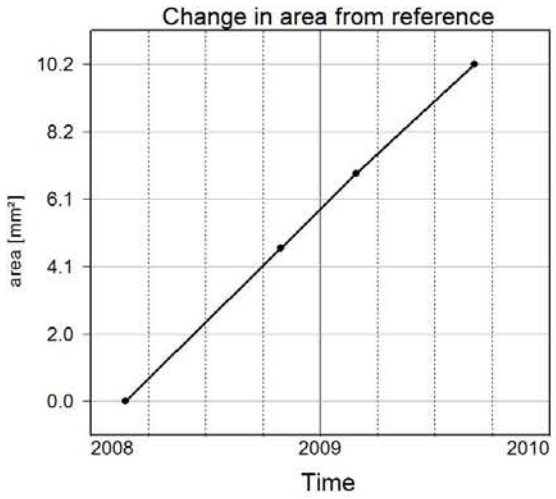

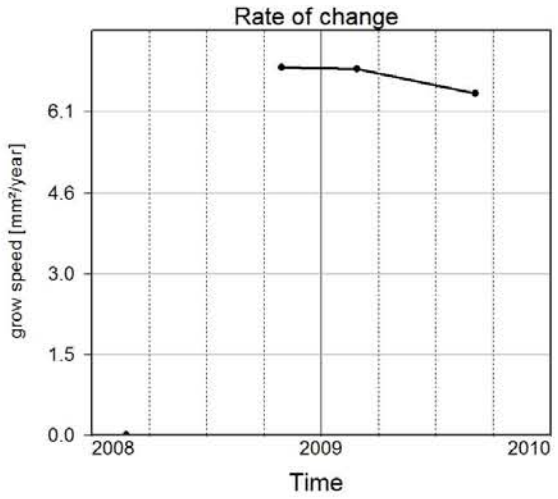

Exam Date	2/25/2008	10/29/2008	2/26/2009	9/3/2009

Original

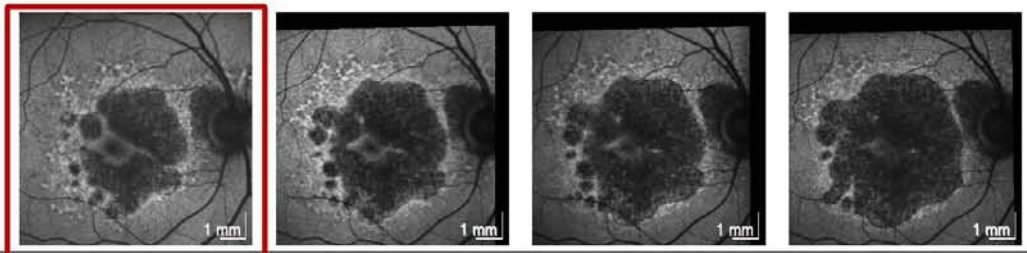

RegionFinder

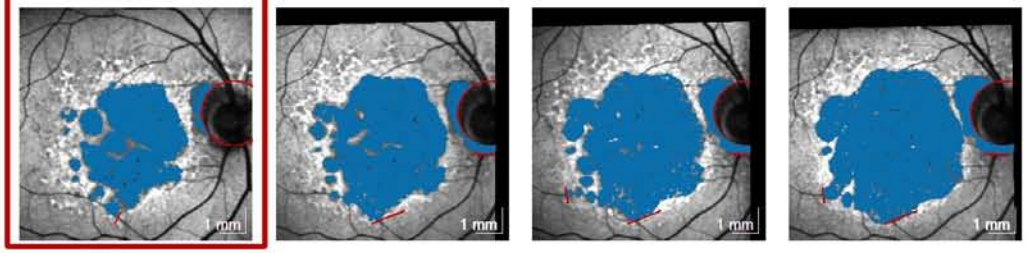

Reference

Ongoing Dry AMD Trials

Emerging Therapeutics for Dry AMD

Company/Org.	Study	Treatment		Status
Sirion		Fenretinide	(oral)	Completed
Alcon	GATE	AL-8309B	(topical)	Phase III
Acucela/Otsuka Pharmaceutical	ENVISION	ACU-4429	(oral)	Phase II
Alexion	COMPLETE	Eculizumab	(systemic IV)	Phase II
Allergan		Brimonidine	(implant)	Phase II
Neurotech		NT-501	(implant)	Phase II
Othera	OMEGA	OT-551	(topical)	Phase I
Quark/Pfizer		PF-04523655/RTP801i.14	(intravitreal)	Phase I
Genentech		FCFD4514S	(intravitreal)	Phase I
Ophthtech		ARC1905		Phase I
Optherion				Phase I
Pfizer		RN6G	(systemic IV)	Phase I
Alimera		Medidur FA		
OcuCure Therapeutics Inc.		OC-10X	(topical)	
Oak Park Natl Laboratory	TORPA	Photobiomodulation		
NEI		Sirolimus		
NEI	AREDS II	Antioxidants		
NY Eye & Ear		Copaxone vaccinations		

Updated: Sep 2010

COMPLETE Study

- COMPLement Inhibition with Eculizumab for the Treatment of Non-Exudative Age-Related Macular Degeneration Study
- Investigator Sponsored Trial
- FDA IND #104471: Approved
- IRB: Approved
- Duration: 12 months
- Single center, randomized, prospective, controlled trial

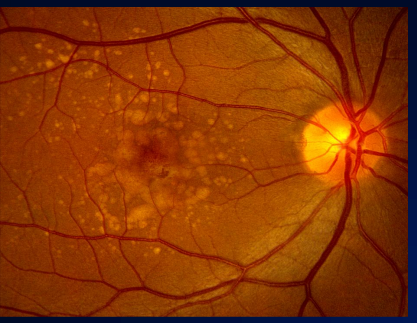

COMPLETE Study Design

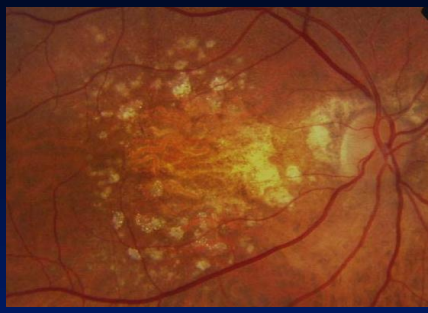

Phase II COMPLETE Study: Bascom Palmer Eye Institute

Inclusion:

High Risk Drusen

OR

Geographic Atrophy

Drusen Cohort
N = 30
2:1 Randomization

Eculizumab/Placebo

26 weeks

GA Cohort
N = 30
2:1 Randomization

Follow-up through one year

RECRUITING PATIENTS WITH VISION OF 20/63 OR BETTER

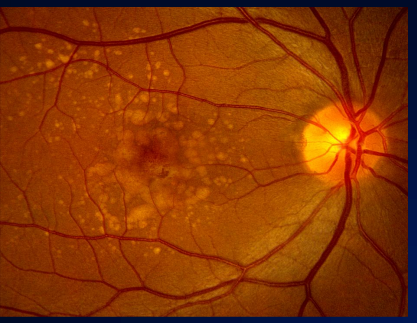

COMPLETE Study Design

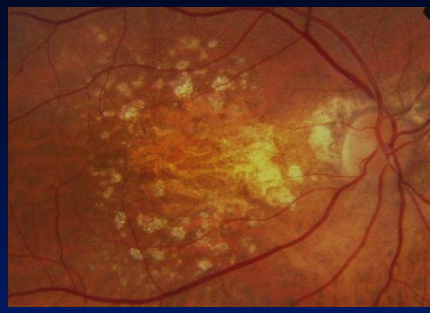

Phase II COMPLETE Study:
Bascom Palmer Eye Institute

Drusen Cohort
N = 30

Drusen volume ≥ 0.050 mm^3

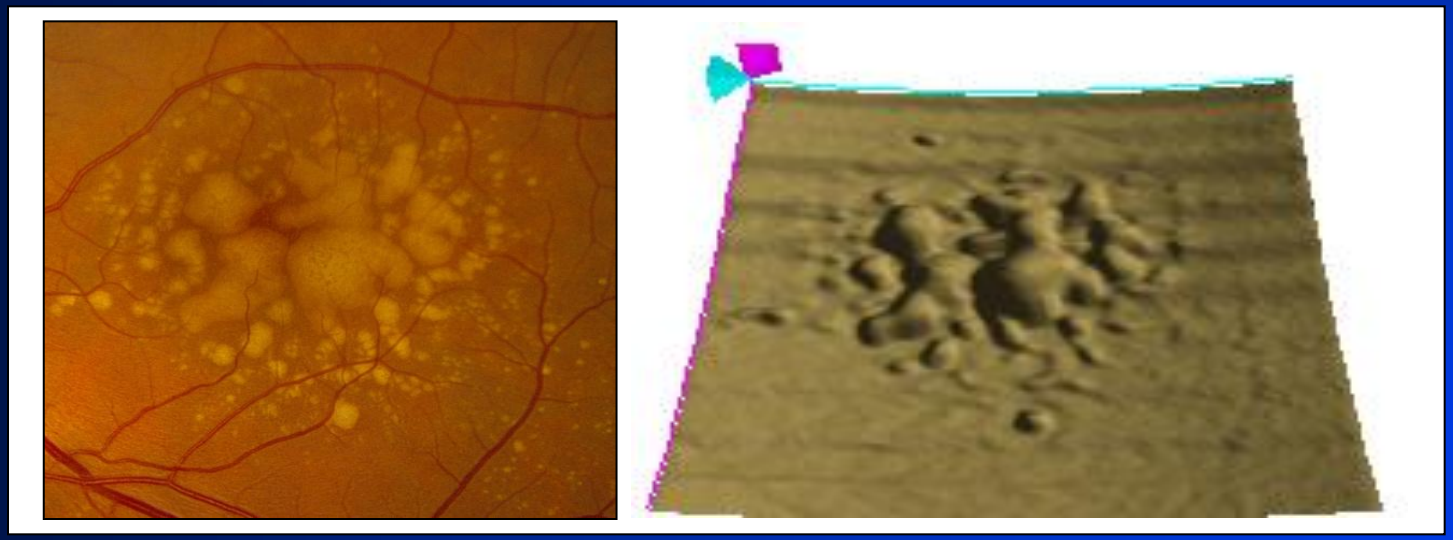

Color Fundus

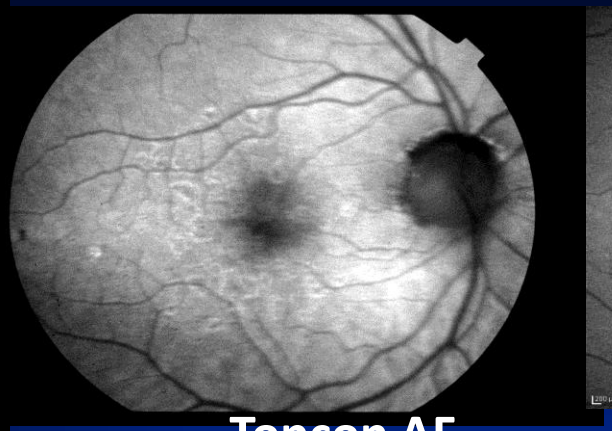

Topcon AF

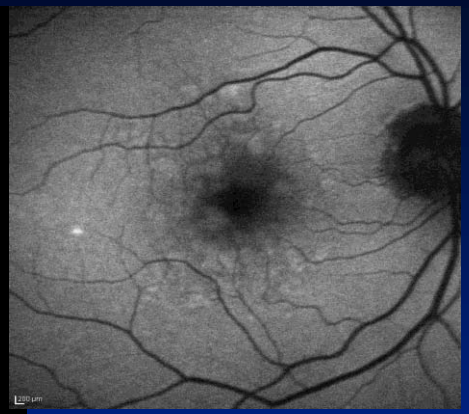

Heidelberg AF

Fluorescein angiography

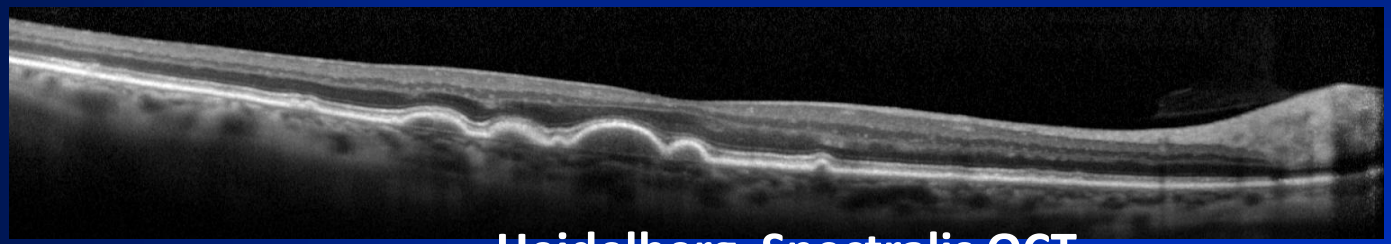

Heidelberg Spectralis OCT

Zeiss Cirrus OCT

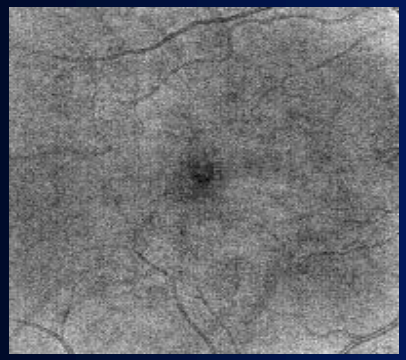

OCT Fundus Image

RPE map

3 mm circle

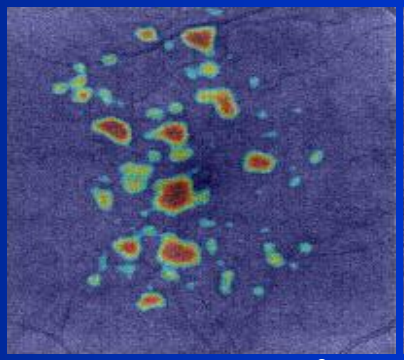

Area : 4.29 mm^2

Vol : 0.2084 mm^3

5 mm circle

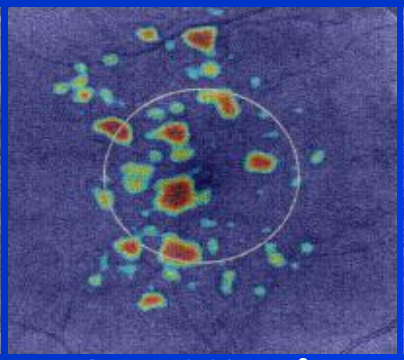

Area : 2.28 mm^2

Vol : 0.1184 mm^3

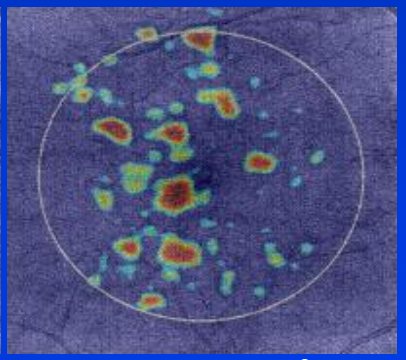

Area : 4.02 mm^2

Vol : 0.1973 mm^3

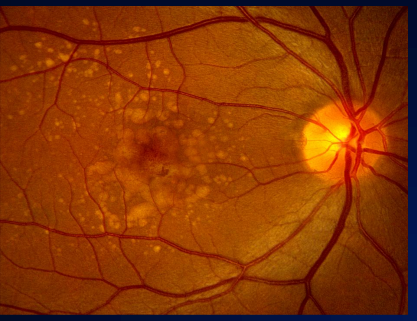

COMPLETE Study Design

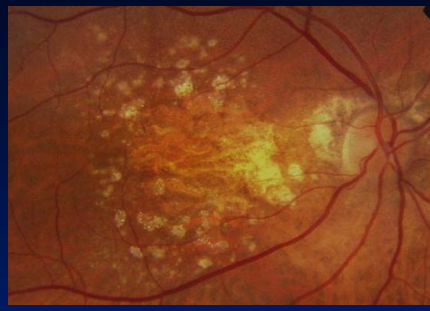

Phase II COMPLETE Study:
Bascom Palmer Eye Institute

GA Cohort
N = 30

GEOGRAPHIC ATROPHY (> 0.5 disc area)

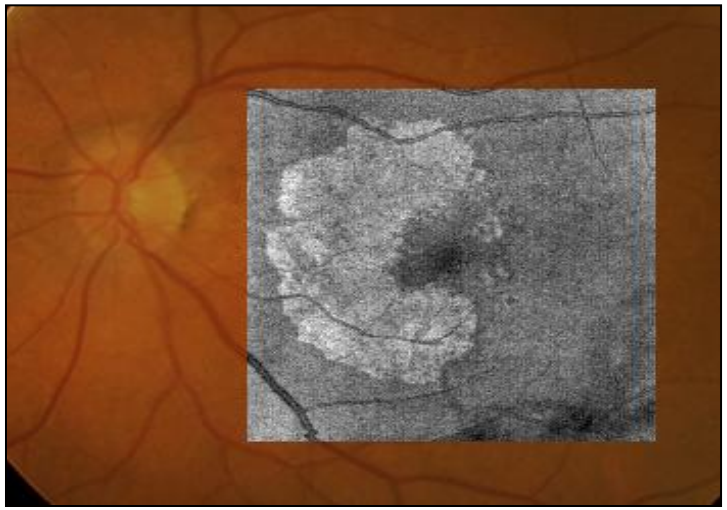

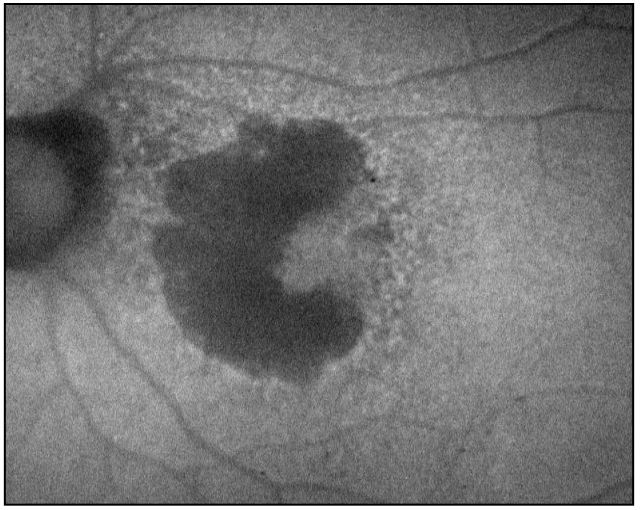

Color Fundus

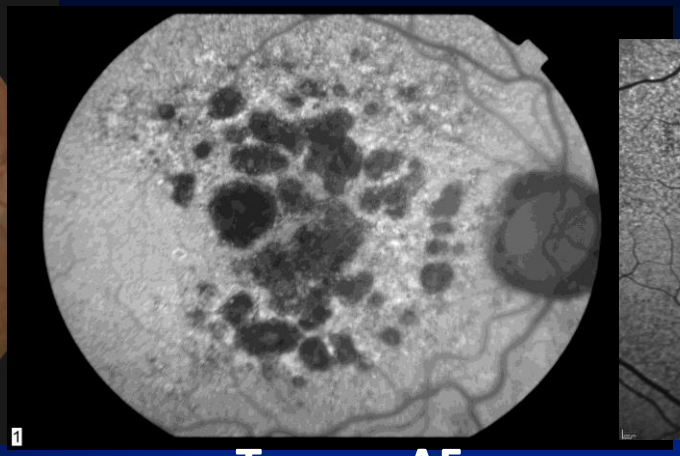

Topcon AF

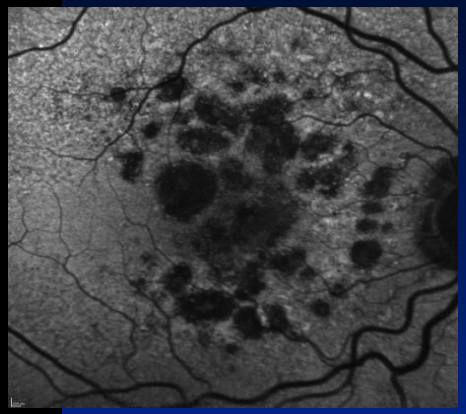

Heidelberg AF

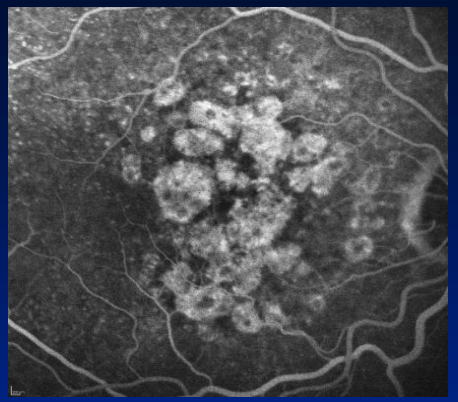

Fluorescein angiography

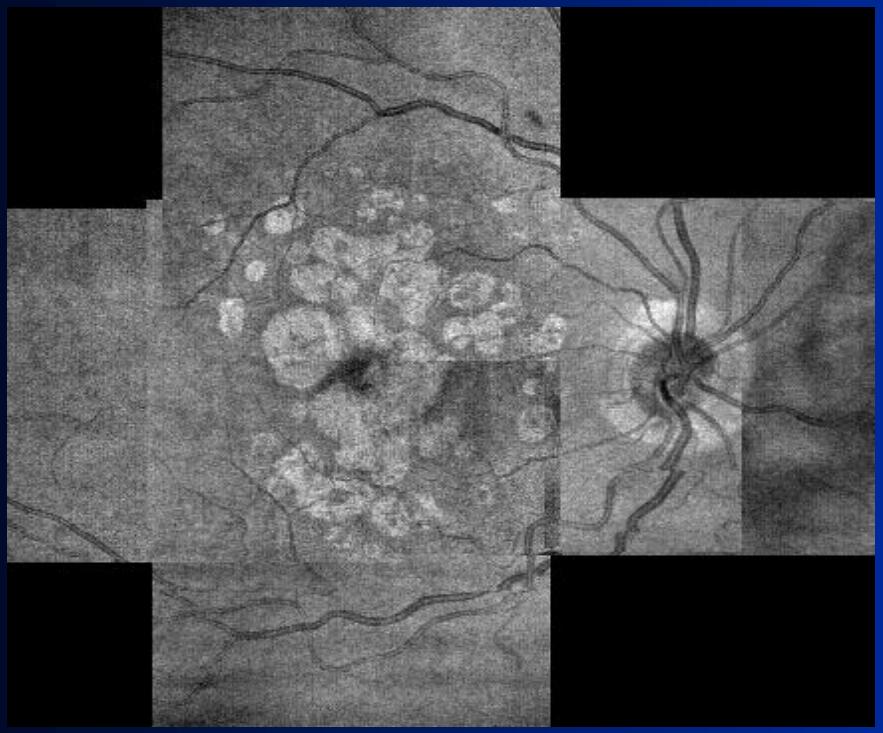

Zeiss Cirrus OCT Fundus Image

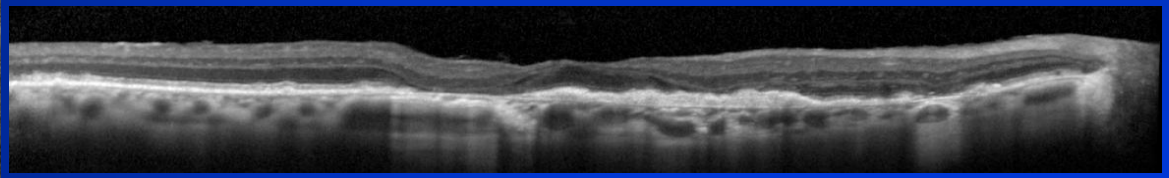

Heidelberg Spectralis OCT

Clinical Application…

…for the “Blue Collar, Lunch Pain Optometrist”

54 y/o Hisp Male

⬇ VA RE X 10 Yrs

20/400

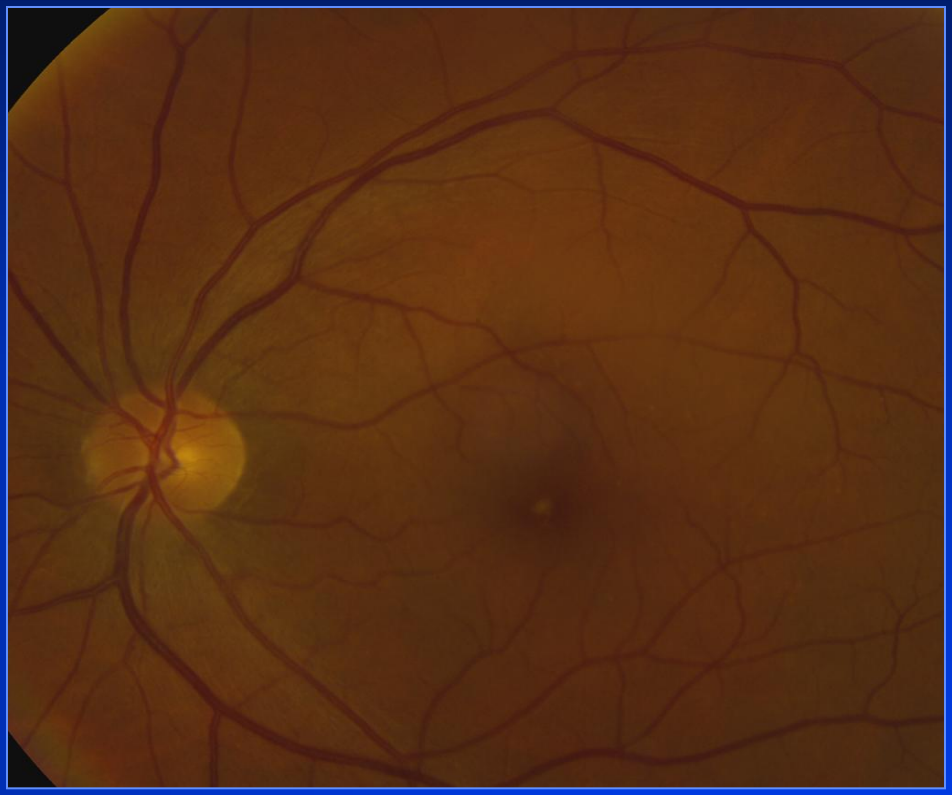

20/20

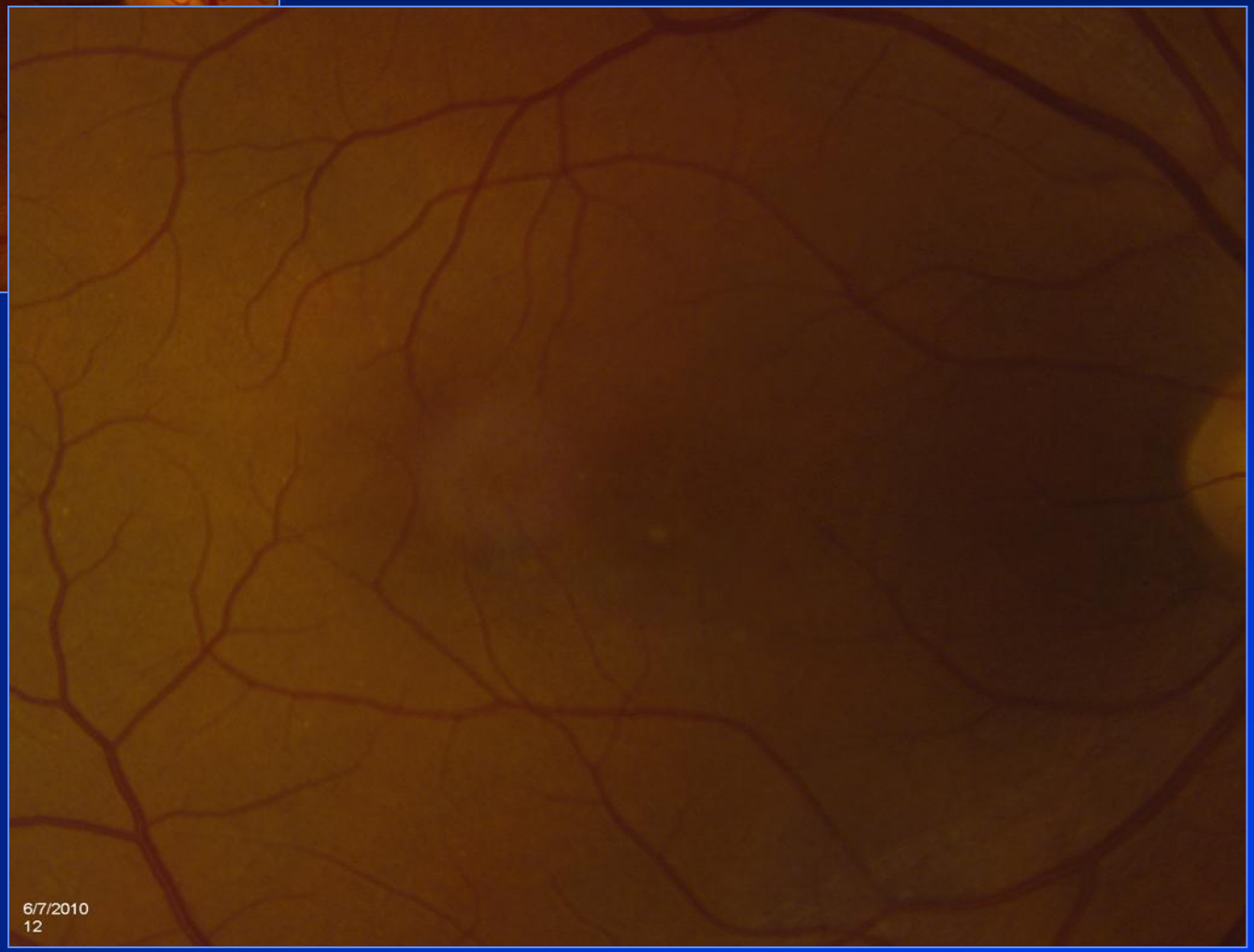
6/7/2010
12

High Definition Images: HD 5 Line Raster

OD ● ○

Scan Angle: 0° Spacing: 0.25 mm Length: 6 mm

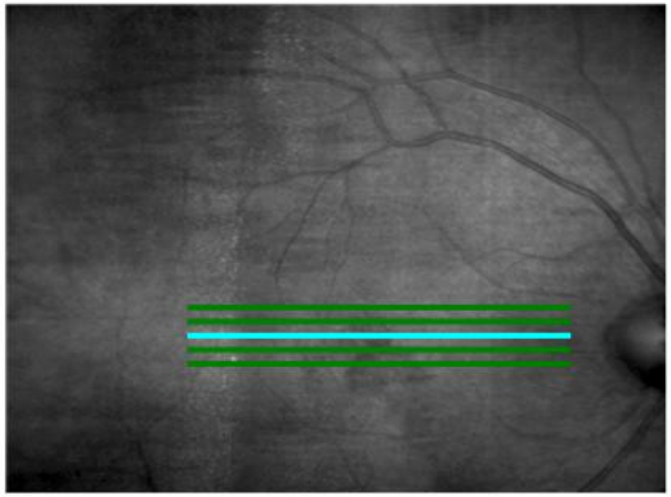

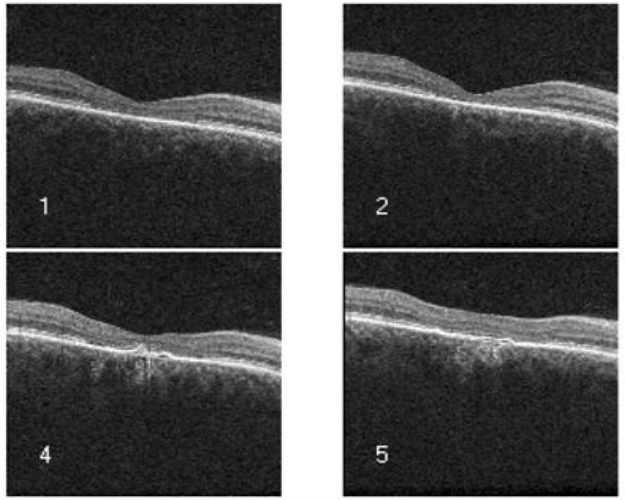

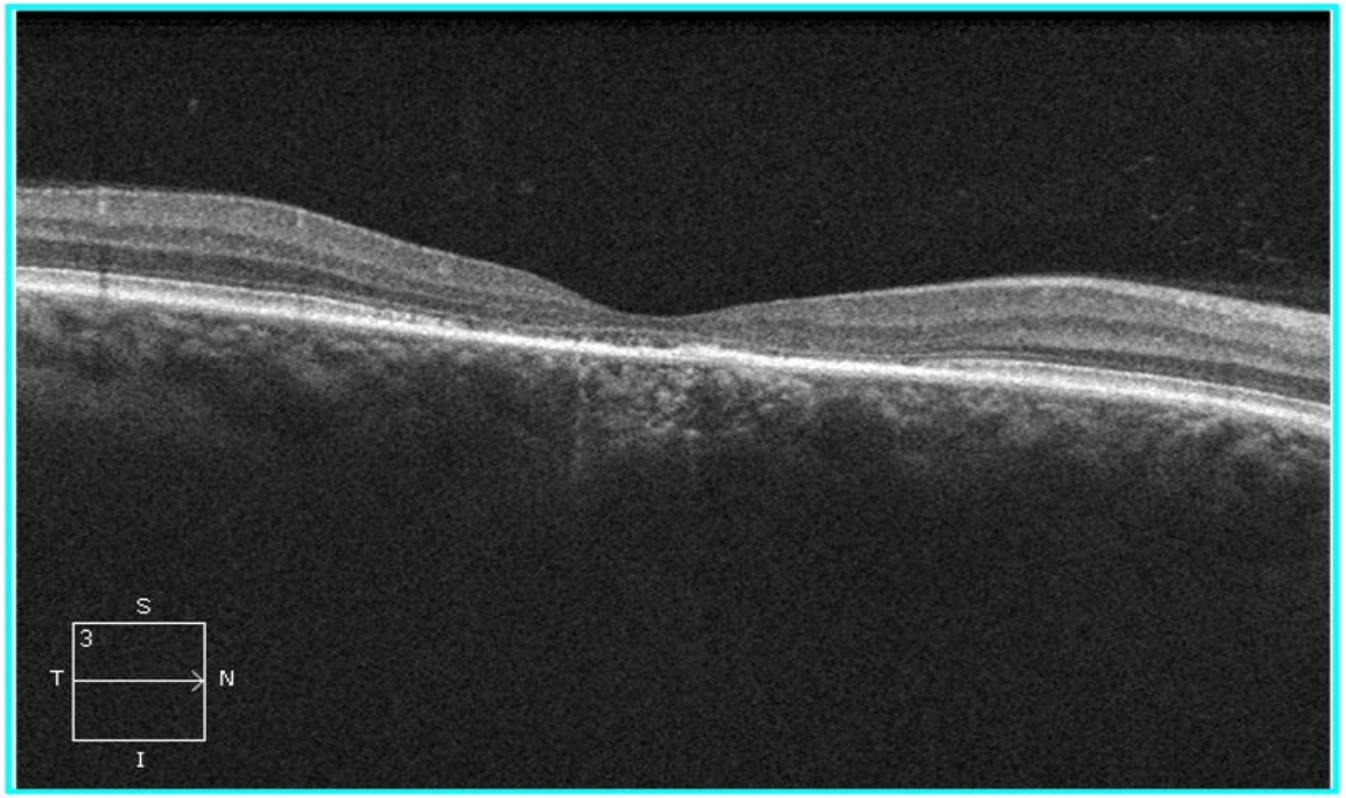

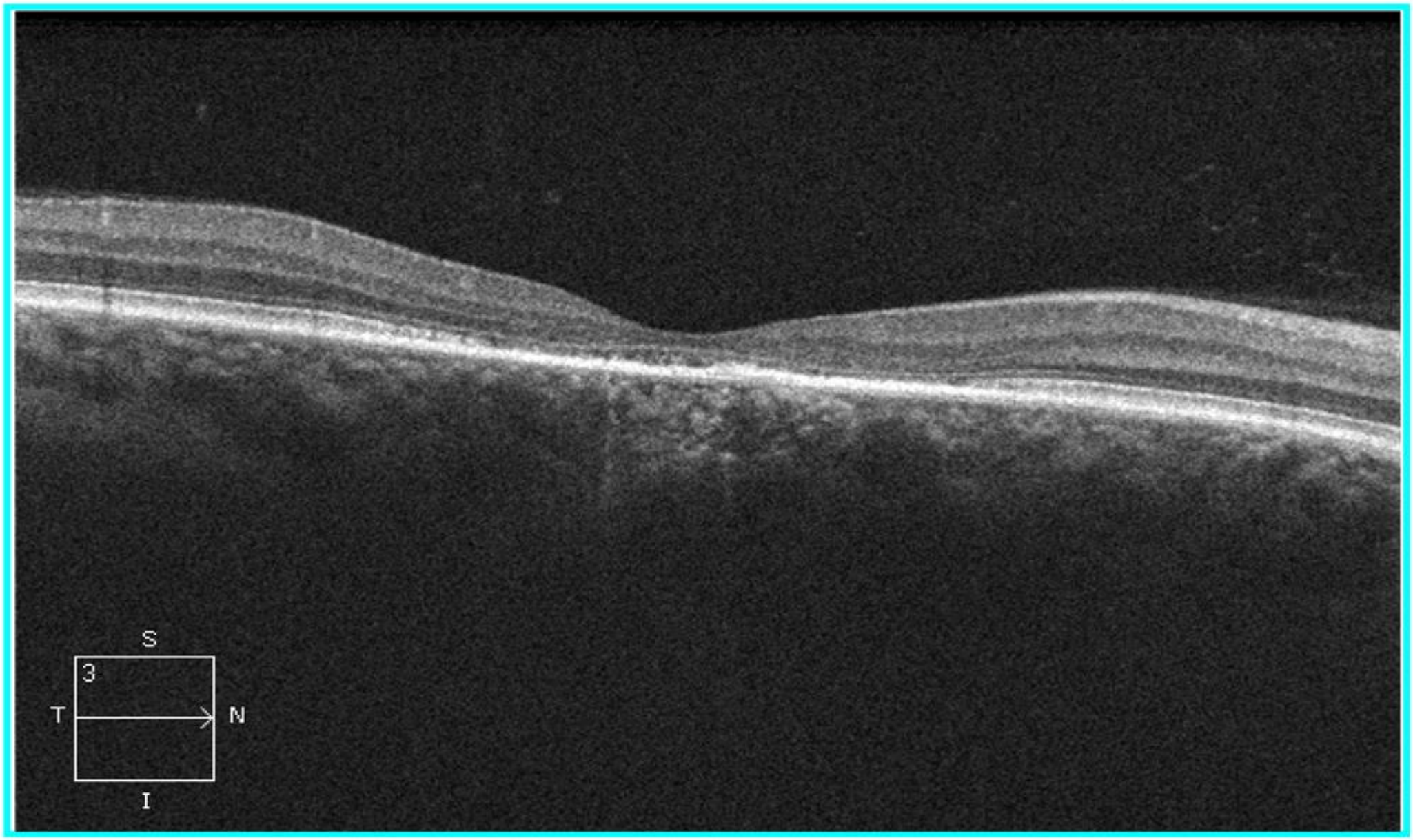
S
3
T
N
I

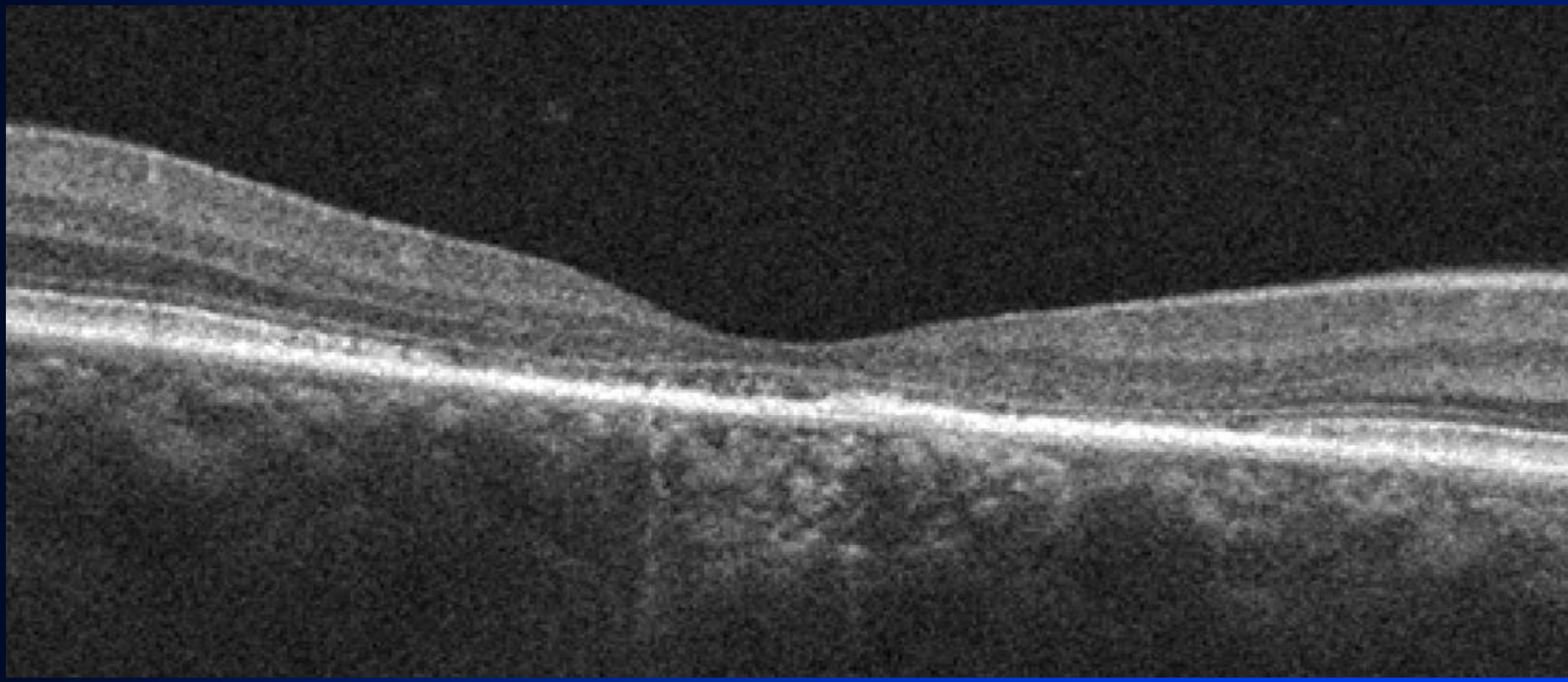

Macula Thickness : Macular Cube 200x200

OD ● ○ OS

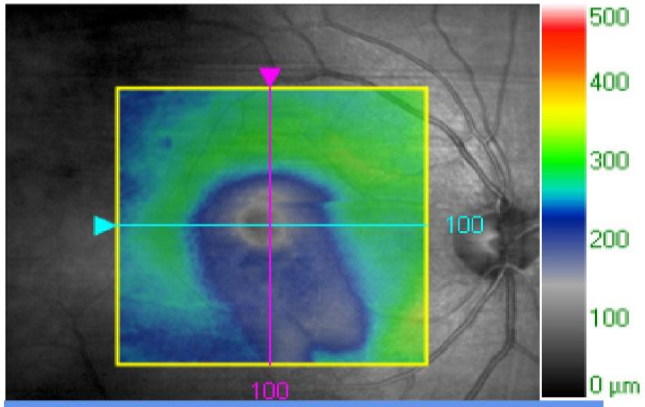

Overlay: ILM - RPE Transparency: 50 %

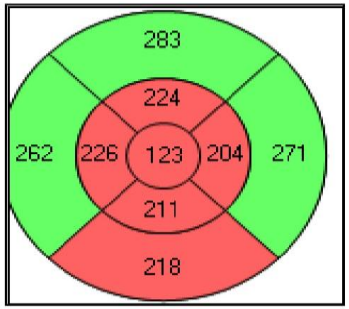

ILM-RPE Thickness (µm)

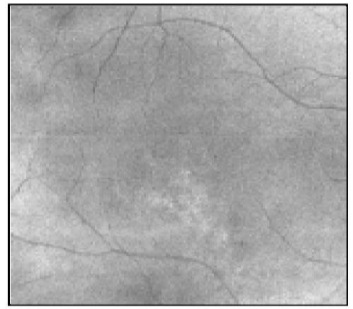

Fovea: 92, 100

High-definition mode

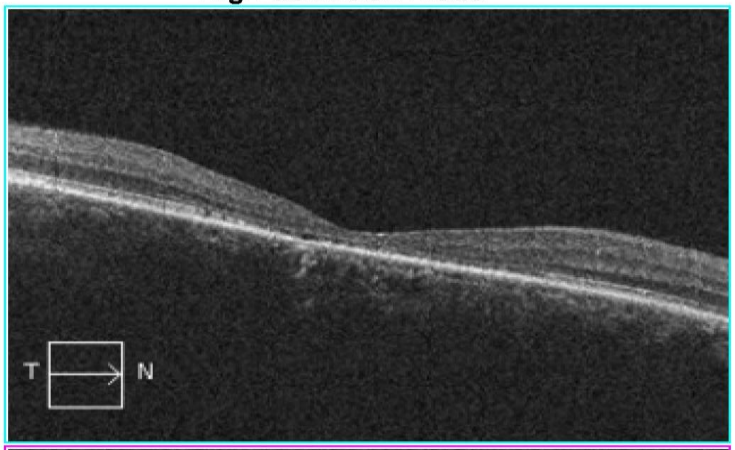

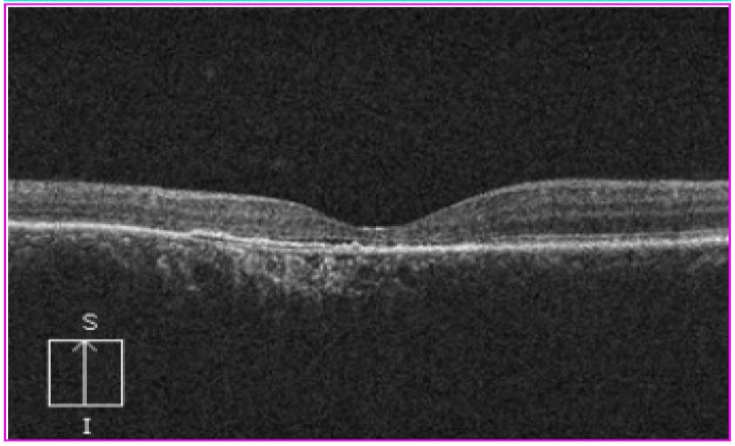

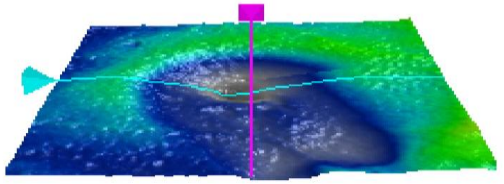

ILM - RPE

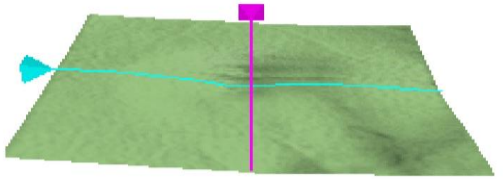

ILM

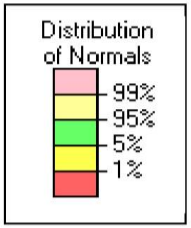

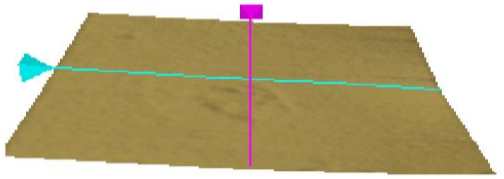

RPE

	Central Subfield Thickness (µm)	Cube Volume (mm³)	Cube Average Thickness (µm)
ILM - RPE	123	9.0	250

Macula Thickness : Macular Cube 200x200

OD ○ | ● OS

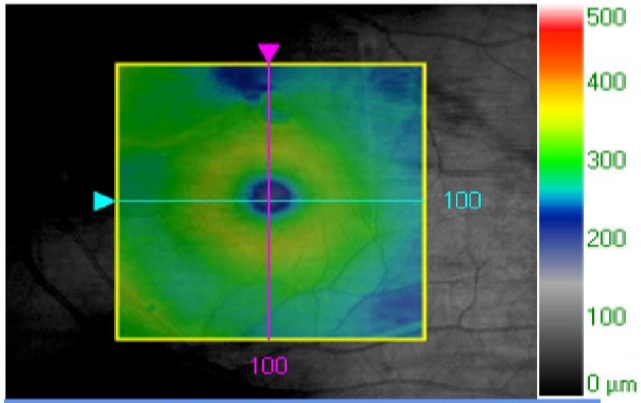

Overlay: ILM - RPE Transparency: 50 %

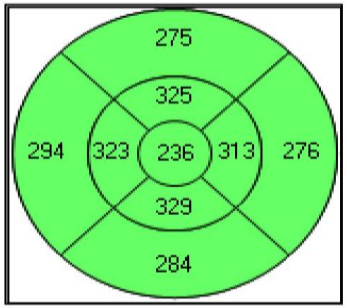

ILM-RPE Thickness (µm)

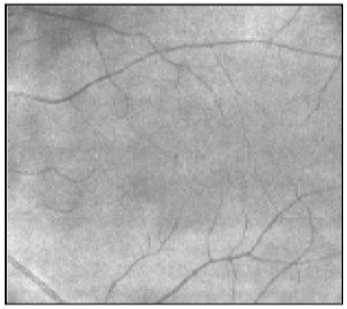

Fovea: 100, 98

High-definition mode

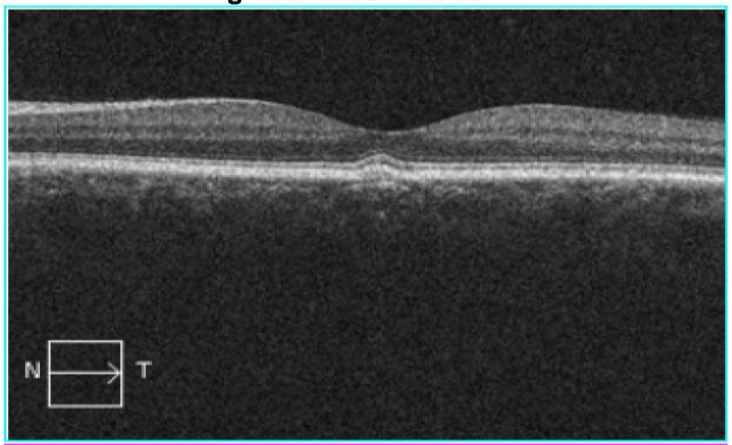

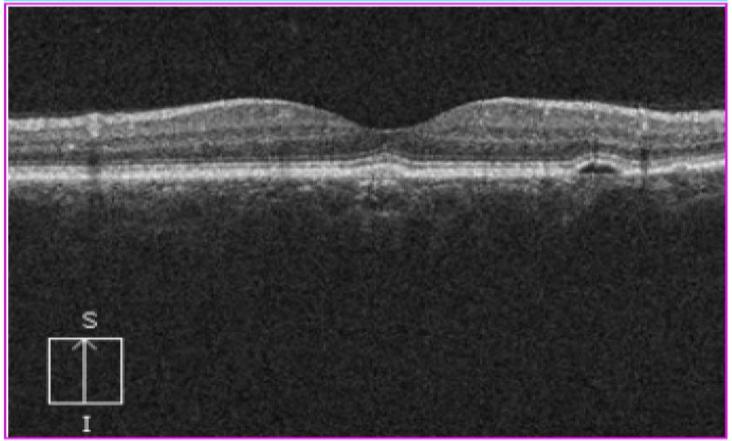



ILM - RPE

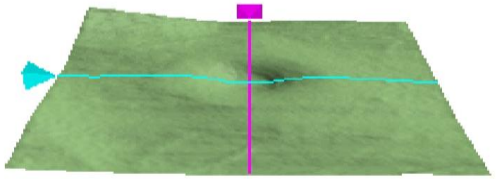

ILM

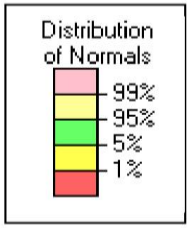



RPE

	Central Subfield Thickness (µm)	Cube Volume (mm³)	Cube Average Thickness (µm)
ILM - RPE	236	10.3	286

Diagnosis?

Central Serous Chorioretinopathy (CSR)

52 y/o Hispanic Male
20/30

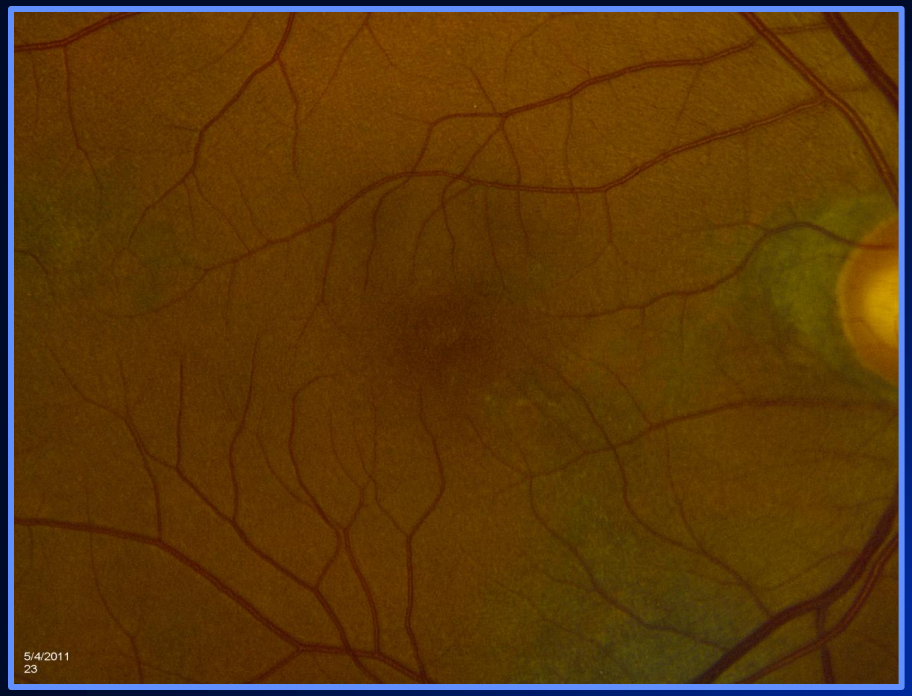
5/4/2011
23

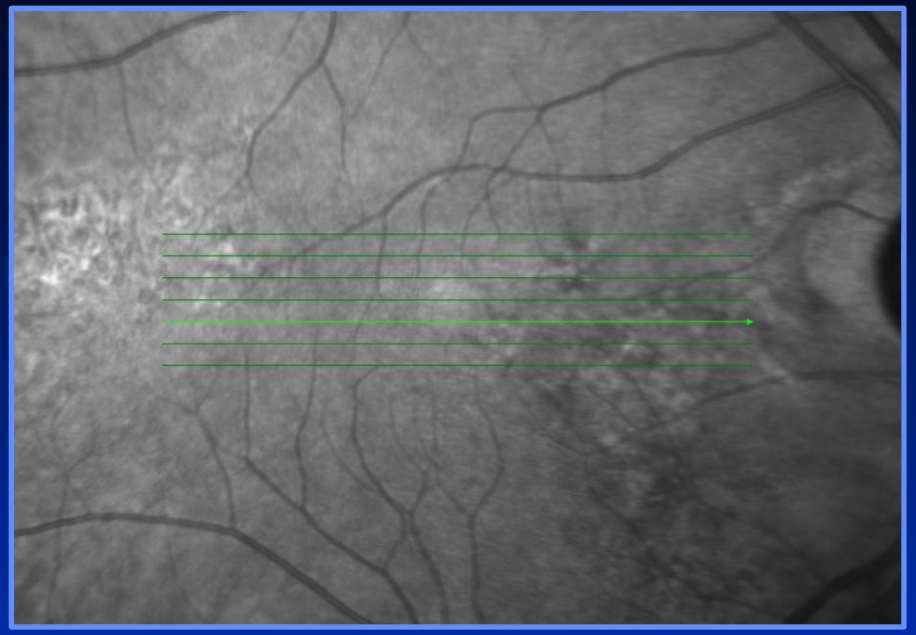

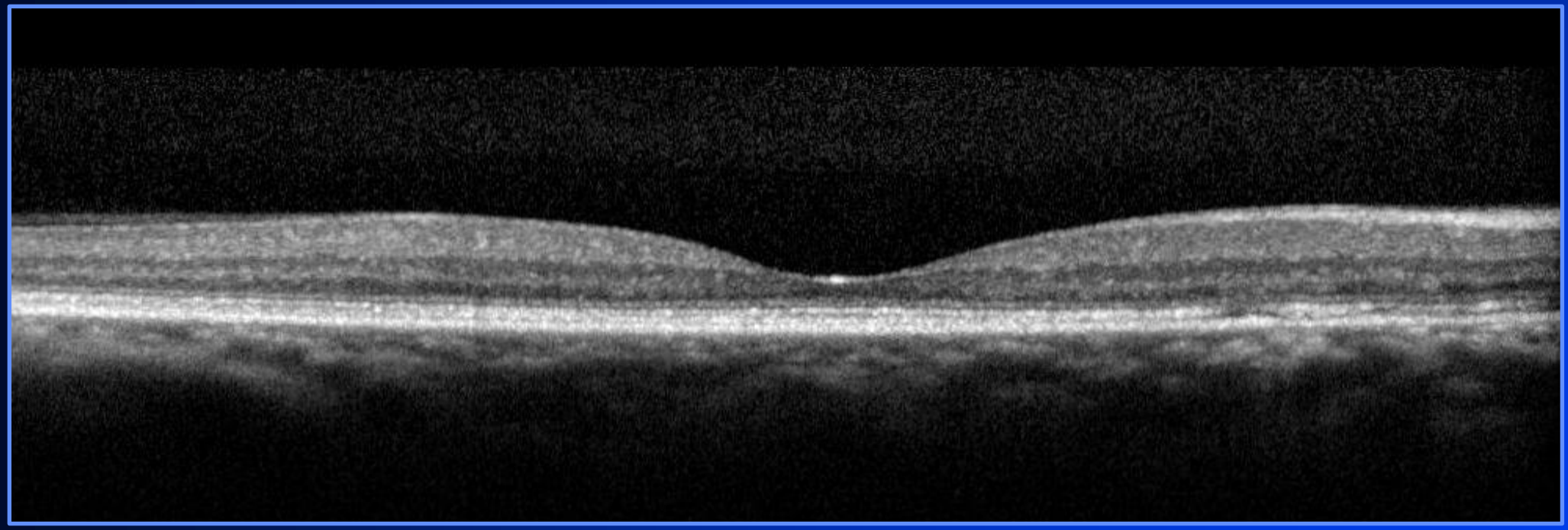

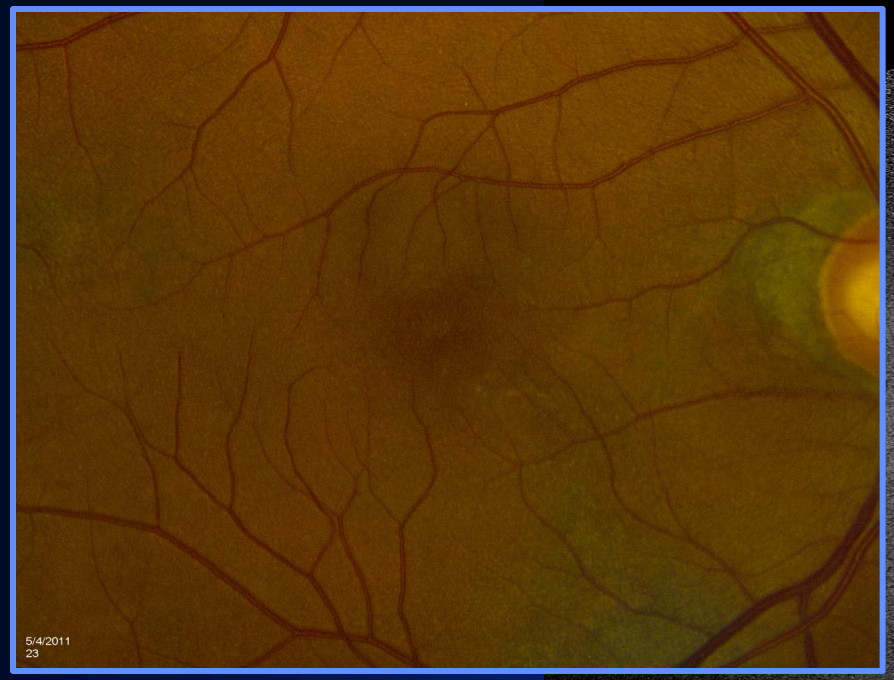

FAF

200 µm

5/4/2011, OD
AF 55° ART(7)

HEIDELBERG ENGINEERING

52 y/o Hispanic Male
20/30

56 y/o Hispanic Male: Long standing decreased VA RE

Recent blurred VA/Met LE

4/3/2012
10

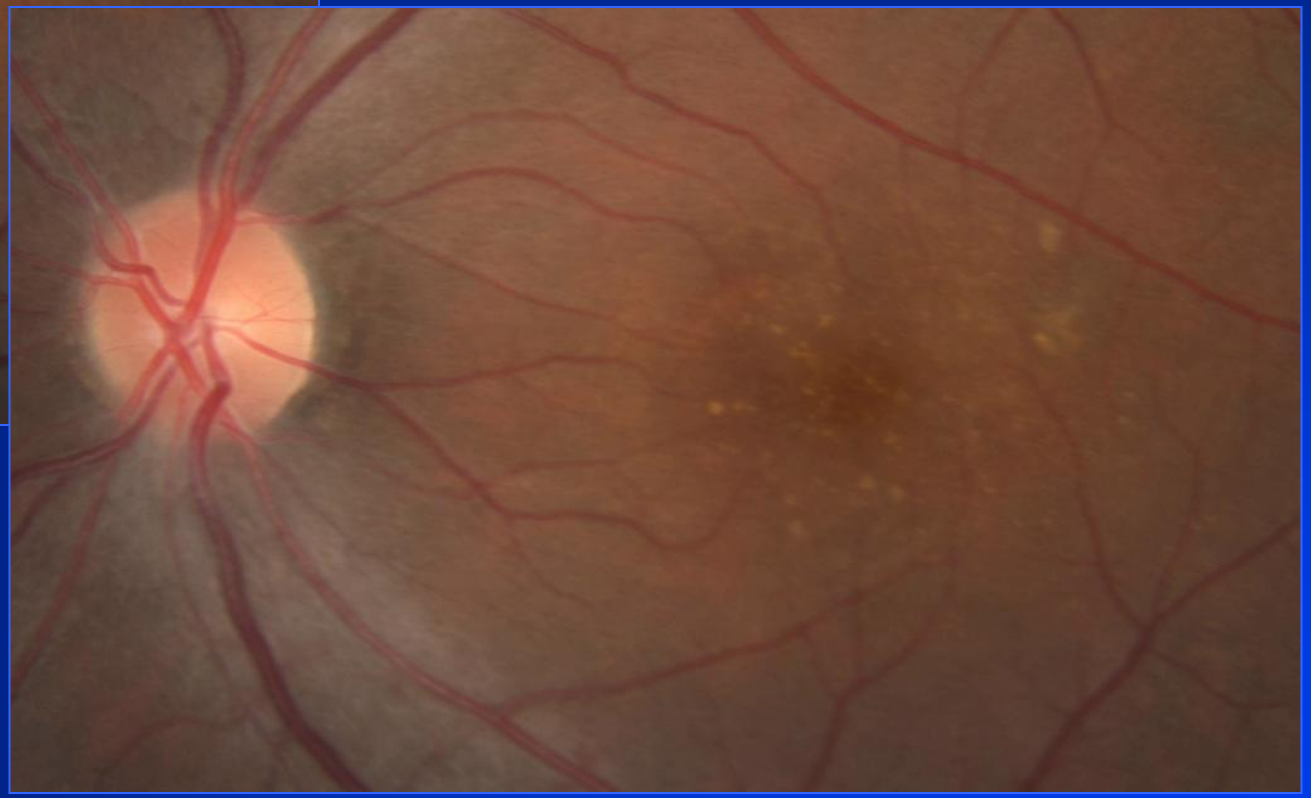

Doctor: Signal Strength: 6/10

High Definition Images: 5 Line Raster

OD ● ○ OS

Scan Angle: 0° Spacing: 0.25 mm Length: 6 mm

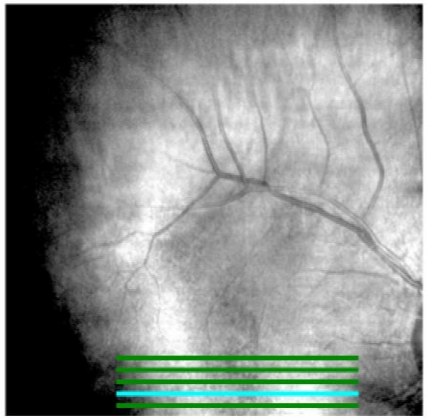

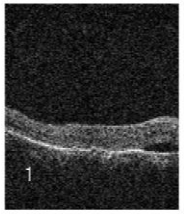

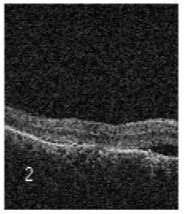

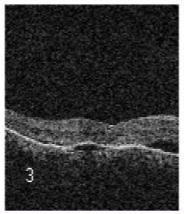

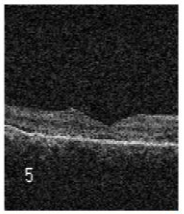

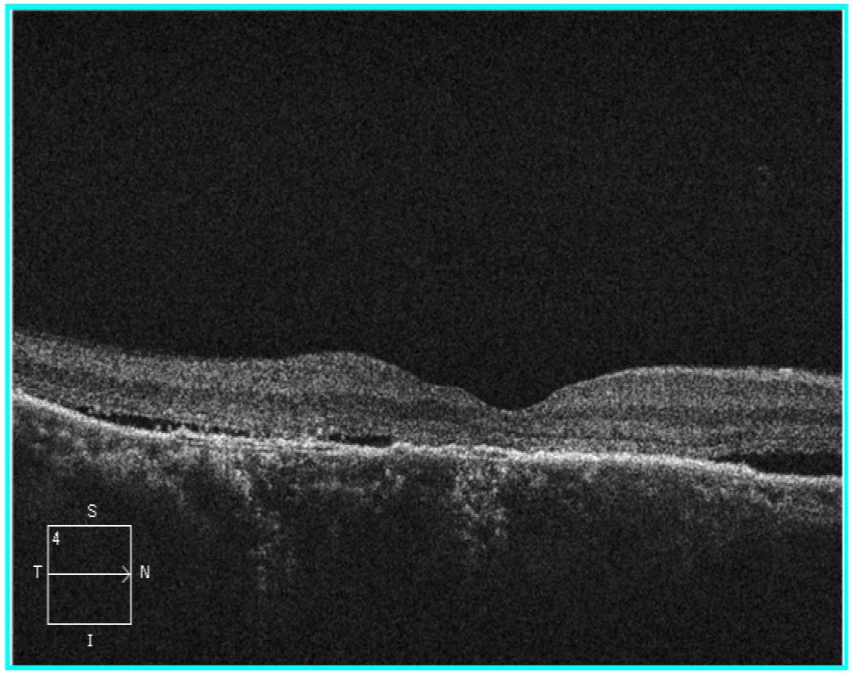

Doctor: Signal Strength: 8/10

High Definition Images: 5 Line Raster

OD ○ ● OS

Scan Angle: 0° Spacing: 0.25 mm Length: 6 mm

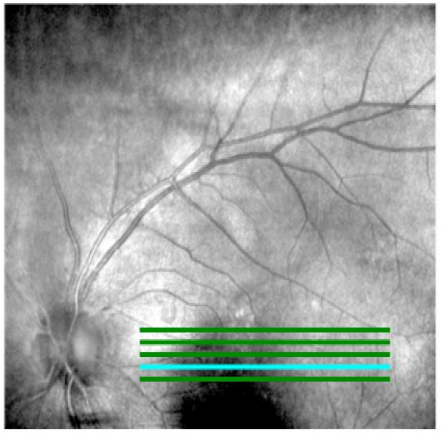

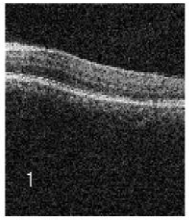

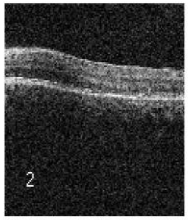

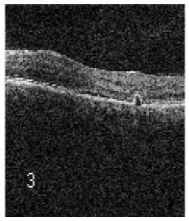

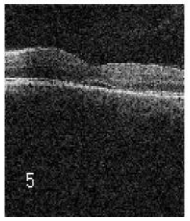

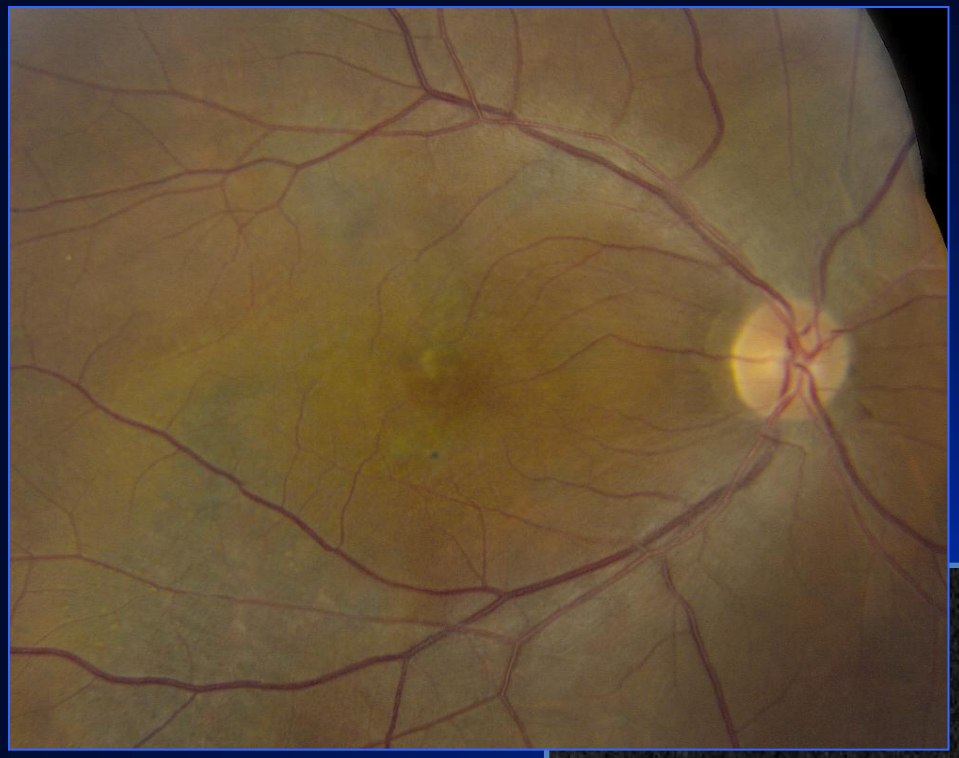

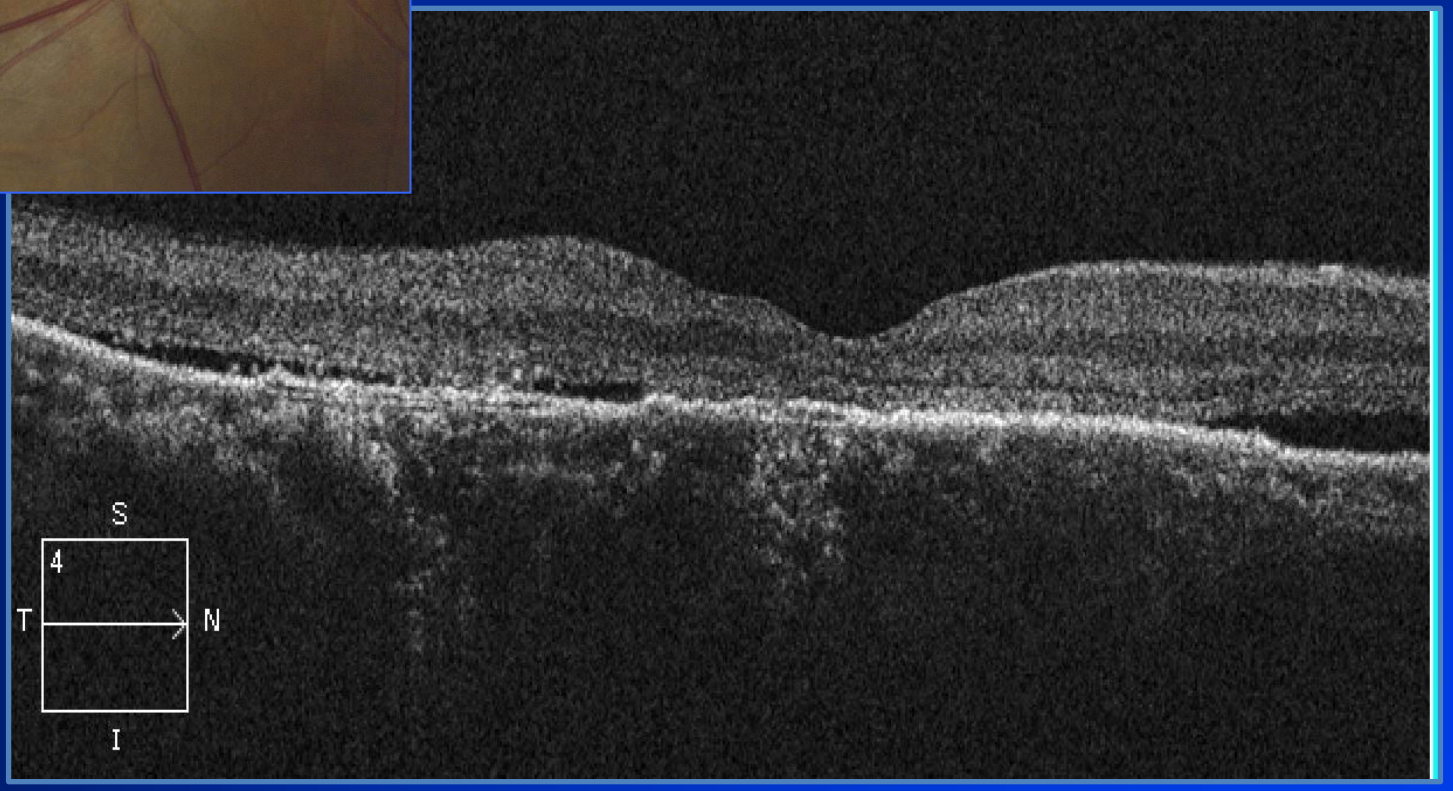
S
4
T
N
I

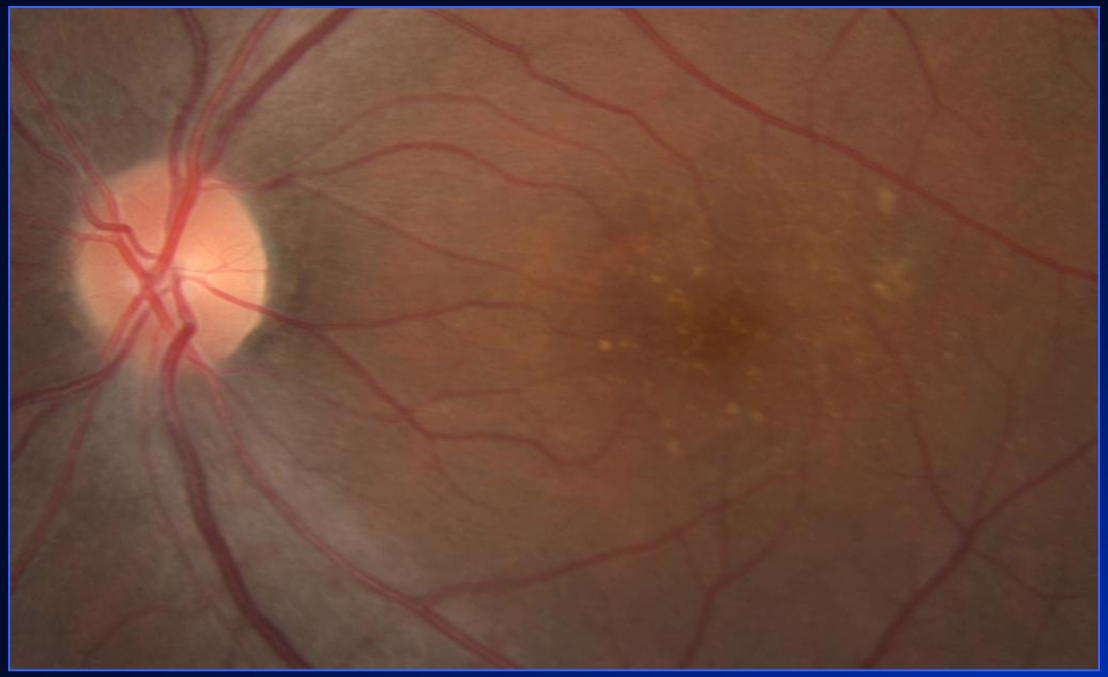

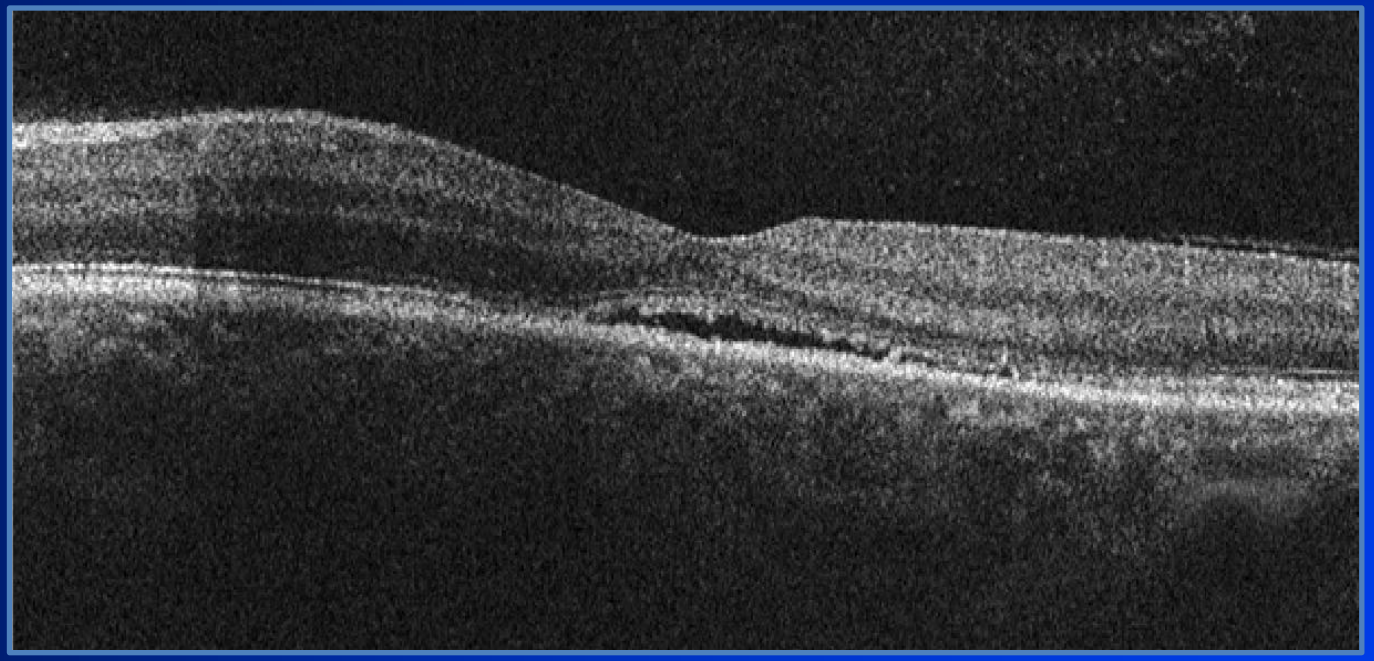

4/3/2012, OD
AF 30°Composite 46°x46° (3)
HEIDELBERG ENGINEERING

65 y/o Middle Eastern American Male
Reduced Acuity RE X >10 yrs
VA: 20/400 RE, 20/20 LE

65 y/o Middle Eastern American Male
Reduced Acuity RE X >10 yrs
VA: 20/400 RE, 20/20 LE

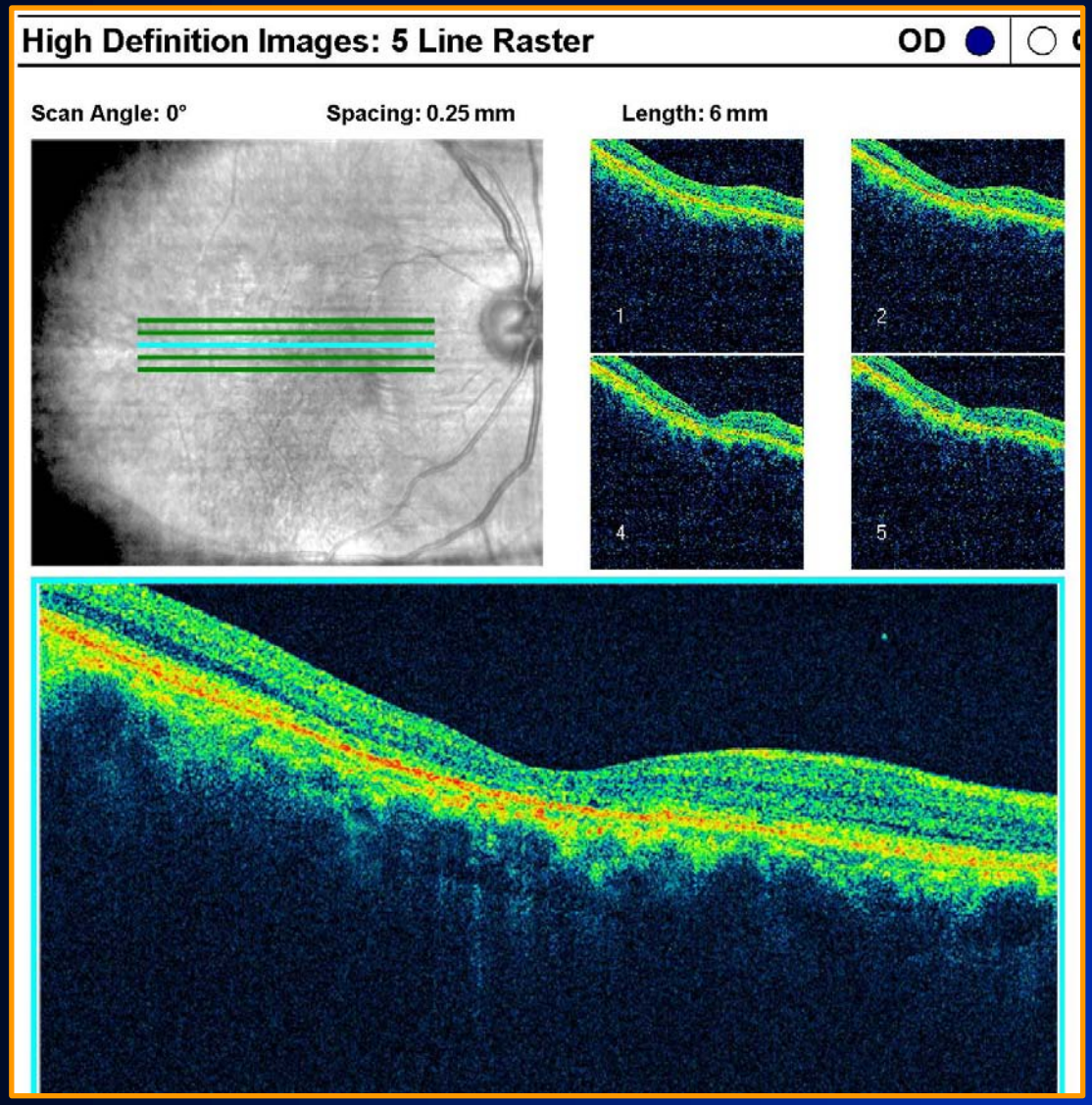
High Definition Images: 5 Line Raster
OD
Scan Angle: 0°
Spacing: 0.25 mm
Length: 6 mm
1
2
4
5

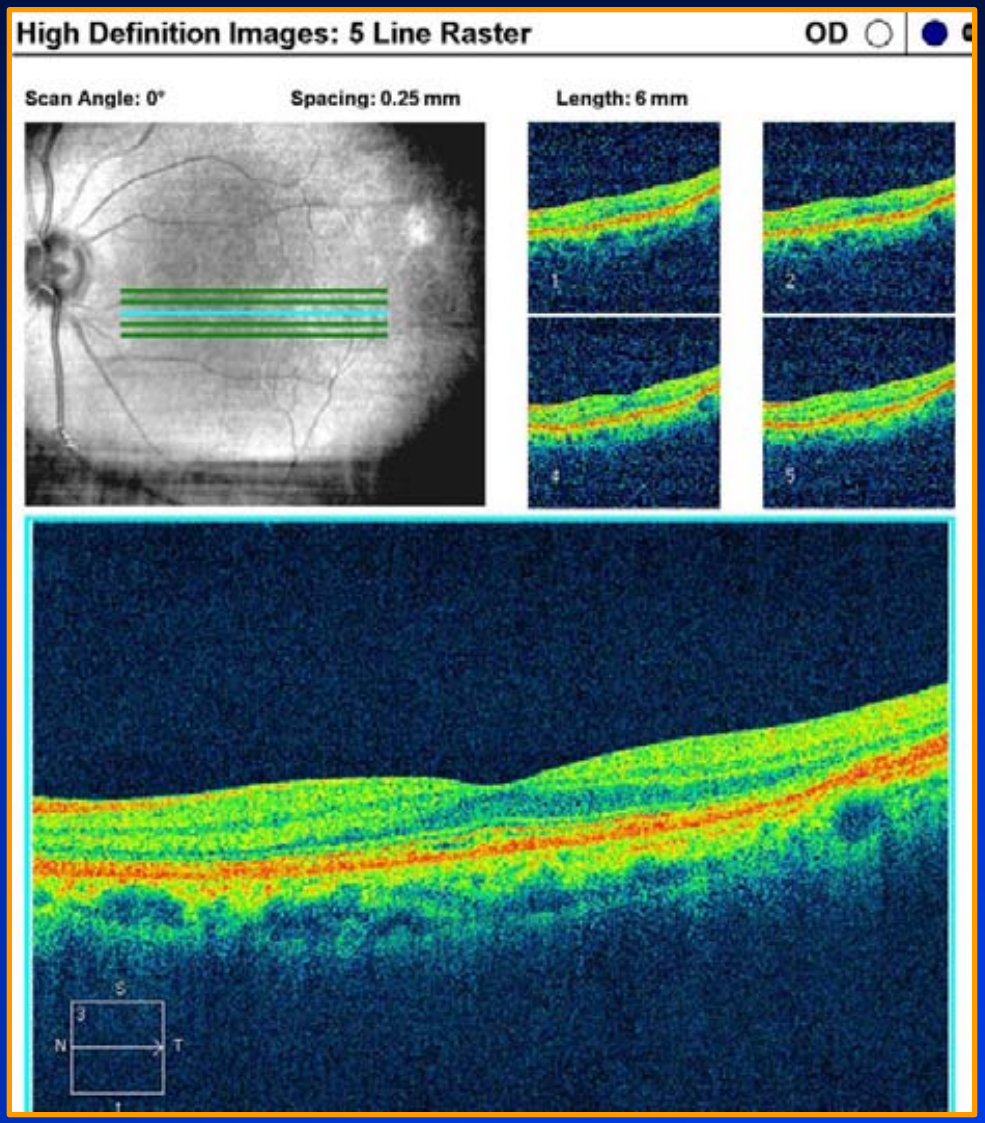
High Definition Images: 5 Line Raster
OD
Scan Angle: 0°
Spacing: 0.25 mm
Length: 6 mm
S
I
N
T
I

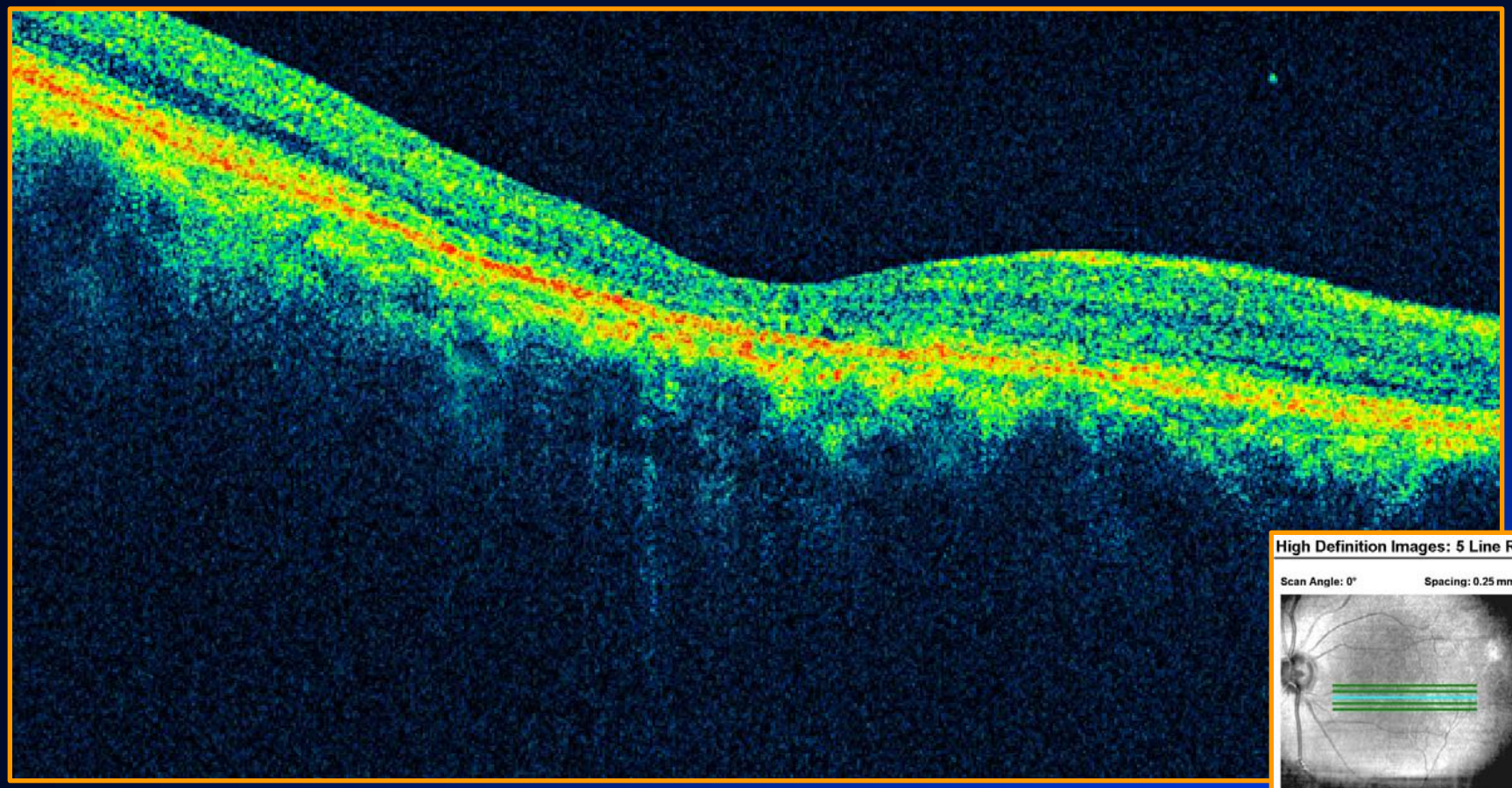

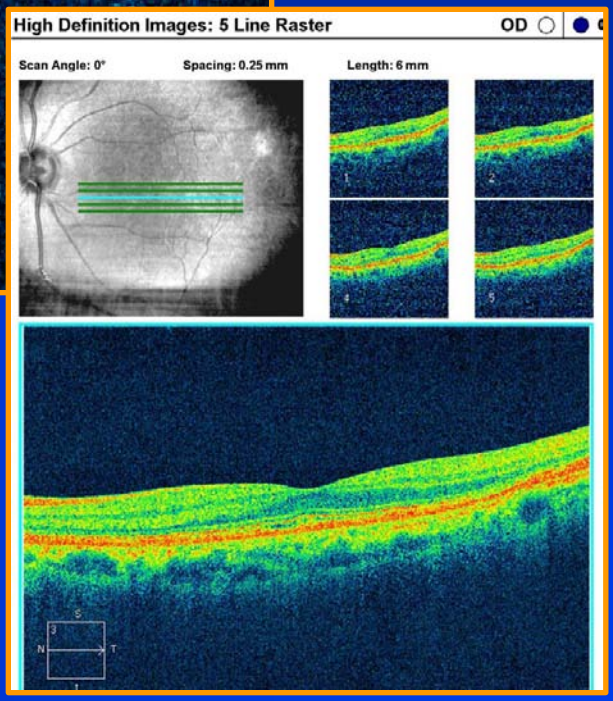
High Definition Images: 5 Line Raster
OD
Scan Angle: 0°
Spacing: 0.25 mm
Length: 6 mm

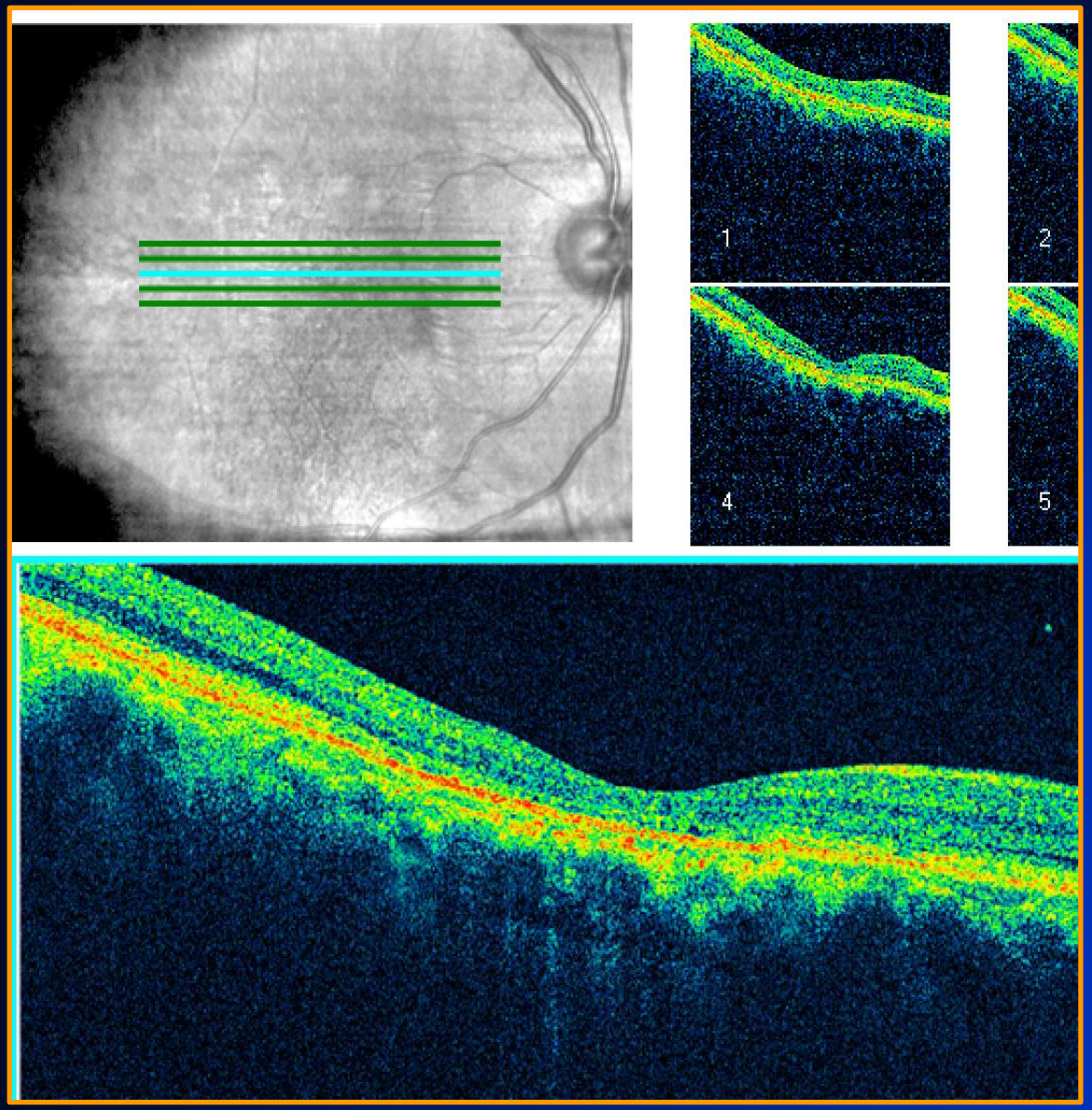

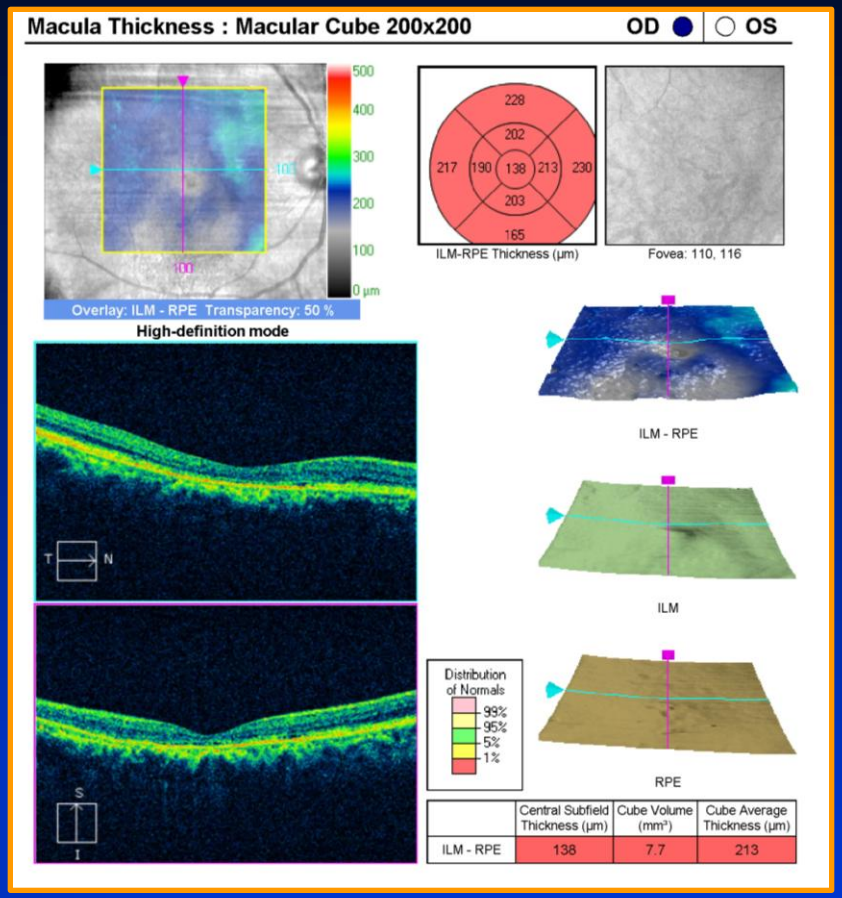

	Central Subfield Thickness (µm)	Cube Volume (mm³)	Cube Average Thickness (µm)
ILM - RPE	138	7.7	213

Diopsys

- **“Designer” VEP that can help diagnose visual pathway disorders**
- **Easy, objective, functional**
- **Maybe helpful in early glaucoma or neurologic disease**
- Easy to read Typical reimbursement for CPT Code 95930 exceeds $100

Diopsys

- Objectively measures the neurological responses of the entire visual pathway
- Enables testing of preverbal children, infants, and patients with communication difficulties
- Supplies objective measurements on patients' response to physicians treatment (lenses, patching, vision therapy, prisms, etc.)
- Clinician can perform comparative VEP studies to assess therapy over time,

Multi-Spectral Imaging

RHA

From Annidis Health Systems

- Ocular pathology management systems that integrates advanced multi-spectral imaging with analytic software for early detection and management of ocular pathology

What is Multi-Spectral Imaging?

- New and unique way to view the all layers of the retina non-invasively
- The device uses a series of discrete monochromatic lights to create a series of en face “spectral slices” throughout the entire thickness of the retina
  - The instrument uses up to12 wavelengths of color generated by LEDs
- This creates a series of monochromatic *en face* fundus spectral slices
- Provides clinicians an enhanced view of the entire retina including the deep retinal architecture of the RPE and choroid
- Allows for very early detection of retinal pathology

RHA Multi-Spectral Imaging

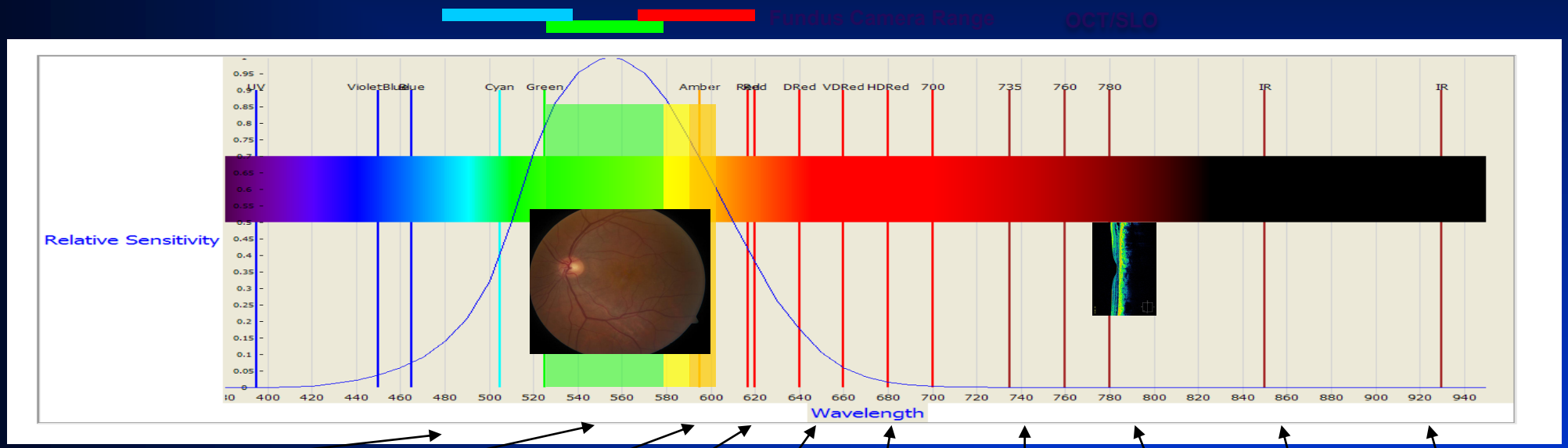

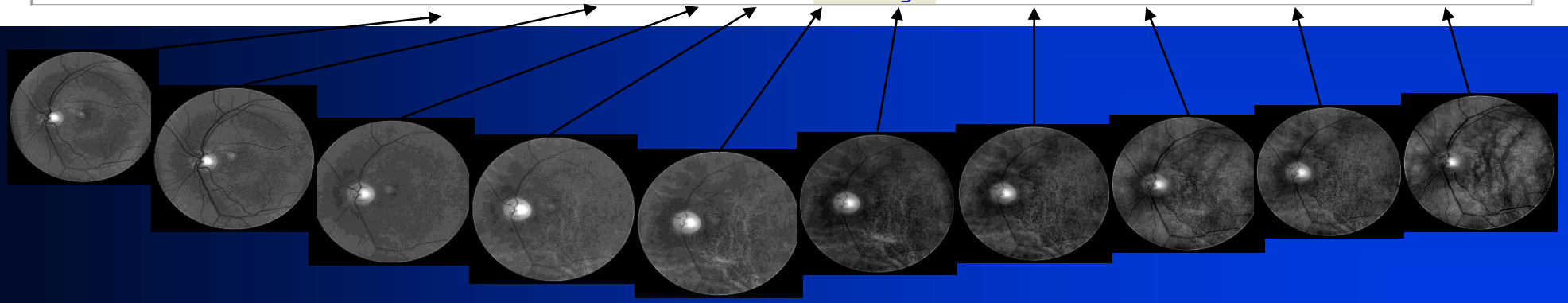

The doctor sees all of these images

Multispectral Imaging
Deep Retinal & Choroidal Views

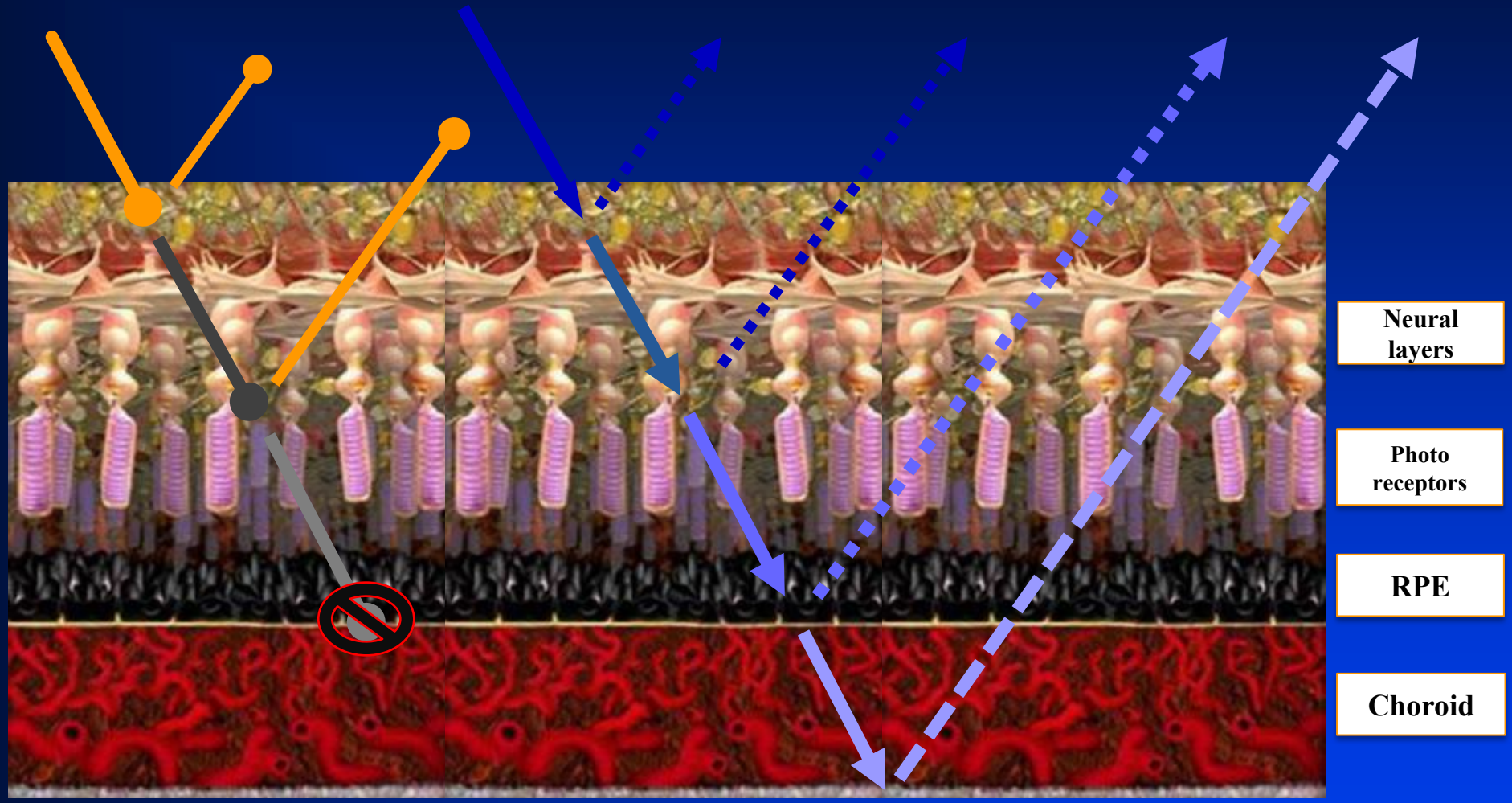

Based on the principle of "reflectometry"

Seeing and Visualizing the RPE is Essential

- The RPE is considered to be one of the most essential retinal structures and is comprised of lipofuscin and melanin
- The RPE is involved in activities critical to the viability of the photoreceptors and visual functioning
- The start of many retinopathies is triggered when there is a disruption to the RPE

Fundus Camera / OCT vs. RHA™

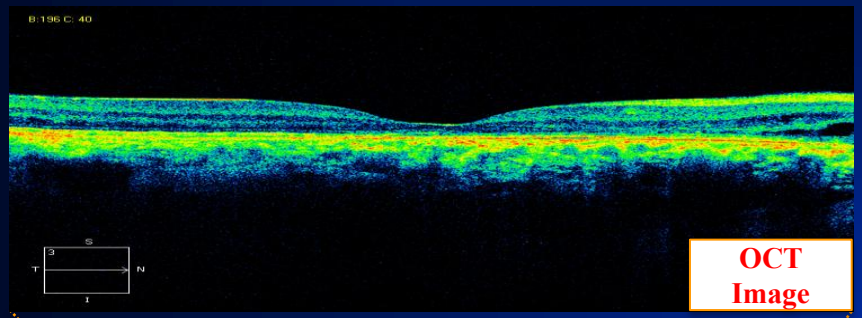

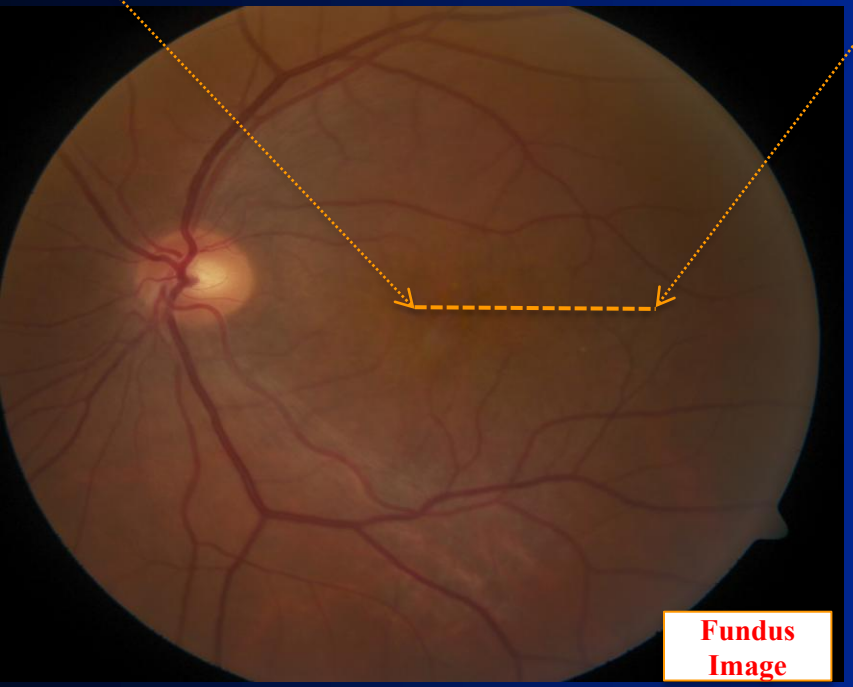

Annidis RHA Imaging
Reveals Significant RPE Pigment Disruption

Pigment: Fundus Camera vs. RHA™

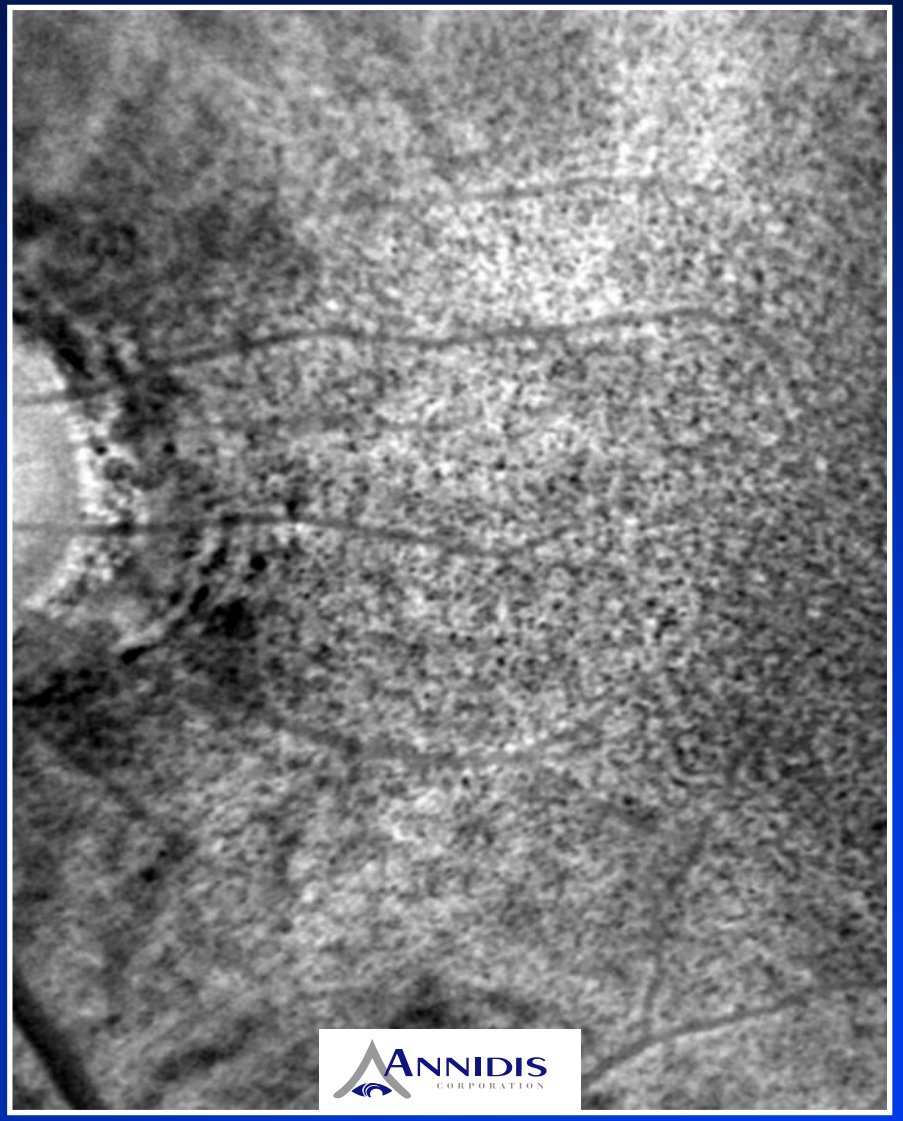

RPE Melanin Visibility by RHA™

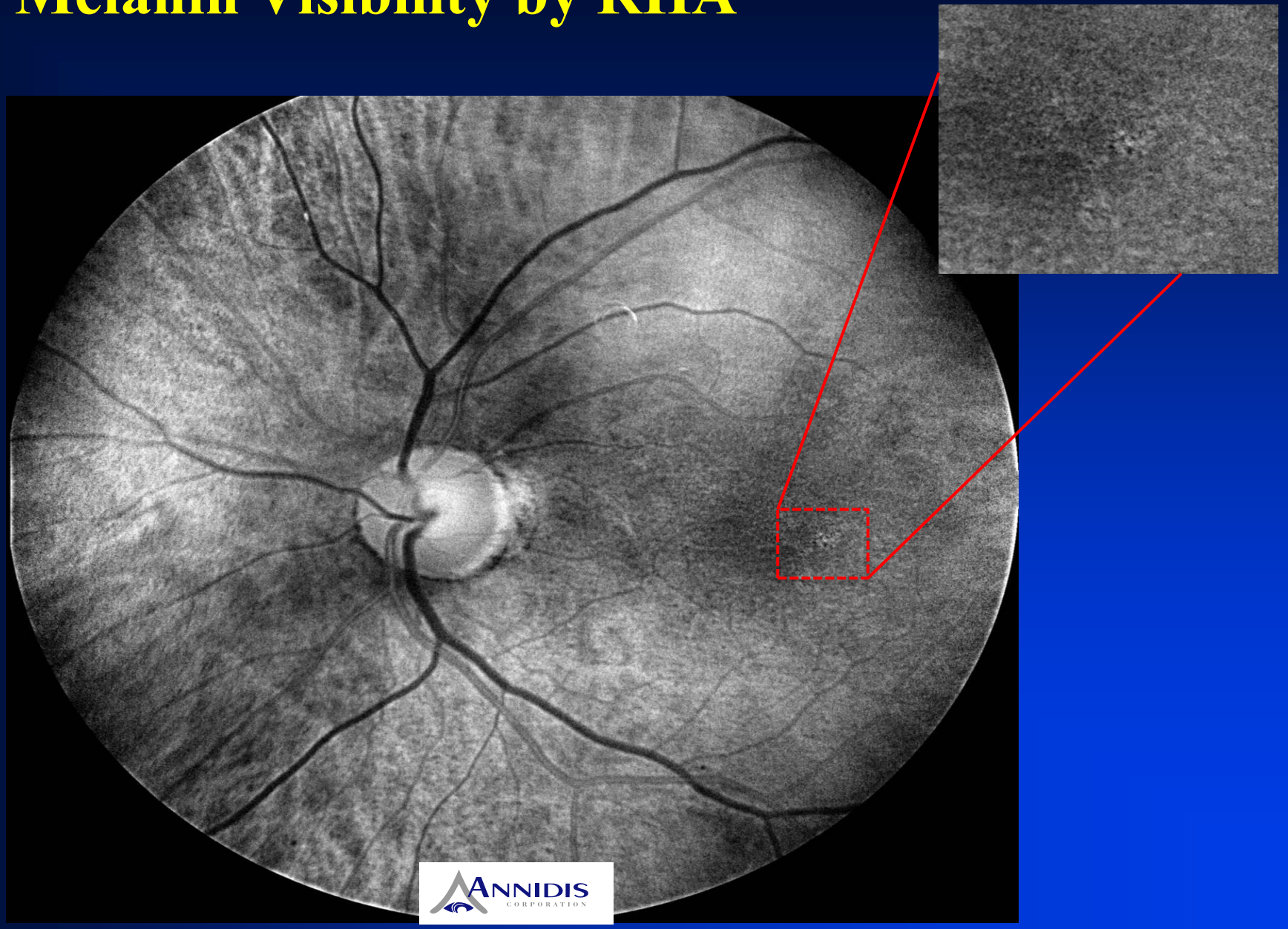

RPE Melanin Visibility by RHA™

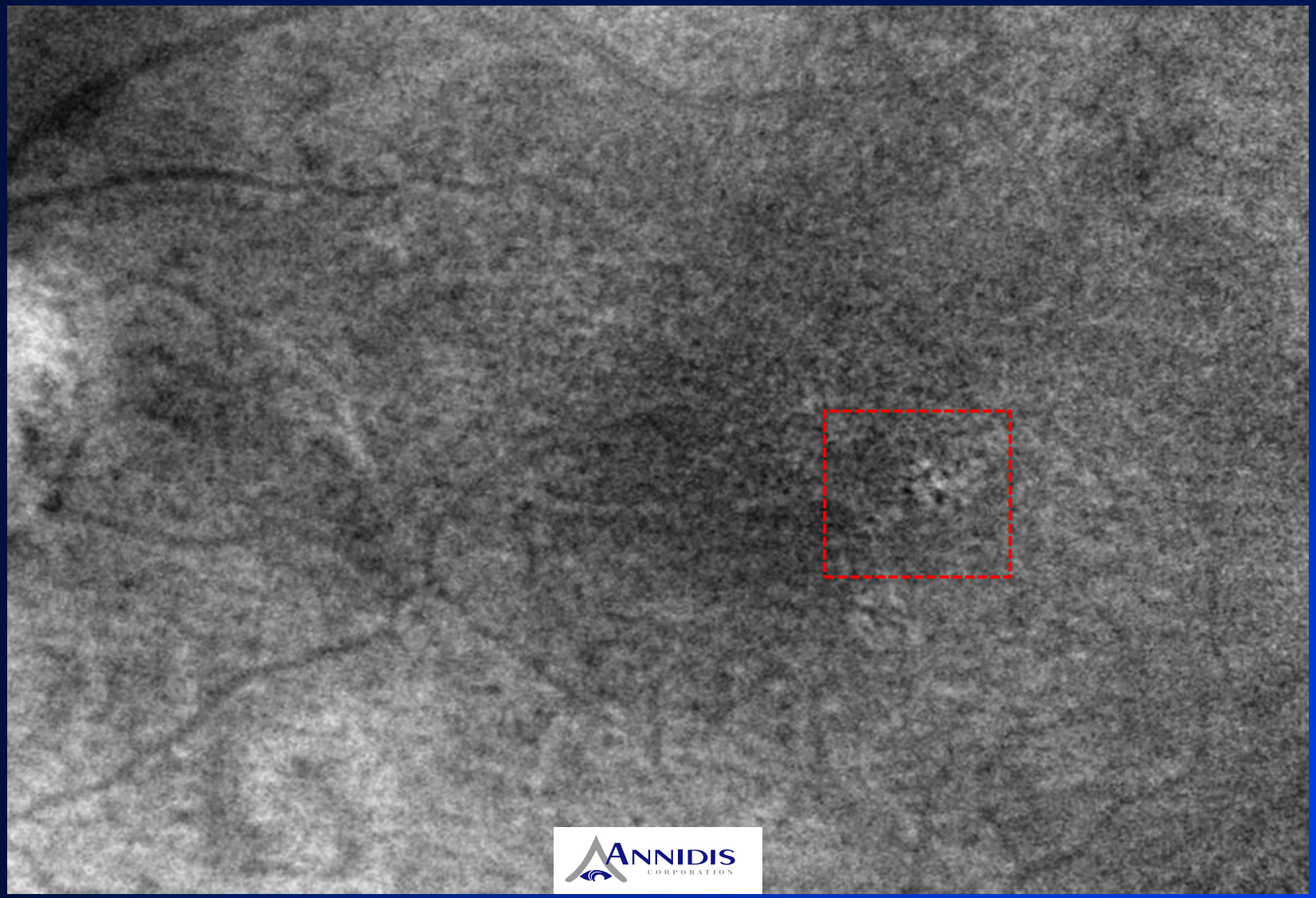

Deep Retina: GA

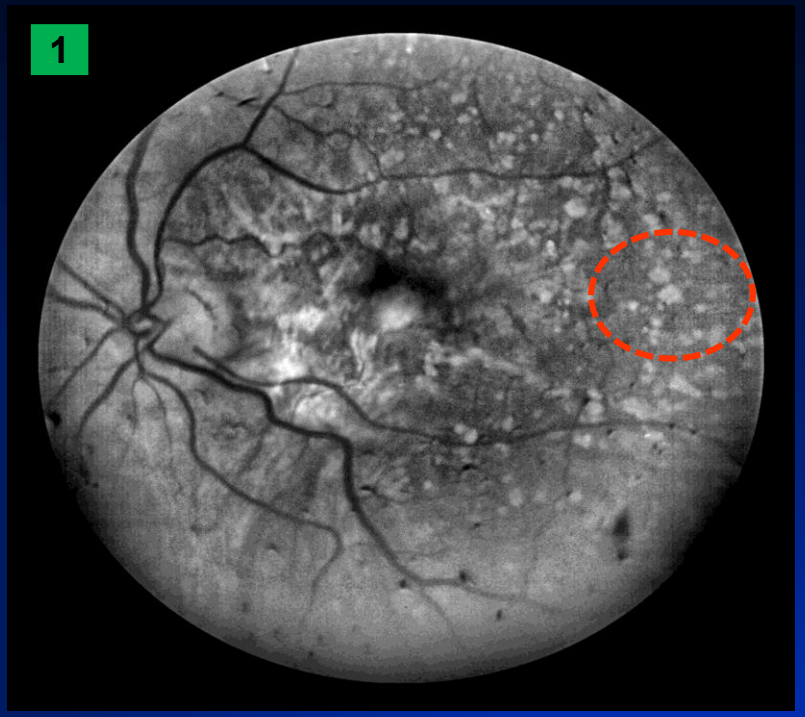

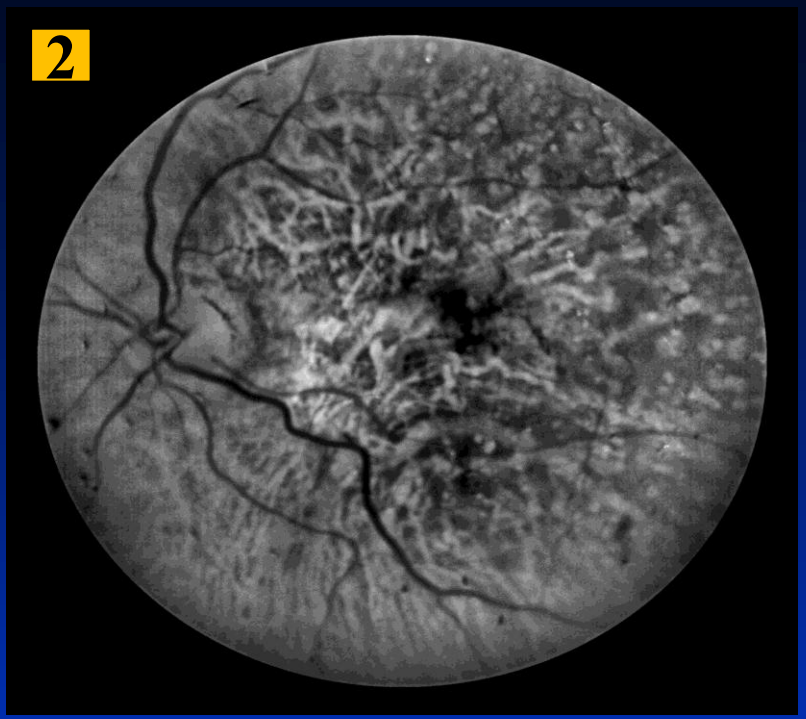

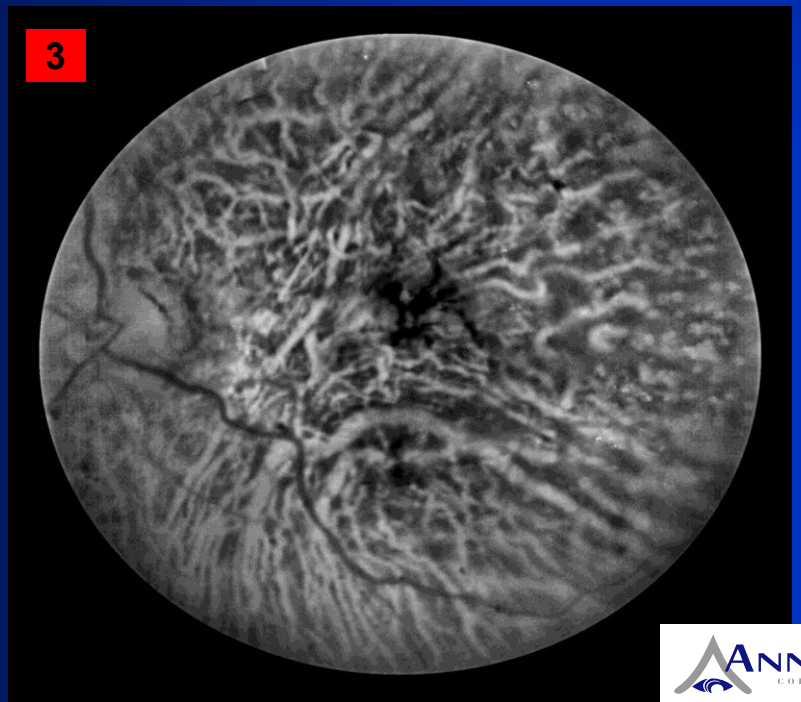

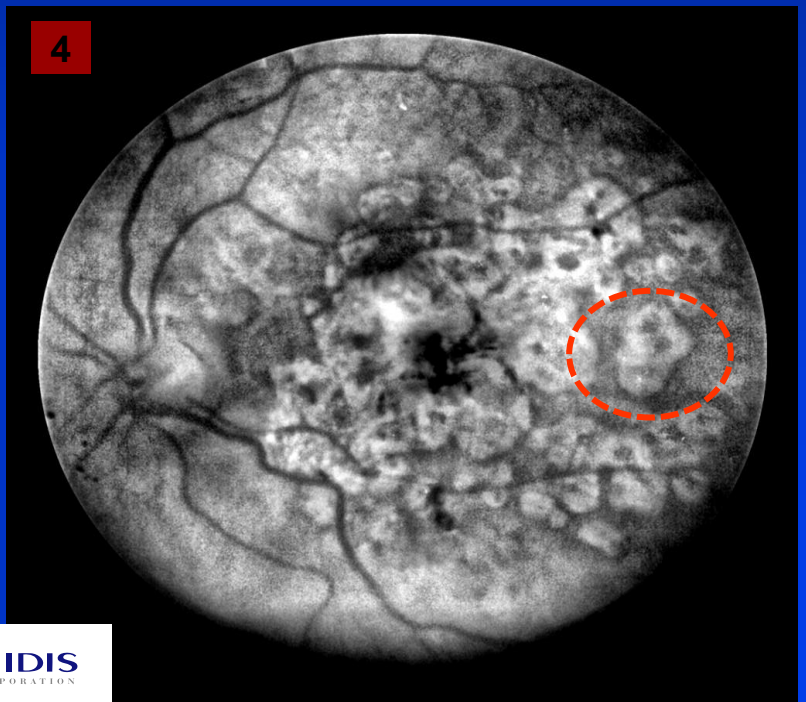

ANNIDIS CORPORATION

Diabetic Retinopathy Localization

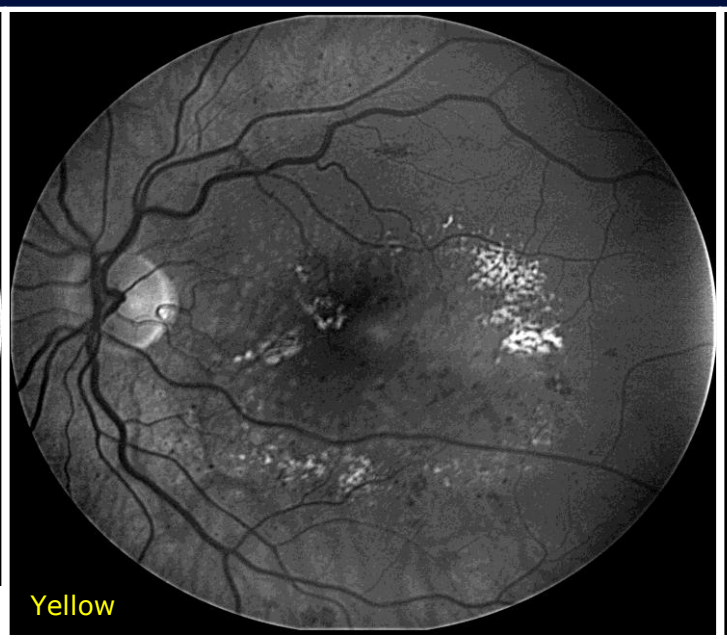

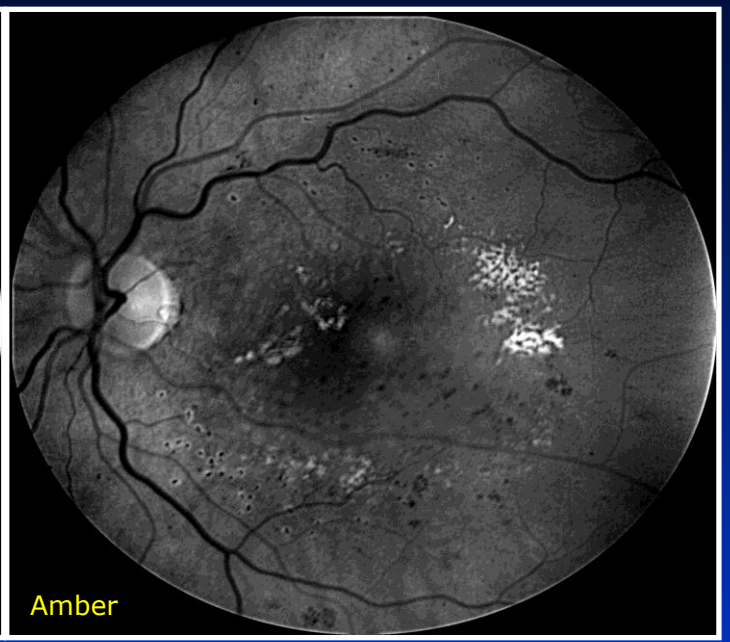

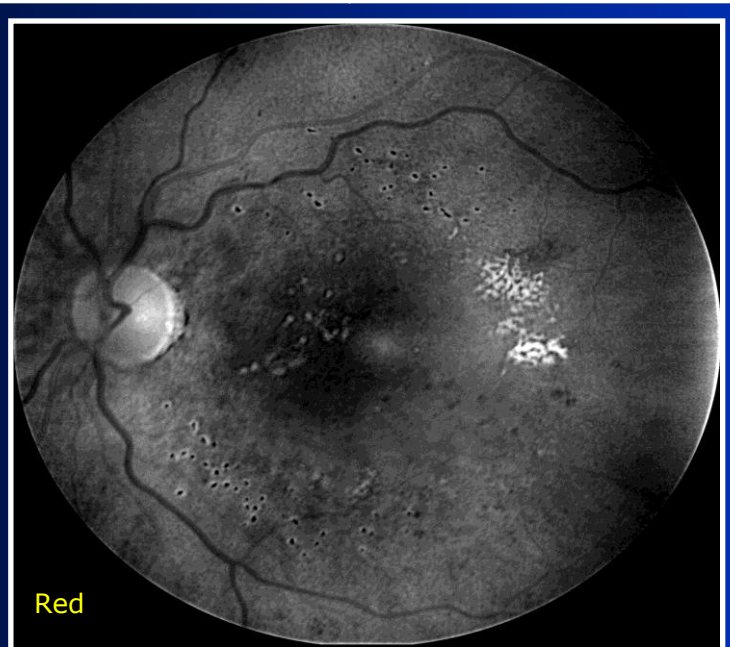

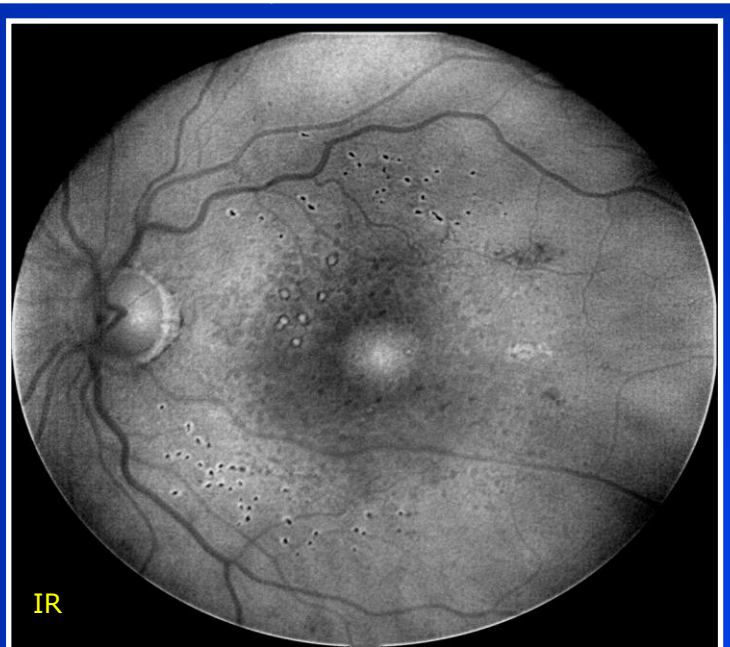

Retinotoxicity: Hydroxychloroquine

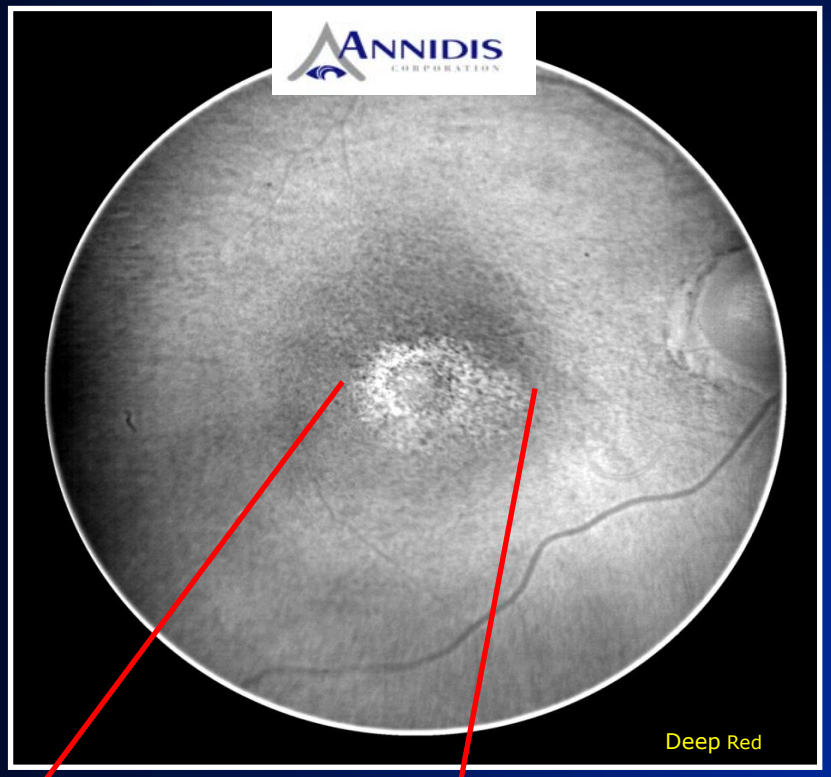

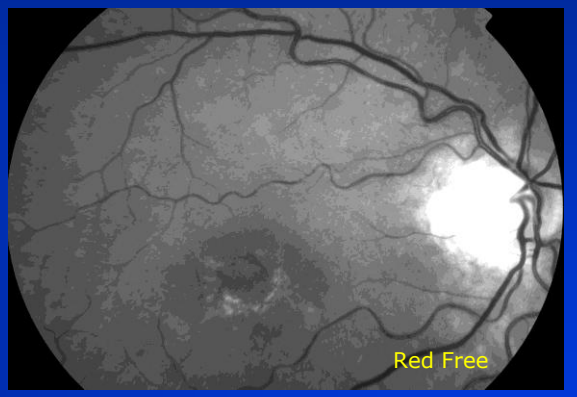

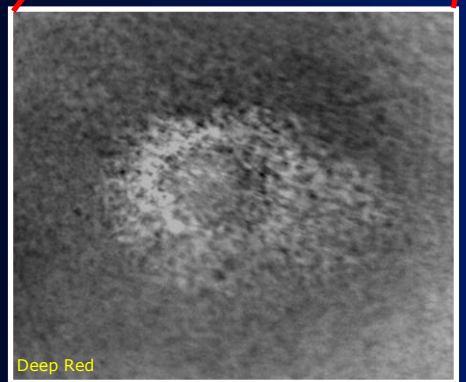

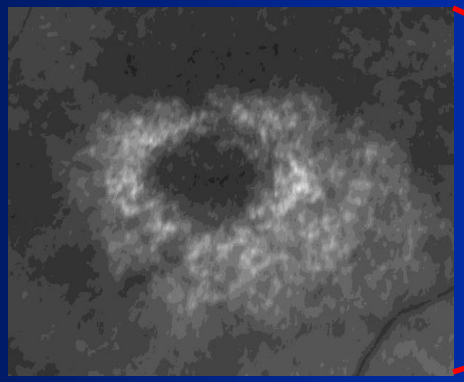

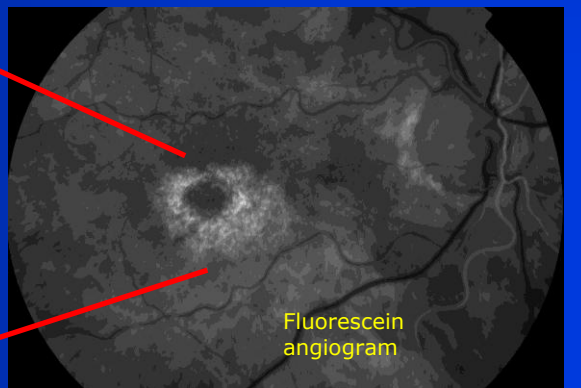

CHRPE : Fundus Camera vs. RHA™

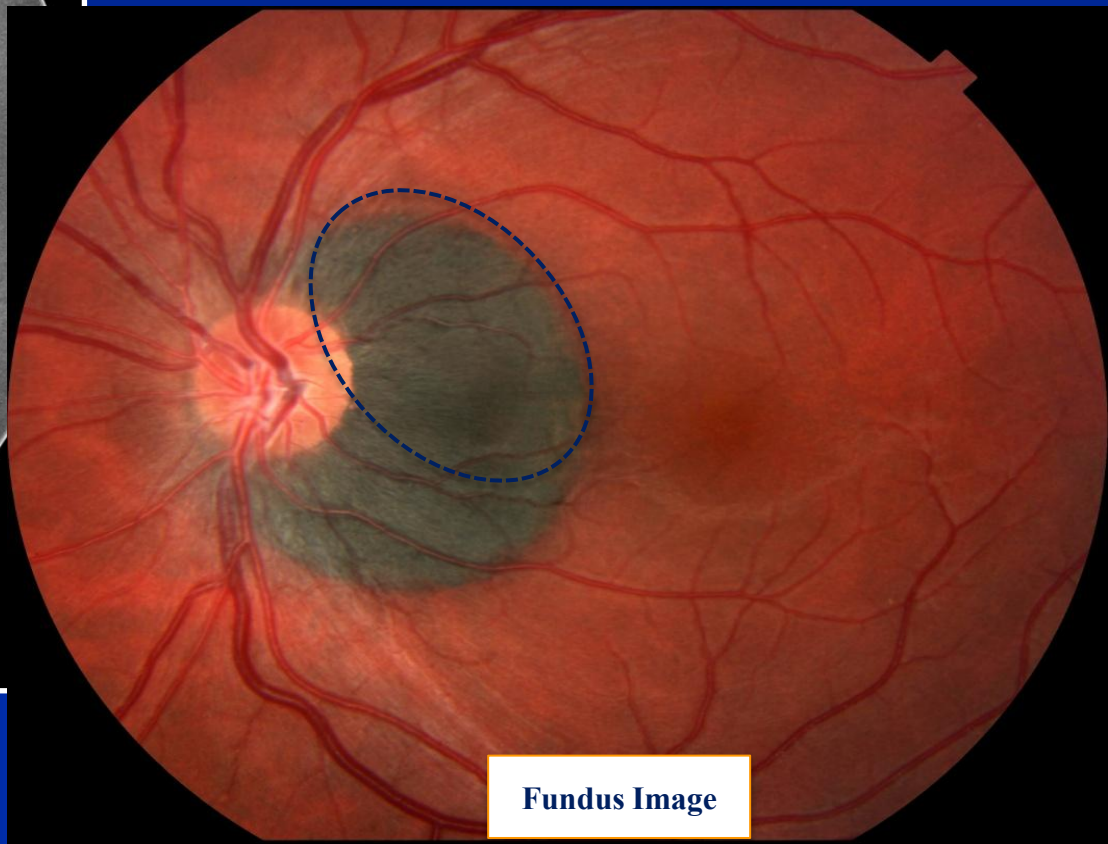

Deep Retina: Angioid Streaks (PXE) Series

Deep Retina: Melanoma

Oxygen enhanced vasculature by RHA™ (No Dye Injection)

Annidis actually uses a couple different LED's to create different wavelength combination that flouresce the hemoglobin and oxygentated or deoxygenated contents of blood in both the choroid and the retina.

Epiretinal Membrane by RHA™

Early AMD:
Spectral Slices by RHA Showing Atrophic

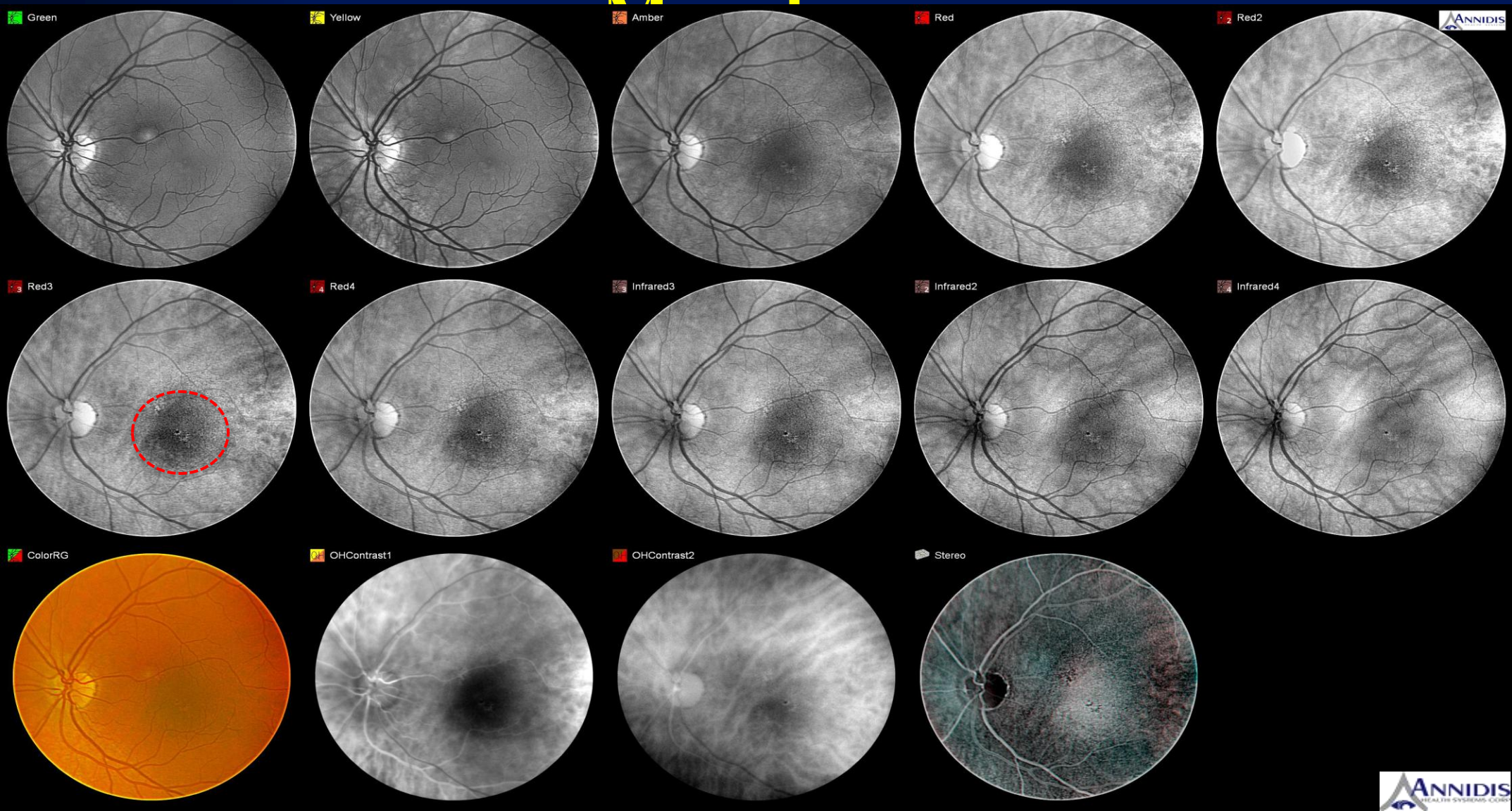

Neurofibromatosis (NF)

Case 51: Multi-Spectral Imaging (MSI) of choroidal lesions in NF

Case 1: Topcon 3D OCT Fundus Image OD

A 25 year old female presented with blurred vision in her right eye. She was concerned about her eyes because she was told by her neurologist that patients with her disorder, neurofibromatosis type 1, sometimes develop visual problems. Previous eye exams failed to reveal any unusual findings. Our patient was first relieved when a -1.00 lens corrected her vision in her right eye to 20/20 and a -0.50 in her left eye also resulted in 20/20. The slit lamp exam revealed several iris spots which were perhaps small Lisch nodules or just commonplace iris freckles.

The fundus through a dilated pupil was considered to be unremarkable with direct ophthalmoscopy and with indirect ophthalmoscopy (with a 78D lens and with a BIO). Fundus photography was also judged to be unremarkable in both the right and left eye.

Case 1: Topcon 3D OCT Fundus Image OS

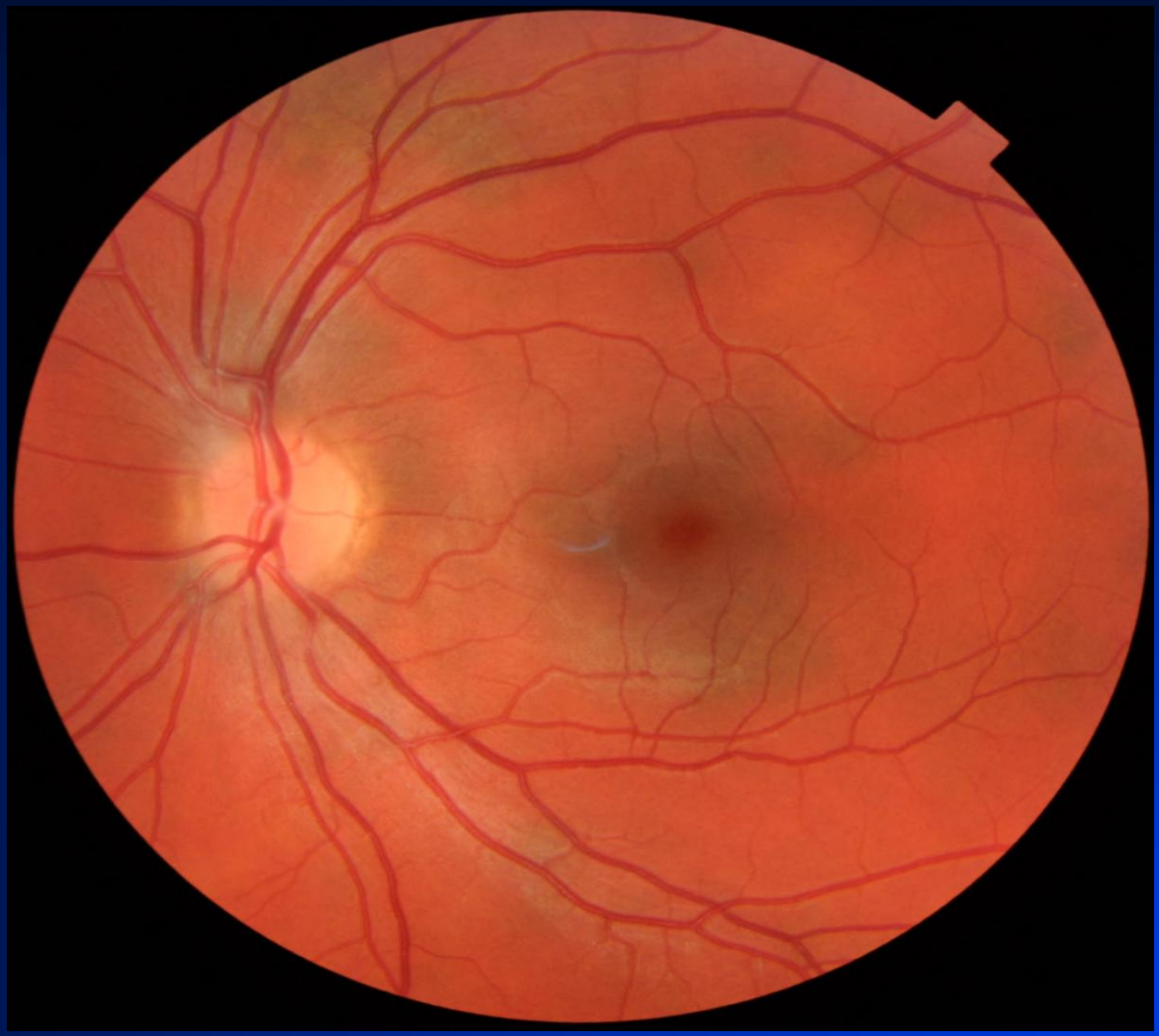

Case 1: Topcon 3D OCT Image OU

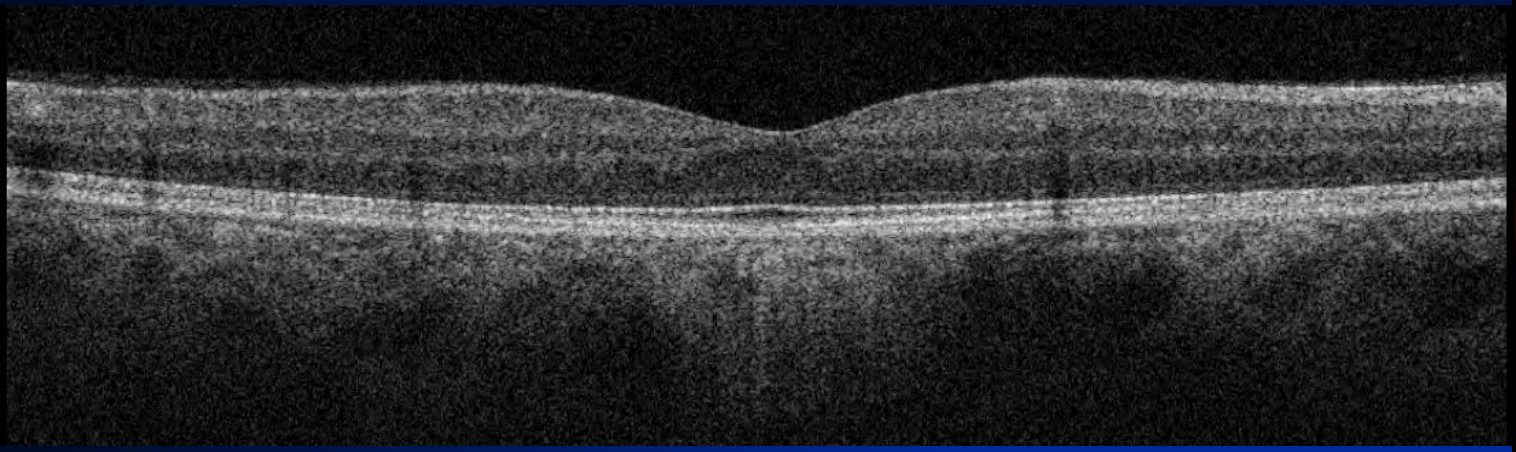

SD OCTs with the Topcon 3D OCT 2000 also appeared to be within normal limits. All retinal layers, including the Photoreceptor Integrity Line (PIL) appeared normal. The normal PIL under the fovea predicts normal (corrected) visual acuity. In addition to the retina, the vitreous and the choroid also appeared normal in each eye.

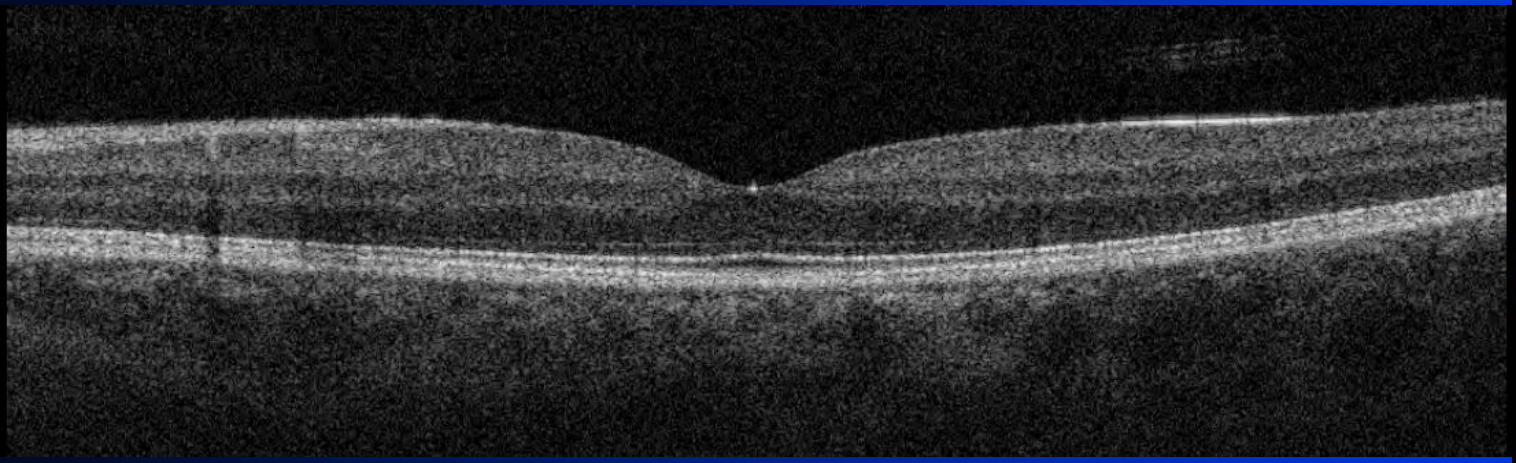

Case 1: Annidis Infrared LED Image OD

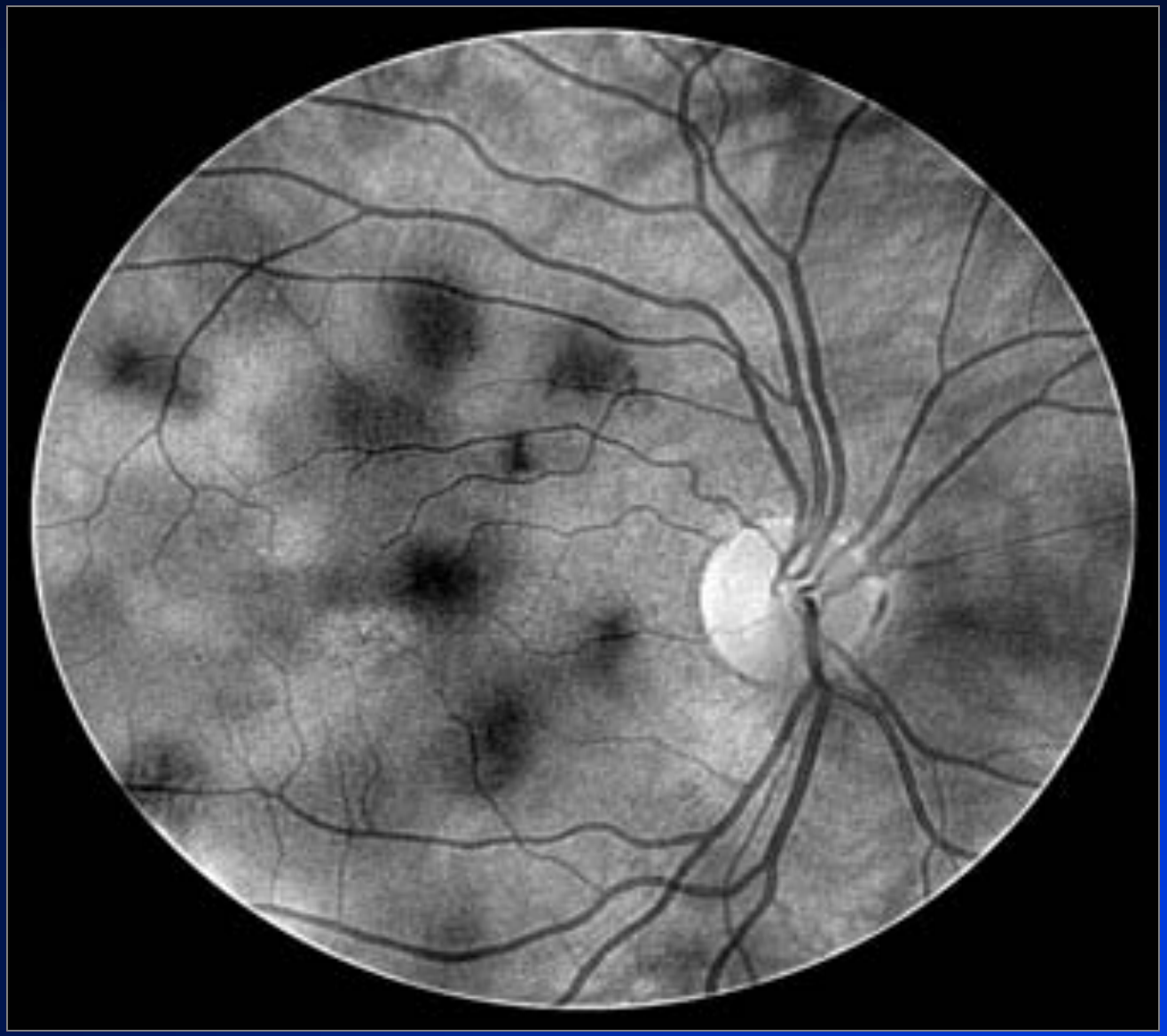

Multi-Spectral Imaging (MSI) was obtained with the new Annidis RHA system. Although the color composite MSI image was normal, scans in the

Case 1: Optomap® Ultra-Widefield Auto Fluorescence OD

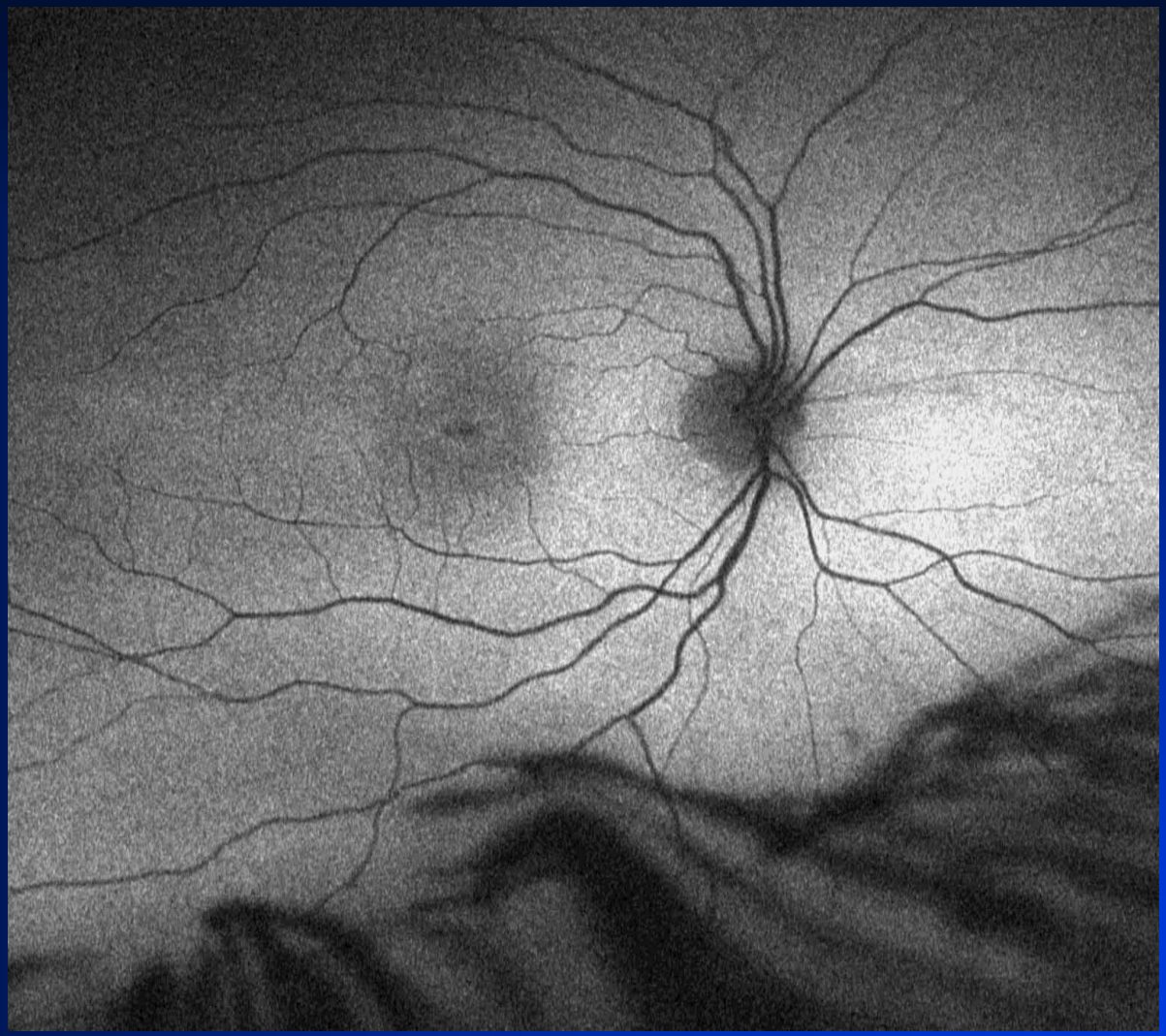

AF (see RR 42, 45, 47 LINK!!!) is a novel imaging procedure which yields information about the RPE. Most AF in the fundus is to the aging pigment, lipofuscin. Here the vast majority of the retina reveals a normal AF glow suggesting that the RPE is normal. There is perhaps a subtle bull's eye suggesting some minor RPE involvement in the macula. (Note the shadowing inferiorly due to superior eyelashes.)

Case 1: Topcon Fundus Image and Optomap® *plus* with Resmax ™ Color Image OD

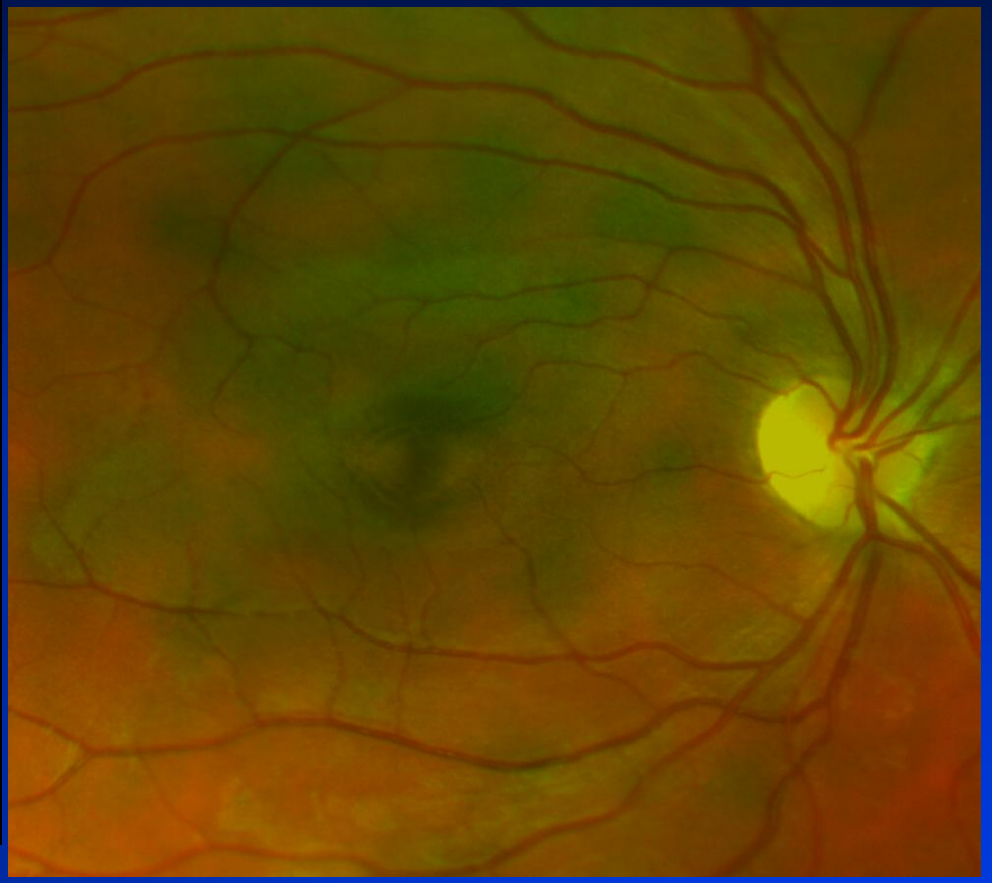

With the aid of the Optos image on the right, subtle pigment lesions may appear visible in the Topcon image on the left. Careful observation of the macula with either the Topcon Fundus Image or the Resmax Color Image

Case 1: Optomap® Fluorescein Angiography Image OD

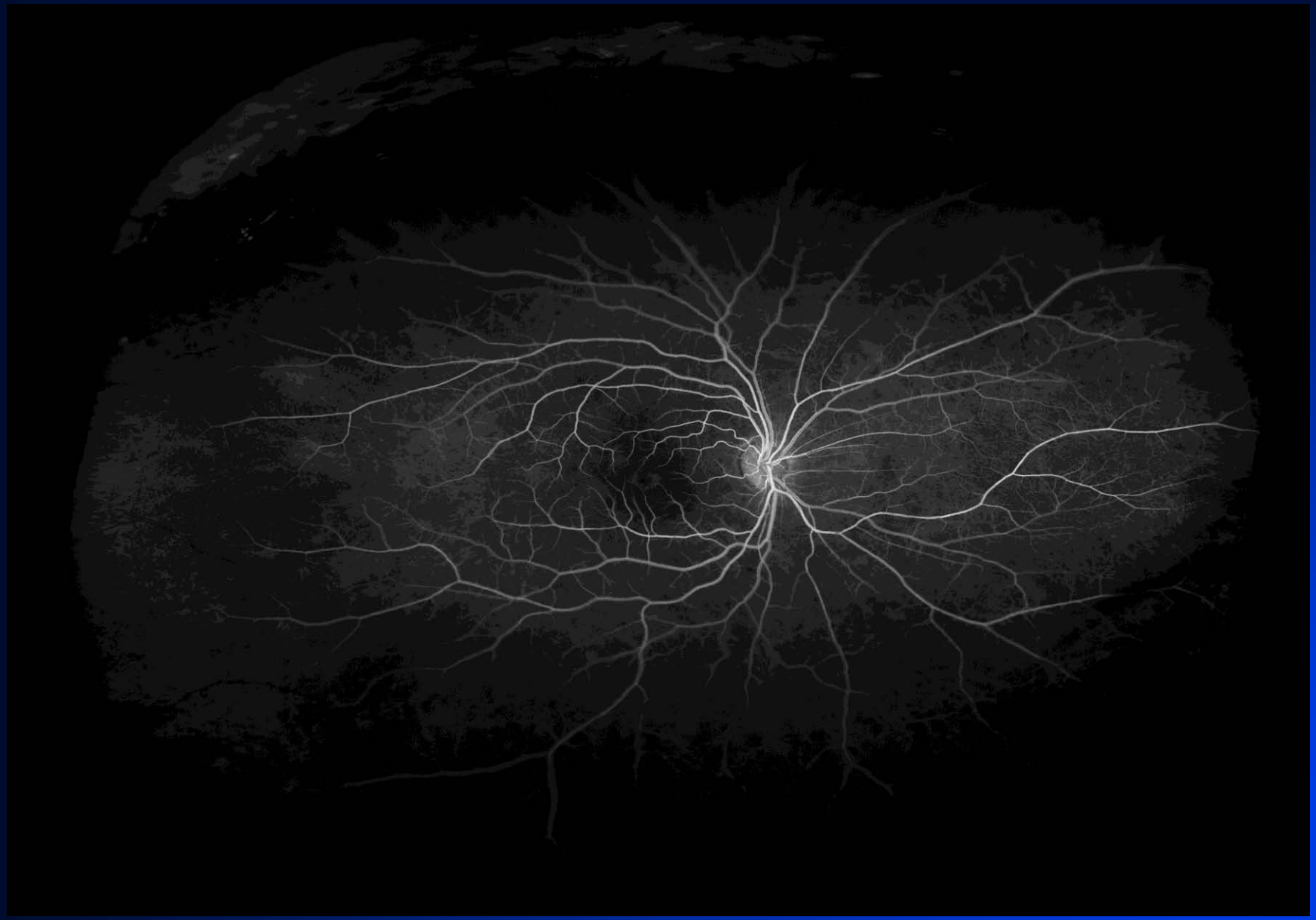

Case 1: Optomap® Fluorescein Angiography Image OS

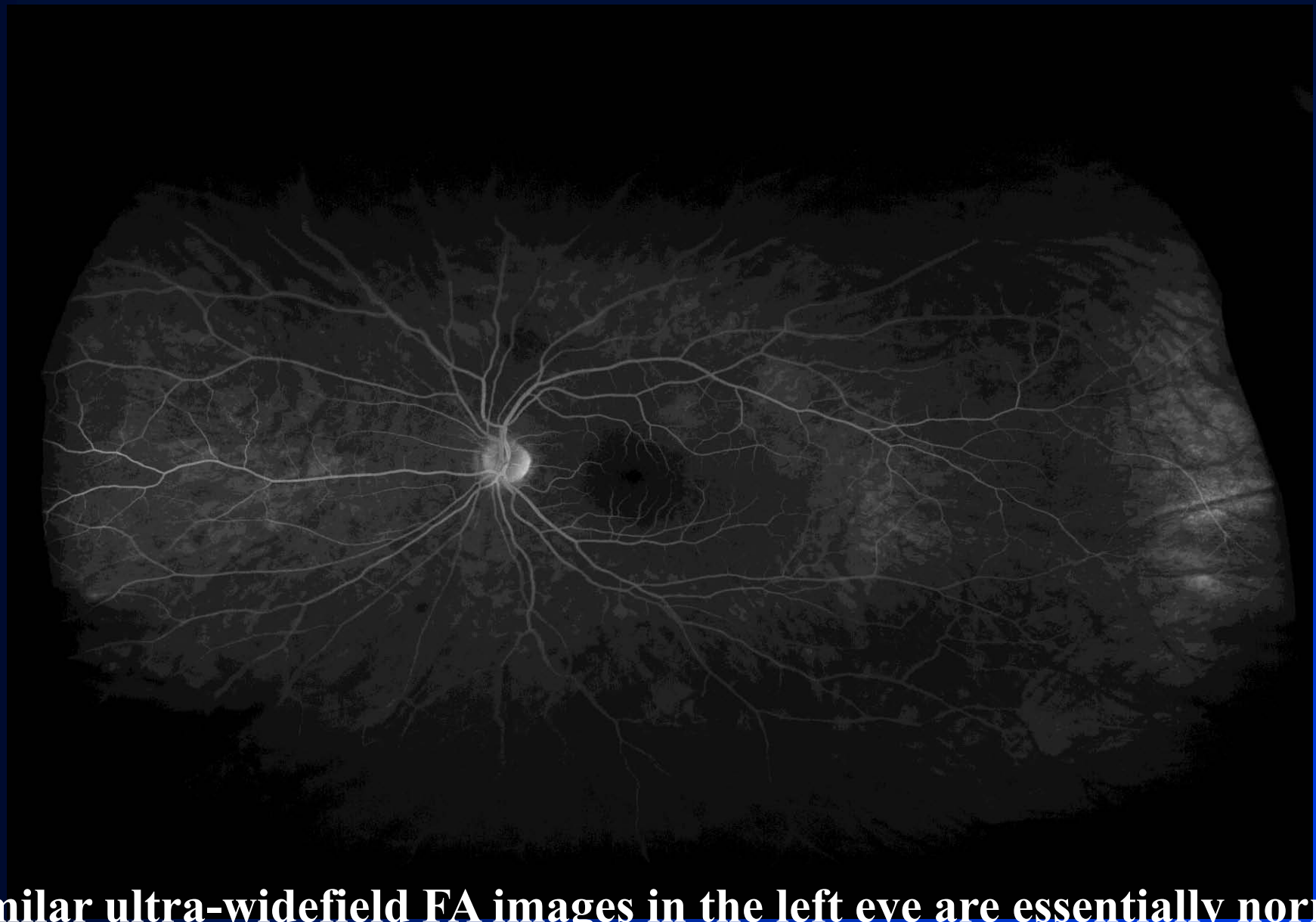

Similar ultra-widefield FA images in the left eye are essentially normal. Lesions at the level of the choroid are often not visible with FA.

Case 1: Annidis MSI OD

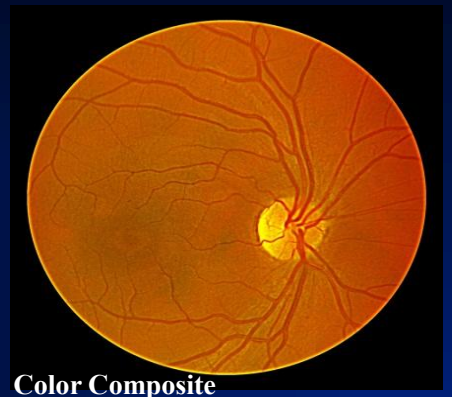

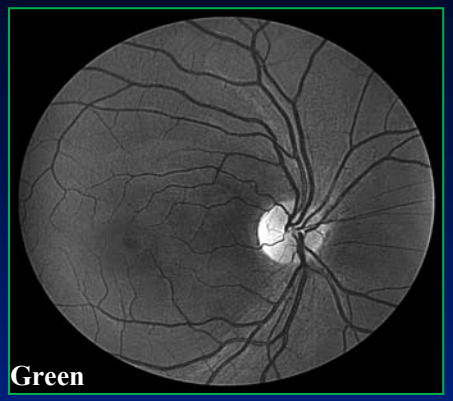

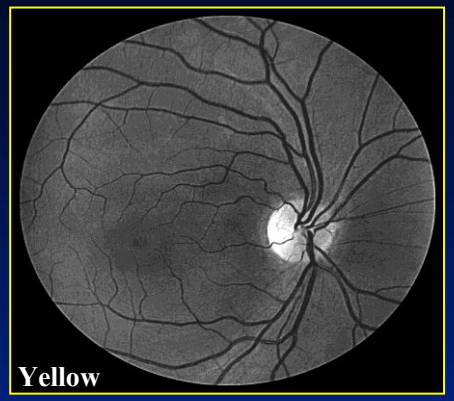

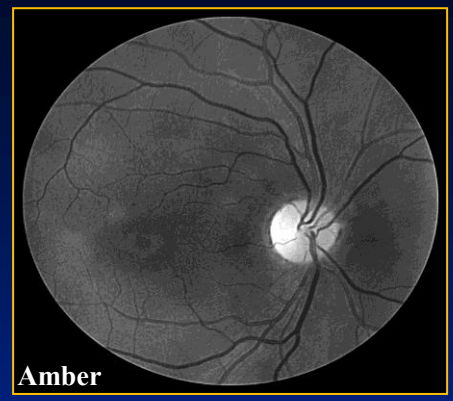

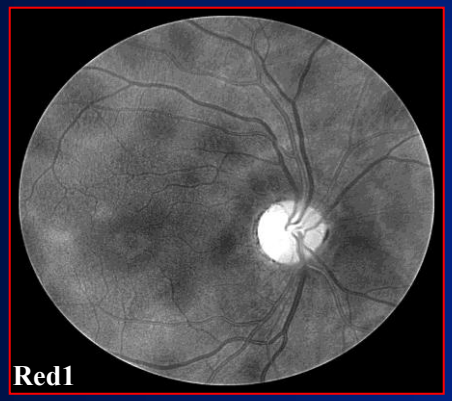

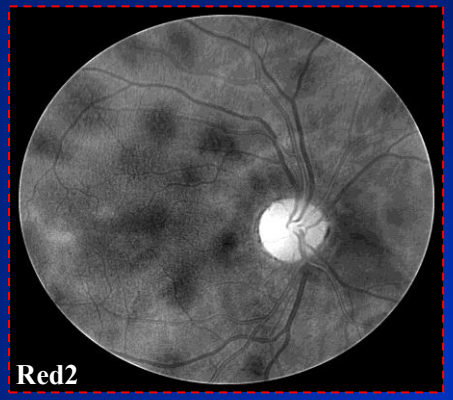

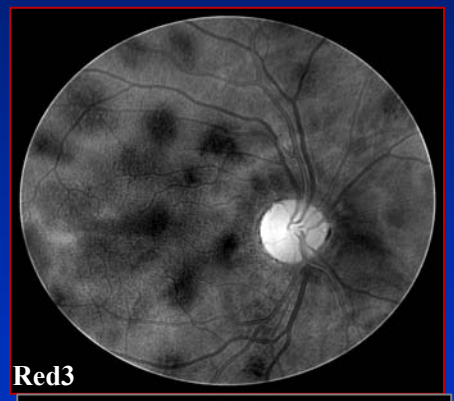

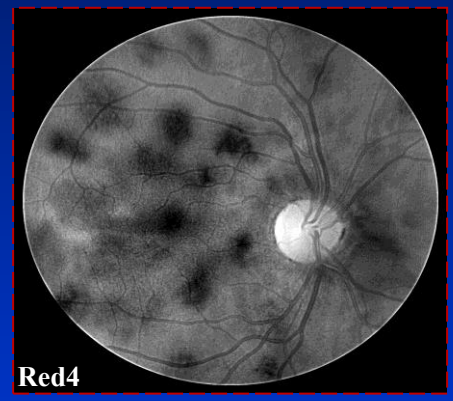

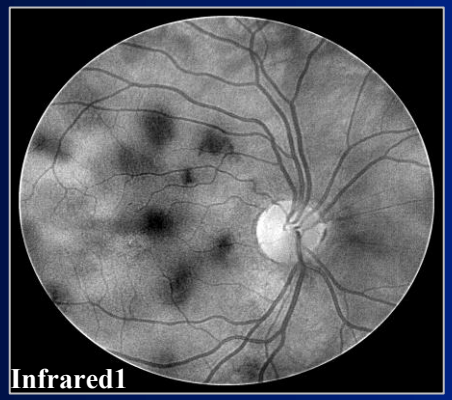

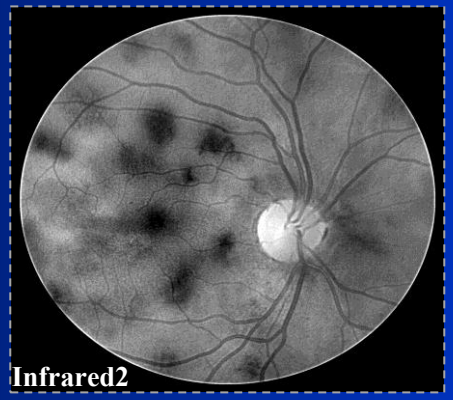

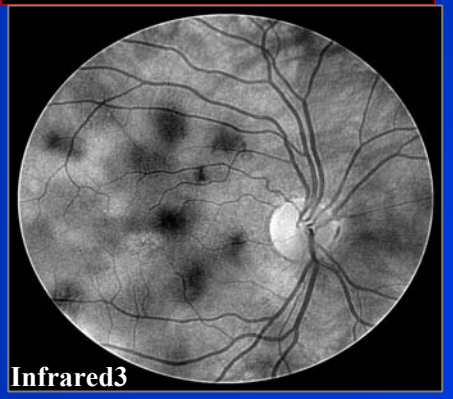

The Annidis Multi-Spectral Imaging, of our patient with NF. uses 10 different LEDs, each of a different color and somewhat different penetration range. The Green, Yellow and Amber LEDs reveal detailed information about the shallow retinal structures. The Red and Infrared LEDs penetrate deeper into the retina and choroid and reveal abnormalities not visualized with the Green, Yellow and Amber LEDs.

Case 1

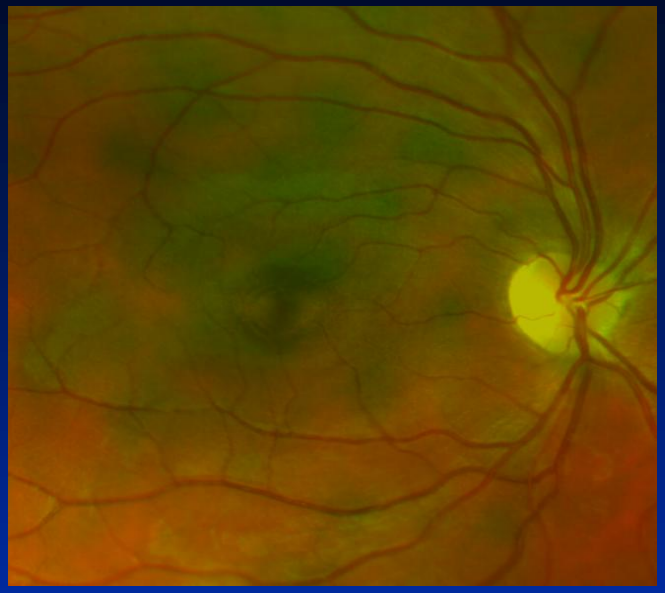

Although traditional fundus photography (top left) and Optos Color Image (top right) yield some information about the deep lesions, the Annidis MSI yields important information about the deep lesions not clearly visible before.

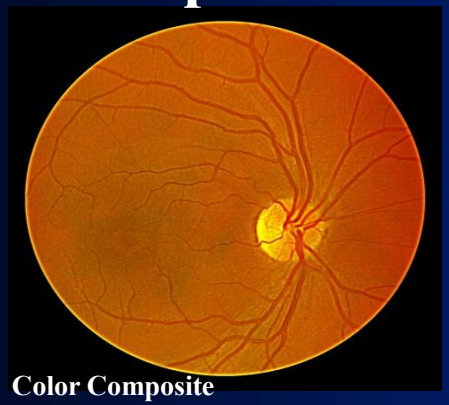

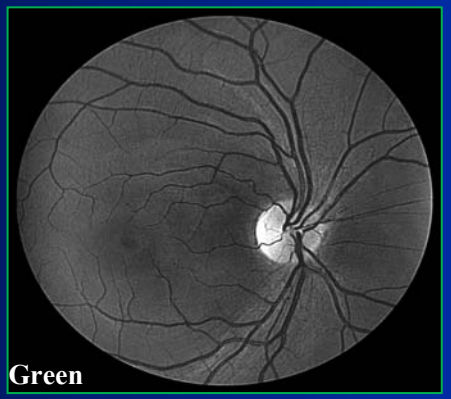

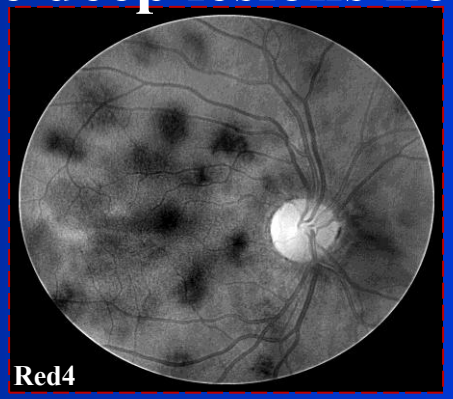

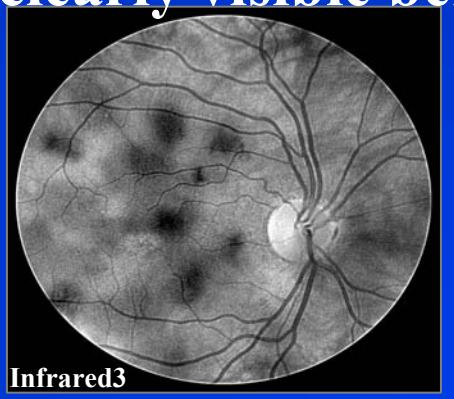

Case 1

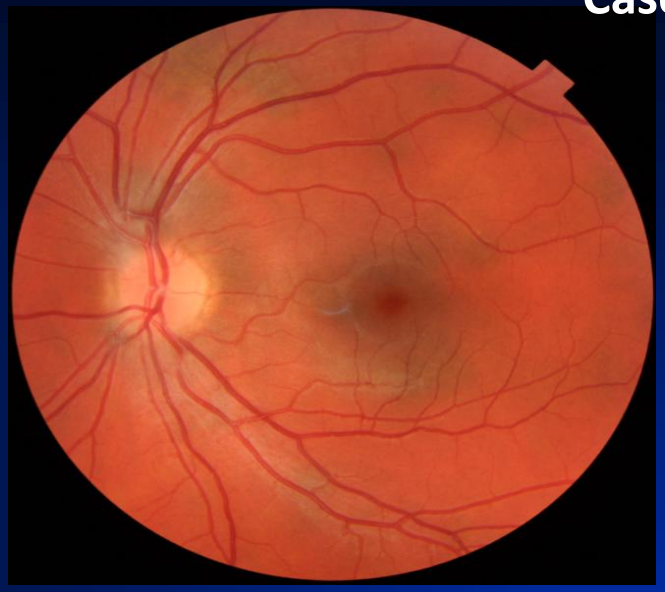

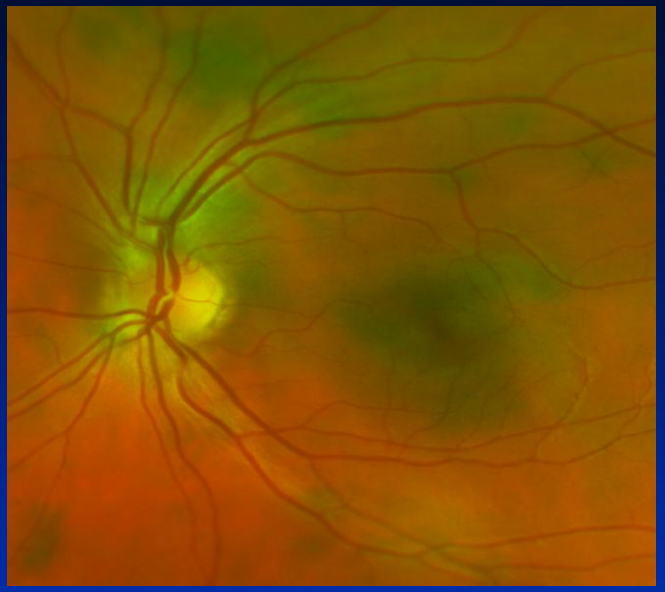

Note similar findings in the left eye as well.

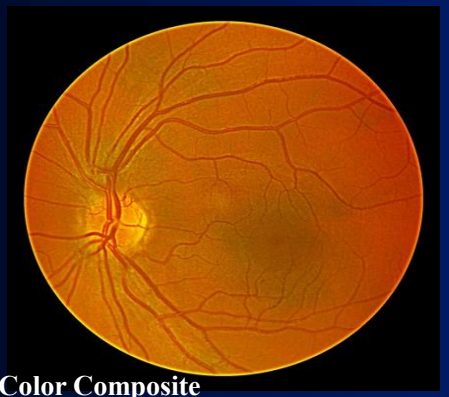

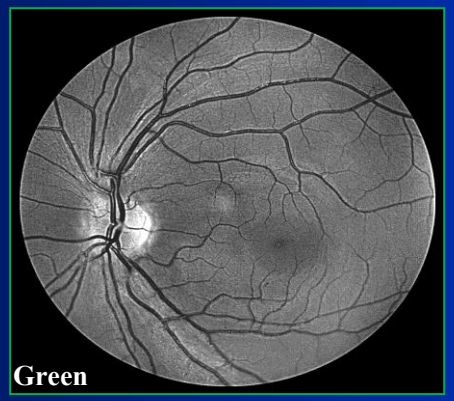

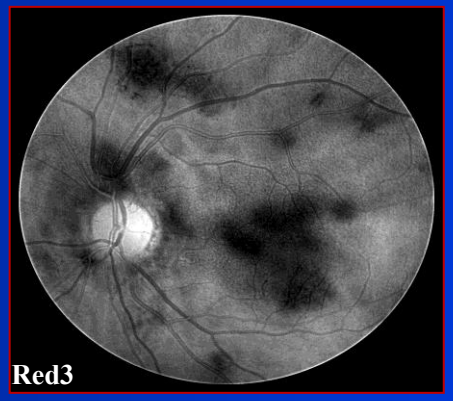

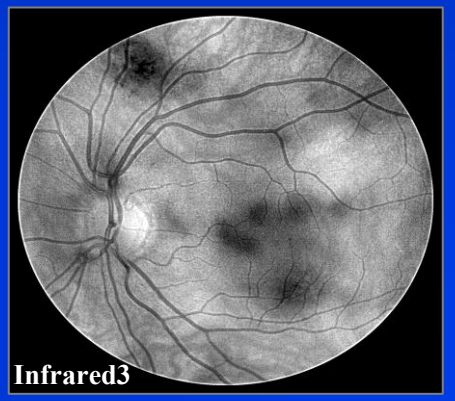

Innovations in Treatment of Retinal Disease

64 y/o White Female
Blurred VA X 10 days
Seen 2 mo ago: normal exam

VA: 20/40

Vitreous Surgery for Macular Holes

- Kelly, Wendel: Arch of Ophth. May 1991
  - 52 patients
  - PPV/Removal vitreous cort, Fld/Gass exchange
  - 58% anatomic success, 73% visual success
  - Overall 42% success rate
- Kelly, Wendel: Ophth Nov1993
  - 170 patients
  - 73% anatomic success, 76% visual success
  - Overall 56% success rate

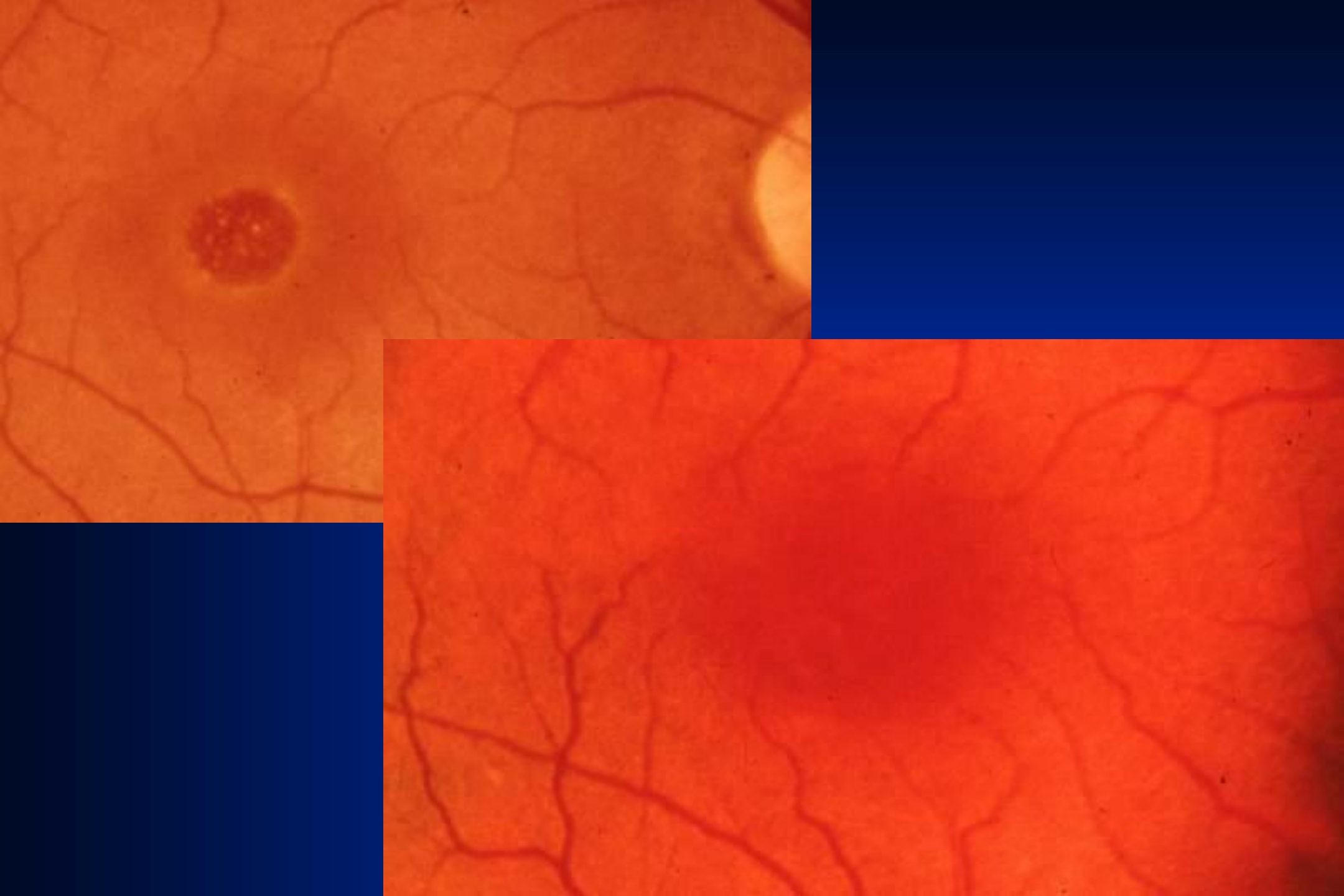

64 y/o White Female
Blurred VA X 10 days
Seen 2 mo ago: normal exam

VA: 20/40

64 y/o White Female
Blurred VA X 10 days
Seen 2 mo ago: normal exam

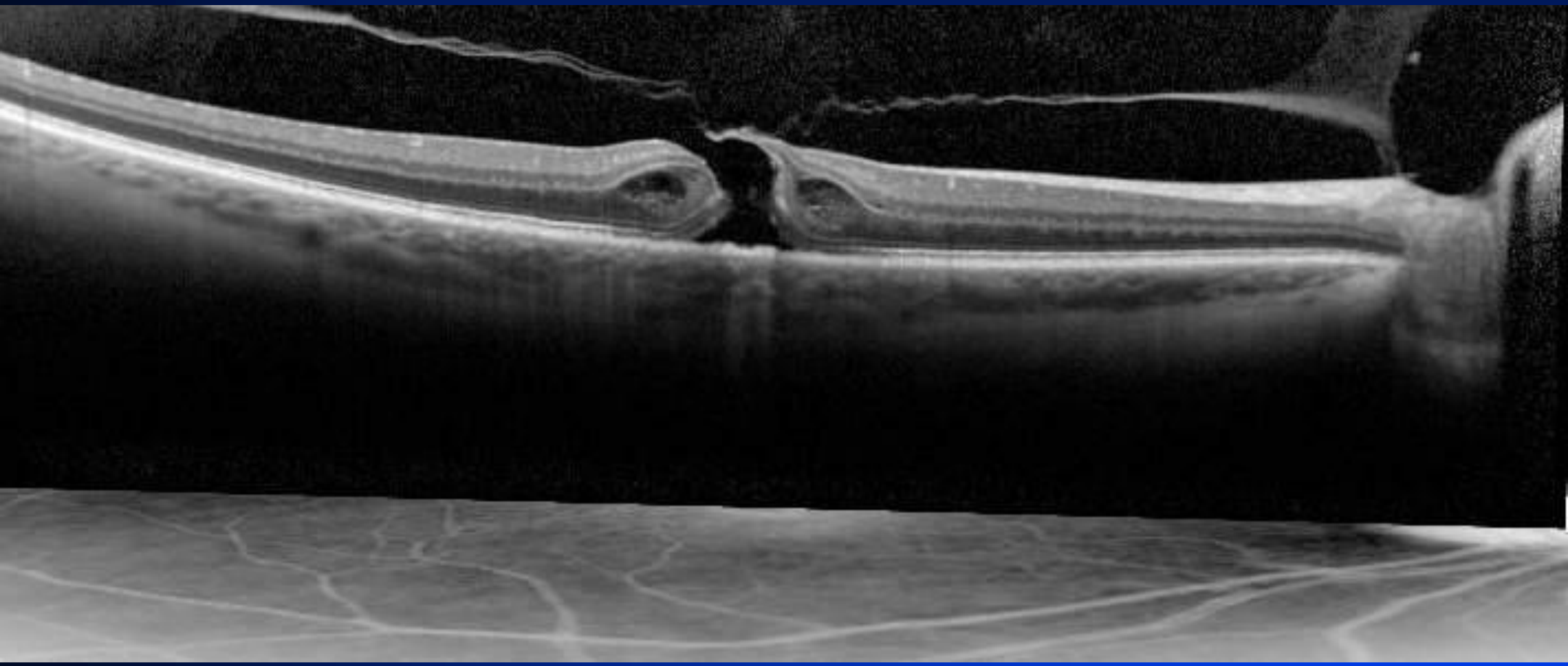

6/1/09

20/30

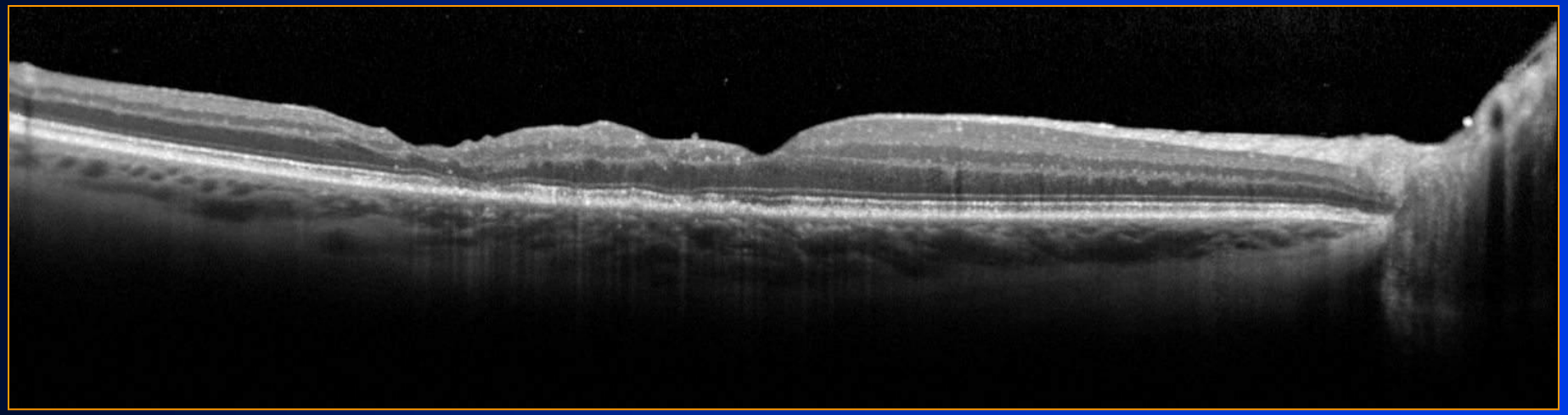

Macular Hole Surgery

Postoperative Period

- Face down for 2 weeks
- Has evolved to face down for 1 wk

Microplasm (ThromboGenics)

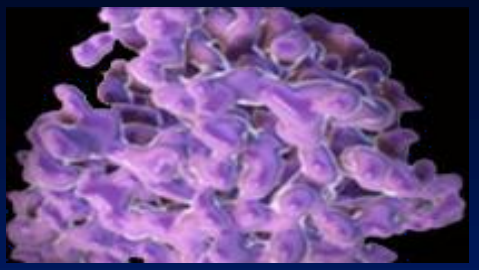

- Microplasmin is a **proteolytic enzyme** that has the potential to facilitate the development of PVD
  - Breaks down the protein structures, which join the vitreous to the retina
    - Results in liquefaction of the vitreous
    - **LYSIS** between vitreous cortex and
- Microplasmin is a molecule created from plasminogen
  - Similar protein formations are also seen linking the vitreous to the retina in the eye
- Microplasmin hs evolved as a non-surgical treatment for focal vitreomacular adhesions and macular hole

Aug 15, 2012 The NEW ENGLAND JOURNAL of MEDICINE

ORIGINAL ARTICLE

Enzymatic Vitreolysis with Ocriplasmin for Vitreomacular Traction and Macular Holes

Peter Stalmans, M.D., Ph.D., Matthew S. Benz, M.D., Arnd Gandorfer, M.D., Anselm Kampik, M.D., Aniz Girach, M.D., Stephen Pakola, M.D., and Julia A. Haller, M.D., for the MIVI-TRUST Study Group*

- **Largest interventional clinical trial ever performed to specifically evaluate the vitreoretinal interface in patients with retinal disorders**
  - **652 pts at 90 centres in Europe and US randomized**
  - 464 with Ocriplasmin, 188 with placebo

MIVI-TRUST Results

Microplasmin for Intra Vitreous Injection-Traction Release without Surgical Treatment

- **652 patients at 90 centers randomized to single intravitreal injection vs placebo injection**
- **26.4% achieved resolution of their VMT by 28 days vs. 10.2% (182 pts) who received placebo**
- **106 PTS with FT macular hole: 40.6% had closure vs. 10.6% (n47 pts) in the placebo**

MIVI-TRUST Results

Microplasmin for Intra Vitreous Injection-Traction Release without Surgical Treatment

- **Pts without ERM had better outcome:**
  - **37.4% (n 270 patients) achieving resolution VS. 14.3% (119 placebo**
- **Total PVD more prevalent among the eyes treated with ocriplasmin than among those injected with placebo (13.4% vs. 3.7%, P<0.001)**

Ocriplasmin: Macular Hole Arm

- Nonsurgical closure of macular holes was achieved in 40.6% of ocriplasmin-injected eyes vs. 10.6% of placebo injected eyes ($P<0.001$).
- BCVA was more likely to improve $\geq$ 3 lines with ocriplasmin
- Ocular adverse events (e.g., vitreous floaters, photopsia, or injection-related eye pain— all self-reported — or conjunctival hemorrhage) occurred in 68.4% of treated eyes vs. 53.5% of placebo-injected eyes ($P<0.001$)
- Conclusion: Intravitreal injection of ocriplasmin resolved VMT and closed macular holes in significantly more patients than did injection of placebo

MIVI-TRUST

Phase III Outcomes:

- **Success in resolving vitreomacular adhesion**
- **Ability to cure full thickness macular hole with no surgery required**
- **Improvement in the vision of patients with no surgery required**
- **Safe and well tolerated**

Microplasim: The Future

- Potential treatments for diabetic retinopathy and AMD, particularly in those patients where vitreomacular adhesion may play an important role in their condition.

VA: 20/40

2008

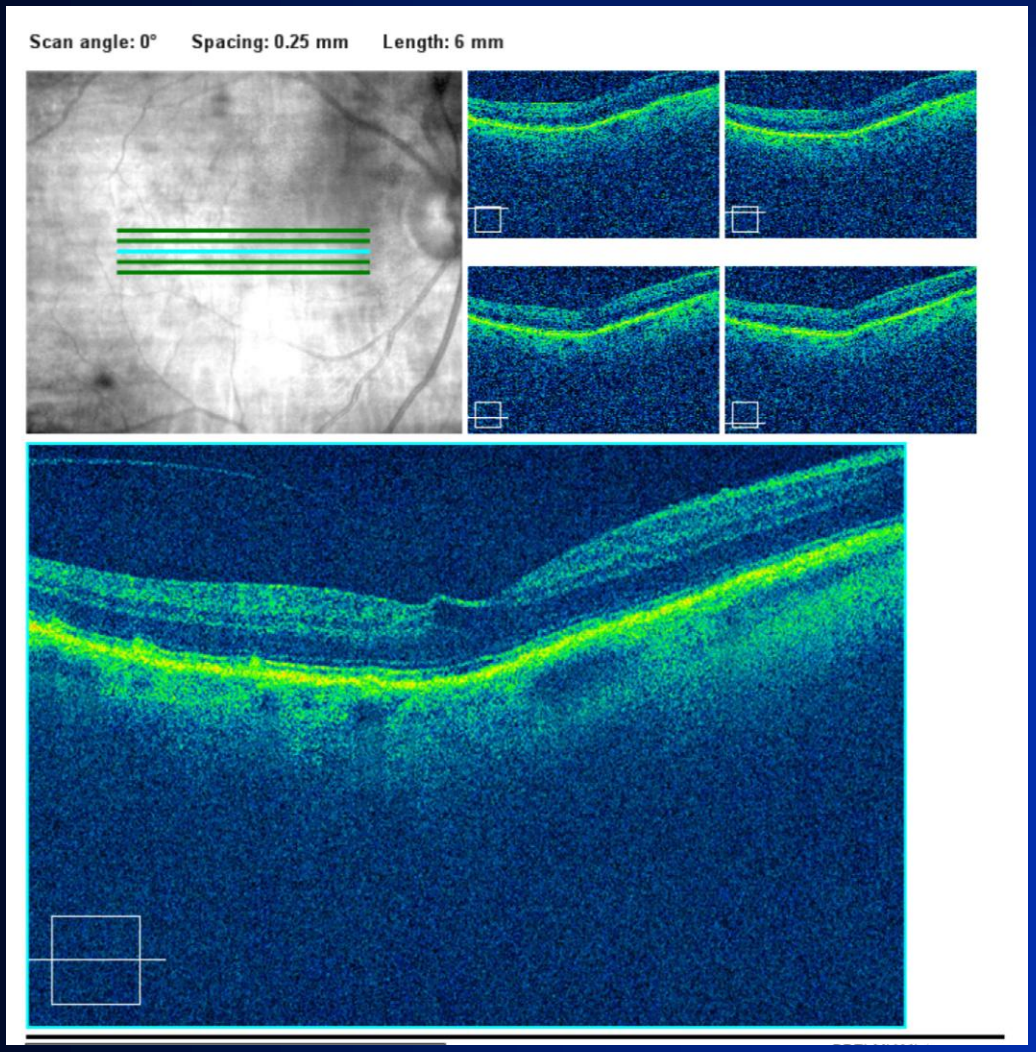

2012

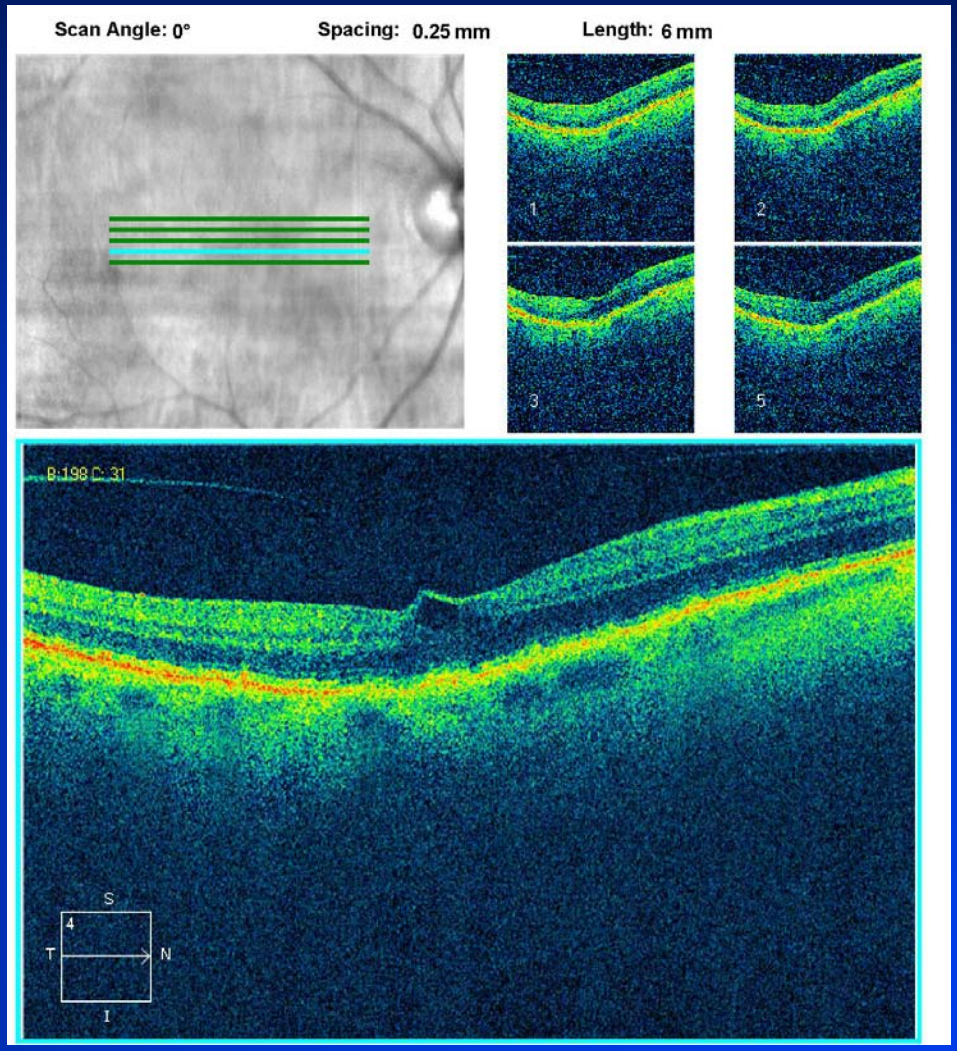

Lucentis vs. Avastin

Is one drug better than the other?

The NEW ENGLAND JOURNAL of MEDICINE

Ranibizumab and Bevacizumab for Neovascular Age-Related Macular Degeneration

The CATT Research Group*

ABSTRACT

BACKGROUND

Clinical trials have established the efficacy of ranibizumab for the treatment of neovascular age-related macular degeneration (AMD). In addition, bevacizumab is used off-label to treat AMD, despite the absence of similar supporting data.

METHODS

In a multicenter, single-blind, noninferiority trial, we randomly assigned 1208 patients with neovascular AMD to receive intravitreal injections of ranibizumab or bevacizumab on either a monthly schedule or as needed with monthly evaluation. The primary outcome was the mean change in visual acuity at 1 year, with a noninferiority limit of 5 letters on the eye chart.

RESULTS

Bevacizumab administered monthly was equivalent to ranibizumab administered monthly, with 8.0 and 8.5 letters gained, respectively. Bevacizumab administered as needed was equivalent to ranibizumab as needed, with 5.9 and 6.8 letters gained, respectively. Ranibizumab as needed was equivalent to monthly ranibizumab, although the comparison between bevacizumab as needed and monthly bevacizumab was inconclusive. The mean decrease in central retinal thickness was greater in the ranibizumab-monthly group (196 μm) than in the other groups (152 to 168 μm, P=0.03 by analysis of variance). Rates of death, myocardial infarction, and stroke were similar for patients receiving either bevacizumab or ranibizumab (P>0.20). The proportion of patients with serious systemic adverse events (primarily hospitalizations) was higher with bevacizumab than with ranibizumab (24.1% vs. 19.0%; risk ratio, 1.29; 95% confidence interval, 1.01 to 1.66), with excess events broadly distributed in disease categories not identified in previous studies as areas of concern.

CONCLUSIONS

At 1 year, bevacizumab and ranibizumab had equivalent effects on visual acuity when administered according to the same schedule. Ranibizumab given as needed with monthly evaluation had effects on vision that were equivalent to those of ranibizumab administered monthly. Differences in rates of serious adverse events require further study. (Funded by the National Eye Institute; ClinicalTrials.gov number, NCT00593450.)

The members of the writing committee (Daniel F. Martin, M.D., Cleveland Clinic Cole Eye Institute, Cleveland; Maureen G. Maguire, Ph.D., Gui-shuang Ying, Ph.D., and Juan E. Grunwald, M.D., University of Pennsylvania, Philadelphia; Stuart L. Fine, M.D., University of Colorado Denver, Aurora; and Glenn J. Jaffe, M.D., Duke University, Durham, NC) assume responsibility for the integrity of the article. Address reprint requests to Dr. Maguire at the Scheie Eye Institute, University of Pennsylvania, 3535 Market St., Suite 700, Philadelphia, PA 19104, or at maguirem@mail.med.upenn.edu.

*The members of the Comparison of Age-Related Macular Degeneration Treatments Trials (CATT) research group are listed in the Supplementary Appendix, available at NEJM.org.

This article (10.1056/NEJMoa1102673) was published on April 28, 2011, at NEJM.org.

N Engl J Med 2011.

Copyright © 2011 Massachusetts Medical Society.

4/28/2011, NEJM.org

Highlights

- 1208 Pts Randomized
- Equivalent VA outcomes: Ranizumab vs. Bevacizumab
  - Lucentis gained 8.5 letters vs. Avastin 8 letters
- Equivalent VA outcomes: monthly vs. PRN ranibizumab
- Inconclusive/ significant difference in VA Bevacizumab monthly vs PRN

Statistics From CATT 1 Year Results

	Lucentis Monthly	Lucentis PRN	Avastin Monthly	Avastin PRN
Average change in acuity (letters gained)	8.5	6.8	8.0	5.9
Average ending visual acuity score (mean no. of letters)	68.8	68.4	68.4	66.5
Decrease in CMT (μm)	196	168	164	152
Number treatments needed	11.7	6.9	11.9	7.7
Systemic adverse events (TIA, MI, CVA, HTN)	6.9%	7.1%	8.0%	10.4%

CMT=central macular thickness
CVA=cardiovascular accident
HTN=hypertensive nephropathy
MI=myocardial infarction
TIA=transient ischemic attack

CATT Research Group. *N Engl J Med*. 2011;364(20):1897-1908.

CATT: 2 Year Results

- 1,107 patients followed for yr 2
- Patients initially assigned to monthly treatment were reassigned randomly to monthly or as-needed without changing the drug assignment
- Mean gain in VA was similar for both
- Mean gain was greater for monthly treatment than for as-needed (difference, -2.4 letters; 95% CI
- The proportion of patients without fluid:
  - 13.9% in the bevacizumab as-needed group
  - 45.5% in the ranibizumab monthly group (drug, P = .0003; regimen, P <.0001).

ARVO May 2012

CATT: 2 Year Results

Other interesting tidbits:

- **Estimated 2-year drug cost per patient:**
  - **$705 in the bevacizumab as-needed group to $44,800 in the ranibizumab monthly group.**
- **Proportion of eyes with geographic atrophy at 2 years ranged:**
  - **25.8% in the ranibizumab monthly group**
  - **12.9% in the bevacizumab as-needed group**

Ranibizumab versus Bevacizumab to Treat Neovascular Age-related Macular Degeneration

One-Year Findings from the IVAN Randomized Trial

*The IVAN Study Investigators**
Writing Committee: Usha Chakravarthy, PhD, FRCS,[1] Simon P. Harding, MD, FRCS,[2] Chris A. Rogers, PhD,[3] Susan M. Downes, MD, FRCS,[4] Andrew J. Lotery, MD, FRCS,[5] Sarah Wordsworth, PhD,[6] Barnaby C. Reeves, DPhil[3]

bevacizumab; bevacizumab was less costly for both treatment regimens ($P<0.0001$).

Conclusions: The comparison of visual acuity at 1 year between bevacizumab and ranibizumab was inconclusive. Visual acuities with continuous and discontinuous treatment were equivalent. Other outcomes are

Eylea

- VEGF Trap-Eye
- Mimics the VEGF receptor, traps VEGF
- Recently FDA approved for q8wk dosing
- Q8wk dosing = q4wk Lucentis dosing

Eylea: VEGF Trap by Regeneron

- Recombinant soluble VEGF receptor with affinity to all VEGF-A, placental growth factor 1&2, VEGF-B,C&D
  - Creates decoy receptor to "Trap" the VEGF

- VEGF Trap-EYE
  - Intravitreal injections
  - Similar ophthalmic results without systemic findings

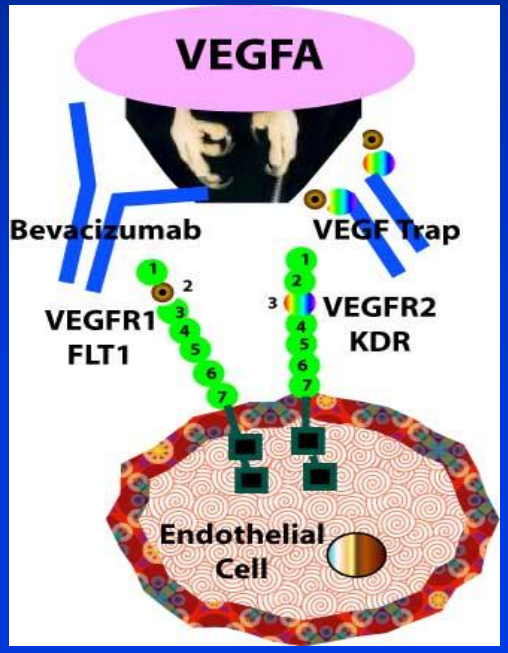

VEGF Trap and CNVM in AMD: Nguyen et al. Ophthalmology Vol 113 Sep 2006. 1522-32

Results of VEGF Trap VEGF trap vs SHAM

- Galileo 6M results
  - 60% of pts in txed gained ≥15 letters
    - Mean gained was 18 letters for treated and 3 letters for sham grp
- Copernicus 6M results
  - 56% of pts in txed group gained ≥15 letters
    - Mean gain was 17 letters in Tx group vs 4 letters in sham group

At month 6 sham grp transfer to trt & treated grp gets PRN

2nd yr of study: pts will continue tx w same dose but every 3M(sooner if worsening)

- **Results:**
  - VIEW 1 was US and VIEW 2 was international
  - ≥90% maintained VA in ALL grps

	Ranibizumab 0.5 mg monthly	VEGF Trap-Eye 0.5 mg monthly	VEGF Trap-Eye 2 mg monthly	VEGF Trap-Eye 2 mg every two mos.
Maintenance of vision* (% patients losing <15 letters) at week 52 versus baseline				
VIEW 1	94.4%	95.9%**	95.1%**	95.1%**
VIEW 2	94.4%	96.3%**	95.6%**	95.6%**
Mean improvement in vision* (letters) at 52 weeks versus baseline (p-value versus ranibizumab 0.5 mg monthly)**				
VIEW 1	8.1	6.9 (NS)	10.9 ($p<0.01$)	7.9 (NS)
VIEW 2	9.4	9.7 (NS)	7.6 (NS)	8.9 (NS)

Recently received *FDA approval*

Am J Ophthalmol. 2012 Aug;154(2):222-6.

PERSPECTIVE

Aflibercept for Age-Related Macular Degeneration: A Game-Changer or Quiet Addition?

DAVID J. BROWNING, PETER K. KAISER, PHILIP J. ROSENFELD, AND MICHAEL W. STEWART

• CONCLUSIONS: Aflibercept promises to deliver excellent visual outcomes for exudative age-related macular degeneration patients while undergoing fewer injections compared with ranibizumab. With a wholesale cost of $1850 per dose, the cost per patient with aflibercept treatment promises to be lower than with ranibizumab.
(Am J Ophthalmol 2012;154:222–226. © 2012 by Elsevier Inc. All rights reserved.)

Age-Related Macular Degeneration

Normal disease progression

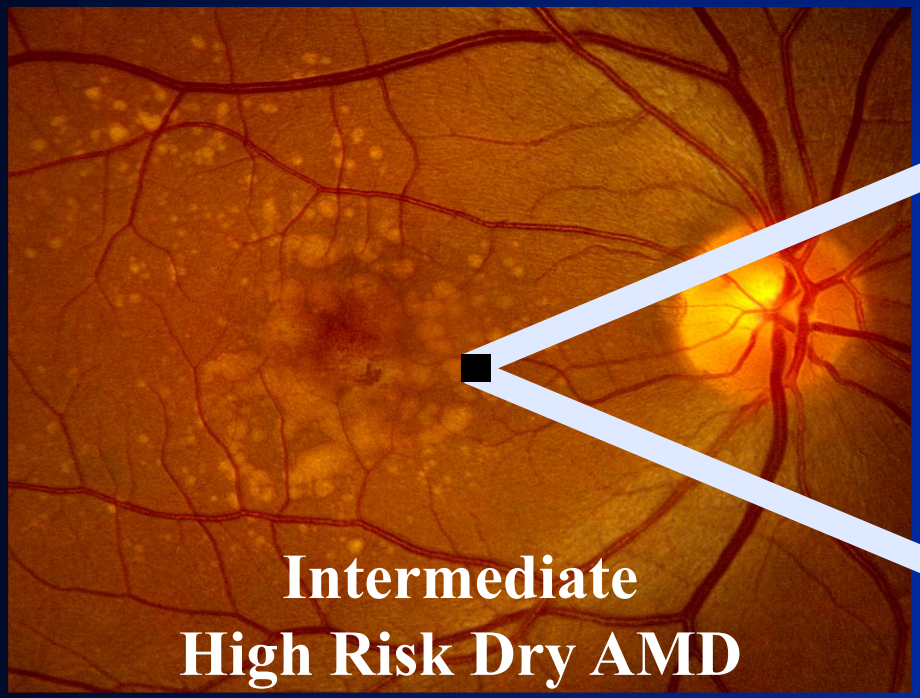

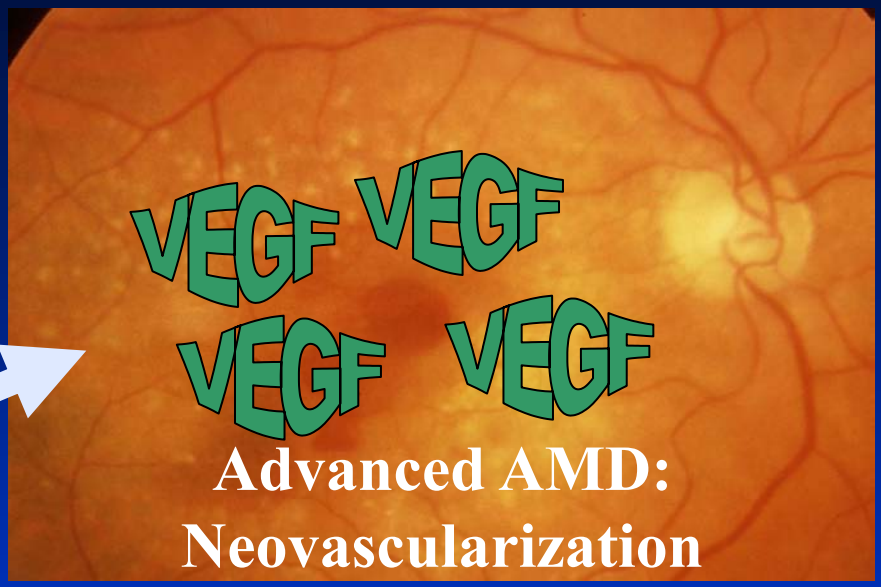

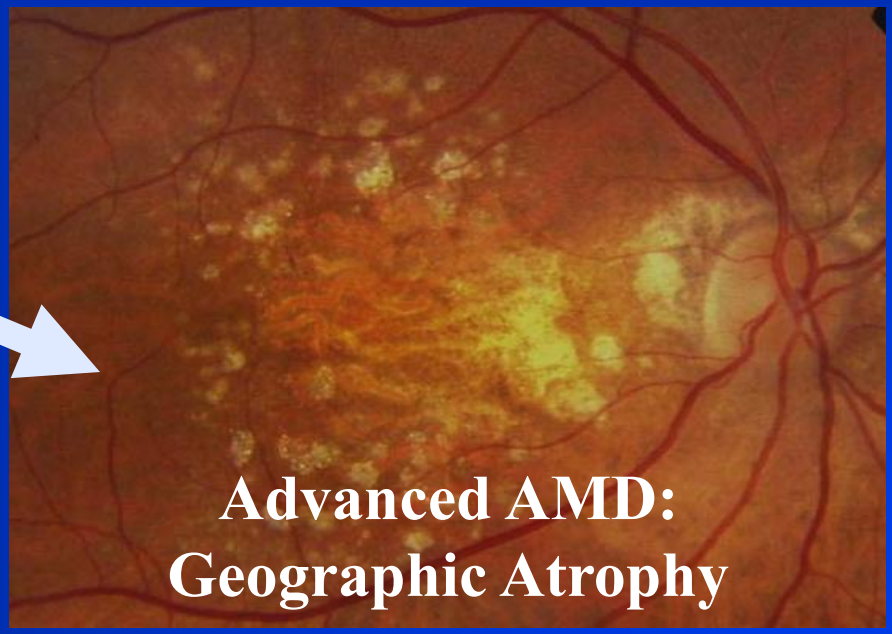

Age-Related Macular Degeneration

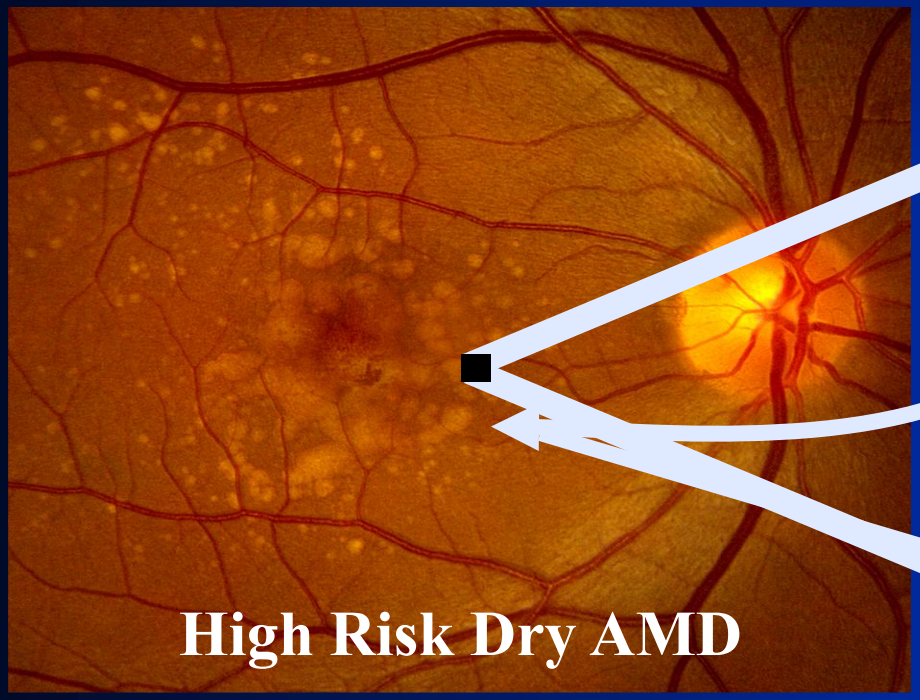

High Risk Dry AMD

Vitamin and nutritional recommendations just slow progression

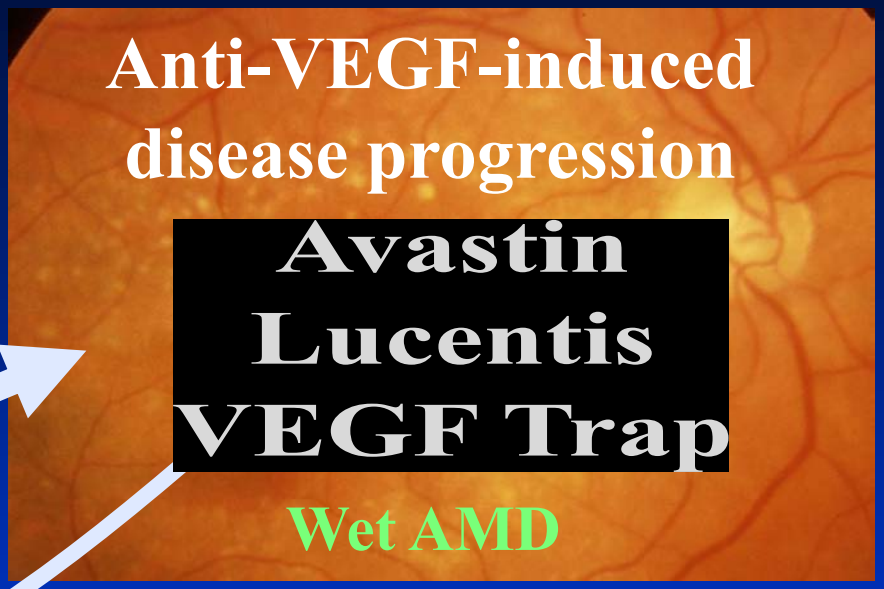

Anti-VEGF-induced disease progression

Avastin
Lucentis
VEGF Trap

Wet AMD

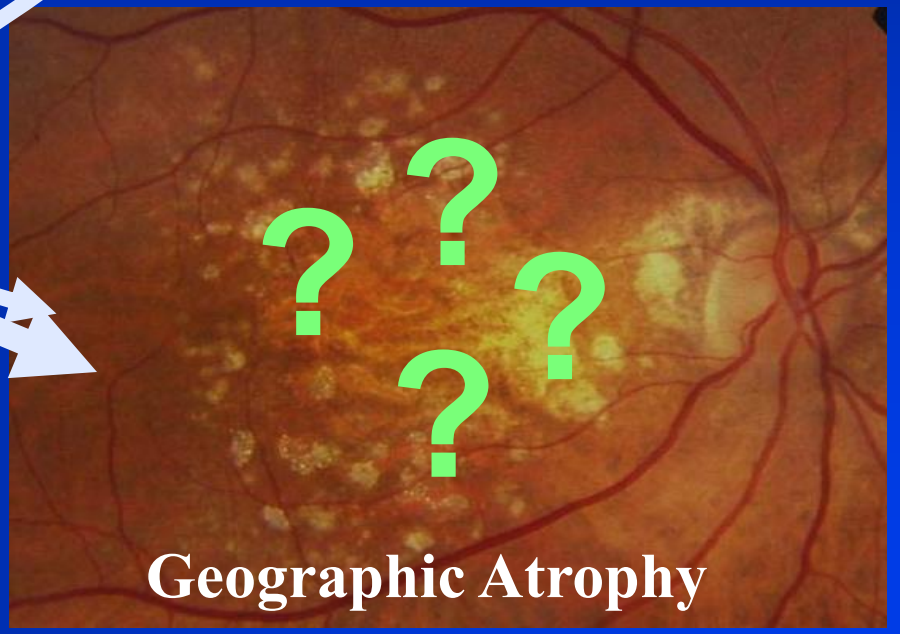

Geographic Atrophy

Emerging Treatments for Dry AMD

- **Treatment strategies:**
  - **Prevent photoreceptor & RPE loss**
    - **Neuroprotection**
    - **Block build-up of toxic metabolites**
    - **Prevent oxidative damage**
    - **Suppress inflammation (Histopathology and Genome Wide Association Studies)**

Genetic Breakthroughs in AMD: 2005

NEI News Release
March 2005

Gene Found to Increase Risk of AMD

- **4 independent research teams (including NEI) discovered a gene that is "strongly associated" with the development of AMD**
- **Gene is called Compliment Factor H**
- **CFH gene produces a protein that helps regulate inflammation in part of the immune system that attacks diseased and damaged cells**

The Compliment System

- The Complement Pathway is one of the body's primitive defense systems - more primitive than antibodies, that fights against disease
- Complement activation is an inflammatory process involving dozens of plasma proteins, ultimately leading to cell membrane disruption through a process called the membrane attack complex (MAC)
- Inappropriate or excessive complement activation can have destructive consequences

Diseases in which Complement Pathway Has Been Implicated

- Membraneoproliferative glomerulonephritis type II (MGNII)
- Atypical hemolytic uremic syndrome (aHUS)
- Paroxymal nocturnal hematuria (PNH)
- Rheumatoid arthritis
- Systemic lupus erythematosis (SLE
- Myocarditis
- Multiple sclerosis (MS)
- Traumatic brain injury
- Traumatic spinal cord injury
- Intestinal and renal IR (ischemia-reperfusion) injury
- Anti-phospholipid Ab syndrome
- Recurrent pregnancy loss syndrome
- Asthma
- Ab-mediated cutaneous disease

The role of complement factor H in Age-relatd macular degeneration: A review. Surv Ophthalmol. 2010 May-Jun;55(3):227-46.

Understanding AMD: Putting it All Together

- CFH helps regulates this complement system to prevent it from "getting out of control"
- Drusen contain most all of the proteins that make up the complement system
- AMD may result from a deficiency in regulation of the Complement System
  - Key driver in angiogenesis

Age-Related Macular Degeneration (AMD)

2005 - 2008: Three complement genes strongly associated with AMD

- 2005 — Complement Factor H (CFH)
- 2006 — Component C2/Factor B
- 2007 — Component C3
  - Component C7
  - Mannose Binding Lectin 2
- 2008
  - CFH-related gene 1 (CFHR 1)
  - CFH-related gene 3 (CFHR 3)
  - C1 Inhibitor

ArcticDX Inc.

http://www.arcticdx.com/index.jsp

Revolutionary Genetic Test Now Available for AMD

- March 10, 2009: For the first time ever, an individual's inherent risk of developing this devastating eye disease can be determined
- ArcticDX inc: a molecular diagnostic company with expertise in the design, development and commercialization of validated molecular diagnostic tests
- The test is called: Macula Risk (R)

AMD – A Genetic Disease

Macula Risk®

A test that identifies AMD patients that will progress to Adv stage of dz with associated VL.

83% Predictive Value*

J.M. Seddon, B Rosner et al; IOVS Papers in Press Dec. 2008

Patient Sampling

1. In office saliva test / cheek swab;
2. No refrigeration;
3. No hazardous material (transportation issues);
4. Recommend gloves for Technicians
5. NO CLIA form necessary
6. Inform consent

The Genetic Components of AMD

Naturally occurring variations conferring AMD risk

Drusen
Complement Protein

VEGF
Oxidative Stress

Marker	Allele	Odds Ratio	Freq
CFH	H1+H3 (risk)	>17	0.202
	Average		0.495
	(H2+H4)		0.303
C3 rs2230199	G (risk)	2.6	0.18
	C		0.83
ARMS2 (indel)	(risk)	8.2	0.17
	(no-risk)		0.83
Smoking	Current (risk)	3.14	0.17
	Never		0.55
ND2 mt A4917G	G (risk)	2.2	0.09
	A		0.90

Version 2: Add C2BF, CFI, LIPC, TIMP3

3 Gene Groups Involved in AMD

- Inflammation
- Oxidation
- Mitochondrial health

Macula Risk® Score

Risk of Progressing to Advanced AMD by 80 Years of Age

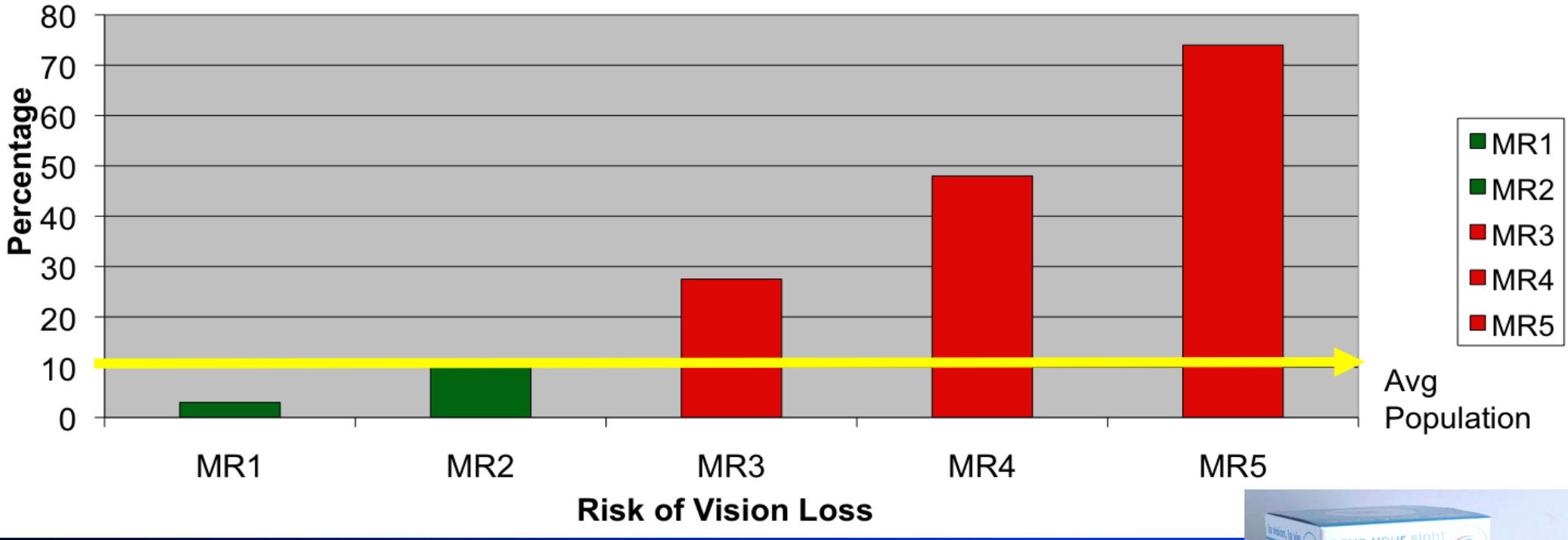

The Macula Risk® results place the patient in 1 of 5 different categories which correlates to the patient's risk of developing AMD that progresses to vision loss.

Sample Patient Report, Macula Risk Category 1

PATIENT TEST RESULTS

Risk Measures

OVERALL RESULTS SUMMARY	TOTAL RISK SCORE[1]: 2.7
RISK CATEGORY: 1	LIFETIME RISK: 0.65 - 4.6% (2.4% median)

[1]Your total risk score was calculated using your genotypes for the 8 SNPs listed below and your smoking history. For detailed information on how your risk score was derived please refer to the "Explanation of risk score calculation used in this test" on page 3 – 4.

GENE	SNP[2]	GENOTYPE	HAPLOTYPE[3]	COMMENT
Complement Factor H (CFH)	rs1048663	GG	H2/H2	This haplotype is associated with a low risk for AMD
	rs3766405	TT		
	rs412852	TT		
	rs11582939	CC		
	rs1066420	AA		
Complement Component 3 (C3)	rs2230199	CC	Two copies for non risk allele detected	

Drusen - related

GENE	SNP[2]	GENOTYPE	COMMENT
Age-Related Maculopathy Susceptibility 2 (ARMS2)	NM_001099667.1:C.*372_815del443ins54	Heterozygous	One copy for indel risk variant detected
Mitochondrially encoded NADH dehydrogenase 2 (MT-ND2)	rs28357980	A	Low risk allele detected

Oxidative stress

AMD Management Today

CNV

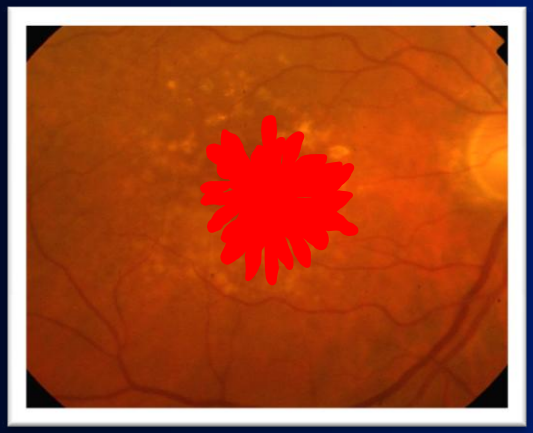

Referral to Retina Specialist

Treat First Eye

Lucentis / Avastin /Combinations

Focus on Saving the Second Eye

Risk of Conversion to Advanced AMD 14.8% - 53.1%[1]

[1] *AREDS Report No.18: Arch Ophthalmol / Vol: 123, Nov 2005*

Save the First Eye

Dry AMD

1/5

Treat First Eye

+

Save the Second Eye

Risk of Advanced AMD
15% - 96.5%[1]

[1] Macula Risk Prognostic Score @ 3,4,5

'Predict and Protect'

Risk of Advanced AMD
14.8% - 53.1%[2]

[2] AREDS Report No.18: Arch Ophthalmol / Vol 123, Nov 2005

Macula Risk Score

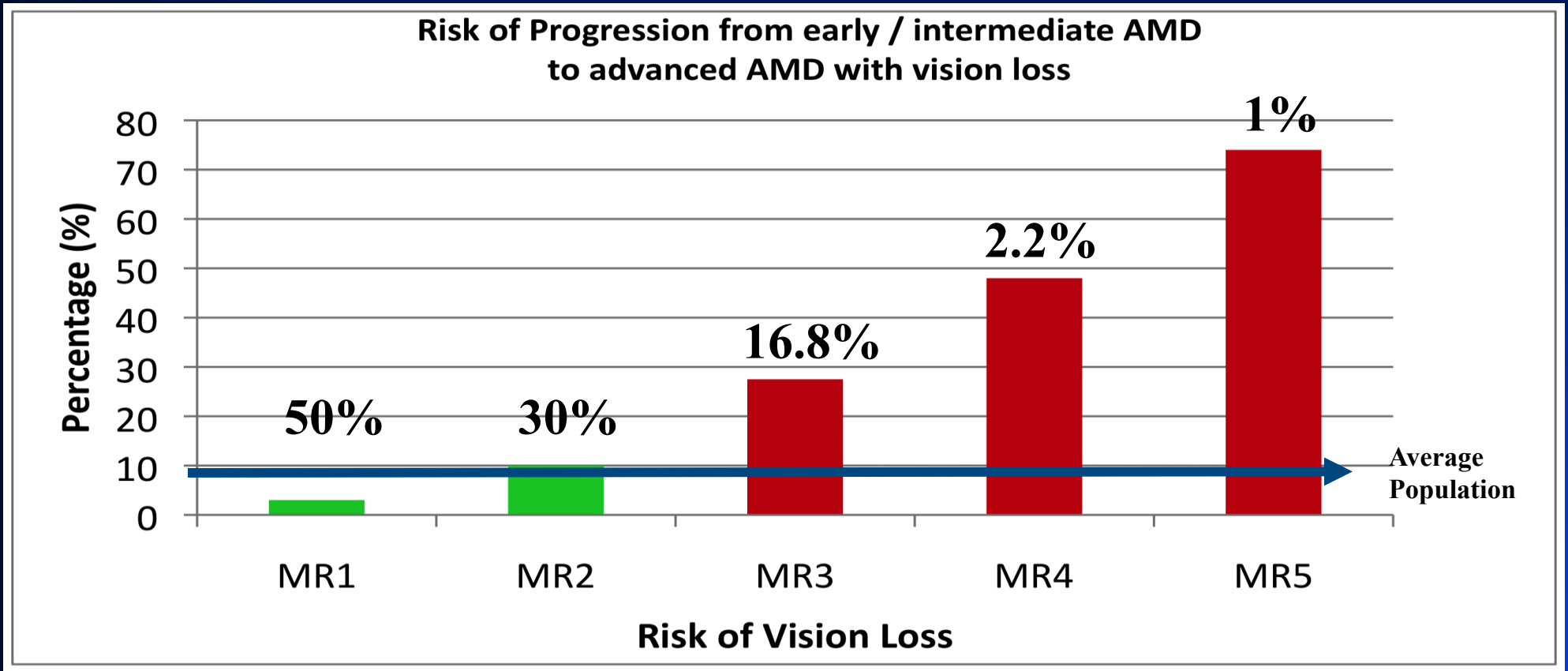

Macula Risk 3, 4 & 5 = 20% of the Caucasian population

Highest Risk

Patient profile:

- Age greater than 65;
- Present with Drusen;

Should be monitored more than once / year

Macula Risk Score	Risk of GA or CNV (%)	Prevalence %
1 (Low)	0-5	49.6
2 (Average)	6-15	30.6
3 (Increased)	16-40	16.6
4 (High)	40-55	2.2
5 (Very High)	55 – 96.5	1.0

The AMD Lane…Predict and Protect

Dry AMD

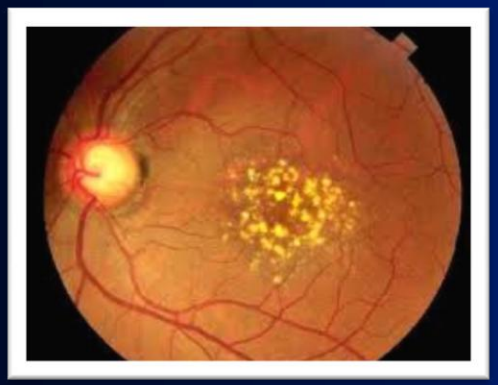

1/5

Treat First Eye Earlier

+

Save Both Eyes

Practice Recommendations

- **All specialties screen patients over 65 yrs and/or with drusen (early/int. AMD);**
- **Consult w / Retina or share retinal photo's for 2nd opinion *If you have technology***

- **Monitor MR 1 & 2……. 12 – 24 months;**
- **Monitor MR 3…… Twice per year;**
- **Monitor MR 4…… Three times per year;**
- **Monitor MR 5…… Four times per year;**

High Risk (20%)

- **Ongoing Follow-up, patient/family education, etc. with practice**

Which of the New Technologies Do You Think Will Emerge Ready For The Prime Time Optometrist”

A. FAF
B. Multi-Spectral Imaging (Annidis)

Which Feature of an SD OCT Would Influence You Most to Buy That Brand?

A. Overall image quality
B. Advances in software
C. Price
D. Loyalty to a company

How Likely Would You Perform Genetic Testing on Your AMD Patients This Year?

A. Not very
B. Highly likely
C. I already have
D. I routinely do it