

REVIEW[®] *of* OPTOMETRY

ANNUAL DIAGNOSTIC SKILLS
AND TECHNIQUES ISSUE

Slit lamp technique, PAGE 32

Optic nerve edema, PAGE 40

Peripheral retinal exam, PAGE 48

New VF headsets, PAGE 58

February 15, 2024 • reviewofoptometry.com

Leadership in clinical care

Navigating Optic Nerve Differentials

Times Change

Address the dynamic vision needs of today's
presbyopes with **INFUSE[®] Multifocal**.



FIND OUT HOW



REVIEW[®] *of* OPTOMETRY

February 15, 2024 • reviewofoptometry.com

Leadership in clinical care

ANNUAL DIAGNOSTIC SKILLS
AND TECHNIQUES ISSUE

Slit lamp technique, PAGE 32

Optic nerve edema, PAGE 40

Peripheral retinal exam, PAGE 48

New VF headsets, PAGE 58

Navigating Optic Nerve Differentials

Use this systematic protocol to arrive at the
proper diagnosis without delay.

Page 40

↑ 11mi
Continue Straight

↙ 2.2mi
Take Exit

↘ .08mi
Turn Right

🛢️
↘ 15mi

60
mph

🚗
60

For the treatment of all stages
of neurotrophic keratitis (NK)



NOT JUST ANY SOLUTION A RESOLUTION

Complete and long-lasting resolution of NK for most patients*¹⁻⁴

- Up to 72% of patients achieved complete corneal healing in clinical trials*¹⁻³
- 80% of these patients remained healed at 1 year (REPARO trial)*⁴

* Resolution was evaluated in clinical trials as complete corneal healing, defined as the absence of staining in the lesion area and no persistent staining in the rest of the cornea after 8 weeks of treatment and as <0.5-mm lesion staining at 48-week follow-up.^{1,3}

† Key study findings were after 8 weeks of treatment, 6 times daily. REPARO (Study NGF0212): 52 European patients with neurotrophic keratitis (NK) in 1 eye per group; 72% of patients completely healed; vehicle response rate 33.3%.

Study NGF0214: 24 US patients with NK in 1 or both eyes per group; 65.2% completely healed; vehicle response rate 16.7%.^{2,3}

Important Safety Information WARNINGS AND PRECAUTIONS

Use with Contact Lens

Contact lenses should be removed before applying OXERVATE because the presence of a contact lens (either therapeutic or corrective) could theoretically limit the distribution of cenergermin-bkbj onto the area of the corneal lesion. Lenses may be reinserted 15 minutes after administration.

Eye Discomfort

OXERVATE may cause mild to moderate eye discomfort such as eye pain during treatment. The patient should be advised to contact their doctor if a more serious eye reaction occurs.

ADVERSE REACTIONS

In clinical trials, the most common adverse reaction was eye pain following instillation which was reported in approximately 16% of patients. Other adverse reactions occurring in 1% to 10% of OXERVATE patients and more frequently than in the vehicle-treated patients included corneal deposits, foreign body sensation, ocular hyperemia, ocular inflammation and tearing.

USE IN SPECIFIC POPULATIONS

Pregnancy

There are no data from the use of OXERVATE in pregnant women to inform any drug associated risks.

Lactation

The developmental and health benefits of breastfeeding should be considered, along with the mother's clinical need for OXERVATE, and any potential adverse effects on the breastfed infant from OXERVATE.

Pediatric Use

The safety and effectiveness of OXERVATE have been established in the pediatric population. Use of OXERVATE in pediatric patients 2 years of age and older is supported by evidence from adequate and well-controlled trials of OXERVATE in adults with additional safety data in children.

INDICATION

OXERVATE® (cenergermin-bkbj) ophthalmic solution 0.002% (20 mcg/mL) is indicated for the treatment of neurotrophic keratitis.

DOSAGE AND ADMINISTRATION

Instill one drop of OXERVATE in the affected eye(s), 6 times a day at 2-hour intervals for eight weeks.

To report ADVERSE REACTIONS, contact Dompé U.S. Inc. at 1-833-366-7387 or FDA at 1-800-FDA-1088 or www.fda.gov/medwatch.

Please see the Brief Summary of full Prescribing Information for OXERVATE on the following page.

References: 1. OXERVATE® (cenergermin-bkbj) ophthalmic solution 0.002% (20 mcg/mL) [US package insert], Boston, MA; Dompé U.S. Inc.; 2019. 2. Bonini S, et al. *Ophthalmology*. 2018;125:1332-1343. 3. Pflugfelder SC, et al. *Ophthalmology*. 2020;127:14-26. 4. Data on File. Clinical Study Report (NGF0212). Dompé U.S. Inc., 2016.

oxervate® 
(cenergermin-bkbj ophthalmic
solution) 0.002% (20 mcg/mL)



Brief Summary of full Prescribing Information

Consult the full Prescribing Information for complete product information, available at www.oxervate.com/prescribing-information.

INDICATIONS AND USAGE

OXERVATE® (cenegermin-bkbj) ophthalmic solution 0.002% is indicated for the treatment of neurotrophic keratitis.

DOSAGE AND ADMINISTRATION

General Dosing Information

Contact lenses should be removed before applying OXERVATE and may be reinserted 15 minutes after administration.

If a dose is missed, treatment should be continued as normal, at the next scheduled administration.

If more than one topical ophthalmic product is being used, administer the eye drops at least 15 minutes apart to avoid diluting products. Administer OXERVATE 15 minutes prior to using any eye ointment, gel or other viscous eye drops.

Recommended Dosage and Dose Administration

Instill one drop of OXERVATE in the affected eye(s), 6 times a day at 2-hour intervals for eight weeks.

WARNINGS AND PRECAUTIONS

Use with Contact Lens

Contact lenses should be removed before applying OXERVATE because the presence of a contact lens (either therapeutic or corrective) could theoretically limit the distribution of cenegermin-bkbj onto the area of the corneal lesion. Lenses may be reinserted 15 minutes after administration.

Eye Discomfort

OXERVATE may cause mild to moderate eye discomfort such as eye pain during treatment. The patient should be advised to contact their doctor if a more serious eye reaction occurs.

ADVERSE REACTIONS

Clinical Studies Experience

Because clinical studies are conducted under widely varying conditions, adverse reaction rates observed in the clinical studies of a drug cannot be directly compared to rates in the clinical studies of another drug and may not reflect the rates observed in practice.

In two clinical trials of patients with neurotrophic keratitis, a total of 101 patients received cenegermin-bkbj eye drops at 20 mcg/mL at a frequency of 6 times daily in the affected eye(s) for a duration of 8 weeks. The mean age of the population was 61 to 65 years of age (18 to 95). The majority of the treated patients were female (61%). The most common adverse reaction was eye pain following instillation which was reported in approximately 16% of patients. Other adverse reactions occurring in 1-10% of OXERVATE patients and more frequently than in the vehicle-treated patients included corneal deposits, foreign body sensation, ocular hyperemia, ocular inflammation and tearing.

USE IN SPECIFIC POPULATIONS

Pregnancy

Risk Summary

There are no data from the use of OXERVATE in pregnant women to inform any drug associated risks.

Administration of cenegermin-bkbj to pregnant rats or rabbits during the period of organogenesis did not produce adverse fetal effects at clinically relevant doses. In a pre- and postnatal development study, administration of cenegermin-bkbj to pregnant rats throughout gestation and lactation did not produce adverse effects in offspring at clinically relevant doses.

Lactation

Risk Summary

There are no data on the presence of OXERVATE in human milk, the effects on breastfed infant, or the effects on milk production. The developmental and health benefits of breastfeeding should be considered, along with the mother's clinical need for OXERVATE, and any potential adverse effects on the breastfed infant from OXERVATE.

Pediatric Use

The safety and effectiveness of OXERVATE have been established in the pediatric population. Use of OXERVATE in this population is supported by evidence from adequate and well-controlled trials of OXERVATE in adults with additional safety data in pediatric patients from 2 years of age and older.

Geriatric Use

Of the total number of subjects in clinical studies of OXERVATE, 43.5 % were 65 years old and over. No overall differences in safety or effectiveness were observed between elderly and younger adult patients.

NONCLINICAL TOXICOLOGY

Carcinogenesis, Mutagenesis, Impairment of Fertility

Carcinogenesis and Mutagenesis

Animal studies have not been conducted to determine the carcinogenic and mutagenic potential of cenegermin-bkbj.

Impairment of fertility

Daily subcutaneous administration of cenegermin-bkbj to male and female rats for at least 14 days prior to mating, and at least 18 days post-coitum had no effect on fertility parameters in male or female rats at doses up to 267 mcg/kg/day (1709 times the MRHOD).

In general toxicology studies, subcutaneous and ocular administration of cenegermin-bkbj in females was associated with ovarian findings including persistent estrus, ovarian follicular cysts, atrophy/reduction of corpora lutea, and changes in ovarian weight at doses greater than or equal to 19 mcg/kg/day (119 times the MRHOD).





Ten States Actively Pursuing Lasers in 2024

California's most recent bill is already out of the running, but many others continue to progress.

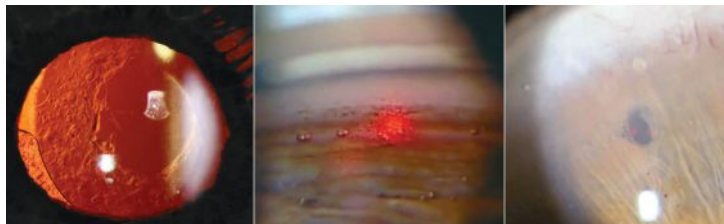
We're less than two months into 2024, and a lot has happened regarding scope expansion efforts across the US. At least a dozen states, as well as Washington, D.C., have introduced or plan to introduce legislation this year advocating for various optometric privileges. Several states are still working out the language of their bills, but at least 10 plan to pursue optometric laser privileges.

Last month, California had its newest laser bill prematurely kicked to the curb. With this state out of the running, the remaining ones with active laser legislation for 2024 include Alabama, Nebraska, New Jersey, Ohio, West Virginia, Utah, Vermont, New Hampshire, South Dakota, Missouri and likely others.

Here's more on what went wrong in California and where things stand with some of the other bills that have been introduced so far this year.

California's Laser Bill Killed Without Explanation

Optometrists in California are experiencing a sad feeling of *déjà vu* after the recent announcement that the state's laser bill, AB 1570, is officially out of the running for the 2024 legislative session, despite passing the Assembly Business and Professions Committee just a few weeks prior. ODs and advocates in the state first began pursuing this legislation in 2022 and secured enough votes for passage only to see it ultimately vetoed by Governor Gavin Newsom, who expressed concern



Most states with scope expansion legislation in play in 2024 are pushing optometric laser privileges, which will help improve patient access to these necessary procedures for glaucoma and post-cataract surgery care.

about optometrists' level of training on advanced procedures in his letter defending his decision. This time around, there seems to be no reason offered why the bill was killed.

"Our scope of practice bill, AB 1570, died today," Kristine Shultz, executive director of the California Optometric Association (COA), regrettably wrote in a message sent out to COA members on January 18. "It was held back on Assembly Appropriations Committee Suspense File. This means there was no vote and no official reason given." She added, "I'm very disappointed in the Legislature, but I'm proud of all of you."

Despite the loss, it's encouraging to see such a tremendous level of support displayed by optometrists and advocates across the state. The COA shares that about a dozen optometrists showed up in person to testify in support at the Business and Professions Committee Hearing on January 9 with very little notice. Additionally, Ms. Shultz says "23

"What can I do to help?" Advocates consistently stress that supporters of scope expansion should reach out to their respective state associations to learn how to help 'fight the good fight' for your profession and your patients.

COA members met with their lawmakers in person or via Zoom to advocate for this legislation and 248 people called their lawmakers in the weeks prior to the hearing. Some had their family and employees call, too. These actions didn't go unnoticed at the Capitol."

The COA's lobbying team has already regrouped to begin discussing the options moving forward. One thing is for sure—the battle for lasers isn't over.

"The legislative process isn't easy," Ms. Shultz reminds her colleagues, both within California and beyond. "Setbacks like this can sometimes represent our biggest learning and growth moments."

West Virginia

Coming back from an unsuccessful run last year, ODs and their advocates in West Virginia have reintroduced their laser bill, HB 4783, which proposes the modernization of the practice scope to encompass all procedures taught in optometry schools today. This includes minor and surgical procedures such as lesion removal, capsulotomy, selective laser trabeculoplasty (SLT) and laser peripheral iridotomy (LPI).

Last month, HB 4783 passed the House 91-2 with strong bipartisan support. It's now in the hands of the Senate Health and Human Resources Committee awaiting a hearing.

Nebraska

This state first introduced LB 216 into the legislature last year proposing to allow Nebraska optometrists to perform SLT, a

procedure increasingly being recognized as a first-line option to treat glaucoma. The bill will continue into this year's session, but so far there hasn't been any movement; it currently remains under consideration by the Health and Human Services Committee, where a vote has been pending since the hearing last January. While awaiting the verdict, the Nebraska Optometric Association will continue its advocacy efforts with Committee members to vote the bill out of Committee during the 2024 legislative session.

Vermont

For the first time since the state's scope battle loss in 2020, Vermont has introduced a laser bill pursuing the right to perform in-office procedures including certain injections, removal of benign lid lesions, corneal crosslinking, YAG capsulotomy, SLT and LPI. This year, the bill is backed by the support of the Office of Professional Regulation, which recently recommended the expansion of optometry's scope to include the above procedures. It currently awaits a hearing in the state's Senate Healthcare Committee.

New Jersey

Last May, New Jersey introduced two identical laser bills, both of which were reintroduced this month (as A-920 and S-354) to play out in the 2024 legislative session. The bill's language has not changed since its introduction and proposes to allow New Jersey ODs to perform SLT, capsulotomy and LPI, as well as remove styes and skin tags. It also calls for an expansion of vaccine and prescription authority to improve access to needed care for state residents.

"By expanding the scope of practice, optometrists can provide critical eye care when and where it's needed most and ensure all New Jersey residents have timely access to vision and medical eye care," says Keira Boertzel-Smith, executive director of the New Jersey Society of Optometric Physicians. "It also lowers costs by eliminating duplication of services and extra copays for redundant office visits and reduces patient travel time and missed

hours at work," she adds. Hearings for both bills will be scheduled soon.

Ohio

For the first time in over 15 years, optometrists in Ohio are gearing up to pass a laser bill in 2024. The legislation—SB 129, which was first introduced to the Senate Health Committee last June before the summer recess—proposes to allow ODs in the state to remove benign lesions, cysts and skin tags, as well as perform three laser procedures: capsulotomy, SLT and LPI. Additionally, the bill also pursues an update to optometrists' pharmaceutical regulations and would give authority to the Vision Professionals Board to establish training and infection control standards. Hearings are awaiting scheduling.

Utah

After a loss in the Senate in 2022, Utah is coming back this year with another laser bill thanks to a favorable recommendation from the Office of Professional Licensure Review for ODs to perform capsulotomy and SLT.

Weston Barney, OD, legislative chair of the Utah Optometric Association (UOA), comments, "We have great support in the House, where the bill passed two years ago, and have been actively lobbying the Senate to get it done this year," says Dr. Barney. He reported at the time of this writing that the bill was currently in legislative research and would be assigned a bill number in the next few weeks.

While the UOA works tirelessly over the next few months to see this bill through, Dr. Barney points out that one troublesome piece of legislation—HB 189—will make this an especially busy year for ODs and advocates in Utah.

"The UOA has been closely monitoring Rep. Jordan Teuscher's HB 189 Contact Lens Purchasing Amendments bill since its introduction three years ago," the Association wrote in a recent press release. Essentially, this bill would prohibit prescribing doctors from selling contact lenses to their patients, encroaching upon the doctor-patient relationship. The current language of this bill also "mandates

by law that a contact lens prescriber *must* write a prescription for any and all contact lenses requested by the patient, completely disregarding the doctor's expertise and medical advice," the UOA explained.

Utah's ongoing battle to defeat HB 189 will compete with the laser bill for the focus of legislative efforts this year.

Alabama

A bill (HB 249) introduced last April to add SLT, capsulotomy, lid lesion removal and other responsibilities passed the Alabama House the following month but was stymied by the Senate Healthcare Committee, which refused to bring it to the floor for a vote. Howard Day, OD, president of the Alabama Optometric Association, nevertheless feels optimistic about reintroducing the bill this year. "We haven't had such passion to update our scope in years," says Dr. Day. "Our *esprit de corps* is at an all-time high. We will prevail," he assures. "Lasers in '24!"

New Hampshire

After passing a bill this past August that allows the state's ODs to administer adult vaccines for influenza, COVID-19 and shingles, New Hampshire optometrists are now pursuing the authority to perform laser procedures. SB 440, introduced in early January, was scheduled for a Senate hearing on February 8.

South Dakota

Last year, this state's laser bill was killed in the House, but instead of backing down, scope expansion advocates in South Dakota have once again introduced this legislation in the 2024 session. The bill, HB 1099, passed the House Health and Human Services Committee on February 2 and now heads to the Senate.

Missouri

This state introduced two identical laser bills this year, SB 956 and HB 1963, which propose the expansion of optometry's practice scope to encompass all procedures taught in optometry schools today, including minor surgery and the use of lasers. Both bills are awaiting hearings in their respective branches. ◀

Post-Cataract IOP Spike Rate 3.7%, IRIS Data Shows

Male sex, Black race, older age, glaucoma and complex surgical procedures were all key risk factors.

Researchers recently aimed to determine if specific demographic or clinical factors were associated with an increased risk of IOP spike in the early postoperative period after stand-alone phacoemulsification. Their study, published in *Ophthalmology*, confirmed several demographic and ocular risk factors that contribute to post-op IOP spike, including a glaucoma diagnosis and pseudoexfoliation syndrome.

The team analyzed data from 1,191,034 eyes that underwent stand-alone phaco (mean patient age 71.3 years, 61.2% female and 24.8% with glaucoma). An IOP spike occurred in 3.7% of all eyes, 5.2% of eyes with glaucoma and 3.2% of eyes without glaucoma. Multi-variable analyses indicated a greater risk of IOP spike with higher baseline IOP (odds ratio; OR: 1.57 per 3mm Hg), male sex (OR: 1.79), glaucoma (OR: 1.19), Black race (OR: 1.39 vs. Asian and OR: 1.21 vs. Hispanic), older age (OR: 1.07 per 10 years) and complex surgery coding (OR: 1.22).

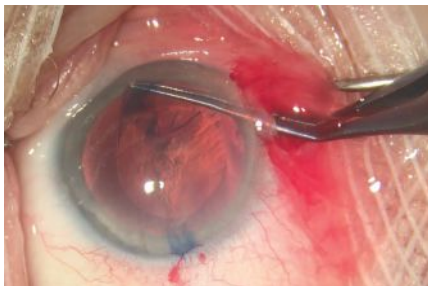The team noted that diabetes and aphakia after surgery appeared to be protective against IOP spike. Compared with glaucoma suspects, there was a greater risk of IOP spike with ocular hypertension (OR: 1.55), pigmentary glaucoma (OR: 1.56) and pseudoexfoliative glaucoma (OR: 1.52). There was

a lesser risk for patients with normal-tension glaucoma (OR: 0.55) and those who were primary angle-closure suspect (OR: 0.67) or had primary angle-closure glaucoma (OR: 0.81). More glaucoma meds at baseline was associated with IOP spike (OR: 1.18 per medication) while topical beta-blockers (OR: 0.68) were protective.

“Given our results, one could consider administering topical beta-blocker for patients at highest risk of IOP spike,” the authors wrote in their paper. “This study can help inform pre-op planning, discussions with patients prior to cataract surgery and surgical decision-making, particularly when caring for patients who are most vulnerable to the harmful effects of an IOP spike,” they concluded. ◀

Lidder AK, Vanner EA, Chang TC, et al. Intraocular pressure spike following stand-alone phacoemulsification in the Intelligent Research in Sight (IRIS) Registry. *Ophthalmology*. January 19, 2024. [Epub ahead of print].

Photo: Leonard Skornik, Jr, DO, OD



Glaucomatous eyes demonstrated different risk profiles of increased IOP spike dependent on subtype of glaucoma.

Keep Up Oral Hygiene for Better Sight

Gingivitis’ more severe counterpart periodontitis has been independently associated with a number of chronic inflammatory markers and causes of systemic inflammation. Researchers recently analyzed its potential association with early biomarkers of degenerative retinal conditions in patients without eye disease. Their findings, published in *Ophthalmology Science*, suggest it might be useful to recommend oral hygiene to patients at risk for AMD.¹

The researchers acquired baseline macular OCT images to assess retinal sublayer thickness. In a questionnaire, 4.3% of patients reported very severe periodontitis. On average, these individuals were older, living in areas of greater socioeconomic deprivation and more likely to have hypertension or diabetes and currently smoke. Individuals with very severe periodontitis were myopic, on

average, while unaffected individuals were typically hyperopic.

“The photoreceptor layer of individuals with very severe periodontitis was, on average, 0.55µm thinner than that of controls but this was driven largely by differences in the 60- to 69-year age group,” the researchers reported. They added that photoreceptor layer thinning is a noted feature of late AMD but is increasingly recognized in early disease and “may be the earliest manifestation of emerging AMD.”

“Periodontitis is associated with heightened systemic inflammation and addressing it through dental treatments leads to a reduction in inflammatory markers,” they continued. “Given the role of systemic inflammation in the pathophysiology of AMD, anti-inflammatory measures may have beneficial effects on outer retinal health.”

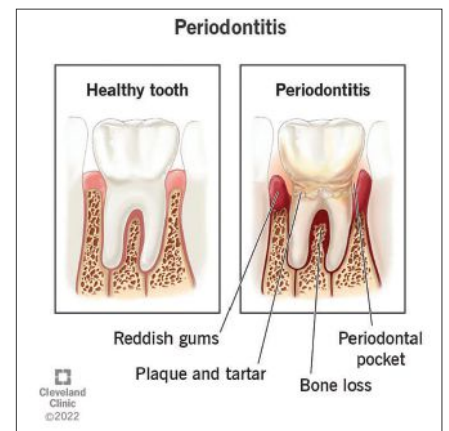


Photo: Cleveland Clinic

Bone loss from periodontal disease is the result of an immune response to plaque biofilm and metabolic byproducts.²

They concluded that recommending oral hygiene “may hold additional relevance” for patients at risk for AMD. ◀

1. Wagner SK, Patel PJ, Huemer J, et al. Periodontitis and outer retinal thickness: a cross-sectional analysis of the UK Biobank cohort. *Ophthalmol Sci*. January 19, 2024. [Epub ahead of print].

2. Periodontitis: Key Points. American Dental Association. www.ada.org/en/resources/research/science-and-research-institute/oral-health-topics/periodontitis. Accessed January 23, 2024.

xdemvy[®]
(lotilaner ophthalmic
solution) 0.25%



Learn more at
XDEMYYHCP.com

XDEMYY gives you
might over mites
to eradicate *Demodex* blepharitis.^{1,2}

Lotilaner, the active ingredient in XDEMYY^{1,3,4}:



Is a lipophilic agent in an aqueous drop that...



Acts specifically via mite GABA-gated
chloride channels to...



Target, paralyze, and kill *Demodex* mites

GABA=gamma-aminobutyric acid.

INDICATIONS AND USAGE

XDEMYY (lotilaner ophthalmic solution) 0.25% is indicated for the treatment of *Demodex* blepharitis.

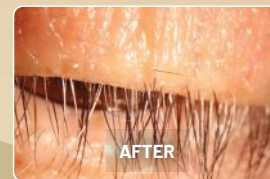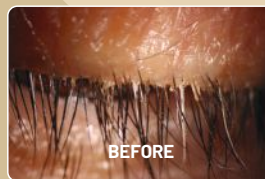IMPORTANT SAFETY INFORMATION:

WARNINGS AND PRECAUTIONS

Risk of Contamination: Do not allow the tip of the dispensing container to contact the eye, surrounding structures, fingers, or any other surface in order to minimize contamination of the solution. Serious damage to the eye and subsequent loss of vision may result from using contaminated solutions.

Use with Contact Lenses: XDEMYY contains potassium sorbate, which may discolor soft contact lenses. Contact lenses should be removed prior to instillation of XDEMYY and may be reinserted 15 minutes following its administration.

Real results



44% and 55% of patients taking XDEMYY in SATURN-1 (N=209) and SATURN-2 (N=193), respectively, achieved a significant improvement in their eyelids (reduction of collarettes to no more than 2 collarettes per upper lid) at Day 43 vs 7% (N=204) and 12% (N=200) of patients taking vehicle ($P<0.01$ in each trial).^{1,*}

All images are of actual patients who participated in clinical trials for Tarsus Pharmaceuticals.

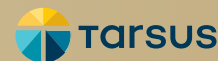ADVERSE REACTIONS: The most common adverse reaction with XDEMYY was instillation site stinging and burning which was reported in 10% of patients. Other ocular adverse reactions reported in less than 2% of patients were chalazion/hordeolum and punctate keratitis.

Please see next page for a Brief Summary of the full Prescribing Information.

References: 1. XDEMYY [prescribing information]. Tarsus Pharmaceuticals, Inc; 2023. 2. Gao YY et al. *Invest Ophthalmol Vis Sci.* 2005;46(9):3089-3094. 3. Yeu E et al. *Cornea.* 2022;42:435-443. 4. Toutain CE et al. *Parasit Vectors.* 2017;10(1):522.

*The safety and efficacy of XDEMYY for the treatment of DB were evaluated in a total of 833 patients (415 of whom received XDEMYY) in two 6-week, randomized, multicenter, double-masked, vehicle-controlled studies (SATURN-1 and SATURN-2). Patients were randomized to either XDEMYY or vehicle at a 1:1 ratio, dosed twice daily in each eye for 6 weeks. All patients enrolled were diagnosed with DB. The primary efficacy endpoint was defined as the proportion of patients with collarette reduction to no more than 2 collarettes per upper eyelid at Day 43.

© 2024 Tarsus Pharmaceuticals, Inc. All rights reserved.
Tarsus, XDEMYY, and the associated logos are trademarks of
Tarsus Pharmaceuticals, Inc. US--2300617 1/24



XDEMYV® (lotilaner ophthalmic solution) 0.25%, for topical ophthalmic use

BRIEF SUMMARY OF PRESCRIBING INFORMATION
Please see the XDEMYV® package insert for full Prescribing Information.

INDICATIONS AND USAGE

XDEMYV is indicated for the treatment of *Demodex* blepharitis.

CONTRAINDICATIONS

None.

WARNINGS AND PRECAUTIONS

Risk of Contamination Do not allow the tip of the dispensing container to contact the eye, surrounding structures, fingers, or any other surface in order to minimize contamination of the solution. Serious damage to the eye and subsequent loss of vision may result from using contaminated solutions.

Use with Contact Lenses Contact lenses should be removed prior to instillation of XDEMYV and may be reinserted 15 minutes following its administration.

ADVERSE REACTIONS

Because clinical studies are conducted under widely varying conditions, adverse reaction rates observed in the clinical trials of a drug cannot be directly compared to rates in the clinical trials of another drug and may not reflect the rates observed in practice.

XDEMYV was evaluated in 833 patients with *Demodex* blepharitis in two randomized, double-masked, vehicle-controlled studies (Saturn-1 and Saturn-2) with 42 days of treatment. The most common ocular adverse reaction observed in controlled clinical studies with XDEMYV was instillation site stinging and burning which was reported in 10% of patients. Other ocular adverse reactions reported in less than 2% of patients were chalazion/hordeolum and punctate keratitis.

USE IN SPECIFIC POPULATIONS

Pregnancy: Risk Summary There are no available data on XDEMYV use in pregnant women to inform any drug associated risk; however, systemic exposure to lotilaner from ocular administration is low. In animal reproduction studies, lotilaner did not produce malformations at clinically relevant doses.

Data Animal Data In an oral embryofetal developmental study in pregnant rats dosed during organogenesis from gestation days 6-19, increased post-implantation loss, reduced fetal pup weight, and incomplete skeletal ossification were observed at 50 mg/kg/day (approximately 1390 times the recommended human ophthalmic dose (RHOD) on a body surface area basis) in the presence of maternal toxicity (i.e., decreased body weight and food consumption). A rare malformation of situs inversus of the thoracic and abdominal viscera occurred in 1 fetus from a pregnant rat receiving 50 mg/kg/day; whether this finding was treatment-related could not be excluded. No maternal or embryofetal toxicity was observed at 18 mg/kg/day (approximately 501 times the RHOD on a body surface area basis). In an oral embryofetal development study in pregnant rabbits dosed during organogenesis from gestation days 7-19, no embryofetal toxicity or teratogenic findings were observed at 20 mg/kg/day (approximately 580-times the RHOD on an AUC basis), even in the presence of maternal toxicity (i.e., decreased food consumption and body weight).

In an oral two-generation reproductive toxicity study, F0 male and female rats were administered lotilaner at doses up to 40 mg/kg/day for 10 weeks before pairing and during the 2-week pairing period (3 weeks for males). Dosing for F0 females continued through lactation day 22. F1 male and female rats were administered lotilaner at 1 and 5 mg/kg/day post-weaning from day 23 for 10 weeks before pairing and during the 2-week pairing period (3 weeks for males). Dosing for F1 parental females continued through lactation day 22. There were no clear adverse effects on the F1 generation, and a slightly lower mean body weight during lactation was noted for F2 pups at 5 mg/kg/day. The no observed adverse effect level (NOAEL) was determined to be 5 mg/kg/day

(approximately 139 times the RHOD on a body surface area basis).

Lactation: Risk Summary There are no data on the presence of XDEMYV in human milk, the effects on the breastfed infant, or the effects on milk production. However, systemic exposure to lotilaner following 6 weeks of topical ocular administration is low and is >99% plasma protein bound, thus it is not known whether measurable levels of lotilaner would be present in maternal milk following topical ocular administration. The developmental and health benefits of breastfeeding should be considered along with the mother's clinical need for XDEMYV and any potential adverse effects on the breast-fed child from XDEMYV.

Pediatric Use: Safety and effectiveness in pediatric patients below the age of 18 years have not been established.

Geriatric Use: No overall differences in safety or effectiveness have been observed between elderly and other adult patients.

NONCLINICAL TOXICOLOGY

Carcinogenesis, Mutagenesis, Impairment of Fertility

Carcinogenesis Long-term studies in animals have not been performed to evaluate the carcinogenic potential of lotilaner.

Mutagenesis Lotilaner was not genotoxic in the following assays: Ames assay for bacterial gene mutation, *in vitro* chromosomal aberration assay in cultured human peripheral blood lymphocytes, and *in vivo* rat micronucleus test.

Impairment of fertility In a two-generation study of reproductive performance in rats, F0 male and female rats were administered lotilaner at oral doses of 40 mg/kg/day for 80 days reduced to 20 mg/kg/day for 47-50 supplementary days. Reduced pregnancy rates and decreased implantation rates were observed in F0 females at doses 20 mg/kg/day (approximately 556 times the RHOD on a body surface area basis), which were also associated with maternal toxicity (i.e., decreased body weight and food consumption). No effects on fertility were observed in F0 females at the dose of 5 mg/kg/day (approximately 139 times the MRHOD on a body surface area basis). No effects on fertility were observed in F0 males at the oral dose of 20 mg/kg/day (approximately 556 times the RHOD on a body surface area basis), and no effects on fertility were observed in F1 males and females at the oral dose of 5 mg/kg/day (approximately 139 times the RHOD on a body surface area basis).

PATIENT COUNSELING INFORMATION

Handling the Container Instruct patients to avoid allowing the tip of the dispensing container to contact the eye, surrounding structures, fingers, or any other surface in order to minimize contamination of the solution. Serious damage to the eye and subsequent loss of vision may result from using contaminated solutions.

When to Seek Physician Advice Advise patients that if they develop an intercurrent ocular condition (e.g., trauma or infection), have ocular surgery, or develop any ocular reactions, particularly conjunctivitis and eyelid reactions, they should immediately seek their physician's advice concerning the continued use of XDEMYV.

Use with Contact Lenses Advise patients that XDEMYV contains potassium sorbate, which may discolor soft contact lenses. Contact lenses should be removed prior to instillation of XDEMYV and may be reinserted 15 minutes following its administration.

Use with Other Ophthalmic Drugs Advise patients that if more than one topical ophthalmic drug is being used, the drugs should be administered at least 5 minutes between applications.

Missed Dose Advise patients that if one dose is missed, treatment should continue with the next dose.

RX only

© 2024 Tarsus Pharmaceuticals, Inc. All rights reserved.

XDEMYV is a trademark of Tarsus Pharmaceuticals, Inc.

US--2300345 1/24

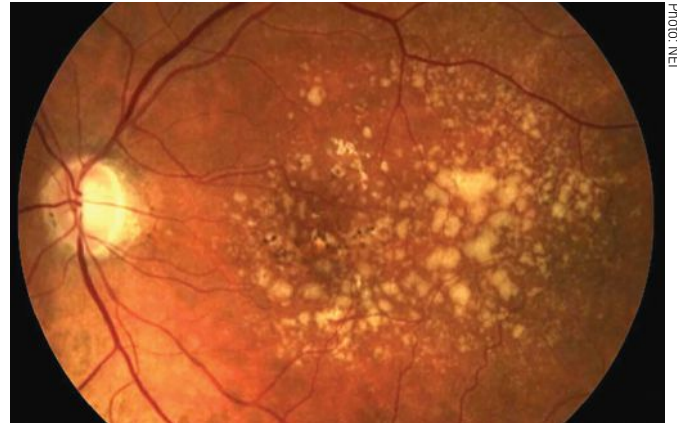


Photo: NEI

Alzheimer's patients on acetylcholinesterase inhibitors had a 6% lower hazard of AMD.

Common Alzheimer's Drug May Reduce AMD Incidence

While no cure exists for Alzheimer's disease, use of acetylcholinesterase inhibitors (AChEIs) may help improve quality of life. This workhorse therapy has revealed secondary benefits, including lower mortality, myocardial infarction and stroke risks and even slowed progression of chronic kidney disease. Now, a recent study published in *JAMA Ophthalmology* suggests AChEIs may reduce the incidence of age-related macular degeneration in those with Alzheimer's.

The retrospective cohort analysis included healthcare facilities within the US Department of Veterans Affairs between 2000 and 2023. Participants were patients diagnosed with Alzheimer's between ages 55 and 80 with no preexisting AMD diagnosis, totaling 21,823 veterans. Those in the treatment group receiving AChEIs every additional year resulted in a 6% lower hazard of AMD, compared to untreated patients.

Some research has correlated Alzheimer's and AMD development based on drusen-producing peptides in these patients, theoretically triggering subsequent AMD. The study authors stated that their hypothesis was "based on the idea that AMD may be linked to neuroinflammatory processes in the macula. Preclinical studies have suggested that AChEIs may have the ability to mitigate neuroinflammation." AChEIs have also been found to promote vasoprotection and maintain the integrity of the microvasculature in the eye, which may provide a potential protective effect against AMD, according to other research.

Randomized clinical trials are necessary to truly evaluate any cause-and-effect relationship, according to the authors. Nonetheless, this study bolsters the body of literature demonstrating the secondary benefits of AChEIs, which may play a significant role in treatment decisions for Alzheimer's patients. ◀

Sutton SS, Magagnoli J, Cummings TH, Hardin JW, Ambati J. Alzheimer Disease treatment with acetylcholinesterase inhibitors and incident Age-Related Macular Degeneration. *JAMA Ophthalmol*. January 4, 2024. [Epub ahead of print].

Breathing Technique Reduces IOP, Stress in Glaucoma

Study shows when used daily as an adjuvant therapy along with medications, this exercise can contribute to prevention of long-term progression.

Spending five minutes taking slow, deep breaths three times per day—a technique called ‘365 breathing’—is recommended by therapists to help deal with stress, as slow breathing techniques have been shown to shift towards parasympathetic dominance, increase respiratory sinus arrhythmia and augment heart rate variability. As previous studies have shown that mindfulness-based stress reduction helps reduce IOP, researchers recently evaluated the effect of the 365 breathing technique on IOP autonomic functions and stress biomarkers in patients with primary open-angle glaucoma (POAG) and found it caused a significant reduction in IOP (2mm Hg) after six weeks of practice.

Forty subjects in the intervention group followed 365 breathing for three times a day at a breathing rate of six cycles per minute for five minutes, in addition to their pharmacological glaucoma treatment. It was explained to subjects that breathing should be smooth, slow, deep and via nasal route, with five seconds devoted to each inhalation and exhalation. “Each day patients were asked to practice first session as soon as they wake up; second session four hours after the first or just before lunch and the third session at the start of their evening,” the authors wrote in their paper.

Another 40 subjects in the control group continued only with their pharmacological glaucoma treatment. IOP, serum cortisol, heart rate variability and heart rate response to deep breathing test were recorded at pre-intervention and six weeks post-intervention.

The 365 breathing technique reduced IOP by 2mm Hg and significantly increased the parasympathetic activity in interven-



Photo: Patrick Malerue/Unsplash

The ‘365 breathing technique’ reduced IOP by 2mm Hg after six weeks of practice, showing that it can help in preventing long-term glaucoma progression.

tion group after six weeks. Previous studies reported 1.5mm Hg to 6.1mm Hg of IOP reduction after a short course (three to six weeks duration) of meditation/mindfulness-based stress reduction in patients with glaucoma/ocular hypertension. The breathing technique also reduced serum cortisol (stress biomarker) and improved autonomic dysfunction in glaucoma patients.

“Stress is not only a result but also a possible risk factor/cause of glaucoma,” the authors explained. “Acute and chronic stress have been shown to increase IOP.” They added that cortisol is known to increase in response to stress

and alter trabecular meshwork morphology resulting in reduced aqueous humor outflow, thereby elevating IOP.

It is proposed that the increase in melatonin and nitric oxide could have led to decrease in IOP. An additional decrease in cortisol, as noted in this study, also contributes to decrease in IOP. The decreased sympathetic activity and increased parasympathetic activity can decrease in aqueous production and increase in aqueous outflow leading to decreased IOP, the authors explained.

“In our study, the IOP reduction after six weeks of practicing 365 breathing was 11% and though this is a small reduction, it can help in preventing long-term glaucoma progression. So, the 365 breathing technique cannot be used as a standalone modality to reduce IOP, but it can be used as an adjuvant therapy along with glaucoma medications,” the authors explained. ◀

Harvey DH, Roberts CJ, Mahmoud, AM, Nuñez, FM, Ma Y, Fleming, GP Biomechanical and vascular metrics between eyes of patients with asymmetric glaucoma and symmetric glaucoma. *J Glaucoma*. January 9, 2024. [Epub ahead of print].

IN BRIEF

■ **OCT-A Useful for Monitoring Kids with Type 1 Diabetes.** New research suggests that **OCT angiography may help detect early retinal microvascular changes in children with type 1 diabetes.**

The study, recently published in *Retina*, measured microvascular and neurodegenerative changes in children with type 1 diabetes without diabetic retinopathy and also assessed the effects of two types of insulin therapy on the microvasculature. It found that

one of these therapies may be more protective.

The study included 41 children receiving multiple daily insulin injections (MDI), 22 receiving continuous subcutaneous insulin infusion (CSII) and 62 controls. The researchers scanned a 6x6mm² area of posterior retina using the Spectralis OCT.

They observed lower vessel density of the superficial vascular plexus, intermediate capillary plexus and deep capillary plexus in the MDI group vs. the CSII and control groups. **In the MDI group,**

there was an association between lower vessel density of the superficial vascular plexus and higher HbA1c. The FAZ morphology index in this group and the CSII group were smaller than that of the control group. No difference in retinal thickness was noted among the three groups.

The researchers say their results and those of prior studies suggest “reduction of blood flow and impairment of the blood-retinal barrier [occur] due to chronic hyperglycemia before apparent signal of diabetic retinopathy in

type 1 diabetes mellitus children.” They concluded that **OCT-A may help detect retinal abnormalities in children with type 1, and that CSII may be a better choice for preventing retinal complications compared with MDI, as “CSII therapy may be protective against retinal microvascular damage in early diabetic retinopathy stages.”**

Guo Y, Zheng X, He Hongwu, et al. Retinal microvasculopathy with different insulin infusion therapies in children with type 1 diabetes mellitus without clinical diabetic retinopathy. *Retina*. December 21, 2023. [Epub ahead of print].

Reduced Kidney Function Associated with Late AMD

This finding underscores the importance of eye exams in these patients.

As chronic kidney disease (CKD) and age-related macular degeneration (AMD) share some of the same risk factors, pathogenic mechanisms and genetic polymorphisms, researchers have speculated that there may be a correlation between renal function and AMD. To further investigate, a team in Asia conducted a large cross-sectional study that revealed an association between CKD and late AMD, but none between kidney disease and early AMD.

Participant data (n=51,253) was gathered from 10 population-based Asian studies. Definitions for early AMD combined criteria in three different grading scales but generally included soft drusen and RPE changes. Late AMD was defined by the presence of either geographic atrophy or neovascularization and CKD was defined as estimated glomerular filtration rate (eGFR) below 60mL/min/1.73m².

The researchers examined associations between CKD and eGFR with AMD (early and late), adjusting for confounders including age, sex, hypertension, diabetes, body mass index, smoking status and total cholesterol. The mean age of participants was 54.1. The percentages of the cohort with CKD, early AMD and late AMD were 9.9%, 9.0% and 0.71%, respectively. After confounder adjustment, the researchers found CKD was associated with higher odds of late AMD (odds ratio, OR: 1.46), as was poorer kidney function (OR: 1.12). Neither CKD nor eGFR were significantly associated with early AMD.

The lack of an association between renal function and AMD in its early stage suggests “a nuanced relationship between kidney function and different stages of AMD, warranting deeper exploration,” the researchers wrote in their paper, published in *Ophthalmology*. “Importantly,” they added, “our current findings warrant further evaluation of kidney function as a predictor for the progression of AMD from early to late stages.”

This study is certainly not the first to draw a parallel between CKD and late-stage AMD; for example, one from 2011 found a significant association with late but not early AMD. More recently, in 2017 a study conducted in Taiwan reported an association between mild to moderate CKD and AMD, which was

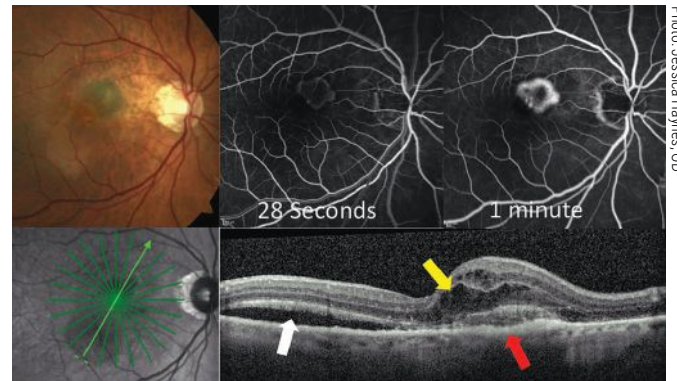


Photo: Jessica Haynes, OD

The connection between kidney function and AMD may be attributed to shared risk and genetic factors and pathogenic mechanisms. In this study, only late AMD (and not early AMD) showed an association with compromised kidney function.

most prominent in late AMD, and another found that reduced eGFR was significantly associated with geographic atrophy.

Causal links between reduced kidney function and AMD must still be elucidated, but current research shows that the connection “may be attributed to shared influencing factors including common susceptibility genes like complement factor H and apolipoprotein E, as well as overlapping pathogenetic mechanisms such as the upregulation of the renin-angiotensin aldosterone system.” Furthermore, “CKD may lead to increased oxidative stress due to reduced glomerular filtration of free radical-generating nitrogenous waste products,” thereby accelerating lipid deposition within Bruch’s membrane, “which can further contribute to the degeneration and calcification of elastin and collagen,” the study authors wrote.

The researchers concluded that the observed association further underscores the importance of ocular examinations in individuals with kidney disease. ◀

Xue CC, Sim R, Chee ML, et al. Is kidney function associated with age-related macular degeneration? Findings from the Asian Eye Epidemiology Consortium. *Ophthalmology*. December 29, 2023. [Epub ahead of print].

IN BRIEF

■ Topical 5-FU shows Promise in Treating Demodex. Last year’s FDA approval of Xdemvy (lotilaner, Tarsus) reinvigorated efforts to treat *Demodex* blepharitis, which traditionally involved non-targeted therapies such as tea tree oil and techniques to improve lid hygiene. Another topical agent that shows promise has a long track record of success in eye care: 5-fluorouracil (5-FU), commonly used to maintain glaucoma filtering bleb patency

and to treat ocular surface squamous neoplasia. Included in the observational retrospective review were 13 eyes from 13 patients (ages 30 to 84 years) with conjunctival neoplastic lesions and concomitant *Demodex* lash infestation. All received topical 1% 5-FU in a cyclical fashion: one cycle of treatment comprised one week of eye drops, administered four times per day, followed by three weeks with no drop use. After two cycles of 5-FU therapy, the researchers reported

that all 13 patients had a marked reduction in cylindrical dandruff in the treated eye. Additionally, cylindrical dandruff completely resolved in 10 of 13 treated eyes vs. zero of 13 untreated eyes. In the six patients who received epilation, the lashes from the treated eye showed no *Demodex*, while persistent *Demodex* was seen in lashes from the fellow untreated eye. “We found that 1% 5-FU treatment had a prolonged clinical effect of reducing *Demodex* in-

festation for up to 55 months,” the researchers wrote in their paper on the study, published recently in *Cornea*. “This finding prompts further investigation of the off-label use of topical 1% 5-FU for the treatment of *Demodex* blepharitis,” they concluded. Future studies with larger cohorts may also augment the significance of these findings. Amer MM, Ho JW, Theotoka D, et al. Role of topical 5-fluorouracil in *Demodex*-associated blepharitis. *Cornea*. January 18, 2024. [Epub ahead of print].

Aspirin Not Effective in Preventing Early DR

Preclinical studies have indicated a potential use for chronic aspirin use in preventing diabetic eye disease, but newer findings from randomized trials are more sobering. In a study appearing in *Ophthalmology*, researchers conducted a double-blind, randomized and placebo-controlled trial to test prior studies' results. This is a sub-study of a trial called A Study of Cardiovascular Events in Diabetes (ASCEND).

Included were 15,480 UK adults with diabetes aged 40 years or older. Of those, linkage data was obtained for 7,360 (48% of those randomized in ASCEND). Over a mean follow-up of 6.5 years, 14.6% had a referable disease event in the aspirin group (100mg daily), defined as referable diabetic retinopathy (DR) or maculopathy based on grading criteria defined by the UK National Screening Committee. This percentage was extremely similar to that of the placebo group, in which 14.2% had a referable disease event.

There was also no significant difference in proportion of sight-threatening eye bleed events, with the aspirin group experiencing this in 0.7% of cases and 0.8% of cases in the placebo group. The aspirin also had no effects on secondary or tertiary outcomes.

The study authors point to their results building off evidence from the ETDRS study, in which 650mg of aspirin taken daily for seven years did not prevent development of high-risk proliferative features in 3,711 DR patients. There was a subgroup analysis indicating that aspirin had no significant effects on incident maculopathy events in eyes assigned to either schedule in ETDRS.

The ASCEND eye study was a better test of aspirin at an earlier DR stage, since in the ETDRS study, participants already underwent pathological changes beyond cascading events at baseline. That is, the events of retinal capillary occlusion due to platelet thrombi or inflammatory changes involving the vascular endothelium are both identified triggers for a chain of events causing ocular diabetic microangiopathy. The dose of aspirin used in ASCEND was enough to inhibit certain agents, effectively lowering risk of vasoconstriction and platelet thrombosis, though this may not have been enough to suppress an inflammatory mechanism of disease.

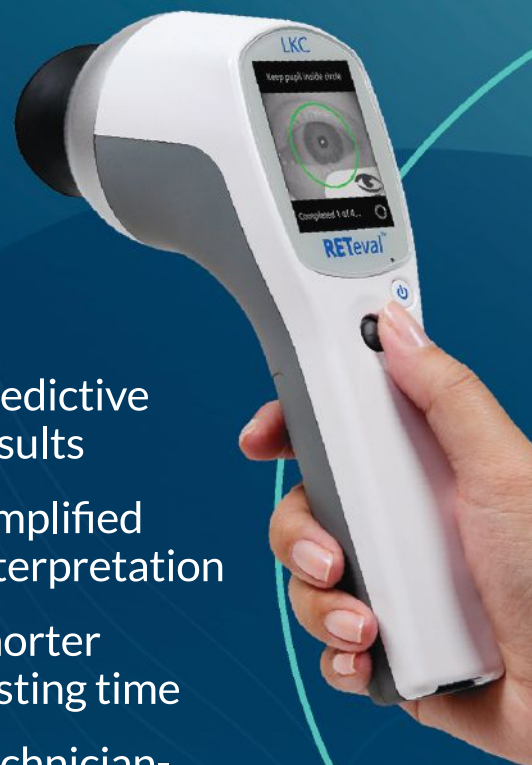Although their results were null, the authors still convey the clinical relevance of their research: "We have shown the feasibility of using the routine retinopathy screening data to define outcomes in a large randomized trial. We have also introduced a new, clinically relevant way of defining the severity of eye-bleeding events." At the very least, "these randomized data exclude any clinically meaningful effects of aspirin for DR but provide reassurance regarding the ophthalmological safety of aspirin." ◀

Sammons EL, Buck G, Bowman LJ, et al. ASCEND-Eye: effects of aspirin on diabetic retinopathy. *Ophthalmology*. January 16, 2024. [Epub ahead of print].

RETeval®


ERG SIMPLIFIED

THINK YOU KNOW ERG?



- ✓ Predictive results
- ✓ Simplified interpretation
- ✓ Shorter testing time
- ✓ Technician-friendly
- ✓ Affordable & reimbursable

 **LKC**
TECHNOLOGIES

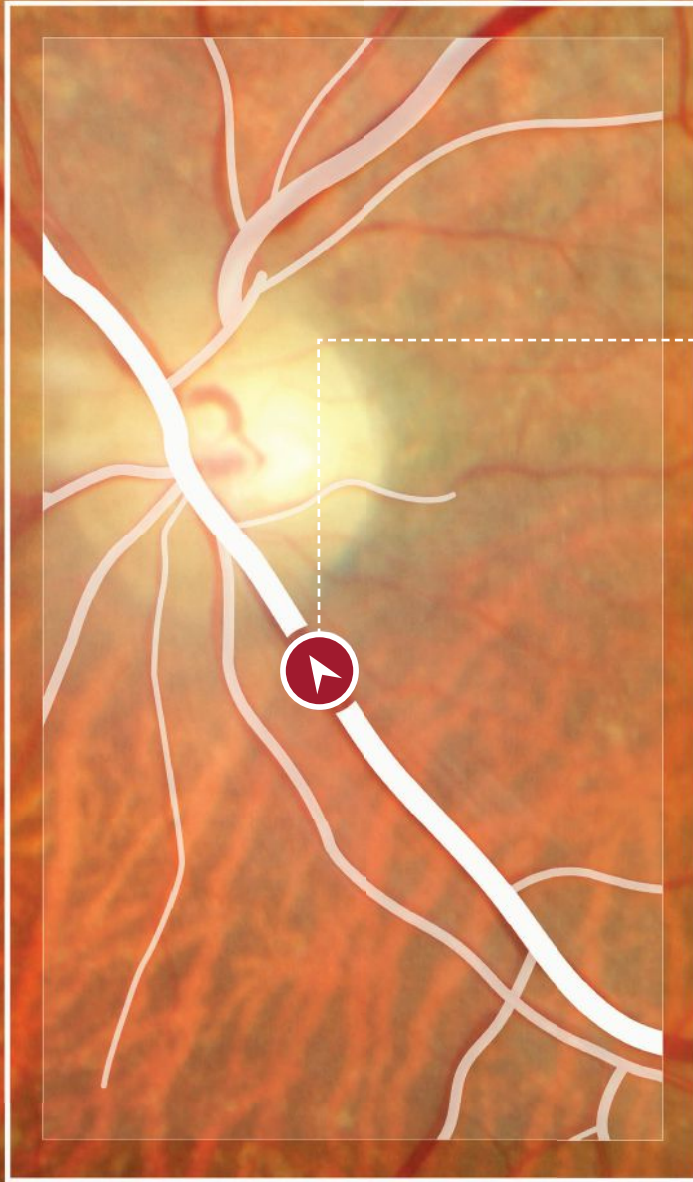


www.lkc.com

FEATURES

REVIEW OF OPTOMETRY • Vol. 161, No. 2 • FEBRUARY 15, 2024

DIAGNOSTIC SKILLS AND TECHNIQUES



32

Sharpen Your Slit Lamp Technique

Refine your skills and master the tricks this instrument offers to help examine patients more thoroughly.

By Nicholas Colatrella, OD, and Jeffrey Varanelli, OD

40

Navigating Optic Nerve Differentials

Use this systematic approach to arrive at the proper diagnosis without delay.

By Saidivya Komma, OD

48

Fundus Examination: Pay Attention to the Borders

Tips and pearls for expanding your view of the peripheral retina.

By Karina Miller, OD, MS, and Steve Njeru, OD, MS

58

Get a Handle on Head-mounted Perimetry

Learn how this option stacks up against the tried-and-true methods and how well you can integrate it into your practice.

By Marcia Hoepf, OD, and Michael Chaglasian, OD

EARN 2 CE CREDITS

66 Demystifying the Complement System

Learn to better understand the physiology and pathophysiology of this complex cascade and how it gives rise to AMD.

By Anna Bedwell, OD

REVIEW OF OPTOMETRY (ISSN 0147-7633) IS PUBLISHED MONTHLY, 12 TIMES A YEAR BY JOBSON MEDICAL INFORMATION LLC/WEBMD, 283-299 MARKET STREET, 2 GATEWAY CENTER, 4TH FLOOR, NEWARK, NJ 07102. PERIODICALS POSTAGE PAID AT NEWARK, NJ AND ADDITIONAL MAILING OFFICES. POSTMASTER: SEND ADDRESS CHANGES TO REVIEW OF OPTOMETRY, PO BOX 81, CONGERS, NY 10920-0081. SUBSCRIPTION PRICES: US: ONE YEAR \$56, TWO YEARS \$97, CANADA: ONE YEAR \$88, TWO YEARS \$160, INT'L: ONE YEAR \$209, TWO YEARS \$299. FOR SUBSCRIPTION INFORMATION CALL TOLL-FREE (877) 529-1746 (USA); OUTSIDE USA, CALL (845) 267-3065. OR EMAIL US AT REVOPOTOMETRY@CAMBEYWEST.COM. PUBLICATIONS MAIL AGREEMENT NO: 40612608. CANADA RETURNS TO BE SENT TO BLEUCHIP INTERNATIONAL, P.O. BOX 25542, LONDON, ON N6C 6B2.

Could it be KC (KERATOCONUS)?

KC File #1: The Patient Who Corrects to 20/20



Mitch "Private Eye" Ibach OD, FAAO, Vance Thompson Vision

A 29-year-old patient came to our office for a LASIK consult because she was unhappy with fluctuating vision in her contact lenses. The patient had ocular allergies but had no other ocular diagnoses.

Her entering glasses prescription was a modest one and we were able to refract her to 20/20. However, the refraction in the right eye was our first clue that something was not quite right.

Not only is >2.00 D of refractive cylinder a warning signal for keratoconus, but the oblique axis is also unusual. About 90% of young corneas have with-the-rule (WTR) astigmatism.¹ The change in myopic spherical equivalent (SE) from baseline (the glasses prescription) was not what we would expect to see in an adult patient, either.

Autokeratometry from her referring optometrist was on the steeper side of normal, and our pachymetry measurements showed that both eyes had borderline thin corneas. Upon further questioning, the patient recalled that her sister had keratoconus. Having a first-degree relative (a parent, sibling, or child) with keratoconus increases the risk of developing the disease by 15- to 67-fold.²

At this point, we have some risk factors, but not a clear diagnosis. A closer look at topography, tomography, and anterior segment OCT epithelial mapping provided further information to make a decisive diagnosis of progressive keratoconus in the right eye.

This case illustrates that patients who see 20/20 at the phoropter can still have keratoconus. At 29, our patient was at an age where there is greater risk of progression,³ and her ocular allergies and family history elevate that risk. She was fortunate to be diagnosed and treated early in the course of her disease, while she was still correctible to 20/20. **Simply by following the KC clues that are hiding in plain sight, you can help patients like this one preserve their vision by referring them to a corneal specialist. If further testing confirms the patient has progressive KC, iLink® cross-linking could slow or halt its progression. Visit iDetectives.com to learn more.** ●

REFERENCES:

1. Kojima T, et al. *Am J Ophthalmol* 2020;215:127-34. 2. Wang Y, et al. *Am J Med Genet* 2000;93(5):403-9. 3. Ferdi AC, et al. *Ophthalmology* 2019;126(7):935-45.

#FollowTheClues



INDICATIONS Photrexa® Viscous (riboflavin 5'-phosphate in 20% dextran ophthalmic solution) and Photrexa® (riboflavin 5'-phosphate ophthalmic solution) are indicated for use with the iLink System in corneal collagen cross-linking for the treatment of progressive keratoconus and corneal ectasia following refractive surgery.

IMPORTANT SAFETY INFORMATION Corneal collagen cross-linking should not be performed on pregnant women. Ulcerative keratitis can occur. Patients should be monitored for resolution of epithelial defects. The most common ocular adverse reaction was corneal opacity (haze). Other ocular side effects include punctate keratitis, corneal striae, dry eye, corneal epithelium defect, eye pain, light sensitivity, reduced visual acuity, and blurred vision. These are not all of the side effects of the corneal collagen cross-linking treatment. For more information, go to www.livingwithkeratoconus.com to obtain the FDA-approved product labeling. You are encouraged to report all side effects to the FDA. Visit www.fda.gov/medwatch, or call 1-800-FDA-1088.

iLink | SPONSORED AND SUPPLIED BY GLAUKOS

© 2023 Glaukos PM-US-1553 Rev.1

Refraction and exam findings

	RIGHT EYE	BCVA	LEFT EYE	BCVA
Lensometry	-0.50 -1.50 x31	20/30	-1.50 -0.50 x172	20/20-
Refraction at Phoropter	-0.75 -2.25 x34	20/20	-1.75 -0.75 x160	20/20+
Pachymetry	478 µm		483 µm	
Autokeratometry	45.5 / 47.50 x 112		44.9 / 46.75 x80	

KC File #1: THE CLUES

- Large change in refraction from lensometer to phoropter
- High astigmatism (-2.25 D) with an oblique axis
- Borderline thin corneas (478/483 µm)
- Relatively steep auto Ks (47.5)



iDetective
Following the clues
for early KC detection

DEPARTMENTS

REVIEW OF OPTOMETRY • FEBRUARY 15, 2024

FOLLOW US ON SOCIAL MEDIA

Facebook: revoptom

Twitter: revoptom

Instagram: revoptom

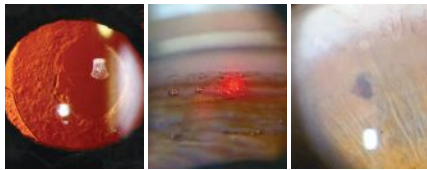
Threads: revoptom

LinkedIn: company/review-of-optometry

4

NEWS REVIEW

Clinical, legislative and practice updates for ODs.



16

OUTLOOK

Screen Time on Steroids

Apple's new VR headset will put digital displays ever closer to vulnerable eyes.

Jack Persico, Editor-in-Chief

19

THROUGH MY EYES

Efficiency is Key

Newer tech can lead to more accurate diagnoses.

Paul M. Karpecki, OD

20

CHAIRSIDE

My Favorite Patients

Kids, dads, gamers, know-it-alls—I just love them.

Montgomery Vickers, OD

22

CLINICAL QUANDARIES

Sounds of Silence

Hearing-impaired individuals require tailored eye exams.

Paul C. Ajamian, OD



24

YOU BE THE JUDGE

A Triad of Etiologies Complicates Diagnosis

Amblyopia can be supported by anisometropia and/or strabismus, but does not rule out more serious etiologies.

**Jerome Sherman, OD,
and Sherry Bass, OD**

29

FOCUS ON REFRACTION

Should Hindsight Be 20/20?

When a child's acuity meets their visual needs, they may benefit more from a delayed glasses Rx.

**Pamela H. Schnell, OD,
and Marc B. Taub, OD, MS, EdD**



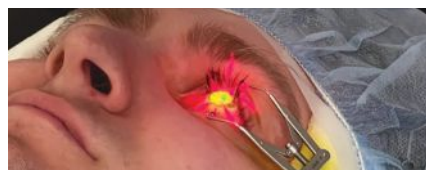74

ADVANCED PROCEDURES

Hat's Off to Epi-Off

Make sure you link a keratoconus diagnosis with a timely treatment approach.

Alia Cappellani, OD, and Nate Lighthizer, OD



78

THERAPEUTIC REVIEW

Common Threads

RNFL defects are an important clinical finding in glaucomatous optic neuropathy, but the diagnosis may not always be obvious.

Jessica Steen, OD

82

GLAUCOMA GRAND ROUNDS

Coordinating Care, Delaying Clinic

Making arrangements for proper management is not usually difficult, but it can cut into office efficiency.

James L. Fanelli, OD

84

PRODUCT REVIEW

New items to improve clinical care.

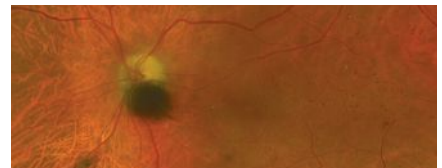
86

RETINA QUIZ

Spot On

Can you recognize this pigmented lesion?

Rami Aboumourad, OD



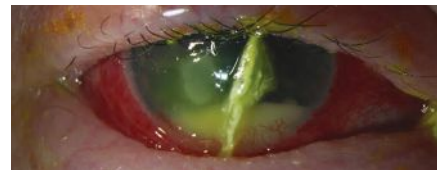
88

CORNEA AND CONTACT LENS Q + A

Fungal Frenzy

Certain species have more recently been studied for nonconventional forms of therapies.

Joseph P. Shovlin, OD



90

DIAGNOSTIC QUIZ

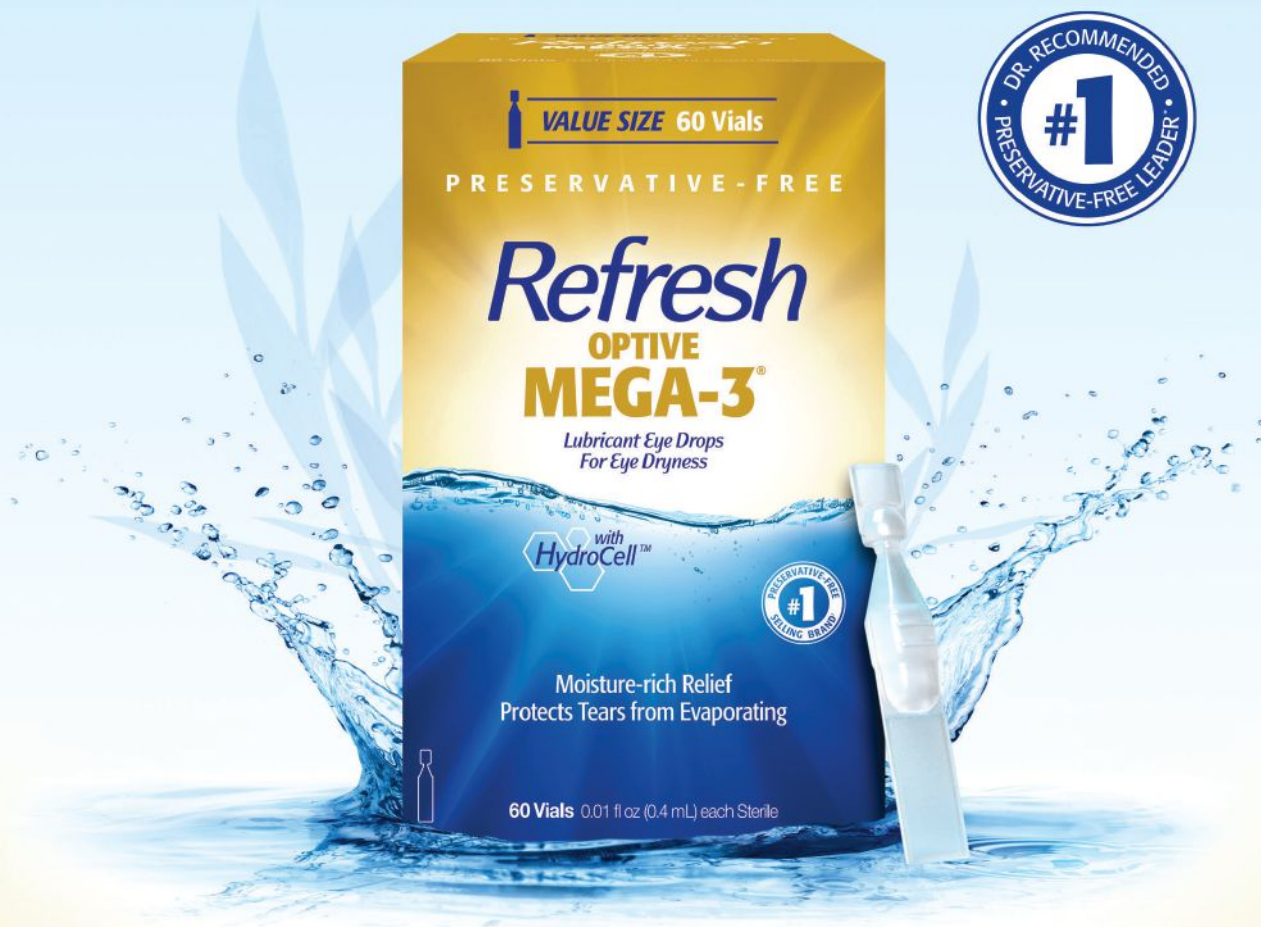Peaked Interest

A patient expressed concern about a pupil abnormality.

Andrew S. Gurwood, OD

EVAPORATIVE DRY EYES? LOOK TO MEGA-3[®]

A FIRST-LINE CHOICE



RELIEF FOR DRY EYES THAT MAY BE DUE TO MGD



Stabilizes the tear film



Fortifies the lipid layer



Includes Flaxseed Oil[†]
and antioxidants[†]

EDITOR-IN-CHIEF

JACK PERSICO
(610) 492-1006 • jpersico@jobson.com

SENIOR EDITOR

JULIE SHANNON
(610) 492-1005 • jshannon@jobson.com

SENIOR ASSOCIATE EDITOR

MARK DE LEON
(610) 492-1021 • mdeleon@jobson.com

ASSOCIATE EDITOR

LEANNE SPIEGLE
(610) 492-1026 • lspiegle@jobson.com

ASSOCIATE EDITOR

RACHEL RITA
(610) 492-1000 • rrita@jobson.com

SENIOR SPECIAL PROJECTS MANAGER

JILL GALLAGHER
(610) 492-1037 • jgallagher@jobson.com

ART DIRECTOR

LYNNE O'CONNOR
lyoconnor@jobson.com

GRAPHIC DESIGNER

JAINE KOPALA
jkopala@jobson.com

DIRECTOR OF CE ADMINISTRATION

REGINA COMBS
(212) 274-7160 • rcombs@jobson.com**Clinical Editors**

Chief Clinical Editor • Paul M. Karpecki, OD

Associate Clinical Editors

Joseph P. Shovlin, OD, Christine W. Sindt, OD

Clinical & Education Conference Advisor

Paul M. Karpecki, OD

Case Reports Coordinator • Andrew S. Gurwood, OD

Columnists*Advanced Procedures* – Nate Lighthizer, OD*Chairside* – Montgomery Vickers, OD*Clinical Quandaries* – Paul C. Ajamian, OD*Cornea and Contact Lens Q+A* – Joseph P. Shovlin, OD*Diagnostic Quiz* – Andrew S. Gurwood, OD*The Essentials* – Bisant A. Labib, OD*Focus on Refraction* – Marc Taub, OD, Pamela Schnell, OD*Glaucoma Grand Rounds* – James L. Fanelli, OD*Ocular Surface Review* – Paul M. Karpecki, OD*Retina Quiz* – Rami Aboumourad, OD*Surgical Minute* – Derek Cunningham, OD, Walter Whitley, OD*Therapeutic Review* – Jessica Steen, OD*Through My Eyes* – Paul M. Karpecki, OD*Urgent Care* – Alison Bozung, OD*You Be The Judge* – Jerome Sherman, OD, Sherry Bass, OD**Editorial Offices**

19 Campus Blvd., Suite 101 • Newtown Square, PA 19073

Jobson Medical Information/WebMD
283-299 Market Street, 2 Gateway Center, 4th Floor
Newark, NJ 07102Subscription inquiries: (877) 529-1746
Continuing Education inquiries: (800) 825-4696

Printed in USA

BY JACK PERSICO
EDITOR-IN-CHIEF
OUTLOOK

Screen Time on Steroids

Apple's entry into the VR market will popularize headset devices, putting digital displays closer than ever to vulnerable eyes.

The concept of computer technology that can create an artificial visual environment capable of manipulation by the user began firmly in the realm of applied science for niche groups—flight simulators and surgical training devices and the like—then was popularized by science fiction writers who imagined, and tantalized us with, all sorts of improbably fantastic scenarios.

At least two things have held back widespread adoption of virtual reality among the general public: first, the technology was nowhere near capable of delivering on what was in the popular imagination and, secondly, people look pretty ridiculous wearing the devices. I still remember laughing out loud in a theater 30 years ago for both those reasons as I watched Michael Douglas use VR goggles in the 1994 movie *Disclosure*.

But for the last decade, VR headsets have made good progress on tackling that first problem at least—the technology is pretty capable these days—and Apple's launch of its own device earlier this month, called Apple Vision Pro, is sure to accelerate adoption. It's too expensive (a whopping \$3,500) and inessential right now to be a massive hit like the iPhone, but it's on its way. Every new model will get more useful than the last, and eventually a lower-cost option will be introduced that puts these devices on millions of faces.

I bring this up because the visual consequences of this sort of screen use on mass populations are not well known yet. ODs will be getting more questions—and likely more complaints—from patients in the coming years. A big new report from the AOA calls out the dangers of unmitigated digital device use, noting that “31% of Americans

exposed to excessive screen time did not see a doctor of optometry within the past 12 months, while 55% of this group reported the presence of vision-related symptoms that may be improved or resolved from regular visits” to an OD.

Do you think that will get better or worse as Apple's headset puts two 4K screens mere inches from the wearer's eyes? Even its mode that approximates augmented reality—where overlays of computer graphics float atop the “real” world—blasts the viewer with video passed through from the front of the device rather than showing their actual environment through clear lenses and layering digital images above it.

One novelty feature, which may very well get dropped in future releases because it's so goofy, is an external screen that displays a simulated real-time rendering of the wearer's eyes so other people in the room can feel like they're making eye contact with the wearer. Apple calls it EyeSight. So, while wearing this device and having a conversation, you're seeing the other person through a screen (but pretending you aren't) and they're seeing your eyes recreated on another screen but are supposed to feel like they're actually looking you in the eye.

Enough already. Just take the damn thing off and talk face to face, geez.

Either way, it's worthwhile to get up to speed on Apple's device so you can provide proper patient education. Wearers needing refractive correction will have to buy custom Zeiss lens inserts through Apple. Hopefully that will prompt a few routine exams from your more affluent patients? Here's hoping. And, who knows, maybe Apple's brand cachet will even make the notion of wearing high-tech ski goggles feel a little less silly. ■

veveye™

(cyclosporine ophthalmic solution) 0.1%

NOW AVAILABLE!

A Different Cyclosporine

VEVYE® (cyclosporine ophthalmic solution) 0.1% is the first and only water-free cyclosporine dissolved in a semifluorinated alkane (perfluorobutylpentane) approved to treat both the signs and symptoms of dry eye disease.¹⁻³

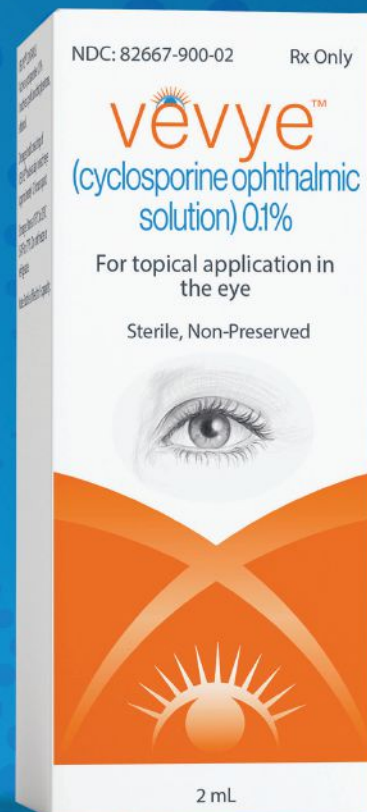
In clinical studies,

- Over 50% of patients had 3 grades of total corneal fluorescein staining improvement at Day 15*⁴
- 72% of patients showed at least 3 grades of improvement in corneal staining at day 29*⁴
- 99.8% of patients experienced no or mild instillation site irritation*⁴
- VEVYE provided sustained improvement over 12 months**⁴

* A Phase 3, multi-center, randomized, double-masked, vehicle-controlled clinical trial

** An open-label, single-arm, extension study

Scan or visit veveye.com to learn more or request FREE samples



INDICATION AND USAGE: VEVYE (cyclosporine ophthalmic solution) 0.1% is indicated for the treatment of the signs and symptoms of dry eye disease.

IMPORTANT SAFETY INFORMATION

Warnings and Precautions

- **Potential for Eye Injury and Contamination** – To avoid the potential for eye injury and/or contamination, patients should not touch the bottle tip to the eye or other surfaces.
- **Use with Contact Lenses** – VEVYE should not be administered while wearing contact lenses. If contact lenses are worn, they should be removed prior to administration of the solution. Lenses may be reinserted 15 minutes following the administration of VEVYE.

Adverse Reactions

In clinical trials with 738 subjects receiving at least 1 dose of VEVYE, the most common adverse reactions were instillation site reactions (8%) and temporary decreases in visual acuity (3%).

You are encouraged to report negative side effects of prescription drugs to the FDA. Visit www.fda.gov/medwatch, or call 1-800-FDA-1088.

For additional information about VEVYE, please see Brief Summary on adjacent page and Full Prescribing Information at veveye.com.

References: 1. Vevye (cyclosporine ophthalmic solution) 0.1% [package insert]. Harrow IP, LLC; 2023. 2. Cequa (cyclosporine ophthalmic solution) .09% [package insert]. Sun Ophthalmics, LLC; 2023. 3. Restasis (cyclosporine ophthalmic emulsion) 0.05% [package insert]. Allergan, LLC; 2023. 4. Data on file. Vevye and the Vevye logo are trademarks of Novaliq GmbH.

Harrow and the Harrow logo are registered trademarks of Harrow IP, LLC. ©2023 Harrow. All Rights Reserved. VYE-00051 01/24



vevye™

(cyclosporine ophthalmic solution) 0.1%

BRIEF SUMMARY – PLEASE SEE THE VEVYE® PACKAGE INSERT FOR FULL PRESCRIBING INFORMATION

INDICATIONS AND USAGE:

VEVYE® (cyclosporine ophthalmic solution) 0.1% is indicated for the treatment of the signs and symptoms of dry eye disease.

DOSAGE AND ADMINISTRATION:

Instill one drop of VEVYE® twice a day in each eye approximately 12 hours apart.

WARNINGS AND PRECAUTIONS

- **Potential for Eye Injury and Contamination** – To avoid the potential for eye injury and/or contamination, patients should not touch the bottle tip to the eye or other surfaces.
- **Use with Contact Lenses** – VEVYE® should not be administered while wearing contact lenses. If contact lenses are worn, they should be removed prior to administration of the solution. Lenses may be reinserted 15 minutes following the administration of VEVYE®.

ADVERSE REACTIONS

Clinical Trial Experience – Because clinical trials are conducted under widely varying conditions, adverse reaction rates observed in the clinical trials of a drug cannot be directly compared to rates in the clinical trials of another drug and may not reflect the rates observed in practice.

In clinical trials with 738 subjects receiving at least 1 dose of VEVYE®, the most common adverse reactions were instillation site reactions (8%) and temporary decreases in visual acuity (3%).

USE IN SPECIFIC POPULATIONS

PREGNANCY

Risk Summary

There are no adequate and well-controlled studies of VEVYE® administration in pregnant women to inform a drug-associated risk. Oral administration of cyclosporine to pregnant rats or rabbits did not produce teratogenicity at clinically relevant doses. VEVYE® doses are approximately 4,700 times lower than recommended oral doses, with blood concentrations being undetectable after topical administration.

Data

Animal Data: Oral administration of cyclosporine oral solution to pregnant rats or rabbits was teratogenic at maternally toxic doses of 30 mg/kg/day in rats and 100 mg/kg/day in rabbits, as indicated by increased pre- and postnatal mortality, reduced fetal weight and skeletal retardations. These doses (normalized to body weight) were approximately 7,250 and 48,000 times higher than the daily maximum recommended human ophthalmic dose (MRHOD) of 0.67 mcg/kg/day, respectively.

No adverse embryofetal effects were observed in rats or rabbits receiving cyclosporine during organogenesis at oral doses up to 17 mg/kg/day or 30 mg/kg/day, respectively (approximately 4,100 and 14,500 times higher than the MRHOD, respectively).

An oral dose of 45 mg/kg/day cyclosporine (approximately 10,900 times higher than MRHOD) administered to rats from Day 15 of pregnancy until Day 21 postpartum produced maternal toxicity and an increase in postnatal mortality in offspring. No adverse effects in mothers or offspring were observed at oral doses of up to 15 mg/kg/day (3600 times greater than MRHOD).

LACTATION

Risk Summary

Cyclosporine is known to be excreted in human milk following systemic administration but excretion in human milk after topical treatment has not been investigated. VEVYE® doses are approximately 4,700 times lower than recommended oral doses of cyclosporine, with blood concentrations being undetectable after topical administration. However, caution should be exercised when VEVYE® is administered to a nursing woman.

PEDIATRIC USE

Safety and effectiveness in pediatric patients below the age of 18 years have not been established.

GERIATRIC USE

No overall difference in safety or effectiveness has been observed between elderly and younger patients.

NONCLINICAL TOXICOLOGY

Carcinogenesis, Mutagenesis, Impairment of Fertility

Carcinogenesis

Evaluation of the potential carcinogenicity of cyclosporine was conducted in male and female mice and rats. In a 78-week oral (diet) mouse study, at doses of 1, 4, and 16 mg/kg/day, evidence of a statistically significant trend was found for lymphocytic lymphomas in females, and the incidence of hepatocellular carcinomas in mid-dose males significantly exceeded the control value.

In a 24-month oral (diet) rat study, conducted at 0.5, 2, and 8 mg/kg/day, pancreatic islet cell adenomas significantly exceeded the control rate in the low dose level. The hepatocellular carcinomas and pancreatic islet cell adenomas were not dose related. The low doses in mice and rats were approximately 120 times higher than the maximum recommended human ophthalmic dose (0.67 mcg/kg/day), normalized to body surface area.

Mutagenesis

In genetic toxicity tests, cyclosporine has not been found to be mutagenic/genotoxic in the Ames Test, the V79-HGPRT Test, the micronucleus test in mice and Chinese hamsters, the chromosome-aberration tests in Chinese hamster bone-marrow, the mouse dominant lethal assay, and the DNA-repair test in sperm from treated mice. Cyclosporine was positive in an in vitro sister chromatid exchange (SCE) assay using human lymphocytes.

Impairment of Fertility

Oral administration of cyclosporine to rats for 12 weeks (male) and 2 weeks (female) prior to mating produced no adverse effects on fertility at doses up to 15 mg/kg/day (approximately 3,600 times higher than the maximum recommended human ophthalmic dose).

PATIENT COUNSELING INFORMATION

Risk of Contamination

Advise patients to wash their hands well before each use. Advise patients not to allow the dropper tip to touch the eye or any other surface, as this may contaminate the solution.

Contact Lens Wear

Advise patients not to touch the dropper tip to any surface to avoid contaminating the contents.



Distributed by
Harrow Eye, LLC
102 Woodmont Blvd. Suite 610
Nashville, TN 37205
USA
©2023



BY PAUL M. KARPECKI, OD
CHIEF CLINICAL EDITOR

THROUGH MY EYES

Efficiency is Key

Newer technologies can lead to more accurate diagnoses.

The motivation for new diagnostic equipment has changed over the years. When I graduated, a well-known practice management consultant told me to determine how long it would take for reimbursement to pay for the equipment. If it was less than a year, consider it; if less than six months, buy it. How times have changed! Frankly, if the diagnostic equipment was valuable for proper disease diagnosis, identifying pathology I might miss or increasing efficiency, the reimbursement would be a last consideration.

Let's look at some newer diagnostic equipment that meets the above criteria in various areas of clinical practice.

Glaucoma

This condition is relatively complex, even though it should be simplified to identify a glaucoma suspect vs. glaucoma patient and if they are progressing or not. This often requires diagnostics that reveal information we can't identify on optic nerve evaluation alone. The precision of intraocular pressure (IOP) measurements can be improved by including corneal hysteresis, using the Ocular Response Analyzer (Reichert Technologies), which provides a "true" IOP and an indicator of disease progression potential. OCT is the perfect example of essential technology for glaucoma management. Newer versions such as Cirrus Photo 600 (Zeiss) take 100,000 B-scans per second with a wider field of view. One innovation in visual field (VF) testing includes virtual reality (VR) headsets—more about that later.

One of the more impressive innovations for 2024 is ObjectiveField (Konan Medical). No longer do we have to rely on sketchy subjective patient responses. The device uses subtle pupil responses to assess neurological field defects. It takes about three minutes per eye, uses familiar VF displays but provides information beyond current field testing, including latency responses and total deviation plots. That's the type of technology where the value of diagnosis far exceeds reimbursement.

“**The N3 VR Head (Neurolens) can measure phorias at distance and near, AC/A and determine exact misalignment down to a fraction of a prism diopter.**”

Refraction and Eye Misalignment

Accurate lensometers such as the Visionix VX 40 (Visionix) to more precise refractors are forcing a sea change in practice. One day these will be so accurate that doctors will need to focus more on the analysis of data collection than being expert refractionists. An example concerns eye misalignment. The N3 VR Headset (Neurolens) can measure phorias at distance and near, AC/A and determine exact misalignment down to a fraction of a prism diopter. This three-minute test has essentially eliminated the need for subjective Von Graefe testing and Maddox rods, saving immense time and greatly increasing accuracy.

Ocular Surface Disease

The Keratograph M5 (Oculus) supports the best diagnostic methodologies to provide everything from non-invasive break-up time to meibography. In the near future, it will incorporate artificial intelligence to help determine optimal treatment directions. New technologies use ray tracing to identify dry eye patients, such as Tear Film Index software for the iTrace (Tracey Technologies), to interferometry of the tear layers, such as Tear Film Imager (AdOM), both of which continue to advance diagnostics. A new device to help diagnose dry eye known as Idra (Mecroframes) is also set to reach the market soon.

Retinal Disease Evaluation

I recently saw a patient, who had been on Plaquenil 400mg per day for over nine years, for slight vision changes. A recent fundus photograph showed no noticeable pathology. With confocal imaging using the Eidon TrueColor Widefield Confocal Scanner (iCare), we were able to clearly see a bull's eye maculopathy and have the medication stopped. While fundus photography is reimbursable, this information, which prevented further permanent vision loss, is invaluable. Handheld ERG (RetEval, LKC), while effective in glaucoma, AMD, hypertensive retinopathy and other conditions, is extremely valuable in assessing diabetic retinopathy progression.

Efficiency and accuracy, information not available by other means, and *perhaps* reimbursement make these new technologies formidable, help us avoid missing essential pathologies, prevent malpractice lawsuits and—most importantly—save vision. They also make clinical practice far more enjoyable as we put the pieces of the puzzle together to make an accurate diagnosis, leading to more effective management. ■

About
Dr. Karpecki

Dr. Karpecki is the director of Cornea and External Disease for Kentucky Eye Institute and an associate professor at KYCO. He is the Chief Clinical Editor for Review of Optometry and chair of the New Technologies & Treatments conferences. A fixture in optometric clinical education, he consults for a wide array of ophthalmic clients, including ones discussed in this article. Dr. Karpecki's full disclosure list can be found in the online version of this article at www.reviewofoptometry.com.



My Favorite Patients

Kids, dads, gamers, know-it-alls—I just love them.

None of us will admit it, but each optometrist has—albeit hidden from plain view—a dirty little secret. Hey, don't drift into weird. That's another column altogether, probably not suitable for this wonderful, serious medical publication. It may be better suited for the latest issue of *Creepy Psychology Monthly*... circulation 27.

It is simply a fact that we all have our favorite and least favorite patient types. In no particular order, I present a list of patients I find especially challenging:

1. Kids. I love kids. I have a couple of my own, ages 40 and 41, and hope to retire before they need progressives. I also have six grandchildren, most of whom I adore, ages eight to 14—three boys and three girls—and I hope to retire before they need progressives, too. But kids can be challenging patients. First of all, they are mostly smarter than me and more than willing to remind me of that as they toy with me on their VAs and subjective answers when refracted. How do I know whether they can see whatever I show them? They apparently just want me to squirm. I kind of blame Paul Karpecki and Joseph Sowka, since they like to remind me that 20/20-2 VA could mean a brain tumor.

2. Dads. I love dads. I just told you I am one myself. But moms care if the kid can see. Dads only care about how much it costs. That is, unless it can make Johnny a better wide receiver. Then money is no object. I am quite tired of promising that these contact lenses will mean a full-ride in a D1

college when the kid is eight, 3'9" and 30 pounds ringin' wet. Hopefully I'll retire before the offers "come pouring in" as promised.

3. Those who proudly announce, "I used to work for an eye doctor." Now, don't get me wrong... working for an eye doctor is a worthy career, assuming the doctor is smart, kind and appreciative. But formerly working for an eye doctor does not mean you need to tell me that eye doctor told you 17 years ago to never wear PALs and that you will *always* be better than 20/20 in contact lenses. How come I'm always the one who has to explain presbyopia?

4. Family. Yes, my family, but much more than that, I'm talking about looking at my afternoon schedule and seeing five family members in a row. One hangnail and your afternoon is shot. Even worse—they may all show up! I suggest you refer to #2. It's hard enough for dad to write that check for one kid; just wait until he sees the total bill for every member of his family at once!

I can't convince him they will *all* get football scholarships, although his wife seems sturdy enough, I guess.

5. Gamers. So what if they're 2D myopes. Every single thing they ever look at is less than 30 inches from their greasy unshaven faces, and that's just the girls. They are only in your office because that's the price they pay for free room and board in mom's attic. They will ignore every single thing you tell them. Could it be because of the earbuds? Even my best references to "Pong" leads to zero engagement.

6. Insurance maniacs. You know the ones, right? If they had an arrow sticking out of their chest, just before they bleed out, on their last breath they'd tell the ER doctor, "I only want what my insurance will cover."

Will that fit on a tombstone? Only if their prepaid funeral plan covers it.

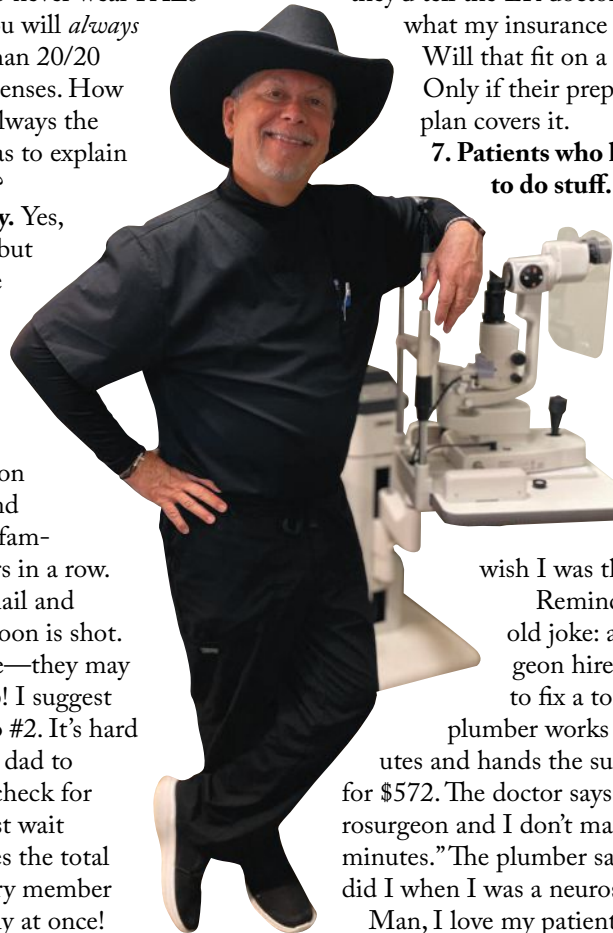
7. Patients who know how to do stuff. They can

change out a breaker, fix plumbing, deal with a car making strange noises and still bag a deer every season. I really

wish I was them.

Reminds me of an old joke: a neurosurgeon hires a plumber to fix a toilet. The plumber works for 43 minutes and hands the surgeon a bill for \$572. The doctor says, "I'm a neurosurgeon and I don't make \$572 in 43 minutes." The plumber says, "Neither did I when I was a neurosurgeon."

Man, I love my patients! ■



About Dr. Vickers

Dr. Vickers received his optometry degree from the Pennsylvania College of Optometry in 1979 and was clinical director at Vision Associates in St. Albans, WV, for 36 years. He is now in private practice in Dallas, where he continues to practice full-scope optometry. He has no financial interests to disclose.

From the makers of the #1-prescribed dry eye brand in Europe*

Covering the spectrum of

Dry Eye Relief

Over-the-counter iVIZIA® lubricant eye drops protect the ocular surface and deliver a unique combination of immediate and long-lasting relief in a **preservative-free** formulation.

- A unique formulation—including povidone (active), trehalose (inactive), and hyaluronic acid (inactive)
- Proprietary, **multi-dose preservative-free (MDPF)** bottle

Chronic Dry Eye Patient Usage Study[†]:

Up to
8 hours
of relief

as well as improved comfort during computer work, reading, and driving¹

84%

of users reported iVIZIA worked better than their previous eye drops¹



Safe for use with contact lenses[‡]



Recommend iVIZIA and request samples by visiting [iVIZIA.com/ECP](https://www.theapharma.com/ECP)

Scan here.

*Prescription market data, Dec. 2022 - S01K without cyclosporine.

¹In a chronic dry eye patient usage study, participants from a variety of socioeconomic backgrounds answered questions about their experience with iVIZIA lubricant drops. In the study, 203 chronic dry eye patients, 28-80 years old, switched from their dry eye artificial tears to iVIZIA for a month.¹

[‡]To limit blurriness when using contact lenses, remove contacts, apply drops, then insert contacts.

Reference: 1. Thea Data on File.

Copyright ©2024 Thea Pharma Inc. | All Rights Reserved. | PRC-IED-1030-v4 1.2024





EDITED BY PAUL C. AJAMIAN, OD

CLINICAL QUANDARIES

Sounds of Silence

Hearing-impaired individuals require tailored eye exams.

Q What considerations should be given when performing eye examinations on patients who are deaf?

A “As a hearing and seeing individual, we often take these senses for granted. But as optometrists, we have the privilege of understanding how valuable and precious the gift of sight is,” says Ciara A. Goodwin, a fourth-year student at Rosenberg School of Optometry at University of the Incarnate Word and a recent student extern at Omni Eye Services of Atlanta. “Deaf individuals rely on sight as their number-one form of communication, so imagine how difficult life can be when your only form of communication begins to decline.”

When an 80-year-old totally deaf male was referred to the Omni Atlanta practice for a cataract evaluation accompanied by his totally deaf daughter, Ms. Goodwin was willing to take on the task, having had four years of American Sign Language (ASL) training.

The patient was thoroughly evaluated by Ms. Goodwin and met all the criteria for surgery. She made sure that he understood all the details of the procedure and helped to schedule each eye two weeks apart. “Since it had been a while since I had had full conversations with others in ASL, I boned up on my knowledge of medical signs and made sure to look up any words or phrases that could be used in an eyecare setting to better aid in communicating with him throughout his two surgeries and post-op visits,” she notes.

On surgery day, the patient was instructed on directional touch, where he was taught by the extern to adjust his line of sight toward the direction of gaze



The patient with Omni extern Ciara Goodwin. (Photo taken and used with patient's consent.)

that the surgeon was tapping around the eye. Ms. Goodwin was with him every step of the way, from pre-op to surgery and recovery.

The surgery itself was successfully completed in under seven minutes! At the one-day follow-up visit, the patient was smiling ear to ear and told Ms. Goodwin how much his vision had improved. The patient and his daughter expressed how fortunate they were to have someone available who could communicate with them in their language.

As his interpreter, Ms. Goodwin certainly played a major role in the success of the surgery process. “Imagine, for a moment, how much courage it takes to have eye surgery while not being able to hear,” she says.

Scout's Motto

Ms. Goodwin has provided a list that can help us be prepared with the proper accommodations for patients who are hearing-impaired.

1. In the case of partially hearing-impaired patients, there is no need to yell or talk extremely slow. Proper pronunciation at an appropriate speed will work

just fine. If they have a better-hearing ear, speak closer to that side.

2. Always face your patient, as lip reading is often used by people with various degrees of hearing loss.

3. If an interpreter is not available, invest and familiarize yourself with interpreting apps such as “Jeenie: 24/7 Live Interpreting” or website resources such as www.rid.org.

4. Provide reading material (e.g., pamphlets, drug sheets, instructions) in large enough font for all patients to read and understand.

5. Keep an inclusive office. Supply dry-erase boards and markers or paper and pens for easier communication, along with various common symptom surveys that can be filled out beforehand.

6. Allow patients to sign or draw the alphabet during visual acuity testing as some prefer not to speak.

7. A reminder that the Americans with Disabilities Act, Section 504 of the Rehabilitation Act of 1973, states that public accommodations, such as doctors' offices, are required to provide ASL interpreters and other auxiliary aids to ensure effective communication with deaf and hard of hearing individuals.¹ Remember that you are responsible for providing a translator if the patient does not have one, including the cost of the translator and their travel time to and from the practice.²

“Just imagine if you were unable to communicate with these patients,” Ms. Goodwin emphasizes. There are countless resources available to better aid both deaf and hard-of-hearing patients with the best visual outcome possible. ■

1. Your rights under section 5043 of The Rehabilitation Act. US Department of Health and Human Services. www.hhs.gov/sites/default/files/ocr/civilrights/resources/factsheets/504.pdf. Accessed January 18, 2024.

2. ADA requirements: effective communication. US Department of Justice Civil Rights Division. www.ada.gov/resources/effective-communication. Last updated February 28, 2020. Accessed January 18, 2024.

About Dr. Ajamian

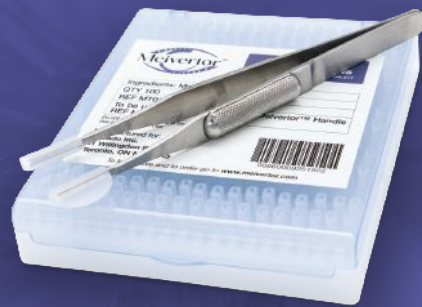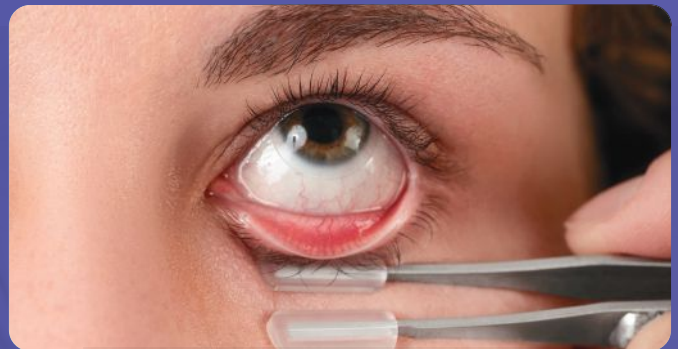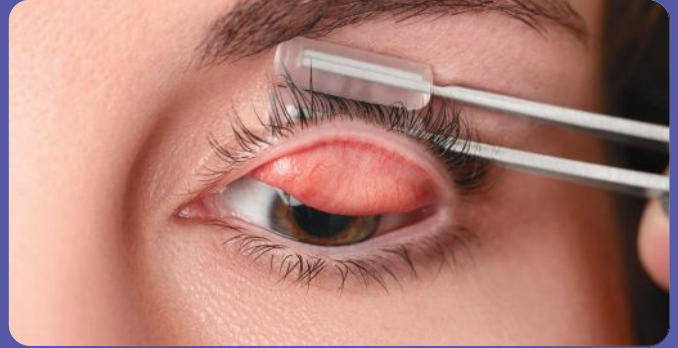Dr. Ajamian is board certified by the American Board of Optometry and serves as Center Director of Omni Eye Services of Atlanta. He is vice president of the Georgia State Board of Optometry and general CE chairman of SECO International. He has no financial interests to disclose.



US Patent 11,446,017

The ONLY SINGLE-HANDED UPPER and lower eyelid EVERSION TOOL

- Optimize the functionality of your meibographer
- Empower your technician to take the images you need – flipping a lid has never been easier
- Whenever you evert an upper eyelid – AND need a free hand – use your Meivertor



“Amazingly well designed, incredible balance to the instrument, and ease of use. I would recommend every technician who does meibography have one.”

-Dr. Paul Karpecki, OD, FAAO



“Love the Meivertor. First true game changer in the meibography game in my opinion.”

-Dr. Bradley Barnett, MD



“The Meivertor is a terrific product that has become one of my staff’s favourite in a very short time!”

-Dr. Kimberly K. Friedman, OD, FAAO



“Anyone struggle with lid eversion for meibomian gland imaging? Try using the Meivertor. Teaching techs has been a breeze and we can image both the upper and lower lids with ease!”

-Dr. Preeya Gupta, MD



For more information and to purchase go to meivertor.com



BY JEROME SHERMAN, OD, AND SHERRY BASS, OD

YOU BE THE JUDGE

A Triad of Etiologies Complicates Diagnosis

Amblyopia can be supported by anisometropia and/or strabismus, but it does not rule out more serious etiologies.

A child with monocular visual acuity reduction, significant hyperopic anisometropia and a constant unilateral strabismus in the same eye most likely has amblyopia. If no relevant new symptoms arise and clinical findings remain unchanged, most clinicians will not suspect an ominous, hidden disorder such as an optic nerve tumor. As stressed in our August 2023 “You Be the Judge,” diagnosing amblyopia without anisometropia and/or without constant unilateral strabismus could prove to be disastrous. On rare occasions, visual acuity (VA) reduction could be due to myriad disorders in the same eye, including, but not limited to, constant unilateral strabismus and significant hyperopic anisometropia. The timely diagnosis of disorders such as an orbital or brain tumor may be complicated by the presence of the more benign and common disorders.

Case

The daughter of a physician was first examined by an eye clinician at age nine. Best-corrected VA at the time was 20/50 through +9.00D sphere OD and 20/25 through a +6.00D sphere OS. Pinhole testing did not improve the VA in either eye. The external exam was noted to be normal, including pupillary testing and confrontation visual fields. The fundus exam revealed slightly small optic nerve heads, right being smaller than the left.

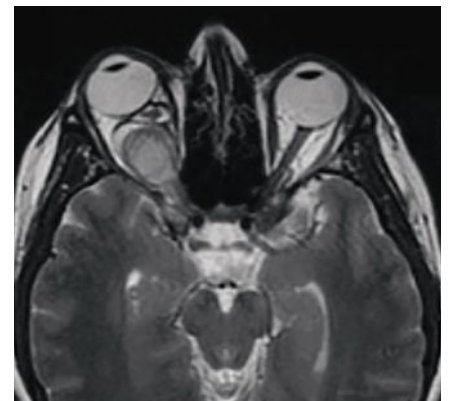
The foveal reflex was present in both eyes. The diagnosis was amblyopia in the right eye and glasses; contact lenses were later prescribed. No substantial change occurred over the next decade until automated visual fields were first performed and revealed a small inferior visual field defect in the right eye only. The patient was instructed to return in six months for a contact lens check and a repeat visual field.

At the next scheduled visit, she reported no new symptoms, and the best-corrected VA was still 20/50 OD and 20/25 OS with the same refractive error as previously. Visual fields were repeated with a Frequency Doubling Technology and an Octopus 1-2-3 perimeter. Both devices revealed minor loss in the inferior nasal quadrant in the right eye and a normal visual field in the left eye. Recognizing that amblyopes should not demonstrate a field loss, the primary eye clinician decided to refer the patient to a prominent neuro-ophthalmologist at a major academic medical center.

The neuro-ophthalmologist obtained a history of the patient requiring glasses since a very young age and noted that she never had 20/20 vision in the right eye. The patient denied worsening of vision in either eye or any other visual symptoms. The external exam was unremarkable, including confrontation visual fields. Motility and pupils were noted as normal.

There was no red desaturation reported with the right eye. On cover test, a small hypertropia OD was observed. This exam revealed very similar refractive error measurements and best-corrected visual acuity measurements as previously recorded. Visual field testing with a Goldmann perimeter was notable for constriction with the I2e isopter in the right eye, especially inferiorly. The left field was normal. A dilated fundus exam revealed hypoplastic discs, smaller in the right eye. Intraocular pressures, on this and previous exams, were always normal.

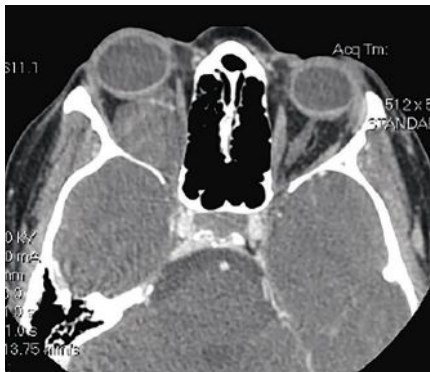The neuro-ophthalmologist concluded: “I believe the patient has a long-standing amblyopia of the right eye and she may have a small suppression scotoma with a slight hypertropia as well.” His plan was to re-evaluate the patient in six months and obtain neuroimaging if there was any change in visual status. The patient never returned to the specialist but followed up with her primary eye clinician. An exam a year later for new contact lenses and a repeat visual field demonstrated no change. The inferior field defect in the right eye persisted but did not worsen. Over a decade and a half, the patient developed conjunctivitis several times



Axial MRI section through the orbital mass OD (on the left) and the normal optic nerve OS (on the right).

About Drs. Sherman and Bass

Dr. Sherman is a Distinguished Teaching Professor at the SUNY State College of Optometry and editor-in-chief of *Retina Revealed* at www.retinarevealed.com. During his 53 years at SUNY, Dr. Sherman has published about 750 various manuscripts. He has also served as an expert witness in 400 malpractice cases, approximately equally split between plaintiff and defendant. Dr. Sherman has received support for *Retina Revealed* from Carl Zeiss Meditec, MacuHealth and Konan. **Dr. Bass** is a Distinguished Teaching Professor at the SUNY College of Optometry and is an attending in the Retina Clinic of the University Eye Center. She has served as an expert witness in a significant number of malpractice cases, the majority in support of the defendant. She serves as a consultant for ProQR Therapeutics.



Axial CT section at the same level as the previous image.

and was treated without incident by her primary eyecare clinician.

About a year later, the patient, now in her mid-20s, married and became pregnant. In the middle of her third trimester, her physician dad observed her right eye to be slightly hyperemic and slightly bulged. He was well aware that his daughter was very hyperopic, and high hyperopes with small globes don't develop bulging eyes. Although he was very concerned, he waited until several weeks after the arrival of his first grandchild to have his daughter evaluated by an ophthalmic oncologist. Both MRIs and CTs revealed a mass nearly the size of her globe in the right orbit. Without a biopsy, the diagnosis arrived upon by the ophthalmic oncologists was an optic nerve glioma. The patient was treated with several sessions of tomotherapy—a form of irradiation—and her vision has remained stable.

Malpractice Allegation

The patient sued the eyecare practitioner and neuro-ophthalmologist for failure to detect her orbital tumor years earlier. The orbital specialist opined that the long-term history of reduced vision in the right eye and persistence of an inferior altitudinal field defect in the right eye suggested that the orbital tumor was present some eight years earlier when she saw the neuro-ophthalmologist. After reviewing the neuro-ophthalmologist's findings, the more current testing revealed that the tumor had progressed with subsequent expansion of the optic canal, now threatening the chiasm. Best-corrected VA after treatment in the OD was 20/80 to 20/100.

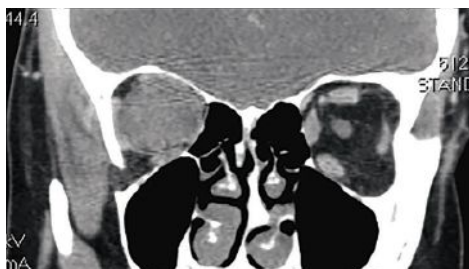You Be the Judge

In light of the facts presented thus far, consider the following questions:

- Was the primary eye clinician justified to arrive at a diagnosis of amblyopia in the OD?
- Was the referral to a specialist in a different city justified when a repeatable field defect was documented?
- Should the neuro-ophthalmologist have obtained neuroimaging?
- Is it possible for the VA reduction in the OD to be due to four different causes?
- Is the primary eye clinician culpable of malpractice?
- Is the neuro-ophthalmologist culpable of malpractice?
- Is the patient partly responsible for the delayed diagnosis?
- Is the patient's dad, a licensed physician, who treated his daughter, partly responsible?

Our Opinion

One of us (JS) was requested to review the case, concentrating on the care rendered by the primary eye clinician, an optometrist. After reviewing all the available information, I reached the conclusion that the diagnosis of amblyopia was justified, because of the hyperopic anisometropia. Moreover, the referral to a neuro-ophthalmologist met the standard of care when a repeatable field defect in the right eye was documented. The neuro-ophthalmologist also detected a small constant unilateral strabismus in the right eye, which is also recognized as a cause of monocular reduced vision, or amblyopia. Both clinicians detected hypoplastic discs, a smaller disc in the right eye than the left eye, and a hypoplastic disc is often the etiology of reduced VA and variable



Coronal CT section through the orbital mass OD (left) and the optic nerve OS (right).

field loss.¹ One of us (SB) examined two patients with hypoplastic discs, both of whom demonstrated repeatable inferior field defects in the eye with the hypoplastic disc.

One expert opined that the glioma was most likely present but dormant for years, and the pregnancy initiated the growth of the tumor. The plaintiff's attorneys had difficulty finding experts to testify against the optometrist and even greater difficulty in finding a neuro-ophthalmologist to testify against one of the nation's premier neuro-ophthalmologists.

The plaintiff's attorneys produced pictures of the patient's face over a decade that clearly documented subtle but increasing exophthalmos of the right eye. I agreed that this carefully selected group of images over a decade documented increasing exophthalmos on the right side only but noted that the patient, her childhood boyfriend and her dad (a treating physician) did not notice it. Remarkably, the plaintiff's attorneys then resorted to claiming that images of a patient's face should have been taken by the optometrist on each visit for over a decade. But of course, this is not the standard in ophthalmic care. This case was settled for a modest amount.

Takeaways

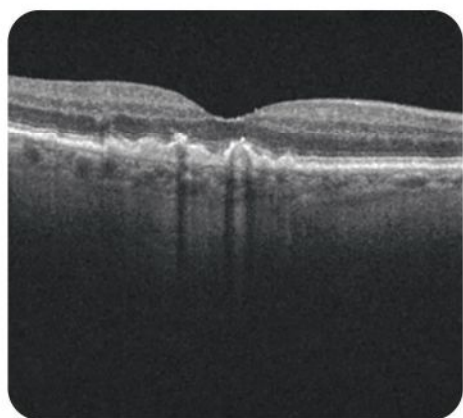
This is a remarkable case in that there are four possible etiologies for the VA reduction OD:

- Hyperopic anisometropia.
- Constant unilateral strabismus.
- Optic nerve hypoplasia.
- Orbital glioma. ■

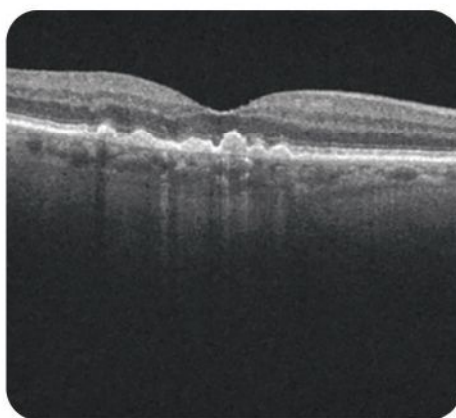
1. Sadun AA, Wang MY. Abnormalities of the optic disc. *Handbook of Clinical Neurology*. Vol 102. Elsevier, Amsterdam; 2011:117-57.

NOTE: This article is one of a series based on actual lawsuits in which the author served as an expert witness or rendered an expert opinion. These cases are factual, but some details have been altered to preserve confidentiality. The article represents the authors' opinion of acceptable standards of care and do not give legal or medical advice. Laws, standards and the outcome of cases can vary from place to place. Others' opinions may differ; we welcome yours.

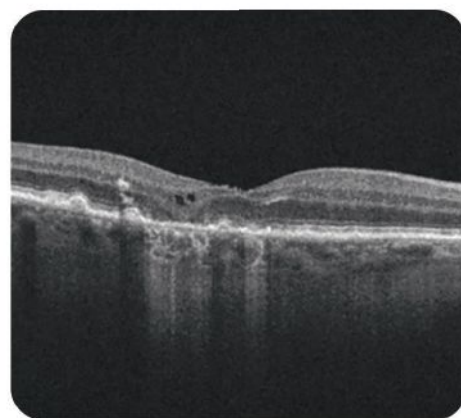
GEOGRAPHIC ATROPHY (GA) CAN PROGRESS FASTER THAN YOU THINK¹



Baseline



Month 3



Month 6

1. Boyer D, Schmidt-Erfurth U, van Lookeren Campagne M, et al. The pathophysiology of geographic atrophy secondary to age-related macular degeneration and the complement pathway as a therapeutic target. *Retina*. 2017;37(5);819-835.

INDICATION

IZERVAY™ (avacincaptad pegol intravitreal solution) is indicated for the treatment of geographic atrophy (GA) secondary to age-related macular degeneration (AMD)

IMPORTANT SAFETY INFORMATION

CONTRAINDICATIONS

IZERVAY is contraindicated in patients with ocular or periocular infections and in patients with active intraocular inflammation.

WARNINGS AND PRECAUTIONS

Endophthalmitis and Retinal Detachments

Intravitreal injections, including those with IZERVAY, may be associated with endophthalmitis and retinal detachments. Proper aseptic injection technique must always be used when administering IZERVAY in order to minimize the risk of endophthalmitis. Patients should be instructed to report any symptoms suggestive of endophthalmitis or retinal detachment without delay and should be managed appropriately.

EVERY MONTH MATTERS WHEN TREATING GA


izervay[™]
(avacincaptad pegol
intravitreal solution) 2 mg



Learn more at
[IZERVAYecp.com](https://www.izervayecp.com)

Neovascular AMD

In clinical trials, use of IZERVAY was associated with increased rates of neovascular (wet) AMD or choroidal neovascularization (7% when administered monthly and 4% in the sham group) by Month 12. Patients receiving IZERVAY should be monitored for signs of neovascular AMD.

Increase in Intraocular Pressure

Transient increases in intraocular pressure (IOP) may occur after any intravitreal injection, including with IZERVAY. Perfusion of the optic nerve head should be monitored following the injection and managed appropriately.

ADVERSE REACTIONS

Most common adverse reactions (incidence $\geq 5\%$) reported in patients receiving IZERVAY were conjunctival hemorrhage, increased IOP, blurred vision, and neovascular age-related macular degeneration.

Please see full Prescribing Information for more information.

Copyright © 2023 IVERIC bio, Inc. An Astellas Company.
All rights reserved. US-AP-2300334 10/23

IVERIC
BIO
An Astellas Company

IZERVY™ (avacincaptad pegol intravitreal solution)

Rx only

Brief Summary: This information is not comprehensive. Visit IZERVAYecp.com to obtain the FDA-approved product labeling or call 609-474-6755.

1 INDICATIONS AND USAGE

IZERVAY is indicated for the treatment of geographic atrophy (GA) secondary to age-related macular degeneration (AMD).

2 DOSAGE AND ADMINISTRATION

2.1 General Dosing Information

IZERVAY must be administered by a qualified physician.

2.2 Recommended Dosage

The recommended dose for IZERVAY is 2 mg (0.1 mL of 20 mg/mL solution) administered by intravitreal injection to each affected eye once monthly (approximately every 28 ± 7 days) for up to 12 months.

2.4 Injection Procedure

Only 0.1 mL (2 mg) should be administered to deliver a single dose. Any excess volume should be disposed.

Prior to the intravitreal injection, patients should be monitored for elevated intraocular pressure (IOP) using tonometry. If necessary, ocular hypotensive medication can be given to lower the IOP.

The intravitreal injection procedure must be carried out under controlled aseptic conditions, which includes the use of surgical hand disinfection, sterile gloves, a sterile drape, and a sterile eyelid speculum (or equivalent). Adequate anesthesia and a broad-spectrum topical microbicide should be given prior to the injection.

Inject slowly until the rubber stopper reaches the end of the syringe to deliver the volume of 0.1 mL. Confirm delivery of the full dose by checking that the rubber stopper has reached the end of the syringe barrel.

Immediately following the intravitreal injection, patients should be monitored for elevation in intraocular pressure (IOP). Appropriate monitoring may consist of a check for perfusion of the optic nerve head or tonometry.

Following intravitreal injection, patients should be instructed to report any symptoms suggestive of endophthalmitis (e.g., eye pain, redness of the eye, photophobia, blurring of vision) without delay.

Each vial and syringe should only be used for the treatment of a single eye. If the contralateral eye requires treatment, a new vial and syringe should be used and the sterile field, syringe, gloves, drapes, eyelid speculum, filter needle, and injection needle should be changed before IZERVAY is administered to the other eye. Repeat the same procedure steps as above.

Any unused medicinal product or waste material should be disposed of in accordance with local regulations.

3 DOSAGE FORMS AND STRENGTHS

Intravitreal solution: 20 mg/mL clear to slightly opalescent, colorless to slightly yellow solution in a single-dose vial.

4 CONTRAINDICATIONS

4.1 Ocular or Periocular Infections

IZERVAY is contraindicated in patients with ocular or periocular infections.

4.2 Active Intraocular Inflammation

IZERVAY is contraindicated in patients with active intraocular inflammation.

5 WARNINGS AND PRECAUTIONS

5.1 Endophthalmitis and Retinal Detachments

Intravitreal injections may be associated with endophthalmitis and retinal detachments. Proper aseptic injection techniques must always be used when administering IZERVAY in order to minimize the risk of endophthalmitis. Patients should be instructed to report any symptoms suggestive of endophthalmitis or retinal detachment without delay, to permit prompt and appropriate management.

5.2 Neovascular AMD

In clinical trials, use of IZERVAY was associated with increased rates of neovascular (wet) AMD or choroidal neovascularization (7% when administered monthly and 4% in the sham group) by Month 12. Patients receiving IZERVAY should be monitored for signs of neovascular AMD.

5.3 Increase in Intraocular Pressure

Transient increases in intraocular pressure (IOP) have been observed after an intravitreal injection, including with IZERVAY. Perfusion of the optic nerve head should be monitored following the injection and managed as needed.

6 ADVERSE REACTIONS

The following potentially serious adverse reactions are described elsewhere in the labeling:

- Ocular and periocular infections
- Active intraocular inflammation
- Endophthalmitis and retinal detachments
- Neovascular AMD
- Increase in intraocular pressure

6.1 Clinical Trials Experience

Because clinical trials are conducted under widely varying conditions, adverse reaction rates observed in the clinical trials of a drug cannot be directly compared to rates in the clinical trials of another drug and may not reflect the rates observed in practice.

The safety of avacincaptad pegol was evaluated in 733 patients with AMD in two sham-

controlled studies (GATHER1 and GATHER2). Of these patients, 292 were treated with intravitreal IZERVAY 2 mg (0.1 mL of 20 mg/mL solution). Three hundred thirty-two (332) patients were assigned to sham.

Adverse reactions reported in ≥2% of patients who received treatment with IZERVAY pooled across GATHER1 and GATHER2, are listed below in Table 1.

Table 1: Common Ocular Adverse Reactions (≥2% and greater than Sham in Study Eye

Adverse Drug Reactions	IZERVAY N = 292	Sham N = 332
Conjunctival hemorrhage	13%	9%
Increased IOP	9%	1%
Choroidal neovascularization	7%	4%
Blurred vision*	8%	5%
Eye pain	4%	3%
Vitreous floaters	2%	<1%
Blepharitis	2%	<1%

* Blurred vision includes visual impairment, vision blurred, visual acuity reduced, visual acuity reduced transiently.

8 USE IN SPECIFIC POPULATIONS

8.1 Pregnancy

Risk Summary

There are no adequate and well-controlled studies of IZERVAY administration in pregnant women. The use of IZERVAY may be considered following an assessment of the risks and benefits.

Administration of avacincaptad pegol to pregnant rats and rabbits throughout the period of organogenesis resulted in no evidence of adverse effects to the fetus or pregnant female at intravenous (IV) doses 5.1 times and 3.2 times the human exposure (based on AUC) at the maximum recommended human dose (MRHD) of 2 mg once monthly, respectively.

In the U.S. general population, the estimated background risks of major birth defects and miscarriage in clinically recognized pregnancies is 2-4% and 15%-20%, respectively.

Animal Data

An embryo fetal developmental toxicity study was conducted with pregnant rats. Pregnant rats received daily intravenous (IV) injections of avacincaptad pegol from day 6 to day 17 of gestation at 0.1, 0.4, 1.2 mg/kg/day. No maternal or embryofetal adverse effects were observed at any dose evaluated. An increase in the incidence of a non-adverse skeletal variation, described as short thoracolumbar (ossification site without distal cartilage) supernumerary ribs, was observed at all doses evaluated. The clinical relevance of this finding is unknown. Plasma exposures at the high dose were 5.1 times the MRHD, based on Area Under the Curve (AUC).

An embryo fetal developmental toxicity study was conducted with pregnant rabbits. Pregnant rabbits received daily IV injections of avacincaptad pegol from day 7 to day 19 of gestation at 0.12, 0.4, 1.2 mg/kg/day. No maternal or embryofetal adverse effects were observed at any dose evaluated. Plasma exposure in pregnant rabbits at the highest dose of 1.2 mg/kg/day was 3.2 times the human exposure at the MRHD, based on AUC.

8.2 Lactation

There is no information regarding the presence of avacincaptad pegol in human milk, the effects of the drug on the breastfed infant or on milk production.

The developmental and health benefits of breastfeeding should be considered along with the mother's clinical need for IZERVAY and any potential adverse effects on the breastfed infant from IZERVAY.

8.4 Pediatric Use

Safety and effectiveness of IZERVAY in pediatric patients have not been established.

8.5 Geriatric Use

Of the total number of patients who received IZERVAY in the two clinical trials, 90% (263/292) were ≥65 years and 61% (178/292) were ≥75 years of age. No significant differences in efficacy or safety of avacincaptad pegol were seen with increasing age in these studies. No dose adjustment is required in patients 65 years and above.

17 PATIENT COUNSELING INFORMATION

Advise patients that following IZERVAY administration, patients are at risk of developing neovascular AMD, endophthalmitis, elevated intraocular pressure and retinal detachments. If the eye becomes red, sensitive to light, painful, or if a patient develops a change in vision, instruct the patient to seek immediate care from an ophthalmologist.

Patients may experience temporary visual disturbances and blurring after an intravitreal injection with IZERVAY and the associated eye examinations. Advise patients not to drive or use machinery until visual function has recovered sufficiently.

Manufactured by:

IVERIC bio, Inc., An Astellas Company. Parsippany, NJ 07054

©2023 IVERIC bio, Inc., An Astellas Company. IZERVAY is a trademark of IVERIC bio, Inc., An Astellas Company.



BY PAMELA H. SCHNELL, OD, AND MARC B. TAUB, OD, MS, EdD

FOCUS ON REFRACTION

Should Hindsight Be 20/20?

When a child's acuity meets their visual needs, they may benefit more from a delayed glasses prescription.

The decision on when to give a child their first pair of glasses might not be as clear-cut as the guidelines lead us to believe. The current guidelines from optometry and ophthalmology are set up based on age and refractive error. If a child is over a certain age and you measure a refractive error of roughly a set amount, the recommendation is that you prescribe that amount so that the child can have the best possible vision.

This sounds great in theory, but as we have discussed in this column time and time again, there is so much more to vision than seeing a 20/20-sized letter from a specified distance.

We must always take into account the visual needs of the child, which includes their development. The question at hand is whether all kids absolutely need to see 20/20. Yes, we said it out loud (well, wrote it). When we are prescribing, we must account for age, visual needs and development.



Fig. 1. Second grade classroom in a private school, where the farthest seating is only about 10 feet from the whiteboard.

For example, the visual needs of a child with a developmental disability are often different than those of a normally developing child. The visual needs of a three-year-old are quite different than those of an eight-year-old, and even more different than the needs of a 15-year-old.

Before we delve into a few case examples, two articles help to lay the groundwork for our thinking.

Langford and Hug studied the classroom visual demands of children from kindergarten to fifth grade. They measured vertical letter sizes at distance and near and the distances of the various desk rows. A near distance of 16 inches was assumed, but that itself might be too far away for some children in this age group, in our opinion. The authors found that from kindergarten to second grade the visual acuity demand at distance ranges from 20/100 to 20/300, and from grades three to five it approximates 20/60. At near, the demand for all grades ranged from 20/100 to 20/500. In their conclusions, the authors noted that “children with mild to moderate distance refractive errors may be able to perform in classroom activities without correction.”¹ We will come back to this concept later.

Another study (by Negiloni et al.) looked at 33 classrooms from grades four to 12 in India. The minimum visual acuity demand at specific desks from the various grades was evaluated. The average distance and near threshold visual acuity demands were approximately 20/40 and 20/55, respectively. The mean visual acuity demand in grades four to eight was 20/45, and in grades nine to 12 it was 20/36.² The authors point out that lighting, letter contrast and legibility can, of course, also play a role in and impact the visual demand. As we have both performed our share of vision screenings, we can attest that the lighting in classrooms can often be lacking or variable.

Once again, before we present a few cases, we need to look at a few classrooms that showcase some of the challenges in using a refractive error-based guideline. *Figure 1* is from a local private school. You will notice that this second grade classroom is not set up in the traditional row design that many

About Dr. Taub and Schnell

Dr. Taub is a professor and co-supervisor of the Vision Therapy and Pediatrics residency at Southern College of Optometry (SCO) in Memphis. He specializes in vision therapy, pediatrics and brain injury. **Dr. Schnell** is a professor at SCO and teaches courses on ocular motility and vision therapy. She works in the pediatric and vision therapy clinics and is co-supervisor of the Vision Therapy and Pediatrics residency. Her clinical interests include infant and toddler eye care, vision therapy, visual development and the treatment and management of special populations. They have no financial interests to disclose.

of us used when we were in school. The desks are instead arranged in a sort of semicircle, and even the set of desks farthest from the whiteboard is only about 10 feet away. The closest set of desks is only about three to four feet from the front.

Figure 2 shows a third grade classroom from a local public school. At once, you should notice a different desk configuration; none of the desks actually face the front of the room! The kids in this classroom must turn their heads and/or bodies to see what is written at the front of the classroom. Our necks hurt just thinking about it! The closest desks are about five to six feet away, and the farthest are about 12 to 13 feet from the front. The observation can be made here that even though the classrooms are quite different, there is ample opportunity to move a child to the front of the room if there is less than perfect vision. Now, on to the cases!

Case 1

A four-year-old presented for a routine examination without parental complaint of squinting or getting too close to the television. Development was normal: crawling, talking, walking and

shape recognition occurred at the expected times. Visual acuity was 20/40 at distance and 20/40 at near OU. Near point of convergence was “to the nose” x3 and stereo showed gross global forms at 400 seconds of arc. Cover test was ortho at distance and three exophoria at near. Retinoscopy was plano -2.00x180 OD and OS.

To anticipate your question: Yes, this child will stand a good chance of needing glasses down the line, since with-the-rule cylinder of this power tends to be fairly consistent as children age. However, the question you should ask is whether the child needs this correction now. In our opinion and based on the Langford and Hug study, the child’s visual acuity meets their visual needs. We decided simply to sit back and watch for another year while also educating his parents accordingly.

Case 2

An eight-year-old presented for a routine examination without complaints

of squinting or having trouble seeing the board in school. Development was normal and the child was performing well in school, with reading on grade level. Visual acuity was 20/30 at distance and 20/30 at

near OU. Near point of convergence was “to the nose” x3 and stereo showed local forms at 25 seconds of arc. Cover test was ortho at distance and 4 exophoria at near. Accommodative amplitude was 14.00D OD and 15.00D OS. Retinoscopy was -0.75 -0.25x180 OD and OS.

Since there were no complaints from the child or parents, we decided against prescribing at the current time and suggested that the child be moved towards the front of their classroom. We did decide to educate the parents on myopia control, and both they and patient agreed to begin atropine 0.05% to reduce the expected myopic progression due to age and increased nearpoint demand. Based on the Negiloni study, the child’s 20/30 acuity is below the average visual threshold, and moving them up closer to the front would help even more.

Takeaways

While both of these cases highlight “need” according to refractive error, based on their histories—including normal development and lack of symptoms or complaints—we chose not to act. These decisions were purposeful and deliberate. Prescribing is the easy choice, but it is one that comes with potential consequences to visual development. We challenge you to consider the alternative option of temporarily withholding prescription, instead letting the child enjoy more time exploring their world free of glasses. ■

1. Langford A, Hug T. Visual demand in elementary school. *J Pediatr Ophthalmol Strabismus*. 2010;47(3):152-6.

2. Negiloni K, Ramani KK, Sudhir RR. Do school classrooms meet the visual requirements of children and recommended vision standards? *PLoS One*. 2017;12(4):e0174983.

“ Prescribing is the easy choice, but it is one that comes with potential consequences to visual development. ”



Fig. 2. Third grade classroom at a public school. Note how close kids can be moved to accommodate visual need.

Searching for a scleral to fit any cornea?

eJupiter™

eJupiter™ delivers the perfect balance

With proven performance and all-day-comfort, eJupiter scleral contact lenses provide great vision for a wide range of patients, even those with Dry Eye symptoms. And for your presbyopic patients, eJupiter Plus™ offers an extended range of vision without compromising distance. Prescribe eJupiter scleral contact lenses and help your patients see more, comfortably.

✓ Unlimited Warranty

✓ Expert Consultation



Come See Us at SECO Booth #2224

800.366.3933



SHARPEN YOUR SLIT LAMP TECHNIQUE

Refine your skills and master the tricks this instrument offers to help examine patients more thoroughly.



BY NICHOLAS COLATRELLA, OD,
AND JEFFREY VARANELLI, OD
ST. CLOUD, MN; WARREN, MI

The slit lamp biomicroscope is the fundamental diagnostic tool for ocular examination and proficiency in its use is crucial for developing expertise in eye care. The stereoscopic nature of the instrument permits three-dimensional visualization of the ocular anatomy, which allows for qualitative and quantitative analysis of various features. Beyond assessing pupil size, corneal thickness and anterior chamber depth, optometrists can use this tool to observe structures such as the adnexa, ocular surface, iris and crystalline lens.¹ With the incorporation of handheld diagnostic lenses, not only can the posterior segment be evaluated but also the iridocorneal angle.

While you undoubtedly are familiar with the slit lamp, here we will explore methods you may not have previously thought of or attempted very often. Throughout, we will offer tips and share tricks to enhance your slit lamp skills in hopes of leading you to a more comprehensive examination.




Photo: Carl Zeiss Archive

Fig. 1. The slit lamp has certainly evolved over the years. Here's the original the instrument introduced in 1911 by Swedish ophthalmologist Allvar Gullstrand, who went on to win the Nobel prize for his many contributions to eye care.

Equipment and Set-up

The earliest slit lamp emerged in 1911 (offering monocular viewing only) and

has undergone substantial modifications over the past century (*Figure 1*).¹

The contemporary slit lamp biomicroscope consists of two principal components: the illumination system and the observation system. In today's slit lamps, the illumination system can generate a uniform and aberration-free beam. The use of halogen bulbs may enhance the visualization of smaller structures for practitioners. The second component, the observation system, primarily pertains to magnification. Most modern slit lamps feature magnification systems ranging from 5x to 25x, although some models allow for up to 100x magnification.²

Prior to examination, ensuring the comfort and alignment of both the patient and the practitioner is crucial. Position the patient's chin and forehead so that the canthus aligns with the eye mark on the post, as depicted in *Figure 2a*. The oculars should be adjusted to the correct pupillary distance and the eyepieces neutralized to account for the examiner's prescription (*Figure 2b*). These factors will allow for a more comfortable and accurate viewing experience for both the doctor and patient.

About the authors

Dr. Colatrella is the medical director and owner of PineCone Vision Center in Sartell and St. Cloud, MN. He is a fellow in the American Academy of Optometry, past chair of its disease section and a founding chair of the anterior segment section as well as one of the first of two diplomates in anterior segment disease. **Dr. Varanelli** practices at Simone Eye Center in Warren, MI, where he specializes in comprehensive eye care with an emphasis on the medical and surgical comanagement of eye disease. He is a Fellow of the American Academy of Optometry and a past chair of its anterior segment section.

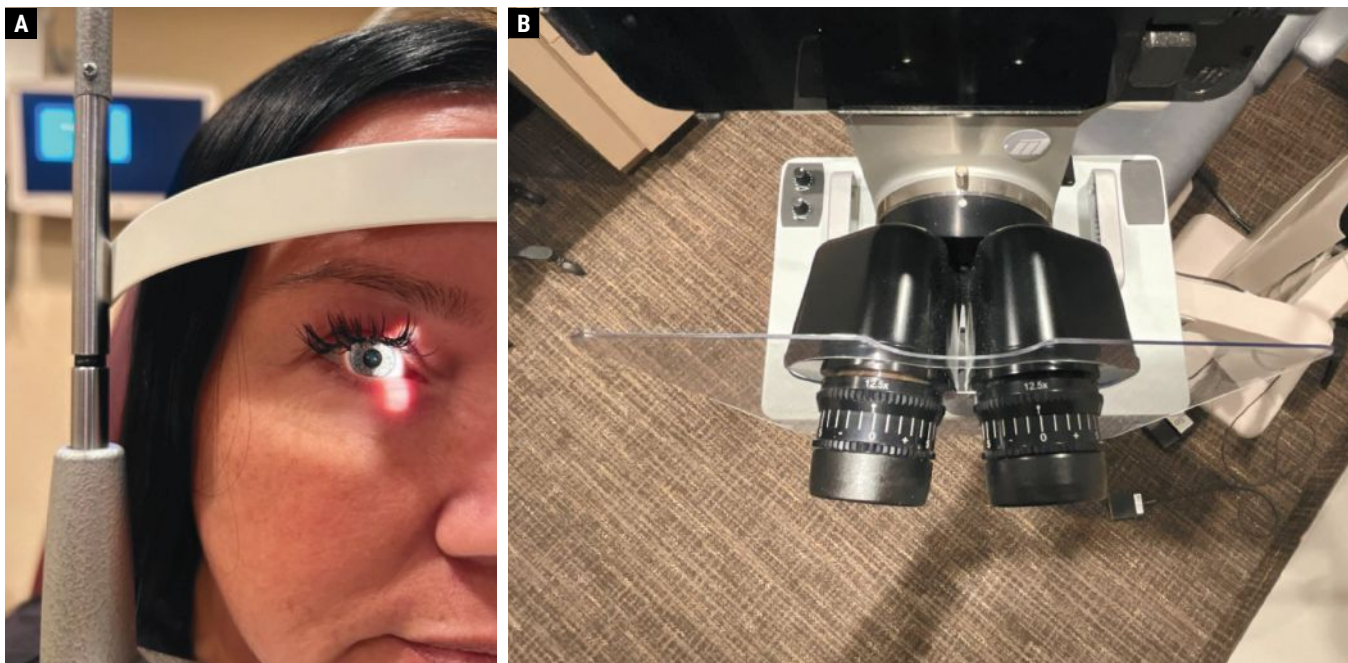


Fig. 2. (a) It is important to properly align the patient's canthus with the mark on the slit lamp post. **(b)** The eyepieces should be neutralized for the examiner's prescription and adjusted for their correct PD.

Pro tip. Different body styles can sometimes be a challenge to position in the slit lamp. For those with a prominent bosom or abdomen, comfortable examination of these patients may prove difficult. To address this, elevate the examination chair to a higher position and instruct the patient to move forward in the seat, leaning into the slit lamp for a more comfortable examination.

Choosing the appropriate slit lamp illumination and beam size is essential for achieving optimal visualization of the structures being examined.³ A longer and wider beam size is ideal for a thorough examination of specific structures like the lids, cornea, conjunctiva and sclera. Conversely, a fine, short beam size is more suitable for detailed viewing.

Commonly employed techniques include diffuse illumination, direct illumination (using methods such as parallelepiped, optic section, conical beam, specular reflection and tangential) and indirect illumination (involving techniques like retroillumination and sclerotic scatter). Each of these offers distinct advantages in visualizing different aspects of ocular structures, which are explained in detail ahead.

Pro tip. When inspecting the cornea, use the brightest illumination that the patient can comfortably tolerate. Many times, slight irregularities become apparent with just a slight increase in brightness (*Figure 3*).

Next, let's consider the three principal illumination methods with advice on performing various techniques.

Diffuse Illumination

This technique provides a comprehensive overview of the eye, emphasizing overall features rather than fine details. Primarily employed for a broad survey of the eye, it is effective for assessing corneal scars or infiltrations, identifying folds in Descemet's membrane, detecting invading blood vessels in the cornea and observing edema of the epithelium, which appears hazy, gray

and somewhat granular. To achieve this, set the angle between the slit lamp and the light source at 30° and 45°, use the widest slit and opt for low to medium magnification. Employ a diffusing filter for the widest slit width and maintain a medium to high illumination level (*Figure 4*).

Direct Illumination

This is the workhorse mode we optometrists tend to employ day in and day out. Several specific applications are discussed below.

Parallelepiped. This illumination technique is most effective when focusing on specific features and defects of the cornea. Parallelepiped illumination provides enhanced visualization of opaque features in the cornea such as scars, abrasions, nebulae, blood vessels

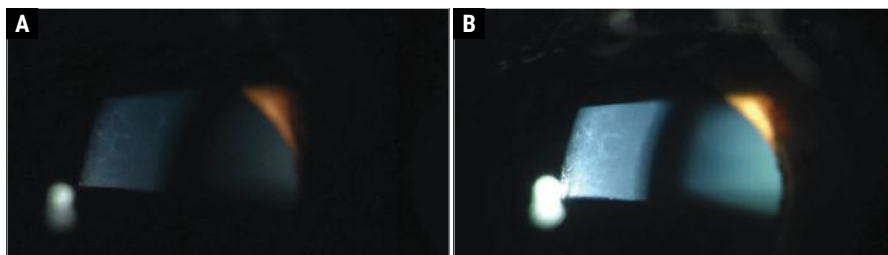


Fig. 3. ABMD in (a) dim illumination and (b) bright illumination at the slit lamp.

tyrvaya[®]
(varenicline solution)
nasal spray 0.03 mg

FOR THE SIGNS
& SYMPTOMS OF
DRY EYE DISEASE

SHE'S LOOKING TO YOU FOR A
DIFFERENT APPROACH WHEN
ARTIFICIAL TEARS ARE NOT ENOUGH.¹

BEFORE ANOTHER DROP

ACTIVATE REAL TEARS

WITH THE FIRST AND ONLY NASAL
SPRAY FOR DRY EYE²



Tyrvaya[®] is not another drop

It's an **ocular surface-sparing** nasal spray.²



Activates real, basal tears

Tyrvaya[®] is believed to work by activating the trigeminal parasympathetic pathway resulting in **basal tear production**.^{2*}



Real tears, real fast

In 2 clinical trials with **mild, moderate, and severe** dry eye disease patients, Tyrvaya increased tear production from baseline by **≥10 mm in Schirmer's Test Score (STS) in nearly 50% of patients at week 4**, with increased tears seen as early as the first dose and over 12 weeks.^{2-8†}

SEE WHAT
TYRVAYA
CAN DO



*The exact mechanism of action is unknown.

†Tyrvaya was evaluated across 3 randomized, vehicle-controlled, double-masked studies in which adults aged ≥22 years diagnosed with dry eye disease received 1 spray of either active drug or vehicle in each nostril twice daily. Primary endpoint: % of patients with mean change from baseline in STS of ≥10 mm at week 4 in ONSET-1: 52% with Tyrvaya (n=48) vs 14% with vehicle (n=43) and in ONSET-2: 47% with Tyrvaya (n=260) vs 28% with vehicle (n=252). Onset of action: mean change from baseline in STS ~5 minutes after first dose (not a prespecified endpoint) in ONSET-1 was 17.2 mm with Tyrvaya (n=48) vs 4.0 mm with vehicle (n=43) and in ONSET-2 was 16.5 mm with Tyrvaya (n=260) vs 6.9 mm with vehicle (n=251). Observed data. On Day 1 in clinical studies, a baseline anesthetized Schirmer's test was performed. Tyrvaya was then administered concurrently with Schirmer's test. Schirmer's test results were measured at ~5 minutes. Mean change from baseline in STS at week 12 in the MYSTIC study was 10.8 mm with Tyrvaya vs 6.0 mm with vehicle. Limitations: Ex-US, single-center study. All subjects were Hispanic or Latino. Tyrvaya group mean baseline STS 5.5 mm (n=41); vehicle group mean baseline STS 5.3 mm (n=41). All randomized and treated patients were included in the analysis and missing data were imputed using last-available data.²⁻⁸

See references on next page.

Indication

Tyrvaya[®] (varenicline solution) nasal spray is indicated for the treatment of the signs and symptoms of dry eye disease.

Important Safety Information

The most common adverse reaction reported in 82% of patients was sneezing. Events that were reported in 5-16% of patients were cough, throat irritation, and instillation-site (nose) irritation.

Please see Brief Summary of Prescribing Information on the next page and the full Prescribing Information at Tyrvaya-pro.com.

BRIEF SUMMARY: Consult the full Prescribing Information for complete product information available at www.tyrvaya-pro.com.

INDICATIONS AND USAGE

TYRVAYA[®] (varenicline solution) nasal spray is a cholinergic agonist indicated for the treatment of the signs and symptoms of dry eye disease.

ADVERSE REACTIONS

Clinical Trials Experience: Because clinical trials are conducted under widely varying conditions, adverse reaction rates observed in the clinical trials of a drug cannot be directly compared to rates in the clinical trials of another drug and may not reflect the rates observed in practice.

In three clinical trials of dry eye disease conducted with varenicline solution nasal spray, 349 patients received at least 1 dose of TYRVAYA. The majority of patients had 31 days of treatment exposure, with a maximum exposure of 105 days.

The most common adverse reactions reported in 82% of TYRVAYA treated patients was sneezing. Other common adverse reactions that were reported in >5% of patients include cough (16%), throat irritation (13%), and instillation-site (nose) irritation (8%).

USE IN SPECIFIC POPULATIONS

Pregnancy: Risk Summary: There are no available data on TYRVAYA use in pregnant women to inform any drug associated risks. In animal reproduction studies, varenicline did not produce malformations at clinically relevant doses.

All pregnancies have a risk of birth defect, loss, or other adverse outcomes. In the US general population, the estimated background risk of

major birth defects and miscarriage in clinically recognized pregnancies is 2% to 4% and 15% to 20%, respectively.

Data: Animal Data: Pregnant rats and rabbits received varenicline succinate during organogenesis at oral doses up to 15 and 30 mg/kg/day, respectively. While no fetal structural abnormalities occurred in either species, maternal toxicity, characterized by reduced body weight gain, and reduced fetal weights occurred in rabbits at the highest dose (4864 times the MRHD on a mg/m² basis).

In a pre- and postnatal development study, pregnant rats received up to 15 mg/kg/day of oral varenicline succinate from organogenesis through lactation. Maternal toxicity, characterized by a decrease in body weight gain, was observed at 15 mg/kg/day (1216 times the MRHD on a mg/m² basis). Decreased fertility and increased auditory startle response occurred in offspring at the highest maternal dose of 15 mg/kg/day.

Lactation: Risk summary: There are no data on the presence of varenicline in human milk, the effects on the breastfed infant, or the effects on milk production. In animal studies varenicline was present in milk of lactating rats. However, due to species-specific differences in lactation physiology, animal data may not reliably predict drug levels in human milk.

The lack of clinical data during lactation precludes a clear determination of the risk of TYRVAYA to an infant during lactation; however, the developmental and health benefits of breastfeeding should be considered along with the mother's clinical need for TYRVAYA and any potential adverse effects on the breastfed child from TYRVAYA.

Pediatric Use: Safety and efficacy of TYRVAYA in pediatric patients have not been established.

Geriatric Use: No overall differences in safety or effectiveness have been observed between elderly and younger adult patients.

References: **1.** Jones L, Downie LE, Korb D, et al. *Ocul Surf.* 2017;15(3):575-628. **2.** Tyrvaya. Prescribing Information. Oyster Point Pharma; 2021. **3.** Oyster Point Pharma. Data on file. OPP-002 (ONSET-1) Clinical Study Report. August 4, 2019. **4.** Oyster Point Pharma. Data on file. OPP-101 (ONSET-2) Interim Clinical Study Report. October 13, 2020. **5.** Quiroz-Mercado H, Hernandez-Quintela E, Chiu KH, Henry E, Nau JA. *Ocul Surf.* 2022;24:15-21. **6.** Wirta D, Torkildsen GL, Boehmer B, et al. *Cornea.* 2022;4(10):1207-1216. **7.** Wirta D, Vollmer P, Paauw J, et al. *Ophthalmology.* 2021;0(0):379-387. **8.** Oyster Point Pharma. Data on file. OPP-004 (MYSTIC) Clinical Study Report. March 19, 2020.

Manufactured for Oyster Point Pharma, Inc. 202 Carnegie Center, Suite 106, Princeton NJ 08540. For more information, visit www.tyrvaya-pro.com. To report an adverse event, contact 1-877-EYE-0123.

© 2023 Viatrix Inc. and/or its affiliates. All rights reserved. VIATRIS and the Viatrix Logo are trademarks of Mylan Inc., a Viatrix Company. Oyster Point[®], Tyrvaya[®], and the Tyrvaya logo are trademarks of Oyster Point Pharma, Inc., a Viatrix company, in the United States and certain jurisdictions. OP-TYR-002308 7/23

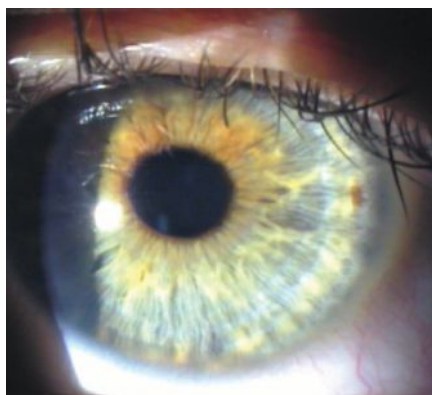

Fig. 4. Diffuse illumination allows for a broad overview of the eye rather than fine details.

and folds in Descemet's membrane. These will reflect light and appear whiter than the surrounding areas. It is also advisable to examine these features under retroillumination.

For a thorough assessment of corneal scarring or foreign bodies, higher magnification is preferred over the wide beam illumination, allowing for a detailed evaluation of both the depth and extent of these conditions. Corneal nerves, resembling fine white silk threads typically branching into a Y shape and mostly visible in the middle third of the stroma, become apparent under higher magnification (*Figure 5*). This technique is valuable for detecting corneal striae that develop in response to edema associated with contact lens wear, ocular surgery and keratoconus.

Moreover, the parallelepiped beam is instrumental in examining the endo-

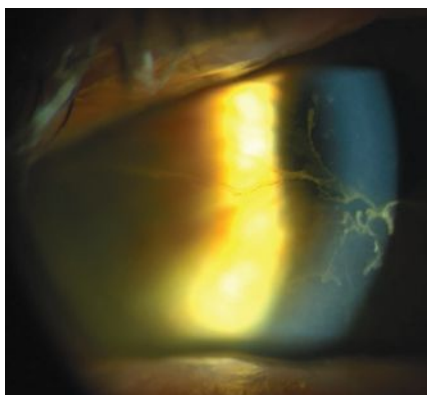


Fig. 5. Parallelepiped illumination is most useful when focusing on specific features of the eye.

thelium. To achieve a parallelepiped, the beam width is narrowed to 1mm to 2mm, illuminating a rectangular area of the cornea. Position the microscope directly in front of the patient's cornea with the light source approximately 45° from a straight-ahead position.

Optic section. Creating an optic section involves a very thin parallelepiped that optically cuts a minute slice of the cornea with maximum magnification. To achieve this, the slit length should be kept small. When examining anterior chamber depth, a wider slit width of 0.1mm to 0.3mm is recommended. The angle between the illuminating and viewing paths should be 45°, intersecting in the region of the anterior eye media under examination, such as the individual corneal layers.

This technique is employed to pinpoint and localize various features, including nerve fibers, blood vessels, infiltrates, cataracts and anterior chamber depth. It is particularly useful for identifying thickening, thinning and distortions in the corneal contour (*Figure 6*). Additionally, the optic section aids in determining the depth of foreign bodies or opacities within the corneal substance, expressed as a percentage of the total corneal thickness. To observe a wide slice of stroma, increase the angle between the microscope and illuminating arm.




Fig. 6. The optic section is commonly used to identify changes in the cornea as well as determining depth or location of a defect.

Furthermore, the optic section can be valuable for perceiving flare in the aqueous. The luminous beam is directed in a way that the upper portion enters the lower part of the pupil, allowing the dark areas immediately above to serve as a contrasting background, enhancing visibility.

A very narrow optic section can also be used for the Van Herick method, which is used to assess the anterior chamber angle without using gonioscopy. It involves using medium magnification, directing a narrow beam close to the limbus at an angle of 60°. The evaluation is based on the depth of the anterior chamber in relation to the thickness of the cornea (*Figure 7*):

Grade 0: Closed anterior chamber, where the cornea "sits" on the iris.

Grade 1: Risky narrow anterior chamber angle with a ratio less than 1:4.

Grade 2: Narrow anterior chamber angle with a 1:4 ratio.

Grade 3: Open anterior chamber angle with a 1:2 ratio.

Grade 4: Open anterior chamber angle with a 1:1 ratio.

Conical beam. This light source is generated by reducing the vertical height of a parallelepiped to create a small circular or square spot of light. Position the light source to 45° to 60° temporally and direct into the pupil (*Figure 8*). Set the magnification to high (16x to 25x) and adjust the intensity of the light source to the highest setting. Focus the beam between the cornea and the anterior lens surface, with careful observation of the dark zone between the cornea and anterior lens. This technique is particularly valuable for examining the transparency of the anterior chamber to identify evidence of floating cells and flare, often observed in cases of anterior uveitis.

The Tyndall effect is the phenomenon that operates on the same principle as a beam of sunlight streaming through a room illuminating airborne dust particles. In the context of the eye, cells, pigment or proteins in the aqueous humor reflect light, creating a faint fog-like appearance. To visualize this

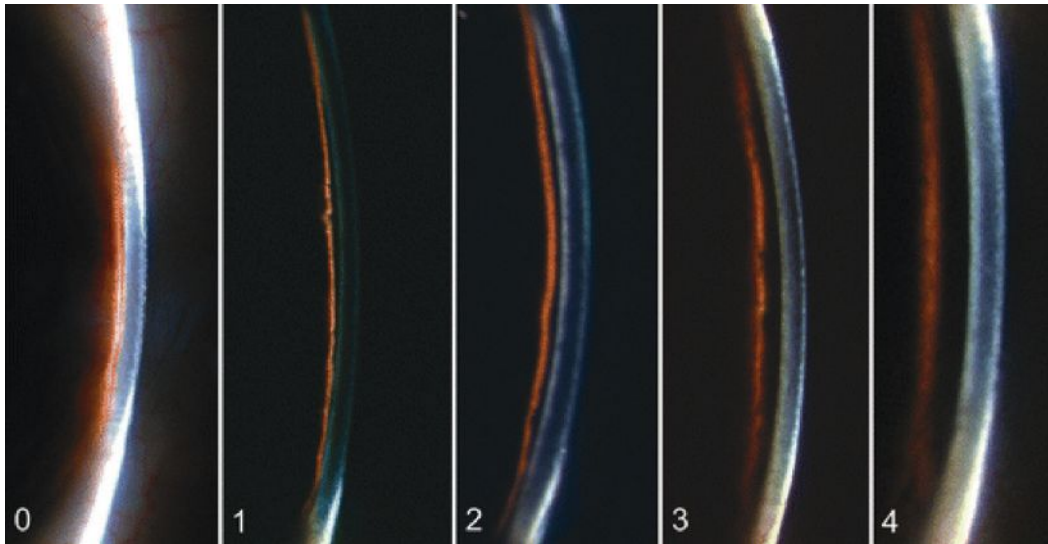


Fig. 7. The Van Herick method assesses the depth of the anterior chamber in relation to the thickness of the cornea from grades 0 to 4, as pictured here.

phenomenon, the slit illuminator is adjusted to the smallest circular beam and projected through the anterior chamber from a 45° to 90-degree angle, with the strongest reflection occurring at 90°.

Pro tip. Once cells in the anterior chamber have been identified using a conical beam, elongate the beam to improve the differentiation between cells, pigment, blood, lens fragments or even foreign bodies. Cells in the anterior chamber can sometimes be confused with other elements, and a slight enlargement of the beam can assist in clearer differentiation.

Specular reflection. This viewing scenario is achieved by positioning the microscope and slit beam at equal angles, away from the normal positioning to the cornea. The light source is set at a 30-degree angle to one side and the microscope is placed at a 30-degree angle to the other side. The angles of the illuminator and microscope must be equal and opposite. Adjust the angle of the light until a bright reflex is obtained from the corneal surface, known as the zone of specular reflection. This technique is employed to assess the integrity of the corneal and lens surfaces. An even and regular reflection indicates a smooth surface, while irregularities, breaks or roughness will result in darker areas that fail to reflect light.

For visualizing the endothelium, initiate the process with lower magnification (10x to 16x), directing a relatively narrow beam onto the cornea. Transition to the highest available magnification and observe the endothelium using only one ocular. Under specular reflection, the anterior corneal surface appears as a white, uniform surface, while the endothelium exhibits a mosaic pattern.

Tangential. This illumination method employs a medium-wide beam of moderate height. To implement this technique, swing the slit lamp arm to the side at an oblique angle, which necessitates a 90-degree separation between the illumination arm and the viewing arm. Magnifications of 10x, 16x or 25x are commonly applied. This method is used to observe both the anterior and posterior cornea and provides an optimal view of the iris without dilation. It is particularly useful for examining the anterior lens, making it an effective approach for viewing conditions like pseudoexfoliation.

Pro tip. Frequently, it is advisable to use a combination of illumination techniques. Corneal lesions, including nodules, foreign bodies,

scars and the like, can be readily identified by employing sclerotic scatter and a broad parallelepiped beam. Subsequently, examining the same lesion with an optic section is recommended to help determine its depth.

Indirect Illumination

Lesions that are more subtle, refractile and/or transparent are usually revealed better via indirect illumination techniques.

Sclerotic scatter.

Achieving this technique involves directing a bright yet narrow beam onto the

limbus. With low 10x magnification and an angle of 40° to 60°, aligning the microscope correctly reveals a ring of light surrounding the cornea, effectively highlighting any corneal pathology. The microscope is directed straight ahead, and when the light is appropriately aligned with respect to the eye, a distinct ring of light becomes visible around the cornea. This light is absorbed and scattered through the cornea, accentuating pathology for a detailed examination.

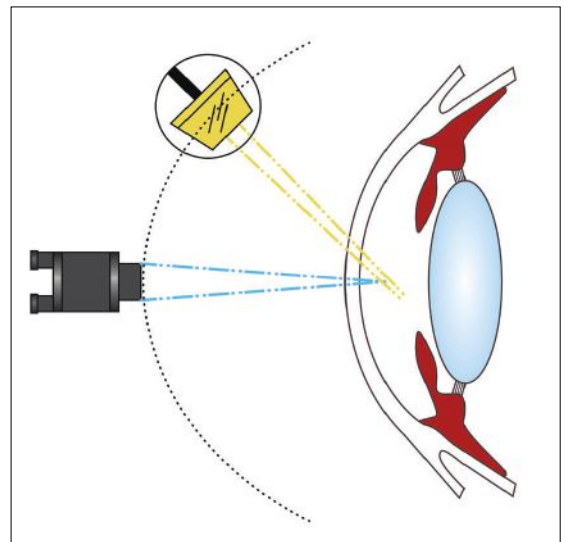


Fig. 8. An example of a conical beam. This light source is generated by reducing the vertical height of a parallelepiped to create a small circular or square spot of light.

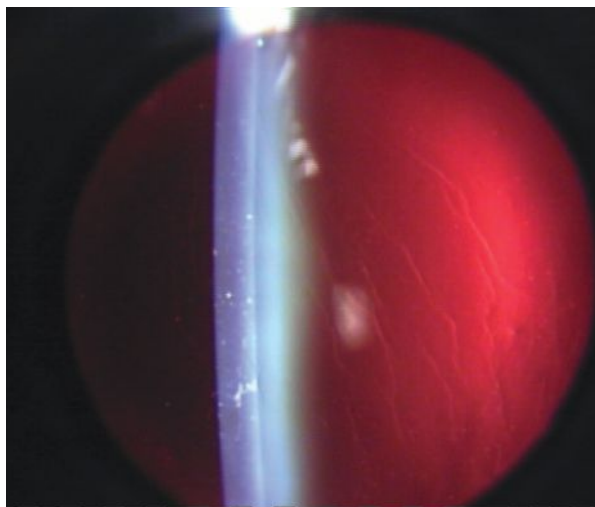


Fig. 9. Retroillumination from the fundus will highlight different corneal changes.

Retroillumination. Reflecting light from a slit beam off a structure situated more posterior than the one under observation will create retroillumination. A vertical slit beam, typically 1mm to 4mm wide, is commonly employed. This technique is frequently used to identify keratic precipitates and other debris on the corneal endothelium (Figure 9). Additionally, retroillumination can be applied to view water clefts, vacuoles of the anterior lens and posterior subcapsular cataracts in the crystalline lens.

Direct retroillumination from the iris involves using a magnification of 16x to 25x and directing the light from a 45-degree angle. Position the microscope straight ahead to observe corneal pathology. Direct a moderately wide slit beam toward the iris directly behind the

corneal anomaly. Indirect retroillumination from the iris follows a similar process, but the beam is directed to an area of the iris bordering the portion behind the pathology. This method provides a dark background, enhancing the contrast for viewing corneal opacities and other details such as the angles.

Retroillumination from the fundus involves placing the slit illuminator in an almost coaxial position with the biomicroscope. Shorten the slit

beam—angled at 2° to 4°—to the height of the pupil to prevent reflection of bright light off the iris. The decentered slit beam is projected near the pupil margin through a dilated pupil. Focus the microscope directly on the pathology using 10x to 16x magnification and opacities will appear in silhouette.

Transillumination. With the pupil in a state of mid-mydriasis (3mm to 4mm when light stimulated), transillumination of the iris becomes possible. Align the light source coaxially (directly in line) with the microscope and employ a full-circle beam of light equivalent to the size of the pupil. Project the light through the pupil and into the eye, focusing the microscope on the iris; a magnification of 10x to 16x is sufficient. The evaluation of the iris involves

assessing how light passes through it, leveraging the red reflex. Normally, the iris pigment absorbs the light; however, pigmentation defects allow the red fundus light to pass through.^{4,5}

Pro tip. Establish a methodical protocol for patient exams to minimize the risk of overlooking any structures or disease states. Irrespective of the exam's purpose, our standardized procedure involves inspecting the lids, lashes, conjunctiva, corneal epithelium to endothelium, anterior chamber, iris with transillumination, lens from anterior to posterior and concluding with an examination of the anterior vitreous prior to use of handheld diagnostic lenses.

Takeaways

In conclusion, the slit lamp biomicroscope stands as the cornerstone of ocular diagnostics, playing a pivotal role in comprehensive eye care. Mastery of this instrument is essential for optometrists, as it enables a three-dimensional visualization of the anterior segment, allowing for both qualitative and quantitative analysis of various ocular features. The evolution of the slit lamp over the past century has equipped practitioners with advanced illumination and observation systems, enhancing the ability to visualize minute structures and abnormalities. Continuous exploration and refinement of slit lamp skills are paramount. By embracing these techniques, you can deepen your understanding of ocular pathology, improve diagnostic accuracy and ultimately elevate the standard of care provided to your patients. ■

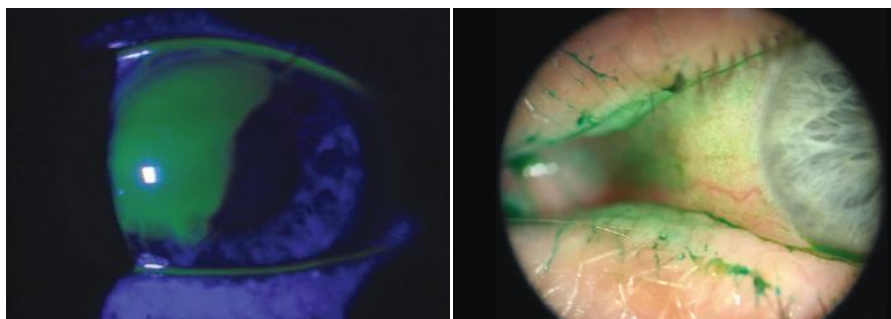


Fig. 10. The use of vital dyes is imperative when assessing the ocular surface for signs of infection, trauma, surface abnormalities among others. Using the cobalt blue filter in conjunction with sodium fluorescein will highlight certain corneal abnormalities. Lissamine green tends to highlight dead and degenerating cells. It will also easily adhere to mucus strands and filaments and even show advanced conjunctival staining in dry eye patients.

1. Kaur K, Gurnani B. slit lamp biomicroscope. In: StatPearls [Internet]. Treasure Island (FL): StatPearls Publishing. June 11, 2023. Accessed January 23, 2024. www.ncbi.nlm.nih.gov/books/NBK587440/.

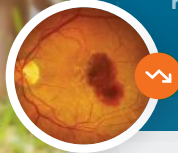2. Kalayoglu MV. The evolution of slit lamp biomicroscopy. November 30, 2005. Accessed January 25, 2024. www.opthalmologyweb.com/tech-spotlights/26450-the-evolution-of-slit-lamp-biomicroscopy/.

3. Martin R. Cornea and anterior eye assessment with slit lamp biomicroscopy, specular microscopy, confocal microscopy and ultrasound biomicroscopy. Indian J Ophthalmol. 2018;66(2):195-201.

4. Scott A. Introduction to slit lamp utilization. Canadian Association of Optometrists. April 10, 2019. Accessed January 23, 2024. <https://srpc.ca/resources/documents/RR/2019/syllabus/handouts/333.pdf>.

5. Jacobs N. Advanced slit lamp skills. March 3, 2015. Accessed January 23, 2024. www.healthpartners.com/institute/wp-content/uploads/2018/05/3-SA-45-SLE-Handouts-new.pdf.

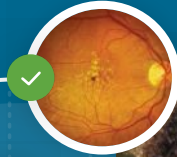Prevent AMD Vision Loss with Digital Healthcare



IRIS REGISTRY

20/83 VA

Average at wet AMD diagnosis according to IRIS Registry real-world data¹



ALOFT STUDY

≥20/40 VA

Average at wet AMD diagnosis with ForeseeHome²



ForeseeHOME™
AMD Monitoring Program

Early Detection Helps Preserve Vision

ForeseeHome is a **remote monitoring** program for at-risk dry AMD patients that helps **detect wet AMD earlier** and alerts you of changes.


Remote patient monitoring leads to better outcomes and stronger optometric practices

- ✓ FDA Cleared
- ✓ Medicare Covered

- Plug and play digital health solution for your patients
- Solidify long-term relationships with your patients
- No cost to your practice
- Strengthen your referral relationships with qualified wet AMD referrals

The Key to Successful Home Monitoring

NOTAL VISION MONITORING CENTER



Engagement & Education
Benefits Verification & Authorization
Continuous Monitoring



Practice Workflow Implementation
Remote Patient Management
Vision Alert Management



ForeseeHome is a registered trademark, and the ForeseeHome AMD Monitoring Program and logo and the Notal Vision logo are trademarks of Notal Vision. © 2023 Notal Vision, Inc. All rights reserved.

References: 1. Rao P et al. *Ophthalmology*. 2018;125(4):522-528. 2. Mathai M, Reddy S, Elman MJ, Garfinkel RA, Ladd B, Wagner A, Sanborn GE, Jacobs J, Busquets M, Chew EY; ALOFT study group. Analysis of the Long-term visual Outcomes of ForeseeHome Remote Telemonitoring - The ALOFT study. *Ophthalmology Retina*. 2022;6:922-929.

See website for FDA Indication for Use.

SM-169.3



GET STARTED TODAY

1-855-600-3112

Mon-Fri, 8 AM to 6 PM EST

notalvision.info/revopt

NAVIGATING OPTIC NERVE DIFFERENTIALS

Use this systematic protocol to arrive at the proper diagnosis without delay.



SAIDIVYA KOMMA, OD
GREENSBORO, NC

Acute vision loss is enough to set off alarms in the office, but add disc swelling to the presentation and the case quickly becomes an ocular emergency that needs to be tended to right away. It is important to thoroughly test these patients to make the appropriate diagnosis and come up with a proper management plan. During a busy clinic day, this is easier said than done, so developing a systematic approach to disc edema helps efficiently narrow down the differentials. Adapting this protocol can ultimately save a patient's vision, and in some cases, a patient's life.

There are a few definitions of disc swelling to outline before categorizing the differential diagnoses:

- **Pseudopapilledema:** appearance of swollen nerves in the absence of true edema.
- **Papilledema:** bilateral optic disc edema secondary to increased intracranial pressure (ICP).¹
- **Disc edema:** swelling of the optic disc due to fluid accumulation within or around the axons.

Pseudopapilledema

These cases are easiest to diagnose with fundus photography and OCT imaging. Patients are typically asymptomatic and the nerves usually arouse suspicion during the dilated fundus exam or on routine fundus photography. Differential

diagnoses for pseudopapilledema include disc drusen, congenitally anomalous nerves, vitreopapillary traction and a peripapillary choroidal neovascular membrane.

Disc drusen are acellular deposits of proteins and calcium that have an autosomal dominant inheritance pattern.² Eighty-seven percent of these patients, particularly those with superficial disc drusen, will develop visual field defects that can manifest from an enlarged blind spot to a nasal or arcuate defect.^{2,3} Although hyperreflectivity on B-scan ultrasonography used to be the gold standard for diagnosis, the prevalence and ease of OCT instruments has made enhanced depth imaging the diagnostic test of choice in recent times.³ Superficial disc drusen will hyperautofluoresce on

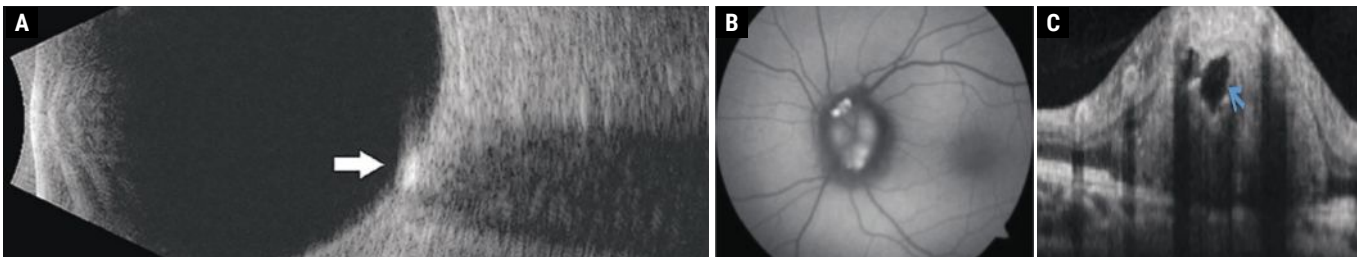


Fig. 1. (a) Disc drusen seen as hyperreflective deposit on B-scan ultrasonography. (b) Disc drusen exhibiting hyperautofluorescence on FAF photography. (c) Disc drusen seen as a signal-poor core with hyperreflective borders on enhanced-depth imaging OCT.

About the author

Dr. Komma is an optometrist at Guilford Eye Center in Greensboro, NC. She graduated from the Pennsylvania College of Optometry and completed her ocular disease residency at the Salisbury VA Medical Center. She served as an externship coordinator for the Kernersville VA Healthcare Center and is a Fellow of the American Academy of Optometry. She is the current president of the NCAAO. She has no financial interests to disclose.

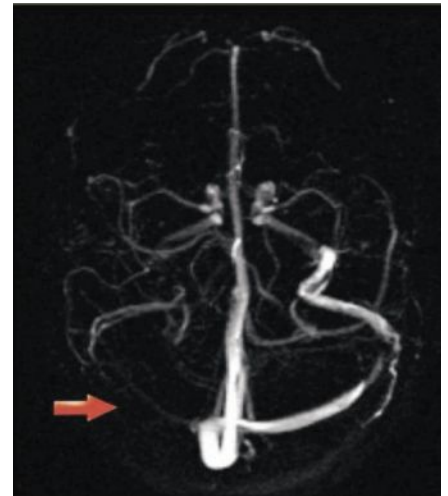
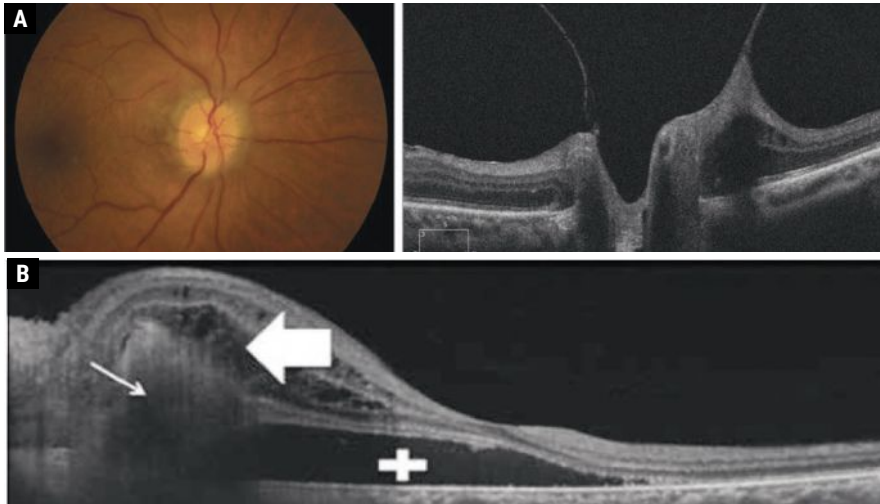


Fig. 2. (a) Vitreopapillary traction causing the appearance of pseudopapilledema. (b) Peripapillary choroidal neovascular membranes with subretinal fluid causing the appearance of elevated disc margins.

Fig. 3. Magnetic resonance venography showing that the right venous sinus has no signal due to thrombosis.

fundus autofluorescence (FAF) and stain with fluorescein angiography (*Figure 1*).³ Patients with disc drusen should be monitored with serial perimetry and optic nerve scans annually. Although there is no standard of care for treatment in patients with structural or functional progression, topical brimonidine may be considered off-label due to its possible neuroprotective benefits.^{2,3}

A hallmark sign to look for in patients with congenitally anomalous nerves is the presence of a spontaneous venous pulse (SVP), which is present in 80% of the normal population.⁴ However, it is important to note that ICP, like intraocular pressure, exhibits diurnal fluctuation. So, although an SVP is present during the exam, it may not be enough to rule out papilledema in the presence of other symptoms. Other physiologic changes within the nerve that can cause the appearance of indistinct nerve margins are vitreopapillary traction and peripapillary choroidal neovascular membranes, both of which can be identified with OCT (*Figure 2*).

Papilledema

Causes of ICP include intracranial masses, increased venous pressure, inflammation, sleep apnea and medications. Although idiopathic intracranial hypertension (IIH) is the most common cause, it is a diagnosis of exclusion.^{1,5}

Patient History

The patient's presenting symptoms and history can help narrow down the differential diagnoses for papilledema. The typical clinical profile for an IIH patient is an overweight female of childbearing age. Beyond that, increased intracranial pressure most commonly causes headaches (worse when supine), pulsatile tinnitus, transient visual obscurations with postural changes, and diplopia.^{1,5} Recent history of a fall or head trauma can indicate the presence of an intracranial hemorrhage. The existing diagnosis of a hypercoagulability disorder in the background of a persistent headache may raise suspicion for cerebral venous sinus thrombosis (*Figure 3*).⁶

Certain medications can cause papilledema as well, so it is important

to rule out the current or recent use of the following substances: tetracyclines, hormonal contraceptives, ethambutol, amiodarone, isoniazid, vitamin A derivatives (Accutane, tretinoin), lithium, sex hormones and steroids.⁷ Lead and methanol poisoning can also cause papilledema.⁷

Entrance Testing

Here is what to look for when examining patients with papilledema:

- **Visual acuity:** usually unaffected unless the patient has advanced nerve atrophy or visual field loss.
- **Blood pressure:** within normal limits.
- **Pupils:** (-)APD.
- **EOMs:** (+)sixth nerve palsy (unilateral or bilateral), third and fourth nerve palsies less common.

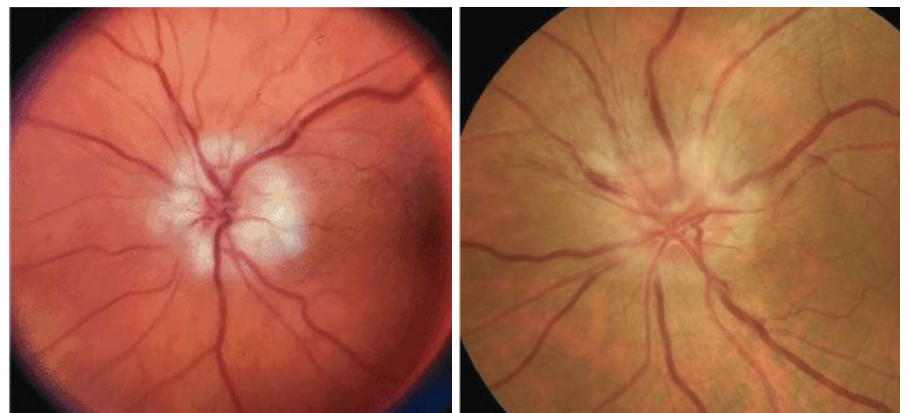


Fig. 4. AAION on the left and NAION on the right.

- **Visual field:** enlarged blind spot is most common, nasal step is the second most common defect.

Imaging

Use available imaging tools to narrow down the differentials and document disease progression:

- **Fundus photography.** Photo documentation of baseline nerve appearance is very useful for patient education, follow-ups and comanagement.

- **OCT nerve and ganglion cell complex.** Initial scans will show thickening of the retinal nerve fiber layer to some extent, but it is important to get baseline nerve scans on all papilledema (and pseudopapilledema) patients to monitor for change over time. The goal is to avoid irreversible optic atrophy with timely referral and treatment, but prognosis can be difficult to judge in the early stages.

- **MRI of brain and orbits with contrast/MRV.** Head imaging is key in identifying other causes of elevated ICP, such as masses, hydrocephalus, clots, cerebral inflammatory disorders or venous insufficiencies. Lumbar punctures induce an acute pressure gradient that can cause brain herniation if there are undetected space occupying lesions. This is why it is imperative for every papilledema patient to undergo head imaging prior to proceeding with the next steps.

Management

There are a few considerations to make when managing papilledema:

- **Lumbar puncture with cerebrospinal fluid (CSF) analysis.** The normal opening pressure for a lumbar puncture is 6cm H₂O to 25cm H₂O in adults—anything above that indicates elevated ICP.^{1,5} CSF analysis helps rule out inflammatory, infectious and neoplastic causes of elevated ICP.

- **Treatment.** Standard for IIH is oral acetazolamide, starting at 500mg BID and titrated as high as 4g BID.^{1,5} Patients on oral acetazolamide long-term need to get routine renal function testing. In addition, heavy emphasis should be placed on diet and lifestyle,

as studies found losing 6% of the body weight yields improvement in signs and symptoms of IIH.^{1,5}

- **Sleep study.** A diagnosis of sleep apnea should be considered in all papilledema patients. Sleep apnea is thought to cause intermittent increases in ICP as nocturnal hypoxia triggers vasodilation, which has been associated with cases of persistent papilledema that resolved with CPAP use.⁸ This is a tricky diagnosis because daytime lumbar punctures will be normal in these patients and their symptoms more closely follow silent optic atrophy.

Disc Edema

Causes of disc edema with normal intracranial pressure can be categorized as *ischemic, inflammatory, compressive, infiltrative* or *hereditary*. Non-perfusion leads to failure of ATP-dependent ion transport, the buildup of intracellular sodium and the eventual accumulation of water to maintain the osmotic gradient.⁹ These physiologic changes cause the appearance of disc edema in cases of arteritic anterior ischemic optic neuropathy (AAION), non-arteritic ischemic optic neuropathy (NAION), central retinal vein occlusions, diabetic papillopathy and malignant hypertension.⁹⁻¹²

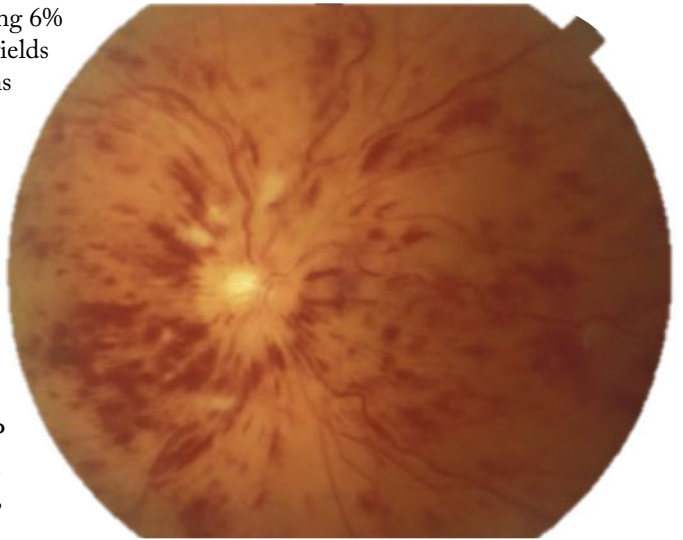


Fig. 5. Central retinal vein occlusion with disc edema.

Ischemic

These typically present with painless, acute vision loss. It is imperative to rule out AAION in all patients over age 50 due to its high correlation with giant cell arteritis, which can be fatal. In comparison to the hyperemic disc seen in NAION, AAION has a chalkier disc appearance and is often associated with scalp pain, headaches, jaw claudication, fever, amaurosis fugax and weight loss (*Figure 4*).^{12,13} NAION has a slightly younger at-risk population (under 50 years old) and occurs secondary to vasculopathic causes, such as hypertension, hyperlipidemia, diabetes and sleep apnea.¹³ The use of erectile dysfunction medications also increases the risk for NAION. Patients with inherently smaller C/D ratios present with higher risk for NAION, or a “disc at risk.” Both conditions may present with altitudinal field defects

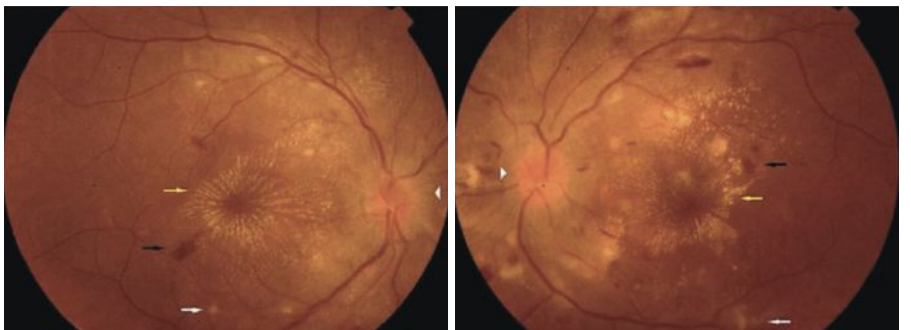


Fig. 6. Malignant hypertension with bilateral disc edema, macular stars, flame hemes and cotton wool spots.

Visit us at
SECO Booth 1723

OPEN YOUR EYES to Bruder[™]

a Hilco Vision Company[®]

HYGIENE | HEAT | HYDRATION



Open your eyes to Bruder[®]. You know us for our #1 doctor-recommended moist heat eye compress. But did you know we also offer a comprehensive line of science-based products for lid hygiene and hydration?

Healthy eyes start with three dry eye essentials: Hygiene, Heat and Hydration. Proper lid hygiene, with Bruder Wipes and Solution Spray (HOCl), helps to relieve dry eye symptoms, supports the tear film and reduces bacteria. Moist heat applied to closed eyes, using a Bruder Mask or new Eyedration[®] Mask, supports production of tears and unclogging of the meibomian glands, releasing natural oils that balance the tear film. Hyper-hydrating with our new specially formulated drink mix, Dry Eye Drink[™] by Bruder, helps fight dehydration that has been associated with dry eye and other ocular diseases.

Learn more about our new and core products on our professional portal bruder.com/pro

Ready to provide relief? Stock up now on Bruder dry eye essentials at order.brunder.com or contact us at eye@bruder.com or 888-827-8337.



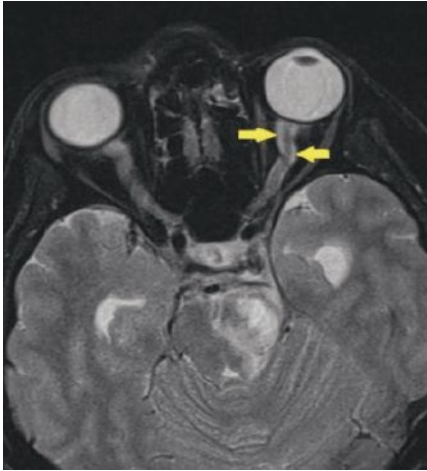


Fig. 7. Optic nerve sheath enhanced in a case of optic perineuritis, also known as the “tram-track” sign. This sign is not specific to optic perineuritis and can also be seen in optic nerve sheath meningiomas.

and a relative afferent pupillary defect (RAPD). An ischemic central retinal vein occlusion can also present with a RAPD and disc edema, the latter of which resolves with time (Figure 5).¹¹

Differentials of ischemic disc edema that typically do not present with an RAPD include diabetic papillopathy and malignant hypertension. Diabetic papillopathy is a diagnosis of exclusion that resolves with improved blood sugar control and has good visual prognosis.¹⁴ Blood pressure readings >180/120 should raise alarms for malignant hypertension, or grade 4 hypertensive retinopathy (Figure 6). These patients need to be sent to the emergency room for immediate blood pressure lowering.

Inflammatory

Optic neuritis should be ruled out in young patients (15 to 45 years) presenting with unilateral, acute vision loss. Other associated symptoms include decreased color vision, (+)RAPD and pain on eye movements. It is important to note that only one-third of optic neuritis cases present with disc edema, while two-thirds of cases are retrobulbar. A lesser-known cause of orbital inflammation is optic perineuritis, which presents with signs and symptoms similar to optic neuritis, but with slower onset

and milder effect on central vision.¹⁵ The best way to differentiate the two is with directed orbital imaging, in which optic neuritis presents with optic nerve enhancement and possible white matter lesions, while optic perineuritis presents with enhancement around the optic nerve sheath (Figure 7).¹⁵

Infections

Neuroretinitis is another cause of disc edema with infectious etiology most commonly caused by *Bartonella henselae* or *quintana*, or cat-scratch disease. This condition also presents with unilateral, acute vision loss, dyschromatopsia and a (+)RAPD. Similar to malignant hypertension, it also presents with a macular star. Neuroimaging is normal and not indicated in these cases and treatment can be started empirically while waiting on lab testing.¹⁶ Less common causes of infectious disc edema include Lyme

disease, syphilis, toxoplasmosis, histoplasmosis and tuberculosis.

Compressive

Disc edema can manifest in response to compressive forces within the orbit by thyroid orbitopathy, idiopathic orbital inflammation, optic nerve sheath meningioma and other orbital tumors.¹⁷ These patients will present with progressive vision loss, dyschromatopsia, proptosis and abnormal extraocular motility. They are best diagnosed with an MRI of the orbits, chiasm and brain with contrast. In thyroid orbitopathy, the MRI will show enlarged recti with tendons spared. This is in contrast to idiopathic orbital inflammation, which is typically unilateral and shows enlargement of tendons, recti and the lacrimal gland. Optic nerve sheath meningiomas will present similarly to optic perineuritis on head imaging, but without the acute symptoms.¹⁷

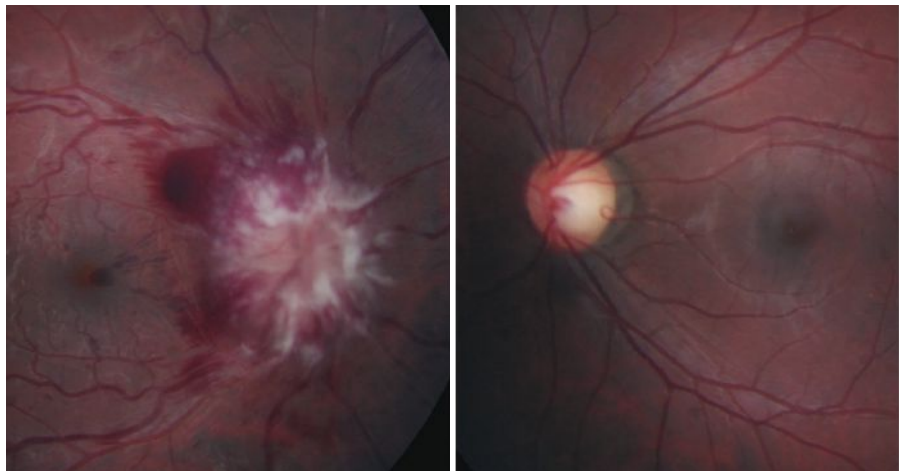


Fig. 8. Leukemic infiltrative optic neuropathy.

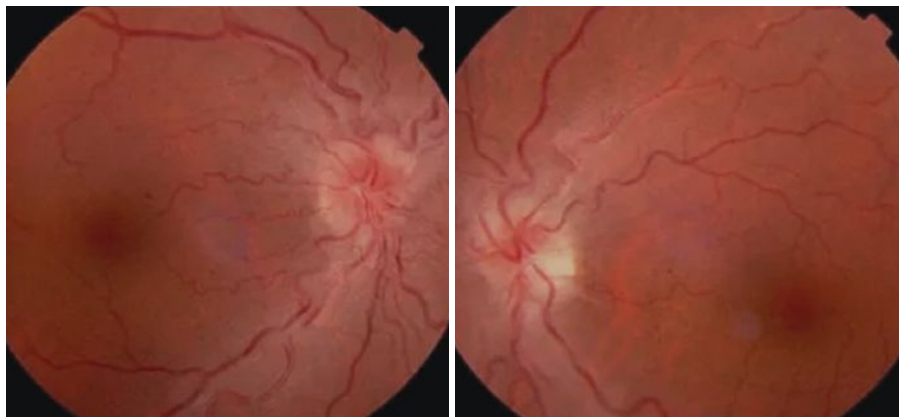


Fig. 9. Leber's hereditary optic neuropathy.

An efficiency
tool that propels
your practice
into the future.



Olleyes VisuALL Virtual Reality Software

We bring you unparalleled office efficiency, cutting edge testing technology, and the new era of patient comfort, in just one device.

3 essential elements that place you at the cutting edge.

Dynamic Matrix



Our proprietary eye tracking algorithm can reduce fixation losses to zero, automatically.

Scientific Validation



Reliable, accurate results validated by esteemed scientific institutions.

AI Virtual Assistant



Annie can increase office efficiency, monitor patients, speak over 35+ languages and so much more.

One product. One complete diagnostic universe.



Visual Acuity



Visual Field



Extraocular Motility



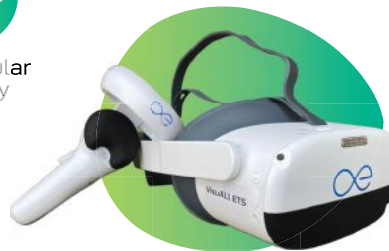Color Vision



Pupillometry



Contrast Sensitivity



Equip your practice with a game-changing technology today.

Scan code to know more or visit www.olleyes.com

DISC EDEMA

UNILATERAL

NORMAL VISION

Pseudopapilledema

1. **Disc drusen**
 - OCT, FAF, CT
2. **Congenitally anomalous optic nerves**
 - (+)SVP in 80% of normal population
3. **Vitreopapillary traction**
 - OCT
4. **Peripapillary CNVM**
 - OCT, FA

If none of the above, order MRI of brain and orbits with contrast to rule out:

Optic nerve sheath meningioma (and other lesions compressing the optic nerve)

- some degree of proptosis
- slow, progressive vision loss
- observe with serial visual fields and imaging once every six months

Optic nerve perineuritis

- variant of idiopathic inflammatory disease (e.g., sarcoidosis, granulomatosis with polyangiitis, Behcet's) or infection (syphilis)
- neuroimaging shows enhancement of nerve sheath instead of nerve head

If neuroimaging is normal:

Incipient NAION

- (-)RAPD, enlarged blindspot on VF, small C/D ratio of uninvolved eye
- one-third of cases progress into NAION, the rest spontaneously resolve

Diabetic papillitis

- resolves spontaneously

Non-ischemic CRVO

- peripapillary hemorrhages, dilated and tortuous veins

Asymmetric papilledema

ABNORMAL VISION

AGE <50

Idiopathic demyelinating optic neuritis

- (-)peripapillary hemorrhages, 70% of cases are women (20s to 40s), 90% have pain on EOMs, subacute vision loss and one-third exhibit disc edema
- thickening on OCT, focal enhancing lesions on MRI
- first presenting sign in 20% of MS patients
- visual function returns in six weeks

vs. less common forms of optic neuritis...

Neuromyelitis optica spectrum

- non-caucasian, counting fingers vision, enhancement of long segments of optic nerve on MRI, bilateral involvement, poor visual recovery at two months

Anti-myelin oligodendrocyte glycoprotein

- 30 to 50 years old, recurrent episodes of optic neuritis, poor visual function, 80% exhibit disc edema
- order anti-MOG titers

LESS COMMON CONDITIONS

Compressive optic neuropathy

- gradual vision loss and proptosis

Optic nerve glioma

- neurofibromatosis type 1
- neuroimaging of orbit

Neoplastic infiltrative neuropathies

- patients with known malignancies, explosive presentation

Non-infectious inflammatory conditions

- an example is sarcoidosis; will present with other signs such as posterior uveitis, vitritis, vasculitis and/or retinal vascular occlusions

Infective optic neuropathies

- syphilis, TB, HIV
- HSV/HZV, CMV, West Nile virus, chikungunya, dengue (these will present with vitritis)

Neuroretinitis

- swollen nerve with macular star
- infectious: bartonella, syphilis, TB, Lyme
- non-infectious: sarcoidosis

Leber's hereditary optic neuropathy

- telangiectatic vessels, mitochondrial inheritance, males 20s to 30s
- second eye affected weeks-months later (counting fingers or worse VA)
- genetic testing

Infiltrative

These tend to have acute explosive presentation secondary to leukemia, lymphoma, metastases from other tumors and sarcoidosis (Figure 8).¹⁸ Patients usually have a history of known malignancies and may be symptomatic for progressive vision loss, (+)RAPD and dyschromatopsia.¹⁸ Due to the unpredictable nature of the etiology, symptoms can vary widely.

Hereditary

Leber's hereditary optic neuropathy has a mitochondrial inheritance pattern

and thus a predilection toward men in their 20s and 30s. They present with symptoms of painless, bilateral vision loss over the course of days or weeks. Visual field testing shows dense central scotomas and funduscopy may show peripapillary telangiectasia (Figure 9).¹⁹ Family history typically reveals generations of blindness and can be confirmed with genetic testing. Unfortunately, visual prognosis for these patients is poor (counting fingers vision or worse) and they should be set up with low vision rehabilitation services. A cardiology referral is also indicated due to the

associated risk for cardiac conduction abnormalities.¹⁹

Takeaways

Hopefully with this information in your cache, the next in-office presentation of disc edema will be less nerve-wracking. Knowing the differentials, their risk factors and associated signs and symptoms can help narrow down your diagnosis (Figure 10). While reaching the correct diagnosis is important, management of optic atrophy also matters. As a result, getting as much baseline testing as possible in the initial visits of non-

BILATERAL

NORMAL VISION

Papilledema

- (-)RAPD, enlarged blind spot on VF (unless exuberant amount of edema leaks into macula)
- otherwise, normal visual function
- long-standing papilledema can cause varying degrees of optic atrophy, which can result in a decrease in central VA
- headaches, transient visual obscurations, nausea, vomiting and pulsatile tinnitus caused by increased intracranial pressure
- look for SVP to rule out pseudopapilledema
- increased intracranial pressure can result from CSF outflow obstruction, increased CSF production or decreased CSF absorption
- order MRI/MRV; if neuroimaging normal, proceed with lumbar puncture

Once other causes of papilledema are excluded:

Idiopathic intracranial hypertension

- increased opening pressure on lumbar puncture, sixth nerve palsy, enlarged blindspot on VF
- overweight, fertile females
- treat with weight loss (6% of body weight) with or without oral acetazolamide
- if progressive visual field defects or decrease in central VA, resort to CSF diversion procedures

ABNORMAL VISION

Optic neuritis

- bilateral optic neuropathies require MRI of brain and orbits with contrast; look for optic nerve enhancement and intracranial abnormalities

Giant cell arteritis

- if highly suspicious, start steroids, even prior to receiving lab results to save other eye

NAION

- diagnosis of exclusion in bilateral cases

Non-infective inflammatory optic neuropathy

- e.g., sarcoidosis

Thyroid eye disease

- nerve compressed by enlarged extraocular muscles

Infiltrative optic neuropathies

Acute methanol poisoning

Paraneoplastic optic neuropathy

- very rare, accompanied by vitritis

Malignant hypertension

AGE >50

NAION

- Segmental swelling, peripapillary hemorrhages, small C/D ratio in fellow eye (90% of the time), (+)RAPD
- caused by impaired blood flow to the short posterior ciliary arteries (vasculopathic comorbidities)
- sudden vision loss with worsening up to 30 days after onset
- 12% experience mild eye pain (not on EOMs)
- altitudinal defect on VF
- no meaningful improvement in visual function (~30% may improve)

AAION

- Caucasians 70 to 80 years old
- 80% have headaches, fatigue, weight loss, fever, jaw claudication, shoulder pain and scalp tenderness
- 20% show visual loss as first manifestation
- highly associated with giant cell arteritis, a vasculitis which affects medium and large vessels (such as the internal carotid artery and ophthalmic arteries)
- pallid optic disc swelling with or without central retinal vascular occlusions
- severe vision loss
- order stat ESR/CRP/CBC, consider temporal artery biopsy (beware of skip lesions)
- treat with high-dose steroids

Fig. 10. Flow chart of disc edema differentials.

emergent cases would be beneficial for long-term follow-up. ■

1. Dhoot R, Margolin E. Papilledema. PubMed. In: Stat Pearls. August 8, 2023. Accessed November 16, 2023. <https://www.ncbi.nlm.nih.gov/books/NBK538295/>.
2. Bhakhri R, Luce C. Optic disc drusen and associated complications: a teaching case report. The Journal of Optometric Education. Accessed November 16, 2023. <https://journal.opted.org/article/optic-disc-drusen-and-associated-complications-a-teaching-case-report/>.
3. Silverman AL, Tatham AJ, Medeiros FA, Weinreb RN. Assessment of optic nerve head drusen using enhanced depth imaging and swept source OCT. J Neuroophthalmol. 2014;34(2):198-205.
4. Moret F, Poloschek CM, Lagrèze WA, Bach M. Visualization of fundus vessel pulsation using principal component analysis. Invest Ophthalmol Vis Sci. 2011;52(8):5457.
5. Thurtell MJ, Wall M. Idiopathic intracranial hypertension (pseudotumor cerebri): recognition, treatment and ongoing

- management. Curr Treat Options Neurol. 2012;15(1):1-12.
6. Park MG, Roh J, Ahn SH, et al. Papilledema and venous stasis in patients with cerebral venous and sinus thrombosis. BMC Neurology. 2023;23(175).
7. Thon OR, Gittinger JW. Medication-related pseudotumor cerebri syndrome. Semin Ophthalmol. 2016;32(1):134-43.
8. Purvin VA, Kawasaki A, Yee RD. Papilledema and obstructive sleep apnea syndrome. Arch Ophthalmol. 2000;118(12):1626-30.
9. Weiner G. Case Studies of Optic Disc Edema. American Academy of Ophthalmology. October 1, 2015. Accessed January 13, 2024. www.aao.org/eyenet/article/case-studies-of-optic-disc-edema.
10. Jung JJ, Baek H. Analysis of the causes of optic disc swelling. Kor J Ophthalmol. 2011;25(1):33-6.
11. Margolin E. The swollen optic nerve: an approach to diagnosis and management. Prac Neurol. 2019;19(4):302-9.
12. Bernstein SL, Johnson MA, Miller NR. Nonarteritic anterior ischemic optic neuropathy (NAION) and its experimental models. Prog Retin Eye Res. 2011;30(3):167-87.

13. Raizada K, Margolin E. Non-arteritic anterior ischemic optic neuropathy. PubMed. October 31, 2022. Accessed January 13, 2024. www.ncbi.nlm.nih.gov/books/NBK559045/.
14. Giuliari GP, Sadaka A, Chang PY, Cortez RT. Diabetic papillopathy: current and new treatment options. Curr Diabetes Rev. 2011;7(3):171-5.
15. Gupta S, Sethi P, Duvesh R, et al. Optic perineuritis. BMJ Open Ophthalmol. 2021;6(1):e000745.
16. Purvin V, Sundaram S, Kawasaki A. Neuroretinitis: review of the literature and new observations. J Neuroophthalmol. 2011;3(1):58-68.
17. Rodriguez-Beato FY, De Jesus O. Compressive optic neuropathy. PubMed. August 23, 2023. Accessed January 13, 2024. www.ncbi.nlm.nih.gov/books/NBK560583/.
18. Compressive and Infiltrative Optic Neuropathies | Walsh and Hoyt Textbook. November 16, 2023. Accessed January 13, 2024. <https://collections.lib.utah.edu/details?id=190040>.
19. Shemesh A, Sood G, Margolin E. Leber Hereditary Optic. PubMed. September 24, 2022. Accessed January 13, 2024. <https://www.ncbi.nlm.nih.gov/books/NBK482499/>.

FUNDUS EXAMINATION: PAY ATTENTION TO THE BORDERS

Tips and pearls for expanding your view of the peripheral retina.



**KARINA MILLER, OD, MS, AND
STEVE NJERU, OD, MS**
CHILLICOTHE, OH

In today's fast-paced world, patients may be quick to decline dilation because they might not consider it as important as their refractive needs; however, assessing the fundus, particularly the periphery, is critical in providing excellent eye care. There is now new imaging technology and diagnostic lenses to aid in the evaluation and diagnosis of retinal diseases better than ever before. Although photography is an excellent screening technique, dilation with funduscopic examination is still required to manage retinal disorders adequately. Here is an overview of tips and pearls for evaluating the peripheral retina.

Where Am I in the Periphery?

Prior to diving into the peripheral retinal, it's crucial to become familiar with its landmarks and unique vascular supply. The posterior pole is made up of the optic nerve head, macula and vascular arcades. The retina is supplied by both the central retinal artery and

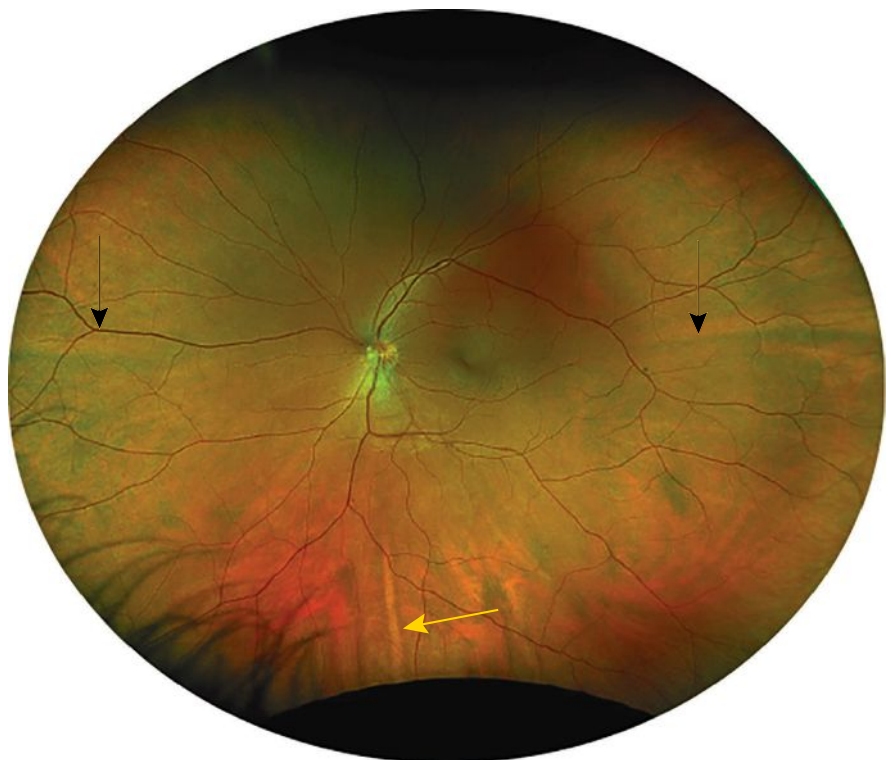


Fig. 1. Black arrows mark the long posterior ciliary nerves; the yellow arrow marks the short posterior ciliary nerve.

choroidal blood vessels, with roughly 20% to 30% of the retina flowing through the central retinal artery from

the optic nerve head and nourishing the inner retinal layers as it splits into four main branches.¹

About the authors

Dr. Njeru is a staff optometrist at the Chillicothe VA Medical Center. He graduated from Ohio State University College of Optometry and completed his ocular disease residency at the Chillicothe and Columbus VA. He is a fellow of the American Academy of Optometry. **Dr. Miller** is also a staff optometrist at the Chillicothe VA Medical Center. She graduated from Ohio State University College of Optometry and completed her ocular disease residency at the Chillicothe and Columbus VA. They have no financial interests to disclose.

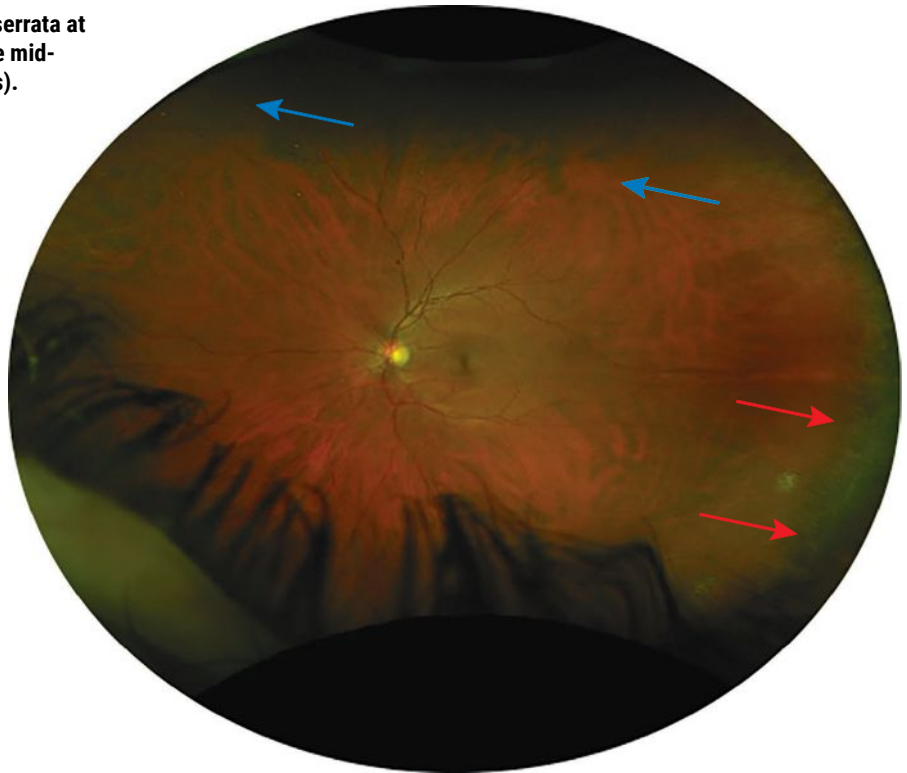
Fig. 2. This Optos photo shows an area of ora serrata at temporal retina (marked by red arrows) and the mid-peripheral vortex veins (marked by blue arrows).

The choroid, conversely, supplies roughly 65% to 85% of ocular blood flow and maintains the blood supply for the outer retina, which is vital in providing nutrients to photoreceptors.¹ Additionally, the arterial intraretinal branches supply the three capillary networks of the retina: the radial peripapillary and the inner and outer layers, which are most dense in the posterior pole and decrease in density as the supply becomes more peripheral. This is paramount when trying to better understand vascular retinal diseases. For instance, diabetic retinopathy is more likely to be found in the posterior pole because of microvascular complications that affect the capillary network.

The midperipheral retina extends from the vascular arcades to the posterior edge of the vortex vein and ampulla. These latter structures (the vortex veins and ampulla), which are found in the oblique quadrants of the retina, serve as excellent identifiers between the midperiphery and periphery.²

These veins drain the blood supply from the posterior ciliary arteries and penetrate the sclera to merge into the central retinal vein. You might also observe the long posterior ciliary nerves in the temporal and nasal aspects of the midperiphery, which appear yellow in color.² They can be used as a horizontal divider between the superior and inferior retina. The short posterior ciliary nerves located directly superior and inferior can act as a vertical divider, as seen in *Figure 1*.²

The far periphery is defined as the anterior edge of the vortex vein and ampulla and beyond to the pars plana. The ora serrata, seen in *Figure 2*, comes into view when you approach the peripheral retina. This structure is made up of dentate processes (retina) and bays (pars plana), which act as the serrated junction between the retina and the ciliary body.² The



dentate processes will appear as white or iridescent spikes, whereas ora bays appear as darker-colored scallops. The strongest connection of the vitreous to the retina is the overlying vitreous base, which extends anteriorly and posteriorly to the ora serrata. This 3mm-to-6mm wide region crossing the ora might be more noticeable in people with darker fundi.²

What Techniques Do I Use?

There are a couple of options to choose from.

Binocular indirect ophthalmoscopy (BIO). When performing a peripheral retinal exam, BIO offers a larger field of view than slit lamp biomicroscopy. The retinal images are upside down and reversed during BIO, and this is true for slit lamp funduscopy as well.

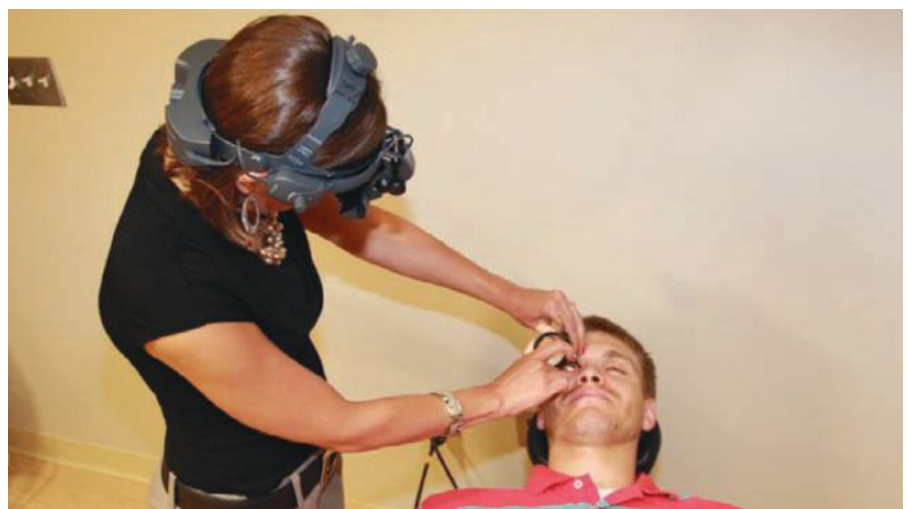

Fig. 3. An example of a provider who has positioned themselves below a reclined patient while performing BIO to observe the superior retina.³

Photo: Amy Dinaro, OD, MBA, and Philip Walling, OD

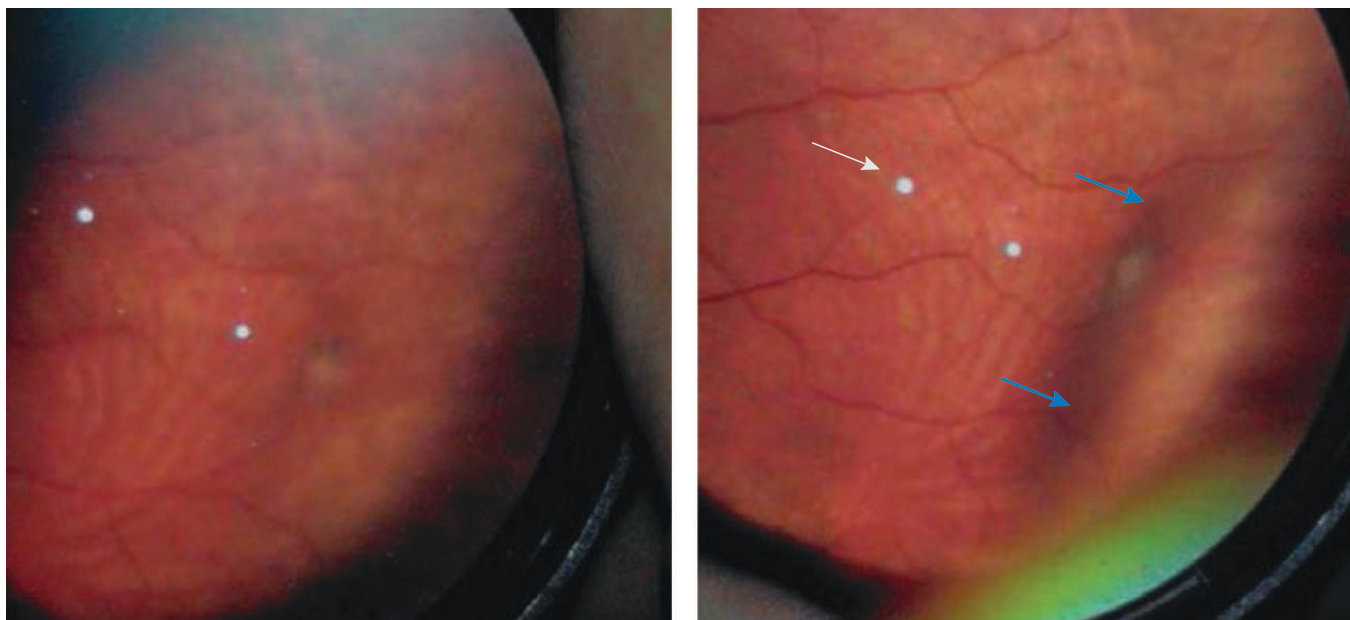


Photo: Amy Dinardo, OD, MBA, and Phillip Walling, OD

Fig. 4. This is a BIO view of a vitreal tuft. On the right is an indentation from applying a scleral depressor (marked by blue arrows) to improve the detail seen of the abnormality.³ The white dots (marked by white arrow) in both photos are lens artifact.

The alignment of the optical seeing system, which consists of the patient's retina, the instrument, the examiner and the condensing lens, is essential in obtaining good BIO views. Examiners need to verify that the pupillary

distance on the headset is accurate and can be changed as necessary. This will aid in achieving binocularity, allowing the examiner to view the retina with stereopsis, a vital part to assess pathology for characteristics such as elevation.

A patient with completely dilated pupils would benefit from the BIO's largest light aperture, which can be reduced in patients with smaller pupils to minimize glare. There are a variety of condensing lenses ranging from +14D to +30D that can be used, with the field of view getting smaller as the magnification increases. The most commonly used condensing lens during routine eye exams is the 20D lens since it offers a good balance between magnification and field of view.

When examining the far periphery, a +28D or +30D lens allows for a wider field of view, making the ora serrata easier to see. These lenses may be helpful in examining patients with smaller pupils or media opacities. These lenses require a different working distance, thus the examiner needs to hold them further away because of the lower magnification. Other lenses like the digital series can also be used to obtain views with higher resolution. Smaller spot sizes are also advantageous when examining patients with small pupils or who do not dilate well.

One of the advantages of BIO is its dynamic nature, which allows you to move and adapt your positioning based on the patient. The individual may lie down, sit up straight or be at



Photo: Jay M. Haynie, OD

Fig. 5. Different types of scleral depressors, including a cotton-tipped applicator, a flat double-ended depressor and thimble depressors.⁴

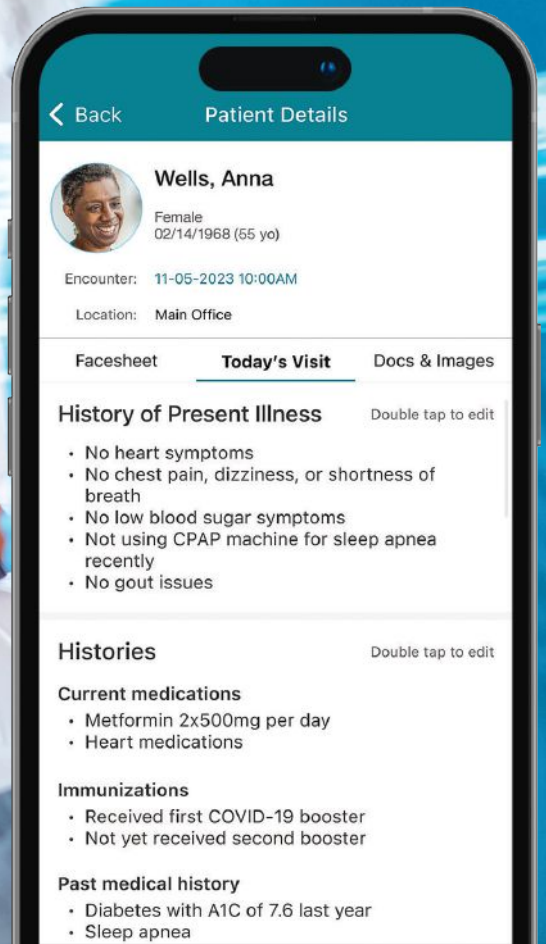
NextGen® Ambient Assist *is the greatest improvement in technology since X-rays went digital.*

Chris Wixon, MD, Cardiovascular | Savannah Vascular Institute

Integrated ambient listening technology securely converts the natural patient-provider conversation into a structured note that can quickly be reviewed and sent into the patient's chart—all in seconds.

Schedule a Demo

Call us at 855-346-1528
or visit nextgen.com/ambient



The product images shown are for illustration purposes only. The actual product may vary.

© 2024 NXGN Management, LLC. All Rights Reserved. NextGen is a registered trademark of NXGN Management, LLC. All other names and marks are the property of their respective owners.

an angle during BIO. When a patient is reclining in the examination chair, it may be simpler to face the opposite direction of the patient's gaze when positioning yourself. For example, when viewing the superior retina, the examiner should place themselves below the patient's head when they are looking up, as depicted in *Figure 3*.

Recall that as patients look off into extreme gazes, the condensing lens may not always fill completely when trying to view the far periphery. To further improve peripheral views, an examiner can instruct the patient to tilt their head slightly towards them while the patient still maintains the directed gaze. For patients who have difficulty looking where you tell them to, especially those who are in a reclining position, have them extend an arm into the field of gaze you wish to examine and instruct them to look at their hand.

Scleral depression. There are certain disease states as well as symptomatology that require adjunct testing in addition to BIO. The peripheral retina can be best visualized by using scleral depression, a technique used in *Figure 4*. Like other examination techniques, it is important to practice more and more to attain good views. For scleral depression, a proper dilation is done with use of 2.5% phenylephrine and 1% tropicamide. Then, wait until maximal dilation is achieved. Additionally, topical anesthetic may be used to make patients more comfortable.

There are several different types of scleral depressors available on the market, ranging from thimble depressors to single- or double-pointed, straight or

curved depressors as seen in *Figure 5*. Although they are convenient, cotton-tipped applicators might increase the complexity of a dynamic exam as you move circumferentially around the eye to obtain peripheral views.

Scleral depression can be performed while the patient is supine or upright and depends on the physician's comfort level. First, apply your scleral depressor to the eyelid at roughly 5mm to 8mm behind the limbus while the patient looks in the opposite direction from the area being examined.³ Next, slowly guide the patient's gaze in the desired direction while gently applying pressure so that the scleral depressor follows along the lid in a perpendicular fashion. If the depressor is pressing into a muscle insertion or perpendicular to the eye, the patient will start to feel uncomfortable. When aligned properly, the examiner should watch the red reflex of the pupil and look for a small shadow or area of darkening, as this indicates the depressor is in the right location.³

Then, move your condensing lens into view. There will be a

bump indicative of successful alignment. For cases when it is difficult to find the bump, consider moving the scleral depressor away from the limbus and asking your patient to look slightly off axis rather than in extreme gazes; this might improve view of the retina and make it simpler to locate the bump. Some clinicians describe the bump as appearing like a "mouse under a blanket," especially as one moves the depressor.

The easiest views to obtain with scleral depression are those of the superior and inferior retina. As for the nasal and temporal views, there are different ways to obtain these, such as using a topical anesthetic, then directly depressing onto the globe. Another method involves using the depressor to move the eyelid into the nasal and temporal aspects of the globe. This dynamic technique allows for evaluation at both three o'clock and nine o'clock without direct contact to the globe.

Scleral depression is indicated when examining patients who have




Fig. 6. The A mirror (semi-circle) allows views of the peripheral retina and anterior chamber angle. The B mirror (rectangle) allows views between midperiphery and the periphery. The C mirror (trapezoid) allows for views of the midperiphery. Remember that the view in these mirrors is 180° away. Therefore, if you want to view a hole at six o'clock in the periphery, you would place the trapezoid mirror (mirror B) at 12 o'clock. The central (D) mirror of the three-mirror lens can also be used to get a direct (not indirect) view of the posterior pole and is useful for detailed examination of the macula and optic nerve head.

Look for choroidal hypertransmission, a marker of Geographic Atrophy (GA) on OCT^{1*}

- While BCVA is poorly correlated to lesion size, visual function continues to decline as lesions grow^{2,3}
- It is critical to recognize GA and refer patients in a timely manner, as disease progression is relentless and irreversible^{1,3-7}

Learn more about identifying GA
at [RecognizeAndReferGA.com](https://www.recognizeandreferga.com)



**RECOGNIZE
AND REFER**

*GA is defined by atrophic lesions, resulting from loss of photoreceptors, RPE, and underlying choriocapillaris. This results in a choroidal hypertransmission defect on OCT.^{1,8,9}
BCVA=best-corrected visual acuity; OCT=optical coherence tomography; RPE=retinal pigment epithelium.

References: 1. Fleckenstein M, Mitchell P, Freund KB, et al. The progression of geographic atrophy secondary to age-related macular degeneration. *Ophthalmology*. 2018;125(3):369-390. doi:10.1016/j.ophtha.2017.08.038. 2. Heier JS, Pieramici D, Chakravarthy U, et al. Visual function decline resulting from geographic atrophy: results from the chroma and spectri phase 3 trials. *Ophthalmol Retina*. 2020;4(7):673-688. doi:10.1016/j.oret.2020.01.019. 3. Sunness JS, Margalit E, Sirkumaran D, et al. The long-term natural history of geographic atrophy from age-related macular degeneration: enlargement of atrophy and implications for interventional clinical trials. *Ophthalmology*. 2007;114(2):271-277. 4. Boyer DS, Schmidt-Erfurth U, van Lookeren Campagne M, Henry EC, Brittain C. The pathophysiology of geographic atrophy secondary to age-related macular degeneration and the complement pathway as a therapeutic target. *Retina*. 2017;37(5):819-835. doi:10.1097/iae.0000000000001392. 5. American Optometric Association. AOA Comprehensive adult eye and vision examination. *Quick Reference Guide: Evidence-Based Clinical Practice Guideline*. 1st ed. Accessed July 13, 2023. https://www.aoa.org/documents/EBO/Comprehensive_Adult_Eye_and_Vision_%20QRG.pdf. 6. Holz FG, Strauss EC, Schmitz-Valckenberg S, van Lookeren Campagne M. Geographic atrophy: clinical features and potential therapeutic approaches. *Ophthalmology*. 2014;121(5):1079-1091. doi:10.1016/j.ophtha.2013.11.023. 7. Lindblad AS, Lloyd PC, Clemons TE, et al; Age-Related Eye Disease Study Research Group. Change in area of geographic atrophy in the age-related eye disease study: AREDS report number 26. *Arch Ophthalmol*. 2009;127(9):1168-1174. doi:10.1001/archophthalmol.2009.198. 8. van Lookeren Campagne M, LeCouter J, Yaspan BL, Ye W. Mechanisms of age-related macular degeneration and therapeutic opportunities. *J Pathol*. 2014;232(2):151-164. doi:10.1002/path.4266. 9. Chakravarthy U, Bailey CC, Scanlon PH, et al. Progression from early/intermediate to advanced forms of age-related macular degeneration in a large UK cohort: rates and risk factors. *Ophthalmol Retina*. 2020;4(7):662-672.

Apellis

The APPELLIS® name and logo is a registered trademark of Apellis Pharmaceuticals, Inc.
©2023 Apellis Pharmaceuticals, Inc. 8/23 US-GA-2300089 v1.0

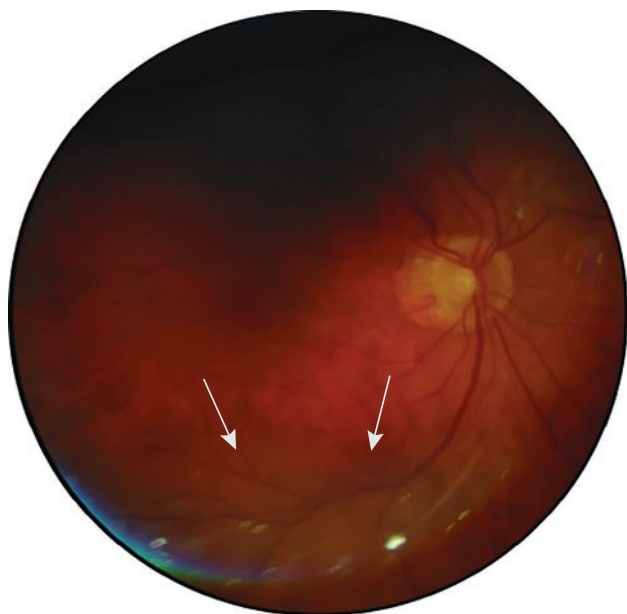


Fig. 7. A traditional fundus photo capturing an elevated area within the inferior retina of the posterior pole in the right eye (marked by white arrows).

symptoms or history of peripheral retinal disorders, such as a retinal break, retinal detachment, lattice degeneration, vitreoretinal adhesions, photopsia and/or sudden increase in floaters. However, it is contraindicated in those with hyphema, penetrating globe injuries or history of recent ocular surgery. Caution should be given to those with glaucoma or ocular hypertension, as scleral depression will temporarily increase intraocular pressure.

Slit Lamp Biomicroscopy and Contact/Non-Contact Lenses

A slit lamp examination can offer a higher magnification and higher quality image of the peripheral retina. There are numerous options for both contact and non-contact lenses to view the peripheral retina, with each possessing a different field of view, magnification and potential uses.

The different condensing lenses can be either high magnification or wide-angle lenses and typically have a double aspheric design to aid in improving depth of field and reducing peripheral image distortion.⁵ The dynamic field of vision is observed with a 15° tilt to either side of the optical axis, whereas

the static field of view is the maximum view that can be seen without tilting the lens.⁵ When looking at the peripheral retina behind the slit lamp, the following non-contact lenses make good choices.

- **90D lens.** One of the most common lenses used at the slit lamp is the 90D. Its 89° field of view and 0.76x magnification make it suitable for dynamic examinations, especially since it has a smaller diameter ring.⁵

- **Digital Widefield lens.** This type features improved stereopsis and less chromatic aberrations, thanks to its sophisticated optical lens design. In addition to improving optical clarity, it features antireflective coatings that can cut reflections and glare by up to 50% more than conventional coatings. It has a greater dynamic field of view at 124° and a magnification of 0.72x. This field of view is roughly 40% wider than the 90D.⁵

- **SuperField lens.** Also referred to as the Super 90D, this lens offers a detailed picture of the mid-periphery and even reaches the ora serrata. It has a magnification of 0.76x with a dynamic field of view of 116°, or 30% wider than a 90D lens.⁵

- **Super Vitreo-Fundus lens.** This is a different widefield imaging lens and is perfect for checking the peripheral retina for retinal breaks or detachment because of its 0.57x lower magni-

fication, shorter working distance and 124° dynamic field of view.⁵

A three-mirror gonioscopy lens is a contact lens that adheres to the front surface of the eye, consisting of three mirrors and a central lens. It allows examiners to view multiple areas of the retina, as shown in *Figure 6*. It is necessary to anesthetize the eye and use a coupling solution like Celluvisc (carboxymethylcellulose sodium 1%, Allergan) on the inner surface of the lens before applying it to the cornea to ensure good comfort for the patient. When examining the posterior pole, the central lens has a 1.08x magnification and a 36° view of the retina.⁵ The trapezoid mirror (mirror C) is the largest and gives views of the midperiphery. The smaller rectangular mirror (mirror B) is used to view between the midperiphery and the periphery, and the semicircular mirror (mirror A) is the smallest and allows views of the far periphery, but is primarily used to obtain high quality views of the anterior chamber angle and its structures.

Widefield and Ultra-Widefield Imaging

When monitoring ocular disorders such as diabetic retinopathy, maculopathies and other retinal

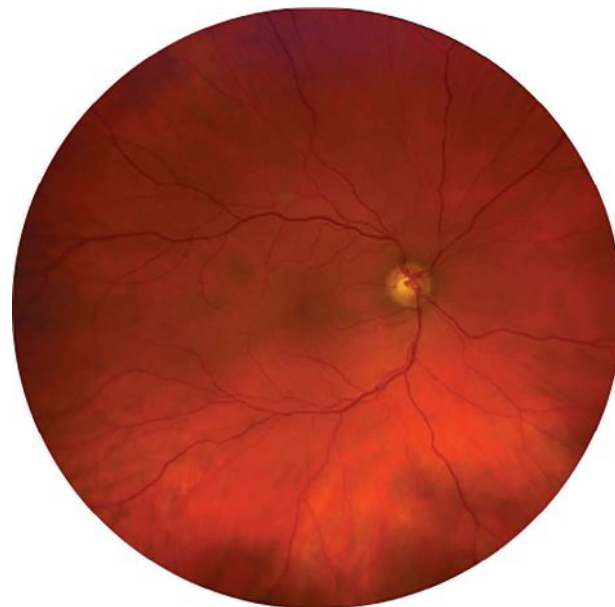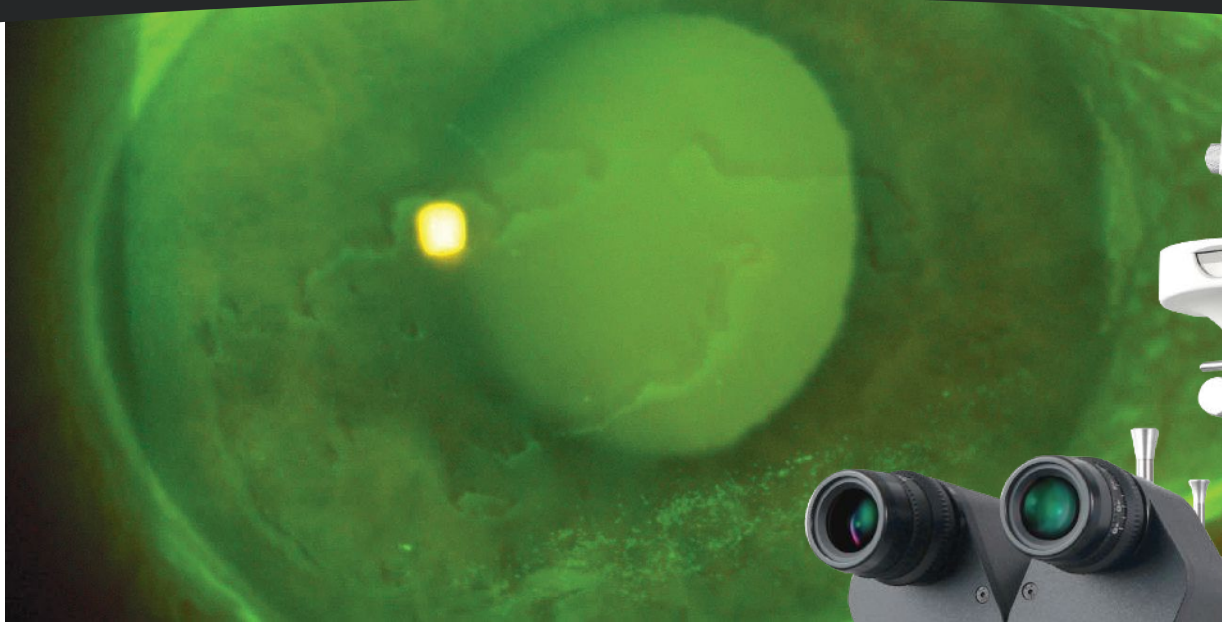


Fig. 8. A normal Clarus photo showing a larger field of view than traditional fundus photography.

The Anterior Segment Virtuoso

Firefly®

SECO 1655
VEE F2753



Nothing performs better in the anterior chamber than the Firefly® Imaging System. Using wavelengths similar to natural light, it delineates eye anatomy with an optical resolution of 200 lp/mm.

The standard Firefly comes fully loaded with video capture, automatic exposure, artificial intelligence, meibography, and a Wratten yellow filter. Optional Dry Eye Diagnostic module.

See Firefly's online image gallery, and we're sure you'll applaud the performance. Visit eyefficient.com



FIREFLY'S ONLINE GALLERY



EYEFFICIENTSM

© 2023 EYEFFICIENT, ALL RIGHTS RESERVED

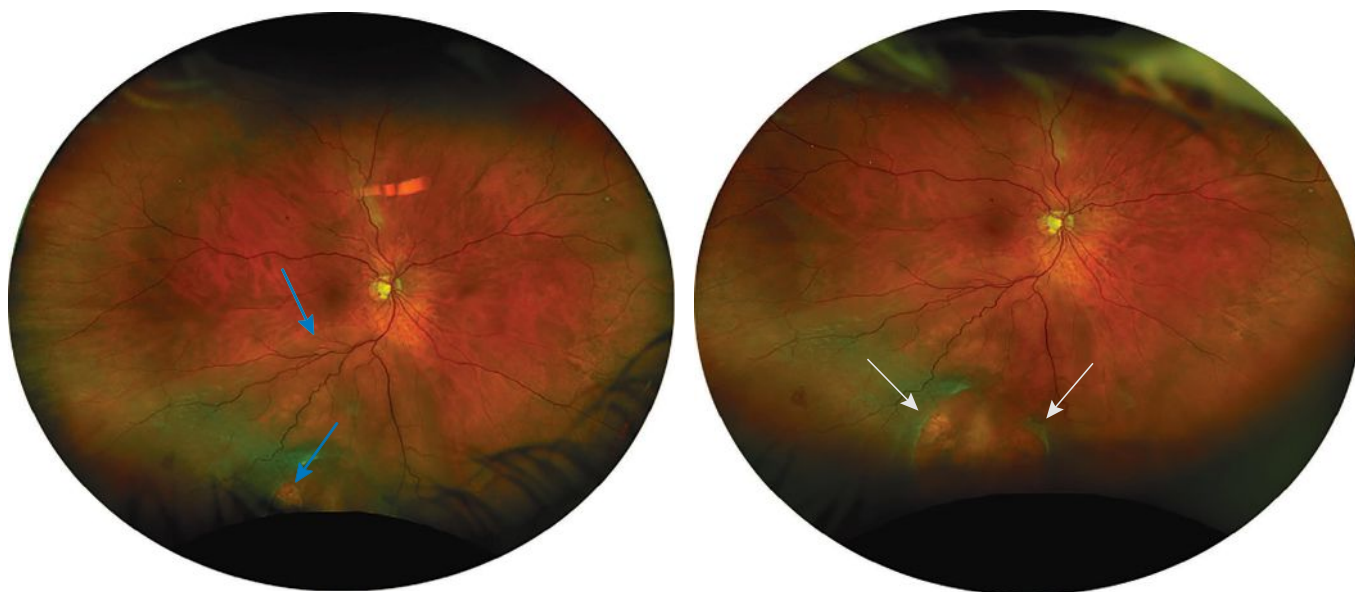


Fig. 9. This Optos photo captures a retinal detachment that could not be fully seen in Figure 7. The left photo was captured in primary gaze and shows an inferior retinal detachment with at least one retinal break (marked by blue arrows). The right photo was captured with inferior steering and shows two large retinal breaks (marked by white arrows) that could not be fully seen in primary gaze.

conditions, fundus photography has widely been adopted by eyecare providers. A valuable yet incomplete picture of the retina and optic nerve can be obtained using traditional fundus photography, which covers just 30° to 50° of the retina, as seen in *Figure 7*.⁶ As a result, widefield and ultra-widefield imaging have gained popularity as testing techniques, particularly for patients who decline dilation or those in which dilation is contraindicated, such as narrow angles due to risk of angle closure.

At this time, widefield fundus imaging devices are defined as those capable of capturing a field of view between 60° to 100°, covering the retina extending from the vascular arcades to the posterior edge of the vortex vein ampulla, or the midperiphery.⁶ Ultra-widefield imaging devices, by contrast, differ by being defined as having a field of view between 110° to 220° and the ability to capture the anterior edge of the vortex vein ampulla to the pars plana, or the far periphery.⁶

Up to 133° of the retina can be captured with the Clarus ultra-widefield imaging system, seen in *Figure 8*.⁶ It proves true color imaging while using a partially confocal optics function to

reduce artifact from lids and lashes. It additionally features a montage tool to aid in further piecing together peripheral findings. In contrast, the Optos can capture up to 200° of the retina using an ellipsoid microscope and confocal scanning laser, seen in *Figure 9*.⁶ If the montage feature is used by steering, it increases view of the retina up to 220°. Note that lash artifact, peripheral distortion and pseudo-coloring are common disadvantages to using Optos. No matter which system is used, one must take care to clean the mirror during the day to remove dust, which can cause artifacts.

Clinicians can now precisely document and clearly educate patients on ocular diseases like retinal holes or tears, retinal detachments, peripheral hemorrhages and more by using widefield or ultra-widefield imaging.

Takeaways

There are many imaging modalities to optimize peripheral retinal exams. Although widefield and ultra-widefield imaging is easier and more convenient for patients, clinicians should still advise patients on the importance of dilation for their ocular health. This is essential to make sure that retinal

conditions like holes, tears, peripheral disease or detachments have not been missed by imaging due to artifact. Additionally, using steering to make the patient look into extreme fields of gaze to view the periphery when using widefield imaging will capture more retinal views. Techniques such as scleral depression, BIO and three-mirror gonioscopy are essential to view the periphery and should be practiced routinely to feel more comfortable performing them on patients. Doing so will ensure that clinicians may better diagnosis and monitor conditions within the periphery. ■

1. Kolb H. Simple anatomy of the retina. In: The organization of the retina and visual system. Salt Lake City (UT): University of Utah Health Sciences Center. Last updated January 31, 2012.
2. Rafeetary M. Navigating the retinal periphery. *Rev Optom.* 2021;158(2):58-68.
3. Dinardo A, Walling P. The lost arts of optometry, part one: a refresher on scleral depression. *Rev Optom.* 2013;150(8):44-50.
4. Haynie JM. Can we pre-empt damage from retinal detachment? *Rev Optom.* 2020;157(9):72-77.
5. Gupta A, Singh P, Tripathy K. Auxiliary lenses for slit-lamp examination of the retina. In: StatPearls. Treasure Island (FL): StatPearls Publishing. Last updated August 25, 2023.
6. Patel SN, Shi A, Wibbelsman TD, Klufas MA. Ultra-widefield retinal imaging: an update on recent advances. *Ther Adv Ophthalmol.* 2020;12:2515841419899495.

Driving Innovation,
Defining Excellence:

LEADING THE MARKETPLACE FORWARD

We take pride in our longstanding commitment to excellence in readership, reach and influence in the vision care field with our print, digital and multi-platform (print/digital/virtual & live) education offerings. Our signature brands deliver a powerful and impactful marketing mix of print and digital marketing opportunities.

Jobson Optical Group brands are readers' most trusted source for news, product information, education, industry trends, research & surveying ECP's, business strategy and practice management insight.

For more information about products, services, and subscriptions, contact us at info@jobson.com

Jobson
Optical Group

The vision to help you succeed

20/20

WO
WOMEN IN OPTOMETRY®

REVIEW
of OPHTHALMOLOGY

Frames
Data®

LT

Jobson OPTICAL
RESEARCH

RCCL®
REVIEW OF CORNEA
& CONTACT LENSES

my frame
GALLERY
by Frames Data

20/20
PRO TO PRO

Review
of MYOPIA
MANAGEMENT

REVIEW
of OPTOMETRY

EyeRep®

Jobson
INTERACTIVE

VM
VISION MONDAY

Jobson
creative

REVIEW
Education GROUP

VM LEADERSHIP
SUMMIT

RETINA®
SPECIALIST

Review
of Optometric
Business

Jobson
Event Services

VMAIL

REVIEW
of PRESBYOPIA
and the Aging Eye

U.S. Pharmacist
The Pharmacist's Resource for Clinical Excellence

GET A HANDLE ON HEAD-MOUNTED PERIMETRY

Learn how this option stacks up against the tried-and-true methods and how well you can integrate it into your practice.



MARCIA HOEPF, OD,
AND MICHAEL CHAGLASIAN, OD
COLUMBUS, OH; CHICAGO, IL

Head-mounted perimetry is a rapidly expanding new modality for testing the visual field (VF). These small, portable, video-based devices that are worn by patients are looking to update and transform this workhorse diagnostic test. The traditional bowl-based devices that have been the primary method for more than four decades have several size and ergonomic limitations that hinder their use in many practice settings and with certain patients who physically can't place their head into the device.

A head-mounted device is light enough to wear and can be brought into the exam room, potentially allowing more patients to complete the exam. In addition, the efficiencies of a shorter test time, if realized, could be a great advantage in today's busy practices. In many models, other diagnostic tests (e.g., color vision, contrast sensitivity) may also be added into the device as it runs on its own, freeing up time the staff or doctor may

not need to spend with the patient directly.

In the last several years, perhaps a dozen different models have been introduced. The marketplace is changing so rapidly that it's difficult to keep track of what's in and what's out. Perimeters are designated as a Class 1 medical devices, which pose the lowest risk, and thus are exempted from the formal premarket notification application and FDA clearance process (an OCT imaging device requires this clearance). The devices are registered by the FDA. This "low bar" of entry, along with a need for more patient- and practice-friendly visual field devices has helped spur the large number of companies (including many new start-ups) to get in the game. However, it calls into question the accuracy, sensitivity and specificity of the new head-mounted devices as there are only a small number of published articles in this area—and certainly not a refereed publication for each commercially available device.

Optometrists should be aware of certain limitations, along with the potential advantages, prior to making a

purchase for their practice. Let's take a closer look at the key issues for head-mounted perimetry devices.

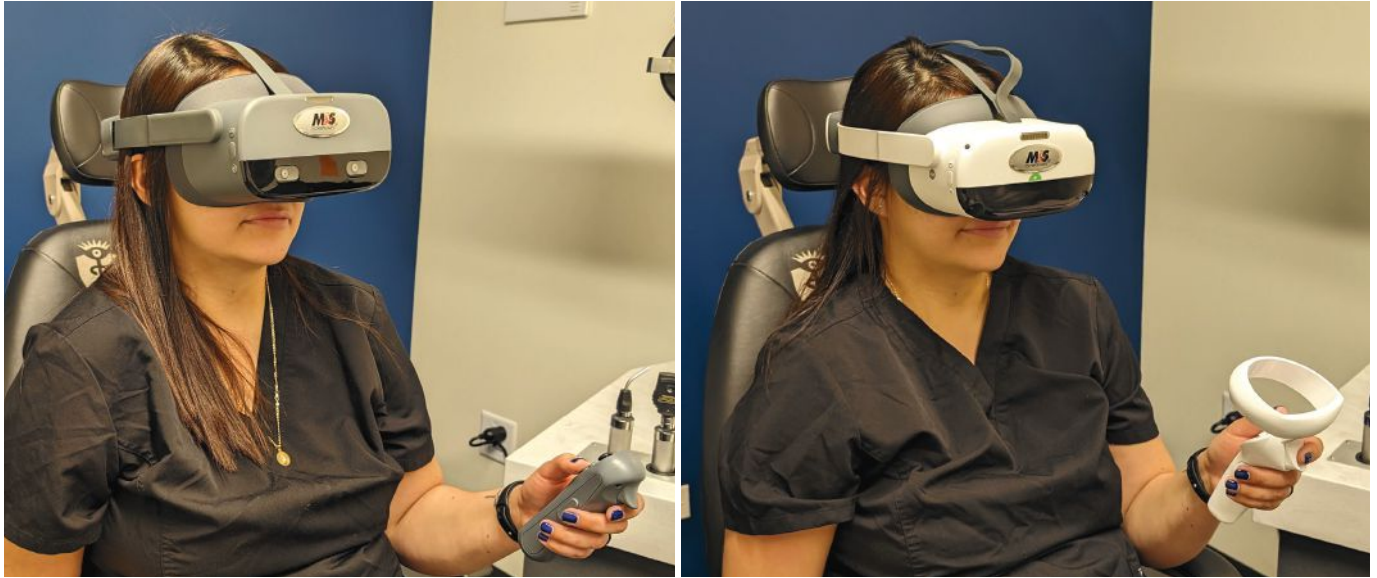Features

The current head-mounted devices (HMDs) available on the market are lightweight, ranging from 6oz to 12oz. Their ergonomic design helps improve patient comfort by not requiring them to remain in one position throughout the entire test. They also do not require the use of an eye patch as most of the virtual reality (VR) testing protocols offer simultaneous viewing while stimulating each eye individually. Allowing the patient to keep both eyes open throughout the test is typically more comfortable for the patient vs. wearing a patch. Standard Humphrey VF has a testing distance of 30cm, thus requiring trial lenses. VR allows for test stimuli to be placed at a distance of infinity, which also means the patient can wear their own habitual glasses or a custom-designed trial lens built into the headpiece, thus, eliminating a common artifact seen with standard automated perimetry.

Most of the commercially available head-mounted perimetry devices

About the authors

Dr. Hoepf is an assistant professor of clinical practice at Ohio State University, where she supervises optometry externs in the clinical setting at Columbus Ophthalmology Associates. She has no financial disclosures. **Dr. Chaglasian** is an associate professor at Illinois College of Optometry and chief of staff of the Illinois Eye Institute. He is also executive vice president of the Optometric Glaucoma Society. He has been a consultant to and/or received research funding from Bausch + Lomb, Carl Zeiss Meditec, Topcon and Optos.



The M&S Smart System VR Headset during live testing. The latest version of the device is on the right.

offer the common testing grid patterns (24-2, 30-2 and 10-2) while some even include kinetic, full-field 120 and screening methods for ptosis evaluation. Testing protocols use a Goldmann size III test stimuli under mesopic testing conditions, where a white stimulus is shown against a gray or black background. The average test time slightly differs among each device while several are shorter than standard bowl perimetry.¹⁻²

Note that there is not enough published information at this time to assess the test duration for all testing strategies on all devices. The reader is advised to investigate this carefully for each headset.

One feature that accounts for shorter test times and improved reliability of VR testing is enhanced eye tracking and monitoring capabilities. The re:Vive (Heru) platform uses an active eye tracking system via an infrared camera that will prompt the patient to regain fixation by wiggling the target if fixation is lost.³ Other platforms will pause the test when fixation is lost until the patient realigns to the target. Vivid Vision Perimetry (VVP), a VF platform designed to operate on commercially available VR headsets without a dedicated set of goggles,

uses oculokinetic perimetry, where the target stimulus is dynamic and changes location from trial to trial, while the patient responds by moving their head to line up their fixation with the target.⁴ VR is ideally suited for these features, and some devices even include continuous monitoring during the test with AI support.

Finding a way to make VF testing more interactive while allowing patient freedom to move their head, and eyes in some cases, is a clear benefit for the patient experience as well as the physician who receives more reliable and valid reports to interpret.⁵⁻⁶ The

use of video instruction and monitoring eliminates the need for a technician to run the test and can improve overall clinical efficiency. Using this platform can open the possibility for other tests to be incorporated into the device. Many have already adopted other testing protocols, such as visual acuities, color vision, contrast sensitivity and extraocular motility testing, which can further increase productivity in the clinic.

The hardware for many of the current generation of headset perimeters is built around a popular VR gaming headset that is commercially available

Advantages of Head-Mounted Perimetry

- 1. Improved patient comfort.** These devices can provide a more comfortable testing experience for patients compared with traditional perimetry machines.
- 2. Increased accessibility.** Portable head-mounted perimetry devices may offer increased accessibility, allowing for VF testing in various settings, including remote or underserved areas.
- 3. Real-time data and analytics.** Some head-mounted perimetry devices can provide real-time data and analytics, enabling healthcare professionals to monitor and analyze visual field changes more efficiently.
- 4. Customized testing.** Head-mounted perimetry devices may allow for more customized and targeted visual field testing, tailoring the assessment to specific patient needs or conditions.
- 5. Patient engagement.** The use of modern technology, such as head-mounted perimetry, may enhance patient engagement in the testing process, potentially leading to more accurate results.

for modification (Pico Immersive). Despite having a common piece of integral hardware, the programming and software variances between HMDs can be significant.

Of course, these hardware and software differences lead to questions about their similarity to the standard Humphrey Field Analyzer (HFA) bowl tests. Headset device companies have taken a variety of approaches to validating their devices. While companies may have some limited documentation of internal studies, most of this work has not been published (this is not an FDA requirement for VF testing devices).

From our review of the currently available publications, it is difficult to draw any clear conclusions regarding the sensitivity and specificity of these devices as compared with a traditional

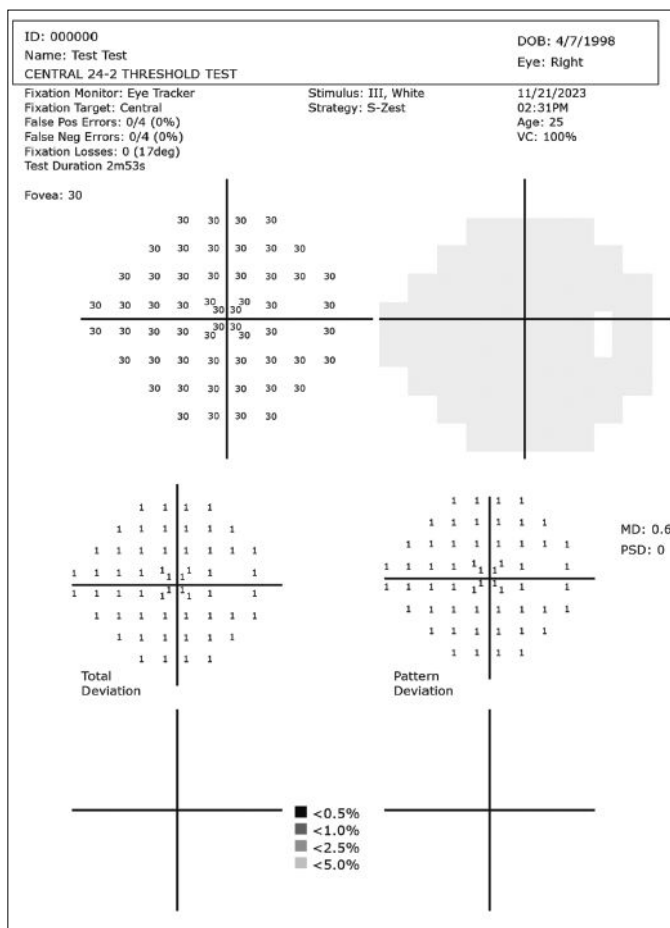
bowl perimeter.⁷⁻⁸ This is not to say that head-mounted perimetry units don't work at all; they clearly do. We've used several of them in our clinics over the past year. The HMDs do indeed identify field defects on our glaucoma patients; however, they vary significantly in size, shape and location of the defect vs. our HFA3 device, leaving us in a quandary as to as which results are most accurate: the new shorter test that many patients seem to prefer or the gold standard device with 40 years of research and validation?

Each of the head-mounted perimetry devices offers cloud-based storage, are DICOM compatible and can be integrated into many practice EMR systems. The Radius, VF2000 and Vivid perimetry can be performed offline. This allows mobile testing

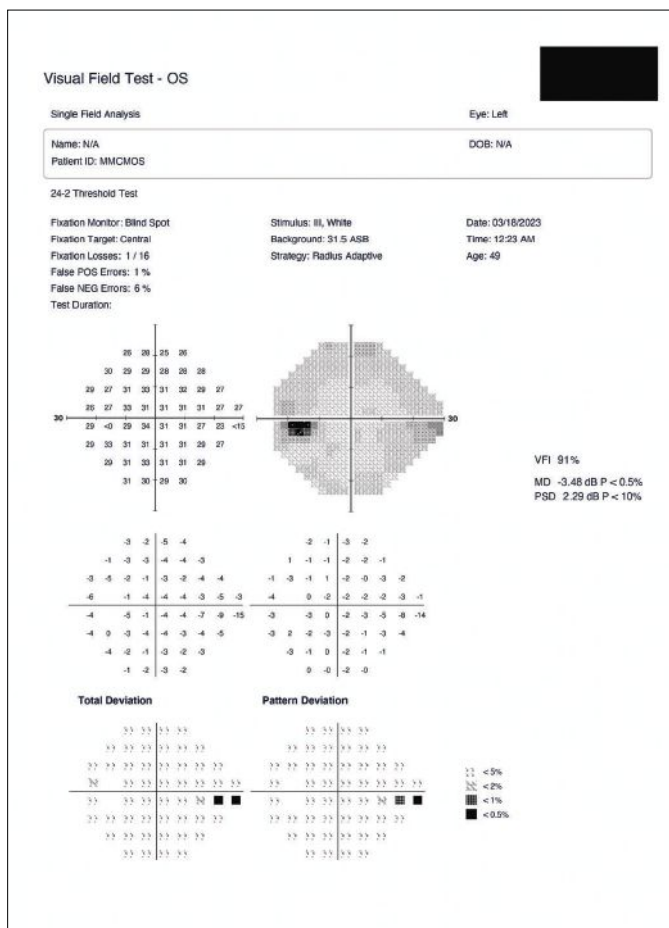
opportunities such as nursing homes, hospitals and home-based perimetry. All the data is saved locally then synced with the cloud once Wi-Fi becomes available. The report generated by each device is familiar to the practitioner and features all the traditional analysis seen on HFA perimetry printouts. These include a VF greyscale plot, mean deviation, total deviation, pattern deviation and reliability indices composed of false positives, false negatives and fixation losses.

Optimal Situations

Wearable HMDs have been shown to improve patient experience and comfort while increasing clinical efficiency, but how does this fit into your practice today?^{5,6} We can certainly see the advantage this might offer



Healthy right eye visual field example for reference. These test results are from an unaffected 26-year-old using an HMD. Testing time was 2m 53s.




Head-mounted device example with early glaucoma defect. This was a 49-year-old glaucoma patient with an inferior nasal step in the left eye as detected by the HMD.

Smart System® | VR Headset

Developed by the industry leader
in vision testing for over 33 years

SECO 2024
Booth #1723



Technology You Know, Expertise You Can Trust

The programmable Smart System® VR Headset with Surface Pro Tablet provides a more efficient and comfortable approach to visual field tests, backed by over 33 years of experience developing computerized vision testing.



Test Anywhere

No internet connection needed to run the device. Smoothly set up and run visual field tests and then export the results to your EMR.



Get Reliable Results, Fast

M&S SMARTracker™ 2 technology continuously monitors patient fixation and pauses the test when fixation is lost. Full threshold test results in under 3 minutes per eye.



Enjoy Better Patient Compliance

A lightweight design and intuitive interface makes patients much more comfortable. Using familiar technology ensures the patient can complete all testing accurately.

Visual Field Color Vision Stereo Testing Contrast Sensitivity

Schedule a demo at:
mstech-eyes.com/vr-headset



M&S
TECHNOLOGIES®



847-763-0500
mstech-eyes.com

The First Choice in Vision Testing Systems
A HILCOVISION COMPANY

CE ©2024 M&S and Smart System are registered trademarks of the Hilsinger Company Parent LLC. All rights reserved. The Hilsinger Company Parent LLC holds US Patents 7,354,155; 7,926,948; 8,425,040; 8,167,429; 8,419,184; 8,550,631; 8,992,022; 9,433,347; 9,820,644; 10,244,938 and 10,182,713. Other Patents Pending.

Setting a New Tempo

The Tempo automated perimeter (Topcon Healthcare) is a new visual field device that bridges the gap between traditional standard automated perimetry (SAP) and wearable perimeters. An alternative to a virtual reality or head-mounted devices, this novel, non-bowl-based device maintains the technical capabilities of traditional perimetry devices.

It has the advantages of a modest tabletop instrument to ensure easy positioning of a patient's head during testing while allowing visual field tests to be conducted in ambient room lighting, eliminating the need for a dedicated dark room.

The Tempo perimeter uses ALZE, or Ambient Interactive ZEST (CREWT Medical Systems), a strategy that determines the sensitivity thresholds across the retina by using a basic algorithm of ZEST through interaction with immediate surrounding test points. As a result, it offers test performance equal to conventional standard automated perimetry while shortening measurement time.^{1,15-17}

This perimeter takes advantage of a binocular simultaneous strategy in which stimuli are randomly presented to one eye at a time under binocular viewing conditions. This approach not only removes the risk of Ganzfeld blackout, but it may also cut inter-eye setup and improve fixational stability. The theory that a binocular simultaneous strategy in visual field testing can reduce test duration corresponds to that of the Tempo reducing measurement time by 39% in comparison to the HFA SITA-Fast.¹⁷⁻¹⁹

Most perimetric devices today, including the Tempo and the HFA, use a standard background luminance of 10cd/m² (31.5 apostilbs) and a white-on-white setup of stimulus and background. This background luminance provides a low photopic adaptation that resides on the linear aspect of the Weber function; therefore, changes in pupil size or ocular media would not impact the patient's ability to detect the stimuli. Lower background luminance can produce an uneven adaptation state from one location to another in the visual field and even require too much dark adaptation time to be useful in clinical practice.

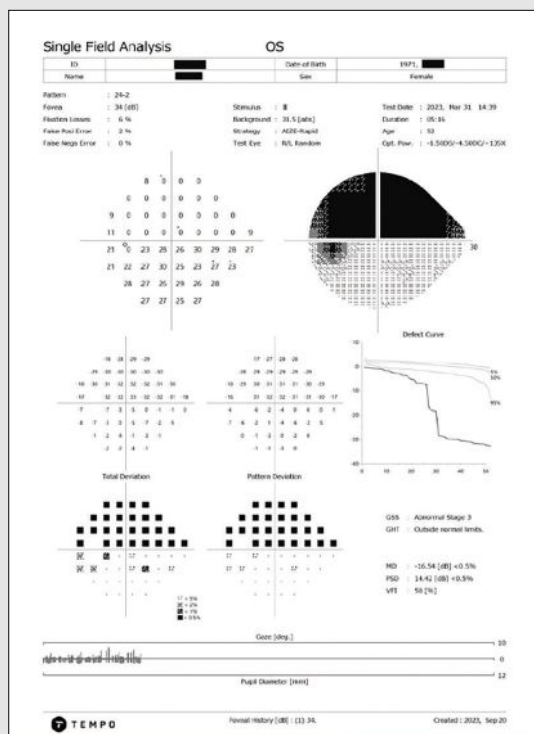


Photo: Topcon

A sample report from the Topcon Tempo.

in settings where use of standard perimetry would otherwise not be an option, such as bedridden, hospital-based or nursing home patients and those with physical limitations that prevent them from being in one position throughout the entirety of VF testing.

Practices who serve a high volume of pediatric patients could also benefit from such technology. There have been attempts to create game-based perimetry to make testing more appealing to this population. The VisuAll K VRP (Oleyes) is a pediatric video game-based static threshold perimeter that provides a format that is easy to perform and offers more reliability due to improved attention.⁹ A recent study was performed where a normative database was established and showed good correlation with HFA perimetry.⁹

One limitation in identifying glaucoma disease and progression in those

who speak non-English languages is the ability to many times conduct a reliable VF. The devices we have reviewed here all offer video instruction and continuous monitoring in multiple languages. Community health centers and practices who serve a diverse population could greatly benefit from this type of technology.

Although most studies report a high rate of patient acceptance of the HMD, sample sizes have been small and do not encompass a diverse range of the population. Wearable HMDs may be problematic for patients with head and neck injuries, those who suffer from claustrophobia or in age demographics reticent to accept advanced technology. Some patients may appreciate the progressive and innovative design, while others may be intimidated and overwhelmed, particularly the demographic where glaucoma is most prevalent. These are

times when you may still want to have access to standard perimetry.

One thing the COVID-19 pandemic showed us was the vulnerability we have to clinic-based medicine. Many health specialties use telemedicine to better serve patients, especially those in rural areas or those with limited access to health care. Eyecare providers rely heavily on office-based devices which makes it difficult to offer remote care to our patients. Head-mounted perimetry could allow for home-based testing of visual fields, which might allow access for these patients, free up clinical space, as well as improve our ability to track disease progression. In the future, home-based model testing (which the patient could rent) could be performed with increased frequency.

More frequent visual fields have been reported in the literature to be superior to biannual testing in detecting rapid progression.¹⁰⁻¹¹ Typically, it takes

three to four fields to overcome learning curves, which could be achieved more quickly with access to increased frequency of testing.¹²

Artificial intelligence has been used in many areas of medicine in recent years. Use of AI to analyze structural information (such as RNFL OCT) has been studied recently to aid in detection of disease progression. This same technology could be applied to perimetry, and the current platform for VR testing may open up opportunities for future integrations with other tests. The application of AI could aid in detection and monitoring of disease and may be the future of glaucoma care.¹³

Limitations

Some practical limitations of VR perimetry include: (1) questions of accuracy and reproducibility as compared with established testing standards, (2) limited field of view: often only central 30° can be tested, (3) adaptation and learning effects: not all patients will perform well with a HMD, and many of our older patients get disoriented with the device on their head.

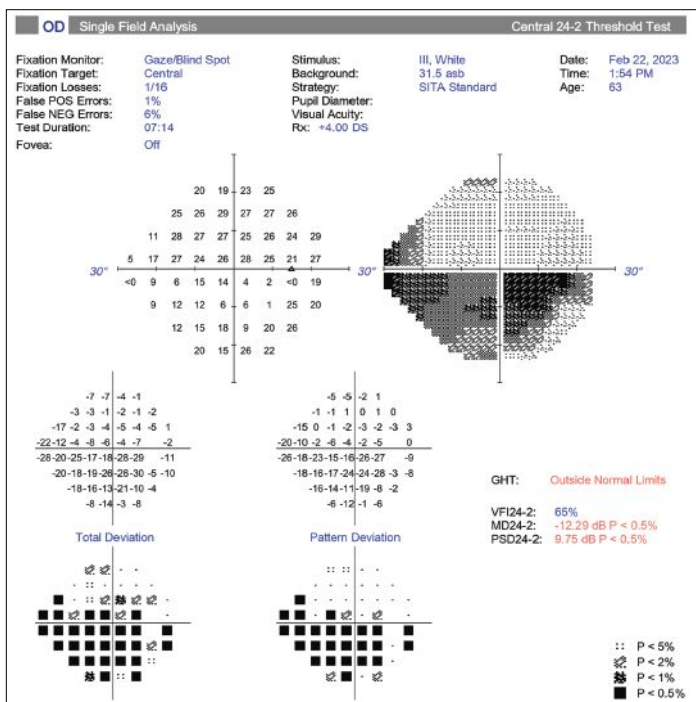
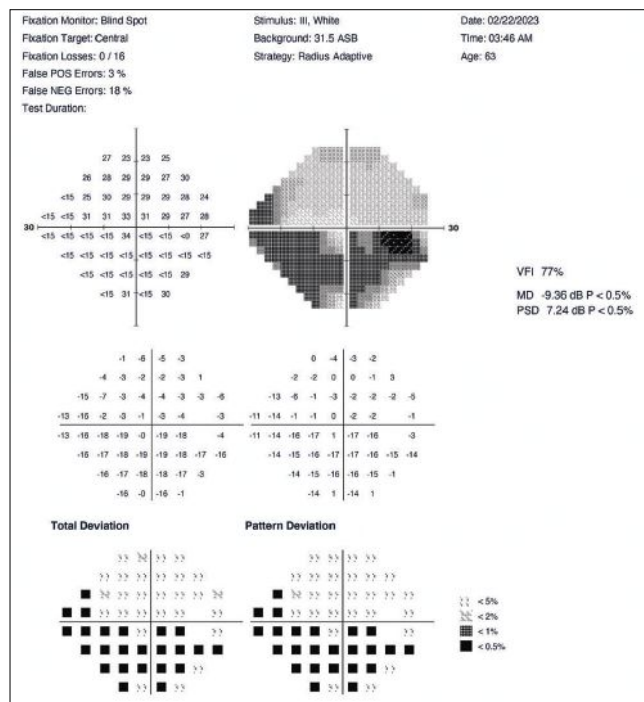
Regarding the current hardware and software limitations, there are at least three notable ones to be aware of. First, current HMDs do not always have the wide “dynamic range” that will allow for the presentation of a very dim stimulus (*e.g.*, >35dB) nor the capability to present a very bright stimulus (<15dB). Thus, there are device limitations for fully assessing patients with deep, dense and severe field defects, such as found in moderate to severe stage glaucoma.

A second general technical difference between the HMDs and traditional devices is that the background illumination in the headset is somewhat brighter. While most perimeters have standardized background illumination to the photopic range (HFA is 10cd/m²) the HMDs have a typically have a background illumination in a dimmer mesopic range (0.01cd/m² to 3cd/m²).¹⁴

A third area of concern is the inconsistent implementation of progression analysis. This is used to track mean deviation (MD) and other parameters over a series of tests. Regression lines

are calculated to identify a negative slope, which is a potential indicator for disease progression. While some of the currently available HMDs have some form of progression analysis, not all do. Readers are again reminded to evaluate each device carefully to assure that it will meet their practice needs. Clinical studies with published results are the best way to determine the full impact of these feature differences between HMDs and traditional perimeters.

Which leads to another point of concern, how does a practitioner “change over” their practice from a bowl device to an HMD? The answer is not straightforward and will vary across practice settings. Certainly it’s recognized that switching to a new diagnostic device that has different hardware and software test results between the old and new device may not be comparable and potentially could lead to an error in patient management. Generally speaking, obtaining a new baseline of HMD VF tests for all patients switching over would be the best practice approach for maintaining clinical care accuracy.



HMD (left) and HFA (right) examples of a glaucoma patient with a severe defect in the left eye. In this case, there is good general agreement between the two devices. However, there is a 3dB difference between the mean deviation values (HMD=-9.36; HFA=-12.29). Different testing strategies account likely account for this.

TABLE 1. CURRENTLY AVAILABLE HEADSET PERIMETRY DEVICES

Manufacturer	Head-Mounted Device	Website
Elisar	AVA	elisar.com
Heru	re:Vive	seeheru.com
M&S	Smart System VR	www.mstech-eyes.com/vr-headset
MicroMedical Devices	VF2000	micromedinc.com
Oculus	EasyField VR	www.oculus.de/us/products/easyfield-vr/
Olleyes	VisuAll	olleyes.com
RadiusXR	RadiusXR	radiusxr.com
Virtual Field	Virtual Field	virtualfield.io
Virtual Vision	Virtual Eye	virtualvision.health

Use in Practice

Our experience with HMDs varies with the practice setting and the clinical use of perimetry. Adoption in general eyecare practices with limited or no medical management has been very positive. In these settings, the HMD is used mostly for screening and success is dependent upon implementation, training, the ease of set up and connectivity between devices. Patient acceptance is generally quite high. As mentioned, the HMD may also offer other pre-test procedures that improve office patient flow. Lower cost and small size offer an option for placing devices in multiple exam and testing rooms. Transitioning from an older device is not too much of a concern in this setting as most patients are healthy and have not been managed for chronic disease.

In offices with a large percentage of glaucoma patients, complete change over and exclusive implementation of any HMD is not practical at this time, in our opinion. However, there clearly is still a need and a role for HMDs in these medically focused offices. HMDs can be excellent for those patients who can no longer sit for a bowl device test and for those with mild, nonprogressive disease where an easy to administer HMD meets all testing needs. In cases where there is good similarity (judged on the shape, location, depth of scotoma) between the two test reports (patient would complete testing on both devices on

the same or within a short time), we feel more confident in moving forward with an HMD. For those patients with more advanced disease or who are at higher risk of progression we're generally more comfortable staying with a traditional test that has well-established progression analysis software. However, even in limited testing in our glaucoma practices, we've seen a clear and growing role for HMDs.

Takeaways

Overall, virtual reality or head-mounted perimetry has the potential to revolutionize visual field testing in our offices and clinics. The ergonomics and space saving features clearly offer advantages to many. However, caution should be exercised in these very early days of development and adoption. As clinicians, we must demand evidence of validation from the device manufacturers, and these studies should be published in the literature. The marketing approaches often address this superficially. Further long-term tests are also required to determine reproducibility and test-retest variability of this technology; without these, studies' progression analysis cannot be appropriately incorporated into the summary reports.

Until that time, we suggest a careful and somewhat cautious integration of these devices. One thing is certain, the demand for innovation and change with traditional bowl perimetry is high, and the demand for high quality,

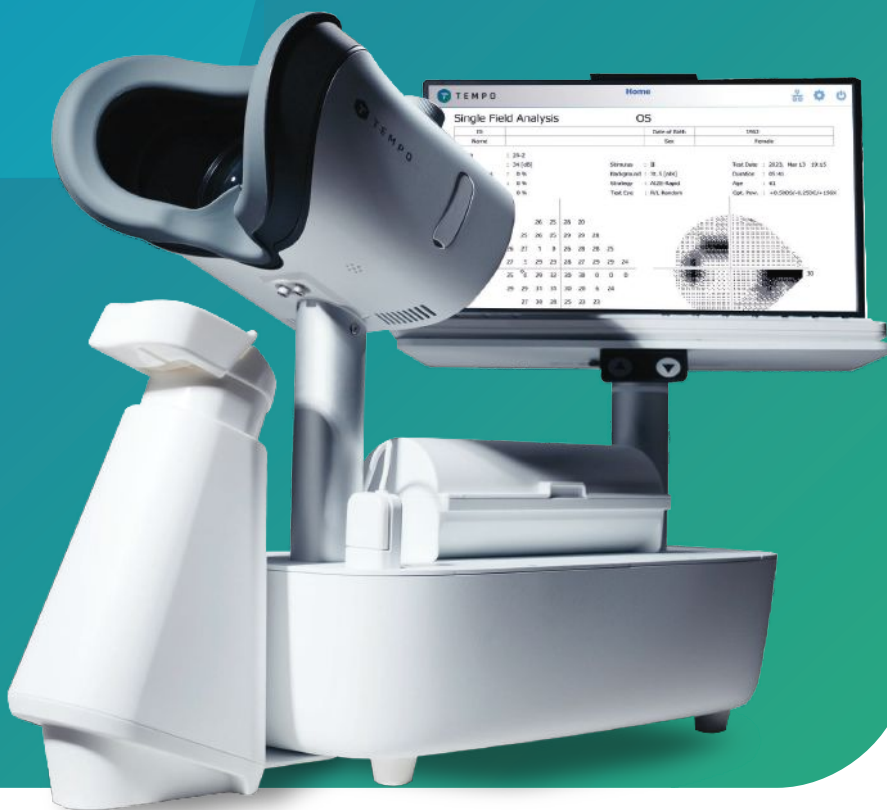reliable testing will drive the necessary improvements. ■

- Kimura T, Matsumoto C, Nomoto H. Comparison of head-mounted perimeter (imo) and Humphrey Field Analyzer. *Clin Ophthalmol.* 2019;13:501-513.
- Olleyes - Virtual reality (VR) mobile perimeter and more. *olleyes.com.* Accessed January 18, 2024.
- Montelongo M, Gonzalez A, Morgenstern F, et al. A virtual reality-based automated perimeter, device and pilot study. *Transl Vis Sci Technol.* 2021;10(3):20.
- Ou Y. Checking visual fields using virtual reality. *Rev Ophthalmol.* 2021;28(3):64-6.
- Jones L, Callaghan T, Campbell P, et al. Acceptability of a home-based visual field test (Eyecatcher) for glaucoma home monitoring; a qualitative study of patients' views and experiences. *BMJ Open.* 2021;11:e043130.
- Tsapakis S, Papaconstantinou D, Diagourtas A, et al. Visual field examination method using virtual reality glasses compared with the Humphrey perimeter. *Clin Ophthalmol.* 2017;11:1431-43.
- Razeghinejad R, Gonzalez-Garcia A, Myers JS, Katz LJ. Preliminary report on a novel virtual reality perimeter compared with standard automated perimetry. *J Glaucoma.* 2021;30(1):17-23.
- Johnson C, Sayed A, McSoley J, et al. Comparison of visual field test measurements with a novel approach on a wearable headset to standard automated perimetry. *J Glaucoma.* 2023; 32(8):647-57.
- Groth SL, Linton EF, Brown EN, et al. Evaluation of virtual reality perimetry and standard automated perimetry in normal children. *Transl Vis Sci Technol.* 2023;12(1):6.
- Chauhan BC, Garway-Heath DF, Goñi FJ, et al. Practical recommendations for measuring rates of visual field change in glaucoma. *Br J Ophthalmology.* 2008; 92(4):569-573.
- Anderson AJ, Bedgood PA, George Kong YX, et al. Can home monitoring allow earlier detection of rapid visual field progression in glaucoma? *Ophthalmology.* 2017;124(12):1735-42.
- Myers L, Hu R, Morgan LS, et al. A comparison of learning effects for standard automated perimetry, short-wavelength automated perimetry and frequency-doubling technology perimetry in healthy subjects. *Invest Ophthalmol Vis Sci.* 2014;55(13):5612.
- Yousefi S, Goldbaum MH, Balasubramanian M, et al. Glaucoma progression detection in using structural retinal nerve fiber layer measurements and functional visual field points. *IEEE Trans Biomed Eng.* 2014;61(4):1143-54.
- Hejli A, Patella VM, Bengsston B. *The Field Analyzer Primer: Excellent Perimetry.* 5th Ed. Carl Zeiss Meditec, Inc, 2021.
- Nishida T, Eslani M, Weinreb RN, et al. Perimetric comparison between the IMOVifa and Humphrey Field Analyzer. *J Glaucoma.* 2023;32(2):85-92.
- Nakai Y, Bessho K, Shono Y, Taoka K, Nakai Y. Comparison of imo and Humphrey field analyzer perimeters in glaucomatous eyes. *Int J Ophthalmol.* 2021;14(12):1882-7.
- Goukon H, Hirasawa K, Kasahara M, Matsumura K, Shoji N. Comparison of Humphrey Field Analyzer and imo visual field test results in patients with glaucoma and pseudo-fixation loss. *PLoS One.* 2019;14(11):e0224711.
- Wakayama A, Matsumoto C, Ayato Y, Shimomura Y. Comparison of monocular sensitivities measured with and without occlusion using the head-mounted perimeter imo. *PLoS One.* 2019;14(1).
- Nishida T, Weinreb RN, Arias J, Vasile C, Moghimi S. Comparison of the TEMPO binocular perimeter and Humphrey field analyzer. *Sci Rep.* 2023;13(1):21189.

TEMPO™

Perimeter

The comfortable binocular perimeter that performs 39% faster than standard automated perimetry.¹



FAST, ACCURATE, COMFORTABLE


Visual Field Testing

The novel, binocular approach makes testing faster and more comfortable which results in effective testing from screening through advanced glaucoma — without compromising accuracy. TEMPO reduces the tedium of perimetry for patients and technicians.



Test results are reliable and repeatable with less patient chair time. Testing both eyes simultaneously offers clinical efficiency and enhanced comfort with a notable patient preference over bowl perimetry.

Takashi Nishida, MD, PhD
Shiley Eye Center, UC San Diego*



1. Nishida T, Eslani M, Weinreb RN, Arias J, Vasile C, Mohammadzadeh V, Moghimi S. Perimetric Comparison Between the IMOVia and Humphrey Field Analyzer. J Glaucoma. 2023 Feb 1;32(2):85-92. doi: 10.1097/JG.0000000000002134. Epub 2022 Oct 7. PMID: 36223309.

*Topcon appreciates the contributions from our partners. At times, an honorarium is provided.

Earn 2 CE Credits
(COPE APPROVED)

DEMYSTIFYING THE COMPLEMENT SYSTEM

Learn to better understand the physiology and pathophysiology of this complex cascade and how it gives rise to AMD.



BY ANNA BEDWELL, OD
INDIANAPOLIS, IN

The onset of new geographic atrophy (GA) treatments, both targeting complement inhibition, has sparked renewed interest in the complement pathway. Eyecare providers understand VEGF and its role in exudative macular degeneration; however, do they similarly understand the complement system, as well as its relationship with the other advanced form of AMD? Probably not, as most of us haven't thought much about the complement pathway since optometry school.

This system is undoubtedly complex, but this article will break it down into a simpler understanding focusing on its relationship with age-related macular degeneration (AMD) and pertaining to GA treatments that have recently become available.

The Complement System

A cascade of proteins (more than about 50) in membrane-bound and fluid-phase, the complement system is responsible for removing cellular debris and pathogens like bacteria.¹ It does this by using opsonization (a form of tagging), attracting phagocytes via chemotaxis and targeting cells for lysis.¹ Tissue homeostasis relies on the complement pathway to continuously turn over. The complement system operates locally in the eye as well as systemically, produced in the liver. In the retina, the complement system maintains the retinal integrity by several means, including clearing the turnover of photoreceptor outer segments in the retinal pigment epithelium (RPE).²

The complement system must sustain tight regulation to avoid unwarranted inflammation and subsequent tissue damage. Overactivation of the pathway promotes the pathogenesis of systemic disease and organ-specific disease such as AMD. Individuals

with AMD have been found to have increased levels of complement end product in the choriocapillaris.^{3,4} Additionally, complement components have been found in the retina, particularly in drusen.^{3,5} A basic understanding of the complement system helps to understand this relationship with AMD and why the system has been targeted as a means of GA treatment.

Let's break down the complement cascade into its four main sections: the pathways, C3 convertase, C5 convertase and formation of the membrane attack complex (MAC).

1. The pathways. Three pathways mark the start of the cascade: classical, lectin and alternative. Each pathway operates independent of one another but ultimately converges toward a final result in the MAC, responsible for creating a pore on pathogens and debris, resulting in cell lysis.

The classical pathway is dependent on an adaptive immune response, meaning the pathogen must have

About the authors

Dr. Bedwell is a clinical associate professor at Indiana University School of Optometry. She is a fellow of the American Academy of Optometry and the Optometric Retina Society, as well as a member of the American Optometric Association. She also serves as editor of the Optometric Retina Society's e-newsletter. She is a consultant for Iveric Bio.

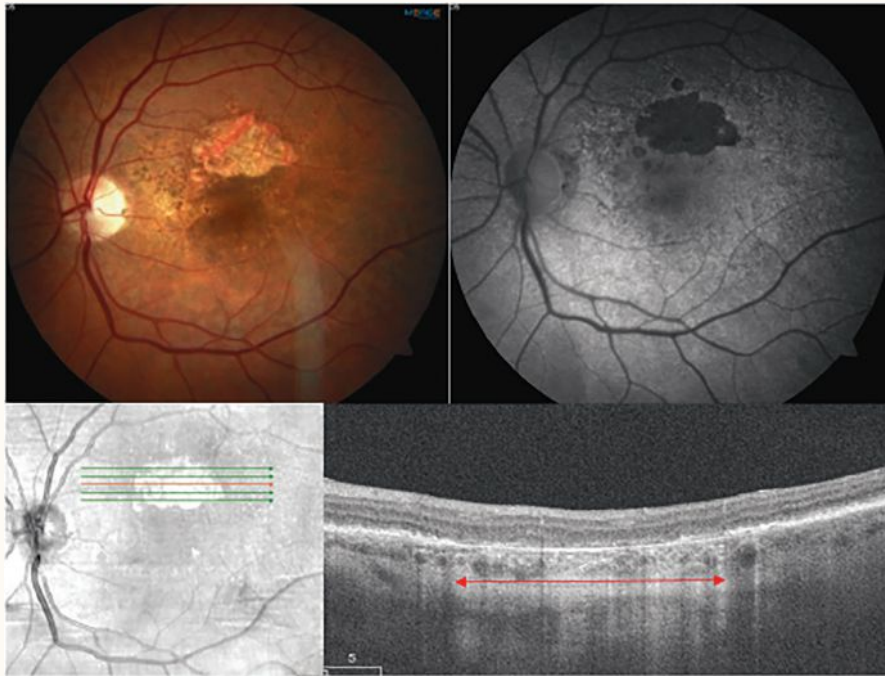


Fig. 1. Multimodal imaging of geographic atrophy. The top row shows a color fundus photo of a non-foveal island of GA in dry AMD and a fundus autofluorescence image in which the atrophy demonstrates classic hypoautofluorescence. The bottom row shows a near infrared image and an OCT scan through the GA lesion. There is a loss of ellipsoid zone and RPE in the outer retina and a choroidal hypertransmission defect (red arrow).

This complex drives the split of C2 and C4, akin to the classical pathway, to ultimately result in the same C3 convertase.

The dominant player in the complement system, the alternative pathway, is credited for over 80% of complement system end product of MAC formation.⁶ The alternative pathway is constantly in action at low levels via spontaneous hydrolysis of C3, also known as complement “tickover,” making it ready for immediate C3b deposition on pathogens for target opsonization, the process of tagging pathogens for phagocytic lysis.

In a multistep process, spontaneous cleavage of the thioester bond in C3 creates a distinct C3 convertase (C3bBb). It binds with properdin, a serum protein, to stabilize. Then, this

been previously combated to create an antibody response.¹ Antibodies, such as IgG and IgM serve as activators.¹ This pathway is triggered when antibodies bind to the protein C1q, which in turn recognizes and binds to the surface of an invading pathogen. This forms an antibody-antigen complex, leading to the split of two proteins, C2 and C4. The fragments of these proteins, C2a

and C4b, join together to form the enzyme C3 convertase (C4b2a).

The lectin pathway operates similar to the classical except that it isn’t antibody driven. Rather, mannose-binding lectin and its binding partners, mannose-associated serine proteases, recognize and bind to the carbohydrate structures (oligosaccharides) found on a microbial surface to form a complex.

Demystifying the Complement System

Jointly provided by Postgraduate Institute for Medicine (PIM) and Review Education Group

Release Date: February 15, 2024

Expiration Date: February 15, 2027

Estimated Time to Complete Activity: two hours

Target Audience: This activity is intended for optometrists who want to learn about the impact this system has on practice.

Educational Objectives: After completing this activity, participants should be better able to:

- Comprehend the physiology and pathophysiology of the complement cascade.
- Recognize the complement system’s involvement in AMD.
- Identify current treatment options that target the complement system.
- Effectively manage patients with geographic atrophy.

Faculty: Anna Bedwell, OD

Disclosure of Conflicts of Interest: PIM requires faculty, planners and others in control of educational content to disclose all their financial relationships with ineligible companies. All identified conflicts of interest are thoroughly vetted and mitigated according to PIM policy. PIM is committed to providing its learners with high-quality, accredited CE activities and related materials that promote improvements or quality in health care and not a specific proprietary business interest of an ineligible company.

Those involved reported the following relevant financial relationships with ineligible entities related to the educational content of this CE activity: *Faculty* – Dr. Bedwell is a

consultant for Iveric Bio. *Planners and Editorial Staff* – PIM has nothing to disclose. The Review Education Group has nothing to disclose.

Accreditation Statement: In support of improving patient care, this activity has been planned and implemented by PIM and the Review Education Group. PIM is jointly accredited by the Accreditation Council for Continuing Medical Education, the Accreditation Council for Pharmacy Education and the American Nurses Credentialing Center to provide CE for the healthcare team. PIM is accredited by COPE to provide CE to optometrists.

Credit Statement: This course is COPE-approved for two hours of CE credit. Activity #127640 and course ID 89405-SD. Check with your local state licensing board to see if this counts toward your CE requirement for relicensure.

Disclosure of Unlabeled Use: This educational activity may contain discussion of published and/or investigational uses of agents that are not indicated by the FDA. The planners of this activity do not recommend the use of any agent outside of the labeled indications. The opinions expressed in the educational activity are those of the faculty and do not necessarily represent the views of the planners. Refer to the official prescribing information for each product for discussion of approved indications, contraindications and warnings.

Disclaimer: Participants have an implied responsibility to use the newly acquired information to enhance patient outcomes and their own professional development. The information presented in this activity is not meant to serve as a guideline for patient management. Any procedures, medications or other courses of diagnosis or treatment discussed or suggested in this activity should not be used by clinicians without evaluation of their patient’s condition(s) and possible contraindications and/or dangers in use, review of any applicable manufacturer’s product information and comparison with recommendations of other authorities.



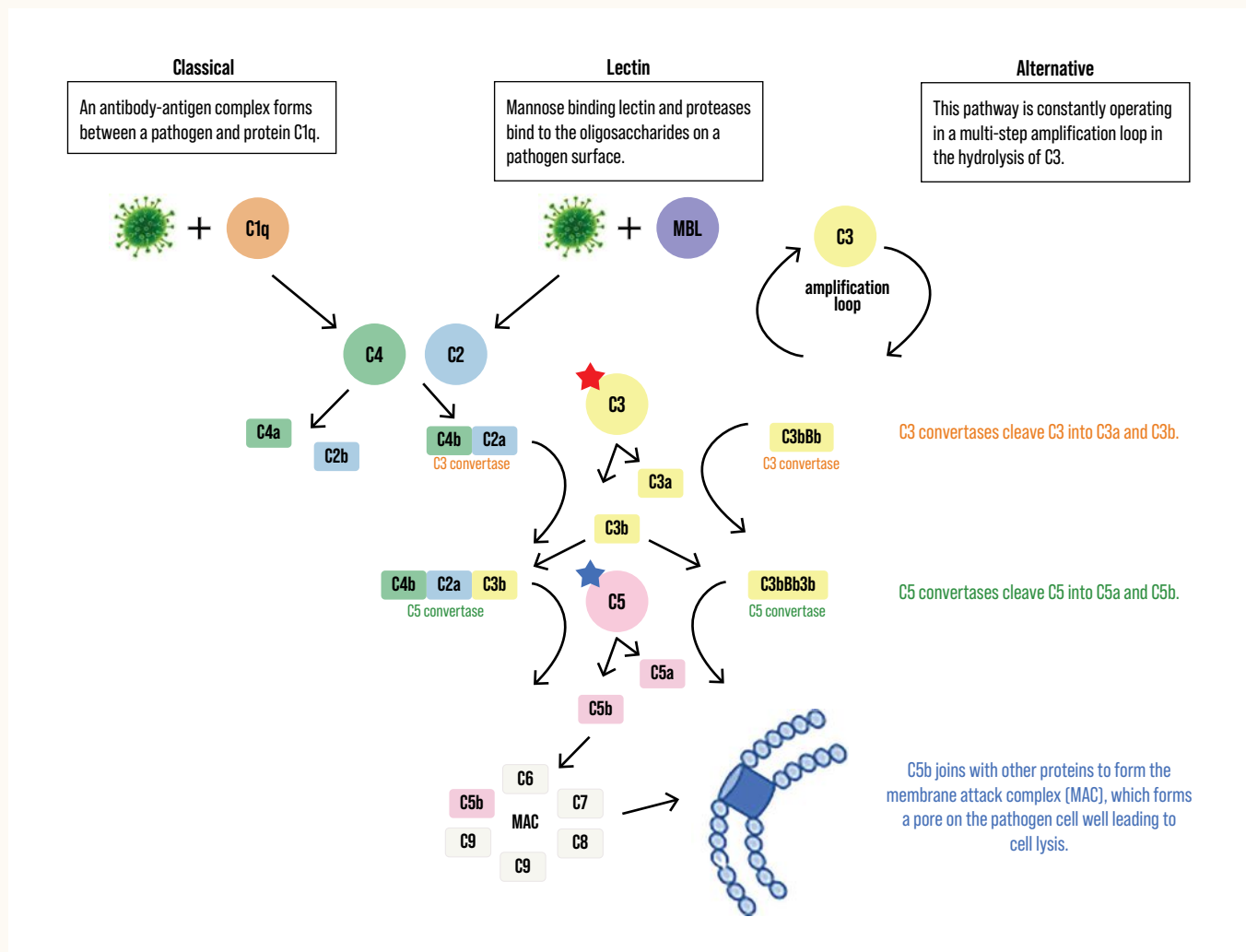


Fig. 2. Simplified schematic of the complement pathway from the pathways to the terminal endpoint of the membrane attack complex. The inhibition target for pegcetacoplan is C3 indicated by the red star. The blue star highlights C5, the inhibition target for avacincaptad pegol.

distinct form starts an amplification loop cleaving C3 into C3a and C3b. The C3b is in turn used to create extra C3 convertase, keeping the terminal pathway going to form MAC. This process is regulated by complement factors, the enzyme mediators of the system. These regulators help to focus the complement activity specifically to pathogens. The complement factors will be described in a later section when it applies to genetic risk for AMD development.

2. C3 convertase. The three pathways converge at C3 convertase, an enzyme family. The C3 convertase produced via the classical and lectin pathways is C4b2a while the alternative results in C3bBb. Both of these C3

convertases operate the same by cleaving C3 into C3a and C3b. C3a is an anaphylatoxin, a molecule that prompts chemotaxis, the movement of eosinophils and phagocytic cells to generate increasing concentrations of C3a. C3b keeps the complement pathway moving. It is an unstable molecule that quickly stabilizes by forming a covalent bond to the surface of microbial cells triggering phagocytosis.

3. C5 convertase. The enzymes C3 and C5 convertase differ in their C3b requirement. C5 convertase necessitates at least two molecules of C3b to form. In the previous step, extra C3b molecules were generated. These bind to a C3 convertase and in turn become C5 convertase. The role of C5 conver-

tase is to cleave C5 into C5a and C5b. C5a is another anaphylatoxin like C3a described above. C5b then initiates the terminal pathway described next.

4. Membrane attack complex (MAC). The terminal step of the complement system is the assembly of MAC, a group of five globular plasma proteins. The C5b generated in the preceding step combines with C6, C7, C8 and multiple C9s. This complex attaches to the cell membrane and forms a pore, destroying the membrane integrity and resulting in cell death.

Genetic Associations

In 2001, one study discovered complement byproducts in drusen, most notably complement factor H (CFH),

implying the complement system's involvement in AMD.⁷ To date, multiple genome-wide association studies have confirmed at least 52 independent gene variants and 34 genetic loci, accounting for over half of the genetic risk for AMD.⁸ A portion of these identified high-risk genetic variants code for key enzymes and proteins of the complement system.^{8,9}

However, the complement system is not the only contributor, as other variants are tied to extracellular matrix remodeling, lipid metabolism, angiogenesis and oxidative stress response demonstrating the complex AMD pathophysiology. These genetic variants span from common in the population, typically conveying a low AMD risk, while other variants are quite rare but impart a nearly complete penetrance for AMD development. About two-thirds of the heritability of AMD is attributed to the common variants, the remaining attributed to rare variants which are more likely to be disease causative.¹⁰ The variants are referred to as single-nucleotide polymorphisms (SNPs), genomic variants at a single base position in the DNA.

Complement factors. Of the three initial pathways, the alternative pathway has been linked most frequently with AMD development.⁴ Complement factors B, D, F, H and I within the alternative pathway all have genetic variants discovered to be associated with AMD.¹¹⁻¹³ The most well-established of these is the CFH gene found on chromosome 1.⁷ In the complement pathway, it regulates the alternative pathway by acting as a cofactor to complement factor I (CFI) in the inactivation of C3b. When CFH function is compromised, dysregulation of the complement cascade occurs, allowing for damage to healthy tissue rather than isolating to pathogens. CFH risk variants have a slightly greater association with risk for GA vs. exudative AMD.^{8,14}

A substantial portion of the AMD genetic risk lies in two CFH variants: rs1061170 (also known as Y402H) and rs1410996. Thirty percent of the

population of European descent carry at least one copy of the Y402H allele.¹⁵ Those with one allele have a 2.3-fold increased risk of AMD, which jumps to a 5.2-fold risk with two alleles.¹⁵ Other, less common CFH variants have also been discovered, some of which are associated with an exceedingly high risk for advanced AMD, such as R1210C. This variant has been linked to a much younger onset age of AMD and displays the strongest genetic risk for AMD of variants found to date.¹⁰

CFI, mentioned earlier as cofactor to CFH in the alternative pathway, also has genetic variants linked to AMD. In particular, it holds several rare variants, with at least 59 identified.¹² One study found that 7.8% of AMD cases vs. 2.3% of controls harbored rare missense CFI variants.¹¹ These rare variants were associated with a 7.5-fold elevated risk of advanced AMD.¹¹ CFI is a rate-limiting enzyme of complement termination. *In vitro* study has found that increasing CFI concentration by just 25% can essentially shut down alternative pathway activation.^{16,17}

Complement components. Several AMD-associated variants have been found in the complement C3 gene. The three complement pathways converge on C3, making it a critical step of the

complement system. The most common variant in the population associated with C3 is R102G.^{18,19} Another variant of interest is K155Q, which results in feedback amplification of the alternative pathway with an effect very similar to the aforementioned R1210C variant in CFH.¹¹

Complement component 9 (C9) also shows ties to AMD, particularly in P167S.¹¹ The previously mentioned variants all were associated with the alternative pathway. However, C9 is responsible for the formation of the MAC in the terminal pathway, reminding us that there is not a single route by which the complement system contributes to AMD development.

Another well-established genetic locus in ARMS2-HTRA1 may have ties to the complement system, but this remains unclear. Multiple high-risk variants have been found in the ARMS2-HTRA1 region of chromosome 10. Together, these variants in combination with CFH variants account for over half of the genetic risk associated with AMD.^{8,20,21} The mechanisms of AMD development from dysfunction in the ARMS2-HTRA1 region is not well understood. At least in part, ARMS2 appears to be involved in complement-mediated

TABLE 1. GENETIC VARIANTS FOUND IN THE COMPLEMENT SYSTEM ASSOCIATED WITH AMD

	Single-nucleotide polymorphism (SNP)	Location	What makes it noteworthy?
Common SNPs	Y402H (rs1061170)	CFH	First discovered, found in 30% of those European descent
	rs1410996	CFH	
	R102G (rs2230199)	C3	Most common C3 variant in the population
	rs10033900	CFI	
	A69S (rs10490924)	ARMS2	Associated with younger age of AMD onset; questionable complement ties
	rs11200638	HTRA1	
	E318D (rs9332739)	C2	C2 associated with the classical and lectin pathways
	R32Q (rs641153)	CFB	CFB contributor in the alternative pathway
Rare SNPs	R1210C	CFH	Carries the strongest genetic risk for developing AMD
	K155Q (rs147859257)	C3	High risk of advanced AMD
	59 rare variants	CFI	Linked to 7.5-fold risk of advanced AMD
	P167S	C9	Tied to the terminal pathway/MAC formation

clearance of cellular debris.²² As such, protein deficiencies in ARMS2 may be involved in drusen formation.²²

Genetic testing in AMD. With the genetic ties mentioned, will genetic testing become a standard of care for AMD? Perhaps. It has certainly become more commonplace to use genetic screening for assessing risk and considering suitability for vitamin supplementation. Presently, the caveat lies in that AMD is a multifactorial disease involving genes and environmental factors—such as smoking, nutrition and body mass index—all playing a role. This makes risk stratification tricky. There are two commercially available AMD genetic testing providers: Arctic Medical Laboratories and Visible Genomics. Arctic tests for 14 SNPs associated with AMD and Visible Genomics tests for 15 SNPs. Both use an algorithm based on genetic and environmental risk factors.

Visible Genomics offers two tests: one that assesses the risk of developing AMD and the other for those with early or intermediate stage AMD to assess risk for advanced stage disease. On the other hand, Arctic only offers genetic tests for those who already have a diagnosis of drusen or any stage of AMD. They offer two types of tests: the Macula Risk test, which gives a two-, five- and 10-year risk for progression to advanced AMD and Vita Risk, which can be ordered stand-alone or added to Macula Risk, which uses the patient’s genetic profile to guide whether AREDS formulation, antioxidants alone or zinc alone would be most beneficial. This is based on research—albeit controversial—finding that high-dose zinc can increase risk of advanced AMD in those with CFH risk alleles.²³⁻²⁵

Genetic testing in AMD remains a debated topic. Those that argue for it find that patients can benefit from more frequent follow-up for early detection of progression to advanced stage and an opportunity to tailor preventive nutritional supplements. The American Academy of Ophthalmology does not recommend genetic testing

TABLE 2. APPROVED COMPLEMENT-INHIBITING GEOGRAPHIC ATROPHY TREATMENTS

Complement Inhibitor	Syfovre (pegcetacoplan)	Izervay (avacincaptad pegol)
Manufacturer	Apellis	Iveric Bio
Approval date	February 2023	August 2023
Complement target	C3	C5
Supportive Phase III trials	OAKS/DERBY/GALE	GATHER1/GATHER2
Dosing	15mg intravitreal injection q25 to 60 days	2mg intravitreal injection monthly

for AMD.²⁶ However, if a gene-targeted treatment were to be approved, then genetic testing would quickly become a necessity.

Treatment Targeting Complement

The genetic and biological evidence that complement is a major driver in AMD has been established. However, targeting the complement system with treatment isn’t as straightforward. There are many considerations, given that the ideal target treatment point within the complement cascade remains debated. It is also important to note that the complement system has many necessary functions in preventing infection. Can that just be turned off?

Historically, previous treatments aimed at the complement system, such as eculizumab (targeting C5) and lamalizumab (targeting CFD), failed.²⁷ However, the treatment landscape for GA changed completely in 2023 with the FDA approval of two complement inhibitors for the treatment of GA secondary to AMD. Below we will discuss how these treatments fit into the complement puzzle.

The first approval came in February with Syfovre (pegcetacoplan injection), a C3 inhibitor.²⁸ Syfovre is composed of two cyclic peptides attached to a polyethylene glycol chain, to provide a longer half-life and enhance solubility.²⁹ The peptides bind to C3 and the activation fragment C3b to halt production of the complement system.²⁹ The approval came at the heels of two Phase III studies: DERBY and OAKS.

At 12 months, OAKS showed a significant reduction in GA expan-

sion, whereas DERBY did not.³⁰ This improved for both trials at the 24-month follow-up in monthly and every-other-month treatment groups.³¹ GALE, a phase III extension study from DERBY and OAKS, evaluating the 36-month long-term safety is in progress.³² First year results for GALE were recently announced, which showed reduced GA lesion growth of 35% with monthly injections and 24% with every-other-month compared with the projected sham arm.³³

Safety concerns arose in summer of 2023 when the American Society of Retina Specialists Research and Safety in Therapeutics Committee linked pegcetacoplan to six cases of occlusive retinal vasculitis.³⁴ Retinal vasculitis was not observed in DERBY, OAKS or even the first year of GALE, though conversion to wet AMD remains the highest safety concern. Over three years, GALE found 19.5% cumulative risk of conversion to wet AMD in the monthly group compared to less than 9% in the every-other-month group.³³

The second FDA approval arrived in August with Izervay (avacincaptad pegol).³⁵ Izervay is a pegylated RNA aptamer targeting inhibition of C5, in turn decreasing the production of C5a and C5b.³⁶ The FDA approval for monthly treatment was based on 18-month and 12-month data from the Phase III GATHER1 and GATHER2 clinical trials, respectively.

In total across the trials, 292 patients (vs. 332 with sham) were treated with an intravitreal injection of avacincaptad pegol (2mg) monthly.³⁶ There was a 35% decrease in GA lesion growth in GATHER1 and 18% in GATHER2.³⁶

Recently, Iveric Bio released 24-month data from GATHER2.³⁷ The second year of the trial re-randomized patients to monthly or every-other-month treatment.³⁷ At 24 months, the monthly treatment group had a 14% reduction in GA growth compared with a 19% reduction for the every-other-month group.³⁷

There was one case of endophthalmitis and non-serious intraocular inflammation. There were no cases of retinal vasculitis or ischemic optic neuropathy. The rate of choroidal neovascularization was 12% in treated patients compared with 9% in the sham group.³⁷ Of note, the GATHER trials evaluated only those with extrafoveal GA lesions. As such, treatment results cannot be directly compared with trials of pegcetacoplan, which additionally included fovea-involving GA lesions.

Both treatments attack central components of the complement system. Other therapeutic strategies, by comparison, have targeted complement factors, the regulators of the system. Both drugs in trial have demonstrated decreased GA lesion growth, although some have criticized these results as meager.²⁷

Unfortunately for patients, none of these trials showed an improvement to visual function for the trade-off of frequent in-office treatments.²⁷ Rather the goal with these treatments is to preserve vision for a longer time period, which can be a difficult concept for patients to grasp when they don't recognize immediate gains as in exudative AMD treatments. On an encouraging note, both drugs have demonstrated that the treatment effect over placebo improved with treatment duration.

Additionally, a concern for both treatments is the increased risk of choroidal neovascularization. How that occurs is unclear. Is there too much shut-off of the complement system? Some have suggested that polyethylene glycol, present in both therapies, may be the culprit, as it has demonstrated in mouse models to induce CNV.³⁸ Real-world data will be telling as both

of these treatments have now entered retina specialist practice.

The long-awaited treatment for geographic atrophy has finally arrived. For optometry, understanding the complement system in AMD development and complement inhibition with GA treatment helps to better serve our patients with GA. ■

- Male D, Stokes PR, Male V. Immunology. 9th ed. Elsevier. 2021.
- Mukai R, Okunuki Y, Husain D, et al. The complement system is critical in maintaining retinal integrity during aging. *Front Aging Neurosci.* 2018;10:15.
- Anderson DH, Radeke MJ, Gallo NB, et al. The pivotal role of the complement system in aging and age-related macular degeneration: hypothesis re-visited. *Prog Retin Eye Res.* 2010;29(2):95-112.
- Loyet KM, Deforge LE, Katschke KJ Jr, et al. Activation of the alternative complement pathway in vitreous is controlled by genetics in age-related macular degeneration. *Invest Ophthalmol Vis Sci.* 2012;53(10):6628-37.
- Khandhadia S, Cipriani V, Yates JR, et al. Age-related macular degeneration and the complement system. *Immunobiology.* 2012;217(2):127-46.
- Harboe M, Ulvund G, Vien L, et al. The quantitative role of alternative pathway amplification in classical pathway induced terminal complement activation. *Clin Exp Immunol.* 2004;138(3):439-46.
- Hageman GS, Luthert PJ, Victor Chong NH, et al. An integrated hypothesis that considers drusen as biomarkers of immune-mediated processes at the RPE-Bruch's membrane interface in aging and age-related macular degeneration. *Prog Retin Eye Res.* 2001;20(6):705-32.
- Fritsche LG, Igl W, Bailey JN, et al. A large genome-wide association study of age-related macular degeneration highlights contributions of rare and common variants. *Nat Genet.* 2016;48(2):134-43.
- Fritsche LG, Fariss RN, Stambolian D, et al. Age-related macular degeneration: genetics and biology coming together. *Annu Rev Genomics Hum Genet.* 2014;15:151-71.
- Seddon JM. Macular degeneration epidemiology: nature-nurture, lifestyle factors, genetic risk and gene-environment interactions - The Weisenfeld Award lecture. *Invest Ophthalmol Vis Sci.* 2017;58(14):6513-28.
- Seddon JM, Yu Y, Miller EC, et al. Rare variants in CFI, C3 and C9 are associated with high risk of advanced age-related macular degeneration. *Nat Genet.* 2013;45(11):1366-70.
- Schramm EC, Clark SJ, Triebwasser MP, et al. Genetic variants in the complement system predisposing to age-related macular degeneration: a review. *Mol Immunol.* 2014;61(2):118-25.
- Shughoury A, Sevgi DD, Ciulla TA. Molecular genetic mechanisms in age-related macular degeneration. *Genes (Basel).* 2022;13(7):1233.
- Fritsche LG, Chen W, Schu M, et al. Seven new loci associated with age-related macular degeneration. *Nat Genet.* 2013;45(4):433-9.
- Sofat R, Casas JP, Webster AR, et al. Complement factor H genetic variant and age-related macular degeneration: effect size, modifiers and relationship to disease subtype. *Int J Epidemiol.* 2012;41(1):250-62.
- Lachmann PJ. The amplification loop of the complement pathways. *Adv Immunol.* 2009;104:115-49.
- Boyer DS, Schmidt-Erfurth U, van Lookeren Campagne M, et al. The pathophysiology of geographic atrophy secondary to age-related macular degeneration and the complement pathway as a therapeutic target. *Retina.* 2017;37(5):819-35.
- Yates JR, Sepp T, Matharu BK, et al. Genetic Factors in AMD Study Group. Complement C3 variant and the risk of age-related macular degeneration. *N Engl J Med.* 2007;357(6):553-61.

- Zhang J, Li S, Hu S, et al. Association between genetic variation of complement C3 and the susceptibility to advanced age-related macular degeneration: a meta-analysis. *BMC Ophthalmol.* 2018;18(1):274.
- Klein R, Myers CE, Meuer SM, et al. Risk alleles in CFH and ARMS2 and the long-term natural history of age-related macular degeneration: the Beaver Dam Eye Study. *JAMA Ophthalmol.* 2013;131(3):383-92.
- Holliday EG, Smith AV, Cornes BK, et al. Insights into the genetic architecture of early stage age-related macular degeneration: a genome-wide association study meta-analysis. *PLoS One.* 2013;8(1):e53830.
- Micklisch S, Lin Y, Jacob S, et al. Age-related macular degeneration associated polymorphism rs10490924 in ARMS2 results in deficiency of a complement activator. *J Neuroinflammation.* 2017;14(1):4.
- Awh CC, Lane AM, Hawken S, et al. CFH and ARMS2 genetic polymorphisms predict response to antioxidants and zinc in patients with age-related macular degeneration. *Ophthalmology.* 2013;120(11):2317-23.
- Awh CC, Hawken S, Zanke BW. Treatment response to antioxidants and zinc based on CFH and ARMS2 genetic risk allele number in the Age-Related Eye Disease Study. *Ophthalmology.* 2015;122(1):162-9.
- Vavvas DG, Small KW, Awh CC, et al. CFH and ARMS2 genetic risk determines progression to neovascular age-related macular degeneration after antioxidant and zinc supplementation. *Proc Natl Acad Sci USA.* 2018;115(4):E696-E704.
- Mukamal R. Genetics and age-related macular degeneration. *American Academy of Ophthalmology.* www.aao.org/eye-health/diseases/age-related-macular-degeneration-amd-genetics. Accessed January 12, 2024.
- Spaide RF, Vavvas DG. Complement inhibition for geographic atrophy: review of salient functional outcomes and perspective. *Retina.* 2023;43(7):1064-9.
- Park B. Syfovre approved for geographic atrophy secondary to AMD. *Medical Professionals Reference.* February 21, 2023. Accessed January 12, 2024.
- Syfovre (pegcetacoplan injection) [package insert]. Waltham, MA: Apellis Pharmaceuticals, Inc; 2023.
- Steinle N, Boyer DS, Mones J, et al. Efficacy of intravitreal pegcetacoplan in patients with geographic atrophy (GA): 12-month results from the Phase III OAKS and DERBY studies. *Invest Ophthalmol Vis Sci* 2022;63(7):1500.
- Wyckoff, C. Treatment of geographic atrophy secondary to AMD With pegcetacoplan: two-year outcomes from the randomized Phase III OAKS and DERBY Trials. Presented at the American Academy of Ophthalmology Annual Meeting 2022.
- An extension study to evaluate the long-term safety and efficacy of pegcetacoplan (APL-2) in subjects with geographic atrophy secondary to AMD (GALE). August 31, 2023. clinicaltrials.gov/ct2/show/NCT04770545. Accessed January 12, 2024.
- Wyckoff CC, Heier JS, Jones D, et al. Long-term efficacy and safety of pegcetacoplan from the GALE open-label extension of the Phase III OAKS and DERBY Trials. Presented at the American Academy of Ophthalmology Annual Meeting 2023.
- Hutton, D. ASRS reports six cases of occlusive retinal vasculitis linked to pegcetacoplan injection. *Ophthalmology Times.* July 19, 2023. www.opthalmologytimes.com/view/asrs-reports-six-cases-of-occlusive-retinal-vasculitis-linked-to-pegcetacoplan-injection. Accessed January 12, 2024.
- Park B. Izervay approved for geographic atrophy secondary to AMD. *Medical Professionals Reference.* August 7, 2023. Accessed January 12, 2024.
- Izervay (avacincaptad pegol intravitreal solution) [package insert]. Parsippany, NJ: IVERIC Bio, Inc; 2023.
- Khanani AM, Patel SS, Staurenghi G, et al. GATHER2: two-year data. Presented at the American Academy of Ophthalmology Annual Meeting 2023.
- Lyzogubov VV, Bora NS, Tytarenko RG, et al. Polyethylene glycol induced mouse model of retinal degeneration. *Exp Eye Res.* 2014;127:143-52.

OPTOMETRIC STUDY CENTER QUIZ

To obtain CE credit through the Optometric Study Center, complete the test form on the following page and return it with the \$35 fee to: Jobson Healthcare Information, Attn.: CE Processing, Jobson Healthcare Information, LLC/WebMD, 283-299 Market Street, 2 Gateway Center, 4th Floor, Newark, NJ 07102. To be eligible, please return the card within three years of publication. You can also access the test form and submit your answers and payment via credit card online at revieweducationgroup.com. You must achieve a score of 70 or higher to receive credit. Allow four weeks for processing. For each Optometric Study Center course you pass, you earn two hours of credit. Please check with your state licensing board to see if this approval counts toward your CE requirement for relicensure.

1. Which of the following is NOT a pathway in the complement system?
 - a. Alternative.
 - b. Lectin.
 - c. Amplification.
 - d. Classical.
2. Which of the pathways is dependent on an adaptive immune response via antibodies?
 - a. Alternative.
 - b. Terminal.
 - c. Lectin.
 - d. Classical.
3. The alternative pathway is credited for _____% of the complement system's end product of membrane attack complex formation.
 - a. 20.
 - b. 40.
 - c. 60.
 - d. 80.
4. Which of the following is the rare CFH variant that has been associated with a high risk of advanced AMD and a younger age of AMD onset?
 - a. R1210C.
 - b. Y402H.
 - c. B758M.
 - d. V854T.
5. Which complement component is inhibited by Izervay (avacincaptad pegol)?
 - a. C2.
 - b. C3.
 - c. C5.
 - d. C9.
6. Of the initial complement pathways, which has been associated most often with AMD development?
 - a. Lectin.
 - b. Classical.
 - c. Alternative.
 - d. Both A and B.
7. Which of the following defines the process of tagging pathogens for phagocytic lysis?
 - a. Chemotaxis.
 - b. Opsonization.
 - c. Hydrolysis.
 - d. Encapsulation.
8. Syfovre (pegcetacoplan) inhibits which complement component?
 - a. C2.
 - b. C3.
 - c. C4.
 - d. C5.
9. What percent of patients of European descent carry at least one copy of the common CFH variant, Y402H?
 - a. 10.
 - b. 30.
 - c. 60.
 - d. 75.
10. Izervay (avacincaptad pegol) was approved by the FDA for what dosing schedule?
 - a. One month.
 - b. Six weeks.
 - c. Three months.
 - d. Four months.
11. Which of the following is a potential adverse effect of both FDA-approved GA treatments?
 - a. Retinal detachment.
 - b. Vitreous hemorrhage.
 - c. Choroidal neovascularization.
 - d. PSC cataract.
12. Which of the follows shows the correct order of the complement system?
 - a. Pathways activated, C5 convertase, C3 convertase, MAC.
 - b. Pathways activated, C3 convertase, C5 convertase, MAC.
 - c. C3 convertase, pathways activated, C5 convertase, MAC.
 - d. C3 convertase, C5 convertase, pathways activated, MAC.
13. Which two genes have been most often implicated in AMD development?
 - a. CFH and CFI.
 - b. CFH and ARMS2-HTRA1.
 - c. CFI and CFD.
 - d. ARMS3-HTRA1 and CFD.
14. Which pathway is constantly in action via complement "tickover"?
 - a. Alternative.
 - b. Lectin.
 - c. Classic.
 - d. None of the above.
15. By what process is the membrane attack complex responsible for cell lysis?
 - a. Opsonization.
 - b. Increasing C5 production.
 - c. Attracting macrophages.
 - d. Creating a pore on pathogens.
16. Where is the convergence point of the three initial pathways of the complement system?
 - a. C5 convertase.
 - b. MAC.
 - c. CFH.
 - d. C3 convertase.
17. Which organ, besides the eye, produces the complement system?
 - a. Liver.
 - b. Kidney.
 - c. Thyroid.
 - d. Pancreas.
18. Where in the complement system is complement component C9 found?
 - a. Creation of C3 convertase.
 - b. Assembly of MAC.
 - c. Amplification loop.
 - d. Lectin pathway.
19. Which of the following is an environmental risk factor for geographic atrophy?
 - a. Diabetes.
 - b. Smoking.
 - c. Low BMI.
 - d. Mediterranean diet.
20. Which of the following is true regarding the FDA approved geographic atrophy (GA) treatments?
 - a. Syfovre (pegcetacoplan) is pegylated, Izervay (avacincaptad pegol) is not.
 - b. Clinical trials found improved visual function with both therapies.
 - c. Syfovre (pegcetacoplan) inhibits CFH while Izervay (avacincaptad pegol) inhibits CFI.
 - d. Clinical trials found a decrease in GA lesion growth with both therapies.

Examination Answer Sheet

Demystifying the Complement System

Valid for credit through February 15, 2027

Online: This exam can be taken online at revieweducationgroup.com. Upon passing the exam, you can view your results immediately and download a real-time CE certificate. You can also view your test history at any time from the website.

Directions: Select one answer for each question in the exam and completely darken the appropriate circle. A minimum score of 70% is required to earn credit.

Mail to: Jobson Healthcare Information, LLC/WebMD, 283-299 Market Street, 2 Gateway Center, 4th Floor, Newark, NJ 07102.

Payment: Remit \$35 with this exam. Make check payable to Jobson Healthcare Information, LLC.

Credit: This course is COPE-approved for two hours of CE credit. Course ID 89405-SD.

Processing: There is a four-week processing time for this exam.

Jointly provided by PIM and the Review Education Group.

Answers to CE exam:

- 1. (A) (B) (C) (D)
- 2. (A) (B) (C) (D)
- 3. (A) (B) (C) (D)
- 4. (A) (B) (C) (D)
- 5. (A) (B) (C) (D)
- 6. (A) (B) (C) (D)
- 7. (A) (B) (C) (D)
- 8. (A) (B) (C) (D)
- 9. (A) (B) (C) (D)
- 10. (A) (B) (C) (D)
- 11. (A) (B) (C) (D)
- 12. (A) (B) (C) (D)
- 13. (A) (B) (C) (D)
- 14. (A) (B) (C) (D)
- 15. (A) (B) (C) (D)
- 16. (A) (B) (C) (D)
- 17. (A) (B) (C) (D)
- 18. (A) (B) (C) (D)
- 19. (A) (B) (C) (D)
- 20. (A) (B) (C) (D)

Post-activity evaluation questions:

Rate how well the activity supported your achievement of these learning objectives. 1=Poor, 2=Fair, 3=Neutral, 4=Good, 5=Excellent

- 21. Comprehend the physiology and pathophysiology of the complement cascade. (1) (2) (3) (4) (5)
- 22. Recognize the complement system's involvement in AMD. (1) (2) (3) (4) (5)
- 23. Identify current treatment options that target the complement system. (1) (2) (3) (4) (5)
- 24. Effectively manage patients with geographic atrophy. (1) (2) (3) (4) (5)
- 25. Based upon your participation in this activity, do you intend to change your practice behavior? (Choose only one of the following options.)
 - (A) I do plan to implement changes in my practice based on the information presented.
 - (B) My current practice has been reinforced by the information presented.
 - (C) I need more information before I will change my practice.
- 26. Thinking about how your participation in this activity will influence your patient care, how many of your patients are likely to benefit? (please use a number):
- 27. If you plan to change your practice behavior, what type of changes do you plan to implement? (Check all that apply.)
 - (A) Apply latest guidelines
 - (B) Change in diagnostic methods
 - (C) Choice of management approach
 - (D) Change in current practice for referral
 - (E) Change in vision correction offerings
 - (F) Change in differential diagnosis
 - (G) More active monitoring and counseling
 - (H) Other, please specify: _____
- 28. How confident are you that you will be able to make your intended changes?
 - (A) Very confident
 - (B) Somewhat confident
 - (C) Unsure
 - (D) Not confident
- 29. Which of the following do you anticipate will be the primary barrier to implementing these changes?
 - (A) Formulary restrictions
 - (B) Time constraints
 - (C) System constraints
 - (D) Insurance/financial issues
 - (E) Lack of interprofessional team support
 - (F) Treatment related adverse events
 - (G) Patient adherence/compliance
 - (H) Other, please specify: _____
- 30. Additional comments on this course: _____

Please retain a copy for your records. Please print clearly.

First Name

Last Name

E-Mail

The following is your: Home Address Business Address

Business Name

Address

City State

ZIP

Telephone # - -

Fax # - -

OE Tracker Number

Rate the quality of the material provided:

1=Strongly disagree, 2=Somewhat disagree, 3=Neutral, 4=Somewhat agree, 5=Strongly agree

31. The content was evidence-based.

(1) (2) (3) (4) (5)

32. The content was balanced and free of bias.

(1) (2) (3) (4) (5)

33. The presentation was clear and effective.

(1) (2) (3) (4) (5)

By submitting this answer sheet, I certify that I have read the lesson in its entirety and completed the self-assessment exam personally based on the material presented. I have not obtained the answers to this exam by any fraudulent or improper means.

Signature _____

Date _____

Lesson 124643 RO-OSC-0224



BY NATE LIGHTHIZER, OD

ADVANCED PROCEDURES

Hat's Off to Epi-Off

Make sure you link a keratoconus diagnosis with a timely treatment approach.

BY ALIA CAPPELLANI, OD, AND NATE LIGHTHIZER, OD
CALGARY, AB, CANADA; TAHLEQUAH, OK

Keratoconus (KC) is a chronic, clinically non-inflammatory, bilateral ectasia of the cornea characterized by progressive corneal steepening and apical thinning leading to irregular astigmatism, higher-order aberrations and visual distortion.¹ KC classically manifests during puberty and can progress at an unpredictable rate until the third to fourth decade of life. The prevalence varies geographically but is estimated to be 1.38 per 1000 in the world's population, with a rate of 0.15% in the United States as of 2016.^{2,3}

Other corneal ectasias include pellucid marginal degeneration, keratoglobus and post-refractive ectasia. If left untreated, corneal ectasia can lead to vision loss and an increased probability of corneal transplant. Given the significant risk of affecting social and educational development during young adulthood, the crux of corneal ectasia management lies in halting disease progression with corneal crosslinking (CXL) at its earliest stages to reduce the necessity for invasive corneal surgeries and prevent a lifetime of vision loss.⁴

CXL was first introduced over 20 years ago by researchers at the University of Dresden as a novel approach to strengthen corneal tissue by more than

300%.^{5,6} Adopted early and widely used abroad, the FDA approved CXL for progressive KC and corneal ectasia following refractive surgery in 2016. The technique involves the combination of topical riboflavin (vitamin B2) and ultraviolet-A light (UVA) to initiate a chain of chemical reactions that release oxygen free radicals, which generate strong covalent bonds within the stromal collagen, thereby providing structural reinforcement and arresting progression of the ectatic process.

The US Phase III clinical trial demonstrated 1.6D flattening in maximum keratometry after one year.⁷ Since the approval of CXL, multiple studies have confirmed its efficacy in achieving long-term stabilization of KC in addition to reducing the socioeconomic burden of the disease.^{8,9} Corneal ectasia was once the most common indication for penetrating keratoplasty; however,

with the widespread adoption of CXL and newer contact lens innovations, there has been a decline over the last 10 years, and it has fallen to number six on the list.¹⁰ The modern paradigm of corneal ectasia management involves timely intervention with CXL to prevent progression, improving vision and closely monitoring for changes.

Indications and Contraindications

CXL is indicated for progressive keratoconus and post-refractive ectasia. The definition of progression is at the discretion of the physician and usually involves topometric, pachymetric and refractive changes.¹¹ Insurance carriers often require documentation of these specific criteria within 24 months:¹²

- >1D change in the steepest keratometry value (Kmax)
- >1D change in cylinder value in subjective refraction
- >0.1mm back optic zone radius change in gas permeable contact lens parameters

While there is no specific age range in the indication statement for CXL, the FDA-approval clinical trial included patients aged 14 to 65.⁷ Nevertheless, for the vulnerable, faster-progressing younger individuals, closer follow-up and a lower threshold for CXL should be adopted for patients under 17 years old and steeper than 55D Kmax.¹³

CXL is contraindicated in pregnant and nursing mothers as the safety has not been evaluated. Corneal stromal thickness of less than 400µm is contraindicated to prevent endothelial cell damage;

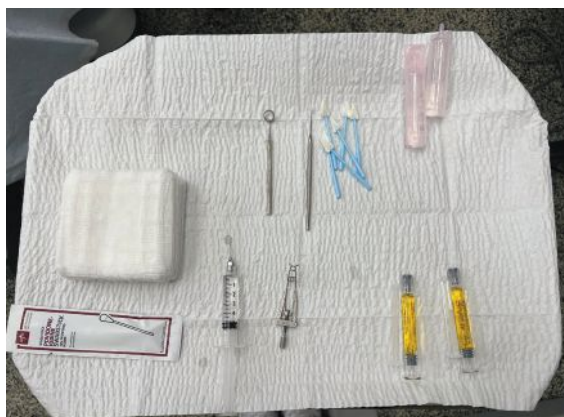

Fig. 1. CXL instrumentation set up on a Mayo stand.

About
Dr. Lighthizer

Dr. Lighthizer is the associate dean, director of continuing education and chief of specialty care clinics at the NSU Oklahoma College of Optometry. He is a founding member and immediate past president of the Intrepid Eye Society. Dr. Lighthizer's full disclosure list can be found in the online version of this article at www.reviewofoptometry.com.

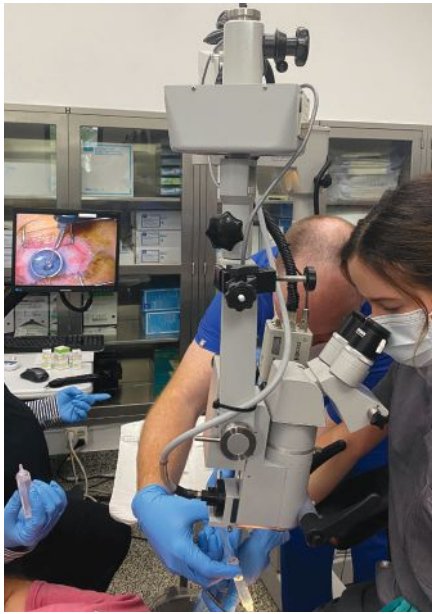

Fig. 2. Instillation of a diluted alcohol solution into the well to soften up the epithelium prior to debridement.

however, hypo-osmolar riboflavin solution can be used to swell the cornea at the time of the procedure. Another proposed alternative is placing a riboflavin-soaked soft contact lens on the eye during UVA irradiation.

UV light exposure may reactivate herpes simplex keratitis, so caution should be taken for patients with a history of herpetic ocular disease, which may include antiviral prophylaxis.⁸

Informed Consent Considerations

A written description of the cross-linking procedure in lay language, its indications, alternative treatments, postoperative expectations and possible adverse events should be read and signed by the patient, clinician and a witness.¹⁴ It must be stressed that the primary purpose of CXL is to stop progression of corneal ectasia, not use as a refractive procedure. However, there are additional studies demonstrating CXL treatment was able to decrease the steepness of the cone, consequently improving both uncorrected and corrected visual acuity.¹⁵

Procedure

Currently, the standard epithelium-off Dresden protocol is the only FDA-approved CXL method (iLink, Glaukos). It entails a 60-minute monocular treatment as follows:⁷

1. Positioning and alignment.

The patient is positioned in a supine position with the surgical microscope focused.

2. Pre-op lid sterilization.

The eyelids and periorbital area should be thoroughly cleaned with povidone-iodine. Topical anesthetic eye drops are instilled three to four times over five-minute intervals in the surgical eye to aid in softening the epithelium, and one drop in the other eye for blink control. An eyelid speculum is placed so the lids and lashes will not interfere with surgery. An instrument tray showing the proper instrumentation needed for the CXL procedure is shown in *Figure 1*.

3. Epithelial removal.

A well is placed onto the cornea, centered around the cone and a diluted ethanol solution is dripped in the well for 30 seconds to loosen the epithelium prior to debridement (*Figure 2*). A dry surgical sponge is used to soak up the ethanol, the well is removed and the eye is rinsed with a balanced salt solution. The epithelium is removed using a surgical sponge and spatula to clear the circular 7mm to 9mm treatment zone.

4. Riboflavin baste.

One drop of Photrex Viscous (riboflavin 5'-phosphate in 20% dextran ophthalmic solution) is instilled topically every two minutes for 30 minutes. The eye is examined with a slit lamp to confirm the presence of yellow flare in the anterior chamber.

If flare is not present, additional Photrex Viscous should be instilled at a rate of one drop every two minutes for an additional two to three drops until there is yellow flare seen in the anterior chamber.

5. Pachymetry check.

Ultrasound pachymetry is performed to ensure the corneal

thickness is a minimum of 400µm. If corneal thickness is less than 400µm, two drops of Photrex (riboflavin 5'-phosphate ophthalmic solution) should be instilled every five to 10 seconds until 400µm is achieved.

6. UV-A irradiation.

Once the yellow flare is visualized and the 400µm threshold thickness is met, corneal irradiation is performed for 30 minutes (*Figure 3*). The KXL system delivers a metered dose of 365nm UV-A light, 3mW/cm² exposure centered over the cornea (*Figure 4*). The instillation of Photrex Viscous is continued at a rate of one drop every two minutes throughout the 30-minute irradiation period. This results in a total treatment dose of 5.4J/cm².

7. Therapeutic contact lens.

A bandage contact lens (BCL) is applied to the eye after the procedure to promote epithelial healing and decrease pain.

Post-op Care

Topical antibiotics are prescribed three to four times per day until re-epithelialization, and topical steroids are tapered over a month. Often, an NSAID is prescribed for the first few days after the procedure to help with pain. An oral narcotic

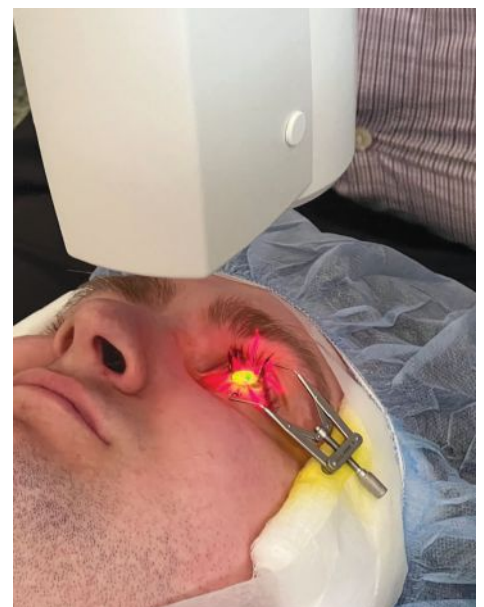

Fig. 3. Irradiation with UVA light following saturation of the cornea with riboflavin.

can also be considered in the two to five days after the procedure to help with post-op pain. Preservative-free artificial tears are used for lubrication and comfort, and no eye rubbing is strongly encouraged.

Follow-up/Comanagement

A typical postoperative follow-up schedule entails an exam at day one, days four to seven, one month, three months and six to 12 months.

Day one: The eye is evaluated for normal healing and a properly positioned BCL. Blurry vision and discomfort are expected.

Days four to seven: The corneal epithelium is monitored for closure, and the BCL is removed once fully reepithelialized.

Month one: Visual acuity and refraction can be assessed more accurately, although these will continue to change. Corneal haze and a demarcation line is expected. Contact lens wear can be resumed at this time.

Month three: Corneal haze is often resolved. Patients are continually monitored for stability with corneal topography every six to 12 months.

Potential Complications

CXL is considered a minimally invasive procedure with a low complication rate; however, potential complications can arise, mainly as a result of epithelial debridement. Postoperative pain, infection, stromal haze, inability to heal and reduced visual acuity are the most commonly reported adverse events.¹⁶

On the Horizon

In an attempt to circumvent the possible side effects, investigational modifications to the Dresden protocol involve transepithelial or epithelium-on (epi-on) CXL. Various protocols aimed at delivering riboflavin across an intact epithelium remain an active subject of research and development, including molecules to enhance penetration, riboflavin-soaked sponges, pulsed UV light and oxygen goggles.⁴

Takeaways

Corneal ectasia is progressive and irreversible; thus, the long-term prognosis hinges on the ability to diagnose and manage the condition in its early stages. In the last two decades, CXL has emerged as an effective method to halt corneal ectasia leading to vision preservation, better contact lens fitting, cornea transplant prevention and, ultimately, improved quality of life. Optometrists are on the front lines of diagnosing corneal ectasias and are actively involved in performing CXL across multiple states.

In regions where this procedure falls outside the current scope of practice, a collaborative comanagement approach fosters

valuable professional relationships with our ophthalmology colleagues, ensuring optimal care for our patients. ■

1. Wagner H, Barr JT, Zadnik K. Collaborative Longitudinal Evaluation of Keratoconus (CLEK) Study: methods and findings to date. *Cont Lens Anterior Eye*. 2007;30(4):223-32.
2. Hashemi H, Heydarian S, Hooshmand E, The prevalence and risk factors for keratoconus: a systematic review and meta-analysis. *Cornea*. 2020;39(2):263-70.
3. Munir SZ, Munir WM, Albrecht J. Estimated prevalence of keratoconus in the United States from a large vision insurance database. *Eye Contact Lens*. 2021;47(9):505-10.
4. Angelo L, Gokul Boptom A, McGhee C, Ziaei M. Corneal crosslinking: present and future. *Asia Pac J Ophthalmol (Phila)*. 2022;11(5):441-52.
5. Spörl E, Huhle M, Kasper M, Seiler T. Artificial stiffening of the cornea by induction of intrastromal crosslinks. *Der Ophthalmologe*. 1997;94,902-06.
6. Wollensak G, Spoerl E, Seiler T. Riboflavin/ultraviolet-A-induced collagen crosslinking for the treatment of keratoconus. *Am J Ophthalmol*. 2003;135(5):620-7.
7. Hersh PS, Stulting RD, Muller D, et al; United States Crosslinking Study Group. United States multicenter clinical trial of corneal collagen crosslinking for keratoconus treatment. *Ophthalmology*. 2017;124(9):1259-70.
8. Mohammadpour M, Masoumi A, Mirghorbani M, et al. Updates on corneal collagen cross-linking: Indications, techniques and clinical outcomes. *J Curr Ophthalmol*. 2017;29(4):235-47.
9. Lindstrom RL, Berdahl JP, Donnenfeld ED, et al. Corneal crosslinking vs. conventional management for keratoconus: a lifetime economic model. *J Med Econ*. 2021;24(1):410-20.
10. Mathews P, Benbow A, Corcoran K, et al. 2022 Eye Banking Statistical Report—executive summary. EBCT. 2023;2(3):e8-12.
11. Gomes JA, Tan D, Rapuano CJ, et al. (2015). Global consensus on keratoconus and ectatic diseases. *Cornea*. 2015;34(4):359-69.
12. iLink. Understanding insurance coverage for cross-linking in the US. www.glaukos-ilink.com/blogs/understanding-insurance-coverage-for-cross-linking-in-the-u-s/. Accessed November 8, 2023.
13. Ferdi AC, Nguyen V, Gore DM, et al. (2019). Keratoconus natural progression: a systematic review and meta-analysis of 11,529 eyes. *Ophthalmology*. 2019;126(7):935-45.
14. Chu YR, Heckman J. Corneal cross-linking. In: Freisber L, Lighthizer N, Skorn L, et al., eds. *The Ophthalmic Laser Handbook*. Lippincott Williams & Wilkins; 2021:165-75.
15. Meiri Z, Keren S, Rosenblatt A, et al. (2016). Efficacy of corneal collagen cross-linking for the treatment of keratoconus: a systematic review and meta-analysis. *Cornea*. 2016;35(3):417-28.
16. Agarwal R, Jain P, Arora R. (2022). Complications of corneal collagen cross-linking. *Indian J Ophthalmol*. 2022;70(5):1466-74.

ABOUT THE CO-AUTHOR



Dr. Cappellani is a residency-trained optometrist with clinical emphasis on specialty contact lenses, myopia management and ocular disease at Mission Eye Care in Calgary, AB, Canada. She is a fellow of the American Academy of Optometry and Scleral Lens Society, as well as a diplomate of the American Board of Optometry. She has no financial disclosures.

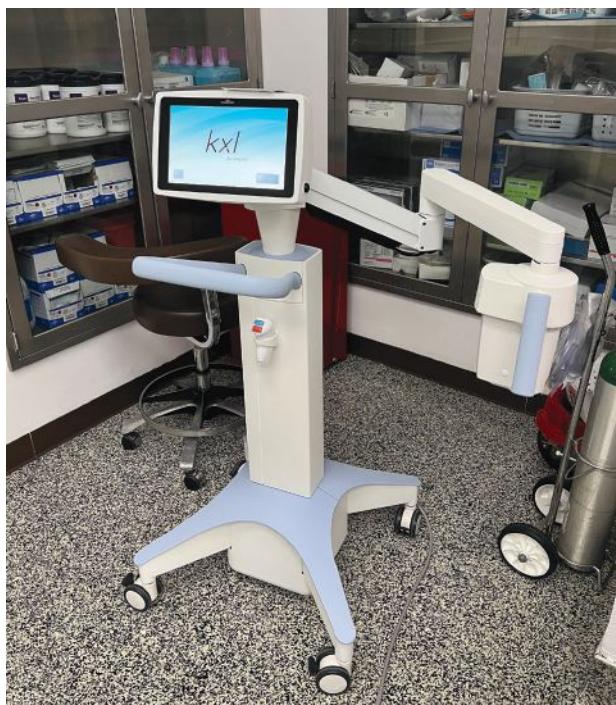
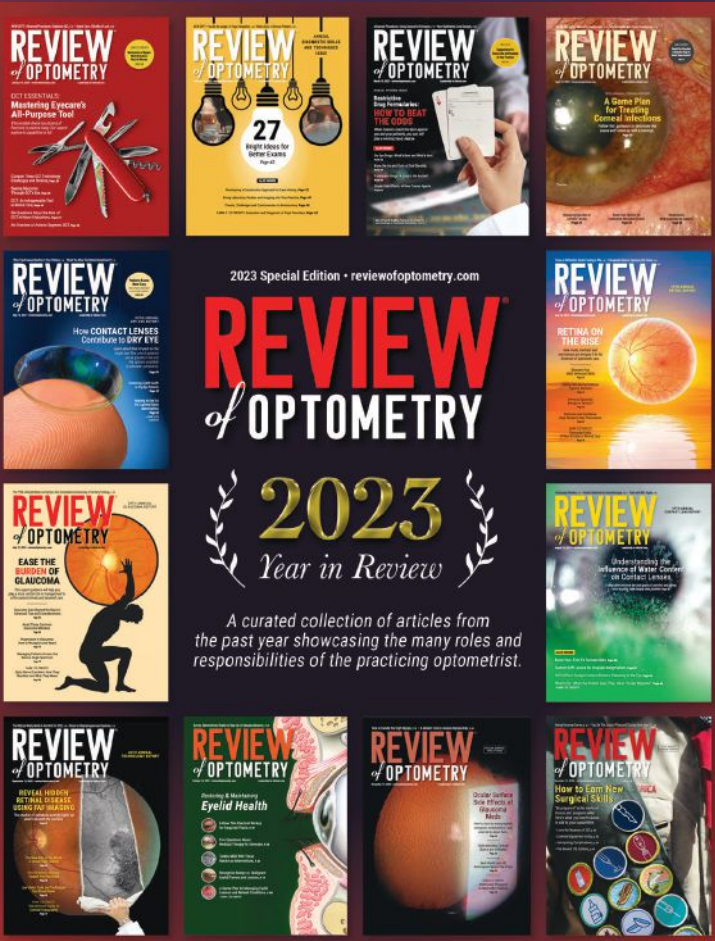
Fig. 4. The iLink remains the first and only FDA-approved crosslinking device.

A Year in the Making.



Our 2023 recap delivers:

- “How-to” guidance on dozens of clinical techniques
- Timely insights from the scientific literature
- The year’s biggest legislative news stories
- Commentary from trusted voices in the profession

...all in one place!

Available now at reviewofoptometry.com





Common Threads

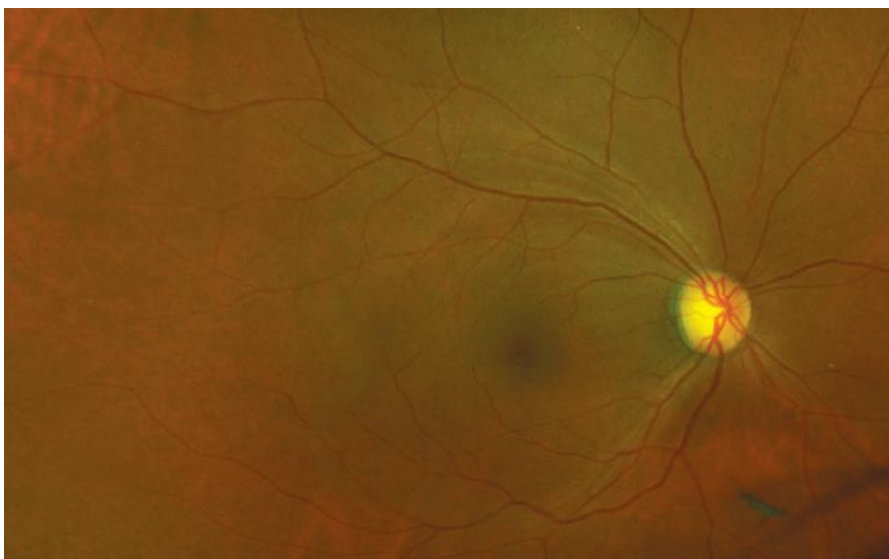
RNFL defects are an important clinical finding in glaucomatous optic neuropathy, but the diagnosis may not always be obvious.

A 57-year-old African American woman was referred for evaluation of suspicion of glaucoma secondary to retinal nerve fiber layer (RNFL) defect in the right eye. Her best-corrected visual acuity was 20/20 in both eyes without afferent pupillary defect. Her medical history was positive for HIV, for which her managing physician recently shifted medication from Symtuza (darunavir, cobicistat, emtricitabine and tenofovir alafenamide, Janssen Pharmaceuticals) tablets to Cabenuva (cabotegravir, rilpivirine extended-release injectable suspension, ViiV Healthcare).

Her viral load was undetectable, and her CD4 count was greater than 1000cells/mm³. The patient's blood pressure was 130/85mm Hg in office.

Intraocular pressures were 19mm Hg OD and 21mm Hg OS with central corneal thickness of 543µm OD and 542µm OS. She had split focal RNFL defects superior temporally in the right eye, while the optic discs were sharp and pink with healthy, symmetric neuroretinal rim tissue without focal rim loss.

RNFL and ganglion cell-inner plexiform layer (GCIPL) imaging fell within the normative range in each eye, as did neuroretinal rim thickness. Automated visual fields were full in each eye. Careful evaluation of the combined RNFL and GCIPL analysis of the right eye reflected the subtle RNFL defect visible clinically and in widefield imaging, which extended toward, without reaching, the optic disc.



Ultra-widefield image demonstrating superior temporal RNFL defect in the absence of neuroretinal rim notching. A posterior vitreous detachment is visible inferior to the disc.

RNFL Loss

Observation of a focal RNFL defect that is representative of axonal loss of retinal ganglion cells either clinically or by fundus photography is an important structural finding in glaucomatous optic neuropathy; however, these defects are not pathognomonic for glaucoma. In nonglaucomatous eyes, RNFL loss may develop as a result of underlying neurological, systemic or retinal disease, or as a result of certain systemic medications and treatments. This means that their presence requires careful ophthalmic examination and review of medical history, and may require further medical or neurologic investigation.¹⁻⁶

In the case of the incidental finding of focal RNFL defect in a nonglaucomatous, otherwise healthy eye, the most common cause is a past microvascular anomaly, or resulting axonal loss following a focal ischemic event leading to disruption of axoplasmic transport: a resolved cotton wool spot. These entities are common ocular manifestations of diabetes mellitus and hypertension—and may also occur in the context of HIV.^{1,2,4-6} Following resolution of a cotton wool spot, an RNFL defect may be apparent due to the local disruption to axonal transport, resulting in axonal death, and a corresponding subtle, nonprogressive visual field defect or microperimetry abnormality may also be detectable.^{1,5}

HIV Retinopathy

This condition is classified as either infectious, which includes cytomegalovirus retinitis, herpetic necrotizing retinitis and other opportunistic infections, or non-infectious. Non-infectious HIV retinopathy, or HIV microangiopathy, is evidenced through the presence of cotton wool spots or,

About Dr. Steen

Dr. Steen is an associate professor at Nova Southeastern University College of Optometry, where she serves as director of the Glaucoma Service, coordinator of the Primary Care with Emphasis in Ocular Disease Residency and teaches courses in glaucoma and ocular pharmacology. Her financial disclosures include Bausch + Lomb, Santen, Ocuphire, Carl Zeiss Meditec, Oyster Point Pharma, Ocuterra, Peripherex, Clearside Biomedical, Allergan, Iveric Bio, Alcon and Thea Pharma.

Medscape **LIVE!**


Presents

Save the Date

2024 CE CONFERENCES

IN-PERSON *Review of Optometry*[®]

presents a collaboration between

**Spring | May 17–19, 2024**Sign up to be notified when
spring registration opens.**Fall | November 15–17, 2024****December 6–7, 2024**

THE OPTOMETRIC RETINA SOCIETY AND REVIEW EDUCATION GROUP PRESENT

RETINAUPDATE2024**December 7–8, 2024**

Locations to be announced.

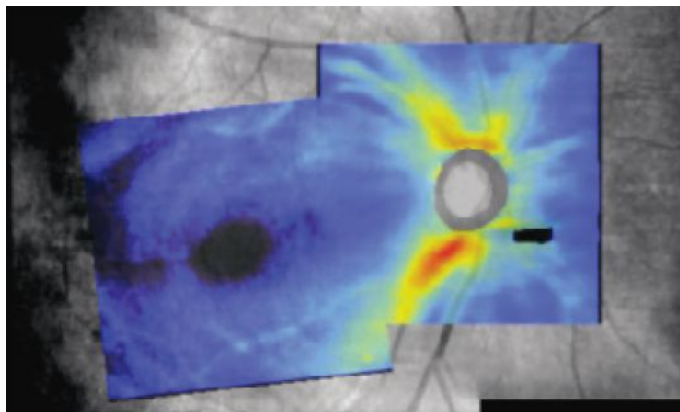
Scan the QR Code or visit www.reviewedu.com/events
for information as it becomes available.

Follow us on social media!

Search: Review Education Group

Postgraduate Institute
for Medicine**REVIEW**
Education GROUP

following their resolution, focal RNFL defects. It is estimated to occur in up to 60% of untreated HIV-positive patients.⁶ OCT angiography has also been demonstrated to be useful in detecting subclinical microvascular abnormality in individuals with HIV who undergo antiretroviral therapy (ART) in the absence of infectious retinitis.⁷



Combined RNFL and ganglion cell analysis map of the right eye demonstrating subtle superior temporal RNFL loss not extending to the optic disc. The area of missing data inferior nasal to the optic disc correlates to the posterior vitreous detachment.

HIV Treatment

Advancements in HIV prevention, treatment and cure research have continued at a rapid pace since the initial approval of the first ART in 1996. Currently, antiretroviral therapy is recommended to be initiated as soon as possible following HIV diagnosis with the goal of reducing plasma HIV RNA to an undetectable level, ultimately reducing disease-related morbidity and mortality as well as preventing viral transmission.⁸ Initial therapy generally includes three oral medications from two or more HIV drug classes.⁸

Real-world challenges related to ongoing, long-term viral suppression include the requirement of excellent adherence to often complex oral medication regimens, adverse effects related to therapy and access to treatment. Therapeutic and prevention strategies for individuals diagnosed with or at risk of developing HIV are central to long-term public health strategies to reduce new infections.⁸

Recently approved HIV therapies aim to improve adherence to therapy through longer acting agents and to address multidrug resistance. Cabenuva, approved in 2021, is indicated for individuals who have achieved viral suppression on their current ART as a replacement for oral therapy and is administered subcutaneously every one to two months in a physician's office. Sunleca (lenacapavir, Gilead Sciences), approved in 2022, is used in addition to other antiretroviral therapies

in patients who have demonstrated multidrug resistance.

Following initial treatment, which includes oral and injectable formulations of lenacapavir over either a two- or 15-day pre-specified course, long-term maintenance dosing calls for subcutaneous injection every six months.⁸ For individuals at increased risk of HIV infection, pre-exposure prophylaxis (PrEP) can reduce the risk of HIV infection by up to 99%. Currently in the United States, there are two oral medications and one long-acting injectable medication approved for PrEP.⁹

Diagnosis

After a thorough review of systems without positive findings, we discussed the patient's medical history in more detail. The patient had access to her recent complete metabolic panel and complete blood count (with platelets), which were negative for evidence of underlying infection, inflammation, hematologic or metabolic concern. She reported no history of positive COVID-19 test and, despite her elevated systolic blood pressure in office, she reported typical greater concern for low blood pressure by her managing physician.

She shared that her symptoms that led her to seek medical care where she was ultimately diagnosed with HIV eight years prior were very severe:

rapid, significant weight loss, lethargy and flu-like symptoms. At the time of diagnosis, she recalled that her CD4 count was "very low."

The patient described multiple therapeutic challenges since diagnosis including adverse effects of nausea, weight gain, lethargy and brain fog until the change to her current long-term injectable therapeutic strategy. Now, for the first time since being diagnosed with HIV, she reported having the energy and ability to think

clearly that she recalled from prior to her HIV diagnosis. Clinical stability of the RNFL and GCIPL imaging has been demonstrated over a 12-month period without intervention.

In the absence of optic neuropathy, nonprogressive RNFL defects may indicate previous presence of a cotton wool spot or microvascular insult related to underlying treatable systemic conditions including HIV.

1. Ioannides A, Georgakarakos ND, Elarouf I, et al. Isolated cotton-wool spots of unknown etiology: management and sequential spectral domain optical coherence tomography documentation. *Clin Ophthalmol*. 2011;5:1431-3.

2. Brown GC, Brown MM, Hiller T, et al. Cotton-wool spots. *Retina*. 1985;5(4):206-14.

3. Marinho PM, Marcos AAA, Romano AC, et al. Retinal findings in patients with COVID-19. *Lancet*. 2020;395:1610.

4. Freeman WR, McCutchan AJ, Arevalo JF, et al. HNRC Group. The relationship between AIDS retinal cotton wool spots and neuropsychological impairment in HIV-positive individuals in the pre-highly active antiretroviral therapy era. *Ocul Immunol Inflamm*. 2004;12(1):25-33.


5. Shin, JY, Lee, J, Lee, CJ et al. Association between localised retinal nerve fiber layer defects and cardiovascular risk factors. *Sci Rep*. 2019;9(1):19340.

6. Abu EK, Abokyi S, Obiri-Yeboah D, et al. Retinal microvasculopathy is common in HIV/AIDS patients: a cross-sectional study at the cape coast teaching hospital, Ghana. *J Ophthalmol*. 2016;20:8614095.

7. Du KF, Huang XJ, Chen C, et al. Macular changes observed on optical coherence tomography angiography in patients infected with human immunodeficiency virus without infectious retinopathy. *Front Med (Lausanne)*. 2022;9:820370.

8. Panel on Antiretroviral Guidelines for Adults and Adolescents. Guidelines for the use of antiretroviral agents in adults and adolescents with HIV. Department of Health and Human Services. 2023. clinicalinfo.hiv.gov/en/guidelines/adult-and-adolescent-arv. Accessed December 20, 2023.

9. US Public Health Service. Preexposure prophylaxis for the prevention of HIV infection in the United States-2021 Update. A clinical practice guideline. 2021. www.cdc.gov/hiv/pdf/risk/prep/cdc-hiv-prep-guidelines-2021.pdf. Accessed December 20, 2023.



LIVE IN ATLANTA!

XDEM VY Experts: Real-World Patient and OD Perspectives

Friday, March 1, 2024

7:00–9:00 PM ET

Georgia Aquarium
225 Baker St. NW
Atlanta, Georgia

Come hear from patients and physicians who have first-hand experience with FDA-approved XDEM VY (lotilaner ophthalmic solution) 0.25%. Reception and dinner will be provided.

OD Experts:



Janelle Davison, OD
Brilliant Eyes Vision Center
Smyrna, Georgia



Shane Kannarr, OD
Kannarr Eye Care
Pittsburg, Kansas



Cecelia Koetting, OD, FAAO
Hines Sight
Denver, Colorado



Nathan Lighthizer, OD, FAAO
NSU Oklahoma College
of Optometry
Tahlequah, Oklahoma



TO REGISTER, **SCAN QR CODE OR VISIT:**
www.reviewofoptometry.com/xdemvy-atl

Sponsored by



Brought to you by



US--2400049 0224



BY JAMES L. FANELLI, OD

GLAUCOMA GRAND ROUNDS

Coordinating Care, Delaying Clinic

While making background arrangements for proper management is not usually difficult, it can cut into office efficiency.

As a clinician who spends each clinic day in the trenches, and in keeping with my idea of penning columns for fellow doctors in the trenches, sometimes the ancillary issues with rendering good patient care need to be discussed. Whether we are managing a case of glaucoma, even straightforward cases such as this one, or more complex issues like neuro-ophthalmic disorders, coordinating care for our patients is part and parcel of every day in clinic. While many of us don't actually do all the coordinating of the behind-the-scenes pieces to the puzzle of delivering patient care, such as wading through the pre-authorization process for a particular medication, we do spend considerable time communicating with other physicians about the particular patient we are deal-

ing with, such as with their primary care internist when a patient has diabetes.

In glaucoma care, the majority of our "behind-the-scenes" time is spent dealing with pre-authorizations for medications, coordinating interventional glaucoma surgery, also coordinating a surgical plan for our glaucoma patients who need cataract surgery and discussing the potential for incorporating various minimally invasive glaucoma surgery (MIGS) devices such as iStent inject. Occasionally, though, there is a curveball thrown at us that consumes even more of our time, and that of our ancillary staff. This is one of those situations.

Case

This pleasant 79-year-old African American male presented as a new patient

about two years prior with advanced glaucoma OD and moderate glaucoma OS. His initial visit was to establish care with me and establish if I could help him see better with his right eye in particular, as his previous provider was not able to improve his vision. Current medications included travoprost HS OU and Cosopt (dorzolamide hydrochloride and timolol maleate ophthalmic, Théa Pharma) BID OU. Systemic medications included lisinopril, metformin and 81mg aspirin daily with no reported allergies to medications.

At the initial visit, pressures were 10mm Hg OD and 14mm Hg OS by applanation. Pachymetry readings were 501 μ m OD and 509 μ m OS. Best-corrected visual acuities were 20/60 OD and 20/30+ OS. Pupils were ERRLA with a +1 APD OD, extraocular movements were full in all positions of gaze and the anterior segments were unremarkable with deep open chamber angles, as the patient was pseudophakic. Through dilated pupils, his intraocular lenses were well-centered OU; the posterior capsule OD was opened and that of the left was clear and intact. Bilateral posterior vitreous detachments were present.

The posterior pole evaluations were consistent with the staging of glaucoma, with a 0.9x0.95 cup-to-disc ratio in the right eye and 0.65x0.75 in the left. The right neuroretinal rim was thin, especially temporally, with inferior temporal erosion of the rim. The left neuroretinal rim was thin, too, but the remaining tissue was plush and well perfused. These clinical findings were supported by OCT imaging, as seen in *Figures 1* and *2*. The physical examination of both maculae were consistent with only age-related retinal pigment epithelium granulation. The retinal vasculature was characterized only by mild arteriosclerotic retinopathy OU and a diffuse epiretinal membrane (mild) was present OD. There was no

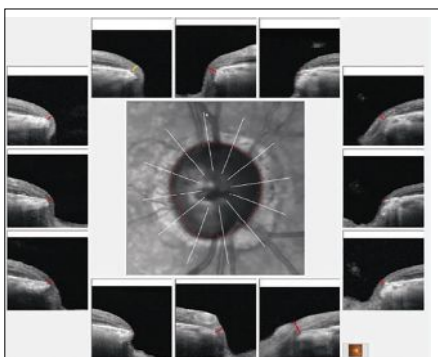


Fig. 1. Bruch's membrane opening minimum rim width (BMO-MRW) overview of the right neuroretinal rim. Note the eroded temporal rim, along with notching of the inferotemporal segment.

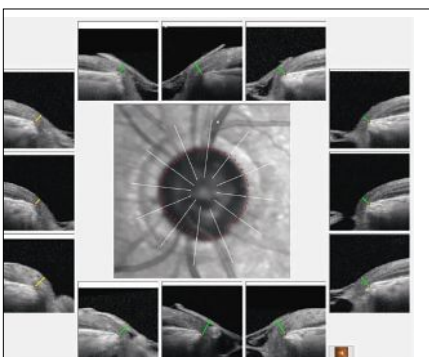


Fig. 2. BMO-MRW overview of the left neuroretinal rim. Note the overall thin neuroretinal rim, but with the remaining rim still adequate for relatively good visual field levels.

About
Dr. Fanelli

Dr. Fanelli is the founder and director of the Cape Fear Eye Institute in Wilmington, NC. He is chairman of the EyeSki Optometric Conference and the CE in Italy/Europe Conference. He is an adjunct faculty member of PCO, Western U. and UAB School of Optometry. He is on advisory boards for Heidelberg Engineering and Glaukos.

evidence of diabetic retinopathy and the peripheral retinal examination was essentially unremarkable.

At the initial visit, I did not have previous records to review, but his complaint of decreased vision in the right eye was likely attributable to field loss associated with the advanced state of glaucoma. I asked him to continue his medication therapy and see me back in about six weeks so that I could better assess his visual needs, as well as to obtain a baseline visual field study. I was also hoping to receive his previous records in the interim so that I would have some comparative data to evaluate.

The patient presented as requested. Threshold visual fields in the right not surprisingly demonstrated a dense superior arcuate scotoma involving fixation, along with a dense inferior arcuate defect with a nasal step, also involving fixation. Field studies of the left demonstrated mild arcuate defects consistent with the level of structural damage seen. Gonioscopic examination of both anterior chamber angles demonstrated wide open angles or moderate trabecular pigmentation, and the presence of two iStent inject MIGS devices bilaterally. Refraction prior to gonioscopy did not improve visual acuities beyond his entering acuities. In *Figures 3 and 4*, we can see the effect of the glaucomatous damage on the macular ganglion cell layer in each eye, with the right suffering significantly more ganglion cell loss than the left.

I discussed with the patient that I did not feel that changing his spectacle Rx would offer any improvement in his vision, as the decreased vision was related to visual loss from glaucoma—not due to a refractive change. He disappointedly said that is essentially what his previous doctor had told him. I tried to be positive and reinforce that although we could not improve his vision, we would do everything possible to preserve his remaining vision. Similar notations were found in his previous provider's records.

Spring the clock ahead to December 2023. Both structurally and function-

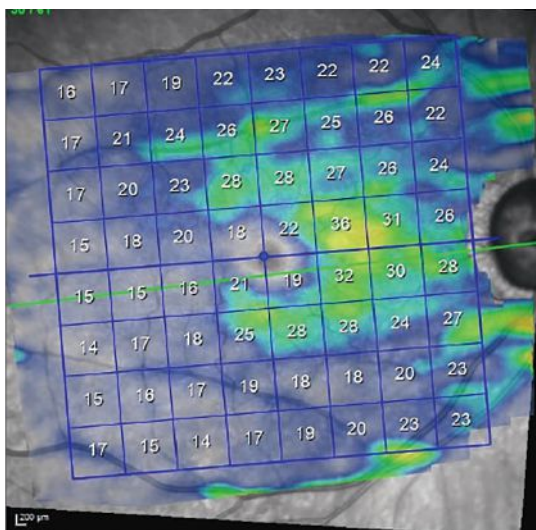


Fig. 3. Ganglion cell thickness OD demonstrates loss of ganglion cells consistent with the visual field loss present in this eye, which involves fixation.

ally, the patient has remained stable OU. But on just about every visit, the patient complained about his vision in the right eye “not being good” and asked if we could make it somewhat better. Each time, trying a different tack, he was told that the vision in the right eye could not substantively be improved. In fact, in that two-year interim he presented urgently two times with complaints of not seeing well with the right eye, with each visit demonstrating the same structural and functional defects.

Earlier last week (as of this writing), he called the office asking for a referral to someone for a “YAG laser procedure” for his right eye. My technician fielded the call, gathering that he had spoken with an acquaintance who told him that after cataract surgery he too had poor vision, which improved after a YAG procedure, so he should get one, too. My tech reminded me he had already undergone a YAG capsulotomy in the right eye, with review of my records revealing no partial fibrosis nor capsular strands on the visual axis. I asked my tech to tell him that he already had that procedure done and that it would not help improve his vision. He called back later that same day and told us he scheduled an appointment himself. After discovering who he had made the appointment with, I spoke with that provider to explain the situation as to

what they would be seeing upon his arrival.

Discussion

While I'm not worried about an unnecessary YAG procedure, these types of events do consume time. As it turns out, the patient was beginning to develop early dementia, as reported by his wife during a different phone conversation, which would certainly explain the repeated discussions about the decreased vision OD, but might also explain his fixation on improving vision in that eye. Be that as it may, what would normally be a straightforward case of glaucoma and normal chair time rather easily expanded into several calls that, in a perfect world, would not have been necessary.

But this is the practice of medicine and optometry, and it crosses all types of ophthalmic conditions from the anterior segment to the retina, optic nerve and other organ systems. Practicing good, ethical care involves clinical knowledge, empathy and communication, but it also involves an efficient office. Situations like these can eat up some of that efficiency.

Interestingly, just before I sat down to pen this column, my good friend Dr. Tom Cheezum sent me a note about a change in CPT coding for 2024. Tom is a coding guru, and when he saw this change he thought of me, as I see complex cases all day, most of which involve a significant amount of coordination of care. Apparently, as of January 1, primary care providers (such as ourselves), when seeing patients with chronic illnesses like glaucoma, can code G2211 as an add-on code to E/M services. As I gather, this code was introduced to help defray the costs associated with coordinating care, such as in cases like this one. While the reimbursement is not large (less than \$20), for those of us seeing 30 or so chronic cases each day, this will help offset the extra time spent on these patients outside of the exam room.

In any event, if you offer good, compassionate care, you will be rewarded in one way or another. Besides, that's our job anyway. ■

PRODUCT REVIEW

New items to improve clinical care and strengthen your practice.



ONLINE FIRST:
GET THE LATEST
PRODUCT NEWS AT
www.reviewofoptometry.com

► DIAGNOSTIC EQUIPMENT

New Imaging Device Combines OCT, UWF Imaging

The fast-moving world of retinal imaging has seen many innovations over the last decade, including ultra-widefield photography, which can capture over 200° of the retina in a single image. OCT angiography has also opened new possibilities in the diagnosis and management of various retinal conditions. For ODs in the US looking to add this advanced tech to their practice, one option that just hit the market is a multimodal imaging system from Nidek called Mirante. The device combines HD scanning laser ophthalmoscopy and OCT with UWF imaging, the company says, and can also capture fundus autofluorescence and use several angiography modes.

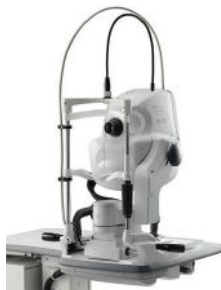The imaging platform also includes a feature unique to the company called “retro mode” that allows clinicians to visualize deeper than the RPE and can help identify and evaluate pathologic changes in the choroid through pseudo-3D images, the company says. Another feature, which Nidek calls the “flex track” algorithm, offers ODs the capability to correct image distortion due to unstable fixation. Other features include dynamic blood flow recording, simultaneous acquisition of FA and ICG images and options for anterior-segment OCT.

All-in-one Device for Ocular Surface Assessment

Developed by M&S Technologies and Bruder Healthcare, the new Bruder Ocular Surface Analyzer performs 10 non-invasive dry eye tests within seconds to minutes. The device can capture the following four dry eye measurements in 15 seconds per eye, according to the companies: auto interferometry for lipid layer thickness, auto tear meniscus height, auto tear breakup time and auto blink evaluation. Six additional tests may be performed in a matter of several minutes, including auto meibography (gland detection), bulbar redness, fluorescein staining, lissamine green staining and pupillometry and white-to-white tests. The device also includes documentation for *Demodex* and blepharitis, the DEQ5 dry eye questionnaire, a lifestyle questionnaire and the ability to compare test results across grading scales, the company press release notes.

New Oculus Headset Touts Faster Testing

Oculus just unveiled its first head-mounted visual field tester, called the Easyfield VR headset, which conducts VF screenings, threshold exams (30-2, 24-2 and 10-2) as well as color vision,



contrast sensitivity and stereo vision screenings. The device is placed over the eyes and secured behind the head. Wireless hand controllers are used by the patient during the exam. Testing can also be conducted in various settings without requiring a dark room. Practitioners can start and monitor the exam process from a Microsoft Surface Pro tablet, no internet required.

Oculus says the device’s continuous eye tracking and fixation monitoring ensures reliable, reproducible results. The company also mentions that audio-guided exams (in English and Spanish) may help patients complete their testing autonomously, reducing demands on technician time.



Reichert to Launch Four Dry Eye Devices in 2024

This year, Reichert plans to bring four new devices for dry eye assessment and treatment to the US via its recent partnership with SBM Sistemi, an Italian medical equipment manufacturer.



The first two—called Idra and OS1000—assist with ocular surface evaluation, the company says. The Idra device is designed to evaluate all three layers of the tear film as well as meibomian glands to help identify the specific type of dry eye disease present and provide personalized treatment recommendations. Next up, the OS1000 is a corneal topographer that also performs pupillometry, white-to-white measurement, NIBUT, meibography and several other tests, Reichert says. It also features keratoconus screening and a contact lens fitting simulation.

The third device to roll out in the US this year—called the DSLC200—is an anterior imaging camera system compatible with a large catalog of slit lamps, its developers say. By adding a dry eye module (named DEM100), Reichert says the system essentially turns your slit lamp into a complete dry eye assessment tool with the following exam tools: interferometry, tear meniscus measurement, blink assessment, standard and 3D meibography, blepharitis evaluation and cylindrical dandruff identification.

Lastly, the Activa device will be an eye mask for MGD and evaporative dry eye that the company says heats and stimulates the meibomian glands through microvibrations. ■

Merchandise Offered

FRAME DISPLAYS & OPTICAL INTERIORS

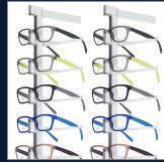FrameDisplays.com is the one-stop-shop for all your optical displays, furniture, and design needs.



Wall Mount



Counter Top



Locking Rods



Trays & Frame Bags



Custom Frame Rods



Optical Cabinets



1-877-274-9300 • www.framedisplays.com

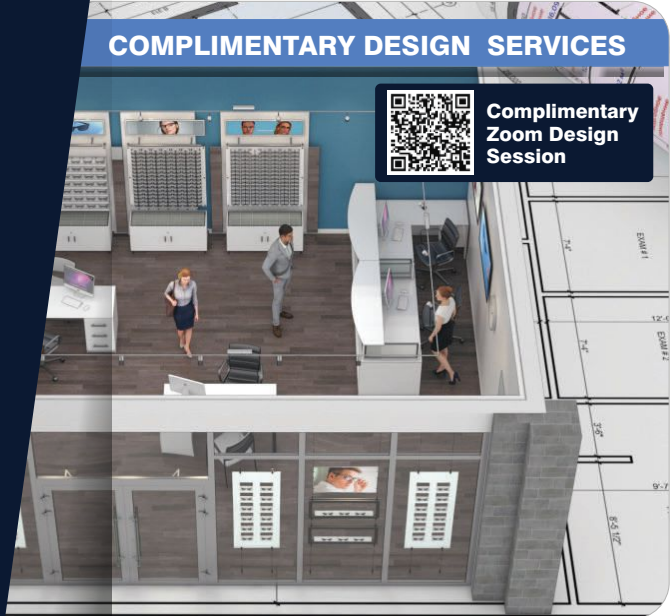

Trusted by more than 40,000 eye care professionals worldwide.

COMPLIMENTARY DESIGN SERVICES



Complimentary Zoom Design Session



0% Financing & Interest for 36 Months*

FREE SHIPPING

\$100+ Orders* *) Excludes Freight Shipments

Code: **FREESHIPROOP**

Practice For Sale



Practice Sales • Appraisals • Consulting
www.PracticeConsultants.com

PRACTICES FOR SALE NATIONWIDE

Visit us on the Web or call us to learn more about our company and the practices we have available.

info@PracticeConsultants.com

925-820-6758

www.PracticeConsultants.com

Targeting Optometrists?

CLASSIFIED ADVERTISING WORKS

- JOB OPENINGS
- CME PROGRAMS
- PRODUCTS & SERVICES
- AND MORE...

Contact us today for classified advertising:

Toll free: **888-498-1460**

E-mail: sales@kerhgroup.com

Do you have CE Programs?

CONTACT US TODAY FOR CLASSIFIED ADVERTISING

Toll free: 888-498-1460

E-mail:

sales@kerhgroup.com



Spot On

Can you recognize the clinical features of this pigmented lesion?

BY RAMI ABOUMOURAD, OD, AND JULIA CAMPBELL, OD
MIAMI, FL

A 74-year-old Hispanic male was referred for evaluation of a “black spot” OS. He denied any pain, redness, photophobia, photopsias or floaters. His medical history included diabetes mellitus, arthritis, kidney disease and heart arrhythmias, all of which were being treated medically. His ocular history included bilateral cataract surgery.

Entering VA was 20/40 OD and 20/60 OS with no pinhole improvement. IOPs were 12mm Hg OU. Pupils were equally round and reactive without a relative afferent pupillary defect, and confrontation visual fields were full OU. Anterior segment exam showed pseudophakia OU with mild posterior capsular opacification OD and an open posterior capsule OS; there was no evidence of anterior segment neovascularization.

Take the Retina Quiz

1. Which of the following is false regarding Figures 1 and 2?

- B-scan shows a hyperechoic and mildly elevated optic nerve head lesion.
- B-scan shows low internal reflectivity.
- OCT shows superficial hyperreflective opacities within the optic nerve head.
- There is a darkly and evenly pigmented lesion partially obscuring the optic nerve.

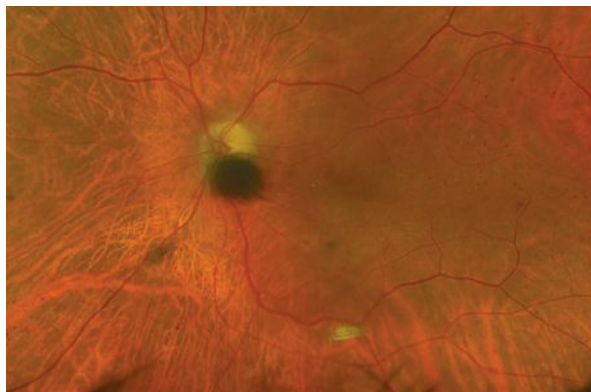


Fig. 1. Optos fundus photograph of the left eye.

2. What is the most likely diagnosis for the pigmented lesion of the left eye?

- Choroidal nevus.
- Juxtapapillary choroidal melanoma.
- Optic nerve melanocytoma.
- Primary optic nerve melanoma.

3. How would you describe the B-scan (Figure 2)?

- Hyperechoic, mildly elevated optic nerve head lesion with high internal reflectivity.
- Hypoechoic, mildly elevated optic nerve head lesion with high internal reflectivity.
- Hyperechoic, mildly elevated optic nerve head lesion with low internal reflectivity.
- Hypoechoic, mildly elevated optic nerve head lesion with low internal reflectivity.

4. What is the general prognosis for this condition?

- Excellent, no potential for malignant transformation.
- Good, however 1% to 2% chance for malignant transformation.

- Guarded, 50% chance for malignant transformation.
- Poor, malignant lesion with high risk of metastasis.

5. What is the appropriate management?

- Urgent referral for fine needle aspiration biopsy of lesion.
- Genetic testing to rule out an inherited retinal dystrophy.
- Observation with annual fundus exams and serial fundus photography.
- All of the above are necessary.

Diagnosis

Fundus exam revealed a posterior vitreous detachment OU, diabetic retinopathy OU and a hyperpigmented melanocytic lesion contiguous with the inferior optic nerve head OS (Figure 1). B-scan ultrasound showed this was an elevated, hyperechoic lesion of the optic nerve head OS that was measured to have an apical thickness of 1.05mm and greatest basal diameter of 2.85mm (Figure 2). OCT through the lesion showed a shallow dome-shaped mass with superficial hyperreflective opacities and underlying shadowing with temporal epiretinal membrane (Figure 3). A clinical diagnosis of optic nerve melanocytoma was based on these findings.

Discussion

Optic nerve melanocytoma is a benign neoplasm of the optic nerve head that was first described in 1933.¹ The term *melanocytoma* was later coined in 1965 based upon histopathologic similarities to the melanocytic lesions found in ocular melanocytosis.¹ Melanocytoma is actually a broad term to describe any lesion comprised of melanocytes; a more accurate descriptor would have been *hyperpigmented magnocellular nevus of the optic disc*, though this never gained enough traction to supplant the simpler term melanocytoma.¹

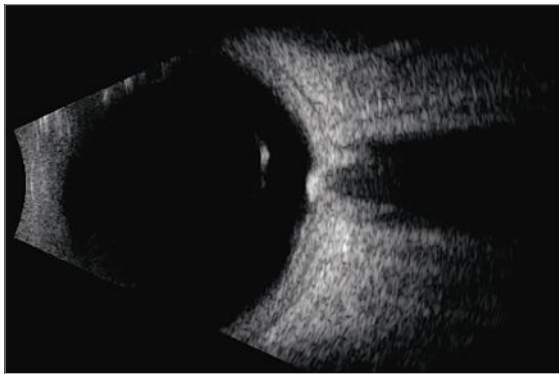

Fig. 2. Horizontal axial B-scan of the left globe.

Melanocytomas appear to have a slight female predilection (63%) with no clear racial predilection and average age of 50 years at time of initial diagnosis.^{1,2} Exact pathophysiology is unknown, and it was once thought to be a congenital lesion; however, it is interesting to note that melanocytomas are rarely seen in children and there are numerous reports of acquired lesions in patients with documented fundus photography before and after the occurrence.¹ This has led to speculation that melanocytomas may initially arise as amelanotic lesions that later acquire pigment, though further studies are needed to better understand this process.^{1,2}

The differential diagnosis for melanocytoma includes choroidal nevus, juxtapapillary uveal melanoma, hyperplastic retinal pigment epithelium (RPE), combined hamartoma of the retina and RPE and, more rarely, primary optic nerve melanoma or metastatic melanoma to the optic nerve.^{1,3} Melanocytoma is a largely clinical diagnosis based on the characteristic presentation of a unilateral intensely pigmented lesion involving all or part of the optic nerve head.¹ Further-

more, lesions may be isolated to the optic nerve head or extend into the adjacent choroid or neurosensory retina.¹ That being said, melanocytomas can be indistinguishable from melanoma in certain clinical contexts and a high clinical suspicion must be maintained.^{1,3,4}

Ancillary testing such as fundus photography can be useful to monitor evolution of the lesion over time.^{1,3}

Ultrasonography is of little diagnostic value, but notably depicts mildly elevated (28%) or dome-shaped (62%) lesions with medium-high internal reflectivity (85%) and are largely avascular (89%).³ These features are contrasted with melanomas, which often depict lower echogenicity and greater vascularity.^{3,5} Fluorescein angiography can delineate tumor borders (hypofluorescence) when difficult to discern clinically.^{1,5} While there are no pathognomonic features of melanocytoma on OCT, the lesions tend to have a hyperreflective superficial border, superficial hyperreflective opacities and dense shadowing.^{1,5,6} Despite its limitations, OCT can still be a useful tool to monitor for exudation and peripapillary extension.^{1,5-7}

Prognosis

Fortunately, the prognosis is generally excellent, as many (93%) retain undisturbed VA of better than 20/40 with low risk of malignant transformation.^{1,4} Furthermore, the presence of a relative afferent pupillary defect has been seen in 7% to 30% of patients and seems to be associated with VA worse than 20/50.^{1,8}

The majority of patients have some degree of visual field deficit, most commonly manifesting as enlargement of the blind spot.^{1,2}

Despite the benign nature of these presentations, serial fundus photography has shown subtle enlargement in 10% to 15% of melanocytomas when observed over the course of years.^{1,5,8} In a review of 116 eyes, tumor enlargement was demonstrated in 11% to 14% of patients at five years, 32% at 10 years and 38% at 20 years; an initial thickness of >1.5mm at diagnosis is a predictive risk factor for growth.^{1,2,8} Although growth often represents the benign natural history of the lesion, it can alternatively represent tumor necrosis, which may produce a secondary optic neuropathy with severe vision loss.¹

In conclusion, optic nerve melanocytomas are benign lesions that typically have no visual consequences. Occasionally, these lesions exhibit growth, produce retinal vein occlusions and rarely can progress to malignancy. Therefore, careful monitoring with annual fundus exam and serial photography are indicated monitor for transformation. ■

- Shields JA, Demirci H, Mashayekhi A, et al. Melanocytoma of the optic disc: a review. *Indian J Ophthalmol.* 2019;67(12):1949-58.
- Shields JA, Demirci H, Mashayekhi A, Shields CL. Melanocytoma of optic disc in 115 cases: the 2004 Samuel Johnson Memorial Lecture, part 1. *Ophthalmology.* 2004;111(9):1739-46.
- Gologorsky D, Scheffler AC, Ehlihs FJ, et al. Clinical imaging and high-resolution ultrasonography in melanocytoma management. *Clin Ophthalmol.* 2010;4:855-9.
- Mohmad Z, Kah TA, Yong KC, et al. Melanocytoma of the optic nerve head - a diagnostic dilemma. *Clin Pract.* 2011;1(3):e60.
- Zhang P, Hui YN, Xu WQ, et al. Infrared autofluorescence, short-wave autofluorescence and spectral-domain OCT of optic disk melanocytomas. *Int J Ophthalmol.* 2016;9(5):713-6.
- Raval V, Reddy R, Kaliki S, et al. Optic nerve head melanocytoma: Optical coherence tomography/angiography features. *Indian J Ophthalmol.* 2021;69(2):332-6.
- Lee E, Sanjay S. Optic disc melanocytoma report of five patients from Singapore with a review of the literature. *Asia Pac J Ophthalmol (Phila).* 2015;4(5):273-8.
- Lee CS, Bae JH, Jeon IH, et al. Melanocytoma of the optic disc in the Korean population. *Retina.* 2010;30(10):1714-20.

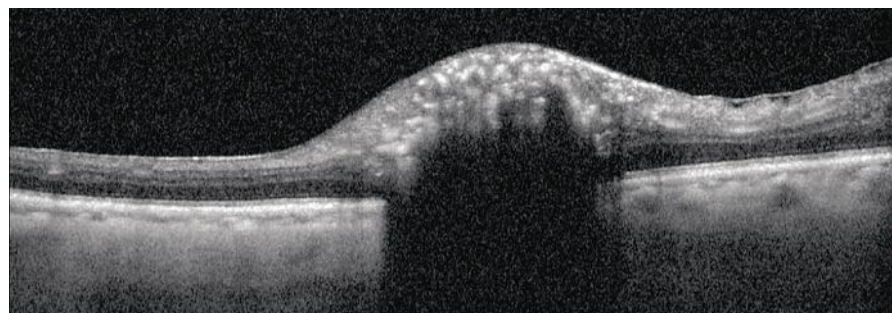

Fig. 3. Heidelberg Spectralis OCT of the left optic nerve head.

ABOUT THE CO-AUTHOR



Dr. Campbell graduated from the University of Houston College of Optometry and is completing an ocular disease residency at Bascom Palmer Eye Institute.



EDITED BY JOSEPH P. SHOVLIN, OD

CORNEA AND CONTACT LENS Q+A

Fungal Frenzy

Certain species have more recently been studied for their responsiveness to nonconventional forms of therapies.

Q I have a patient with a severe fungal infection following overnight contact lens wear. The cornea specialist seeing our patient mentioned potentially including newer treatment options of hypochlorous acid, photodynamic therapy or testing to look for mycotoxins. How would these work differently from typical treatment?

A Infectious keratitis is the leading cause of unilateral blindness worldwide, and fungal keratitis presents as a challenge in terms of treatment, often necessitating a therapeutic corneal transplant (TPKP) when conventional medical treatment falls short. “The Bascom Palmer Eye Institute (BPEI) regularly handles cases from across south Florida and the Caribbean, constituting approximately 28% of our annual microbiology isolates,” Salomon Merikansky, MD, part of BPEI, explains.

“*Fusarium* species top the list as the most prevalent causative filamentous fungi, followed by other species like *Aspergillus* and *Curvularia*. Among yeast, *Candida* species is the most prevalent,” he adds.

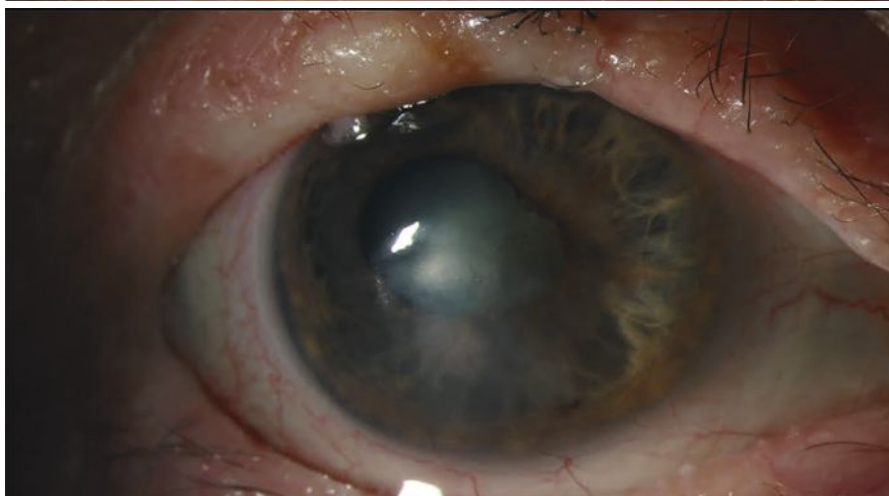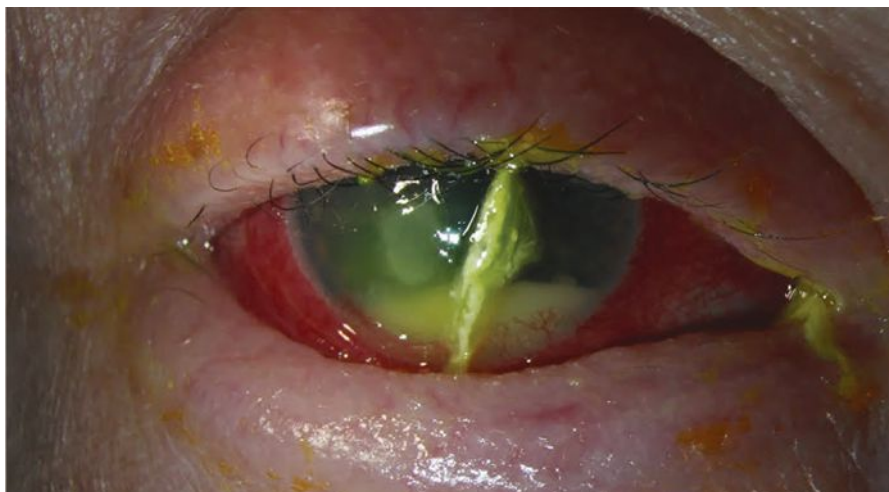
Typical Treatment

Our current therapy guidelines for filamentous fungal keratitis are based on the Mycotic Ulcer Treatment Trial (MUTT), a multicenter, randomized, double-masked study funded by the National Eye Institute and conducted in Madurai, India. MUTT demonstrated that topical natamycin 5% was more effective than topical voriconazole 1% in treating *Fusarium*

infections. For yeast infections attributed to *Candida* species, we use topical voriconazole 1% or amphotericin B 0.15%. “It’s important to mention,” Dr. Merikansky relays, “that we strictly avoid the use of topical and/or systemic steroids, instead managing inflamma-

tion with topical cyclosporine or topical tacrolimus.”

In cases of advanced corneal fungal disease, the vision and/or globe saving treatment continues to be surgical intervention, such as therapeutic penetrating keratoplasty (PK). MUTT showed that patients with clinical signs of hypopyon, infiltrate larger than 6mm or those involving more than two-thirds of the corneal thickness were most likely to have failed medical therapy and require a PK. Dr. Merikansky notes that “since many of



Slit-lamp photograph of a patient with bilateral *Curvularia* keratitis (top), who was successfully treated with medical therapy and RB-PDAT (bottom).

About Dr. Shovlin

Dr. Shovlin, a senior optometrist at Northeastern Eye Institute in Scranton, PA, is a fellow and past president of the American Academy of Optometry. He consults for Kala, Aerie, AbbVie, Novartis, Hubble and Bausch + Lomb and is on the medical advisory panel for Lentechs.

the patients that come to our ER have advanced disease, surgical intervention is often required. We have been looking into alternative treatments that try to delay or avoid the need of PK.”

New Options?

Over the past decade, the BPEI has explored rose bengal photodynamic antimicrobial therapy (RB-PDAT) as a potentially emerging treatment for infectious keratitis. This innovative approach uses a photosensitizer (rose bengal) activated by green light to generate singlet oxygen. The method has shown promising results, particularly in early-to-moderate fungal keratitis cases and those caused by *Fusarium* species. The ongoing Rose Bengal Electromagnetic Activation with Green Light for Infection Reduction study (REAGIR) is a double-masked, randomized clinical trial currently underway and aims to provide critical insights into the future viability of RB-PDAT for fungal keratitis treatment.

“While hypochlorous acid has shown efficacy in treating biofilms on contact lens cases, its direct application as a therapeutic agent remains unexplored in our practice,” Dr. Merikansky says. “However, we do know another key molecule that plays an important role in the pathogenesis of fungal keratitis, that being the work of mycotoxins. They play a significant role in the inflammatory response created by the pathogen and the host’s immune response.”

He adds that “our microbiology laboratory recently published a paper identifying various mycotoxins, where *Fumonisin B* displayed being a key secondary metabolite of *Fusarium* species. These toxins contribute to cellular toxicity, potentially leading to keratolysis and perforation.” Understanding the pathophysiology of mycotoxins is crucial, and future research should focus on developing therapies that inhibit mycotoxins to minimize their harmful effects and control the inflammatory response without resorting to steroids.

Where to Start?

These cases are rare, but Dr. Merikansky has a few suggestions for dealing with one if you encounter it. “Prevention and early detection should be our first line of defense. Every eyecare provider should try to excel in educating patients on the correct usage of contact lenses and the potential complications associated with improper use.”

He continues that, in the management of corneal abrasions and/or early keratitis, eyecare providers should be able to identify clinical signs of a possible fungal infection. “For this reason, a high level of suspicion should be made on cases that do not respond to topical broad-spectrum antimicrobial treatments. The use of steroids should always be decided upon judiciously and should only be administered when backed up by microbiological data,” he concludes. ■

Dr. Merikansky is a research fellow of Guillermo Amescua, MD, who supervised the content for this column.

ADVERTISER INDEX

This index is published as a convenience and not as part of the advertising contract. Every care will be taken to index correctly. No allowance will be made for errors due to spelling, incorrect page number, or failure to insert.

Allergan Refresh.....15	Eyefficient.....55	Notal Vision.....39
www.allergan.com	800-417-8136 https://www.eyefficient.com/	1 855 600-3112 https://notalvision.com/
Apellis.....53	Glaukos.....13	Olleyes.....31
www.apellis.com	800 452-8667 www.glaukos.com	855 655-3937 www.olleyes.com info@olleyes.com
Bausch + Lomb.....Covertip	Harrow.....17, 18	Oyster Point.....34, 35
866 246-8245 https://ecp.bauschcontactlenses.com/	https://www.harrow.com/	https://oysterpointrx.com/
Bruder Healthcare Company.....43	Iveric Bio.....26-28	Tarsus.....7, 8
888 827-8337 www.bruder.com eyes@bruder.com	www.ivericbio.com	https://tarsusrx.com
Dompe.....Cover 2, 3	LKC.....11	Thea Pharma.....21
866-246-8245 www.oxervate.com/HCP	301 840-1992 www.lkc.com/	781 832-3664 https://www.ivizia.com/
CooperVision.....Cover 3	M&S Technologies.....61	Topcon.....65
800-341-2020 https://coopervision.com/	847 763-0500 www.mstech-eyes.com/vr-headset	201 599-5100 www.topconhealthcare.com
	Meivertor.....23	X-Cel Specialty.....Cover 4, 31
	Meivertor.com	800 241-9312 www.xcelspecialtycontacts.com/
	Nextgen.....51	
	www.nextgen.com/1-ophth	



Peaked Interest

A patient expressed concern about a pupil abnormality. What's the appropriate workup? How should you triage the case?

A 77-year-old female patient presented to the office emergently with a chief complaint of pupil distortion. She was admitted to the hospital after a fall, had a small subconjunctival hemorrhage inferiorly. While looking at the eye more closely, she noticed her pupil looked funny. She explained she had not noticed this before and denied trauma to the eye. She had no previous medical or ocular history. She was taking only an oral antibiotic prescribed by her doctor and denied allergies of any kind.

Clinical Findings

Her best-corrected entering visual acuities were 20/20 OD and 20/20 OS at distance and near. Her extraocular motilities were normal and her confrontation fields were full OU. The pertinent external and pupillary observations are demonstrated in the photograph. There was no afferent defect. Her biomicroscopic examination was normal and Goldmann applanation tonometry was measured at 17mm Hg in both eyes. Dilated fundus examination revealed no significant posterior pole or peripheral retina findings. The nerves were

distinct with cup-to-disc ratios of 0.3/0.35 OD and OS.

Additional Testing

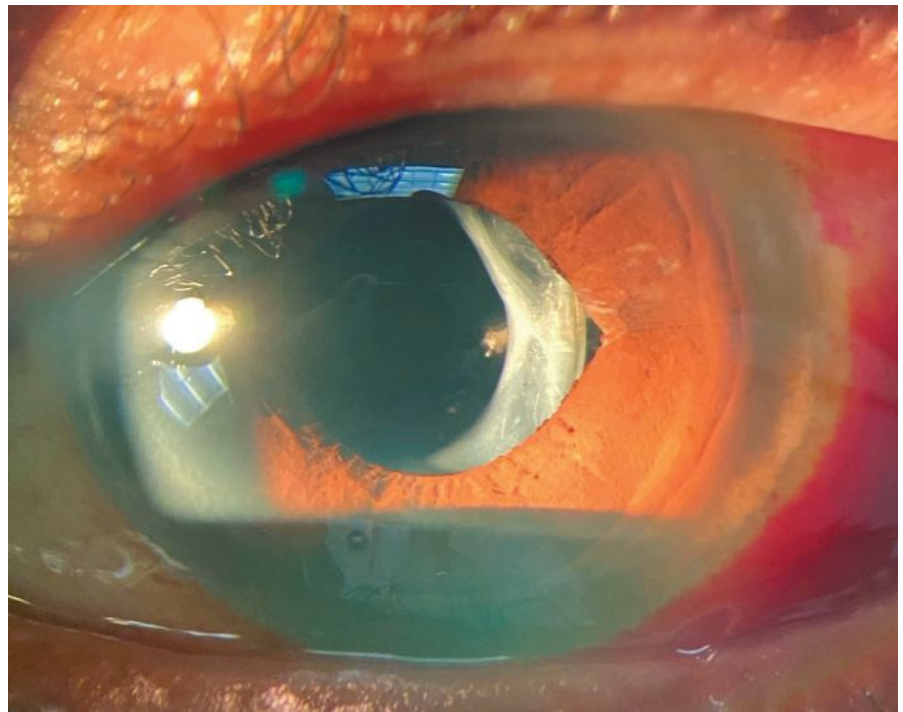
The clinician measured the pupils in both bright and dim illumination to rule out pathologic anisocoria. Inspecting old photographs was also

completed to determine whether or not the issue was in fact new. The eye was dilated to confirm no posterior segment pathology.

Your Diagnosis

What would be your diagnosis in this case based on the findings presented? What's the likely prognosis? Which interventions would you recommend? To find out, read the online version of this article at www.reviewofoptometry.com. ■

Dr. Gurwood thanks Colin Kane, OD, for contributing this case.



This is the patient's presentation. What does it tell you about the potential etiology?

About Dr. Gurwood

Dr. Gurwood is a professor of clinical sciences at The Eye Institute of the Pennsylvania College of Optometry at Salus University. He is a co-chief of Primary Care Suite 3. He is attending medical staff in the department of ophthalmology at Albert Einstein Medical Center, Philadelphia. He has no financial interests to disclose.

NEXT MONTH IN THE MAG

In March, we present our annual issue devoted to ophthalmic pharmaceuticals. Articles will include:

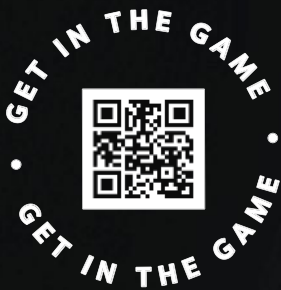- The "New Drug" Deluge: Making Sense of the Latest Meds
- A Results-oriented Approach to Oral Med Prescribing

Also in this issue:


- Ease Your Way into Myopia Management
- Optometric Scope of Practice State by State: A Comprehensive Look at the New Landscape
- OCT Beyond the Basics: Unlock the Power of This Essential Tool

SPEED. EASE. RANGE.

MyDay® daily disposable multifocal with CooperVision Binocular Progressive System® is a game-changer.¹



Micaela Crowley, O.D.
Lexington, MA



MyDay® multifocal leverages the latest innovation in multifocal contact lens technology with **CooperVision Binocular Progressive System®** to optimize vision for all levels of presbyopia and visual acuity at all distances.² With its speed and ease of fit using OptiExpert™, you can **successfully fit 98% of the time** with two pairs or fewer.^{3,4} Plus, with the **incredible comfort of Aquaform® Technology** that patients' eyes deserve⁵, MyDay® multifocal has changed the game.

If you haven't fit MyDay® multifocal, what are you waiting for? Get in the game.

1. CVI data on file as of May 2023 vs. leading manufacturers. 2. CVI data on file 2020. Prospective, double-masked, bilateral, 1-week dispensing study with MyDay daily disposable multifocal; n=104 habitual MFCL wearers. 3. CVI data on file 2020. Prospective, double-masked, bilateral, one-week dispensing study UK with MyDay® multifocal; n=104 habitual multifocal contact lens wearers. 4. CVI data on file 2021. Prospective, subject-masked, randomized, bilateral, two-week dispensing study at 5 US sites with MyDay® multifocal; n=58 habitual multifocal contact lens wearers. 5. CVI Data on file 2022. Based on global product sales and internal estimates of products using Aquaform® Technology over 12 months in 2022. ©2023 CooperVision 14777ROO 12/23



Changing SIGHT Overnight.

Overnight Orthokeratology

1. NCLE certified consultation experts to guide you through the entire fitting process
2. Highly adjustable parameters with an online lens design calculator
3. Dynamic Edge Profile™ delivers remarkable comfort
4. Diameter & optic zone options allow the doctor to customize the lens to the patient



Scan to learn more about REMLens® and get certified today.



SECO BOOTH #2224



800.241.9312
xcelspecialtycontacts.com/remlens

Vision Shaping Treatment VST™

MADE EXCLUSIVELY WITH BOSTON® EQUALENS® II LENS MATERIALS